

Lectures on operative dental surgery and therapeutics.

Contributors

Thompson, W. Finley.
University of Toronto

Publication/Creation

London : John Bale & Sons, 1881.

Persistent URL

<https://wellcomecollection.org/works/h6cmncxp>

License and attribution


This material has been provided by This material has been provided by the University of Toronto, Harry A Abbott Dentistry Library, through the Medical Heritage Library. The original may be consulted at the Harry A Abbott Dentistry Library, University of Toronto. where the originals may be consulted.

This work has been identified as being free of known restrictions under copyright law, including all related and neighbouring rights and is being made available under the Creative Commons, Public Domain Mark.

You can copy, modify, distribute and perform the work, even for commercial purposes, without asking permission.




Wellcome Collection
183 Euston Road
London NW1 2BE UK
T +44 (0)20 7611 8722
E library@wellcomecollection.org
<https://wellcomecollection.org>





22

ROYAL COLLEGE OF
17
DENTAL SURGEONS OF ONTARIO.



W. G. Beebe
London, Eng. 21 Aug 1881

LECTURES
ON
OPERATIVE
DENTAL SURGERY
AND
Therapeutics.

By W. FINLEY THOMPSON, M.D., D.D.S.

London :

PUBLISHED BY
JOHN BALE & SONS, 87-89, GREAT TITCHFIELD STREET, W.

—
1881.

These twelve Lectures, when revised, are to form part of the latter section of a work now in preparation on Pathological Dental Anatomy and Operative Dental Surgery, by W. FINLEY THOMPSON, M.D., D.D.S., and THOMAS GADDES, L.D.S.Eng: and Edin.

41, *Brook Street, W.*

June, 1881.

TO

MY FRIEND AND FORMER PARTNER,

DR. J. H. HATCH,


THESE LECTURES ARE DEDICATED

AS A FEEBLE BUT

SINCERE TRIBUTE

TO HIS

SOCIAL AND PROFESSIONAL WORTH.




LECTURES.

	PAGE
LECTURE I.—Introductory Remarks. Histology of the Teeth. The Pulp and its resistance to disease. Pathology of the Teeth (preliminary)	1-16
LECTURE II.—Definition of Operative Dentistry, and the head- ings under which its divisions may come. Classification of Operations. Progress of Caries. Exploring Instruments. Treatment of Gums. Wedging. Rubber Dam. Clamps. Specially devised Clamps. Ligatures. Preparation of Cavities. Instruments for preparing Cavities	17-32
LECTURE III.—The Dental Engine. Mallets—varieties of. The Hand Mallet, method of using. Pluggers; the Author's pattern. Hand Pluggers. Examinations of the Mouth. Material for filling Children's Teeth. Management of Children. Six year old Molar. Deficiency of Bone pro- ducing elements in ordinary Flour	33-48
LECTURE IV.—The Oral Cavity. Alimentation. Function of the Teeth. Four stages of Decay. Necessity for a precise Nomenclature. Division of the Teeth into Regions. Pro- posed Nomenclature. The Dentes Sapiientiæ. Positions of Disease in the Teeth. Erosion and Abrasion	49-64
LECTURE V. To Students. Erosion (continued). Spasmodic action of the Oral and Labial Muscles. The Saliva Ejector. Reniform Clamp, difficulties to be contended with in its use. Digital compression	65-80

- LECTURE VI.—Preparation of Cavities (continued). Further consideration of the forms of Caries. Gold. Cohesiveness. Anomalies in gold ; its occasional intractability. Annealing. The introduction of gold into Cavities. The Operating Room ... 81-96
- LECTURE VII.—Replantation of Teeth. Hunter—his Experiments. Constitutional Diseases and their effects on Replantation. Necessity for Drainage. Treatment of Socket. Antiseptic treatment of tooth. Neuralgia. Interesting cases. *Modus operandi* of Capping and Filling the Extracted Tooth. Gold Pin for Tube. Remarks ... 97-120
- LECTURE VIII.—Caries ; its positions (continued). Second stage of Disease in the Incisors. Filling same with Gold. The Masseter and Buccinator Muscles. Third stage of Disease. Accidental Penetration of the Pulp. Capping of Pulp. Decay at or underneath the Gum. The fourth stage of Caries. Complicated cases. Treatment ... 121-136
- LECTURE IX.—Irritation of Peridental Membrane by Gases in the Pulp Chamber. Instruments for filling Pulp Canals. Means adopted for protecting weak Enamel. Grooves, Anchorages, Screws, and attachments, various examples, fourth stage. Use of Splint in delicate operations. The Mortality of Infancy. Statistics of Disease in first Molar. Interposition of teeth formed of Gold, with Porcelain face... 137-152
- LECTURE X.—Interposed Teeth, continued. When contra-indicated. Illustrated examples of attachments. Odontotripsis, Chemical and Mechanical. Traumatic Abrasion. Restorations. Full Contour and its importance... 153-168
- LECTURE XI.—The maxillæ. Temperaments. The teeth commonly associated with different temperaments. Tuberculous disease and caries. Diseases in children which may be attributed to the teeth. Otitis occasioned by the teeth. Pregnancy and its influence on the teeth of the mother. "Diffused" nervous action. Odontalgia. Pericementitis. Trismus ... 169-184

LECTURE XII. — Facial Neuralgia. Endostosis — Exostosis.	
Examples of Endostosis and Exostosis. Anchylosis or	
Gemination of Teeth. Hæmorrhage in general. The	
Antrum of Highmore—Salivary Calculus and its asso-	
ciation with Ranula. Pyorrhœa Alveolaris. Premature	
Extraction of a Deciduous Tooth. Remarks 185-200




ILLUSTRATIONS.

FIG.	PAGE
1. The Enamel, its hexagonal columns	6
2. Formation of Dentine and Cementum (after Owen)	8
3. Exploring Instrument	21
4. " "	21
5. Wedging; pellet of cotton, ligated	24
6. Case requiring specially devised Clamp	26
7. Specially devised Clamp and Rubber Dam <i>in situ</i>	27
8. Caries, cervico-buccal and proximate	29
9. Method of holding the Hand Mallet	38
10. Plugging Instruments, the Author's pattern	39
11. Hand Pluggers	41
12. Decay in the ante- and post-medial positions	54
13. " showing the confluence of both centres of decay	54
14. Proposed new nomenclature—molars	56
15. " " incisors	57
16. Decay—illustrating different Stages	58
17. Caries in the Incisors (Lingual aspect)	62
18. " " (Labial aspect)	62
19. Lower Molar (abrasion)	63
20. Gold blocked in to resist abrasion...	63
21. Erosion extending below the Gum	63
22. Prepared Cavity, with gum dissected back	64
23. Erosion	69
24. " "	69
25. Perforations to be made in the Rubber Dam	72
26. Linear extension of Rubber Dam	74
27. Inefficiency of reniform clamp in buccal decay	75
28. Rubber applied with digital compression...	77
29. " with gold reef established	79
29A. Crown Cavities, circular and interstitial	85

FIG.		PAGE
30.	Replantation, tubing and filling of upper molar ...	106
31.	„ upper molar with abscess sac ...	109
32.	„ tubing and filling inferior molar ..	111
33.	„ vice, with wooden clamps, tooth in position for tubing ...	115
34.	„ tube, cap and pin ...	116
35.	„ steel die plate and punches... ..	117
36.	Operations—proximate and lingual aspect of Incisors ...	123
37.	Canine Tooth, extensive but superficial caries ...	124
38.	Wisdom Tooth (filled) ...	124
39.	Fillings in Bicuspids, second and third stages ...	127
40.	Exposure of Pulp, Crown, Septum, and Anchorages ...	128
41.	„ Split Section „ ...	129
42.	„ Perspective View „ (antero-posterior)	130
43.	„ Transverse Split Section, Lower Molar ...	133
44.	Fourth Stage „ „ „ ...	134
45.	The same Tooth, Cavity prepared ...	135
46.	„ Plan of Cavity ...	135
48.	Cavity, prepared in superior Molar ...	139
49.	Split section of lower Molar, bevelled enamel and headed screws	140
50.	Longitudinal section of ditto ...	140
51.	Bicuspids, with step and position of screws ...	142
52.	Incisor, with split cylinder of gold for anchorage ...	144
53.	Split Cylinder with its extensions... ..	144
54.	Canine with Cavities in Meso and disto-lingual Regions ...	146
55.	Central Incisor „ „ ...	146
56.	Incisor—the labial wall of the enamel only remaining ...	147
57.	The same restored and the enamel framed in with gold... ..	147
58.	Interposition—Cavities prepared in Molar and Bicuspid teeth, buccal aspect	150
59.	Interposition—the cavities in the adjacent teeth, lingual view	151
60.	„ Floors of prepared Cavities ...	151
61.	„ Cavities filled, and interposed tooth ...	152
60A.	Interposed Tooth—diagram of extension bars ...	154
61A.	„ „ „ „ ...	154
62.	Superior Centrals, restored with gold, (labial) ...	156
63.	The same (lingual)	156
64.	Complicated case of Abrasion ...	159
65.	„ „ Restoration, right side ...	161

FIG.		PAGE
66.	Complicated split section of tooth and restoration ...	162
67.	Hiatus on left, consequent upon restoration of right side ...	164
68.	Restoration of the left side ...	165
69.	Inferior Molar, with cystic attachment ...	182
70.	Endostosis, enlarged section showing Nodules of Secondary Dentine ...	186
71.	Exostosis, diffuse ...	187
72.	„ Example of ...	187
73.	„ „ ...	187
74.	„ with Alveolar Fracture, buccal view ...	188
75.	„ „ lingual view ...	188
76.	Difficulties of Extraction. Distorted roots, upper molar ...	189
77.	„ „ Bicuspid, with exostosis ...	189
78.	Exostosis, Example of ...	190
79.	„ „ ...	190
80.	„ „ ...	190
81.	Anchylosis and Gemination of Teeth ...	191
82.	„ „ „ ...	191
83.	Salivary Calculus ...	196
84.	„ on inferior incisor ...	197
85.	Deciduous Molar and Permanent Bicuspid — accident in Extraction ...	198



LECTURE I.

Delivered at the National Dental College, London, October 8th, 1879.

GENTLEMEN,—My remarks this evening will be introductory to a proposed series of Lectures on Operative Dental Surgery and Therapeutics—a specialty which, until a comparatively recent period, has failed to excite attention commensurate with its importance.

From the very dawn of civilization, Dentistry must have existed in a more or less primitive state; yet the records preserved from ancient literature are scanty and incomplete. This, perhaps, is not to be wondered at, as a preference for rhetorical disquisition, rather than a description of natural facts, seems to have been the tendency.

It is a wide spread and generally believed theory that the Egyptians were the first to engage in the practice of filling teeth. This, however, must be considered in a purely speculative light, as the evidence does not justify such a belief; on the contrary, it is a well authenticated fact that their artistic dental operations were of a superficial character, mere gilding, which was intended only for ornamental purposes. Be that as it may, if dentistry were practised in Egypt, it must have been under the direction and limitation of the priesthood, who jealously conserved to themselves and

mystified whatever was then known in science and art. The instruction of the student was accompanied with ceremony and restrictions, and we may imagine the neophyte brought face to face with some of what are to us the simplest elementary problems, under circumstances calculated to strike awe into his mind.

Doubtless this conservatism among the ancient Egyptians, and the rigour with which each handicraftsman was kept in his place—any infraction of rules being liable to punishment with death—produced the exquisite finish apparent in Egyptian art; but, at the same time, it has probably prevented the name of any early dentist being handed down to us. History, then, is scanty in its records of very early dentistry—coeval, say, with the hewing of Cleopatra's needle.

Before parting with the Egyptians, who are supposed to have been the first people having the practice of dentistry established among them, let us acknowledge the debt which the world owes to them. Nearly every art, nearly every science, was to some extent prefigured; and we may readily imagine, even in the absence of direct proof, that our specialty did receive some attention. Mechanical dentistry is supposed to have been practised upwards of two thousand years ago; but to attempt to fix, even approximately, the period of the introduction of the art of *filling teeth*, would land us in an investigation speedily bounded by the mists and clouds of the past.

History claims the honour for Celsus (100 B.C.). He, however, does not seem to have filled teeth with a view of saving them, but simply for the purpose of preventing their being broken under the forceps.

I may here remark that Erasistratus, "who is recorded as a dental operator (300 B.C.) deposited in the temple of the Delphian Apollo, a leaden odontogogue, which we

OTHOOT

should call a tooth-drawer (forceps), to prove that (only) those teeth ought to be removed which are loose or relaxed, and for which a leaden instrument will suffice." This conservative practice shows how reluctant the ancients were in permitting the operator to touch any tooth firmly attached in its socket, no matter what the condition of disease.


Dentistry is mentioned by various other writers whose names have figured conspicuously at different periods. They lived at epochs more or less remote, but the perspective of the lapse of centuries causes them to gather up into a galaxy of intellect, projected like stars on the dark background of the past. The interval between their time and the present has not been entirely unbroken; but the progress of dentistry has been slow and tentative until of late years, during which it has steadily increased in favour with the public, mainly through the efforts of conscientious men, who, breaking the bonds of empiricism, laid the foundation of an enlightened practice, which has placed dentistry in an honourable and self-sustaining position. Its rapid advancement may in coming years enable you to regard even the present progress as slow, compared with things not yet revealed. As your profession advances, so must you go with it. The indolent can no longer ride on the shoulders of the industrious, and over confidence, accompanied with plausible theories, will only serve a temporary purpose. No matter at what period of life, the progressive man is always a student; and as such he must be thorough, conscientious, and just. Thorough, that he may never feel the self-condemnation which always follows a hastily-performed or poorly-executed task; conscientious, that he may study the method best adapted to insure the greatest amount of good; and just to others, that he may be just to him-

self. "If, where all are important, we must choose what particular qualification may be ignored, manipulative skill must be the last to be slighted." "Any preparation which fails to develop a high order of mechanical dexterity, fails in that which is the first requisite of the dentist, as indeed it is that of the surgeon at large."

My remembrance of failures in early practice, and the loss of confidence a poor operation now and then occasioned, makes me call your attention to the different, I might add, in many cases, indifferent manner in which our calling is conducted; and as we hastily scan the horizon of our professional sky, we must confess the need of reformation: but where shall this commence, unless within the College walls, for it is there professional character is moulded?

To hope for any change in those already established in practice is useless; for their positions are so pronounced, and the groove in which their daily affairs are managed so deep, that it is difficult to make a change. Once established, there is no turning round; for it would involve temporary embarrassment at least, and this too serious to be faced by the dentist of ordinary moral courage; so they readily excuse themselves by wheeling into line that ever-convenient piece of artillery—"extenuating circumstances."

Character must be established in the student. To dream of being eminent will but little serve the purpose. Vain reverie may erect ærial castles; but, at the call for aid, these vapoury structures will fade away, or what is worse, befog and bewilder the man who has given his time to fanciful imagination. Deep study and unwavering adherence to some carefully laid out plan is essential to success, returning, if necessary, again and again to the work. The author's meaning, once mastered, will do much



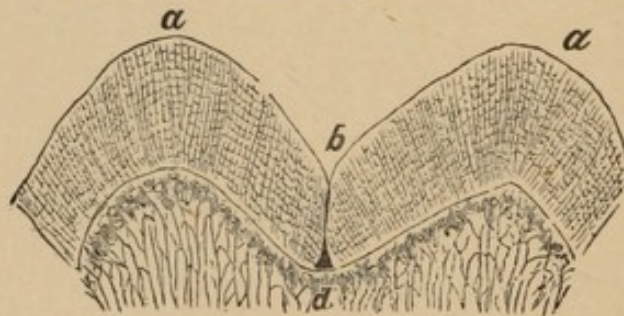
to make the mind capable of original thought. It is indispensable that the structure upon which you are required to operate should be thoroughly understood. Imitate those who conduct their operations with tenderness, yet prolong pain if necessary. He who deceives his patient with a faulty or imperfect operation, to please for the passing moment, will never be found at the head of his profession, nor is the mere pedant likely to occupy that desirable position. The earlier representatives of Dentistry obtained their information under difficulties quite unknown to the student of to-day. Every practitioner now has a clearly defined position that protects him in his justly deserved preferments, making him an ornament to his profession; or, deprecating his unprofessional acts, ostracises him from the companionship of good men in his calling.

The picture may seem overdrawn, but it is not difficult to find this practically demonstrated in the surroundings of actual daily life. Few, compared to the many engaged in practice, are acknowledged men of ability, and descending the professional scale to the medium good, how large do we find the increase; but the masses, so-called dentists, what shall we say of them? Simply that the professional scale does not reach so far, consequently the subject is beyond our jurisdiction. -

Operative dentistry is understood to be a branch in which every precautionary measure is taken to prevent the encroachment of disease in the oral cavity and adjacent parts; and as we recognize the importance of having our instruments tempered to a condition that will ensure perfect execution, so should our judgment be tempered with a knowledge of the anatomical conditions of the teeth, that we may place ourselves in full and direct harmony with questions involving the practical work of this branch;

also, be able to trace in clearly legible characters the ever changing conditions of the mouth, ranging from childhood to adult age.

Begging the kindly forbearance of your most worthy Dean and Lecturer on Dental Anatomy, I shall occupy a few moments in reviewing the different structures upon which your hand will be required to show its cunning. Some of my remarks may seem quite foreign to operative dentistry, but a knowledge of the anatomical condition of the teeth is imperatively necessary to enable you to do your work intelligently, and for this reason I have digressed somewhat, as the subjects are intimately blended.



a. Interstitial pyramidal columns of convex surface. *b.* Meeting at an angle of the ends of the prismoidal columns on a concave surface, and crevice leaving surface of dentine exposed.

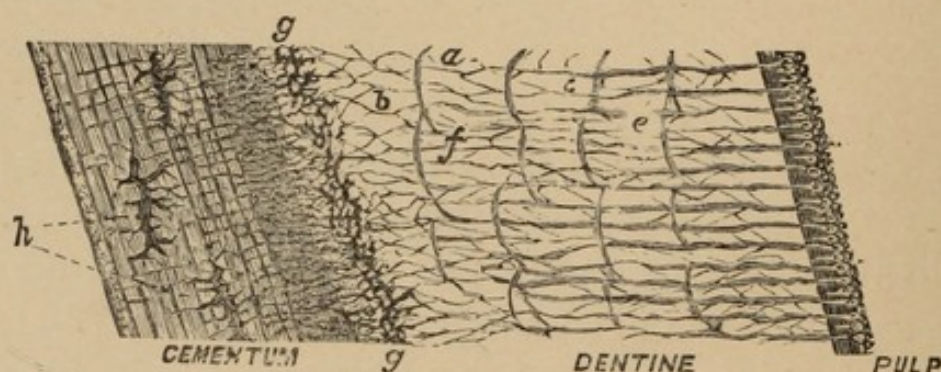
In approaching the subject of the teeth *per se*, the enamel in the sequence of formation naturally first attracts our attention; and, were it dissected from the rest of the tooth, it would appear as a beautiful capsule, bearing prominences and depressions on its upper surface, with sides diminishing, until the edges of them would be almost knife-like in sharpness. The inside of this capsule would be found to follow to some extent the contour of its outer surface, but not entirely so, the curvature of the interior being so much less than the exterior, as to cause an increase of thickness of the material, gradually increasing to a maximum, and then similarly decreasing until the opposite edge is reached, where it is intimately blended in relationship with the

overlapping cementum. Without a perceptible gore or pucker, nature puts this pearly substance like a cap on the dentine or body of the tooth, and wherever you discover a fracture in this beautiful framework, your aim should be to perfectly restore it.

Nothing to the unassisted eye helps the mind to obtain an idea of the structure of this capsule. Examined by the microscope, this hardest of organic substances presents the appearance of a mosaic pavement of hexagonal pieces; each hexagon denoting the end of a minute prism, extending from the interior to the exterior of the capsule, and perpendicular to its surfaces. No traces of vessels of any kind exist in this tissue; but there may be seen the boundary lines of the prisms, also transverse lines, which are ascribed, according to Dr. Beale, to successive layers of calcification. It is difficult to believe that no circulation takes place in the enamel, for all who have worked upon this tissue must be aware of the difference between the living and dead. The one is slightly pellucid, and can be cut with certainty; the other is opaque, chalky, and brittle. It has been suggested, and I regard it as possible, that the canaliculi in the dentine are continued in minute tubes to the outer surface of the tooth at all points, and that circulation is carried on to some extent through pores, bearing out the general analogy of the body. The direction of these hexagonal prisms should be understood, and studied in the preparation of cavities. "In concave surfaces the columns spring from opposite sides, and form angles by meeting at their free end."

In consequence of malformation, caused by these varying directions of the fibres of the enamel, fissures are formed reaching to the dentine, leaving that material exposed; and, in these interstices, surrounded by broken columns, you may always anticipate disease.

The dentine, which constitutes the larger portion of the tooth, is that part which is formed directly by the calcification of the dental pulp. Under the microscope, innumerable canals present themselves to view; they are called canaliculi, and extend in many lines from the surface of the pulp to the periphery of the dentine, giving out branches or ramuli, as they proceed on their course. The canaliculi and ramuli freely anastomose into each other, with the peripheral interglobular spaces, and by loops, returning towards the pulp. The method of connection between the dental pulp and the dentine has been a cause of difference of opinion among microscopists and investigators; some maintaining, with Professor Owen, that distinct fibres enter the dentine, and become a delicate membranous lining for the dental tubes.



a. Dentinal compartments of the original dental cells. *b.* Anastomoses of the ramuli with each other, with the intertubular cells, and with the cells at periphery of dentine. *c.* Earthy matter found in interspaces of tubes and cells. *e.* Aneurismal like dilatations of dentinal tubuli. *f.* Cells of intertubular tissue of ramuli sent off from the main interdental tubes into that tissue. *g.* The modified peripheral layer of the dentine at *g*, to the superior sensibility of which M. Duval first called attention, and distinguished by the name of "dictyodonte."—*After Owen.*

Professor Owen's view of the case may be illustrated by a description of what occurred on dissecting the tusk of an elephant. "Although the pulp could be easily detached from the inner surface of the pulp cavity, it was not without a

certain resistance, and when the edges of the co-adapted pulp and tooth were examined by a strong lens, the filamentary processes from the surface of the pulp could be seen stretching from the dentinal tubes before they broke."

Another view, and at present a popular one, is that "each canaliculus in its principal trunk, its secondary branches, and its anastomotic cavities, is clothed with a wall proper whose existence, often doubted, is clearly revealed by an examination of thin sections of dentine, subjected to the action of a diluted acid." These walls, composed of a resisting tissue, are then isolated from the fundamental substance of the ivory, and float in the preparation as dark filaments. "They are composed of a transparent homogeneous matter, without granulations or striæ, with no trace of organisation in a word, and containing neither vessels nor nerves." It is very probable that the dental canaliculi are filled with living protoplasm, presenting the appearance of fibres, that lose their peripheral ends in the pulp, surrounding in bow-like form the odontoblasts.

The cementum fulfils the same office to the roots that the enamel does to the crown. In its basal constitution it somewhat resembles dentine, passing in some cases into that tissue in a manner oftentimes inappreciable. Bone-like, it has canaliculi, and lacunæ, or osteoblasts (*h*). Its canaliculi in some parts coincide with the canaliculi of the dentine; and although it has been denied that any interchange of circulation can exist, yet we cannot but think that the tooth is more or less permeable throughout its structure to the vivifying fluids brought within its boundary by the ever faithful circulation of the general economy. Its original formation, like the formation of the other hard parts of the tooth, gives rise to discussion among

microscopists, but it appears to be nourished "by the alveolo dental membrane which here performs the office of a true periosteum, and whose vessels communicate with the cemental tissue." On the surface of the cementum is found a tissue of stellate cells, freely communicating with each other, which directly form the tissue of the cementum. In course of time, these cells change from germinal to formed material, and become themselves calcified.

We now come to a consideration of the pulp, which "is the shrunken condition of the tooth germ after it has normally accomplished the work of dentinification." The germinal structure we have not time to discuss, but I shall add that it is liberally supplied with blood vessels, furnished by the trunk which enters its base. A nerve filament enters each root, accompanied by several smaller branches, to the number of six or more. "These branches proceed to the pulp, penetrate it, and then branch again and again, forming a closely woven plexus."

The original office of the pulp is to form the body of the tooth by its calcification. Slowly but surely the deposition of earthy matter proceeds, and the pulp diminishes proportionately; but it may be excited by irritation to show an example of faithfulness, a struggle revealed by science, worthy of admiration. No sooner does caries attack the enamel than a semi-transparent cone—its base ultimately coincident in dimensions with the affected spot—appears in the dentine. The pulp having been stimulated by the aggressive action of disease commences under irritation to produce "an excess of the material which it habitually elaborates." These new elements are called by different authors secondary dentine; they penetrate and become deposited within the canaliculi, transforming the ivory into a compact and uniform mass.

The process does not cease here, for the prisoner pulp continues its efforts of resistance until a part of the chamber in which it is encased throws out a line of retrenchment to resist anticipated harm. The pulp diminishes at an accelerated rate, in consequence of these efforts, and sometimes ossifies and entirely disappears, permitting extensive and destructive caries to go on, attended with but little pain.

Pleasing as this subject is, I am compelled to close my remarks on the histological condition of the teeth, leaving it in the hands of abler men. The object has been simply to outline the structures upon which you are to work, and it is not to be supposed that justice can be done in one evening to a subject upon which whole books have been written without arriving at decided conclusions.

Having hastily scanned the elementary constituents of the teeth, I shall occupy a few moments in reviewing the different forms under which disease manifests itself in those tissues; for pathology is so intimately related to therapeutics, that it seems natural the one should precede the other.

According to the predisposing and exciting causes, caries runs its course slowly or rapidly; some teeth will resist its progress for many years, while others succumb and are totally destroyed in a few months. In either case caries eventually reaches the surface of the dentine, and here its progress is sometimes stayed, or for a long time retarded.

It may not act so powerfully upon dentine as upon enamel; or from slow progress the pulp may have had time to fill up the peripheral cellular places of the dentine and canaliculi.

Continuing, the disease insidiously advances, and soon spreads laterally under the enamel; layer after layer of

the dentine becomes softened and takes on all shades of brown and black, the cavity increasing, and fragments of the different tissues lying scattered in profusion. Portions of the prismoidal columns—vertical, horizontal, and oblique—are mingled with the food in active putrescence, in which are found microscopic, animal, and vegetable, forms.

The patient may be quite unconscious of decay until the crown of the tooth, without previous notice, breaks in. I say without previous notice, yet warning has been given through susceptibility of the pulp to influences, thermal or mechanical, but these influences may have been of such a transitory nature as to have occasioned but little inconvenience. The first breath drawn in a cold atmosphere, after leaving a warm room, a piquant sauce, or the cracking of a nut, might each have produced a twinge without causing the patient to realise the fact that the tooth was affected.

The evidences of the existence of caries must be searched for over the whole surface of the tooth, but your first attention must be directed to those parts most liable to decay.

In some, the jaws allow space for the full complement of teeth, free from a crowding; and, if dense in structure, teeth so favourably positioned are often found perfect in the mouths of people of extreme old age. But in others the teeth, subsidiary to the different forms of face, are crowded, and the points of contact are subject to constant attrition and shock during the mastication of food. The varying pressure and elasticity of the supporting process, and lining periosteal membrane, cause the prismoidal columns of the enamel to become separated and broken, and caries supervenes on the surfaces between the teeth. If caries has penetrated far into the tooth, and pain is experienced from thermal changes, or from pressure of

food into the cavity, the decay has probably advanced too rapidly to permit the pulp to fortify itself, in the manner already described, namely, by the formation of osteo-dentine. When this rapid progress of disease occurs, inflammation and swelling of the pulp ensues, until it sometimes reaches beyond the occluding surfaces of the tooth, resulting in gangrene and death.

The crown of the tooth then disappears piece by piece, until nothing remains but the roots, which are subject to the modifying influence of systemic change.

The subject of dental caries has a range almost beyond comprehension; extreme and exceptionable types of the disease are continually presented with complications quite remote. It therefore becomes a question of importance to the dental student as to how he may be able to combat it, when found under conditions calculated to embarrass the practitioner of experience. In his diagnostic research, it is necessary to take into consideration the possible chance of restoring lost structural tissues artificially to a condition of comfortable use. To accomplish this, he must have a thorough knowledge of the normal as well as abnormal condition of those tissues, their predisposition to caries, and the prophylactic measures to be employed.

Hereditary influence is a cause that must be enquired into; the condition of the mother during gestation, habits of life and diet, that you may be able, if possible, to trace any constitutional cause for mal-formed or ill-conditioned teeth. This, perhaps, may be considered as anticipating a position the dental practitioner should ultimately occupy; for how often are medical men in doubt as to the causation of neuralgia, treating constitutionally what is purely a local trouble: on the other hand, valuable members have been lost through the incompetency of dental practitioners to trace effect to cause. It is not to be supposed that a

mind limited in education, and without a knowledge of the first principles of medicine, should understand that disorders commencing in the teeth sometimes extend to other parts, involving complications of a serious nature. These cases, if properly cared for while yet a local trouble, are amenable to the simplest treatment; but, if neglected, may become unmanageable in the hands of the most scientific.

Early attention to the mouths of children should be observed, and this is one of the most conscientious duties we have to perform. The removal of a tooth too soon, or its retention beyond a proper time, may mould a cast of features that you are quite responsible for. I lay particular stress upon this, for the little ones, as a rule, receive very hasty attention, whereas the reverse is demanded. Deciduous teeth are the cause of great suffering among children, and are neglected too often to their permanent injury. It is the duty of the dental practitioner to educate the parent; laying down prescribed rules, to be observed in the fullest detail, concerning the management of their children's mouths. This duty he owes to his patrons and himself; for, having been consulted in good faith, it must necessarily reflect upon him sooner or later if he fail in this trust. An incalculable number of hideous deformities are produced by mal-attention, the result of ignorance or culpable neglect.

Passing to the materials used in the preservation of the teeth, I shall simply introduce the subject, occupying but a few moments, as they will engage my attention more fully at another time. However, it would be well perhaps to note the periods at which the saving of teeth began to be a specialty.

Not until the commencement of the nineteenth century did filling with gold attract attention of the better class of

dentists—lead being the first and principal material used previous to that time, and this seems a wonderfully tolerant metal in the system, as it has often been found embedded in the soft tissues, very near a vital part, without producing any perceptible amount of irritation. Had it a greater resisting power to force, I believe no better material could be found for filling; in one instance that came under my personal observation, a shot had been forced into the cavity by occlusion from opposite teeth, having done good service as a filling for several years. Upon excavating the cavity, some of the lead was still found, and underneath, the tooth was in a remarkably good state of preservation, very much as we might expect to find it after the removal of tin. Harris says gold was introduced as a filling in the early part of the eighteenth century; others contend, however, it was not until a much later period. It is a material that has undergone many changes in the different modes of preparation, and been subjected to many theories as to the best manner of using. Gold, as a material for filling, stands pre-eminent over its baser rivals, and the difference in its permanency is as marked (tooth structure permitting) as their relative value. It was first used for filling teeth in the form of leaf, but soon rolled gold displaced it, to be in turn superseded by foil; later, a preparation called sponge gold was introduced, which, from its easy working qualities, was hailed with delight, and for a time threatened to completely banish foil from use. Contrary, however, to the expectations of many, this was not realised, and it now occupies a doubtful position. The cause of failure in the use of gold is not always directly attributable to the operator, owing to the absence of lime salts in the teeth; but indirectly it is, for it reflects upon his judgment.

Two things are necessary to produce satisfactory results in its use—density of tooth structure, and delicate manipulative skill; and for the reason that this has not been sufficiently observed, humiliating failures have often occurred. I emphasise the word judgment, because it is not every student of dentistry that can become a good operator, especially when his efforts are directed to the use of this material, and his judgment, *when* to use it and *when* not to use it, is his only saving grace. Then come in rapid transit, tin, the different forms of amalgam, oxy-chloride and pyrophosphate of zinc, Hill's stopping, gutta percha—all of which claim a share of our attention. Among the different materials for filling, amalgam has figured conspicuously over all, many things having been said in its favour, and much against its use. It will be necessary, however, to defer until another time a further consideration of these preparations.

LECTURE II.

Delivered at the National Dental College, London, October 15th, 1879.

DENTISTRY is that branch of the Science and Art of Surgery which treats of the diseases of the teeth and of their contiguous tissues. It may be divided into the Morphology, Physiology, and Pathology, of the tissues, and their Surgical, Therapeutic, and Mechanical treatment.

The term prosthesis is used in the operative department, but it should, perhaps, be qualified by prefixing the word "structural," as the term has been more especially applied to the mechanical section; yet its surgical definition "the addition of an artificial part, to supply a defect of the body," gives us claim to its use in the higher type of operations in the mouth, demanding the restoration—artificially—of lost structural tissue.

This—the structural prosthetic—branch will admit of an extended classification, viz.:

- 1st. Examinations, and mode of conducting the same.
- 2nd. Instruments for, and their adaptability to the work.
- 3rd. Treatment of the gums when impinging upon dis-integrated portions of teeth.
- 4th. Wedging, and the different methods adopted.
- 5th. The rubber dam—its application in connection with ligatures and clamps.
- 6th. Preparation of cavities—instruments for the purpose, their temper, edge, and shapes.
- 7th. Introduction of gold into cavities, instruments to be used, and precautionary measures to be observed.
- 8th. Finishing, treatment of the mouth, and advice.

Your first attention in examining the mouth should be directed to the pathological condition of the teeth and surrounding structures. You must also ascertain if the local disease involves any constitutional disturbance; next, the probable chance of restoring defective teeth, if any, to a condition of usefulness, and a consideration of their removal when beyond the possibility of treatment; finally, the restoration of the mouth to a condition of perfect health.

Too much importance cannot be given to a careful and scrupulous examination, not of the teeth only, but of the condition of the whole oral cavity. Local disease not infrequently has more or less constitutional cause, and, while the filling of the teeth or other local treatment only may be followed by arrest of the disease, under such circumstances, the operation is, in truth, mere trifling with effects, whilst the more recondite cause is allowed to remain. To rightly practise the speciality of dentistry necessitates the exercise of an educated intellect; the possession not only of a special knowledge of the dental tissues, but a general acquaintance with human Morphology and Physiology. The dental practitioner so educated will be expected to trace effects to their cause, local and systemic.

The object of these lectures precludes our entering into a consideration of the causality of the pathological conditions of the teeth, farther than rational prophylactic or remedial measures require. To be able to make a beautiful restoration is but one—an important one truly—of the many qualifications necessary to enable you to intelligently practise this branch of your speciality. You can frequently by advice, and constitutional treatment in youth, bestow greater benefits, aiming at prevention, than can possibly be accomplished by local restorations.

The chief cause for operative dentistry is caries, it being the natural enemy to the teeth; and the different

conditions under which the disease is presented, should incite you to study the methods best adapted to abort it. Caries is defined as a "molecular disintegration of the tooth substance, gradually penetrating towards the centre." This gradual disintegration of the teeth is a disease which, to a very appreciable extent, adds to the ills that beset the human race; and it is recognized as a most insidious foe, and one that frequently baffles every effort at control.

The causes of caries are various, and authors quite disagree in their opinions concerning them; but it is convenient that they should be classified as exciting and predisposing.

The disease invariably commences at some point on the outer surface of the teeth, at which, from formative, mechanical, or chemical conditions, a defect in the enamel has occurred. These defects may from accidents, such as breakage by hard substances, commence on the exposed portions of the enamel; but in searching for caries, you should commence an examination of the sulci or interstitial fissures, for it is in these pits that you may expect to find decay, they being the most vulnerable places in the teeth. The prisms of the enamel are often found imperfect, so much so, that the dentine may be actually exposed. (This was diagrammatically explained at our last lecture, see fig. 1 *b*, p. 8.) In these crevices, particles of food lodge, and, becoming putrid, excite the hard tooth structure to decay; this is caused by the chemical action of acids formed by the decomposition of food, and also from the fluids of the mouth.

The enamel being injured or imperfect in structure, by these subtle destroying agents remaining in undisturbed contact, the prisms become disintegrated; and the first evidences of decay manifest themselves by a chalky opaque spot. To such a point your attention must be directed,

and an attempt made to arrest the progress of disease. Susceptibility of the teeth to thermal or mechanical influences may have been so transient as to occasion but little notice, and the patient will engage your attention only with the cause of immediate trouble which has brought him to you.

We will now consider one or two of the typical cases that present themselves in everyday practice. The first is a patient full of the appreciation of your efforts, submitting to the inevitable; he bears pain without a murmur, and leaves you with expressions of kindly regard and gratitude.

The second shows no reluctance to wait; in fact, would be willing to prefer the claim of priority to another; he has come with the conviction that your art is inseparably connected with pain. Fortunately, the latter are exceptional cases; for with a lack of confidence comes a want of interest. You should struggle against this feeling, however, for your duty is the same; if not to your patients, you at least owe it to yourselves.

Many who come to you will have been under professional advice from early childhood; but another class—and I fear the largest—consider the extraction of a molar the most important feature in dentistry.

Having become acquainted with some of the peculiarities of your patients, it becomes necessary for you to consider the manner in which the examination of the mouth should be conducted. This should be carefully and systematically done with a mirror and an instrument especially adapted for the purpose.

Beginning at the superior third molar on the right side, you should direct your attention especially to those vulnerable places, already alluded to, where caries is most commonly found, and continue an exploration of each tooth until you reach the corresponding molar on the opposite

side. You next turn your attention to the lower jaw, commencing at the third molar on the left side, and carry on the same mode of examination until every tooth in the mouth has been inspected. This I consider the surest method of preventing an oversight, which might by some be uncharitably construed into neglect. If thoroughly done, it generally reveals to the patient a number of cavities in unsuspected teeth.

The instrument used should be made of steel, the handle similar in size to the ordinary excavator, and bent in a gentle curve of cow-horn shape at both ends, the different points bending in opposite directions (as in Fig. 3).

FIG. 3.

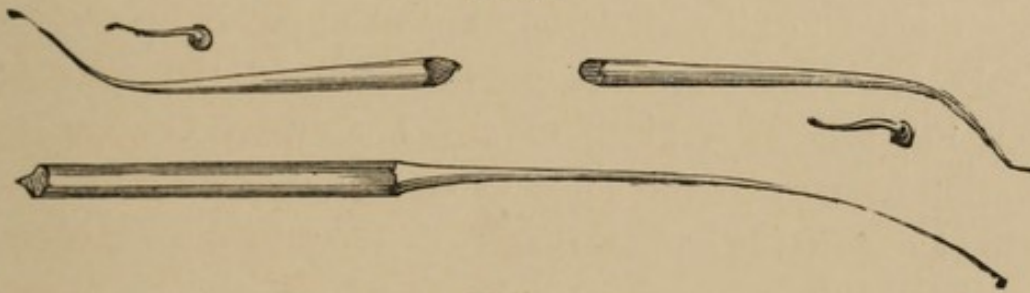


FIG. 4.

Another instrument of great value in making examinations upon the approximal surfaces of bicuspid and molars, will be seen in fig. 4. This is flexible, delicate in shape, and slightly turned at the point.

In searching, you should pursue your investigations along the weak portions of the teeth, carefully examining the buccal and lingual walls. You must also not forget to make an examination of the fillings in the mouth, their condition, as well as the tooth structure surrounding them; and, to do this properly, the instrument illustrated by fig. 4 should be introduced between the teeth, and below or above the base of the filling, with a view of discovering its condition at that point.

An otherwise good filling will often be found imperfect

at the cervical edge, caused by a lack of care in finishing, a portion of the gold having been left overlapping; and, as a result, you will find the instrument entering a cavity of considerable size, extending sometimes below the gum. In such cases, there is but one alternative, viz., removal of the filling, and treatment to press the gum away from the cavity, that it may be re-prepared and filled again.

When the gum interferes with an operation, as it often does in approximal cavities, endeavour to force it back by firmly packing cotton between the teeth, and hard upon the gum; this serves the double purpose of a wedge and compress. Failing in this, treat either by cutting away a portion of the gum, or by applying lunar caustic to produce recession. To be certain in the application of solid nitrate of silver, a small quantity can be readily fused upon the end of a piece of silver wire, by holding the caustic and wire in the flame of a spirit lamp. When in a state of fusion, the caustic readily adheres to the wire; and, in this form, it is under perfect control.

Should a cavity in the buccal surface extend any distance beneath the gingival border, wedge with cotton, that the gum may return again to its place without loss of substance after filling; but, if this treatment will not permit of proper adjustment of the clamp, unhesitatingly divide the gum down to, or even below, the process. Then place the rubber dam over the teeth, gently forcing it between the tooth and gum with a delicately bladed burnisher, and, with the assistance of some one to hold it in position, carry the clamp over the tooth, beyond the decay. While slowly permitting it to close, watch the countenance of your patient, to see that the gum has not been unnecessarily involved; for you will suffer severe, perhaps mentally reserved criticism, if careless in this.

If the gum still proves a source of trouble, it must be sacrificed. Using a sharp bistoury, an incision—crescent shape—should be made, extending below the seat of decay. This is an extreme measure, only permissible when other methods fail; and, never under any circumstances, is it justifiable upon the labial surface of the gum; in such cases, a deep incision, with the gum temporarily forced back, will answer every purpose. After the operation, the excised edges should be carefully placed in apposition, that they may heal.

I shall engage a few moments of your time upon the subject of wedging, for I recognise the importance of saving as much of the tooth as possible, when it becomes necessary to fill on approximal surfaces; and, owing to the extreme difficulty, in many of these cases, to prepare and properly fill, you will be compelled to either wedge or file. One of the favourite methods now in use is that of quick wedging, or separating by driving a piece of orange wood between the teeth. It should be done rapidly, one or two blows being sufficient; then, with the cutting forceps, clip the wedge close to the gum. This is generally done after the application of the rubber dam, and sometimes it materially assists in steadying the tooth, during the process of filling. Another method, and, perhaps, the best, is that of forcing the teeth apart with cotton. This may be done by rolling into a hard pellet as much cotton as can be gently pressed between the teeth, which may be worked into position with a thin bladed instrument, a silk ligature having been previously passed between the necks of the teeth to form a loop. By tying a surgeon's knot and drawing tightly, great expansion will be obtained. (See Fig. 5).

The cotton being compressed in a plane perpendicular to the arch, it is forced laterally, so that separation of the

teeth is accompanied with less annoyance to the patient than by any other mode of wedging, as the loose fibres are not permitted to work out and encroach upon the tongue or lips. Sometimes it will be found advantageous to dip the cotton into sandrac varnish previous to its insertion between the teeth, which soon hardens, and forms a solid block. Should cotton be used for wedging in cavities situated upon the labial or buccal surfaces, as before mentioned, the gum should be split, and the cotton forced into the cavity, until considerable pressure is apparent upon the gum, leaving it there twenty-four or forty-eight hours, when the gingival border will be found driven from its objectionable position. Rubber has a place also among wedging materials, but I cannot advocate its use, for I have not only seen painful, but dangerous, results, frequently involving periosteal trouble, from a violent and too constant pressure.

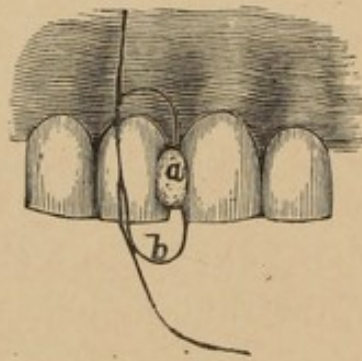


FIG. 5.

- a.* Pellet of cotton wedged between the teeth.
- b.* Silk ligature looped previous to compression.

We now come to a consideration of the rubber dam and its use. As it is important to prevent the encroachment of fluids of the mouth upon that portion of the tooth where the operation of filling is being conducted, this most valuable auxiliary enables us to perform operations which, without it, would be an absolute impossibility, especially

where teeth are decayed on the approximal or buccal surfaces. There are but few cases in which it should not be used; and, when the operator has become skilful in applying it, he willingly gives the extra time for adjusting the rubber dam, to be assured of a satisfactory conclusion of his work.

In using the rubber, it requires, not only tact, but skill; for the clamp frequently impinges upon the gum, inflicting a continuous and most excruciating pain throughout the whole operation; and, in some cases, we discover after its removal that double punishment has been caused.

Tact is required in adapting the dam, and especially in its application for the first time, as some patients complain of suffocation, and insist on having breathing room through the mouth. This feeling is generally an imaginary one, but occasionally the need does really exist, and is provided for by turning the rubber partially to one side, and propping the mouth in such a manner that, while complying with their wishes, you will in no way be inconvenienced.

Skill, that the clamp may be adapted to the differently shaped teeth, so as not to cause pain. This is sometimes exceedingly difficult to do; you are then called upon to candidly explain that the operation cannot be painless, and, with the assurance that every precautionary measure will be taken to prevent suffering, you will generally find your patients willing to co-operate with you.

Under the most favourable circumstances, the gentlest hand will occasionally inflict pain, but you should study every means in your power to avert it.

You will not always find clamps suitable to your wants, and it then becomes necessary to improvise one, adapting it to the shape of the tooth; and here the greatest ingenuity can be displayed.

A case representing the difficulties to be contended with, will be seen in Fig. 6. The dotted line between the teeth, marked *g*, denotes the depression which exists between the buccal and lingual ridges of the gingival margin.

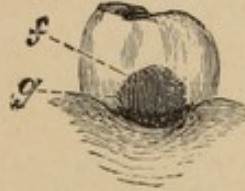


FIG. 6.

It is not an unfrequent occurrence to find the first or second inferior molars in the above-described condition, and so decayed upon the posterior wall as to make effective treatment with an ordinary clamp almost impossible. The decay generally extends to, and sometimes below, the gingival margin; and, when this occurs in mouths having an excessive secretion of the fluids, it becomes correspondingly more difficult to produce desirable results. I am not speaking now of the introduction of plastic materials, but as to how the tooth may be properly and permanently filled with gold.

If you have not the necessary appliances to perform the operation, a careful examination should be made to ascertain what is needed, that it may be supplied before another sitting.

The case illustrated by Fig. 6 was a first inferior molar, right side, that gave great trouble; and the difficulty was only overcome by the use of an improvised clamp, with a flexible heel spring, which I have attempted to illustrate in position, as applied to the tooth (Fig. 7.)

This clamp embraces the cervical portion of the tooth on the buccal and lingual sides, and affords support for a secondary spring which passes over the posterior portion

of the tooth, and rests upon the shrunken gum. The primary spring is attached at such an angle to the grasping plates, that it lies near the first bicuspid, and quite out of the way; also out of the range of light. With the application of an ordinary clamp, at least one half of the cavity would be bridged by the rubber, leaving an orifice underneath for free entrance of the fluids. The clamp seen in Fig. 7 now comes into action; the primary spring keeping the plates firm on the tooth, while the secondary spring presses on the, until now, bridging portion of the dam, and forces it below the edge of the cavity, thereby shutting off the communication which threatened to render all efforts nugatory. This may be better understood by referring to the explanatory notes given below.

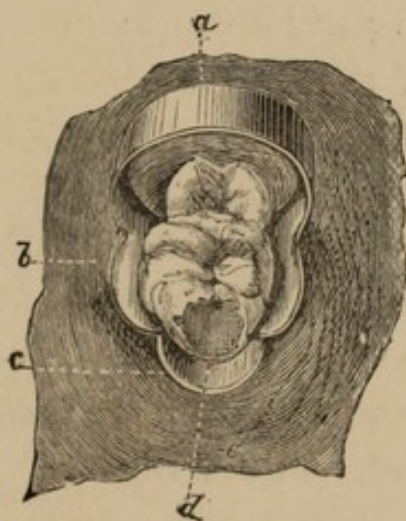


FIG. 7.

a. Primary spring. *b.* Clamping plates. *c.* Secondary spring.
d. Indicating position of rubber on the posterior portion of tooth with ordinary clamp. *e.* Rubber dam.

In cases where recession of the gum has taken place between the molars, extending in crescent shape some distance below or above the outer and inner borders—this is occasionally seen from a too frequent or injudicious use of the toothpick—great trouble is often experienced in

forcing the rubber dam upon the receded portion of gum. This class of operations bring no immediate recompense; for the time consumed, and the ingenuity required to properly fit and adjust the clamp is often very much greater than that of filling the tooth. Another drawback to a successful issue of the operation, is the necessary discomfort to the patient that cannot be avoided; and here the temptation becomes very strong to use plastic materials. You will again be called upon to improvise a clamp that will answer the purpose, which may be done by using one similar in form to that seen in Fig. 7, with this exception,—the heel spring must be made much more delicate, almost wire shape, and carefully adapted to the case in hand; the peculiar feature in the construction of the clamp now under consideration, is its adaptability to the varying widths of teeth. A slot is made in one of the jaws of that portion which we have called the primary spring, and a sliding adjustment fitted to the slot. This adjustment consists of a plate bearing at one end a perforated stud, through which a small steel or iron wire is passed, and at the other end a very short screw, with a square head; the screw is easily actuated with a key made for the purpose, and, when tightened, secures the position of the plate, the stud, and the wire.

By this combination, the position of the wire, which passes between the teeth, can be varied to the extent of about three lines, which is sufficient play to accommodate the differences generally found in the sizes of molars and bicuspid.

The clamp described in Fig. 7 is not to be found in the depôts; nor will many other called-for appliances, so necessary in exceptional cases. In a general way, the depôts supply our wants; but the practitioner dependent wholly upon them can never become proficient

in operative dentistry; for nowhere is conservatism and ingenuity more manifestly required than in the operating room. There will be cases over which it will be necessary to occupy more time than would seem consistent with the coming fee, but here let me caution you not to throw away your chances. These are opportunities!—stepping stones to a future position; the outgrowth of which comes from a careful attention to the little details so important in every walk of life.

Other locations, quite as difficult to adapt the clamp to as in the cases just mentioned, will be found upon the buccal and approximal surfaces, as may be illustrated in the following woodcut (Fig. 8).

At *a* is indicated the commencement of a form of decay which, in the ordinary course, leads to a more aggravated condition, as represented at *b*, where the cavity extends under the margin of the gum denoted by the curved dotted line *c*. Another difficult situation of caries is upon the buccal and cervical portion of the tooth dipping beneath the gingival border, as denoted by the curved line *d*.

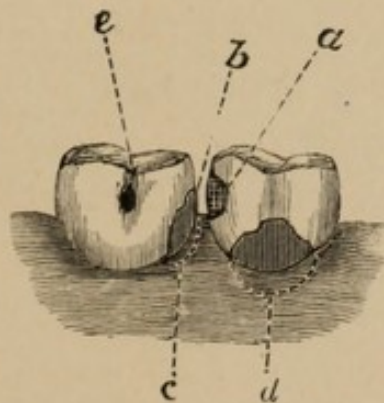


FIG. 8.

When decay upon labial surfaces extends under the gum, an overhanging portion projecting into the cavity, a clamp, forked upon the lingual end, and with a sharp

point at the labial end, will be found in many cases to answer a very good purpose. The advantage in this clamp is, that, after incising the gum, the pointed end, intended to rest upon the labial surface of the tooth, can be placed upon the root, far under the margin of the gum, with but little pain.

On the palatine surface is occasionally found an ugly form of decay extending far under the gum, and towards the grinding surface, until there is nothing but an outer plate of enamel left. Here a vertical incision may not answer the purpose, in which case it is advisable to make a circular cut, removing the gum as far even as the alveolar process, if necessary; then to pack the cavity with cotton, moistened with an anodyne, to allay irritation. Leave this, if convenient, twenty-four hours, when the rubber and clamp can be more readily applied, and with less discomfort to the patient, there being no hæmorrhage to contend with. The reason I have elaborated so fully upon the subject of clamps is, that they are the prominent feature in many operations.

A silk ligature is frequently found to be of more service than the clamp, but you must bear in mind that very cruel pain can be inflicted in this way; so great care should be taken in ligaturing to prevent the silk being forced to an unnecessary extent under the gum; for here again difficulties are to be contended with, which, unless prevented, will prove a drawback to the perfect execution of your work.

It may seem unnecessary for me to warn you against an oversight that sometimes does occur, viz., a neglect to remove the ligature after operating; but I have seen complications of so serious and painful a nature, the result of this omission, that I would suggest its removal previous to displacement of the rubber, thereby precluding the

possibility of such a mistake. Instead of trying to force it over the teeth, as is sometimes done, you will find it more agreeable to the patient—time also being saved—to cut the ligature; then grasping the knotted portion with foil carriers, it can be gently withdrawn with but little pain.

I would suggest the invariable use of the rubber in prolonged operations, as the exhalations from the lungs often interfere with the true working qualities of gold, thus rendering abortive the best efforts at success.

Some care should be taken in cutting the holes, that they be not too large, or too small. In the first case, moisture is very apt to seep through the edges of the rubber; while in the second, it tears in the attempt to stretch it over the teeth. These difficulties will be obviated as you become accustomed to its use.

Having first adjusted the clamp—if one be used—the rubber should be extended over the anterior tooth first, when placed over more than one, and held, while a ligature is passed between it and the adjoining one—*anterior*—if it still remains; if not, a clamp, reversed, may be employed, when another can be applied to the tooth farther back, with much less trouble.

Before I conclude my remarks concerning the rubber dam, I would call your attention to another most important reason for using it. The protoplasm, or formed material, contained within the dentinal tubuli, is more sensitive to the instrument when the fluids of the mouth come in contact with it, than when protected from moisture. I have frequently been able to prepare cavities when kept perfectly dry, that would have caused much additional suffering had the rubber not been used.

In the preparation of cavities, the manner of operating depends very much upon the seat of decay; if on the approximal surfaces of bicuspid, or molars, with over-

hanging projections, it becomes necessary to use the chisel, that every obstruction to your clear vision may be removed in the parts to be operated upon. This can be accomplished by the aid of delicate and carefully directed blows with the mallet upon the chisel.

In cutting away the decayed portion of tooth, the *débris* and fragmentary pieces should be frequently blown out of the cavity with an air syringe. If the tooth is sensitive to thermal changes, the larger pieces should be removed with annealing pliers, when the remaining bone dust can be expelled by gentle puffs, hardly perceptible to the sensitive dentine.

After opening the cavity with enamel chisels, it will be necessary to use excavators; they should be of the finest steel, and sharpened to the keenest edge. I mean really sharpened and truly set, for the instruments sometimes only require one or two distinct strokes on the stone to produce this result. If more be added, a thin line of steel will be seen hanging to the true edge; this is designated the false edge, which will not disappear with continual application to the stone, as it seems to be constantly renewed by the wearing of the metal. This false edge can be removed by plunging the instrument—pointed—into a piece of soft wood; but if the surface be of a more extended length, the edge should be drawn in the direction of the fibre of the wood.

The experienced operator soon knows whether his instrument is cutting, or simply scraping, its way. I mention this because the amount of suffering is very considerably diminished by a proper attention to instruments; they should always be ready at hand, and in their highest cutting condition, for the benefits derived from this are not alone to the patient.

The same remarks apply to the engine burs.

LECTURE III.

Delivered at the National Dental College, London, October 22nd, 1879.

No appliance in the operating room requires more careful attention than the dental engine, and the profession have become so wedded to its use, that it is now almost indispensable to the well doing of their work. However, it is sometimes found in the worst possible condition—dilapidated, loose jointed, and the hand piece so rusty, that an instrument can with difficulty be introduced or removed; but not alone to this is due the dread so often expressed by patients concerning it, for the frequently unskillful manner of using, has caused it to become still more unpopular. Try to keep your engine in the very best working order; the bearings well oiled, free from a gummy condition, and the flexible arm so positioned as to prevent too much play. Use no more oil on the hand piece than is absolutely necessary, for an excess will not only soil the fingers, but also the lips of the patient. Of the several engines now in use, the “White” seems to occupy a front position; the “Elliott” and “Morrison” are also well liked by many.

It is quite as important that attention be given to the instruments required for it, as to the engine itself; for a badly mounted disk may prevent the creditable finishing of your work. The burs and drills must be perfectly adapted to the socket, neither binding on introducing them, nor yet so loose as to give a clicking sound when pressed laterally to and fro. The revolving cylinder in the hand piece should be carefully inspected, whether rotating smoothly and

without oscillation ; for, if this vibratory movement occur, the most delicate handling will not overcome the repeated rattling noise. Inspect your instruments before using, to see that none are bent, irregular in shape, or roughly made ; for, if they do not rotate on their true centres, the hand piece will be speedily reduced to a condition of little value. After using them, they should be withdrawn from the hand piece and thrown into a receptacle, there to remain until the close of the day ; then wiped with an oiled cloth, and placed in an instrument stand, ready for the coming day's operations. Attended to in this manner, they will not oxidize, and become rough upon their surfaces.

In the preparation of cavities, do not hold the instrument continuously for any length of time upon the tooth ; neither let it revolve slowly. Use the engine under full motion, directing the instrument with true precision to the portion of tooth to be operated upon ; then with firm but delicate pressure, and quick alternate applications, continue the work as rapidly as possible until finished, being careful to give time between the alternations to prevent great thermal change.

Should danger exist from rapid execution, the engine ought to be displaced by the hand instrument. It is important to observe these principles when working near the pulp, as there can be no justifiable plea for exposing it in preparing the cavity ; here your anatomical knowledge of the structures upon which you are working must save you from such an error.

Reviewing in detail the many individual appliances necessary for the operating room, the mallet deserves special mention. I have already spoken of it in connection with the preparation of cavities, but a more important consideration of its use is that of condensing the

gold while filling. Here it becomes necessary to make a selection, there being different kinds, sizes, and shapes, including the hand, electric, automatic, pneumatic and engine* mallets, all of which have their firm advocates. I certainly do not wish to disprove the value of any of them, for I have seen undoubted work produced by each; so that the question resolves itself more into the manner of their being used, than the instruments employed. Among the hand mallets are those made of lead, of wood, and of steel; of the first and last metals named, I for a long time failed to arrive at a satisfactory decision of pre-eminent merit, each having advantages as well as objections. The wood, owing to its lightness, produced a jarring sensation, greatly complained of; and I never felt when using it that the filling was properly condensed; so that it has been abandoned by me for some time. The steel gives an elastic but noisy blow, causing the patient to imagine a great deal that never really exists. On the other hand, lead produces less noise, with an entire absence of elasticity; but, being apparently less objectionable than steel or wood, I have used it in preference to either of them.

Although dulness and inelasticity are properties so commonly associated with lead, these very seeming disqualifications may become objects of importance in the highest degree to the Dentist. The requisite elasticity is given by the method of holding the mallet in connection with the stroke from the hand and fingers, to be hereafter described. The dulness of the metal prevents a second-

* Since delivering this lecture, I have been using an improved engine mallet with very gratifying results—in elaborate and extended work—for building; but I still contend that, in the more delicate and difficult operations, the hand mallet is superior to any other.

ary rebound, and assures the operator that the blows are the result of actual calculation.

In advocating the mallet, I do not wish to deprecate the method of hand pressure; for, in proximate cavities and upon labial surfaces, the combination of both will frequently be found most advantageous. The mallet—whether electric, automatic, pneumatic, engine, or hand—should be most conservatively used; for, if too great force be applied, or the blows unnecessarily prolonged, the gold to some extent loses its cohesiveness. It is desirable, if possible, to get an elastic blow; I mean by this a rebound as quickly as the instrument has been struck. The only way in which I have been able to obtain the nicely modulated and ever varying force required, has been by the use of the hand mallet.

This conclusion is the result of careful observation and experiment, intervening and extending over a period beyond the advent of the electric and automatic. I accord to the inventors of both these instruments their adaptability to the condensation of gold, so far as anything in mechanics can apparently contribute; yet, I cannot but recognise the superiority of a blow intelligently struck, over that given mechanically. This perfect intelligence can only exist when the operator has the mallet in his own hand; for, while the strokes from an assistant may approximate the requirements, it is impossible to operate with the same assurance, self-comfort, and satisfaction, that would exist if the force to be employed were under individual control. The hand acting in concert with the brain, under circumstances capable of supplying the exact want, gives a "motor" that never fails to respond at the right moment; and this can only be relied upon when co-ordinated within oneself.

In the delicate manipulations rendered possible by the

hand mallet, the operator may himself become subject to considerable nervous tension, in fact even to the endangerment of his health; and the relief given at such a moment by the "motor" mallet can scarcely be overstated. In the process of long-continued building, when portions of gold, aggregating to considerable cubical dimensions, are to be consolidated, the advantage of applying an easily and conveniently directed power from an extraneous source is very great indeed, and has, no doubt, contributed much to the advancement of dentistry considered as an art. The electric mallet, however, is sometimes uncertain in its action, and I draw attention to this with the hope that a remedy will soon be found, thereby making it a really valuable and reliable instrument in the hands of those engaged in prolonged and difficult operations. In speaking of the hand mallet, a few prescribed rules regarding its use may be of service. The following are submitted for your consideration, viz.:—

1st, Adaptability.

2nd, Materials used for mallets.

3rd, Manner of holding.

4th, Execution.

Concerning adaptability, the size, shape, weight and form of handle, should be decided upon, after which avoid change, for the hand, once schooled to any particular instrument, fails to respond in as ready a manner to any other.

Of the materials from which you may select, are lead, steel, wood, tin, rubber, &c. Of some of these, and of the different forms of mallet, I have already spoken.

The manner of holding the mallet is one of the important features connected with its use, and requires to be particularly studied. The handle should rest loosely between the thumb and index finger, assisted by the second finger, and

its retention be quite independent of any other portion of the hand. With each stroke of the mallet, the handle should come in contact with the palm of the hand, before reaching the instrument, thereby partially arresting the blow, preparatory to its return. I would not have you forget that the impetus to the stroke must be given from the wrist and hand only. To illustrate this, I have had the following cut made, which is intended to represent one of the positions of the mallet previous to its descent upon the instrument.



Fig. 9.

There is, however, no arbitrary or stereotyped rule by which you can be governed in the use of the hand mallet; and the above illustration is only intended to convey an idea of the light and easy manner of holding, as an absence of all muscular rigidity of the hand is required while using it; further than this, the execution becomes simply a question of time and practice. With this, as with all other instruments used in operating about the mouth, the study should be to attain a delicacy of touch that may be perceptible to your patients; for a heavy hand in dentistry is much to be dreaded.

It now becomes necessary to consider the instruments best adapted for introducing gold into cavities. Those illustrated in Fig. 10 fulfil the requirements of all my ordinary work, and much that is more difficult.

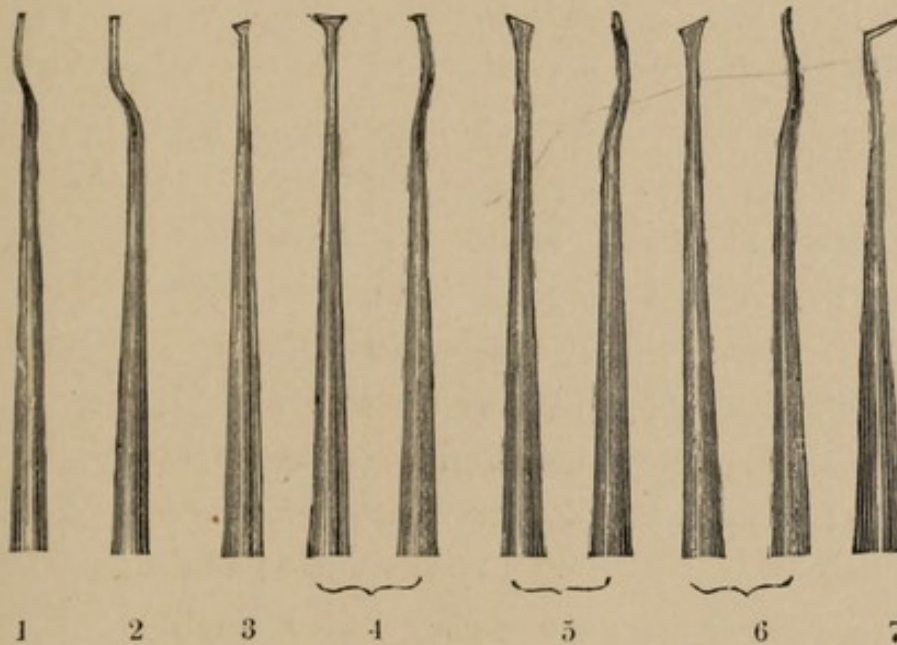


Fig. 10.

No. 1, round pointed and bayonet shaped, gives an unobstructed view while working, and is used as an anchorage instrument. No. 2, similar in all respects, but that its point is square, permits it to come in close contact with flat surfaces, and is used in connection with the foot shaped instruments, in proximate and crown cavities. No. 3 is well adapted for filling fine fissures which, occurring in the bicuspid, sometimes unite the caries existing in the ante-medial and post-medial* regions of the crown surface. It is an instrument also well adapted to filling the crucial fissures on the grinding surface of lower molars. Of the instruments represented in the above cut, Nos. 4

* An explanatory illustration of regional nomenclature, including these terms, will appear with the next lecture.

to 7 are well suited for filling cavities on the proximate and labial surfaces. The angle of the foot-shaped instruments (5, 6 and 7) keeps the serrated portion in a horizontal position, and at the same time throws the handle quite out of the line of sight.

The instruments used in filling teeth require delicately formed points, the serrations to be shallow, but sharp and clearly defined, that each pellet of gold may be well struck, securely fastened, and thoroughly blended with its predecessor, thereby losing its individuality in perfect union; otherwise there will be a sliding uncertain action of the instrument while condensing the gold. A few instruments well selected will answer every purpose; more than are absolutely required only cause confusion. The principal reason for having few instruments is, that the hand becomes accustomed to their use; and this familiarity enables you to operate with greater facility. It is, however, beyond my power to dictate the requirements of your individual wants. Extensive paraphernalia, in some cases, shows a mistaking of the means for the end. In one of the comic periodicals, there was lately given a series of pictures representing the efforts made by an artist to improve his materials; among other things, was a golden palette, and an easel of gigantic size, made of costly wood and of gothic design. The artist inquired of a friend whether there was anything further wanted. "Nothing," was the reply, "but talent." If the friend did not add "industry" also, we will supply the deficiency. Talent is a great and enviable possession in dentistry, as in other pursuits; but ability, the outgrowth of industry, eventually removes every obstruction to professional advancement.

Before dismissing the subject of instruments, I must draw your attention to those for hand pressure, represented in Fig. 11. These will be found of great value in the

cervical walls of proximate cavities, and upon buccal margins where the cavities impinge upon the gum. Not only do the serrated ends of these differ from the last described, in the angle they form with the axis of the instrument, but their proportions are much heavier, and the handles are of a shape convenient to obtain a firm and decided pressure.

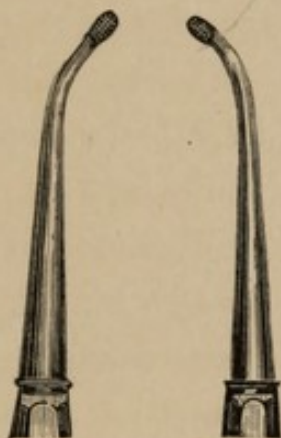


Fig. 11.

In my second lecture, I alluded to the necessary examination of the mouth, and also to the constitutional treatment of youth. I wish again to revert to these subjects, and to somewhat enlarge upon them. For, in examining the mouth, you must endeavour to ascertain—

First, the density of the teeth and their fitness to receive gold as a filling.

Second, the applicability of plastic fillings to teeth not having sufficient density for gold.

Third, the proper management of children when brought for consultation.

Having so far completed a clinical examination of the mouth as to fully understand the condition of the teeth, your investigations are by no means at an end. You have to ascertain, if possible, the resisting power of the teeth to the destructive agencies in the mouth. Age

will partly guide you in this, also the colour of the caries, as well as resistance to the instrument in cutting.

Some teeth are hard and dense, and decay makes but slow progress in them ; while others, deficient in the denser constituents of the tooth structure from imperfect development, become susceptible to every influence, whether local or constitutional. When teeth of this latter type are presented for treatment, it becomes a question of some importance to discriminate between the different materials that may be employed. Gold requires a good setting to insure permanency, and is not compatible with teeth incapable of resisting the slightest shock. Where you meet with teeth of this character—reduced by caries to mere blue transparent shells in a few months—they must be filled with a material that can be easily applied and often renewed, and in this way they may be saved for a considerable period ; but your attention will be required at frequent intervals, to inspect the work so placed.

In the mouths of children, the use of plastic materials in permanent teeth is sometimes most essential, and serves an excellent purpose in carrying them along until an advance in age shall have so solidified the teeth, as to enable your efforts to be attended with greater success in the insertion of more permanent and useful fillings. Discrimination and judgment should be so nicely balanced as to produce an equitable weighing of facts ; or gold, as well as other materials, will be brought into disrepute. Having ascertained that the tooth structure is of a character to permit gold being employed, it becomes your duty to use it—patient permitting,—in the knowledge that gold only can be depended upon for permanent service. The distinguishing difference between gold and plastic materials is, that gold is not acted upon chemically by any of the tissues or secretions of the mouth ; and, in turn, does not act chemically upon them. Its

office is to mechanically close up the cavity, and, so long as the tooth structure around it shall exclude the fluids of the mouth, this answers the purpose, in advance of any other material yet discovered.

This neutrality not being so absolutely preserved by other substances, you can sometimes avail yourselves of their chemical reactions, in a manner favourable to tooth preservation; and especially does this apply to tin. The use of this metal for filling teeth is of considerable antiquity, and the chief objection to it, is the lack of resistance to attrition. For mal-conditioned (soft and chalky) teeth, tin has a claim upon our consideration, owing to its specific action on the walls of the cavity it fills, resulting in a hardening process from oxidization, and from contact with them. Especially do I advocate tin for children's teeth, when of this uncertain character; for I have seen the bad effects of using gold for operations of this class, and have witnessed the gradual disintegration of the tooth structure round the edges of the filling, extending far into the crucial interstices of the tooth. These teeth would be better preserved, and more safely carried along to a period that would admit of gold, by the use of tin, or some of the different plastic materials, and the little patient subjected to less punishment.

And now, concerning the management of children—as well as their teeth—when brought for consultation; I have to say, that you will find no class of patients more difficult to deal with. Not only is there the impatience of pain peculiar to early age, but the natural restlessness of childhood to contend with. The teeth of youth, with their large pulps and imperfectly calcified dentine, are additionally susceptible of uneasiness. It is useless to attempt deception. The instrument may be concealed, fine representations made, or a cloud of delusive words used; but the deception only lasts for a moment; the child is embittered

against you, and becomes suspicious and even rebellious upon each future occasion he is compelled to accept of your services. This prejudice stamped on the impressionable mind of the child, may unconsciously influence him in after life, and cause him to defer until the last moment the most necessary dental operations.

At this important period, Parents and Dentist should be in unison. Parental authority must be united with the kind, but really explanatory words of the operator. The higher feelings of the child, its fortitude and courage, should be appealed to, age permitting. That some part of the operation will not cause pain, can be taught and demonstrated; while that part which will give pain, can be notified to the little patient, who will then nerve itself for the trial.

At no period of life do the teeth demand more attention than at the age of from six to twelve years, and parents should be taught that, at this time of childhood, they require to be examined repeatedly; for in these six years peculiar and constant changes are taking place in the mouth. The deciduous teeth are not to be rashly removed, as they play an important part in the formation of the dental arch, and their presence, so to speak, encourages the development of the permanent ones; on the other hand, should they be retained too long, the permanent teeth may be thrown out of their true position, thereby causing disfigurement. So much of health, happiness, and sometimes well-being in the world depends upon a comely set of teeth, that every care should be taken to preserve them.

It has been remarked that no set of organs have, in the aggregate, caused more pain than the teeth. Without assenting to so sweeping an assertion, I may say that much suffering might be averted by preventive measures. Parents should be impressed that although the deciduous

teeth are ultimately to be replaced, yet some six years or more are required to complete the process, and that caries should be looked for and continually guarded against in these teeth. The consequence of this would be the prevention of much pain to the little one, while nights of unbroken and ever needful sleep, now lost to child, parents and nurse, would be saved. Teeth destroyed by caries, or injured by unwonted applications, and by the untoward and irrepressible actions of childhood, with swollen and inflamed gums, give rise to considerable constitutional disturbances, and a lowness of condition favourable to the approach of serious diseases; or to reducing the powers of resistance, should the diseases incidental to childhood make their appearance.

Your aid will frequently be invoked under circumstances that will scarcely justify you in an attempt at any effort beyond palliative treatment. The pulps of one or more teeth may perhaps be exposed, and susceptible of causing exquisite suffering. The treatment then becomes a matter of conscientious regard to the future welfare of the child. Where possible, I avoid the use of arsenic, even in adults, for the devitalization of pulps, but, in children I consider the exhibition of it still more objectionable, as the large pulps of the deciduous teeth are so absorbent that the action of the arsenic may be transmitted to adjacent tissues. In the Therapeutical part of these lectures, I shall enter more fully on the method of obtunding.

The first appearance of the permanent teeth has always to my mind been deeply interesting; but not unfrequently are they a cause of anxious thought to parents, for at the moment of eruption, or as soon as the crown can be seen, we find that the seal of destruction—in many cases—has been set upon them. Especially is this the case with the six year old molars. For we see manifestations of disin-

tegration, lines of imperfect development, the enamel and the dentine disconnected, and in fact, find evidences showing that the early loss of these teeth may be predicted.

The cause of this imperfect development is invariably constitutional; and it is in measures taken to fortify the general health, and to aid in the nutrition of the body, that a remedy for this distressing state of things may be found. I am aware that these remarks belong to the therapeutical part of my lectures, and I shall have to recur to this again when I reach that part of the series; but I feel that this section would be incomplete were I not to mention the prophylactic measures necessary.

The ensurement of a general state of good health is of course a *sine qua non*, but the measures taken with that view, do not enter within the scope of these lectures, farther than those pertaining to the proper development of the teeth. Many of the abnormal conditions found in, and upon the teeth, might have been prevented by appropriate diet in early youth. In the preparation of flour from wheat, some of its most important constituents are eliminated, and this loss of material has been pointed out over and over again by physicians, as a loss to the nation. The diet of children should be guided with a special regard to the introduction of lime salts, so as to convey provision for the bony structures of the body—and among the supplicants for this pabulum are the teeth. Oatmeal, the coarser cereals, bread made of whole flour, brown bread, and milk with lime water should enter largely into the dietary table of infancy, childhood and early youth. With insufficient nutrition, with defective assimilation, or with food improperly selected, rachitis, and kindred disorders, are engendered in the frame, and the effect of each arrest of development painfully manifested in the teeth.

With adults the treatment required is often resisted, and an attempt made to dictate. Under such circumstances, the power of the Dentist is necessarily limited, although disinterested advice and kind explanations will do much towards removing the prejudices that hitherto had existed. In disease involving medical treatment, the symptoms of functional disorder are frequently neglected; lesions of viscera occurring, with perhaps but little pain, nevertheless, slowly and surely affecting the springs of life. This neglect may result from indifference, or from a preoccupied condition of mind. Acute odontalgia, however, admits of no trifling delay, but forces its victim, who should have been under treatment months before, to seek professional aid. Unconscious of the disordered state revealed by a preliminary examination, the patient deprecates every earnest effort made in his behalf, and insists that the operations shall extend over a limited number of hours; not knowing, nor caring to know, in the total engrossment of his daily pursuits, that, unless the bodily health be attended to, the same causes which developed disease in the teeth may render futile all efforts for their future preservation.

Pain is an exceptional state of the body; the teeth, although the cause of great suffering, do not produce fatal ailment; yet every hour of torture is an abridgement of the true enjoyment of life. It may be difficult to substantiate cases in which the teeth are directly affected by the development of constitutional diseases,* but it is highly probable that the cachectic state so favourable to local derangement is frequently indicated by uneasiness in the

* It has been observed that some fatal diseases, as phthisis, have but little direct effect on the teeth; while fevers, as in typhus, prove most disastrous.

dental organs. To this I do not attach any particular importance, as the teeth may be the cause of suffering without the appearance of any other disease in the body; yet the primary origin may be surmised to have been an unhealthy state of the economy at some earlier period.

It does not follow that the Dentist should attempt to cure the bodily diseases which his knowledge enables him to detect. He may indicate his discovery to the patient, and, if the case be serious, consign him to the family physician until health will justify attention to local parts.—In ailments peculiar to the teeth themselves, the Dentist prescribes the remedies universally approved by the profession, or which occur to him as being applicable to the case. To soothe the morbid sensibility of an affected part in the first stages; afterwards to promote absorption of morbid depositions—as in alveolar abscess—should be the aim. In the different stages of disease, the remedies which are calculated to fulfil the first indications may be often conjoined with those intended to accomplish the second; internal and external means being simultaneously used with beneficial results.

Although the Dentist may be incapable of always complying with the wishes of those he has to meet, his professional bearing will imperceptibly produce results, and steadily add to the ever-increasing tendency of the public to place themselves under professional care.

As civilization advances, so will the necessity for the *mens sana in corpore sano* become more evident to the enlightened mind; and that health and symmetry, which in the savage state and functional activity may have been ensured by the “survival of the fittest,” will be aimed at by physiological and hygienic methods, while the aid of the specialist will be increasingly demanded.

LECTURE IV.

Delivered at the National Dental College, London, Oct. 29th, 1879.

THE responsibility of a Dental Practitioner is considerable, and he should not abuse it. No longer will attention to the teeth only fulfil the requirements of his position, but he must examine the state of the whole oral cavity, which is indeed equivalent to an examination of the system at large, for the finger of disease writes with unmistakable characters on the walls and flooring of that passage.

The condition of the tongue is a sure index of the state of the stomach; but debilitating influences may exist which have a direct bearing upon the general health, so that, to clearly define the actual—not the probable—cause of trouble, the gums must be examined, whether inflamed, tumid, or ulcerated; also the ducts of the salivary glands, to see if calculi exist in the tubes; while neuralgia should be mapped out and traced to its origin, to ascertain if it be local or systemic. Carefully diagnosing, the Dentist should attempt to define which causes are constitutional, and which are traceable directly to the teeth and contiguous parts, thereafter adopting treatment according to the conclusions at which he may have arrived. The filling of teeth is too frequently considered the only object to be attained; but this is not all that is necessary before the mouth can be restored to a condition of health, so that the natural functions of mastication and articulation may be perfectly performed. The patient should possess a happy unconsciousness of the existence of his teeth, beyond

the evidence of their meeting the full requirements of his wants. Many, who are particularly observant in cleansing the mouth, are quite ignorant of the fact that it may be filled with vitiated secretions from causes quite independent of the teeth. Defective teeth may be but one link in a chain of complicated disorders; and the Dentist fails in his duties if he does not acquaint his patient with the true condition of the mouth, as the importance of a healthy state of the oral cavity cannot be over-estimated.

Action and reaction, of the system at large, is continual. Fractured teeth irritate and ulcerate the tongue. Roots cause neuralgia. Alveolar abscesses increase, fistulæ are set up, and general stomatitis intervenes. The oral fluids may be poisoned by exudation of pus, as from alveolar abscess, ulceration of the walls of the mouth, gums, or tongue. In mouths so affected, caries progresses very rapidly; the decayed teeth react upon surrounding structures, and local functions are thereby still further modified. Also, the air to the lungs may be vitiated by the exhalations from a foetid stomach and mouth. These local abnormal conditions produce constitutional disturbance by acting directly upon the blood and stomach.

The inattention to health which is revealed to the Dentist is sometimes extraordinary, and the more so when we consider the important functions of the general economy in which the mouth assists.

Few reflect on the usefulness of the teeth; and it is curious to notice the comparative indifference with which their loss is spoken of by many. Instead of being impressed with the beauty of the dental arch and its constituents, the natural, priceless, and, if lost, irrestorable jewels of the mouth are ruthlessly torn from the position to which

nature had appointed them, when an attempt at concealment of the maimed and disfigured condition of the parts is resorted to by artificial dentures.

Another state, most faithfully portrayed in the following lines, lends no enchantment to the picture :—

“ What pity, blooming girl, that lips so ready for a lover,
Should not beneath their ruby casket cover one tooth of pearl ;
But, like a rose beside the churchyard stone,
Be doomed to blush o'er many a mouldering bone.”

The oral cavity, contemplated in its perfect adaptation to the work it has to perform, is a source of wonder and admiration. In the living bones and tissues are placed organs of exquisite mould, forming ridges and prominences for the trituration of food.

The mouth being directly connected with the mucous membrane of the alimentary canal, not only do its functions presage great physiological actions connected with nutrition, but it is influenced by the intellect in speech—the larynx, the tongue, the teeth, and the lips combining to produce and modulate sound, and express ideas. It is the entrance gate to the alimentary passage, and leads to that which may be properly designated the culinary department of the physical economy. At this entrance are situated the teeth, and the act of mastication is one of their most important functions. Should they be absent, or in a condition of disease, the other organs must suffer proportionately. The food being insufficiently prepared, assimilation is rendered defective. While the teeth are reducing and breaking the aliment, provision is made by the complicated, but perfectly-adapted, glandular system, to supply the oral cavity with necessary moisture during the process, and to prepare the bolus for deglutition.

The nerves of special sense, distributed to the tongue

and soft palate, receive the impressions of taste, and convey them to the brain.

Passing the velum-palati, the food is conducted down the pharynx and oesophagus, and irretrievably engulfed and appropriated by the stomach, which gratefully acknowledges the assistance given—if properly rendered—by infusing a genial cheerfulness unknown when digestion is imperfect. The knowledge that the human mind is so susceptible to the varied influences of these different organs, should never fail to impress and encourage the student in a deep and untiring devotion to his profession.

These remarks have been extended much beyond their intended length, but I do not deem them irrelevant, for I speak with a conviction that the important consideration of saving teeth is not yet understood; otherwise there could not exist such a condemnatory and sacrilegious disregard to the welfare of the human race. Those who cry for exemption from ills inflicted by the ever too ready use of forceps, come too late. No benefit can be reaped from knowledge gained at such an hour, beyond the lesson which their sad experience may teach others.

In reviewing the different types of disease in the teeth, I shall classify the various stages under the following heads, viz.:—

- 1st. The inception of decay with primary evidences of disintegration.
- 2nd. An advanced stage of caries with encroachment on the pulp.
- 3rd. A condition of disease involving a partial or complete exposure of the pulp, without necessary loss of the same.
- 4th. A broken down condition of the tooth structure, complicated with pulpitis and death of the pulp.

Beyond this latter stage it would be difficult to indicate any form of treatment. The diseases in adjacent parts induced by caries, do not enter into the scope of this lecture, but will be considered under their separate headings at a future time ; the object now being to define the several conditions of decay as manifested in the teeth.

No arbitrary line divides these stages, which day by day imperceptibly glide into each other, but they apply to certain well-defined appearances which, by degrees, are presented to the view of the Dentist, or in the third and fourth stage are revealed by the sudden, unexpected, and miserably painful breaking in of the crown of the tooth.

As I have explained in my lectures, it unfortunately happens that, in the majority of instances, the patient never consults the Dentist until the third or fourth degree of caries occurs. In such cases, the indispensable preliminary examination often shows all these degrees of caries existing in the teeth. The first spot, the almost inevitable extension of which produces the destruction of the tooth, and the second stage, are generally unsuspected by the patient ; but the third, unless treacherously concealed by the enamel, may cause irritation to the tongue by its coming in contact with the ragged and sharp edges of the cavity, and afterwards becoming excoriated by restless, nervous application.

But even in mouths where well marked instances of these stages are recognised, it does not follow that in different individuals you can adopt precisely the same treatment, or form the cavities in like manner ; for exceptions have to be made according to the age of the patient and the density of the teeth.

The necessity for a precise nomenclature of the various parts of any organ, upon which it is required to speak, suggests itself as the subject becomes more extended.

Various forms of decay are continually presented which, hitherto, have had no clearly defined position ascribed to them; a case of this description may be seen in Fig. 12.



Fig. 12.

Fig. 12, *f* and *g*, represents decay in the ante and post-medial positions.



Fig. 13.

Fig. 13 shows the confluence of both centres of decay.

The object here is to describe in as comprehensive and complete a manner as possible, the different prominences, indentations and articulations that may come in contact with the occluding surface of the opposite teeth, the proximate surfaces of the adjoining teeth, or the outer and inner boundaries of those more elastic tissues, the cheeks, lips, and tongue.

The external surface of the teeth is naturally divided into two well defined parts—that below the gum, and covered by the periosteal membrane, and that above, presenting enamel alone to view. The cervical portion of the tooth constitutes a division, which is conveniently referred to, with the addition of the names of the sides and angles. The region below the gum is mainly composed of the fang. The incisors and cuspids have each but one root. The bicuspid are practically single, though evidences of two fangs present themselves. The upper molars have three fangs—two external, called buccal, and one internal, called palatine. The lower molars have but two fangs, with their bifurcations at right angles to the submaxillary bone; and the terms anterior and posterior distinguish these fangs. Caries so rarely directly invades this region of the teeth,

that this nomenclature is generally sufficient; the necessity for greater explicitness being met as it arises.

But, in the enamel region, you are continually called upon to indicate the location of points upon five surfaces, with their angles and boundary lines. These last are very clear in the molars and bicuspid, but are not so plain in the incisors and cuspids. The established nomenclature for the four surfaces of the incisors and cuspids gives the following definitions: two approximal, one labial, and one palatine or lingual. The term palatine is applied to an upper, and lingual to a lower incisor. The four angles are denoted by the terms right and left labio-approximal, and a right and left palato-approximal or lingua-approximal. The bicuspid and molars have each five surfaces, denoted by the names anterior and posterior-approximal, buccal, palatine or lingual, and grinding or crown surface. The four angles are denominated anterior and posterior-palato-approximal, anterior and posterior bucco-approximal.* These terms are freely quoted from Harris.

But, in describing the ravages of caries, commencing at points on the crown or other surfaces, and continued in lines irregularly disposed, a difficulty in exactly defining the positions of those lines and points presents itself; and I propose to add to our present nomenclature in the manner presented in Figs. 14 and 15, so as to introduce, if possible, an improved "Cartography of the Teeth." In so doing, none of the established terms are superseded. Harris defines, as stated above, the surfaces, the angles and boundary lines. The new nomenclature seeks to establish points on those surfaces, especially upon the crown, intermediate between the angles. Leaving the

* In the new nomenclature I have adopted the word proximate instead of the hitherto accepted term "approximal."

extremities of the diagonals as being already named, the new terms apply to points on, and to the distal ends of, the transverse lines, and to intermediate points on diagonals.

The transverse lines divide the crown surface of molars and bicuspid into four regions, of which two are posterior and two anterior. The centre of each region has an imaginary point (marked *h, i, j, k*, Fig. 14), which may be said to be on the diagonals. The dividing lines define several other points. The mesial line, from the anterior to the posterior portions of the tooth, is also divided, and has points midway between the centre and the anterior and posterior sides. The intersection of all the lines at the centre of the crown surface, I call medial; and it is marked *e*. This division gives us eleven definite and easily-remembered points, and will facilitate oral or written descriptions of the teeth without diagrams.

The following, Fig. 14, illustrates the proposed system:—

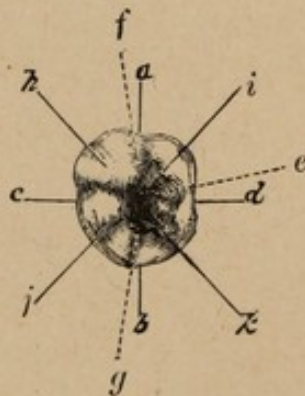


Fig. 14.

- a.* Ante-proximate.
- b.* Post-proximate.
- c.* Buccal.
- d.* Lingual*.
- e.* Medial.
- f.* Ante-proximate-medial.
- g.* Post-proximate-medial.
- h.* Ante-buccal-medial.
- i.* Ante-lingual-medial.
- j.* Post-buccal-medial.
- k.* Post-lingual-medial.

The acute crowns of the incisors and cuspids render a

* I have found it convenient, in connection with this nomenclature, to adopt the word "lingual" instead of "palatine."

modification of this system of nomenclature necessary when applied to them, and this is indicated by Fig. 15, which is a view of a right central incisor projected on a plane perpendicular to the general direction or axis of the tooth.

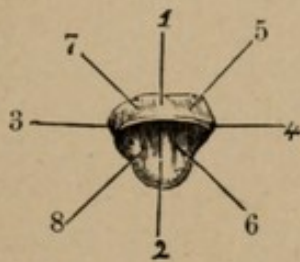


Fig. 15.

1. Labial.
2. Lingual.
3. Distal.
4. Mesial.
5. Meso-labial.
6. Meso-lingual.
7. Disto-labial.
8. Disto-lingual.

In defining these lines and positions, I have resorted to a description analogous to that representing the regional anatomy of the viscera contained in the abdominal cavity, with a view to aid in tracing the irregular forms of caries, as it creeps over the different surfaces of the teeth.

I have had the following diagram prepared, with a view of representing the typical forms of decay that may manifest themselves in and upon the teeth; and, in drawing attention to these different types, I shall use the nomenclature already described and figured.

My attention will now be directed to those teeth most neglected in the mouth, namely, the molars. Here it is not the exception, but the rule, to find that the arch is broken, and the extraction of one tooth is often equivalent to the loss of two. I feel like saying three, for the tooth adjacent, if left alone, is seriously abridged in power to serve the rest. The first molars are generally lost through carelessness or indifference in youth; and not until their absence is really felt, is any thought bestowed upon the rest. No teeth demand more anxious care, at

stated intervals, than the third molars, for how they may be erupted is always doubtful, in consequence of the many complications in connection therewith. The favourable conditions are, sufficient space in the jaw, and a proper direction to permit regular gomphosis; and, in such cases, the wisdom teeth may outlast all the other teeth, and do

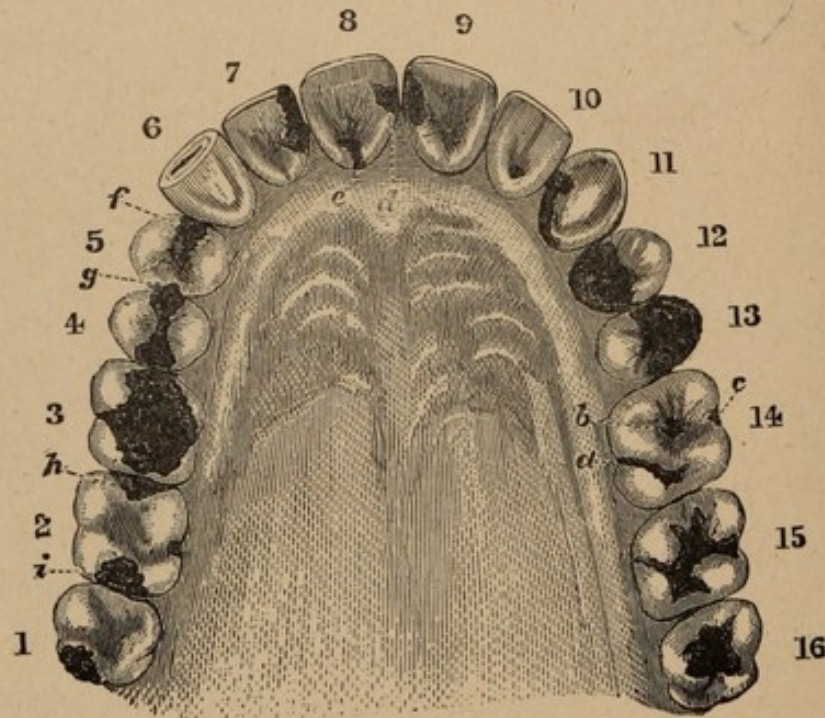


Fig. 16.

Fig. 16 illustrates decay in the teeth as frequently seen in the different stages.

excellent service until expelled from senility. The eruption of the wisdom teeth is sometimes attended with severe local and constitutional disturbance, being in the lower jaw so situated between the ramus and the second molar as to become fixed in their position. They are often found decayed on their first appearance, as if they had been attacked by caries in their developmental sac. The Dentist's labours commence at the earliest indication of the eruption, and perhaps do not end until difficulties far surpassing those presented by the other teeth are sur-

mounted. The extraction of the wisdom teeth is sometimes difficult from their inaccessible position, and in some cases from immobility of the jaw, owing to a constricted condition of the muscles, the patient not being able to open his mouth.

These teeth are at times the subject of grave and anxious thought to both the patient and Dental Practitioner; but it is now necessary to consider them in connection with decay, as they are often found to contain the most unapproachable and unmanageable cavities that exist in the dental arch, owing to their position being far back in the mouth, and situate on a portion of the tooth coming in close contact with the ramus of the sub-maxillary bone. The scene of decay being removed from the light, you must, in many cases, operate by judgment, rather than by direct vision. One of these types may be seen illustrated in Fig. 16, No. 1. The plan of this caries extends from the post-proximate to near the post-buccal medial, and ends opposite that point on the buccal surface. Passing to No. 16, on the right-hand side of the arch, a form of caries is seen which is usual in the wisdom teeth. The plan of this caries is situate entirely round the medial point, and extends into all the regions designated as medial.

It not unfrequently happens that the inception of decay, commencing on the buccal portion of the lower molar teeth—the upper teeth being more exempt from this form of disease—extends into cavities upon the grinding surface. (See Fig. 8, *e*, page 13.)

While the lower molars are more subject to decay on the buccal surface, disease is often found manifesting itself upon the lingual walls of the upper molars. The decay here is generally seen to extend along the fissure running from the lingual to the post-medial cavity, and not unfrequently in conjunction with caries

DENTAL COLLEGE
TORONTO

in the ante-medial region, which almost invariably makes its appearance at about the same time, and may occur simultaneously with caries in the buccal surface. These three centres of decay in their first stages are represented in Fig. 16, No. 14, *a*, *b*, and *c*.

The centres of decay so delineated, in course of time, become confluent, and enter a secondary form, as presented in Fig. 16, No. 15. The original points are just distinguishable, but the whole structure of the crown is perforated, and the remains of the cusps are separated by wide channels of decay. The next, or third stage, is reached by these channels losing their distinguishing forms—resulting in a total ruin of the whole crown, leaving but a narrow brittle rim of enamel here and there at the sides of the tooth. This stage is represented in Fig. 16, No. 3.

No. 2, *h* and *i*, Fig. 16, represents another form of decay involving the ante and post-proximate portions of the crown. This shows a condition of disease that may require the nicest adjustment of the rubber dam, a more comprehensive view of which will be given at another time.

When the decay is permitted to pass to a more advanced stage, the floor of the cavity gives way, and the pulp is unprotected from chemical and mechanical influences. The exposure of the pulp may be so extensive as to involve its loss; but the treatment of this and the other cavities I am now describing, will be deferred until a later period.

The bicuspid teeth are very often found in a badly diseased condition on their proximate surfaces, without any apparent external manifestation, further than a discoloration of the enamel; at other times, a slight fracture will be seen upon the proximate edge of the occluding surface. (See Fig. 16, as in No. 5, *g* on the post-prox-

imate surface of the first bicuspid). On breaking away the overhanging edges, a cavity is seen of startling dimensions, extending to a point impinging upon the pulp, as is represented in the ante-proximate portion of the same tooth (*f*). Then, again, decay is found conjointly commencing on the ante-proximate as well as on the post-proximate surface, and extending along the interstitial line, through the medial portion of the tooth, until the two cavities are blended into one, forming what might be called a saddle cavity, the stirrup portions extending to, or perhaps under the gum, as in Fig. 16, No. 4. In other instances, disease commences in the ante and post-medial portions of bicuspid teeth, as before mentioned and represented in Fig. 12; or the cavity encroaches upon the anterior or posterior wall; this may be seen in Fig. 16, No. 5, *f*.

I have traced, in both molar and bicuspid teeth, the inception and progress of decay; and, in one molar, the figure shows the almost total destruction of the crown of the tooth (Fig. 16, No. 3). A precisely analogous condition of things may occur in the bicuspid, and in Nos. 12 and 13 the crowns are nearly destroyed. But the cusps favour the retention of a wall on either side of the central fissure, and such a wall is shown, in the first bicuspid on the buccal, and in the second bicuspid on the lingual aspects.

The labial and lingual surfaces of the canine teeth, inclining in wedge-like form to the cutting or piercing edge, together with the triangular shape of the proximate surfaces, materially modify the position of the points at which caries commences its attack. The cuspids generally commence to decay in the proximate surfaces, and the seat of disease may extend to or below the gingival border, gradually attenuating the cervical portion of the tooth until the crown assumes the appearance of an inverted pyramid, as seen in No. 11, Fig. 16.

In Fig. 17, the disease has made considerable advance upon the lingual walls of the teeth.

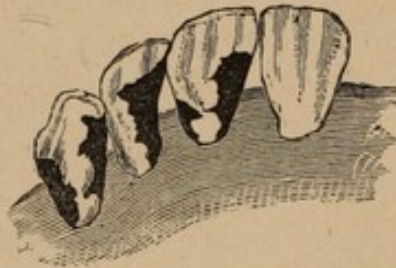

Fig. 17.

Another type of disease commencing upon labial surfaces is represented in Fig. 18.

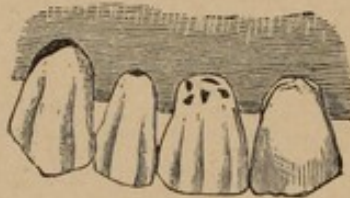

Fig. 18.

Sometimes the cutting edges of the cuspids are abraded in a manner as seen in No. 6, Fig. 16.

The incisors next claim our attention. The expression of human feelings, whether of happiness or sorrow, depends much on the combination of these teeth with the lips; but like the other teeth, caries is ever ready to remove them from the arch which they finish and adorn. The forms of decay in the incisors resemble those occurring in the cuspid or canine teeth. I have figured (No. 10, Fig. 16) a lateral incisor with the inception of decay on its lingual surface. In the right and left central incisors (8 and 9) are represented caries as it frequently occurs in proximate surfaces of those teeth. On the right central incisor (8) decay is seen upon the lingual aspect, extending down to and below the gingival border. In No. 7 is delineated a type of decay involving the partial loss of that portion of the tooth designated mesial and meso-lingual; the cavity ex-

.....

OTHOOT

tending along the mesial line from the cervical portion of the tooth to its cutting edge. In Fig. 19 may be seen a lower molar with its grinding surface well worn down.



Fig. 19.

This form of abrasion, when discovered in time, can be very materially retarded, without changing the articulation, by inlaying blocks of gold, see Fig. 20, as represented by the letters *h*, *i*, *j*, *k*, and *e*, the method of which will be explained at another time.

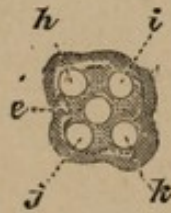


Fig. 20.

See nomenclature *h*, *i*, *j*, *k* and *e*, fig. 14.

Fig. 21 represents an eroded condition often seen upon the buccal surface of teeth extending below the gum,

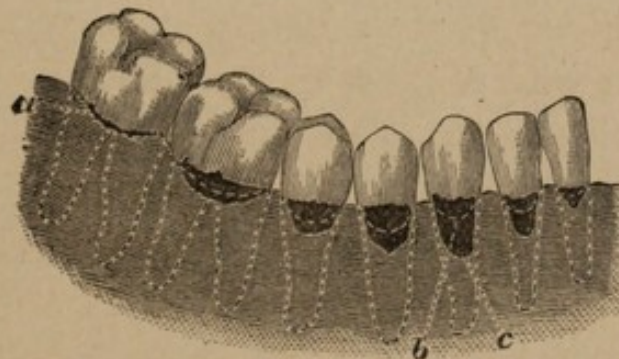


Fig. 21.

Fig. 21, *a*, represents the inception or first stage of decay often found upon the buccal surface of molars, and bicuspids, *b* indicating the gingival border of the gum, while *c* shows a more aggravated and extended form of the disease.

while Fig. 22 shows the manner of preparing such a cavity for filling, previous to operating, however, the gum should be incised and laid back, as seen in cut.

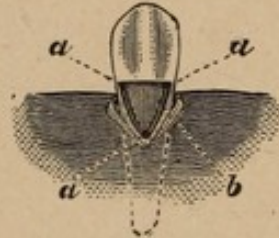


Fig. 22.

In Fig. 22, *a a a* represent the anchorage points in the angles, *b* indicating the triangular groove extending around the walls of the cavity.

It has been suggested that the use of succulent foods, by rendering the teeth less necessary, is affecting their development. This should be received with an allowance, for it is probable that we now have as perfect specimens of the human frame as ever existed among the ancients; while the weak lives preserved by modern appliances and hygiene far surpass those saved in semi-civilised nations.

After what has been advanced respecting the physiological action of abnormal secretions upon the teeth, I need only add that they are either a predisposing or an exciting cause of decay, according to the intensity, duration, and manner of their operation upon these organs, in connection with other causes and influences which may co-operate with them. The general impression that teeth of the present generation are deteriorating is owing to the fact that many disorders which are now known to be connected with these organs—fatally affecting the whole system—were formerly suffered to immolate their victims without the primary sources of disturbance being known. These cases are now placed in their proper category, and serve to swell the black indictment against modern teeth.

LECTURE V.

Delivered at the National Dental College, London, Nov. 5th, 1879.

I HAVE alluded to erosion in a general way, but shall now consider cases of a special nature, as developed upon labial and buccal surfaces of teeth; endeavouring by clinical demonstration to illustrate a means of suppressing the oral fluids from the parts to be operated upon, where clamps are contra-indicated.

Previous, however, to a consideration of the methods by which therapeutic measures may be adopted, it would be well, perhaps, to note the indications which recommend the student in the attainment of qualifications, that will permit him to assume so important a position as the care of the teeth. To preserve these organs intact is the aim of advanced dentistry, and when the worth and usefulness of the Dental Practitioner are universally recognized, and his mission fully understood by the public at large—so that the integrity of the teeth may be properly valued—the science of dentistry will stand on a higher pedestal even than it does to-day. The steadily increasing and generally diffused knowledge in the profession has so extended its boundaries that what was considered typical of dentistry is now but a minor part. Of those who aim by education to fit themselves for their coming professional duties, it may be premised that some, having adopted dentistry, and started with apparent vigour, will, nevertheless, lapse into an indifferent or apathetic condition of mind which will

result in the execution of their work becoming a mere mechanical performance.

This inaptitude is not, however, peculiar to dentistry, but may be attributed to failure of the original impulse, and a lack of that force of character which might lead to the adoption of a more suitable vocation in life.

The method best adapted to ensure success is intuitively grasped by some, while others do not reach the goal without much greater effort. In the reiterated advice to the young, which perennially appears in the literature of the day, the attempt to define talent and genius is constantly made. The first view, calculated to excite enthusiasm, dwells upon the power of labour, and describes talent and genius as marks of an innate power to work.

The other view is admonitory, and should be well considered. A slight bias or inclination to some profession is not an indication that one may enter it. The chances for or against success should be especially considered in connection with dentistry, that those contemplating it may not find themselves unequal to the prescribed task, and later become cognizant that both time and money have been misspent. Those who feel their work a pleasure may justly hope to attain to a proficiency beyond the possible realization of others, who listlessly endeavour—for it is but an attempt—to perform the duties attendant upon the routine of their daily professional life. Where a morbid condition of the nervous system is found to exist, the means appropriate to the varying phases of individual cases will not always be apparent, nor is the usually accompanying prejudice easily displaced for that of confidence. Intelligently considered, however, much may be accomplished in removing the antagonism which not unfrequently proves a barrier to good results. A due consideration of these

principles is of such serious moment to those who are intending to enter the profession that it should not be disregarded; for dentistry cannot be practised to a successful issue without a decidedly pronounced manifestation of self-devotion, allied with judgment of the adaptation of ready means at hand; thereby tending to induce a psychological condition in both operator and patient, leading to such co-ordination, that the efforts of the one are cheerfully endorsed by the other. Any unnecessary or ostentatious display of instruments tends to produce a revulsive effect, and through this moral change of sentiment, the disadvantages to be overcome will be greatly augmented. With these elements combined many obstacles to the attainment of a successful practice will be removed.

The study of the literature of Dental science places the student in communication with many minds, and introduces him to methods of thought and action, which otherwise might never originate with himself. Likewise will he almost unconsciously derive benefits from a close companionship with his fellow students, as a sequence to which there must necessarily result an interchange of sentiment, in many cases, leading on to demonstrations in order to substantiate assertions made.

To resume the subject proper, erosion is a synonym of corrosion, and means an eating away. The term, as applied to the dental organs, signifies deficiency of tooth material, and should not be confounded with caries. This imperfection may be evident at the eruption of the tooth, and is by some ascribed to adverse influences interrupting the nutrient supply to the teeth in their developmental sacs; while others attribute it to the action of acid secretion within the sac. The ulterior ill influence at this period is more of the nature of mal-nutrition than of disease, and

manifests itself by horizontal striations and grooves on the buccal and labial surfaces. In other cases the teeth, especially the molars, are pitted over with small holes, or marked with disintegrated spots; these markings will be found to follow the general rule of horizontal striation, and have a tendency to occur in lines. The deficiency is not confined to the enamel, for the dentine in the vicinity of the eroded parts presents layers of "continuous rows of globules of dentine, with their inter-globular spaces." The spongy condition of such a formation of the dentine is materially less solid than the normally calcified inter-tubular substance. The corrugations caused by erosion occur in teeth of synchronous development and eruption, and simultaneously with the disfigurement on one side, will be found an analogous condition of weakness on the other. This form of erosion is termed congenital, while that which occurs later in life is called accidental. Erosion generally makes its appearance on the vertical walls of the teeth; ostensibly occurring upon the labial and buccal aspects—it being an exception to find it upon proximate surfaces. It is found here, however, as also occasionally upon the lingui-cervical region, presenting inequalities of a parallel elongation, as if an instrument had been drawn across the surface in a direct line with the maxilla, or, as if the enamel had been scraped in lines of unequal depth, the section of the tooth presenting a form homologous to that of the edge of the imaginary instrument so pictured. These deformities frequently exhibit themselves in cavities of peculiar shape and greater development. I may specify one of them by describing it as a groove furrowed in the tooth at its cervical region. The section of this groove is triangular at its largest dimension, the side nearest the gum being at right angles to the buccal surface, the other gradually sloping in the direction of the occluding surface.

The extension of the angular floor of the cavity being but little removed from a right line, it leaves the surface on either side and has its extreme depth at the protuberance of the tooth, to which surface it forms a chord. The anteproximate surface of this seat of erosion presents the form of a partial ellipse—a conic section. Another form, much less decided in outline than the preceding, presents a depression, spoon-like in character, but with edges that blend imperceptibly with the general surface of the enamel and cementum. The formation of these cavities may be ascribed to causes extrinsic, as chemical and traumatic; though it is doubtful if erosion is developed in teeth which are not intrinsically faulty. The chemical agents of destruction must be sought for in the oral fluids; but, doubtless, in cases where the teeth are abnormally disposed to disintegration, the ordinary acidulous components of food imperceptibly combine with the morbid tissues, and may result in the formation of cavities similar to those illustrated in the following figures (Nos. 23 and 24).




Fig. 23.

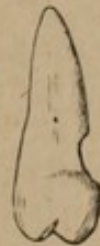

Fig. 24.

The forms of erosion as shown in the above diagrams, are sometimes produced by traumatic agencies, which of course come under the head of abrasion. Friction from badly adjusted clasps on artificial dentures may simulate erosion; this condition may also be attributed to the excessive use of the brush, or by the impingement of teeth against each other through mal-articulation, which may be original, or produced from causes incident to life,—as loss of teeth,

resulting in change of position to those remaining. As the cavity enlarges, it encroaches on territory hitherto occupied by the peri-dental membrane, thereby causing it to recede. Simultaneously with the retrocession of this membrane, we find the gum receding; the morbid influence causing decay to advance to points beyond the margin of the gum.

Erosion and caries produce similar results, but there is a recognisable difference between the two. Caries may attack teeth of apparently strong structure, and evidences of resistance to disease are manifested by layers of semi-decalcified dentine, which retain with great tenacity their connection with the normal tissues; but in erosion, portions of the teeth seem fated to complete disorganisation, the mal-conditioned parts presenting parietes of highly-polished surfaces, giving an appearance of wear, or cavities designedly made. The pulp, however, sometimes evinces, as in caries, defensive action by the formation of secondary dentine. When erosion occurs at the gingival margin, the dentine is usually found very sensitive, and its impressibility may justify therapeutic measures, so as to possibly favour the calcification of the anastomosing canaliculi, which would otherwise remain patulous and subject to varying and destructive influences. With this exception, little can be done with erosion farther than to instruct the patient in the methods of cleansing the teeth, as the indiscreet use of the brush may remove tissue, necessitating the restoration of such lost structure. When it is necessary to operate upon a cavity so formed, whether by caries, erosion, or abrasion, I have found the most expeditious, effective, and, on the whole, less painful process, to be the use of sharp instruments, with thorough and rapid execution.

The cavity upon which I shall operate this morning,—illustrated by diagrams, as well as a plaster model, with the rubber dam *in situ*, which I now pass to the class—shows the difficulties to be contended with in cases of this description. I allude to this with no intention of treating decay in detail, farther than to illustrate the application of one of our most valued agents during prosthetic restitution.

Idiosyncrasy, as manifested in some, occasions an additional trouble in the use of the rubber when applied to inferior incisors, by the spasmodic action of the oral orbicular muscle, conjoined with the elevating muscles of the lower lip—the levatores labii inferioris—which sometimes play a most conspicuously tormenting part, by, in a moment, forcing up that portion of the dam reflected over the lip, thereby obstructing from view the scene of operation, and making it exceedingly difficult to continue treatment. This spasmodic action appears in many to be absolutely beyond the power of control, and is due, no doubt, to the susceptible influence of irritating causes.

As a sequence, where these involuntary contractions of the mouth occur, an excess of the salivary fluids may generally be expected. Obedient to the sympathetic action of nerve irritation, copious exudations of a viscid character flow from the glands into the oral cavity, filling it with a muco-gelatinous effusion that barely finds escape through the saliva ejector.

The effective adjunct just mentioned, prevents overflow from the commissures of the lips of the accumulated secretions, with its attendant train of annoyances.

In adapting the rubber, it is important to accurately calculate the distance intervening between the teeth, in order that corrugations formed by excess of the material may not encroach upon any portion of the structure in-

tended to be operated upon. For if the perforations be made too far apart, the rubber intermediate between the teeth will form convolutions and radial eminences, obstructive to the objective point at which attention is engaged. Again, should an insufficient space be left between the apertures, the work will be jeopardized, or at least delayed, by the seeping in of moisture upon the filling; while if the holes be cut too small, difficulty will be experienced in endeavouring to place it on the teeth without tearing. The other extreme, that of cutting them too large, may be considered quite as dangerous, for, in that case, the rubber will fail to contract upon the teeth to an extent sufficient to exclude all moisture.

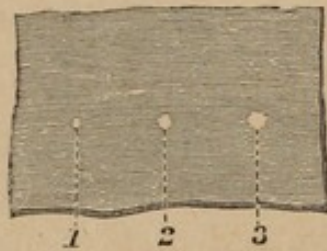


FIG. 25.

The illustration which I now pass to you shows the average three sizes of perforations required when using rubber upon laterals, bicuspid, and molars, of ordinary dimensions; exceptional cases, of course, requiring special adaptation.

For example, when placing the dam on three teeth, the central perforation being applied without tension to the intermediate tooth, the remaining apertures will fall in the vicinity of the proximate surfaces. The first extension carries the holes to the medial points of the crown of each of the three teeth in question, and is made at the expense of the rubber lying in a line with the maxilla, resulting in a proportionate elongation of the holes themselves.

This extension is then supplemented by another perpendicular to the first, which, conjoined with compressing the rubber on the tooth, enlarges the apertures at the expense of the elastic material (1st) on the sides embracing the lingual and buccal aspects, and (2nd) between the teeth. The portion so expanded is limited to a circumscribed area of distension, and is almost wholly expended in the formation of a rim round the tooth, which may be designated a collar. As the compression passes over the tooth the circumferential edge is retarded, and forms a collar inverted in the opposite direction to that required. This is remedied, however, by carefully working the edges of the rubber upon the cervical portion of the tooth and underneath the gum until it forms a matrix, involute in shape, between the hard and soft tissues. The effect of the extension of the rubber is to cause it to invade the greater portion of the interdental regions; but if the mutual distances of the perforations have been carefully estimated, a neutral line will be left, which, although affected by the general distension in length, has not sufficient tension to draw the dam away from the adjacent teeth, thereby causing apertures for the intrusion of moisture. On the selection of the rubber, much will depend as to the comfort and convenient manner in which the operation may be performed. If too thick, the collar will not be easily reversed in its position and carried to the point desired, besides, it greatly complicates matters by an excess of material which must necessarily encroach upon territory that should be left free. On the other hand, should the rubber be too thin, the power of the distended portion would be so abridged as to diminish the collar in size, and consequently its tenacity in resisting the aggressive fluids; also, the substance of the material between the teeth would be so attenuated, that the slightest mis-

calculation in leaving a deficiency between the original perforations, would greatly aggravate the case.

The rubber, when adjusted over convex portions of a tooth, extends in a direct line, from point to point, across any intervening concave surface, leaving a small segmental space unprotected (see Fig. 26.)

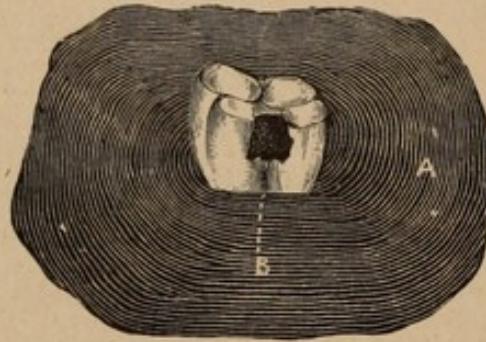


FIG. 26.

The dotted line B points to an interval—a versed sine, as it were—between the rubber and tooth.

When a cavity extends to or near the gum, it becomes necessary to depress the rubber to the required curve by the use of spring appliances. The depression being downwards only, and the tooth below the cavity concave upon its surface, the direct downward pressure will not fill this lateral retrocession, and an opening for the admission of the fluids of the mouth will be left, unless an available compress against the base of the concavity is devised. In some cases, cotton moistened with sandrac varnish may be packed underneath the rubber, and a spring appliance used to press upon the cotton, and against the cervical walls of the tooth. To illustrate such a cavity, Fig. 26 represents the ante-proximate concave, cervical wall of a molar tooth.

Referring to Fig. 27, the difficulties to be surmounted are at once apparent, as the tendency of the rubber dam

when forced beyond the gum is to seek the level of the festooned border. The means usually employed in similar cases is the adaptation of a clamp—reniform—to the tooth, the portion to be applied to the labial surface being aciform, while the other, to be placed on the lingual aspect, is bifurcated; it however cannot be considered free from objections, as it obstructs the light and impedes the hand in its action; as will be seen by reference to the following figure:—

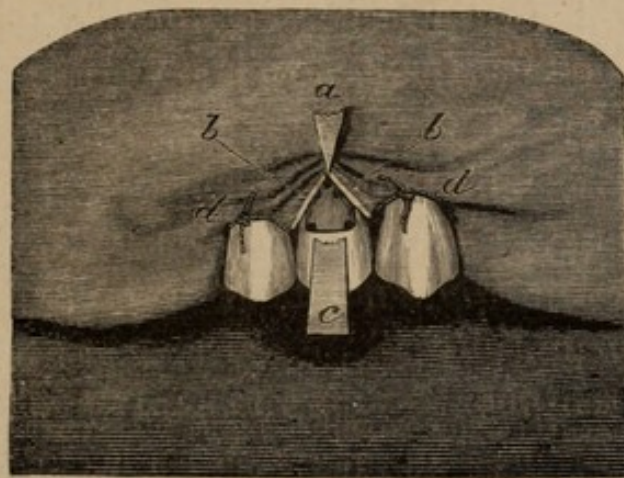


FIG. 27.

The above represents the rubber adjusted on a bicuspid with a clamp, broken, the upper part of which is thrown back to fully expose the morbid part being operated upon.

a, Aciform extremity of clamp laid back, but with its point in position on upper edge of the cavity and between the incised portion of the gum.

b b, Rubber, extending from point of clamp to the inter-dental spaces, showing reflected edges upon the cavity, with open segments on either side.

c, Arching portion of clamp, a continuation of the broken part of which would partly conceal the cavity and the point of the clamp.

d d, Ligatures.

The peculiar shape of the cavity, Fig. 27, nullifies any advantage this clamp may possess, for with the most

careful adjustment it will only retain the rubber at one point, nor can any other clamp be selected presenting pre-eminent merit. When caries extends to a point beyond the margin of the gum, that portion of the clamp placed on the lingual aspect of the tooth not unfrequently is the cause of so much suffering, that the patient insists on the abandonment of the work. For this reason I have endeavoured to dispense with its use, adopting a method which I shall now describe previous to clinical illustration.

It will be noticed, when adjusting the rubber, that its collar-like formation serves to steady it in position; but when forced beneath the festooned border of the gum on either side of the tooth, and at the same time depressed below that level on the other, the elasticity of the material continually inclines the collar to return to the horizontal equilibrium. Without a projecting point on which to retain the rubber, such a return would soon occur; but if a prominence, sufficiently abrupt, be established on the surface of the tooth, this progressive motion will be arrested (see Fig. 29). This can be effected by building the gold beyond the edges of the cavity until it forms a ridge following the sinuosity of the edge of the cavity, upon which the rubber can rest. After dissecting away a portion of the gum—an interval being allowed for the cessation of hemorrhage—the dam is to be adjusted on three teeth; the tooth to be operated upon occupying the central position. The adjustment of the rubber on the adjacent teeth is preserved against derangement by the additional precaution of a silk ligature round each tooth. The next stage of the operation is now entered upon—as shown in Fig. 28—and consists of the withdrawal, by digital compression, of the dam from the proximity of

the cavity. The tension of the rubber being considerable, extending to the orifices through which the proximate teeth are passed, results in the encroachment of the fluids of the mouth on the territory to be operated upon; and only by careful ligation, previously alluded to, can the retrocession of the rubber from the associate teeth be prevented.

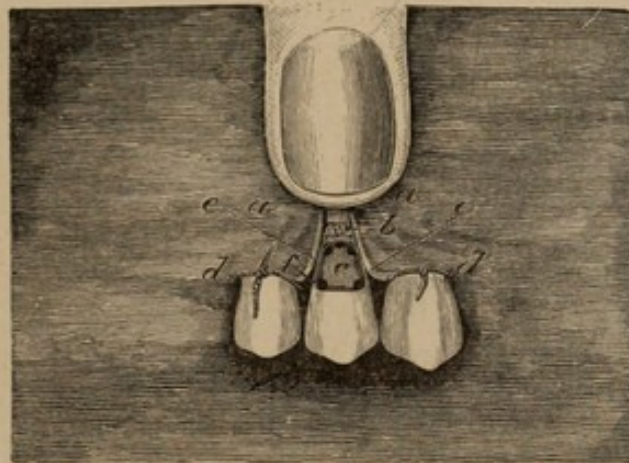


FIG. 28.

- a*, Showing point at which rubber is confined by digital compression.
- b*, Incised edge of gum.
- c*, The cavity.
- d d*, Ligatures upon the canine and second bicuspid.
- e e*, Edges of rubber.
- f*, Anchorages, five in number.

This diagram is intended to illustrate the preparatory steps and first stages of filling, previous to removing the finger from the rubber, which is firmly held in position as so delineated. The superstructure is then commenced by building in the three anchorages which are made in that portion of the tooth hitherto overcast by the festooned border of the gum, carrying the gold up in a divergent line, extending crescentic shape until raised above the general level of the tooth. The length of this preliminary portion of filling should be sufficient to prevent

the funicular formation—caused by the distended portion of rubber—from encroaching upon the mesial or distal edges of the cavity. The prominence, which we will designate a reef, is supported by additional gold until its position as an abutment is secured. During the period of the forcible retention of the rubber it is continually inclining to release itself, and on the withdrawal of the finger contracts upon the gold which is then worked over and upon it, as shown in diagram 29.

In the use of the clamp, as shown in Fig. 27, the preparation of the cavity differs in this respect, that instead of five retaining points, three only are necessary, each of these being located at the extremity of the angles. Fig. 22 more clearly illustrates the method of preparing such a cavity, the triangular groove extending around the outer boundaries of the cavity being clearly delineated, with the anchorages defined therein. But in the figure before us (28), instead of one, three anchorages are required in the apex of the cavity, to assist in building the lunate arch which is to resist encroachment of the rubber upon territory absolutely necessary to be protected.

The advantages secured by this method are so important that I shall discuss them at full length. The generally diffused, but gentle pressure of the rubber in its tendency to return to its original shape is met by an equally uniform resistance; every point of the edge of the elastic material, when coming in proximity with the curved periphery of the cavity is met and contested by the gold reef established at the cervical border—the pressure being almost imperceptible in its contractility on the tooth and parts contiguous. The cornua of the golden crescent are so widely separated as to prevent the rubber trespassing again upon the edges of the vertical walls of the cavity.

Looking at the figure, it will be seen that from the distance to which the cavity extends below the general gingival border, any clamp which might be applied on the cervico-buccal aspect would inevitably cause pain by pressure on the lingual gum. In such an instance, it is compulsory to place the clamp in a vertically-oblique position, while its tendency to contract causes it to advance upon the lingual wall of the tooth, acting in an aggressive manner upon the gum, and resulting—as already stated—in discomfort to the patient, which increases the difficulties to be contended with.

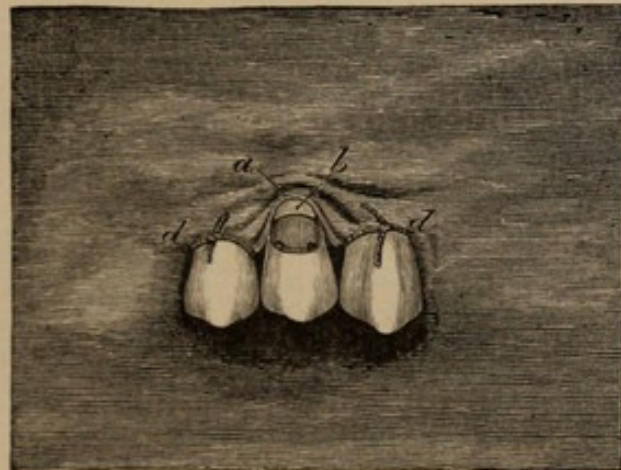

FIG. 29.

a Shows the rubber contracting upon the collar-like formation of gold *b*, which is built, crescentic shape, upon the cervical portion of the tooth; the outer portions indicating points to which the filling is to be built previous to relaxing pressure upon the rubber.

d d, Ligatures.

But there being an entire absence of painful pressure in the method now described, it becomes possible, *cæteris paribus*, to combat the influences that otherwise might frustrate every measure put forth.

Before concluding my remarks upon the rubber, I may add that it should not be kept on hand in any great

quantity, as it suffers a subtle deterioration by age, becomes rotten, and therefore valueless in cases where its use is most essential.

Experiments made on the india rubber of commerce prove its degenerating qualities, for when exposed to light it has been found to absorb oxygen; "five hundred grains of virgin caoutchouc, cut into the form of a tape," gained "14 grains in the course of nine months," "by absorption of oxygen; it became brown, soft and sticky." "It gave up 11.81 per cent. of an oxidized, soft and viscous resin to alcohol;"—which indicates that the rubber dam sheeting should be excluded from light and air as much as possible.

This last remark may be appropriately made in regard to most of the appliances of operative dentistry: as the condition of the instruments, the working qualities of gold, and the elasticity of the rubber, are each of them more or less affected by any unnecessary exposure to atmospheric changes.

LECTURE VI.

• *Delivered at the National Dental College, London, Nov. 12th, 1879.*

OPERATIVE Dentistry, like surgery, has its separate relations, on the one hand, to pure thought and deduction, and on the other, to mechanics, by which latter I mean the dealing with bodies and forces, whether they be the teeth or the application of instruments.

Dentistry however, cannot be contemplated as an abstract study, although the time may come when we shall have consulting Dentists as we now have consulting Surgeons.

Of æsthetic dentistry it must be admitted that theory is effective commensurate only as it is blended in an intimate relationship with practice; and, in support of this opinion, I shall conform to the indications that I believe justify me in making the assertion.

Having reviewed the different forms under which disease may manifest itself in the teeth, your attention is now directed to the following sections of the classification made in Lecture II., viz. :—

6th. Preparation of cavities.

7th. Introduction of gold into cavities.

In calling attention to these two sections, I do so with the object of investigating their direct bearing upon operative dentistry as a whole, in connection with the

speedy accomplishment of purposes to be attained in that department.

I apprehend that your aim is to acquire proficiency that will enable you to deal with matter in its various forms, for purposes therapeutic or prosthetic; so that the training of the hand must, for the overcoming of material difficulties, accompany the acquisition of knowledge. For this purpose the student should endeavour to witness operations of varied character, which, in his coming professional life, he may be called upon to perform.

A quick comprehension of the exact requirements of each case, with the power to effect a rapid execution of the same, will materially advance those engaged in the study of dentistry. The "value of minutes" cannot be overestimated while operating, so that the perfect arrangement of instruments previous to that period may be considered a distinguishing feature in the preparations made. This minute attention to detail, however, must not engender habits of laborious idleness, or detract from the concentration of thought which embraces an entire operation before its commencement.

Each application of the instrument should be made with a specific object, and, the moment that object is attained, the next process must follow in quick succession. If a rest be required, it is to be distinctly taken as such, and not indulged in at the expense of time employed in the operation. An awkward or irresolute manner of selecting an instrument is an evidence that the brain and hand are not in unison. By rapid manipulation I do not wish to convey the impression that I favour undue haste, involving uncertain action or jeopardizing the work. But a waste of time is to be deprecated in operations of an extended character, and this, in a measure, can be avoided by a well-defined and accurate calculation of the requirements

of any particular case, conjoined with a systematic carrying out of the same.

Refrain from unduly sacrificing any portion of the healthy tooth structure; yet do not hesitate to use the instrument freely upon all surfaces presenting a doubtful appearance,—following out the decay, whether interstitial or superficial, to its periphery. Previous, however, to the introduction of gold, presuming that the several walls are carefully shaped and dressed, the finest emery paper may be employed to nicely polish the outer edges of the cavity; as there will always be a feathery or notched condition of the external enamel after the most careful preparation with instruments. When teeth, standing closely impacted, are decayed upon their proximate walls, it is necessary to wedge preparatory to operating, that a proper inspection may be made along the facing surfaces. As a rule, complete exposure of the parietes, as well as of the floor of the cavity, should be made previous to the introduction of the gold; for, if the operation be conducted under the disadvantage of an uncertain light, there must necessarily exist some doubt as to the stability of the work performed.

In shaping the cavities, I would discourage the formation of severe or acute angles, for they are not so easily or solidly filled as when the surfaces are united by a portion of a circle. The walls are also strengthened by this, while an angle is likely to favour the formation of a fissure at the angular point. Having a knowledge of the ramification of the canaliculi with their life-sustaining circulation, which is by some believed to exist in them, try to form the walls of the cavities in lines running—as nearly as possible—in the direction of the dental tubuli. Although theoretically correct, this cannot always be carried out, as the cavities would, in many instances, be the shape of

an inverted truncated cone. But, if this object cannot be attained, the aim must be to so shape the cavity that it shall not exceed the perpendicular, thereby avoiding undercutting, which, by widening the floor, must necessarily divide many of the anastomosing ramifications. Undercut cavities do not, as a rule, retain the gold so well as those with vertical walls. Although that form of cavity may prevent bodily expulsion of the filling when loose, it cannot be estimated as an advantage, for a detached filling is better lost than retained in its uncertain tenure of position, deceiving as it does the patient, and not unfrequently permitting caries to extend without the invariable warning being heeded—this false security causing, as it may, the ultimate loss of the tooth.

Reviewing the different stages under the classification as given in Lecture IV., I will now direct attention to the first, viz.: "The inception of decay with primary evidences of disintegration."

In Fig. 16, No. 14, *a*, *b*, and *c*, is illustrated this stage, while in Fig. 29a is shown the method of preparing and filling the same. I have already in general terms described morbid tendencies as exhibited in the teeth, and, from the fact that these early indications of disease are apt to receive hurried attention, I have endeavoured, by the diagram before you, to illustrate cavities of this description as filled. Here it will be observed that the restoration, as exhibited on the plan of the teeth, may be irregular or even stellate. Disease as herein pictured often commences in an insidious manner, giving but little warning of the extensive waste of tissue; but it is sometimes manifested in a form so pronounced that its presence becomes a declared fact at once. The progress in the one is generally slow, in the other much more rapid. If the decay be superficial, with retarded

action, it is an indication that nature is assuming the defensive by active resistance to the destructive agencies engaged upon the remaining healthy tissue.

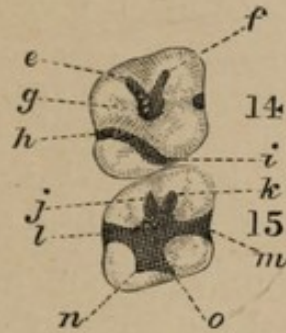


FIG. 29A.

In Fig. 29A, subfigure 14, *e, f, g*, may be seen a cavity filled in the ante-proximate-medial point, extending along fissures in the direction of the ante-buccal-medial and ante-lingual-medial points.

In the post-proximate-medial point, the filling extends from the lingui-cervical portion of the tooth, to the post-proximate point, *h, i*.

In subfigure 15, *j, k, l*, and *m*, represent a filling as previously illustrated in decay; while *n* and *o* shows the general breaking down of the structure between the previously existing interstitial points, with a coalescing of the same.

Although subfigure 14 in the above, depicts the first stage of disease, it likewise delineates a feature in the preparation of cavities that I may not again have an opportunity of so plainly illustrating. In this figure the greatest depth of the caries is at *g*; *e* and *f* showing the termination of superficial decay, at which points are located anchorages. Situate in the post-medial region will be seen a filling, the necessity for which was caused by decay that had extended transversely across the tooth, radiating from a point in the post-medial to the lingui-medial region, as shown at *h*, and to the post-proximate, as shown at *i*. This form of decay sometimes winds over and upon the lingual wall, until it gradually fades away upon the cervico-lingual border of the tooth. Sometimes upon the occluding surface of the lingual

border is found a malformed cusp, with its base surrounded with fissures, some of which are very deep. When decayed at its base, it is better to remove the cusp, and restore its friable foundations to the normal contour of the tooth.

In subfigure 15 we have, radiating in every direction, a restoration of the lost portion of the tooth by filling in the deficiency with gold. The letters *j*, *k*, *l*, *m*, *n*, and *o*, represent the extension of decay, but the filling being superficial in these distal points, and therefore deficient in resistance to change of form, anchorages are necessary in each of the angles and peripheries indicated by the letters. Here will be found an arachnoid spread of caries, which, continuing in the interstices, radiates in every direction from the central point of offence. When these lines of disease are left, they not only increase and insidiously undermine the filling, but they frequently invade the pulp chamber, before any appraisal of danger is made to the patient. It is not necessary for me to add that on the careful restoration of these interstices depends very much the permanent retention of the filling, for the restorations of gold, in this case, are but filaments lying in channels of diminutive size, and would be forced from their point of contact with the tooth, unless well anchored at their distal ends.

Particularly should it be observed that every joining edge be perfect and exactly adapted so as to continue the minute deviations and changes of surface which will occur within very limited spaces on the teeth. This important condition being absolutely fulfilled, the circumscribed outline of the filling considered as a solid of irregular form, will mathematically coincide with the boundaries of the cavity. To better define my meaning, I would have you notice the different characteristics in the ante- and post-

medial cavities; the one being circular in shape, while the other is nearly transverse and extends sometimes beyond the occluding surface and over upon the lingual wall. These cavities require more care than skill, yet it is not an infrequent occurrence to find the operations indifferently performed; especially may this be looked for in the post-medial cavity, where by the undermining of the work, it becomes necessary to treat the second stage.

In the inferior molars are also found several depressions, favouring the invasion of disease; and, when decay simultaneously manifests itself in two of these dips, the intervening wall is soon broken down, resulting in a merging of both cavities into one. Then, again, there are found small grooves or sulci, diverging at right angles across the tooth, which, unless cut out to their extreme distal points, must necessarily involve the destruction of any work bestowed upon them. These irregularly creeping clefts indicate defective calcification or unification of the enamel, the columns having failed to coalesce at these lines of juncture. The fissures, although imperceptible in a hasty examination, have walls diverging as they approach the dentine, where a morbid condition is induced by the infiltration of the fluids of the mouth through this gateway into the body of the tooth, the dental tubuli fast disappearing under the influence of these corroding agents—disintegration continuing until the disease assumes a more pronounced form.

In the commencement of decay upon the buccal walls of lower molar teeth, where a softened condition of the dentine is found running up to, or near the occluding surface, it is required to use the fissure bur. In the medial-buccal surface, where the cavity is small and circular in form, the fissures above and below being pronounced, are to be cut out and filled, thereby preventing

extension of decay, with final loss of the filling. This must be followed out until there shall exist no points intermediate between the central cavity and the peripheral ends of the excavated channels not fairly opened and fully exposed to view.

Before taking up the second section of our subject, I shall occupy a few moments in reviewing some of the incompatibles with gold.

It would be supererogatory to speak of its metallurgy further than to mention that, by various chemical processes, gold is supposed to be prepared absolutely pure for dental purposes.

When we consider that a "single grain, the first cost of which is about twopence, can be beaten out into leaf which shall cover 75 square inches," its wonderful adaptability is at once apparent, so that it becomes only a question to decide in what manner it can be most effectually manipulated for dental purposes.

Considered in its purity, there are many opposing agents in connection with its use that require to be stringently guarded against; and the cause for the recognised differences of "cohesive" and "non-cohesive"—under one or other of which all the preparations of gold used in filling must be included—can only be attributed to peculiar molecular arrangement of its particles, culminated by the mechanical and chemical forces which have been brought to bear upon it.

The condition under which it can exist as a simple body is limited within narrow bounds; for, by the process of annealing, which is simply heating to a blush under certain precautions, the non-cohesive is immediately changed to cohesive. The recognised differences are simple, but there are unrecognised causes of failure which occasion-

ally manifest themselves to the chagrin of the operator; the origin of its intractability being occult or undefinable.

The cohesiveness of metals, like gold and lead, in the solid state, depends upon a chemically clean surface. In the lead such a surface exists at the moment of its being cut. But lead oxidizes, and the thin film so formed very soon prevents cohesion. Gold, a metal of higher virtue, does not so oxidize; therefore, with proper precaution it may be preserved cohesive for an indefinite period.

But, however pure, it possesses the common liability of bodies to come under the influence of the laws of adhesion and condensation. Therefore foreign substance, as moisture, smoke, the motes of the air, exhalations, and a lack of precautionary measures in removing from the fingers the natural sebaceous exudation, which continually rises to the surface of the epidermis, will act as impediments to its use. Any one or all of these may cause a thin film or deposit, which, although imperceptible to the unaided senses, may be subversive of that condition of surface which alone ensures perfect cohesion.

Experience has shown that, owing to peculiar atmospheric changes, or from reasons not traced, the gold has been capricious or has worked with less facility on certain days. The causes for these irregularities, I believe, would be found as taking their origin in periodical emanations from the busy centres of industry and social activity, towards which the dentist naturally gravitates. That these atmospheric or other hindrances may, as far as possible, be overcome, it is better to procure and retain the gold in a non-cohesive state until required, when it should be properly annealed.

Gold is manufactured into many different forms, among which are ribbons, blocks, cylinders, pellets, crystal, or

sponge; also heavy foils, of No. 20, 30, 60, and even higher numbers are employed, but No. 4 has thus far stood firmly to its position in advance of all other preparations for general use. The heavier numbers, like sponge, or crystal gold, seem to have had a spasmodic popularity only, for at present both are used in a much more limited way than heretofore. Foil is used cohesive as well as non-cohesive, and both have answered a very good purpose; some claiming a preference for the soft. Unquestionably, gold, in its non-cohesive state, is a much safer material in the hands of an inexperienced or indifferent operator; and I am firmly of the belief that cohesive foil has been an injury rather than a benefit to the profession at large, as it is generally used. Knowing this to be the case, the peculiarities of this metal should be studied.

The resisting properties of gold to corroding influences, as well as its ready adaptibility to the inequalities of the surface to which it is applied, causes it to occupy an unimpeachable position as a specific metal to oppose the influences of morbid changes in the teeth. Should there, however, be any dereliction in observing the conditions of its use, these natural attributes seem to become perverted, presenting to the mind a parallelism to moral depravity; for, while a portion will be amenable to the instrument, there may be an abrupt refusal on the part of the remainder to coalesce, becoming harsh and quite intractable to the purpose for which it is intended.

Cohesively used, however, it possesses undisputed distinctive qualifications as a material for general adaptation over that of gold in a non-cohesive state, and renders many operations—especially in the more advanced stages—possible, that would not be attempted with other material. But the conditions under which it may be employed to secure the full benefit of its co-adapting qualities

are so complex, and the inherent difficulties of its application so great, that many operations have failed, not from want of virtue in the material, but from the practitioner undertaking that which was beyond both his powers and experience, and which, with only soft gold to rely upon, would have resulted in the selection of a material more effective in such hands. These failures have been laid at the door of the profession generally,—and to cohesive gold in particular—instead of being attributed to the temerity of some of its members. The plausibility of its use in a cohesive form has been a snare to many, for, although this attribute has its intrinsic value, yet the indications to ensure this primary recommendation are such that the neglect of any of these particulars may endanger the work in cases where necessity for its use is demonstrated. Therefore its employment in a cohesive state has not resulted in an unmixed benefit to the profession; in fact, from the reasons stated, so many of its fine working qualities have been negatived by indifferent manipulation, when employed in cases where its application was contraindicated, that it has been unfavorably commented upon.

I wish to lay particular stress upon the advantage of procuring gold in an unannealed condition. With every precautionary measure upon the part of the manufacturer to prevent change in the foil, previous to its transmission for use, the various causes I have enumerated are ever antagonistic to the preservation of the virtues which particularly recommend it as a filling material. Should a state of pronounced declension be established a series of complications, greatly to be dreaded, may result. When recourse is had to a second annealing, it will be found, contrary to general expectation, but established as a fact, that the better nature of the gold will be still more perverted, and that it will become stiff, harsh, and tinny.

The simplest application of the foil is in interstices, in grooves, in pulp canals, and very small cavities, where cohesive gold is used by being torn piece by piece from the leaf, with annealing pliers. But in cavities of larger dimensions, the leaves, whether cohesive or otherwise, may be used in a manner adequate to the size of the cavities. Various methods are adopted in preparing it previous to its introduction into the tooth, to enable it to be directed with accurate precision to its destination.

One of the forms favorable to use, presents a flat surface. By folding the leaf into four—that is to say, twice in the same direction—a parallelogram is obtained, equal in length to the original sheet, but of one-fourth its width. This folded leaf of gold is then subdivided by cutting across its smaller extension at distances varying from $\frac{1}{8}$ or $\frac{1}{2}$, to a full inch apart; these quadrupled bands being always of cohesive gold.

The folding is at the convenience, or personal inclination of the operator, into fourths, thirds, half of, or even a whole sheet. In the latter cases, the foil is usually rolled into ropes—preferably with a napkin—to effect that purpose. Where the foil is to be used cohesively, these ropes are cut into convenient length, and annealed by being rapidly passed through the flame of a spirit lamp.

Another method of preparing is by crimping, and this is accomplished by laying the leaf on a tin plate, one end of which is bent at right angles to the plane of its surface; while another plate similarly reflected is placed upon the first, the bent ends being on opposite sides of the foil. Guides preserve the parallelism of the plates, which, when drawn in opposite directions, cause the gold to become crimped in proportion as their turned margins approximate each other.

Soft gold, being rolled into ropes and introduced into the cavity, is impressed in layers until it rises above the orifice. By impaction it becomes fixed in position through mechanical force, friction and interlocking. Where there are good walls against which to pack, great solidity can be obtained, and the filling made impermeable and lasting. Soft gold, in rope form, is perhaps the most expeditious method of filling, and, in some cavities, proves an excellent preservative of the teeth.

Many of the imperfect and porous fillings so often seen, result from a too rapid packing, and using gold that is too thick; then again it is often pounded until it really loses much of its cohesiveness; instead of packing against the walls of the tooth, it is driven from them—the excessive vibratory motion partially destroying the close contact previously attained. Light and prolonged tapping will better unite the particles of gold, and also cause it to more readily adapt itself to the interstices in the walls of the tooth when used thin, and introduced with gentle force into the cavity. By an intelligent appreciation of the necessity for co-adapting the molecules, and in proportion to the mass to which force is to be applied, it may be stated that the use of small instruments in condensing will give greater coercive force to its particles than could be accomplished by more diffused, though heavier blows. The necessity for *delicate, rapid, and light manipulation*, cannot be over-estimated in operative dentistry, as it is the *acme* of our profession. *In fact, manipulation may be considered the apex of the pyramid, the base of which is knowledge and practice.*

It may be supposed that more time has been devoted to this primary stage, and the concomitant preliminary measures than they deserve. The importance, however, of effective treatment at the inception of disease, to pre-

vent the following stages, has its full significance, for upon accurate views respecting it, altogether depends the success of measures adopted.

Your labors will be greatly augmented by causes physiological and psychological, which will admit of no overdraft being made on your stock of vital energies, and, for this reason, I shall endeavour to show in my demonstrations this morning the advantages to be derived from sitting, when engaged in protracted operations.

Although you may not be able to occupy that position continuously, sit as much as possible, even though it be but for a few moments at a time.

The vivid appreciation of the sensitiveness of the field of operations is no mean factor in causing bodily prostration, and I would advise you to adopt every expedient that may relieve you from this waste of nerve tone. To combat these depressing influences you must particularly observe the physiological laws which protect you from results traceable to clearly definable causes.

The very nature of the work which you will be called upon to perform, as well as the compulsory position of the body to be assumed, will speedily draw upon the reserve of physical power, and, should a certain point of exhaustion be reached, may result in perplexity and annoyances little anticipated.

In some cases, there will be found an electric or magnetic sympathy, placing both patient and operator in full harmony; but, in other instances, they may be in a negative condition, expressing either by word or gesture—equally well understood—the existence of such a state of things. This being known, such measures as might prove effective should be adopted to suppress the evil.

Success may lead you to overlook the healthful disciplinary measures of a regular conformity to system; con-

spicuous among which is the disregard so often evinced concerning fixed hours for meals. The muscles require a reserve of strength, although the touch should be gentle, applied with firm pressure, and directed by the tension of opposing and delicately graduated forces; and this cannot exist without a due observance of this most important principle of health. An atonic condition of body will cause irritation, at a time when contingencies may arise calling for efforts of the most unexpected nature. It is a knowledge of this which brings a sense of responsibility that, unless combated by physiological agencies, may lead to consequences most disastrous; while attention to the ordinary laws of health permit unity of purpose, cheerfulness and an activity of body, the result of energy produced by a normal *vis a tergo* in a healthy organism. Your occupation will be such as to preclude the necessary bodily exercise in the open air, unless the manner of conducting your practice is methodically and systematically arranged; this principle to become a law and unchangeable. None of the professions demand such close observance of hygienic rules as the one you have chosen; and, unless precautionary measures be adopted, your quiescent life will so act upon the mind as to cause it to become susceptible to the influence of morbid impressions and irritations, a diathesis which may be directly traceable—in too many instances—to a lack of mental tone, concomitant with a physically depraved condition.

Considering the important relation of the respiratory to other organic functions of the body, too much care cannot be given to the ventilation of rooms. Especially should this be observed when selecting a room in which to operate, the essentials being unobstructed light, high ceilings and space, that a ready means for free circulation of air may be obtained whenever required. It is a misconception of one

of the most essential conditions to operate in a small or close room; and is objectionable in many ways, prominent among which may be mentioned oppressiveness—producing a state of things that will have a marked tendency to interfere with comfort. This, added to the reasons already mentioned, will very materially influence the character of your work.

LECTURE VII.

Delivered at the National Dental College, London, November 19th, 1879.

REPLANTING TEETH UNDER A NEW METHOD.

Synopsis:—Excising the roots, and capping them with gold when denudation has taken place, with the view to arrest absorption; and tubing through the roots for drainage in cases of abscess and extreme periostitis.

IN introducing the subject of returning teeth to their natural sockets after removal, it is necessary to preface my lecture by a few remarks explanatory of the position occupied by me concerning replantation. I perfectly understand the disfavour under which it rests with the profession generally, having patiently followed the arguments so decidedly pronounced against it; and, remembering this, I have carefully pursued my investigations, until I am prompted to ask, is it not barely possible that Hunter may have advanced the theory of Replantation, the outgrowth of his physiological investigations, that has been problematical because not understood? Profound as he was in research, and conspicuous over others in his anatomical experiments, we are compelled to consider this emanation, as coming from a source to be respected. That, in the absence of the pulp, the low conditioned vitality of the tooth membrane gave him a wide range for thought, culminating in his planting teeth in structures of a similar low conditioned vitality.

Transplanting is a feature in surgery that seems to have been practised by him with more than ordinary pleasure. This, however, I believe can never become popular in the hands of anyone, even the most careful, owing to the difficulty of finding teeth corresponding in form to those lost. While I cannot endorse the treatment for general practice, there are exceptional cases in which teeth may be transplanted, and prove valuable organs for many years. I can well understand the enthusiasm with which Hunter pursued his investigations upon this subject, and it seems evident he was sincere in the belief that he had made a discovery in surgery that would result in great benefit to humanity. He says: "I consider when this practice is attended with success, there is a living union between the tooth and socket, and that they receive their nourishment through this. My reasons for this supposition were founded on observations made in practice itself, for I observed they kept their colour also upon experiments on living animals. I took a sound tooth from a person's head, then made a pretty deep wound with a lancet in the thick part of a cock's comb, and pressed the fang of the tooth into this wound, and fastened it with thread passed through other parts of the comb. The cock was killed some months after, and I injected the head with a very minute injection; the comb was then taken off and put in very weak acid, and the tooth being softened by this means, I split the comb and tooth into two halves, in the long direction of the tooth. I found the vessels of tooth well injected, and observed the external surface of tooth adhered everywhere to comb, by vessels similar to the union of tooth with the gum and socket." I quote this from Hunter's writings, not with a view of advocating the practice of Transplanting teeth, but as an argument in favour of Replantation under certain conditions of disease;

and it would appear that this latter mode of treatment did not originate with Hunter, for it had been practised prior to the time of his writing upon the subject. My endorsement of Replantation extends no farther than the confidence inspired from observations where this treatment, in conjunction with capping and tubing, has been successfully followed when other methods have failed. I would again qualify my remarks by saying that I am a believer in this new mode of practice only to the extent in which I have *seen* beneficial results *practically demonstrated*; and while I am favourably impressed with this treatment in certain cases, it is as yet too new to positively predict any future position it may occupy in the profession. I submit, however, for your consideration this evening, a few of the cases that have been under treatment by me in this new way during the last eight months; these number twenty-one. In forty-five other cases I have filled roots and crowns and replanted.

In the opening of these lectures I dwelt very briefly on the histology of the teeth; I shall now revert to it again with a view of more fully explaining the conditions under which a tooth having been dismembered from the body may again be re-established to a comparatively normal condition of health; and to better illustrate my remarks, I have had this model prepared. The three hard tissues of the tooth are formed of plaster of Paris, the pulp of wax, and the vascular periosteum is glazed on with oil colour. No very marked difference in colour could be used to distinguish with truthfulness the enamel, the cementum, and the dentine; but I have had the hexagonal prisms of the enamel, the lacunæ and the canaliculi of the cementum, and the interglobular spaces, canaliculi, &c., of the dentine engraved on the sectional surfaces presented to view, so as to give a more comprehensive idea of the tooth structure.

In the formation of the teeth in the gum covering the previously existing jaws, we see the building up of a remarkable organisation, extraneous to the superior and inferior maxillary bones, though secondarily and indirectly united with them to form a part of the oral cavity, and especially to serve the purpose of mastication. Resting in the alveolar process surmounting the jaw, the teeth are surrounded with life-giving tissues up to the commencement of the enamel cap; nerves, arteries,* and veins enter the pulp through the apices of the roots and ramify, intermingle, and interloop themselves in the pulp, supplying pabulum to the dentine, while the process of calcification goes on. Upon the cementum, and between it and the alveolar process, is situate the vascular periosteum; vessels enter the periosteum from the alveolar process, the gum, and the pulp vessels, and form themselves into a fine network or plexus throughout the whole of its structure.

We see then that the tooth is well cared for, externally as well as internally; and, in a normal condition, the possessor of this exquisite piece of mechanism is scarcely aware of its existence. When, however, caries enters the domain, piercing the citadel of the living pulp, a death blow is struck to that tissue, and with the loss of the pulp, the periosteal membrane alone is called upon to supply pabulum, apparently necessary to nourish what would be otherwise almost a foreign substance in the jaw. Here again do we see a wonderful provision made by nature in an emergency of this kind, by the periosteum, when not impaired by disease, assuming a long continued devotion to this portion of the animal economy, which would otherwise be rejected.

The tooth being extracted, the living periosteum with its plexus of microscopic vessels is, in part or entirely,

* It has been questioned by some as to whether the circulation in the pulp is arterial or capillary.

removed with it. The tooth is filled, as will hereafter be described, and in a short time after being returned to its socket, adhesion occurs, and the tooth is again nourished, but not to its original perfection, yet sufficient to restore it to usefulness. Circulation in the periosteum is re-established, but whether the pre-existing vessels become the channels of the blood—which is not at all likely—or there is a new system of vessels developed, as in union by adhesive inflammation, is a matter for enquiry.

The reason replantation has not been more generally followed is, perhaps, that up to the present time it has continued experimental in hopeless cases for treatment in the mouth, successes being counterbalanced by failures. In the incipient stages of periostitis leading to alveolar abscess, nature provides a remedy by the process of absorption of the products of inflammation; and in instances of this kind the treatment is simple, being locally and constitutionally antiphlogistic. Such cases can, by the intelligent practitioner, be successfully treated in the mouth; but, in the more aggravated forms of the disease, it is not so easy to arrive at a satisfactory solution of the requirements to meet the exigency of the case. It is more difficult to define the pathological condition that will permit replacement of teeth without drainage; for in these cases we must look for complications beyond and quite remote from the immediate trouble. I here refer more especially to cases where constitutional diseases predominate, such as syphilis; tendencies to necrosis of the jaw, as may be found in workers of phosphorous; sufferers from long continued use of mercury; and also to a more immediate and sometimes puzzling cause of complaint, namely, exostosis of the apical portion of the roots.

To me this subject has been one of great interest, although I cannot recall my earlier efforts at replanting with any degree of pleasure. I believe, however, that the

cases formerly lost might have been saved with my present mode of treatment, for I would not now attempt to replant teeth of a similar character without proper drainage.

The late discussions in Europe have again interested me in the subject, and a few months since I began another series of experiments with better results. Not, however, in the first two attempts, as I lost the teeth in both instances; but the probable causes of failure I shall endeavour to explain farther on.

In the April number of the *Monthly Review of Dental Surgery* of this year, there is an epitome of Magitot's paper upon replantation of teeth, read before the Odontological Society of Great Britain by Mr. Charles S. Tomes. Following the reading of the paper the subject was fully and ably discussed, resulting in a general declared necessity for an open fistula in severe cases of chronic periostitis—after replanting—to permit of drainage, and to re-establish a solid union of the lacerated parts. The importance of this cannot be over-estimated when we consider that a more or less extended inflammation follows the restoration of the tooth to its socket. This inflammation being in part caused by suppressed morbid secretions which nature persistently demands an outlet for, unless a temporary drainage is established, the tooth is forcibly ejected from its socket. Mr. Tomes very justly remarked "there is no anatomical reason whatever, why perfect union of the periosteum should not take place, and doubtless it does take place, so that presumably these replanted teeth may, in the most successful cases, have as much real connection with surrounding parts as any dead tooth has. But there is an accident to which replanted teeth are liable, which I do not see how we can contend against, and that is complete absorption of the roots."

It is with a view of preventing this absorption that I

have practised a method of excising a portion of the roots, and restoring the portion so removed with a cap of gold. My first case, one of some eight months standing, has thus far proved very satisfactory, the patient apparently enjoying all the privileges of a sound tooth. The length of time, however, is not sufficient to warrant the assertion that absorption may not take place. I shall endeavour to watch the several cases so treated, and hope at a later period to give the results in a more decided form to the profession.

Through the kindness of Dr. George W. Field, I am permitted to cite a case that was of long standing, and obstinate to every treatment. The patient was troubled with chronic alveolar abscess, and had been under the doctor's care for a period of six months. In discussing the case with me, I suggested tubing, mentioning that I had been practising it with very gratifying results. The treatment was adopted by Dr. Field, and he afterwards informed me that a cure had been effected in one sitting.

The success of the operation, however, resolves itself into many considerations, of which the following are some of the more important, viz., a careful diagnosis of the condition of the mouth; health of the patient; resisting strength of the tooth under the forceps; its position, attachments, and relationship to other teeth; formation of the alveolus, whether bulging or not; condition of the crown, roots, &c.; and, after extraction, a careful investigation of the covering membrane of the roots of the tooth to be operated upon.

Difficulty is occasionally experienced in attempting to remove the tooth without fracture to the process, especially is this the case with superior molars; and it also sometimes occurs in extracting lower molars. For this reason the patient is better under the influence of an anæsthetic while the tooth is being removed. After the extraction of the

tooth, the socket should be injected with warm carbolized water, and within a few moments a tent, made of cotton loosely rolled, conforming in size to the alveolar cavity, and, having a silk ligature attached, should be gently introduced into the socket; the ends of the ligature extending outside the orifice of the cavity, so that the cotton may afterwards be easily removed, with no chance of any remaining unrecovered, for this might prove the exciting cause of trismus.

We now come to a consideration of the method of preparing the tooth for its return to the socket. The tooth being successfully removed, I would again call your attention to a careful investigation of the covering membrane of its roots, whether denudation has taken place, and if so, to what extent. Not only must you take into consideration the condition of the roots, but your attention should be particularly directed to the gum and the process, whether they are healthy, or in a state of atrophy. As the periodontal membrane will afterwards be dependent upon these tissues for its nourishment, you may expect to find its condition analogous to that of theirs. You must exercise judgment as to when, and under what circumstances, teeth may be restored to their sockets after removal; for it is not to be supposed that every tooth extracted can be replanted. There are certain stages of disease that will permit a return of the tooth without tubing; but if denudation has commenced previous to removal, the roots should be excised and capped with a view to arrest absorption, or rather to prevent a more rapid waste, for the tooth having once lost its pulp, necessarily undergoes a certain condition of atrophy.

There are also certain conditions under which teeth cannot be tubed; and I am now trying a method of capping in such cases, and obtaining drainage through the alveolar

process by making an opening opposite the apex of the root, the results of which I shall give at a later period.

Teeth may sometimes be replaced, when capped, without tubing; but never under any circumstance should I consider it justifiable to tube without capping, on account of the external fracture that would be produced upon the root. In cases of chronic abscess with an open fistula through the gum, where the apical portion of the root is supposed to have lost its periosteum, the tooth should be extracted, and the denuded part excised. The cap may now be filled with gutta percha, warmed, and gently pressed to its position, thereby preventing the secretions from coming in contact with the end of the root after its return. Great care should be taken that the tooth is restored to very nearly its original length; the cap to be made of pure gold, and oviform; while the edges should be very thin, so that they may pass over the end of the root, and if possible underneath the periosteal membrane. The tooth can then be replaced, the fistula answering the purpose of a drainage tube.

I have been questioned as to the necessity—when capping—of restoring the root of the tooth to its original length? In asking this question, it has probably been overlooked that the cap is only required when the apex is diseased and has to be removed, and when its presence would set up irritation. The resection of the root shortens the tooth, which is not in itself desirable. The addition of the cap restores the dimensions, and the cavity of the socket is quite filled, favouring immobility of the tooth, and also pressing out any abnormal secretion which might otherwise collect under the shortened root. The filling of the cap with gutta percha makes it a solid continuation of the tooth. Nature, it has been said, abhors a vacuum, and this holds very good with the economy of the human system. When

from any cause a tooth becomes useless, it is generally cast out, and the alveolar process disappears, while the gum returns to a form which more or less resembles the edentulous arch of the child.

It is on the principle of sealing or protecting the end of the root that I expect to prevent absorption (see fig. 30, *f*). Where there is no open fistula it is necessary to introduce a drainage tube of gold through the roots (letter *c*). In every case so operated upon I have had the most satisfactory results, the tooth being permitted to settle into, and remain firm in its socket during the process of reuniting. In fig. 31 will be noticed an abnormal condition often seen upon the roots of extracted teeth. The treatment ordinarily adopted in such

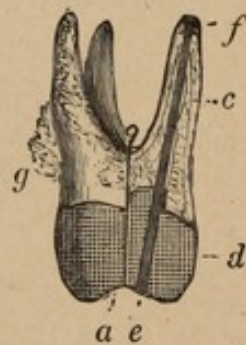


FIG. 30.

Fig. 30 represents an upper molar of the palatine root of which a section has been made. *a b* indicates the line of section. Which section shows at—

- c* the nerve canal filled with oxychloride of zinc.
- d* the gold filling.
- e* the tube, running the whole length of tooth.
- f* the gold cap.
- g* reflected periosteum.

cases would extend over a very uncertain period, perhaps weeks or even months without success. If, however, the disease is controlled, the tough and tenacious cyst upon the root is simply lulled into a passive state, which, upon the slightest provocation by exposure, may manifest itself again

in a still more aggravated form. Other instances have come under my notice where faithful and persistent treatment has *utterly* failed to give relief, the disease having passed into a stage in which the pain was only temporarily reduced in violence by holding iced water in the mouth; the retarded vascular action, of course, being each time followed by a more intensified condition of suffering from a still greater determination of blood to the parts, caused by shock of thermal changes. Again, we have seemingly incurable cases of neuralgia, the diagnostic symptoms being entirely lost. These cases are confusing to both physician and dentist, as the causes appear to be neither constitutional nor local; the physician's prescriptions being powerless to mitigate, while the topical applications of the dentist are quite as futile. A case of this description came under my care some months since, the cause of which I believed to be attributable wholly to exostosis of the root. These different conditions of disease are practical illustrations of the difficulties to be contended with in daily professional life, and have a direct bearing upon our subject this evening.

I shall now engage your attention with a few interesting cases that have been under treatment by the method of tubing and capping. My first case was that of a young lady who consulted me in regard to the treatment of an inferior left molar. Remembering my previous ineffectual efforts in replanting, yet believing the tooth to be beyond the power of treatment in the mouth, I concluded to try the experiment of tubing through the roots; this was done, and the tooth returned to its socket with ultimate good results.

The second was a case of a young man, of nervous, sanguine temperament, and apparently in good health. I was consulted in regard to a first inferior molar, right side,

which I found extremely sensitive to touch, slightly elongated, and a continuous throbbing sensation was experienced at the apex of the root. The tooth had been subject to frequent attacks of this kind, extending over a period of three years, but never in so severe a form as at the time it came under my notice. This seemed to be an unfavorable case for treatment in the mouth, and I decided to remove the tooth, fill, and replant it, which was done without tubing. The patient enjoyed immunity from pain for a period of thirty-six hours, when symptoms of trouble again returned, and he expressed himself as suffering, not only in the face and jaw, but from lancinating pain extending to the temples, and down the neck to the shoulders. During the exacerbations which were more frequent and violent as the malady advanced, he petitioned the removal of the tooth; and, as the manifestations were premonitory of a more aggravated form of trouble, it was done.

I now consider that this tooth was lost from my neglect to tube and cap.

The next was a case of a middle aged gentleman, phlegmatic temperament, who came to me requesting a plate for the left lateral incisor (superior), the other teeth being in good condition. On examination I found that the root still existed, although completely covered by the gum, a circumstance the patient himself was not aware of. I proposed the removal of the root, and grafting a porcelain crown upon it, to which he assented. My first step after extracting was to excise the denuded portion at the apex of the root for a distance of about two lines. I then drilled a canal through the centre the same size as that in Ash's tube tooth. Through both root and tube-tooth I passed an adequate gold wire, to the extremity of which was adapted a small gold cap, such as is used in capping

the denuded roots of replanted teeth. I then returned the tooth to its socket, and in fourteen days—lost it. For ten days the tooth seemed to be getting firmer, and the gum freer from hyperæmia; it then assumed a threatening form which increased until I had to remove it.

I am in doubt about this case, as the periosteal membrane seemed in a fairly healthy condition. The tooth, however, might have been ligatured too tightly in its socket, thereby producing death of the membrane from strangulation, all connection with the nutrient vessels being cut off on one side by pressure; or the confined morbid secretions may have set up new inflammation, with results as before named. After improving so rapidly for a time, it became a matter of surprise to me that the tooth was lost; pivoting as I did, it was difficult to tube.

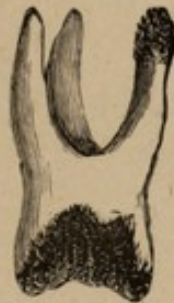

FIG. 31.

Fig. 31 represents an upper molar with abscess sac upon apex of palatine root. The same tooth, after being operated upon, is illustrated by fig. 30.

I now call your attention to fig. 31, representing the condition of a tooth upon which were devoted my second efforts in the application of the tube and cap. It was a second superior molar, on the left side, and one that most of you are familiar with, as it was presented before the class during the period of my demonstrations. The pulp had been dead for some five years, and the tooth was a frequent cause of trouble. The apical portion of the

palatine root presented very much the appearance of that represented in the figure, and its condition after operating will be better understood by referring to fig. 30. This case recovered quite as rapidly as any that has come under my care; and when it was shown to the class—something like a week from the time of replanting—it had nicely settled into its socket, and become firmly attached, the gums quite normal, and the tooth free from pain during the process of mastication.

At the same time and in the same mouth was shown the superior left canine, to which was attached an abscess sac at the time of operating. This was treated without tubing and capping some weeks before, and had become so firmly fixed in its socket that no more movement upon pressure could be observed beyond that to be found in a healthy tooth, the gum being free from any appearance of inflammation.

The next case was that of a young lady, who consulted me concerning an inferior left bicuspid, that had been under treatment. Upon examining, I decided that an heroic course of treatment would accomplish the object and effect a cure. My first application was the cause of such distress that I well nigh lost my patient. She, however, permitted me to continue the treatment, but my most earnest endeavours proved of no avail; and, at last, in a half soliloquizing manner—not knowing what else to do—I suggested the removal of the tooth. This was done, and the same method adopted as in my first case—tubing and capping. No pain was experienced after the first half hour of replanting, farther than tenderness to pressure. The hyperæmic condition of the gums began to fade away on the third day, and on the tenth the case was dismissed as cured, no distinguishing difference being observable along the gingival border. I have learned that the tooth

has occasioned no trouble since, and that it is apparently more firm in its socket than before treatment. This method proving so satisfactory in these two cases, caused me to become more deeply interested in the subject.

The next was a case of an inferior right first molar, which was also exhibited to the class. This had been in a diseased condition only a few months; and it was treated in the manner represented by the vertical section fig. 32. A cure was rapidly effected, the tooth becoming firm, and the soft tissues apparently healing, as might be expected of any ordinary flesh wound.

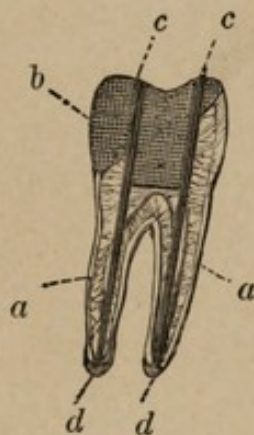


FIG. 32

Fig. 32 represents a section of a lower molar. At *a a* will be seen the nerve canals filled with oxychloride of zinc. At *d d* will be seen the gold caps, while *c c* represent the tubes running from crown of the tooth through the filling to the apices of the roots. *b* shows the gold filling.

The next case is the most interesting to me of any that I have to relate; which assumed some of the peculiar characters before alluded to, so puzzling to physician and dentist. This was a case of neuralgia of over two years' standing, the pathological condition of which had not been clearly enough defined to enable the patient to obtain relief. Upon examination I found the second inferior bicuspid, on the left side, with an amalgam filling in it, but with no symptomatic phenomena apparent, the gums appearing in

a normal condition, and the tooth firm. However, upon interviewing my patient, I discovered that it had been the cause of trouble some time before; but the accessions of the attack not being attributable to any appreciable cause, he had placed himself under medical advice for constitutional treatment. Being suspicious of the tooth, I decided to extract it, when the cause of trouble was explained, there being exostosis of the root. The apical portion of the root was excised, removing the exostosed part, when the same treatment of the tube and cap was adopted as in the previous cases.

The tooth was replaced in its socket, and from the hour of its replanting no farther pain was experienced from it. I have since received letters stating that he was entirely cured of his neuralgia. There are some here to-night quite familiar with this case, having seen the tooth after its return.

My first demonstration of Replanting before the class was on the 27th of June, 1879. This was for a young lady who had been under treatment at this Hospital for acute periostitis, in the first inferior right molar. The case not yielding to treatment I removed, filled and Replanted it; this was not tubed nor capped. The patient was dismissed in two weeks, free from tenderness and hyperæmia, a condition still existing five months afterwards. In this instance, as I have observed in the majority of cases Replanted without drainage, the tooth was not so firm as I should like to have seen it.

The next case before the class was an attempt to tube and cap a right central, and after some time being spent over the case it was decided not to Replant, owing to the defective manner in which the cap and tube were made. This case has not been included in the number I have mentioned.

Owing to this failure I appointed a clinic for the class at my house on the 15th of July, 1879, when I operated upon two teeth in the same mouth, one of which, a superior left central, was tubed and capped, the other, an inferior right second molar, Replanted without that treatment. According to the last information I obtained they were progressing favourably.

Another case was that of a young lady from one of the provincial towns. I found it to be one of acute periostitis of an inferior left first bicuspid; and no relief could be obtained, except by holding cold water in the mouth. The tooth was extracted, filled without tubing, and returned; up to the tenth day the patient had experienced no pain, further than tenderness upon pressure. This case a month afterwards was quite free from tenderness, but not so firm as those which have been tubed.

I would here remark that it has been my aim to operate upon as many cases as I could in the shortest space of time, regardless of the consideration of a fee, that I might the sooner arrive at some definite conclusion concerning the advantages, if any, of this new method. In a number of mouths two, and in one mouth three teeth have been Replanted, treating both with and without tubing in the same mouth, all of which are being worn with comfort. My belief, from observations and experiments is, that without a system of drainage, Replantation can never become popular, owing to the fact, that unless the tooth is permitted to remain *fixed* in position, and the attachments are formed in the first stages, firmness may never be expected, owing probably to the chronic hypertrophied condition of the periosteal membrane.

I have here recorded a few cases that have been treated without tubing, and also with tubing and capping. From careful observation of results obtained by both methods,

I feel convinced that success will be more certainly obtained by capping and tubing than by any other mode of treatment yet advanced, where Replantation is practised. Yet there are instances, and I have herein mentioned one such case of a canine, in which teeth may be replanted and soon become firmly fixed without any drainage. Nevertheless, these are exceptional cases, and it would appear that their well doing depended upon a complete absorption of the secreted substances, thereby removing the baneful condition of retained effusion, which retards the healing process and leads to thickening and imperfect reunion of periosteum, consequently to mobility of tooth.

Having entered into a consideration of the complications that may arise, constitutional or local; also having directed attention to certain conditions of disease, where antiphlogistic measures fail to suppress morbid secretions, when treatment is given in the mouth, I shall endeavour to explain the method of tubing and capping. Fig. 32 shows a vertical section of the lower molar, with the tubes and caps in position, extending through the roots of the tooth and filling. If a cyst is found upon the end of one root only, as in fig. 31, that alone will require tubing; but if both fangs are diseased, it will be necessary to tube both. After the removal of the tooth it should be dropped into warm carbolized water, afterwards carefully wrapped in bibulous paper, saturated in this same solution; it should next be placed in splints of soft wood, shaped in such a manner that when fixed in the vice, and the jaws are firmly closed (see Fig. 33), a generally diffused or even pressure may be obtained over the whole surface of the tooth, and the membrane of the root protected against accident.

The roots should then be cleansed of all extraneous matter, and filled with oxy-chloride of zinc, after which the

tooth may be removed from the vice, and where denudation has taken place, the root excised. Then, with a flexible drill, the canal should be formed as nearly as possible through the centre, following more or less the direction of the nerve canal. The tube then to be introduced into the canal, and the cap carefully adjusted to the apex, so that no projecting surface be perceptible, otherwise there will ensue irritation of the periosteum of the socket, and consequent inflammation, leading to ejection of the tooth. Other complications of a still more dangerous character may arise from this cause of neglect, as trismus.

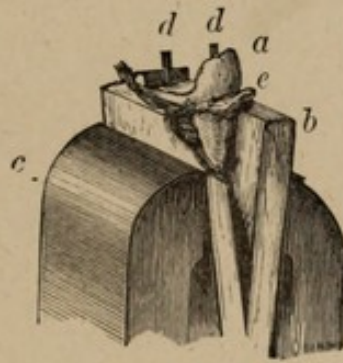


FIG. 33.

Fig. 33 shows *c* the vice holding the tooth *a* by means of the wooden clamps *b*. At *dd* may be seen the tubes running through the tooth and in position, *e* represents the bibulous paper wrapping.

Previous to this, however, it is necessary to prepare the cavity of the crown for the reception of the gold filling, but this is now too well understood by you for me to enter into any particulars; nevertheless, I deem it advisable to mention that great care should be taken not to obstruct the tube while building around it. The orifice at the crown should be somewhat funnel-shaped (see Fig. 34, A) the reason of which will be seen at the time of plugging. Care must be observed in regard to the perfect articulation

of the tooth when replaced, to avoid all undue manipulation upon it after its return to the mouth.

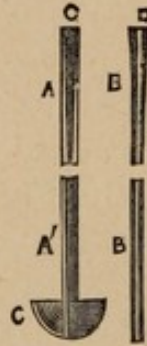



FIG. 34.

Fig. 34. A represents the tube, G indicating the funnel like enlargement at one end, while C shows the cap at the other end, one quarter of which is in section. B represents the pin for closing the tube when the tooth has become once more in a healthy condition. The extremity D being somewhat larger, and made to fit into the funnel-shaped opening of the tube G. This illustration is twice the actual size.

I shall next refer to the gold pin (Fig. 34, B) which is carefully adapted to the tube, in size and length. This to be used only when a pronounced cure has been effected, to hermetically seal all communication with the socket, thus preventing the entrance of all foreign matters, thereby diminishing the danger of secondary affections. The tooth having been prepared according to the foregoing instructions, should be gently introduced into the socket, a small plug of cotton being loosely placed into the orifice of the tube, so that secretions may pass out, at the same time foreign substances be prevented from pressing down into the tooth beyond the cotton. The tube should be kept cleansed by a daily changing of the cotton, the cotton to be supplanted later by the gold pin when the parts have become healthy and united. Small pads of cotton soaked in a solution of chlorate of potash may be applied to the gums to allay inflammation. Should there be any tendency to expulsion



after insertion—as is sometimes the case with incisor and bicuspid teeth—it will be necessary to use a splint or ligature to keep the tooth in place. In this position the tooth is to remain a period of from five to seven days, when, if it has become self-sustaining the splints may be removed, and in a week or ten days later, under ordinarily favourable circumstances, a perfect union should be established.

During the first four or five days, such food as might cause dislocation of the tooth should be avoided, also needless exposures to changeable temperature. I deem it advisable to have the patient use a mouth wash, consisting of a weak solution of the permanganate of potash, as this not only cleanses, but its disinfectant properties prevent decomposition.

I shall now call your attention to the manner in which the caps are struck up, and by reference to fig. 35, may be seen the die, with different sized and shaped indentations also, punches of the several sizes required to fit them.




FIG. 35.

Fig. 35 illustrates the steel die plate *a*, and the punches *b*, used for striking up the gold caps.

The tubes are formed in a manner analogous to wire drawing; the external diameter being about .75 m.m., and the internal diameter about .5 m.m.

From the differences in the diameter of the roots, arising not only from different sizes and forms peculiar to themselves, but also varying according to the distance from the

UNIVERSITY OF TORONTO

apex at which the root is resected, the caps require to be of various shapes and dimensions.

The steel punches (marked 1' to 4' in the cut) corresponding in size to the indentations in the steel die plate, enable me to approximate with considerable facility the dimensions and form of the section of the root which I may desire to cap.

When the cap is adjusted to the root, it will be found, in the majority of cases, necessary to fasten it to the tube at an angle; to obtain this angle, and at the same time to fit the apex of the root, the opening for the tube will not be in the centre of the convexity of the cap, but at some point more or less distant therefrom. Having ascertained the position of the aperture, a hole is drilled, and the tube passed through the cap, when it is soldered on the convex side; after which the projecting part is cut off, and the surface of the cap carefully burnished.

During the building of the gold, the pin should be temporarily placed in the tube, to prevent obstruction by pressure; but afterwards removed. When the filling is completed, the entrance of the tube is slightly enlarged, so as to present the form as may be seen in Fig. 34, B, the pin being made with a long conical head to fit the same. Before replanting the tooth, care must be taken to fit the pin perfectly, both as to its head filling the tube, and as to its length; so that when it is ultimately placed, it may not project in any degree beyond the cap, and at the same time not be so short as to leave any part of the tube unfilled. It has been my aim to enter fully into the very interesting considerations which this subject involves, with a view of directing the attention of others to it.

Drainage after replanting has, for a long time, been attempted; but all the different methods have presented

.....

.....

to some extent objectionable features, whether in the establishment of a fistula by an aperture through the alveolar process, or by cutting a groove in the side of the tooth. As our efforts are to preserve as much of the periosteum as possible, the last mentioned method seems the more impracticable of the two. Notwithstanding this, a considerable percentage of the operations in Replanting have apparently been successful.

By tubing, the abnormal secretions are removed from the point where they are most likely to be formed, without coming in contact with any of the living tissues, as they are conducted by the golden and unalterable canal to a boundary beyond their influence for harm, permitting—when health has again been established—closure of the tube. In the upper teeth the force of gravity causes the secretions to descend, while in the lower a different condition, as connected with the tube, exists; however, the secretions, when limited to the quantity contained in so small a compartment as the tube, are not appreciable to an extent that causes inflammation, and the result is—when the discharge has ceased to carry them beyond the external orifice—absorption. In regard to teeth which I have Replanted in conjunction with drainage by tubing, the periosteum has seemed to attach itself with greater rapidity and firmness to the surrounding tissues. In fact, I find that when the products of inflammation are effectually removed, inflammation soon ceases.

In conclusion, I have but to say, that in every instance where I have followed this course of treatment the cases have progressed in a manner highly favourable to my hopes. I have admitted failures, but up to the present time no failure has occurred where I have tubed and capped. Without claiming anything as yet for the practice of Replanting teeth, I must say that the action of

this system of drainage from the first, has been that which I wished for and anticipated, but what may be its popularity, or the benefits it may confer, must remain a question of the future.

EDITORIAL COMMENTS ON REPLANTATION.

FROM THE

"MONTHLY REVIEW OF DENTAL SURGERY,"

DECEMBER 15TH, 1879.

Replantation of Teeth.

THE History of the Replantation of Teeth is so well known that we need not here reiterate it. But from the time of Hunter, who made known the possibility of transplanting teeth, and also wrote upon replanting teeth, these methods of treatment have been practised by numerous individuals, both in Europe and in America.

The question of replanting teeth appears to have had a somewhat spasmodic existence, and it has, notably during the present year, again been brought prominently before the profession.

In the number for March, 1879, of the "*Bulletins et Memoires de la Société de Chirurgie*," there is a very long paper by Dr. Magitot on this subject, containing a report of fifty cases. An epitome of this article was read by Mr. Charles S. Tomes before the Odontological Society in March last (see page 160 of the *Review*). In our February number, page 55, there is an article on Replantation by Mr. George Torpey; and again in this issue, at page 521,

there is published a very excellent lecture by Dr. Thompson.

From all that has been written on this subject we may set forth the following conclusions :—

Where the periosteum is healthy, teeth may be extracted, pulp canals filled, and replanted with a large per centage of successes.

Where the periosteum is in a state of chronic inflammation, with the same treatment as before-mentioned, there is a less per centage of successes.

In cases of alveolar abscess the best results are obtained when, in conjunction with replantation, a system of drainage is established.

It is in cases of alveolar abscess which are difficult to treat in the mouth, that the practice of replantation is most justifiable. To obtain drainage of the substances exuded during the healing process different methods have been adopted, such as a fistula through the alveolar process to the apex of the root, and to this may be added a seton; also by having a groove cut in the side of the root, from its apex to the neck of the tooth. But Dr. Thompson has devised a novel method of drainage by having a tube running through the centre of the root, and opening upon the grinding surface of the tooth. When the cavity, which was occupied by the abscess sac has healed up, and all exudation ceased, the tube can be accurately filled up by a pin, which was adjusted to the tube before replanting the tooth. This principle of drainage adopted by Dr. Thompson is the most complete and effectual, where it can be adopted, of any method hitherto made known; yet we must not overlook the position of a tooth so tubed in the lower jaw, in which case the discharge has to accumulate until it reaches, and is taken up by the cotton wool dressing, daily placed in the tube; whereas with such teeth in the upper jaw, gravitation favours the exudation

quickly passing away. Nevertheless, the practical results, some of which we ourselves have witnessed, in all cases where this system of drainage has been adopted, have been eminently satisfactory.

There are numerous instances of Replantation where alveolar abscess had existed, and no drainage had been provided, and the cases have done well. But there are evidently more failures, and less good results obtained, when alveolar abscess is thus treated without drainage, than when drainage is provided for.

When Replanted teeth have become firm and useful, future trouble is not necessarily overcome; for in the course of one or more years the process of absorption may bring about the loss of the tooth. With the view of reducing the liability to absorption, Dr. Thompson excises the portion of the root denuded of periosteum, and restores this with a cap of gold, through which he also passes the drainage tube. It appears that this cap of gold at the apex of the root has been tolerated, indeed, has not given rise to any perceptible disturbance, for, so far, eight months. Though absorption of the gold is not at all likely, yet any portion of the tooth substance which is contained within the alveolus is liable to be so eaten away. The tendency to destructive absorption of the root may, perhaps, be lessened by the removal of the necrosed portion, which is generally considered as an intolerable irritant; but it remains for time and observation to teach us whether a foreign substance, such as a gold cap, in this situation is more acceptable to animate nature than the tissue of her deserted habitation.

The position we have attained with regard to Replantation in cases of intractable alveolar abscess may, therefore, be said to be that this treatment, to ensure the best results, should be in conjunction with drainage.

LECTURE VIII.

Delivered at the National Dental College, London, Nov. 26th, 1879.

HAVING, in my last Lecture, digressed, I shall only add, concerning the subject of replanting, that the complicated nature of the means proposed precludes the possibility of any conclusive opinion being given, until the principles of treatment as described are more fully tested. I shall now resume the subject of caries in its first stage, as shown in Lecture VI.

Referring to Fig. 18, will be seen the inception of disease on the labial surface of a right central incisor. Here are found several spots, which, on examination, show the organ to have lost its osseous integrity. The surrounding tissue may be dense and hard, in which case the small cavities can be filled so as to avoid the appearance of a mass of gold; but the contiguous structure will generally be found soft, with disintegration extending into the proximate surfaces, thus necessitating the removal of such morbid tissue.

The disease sometimes, however, concentrates in one place, as figured in the lateral, instead of forming a collection of spots as in the central, figure 18, which may not extend much under the gum, but have a tendency to spread in a linear manner, as shown in the canine. This may continue in either direction, until it nearly encircles the tooth; but, should its depth bear any great proportion to the diameter of the organ, the crown may be fractured vertically or transversely. The forms of decay as here presented are frequently signs of approaching senility,

the more marked indications being the attenuated condition of the cervical portions of the teeth, accompanied, usually, with retrocession of the gums.

While Fig. 16 represents a plan of the horizontal or crown surface of the teeth; Fig. 21 shows an elevation of the buccal walls, and especially illustrates the advance of decay from its inception, on the second molar, at *a*, to the canine, *b c*, where it may be considered as having reached its third stage. This diagram also shows the position of erosion, which is identical with that of caries proper, and serves to illustrate both, the distinguishing differences having been given in a previous lecture.

The second condition of the disease is now reached, *i.e.*: "An advanced stage of caries with encroachment on the pulp."

The several points of decay, as illustrated in Fig. 18, may merge into one cavity, and assume the appearance presented in Fig. 17, describing the third stage. The inferiority of bulk in the incisors makes this nearly equivalent to the fourth stage.

The second stage is also exemplified in the incisors, Nos. 7, 8, 9, and 10, Fig. 16. The pulp here is not yet involved, but is protected by a dark layer of dentine which is the seat of a passive form of decay sometimes presenting a hard and dense appearance.* Examples are frequently seen of the apparent arrest of disease after an extended encroachment in the body of the tooth; the darker and more repulsive its appearance, the more effectually protected seems the organ. This, no doubt, may be attributed to a deposition of earthy matter in the calcigerous cells,—a physical or a physiological

* Especially is this the case when found on the grinding surface of molars.

phenomenon, which causes the tooth to lose its distinguishing characteristics. The diagram before you is intended to illustrate the cavities—as shown in Fig. 16—filled, and the teeth restored to their original shape.

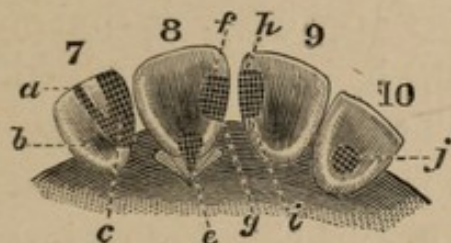


FIG. 36.

In No. 7, of this Figure, is represented a filling built upon a right lateral, so as to give the greatest security. Obliquely along the lingual wall will be seen an arm, or extension, which is intended to aid in the support of the filling—the mesial portion of the enamel still existing on the labial wall of the tooth; this is so frail sometimes as to require most careful bracing. At *a* is shown the retention point on the cutting edge, while *b* and *c* indicate the anchorages at the base. In bridging the intermediate portion of the tooth between the extension and the central body of the filling,* it is advisable to cut away 8 m.m., perhaps, of the lingual wall.

The superior centrals, sub-figures 8 and 9, represent the teeth restored to their full contour. The cavities in the mesial region extend antero-posteriorly to the labial wall, and, in their preparation, require to be cut vertically both to the proximate and lingual surfaces, and in a rectangular form, viewed in any of their three dimensions. The location of the anchorages are indicated by

* This leaves a septum on the tooth intermediate between the two extensions, over which the filling is carried until the whole lingual surface is closed in extending from the mesial point to that designated at *a*.

the dotted lines pointing from the letters *f*, *g*, *h*, and *i*. On the right central (*e*), decay is seen upon the lingual aspect; this type involves treatment by incision of the gum. Disease, as frequently seen on the lingual wall of the incisors, is represented, after filling, in No. 10, *j*.

The second stage may cover a superficial area of considerable extent, the body of the tooth still being an excellent basis on which to restore with gold. This necessitates work very similar in appearance to that required in the fourth stage; figure 37 showing an instance which came under my notice.

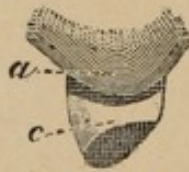

FIG. 37.

a shows the point to which the filling extended under the gum.
c the only remaining portion of enamel left.

Here the disease, without touching the pulp, had spread over the greater portion of the lingual surface of a canine, and under the margin of the gum on the distal surface, to the point indicated by *a*; it had also extended over the major part of the labial aspect, diverging on the cervical border in a meso-distal direction. Of the whole lingual wall of the tooth, it was possible to save only the strip of enamel seen in the figure, which extended from the meso-lingual point to the opposite proximate boundary.

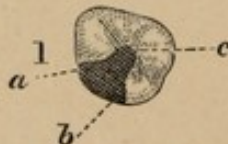

FIG. 38.

In the above, corresponding with the wisdom tooth, No. 1, Fig. 16, is exhibited a filling; *a*, *b*, and *c*, showing the points of anchorage.

I have already spoken of the seat of caries, represented

in Fig. 38, as being in the most difficult position for treatment of any in the mouth; and, in operations of this description, it will be necessary to adopt such measures as may suggest themselves in each individual case.

In preparing the cavity, the anchorages should be formed at the base of the walls radial to the coronal centre, at locations indicated in the diagram. The greatest power of resistance, however, will be obtained by slightly changing the direction of the converging walls; causing them to again diverge before joining with the semi-circular wall of the medial region. At *a* and *b* grooves are formed along the vertical walls, which should be solidly packed with leaf foil, in conjunction with the carrying along of the body of the filling with gold of heavier preparation; the keystone of the work terminating at the dove-tail *c*.

The application of the rubber to these teeth cannot always be made, in which case pads of bibulous paper may be adjusted so as to compress the duct of Steno. In addition to this, a prop may be introduced to distend the jaws in a position not uncomfortable to the patient, yet in such a manner as to give an unobstructed view, if possible, of the parts to be operated upon. The maxillæ cannot be separated beyond a certain limited extent, as, after that degree is exceeded, the buccinator muscle is rigidly contracted upon the molar teeth, causing the mucous membrane to encroach upon territory difficult of access. This, however, is but one of several obstacles to be contended with; for the strong and powerful masseter plays its part with the antagonistic forces in the contest, and adds to the inaccessibility of the third molars by limiting the angular distance through which manipulation can be conducted, and also, in conjunction with the buccinator, coerces the mucuous membrane into a position that makes

it susceptible to injury. This muscle, however, acts in a somewhat compensating manner as an auxiliary to the use of pads, and assists in temporarily arresting the spontaneous flow of the parotid secretion into this already too circumscribed area in which to operate. In viewing the cavity, it will be seen that it is situated upon the rounded turn of the tooth, also that it is V-shaped, the divergent part being upon the external portion. A hope of the retention of a filling placed in such a locality must exist in measures adopted to secure this end. Too much importance may be attached to the retaining power of the anchorages; these are valuable aids, but they cannot be regarded further than the part they fulfil in steadying the gold during the starting period. Hyperæsthesia usually exists in the wisdom teeth far in excess of that found in the associate dental organs, while the decay, extending in a lineal direction around the cervical portion of the tooth, frequently reveals so much new territory in a state of semi-disintegration, that it involves the mind in doubt as to when and where to discontinue the work of preparation. This has its exceptions, yet being so much the rule, the wisdom teeth are not considered such as to permit any strong hopes being based upon their permanent retention. However, in the absence of the first or second molars removed in youth, every effort should be made to save them.

I must now call attention to measures required in the second stage. The limited intermediate substance between the external surfaces and the pulp restricts the disease to a very circumscribed invasion—where this organ is not encroached upon. Therefore, in the triangular cavity, Fig. 22, an anchorage is to be made in each angle, as also a minute groove at the base of the surrounding walls. In filling a cavity of this

description, commence in the lower anchorage, and continue to build until the gold reaches perhaps an equidistance from the base to the upper portion of the cavity; then build in each of the remaining anchorages, working towards the centre, at which the different portions of the filling will meet and blend. On the foundation thus obtained, additional gold can be applied until the surface of the tooth is symmetrically followed.

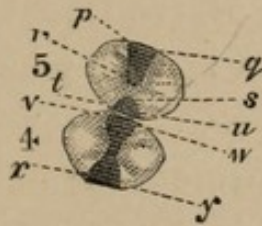


FIG. 39.

In the above—seen as cavities in Fig. 16—are shown the bicuspid after being operated upon.

No. 5, second stage. Filling on ante-proximate surface, at *p*, *q*, extending to medial point. Filling at *t*, *u*, on post-proximate surface; *r* and *s* showing points at which dovetail steps are to be made—similar in principle to that described in the wisdom teeth—in which anchorages are formed.

No. 4, third stage, represents a more extended condition of decay, restored with gold, the two cavities merging into one, with anchorages at *v*, *w*, *x*, *y*.

In the conduct of operations—first and second stages—you will have an opportunity for practice which will aid you in more difficult cases, as those in the third and fourth stages, to a consideration of which we are now approaching.

The third stage I have defined as “A condition of disease involving partial or complete exposure of the pulp, without necessary loss of the same.”

The exposure of the pulp implies a series of complications which may extend over an area quite unexpected, and calls not only for skilful treatment, but a full recognition of the therapeutic as well as prosthetic measures to be adopted.

That the study of every stage of caries should be as exhaustive as possible is rendered evident by the fact that, in actual practice, it is at this period, developed in some one tooth, that the ordinary patient presents himself for treatment. But, when the magnitude of the operation becomes evident, and examination shows the existence of caries of the first and second stages, one or both of the following causes may stand as an opposing influence to a successful course of treatment, *i.e.*, idiosyncrasy or mental reservation—the last of which may be antipathy, prejudice, or indifference.

To comprehensively present the following case in connection with its relationship to the third stage, I shall be compelled to introduce several diagrams. Referring to Fig. 16, No. 2, will be seen the right superior second molar which is decayed upon its ante and post-proximate aspects. Fig. 40 illustrates in plan the preparation of the crown cavities; the anchorages, grooves and steps of which are more clearly delineated in diagrams 41 and 42.

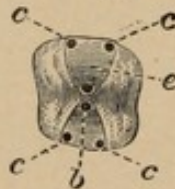


FIG. 40.

The above cut represents a second molar in the third stage.

b. Anchorage in the septum—medial region.

c c c c. Anchorages on the ante and post-proximate boundaries of cavities.

e. Pointing to exposure of pulp, which is further illustrated in cuts 41 and 42.

During the preparation of the ante-proximate cavity, it is discovered that the cornu of the pulp below the ante-lingual-medial point has become exposed by the intersection of the curved surface of the floor of the cavity, as is represented at *e*, Figs. 40, 41, and 42. Capping, as a diasostic measure, is indicated, but the

treatment will necessarily vary with the extent to which inflammatory irritation may have been induced. The exposure involves but a small area, and may be effectually sealed from external influences by the use of thick carbolized paper, which from its pliancy is readily adapted to the interstices in the floor of the cavity, without becoming inimical to the normal condition of the pulp. The ovoidal end of the handle of an excavator can, in the absence of a special instrument, be used to make an indentation in the paper sufficient to arch over this minute exposure; while the paper should be accurately adapted to the concavity so formed, and gently placed in its position. To re-duplicate the paper would be to give too great a proportion of a yielding substance in the restora-

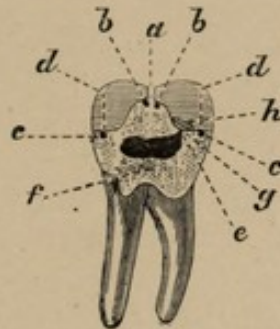


FIG. 41.

Tooth split between the lingual and buccal fangs to show the third stage of disease.

a. Parieties extending from the grinding surface of the enamel to the more solid body of dentine covering the pulp chamber.

b b. Anchorages in the medial region.

c c. Anchorages in the post- and ante-proximate regions.

d d. Terminations of the grooves under the enamel.

e. Point of exposure of the pulp.

f. Fractured surface.

g. Carbolized paper capping the pulp.

h. Oxychloride of zinc, interposed as a non-conductor to thermal change.

tion; therefore, oxychloride of zinc should be placed above the paper capsule, as a further protection from thermal change.

The subject under consideration cannot be too well

understood; and, for this reason, I shall endeavour to give a detailed description of the dangers which encompass the attempt at preservation of an exposed pulp. The repeated excitation of this organ, or continued irritation for any length of time, materially augments the morbid tendencies. Commencing with local irritation, following with congestion, and terminating in suppuration; it ultimately extends to adjacent tissues, when the disease can no longer be considered local, but systemic, and must be treated as such. The cornu, not being in any particular plane, curves concentrically with the surfaces of the teeth. The following illustration is intended to more clearly reveal the position as shown in Fig. 41.

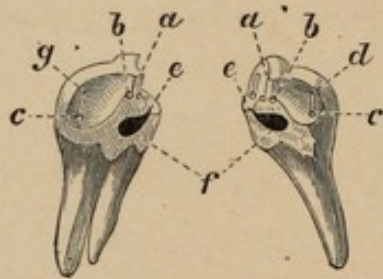


FIG. 42.

Perspective view of the last Figure.

- a.* Walls between cavities.
- b b, c c.* Anchorages.
- d.* Groove.
- e e.* Point of exposure.
- f.* Fracture.
- g.* Prepared Cavity.

The difficulty presented in this instance does not, however, express the degree to which, by complication, even the initial exposure of the pulp may be aggravated. In the case before us, the cornu has been intersected at a point; but, should the area of disease assume a parallelism with the superficies of the pulp chamber, a single stroke of the excavator may remove the osseous covering and reveal a projecting angle, or, further, a portion of the parietes may be destroyed, causing an exposure of a very

appreciable length and breadth. Such an occurrence is sometimes associated with the accidental penetration of the pulp, and must be met by the adoption of methods of obtunding pain commensurate with the gravity of the occasion. The increased vascularity of the pulp where the floor of the cavity is porous, causes actual hemorrhage to occur before the pulp is impinged upon. Should, however, there be no firm basis reached, it will be proper to leave a thin capsule even of this imperfect material over the pulp, as its exposure is always to be considered a disaster, and to be avoided. In preparing the cavity, increase the circumferential area in which to cut a rudimentary groove around the fractured surface. A metal cap can then be adjusted in conformity to the shape of this groove, its concavity being such as not to touch the pulp. Oxy-chloride of zinc will now fix the cap in position, and also act as a non-conductor; but the anchorages and grooves, on the principles enunciated, will have to be made at points independent of the floor of the cavity. In capping, the preservation of the pulp cannot always be hoped for; the practice, however, has met with success that justifies its adoption, and I need hardly add that it is a distinguishing feature in conservative treatment. The pulp devitalised, a legacy of weakness is left to the tooth; discolouration ensues, and this portion of the economy as it dies so involves its ally—the peridental membrane—as to threaten its destruction. Commencing with passive congestion, it runs through the different stages of disease, until the general system is incited to rebel against the inanimate cause of such discord, even to ultimate rejection and expulsion.

If the pulp can be protected from contact with external influences, the formation of secondary dentine, though problematical, is greatly favoured. When the pulp chamber has been but recently invaded, it is not unreasonable to

suppose that treatment by capping will be successful; with an extension of time, however, the case becomes more aggravated, owing to atmospheric and mechanical action upon the pulp.

Opinions are much at variance as to the benefits derived from different materials used for capping; for, as all remedies are valuable only from their appropriate use, experience of their applicability is required to ascertain the circumstances in which they are truly of service. The means of capping, in all cases of recent exposure, are directed with a view of restoring the pulp to a normal functional condition. Previous, however, to such treatment being adopted, it is necessary, if pain exist, to subdue the paroxysms by mild but active measures. Any tendency to pulpitis must be aborted, and a quiescent state induced, before recourse can be had to capping.

The treatment entirely depends upon the circumstances of the case, anodynes being indicated, but they should not be employed indiscriminately or without investigation as to the existing pathological condition; this, however, leads us into therapeutics, and will be more particularly dwelt upon at another time.

Reverting to Fig. 21, the progress of caries in the vicinity of the gum conveys an impression that it is even more insidious than that which commences on the crown surface. In the cervico-buccal region, especially in the molars, it is sometimes hidden by the festooned edge of the gum, which nearly coincides with it in shape. No section has hitherto been necessary to represent the encroachment of disease in Fig. 21; but, to show the extent, or rather depth of the caries, a transverse section has been made. Teeth split between the fangs, instead of the usual section, exactly fulfil the requirements of the case, and enable me to

more clearly depict the encroachment of disease on the pulp. In a lower molar, we are able to trace the third stage; commencing at, or near the gum, decay has extended into the body of the tooth both laterally and vertically, until the pulp chamber is penetrated, *vide* Fig. 43, split section of a lower molar.

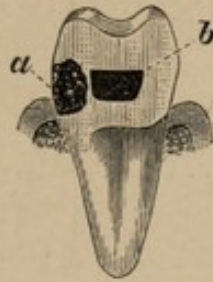


FIG. 43.

- a.* Caries extending below the gum, and touching the pulp chamber.
- b.* Pulp chamber (section between fangs).

I wish now to direct attention to the fourth stage, viz.: "A broken down condition of the tooth structure, complicated with pulpitis and death of the pulp."

This stage involves some of the most interesting examples of restoration, and has drawn largely on the resources of the dental art.

Not only are these cases complicated in character, but they vary in almost every instance, and require a special adaptation of means at the hands of the dentist. Gold, excellent as it is as a filling material, does not adhere to the sides of a cavity, but remains mechanically fixed therein, by being forcibly packed against the surrounding walls. But when the substance of the tooth is wasted, the foundation becomes insecure, and the filling must, therefore, be fixed to its position by means independent of adjacent lateral support; otherwise, the slightest shock in masticating may result in disaster to the work. Between an extreme condition of instability, and the almost certain fixity attainable in solid

walls, various degrees of conflicting difficulties are sure to be present; however, by a judicious appropriation of that portion of the tooth that can be saved, and the use of differently constructed appliances for retention—inserted in the solid dentine—a substitute for the lost tissue may be obtained. These extra attachments, or retaining appliances, are especially demanded in the designated fourth stage.

Figure 43 illustrates a condition, the continuation of which is further shown in the following representation of extensive decay.

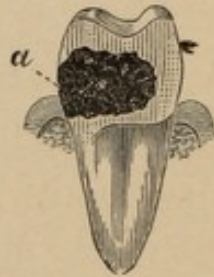

FIG. 44.

At *a* is seen caries extending into the pulp chamber and below the gum, threatening the bridge between the fangs, and leaving the crown supported on the lingual and proximate parietes of the tooth.

In the above may be seen an exemplification of caries which has destroyed the parietes, and spread itself in every direction, until the tooth is undermined and left with no other support than perhaps a portion of its lingual or buccal sides, and portions only of the proximate surfaces. In treating a case similar to the above, it will be imperative to remove that portion of the crown which is situated immediately over the diseased part of the tooth, as otherwise the pulp chamber and its divergent extensions might prove abortive of every attempt to insinuate instruments of the most pliant and filamentary character.

The elevation of this tooth showing the prepared cavity illustrates very plainly the anchorages and grooves, and

also the position of a step made in the medial region. On the floor will be seen the entrance to the root canals at the point at which they become confluent in the lower part of the pulp chamber. The plan 46 gives still more clearly the position of the intersection of the united canals by the floor of the cavity.

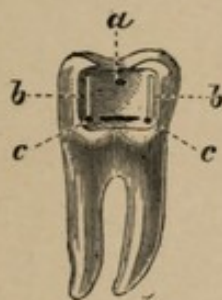


FIG. 45.

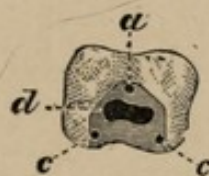


FIG. 46.

The above cuts represent a lower molar prepared for filling, fourth stage, in which decay originally commenced at the gum. See Fig. 44.

a. Anchorage in medial region on a step made in the angle of the V-shaped part of the cavity; the step being about 1-6 m.m. below the crown enamel surface.

b. b. Grooves cut from under the enamel extending to anchorages *c c*.

c c. Anchorages on floor of cavity near buccal edge of same.

d. Pulp chamber.

I have exhibited to you the formation of cavities from the earliest inception of decay, passing through the different stages; also selected instances from Figures 16 and 21, sufficient to show methods adapted to the various stages of disease. Some have been simple, others difficult, calling for the greatest manual skill in their execution. But I shall now describe cases of an exceptional character, that require an originality of thought and action quite independent of any teaching or prescribed rules which might govern you in ordinary practice. You will have no precedent, nor will the text books aid you further than with suggestions in a general way. The treatment carried to a successful issue, however, will result in the establish-

ment of confidence, leading to a position which might not be attained through any other medium.

In my next lecture I shall endeavour to show wherein the gold may not only supply tooth deficiency, but, by a system of bracing, enable the frail portions remaining to be protected from shock and consequent fracture, as well as from contact with the fluids of the mouth, or other and deteriorating influences.

The cases now under consideration are peculiarly trying to those compelled to submit to treatment, the imperative nature of which must necessarily involve mental and physical endurance, difficult to be understood previous to the operation. The obvious duty of the dentist, under such circumstances, is, 1st, to ascertain the pre-disposing influences which may combine to oppose him in the measures marked out for his adoption; and, 2nd, to make a full and comprehensive statement of the difficulties attendant upon the operation, in order that it may not result in confusion to himself and distrust to his patient. The choice and application of the means must be suggested at the time of operating; for it is impossible to lay down any prescribed rules or measures to be adopted, owing to the many unforeseen and conflicting contingencies that may arise. This must come from experience or intuition, or, perhaps, a combination of both, which makes the practitioner master of his position.

LECTURE IX.

Delivered at the National Dental College, London, Dec. 3rd, 1879. .

CONSIDERING the effects consequent upon the retention of any portion of a devitalized pulp in its canals—as irritation of the peridental membrane—caused by the results of decomposition, gaseous or fluid, it may be readily inferred that such a contingency is necessarily followed by a train of complications not always easily controlled. The obvious indication is to remove every incentive to hyperæmia, preventing, if possible, lesions which might otherwise seriously involve the surrounding tissues. In this, much will depend upon the skill and judgment brought to bear in the preparation of the minute and tortuous passages which naturally follow any distorted configuration of the roots. The injurious influences of structural change are apt to be underestimated; and, for this reason, I direct attention to the importance of most effective measures being adopted.

In removing the pulp, do not allow the instrument to pass beyond the foramen at the apex of the root, as the remaining trunk of the nerve may retain its excitability in the immediate vicinity of this strait. The instruments for this purpose should be pliant, that they may be easily bent in any direction to prevent accident; for it is always awkward when a broach becomes broken in these, not infrequently, almost inaccessible repositories. Pluggers of exceedingly delicate shape are now required; which should be well tempered, and, for some distance from the points, flexible, that they may be readily adapted to the different conditions under

which they are to be used. Every precautionary measure must be taken to ensure perfect impaction of the gold in the interstices between the apical foramen and the pulp chamber; for, should any interval be left near the apex, exudations will percolate through the foramen, which might, by the generation of gases, induce a pathological condition difficult to control.

Perhaps a more effective way to prevent abnormal excitation would be in the use of wire made of pure gold; which, being soft and pliant, readily adapts itself to the deviating course of the fang. But, should the wire not be suited to its intended point of location, it must be withdrawn and shaped so nearly the size required, that, with finely-pointed pluggers, it can be driven to its position, as illustrated in Fig. 50, and described in relation thereto.

In cases where susceptibility to thermal change exists, with a predisposing inflammatory condition of the peridental membrane, a non-conducting substance may be introduced as a substratum. Against this cause of future derangement, you will be guided as to the necessity of defensive measures, by a knowledge of the diathesis of the case.

Another method of filling the roots is with oxychloride of zinc; which may be done by using fibres of silk, saturated with a thin solution of this preparation, and carried along the nerve canal by the use of broaches, packing rapidly, that the material may not set before the cavity is filled. Where restorations are made with gold, no portion of any other material used for filling the fangs or protecting a sensitive pulp should be exposed to the secretions of the mouth, as the work will be undermined by their action.

If a temporary filling is made, gutta percha or Hill's stopping will answer the purpose very well. This is

especially adapted to what is called a test filling, after the treatment of teeth, for the reason that it can be readily applied; and also removed when occasion no longer demands its use.

Another case illustrative of the fourth stage, is shown in the prepared cavity Fig. 48.

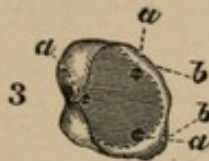

FIG. 48.

Cavity prepared in superior molar corresponding to No. 3 in Fig. 16.

a a a. Anchorages in or near buccal, ante-lingual-medial, and post-lingual medial regions.

b b. The reduced wall and bevelled edge.

Here the buccal wall may be depended upon to resist its complement of the total pressure which will necessarily result from the opposing teeth coming in contact with the composite surface. But, in order to preserve the lingual wall, the basal, as well as intermediate portion, must be protected by sacrificing the frail and unreliable line of enamel to which the wall has been reduced at the crown surface. This, being diminished in thickness, as it rises from the floor of the cavity, presents a knife-like edge, quite incapable of offering resistance to lateral pressure. Notwithstanding deficiency in thickness, the enamel may be good, and capable of much service, if protected from the leverage to which its exposed position subjects it; but, in order to prevent fracture at the top or base, it must be framed in, so as to be exempt from shock, or lateral disturbance. To accomplish this, the wall must be reduced vertically until an appreciable thickness is attained, and then, with evenly mounted discs, bevelled at an angle of about 30° . The gold being carried over this bevelled edge, the effect of any pressure is to clamp

the frail portion, thus shielding it from antagonistic force. The diagram, Fig. 48, better illustrates the walls, angle, and contour of the prepared cavity.

In molar teeth, decay is sometimes found extending antero-posteriorly, completely through the tooth, approaching from opposite directions, until the central wall is destroyed, leaving the outer and inner plates of the tooth standing.

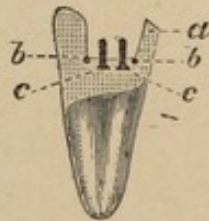


FIG. 49.

Transverse split section of lower molar from buccal to palatine surface.

- a a.* Bevelled edge of lingual wall.
- b b.* Anchorages in line of section.
- c c.* Headed screws sunk in floor of cavity (omitted in Fig 50).

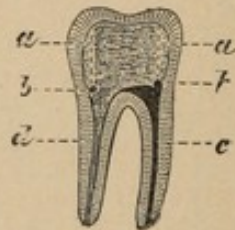


FIG. 50.

Longitudinal section of No. 49 (antero-posteriorly) showing interior of buccal wall.

- a a.* Grooves.
- b b.* Anchorages.
- c.* Pulp canal filled.
- d.* Pulp canal prepared.

This is exhibited, see Fig. 49, in the antero-posterior view of a lower molar with cavity prepared for filling, which, being split between its fangs, the actual division gives the profile of the plates, situation of the screws, and two of the anchorages preparatory to filling. This figure must be considered simultaneously with its companion diagram (50) which is an antero-posterior vertical section from the ante to the post-proximate surfaces, showing the interior of the buccal wall. It represents one fang filled with gold, the other ready for filling.

When the roots are filled, the preparation of the cavity in the body of the tooth may be continued, as represented in Figs. 49 and 50. The walls carefully dressed, and the outer surfaces finished, a fine bur should be

passed along the inner portion of the plates, making four vertical grooves in the walls of the cavity. At the bottom of each groove, an anchorage or retention point is required; these grooves, two on either wall, are situated near the four angles, rather less than a line from the outer edge of the cavity, and extend from the floor to a line separating the dentine from the enamel. Especially do I lay stress on the expediency of having anchorage at the termination of interstitial cavities when situated upon the occluding surfaces of molar teeth, as seen in Figs. 45 and 46, *a, a*.

In Fig. 49, are attachments for the gold, besides those already mentioned; two additional anchorages being formed at the foot of the walls, and midway between the four angles at the proximate edges of the cavity, while, at equal distances between these walls, are inserted two gold screws. The heads of these screws are so far cylindrical, that, when built in their appropriate places, all tendency to unsteadiness is removed.

The grooves and anchorages formed, with the screws in position, the filling should be commenced in one of the retaining points, the gold being conducted diagonally, intermediate between the walls; then, building from the opposite end of the diagonal, it may be worked towards the common centre situate between the two screws.

This process is repeated at the ends of the other diagonal, always approaching the centre, in which, eventually, the walls of both diagonals meet; thereafter connecting them with walls stretching from side to side of the cavity, and along the base. Four triangular cells will thus be formed, out of the floor of which the threaded portion of the screws will project.

By this methodical procedure, a network of gold is secured which, from its position, anchorages, grooves and

screws, offers resistance to any change of form, being welded into a solid mass, in which the walls and cells intervening are blended and lost.

In building, do not forget to devote proper attention to packing along the vertical grooves, as they steady the filling, while receding farther from the floor of the cavity. If the gold be used in fragmentary pieces, torn from the leaf, introduced into the vertical line, and tapped gently, there is no probability of the filling becoming detached from the walls, unless, as sometimes does occur, the outer or inner plate gives way. This can be prevented by dressing down the occluding surfaces, so that the gold may be carried over the edges (see *a*, Figure 49), on the principle before explained. The outer portion, being lower than the inner, draws the standing wall of the tooth towards the filling, thereby keeping it in place; also, being built above with gold, no direct force can come in contact with the tooth.

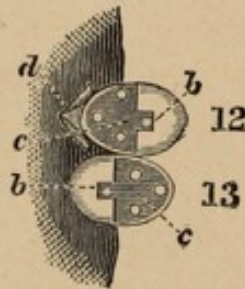


FIG. 51.

These teeth were figured in a condition of decay, see cut 16, Nos. 12 and 13. The white dots are intended to represent the screws.

In Fig. 51 (12 and 13) are two bicuspid teeth prepared for filling, in which one cusp only is left to each tooth. To supply the deficiency as here manifested, will require not only the investment of time, but considerable skill, for the means of attachment are not of a promising nature. These cavities are prepared by cutting perpendicularly and transversely, with a view of preserving as

much of the tooth as possible, and by forming the floor in such a manner that its interior surface shall be slightly beneath the level of the proximate and buccal, or proximate and lingual surfaces, so as to leave a slight elevation of tooth as a rim extending from the wall of the cusp entirely round the floor of the cavity. This rim acts as a support to prevent lateral displacement of the gold, the floor of the cavity having a flat horizontal surface, on which the filling is built. As in the previous cases, it is bevelled, and the gold worked over and upon the edges of the enamel. A square groove should now be vertically cut in the standing cusp, of perhaps the eighth of an inch in depth. On the step thus formed, a short screw is inserted (see *b b*). On the floor (*c*) of the cavity are three longer screws in position, as shown in Nos. 12 and 13. The anchorage, or starting point, is situated in the middle of the floor (No. 13 *e*). The filling has now a wall on one side, and a rim on the other; and, as the gold is built round the screws, it becomes firmly fixed to the floor, while the groove, and the anchorage provided in it, retain the gold in position, thus preventing any movement in the direction of the proximate surfaces.

The restoration should be fully contoured and flush with the remaining cusp, to protect it against accident; for, upon its preservation, depends the permanency of the filling.

In the extreme cases now cited, it will often be found necessary to incise the gum and lay it well back. This has been fully and extensively dwelt upon in former lectures, in connection with the use of clamps: the manner of treating the gum when impinging upon portions of the tooth to be operated upon having been illustrated in several figures.

I shall now refer you to the right lateral incisor in Fig.

17. Here the area and depth of the caries are so great that, when the diseased portion is removed, there is apparently but little upon which the filling can be securely attached. Yet, it is desirable to avoid exposure of gold upon the labial portion of the tooth.

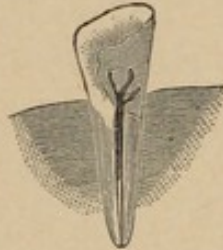

FIG. 52.



FIG. 53.

In Fig. 52 the nerve canal is laid open, illustrating a hollow, split cylinder of gold, inserted in the root previous to filling the tooth. This cylinder is represented in Fig. 53, and the cavity is prepared with a view to the insertion of this tube, the longitudinal division being made on one side, and extending its full length to permit enlargement of the tube at a later period of the operation. The tube is inserted in a socket formed by the circumferential extension of the nerve canal to about the depth represented by the black marking in Fig. 52; the upper portion of which is removed obliquely on one side, to about half its diameter, and about one-tenth of the total length. The edges, being parallel to the sides of the cylinder, are left similar in shape to the formation of a pen; on the projection of which three gold filaments or branches are soldered. When the cylinder is *in situ*, the "scoop" and filaments stand approximating the inner portion of the labial wall. The permanency of this position is now secured by building within the tube, the pressure causing it to expand and accurately coincide with the parietes of the socket.

Restoration is made along the mesial and distal walls of the cavity, in advance of the filling in the

central portion of the tooth, until it reaches a line parallel with the junction of the first extension of the tube. Should the arms be an impediment to the building process, being pliant, they are thrown aside, until the gold is carried to the points of their juncture, after which the arm first approached is forced down upon the floor of the filling, the work being again resumed until the junction of the arm on the opposite side is reached; and, that it shall not extend in length beyond the filling when finished, this also is forced on the floor, as in the case of the first. The third extension is permitted to remain in an oblique position, but so directed as to fall within the line of surface of the filling, as it assumes a narrow or wedge-like shape on approaching the cutting edge of the tooth. When restoring along the mesial and distal lineal border of the cavity, care should be observed to prevent horizontal fracture in the central region of the tooth. The strain becoming obviously increased by the repeated blows of the mallet, as it approaches the cutting edge of the tooth, precautionary measures should be adopted to support the enamel by the application of steady force upon the labio-cervical two thirds. This may be accomplished by the adjustment of a splint made for the purpose, so that the oblique line, or wall of decay, will permit the gold to be substantially packed along its facing surfaces.

In the same mouth (see Fig. 17, Lecture IV.), the central incisor and the canine are similarly affected, with this exception—that the decay in these teeth advances from the mesial and distal surfaces towards the central portion of the tooth, approximating in a juncture of decay.

The disease has penetrated the pulp chamber in both instances. The remaining sound portion of the tooth on the lingual surface, when dressed, conveys the impression

of a septum between the cavities; but the removal of the devitalized pulp forms an interior connection, leaving the septum rather as a support than a division. The extensive undermining of the linguo-cervical portion of the tooth, involving the meso-lingual and disto-lingual points, indicates the propriety of still further associating the septum with the protection of the labial surface. This is effected by carrying the gold over, and completely framing it in. To prevent any projection beyond the original lingual contour, the substance is removed to a depth of about the third of a line, extending to distances marked in the diagram, and tapering so as to connect the cavities without angularity. To be better understood, reference may be made to the following figures.

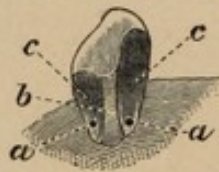


FIG. 54.

a a. Anchorages.
b. Septum.
c c. Labial walls of cavities.

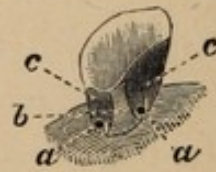


FIG. 55.

a a. Anchorages.
b. Septum.
c c. Labial walls of cavities.

The commencement of the filling is in the anchorage points *a a*, and is continued by building along the inner plate of the labial wall *c c*, until the gold has been carried to a level with the septum; it is then worked over it to preserve the contour of the tooth, part of the septum having been removed as already stated. The treatment of 54 is strictly analogous to that of 55.

In the left lateral (Fig. 56), decay had so destroyed the substance of the tooth that the enamel of the labial surface was literally all that remained above the gum. Frail and brittle, it appeared semi-transparent (*a a*), and presented the ragged and uneven edges as shown.

The nerve canal being prepared and filled, on the floor (*b*), two rectangular excavations were formed; and in each of these depressions, an anchorage was made. These anchorages, combined with the filling of the nerve canal, gave a very strong attachment vertically. To prevent lateral displacement, the feathery edges of the remaining enamel were carefully dressed, reduced slightly in height and width, and then bevelled from the labial to the lingual aspects. The gold, as it rose from the base of the filling, was returned upon the bevel; and, when the operation was completed, and the restoration of the contour of the tooth effected, the plate of enamel appeared framed with gold on three of its boundaries, as is represented in Fig. 57, *c c c*.

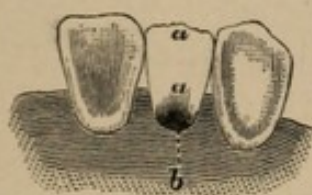


FIG. 56.

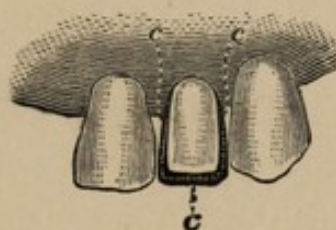

FIG. 57.

The case now presented for your consideration is one possessing unusual interest; and, should the method I propose to demonstrate be adopted by the profession, the hitherto objectionable feature of wearing plates where one or two teeth are missing may, in some instances, be discontinued, and the arch be restored to its full complement of power by the replacement, without plates, of the non-existent manducatory organs.

I formerly regarded with prejudice, and participated in the general impression as to the fallacy of, the means employed in cases of this kind; but I have witnessed results proving that, under favourable conditions, a lasting success may follow such treatment. The adoption of this species of practice must be entered on cautiously; for, unless the

neighbouring teeth are of solid structure, in healthy relationship with the surrounding tissues, and have living pulps, failure, threatening the expulsion of the natural organs, may be predicted. The tendency of modern dental science has been to render interposed teeth as independent as possible of support from adjacent living teeth. But, success being the result of a judicious practising of the method now proposed, it is to be predicated that inherent weakness and unfitness of teeth appropriated to the task, or the use of devitalized teeth, may have discredited a method otherwise adding to the many resources of which we have need.

It is not the exception, but the rule, to find the arch broken in mouths presented for professional advice, the tooth lost almost invariably being the first molar.

Accepting this as a fact, I shall endeavour to show, 1st, the origin of this tooth, following its transitional stages up to the period of eruption; 2nd, the morbid tendencies to which the abnormality of this organ may be directly attributable; 3rd, a means of restoring one or more lost teeth through the interposition of others without plates.

Unquestionably the first molars may be looked upon as being more susceptible to the influences of disease than are any other members of the permanent dentition, except the wisdom teeth. The removal of the first molar produces a break in the continuity of the arch, and often entails upon the victim a series of evils quite overlooked, because not traced to the mal-efficiency of the remaining triturating organs. This intervening space, when existing at any intermediate point along the buccal line, more seriously interferes with mastication than if the loss were directly in the centre of the arch, or at its terminal points.

Appearing in the primary dental channel at a very early period of intra-uterine existence, this tooth enters the tuber-

osity of the maxilla shortly before birth, and its saccular development progresses contemporaneously with that of the deciduous teeth, but so much slower that it is delayed some two years in its eruption, after the completion of the temporary dentition.

The continuation of the first molar in its sac until the sixth year is through a period of successive and severe maladies in the infantile economy; the diseases of childhood being so numerous and attended with such fatality that in a general way it may be stated that nearly one half the human race cease to exist during the period in which the papilla of the first molar has passed through its varied stages of dentinification. At the time of eruption, the disorders of infancy will have reduced the children of contemporaneous birth to the extent of 633 out of every 1000, thus showing the adverse influences which tend to direct nutrition from this tooth. Its eruption is also in unison with the general deficiency of calcification, characteristic at this age.

The completion of the temporary dentition is usually effected by about the fourth year; and, with the exception of such *causa morbi* as may develop in the deciduous teeth, no external manifestation of change is observable for some months subsequently, when the first molars continue their temporarily quiescent dentition.

The first molar, at its eruption, is very frequently mistaken by parents for a temporary tooth. Unrecognised it assumes its position behind the deciduous teeth; and a want of knowledge leads to neglect, under the idea that care is unnecessary; so that the tooth, which is for a long time in a comparatively feeble condition, is often irretrievably compromised before aid is sought. It is also subject to contingencies connected with the shedding of the temporary teeth, owing to lack of support and the

force of the muscles not being distributed equally over the other molars and bicuspid, for some years subsequently.

The recorded results verify the prognosis we are endeavouring to establish; the first molar having the pre-eminence of any of its contemporaries in the frequent attacks of disease. From the tables of Magitot it will be seen that about 33·5 per cent. of the total number of cases of caries are attributable to this tooth.

So great an antipathy exists to any mechanical appliance being worn in the mouth, that, when a few teeth only are missing, protests are made against auxiliaries of an artificial nature; but such being the vicissitudes of the first or six year old molar, and the probability being so great that of all others it will be lost, provision should be made to restore this missing organ with the least possible discomfort to those who have been so unfortunate as to lose it.

In referring to the diagrams illustrative of the method now under consideration, will be seen the several stages as indicated; but a more comprehensive idea may perhaps be obtained from the model which I now pass for your inspection, the buccal view of which is shown in Fig. 58.

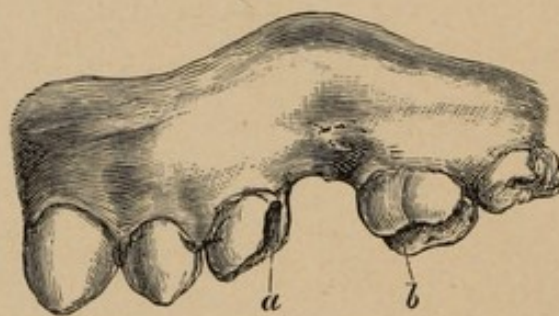


FIG. 58.

a b. Cavities prepared in molar and bicuspid teeth,—buccal aspect.

Here it will be noticed that the arch is complete, with the exception of the first superior left molar; and, as generally occurs, unless the teeth are extracted at

a very early age, or before the eruption of the *dentes-sapientiæ*, partial closure only of the inter-space is the result.

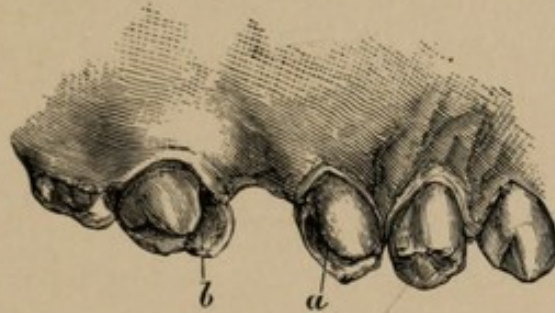


FIG. 59.

a b. Same cavities prepared,—lingual view.

In this case, it will be seen that the two bicuspid have fallen back to anticipate the advance of the molars, the second bicuspid having receded until it is independent and quite free from any impingement upon the adjacent tooth. The first bicuspid, however, has followed it, until the inter-dental space between it and the canine is of much greater extension, showing that the canine has not retrograded in the same *pro rata* to effect a closure equal to that existing between the two bicuspid.

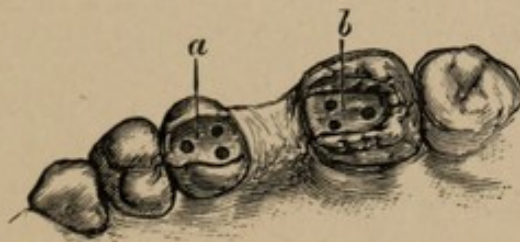


FIG. 60.

a b. Floors of cavities as prepared previous to adjustment of tooth.

Again viewing the space formerly occupied by the missing tooth, you will observe by the partial closure that a bicuspid only can be used. This I have had adjusted to the model that you may be able to see its relative bearings, not only upon the gum, lingual and buccal, but the manner of its attachment to the adjacent teeth.

The porcelain face being adapted to the buccal aspect of the gum, the deficiency upon the lingual side is, you will observe, fully restored with gold and contoured in conformity with the adjacent teeth (*d*), due observance being paid to its dimensions extending in a linguo-buccal direction. On the sides contiguous to the teeth are bars of pure gold, which extend into the adjacent teeth overlapping upon the floor of the cavities to their medial points; and beyond this is located an anchorage in which to start the fillings that are to close in and securely fasten these projecting arms in place.

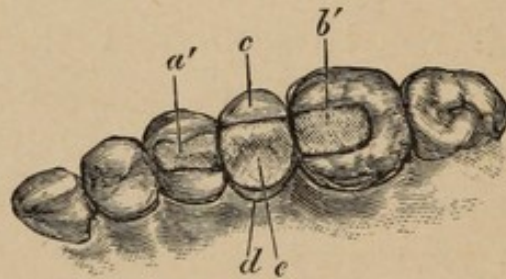


FIG. 61.

a b. Cavities filled, indicating points showing termination of cross bars in teeth.

c. Porcelain face.

d. Point of juncture of gum with linguo-cervical portion of interposed tooth.

e. Gold cusp, made in conformity to adjacent teeth, and to articulate with those opposing.

Without being influenced by the prejudices of others, I have endeavoured to enunciate a method which may, for a time, be sceptically received. The adverse criticisms by the profession, heretofore, I believe to be caused by ill-advised operations upon teeth having their investing membrane complicated by disease at a recent or remote period. Hence the necessity of ascertaining the pathological condition of the organs that will permit an operation of this nature.

LECTURE X.

Delivered at the National Dental College, London, Dec. 10th, 1879.

IN practice you are expected to follow the guidance of fixed principles, yet the mind should be free to accept alternative measures when found more applicable than the traditionary methods of the past. In my previous lecture it was mentioned that, "unless the neighbouring teeth are of solid structure, in healthy relationship with the surrounding tissues, and have living pulps, failure may be predicted." I shall now qualify that remark by saying that, although pulpless teeth are objects of suspicion, there are circumstances under which the risk of the operation may be taken with little or no prospect of bad results; immobility, evidencing the integrity of the periosteal circulation and the general tone of the wearer, should indicate when a devitalized tooth may be used for the attachment of substitute teeth. I question, however, under the most favourable conditions, the advisability of actually fixing, in the manner already described, an artificial crown to a pulpless tooth. Recognizing this feebleness, it would be better, if possible, to avoid any tension further than vertical pressure.

In the case now instanced, the original space of the missing bicuspid was but little diminished, so that the substitute was modelled in form nearly analogous to the plan of the original tooth. At its cervical boundary, it was made to accurately follow the deviating surface of the gum, while cusps and concavities were established on the crown, in perfect conformity with the indentations and cusps of the antagonizing teeth. The arrangement for

its retention, however, was somewhat different from that in the case of interposition illustrated in Lecture IX.

The first bicuspid—devitalized—permitted the connecting bar on the ante-proximate surface of the substitute to be formed so that it fitted into a prepared socket. But in the molar—a living tooth—the filling was much more circumscribed; no vertical turn could be given to the attachment which it was proposed should pass from the substitute into the filling. The post end of the bar was placed in a nearly horizontal position and projected at a slight declination from a right angle to the post proximate surface of the substitute.

When the preparatory cavities in the teeth were filled, a secondary cavity in the gold was formed, and the interposed tooth adjusted to the gum, and articulated with the occluding teeth; the extension bar (*b, c*, Fig. 61) was then secured by building it into the secondary cavity in the filling of the molar. The model which I submit for your inspection will perhaps better explain my meaning, which is still further illustrated by diagrams 60 and 61. The arm on

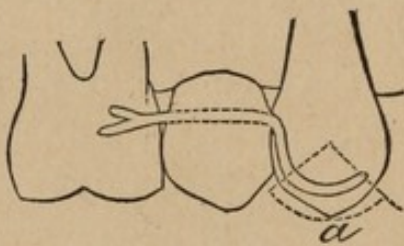


FIG. 60.

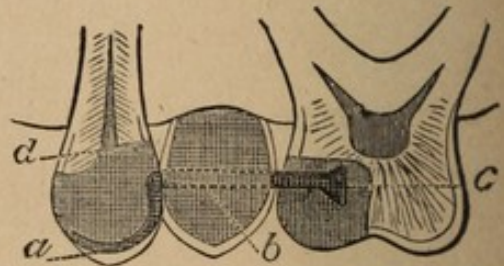


FIG. 61.

the ante proximate portion, being of greater length than that on the post proximate, is bent into a curve which forms part of a circle having the groove in the filling, corresponding in curvature to the wire, for its circumference.

By this arrangement, the dead tooth is permitted to vibrate through a short arc (*a*, Fig. 60) without altering the

nature of its attachment. The curved arm (*a*, Fig. 61) is adjusted to accurately fit the groove; pressing the tooth firmly, but not aggressively. The grooved socket extending over upon the occluding surface is entirely formed in the gold filling, no fractured or decayed portion of the tooth at any point being exposed to the secretions of the mouth, while the extension arm and socket is simply the action of gold upon gold.

In the case of two bicuspid, I had the missing teeth carved in block, so as to fit the model and articulating cast. A platina bar, which extended through both teeth, was adjusted in the block similar to that represented in *b*, Fig. 61. In using mineral teeth, the chances of detecting them as artificial are much lessened, while the artistic appearance of the work is materially enhanced.

The buccal and lingual aspects of the substitute must be contoured so as to strictly conform with the natural curve of the arch, the object being to make this foreign body undistinguishable in form from a natural tooth, the very existence of which should—during the ordinary avocations of life—be forgotten by the wearer.

Where the arms require to be made very delicately—the shape or condition of the teeth not permitting extended excavation—pure gold, with such small sectional dimensions, will not be sufficiently rigid. The bars are then to be made of platina, this being a malleable and tenacious metal, which, once established in position, is apt to be retained.

I have already alluded to the teeth—especially those situated in the anterior part of the mouth—in connection with human physiognomy. This may be deemed unimportant; but its relevancy to the conservative treatment of these organs should not be underestimated.

When the labial aspect of the tooth remains intact, we sometimes find peculiar forms of decay extending over

the lingual portion, until the organ is reduced to a mere semblance of its original dimensions, the substance of the tooth being destroyed by decay approaching the centre from both proximate surfaces. This sometimes results in an entire loss of the lingual wall, the enamel on the labial portion of the tooth requiring to be framed in and supported by means quite independent of itself. You will have to contend with the prejudices of your patients against any elaborate display of gold, under which circumstance an example of ingenuity, as well as of the more solid virtue, skill, will be required.

I now present for your consideration two superior centrals, representing teeth in the condition just mentioned, after having been operated upon.

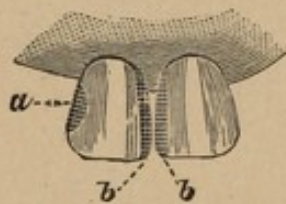


FIG. 62.



FIG. 63

Although one is in the third, and the other in the fourth stage of decay, it is convenient to consider them in conjunction with each other. In the right central incisor the pulp was removed and the root filled, the labial wall of the enamel being so thin in its central part (transversely) as to be incapable of any great resistance to shock. The distal and mesial proximate surfaces (*a b*) were then bevelled upon their labial facings, so as to present an edge lingually; after which anchorages and grooves were made in the more solid substance of the tooth at the base and cutting edges. The filling, when reflected over the mesial and distal proximate surfaces to the commencement of the

bevelled edges on the labial wall, protected the enamel in its weaker parts (see Fig. 62). The gold extending over the lingual wall is shown in the companion Figure (63).

Although the right central presented but little of the tooth proper on which to make restoration, it required less delicate manipulation than that bestowed upon its companion, the left central—a living tooth, but with the pulp exposed. Here the means of attachment were much more difficult, owing to the necessary bridging of the pulp, to obstruct thermal change, which acted as an impediment to the easy formation of any cavity that would support a filling.

The meso-labial portion of the enamel was bevelled, as in the case of the right central, and both teeth contoured to their original shape with gold (*bb* and *a*).

To illustrate the next and last case which I shall bring before you, I am compelled to again introduce the subject of abrasion, which was only alluded to in Lecture IV. and exemplified in Figures 19 and 20.

Caries and erosion are not the only destructive agents acting upon the teeth, but a peculiar mal-condition is frequently found, resulting from abrasion, the lost tissue being worn away without necessarily involving decay, although the latter may co-exist with the former lesion. Abrasion may be considered concomitant with the formation of dentine of repair, which is one of nature's prophylactic measures to arrest encroachment, the pulp receding correspondingly with progressive disintegration, thus so negating the hyperæsthetic condition of the teeth as to permit their being abraded nearly to the gum with little or no inconvenience. Odontotripsis is described under two heads, viz., chemical and mechanical. The first usually makes its appearance on the anterior teeth, rarely extending to or

beyond the pre-molars—differing in character and situation from erosion. It is of comparatively rare occurrence, and has been ascribed to certain electro-chemical influences; also to acid mucous secretions of the vestibule of the mouth. The causes that develop this lesion are obscure, and the text books greatly repeat each other in regard to it; but the instances given and figured in Harris represent the typical forms of the disease. Treatment consists in restoring the abraded teeth with gold until their normal contour is attained. The physiological tendency of abrasion of this kind is to cause disfigurement, with but very little change in articulation, as the force of the disease is generally spent upon the labial and buccal surfaces of the anterior teeth.

In the second description, however, the pathology of the case is very different. Mechanical abrasion may commence at a very early period of life, and continue slowly to break down the substance of the organs until the advance of age determines their further tolerance in the mouth. In the normal articulation, the superior incisors slightly overlap the inferior, and, as an ill-constructed pair of shears may be made to destroy their own edges, in like manner an abnormal closure of the maxillæ may cause the incisors to abrade each other. Where this exists, treatment will consist in restoring the original articulation, as previously described.

Such then are the two recognised agents in causing abrasion; but I shall now describe a case in practice proceeding from the latter, which occasioned constitutional disturbance to such an extent as to produce insomnia. This abnormal condition had developed a species of disease—*stridor dentium*—resulting from an acquired bad habit that eventually resolved itself into functional derangement of a serious character. By this habit the

crowns of the remaining molars and bicuspid had been reduced to very much less than their original length (*vide* illustration).

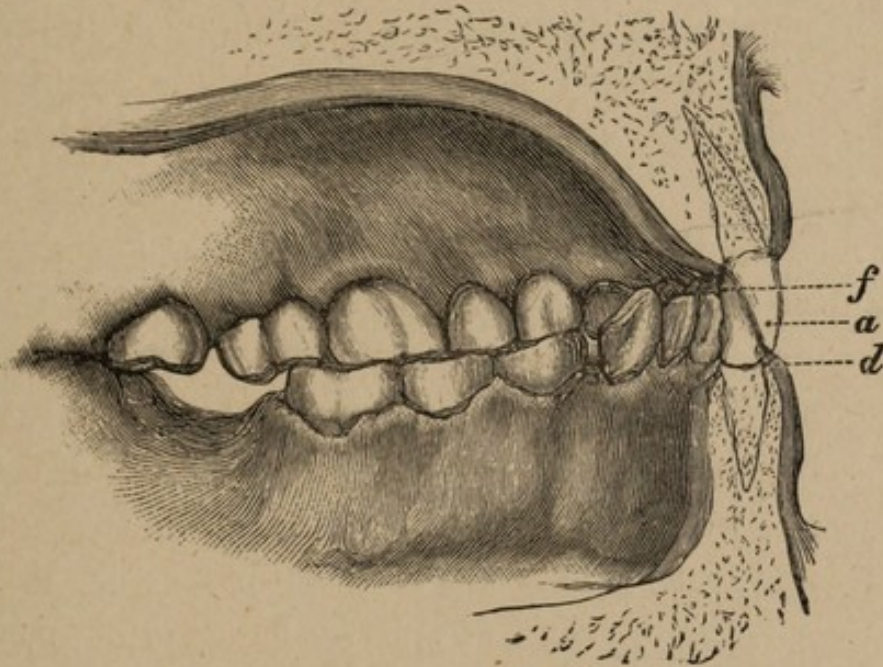


FIG. 64.

- a.* Right superior central (outlined tooth).
- f.* Right inferior central, with cutting edge imbedded in palato-gingival borders.
- d.* Gum, labio-dental region, showing near approach of the superior central to it.

The four cuts delineate the same number of stages, and are intended to define, first, the condition of the mouth as originally presented, showing occlusion, with aggressive action of lower incisors; second, the preliminary and progressive measures during the different stages of operating, comprising restorations with gold on the right side to obtain the normal articulation—leaving a hiatus on the left side in the region of the molars; and, third, the ultimate results as a sequence to adoption of the above measures (see Figures 65 and 67). The drawings are made from split sections of models taken from the mouth, the outlines of roots and gums on the sectional

surface being imaginary, and added to define the relative position of the roots and crowns on occlusion, both in their morbid condition as well as after treatment. The case presented many unusual features of interest, from the peculiar nature of its lesions, conspicuous among which was that the abraded teeth on one side were upon the upper maxilla, while, on the other, this was exhibited upon the lower.

Considering the complications involved as a sequence to mechanical abrasion, the initiatory therapeutic measures made restorations upon the buccal teeth obligatory, in order to effect a release of the incisors from contact with the gum. This was commenced by building the bicuspid and canine on the right side with gold (*b*, Fig. 65) until, upon closure, the maxillæ were separated to a normal articulation, exhibiting a space on the left side (*e*, Fig. 67) showing the extent to which abrasion had occurred.

The maxillæ with their subordinate organs constitute an elaborate mechanism with all the parts in harmony, and the adaptation of this mechanism to the wants of its possessor is clearly recognised. Should, however, these relations be disturbed, the consequences are difficult to foreshadow. The reciprocal action of the teeth on closure avert serious compromise to health. During repose of the maxillæ, it will be observed that the pressure gradually diminishes from the posterior to the anterior part of the mouth, the distribution being more especially upon the molars, decreasing on the bicuspid and canines, while the incisors, in consequence of the superior arch being larger than the inferior, do not occlude, but are held in close juxtaposition at such a distance, and so far overlapping, as to endow them with the cutting capacity from whence their name is derived. The part taken by the molars in sustaining the integrity of the articulation must ever be

remembered, as disease referred to the incisors may really be caused by the loss, from abrasion, of the crowns of the molars and bicuspid. Gradually the antagonising power of the molars decreases, while, in the same proportion, the spaces between the cutting edges of the incisors diminish until they impinge upon each other. A similar condition to the above is shown in Fig. 64, in which it will be observed that, in the molars and bicuspid of the inferior

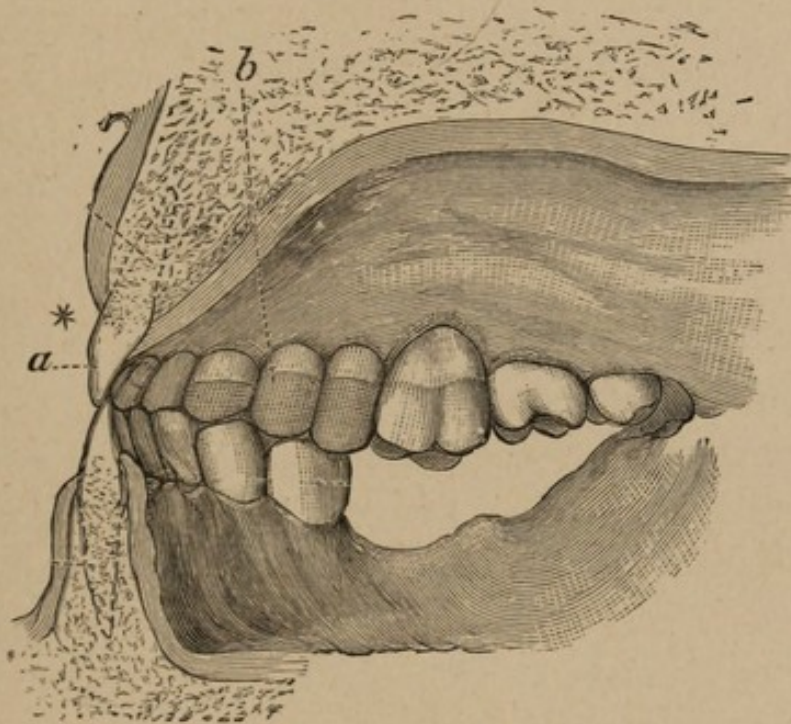


FIG. 65.

- a.* Left superior central (outlined tooth).
- b.* Cross etching, denoting the extent to which the canine and bicuspid were built.

maxilla, great loss of substance had occurred. This gap, so apparent on the diagram, could only be evidenced when the incisors were, by extraneous means, held at their correct distance. Although the teeth now under consideration were so much abraded, they were still firmly fixed in their sockets; but to provide an interposing substance was an imperative and immediate necessity, as the nervous

system had become seriously affected by the disarrangement of the whole articulation.

The abraded organs, with their table-like crowns, came under the description where no walls remain to build upon, and in which special anchorages, or retaining points and grooves, would have to be devised.

This is illustrated in the following enlarged diagrammatic section :

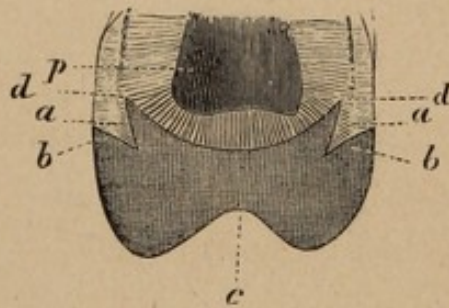


FIG. 66.

- a a.* Keying rim.
- b b.* External bevel, built over.
- d d.* Groove.
- c.* Restoration with gold.
- p.* Pulp.

The exposure of the pulp chambers in the left inferior bicuspid rendered the devitalization of the pulps a necessary measure, and the pulp chambers and canals being filled afforded an anchorage to which further attention need not be drawn; but the case was different in the one molar on the left inferior maxilla and the bicuspid of the superior right. The abrasion had so nearly involved the pulps in their recession as to be in close proximity with their chambers, the intervening substance being dentine of repair. The preservation of the thin intermediate structure was of primary importance; but its lack of substance precluded the removal of any portion of the dentine directly

covering the pulp. Each of the teeth enumerated was bevelled at its periphery, so that the crown when prepared resembled a flattened dome, the bevel increasing in its verticle angle as it reached the enamel. Inside this exterior level, a groove was cut entirely round the crown at a distance of about 1.6 m.m. from its circumferential exterior. This groove was not perpendicular at any part of its section, its exterior wall overhanging its base at an angle of about 15° from the vertical. The interior wall constituted a second bevel parallel to the external one already described, and at about the same horizontal angle. The gold was then forced into this sulcus which, from its sectional peculiarities, afforded security to the filling, and offered resistance to the vertical and lateral pressure, so that it could not be lifted without breaking the keying rim *aa* (Fig. 66). But the pressure outward, during the process of mastication, would have a tendency to totally displace the rim. This was obviated by the external bevel being built over (*bb*, same figure), so encasing the enamel edge as to afford it protection from downward and outward pressure, thus preserving it from shock. Lastly, the dome-like shape of the whole crown would offer an extended and diffused, though passive, resistance to general displacement, the groove and bevel effectually preventing any initial movement, the keying rim *aa* acting as an abutment to the dome.

During the application of remedies to reduce the hyperæmic condition of the gums, the molars and bicuspid of the left inferior maxilla were built to a corresponding antagonism with those restored upon the right side of the superior maxilla.

Fig. 67 is a second view of Fig 64, which shows the improved juxtaposition of the outlined tooth (*a*), with the opposing inferior central. The dotted line (*e*) indicates

the extent of the previous mal-articulation, shown upon the recovery of maxillary equi-distances, by the building of the right superior bicuspids and canine.

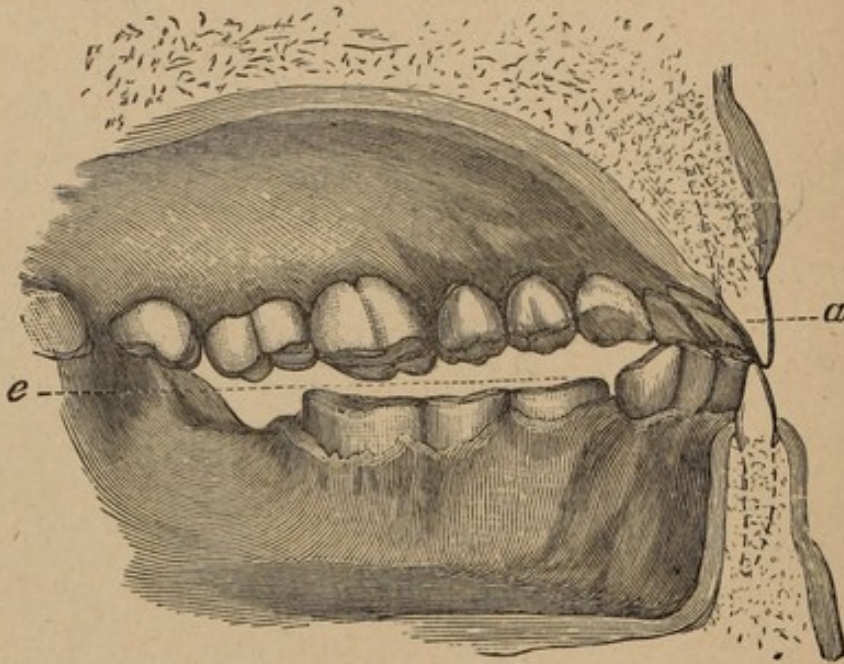


FIG. 67.

a. Right superior central (outlined), shown in contradistinction to the position, as formerly occupied in Figure 64.

e. Dotted line, showing extent of abrasion on left side, the teeth on the right side having been built to their original contour.

The case under consideration was such as rarely occurs in a single dentition, and was the more striking as its lesions were ascribable to a single traumatic cause, which very well illustrates the different characteristics that may be presented, not only in different teeth, but in teeth of the same denomination.

The abrasion was attributable to mechanical attrition, rather than to any lack of the normal constituents of the teeth, their ascertained density being an incentive to the treatment pursued.

Fig. 68 represents one tooth on the superior maxilla and three on the inferior, built to their normal height, thus remedying the deficiency shown in the last figure, by

supplying occluding surfaces, auxiliary to the restored crowns of the teeth on the right side.

The effect of this treatment was to readjust the equilibrium of the arches, and, at the same time, to arrest all traumatic action of the inferior incisors upon the abraded portion of the upper centrals and gum.

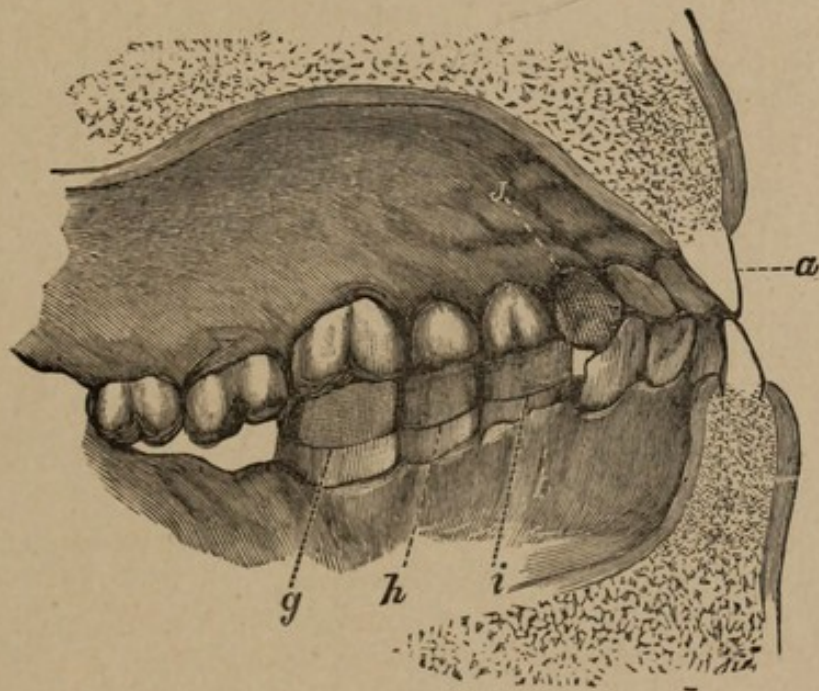


FIG. 68.

- g h i.* Lower bicuspid and molar restored.
i. Superior left canine, with lingual surface rebuilt.

With the readjusted articulation, the facial appearance was much improved, the lips lost their cramped expression, while the nervous irritation under which the patient had been suffering eventually passed away; as also the habit of grinding the teeth.

The success of restoring lost portions of abraded teeth with gold having been exemplified in my own practice, as well as still further evidenced in the work of others, I can unhesitatingly recommend it as a perfectly justifiable measure when adopted by the careful and capable practitioner.

I now come to the eighth clause of the classification as given in Lecture II., *i.e.*, "finishing, treatment of the mouth, and advice." The first section—the more minute details of which will be given in the demonstration room—will occupy my time very briefly; while the last two sections, coming more particularly under the head of therapeutics, will be discussed in that department.

In the formation and retention of a surface, the finish in a great measure depends upon impaction of the gold, especially along the marginal edges. Absolute density cannot be secured, nor is it so essential in the earlier stages as at the closing period of the operation, yet solidity must be attained at a point beyond that which will possibly be involved in the process of finishing. Although differing much in character, and united under peculiar conditions, the tooth and gold should be as nearly the counterpart of each other as mechanical forces can make them. In speaking of contour fillings, I have done so with the conviction that restorations approaching the original form of tooth contribute to functional power, and, by re-establishing the articulation, relieve the associate organs from an excess of work that would otherwise be imposed.

The extra pressure brought upon the remaining teeth, not only in the original direction, but laterally, causes displacement, so that the preservation of true contour is a desideratum. The overhanging or projecting portions of the restoration should be removed, without destroying the shape, which is intended to represent, as nearly as possible, the original tooth.

The finish may be considered a crucial test, and will expose without fail any slovenly manipulation in the primary or previous stages of the operation. Therefore no pains should be spared at this important period,

as it may be fairly surmised that a want of care in this indicates a lack of skill throughout. The gold must not project at any point over the walls of the cavity, neither should it encroach upon any of the outer edges of the enamel; on the other hand a cup-shaped filling will not be admissible, unless occasioned by the occluding cusps of antagonizing teeth. Where there is a lack of continuity—of tooth and filling—causing impediment to an instrument passed over the surfaces in any direction, the attempt at diastostic measures may be considered as yet unaccomplished.

I have endeavoured to bring before you examples of the means that may be employed when operating in a field limited to thirty-two small organs, and the executive talent to apply such means becomes obviously apparent, when viewing the structural change which may occur in the teeth. Hence the necessity that so responsible an organ as the hand should—no matter how skilled—be under the guidance of a mind thoroughly qualified to direct it.

Clinical attendance not only makes the perceptive faculties keen in differential diagnosis; but it is here that valuable information, difficult to be gained through any other medium, may be secured. The tracings of disease in its manifold and diversified stages are calculated, by practical demonstrations, to impress upon the mind the truth of established principles. The student in medicine (of which dentistry is a specialty) will frequently find himself in error through misconceived ideas obtained from theoretical deductions only. For general or special information, it is necessary for him to constantly resort to books; in them he lives again the lives of those who have gone before, and the fire of their imagination glows afresh in his own mind as the facts marshalled in stately array present him with irresistible con-

clusions. To pause here, however, would result in many opportunities being lost through indecision consequent upon defective practical training.

The discrimination requisite to enable him to adopt that which is beneficial can only be gained by an intimate acquaintance with the entire field of the science, the aspect of which constantly changes, though the ancient landmarks may always remain. The whole sphere of human effort indicates the necessity for untiring energy in practical action, until that which at first presented obstacles becomes but a step towards a higher walk, and is lost in the array of things past. The fulfilment of the hopes of the student in acquired competency is happily presented as the end; but it will not be reached without continuous labour,—labour which may result in a gradual concretion of character, skill and theory, until, by imperceptible degrees, the world assigns an unrivalled position.

I shall now pass to the second part of the heading of my lectures, viz., therapeutics, premising that in this division the methods in operative dentistry will for a time become subordinate.

LECTURE XI.

Delivered at the National Dental College, London, December 17th, 1879.

HERETOFORE I have been unable to avoid Pathology, or to entirely dismiss Therapeutics; and it will now be necessary to recapitulate, owing to the intimate relationship of Operative Dentistry to these two sections.

The causes which are found to operate adversely to a normal state of health will also act as an impediment to the full and perfect functional activity of any organ in the economy; and the teeth are not exceptions to this rule.

Peculiar formations of teeth undoubtedly do accompany certain temperaments; but this assertion is only made with the same relative accuracy with which mathematical terms are used in anatomy, and cannot be considered arbitrary. Nature delights us with surprises and exceptions, which, though seemingly anomalous, prove to be but the exponents of a law more remote than we had at first suspected. Every healthy organism has its parts co-ordinate, and each individual economy an established law harmonious to the system of the universe. The differences of feature which distinguish people from each other are unmistakably impressed upon every portion of the frame, including the bones and the teeth.

The maxillæ may be considered as intimately connected with: 1st, physiognomy; 2nd, physiology, and 3rd, temperament. The configuration and the relation to each other of the upper and lower jaws, together with the structure, form and arrangement of the teeth implanted in them, are conditions which essentially de-

termine the functional worth of the teeth and masticatory apparatus. In the well formed arch, with strong regular teeth in constant use, as in the lower races, little or no caries will be found. In crowded and irregular arches, with ill formed teeth and diminished activity, there is marked disposition to and prevalence of caries which brings about impaired mastication, and, as a result, imperfect digestion. These instances will serve to briefly illustrate the relationship between the systematic formation of these parts, their functional use, and the diseases to which they are subject. The massive square jaw will be found to contain the more circular and expanded dentitions, which may be traced through an infinite succession of phases, until the extreme is reached of the narrow maxillæ and overhanging cerebral development of the melancholic or encephalic temperament. The differences blend imperceptibly from the extremities of the scale, and, although diametrically opposite, at points have so much resemblance that some approach to a system of classification might be made. As, in music, the vibrations pass into each other by degrees imperceptible in themselves, until a note, or a portion of a note, becomes so pronounced that it receives a name, and can be borne on the memory, so do we find a law analogous to this in the human species—differences expressed in ordinary language and understood by the masses, while medically they are distinguished as temperaments. In calling attention to the different temperaments, I shall endeavour to give you a classification by which to distinguish disease as manifest in the teeth.

It may be questioned, what special reason is there for introducing the subject of temperaments here? and in what manner, directly or indirectly, does it bear upon operative dentistry? Very much depends upon the intelligent

manner in which remedies are applied, and a most valuable adjunct to diagnosis, where the diathesis is somewhat obscure, lies in a discriminating power to trace cause to effect through a knowledge of certain influencing tendencies in temperament. From the natural reticence of those who apply for relief, it is necessary to have some independent means by which to establish an opinion as to the resistance or susceptibility of disease in any special organ—conclusions that can only be formed by examinations that will give a ready insight into the economy. This may prevent the employment of incompatible materials for filling, which otherwise would ultimately prove a cause of adverse criticism, resulting, not from any lack of care, but from palpable error in judgment. Especially is this the case with young children, and the subject of calcification or disintegration of the teeth with advance of age is one worthy of earnest investigation. Here the subject of temperaments will greatly aid you, as it is not the present state which alone requires attention. Disease existing at the moment may be clearly traceable ; but the treatment best calculated to insure permanently beneficial results must come from a just appreciation of the condition of the system as influencing the teeth, and any practical benefits otherwise conferred must in a measure be considered empirical.

The ancient reasons given for the temperaments are now more or less obsolete ; yet the germ of truth in them was sufficient to warrant the retention of the nomenclature, which affords convenient signs to indicate certain conditions of the organization. They have been classified by some writers under the following headings, namely, the sanguine, the bilious, the melancholic, the lymphatic, and the nervous.

In the sanguine temperament, you may expect a ruddy,

TORONTO

healthy complexion, full contour of neck, and predisposition to determination of blood to the head; the development is usually muscular, the extremities warm, and the mind free from hypochondria. In such an organism, the teeth are generally of a yellowish tint near the gum, gradually fading to a lighter hue at their cutting edges.

The bilious temperament displays a sallow complexion, the circulation of the blood being slower, while the body presents an angular appearance. Those possessing it sometimes fulfil the idea of having "an iron will," but instances of resolution are not unknown to other temperaments, being developed by favouring circumstances, until the original character is overshadowed by the new.

Another temperament embraces a class designated the melancholic. In physique thin and spare, with narrow, deep chest, the distinguishing feature is the prominent and fully developed frontal bone; a severe and usually stereotyped expression being depicted upon the countenance. In this temperament, the powers of thought are ordinarily deep and strong.

The lymphatic temperament imparts a hyper-sensitive-ness to the teeth, and, although these organs may appear good, they will, in many cases, be found defective. Chronic diseases are more often developed in this temperament than in any of the others.

The nervous temperament is characterized by greater activity of body, and is more susceptible to impression. The mind being easily excited, great despondency and nervous fear are occasioned by incidents of a very trifling nature. Here you may look for the contracted maxilla, in which the teeth are crowded from the moment of their eruption.

The characteristics of temperament, so indicative of the predisposition of the teeth, point to the necessity for

systemic treatment in many cases, to avert local consequences.

The teeth may be classified as, first, those usually found associated with the sanguine temperament. The prominent points, although displaying well the presumed cuspid development, are not separated by abnormal sulci, and the organic basis substance is united with the earthy matter by a perfect calcification.

Sometimes, from congenital peculiarities, large teeth are developed in jaws of limited dimensions, resulting in marked disfigurement, a condition that requires careful judgment as to the time when treatment should be given, and the means to be employed. Constant but gentle pressure will generally force the teeth into their normal positions, thus causing expansion of the maxilla adequate to the requirements of any ordinary case. Should, however, the derangement be so excessive as to preclude this measure, the removal of a tooth on each side will permit of ample space in which to force the remaining teeth into their true curve; the tooth to be selected is usually the first molar, for reasons already enumerated. Such a course will often result in greater benefit than if the teeth were permitted to remain. With the recognised mechanical appliances at your disposal, the voids, if not entirely closed, can be reduced to a minimum, and rendered imperceptible to the ordinary observer. Crowded teeth in the mouths of adults are not so amenable to treatment, and are the cause of much serious mischief from mechanical and chemical action. Constant watchfulness will be required to prevent lesions of an aggravated form, owing to the difficulty of a sanitary condition of the mouth being observed; for, while teeth so abnormally situated have the appearance of being sound, disease often makes serious inroads upon them

without cognizance being taken of it. By the irregularity of the teeth, pockets are formed in which, not only food, but vitiated secretions are permitted to lodge, and by chemical action these form acids, destructive to the enamel. Tests should be applied to the fluids pouring from the glands and mucous surface into the mouth, to ascertain whether their condition contributes another destructive agent to decomposition of substances remaining between the teeth. With the particles of food so detained, an alkaline state of the oral secretions may be no security for the preservation of the teeth, save in the exposed parts which we know in caries are often mysteriously preserved; but, on the contrary, by combining with some of the products of decomposition, may release other agents injurious to the teeth. Another ill effect of crowding is friction, developed on the proximate surfaces during mastication. The formation of the alveolar process, and the intervening periosteum, together with the general disposition of the muscles of the face, favour a limited mobility of the teeth. Therefore, when the moderately hard alimentary substances are comminuted, the distribution of pressure over the general surface of the teeth is unequal. Those occluding will sink slightly in their elastic setting to a distance inappreciable to any ordinary measurement, but sufficient to eventually remove by friction the enamel on the proximate surfaces, unless the teeth are independent of each other. This aids the destructive inroads of the various other causes of offence, and hence the numerous cases of decay on the proximate surfaces which are only revealed in their first and second stages by the use of the finest exploring instrument.

The second class of teeth are associated with the lymphatic temperament, and partake of the general attributes of the physical being of the individual. The laxness of

the tissues and the tendency to serous effusions have their counterparts in the excess of gelatinous constituents in the teeth. The tendency to disintegration is associated with exquisite sensitiveness, combined with a leathery toughness indicative of their structural peculiarities.* Here the exhibition of any hardening agent is strongly indicated; and if a sufficient, but not excessive, reaction can be produced, it is not unreasonable to suppose that there will be deposited a semi-transparent dense stratum, thus bringing about a change in the tooth that will admit of the use of gold as a filling material. The oxy-chloride of zinc may be employed as an excitant for promoting the condition just named; tin, however, can hardly be considered second to it as a material for preparatory purposes. After a period of several months, the test filling can be removed and a note made of progress in Nature's defensive efforts. The formation of the hardened stratum extending cone-like towards the pulp may be prolonged for an uncertain time. On the removal of the filling, should it be found that this tooth density has not been attained, it will be necessary to refill the cavity with a similar material, as the only means by which to preserve the organ. Caries in this temperament would run a swift and destructive course if neglected, owing, perhaps, to struma or hereditary tendency to disease. In youth, the use of means adapted to preserve the general health, combined with frequent examinations, will be necessary.

In the third class there is no marked absence of calcerous deposit. While there may be a superabundance of it, it appears to be in an amorphous rather than a globu-

* These teeth are such as not to permit the employment of gold with permanently beneficial results without a preparatory course of treatment, in order to close the foramina of the tubules in proximity to the cavity.

lar condition; indicating that the forces which govern the disposition of the lime salts have been deficient during the development of the organs. The spiculæ into which the anastomoses and ramifications of the canaliculi divide the intertubular deposits figurately resemble carbonate of lime, as illustrated in chalk, rather than the crystalline state of marble, or the fluor spar (fluoride of calcium) which takes so beautiful a polish. These teeth are a most fertile field for dental labour, and are found in all temperaments, but predominate in those of a strumous diathesis. The employment of gold will not always be satisfactory when used even upon adults; so that, in childhood, improvement should be aimed at by a dietetic regimen calculated to stimulate an active deposition of lime salts in the osseous tissues, previous to the use of any permanent filling material. Liquor calcis, the coarser cereals, and general bone-producing elements should be the main staple of food; while the improved tone of the system may favour protoplasmic formations that constitute a part of the normal and healthy tooth.

We will now review the last class—namely, teeth of symmetrical shape and pearl-like tint. These are found in delicate physical organizations, and usually belong to the nervous temperament, sometimes to the encephalic. The dental organs correspond with the general development of the system of the individual, being small and well-formed. They show no special tendency to caries; but, should the incisors be attacked, great disfigurement ensues, as the transparent enamel reveals an intensely blue black spot, which can be seen from a considerable distance. The remarks made on the other teeth apply to these, but the limited original vital impulse is such that treatment should, if possible, be accompanied by strict attention to the general health in youth. In regard to this I may remark that

the development of tuberculous diseases, contrary to what might be expected, does not appear to influence the number of cases of caries—consumptive persons often going to the grave with dentitions perfect to outward appearance; but the deficiencies common to the tuberculous (from that low vitality which permits degenerate substances to be formed within the system) may exist, and distinctive evidences of disease would, I doubt not, be found stamped on the teeth, could a sufficient number of them be examined with microscopic accuracy.

Having briefly noticed the classes of teeth, I shall now pass to the consideration of (1) disease of the teeth, and the deficiencies which may be suspected in their development; (2) the lesions to which they are subject from external influences; and, lastly, Therapeutics as applied to these two sections. Treatment will embrace the hard and soft tissues of the oral cavity, and extend into the facial region, incorporating the diseases of the antrum, the actual contact of which sinus with the apices of the roots of the anterior molars, brings some of its affections strictly within the denomination of dental lesions.

Important and sometimes misunderstood pathognomonic symptoms may be developed in infantile diseases resulting from dentition. There are instances, however, where the eruption of the teeth proceeds with remarkable freedom from pain; but more generally it is accompanied with a variety of lesions, and the dentist, in common with the physician, may be called upon to decide to what extent the disorders of the infant are attributable to the teeth. In recognition of the intimately connected relationship of the teeth with systemic disorders will be found a justification of the extensive curriculum now demanded of the dental student. It is unquestionably a fact, quite overlooked in many instances,

that reflex action primarily induced by erupting teeth is "but the spark to the flame which burns only on some previously existing morbid material." Hence the pathology of such existing disturbance should be thoroughly understood. Dentition in the infant may induce any of the following—*i.e.*, epilepsy, ophthalmia, otitis, cutaneous diseases, diarrhoea and other morbid reflex actions. At the period of eruption, the gums become tumid, the saliva increased, and the child restless. In aggravated cases, the general economy is involved, various symptoms indicating the disturbance, as diarrhoea and pyrexia, which are commonly associated with early dentition.

Although treatment of infantile diseases arising from the teeth might be considered the special prerogative of the dentist, it is the custom to place these cases in the hands of the physician, and, not until systemic derangement resulting from these organs has been superseded by that of a local character, is the attention of the dentist ever called into requisition.

With the busy medical practitioner whose mind is preoccupied with more *apparent* causes of suffering, disorders originating in the teeth are too frequently overlooked, even when reflecting cerebral disturbance, as well as the influence they may exercise upon organs of a less vital character. The complicity existing between these several sections of the economy is clearly proven by the aberration in perception of pain so frequently to be contended with in daily practice; and, to show that the importance of this question is becoming more appreciated by medical men, I quote from an author writing upon the sympathy existing between aural and dental lesions, who "was so much impressed with the frequent co-existence of" those "diseases in many of the patients who came to him with the former affection, that he resolved to assume the task of

recording the results of any subsequent observations on the subject."

He remarks, "The pain of the teeth, which we familiarly associate with their inflammatory condition, is signally absent in many of their affections, and it is to the absence of this symptom that the chief danger is attributable. Clinical experience has furnished me with numerous examples illustrative of this fact, where most extensive and destructive disease of the teeth, gums, &c., were wholly unrecognised by the patient until his attention was drawn to them as the cause of tinnitus aurium and deafness."

* * * * "reviewing the records, which I have since kept of some 1,500 cases, I find that the teeth are more frequently the seat of disease than I at first suspected, for, of these 1,500 aural cases, perhaps one-third owed their origin, or continuance, in a greater or less degree, to diseases of the teeth."

* * * * "opportunity was afforded me to examine the aural cases in a large charitable institution containing children of both sexes, who were almost exclusively within the period embraced by the second dentition. About 6 per cent. of the inmates were found to have otitis media purulenta, or were the subjects of ear-ache."

I have already described (page 45), the difficulties experienced in dealing with children, from their incomplete mental and physical development. In the active change, which is constantly taking place in the nerve centres, and their consequent great susceptibility to morbid influences, will be found a probable explanation of the predominance of disease in the teeth, characterised at this period by reflex action. Where pain is experienced, equal parts of chloroform and tincture of aconite may be administered to the affected pulp on a cotton pellet, taking care, however,

that the cotton is not pressed on the nerve, so as to be itself a mechanical means of offence. The relief so afforded being but temporary, it generally becomes necessary to destroy the nerve. Cobalt may be employed for this purpose in the deciduous teeth, or a milder preparation may be used in the form of a fully saturated tincture of iodine. Fortunately for children, the memory of pain is but transient; and with the shedding of the deciduous teeth, the ills peculiar to those organs cease.

I have hitherto omitted one systemic cause for odontalgia—the sympathetic action and wasting effect on the dental organs by pregnancy. The extreme tendency of child-bearing women to lose their teeth is a well-established fact; and with this, as in many other truths, popular instinct has preceded scientific investigation. If there be a withdrawal of nutriment, it is a strong argument favouring the existence of a circulating medium throughout the dental tissues, which is acted upon by certain abstractions from the system; the condition of the economy from gestatory influences so vitiating the fluids of the oral cavity that the teeth by this means are destroyed.

Pain in one tooth may in effect be transmitted to any of the others, as also to the opposite jaw to that in which it had its origin. This is an example of “diffused” nervous action, the impressions being conveyed to the branch of the trigeminus in much the same way as the mind refers the position of a distant object to the final direction in which a refracted ray reaches the optic nerve through the eye. Where a test is required, each tooth should be gently tapped, and, by the alternate application of hot and cold water, difference in sensation observed.

Those in which pain is evinced should be examined with the mirror, opacity to sunlight indicating death of the pulp.

Sensation is produced in parts quite remote from the focii of disease, extending to the face, the trifacial tract, the scalp, and even to the shoulder, while exceptional instances are recorded of suffering in parts of the body still more remote, these being examples of "associated" and "reflex" nervous action.

The excitant to odontalgia is usually exposure of the pulp, by attenuation of the hard tissues surrounding the pulp chamber; so that the primary examination will be for caries. If pain is produced by exposure, ascertain the condition of the pulp—whether devitalized or only partially so. If it has been the cause of much or repeated suffering, the indication would be to remove it, as its loss may be predicted, in which case the trouble will not be confined to the pulp only. Should however there be no appearance of decay, shock of some kind may be suspected, leading to inflammation of the pulp which, unless properly treated, will extend to the pericementum.

The next stage is the development of parulis, alveolar abscess, or gum boil. The inflammation of the peridental membrane causes a thickening of that part situated at or near the apex of the root. The lymph exuding from the membrane forms a sac or cyst within which pus accumulates. Should extraction from any reason take place at this period, the cyst not unfrequently accompanies the diseased root, presenting a filamentous appearance, bunched at the apex of the root, like that represented in Fig. 69.

The accumulation of pus in the alveolar socket is accompanied with pain sometimes the most intense, which may be compared with that experienced when pus is formed in other and inelastic saccular regions of the frame. By pressure on and absorption of the alveolar

process, a fistula may be produced following the line of least resistance. With the escape of pus, the acute pain ceases. Should the fistula reach the cheek, a permanent disfigurement may be caused; therefore fomentations and treatment must be directed with a view to the evacuation of pus into the oral cavity, where, in ordinary healthy diathesis, its presence is more disagreeable than dangerous.



FIG. 69.

The treatment must be in the use of escharotics thrown into the sac to break up and destroy this pseudo membrane, so as to allow protoplasmic reunion of the tissues at the apex of the root. When there is an open fistula, the abscess syringe may be employed to force the remedy to its objective point, or, perhaps, a better method is to pump the remedy through the root canal and alveolar opening with a nerve broach; filaments of cotton being wound upon the barked end. Creosote, carbolic acid, or iodine, or a combination of these substances, by these means, can be forced through the pulp canals, until, by making their appearance at the fistulous opening, evidence is given of the thoroughness of their application. When the pus has failed to burrow a channel to the external surface, it is not so certain that the disinfectants will penetrate the sac, in which case you may dissect back the gum, and treat as just described; but, should there be a continued discharge of morbid matter, you are justified in cutting off the end of the roof—through the alveolus—

and removing it, together with its morbid cystic attachments. Some care will be required in this, for the following reasons: 1st, you may not hit the apex of the root, which by no means is to be found exactly in the same place in all individuals; and 2nd, although the causes may be nearly identical, they are not always followed by the formation of a sac from circumscribed suppuration. The pus formed may occur in patches on the root of the tooth, or by diffusing itself over the periosteal membrane, produce, first, elongation, and, finally, ejection of the tooth from its socket. You will be to some extent guided as to the difference, by observing whether a well-marked determination to some extraneous point is evidenced, or whether the pain is more generalized, and accompanied with indications of pus at the gingival border.

Ordinarily, slight cases of periodontitis disappear when the source of irritation is removed. But acute periodontitis—unless aborted by antiphlogistic measures, as the use of pediluvia, sedatives and leeches—runs its course, and terminates in a cystic formation upon the fangs.

Pericementitis may, from neglect, assume a threatening condition. Especially is this the case in the *dentes sapientiæ*; the remote positions of these teeth prevent the inspection which can be made of the other teeth, and the pain is referred to other regions—the ear sometimes being implicated. The inferior dental nerve, accompanied by the dental artery, enters the canal at the ramus of the maxilla in a space so confined as to bring it very near the root of the wisdom tooth; and, by pressure on the nerve from cystic formations on the root, causes neuralgia.

Erethism of the masticatory branch of the fifth nerve supervening trismus of a tedious and perhaps dangerous character might ensue. Should this occur, the jaws require to be separated by gradual but persistent force. When the

mouth, by this means, is sufficiently opened, the *dentes sapientiæ*, or teeth causing trouble, can be treated according to the condition in which they are found. The rigidity of the *maxillæ* may not be removed at once, but require prolonged treatment, with the use of special contrivances to stretch the muscles. Other causes of closure of the jaws besides periodontitis and alveolar abscess exist;—but they belong rather to the sphere of surgery at large than to the subject to which I am confining my remarks.

LECTURE XII.

Delivered at the National Dental College, London, December 24th, 1879.

THE sympathetic relation of the teeth to adjacent structures, and the medium through which disease may be transmitted to, or associated with, other portions of the body, make it necessary to ascertain as accurately as possible the succession of morbid manifestations, and their connection with antecedent and existing causes, before any rational basis can be formed for the application of therapeutic remedies. These morbid phenomena are especially conspicuous and often difficult of interpretation in facial neuralgia, and, in the absence of other apparent incentives, the teeth are naturally suspected. When caries cannot be found, enquiry should be made into the previous history of the patient's health, whether suffering from any constitutional disturbance, recent or remote, also as to medicinal treatment employed, mercurial or otherwise,—as these have a marked tendency to mislead in obscure forms of disease. Failing, however, to obtain satisfactory information, the trouble may be surmised as originating from one of two causes, viz., intrinsic calcification of the pulp, or an osseous formation on the root, called exostosis.

The teeth are sometimes affected by the mechanical irritation of calcifying bodies within the pulp—"endostosis"—and the calcification of the periosteum—"exostosis,"—conditions which frequently cause neuralgia in various organs and regions.

In the first—endostosis,—the usual symptoms augment

without any clearly defined indication, until they simulate those of exostosis. When this occurs, no outward cause of pain can be discovered; but, if an examination of the tooth be made after extraction, nodules and tubercles of secondary dentine will be found in the nerve canal, acting as an irritant by pressure upon the pulp.

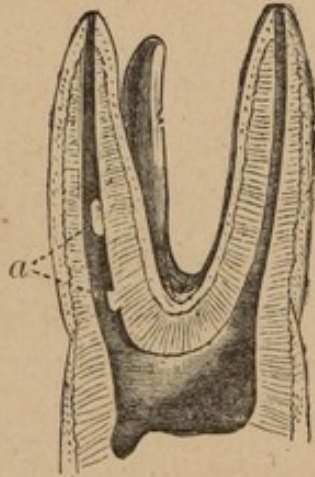


FIG. 70.

Enlarged diagram (split section) showing at *a* tubercles or nodules of secondary dentine.

In other instances, the development of secondary dentine manifests itself as granules interspersed throughout the substance of the pulp. If the nerve canal be found closed with osseous formations, the cause of trouble will probably be at the apex of the root; and the hope then of successful treatment must lie in its excision through the alveolus, or, as a last resort, the tooth may be replanted. These operations have been described in detail in a previous lecture.

The difficulties to be contended with in the extraction of teeth affected by the kindred form of disease—exostosis—are shown in the diagrams, which are drawn from specimens in my possession.

Exostosis is a hypertrophied condition of the cementum, developed from, and intimately connected with, the periosteal membrane. It may be described as nodular and diffuse. The former type consists of isolated circumscribed masses upon the roots of teeth that outwardly present no marked indication of disease. The diffuse type is most conspicuous on teeth which have long been affected with caries (fig. 71.) Crownless roots, however, are also subject to this increase in their dimensions.

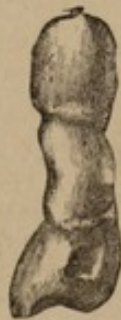

FIG. 71.

The two types of this disease not infrequently run into one another, and, by intermingling, lose their distinguishing characteristics.

In the former, the physical manifestation may be very prominent, yet occasion but little suffering; or be deeply seated and neuralgic in character. In the diffuse type, the pain is usually more lancinating than in the nodular,

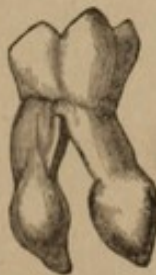

FIG. 72.

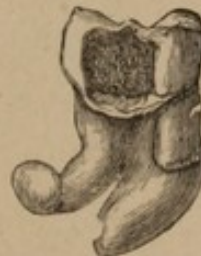

FIG. 73.

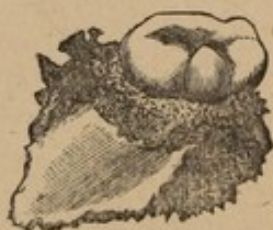hypertrophy causing a tubercle or bulb-like formation on the fang, as shown in figs. 72-3. This may extend equally,

in all directions, until it enlarges the alveolar process, absorption of that tissue being so nearly equivalent to the increase, that physiological change goes on almost imperceptibly.

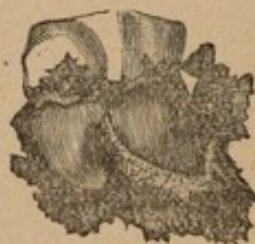The opinions given by various authors as to the dangers of exostosis, and as to the pain caused, conflict. In the earlier stages it seems to occasion little, or no, inconvenience; but an instance is given where a patient had "suffered fourteen years with fistulous openings in the left cheek," osteo-sarcoma having been induced by enlargement of the fang of the dens sapientia, which occasioned the loss of a great part of the maxilla.

The roots of several teeth are sometimes united, and so complicate extraction that a large portion of the alveolus accompanies the tooth. Laceration of the gum is perhaps more to be dreaded than loss of the process; for, unless fracture be so extensive as to endanger the firmness of adjacent teeth, its removal may be considered as only anticipating the absorption which naturally follows extraction.

A case of alveolar fracture is exhibited in figs. 74-5,



Buccal view.
FIG. 74.



Lingual view.
FIG. 75.

(third molar), periosteal excitation having, by adhesive inflammation, developed a condition commonly called ankylosis; yet there is wanting an authenticated case of true ankylosis of cementum and socket. An example

is more perfectly shown, perhaps, in fig. 81, where the teeth seem to have become solidly united. Atrophy and hypertrophy, in Figs. 74-5, have simultaneously affected the roots of the tooth; the wasting process vertically being accompanied by lateral expansion. The former is the buccal, and the latter the lingual view, as shown after extraction.

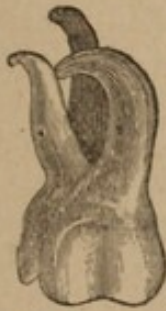

FIG. 76.

Distorted roots sometimes occasion serious fracture, and it will be observed in Fig. 76, that the antero-buccal fang is curved until it has pierced the septum of the alveolus and rests upon the post buccal root. The inclination of the latter is to form a similar curve in the same direction; while, between the buccal fangs, there is no exit or place of escape for the process locked in that position. This is a difficult tooth to remove without fracture to the process, owing to constriction at the neck, and the peculiar formation of the roots.

Aggravated cases for extraction may be seen in figs. 72-3-7-8, in which there is both distortion and exostosis. The bicuspid, fig. 77, will require to be turned out rather than drawn; while the removal of such a tooth as fig. 72, in which bulb-like exostosis is developed, may be looked upon as a case for the excising and root forceps. The constriction at the neck is still more marked than in fig. 76; and, were there no malformation of the roots, their divergence would still offer resistance to any attempt at dislodgment. In fig. 77, exostosis is complicated with the lingual fang of the bicuspid lapping upon the

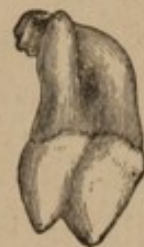

FIG. 77.

curved buccal fang. Here again we might readily predict fracture to the buccal fang, although every care be taken to prevent it. Fig.

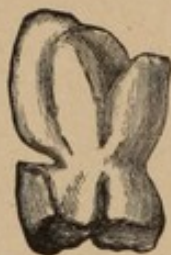

FIG. 78.

78 represents diffuse exostosis, occasioned no doubt, by erosion at the neck, hyperplasia having been induced through pulp and periosteal irritation; the anomalous feature being that, while one part of the tooth was receiving a deposit of extraordinary solidity, another was gradually being dissolved and lost. Erosion, like caries in the other examples figured, acts as an irritant to the pulp and periosteum.

In figs. 79 and 80—caries teeth—such large deposits have accumulated upon the roots that the apices are lost in the attached process and cystic formations.

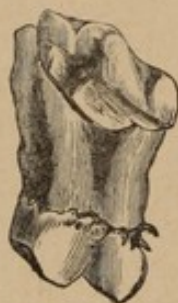

Fig. 79.

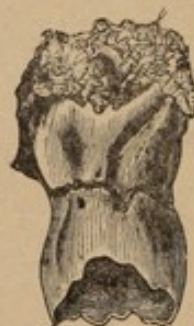

Fig. 80.

Figs. 81-2 illustrate some of the curious freaks of nature in uniting teeth. In the former, both teeth are exostosed, the crown of the posterior tooth being almost at right angles to its normal position; while, in the latter, the bicuspid (*a*) has made its appearance as a supernumerary tooth, being firmly attached to its associate. On several of the teeth described, and which I pass for inspection, will be seen pearl-like prominences; showing the remark-

able vigour of the pericementum in formations of this kind.

Diseased teeth, when neglected, produce irritation in the surrounding tissues to such an extent that, contrary to popular belief, the removal of the tooth does not always give immediate relief. The alveolus, the gums, and even the maxilla may partake of the inflammation and require judicious after treatment. Fomentations, poultices with a little tincture of opium sprinkled upon them, or an anodyne cataplasm of poppy leaves, can be used to alleviate pain. Applications of this kind, however, are not admissible where there is any threatening tendency to an external fistula, and, when thus applied, may lead to most disfiguring consequences.

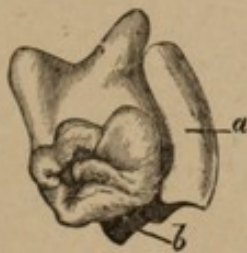


Fig. 81.

- a.* Root of posterior tooth.
- b.* Crown of posterior tooth.

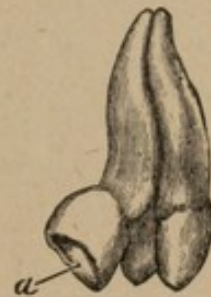

Fig. 82.

- a.* Crown of supernumerary tooth.

Anchylosis or gemination of teeth.

Hæmorrhage from extraction is not, as a rule, considered dangerous, yet deaths have occurred from inability to suppress the flow of blood. You will occasionally meet with patients of the hæmorrhagic diathesis, in whom the blood is deficient in fibrine and coagulative power. Hæmorrhage in such persons seems almost uncontrollable; the blood exuding either in a steady flow, or welling forth with the pulsating intervals of ruptured

arterial circulation. The course ordinarily pursued in such cases consists in packing the socket of the tooth with lint, saturated with styptics, small pieces being introduced and forced into the extreme apex or floor of the socket, so as to compress the arterial trunk, and arrest hæmorrhage at its point of origin.

The apices of the roots of the first and second superior molars are adjusted to conical capsules formed in the floor of the antrum of Highmore; but, occasionally, this septum of bone is perforated by the roots of teeth projecting into that cavity, they being covered by the lining membrane of the sinus; and, should they become diseased, that lining might be the seat of inflammation, and of the profuse formation of pus. The same effect is produced by severe catarrh. The general symptoms are a dull heavy pain in the affected region, with distention of the antrum, the parietes of which crepitate to the touch.

If either the superior first or second molar on the diseased side is decayed, it should be removed, with a view of penetrating the antrum through its socket. The second molar, however, is the tooth usually selected for extraction, owing to the fact that the socket of its palatine fang affords a channel leading most directly through the floor of the antrum; but, should these teeth be sound, we have the alternative of making an opening into the antrum through the canine fossa. Entrance being effected, treatment should consist in evacuating, if possible, all septic matter, followed by copious syringing with warm water, and the use of a solution of permanganate of potash—or Condyl's fluid; the opening to be kept patulous with a tent, and the treatment continued until the formation of pus has ceased. The antrum is occasionally attacked by more acute disorders,—generally complicated with periodontal derangement,—and sometimes by malignant disease.

Although it is understood that the teeth are the Dentist's first object of attention, their not unfrequent connection with disease in the surrounding tissues makes it essentially important that the Dental practitioner should understand the distinguishing differences between tumours of a malignant and those of a benign character.

Carcinoma, in its earlier stages, often assimilates a non-malignant appearance, and it is only when microscopically examined, or when more decided symptoms, such as increase of size, attended with lancinating pains, are present, that its malignancy is discovered. It is advisable, where there seems to be an arrest of growth, to refrain from active measures, but to seek for and, if possible, remove the cause; remembering that even a malignant tumour may remain in a quiescent state, for an indefinite period, unless developed through some extraneous influence. However, all tumours are to be carefully watched, and removed where there is any tendency to spread.

No source of irritation should be permitted to remain in the mouth, such as the fractured edges of the teeth or roots projecting from the gums. In obscure cases where pain is experienced in the superior maxilla, the nose ought to be examined in connection with the teeth, for evidences of antral disturbance; for while polypus sometimes extends from the nose into the antrum, fungus may be forced from the antrum into the nose.

Should a muco-purulent discharge follow the instrument when exploring the antrum, the lesion is usually comparatively easy to treat; but when severe hæmorrhage ensues, the tumour may be strongly suspected as malignant.

The saliva, in combination with the exudations of the mouth, forms calcareous deposits on the teeth, known as salivary calculus, or tartar (odontolithos). These formations vary in hardness and composition. Some are de-

posited slowly in minute quantities, and do not appear to have any perceptible effect on the health; but others, from the nature of their constituents, are fetid combinations of animal and mineral matters. That the saliva is capable of depositing calculi is evinced at almost the commencement of its flow, by the formation of concrete matter within the ducts of the salivary glands. Ranula, or cystic tumours arising from obstruction of those passages, will occasionally require your attention; the glands, especially the sublingual, sometimes giving serious annoyance.

The word ranula is derived from *rana*, a frog; but this would give an incomplete idea of the complications of the disease to which it is applied, as ranula varies in its character. Sometimes there is only a slight enlargement of the glands, arising from superabundant secretion; but, occasionally, massive tumours cause displacement of the tongue from its normal position. Where the cyst is thin, the tumour resembles a frog's belly—hence ranula—and a cure is sometimes effected through rupture of the walls of the cyst. Temporary obstruction to the fluid of the glands through constriction of the sub-lingual ducts may occasion but little inconvenience; but, should this stricture become continuous, accompanied by ptyalism, its influence will, after a time, be felt upon the general system. The contents of the cyst, in course of time, partly solidify, and may form salivary calculus; but, more usually, the secretion becomes inspissated by the absorption of the more fluid constituents.

Ranula is considered to be most commonly an accumulation of fluid within the mucous follicles, or in the midst of the tissues beneath the tongue—even in the substance of the walls of the salivary ducts. In frog belly ranula, the wall of the cyst is semi-transparent, and the contents copious;

but, in other cases, the walls may constitute the larger bulk of the tumour, the cavity being small. Ranula is simulated by inflammatory swellings in the glands themselves; but, whether it be sebaceous deposits, pus, or saliva which cause encysted tumours with enthickened vascular walls, the treatment is the same—incision followed by drainage, or the establishing of setons and the injection of stimulating remedies.

Tartar is essentially an evidence of neglect, as the persistent use of the brush will in most cases prevent this disagreeable deposit; but there are cases in which it is not so easily controlled. The deposit soon hardens and insinuates itself between the gingival border and the cervical portion of the teeth, commencing usually upon the buccal surface of the molars and the lingual aspect of the incisors, owing to their proximity to the ducts of the parotid and sub-lingual glands, until retrocession of the gum is induced. Attempts to clean the teeth now cause so much irritation that they are frequently neglected, and the disease permitted to go on uninterruptedly, to the prejudice of both teeth and gums. This condition appears, in some instances, to be tolerated with little or no inconvenience, until the tartar nearly reaches the apices of the teeth, increasing until several teeth are cemented together by the deposit, which becomes so large that its contour can be traced externally upon the cheek (see fig. 83.) But sometimes it is accompanied with much discomfort, anoréxia, and general derangement of the system, while absorption of the alveolus and loss of the teeth are among the disastrous sequelæ, a case in point being given in fig. 84.

The two specimens which are here illustrated show to what extent salivary calculus may be tolerated in the

mouth, fig. 83 representing the exact dimensions of a mass taken from molar teeth.

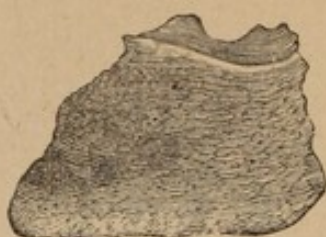

FIG. 83.

In fig. 84, the attachment of tartar to the lingual surface of a lower incisor increased in bulk until, by its erosive influence upon the gum and alveolus, the tooth was lost. From these considerations, it will be seen that the treatment of teeth with tartar upon them is important, and the operation of scaling a necessary prophylactic measure.

The instruments used in the removal of tartar are too well known to require description here, further than that their forms should be adapted to the varying aspects of the teeth, and, while using them, every precaution taken to avoid injury to the enamel; the junction of the surfaces being the line of cleavage. In cases of alveolar absorption and retrocession of the gum, carbolic acid may be applied by means of a stick of orange wood, flattened at the end, so as to permit the ready introduction of the medicine between the teeth and gums. Aromatic sulphuric acid is also sometimes used with most beneficial results where the gums are hypertrophied.

The more advanced cases of tartar-deposit cause atrophy of the gums and alveolar process, which makes treatment a question of doubt and uncertainty.

A condition known as pyorrhoea alveolaris, or sometimes called "Rigg's disease," is characterized by a dis-

charge of pus from the dental periosteum, the separation of that tissue from the cementum, and by the deposit of small, hard, dark coloured grounds upon the root of the tooth. This disease is, in most cases, associated with constitutional debility; but the relation of the local to the general disease, as cause and effect, is apparently irregular.

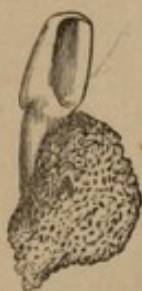

FIG. 84.

After your efforts to arrest disease, it would be well to instruct your patients how to take care of the organs upon which so much attention has been bestowed; warning them that fierce attacks spasmodically made with brushes constitute only an approach to that virtue. The teeth, though capable of resisting great force when in the exercise of their proper function, require gentle but thorough cleansing; and the practice of rubbing them with brushes that are too harsh is almost as reprehensible as the more indifferent zeal sometimes displayed of only brushing them occasionally.

An increasing interest in this matter is gradually pervading all classes of society, whereas the importance of considerate attention to this portion of the physical organism was formerly only recognised by those in the higher walks of life. Even there it was not the invariable rule, but the exception; and the stimulant then was more for the sake of personal appearance than from expectation of realising any actual practical benefit.

Let your aim be to improve this growing interest by impressing upon parents the necessity for periodical examinations of their children's mouths, calling attention to the many vicissitudes to which the teeth are subject during the period of first dentition, and especially combating the idea that, because these teeth are "temporary," attention to them is not necessary.

Hasty operations—the result frequently of opinions expressed by irresponsible parties—are productive of great mischief, the normal position and symmetrical articulation of the permanent teeth being, in many respects, dependent upon the presence or absence of the deciduous teeth.

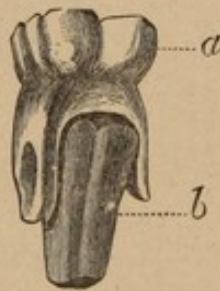


Fig. 85.

- a.* Deciduous molar with roots partly absorbed.
- b.* Permanent bicuspid, in course of development, brought away with the temporary molar.

A case in point is illustrated in fig. 85; which shows that extraction in early dentition should be deferred until the roots of the deciduous teeth are sufficiently absorbed to permit their removal without injury to the permanent ones. The accident pictured having actually occurred, I refer to it that you may be on your guard, although cases of this nature are extremely rare.

The physiological importance of the various subjects incorporated in these lectures, must not be judged by their

poverty of description, for I have been compelled to review in a too brief manner questions that have a literature of their own, and which demand a much more explicit consideration.

That I have repeated things with which you were already acquainted has been unavoidable, and that you will hear them again is to be expected; but each repetition will the more firmly impress, and give that facility of mental reference to facts which is the object of your studentship.


At the commencement of professional life, every young practitioner is apt to indulge the hope of an immediate request for his services; but this expectation is not always realised. The introduction may be considered the probationary test period; self-reliance and conscientious thoroughness being the essentials to success. I repeat the words "self-reliance," because it is not unlikely that you will have to contest any position you may wish to occupy with others as anxious as yourself to secure a practice.

In mouths systematically cared for, the services of the Dentist are materially abridged; but, on the other hand, neglect often involves an expenditure of time, for which no real compensation can be expected. You will not unfrequently be placed in an embarrassing position, from the inability of your patients to appreciate the differences in expense existing in Dental operations.

This question has been the quicksand on which too many good resolutions have been stranded, seriously compromising the beauty, finish, and permanency of much work, and obstructing the advancement of thousands beyond a mediocre professional position. Unless restrictions of this nature are removed, operations of an elaborate character must be superseded by those involving less skill and expense. I would advocate a generous reception and

investigation of new methods. Those who are inclined to censure should consider well any new principles advanced, for many intermediate operations are often required to demonstrate a single fact; and, to distinguish the inconsequent from the useful, new methods must conform to the physiological laws that dominate the human frame.

FINIS.



This book must be returned to
the Dental Library by the last
date stamped below. It may
be renewed if there is no
reservation for it.

Author Thompson, W. Finley

Mem. Lib.

Title Operative Dental Surgery and Therapeutics

DATE.

NAME OF BORROWER.

University of Toronto
Library

H.P.A.

DO NOT
REMOVE
THE
CARD
FROM
THIS
POCKET

Acme Library Card Pocket
Under Pat. "Ref. Index File"
Made by LIBRARY BUREAU

