The anatomy of the human body / By J. Cruveilhier.

Contributors

Cruveilhier, J. 1791-1874.
Pattison, Granville Sharp, 1791-1851.
Madden, William Herries.
Lamar Soutter Library

Publication/Creation

New York : Harper & Brothers, 1844.

Persistent URL

https://wellcomecollection.org/works/gqku9wwq

License and attribution

This material has been provided by This material has been provided by the University of Massachusetts Medical School, Lamar Soutter Library, through the Medical Heritage Library. The original may be consulted at the Lamar Soutter Library at the University of Massachusetts Medical School. where the originals may be consulted.
This work has been identified as being free of known restrictions under copyright law, including all related and neighbouring rights and is being made available under the Creative Commons, Public Domain Mark.

You can copy, modify, distribute and perform the work, even for commercial purposes, without asking permission.

Wellcome Collection
183 Euston Road
London NW1 2BE UK
T +44 (0)20 7611 8722
E library@wellcomecollection.org
https://wellcomecollection.org

LIBRARY
. OF .
Pittsburg Academy of Medicine.
DONATED BY
Dr Windle's Heirs
No. 995

Commenced Thursday Nov. 20th 1862.

Digitized by the Internet Archive
in 2010 with funding from
Boston Library Consortium Member Libraries

http://www.archive.org/details/anatomyofhumanbo00cruv

THE

ANATOMY

OF THE

HUMAN BODY.

BY J. CRUVEILHIER,

PROFESSOR OF ANATOMY TO THE FACULTY OF MEDICINE OF PARIS, PHYSICIAN TO THE HOSPITAL OF SALPETRIERE, AND PRESIDENT OF THE ANATOMICAL SOCIETY OF PARIS.

THE FIRST AMERICAN, FROM THE LAST PARIS EDITION.

EDITED BY

GRANVILLE SHARP PATTISON, M.D.,

PROFESSOR OF ANATOMY IN THE UNIVERSITY OF NEW-YORK, MEMBER OF THE MEDICO-CHIRURGICAL SOCIETY OF LONDON, OF THE WARNERIAN SOCIETY OF NATURAL HISTORY OF EDINBURGH, OF THE SOCIETE MEDICALE D'EMULATION, AND SOCIETE PHILOMATIQUE OF PARIS.

LIBRARY OF THE
Edinburg Academy of Med
NOT TO BE REMO
No. 995

NEW-YORK:

PUBLISHED BY HARPER & BROTHERS,

No. 82 CLIFF-STREET.

1844.

3A
C889

Entered, according to Act of Congress, in the year 1844, by
HARPER & BROTHERS,
In the Clerk's Office of the Southern District of New-York.

EDITOR'S PREFACE.

Numerous and excellent as the works on Anatomy are which have lately been reprinted in this country, still they are, all of them, so decidedly inferior to the "System of Anatomy by Cruveilhier," that the editor feels it unnecessary to offer any apology for having undertaken its republication. Occupying, however, as he does the Chair of Anatomy in the Metropolitan University of the United States, the profession may perhaps think that it would have been more becoming of him to have published a System of Anatomy of his own, rather than to have undertaken the humble office of editing the work of a European anatomist.

The reasons which have influenced him in the course he has pursued are the following:

The science of Anatomy, viewed abstractly, and without reference to its connexion with Physiology, Pathology, and the Practice of Medicine and Surgery, is to the student just commencing a very dry and uninteresting study. Yet in this way it is generally taught in the schools, each system being demonstrated separately, without reference to the others, or to the Physiological and Pathological facts which its demonstrations tend to illustrate. The course followed by the editor, as a teacher of Anatomy, as his numerous students are aware, is very different. His great object has always been to endeavour to give interest to every lesson, by making it not a mere lecture on Anatomy, but a discourse illustrating Physiological and Pathological science, and elucidating the principles which should guide the practitioner in the practice of his profession.

For the editor to have prepared a mere system of Anatomy would have been, in fact, merely to have undertaken the work of a compiler; originality was out of the question, and no industry nor effort could have enabled him to have produced, on this plan, a better work than the systems of Wilson, Quain, or the numerous other systematic treatises on Anatomy which have already been published. The editor having been a teacher of Anatomy for more than thirty years, from his experience is fully aware of the vast importance to the successful performance of his duties as an anatomical professor, of his being enabled to interest his pupils and to fix and enchain their attention, that he is very unwilling to do anything which could have the effect of taking from the interest or diminishing the freshness of his lectures. To pub-

lish a system of Anatomy on the same plan as that adopted in his lectures, he would, of necessity, require to imbody in it the same Physiological, Pathological, and practical views with which they are illustrated; and to have done so, he cannot doubt but that the interest of his lectures would have been diminished, and that he would in future have found it much more difficult to fix the attention of his pupils. This consideration has decided him never to publish, so long as he is engaged in the duties of teaching, an original work on Anatomy.

The system of Anatomy of Cruveilhier has recommended itself to the editor for publication: First, on account of its decided superiority to any other work on Anatomy which has ever been published; and, secondly, from its being prepared, in some measure, in accordance with the plan which he follows in his lectures, many of its details being illustrated by Physiological and Pathological references.

In republishing the work, the editor has so restricted himself in the performance of his task that he feels it can neither add to nor take from his reputation. He has merely furnished to the members of the profession in the United States THE SYSTEM OF ANATOMY OF CRUVEILHIER. Several reasons have influenced him in being sparing in the introduction of notes or additional matter. First. The work is in itself so perfect as not to require them. Secondly. It is very voluminous, and to have increased its size would have been to have diminished its value. Thirdly. The editor has ever thought that an independent mind will shrink from mixing up and incorporating his thoughts with those of another. If a man wishes to obtain reputation as an author, let him publish an original work, and not attempt to gain popularity by illustrating and enlarging the labours of another.

The editor, in disclaiming all credit to himself in the publication to which he has affixed his name, cannot allow the opportunity to pass without calling the attention of the profession to the obligations under which they have been placed by the liberality of the enterprising publishers. The Messrs. Harper and Brothers have commenced a new era in medical publications. Before they entered the field, although a number of the best works on Medicine and Surgery were republished in this country, when every other kind of literature was furnished on very cheap terms, the prices required for medical books was such as to debar the great body of the profession from procuring them. The Messrs. Harper, since they have engaged in medical publications, have entirely reformed this matter. Feeling assured that the excellence of the works they republish will command extensive sales, they are content with very moderate profits. This fact is fully established by their republications of "*Kane's Chemistry*," "*Magendie's Physiology*," and "*Chailly's Midwifery;*" works which they furnish for two dollars each, being not much more than half the price which would have been asked for similar books before they engaged in this department of pub-

lication, and still more so by the low price at which they sell Cruveilhier's Anatomy. The English edition of this work costs thirteen dollars, while they furnish it to the members of the profession in the United States for three dollars.

That the liberal course adopted by these gentlemen might create some feeling among the members of the trade, is not to be wondered at. We can understand the feelings of "Demetrius, the silversmith, who made silver shrines for Diana, which brought no small gain to the craftsmen;" but we confess we could hardly have believed that any of the medical censors of the country, men of science, could have expressed any other feeling but that of unmixed satisfaction; for the Messrs. Harper have diminished nearly 100 per cent. the price of medical books. The remarkable course, however, followed by the medical journals of Philadelphia, in reference to the publications of the Messrs. Harper, only proves how little reliance can be placed on the opinions of reviewers when self-interest interferes with its candid expression. It is very possible, from the course which these gentlemen reviewers have pursued in reference to the publications which have received the *imprimatur* of the professors of the University of New-York, that the System of Anatomy of Cruveilhier may, when reviewed by them, fare no better than the other medical works published by the Messrs. Harper, under the sanction of the medical department of New-York. It is, however, a matter of very little consequence. "*Good wine requires no bush;*" and a good book, if furnished at a low price, must and will always command an extensive sale. New-York is the great metropolis of the Union, and must very soon become, like London and Paris, however distasteful it may be to those who may have other interests, become the great centre, not only for medical publications, but also of medical education.

Since the English edition of Cruveilhier has been published in London, the first and second volumes of a second edition of the work have been published by the author in Paris. The editor has carefully compared the second edition with the first, so far as it has been published, and has incorporated in the American edition whatever he thought could increase its value. He has, however, only followed the second edition when he thought that the changes introduced were improvements. In many instances, with the view of keeping down the size of the book, he has condensed into a few short paragraphs the substance of several pages. In the department of Myology the author has in his second edition made very numerous alterations from the first. As these, in the opinion of the editor, have rather diminished than increased the value of the work, he has only in a very few instances adopted them. The student, he feels satisfied, will find the description of the muscles sufficiently minute. The subdivisions introduced, and the minutiæ which are added to their descriptions in the second edition,

would rather embarrass than promote their improvement; he has, therefore, very generally preferred to follow the first edition in the description of the muscles.

In the original work there are no engravings; this is a great *desideratum*, which has been removed in the English edition by the introduction of numerous woodcuts, selected with care from the best anatomical engravings, and marked with letters of reference. This greatly enhances the value of the work. The translation, which is an excellent one, was made by Dr. Madden.

Systems of Anatomy generally offer little interest except to the anatomical student. This cannot be said of the system of Anatomy of Cruveilhier. It imbodies a fund of information, in connexion with Physiology and Pathology, which will, in the opinion of the editor, procure for it a place in the library of every physician and surgeon who feels any interest in his profession. If the members of the profession only procure the book and peruse it, he cannot doubt but that the cause of Anatomical science will be greatly promoted in the United States; and should this be the case, the editor will be amply repaid for any trouble he may have had in undertaking the republication of Cruveilhier.

University of New-York, Sept. 1*st*, 1844.

AUTHOR'S PREFACE.

The study of man offers three very different objects for contemplation; viz., his organization, his vital functions, and his moral and intellectual faculties.

The organization or structure of man is the object of *anatomy*, a science which investigates every distinguishable material condition of the different parts that enter into the construction of his frame. Anatomy is a science of observation, and is, in this respect, susceptible of mathematical precision and physical certainty.

The vital functions of man are the objects of *physiology*, which reveals to us the actions of organs, with whose structure anatomy has previously made us acquainted. The science of physiology inquires into the various motions that occur within the human body, just as anatomy investigates the form of its component parts. All that we know, in fact, concerning material objects, may be resolved into a knowledge of their motions and their forms.

As a moral and intellectual being, man is the object of the science of psychology, which contemplates him in the exercise of thought and volition, analyzes the operations of his mind and will, and classifies them according to their supremacy.

A perfect acquaintance with man necessarily presupposes a combination of all that is taught by these three sciences; and it is because his anatomy, his physiology, and his moral and intellectual endowments have not been studied by the same class of philosophers, that in the sciences relating to himself so much yet remains to be desired.

Anatomy—the immediate object of this work—constitutes the foundation of medicine. In order to discover the precise seat of a defect in some complicated machine, and the means to be adopted for the reparation of its disordered mechanism, it is necessary to be acquainted with the relative importance, and the particular action of all its constituent parts. "The human body," says Bacon, "may be compared, from its complex and delicate organization, to a musical instrument of the most perfect construction, but exceedingly liable to derangement." And the whole science of medicine is therefore reduced to a knowledge of the means by which that harmonious instrument, the human frame, may be so tuned and touched as to yield correct and pleasing sounds.

But since anatomy forms, as it were, the vestibule of medical science, it is of importance that he who is entering upon its pursuit should fully understand the path he is about to tread; it is necessary, therefore, to assign, on the one hand, the rank which medicine holds as a natural science, and, on the other, the position of anatomy among the various sciences relating to medicine.

The term *science*, according to the admirable definition of the Roman orator, signifies certain knowledge, deduced from certain principles—*cognitio certa ex principiis certis exorta*. Sciences are divided into the *metaphysical*, the *mathematical*, and the *natural*; but since the two former are not connected with our present subject, we shall direct attention to the natural sciences only.

The object of the *natural sciences*, or of *physics*, taken in its widest signification, is a knowledge of the materials of which the universe is composed, and of the laws by which they are governed. They are subdivided into the *physical*, and the *physiological* or *zoological*.

The physical sciences take into consideration all the phenomena presented by inorganic bodies; they comprise, 1. *Astronomy*, which studies the heavenly bodies as they revolve in space, and estimates, by the aid of numbers, the laws by which their movements are governed; 2. *Physics*, properly so called, or the study of the properties of matter in general; in aid of which, experiments are performed in order to exhibit phenomena in every possible light, and calculation is employed to render fruitful the results of experiment; 3. *Geology*, or that science which studies the surface of the globe, and the successive strata which are met with in its interior; which goes back far beyond all historical traditions, brings to light, as it were, the very depths of the earth, and traces, with a sure hand, the history of the globe, and the various revolutions it has undergone; 4. *Chemistry*, which consists in the study of the reciprocal actions of bodies, when reduced to their atomic condition.

The *zoological* or *physiological* sciences embrace all the phenomena presented by living bodies. The science of *botany* examines into the structure and functions of plants; but *zoology*, properly so called, investigates the organization and the life of animals. The examination into structure or organization constitutes *anatomy*. *Physiology* embraces the study of functions or of life.

The facts presented to us in the zoological are of a totally different character from those comprised in the physical sciences. Inorganic bodies, in fact, are governed by constant and immutable laws, acting in perfect harmony with each other; but living bodies are subject not only to physical, but also to vital laws, the latter of which are constantly struggling against the former. This struggle constitutes life; death is the triumph of the physical over the vital laws. In consequence, however, of this continual strife, derangements of structure and disordered functions very often occur; and these become more frequent and more complicated, in proportion as the organization is more highly developed, and the animal more elevated in the scale of creation.

A knowledge of these derangements and of the proper means for restoring both or-

ganization and life to a healthy condition, constitutes the science of *medicine*; and the station which I have just assigned to this most important branch of zoological science will prove, better than any arguments, that the study of the physiological or healthy state of organization and of life should precede that of their pathological or diseased conditions; and that anatomy forms the first link in the chain of medical science.

Each science has its own methods of investigation, and its peculiar elements of certainty. Metaphysics and moral philosophy have a metaphysical and moral certainty. The mathematical sciences set out from a small number of self-evident propositions or axioms founded upon the nature of things, proceed gradually from the known to the unknown, and trust to problems already demonstrated as to so many axioms, by means of which, as steps, they again ascend towards new truths. The natural sciences, again, are founded upon observation, and observation is merely the evidence of our senses; hence arises the necessity of exercising them, in order to increase their acuteness and their activity. Facts, therefore, constitute the elements of the natural sciences; and then reasoning follows, founded upon those facts and upon analogy. It would be absurd to study the natural sciences after the same method as metaphysics.

It may readily be understood, that as the purely physical sciences are based upon constant phenomena, mathematics are directly applicable to them, and hence they are termed physico-mathematical sciences; but in the zoological sciences, effects are continually varying, according to their causes. Any attempts, therefore, to apply the art of numbers to the elements of medicine, would be to imitate the philosopher, Condorcet, who entertained the whimsical notion of subjecting moral probabilities to the test of mathematical precision; who was anxious to substitute $a+b$ for either oral or written legal testimony; who admitted half proofs and fractional proofs, and then reduced them to equations, by means of which he supposed he could arrive at arithmetical decisions, regarding the lives, the fortunes, and the characters of his fellow-men.

It must, however, be reluctantly confessed, that we can acquire a knowledge only of the surfaces of a body; and that to say we are acquainted with its texture, is to state, in other words, that we have a knowledge of the smallest surfaces comprised within its general surface. Sight, touch, &c., the only means of investigation by which we can appreciate the qualities of matter in general, can recognise nothing but surfaces, appearances, and relative properties. Absolute properties they are unable to detect. With our organization, we shall never know of what material objects essentially consist, but only what they are in relation to ourselves.

This work being essentially of an elementary nature, and in some measure adapted for the lecture-room, I have endeavoured to confine myself within narrow limits, and strictly to avoid all considerations which are not immediately connected with the anatomy of organs. At the same time I have not forgotten that this work was intended for the student of medicine, and not for the naturalist; I have, therefore, been induced, in the following pages, if not expressly to indicate, at least to direct attention to the more immediate applications of anatomy to physiology, surgery, and medicine.

The objects which I have constantly had in view have been to exhibit the actual state of the science of anatomy; to present its numerous facts in their most natural order; to describe each fact clearly, precisely, and methodically; to adopt such a method as would form an easy guide to the student, and not involve him in confusion; and, lastly, to give to each detail its peculiar value, by invariably directing particular attention to the more important points, instead of confounding them with matters of less consequence, in an indigested and monotonous enumeration of facts.

The following is the order in which the principal divisions of the subject have been treated.

The first division comprises *Osteology*, *Arthrology* or *Syndesmology*, and *Odontology*.

1. *Osteology*, which, notwithstanding the great number of works on the subject, seems always to offer some new facts to those who study it with zeal, has been treated with the attention it deserves, as forming the basis of anatomical knowledge. An account of the development of the osseous system has appeared to me necessary for the completion of its history. I have therefore considered the following points in connexion with the development of each bone: the number of ossific points; the time of appearance of the primitive and complementary ossific points; the periods at which the several points unite, and the changes occurring in the bone subsequently to its growth. By adopting this method, the most complicated ossifications are reduced to a few propositions easily retained in the memory.

The inconvenience arising from including in a description of the bones all the attachments of the muscles, and nearly the whole anatomy of the part, is so totally at variance with a methodical arrangement of facts, that it is unnecessary to offer an apology for the changes made in this respect. Occasionally, however, I have mentioned those muscular attachments which might serve to characterize the osseous surfaces on which they are situated.

2. Under the title of *Syndesmology*, or *Arthrology*, are united all the articulations of the human body. Assuming as the only basis of classification the form of the articulated surfaces, which is always in accordance with the means of union and the movements of the joint, I have been induced to modify the divisions usually adopted. The *condylar-*

throsis, or *condyloid articulation*, and the articulation by *mutual reception*, form quite as natural genera as the *enarthrosis* and the *arthrodia*. It will, perhaps, be found that the characters of the different kinds of articulation, and in particular those of the *angular ginglymus*, which I have called the *trochlear articulation*, and those of the *lateral ginglymus*, or the *trochoid articulation* of the ancients, are more clearly defined than in other anatomical works.

The mechanism, *i. e.*, the movements of a joint, is so intimately connected with its anatomy, that it was impossible to pass it over in silence; on the other hand, it was sometimes difficult to determine the limit which ought to distinguish an anatomical from a physiological treatise. I have endeavoured to avoid both extremes, by confining myself strictly to the mechanism of each joint in particular, referring to works on physiology for the principal movements of locomotion, and of animal statics, such as walking, running, standing, &c.

3. *Odontology*, or the description of the teeth, concludes the first division. I have taken care to point out that this juxtaposition of the bones and the teeth was founded upon their common indestructibility, and not upon the identity of their nature; the bones being organs composed of living tissues, while the hard portion of the teeth, on the other hand, is but the solidified product of secretion.*

The second division includes *Myology*, *Aponeurology*, and *Splanchnology*.

1. In treating of *Myology*, I have preferred the topographical to the physiological arrangement of the muscles, for this reason only, that it admits of all of them being studied upon the same subject. To unite, as far as was practicable, the undoubted advantages possessed by both methods, I have given, at the conclusion of myology, a general sketch of the muscles, arranged according to their physiological relations; and by grouping them, not after their order of super-imposition, but according to their several actions, I have arranged them around the articulations to which they may belong, and have pointed out the extensors, the flexors, &c.

A muscle being known when its attachments are ascertained, I have thought it advisable to commence the description of each by a brief announcement of its origin and insertion, as a sort of definition or summary. The particular details concerning its mode of insertion, whether it be aponeurotic or fleshy, and concerning the direction of its fibres, complete the description of each muscle considered by itself; the history of which is concluded by an examination of its relations to neighbouring parts, and of its uses. The individual or combined action of the muscles, for the production of simple movements, follows so naturally after their description, and presupposes so correct and positive a knowledge of their anatomy, that it can be treated of with propriety only in a work on anatomy. The compound movements necessary for the consecutive or simultaneous action of a great number of muscles come within the province of physiology.

2. The *aponeuroses*, those important appendages of the muscular system, are separately noticed, in connexion with the muscles to which they belong; but I have also described them together under the head of *Aponeurology*. This combination of analogous parts possesses the twofold advantage of simplifying the science, by enabling one part to elucidate the structure of another, and of permitting us to discover the general laws according to which these structures are disposed.

3. With some modification, I have adopted that old division of anatomy, which treats of the viscera and organs, and which is known by the name of *Splanchnology*.

The brain and the organs of the senses, which were included in this division in all anatomical works preceding those of Sœmmering and Bichat, have been removed from it, and described with the other portions of the nervous system. The description of the heart, in like manner, will be found with that of the other organs of circulation. In short, the old classification of the viscera, according to their locality, that is, into those of the head, the neck, the chest, &c., has been replaced by a more physiological arrangement. Splanchnology will therefore comprehend a description of the organs of digestion and their appendages, of the organs of respiration (among which is included the larynx, or the organ of voice), and, *lastly*, the genito-urinary organs.

To the inquiry why I have departed from the usual custom of placing splanchnology at the end of anatomy, I reply that, in order to study, with advantage, the vessels and the nerves, it is necessary to have a previous acquaintance with the organs to which they are distributed.

The importance of the parts described in this division, and the practical results which flow from even the most superficial knowledge of their forms, connexions, and intimate structure, are at once my reason and excuse for extending, to so great a length, this portion of the work; and, moreover, it is necessary to state, that there are many medical practitioners who learn anatomy only from elementary works.

The third and the last division treats of *the organs of circulation*, viz., the heart, arteries, veins, and lymphatics; and of the *sensory apparatus*, viz., the organs of the senses, the brain, and the nerves.

1. No part of anatomy, perhaps, has been better known than the arteries, since the appearance of Haller's admirable works; I could neither have followed a better guide nor a more perfect model.

* See note, p. 183.

2. The study of the *veins* has acquired an unexpected degree of importance, in consequence of the works of various physicians on phlebitis; and our knowledge of them has been much extended by the researches of M. Dupuytren into the veins of the spine, and the excellent plates of this order of vessels published by M. Breschet.

3. The study of the *lymphatics* has been almost abandoned since the very remarkable publications of Mascagni: I have endeavoured to ascertain what credit was to be given to the assertions of some modern writers concerning the frequent communication between the veins and the lymphatics.

4. The work of Sœmmering on the *organs of the senses* constitutes, perhaps, the highest title to fame possessed by that great anatomist; and it might even be said that he has left nothing for his successors to accomplish, did not the constant study of a science of observation unceasingly proclaim this important truth, that it is in the power of no man to declare, beyond this limit thou shalt not pass.

The brain and the nerves, to which so many able and laborious inquirers have lately directed their attention, have been my favourite objects of investigation; on account of their importance, and perhaps, also, from the difficulties attending their study. Not satisfied with simply tracing the nerves to the various organs in the body, I have studied them in the interior of those organs, and have endeavoured to ascertain the precise branches that are distributed to each particular part.

I may add, that, in order to facilitate the dissection of the nervous system, and, indeed, of all the other parts of the body, I have presented, whenever it was necessary, a short account of the best method of preparation.

With regard to the general spirit of this work, I have been anxious to render it classical; and have avoided, most scrupulously, that species of induction and analogical reasoning, which, in a great measure, constitutes philosophical anatomy. To this kind of anatomy I have never even introduced any allusions, except when its general ideas and views (almost always ingenious, but usually bold and speculative) might elucidate our own subjects.

All the descriptions have been made from actual dissections. It was only after having completed from nature the account of each organ that I consulted writers, whose imposing authority could then no longer confine my thoughts, but always excited me to renewed investigations wherever any discrepancy existed.

Anatomy being, as already stated, the basis of medical science, we should greatly misapprehend its nature did we not consider it the chief of the accessory sciences of medicine.

Without it, the physiologist rears his structure upon sand; for physiology is nothing more than the interpretation of anatomy. It is anatomy that guides the eye and the hand of the surgeon; that inspires him with that ready confidence, which leads him to search among structures, whose lesion would be dangerous or mortal, for some vessel that must be tied, or for a tumour which must be extirpated. Nor is it less indispensable to the physician, to whom it reveals the seat of diseases, and the changes of form, size, relation, and texture, which the affected organs have undergone.

Anatomy is, moreover, the science which, of all others, excites the greatest curiosity. If the mineralogist and the botanist are so eager, the one to determine the nature of a stone, the other to ascertain the characters of a flower; if the love of their particular science induces them to undertake the most dangerous voyages, in order to enrich it with a new species, what ought to be our ardour in pursuing the study of man, that masterpiece of creation, whose structure, possessed of both delicacy and strength, exhibits so much harmony as a whole, and displays so much perfection in its parts!

And while contemplating this marvellous organization, in which all has been provided and prearranged with such intelligence and wisdom, that no single fibre can acquire the slightest addition, or undergo the least diminution of power, without the equilibrium being destroyed and disorder being induced—what anatomist is there who would not feel tempted to exclaim, with Galen, that a work on anatomy is the most beautiful hymn which man can chant in honour of his Creator!*

May this work inspire among students an ever-increasing ardour for the study of the organization of man, which, even if it were not the most eminently useful, would still be the most interesting, and the most beautiful of all the sciences. And what more powerful motive for emulation can present itself to a generous mind, than the idea, "that every acquisition of knowledge is a conquest achieved for the relief of suffering humanity!" Let it never be forgotten that, without anatomy, there is no physiology, no surgery, no medicine; that, in a word, all the medical sciences are grafted upon anatomy as upon a stock; and that the deeper its roots descend, the more vigorous will be its branches, and the more abundantly laden with flowers and with fruit.

I must here express my acknowledgments to M. Chassaignac, the anatomical assistant to the Faculty, who has distinguished himself in several *concours*, and who has assisted me with the greatest zeal in the execution of this work.

* "Sacrum sermonem quem ego Conditoris nostri verum hymnum compono, existimoque in hoc veram esse pietatem, non si taurorum hecatombas ei sacrificaverim, et casias, aliaque sexcenta odoramenta ac unguenta suffumigaverim, sed si noverim ipse primus, deinde et aliis exposuerim quænam sit ipsius sapientia, quæ virtus, quæ bonitas."—(*Galen, De usu part.*, lib. iii.)

CONTENTS.

INTRODUCTION.

Object and Division of Anatomy.—General View of the Human Frame.—Apparatus of Sensation—of Locomotion—of Nutrition—of Reproduction.—General Plan of the Work . . . . . Page 1

APPARATUS OF LOCOMOTION.

OSTEOLOGY.

Of the Bones in General.

The Bones—Importance of their Study.—General View of the Skeleton.—Number of the Bones.—Method of Description.—Nomenclature.—Situation in general.—Direction.—Size, Weight, and Density of Bones.—Figure.—Distinction into long, broad, and flat Bones.—Regions of Bones.—Eminences and Cavities.—Internal Conformation.—Texture.—Development, or Osteogeny.—Nutrition 5

The Vertebral Column.

General Characters of the Vertebræ.—Characters peculiar to the Vertebræ of each Region.—Characters proper to certain Vertebræ.—Vertebræ of the Sacro-coccygeal Region.—The Vertebral Column in general.—Development 18

The Scull.

Composed of the Cranium and Face.—Cranial Bones—Occipital—Frontal—Sphenoid—Œthmoid—Parietal—Temporal.—The Cranium in general.—Development.—Bones of the Face—Superior Maxillary.—Palate.—Malar.—Nasal.—Lachrymal—Inferior turbinated.—Vomer—Inferior Maxillary.—The Face in general.—Cavities.—Development 33

The Thorax, or Chest.

The Sternum.—Ribs.—Costal Cartilages.—The Thorax in general.—Development 64

The Superior, or Thoracic Extremities.

The Shoulder.—Clavicle.—Scapula.—The Shoulder in general.—Development.—Humerus.—Ulna.—Radius.—The Hand.—The Carpus and Carpal Bones.—The Metacarpus and Metacarpal Bones.—The Fingers.—General Development of the Superior Extremities 73

The Inferior, or Abdominal Extremities.

The Haunch.—Os Coxæ.—The Pelvis.—Development.—Femur.—Patella.—Tibia.—Fibula.—The Foot.—The Tarsus and Tarsal Bones.—The Metatarsus and Metatarsal Bones.—The Toes.—Development of the Lower Extremities.—Comparison of the Upper and Lower Extremities.—Os Hyoides 87

The Articulations, or Arthrology.

General Observations.—Articular Cartilages.—Ligaments.—Synovial Membranes.—Classification of the Joints.—Diarthroses.—Synarthroses.—Amphiarthroses, or Symphyses 111

Articulations of the Vertebral Column.

Articulations of the Vertebræ with each other.—Those peculiar to certain Vertebræ.—Sacro-vertebral, Sacro-coccygeal, and Coccygeal Articulations.—Articulations of the Cranium—of the Face—of the Thorax 115

Articulations of the Superior or Thoracic Extremities.

Articulations of the Shoulder.—Scapulo-humeral.—Humero-cubital.—Radio-cubital.—Radio-carpal.—Of the Carpus and Metacarpus.—Of the Fingers 135

Articulations of the Inferior or Abdominal Extremities.

Articulations of the Pelvis.—Coxo-femoral.—Knee-joint.—Peroneo-tibial.—Ankle-joint.—Of the Tarsus.—Tarso-metatarsal.—Of the Toes 154

ODONTOLOGY.

Circumstances in which the Teeth differ from Bones.—Number.—Position.—External Conformation.—General Characters.—Classification—Incisor—Canine—Molar.—Structure.—Development 177

MYOLOGY.

The Muscles in general.—Nomenclature.—Number.—Volume and Substance.—Figure.—Dissection.—Relations.—Attachments.—Structure.—Uses.—Preparation.—Order of Description 190

Muscles of the Posterior Region of the Trunk.

The Trapezius.—Latissimus Dorsi and Teres Major.—Rhomboideus.—Levator Anguli Scapulæ.—Serrati Postici.—Splenius.—Posterior Spinal Muscles.—Complexus.—Inter-spinales Colli.—Recti Capitis Postici, Major et Minor.—Obliqui Capitis, Major et Minor.—General View and Action of the Posterior Spinal Muscles 198

Muscles of the Anterior Abdominal Region.

The Obliquus Externus Abdominis.—Obliquus Internus and Cremaster.—Transversalis Abdominis.—Rectus Abdominis.—Pyramidalis 208

Diaphragmatic Region 212

Lumbar Region.

The Psoas and Iliacus.—Psoas Parvus.—Quadratus Lumborum 214

Lateral Vertebral Region.

The Inter-transversales and Rectus Capitis Lateralis.—Scaleni 217

Deep Anterior Cervical, or Prevertebral, Region.

The Recti Capitis Antici, Major et Minor.—Longus Colli.—Action of these Muscles . . . Page 218

Thoracic Region.

The Pectoralis Major.—Pectoralis Minor.—Sub-clavius.—Serratus Magnus.—Intercostales.—Supra-costales.—Infra-costales.—Triangularis Sterni 220

Superficial Anterior Cervical Region.

The Platysma Myoides.—Sterno-cleido-mastoideus 224

Muscles of the Infra-hyoid Region.

The Sterno-hyoideus.—Scapulo- or Omo-hyoideus.—Sterno-thyroideus.—Thyro-hyoideus . . . 226

Muscles of the Supra-hyoid Region.

The Digastricus.—Stylo-hyoideus.—Mylo-hyoideus.—Genio-hyoideus.—Their Action 228

Muscles of the Cranial Region.

Occipito-frontalis.—Auricular Muscles 230

Muscles of the Palpebral Region.

Orbicularis Palpebrarum.—Superciliaris.—Levator Palpebræ Superioris 231

Nasal Region.

The Pyramidalis Nasi.—Levator Labii Superioris Alæque Nasi.—Transversalis, or Triangularis Nasi.—Depressor Alæ Nasi.—Naso-labialis 233

Muscles of the Labial Region.

The Orbicularis Oris.—Buccinator.—Levator Labii Superioris.—Caninus.—Zygomatici, Major et Minor.—Triangularis.—Quadratus Menti.—Levator Labii Superioris.—Movements of the Lips and those of the Face 234

Muscles of the Temporo-maxillary Region.

The Masseter and Temporalis 239

The Pterygo-maxillary Region.

The Pterygoideus Internus.—The Pterygoideus Externus 240

Muscles of the Shoulder.

The Deltoideus.—Supra-spinatus.—Infra-spinatus and Teres Minor.—Sub-scapularis 241

Muscles of the Arm.

The Biceps.—Brachialis Anticus.—Coraco-brachialis.—Triceps Extensor Cubiti 244

Muscles of the Forearm 249

Muscles of the Hand.

The Abductor Brevis Pollicis.—Opponens Pollicis.—Flexor Brevis Pollicis.—Adductor Pollicis.—Palmaris Brevis.—Abductor Digiti Minimi.—Flexor Brevis Digiti Minimi.—Opponens Digiti Minimi.—The Interosseous Muscles, Dorsal and Palmar 260

Muscles of the Pelvis.

The Glutæi Maximus, Medius, et Minimus.—Pyriformis.—Obturator Internus.—Gemelli, Superior et Inferior.—Quadratus Femoris.—Obturator Externus.—Action of these Muscles 264

Muscles of the Thigh.

The Biceps Cruris.—Semi-tendinosus.—Semi-membranosus.—Tensor Vaginæ Femoris.—Sartorius.—Triceps Extensor Cruris.—Gracilis.—Adductor Muscles of the Thigh 269

Muscles of the Leg.

The Tibialis Anticus.—The Extensor Communis Digitorum.—Extensor Proprius Pollicis.—Peronei Longus et Brevis.—Gastrocnemius, Plantaris and Solaris.—Popliteus.—Tibialis Posticus.—Flexor Longus Pollicis 277

Muscles of the Foot.

The Extensor Brevis Digitorum.—Abductor Pollicis Pedis.—Flexor Brevis Pollicis Pedis.—Adductor Pollicis Pedis.—Transversus Pollicis Pedis.—Abductor Digiti Minimi.—Flexor Brevis Digiti Minimi.—Flexor Brevis Digitorum.—Flexor Accessorius.—Lumbricales.—Interossei 286

APONEUROLOGY.

General Observations on the Aponeuroses.—Structure.—Uses 294

Particular Aponeuroses.

Superficial Fascia.—Aponeuroses of the Cranium—of the Face—of the Neck—of the Thorax—of the Abdomen—of the Pelvis—of the Thigh, Leg, and Foot—of the Shoulder, Arm, Forearm, and Hand . . 297

SPLANCHNOLOGY.

General Observations on the Viscera.—External Conformation.- tructure.—Development.—Functions.—Dissection 320

THE ORGANS OF DIGESTION AND THEIR APPENDAGES.

Alimentary or Digestive Canal.

General Observations.—Division.—Mouth and its Appendages.—Lips.—Cheeks.—Hard and soft Palate.—Tonsils.—Tongue.—Salivary Glands.—Buccal Mucous Membrane.—Pharynx.—Œsophagus.—Stomach.—Small Intestine.—Large Intestine.—Muscles of the Perineum.—Development of the Intestinal Canal . 322

Appendages of the Alimentary Canal.

The Liver and its Excretory Apparatus.—The Pancreas.—The Spleen 384

THE ORGANS OF RESPIRATION

General Observations.—The Lungs and Pleuræ.—The Trachea and Bronchi.—Development of the Lungs.—The Larynx—its Structure, Development, and Functions.—The Thyroid Gland 409

The Genito-Urinary Organs.

The Urinary Organs.

Division.—The Kidneys and Ureters.—The Bladder.—The Supra-renal Capsules . . . Page 435

The Generative Organs.

The Generative Organs of the Male.

The Testicles and their Coverings.—The Epididymis, the Vasa Deferentia, and Vesiculæ Seminales.—The Penis.—The Urethra.—The Prostate and Cowper's Glands 446

The Generative Organs of the Female.

The Ovaries.—The Fallopian Tubes.—The Uterus.—The Vagina.—The Urethra.—The Vulva . . 461

The Mammæ.

Number.—Situation.—Size.—Form.—Structure.—Development 473

The Peritoneum.

The Sub-umbilical Portion.—The Supra-umbilical Portion.—General Description and Structure . . 479

ANGEIOLOGY.

Definition and Objects of Angeiology 479

The Heart.

General Description.—External and Internal Conformation.—Structure.—Development.—Functions.—The Pericardium 479

The Arteries.

Definition.—Nomenclature.—Origin.—Varieties.—Course.—Anastomoses.—Form and Relations.—Termination.—Structure.—Preparation 496

Description of the Arteries.

The Pulmonary Artery.

Preparation.—Description.—Relations.—Size.—Development 499

The Aorta.

Preparation.—Definition.—Situation.—Direction.—Size.—Division into the Arch of the Aorta, the Thoracic Aorta, and the Abdominal Aorta 501

Collateral Branches of the Aorta.

Enumeration and Classification.—Arteries arising from the Aorta at its Origin, viz., the Coronary or Cardiac.—Arteries arising from the Thoracic Aorta, viz., the Bronchial, the Œsophageal, the Intercostal.—Arteries arising from the Abdominal Aorta, viz., the Lumbar, the Inferior Phrenic, the Cœliac Axis, including the Coronary of the Stomach, the Hepatic, and the Splenic, the Superior Mesenteric, the Inferior Mesenteric, the Spermatic, the Renal, and the Supra-renal or Capsular 503

Arteries arising from the Arch of the Aorta.

Enumeration and Varieties.—The Common Carotids.—The External Carotid—the Superior Thyroid—the Facial—the Lingual—the Occipital—the Posterior Auricular—the Parotid—the ascending Pharyngeal—the Temporal—the Internal Maxillary.—The Internal Carotid—the Ophthalmic—the Cerebral Branches of the Internal Carotid.—Summary of the Distribution of the Common Carotids.—Artery of the Upper Extremity.—The Brachio-cephalic.—The Right and Left Sub-clavians—the Vertebral and its Cerebral Branches, with Remarks on the Arteries of the Brain, Cerebellum, and Medulla—the Inferior Thyroid—the Supra-scapular—the Posterior Scapular—the Internal Mammary—the deep Cervical—the Superior Intercostal.—The Axillary—the Acromio-thoracic—the Long Thoracic—the Sub-scapular—the Posterior Circumflex—the Anterior Circumflex.—The Brachial and its Collateral Branches.—The Radial, its Collateral Branches, and the deep Palmar Arch.—The Ulnar, its Collateral Branches, and the Superficial Palmar Arch.—General Remarks on the Arteries of the Upper Extremity 513

Arteries arising from the Termination of the Aorta.

Enumeration.—The Middle Sacral.—The Common Iliacs.—The Internal Iliac, or Hypogastric—the Umbilical—the Vesical—the middle Hæmorrhoidal—the Uterine—the Vaginal—the Obturator—the Ilio-lumbar—the Lateral Sacral—the Glutæal—the Sciatic—the Internal Pudic.—Summary of the Distribution of the Internal Iliac.—Artery of the Lower Extremity.—The External Iliac—the Epigastric—the Circumflex Iliac.—The Femoral—the Superficial Epigastric—the External Pudic—the Muscular—the deep Femoral, its Circumflex and Perforating Branches.—The Popliteal, and its Collateral Branches.—The Anterior Tibial and the Dorsal Artery of the Foot.—The Tibio-peroneal—Peroneal—Posterior Tibial, and the Internal and External Plantar.—Comparison between the Arteries of the Upper and Lower Extremities . 552

The Veins.

Definition.—The Venous System.—Origin of the Veins.—Course.—Anastomoses and Plexuses.—Varieties.—Termination.—Valves.—Structure.—Preparation.—Method of Description 573

Description of the Veins.

The Pulmonary Veins

Preparation.—Description.—Relations.—Size.—Peculiarities 577

The Veins of the Heart.

The Great Coronary or Cardiac Vein.—The Small Cardiac Veins 577

The Superior, or Descending Vena Cava and its Branches.

The Superior Vena Cava.—The Brachio-cephalic Veins—the Inferior Thyroid—the Internal Mammary—the Superior Phrenic, the Thymic, Pericardiac, and Mediastinal—the Vertebral.—The Jugular Veins, viz., the External—the Anterior—and the Internal.—The Encephalic Veins, and the Sinuses of the Dura Mater, viz., the Lateral—the Superior Longitudinal—the Straight—the Superior and Inferior Petrosal—the Cavernous—the Coronary—and the Anterior and Posterior Occipital Sinuses—the Conflux of the Sinuses.—The Branches of Origin of the Jugular Veins—the Facial—the Temporo-maxillary—the Pos-

terior Auricular—the Occipital—the Lingual—the Pharyngeal—the Superior and Middle Thyroid—the Veins of the Diploe.—Summary of the Distribution of the Veins of the Head.—The deep Veins of the Upper Extremity—the Palmar, Radial, Ulnar, Brachial, and Axillary—the Sub-clavian.—The Superficial Veins of the Upper Extremity—in the Hand—in the Forearm—at the Elbow—and in the Arm.—General Remarks on these Superficial Veins . . . . . Page 578

The Inferior, or Ascending Vena Cava and its Branches.

The Inferior Vena Cava—the Lumbar or Vertebro-lumbar Veins—the Renal—the Middle Supra-renal—the Spermatic and Ovarian—the Inferior Phrenic.—The Portal System of Veins—the Branches of Origin of the Vena Portæ—the Vena Portæ—the Hepatic Veins.—The Common Iliacs—the Internal Iliac—the Hemorrhoidal Veins and Plexuses—the Pelvic Veins and Plexuses in the Male and in the Female.—The deep Veins of the Lower Extremity—the Plantar, Posterior Tibial, Peroneal, Dorsal, Anterior Tibial, and Popliteal—the Femoral—the External Iliac.—The Superficial Veins of the Lower Extremity—the Internal Saphenous—the External Saphenous 596

The Veins of the Spine.

General Remarks.—The Superficial Veins of the Spine.—The Anterior Superficial Spinal Veins, viz., the Greater Azygos—the Lesser Azygos—the Left Superior Vertebro-costals—the Right Vertebro-costals—the Vertebro-lumbar—the Ilio-lumbar, and Middle and Lateral Sacral—the Anterior Superficial Spinal Veins in the Neck.—The Posterior Superficial Spinal Veins.—The deep Spinal or Intra-spinal Veins—the Anterior Longitudinal, and the Transverse Veins or Plexuses, and the Veins of the Vertebræ—the Posterior and the Posterior and Lateral Transverse Veins or Plexuses—the Medullary Veins.—General Remarks on the Veins of the Spine 605

THE LYMPHATIC SYSTEM.

Definition, History, and general View of the Lymphatic System.—Origin.—Course.—Termination and Structure of the Lymphatic Vessels.—The Lymphatic Glands.—Preparation of the Lymphatic Vessels and Glands 611

DESCRIPTION OF THE LYMPHATIC SYSTEM.

The Thoracic Duct—the Right Thoracic Duct.—The Lymphatic System of the Lower Extremity—of the Pelvic and Lumbar Regions—of the Liver—of the Stomach, Spleen, and Pancreas—of the Intestines—of the Thorax—of the Head—of the Cervical Regions—of the Upper Extremity and Upper Part of the Trunk 620

NEUROLOGY.

THE ORGANS OF THE SENSES.

The Skin—its External Characters, Structure, and Appendages.—The Tongue considered as the Organ of Taste.—The Organ of Smell—the Nose—the Pituitary Membrane.—The Organ of Sight—the Eyebrows—the Eyelids—the Muscles of the Orbit—the Lachrymal Apparatus—the Globe of the Eye, its Membranes and Humours—the Vessels and Nerves of the Eye.—The Organ of Hearing—the External Ear—the Middle Ear or Tympanum—the Internal Ear or Labyrinth—the Nerves and Vessels of the Ear . 629

THE CEREBRO-SPINAL AXIS.

General Observations 681

The Membranes of the Cerebro-spinal Axis.

General Remarks.—The Dura Mater—the Cranial Portion, its Structure and Uses—the Spinal Portion.—The Arachnoid—its Cranial Portion—its Spinal Portion—the Sub-arachnoid Fluid—their Uses.—The Pia Mater—its External Cerebral Portion 682

The Spinal Cord, and the Medulla Oblongata.

General View of the Cord—its Limits and Situation—the Ligamentum Denticulatum.—Size of the Spinal Cord—Form, Directions, and Relations—the Cord in its Proper Membrane—the Proper Membrane, or Neurilemma of the Cord—the Cord deprived of its Proper Membrane.—Internal Structure of the Cord—Sections—Examination by means of Water, and when hardened in Alcohol—the Cavities or Ventricles of the Cord.—The Medulla Oblongata—Situation—External Conformation—Anterior Surface, the Anterior Pyramids and the Olivary Bodies—the Posterior Surface—the Lateral Surfaces—the Internal Structure—Sections—Examination by Dissection, and under Water.—Development of the Spinal Cord.—Development of the Medulla Oblongata.—Comparative Anatomy of the Spinal Cord.—Comparative Anatomy of the Medulla Oblongata 693

THE ISTHMUS OF THE ENCEPHALON.

General Description and Division.—The Pons Varolii and Middle Peduncles of the Cerebellum—the Peduncles of the Cerebrum—the Superior Peduncles of the Cerebellum and the Valve of Vieussens—the Corpora Quadrigemina.—Internal Structure of the Isthmus, viz., of its Inferior, Middle, and Superior Strata.—Sections.—Development.—Comparative Anatomy 710

THE CEREBELLUM.

General Description.—External Characters and Conformation—Furrows, Lobules, Laminæ, and Lamellæ.—Internal Conformation—the Fourth Ventricle, its Fibrous Layers, its Inferior Orifice, and its Choroid Plexus.—Sections of the Cerebellum, Vertical and Horizontal.—Examination by Means of Water, and of the hardened Cerebellum.—General View of the Organ.—Development.—Comparative Anatomy . 715

THE CEREBRUM, OR BRAIN PROPER.

Definition—Situation—Size and Weight—General Form.—The Superior or Convex Surface.—The Inferior Surface or Base—its Median Region, containing the Inter-peduncular Space, the Corpora Albicantia, the Optic Tracts and Commissure, the Tuber Cinereum, Infundibulum, and Pituitary Body, the Anterior Part of the Floor of the Third Ventricle, the reflected Part of the Corpus Callosum, the Anterior Part of the Longitudinal Fissure, the Posterior Part of the Longitudinal Fissure, the Posterior Extremity of the Corpus Callosum and Median Portion of the Transverse Fissure, and the Transverse Fissure.—The Lateral Regions, including the Fissure of Sylvius and the Lobes of the Brain.—The Convolutions and Anfractuosities of the Brain, upon its Inner Surface, its Base, and its Convex Surface—Uses of the Convolutions and Anfractuosities.—The Internal Structure of the Brain—Examination by Sections—Horizontal Sections showing the Corpus Callosum, the Septum Lucidum, the Fornix and Corpus Fimbriatum, the Velum Interpositum, the Middle or Third Ventricle, the Aqueduct of Sylvius, the Pineal Gland, the Lateral Ventricles, their Superior and Inferior Portions, the Choroid Plexus, and the Lining Membrane and the Fluid of the Ventricles—Median Vertical Section—Transverse Vertical Sections—Section of Willis.—General

Remarks on this Method of examining the Brain.—Methods of Varolius, Vieussens, and Gall.—Gall and Spurzheim's Views on the Structure of the Brain.—General Idea of the Brain.—Development.—Comparative Anatomy . . . . . Page 725

The Nerves, or the Peripheral Portion of the Nervous System.

General Remarks.—History and Classification.—Origin, or Central Extremity.—Different Kinds.—Course, Plexuses, and Anastomoses.—Direction, Relations, and Mode of Division.—Termination.—Nervous Ganglia, and the great Sympathetic System.—Connexions of the Ganglia with each other, and with the Spinal Nerves.—Structure of Nerves.—Structure of Ganglia.—Preparation of Nerves 759

Description of the Nerves.

General Remarks.—Division into Spinal, Cranial, and Sympathetic Nerves 769

The Spinal Nerves.

Enumeration and Classification.—The Central Extremities, or Origins of the Spinal Nerves—Apparent Origins—Deep or real Origins.—The Posterior Branches of the Spinal Nerves—Common Characters—the Posterior Branches of the Cervical Nerves, their Common and Proper Characters—the Posterior Branches of the Dorsal, Lumbar, and Sacral Nerves.—The Anterior Branches of the Spinal Nerves—their General Arrangement 770

The Anterior Branches of the Cervical Nerves.

Dissection.—Anterior Branch of the First, Second, Third, and Fourth Cervical Nerves.—The Cervical Plexus—its Anterior Branch, the Superficial Cervical—its Ascending Branches, the great Auricular and the External or Lesser Occipital—its Superficial Descending Branches, the Supra-clavicular—its deep Descending Branches, the Nerve to the Descendens Noni and the Phrenic—its deep Posterior Branches.—The Anterior Branches of the Fifth, Sixth, Seventh, and Eighth Cervical, and First Dorsal Nerves.—The Brachial Plexus—its Collateral Branches above the Clavicle—its Muscular Branches, Posterior Thoracic, Supra-scapular—opposite to the Clavicle the Thoracic, below the Clavicle the Circumflex—its Terminal Branches, the Internal Cutaneous and its Accessory, the Musculo-cutaneous, the Median, the Ulnar, the Musculo-spiral or Radial.—Summary of the Distribution of the Branches of the Brachial Plexus . 776

The Anterior Branches of the Dorsal Nerves, or the Intercostal Nerves.

Dissection.—Enumeration.—Common Characters.—Characters proper to each 794

The Anterior Branches of the Lumbar Nerves.

Enumeration.—The Lumbar Plexus.—Collateral Branches, Abdominal and Inguinal.—Terminal Branches—the Obturator Nerve—the Crural Nerve and its Branches, viz., the Musculo-cutaneous—the Accessory of the Internal Saphenous—the Branch to the Sheath of the Vessels—the Muscular Branches—the Internal Saphenous 796

The Anterior Branches of the Sacral Nerves.

Dissection.—Enumeration.—The Sacral Plexus.—Collateral Branches, viz., the Visceral Nerves—the Muscular Nerves—the Inferior Hemorrhoidal—the Internal Pudic and its Branches—the Superior Gluteal Nerve—the Inferior Gluteal, or Lesser Sciatic Nerve—the Nerves for the Pyramidalis, Quadratus Femoris, and Gemelli.—Terminal Branch of the Sacral Plexus, or the great Sciatic Nerve.—The External Popliteal and its Branches—the Peroneal, Saphenous, Cutaneous, and Muscular Branches—the Musculo-cutaneous—the Anterior Tibial.—The Internal Popliteal and its Branches—the Tibial or External Saphenous—Muscular and Articular Branches—the Internal Plantar—the External Plantar.—Summary of the Nerves of the Lower Extremity.—Comparison of the Nerves of the Upper with those of the Lower Extremity 804

The Cranial Nerves.

Definition and Classification.—The Central Extremities of the Cranial Nerves, viz., of the Olfactory—of the Optic—of the Common Motor Oculi—of the Pathetic—of the Trigeminal—of the External Motor Oculi—of the Portio Dura and Portio Mollis of the Seventh—of the Glosso-pharyngeal, Pneumogastric, and Spinal Accessory Divisions of the Eighth—and of the Ninth Nerves 816

Distribution of the Cranial Nerves.

The First Pair, or Olfactory Nerves.—The Second, or Optic Nerves.—The Third, or Common Motor Nerves.—The Fourth, or Pathetic Nerves.—The Fifth, or Trigeminal Nerves—the Ophthalmic Division of the Fifth, and its Lachrymal, Frontal, and Nasal Branches—the Ophthalmic Ganglion—the Superior Maxillary Division of the Fifth, and its Orbital Branch—the Spheno-palatine Ganglion, and its Palatine, Spheno-palatine, and Vidian Branches—the Posterior and Anterior Dental, and the Terminal Branches of the Superior Maxillary Nerve—the Inferior Maxillary Division of the Fifth—its Collateral Branches, viz., the deep Temporal, the Masseteric, Buccal, and Internal Pterygoid, and Auriculo-temporal—its Terminal Branches, viz., the Lingual and Inferior Dental—the Otic Ganglion.—The Sixth Pair, or External Motor Nerves.—The Seventh Pair—the Portio Dura, or the Facial Nerve—its Collateral Branches—its Terminal Branches, viz., the Temporo-facial and Cervico-facial—the Portio Mollis, or Auditory Nerve.—The Eighth Pair—its First Portion, or the Glosso-pharyngeal Nerve—its Second Portion, or the Pneumogastric Nerve, divided into a Cranial, Cervical, Thoracic, and Abdominal Part—its Third Portion, or the Spinal Accessory Nerve.—The Ninth Pair, or the Hypoglossal Nerves.—General View of the Cranial Nerves . 824

The Sympathetic System of Nerves.

General Remarks.—The Cervical Portion of the Sympathetic.—The Superior Cervical Ganglion—its Superior Branch, Carotid Plexus, and Cavernous Plexus—its Anterior, External, Inferior, and Internal Branches.—The Middle Cervical Ganglion.—The Inferior Cervical Ganglion.—The Vertebral Plexus.—The Cardiac Nerves; Right, Superior, Middle, and Inferior; Left.—The Cardiac Ganglion and Plexuses.—The Thoracic Portion of the Sympathetic.—The External and Internal Branches.—The Splanchnic Nerves, Great and Small.—The Visceral Ganglia and Plexuses in the Abdomen, viz., the Solar Plexus and Semilunar Ganglia.—The Diaphragmatic and Supra-renal, the Cœliac, the Superior Mesenteric, the Inferior Mesenteric, and the Renal, Spermatic, and Ovarian Plexuses.—The Lumbar Portion of the Sympathetic.—The Communicating, External, and Internal Branches.—The Lumbar Splanchnic Nerves and Visceral Plexuses in the Pelvis.—The Sacral Portion of the Sympathetic.—General View of the Sympathetic System 854

DESCRIPTIVE ANATOMY.

INTRODUCTION.

Object and Division of Anatomy.—General View of the Human Frame.—Apparatus of Sensation—of Locomotion—of Nutrition—of Reproduction.—General Plan of the Work.

Considered in its most extended signification, Anatomy* is the science which has for its object the structure of living beings.

Living beings are divided into two great classes, vegetables and animals; there is, therefore, a *vegetable anatomy* and an *animal anatomy*. When anatomy embraces, in one general view, the whole series of animals, comparing the same organs as they exist in the different species, it receives the name of *zoological*, or *comparative anatomy*.

Zoological anatomy is denominated *philosophical* or *transcendental*, when from the combination and comparison of particular facts it deduces general results, and laws of organization.

When anatomy is confined to the examination of one species only, it receives the name of *special*; such as the anatomy of man, the anatomy of the horse, &c. *Physiological anatomy* considers the organs in their healthy state. *Pathological anatomy* regards them as altered by disease.

When *physiological anatomy* is confined to the examination of the external conformation of organs, that is to say, of all their qualities which may be ascertained without division of their substance, it is called *descriptive anatomy*. If, on the contrary, it penetrates into the interior of organs, in order to determine their constituent or elementary parts, it receives the name *general anatomy*, or of *the anatomy of textures*.

Descriptive anatomy informs us of the names of organs (*anatomical nomenclature*), their number, situation, direction, size, colour, weight, consistence, figure, and relations; it traces, in fact, the topography of the human body. In more than one respect, it is to medicine what geography is to history. The anatomy used by *painters and sculptors* may be regarded as one of its dependances, and may be defined to be the knowledge of the external surface of the body, in the different attitudes of repose, and in its various movements. On this subject it may be observed, that the precise determination of the external eminences and depressions may afford most important indications regarding the situation and state of deeply-seated parts, and is therefore worthy the attention of the physician.

Descriptive anatomy, in the sense here meant, has arrived at a high degree of perfection. It is to this branch that reference is made by those who affirm that nothing now remains to be done in anatomy. But although descriptive anatomy may be all that the surgeon requires to enable him to comprehend the lesions which most commonly fall under his notice, and to perform operations, it will by no means suffice for the physician or the physiologist. For their purposes, anatomical investigations must not be confined to the surface, but penetrate into, and analyze the substance of organs. Now such is the object of general or textural anatomy. By its means the different organs are resolved into their component tissues: these tissues, again, are reduced to their simple elements, which are then studied by themselves, independently of the organs which they form; and subsequently, by considering the elementary constituents as combined in various proportions, the organization of even the most complicated and dissimilar parts is made manifest.

There is one species of anatomy which has of late been cultivated with the greatest success. I mean the *anatomy of the fœtus*.

The anatomy of the fœtus, or the anatomy of the body at different periods of life, named *the anatomy of evolution*, has for its object the study of the development of organs, their successive modifications, and sometimes even the metamorphoses which they undergo, from the time of their first appearance until they arrive at perfection.

Lastly, there is a species of anatomy to which the term of "*applied anatomy*" may be given, because it comprehends all the practical applications of the science to medicine

* The word Anatomy is derived from the Greek (ἀνὰ, up, and τεμνω, I cut). It is, in fact, by means of dissection principally that we are enabled to separate and study the different organs. But injections, desiccation, the action of alcohol, concentrated acids, &c., are also means employed by the anatomist.

and surgery. With this view, the body is divided into regions or departments, and each region into successive layers. The relation of the different layers is pointed out, and in each layer the parts which compose it. In a word, the constant object is the solution of the following question: A region, or any part of the surface of the body being given, to determine the subjacent parts which correspond to it at different depths, and their order of superposition. This has generally been denominated the *anatomy of regions, topographical* or *surgical anatomy*, because it has hitherto been studied only with reference to its uses in surgery. It may easily be shown, however, that with the exception of the limbs or extremities, the anatomical knowledge of which has few applications to medicine, properly so called, the study of regions is no less important to the physician than to the surgeon. To give it, therefore, a name corresponding with its use, it should be called *medico-chirurgical topographical anatomy*.

Such are the different aspects under which anatomy may be regarded. The following work is essentially devoted to descriptive anatomy.*

General View of the Human Body.

Before entering on a detailed description of the numerous organs which enter into the composition of the human body, it is advisable to present a rapid sketch of the whole. Such general views, instead of embarrassing the mind, at once enlighten and satisfy it, by exhibiting the objects of its research in their true relations, and showing the end to be attained.

There is one general covering, which, like a garment, envelops the whole body, and is moulded, at it were, round all its parts. This covering is the *skin*, of which the nails and hair are dependances. The skin presents a certain number of apertures, by means of which a communication is established between the exterior and the interior of the body. These apertures, however, are not formed by a mere perforation or breach of continuity in the skin; on the contrary, this membrane passes inward at the circumference of these openings, and having undergone certain important modifications in its structure, forms the *mucous membranes*, a kind of internal tegument, which may be considered as a prolongation of the external envelope. We might, therefore, strictly speaking, regard the human body as essentially composed of a skin folded back upon itself. This idea is, indeed, realized in some of the inferior animals, which consist of a mere tube or canal. In proportion, however, as we ascend in the scale, we find the layers which separate these two teguments become more and more increased in thickness, and cavities are at length formed between them. Nevertheless, however widely these membranes may be separated from each other, and however different they may be in external aspect, there are abundant analogies to establish unequivocally their common origin.

Under the skin there is a layer of adipose cellular tissue, which gently elevates it, fills up the depressions, and contributes to impart that roundness of form which characterizes all animals, and particularly the human species. In some parts, there are muscles inserted into the skin, which are intended for its movement; these are the cutaneous muscles. In man they are very inconsiderable, and are confined to the neck and face, where they play an important part in giving expression to the physiognomy; but in the larger animals they line the whole skin, and in certain classes, of very simple organization, they constitute the entire locomotive apparatus.

The superficial veins and lymphatics traverse the subcutaneous cellular tissue: the latter, at various parts of their course, pass through enlargements denominated lymphatic ganglions, or lymphatic glands, which are grouped together in certain regions.

Below the cellular tissue are the *muscles*, red, fleshy bundles, arranged in many layers.

In the centre of all these structures are placed the bones, inflexible columns, which serve for a support to all that surrounds them. The vessels and the nerves are in the immediate neighbourhood of the bones, and, consequently, removed as much as possible from external injury. Lastly, around the muscles and under the subcutaneous adipose tissue are certain strong membranes, which bind the parts together, and which, by prolongations detached from their internal surface, separate and retain in their situation the different muscular layers, frequently each particular muscle: these envelopes are the *aponeuroses*.

Such is the general structure of the limbs or extremities.

If next we examine the trunk, we find in its parietes a similar structure, but more internally are cavities lined by thin transparent membranes, named *serous*, on account of a liquid or serosity with which they are moistened. In these cavities are situated organs of a complex structure, called *viscera*, of which we shall give a rapid enumeration in an order conformable to the offices they perform in the animal economy.

The human body, as well as that of other organized beings, is composed of certain parts, denominated organs (ὄργανον, an instrument), which differ from each other in

* Descriptive anatomy ought, in strictness, to be confined to the consideration of the external characters of organs, or what is understood by the term *external conformation*; nevertheless, in order to present a complete view of each organ, after having described its exterior, we shall give a short account of its texture and development.

their structure and use, but are all combined, for the double purpose of the preservation of the individual, and the continuance of the species.

To accomplish these purposes, the organs are distributed in a certain number of groups or series, each of which has a definite end to fulfil. This end is denominated a *function:* the series of organs receives the name of an *apparatus.* Of those necessary for the preservation of the individual, some are designed to place him in relation with external objects, and these constitute the *apparatus of relation:* the others are destined to repair the loss which the parts of the body are constantly suffering; they form the *apparatus of nutrition.*

The apparatus of relation may be subdivided into two classes: 1. *The apparatus of sensation.* 2. *The apparatus of motion.*

Apparatus of Sensation.—The apparatus of sensation consists, 1. *Of the organs of sense;* 2. *Of the nerves;* 3. *Of the brain and spinal cord.*

The organs of the senses are, 1. *The skin,* which possesses sensibility, the exercise of which constitutes tact. The skin being placed under the direction of the will, and rendered mobile in consequence of the peculiar mechanism of the human hand, is called the *organ of touch.* 2. *The organ of taste,* the seat of which is in the cavity of the mouth, that is, at the entrance of the digestive canal. 3. *The organ of smell,* placed in the nasal fossæ, the commencement of the respiratory passages, by which we are enabled to recognise the odorous emanations of bodies. 4. *The organ of hearing,* constructed in accordance with the principles of acoustics, and placed in relation with the vibrations of the air. 5. *The organ of sight,* which bears relation to the light, and exhibits a construction in harmony with the most important laws of dioptrics.

The organs of sense receive impressions from without. Four of them occupy the face, and are, therefore, placed in the vicinity of the brain, to which they transmit impressions with great rapidity and precision; and that organ seems, in its turn, to extend into them, so to speak, by means of the nerves. Indeed, the impressions received by the external organs would be arrested in them, were it not for certain conductors of such impressions: these conductors are the *nerves*—white, fasciculated cords, one extremity of which passes into the organs, while the other is connected to the spinal marrow and the brain, which are the central parts of the nervous system, the nerves constituting the peripheral part.

Apparatus of Locomotion.—The apparatus of *locomotion* consists, 1. Of an active or contractile portion, the *muscles.* These are terminated by *tendons,* organs of a pearly white colour, which direct upon a single point the action of many forces; 2. Of a passive portion, *the bones,* true levers, which constitute the framework of the body, and the extremities of which, by their mutual contact, form the *articulations:* in the latter we perceive (*a*) the *cartilages,* compressible, elastic substances, which deaden the violence of shocks, and render the contact uniform; (*b*) an unctuous liquid, the *synovia,* secreted by membranes denominated *synovial:* this liquid performs the office of the grease employed in the wheel-work of machinery; (*c*) bands or *ligaments,* which maintain the connexion of the bones.

Such is the apparatus designed to establish the relation between man and external objects.

Apparatus of Nutrition.—The apparatus which performs in the human body the important office of nutrition consists of the following parts:

A. The *digestive apparatus,* which consists essentially of a continuous tube or canal, denominated the *alimentary canal.* This canal has not the same form and structure throughout the whole extent: on the contrary, it is composed of a series of very dissimilar organs, all, however, contributing to the formation of one common passage. These organs are, 1. *The mouth;* 2. *The pharynx;* 3. *The œsophagus,* or gullet; 4. *The stomach;* 5. *The intestines;* which are farther subdivided into the *small intestines,* consisting of the *duodenum, jejunum,* and *ileum,* and the *large intestines,* comprising the *cæcum, colon,* and *rectum.*

To this long tube, the greater part of which is contained in the abdomen, where it forms numerous reduplications, are annexed, 1. *The liver,* a glandular organ, whose office it is to secrete the bile, and which occupies the superior and right portion of the abdomen; 2. *The spleen,* whose functions are involved in great obscurity, but which may, perhaps, be termed an appendix to the liver, on the left side; 3. *The pancreas,* which pours a fluid into the duodenum, by an orifice common to it and the biliary duct.

B. On the internal surface of the digestive canal, and particularly that portion of it which bears the name of the small intestine, certain vessels open by numerous orifices or mouths,* and carry off the nutritive fluids prepared by the process of digestion: these are the *chyliferous* or *absorbent vessels,* which are also called *lacteal vessels,* on account of the white, milky aspect presented by their contents while absorption is going on. The absorbent apparatus consists, also, of another set of vessels denominated *lymphatics,* because they contain a colourless liquid named lymph, which they collect from all parts of

* [This must not be understood literally. See account of the lacteals, *infrà.*]

the body. All the absorbent vessels, of whatever order they may be, traverse at different parts of their course certain grayish bodies, called *lymphatic ganglions* or *glands*, and finally terminate in the venous system.

C. The venous system arises from all parts of the body: it takes up, on the one hand, all those matters which, having been employed a sufficient time as part of the body, must be eliminated from it; and, on the other hand, all those substances which are carried into the system, to contribute to its reparation: it is composed of vessels denominated *veins*, which at various distances are provided with valves, and at last unite in forming two large veins called *venæ cavæ*, of which one, *the superior*, receives the blood from the upper part of the body; the other, *the inferior*, brings back that which has circulated in the lower portion.

These two venæ cavæ terminate in the central organ of the circulation, the *heart*, a hollow muscle, containing four contractile cavities: two on the right side, the *right auricle and ventricle*, and two on the left, the *left auricle and ventricle*.

D. Next to these in order of function is the *respiratory apparatus*, composed of two spongy sacs, placed on each side of the heart, and occupying almost the whole of the chest: these are *the lungs*. They receive the air from a common tube, *the trachea*, which is surmounted by a vibratile organ, the larynx, which opens externally by the nose and mouth, and constitutes the organ of voice.

E. From that cavity of the heart which is called the left ventricle, arises a large vessel, *the aorta:* this forms the principal and primitive trunk of the whole class of vessels named *arteries*, whose office it is to convey red blood to all parts of the body, to maintain their heat and life.

F. There still remains one other portion of the nutritive system, *the urinary apparatus*, consisting of, 1. *The kidneys*, organs which secrete the urine: 2. *The ureters*, by means of which the urine, as soon as secreted, passes off into a spacious receptacle, *the bladder*, from whence it is at intervals expelled along a passage which has received the name of *urethra*.

Apparatus of Reproduction.—The apparatus above mentioned is destined for individual preservation: the organs which secure the continuance of the species constitute the *generative* or *reproductive apparatus*. They differ in the male and in the female.

In the male they are, 1. *The testicles*, which prepare the spermatic or fecundating fluid; 2. *The vasa deferentia*, tubes which transmit this fluid from the testicle where it is secreted to the vesiculæ seminales; 3. *The vesiculæ seminales*, or receptacles of semen; 4. *The ejaculatory ducts*, through which the seminal fluid passes into the urethra; 5. *The prostate* and *Cowper's glands*, glandular appendages of the organs for the transmission of the semen; 6. *The penis*, by means of which the fecundating fluid is conveyed into the interior of the genital organs of the female.

The generative apparatus in the female is composed of the following organs: 1. *The ovaries*, the function of which is to produce, or keep in readiness, the ovulum or germ; 2. *The uterine tubes*, which transmit the germ, when fecundated, to the uterus; 3. *The uterus or womb*, in which the product of conception remains and is developed during the period of gestation; 4. *The vagina*, a canal which permits the passage of the fœtus at its final expulsion; 5. As appertaining to the system should be mentioned the *mammary glands*, which secrete the milk destined for the nourishment of the new-born infant.

General Plan of the Work.

There are two methods by which the numerous facts that come within the range of anatomy may be explained. The different organs may be studied in their order of superposition, or in the *topographic order, à capite ad calcem;* in this way the most dissimilar parts are brought together, while others are separated which have the greatest analogy; or they may be considered in a *physiological order, i. e.*, an order founded upon the same grounds as serve for the classification of functions. This is clearly the most rational, because it has the incontestable advantage of preparing for the study of the functions by that of the organs. It may be easily seen, however, that this physiological arrangement should be modified according to the relative difficulty in the study of the different parts of the body; for the great aim in a work of instruction should be to conduct the mind, by degrees, from simple and easy objects to those which are more complicated. It is for this reason that the consideration of the nervous system, which, in strict accordance with physiological arrangement, should be placed near to that of the locomotive apparatus, is deferred. The object proposed has been to adopt an arrangement which would, as far as possible, reconcile both these views, and, at the same time, be compatible with the greatest economy of subjects for dissection; and this appears to be secured by the method generally adopted, at least with a few slight modifications.

The following table presents a view of the general plan of this work:

1. Apparatus of locomotion	1. Of the bones—Osteology. 2. Of the articulations—Syndesmology. 3. Of the muscles—Myology. 4. Of the aponeuroses—Aponeurology.

2. Apparatus of digestion, apparatus of respiration, genito-urinary apparatus	Splanchnology.	
3. Apparatus of the circulation	Heart .	Angeiology.
	Arteries .	
	Veins .	
	Lymphatics	
4. Apparatus of sensation and innervation . .	Organs of the senses	Neurology.
	Spinal cord . .	
	Brain . . .	
	Nerves . . .	

APPARATUS OF LOCOMOTION.

OSTEOLOGY.

OF THE BONES IN GENERAL.

The Bones — Importance of their Study.—General View of the Skeleton.—Number of the Bones.—Method of Description.—Nomenclature.—Situation in general.—Direction.—Size, Weight, and Density of Bones.—Figure.—Distinction into Long, Broad, and Flat Bones.—Regions of Bones.—Eminences and Cavities.—Internal Conformation.—Texture.—Development of Osteogeny.—Nutrition.

The bones are parts of a stony hardness, but yet organized and living. They serve as a support to all other parts of the body, are a means of protection to many, and afford points of attachment to the muscles, in the midst of which they are situated. All the hard parts of the body, however, are not bones. The fundamental character of a bone consists in its being at once hard and organized. As the bones receive vessels for the purpose of nutrition at every part of their surface, they are surrounded on all sides by a membrane which is fibrous and vascular, named the *Periosteum* (περὶ, around; ὀστέον, a bone).

According to this definition, the teeth, horns, nails, and, in articulated animals, the exterior skeleton, are not to be considered as bones, but merely ossiform concretions. We may add, that true bones belong exclusively to vertebrated animals.

The study of the bones constitutes *Osteology*, which may be regarded as the basis of anatomy, for without a knowledge of the bones it is impossible to become acquainted with the muscular insertions, or the exact relations between the muscles, nerves, viscera, and, above all, the vessels, for which the bones afford the anatomist invariable points of reference. Osteology has, therefore, ever since the time of the Alexandrian school, formed the commencement of the study of anatomy.

In the present day, the transcendental anatomists have particularly engaged in the study of the osseous system, doubtless on account of the facility with which it may be investigated; and from their labours, though in many respects speculative, a more accurate knowledge has been obtained of some of the nicer points of osteology, which had scarce attracted notice from the older anatomists.

Lastly, from the admirable researches of Cuvier respecting fossil animals, osteology has become one of the most important bases of comparative anatomy and geology. By the study of bones the anatomist has been enabled to determine genera and species, no longer existing on the face of the globe, and to give, as it were, new life to these old and disjointed relics of the antediluvian animal kingdom. Thus the fossil bones, deposited in an invariable order of superposition in the crust of the earth, have been transformed into monuments more authentic than historical records.

General View of the Skeleton.—The bones form a system or whole, of which the different parts are contiguous, and united to each other. The only exception to this rule is the *os hyoides*, and yet the ligaments by which it is connected with the rest of the system are evidently the representatives of the osseous pieces, which in the lower animals connect this bone with the temporal.

The assemblage of the bones constitutes the *skeleton*. It is called a *natural skeleton* when its different parts are connected by their own ligaments; an *artificial skeleton*, on the other hand, is one of which the bones are joined together by artificial connexions, such as metallic wires, &c.

The result of this union is a symmetrical and regular structure, essentially composed of a central column, denominated the *vertebral column or spine*, which terminates superiorly in a considerable enlargement, the *cranium*, and inferiorly in certain immovably united vertebræ, which constitute the *sacrum and coccyx*. To this column the following appendages are attached: 1. In front of and below the cranium, a complicated osseous structure, the *face*, divided into two maxillæ, the *superior* and *inferior*. 2. On each side twelve bony arches, flexible, elastic, and curved—the *ribs*, which are united in front to another column, the *sternum*. These parts, taken together, form the thorax. 3. Four prolongations, called *limbs* or *extremities:* two superior, or *thoracic*, as they are termed, because they correspond with the chest or thorax; and two inferior or *pelvic*, so named

on account of their connexion with the basin or *pelvis*, but better named *abdominal extremities*. The thoracic and abdominal extremities are evidently modifications of the same fundamental type, and are essentially composed of the same number of analogous parts, viz.: 1. An osseous girdle, the superior constituted by the bones of the shoulder, the inferior by the pelvis. 2. A part which may be in some measure regarded as the body of the limb, viz., the *humerus*, in the thoracic extremity, the *femur* in the abdominal. 3. A manubrium or handle, to use an expression of Galen, above the *forearm*, below the *leg*. 4. Lastly, digitated appendages which form the extremities, properly so called, viz., the *hand* and the *foot*.

Number of the Bones.—Authors do not agree respecting the number of the bones. Some, for instance, describe the sphenoid and the occipital as forming only one bone, while most anatomists consider them two distinct bones. Some admit three pieces in the sternum, which they describe separately. Many, after the example of the older writers, divide the haunch into three distinct bones—the pubes, the ischium, and the ileum: others recognise five pelvic or sacral vertebræ; three or five parts of the os hyoides; and, lastly, the ossa sesamoidea and the ossa wormiana are omitted by some, but by others are reckoned in the enumeration of the bones.

The ideas of certain modern authors with respect to the development of the bones, instead of dispelling the uncertainty which attaches to the enumeration of the parts of the skeleton, have tended not a little to increase the confusion, because many of them have made no distinction between bones, properly so called, and pieces of ossification. All doubt, however, in this respect will cease, provided we consider as distinct bones only those portions of the skeleton which are separable at the time of complete development.

The time at which the osseous system arrives at its perfect development is between the twenty-fifth and thirtieth year.

According to these views, we may count in the human body 198 bones, viz.:

Vertebral column, including the *sacrum* and *coccyx*	26
Cranium	8
Face	14
Os hyoides	1
Thorax (ribs, sternum)	25
Superior extremities, each 32, viz., shoulder, arm, forearm, and hand	64
Inferior extremities, each 30, viz., pelvis, thigh, leg, and foot	60
	198

This enumeration does not include the ossa wormiana, nor the ossa sesamoidea, among which we include the patella.

Of these 198 bones, 34 only are single: all the others are in pairs, which reduces the number to be studied to 116.

Before proceeding to examine each piece of the skeleton in particular, we shall state the method we intend to pursue in the description. The chief points embraced by detailed descriptions of a bone are, 1. Its name; 2. Its general situation; 3. Its direction; 4. Its bulk and weight; 5. Its figure; 6. Its regions; 7. Its relations; 8. Its internal conformation; 9. Its intimate texture; 10. Its development.

Nomenclature.—Osteological nomenclature has many imperfections. Persuaded of the importance of a suitable choice of language in the study of all the sciences, some anatomists have endeavoured to introduce reforms, but with little success, the old denominations being still for the most part retained. From these modern systems of nomenclature we shall adopt only such terms as are strikingly appropriate, or such as have already been sanctioned by usage. We may here observe that the denominations of bones have been derived, 1. From their situation; as the *frontal*, which is so called because it is situated in the forehead: 2. From a resemblance, usually very obscure, to some well-known object, as the bones named *tibia*, *scaphoid*, *malleus*, *incus*, *stapes*; or to some geometrical figure, as the *cuboid*: 3. From their size; as the *os magnum* of the carpus, and the small bones or *ossicula* of the ear: 4. From some circumstance of their external conformation; as the *cribriform* or *ethmoid* bone, the *unciform* or hooked bone: 5. From the name of the author who first most carefully described them; as the ossicles of *Bertin*, of *Morgagni*—wings of *Ingrassias*, &c.

General Situation of Bones.—The situation of a bone is determined by comparing the place which it occupies with that occupied by other bones of the skeleton. In order to make this comparison, the skeleton is supposed to be surrounded by certain planes, which are thus denominated: 1. *An anterior plane*, passing before the forehead, the breast, and the feet; 2. *A posterior plane*, passing behind the occiput and the heels; 3. *A superior plane*, placed horizontally above the head; 4. *An inferior plane*, which passes below the soles of the feet; 5 and 6. *The two lateral planes*, which complete the sort of case or parallelopiped with which we suppose the skeleton to be surrounded. Lastly, the skeleton being symmetrical, *i. e.*, exactly divisible into two similar halves, we admit a seventh imaginary plane, the median or antero-posterior, separating these two halves. By the term median line is understood an imaginary line traced so as to mark exteriorly the division of all the symmetrical bones of the skeleton into two similar halves.

These points being understood, nothing is more easy than to determine the position of a bone. If it approach nearer to the anterior plane than others with which it is compared, it is said to be anterior to them; if it be nearer the posterior plane, it is said to be posterior to them. Let us take, for example, the malar or cheek bones. With respect to the whole face, they are placed at the anterior, superior, and in some degree the lateral part; relatively to the neighbouring bones, they are situated, 1. Below the frontal; 2. Above and a little external to the maxillary; 3. Before the great wings of the sphenoid and the zygomatic process of the temporal.

Direction of Bones.—The direction of a bone is *absolute* or *relative*. The absolute direction is expressed by the terms *straight*, *curved*, *angular*, or *twisted*; in a word, it is the direction of a bone considered by itself, or independently of its situation in the skeleton. The long bones are never quite straight: sometimes they present a slight degree of curvature, as the femur; sometimes their extremities are curved in opposite directions, like the letter S, as the clavicle: sometimes, again, they are twisted upon their own axes, as the humerus, the fibula, &c.

The *relative* direction is determined by reference to the planes which circumscribe the skeleton. Viewed in this manner, a bone is *vertical*, *horizontal*, or *oblique*. It is needless to enter into any explanation of the terms vertical and horizontal; but with regard to the oblique direction, it may be stated that this is determined by the respective situations of its two extremities. For example, a bone is oblique when one extremity approximates the superior, the median, and the posterior planes, while the other approaches nearer to the inferior, lateral, and anterior planes; such a bone is said to be oblique from *above downward*, from *within outward*, and from *behind forward*. It is easy to see that in this way the situation of a bone relatively to the different planes may be determined with the greatest exactness. It should be observed, that in describing the direction of a bone, we should always set out from the same point. Thus, if the direction of a bone from above downward is spoken of in determining its obliquity from before backward, and from within outward, we should always commence with the superior extremity.

Size, Weight, and Density of Bones.—The size of a bone may be measured by the extent of its three dimensions; but as an exact estimate is not in general required, it is sufficient to indicate the volume of each bone relatively to others, whence has arisen the division of bones into *great*, *middle-sized*, and *small*; a distinction, however, altogether vague and futile, since from the largest to the smallest bones there is so regular a gradation that the limits assigned must be quite arbitrary.

The *weight*, or the mass of the skeleton compared with the rest of the body, the weight of each bone, and the comparative weight of different bones, are points of little interest; such, however, is not the case with the specific weight or density of bones.

In respect of *density*, viz., the number of molecules in a given volume, the bones are the heaviest of all organs. The truth of this assertion is by no means contradicted by the lightness of certain bones, which is only apparent, and which is caused by vacant spaces or cells in their substance. This density varies in different kinds of bones, in bones of the same kind, and even in different parts of the same bone. Thus, in the long bones, the greatest density is in the middle: the extremities of the long bones and the short bones have a much lower density. The broad or flat bones hold a middle place between the shaft of long bones and the short bones. Of these broad bones, those of the cranium are heavier than those of the pelvis. Age has a remarkable influence upon the specific weight of bones. It has been said that the bones of the aged are specifically more heavy than those of the adult, just as the bones of the adult are specifically heavier than those of the infant; and this assertion appears the more probable, from it being generally admitted, as a law of organization, that the phosphate of lime increases in bones with the progress of age; and it is well known that the weight of bones depends, in part, on the presence of this calcareous phosphate. But on this point, as on many others, experience has refuted these preconceived opinions. Thus, it is certain that the specific, as well as the absolute weight of bones, is much less considerable in the old person than in the adult; and this difference depends upon the loss of substance which the bones undergo, in common with all other tissues, during the progress of age: thus, in aged subjects, the walls of the cylinder of the long bones are remarkably diminished in thickness, while the medullary cavity is proportionally increased. We may even affirm, with Chaussier, that the medullary cavity of the shaft of long bones has a greater diameter, in proportion as the individual is advanced in age. In like manner, the cells of the spongy tissue become much larger, and their walls acquire an extreme tenuity. It may, nevertheless, be contended, that the weight of the osseous fibre, or, rather, of the osseous molecules of the old people, is greater, comparatively, than that of the same parts in the adult; and this presumption is almost converted into certainty by chemical analysis, which shows an excess of phosphate of lime in the bones of the aged: to remove all doubts upon this point, it would be necessary to grind an adult bone and an old one, and to weigh in the balance an equal bulk of each powder. In this way the contradictory statements of certain authors might be reconciled.

The increasing fragility of bones, and the consequent frequency of fractures in old age, are easily explained, since along with the accumulation of phosphate of lime, which diminishes the elasticity while it increases the brittleness, there occurs a diminution of bulk, and, consequently, there is less resistance. It is with respect to the quantity of calcareous phosphate alone that the osseous system can be said to preponderate in old age.

Shape of Bones.—The shape of a bone is determined, 1. By comparison either with different known objects, or with geometrical figures: thus the frontal bone has been compared to the scallop-shells of pilgrims, the sphenoid to a bat with extended wings, &c. It may be readily conceived that, notwithstanding its want of exactness, this method of comparison, so familiar to the ancients, cannot be altogether proscribed. The comparison of bones whose forms are so irregular with the regular solid figures of which geometry treats is no less inaccurate than the preceding; nevertheless, we shall continue, like other anatomists, to speak of the short bones as *cuboidal*, the shafts of long bones as being *prismatic* and *triangular*, the lower maxillæ *parabolic*, &c. We shall speak of spheres, of cones, of ovoids, of cylinders, &c.

2. The symmetry or want of symmetry of bones is a fundamental point in the determination of their figure: thus, some bones are divisible into two halves exactly resembling each other; these are the symmetrical or *azygos* bones, also called median, because they always occupy the middle line. The others can not be divided into two similar parts: these are the asymmetrical bones, called also *lateral* or *corresponding*, because they are always in pairs, and situated on opposite sides of the median line.

3. The figure of a bone comprehends, also, the proportion which its three dimensions bear to each other. When the three dimensions, length, breadth, and thickness, are nearly equal, the bone is said to be *short;* when the length and breadth are almost the same, and both greater than the thickness, the bone is called *broad* or *flat*. Lastly, the predominance of one dimension over the two others constitutes the character of *long* bones. The distinction here drawn, however, is not altogether exact, because there are certain mixed bones which partake at the same time of the character of the long and the broad bones.

Some general observations upon the three great classes will not be out of place here, as they will be applicable in the description of the individual bones.

General Characters of Long, Flat, and Short Bones.

Of Long Bones.—The long bones are situated in the extremities, in the centre of which they form a set of pillars or levers placed upon each other. The bones of the abdominal extremities are generally longer and larger than those of the thoracic. The longest bones are in the upper part of the limbs; it may be said, indeed, that the length of bones is in the direct ratio of their proximity to the trunk. The diameter of the long bones is smallest in their middle. From this part, as from a centre, they gradually increase in volume, and at their extremities are much enlarged, so as to present a diameter double or treble that of the shaft. Every long bone, therefore, presents a *biconical* form, *i. e.*, is shaped like two cones united by their summits.

A long bone consists of a *shaft* and *extremities*. The *shaft* of the long bones is almost always prismatic and triangular; so much so, that in this respect the bones seem to be an exception to the general rule of organized bodies, which have usually a rounded form, and to approach nearer that of the mineral kingdom, the characteristic shape of which is angular.

The *extremities* of long bones are enlarged, that they may serve, 1. For articulations; 2. For the insertion of ligaments and muscles; 3. For the reflection of tendons, the direction of which they alter. Each extremity presents a smooth articular surface, covered with cartilage in the fresh state, and not perforated by any foramina, and a non-articular portion, rough, pierced with apertures, and covered with eminences and depressions.

Of Broad or Flat Bones.—These bones, intended to form the parietes of cavities, are more or less curved, and present for consideration a circumference and two surfaces; the internal concave, the external convex. No single broad bone constitutes a cavity; there are always a certain number united for this purpose. Some broad bones are alternately concave and convex on the same surface, as the haunch bones. In flat or broad bones there is no accurate correspondence between the inequalities, ridges, or depressions of the two surfaces. Thus, the iliac portion of the haunch bones, instead of presenting a convexity on the inner surface, to correspond with the external iliac fossa, is hollowed out into another depression, the internal iliac fossa. In like manner, in the cranium certain impressions and eminences exist on the internal surface, while the external is uniformly convex, and almost smooth. The parietal, and even the occipital protuberances, would be twice or three times more prominent if the interior concavity were faithfully represented by a corresponding external prominence, and if this concavity were not in a great measure hollowed out from the substance of the bone.

The *circumference* of broad bones being intended either for articulations or for insertions, is for this purpose greatly thickened. Thus the parietal bones, which are very

thin at their centre, become considerably thicker at the circumference. The broad bones present at their circumference sometimes a simple enlargement, when it is intended for muscular insertions only; for example, the haunch bones: sometimes indentations of various kinds, and sinuosities, when it is to serve the purpose of articulation; for instance, the bones of the cranium.

Of Short Bones.—These are principally met with in the vertebral column, the carpus, and the tarsus; in fact, wherever great solidity is required in connexion with slight mobility: several of them are always grouped together; their form is extremely irregular, but generally cuboid; they have also numerous facettes for articulation. The non-articular portion is rough, for the insertion of ligaments and tendons.

Regions of Bones.—There are so many objects to be considered on the surface of a bone, that it is necessary, in order to prevent the omission of any essential detail in the description, to divide the surface into a certain number of parts or regions, which should be successively examined. These different parts or regions have been denominated *faces*, *borders*, and *angles*. Thus, in the prismatic and triangular shafts of long bones, there are *three faces* and *three borders* to be considered; in the flat bones, *two faces* and *a circumference*, which is again subdivided into *borders* and *angles* formed by the meeting of these borders. There are *six faces* in the short bones. These faces and borders are named sometimes, from their situation, *superior*, *inferior*, *anterior*, *posterior*, &c.; sometimes from the parts which they contribute to form, such as the *orbital* and *palatine* faces of the superior maxillary bone; sometimes from their relations to other parts, as the *cerebral* and *cutaneous* face of the bones of the cranium, the *frontal*, *occipital*, and *temporal* borders of the parietal bones. When the borders give insertion to a great number of muscles, it has been deemed advisable to divide these into three parts or parallel lines: the middle is then called the *interstice*, and the two lateral are named *lips*, the *internal* and *external* lip; the superior border of the haunch bone, and the linea aspera of the femur, are examples.

Eminences and Cavities of Bones.—The bones present certain eminences and cavities, of which it is proper to take a general survey in this place.

Eminences of Bones.—The osseous eminences or processes were divided by the ancients into two great classes, *apophyses* and *epiphyses*, distinguished by the difference of their mode of development. According to their view, some of these eminences arise from the body of the bone, appearing to be nothing more than prolongations or vegetations of its substance: these they called *apophyses*; others, on the contrary, are formed by separate osseous centres or nuclei, which make their appearance at various times during the process of the development of bone: to these they gave the name of *epiphyses*. This distinction, however, founded upon incomplete observation, has been totally rejected, since the researches of M. Serres on Osteogeny have rendered it evident that almost all the osseous eminences are developed from isolated nodules; so that an eminence, which at one time is an epiphysis, becomes afterward an apophysis. If, therefore, the majority of eminences are formed from separate osseous points, the difference between them can apply only to the relative periods at which they become united to the body of the bone.

A far more important distinction is that by which the eminences are divided into *articular* and *non-articular*.

The *articular eminences* have received different names. 1. They are called *denticulations* when they form angular eminences resembling the teeth of a saw; these are best seen in the bones of the cranium. This kind of eminence is employed only in immovable articulations.

The others belong to joints which admit of motion, and have received the following names: 1. They are called *heads* when they represent a portion of a sphere supported by a more contracted portion, to which the name of *neck* is given; for example, the head and neck of the femur. 2. The term *condyle* is applied to them when they resemble an elongated head, or a portion of an ovoid cut parallel to its greatest diameter; for example, the condyles of the inferior maxilla.

The *non-articular eminences* are, for the most part, designed for muscular insertions. Their appellations are in general derived from their shape. Thus, they are denominated,

1. *Prominences.* When they are but slightly elevated, smooth, and almost equally extended in all directions; as the parietal and frontal eminences.

2. *Mamillary Processes.* When they resemble papillæ; for instance, the mamillary processes of the internal surface of the bones of the cranium.

3. *Tuberosities.* When they are of a larger size, round, but uneven; for example, the occipital protuberance, the bicipital tuberosity (or tubercle) of the radius.

4. *Spines* or *Spinous Processes.* When, from their acuminated, but generally rugged form, they bear some resemblance to a thorn; as the spine of the tibia, the spinous processes of the vertebræ.

5. *Lines.* When their length greatly exceeds their breadth; as the semicircular lines of the occipital bone. When these lines are more prominent, and covered with asperities, they receive the name of lineæ asperæ; as the linea aspera of the femur.

6. *Crests.* When they are elevated, and have a sharp edge; as the external and internal crest of the occipital bone, the crest of the tibia. One of these eminences has been denominated the *crista galli*, because it bears some resemblance to the comb of a cock.

7. The term *apophyses* (or *processes*) has been retained for those eminences which are of a certain size, and appear to form, as it were, a little bone superadded to that from which they spring; they are distinguished, for the most part, by epithets derived from their shape. Thus, the *clinoid processes* of the sphenoid are so called from their supposed resemblance to the supporters of a bed (κλίνη, a bed; εἶδος, shape). *Pterygoid* processes are those which are like wings (πτέρυξ, a wing). *Mastoid*, such as resemble a nipple (μαστὸς, mamma). *Zygomatic*, such as have the form of a yoke (ζυγὸς, a yoke). *Styloid*, such as are like a style. *Coronoid*, such as are shaped like one of the angular projections of a diadem.* *Odontoid*, such as resemble a tooth; as the odontoid process of the second cervical vertebra. *Coracoid*, such as have the form of a raven's beak (κόραξ, a raven); as the *coracoid* process of the scapula. *Malleoli*, such as are like a hammer (*malleus*, a hammer).

Some processes have received names, 1. From the parts they contribute to form—orbitar processes, malar processes, olecranon (ὠλένη, the elbow; κράνον, head): 2. From their direction; as the *ascending* process of the superior maxilla: 3. From their uses; as the trochanters (τροχάω, to turn), because they serve for the insertion of muscles, which rotate the leg on its own axis.

No part of the language of osteology, perhaps, is more faulty than the nomenclature of the eminences. Thus, how unlike is the spine of the scapula to the spinous processes of the vertebræ, or the styloid process of the temporal to the diminutive projection called styloid of the radius! Many eminences which perform analogous offices have received different names: thus, the eminences of the humerus, which give attachment to its rotating muscles, are called the great and small tuberosities; while the corresponding parts of the femur have been denominated trochanters. While, therefore, we retain the names consecrated by usage, we shall be careful to point out the more rational terms substituted by modern anatomists, and particularly by Chaussier.

The size of the eminences of insertion is in general proportional to the number and strength of the muscles and ligaments which are attached to them. To be convinced of this fact, it is only necessary to compare the male and female skeleton, or that of a man of sedentary habits and that of a person devoted to athletic exercises. This remarkable correspondence between the size of osseous eminences and the strength of the muscles which are inserted into them, has given rise to the opinion that these eminences are formed by muscular traction. It is easy to refute this notion, and without entering into details which belong to general anatomy, we shall prove, by facts, that the osseous projections enter into the primordial plan of organization, so much so, that they would have doubtless existed, even though the muscles had never exercised any traction upon the bones. I have twice had occasion to dissect the thoracic extremities of individuals, who, in consequence of convulsions during their earliest infancy, had suffered complete paralysis of these parts. The limb affected had scarcely the proportions of that of a child of eight or nine years, while the opposite limb was perfectly developed. Nevertheless, in this atrophied limb, the smallest as well as the largest projections were perfectly marked. Moreover, very powerful muscles are often inserted into cavities, as, for instance, the pterygoid cavity of the sphenoid.

Cavities of Bones.—Besides the great cavities of the skeleton, cavities in the formation of which many bones concur, and which are destined to lodge and defend the organs most important to life, there are a great number of smaller excavations formed in the substance of the bone itself.

These cavities, like the eminences, are divided into two great classes, *articular* and *non-articular*. The *articular cavities* have received different names. 1. The term *cotyloid* designates the articular cavity in the haunch bone, because it is deep and round, like a vessel known by the ancients under the name of κοτύλη. 2. The name *glenoid* (from γλήνη) is applied to many articular cavities, which are more shallow; for example, the glenoid cavity of the scapula, the glenoid cavity of the temporal bone. 3. The term *alveoli* has been assigned to the cells or sockets in which the roots of the teeth are lodged. It is not correct, however, to consider as an articulation the union of the teeth with the jaws, because, as we shall afterward show, the teeth are not true bones.

The *non-articular cavities* are to be considered with reference both to their figure and their uses. From their figure, they have received the following denominations: 1. *Fossæ*, or pits, are cavities largely excavated, wider at the margin than at the bottom; *e. g.*, the parietal fossæ. 2. *Sinuses* are cavities with a narrow entrance; as the sphenoidal sinus, maxillary sinus, &c. 3. The term *cells* is applied when the cavities are small, but numerous, and communicating with each other; as the ethmoidal cells, &c. 4. *Channels* (*gutters*) are cavities which resemble an open semi-cylindrical canal; as the channels for the longitudinal and lateral sinuses of the scull. 5. These take the name of grooves

* [Also from κορώνη, a crow—like a crow's beak.]

(*coulisses*) when they are lined by a thin layer of cartilage, for the passage of tendons; as the bicipital groove of the humerus. The term *pulley* or *trochlea* is applied to grooves which have their two borders also covered with cartilage. 6. *Furrows* are superficial impressions, long, but very narrow, and intended for the lodgment of vessels or nerves, as the furrows for the middle meningeal artery. 7. When more deeply excavated than the last, and angular at the bottom, they are named by the French anatomists *Rainures*. 8. *A notch* (*incisura*) is a cavity cut in the edge of a bone.*

The cavities which we have described exist only on one surface of a bone; those which perforate its substance are usually denominated *foramina* or *holes*.

1. When a foramen has an irregular, and, as it were, lacerated orifice, it is named a *foramen lacerum*. 2. When its orifice is very small and irregular, it is called *hiatus*; when the opening is long, narrow, and resembling a crack or slit, it is denominated a fissure; as the sphenoidal fissure, the glenoid fissure, &c. 3. If the perforation runs some way through the substance of a bone, it is called a *conduit* or *canal*; as the Vidian canal, carotid canal, &c.

There are some canals which lodge the vessels intended for the nourishment of the bone: these are called *nutritious canals*. They are divided into three kinds.

The first, which belong exclusively to the shafts of long bones, and to some broad bones, penetrate the substance of the bone very obliquely. These are the *nutritious canals properly so called*. Anatomists carefully point out their situation, size, and direction, in describing each bone.

The second kind are seen on the extremities of long bones, on the borders, or adjoining the borders, of broad bones. Canals of this kind are generally near the articular surfaces. Their number is always considerable. Bichat has counted 140 on the lower end of the thigh bone, twenty upon a vertebra, and fifty upon the os calcis.

The third kind of nutritious canals are exceedingly small, and might be denominated the *capillary canals of bones*. They are found in great numbers on the surfaces of all bones. They may be easily seen by the aid of a good magnifying glass; their presence is also indicated by the drops of blood which appear upon the surface of a bone on tearing off the periosteum; for example, on the internal surface of the cranium, after separating the dura mater. The diameter of these little canals has been calculated to be about the 1-20th of a line.

The farther progress of the above-mentioned canals is as follows: those of the first kind, which belong to the long bones, soon divide into two secondary canals, one ascending, the other descending, and communicating with the central or medullary cavity. Those which are situated in the broad bones form winding passages, which run for a considerable distance in the substance of the bone.

The canals of the second kind sometimes pass completely through the bone (as in the bodies of the vertebræ), and they communicate with the spongy tissue. The canals of the third kind terminate at a greater or less depth, in the compact substance of the long bones, and in the spongy tissue of the short bones. Such are the forms and general arrangement of all the cavities which exist on the surface of the bone; the following are their uses: 1. They serve for the reception and protection of certain organs; ex., the occipital fossæ, which receive a portion of the cerebellum. 2. For insertion or surfaces of attachment, as those on which muscular fibres are implanted, as the temporal and pterygoid fossæ. 3. For the transmission of certain organs, such as vessels and nerves which have to pass into or out of an osseous cavity; such are the fissures, canals, foramina, &c. 4. For increasing the extent of surface; as the sinuses and cells connected with the organ of smelling, the surface of which they greatly enlarge by their numerous anfractuosities.† 5. For the easy passage of tendons, and sometimes for their reflection, so that the original direction of the force is changed. To this class belong the bicipital groove of the humerus, that for the tendon of the obturator internus, &c. They are generally converted into canals by means of fibrous tissue, which lines and completes them. 6. For the nutrition of bones, such being the use of the three orders of nutritious canals already described. We must mention, along with these osseous cavities, other markings or impressions seen on the surface of many bones; for example, the shallow depressions in the lower jaw bone for the sub-lingual and sub-maxillary glands, the impressions named digital on the internal surface of the cranium.

As the eminences of bones have been attributed to the mechanical effect of muscular traction, so the various impressions and vascular furrows upon the internal surface of the cranium have been considered to be the result of pressure and pulsation; but it would be more correct to limit ourselves to the simple statement, that the impressions and eminences on the inside of the cranial bones exactly correspond with the elevations and depressions on the surface of the brain, and also that the osseous furrows for the middle meningeal artery correctly represent the ramifications of that vessel.

* [There is great latitude among anatomical writers in the use of these terms.]

† [Whatever other purpose they may serve, such cells and sinuses are, in most instances, to be regarded as a provision for increasing the bulk and strength of bones without a corresponding augmentation of weight.]

We may here point out certain rules to be followed in describing the external conformation of bones. 1. In describing the surface of a bone, it should be so divided that the description may comprehend but few objects at a time. Thus, a broad bone is to be divided into two surfaces, into angles and borders, which are to be successively studied. 2. The bone being thus subdivided into regions, each of these is then examined, care being taken regularly to proceed from one part to its opposite, *i. e.*, to pass from the superior to the inferior surface, and from the anterior to the posterior. This is the only method which, in a long description, will guard against omissions and avoid tiresome repetitions. 3. It is also of great importance, in considering the objects presented by each region or surface, to follow an invariable and regularly progressive order. Thus, after exposing the objects placed in front, the examination should be continued uninterruptedly from this point backward. 4. In the symmetrical bones, it is advisable to describe, first, the objects situated in the median line, and afterward those placed laterally.

Internal Conformation of Bones.—The tissue of bones, like that of most other organs, presents the appearance of fibres, whose properties are throughout identical, but which, by certain differences in their mode of arrangement, give rise to two forms or modifications of structure. To one of these the name of *compact substance* has been given; to the other, that of *spongy or cancellated substance.* A subordinate modification of the latter has long been described under the name of *reticular tissue.*

The spongy or cellular substance has the appearance of cells and areolæ, of an irregular shape and variable size, all of which communicate with each other, and their walls are partly fibrous, partly lamellar. The compact substance seems to consist of fibres strongly compressed, so as to form a close, firm tissue. It is both fibrous and areolar. By means of careful inspection, softening the bone in nitric acid, and studying its development, it has been clearly proved that it is *fibrous*, and that in long bones the fibres are arranged longitudinally, while in broad bones they seem to diverge like rays from the centre to every part of the circumference; and that in the short bones they are disposed irregularly, so as to form a superficial layer or crust. The researches of Malpighi have conclusively shown that it is also *areolar* or *spongy.* By examining a bone softened by nitric acid, or studying it in the fœtal state, it may be seen that, in fact, the compact tissue is nothing more than an areolar substance, the meshes of which are extremely close and much elongated. Accidental ossifications, and the diseases of bone which so frequently exhibit the compact tissue converted into spongy, and the spongy changed into compact, complete the demonstration.*

In strictness, therefore, but one form of osseous tissue can be admitted, namely, the areolar, which presents itself under two aspects, sometimes being close, compact, and fasciculated; sometimes spongy and cellular. Having thus become acquainted with these two forms of osseous tissue, their general arrangement in the different kinds of bones is next to be examined.

Internal Structure of Long Bones.—A vertical section of a long bone presents, in the body or shaft, a cylindrical cavity, which, in the fresh state, is filled with a soft, fatty substance, named the *marrow.* This cavity, or *medullary canal*, is of greatest diameter at the middle of the shaft; and, as it recedes from this point, it is narrowed and intersected at various parts by lamellæ detached from the sides, and forming a sort of incomplete partitions. Sometimes, however, there is a complete partition; thus, I have seen the cylinder of a femur divided into two distinct halves by a horizontal partition situated precisely in the middle of the bone. The medullary canal is not regularly cylindrical, nor does it correspond in figure with the external surface of the bone. It communicates with the exterior by means of the nutritious canals, which sometimes run, for a considerable distance in the substance of the bone, parallel to the medullary cavity, with which they communicate by numerous apertures, and transmit the vessels as far as the extremities of the bone. Some have supposed that the cavity existed only in order to receive the marrow, while, on the other hand, it has been maintained that the marrow existed only to fill up the cavity. Whatever be the uses of the marrow, it is certain that the existence of a cavity in the centre of long bones is an advantageous provision for strength; for it is proved in physics, that, of two cylinders, composed of the same material in equal quantity, the one which is hollow, and whose diameters are, consequently, greater, will offer greater resistance than that which is solid. By the contrivance, therefore, of the medullary canal, there is an increase of strength without aug-

* [The description in the text applies to the more obvious structure of bone; but, when examined with the microscope, the osseous substance, both compact and spongy, is seen to consist of exceedingly fine lamellæ laid on one another. In the compact external crust of bones, these lamellæ run parallel with the surface; they also surround, concentrically, the small cavities of the compact substance and the cells of the spongy texture, the parietes of which they form. They are not to be confounded with the coarser layers and plates described in the compact substance by Gagliardi, Monro, and others of the older writers. Along with the lamellæ there are minute, opaque, white bodies, with extremely fine lines irregularly branching out from them. These bodies, which can be seen only with the aid of the microscope, are named the osseous corpuscules; they obviously contain calcareous matter, and are, probably, minute ramified cavities lined with earthy salts. The earthy matter of bone, however, is not confined to the corpuscules, for the intermediate substance is also impregnated with it. For a representation of the minute structure of bone, see *Müller's Physiology*, translated by Baly, plate 1.]

mentation of weight. There is another advantage in this arrangement, viz., the increase of volume without corresponding increase of weight; for, since the bones are intended to give insertion to numerous muscles, it is necessary that their surfaces should not be reduced to too small dimensions; but this must have been the result had the walls of the hollow cylinder been compressed so as to form a solid rod. The marrow consists of two distinct parts: 1. The medullary membrane, which lines the walls of the canal. 2. The fatty tissue, properly so called, or the medullary liquid.

The membrane, highly vascular, serves to nourish the internal layers of the bone: it possesses great sensibility and a high degree of vitality. The fatty tissue, on the contrary, is altogether insensible. If a probe be introduced into the centre of the medulla of a long bone in a living animal, no sign of pain is evinced *so long as the instrument does not touch the walls of the cavity*; but whenever the walls are rubbed or scratched, the pain becomes excessive, and is manifested by piercing cries and violent struggles.

The proportion between the thickness of the walls of the cylinder and the diameter of the medullary canal varies not only in different individuals, but in the same person at different periods of life. In the aged, the thickness of the walls is proportionally much less than in the adult: this is one cause of the great fragility of the bones in old age. Sometimes in the adult the walls are so thin, that the bone breaks by the slightest force: in such cases, there is in some sort hypertrophy of the medulla and atrophy of the bone. It is in such cases that fractures occur from the simple effect of muscular contraction, or even from moving in bed.

It is in the central canal of long bones that those very delicate osseous filaments are observed, which, interlacing with each other, and forming large meshes, give rise to that variety of spongy tissue which has received the name of *reticular*, and which appears intended to give support to the medulla. The compact tissue diminishes, and the cells increase in number, the greater the distance from the centre of the bone, so that the extremities are entirely composed of spongy substance covered by a thin layer of compact tissue. It appears that the compact tissue which forms the shafts of the bones divides and subdivides into lamellæ, in order to form the cells of the extremities. It is easy to perceive the advantage of a spongy structure in the usually voluminous extremities of the long bones: they could not have been compact without a great increase of weight, while the additional strength thus acquired would have been redundant, and altogether useless.

The cells of the spongy substance are filled by an adipose tissue, similar to that which exists in the bodies of long bones: from its greater fluidity, it has been denominated *medullary juice*.

Internal Structure of Broad Bones.—If the surface of a broad bone be scraped, or if the bone be sawn across perpendicularly or obliquely, it will be found to consist of two *lamellæ* or *tables*, separated by a greater or less thickness of spongy tissue. Hence the two plates are insulated, and one may be fissured or broken without injury to the other. The thickness of the compact laminæ and of the spongy tissue is not uniform throughout the whole extent of a broad bone. At the centre, for example, there is scarcely any spongy tissue, and hence the transparency of the bone at this part. Towards the circumference, on the contrary, the spongy tissue forms a very thick layer.

In the bones which form the vault of the cranium, the spongy substance takes the name of *diploë* (διπλόος, double), because it occupies the interval between the two tables.

From what has been said regarding the internal structure of broad bones, it is evident that their distinctive character depends as much upon their internal as their external conformation, and therefore the ribs, which, according to their external characters, seem rather to belong to the long bones, have been classed among the broad, because they exhibit in their internal structure the characters of the latter kind of bones.

Internal Structure of Short Bones.—The extremity of a long bone, if separated from the shaft, would represent a short bone, both in its external and internal conformation; for a short bone is a spongy mass, covered by a thin layer of compact tissue. To their spongy structure the short bones, as well as the extremities of the long, owe their specific lightness.

It should be observed, that what has been said concerning the internal structure of bones applies, in strictness, only to those of the adult, because the younger the subject, the less are the cells of the spongy tissue developed. And, in like manner, as the walls of the cylinder of long bones diminish in thickness, and the medullary cavity increases in diameter in the aged, so by the progress of age the walls of the cells become extremely thin, and the cells themselves very large. In some cases of disease, for example, after white swelling of the ankle-joint, I have observed true medullary canals in the cuboid bone and calcaneum; and I have remarked in one case of cancer of the breast, that the ribs adjoining the tumour were hollowed out by a sort of medullary canal. It is to this diminution of the osseous substance, this kind of atrophy of the bone, that I am disposed to attribute the fragility so often observed in the whole osseous system in cancerous diseases.

Chemical Composition of Bones.—The bony tissue consists essentially of two distinct elements, one *inorganic*, the other *organized*. When a bone is subjected to the action of dilute nitric acid, the salts are removed; it becomes flexible and elastic like cartilage, and though retaining its original bulk and form, it is found to have lost a great part of

its weight. By this process its saline ingredients have been dissolved, and nothing remains but its organic constituents, which, being subjected to boiling, present all the characters of gelatine.

On the other hand, if a bone be calcined, the whole of its organic matter is destroyed, giving out during the process the odour of burned horn. A substance remains which preserves exactly the shape and size of the original bone, but at the same time is very light, porous, and so friable that it crumbles to powder under the slightest pressure. If the calcination be complete, the bone is rendered perfectly white, but it is black when the burning has not been carried sufficiently far; it may even be vitrified by a more intense heat applied for a longer time. Prolonged exposure to the action of air and moisture in like manner remove the organized substance, and leave only a calcareous residue. The two elements of bone do not bear the same proportion at different ages. Certain diseases greatly affect the predominance of one or the other, producing almost the same effects as chemical agents.

To the inorganic matter the bones owe their hardness and durability; to the organized substance they are indebted for their vitality and the slight degree of flexibility and elasticity which they possess.

The following are the results furnished by the chemical analysis of M. Berzelius:

1. Organized Part	1. Animal matter reduced to gelatine by boiling	32·17
	2. Insoluble animal matter	1·13
2. Inorganic Part	Phosphate of lime	51·04
	Carbonate of lime	11·30
	Fluate of lime	2·0
	Phosphate of magnesia	1·16
	Soda and chloride of sodium	1·20

The bones are furnished with vessels: by one set arterial blood is transmitted, by another venous blood is returned.

1. The *arteries* are of three orders, corresponding with the osseous canals, which have been described in speaking of the cavities of bones.

First Order, or *Arteries of the Medullary Canal of Long Bones*.—In each medullary canal there is at least one principal artery which enters by the nutritious canal and divides almost immediately into two branches, one ascending, the other descending. These subdivide into an infinite number of small branches, the interlacements of which form that vascular network called the medullary membrane. With this network the vessels of the second order freely anastomose after their entrance at the extremities of the bone. In consequence of this important communication, the vessels, notwithstanding the great difference in the manner of their entering the bone, can reciprocally supply each other with blood. In illustration of this, Bichat relates a singular case, in which the nutritious foramen of a tibia was completely obliterated, and yet the nutrition of the bone was unimpaired. The medullary artery gives off the twigs for those layers of compact tissue which form the parietes of the medullary cavity.

The arteries of the second order, destined for the spongy tissue, enter the bones by the nutritious foramina of the second order; but their number by no means corresponds with that of the foramina, which are for the most part destined for the transmission of veins. These arteries communicate both with the medullary artery already mentioned and with the arteries of the periosteum.

The arteries of the third order, or the *periosteal arteries*, are exceedingly numerous. This class comprehends the innumerable little arteries which, after ramifying in the periosteum, enter the bone by the minute canals of the third order. These small vessels, specially distributed to the exterior layers of compact substance, anastomose with the two preceding orders of vessels.

2. The *veins* of bones follow the course of the arteries. But there are peculiar venous canals in the interior of the broad and the short bones, and in the spongy extremities of the long bones. These canals were first described by M. Dupuytren in the cranial bones, where they are very obvious: they are perforated with lateral openings, by which they receive blood from the adjoining parts; their parietes are formed by a very thin plate of compact tissue, and they are lined by a prolongation of the internal membrane of the veins. We shall afterward see that there is a complete analogy between these venous canals and the sinuses of the dura mater, the only difference being in the nature of their parietes, which are fibrous in the sinuses, but bony in the canals in question. I have remarked, that in the fœtus and new-born infants, the cells of the spongy tissue, which subsequently contain adipose matter, are filled with venous blood.

Lymphatic vessels have not yet been actually demonstrated in the bony tissue; but it is probable that they really exist there; at least, the process of nutrition in bones, and certain morbid phenomena which they present, lead to the belief of their existence.

The *cellular tissue* also enters into the composition of the bones: it contributes to form their fibrous structure.

Nerves can be demonstrated in connexion with most of the bones of the skeleton. But it is necessary to distinguish those nerves which merely pass through the bones from those which are distributed on their substance.

Development of Bones, or Osteogeny.

From the time of their first appearance in the fœtus, to the period of their complete development, the bones pass through a series of changes, which constitute one of the most important circumstances in their history. The investigation of these changes, or of the successive periods of development, is the object of *osteogeny*.

The development of the bones, considered generally, presents three phases or periods, designated by the name *mucous*, *cartilaginous*, and *osseous stage*.

1. The *mucous stage*. The mucous condition, the cellular of some authors, has not been well defined. Some apply the term to that period of formation in which the bones and the other organs of the body form but one homogeneous mass of a mucous aspect: others use the term to signify a more advanced stage, in which the bones, acquiring a greater consistence than the surrounding parts, begin to show their development through these more transparent tissues. In the latter sense, the mucous stage is obviously nothing but the commencement of the cartilaginous, and therefore the first acceptation is the only one to be retained.

2. The *cartilaginous stage* succeeds the mucous, though the time of the transition from the one to the other has not been precisely ascertained. Several anatomists are of opinion, with Mr. Howship, that the cartilaginous state does not necessarily intervene between the mucous and osseous conditions; that its occurrence is only satisfactorily demonstrated in such bones as are late in ossifying, and that it constitutes a sort of provisional condition, in which the cartilage is employed to perform the office of bone. But when we take into consideration, in the first place, the rapid transition from the cartilaginous to the osseous stage in certain bones, and, secondly, the translucency of newly-formed cartilage when of inconsiderable thickness, as in the cranium, where the cartilage is scarcely to be distinguished from the two membranes between which it is placed, we can conceive that the cartilaginous stage may easily have been overlooked. On the other hand, the constant result of my observations proves that, in the natural process of ossification, every bone passes through the state of cartilage.

When the different pieces of the skeleton assume the cartilaginous condition, the change occurs throughout their whole substance at once. The notion of central points of cartilaginification, corresponding with the points of ossification, is purely hypothetical: a bone becomes cartilaginous in all parts simultaneously, and never by insulated points. The cartilage has the same figure as the future bone.

Bones which are to be permanently united by intermediate cartilage, are formed from one primitive piece of cartilage, as those of the cranium and face: those, on the other hand, which are connected together only by ligaments, are distinct and separable while in the cartilaginous state.

3. The *osseous stage*. The cartilaginous condition of the skeleton is completed by the end of the second month;* but ossification commences in several places long before this period. The first point of ossification appears after the fourth week in the clavicle; the second, in the lower jaw. From the thirty-fifth to the fortieth day points of ossification appear sometimes successively, in other cases simultaneously, in the thigh-bone, the humerus, the tibia, and upper jaw-bone. From the fortieth to the fifty-fifth day, points of ossification appear at short intervals in the annular portion of the uppermost vertebræ, in the bodies of the dorsal vertebræ, in the ribs, the tabular bones of the scull, the fibula, the scapula, the ilium, the nasal, palatine, and metacarpal bones, the phalanges of the fingers and toes, the metatarsus, &c. Once commenced, the ossification proceeds with more or less rapidity in the different bones during the remainder of intra-uterine life.

In the child at birth, the shafts of the long, as well as the broad bones, are far advanced in development. As to the short bones, the vertebræ are scarcely less early in their evolution than the long and broad bones; the calcaneum, cuboid, and sometimes the astragalus, have points of ossification, but only commencing. The extremities of the long bones, with a single exception, the lower end of the femur, are as yet without ossifying points. The remaining short bones and extremities of long bones ossify subsequently. Of the tarsal bones, the scaphoid is the last to ossify; the pisiform is the latest among the carpal bones; the patella is ossified at the age of three years.

In regard to the process of ossification, a question of the highest interest presents itself, viz., *Is the successive appearance of the centres of ossification governed by any general law?*

The order of commencement of the points of ossification is in no way dependant on the size of the bones. It is true that the smaller bones, excepting the ossicles of the ear, are later in appearing; but, at the same time, it is not the largest bones that are the earliest; thus, the bones of the pelvis appear long after the clavicle.

* [The relative time of ossification of the different bones, or, at least, the order in which it commences in them, is easily determined; but owing to the uncertainty respecting the age of the embryo in its early stages, the absolute time of fœtal life at which each bone begins to ossify is very uncertain, and, accordingly, the statements of many anatomists differ from that given in the text: thus the seventh week is assigned by some as the period when ossification commences in the clavicle. The age fixed by the author appears too early.]

Proximity to the heart or great vessels has no effect on the precocity of development. Though the ribs which are near the heart ossify speedily, the breast-bone, on the other hand, which is still nearer, is one of the bones latest in ossifying. Again, the anterior and inferior angle of the parietal, which is close to the anterior branch of the middle meningeal artery, is the part of the bone which last ossifies. The femoral artery lies on the confines of the os pubis and ilium, which at that part long remain cartilaginous.

The true law which governs the order of appearance of the points of ossification is this, viz., that the period of formation is earlier or later in the several bones according to the period at which they are required to fulfil their office in the economy. Thus, the jaws being required to act immediately after birth, are ossified before the other bones of the head. In the same way, the ribs, destined for a function which must commence from the moment of birth, are for this purpose completely ossified: the vertebræ and bones of the cranium appear early, because of their use as protecting the spinal cord and brain; and it is thus that the pretended correspondence between the rapidity of ossification and proximity to the nervous centres is explained.

Although several of the bones are completed solely by an extension of the primitive nuclei of ossification, the greater number acquire, in addition to these principal or essential pieces, complementary points of ossification named *epiphyses*. Thus, while in the frontal the two original points of ossification suffice by their extension for the completion of the bone, the vertebræ, on the other hand, have three primary osseous nuclei, one for the body, and two for the laminæ and processes; and five complementary pieces of ossification, namely, two for the body, and one each for the tips of the spinous and transverse processes.

The *transition from the state of cartilage to bone* is attended with the following phenomena: the cartilage becomes more dense; its colour is at first a dull white, but subsequently changes to deep yellow; small irregular cavities are formed in its substance; red vessels show themselves; a bony point appears in the midst of these vessels, and this bony nucleus is spongy and penetrated with blood. The ossification spreads by little and little, always preceded by a great development of vessels; so that, in attentively examining an ossifying cartilage, we find first an osseous point, then a red zone, next an opaque layer of cartilage which is permeated by canals, and, lastly, the remaining cartilage traversed only by a few vascular canals which run towards the point of ossification. Moreover, it is always at some depth within the substance of the cartilage that the first osseous points appear, and never at the surface. It is only in cases of accidental or diseased ossification, as in the cartilages of the ribs, that it occasionally begins at the surface. It is unnecessary to pursue farther the immediate process of ossification: nor need we here discuss the purely speculative question, whether the bone is really a new part essentially distinct from the cartilage, which is absorbed and gives place to it, or merely a deposite of earthy phosphate in a cartilaginous tissue.

In admitting that ossification is always preceded and accompanied by a great development of vessels, a fact proved incontestably by Haller and Bichat, I must, nevertheless, decidedly dissent from the opinion that the appearance of blood in a cartilage is a constant indication of approaching ossification; for several cartilages have naturally bloodvessels, as may be seen in the cartilages of the ribs and larynx.

The study of the development of the bones does not consist merely in determining the number and time of appearance of their points of ossification: it comprehends, also, the ulterior changes which take place in the osseous system, viz., *the union of the primitive points of ossification, and the appearance and junction of the complementary points of ossification*. It is to be remarked, that the order of development and union of the points of ossification does not always correspond with that in which they originally appear; nay, it is often the reverse. Thus, the lower epiphysis of the femur is the earliest in appearing, and it is the last in joining; while, on the other hand, the upper end of the radius is one of the latest of the epiphyses in appearing, but is joined to the bone before all, or nearly all, the rest. The junction of the pieces of ossification is not complete till about the age of twenty-five years, at which time the lower epiphysis of the femur unites with the body of the bone.

General Mode of Ossification of Eminences and Cavities.—M. Serres, in a very remarkable work, has given, under the title of *General Laws of Osteogeny*, the results of his observations concerning the development of azygos or median bones, and of eminences and cavities; and with a rapid notice of these, we shall conclude what is to be said on the points of ossification.

1. By the *law of symmetry*, which, according to M. Serres, governs the development of all bones situated on the median line, every such bone is originally double, that is, composed of two separate halves, which, advancing to meet each other, are at last joined. Thus there are originally two osseous halves of the spinal column, and two demisterna. The basilar portion of the occipital, the body of the sphenoid, the cribriform plate of the ethmoid, the vomer, and the spinous processes of the vertebræ, have, according to this view, originally been double. But this law has many exceptions. Thus, although some of the pieces of the sternum are commonly formed from two lateral

points, the first and the last are always, or almost always, developed from a single point in their middle. The bodies of the vertebræ are most commonly formed from a single primitive nucleus: the same is the case with the basilar portion of the occipital, the perpendicular plate of the ethmoid, the vomer, and the spinous processes of the vertebræ. Instances of incomplete division of bones on the median line must not be adduced in proof of the existence of two primitive points of ossification.

2. Every eminence, according to M. Serres, is developed by a special point of ossification. This is true generally: but how many eminences are formed merely by the extension of ossification from the piece which supports them! Where, it may be asked, is the special point of ossification for the articular processes of the vertebræ, the coronoid process of the ulna, the external and internal protuberances of the occipital, &c.? There are even double eminences developed from a single point, as the condyles of the femur.

3. Every cavity is formed by the union of at least two pieces of ossification; so that, when a bone furnished with a cavity consists of several pieces, the place of junction of these pieces is at the cavity. Thus, the three pieces of the os innominatum meet together at the cotyloid cavity. The same law, according to M. Serres, regulates the formation of the foramina and osseous canals of every kind, as the medullary cavity of the long bones, all the canals for vessels and nerves, as the carotid, vidian, &c.: according to the same law, all the foramina in the bones of the scull are formed originally of two halves. But the facts are opposed to this doctrine when applied so universally.

Progress of Ossification in the three Kinds of Bones.—1. *In the long bones.* Ossification commences in their middle part. A small cylinder of bone appears, narrow in the middle, expanded at the ends, tubular within, perforated already with the nutritious foramen, which is very obvious, and receives very large vessels. This little cylinder grows gradually thicker and longer, extending towards the extremities of the bone, which it reaches about the time of birth; while at this period the ossification is so far advanced in the body of the long bones, their extremities are not yet osseous. It is only at later periods, varying in different bones, that an osseous nucleus appears in the cartilaginous extremities, increasing and encroaching upon the portion of cartilage which separates it from the bony shaft, until that cartilaginous partition, gradually becoming thinner, is at last itself invaded by the ossification. All the long bones have two essential or principal epiphyses, to which complementary epiphyses are sometimes added. The phalanges* are an exception; they have only one. It is this process which is named junction of the epiphyses. The time of its completion is not confined to any very definite limits, but it is over by twenty or twenty-five years.

Throughout the whole time of development the growth in length takes place, chiefly by ossification of the intermediate cartilage, which separates the epiphyses from the shaft, but partly, also, by longitudinal expansion of the ossified shaft itself. The former mode of increase has been satisfactorily established by Hunter; the latter is proved by the following experiment of Duhamel: Three needles being fixed in the shaft of a long bone of a bird, at measured distances, it is found that after a certain time they become farther separated, which proves that the osseous cylinder has undergone an elongation.

2. *In the broad bones.* 1. Among the broad bones, those which are symmetrical often commence by two points placed one on each side of the median line. 2. The asymmetrical bones are developed sometimes from a single point of ossification, as the parietal; sometimes by several, as the temporal.

One of the most remarkable circumstances in the development of broad bones is the sort of radiation by which the deposition of calcareous phosphate extends, which spreads from the centre where the first osseous point was deposited, and advances by divergent rays to all points of the circumference, forming bony striæ separated by intervals, which are soon filled up by new osseous rays. As these rays are of unequal length, and are separated at the circumference by intervals of greater or less extent, it follows that a broad bone in the process of ossification must have at its circumference a scalloped or jagged border, like the toothed edge of a comb. It is this form of ossification which gives rise to the serratures of the sutures.

The broad bones are proportionally much thinner in the early periods of ossification than subsequently, because at first the spongy texture is scarcely developed. At the time of birth, the primary pieces of ossification not having united except in very few places, and the ossification which spreads from the centre of the bones not having yet reached the limits of their circumference, it follows that the constituent parts of bones, and the edges of different bones which are destined in the end to meet together, are at this period separated by cartilaginous, and, in some measure, membranous intervals, which in the cranium constitute the fontanelles. After birth, ossification spreads more and more in the broad bones; at the same time they increase in hardness and thickness, appearing as if to separate into two plates or tables, the interval between which becomes filled with spongy tissue.

The epiphysary or complementary points of ossification of some of the broad bones

* [Also the clavicle, the metatarsal, and usually the metacarpal bones.]

represent, in a certain degree, the epiphyses of the long bones. They occupy the circumference, and are thence named *marginal epiphyses*. Thus, in the cartilaginous border of the haunch-bone, which represents the crest of the ilium, a point of ossification commences, and extending along its whole length, forms a marginal epiphysis, which subsequently joins the rest of the bone, and in this respect is perfectly analogous to the epiphyses at the extremities of the long bones. The epiphyses, then, are not an exclusive attribute of the long bones, as Bichat maintained. They are found, also, in some of the short bones. But it would be indulging in a false analogy to class the Wormian bones, formed during the development of the cranium, with the epiphyses of the long and the broad bones; for they have peculiarities which are never found in true epiphyses. Thus, 1. They are not joined by osseous union, as is the case with epiphyses, but always by suture. 2. There is no constancy in their time of appearance, nor in their figure, which is irregular, nor in their size, which is, in general, greater the earlier they have appeared, because they have then had longer time to extend themselves before meeting the neighbouring bones.

From what has been said, we conclude that the broad bones have a twofold mode of increase in breadth, namely, the successive addition of bony substance to their borders, and the formation of marginal epiphyses. In every broad bone which is formed from several pieces, and which has on its surface a part for articulation, this last becomes the centre in which the different pieces meet, and are ultimately joined when the ossification is completed.

3. *In the short bones.* These are the latest in being ossified; a great number of them are still cartilaginous at birth. The short bones are not destitute of epiphyses, as is proved by the ossification of the vertebræ and calcaneum. Their ossification, in fine, presents the same phases, and follows the same progress, as that of the extremities of the long bones, which they resemble in so many respects.

Changes which take place in Bones after Maturity.

To obtain a complete notion of the development of the bones, we must not rest satisfied with ascertaining the number of points of ossification, their successive appearance, and their mode of junction; we must also study the changes which they undergo after they have attained their full growth.

The increase of the bones in height terminates when their several pieces have become united: the time when this is accomplished varies from the age of twenty to thirty years; but they continue to increase in thickness for a considerable time longer. In proof of this, we need only compare the bones of a young man with those of an adult of forty. In old age the bones still undergo important changes: the medullary canal of the long bones augments in width, and the thickness of its parietes diminishes in proportion; and something similar takes place in the broad and the short bones.

Another important fact to be here mentioned is, that the relative proportion of calcareous phosphate and animal matter undergoes continual changes in the course of life. Thus, by an analysis of Dr. I. Davy, it was shown that the proportion of calcareous phosphate was a fifth less in a child of fifteen years than in the adult. The same chemist found that the proportion of phosphate of lime in an adult occipital was to that in an occipital bone of an aged person as sixty-four to sixty-nine.

Nutrition of Bones.

The fact of the nutrition of bones, and the process of composition and decomposition in which it consists, appear to me to be demonstrated by the experiment with madder. If an animal is fed for some time with food impregnated with the juice of madder, its bones soon become coloured red, as may be ascertained by amputating a limb; but, by suspending the use of that substance for some time, the bones recover their natural colour. In this experiment, there is no doubt that the calcareous phosphate is the vehicle of the colouring matter, for the bones are the only parts that become coloured; all that is cartilaginous remains free from colour. We may infer from this that a twofold movement continually goes on in bones, by which new molecules are first deposited and then removed, after they have for a longer or shorter period formed part of these organs.*

The administration of madder, moreover, demonstrates a fact, which was proved by Duhamel du Monceau in a very curious set of experiments, namely, that the growth of bones takes place by the successive deposition of new layers, formed by the undermost or contiguous layers of the periosteum. Thus, let a pigeon be fed with food impregnated with madder, suspend the use of the madder for a time, then renew it; after this, the bones, when cut through, exhibit a red layer next their surface, then a white layer, then a red layer again.

Thus the bones grow in two ways, namely, by the interstitial mode of growth, or by intussusception, which they have in common with the other tissues; and, secondly, by juxtaposition.

* A somewhat subtle objection would be the following: May not the colouring matter be deposited and again carried off without the particles of phosphate of lime being necessarily subject to the same vicissitudes?

THE VERTEBRAL COLUMN.

General Characters of the Vertebræ.—Characters peculiar to the Vertebræ of each Region.—Characters proper to certain Vertebræ.—Vertebræ of the Sacro-Coccygeal Region.—The Vertebral Column in general.—Development.

Fig. 1.

The *vertebral column* (from the Latin word *vertere*, to turn, because the body turns round this as an axis), *spine*, or *rachis*, is that long, flexible, hollow, bony stem, the principal lever of the body, which affords support to almost the entire skeleton, and, at the same time, shields and protects the spinal marrow. It is situated at the posterior and median portion of the trunk, extending from the cranium to the pelvis, where it terminates in two osseous pieces, the sacrum and coccyx, which may, in fact, be regarded as a continuation of the column. The *sacrum* and the *coccyx* have been separated from the vertebral column merely on account of the osseous junction of the vertebræ of which they are composed.* It is articulated with the base of the cranium at the part where the posterior joins the two anterior thirds of this cavity: it corresponds with the posterior portion of the pelvis, an arrangement most favorable for maintaining the erect position.

The vertebral column is situated behind the alimentary canal in man, above it in the lower animals. In front are suspended the organs of respiration and circulation, to which it affords protection, and which constantly tend to incline it forward: to its sides are attached the ribs and the extremities, the thoracic having an indirect and movable, the abdominal a fixed connexion.

From the limits here assigned to the vertebral column, it follows that this part of the skeleton extends the whole length of the trunk, forming the entire osseous support of the neck and loins, the posterior column of the thorax, and even the posterior wall of the pelvis. Hence it is divided into four regions, viz., a cervical, a dorsal or thoracic, an abdominal, and a pelvic or sacro-coccygeal region.

The vertebral column (*fig.* 1) is composed of twenty-six bones piled above each other: the last two have received the names of *sacrum* and *coccyx*, and the others, which constitute the vertebral column, properly so called (*a d*), are denominated *vertebræ:* they have also been called *true vertebræ*, as distinguished from the *false vertebræ*, which, by their osseous union, form the sacrum (*d e*) and coccyx (*e f*). The sacrum is composed of five of these false vertebræ, and the coccyx of four, in a rudimentary state. The description of these latter bones will be deferred, in the mean time. The first seven true vertebræ form the cervical region (*a b*); the twelve which succeed constitute the dorsal (*b c*); and the last five the lumbar region (*c d*).

There are occasionally, but very rarely, some variations in the number of vertebræ. In a few cases only six cervical vertebræ have been found; and Morgagni, who first observed this anomaly, considers it to be a predisposing cause of apoplexy, on account of the accompanying shortness of the neck, and consequent approximation of the heart and brain. There are sometimes thirteen dorsal vertebræ: sometimes the fifth lumbar is united to the first sacral, and there are then only four lumbar vertebræ. In other cases, the first sacral vertebra is distinct from the rest, and the lumbar portion of the column then consists of six.

The vertebræ present general characters, which distinguish them from all other bones: they have also characters peculiar to each particular region; and in each group or region certain vertebræ have individual distinctive characters.

General Characters of the Vertebræ.

Every vertebra (*figs.* 2, 3, 4, 5, 6, 7) is essentially a symmetrical ring, a segment of the cylinder which protects the spinal marrow, and is, consequently, perforated by a foramen, denominated the *vertebral* or *rachidian foramen* (1, *fig.* 2). As it concurs also to form part of a supporting column, it presents a kind of enlargement or solid cylinder, of which the posterior fifth has been removed. This enlargement is the *body* of the vertebra (2). Each vertebra gives attachment to numerous muscles, by very marked eminences for insertion—the *spinous* (3) and *transverse processes* (4 4). It is articulated with the other

Fig. 2.

* The same is true of anchylosis, as of certain differences of form and development, viz., that they lead to the establishment of varieties, but cannot form the ground of total separation.

vertebræ by four *articular processes* (5 5), two *superior* and two *inferior*. Lastly, it presents two *superior* and two *inferior* notches (7, *figs.* 4, 5), which unite to form the *intervertebral foramina*, through which the vessels and nerves are transmitted.

Fig. 3.

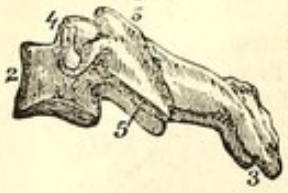

A. *The body of the vertebra* (2) occupies the anterior portion of the vertebral ring, and presents *four surfaces*. The superior and inferior surfaces are connected with the contiguous vertebra, and are slightly hollowed for the reception of the intervertebral substance. This double excavation is the vestige of the deep biconical cavity, so remarkable in the vertebræ of fishes. The anterior surface is convex transversely, and presents a horizontal groove (2, *figs.* 4 and 5), which is deeper laterally than in the median line, and in cases of abnormal curvature is greater on one side than on the other. This groove is the rudiment of that circular constriction which exists in the vertebræ of reptiles and fishes, and in the cervical vertebræ of birds : it has the double advantage of economy, both as to the weight and the bulk of the bone. The posterior surface is concave, and forms part of the vertebral canal. It is pierced by numerous foramina of considerable size, which are the orifices of venous canals hollowed out in the substance of the vertebra. Smaller foramina of the same nature exist also on the anterior surface.

B. *The vertebral foramen* (1, *fig.* 2) exhibits certain variations in form and dimensions in the different regions of the spine ; but in nearly all the vertebræ it approaches more or less to the triangular form. The differences which it presents in the extent of its diameters bear reference partly to the size of the spinal marrow, and partly to the extent of motion in each region.

C. *The spinous process* (3, *figs.* 2, 3, 4, 5) is that eminence of considerable size which arises in form of a spine from the posterior part of the vertebral arch. It forms a lever for the extensor muscles of the trunk, and accordingly varies in length, shape, and direction, in the different regions. It bifurcates, as it were, at its base, and passes into the two *laminæ* (*b b*, *fig.* 2), which constitute the lateral and posterior portions of the arch.

D. *The articular processes* (5 5) arise from the lateral portions of the arch near its junction with the body of the vertebra : their direction is in general vertical, *i. e.*, perpendicular to the direction of the articulating surfaces of the body, which are horizontal. They are four in number, two *superior* or *ascending*, and two *inferior* or *descending* ; they are placed symmetrically on each side of the median line, and are covered with cartilage in the fresh state, to form a movable joint with the articular processes of the adjacent vertebræ ; they project beyond the level of the bodies of the vertebræ, so that their articulations correspond with the intervertebral substances. Hence the vertebral column presents two successive series of articulations : one constituted in front, by the union of the bodies ; the other behind, by the articular processes.

E. *The transverse processes* (4 4) are lateral prolongations, which arise from each side of the vertebral ring, pass horizontally outward, and vary in length and size in the different regions.

F. In front of the articular and transverse processes, immediately behind and at the side of the body of the vertebra, are *four notches* cut in the lateral parts of the ring (7, *figs.* 4 and 5) : the inferior are generally deeper than the superior, but their depth varies considerably in the different regions. The part of the vertebral ring between the upper and lower notches is reduced to a sort of *pedicle* ; it is the weakest part of the vertebra, and, consequently, it is the principal seat of torsion in curvatures of the spine. The constituent parts of a vertebra are, therefore, 1. In the median line, *the body, the foramen, the spinous process*, and the *laminæ* ; 2. On each side, *the articular and transverse processes, the notch*, and the *pedicle*.

Characters peculiar to the Vertebræ of each Region.

Fig. 4.

The characters distinctive of the vertebræ of each region of the spine are most marked in those placed in the middle of the respective region, for at its extremes the vertebræ acquire intermediate or mixed characters belonging to the two regions near the confines of which they are situated. It may be remarked, that the vertebræ of each region may be at once recognised by one single distinctive character : thus, the cervical vertebræ are always known by a foramen in the base of the transverse processes (*a*, *fig.* 2) ; the dorsal vertebræ by facettes hollowed out on the sides of the bodies (6 6, *fig.* 4) ; and the lumbar (*fig.* 5) by the absence of the two preceding marks. The characters just mentioned might, then, suffice as mere distinctive marks, but

Fig. 5.

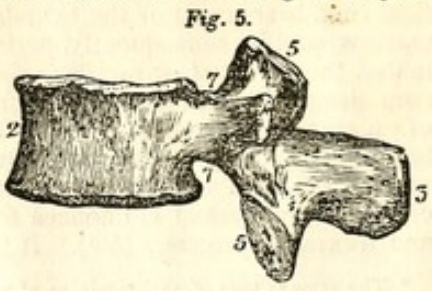

they would not answer the purposes of exact anatomical description. Indeed, a vertebra is cervical, dorsal, or lumbar, rather in virtue of its entire form and structure than by reason of any single circumstance pertaining to it.

We shall examine in regular order each part of a vertebra, as it exists in the different regions.

Bodies of the Vertebræ in different Regions.

The first distinctive character is their size. *This progressively increases from the cervical to the lumbar region* (*a*, *b*, *c*, *d*, *fig.* 1): taking the size of the bodies of the lumbar vertebræ as unity, that of the dorsal would be two thirds, and that of the cervical one half.

The second distinctive character is the *proportion of the diameters.* In all vertebræ the transverse diameter is the greatest, and the vertical the smallest. In the lumbar vertebræ the height or vertical diameter is twelve lines (one inch), in the dorsal nine lines (three quarters of an inch), and in the cervical six lines (half an inch). In the cervical and lumbar regions, the vertical diameter of the body is less behind than before, which inequality gives rise to the anterior convexity of these regions. In the dorsal region, on the other hand, the vertical diameter is shortest anteriorly. In the lumbar region, the transverse diameter does not exceed the vertical and the antero-posterior by more than one third at most. In the dorsal region no one diameter is strikingly predominant; but in the cervical the transverse is almost double that of the antero-posterior and the vertical diameters.

The third distinctive character is formed by the *lateral ridges of the bodies of the cervical vertebræ.* From the two sides of the superior surface of the bodies of the cervical vertebræ arise two small ridges (*fig.* 2, on each side of 2), which are received into corresponding depressions on the inferior surface of the vertebra above. This mutual fitting-in of the bodies of the cervical vertebræ compensates for the less secure connexion of their articular processes, and which insecurity is, moreover, of less importance, from the bodies being united by disks of intervertebral substance.

The fourth distinctive character consists in the *two demi-facettes on each side of the bodies of the dorsal vertebræ* (6 6, *fig.* 4). These demi-facettes, when united with the corresponding parts of the neighbouring vertebræ, form angular excavations, in which the posterior extremities of the ribs are received. This character belongs exclusively to the dorsal vertebræ.

The fifth distinctive character is the *excavation of the superior and inferior surfaces of the bodies, which is less in the dorsal region than in the cervical or lumbar.* From this disposition it results, that a lenticular space of a much greater size intervenes between every two of the lumbar and cervical vertebræ than between the dorsal: the mobility is consequently much increased, from the greater size of the intervertebral substance.

The specific characters, then, of the bodies of the vertebræ in the different regions are the following: 1. *Lateral ridges on the superior surface of the cervical vertebræ.* 2. *Lateral facettes on the dorsal vertebræ.* 3. *The absence of these two characters, and the preponderance of size in the lumbar vertebræ.* If the body of a vertebra be presented for our inspection, we can at once determine from these characters the region to which it belongs.

The Vertebral Foramen and the Notches in the different Regions of the Spine.

The vertebral foramen and the notches present certain marked distinctions in the vertebræ of the three regions, by which they may be recognised by a practised eye.

1. In the cervical region, the transverse diameter of the foramen (1, *fig.* 2) considerably exceeds the antero-posterior. 2. In the dorsal region, the two diameters are almost equal, but there is this much which is remarkable, that a very considerable depression exists on the posterior surface of the body of the bone. 3. In the lumbar region, the transverse diameter is the greater, but the difference is much less remarkable than in the cervical. The following is a comparative table of the diameters in the three regions:

Transverse diameter.	*Antero-posterior diameter.*
In the neck, 11 lines.	In the neck, 6 lines.
back, 7 lines.	back, 6 lines.
loins, 10 lines.	loins, 8 lines.

It may be remarked here, that these differences correspond with the extent of motion in each region. In the lumbar region, which is more movable than the dorsal, the foramen is larger; and in the cervical region, where the lateral motions are more extended than in the loins, the transverse diameter is still greater, in the proportion of eleven to ten. It must be observed, however, that the diameters of the foramen bear reference not only to the mobility of the part, but also to the size of the spinal marrow.

The *notches* present also certain differences in the different regions; thus, in the dorsal and lumbar regions (7, *figs.* 4 and 5), the inferior are much deeper than the superior; in the cervical region they are of almost equal depth (*fig.* 3). It may also be remarked, that the depth of the notches, and, consequently, the size of the intervertebral foramina,

are generally proportional, not only to the size of the spinal ganglions, but also to the capacity of the venous canals, which establish a communication between the external and internal veins of the spine. It is then possible, when only the vertebral foramen and the notches are seen, to determine the region to which the bone belongs.

The Spinous Processes and Laminæ in the different Regions.

1. *In the cervical region*, the spinous processes are prismatic and triangular (3, *figs.* 2, 3), grooved inferiorly for the reception of the spinous process of the vertebra below during the movements of extension, and bifurcated at their summit, for the purpose of muscular insertion. Their direction is horizontal, and, consequently, favourable to extension.

2. *In the dorsal region* (3, *fig.* 4) they are prismatic and triangular, with a tubercle at their summit; their direction is extremely oblique, approaching to the vertical. This direction, together with their great length, causes them to descend considerably below the inferior surface of the body of the vertebra. Hence a sort of imbrication, and to such a degree that a very slight movement of extension causes them to touch each other.

3. *In the lumbar region* the spinous processes (3, *fig.* 5) are broad, thick, and quadrilateral, presenting on their sides a large surface for muscular insertion; their posterior border is thick, tuberculated, and triangular. Their direction, being horizontal, presents no obstacle to extension.

The two laminæ (*b b*, *fig.* 2), which form the posterior arch of the vertebra, are continuous with the base of the spinous process. Their length is directly proportionate to the dimensions of the part of the canal to which they correspond, and their thickness is in proportion to the size of the spinous process.

1. *In the cervical region* the laminæ are thin, very long, and so inclined that when the head is erect, *i. e.*, in a position intermediate between flexion and extension, the inferior edge of the superior laminæ passes beyond the superior border of the vertebra below, so that there is a true imbrication of these laminæ, not less marked than that which we have observed of the spinous processes in the dorsal region. There has been, consequently, no case recorded of the entrance of any penetrating instrument into the spinal canal, in the situation of the undermost five cervical vertebræ; which fact is the more easily conceivable when we reflect that the least impression upon the back of the neck excites, instinctively, an extension of the head, and thus increases the imbrication of the laminæ. 2. In the *dorsal region* the thickness of the laminæ is greater than in the neck, but still inferior to that in the loins; they are comparatively much shorter than in the cervical region, and, instead of forming an elongated rectangle, they represent a square—nay, their vertical dimension almost exceeds the transverse. 3. In the *lumbar region* they are characterized by great thickness, by diminution of the transverse, and marked increase of the vertical diameter. In general, it may be stated that the height of the lamina corresponds with the thickness of the body of the vertebra to which it belongs; hence they are so narrow in the cervical region.

To sum up, then, the characters of the spinous processes and the laminæ:

1. Cervical Region.—*Processes prismatic and triangular, grooved inferiorly, bifurcated with two tubercles at their summit, horizontal, short, and continuous, with long, narrow, and thin laminæ, inclined so as to become imbricated.* 2. Dorsal Region.—*Spinous processes prismatic and triangular, long, oblique, and tuberculated at their summit, with short vertical laminæ.* 3. Lumbar Region.—*Spinous processes quadrilateral, strong, and horizontal, with very short, thick, and vertical laminæ.* It is possible, then, from the spinous process and its laminæ alone, to determine the region of any vertebra.

The Articular Processes in the different Regions.

In the *cervical region* (5 5, *figs.* 2 and 3) the articular processes form small columns, and are so directed that their articular surface makes, with the horizon, an angle of about 45°; the superior look upward and backward, the inferior downward and forward. It is important to remark this direction, because it permits the movements of flexion, extension, and lateral inclination: it is owing to the same circumstance, also, that luxations of the cervical vertebræ may occur without fracture of their articular processes. It should be also observed that the articular surfaces of the right and left sides are in the same plane.

2. In the *dorsal region* (5 5, *fig.* 4) the articular processes are simple laminæ, the direction of which is vertical and the surface plane. The superior look backward and outward, the inferior forward and inward. The articular facette of the right side is not on the same plane as that of the left.

I should observe that, in certain cases, the dorsal articular processes are found, as it were, locked together, the extremity of the superior process being received into a deep notch on the surface of the inferior process of the vertebra above.

3. In the *lumbar region* (5 5, *fig.* 5) the articular processes are very strong, with curved

surfaces. The superior concave look backward and inward, the inferior convex forward and outward. They both represent two segments of a cylinder, one of which completely surrounds the other, or, rather, the inferior resemble half hinges, which are received into the half rings formed by the superior processes. It should be observed here, that the superior articular processes are prolonged by certain tubercles, to which the name of *apophysary* may be correctly applied, and which serve for the insertion of muscles. To sum up, then, what has been said: *The cervical articular processes are small columns, cut with plane faces, at an inclination of* 45°, *those of both sides on the same plane; the dorsal are thin laminæ, plane and vertical, but not in the same plane; the lumbar strong, vertical, and tuberculated laminæ, with a curved articular surface.* The region of any given vertebra may be easily recognised from its articular processes alone.

The Transverse Processes in the different Regions of the Spine.

No part of the vertebræ presents more decided variations in the different regions than the *transverse processes.*

1. In the *cervical region* (4 4, *figs.* 2 and 3) they are grooved superiorly for the lodgment of the anterior branches of the cervical nerves; their base is perforated (*a*, *fig.* 2) for the passage of the vertebral artery; they have two borders, an anterior and posterior, to which the inter-transversal muscles are attached; their free extremity is bifurcated for the attachment of muscles. It should be added, that these transverse processes, being on the same plane with the bodies of the vertebræ, double their transverse diameter in front, and enable them to afford support to a great number of parts.

2. In the *dorsal region* (4, *fig.* 4) they are large and horizontal, much stronger than in the other regions, and twice or three times the size of the spinous processes; they are much inclined backward, and the anterior surface of their extremity has a depression for articulation with the tubercle of the ribs. Some anatomists have attached great importance to the direction of the articular facettes, making it the basis of their notions of the mechanism of respiration. The important modifications which the transverse processes of the dorsal vertebræ present are evidently connected with the nature of their functions, which are not only that of affording points of insertion to muscles, but also of supporting the ribs with which they are articulated.

3. In the *lumbar region*, the transverse processes (4, *fig.* 5) are thin, narrow laminæ, flattened from before backward. They are situated in a plane anterior to that which the transverse processes of the dorsal vertebræ occupy, and almost correspond with that of the ribs, with which, also, they have numerous other analogies: hence the name *costiform processes* given them by some anatomists.* The characteristics, then, of the three kinds of transverse process are, *in the cervical region, a grooved projection with a foramen at the base; in the dorsal region, a strong process inclined backward, tuberculated, and articular at the extremity; in the lumbar region, a small, thin, blunted projection.* It is, therefore, extremely easy to determine the situation of a vertebra by the transverse process.

The truth of what we formerly remarked will be now evident, viz., that a vertebra is distinguished as cervical, dorsal, or lumbar, by the form of all its constituent parts. Uniform in their fundamental type, these bones present, in each region, and in each part, certain differences adapted to their respective uses.

Characters proper to certain Vertebræ.

We have now noticed, 1. The general characteristics of the vertebræ, by means of which they may be recognised from all other bones; 2. The peculiar distinguishing chraracters of the vertebræ in each region. We have now to examine in each region those vertebræ which are distinct from all the others of that part of the spine. The place of each vertebra might, strictly speaking, be determined by comparing it with all the other vertebræ of the same region: in this way, those who are accustomed to articulate skeletons acquire surprising readiness. But a few vertebræ only possess sufficiently characteristic peculiarities to determine their situations without comparison with the others. It is only in the vertebræ at the extremity of each region, and which, on account of their position, have a mixed character, that such distinctive and individual attributes can be observed.

The first, second, and seventh cervical vertebræ, the first, eleventh, and twelfth dorsal, and the fifth lumbar, require special description.

First Cervical Vertebra, or Atlas (fig. 6).

In the *first vertebra*, or *atlas*, the place of the body is supplied by an arch (*a g*), flattened

* The description which we have given of the transverse processes is in accordance with that usually found in works on human anatomy. Several modern anatomists, however, do not admit of the arrangement which we have adopted. From the existence of cervical and lumbar ribs in the skeletons of many vertebrated animals, they maintain that in man the anterior half of the cervical transverse processes, and the thin plates of the lumbar transverse processes, represent the ribs of the dorsal region; while the parts truly analogous to the dorsal transverse processes are, 1. In the cervical region, the posterior half of the transverse process; 2. In the lumbar region, those projections which we have called apophysary tubercles.

Fig. 6.

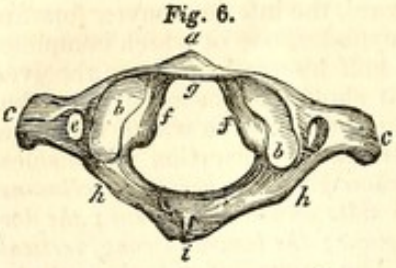

from before backward, *the anterior arch of the first vertebra*. Its convexity, turned forward, is marked by a tubercle (*a*), *the anterior tubercle of the atlas*. Its concavity, looking backward, presents an oval facette, slightly hollowed for articulation with the odontoid process of the second vertebra. The superior and inferior borders afford attachment to ligaments.

The *foramen* of the first vertebra is much larger than that of all the others. The antero-posterior diameter, which in the neck and back is six lines, and in the loins eight, is here fourteen; the transverse diameter, eleven lines in the neck, seven in the back, and ten in the loins, is here thirteen. This remarkable extent of all the diameters is not simply owing to the size of the spinal marrow at this point, for the anterior portion of the foramen (*f*, *g*, *f*) gives lodgment to the odontoid process of the second vertebra, so that the antero-posterior diameter of the part which contains the spinal cord does not greatly exceed that of the foramen in the succeeding vertebræ. The transverse diameter alone is more considerable, whence the possibility of lateral displacements or incomplete luxations of the first upon the second vertebra without any marked compression of the cord.

The *notches* (*h h*) are situated on the posterior arch at its junction with the lateral masses. They are posterior to the articular processes, while in all the other vertebræ they are anterior. The *superior* are very deep, often converted into foramina by a bridge of bone, and seem to be continuous with the foramen in the base of the transverse process, by means of a horizontal groove which winds round behind the articular process. This groove is sometimes almost converted into a complete canal. From the union of these parts, viz., the notch, groove, and foramen, a *twisted canal* results, vertical at first, and afterward horizontal, along which the vertebral artery runs in its passage into the cranium. Through the superior notch, which almost forms by itself the first intervertebral foramen, the vertebral artery and vein and the first cervical nerve pass. The *inferior* notches present nothing remarkable, excepting that they are sufficiently deep to form, by themselves, the intervertebral foramina between the first and second vertebræ.

There is no *spinous process:* its place is supplied by a *posterior tubercle* (*i*) for muscular insertion, analogous to the anterior tubercle, or, more correctly, resembling a spinous process truncated. Sometimes, instead of a tubercle, there are only some inequalities. The *posterior arch* (*h*, *i*, *h*), which forms more than half the circumference of the vertebra, consists of two strong and long plates.

The *articular processes* or *columns*, which we have remarked throughout the whole cervical region, are very large in the atlas, and bear the name of *lateral masses*. This structure is connected with the use of the bone, which is to support the occipital condyles, and, consequently, the weight of the head.

Of the four articular processes, the superior (*b b*) are concave, slanting inward, oval, and obliquely directed from behind forward, and from without inward. Their form exactly corresponds with the convexity of the occipital condyles (7 7, *fig.* 10), which they receive, and for this purpose their external borders and posterior extremities are considerably elevated. Within and below the articular surface are certain inequalities (*f f*, *fig.* 6), which give attachment to the transverse ligament. The *inferior* articular processes are circular and plain; they look downward and a little inward.

The *transverse processes* (*c c*) are very large and triangular: they have only one tubercle, into which are inserted the principal rotatory muscles of the head: they are perforated by a foramen (*e*) at the base, but are not grooved on their surface.

The characteristics, then, of the atlas are, *an annular form; great lateral dimensions, so that it surmounts the vertebral column like a capital; a very large vertebral foramen; no body, nor spinous process; large lateral masses, supporting very strong transverse processes, which are not grooved, and have only one tubercle.*

Second Vertebra, Axis, or Vertebra Dentata (*fig.* 7, side view).

The body is surmounted by an eminence (*g*, *a*, *l*, *fig.* 7), which, in the connected skeleton, corresponds with the anterior arch of the atlas. This eminence has received the name *odontoid process*, or *processus dentatus*, from its tooth-like form. It constitutes a species of cylindrical pivot, about half an inch in length, round which the head turns; and hence the name *axis* given to the entire vertebra. It is attached to the body of the bone by a broad basis, is then constricted, and terminates superiorly in an enlargement called the head, which is rough at its summit (*a*), and gives attachment to the odontoid ligaments. The contracted portion (*l*) is called the *neck;* it is the weakest part of the process, and is, consequently, the invariable seat of its fractures. This circular con-

Fig. 7.

striction of the inferior part of the odontoid process contributes to maintain it in the semi-osseous, semi-ligamentous ring in which it turns. Two articular facettes are seen on this process: one in front (*g*), corresponding with the anterior arch of the atlas; the other behind (at *l*), for the transverse ligament.

The *body* (*c*) of the axis presents anteriorly a triangular vertical ridge, which separates two lateral depressions for the attachment of muscles. The posterior surface corresponds with the vertebral canal. The greatest diameter of the inferior surface is the antero-posterior: it is obliquely sloped downward and forward, and slightly concave, for the reception of the body of the third cervical vertebra. This mutual reception of the two bones does not take place between any of the succeeding vertebræ.

The foramen is shaped like the figure of a heart on playing cards: its antero-posterior diameter is eight lines, which is two lines more than in the other cervical vertebræ, and its transverse diameter is the same. This great size of the foramen of the second vertebra corresponds with the extent of the movements between it and the atlas.

There is no *superior notch*, the inferior notch of the atlas forming by itself the inter-vertebral foramen. The inferior notch presents nothing peculiar.

The spinous process (*k*, *m*), though of great length, is even more remarkable for its breadth and thickness, presenting, as it were, in an exaggerated degree, the characters of the cervical spinous processes: its form is prismatic and triangular; it is grooved inferiorly, and terminates by two tubercles for the attachment of powerful muscles. The spinous process is for the axis that which the transverse process is for the atlas, both giving insertion to powerful muscles, which move the head upon the vertebral column.

The *laminæ*, which correspond, as usual, with the size of the spinous process, are remarkably strong.

The *superior articular processes* (*d*) are placed on each side of the body. Their facettes are broad, flat, and almost horizontal, being slightly inclined outward. This direction permits the atlanto-axoidean articulation to be the centre of all the rotatory movements of the head.

The *inferior articular processes* (*e*) resemble those of the other cervical vertebræ.

The *transverse processes* (*n*) are small, with only one tubercle, triangular, bent downward, and perforated at the base by a foramen (*f*), or, rather, a bent canal, which is hollowed out on each side of the body of the bone; and is vertical in the first part of its course, then horizontal. This canal, and that which we have described upon the atlas, mark the winding course of the vertebral artery before it enters the cranium.

The specific characteristics, then, of the second vertebra are, *the odontoid process, the great size of the spinous process and the laminæ, the large size and horizontal direction of the superior articular processes, which are placed on each side of the body, and the shortness of the transverse processes, which are triangular, and have one tubercle.*

Seventh Cervical Vertebra, or Vertebra Prominens (*b, fig.* 1).

The *body* has the ordinary characters observed in the cervical vertebræ, but in size it resembles that of the dorsal vertebræ, and frequently presents laterally a small impression for articulation with the head of the first rib. The *spinous process* bears the greatest resemblance to those of the dorsal vertebræ: it is pyramidal, terminates in a single tubercle, and is of great length, projecting considerably beyond the level of the other cervical vertebræ; hence its name of *vertebra prominens*. The articular processes are almost vertical, and are not supported by small columns. The *transverse process*, although grooved and perforated at the base, as in all the other cervical vertebræ, closely approaches to the characters of the dorsal. The posterior border of the groove, or posterior root of the process, is thick, tubercular, and exactly similar to a dorsal transverse process, while the anterior is thin and rudimentary, excepting in cases where it is separated from the body of the bone, and forms a supernumerary rib.* The *foramen* in the base of the transverse process is very rarely absent, but is most commonly small: in one case only I have found it double. It is never traversed by the vertebral artery.

First Dorsal Vertebra.

This vertebra resembles the cervical, in having its body surmounted laterally by two hook-like processes or ridges, but, in all other respects, it is strictly analogous to the other dorsal vertebræ. It should be also observed, that the body presents an entire facette for the first rib, and a third or fourth part of another for the second.

Eleventh and Twelfth Dorsal Vertebræ.

The eleventh dorsal vertebra presents on each side of the body an entire facette for the eleventh rib. Its body is very large, and the place of the transverse process is supplied by a tubercle.

The twelfth dorsal vertebra (*c, fig.* 1) resembles the lumbar in its body, which is scarcely

* This circumstance is one of the facts appealed to with most success by those who make the distinction of *transverse* and *costiform* processes.

smaller than that of the lumbar vertebræ, and of which the transverse diameter begins to predominate. The spinous process is horizontal, strong, and quadrilateral. The transverse processes are represented by tubercles, which, like those of the preceding bone, are evidently continued in the lumbar region by those tubercles which we have denominated apophysary. Lastly, the body presents entire articular facettes. It is distinguished from the eleventh dorsal vertebra by the curved surface of the inferior articular processes.

Fifth Lumbar Vertebra.

The inferior surface of the body slopes very obliquely downward and forward. The transverse processes vary in size, but are generally much larger than those of the other lumbar vertebræ; the inferior articular processes, which are farther separated from each other, have a flat surface, and look directly forward.

These are the only vertebræ which in each region present peculiarities. Excepting the first and second cervical, which have many characters quite foreign to the vertebræ of the region to which they belong, it might be said of those peculiar vertebræ which have been specially described, that their peculiarities are comprehended in the general statement that those vertebræ which are placed at the limits of any two regions possess characters belonging to both regions.

Vertebræ of the Sacro-coccygeal Region.

All the vertebræ of this region, nine in number, are in the adult state united into two bones: the five superior form the *sacrum*, the four inferior the *coccyx*.

The Sacrum (*d*, *e*, *figs.* 1 and 8).

The *sacrum* has received its name from the alleged practice of the ancients of offering this part of the victim in sacrifice. It occupies the posterior and median part of the pelvis, behind the point where this cavity articulates with the thigh bone, an arrangement advantageous for the erect position. It is inserted, like a wedge, between the two haunch bones. Above, it corresponds with the true vertebral column; below, with the coccyx. It is directed obliquely backward and downward; hence the column represented by the sacrum forms an obtuse angle with the lumbar column, the projection of which is anterior. This angle is denominated the *promontory*, or the *sacro-vertebral angle* (*d*, *fig.*1): it is an important object of study, both with reference to the mechanism of standing, and in the practice of midwifery.* The sacrum is curved upon itself, from behind forward, so as to present an anterior concavity. It is the largest of all the bones of the vertebral column; hence the name of *great vertebra* applied to it by Hippocrates. It is proportionally more developed in man than in any other mammiferous animal, which is connected with the erect bipedal attitude and the sitting attitude which belong to him in a special manner.† The form of the sacrum is that of a quadrangular pyramid with a truncated apex, the base looking upward. It is symmetrical, like all the median bones, and presents for consideration *an anterior*, *a posterior*, and *two lateral surfaces*, *a base*, and a *summit*.

The *anterior*, *pelvic*, or *rectal surface* (*fig.* 8) forms part of the cavity of the pelvis. Its concavity varies much in different individuals, and in the two sexes: but on this latter point there is great diversity of opinion among anatomists. Some believe that it is greater in the female, whence, it is said, results the advantage of a larger capacity of the pelvis, and, consequently, an increased facility for the passage of the head of the fœtus during parturition. Others, on the contrary, contend that the male sacrum is more curved, and that of the female almost straight; and they argue that, had the opposite been the case, the coccyx, which forms a continuation of the curve of the sacrum, would have been directed forward, and thus diminished the antero-posterior diameter of the outlet of the pelvis; whereas, with a slight curve of the sacrum, the coccyx has no tendency to project, but is easily bent backward during labour.‡

Fig. 8.

In order to determine the validity of these opposing statements, I have compared a great number of sacra from both sexes, but I could never detect any difference sufficiently marked or constant to be considered as characteristic of the sex.

* The sacro-vertebral angle is most remarkable in man, because he alone is destined for the erect posture. By this angle the impetus of movement transmitted from the vertebral column to the sacrum is in part destroyed. In midwifery it explains the rarity of median positions of the vertex.

† Birds, which, like man, are biped, are also remarkable for the size of their sacrum.

‡ A very great curvature of the sacrum diminishes not only the antero-posterior diameter of the inferior, but also that of the superior aperture of the pelvis; and it thus opposes the ascent of the uterus from the true into the false pelvis. Accoucheurs cannot too carefully study the varieties presented by the curvature of this bone. The sacrum is often affected by a species of rickets, when the other bones of the pelvis are free from deformity: and this fact may be easily explained by a reference to the uses of this bone in supporting the whole weight of the trunk.

The anterior concavity of the sacrum is interrupted by four transverse projections (1 1 1, *fig.* 8), which correspond with the points of union of the sacral vertebræ, and are analogous to the intervertebral prominences. The first is sometimes so prominent, that it might be mistaken for the sacro-vertebral angle in an examination *per vaginam*.

On each side of the median line are the anterior sacral foramina (2 2 2), four in number, the two superior much greater than the two inferior. They give passage to the anterior branches of the sacral nerves, to the sacral veins, and some small arteries. External to these are grooves for the nerves, and the attachment of the pyramidalis muscle. The anterior surface of the sacrum is contiguous to the rectum, which follows its curvature.

Posterior, spinal, or cutaneous surface. Its convexity is exactly proportioned to the anterior concavity. 1. In the *median line* it presents the *sacral ridge*, formed by a continuation of the spinous processes of the vertebral column. This is often entire in its whole length, but sometimes interrupted: it bifurcates inferiorly, and forms the borders of the groove which terminates the sacral canal. The sacral ridge is rarely found cleft throughout its whole length.

2. *On each side of the median line* are two shallow grooves, named *the sacral grooves:* they are continuations of the vertebral grooves; they are pierced by *four posterior sacral foramina*, smaller than the anterior foramina, and differing less from each other in diameter. These afford passage to the posterior branches of the sacral nerves, to some veins and arteries. They are bordered by two ranges of unequal projections: the first row, placed interior to the foramina, represent the articular processes united together; the second, external to the foramina, are more marked, and correspond with the transverse processes also united.

The *lateral surfaces* (*d*, *e*, *fig.* 1) are triangular, broad above, narrow below, where they constitute mere borders. They slope obliquely from before backward and from without inward, so that the sacrum is wedged between the haunch bones in an antero-posterior as well as in a vertical direction. In front is a demi-oval or crescentic surface (7, *fig.* 8), compared from its shape to the human ear, and hence denominated *auricular surface*. In the fresh state it is covered with cartilage, and articulates with the os innominatum. Behind it is a very rugged surface with irregular depressions, giving attachment to the posterior sacro-iliac ligaments. The sinuous border which terminates each lateral surface inferiorly gives attachment to the sacro-sciatic ligaments.

The *base* presents, 1. In the middle an oval facette (3, *fig.* 8), in all respects similar to the body of a lumbar vertebra, with the last of which bones it is articulated. Behind this is a triangular aperture resembling the foramen of other vertebræ, and completed posteriorly by two *laminæ*, which unite, and form a spinous process,* the commencement of the sacral ridge. 2. On each side *two triangular surfaces* (4 4), smooth, looking forward and upward, and constituting part of the greater or *false* pelvis. They are separated from the anterior surface of the sacrum by a blunt edge, which forms, as we shall afterward see, a portion of the superior aperture of the pelvis. Behind the oval surface of the body are *notches*, which complete the last intervertebral foramina; and behind these notches are the *articular processes* (5 5), which resemble the superior articular processes of the fifth lumbar vertebra, and receive the inferior processes of that bone.

The *apex* (6) is truncated, and presents a transverse elliptical surface, which articulates with the base of the coccyx. Behind it is the termination of the sacral groove, bounded by two small apophyses, intended to unite with two similar projections of the coccyx. These are *the small cornua of the sacrum.*

The *sacral canal.* The termination of the vertebral canal is prismatic and triangular, wide superiorly, contracted and flattened inferiorly, where it degenerates into a groove, which is converted into a canal by ligaments. This canal lodges the sacral nerves, and communicates both with the anterior and posterior sacral foramina.

The Coccyx (8, 9, *fig.* 8).

This consists of four, rarely of five, pieces of bone: they are flattened from before backward, and diminish successively in size from the first to the last: they are commonly united together, rarely separate, the largest corresponding with the apex of the sacrum; the smallest is a mere nodule of bone, generally unattached. The whole knotted-like bone, thus constituted, has a triangular shape, and follows the direction of the lower part of the sacrum. It may be regarded as the rudiment of the tails of the lower animals. In some cases I have seen it form a right angle, or even an acute angle with the sacrum.

1. The *posterior, spinal, or cutaneous surface*, is rough, for the insertion of the aponeurosis of the *gluteus maximus*.

2. The *anterior surface* resembles the same part of the sacrum in miniature, and, like it, is in immediate proximity to the rectum.

3. The *borders* are narrow, sinuous, and tubercular, and give attachment to the sacro-sciatic ligaments.

* I have seen this spinous process completely bifurcated.

4. The *base* is often united by bone to the sacrum, even in young subjects; it presents an elliptical articular surface, exactly corresponding with that on the lower end of the sacrum. Behind are two processes directed upward (cornua of the coccyx, 8 8, *fig.* 8), which are sometimes continuous with the small cornua of the sacrum. Externally are two *notches*, which are converted into foramina by means of ligaments, and afford passage to the fifth pair of sacral nerves.

5. The *apex* (9), which is sometimes enlarged and sometimes bifurcated, gives attachment to the levator ani muscle. It is not uncommon to find the last pieces of the coccyx deviating from the median line.

Of the Vertebral Column in general.

Having already described the situation of the vertebral column, we shall now consider its dimensions as an entire piece of the skeleton.

Dimensions of the Vertebral Column.

1. The *length* or *height* of the vertebral column does not correspond with the length of the spinal marrow, which does not extend below the first lumbar vertebra. It varies at different ages: most commonly it increases up to the twenty-fifth year, but occasionally its growth is completed before this period. In the adult it remains unaltered, but in old age it becomes shortened by the incurvation of the trunk forward, and the yielding of the bodies of the vertebræ and the intervertebral substances. This latter cause is also productive of a very appreciable shortening of the trunk, sometimes to the extent of half an inch, after long walking or standing.

When measured along its curvatures, the length of the column is generally two feet four inches; in vertical height it is two feet two inches. These dimensions are not exactly proportional to the height of the individual, which depends principally upon the length of the lower extremities. In this respect I have never found any marked difference between tall and short persons. In an adult of medium stature, the cervical portion measures five inches and a half, the dorsal nine inches and a half, the lumbar six inches and a half, and the sacro-coccygeal six inches and a half.

It may be easily conceived that, in cases of abnormal curvature, the vertical height must present considerable differences, while the actual length of the column may remain almost constant. In the skeleton of a female affected with rickets, a vertical line, stretched from the tubercle of the atlas to the base of the sacrum, measured one foot, six inches, and six lines; while a line which followed the inflections of the column, measured two feet eighteen lines—giving a difference of seven inches. Hence the possibility of a rapid and considerable increase in length in those patients who are submitted to continued extension.

2. *Antero-posterior dimensions.* The antero-posterior diameter, at the sacro-vertebral angle and in the lumbar region, is three inches; in the dorsal region, two inches, four lines; in the middle of the cervical region, one inch, six lines.

3. *Transverse dimensions.* The transverse diameter is eighteen lines in the lumbar region, thirteen in the middle of the dorsal, and twenty-two in the cervical. It should, however, be remarked, that the transverse processes are included in this measurement of the cervical region, but not in the others.

Direction.

The general direction of the spinal column is vertical, but it presents certain *alternate curvatures*. There are four antero-posterior curvatures, viz., in front, a convexity in the neck (*a*, *b*, *fig.* 1), a concavity in the dorsal region (*b*, *c*), a convexity in the loins (*c*, *d*), and a concavity in the sacro-coccygeal region (*d*, *e*, *f*). Behind, the opposite curvatures are observed. The degree of each curvature is always proportioned to that of the others; thus, if there be a remarkable projection in the cervical region, there is a corresponding degree of concavity in the dorsal, and a proportional convexity in the lumbar regions. So great, indeed, is the mutual dependance of these curvatures, that the slightest modification of one produces corresponding alterations in all the others.

There are many individual varieties of these curvatures; their effect appears to be that of augmenting the power of resistance in the vertical direction, or, at least, of diminishing the effect of vertical pressure. It may be physically demonstrated, that of two similar rods made of the same materials, that which presents alternate curves will support a greater amount of pressure in the vertical direction than that which is straight, on account of the decomposition of forces which occurs at each curvature.*

In addition to these antero-posterior curvatures, there is at the level of the third,

* Some physiologists have even gone so far as to express by figures what the difference of resistance of a recto-lineal vertebral column would be, as compared to one formed with curves like the spine, and have made it as 1 : 16. It has also been asserted, that the curvatures of the spinal column were the result of muscular action. This is certainly not the fact. These curves are too fixed and too important to be made to depend on an agent so variable as that of muscular contraction. They are produced by the general law which regulates the organization of the body.

fourth, and fifth dorsal vertebræ a *lateral inclination*, the concavity of which is on the left side. This being the exact situation in which the *aorta*, the principal artery of the body, makes a curve downward, the older anatomists have ascribed the concavity of which we speak to the curvature of this vessel. Bichat imagined it to be owing to the almost universal habit of employing the right hand, in which action the upper part of the trunk is inclined to the left, so as to afford a point of support, and, as it were, a counterbalance to the action of the right arm, which inclination, by frequent repetition, becomes permanent. According to this hypothesis, left-handed individuals should present a curvature in the opposite direction, and Béclard has shown that such is in reality the case. I may add, that I have always found the deviation greatest in those who used their right arm in the most laborious employments. Of late years it has been supposed that the lateral curvature depended upon the position of the fœtus in utero; had this been the case, it should exist at birth, which, as I can affirm, it never does. Notwithstanding the likelihood of Bichat's opinion, yet, if we consider that in every case in which an artery is immediately contiguous to a bone, that bone presents a corresponding depression, it may be questioned whether the opinion of the older anatomists has not more foundation than is generally admitted.* However slight this lateral incurvation may be, it always produces a correspondent one in the lumbar region, though in the majority of cases this is scarcely perceptible.

The history of abnormal curvatures or deviations belongs to pathological anatomy. I shall only observe, that they are all due to the following causes: 1. The wasting of the vertebræ by caries or softening. 2. Want of equilibrium between the strength of the vertebral column and the weight of the body, either alone or when loaded with burdens. 3. Muscular traction. 4. The frequent repetition of any attitude in which the column is curved.

Figure and Aspects.

Viewed in front, the vertebral column represents two pyramids united by their bases. The inferior pyramid is constituted by the sacrum and coccyx; the superior pyramid is the true spine; its base rests on the former, and its summit is surmounted by the atlas.

The contraction which exists at the fourth and fifth dorsal vertebræ has led to the subdivision of this superior pyramid into two others, united by their summits. Other subdivisions have been instituted, which we shall not point out, since they are useless. What it is important to know is, that the vertebral column increases progressively in size from above downward, which satisfactorily proves that man was formed for the erect position. There are partial enlargements in different parts, as, for instance, in the first two cervical vertebræ, in the seventh cervical, and last dorsal, &c.

Upon the whole, it may be said that the vertebral column presents in front the appearance of a knotted cylinder; behind, that of a triangular pyramid, bristled with eminences and perforated with holes. How irregular does the spine appear when cursorily examined! Yet, when viewed as a whole, and when we examine its figure and processes in reference to its uses, we are lost in admiration in perceiving that there is not the smallest tubercle, nor the most minute hole, nor the most trifling circumstance in its configuration, which is not of great importance in securing the perfection of the entire column.

The vertebral column presents for consideration an anterior, a posterior, and two lateral surfaces, a base, and a summit.

Anterior Surface.—Here are observed, 1. The curvatures already described; 2. The range of bodies of the vertebræ, having the form of small columns piled on each other, and separated in the fresh state by certain prominent disks of a white colour and fibrous structure. 3. A range of transverse grooves on the bodies of the vertebræ, which are deeper in the aged than in the young subject. This surface presents in its transverse diameters those variations which we have already noticed. The parts placed in front of the vertebral column are, 1. Immediately on its anterior surface a ligamentous layer, which completely invests it, with the anterior recti muscles of the head, the longi colli, the crura of the diaphragm, and the psoæ muscles. 2. At a greater distance the alimentary canal, which rests on the spine at its commencement and termination, and is attached to it by membranous connexions, even where it advances forward to form its numerous convolutions. 3. The organs of circulation, viz., the heart, the aorta, in almost its whole extent, the carotid, vertebral, and common iliac arteries, the venæ cavæ, the jugular and common iliac veins, the vena azygos, and the thoracic duct. From this position of parts arises the possibility of effectually compressing the arteries against the vertebral column, a method which has been successfully adopted with the carotid arteries and abdominal aorta. It also explains the marked pulsations in the abdominal region frequently observed in emaciated subjects, and often giving rise to an erroneous suspi-

* This opinion seems to be still farther corroborated by a case lately reported to the Academy of Medicine by Doctor Géry, of complete inversion of the viscera, where the aorta was placed on the right side of the vertebral column, and where the concavity, or, rather, lateral depression, was situated on the right side. The facts of the case are satisfactorily established by M. Bonamy, who examined the subject. *Positive proof was obtained that this individual was not left-handed.*

cion of aneurism. 4. The trachea and the lungs. 5. The great sympathetic nerves are connected with it in its entire extent, and the ganglionic enlargements of which correspond in number to the number of its different pieces.

Posterior Surface.—This presents, 1. *In the median line*, the row of spinous processes, the whole of which constitute a vertical crest or ridge denominated *spine*, and hence the names spinal column and rachis (ῥαχὶς, spine). This ridge is far from being regular, but its irregularities are all perfectly adapted for the fulfilment of the movements of the different regions. It commences with the tubercle of the first vertebra, is suddenly enlarged at the second, diminishes again at the third, fourth, and fifth cervical vertebræ, and projects anew at the sixth, and more remarkably at the seventh; thence named vertebra prominens. Below this point the processes become oblique, prismatic, triangular, and with one tubercle: their obliquity increases, but they become more slender from the first to the tenth: in the tenth, eleventh, and twelfth dorsal, they become horizontal, shorter, and stronger; and they are broad, square, rectangular, and horizontal in the lumbar region. Lastly, the ridge gradually sinks down in the sacro-coccygeal region, when it ends by dividing into two smaller ridges, leaving between them a furrow, which is continued along the coccyx. We cannot fail to perceive the importance of the most trifling circumstance in the conformation of the spinal ridge, whether examined in reference to physiology or pathology. 1st. In reference to physiology. This ridge must be viewed as the lever of those powers which produce extension. We know that the movements of extension are greatest in the cervical portion, that they scarcely exist in the dorsal, and are again considerable in the lumbar. The interval between the spinous processes measures the extent of motion. The three enlargements above referred to, viz., that of the second cervical vertebra, that of the seventh cervical and first dorsal, and that of the twelfth dorsal and first lumbar, explain these movements. The first is for the articulation of the particular movements of the head, the second for the movements of the neck, and the third for the insertion of the extensor muscles of the loins. 2d. In reference to pathology. The spinal ridge being the only part of the vertebral column which we can see or feel in the living subject, it is clearly of the greatest importance to study the slightest differences which it presents, because it is thus alone that we are able to judge of the extent of deviation in the column; and yet the indications it affords are not absolutely certain, because the pedicles of the vertebræ being susceptible of torsion, a curvature may exist in the bodies of the vertebræ without any corresponding alteration of the spinous processes.

2. *On each side* of this median ridge are two grooves, broad and shallow in the cervical, broad and deep in the upper part of the dorsal region, contracted at the lower part of the back, enlarged again in the loins and at the base of the sacrum, contracted, and finally obliterated, at the lower part of this bone. These grooves are filled by a muscular mass, which, in robust individuals, projects beyond the spine, while in those who are emaciated the ridge forms the most prominent part.

Lateral Surfaces.—These present, 1. In front, the sides of the bodies of the vertebræ and their transverse grooves, which are deeper at the sides than in front, also deeper in the loins than in the neck and back; 2. In the dorsal region, facettes for the costo-vertebral articulations; 3. Still more posteriorly, the *intervertebral foramina*, equal in number to that of the vertebræ. The largest of these foramina is the one situated between the fourth and fifth lumbar vertebræ: from this point they gradually diminish in size to the upper part of the back: in the cervical region, again, they are somewhat larger; and in the sacro-coccygeal they are double, with an anterior and a posterior opening,* in consequence of the lateral conjunction of the false vertebræ of the sacrum. In general, their dimensions are in proportion to the size of the veins which communicate between the intra and the extra vertebral venous system. Between these foramina are the transverse processes, which contribute to form the sides of the posterior grooves, and, between the transverse processes, the articulating processes are visible.

The *base and the summit* of the vertebral column have been already considered, in the special description of the atlas and the fifth lumbar vertebra.

Vertebral Canal.—This canal, into which the intervertebral foramina open, follows all the curves of the spinal column, but does not altogether correspond in shape with its external figure. It may be even said that its dimensions, at different heights, bear an inverse proportion to those of the column; thus, while the canal is most capacious in the neck, the column, on the other hand, is largest in the loins. It has been said that the widest portions of the canal correspond with the enlargements of the spinal cord: but this is not correct. The capacity of the canal is proportioned to the mobility of the respective portion of the column, so that, in the most extensive movements, the spinal marrow is effectually guarded from compression: thus it is largest in the neck and loins, and smallest in the back and sacrum.†

* [The foramina which lead from the sacred canal are single at their internal orifices, though, for the reason given in the text, they open externally by two orifices. It is the internal orifice which answers to the intervertebral foramen of the other vertebræ.]

† In the *Philos. Trans.*, 1822, Mr. Earl has published a paper to establish this fact from observation in comparative anatomy.

The canal is almost equally well protected in front and behind: anteriorly by the bodies of the vertebræ, posteriorly by the spinous processes, which, as it were, ward off mischief from the spinal canal. Laterally it is defended by the articular and transverse processes. Behind, on each side of the median ridge, it is protected by the laminæ, the intervals of which are filled up by what are named the *yellow ligaments*. Any loss of security occasioned by the existence of these yellow ligaments is compensated by the following circumstances: 1. The ligaments are very short, so that the edges of the laminæ are almost contiguous. 2. In the neck, where the intervals are greatest, the laminæ are so inclined, that the inferior border of the one above overlaps the superior border of the one below. 3. In the loins, where the intervals are nearly as great, the laminæ are small, and their place is in a great measure occupied by the lateral masses and the pedicles, which are proportionally increased in development. It is impossible for an instrument to penetrate into the canal in the lumbar region, excepting between the spinous processes. The same difficulty exists in the cervical region during extension, on account of the imbrication of the laminæ. During forcible flexion, however, an instrument may enter between them, when directed from below upward.

Internal Structure of the Vertebræ.

Excepting the thin external layer of compact tissue, the bodies of the vertebræ are almost entirely composed of open, spongy texture. The different processes, on the other hand, have a considerable quantity of compact tissue; but, in all places where they undergo any enlargement, they are cellular. The laminæ are formed almost exclusively of compact tissue. This abundance of the spongy tissue explains the fact of the weight of the spinal column being so inconsiderable in proportion to its size.

The venous canals are larger in the vertebræ than in any other bones. They are, for the most part, arranged within the body of the bone in the following manner: A single canal, directed horizontally, and from behind forward, commences at the posterior surface of the body of the vertebra; at the distance of a few lines from its commencement, it divides into two, three, or four canals, which diverge from each other, and terminate partly upon the anterior surface of the bone, partly in the cells in its interior; all these canals are lined by a thin layer of compact tissue, and perforated by foramina.

Development.

The development of the vertebral column comprises, 1. That of the vertebræ in general; 2. That of certain vertebræ which differ from the rest; and, 3. That of the column considered as a whole.

Development of the Vertebræ in general.—Each vertebra is developed at first from three points of ossification,* viz., one median for the body, and two lateral for the rest of the vertebral ring. To these primitive points are added, at different periods, five secondary or epiphysary points, viz., one for the summit of each transverse process, one for the summit of the spinous process, and two for the body, the one on the superior surface, the other on the inferior surface, where they form two very thin plates, so that at one time the body of every vertebra of the spine is, in fact, a triple disk. Lastly, there is a complementary point for each apophysary tubercle of the lumbar vertebræ, which gives to this class of vertebræ seven secondary points of ossification.

The first osseous points generally appear in the laminæ; they precede, by some days, the deposition of bone in the bodies. This law, however, as Béclard has remarked, is by no means general.

The first ossific points are visible from the fortieth to the fiftieth day; that in the body occupies the centre of the cartilage, under the form of an osseous granule, which extends horizontally, so as to present a lenticular aspect. The points of ossification of the laminæ appear in the situation of the future transverse and articular processes.

The complementary osseous points are not formed until the fifteenth or eighteenth year. Sometimes, however, as Bichât has observed, the point for the summit of the spinous process is included among the primitive nuclei, and in such cases it is situated at the place where that process becomes continuous with the laminæ.

The lateral osseous points are always united together before joining the body of the bone: this union commences about a year after birth; they are not united with that of the body until about four years and a half. The lateral points are so joined to the central one that they form the sides of the body, and in the cervical region, from their more rapid increase, they constitute of themselves fully two fifths of the body of the vertebra. It is, then, on the body of the vertebra, or on what is essentially the *articular* part of the bone, that the three primitive points are united together. The epiphysary points of the transverse and spinous processes are joined to the rest from the twentieth to the twenty-fifth year; the union of the epiphysary laminæ of the bodies is not completed until from the twenty-fifth to the thirtieth year.

* Some anatomists admit two primitive points for the body of the vertebra. It would exceed our limits to give an account of the discussions to which this question of osteogeny has given rise.

Development of particular Vertebræ.—Those vertebræ which present great differences of form present striking differences, also, in their mode of development; such are the atlas, axis, seventh cervical vertebra, first lumbar, and those which constitute the sacrum and coccyx.

Atlas.—Modern anatomists admit five or six points of ossification for this bone; one or two for the anterior arch, two for the lateral masses, and two for the posterior arch. I have never observed more than two lateral points, the same point belonging at once to the lateral masses, and half of the arch on each side. They appear in the following order: those for the posterior arch make their appearance from the fortieth to the fiftieth day; those for the anterior arch not until during the first year after birth. The two osseous points of the posterior arch unite together, those of the anterior arch do the same, and then the anterior is united to the posterior arch.

Axis.—There are often two osseous points for the body of this bone, and always two lateral ones for the odontoid process: it has, therefore, in all, five or six points, viz., two for the laminæ or posterior arch, one or two for the body, and two for the odontoid process. Meckel and Nesbit admit one other nucleus between the odontoid process and the body, which appears in the course of the first year after birth. The points in the laminæ appear from the fortieth to the fiftieth day; those in the body during the sixth month; and those in the odontoid process, a short time after. At birth the body of the axis is proportionally more developed than that of the other vertebræ. The union of its several parts takes place in the following order: the two laminæ are joined together shortly after birth; the two points of the odontoid process remain distinct during the whole of the first year; the body and the odontoid process are united in the course of the third year; and the laminæ and the body during the fourth or fifth year.

Seventh Cervical Vertebra.—Independently of the osseous points common to all the vertebræ, this bone has two others situated on each side of the body in the cartilage which forms the anterior half of the transverse process. The existence of this point, which was described by Hunauld, but which does not appear to me to be constant, establishes an analogy between the transverse processes of the cervical vertebræ and the ribs; it represents in a rudimentary state the permanent cervical ribs of some animals; and explains an anomaly which is not very uncommon in the human subject, viz., the existence of a supernumerary cervical rib.

First Lumbar Vertebra.—Its transverse process is sometimes developed by a point which remains separate from the body of the bone, and forms a *supernumerary lumbar rib.*

Development of the Sacrum and Coccyx.—The first three sacral vertebræ each present five primitive points, viz., one for the body, two for the laminæ, and two for the anterior portion of the lateral masses. The last two sacral vertebræ have only three points.

Each of the coccygeal vertebræ is developed from one point only, but it is not uncommon to see the first two formed by two lateral points, which subsequently unite in the median line: there are, therefore, twenty-one primitive points in the sacrum, and four in the coccyx. Subsequently two epiphysary laminæ are formed for the body of each sacral vertebra, making ten new complementary osseous points. At a still later period two laminæ are developed, one on each side of the sacrum, corresponding with the auricular surface, so that the whole number of osseous points in the sacrum is thirty-three.

Ossification proceeds more slowly in the sacral and coccygeal vertebræ than in the others: it commences in the body, the first points appearing from the second to the third month in the first three sacral vertebræ, from the fifth to the sixth month in the fourth and fifth vertebræ; the laminæ begin to ossify in the interval between the sixth and ninth month: the first vertebra of the coccyx usually begins to ossify during the first year after birth; the second, from the fifth to the tenth; the third, from the tenth to the fifteenth; and the fourth, from the fifteenth to the twentieth year.

The union of the osseous points takes place at different times; the osseous pieces of each vertebra are first joined together, and subsequently the vertebræ themselves.

1. *Union of the Osseous Nuclei of each Vertebra.*—The osseous points of the laminæ are first united; these then join with the anterior lateral nuclei of the first three vertebræ: at a much later period the lateral masses become connected with the body.

The union of the lateral masses with the body takes place much earlier in the fourth and fifth sacral vertebræ than in the three others, though these latter first showed osseous points. After the union of the lateral masses, the sacrum is composed of five pieces, which remain separate until the fifteenth year.

2. *Union of the Sacral Vertebræ with one another.*—This process commences between the fifteenth and eighteenth year, at which time the epiphysary laminæ of the bodies of the sacral vertebræ are developed. At the age of twenty-five the epiphysary laminæ of the iliac surface of the sacrum are developed. The union commences with the lower vertebræ, and proceeds upward. The first is not completely joined to the others until from the twenty-fifth to the thirtieth year.

The union of the body of each vertebra with its epiphysary laminæ proceeds from the circumference to the centre, so that, in a vertical section of a sacrum, which is completely ossified externally, we often find an intermediate lamina of cartilage. I have

observed this cartilage between the first and second sacral vertebræ in subjects of a very advanced age.

The union of the pieces of the coccyx takes place sooner than those of the sacrum. It commences with the first two pieces; the third and fourth then follow; and, in the last place, the second and third are united. Towards the fortieth or fiftieth, or sometimes the sixtieth year, the coccyx becomes united to the sacrum. This junction is later in the female than in the male; sometimes it never takes place.

Development of the Spine in general.—Up to the end of the first month of conception, the length of the spine is commensurate with that of the body, the extremities as yet only existing under the form of small tubercles. This disproportion between the spine and members is gradually effaced by the elongation of the limbs, so that at birth the vertebral column does not constitute more than three fifths of the height of the subject. In the adult it forms only two fifths.

All the parts which concur in forming the canal for the defence of the spinal cord are developed prior to those which are specially devoted to locomotion, as is shown in the development of the laminæ, as compared with that of the body and processes. The ossification of the laminæ proceeds in regular succession from above downward, from the neck to the sacro-coccygeal region. The ossification of the bodies takes a different course, commencing in the dorsal region as a centre, and proceeding to either extremity of the column. The ossification of the bodies of the vertebræ commences in the centre of the bone, and accordingly, if the spine of a fœtus be dried, the cartilages shrink, and the series of osseous nodules, which represent the bodies of the vertebræ, look like grains of Indian corn strung together.

In the first periods of its development, the spinal column presents the following remarkable differences from its subsequent condition. It is completely devoid of curvature, and instead of resembling in shape a pyramid with the base below, it is precisely the reverse, the base of the pyramid being uppermost. As the child grows up, the spine gradually acquires those characters which it presents in the adult. In the old subject it is always more or less bent forward. It is not uncommon to meet with several dorsal or lumber vertebræ more or less completely united by a layer of bone, which forms a sort of sheath or clasp. To this I have applied the name of anchylosis by invagination.

THE SCULL.

Composed of the Cranium and Face.—Cranial Bones.—Occipital.—Frontal.—Sphenoid.—Ethmoid.—Parietal.—Temporal.—The Cranium in general.—Development.—Bones of the Face.—Superior Maxillary.—Palate.—Malar.—Nasal.—Lachrymal.—Inferior Turbinated.—Vomer.—Inferior Maxillary.—The Face in general.—Cavities.—Development.

The scull is the most complicated portion of the skeleton. It has been more minutely investigated than any other part, probably on account of the difficulty of the study. It is composed of two distinct portions: one, *the cranium*, designed to enclose and protect the brain; the other, *the face*, which affords lodgment to almost all the organs of the senses, and, at the same time, is employed in the function of mastication.

The Cranium.

The cranium (κράνος, a helmet) is a round osseous case, composed of eight bones, that is, of eight pieces, distinct and separable after the complete development of the skeleton. Four of these are single, and placed on the median line, viz. (counting from behind forward), the *occipital*, the *sphenoid*, the *ethmoid*, and the *frontal*; the remaining four are in pairs, and are situated laterally, viz., the two *parietal* and *the two temporal*. To these must be added the two small supernumerary bones denominated *ossa wormiana*, or *triquetra*.

The Occipital Bone (figs. 9 and 10).

The occipital bone occupies the posterior, inferior, and middle portion of the cranium, a great part of the base of which it constitutes.* Below it is articulated with the vertebral column; in front with the sphenoid; and it is, as it were, wedged in between the parietal and temporal bones of the right and left sides. It is broad and symmetrical; in shape, an irregular segment of a spheroid, notched round the circumference. It has *an anterior* and a *posterior surface*, and a *circumference* having *four borders* and *four angles*.

The *posterior or cutaneous surface* (*fig.* 9) is convex, and presents the *inferior orifice of the occipital foramen* (1, *fig.* 9; *d*, *fig.* 21), (foramen magnum), the largest of all the foramina in the skeleton, excepting the *sub-pubic*, or *obturator foramen* of the os innomina-

* It is the *os proræ* of Fabricius of Aquapendente, who, following out the same metaphor, has given the name of *os puppis* to the frontal, and *os carinæ* to the sphenoid.

tum. It gives passage to the spinal marrow with its envelopes, the spinal accessory nerves, and vertebral arteries. In front of the foramen is the inferior surface of the basilar process (2, *fig.* 9; *n*, *fig.* 21), which forms the bony roof of the pharynx; it is placed horizontally, is rough, and has a ridge in the median line, more or less prominent in different subjects. Behind the foramen, and in the median line, is the *external occipital ridge* (*perpendicular spine*) (3 4, *fig.* 9; *c a*, *fig.* 21), extending from the posterior edge of the foramen to the *external occipital protuberance*. This projection is wanting in some individuals, and in others its place is occupied by a depression. On each side of the ridge are unequal surfaces, bounded above by a line, with the concavity looking downward. Thus, the *superior semicircular line* (5 5, *fig.* 9; *a b*, *fig.* 21) commences at the occipital protuberance (4, *fig.* 9; *a*, *fig.* 20), and proceeds horizontally outward. The irregular surface included between this line and the foramen is again divided by a line whose concavity is directed upward (6 6, *fig.* 9), and which is called the *inferior semicircular line*. These lines and these inequalities are destined to receive the insertion of a great number of muscles.

Fig. 9.

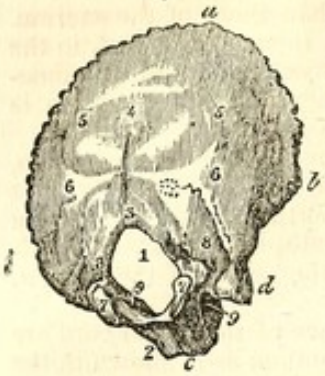

On each side of the occipital foramen, and towards the fore part, are the *condyles* (7 7, *fig.* 9; *e*, *fig.* 21), two articular eminences, convex, elliptical, directed from behind forward, and from without inward, their surfaces looking downward, and somewhat outward. They articulate with the atlas. Behind these are two fossæ: the *posterior condyloid*, which are often perforated by an aperture; the *posterior condyloid foramen* (8, *figs.* 9 and 21), giving passage to a vein. In front, and external to the condyles, are the *anterior condyloid fossæ* and *foramina* (9 9, *fig.* 9); the latter are really flexuous canals, through which the hypoglossal nerves pass out of the scull. External to the condyles is a rough surface, the *jugular surface* (*i*, *fig.* 21), which gives attachment to the *recti laterales* muscles of the head.

The *anterior internal* or *encephalic surface* (*fig.* 10), in common with all the other bones of the cranium, is lined by the dura mater. It presents, 1. *The internal orifice of the occipital foramen* (1, *fig.* 10), which is larger than the external. 2. Before the foramen the *basilar groove* (2), sloping gently from above downward and backward: the sides of the groove are marked by other very small grooves, which concur in forming the *inferior petrosal groove*. 3. On each side of the occipital foramen, and towards the fore part, is a projection (3 3) which corresponds with the condyle, and particularly with the anterior condyloid canal. 4. A little more external and posterior is a small portion of a groove (4), which contributes to form the termination of the lateral sinus. 5. Behind the foramen are the four *occipital fossæ*, two *superior* or *cerebral* (5 5), and two *inferior* or *cerebellar* (6 6), separated from each other by a crucial ridge. The vertical branch of this ridge (*g a*) joins the termination of the sagittal groove above; below it is formed by the *internal occipital crest* (7). The horizontal branches (*g b*) correspond with the grooves for the *lateral sinuses of the dura mater*. The *internal occipital protuberance* (*g*) is situated at the confluence of the four branches. The right and left lateral grooves are rarely of the same size and depth; the right is generally the larger, and forms by itself the continuation of the sagittal or longitudinal groove.

Fig. 10.

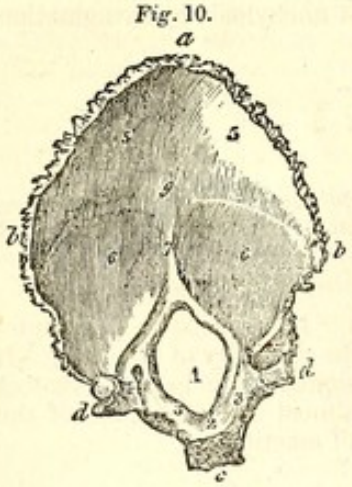

The *circumference* presents four borders and four angles. *The superior* or *parietal borders* (*a b*, *a b*), which are remarkable for the length of their indentations, articulate with the posterior borders of the parietal bones forming the lamdoidal suture.

The *inferior* or *temporal borders* (*b c*, *b c*) are divided into two equal portions by the *jugular eminence* (*d*), which articulates with the temporal bone. This eminence, in most subjects small, in some instances is largely developed, so as to form a true jugular process. I have seen this process articulated to the transverse process of the atlas. The part (*b d*) above this eminence is slightly denticulated, and united to the mastoid portion of the temporal bone; the part (*d c*) below is thick, sinuous, but without indentations, and articulates, by juxtaposition, with the petrous portion of the temporal. In front of the jugular eminence is a deep notch, sometimes divided into two parts by a process of bone, which contributes to form the *foramen lacerum posterius*.

The *superior angle* (*a*) is acute, and is received into the retreating angle formed by the posterior borders of the parietal bones. Its place is sometimes supplied by a Wormian bone. In the young subject, the *posterior fontanelle* is placed here. The *inferior angle* (*c*) is truncated, and very thick; it forms the *basilar process*, which presents a rough articular surface for union with the body of the sphenoid. The connexion is established

by means of a cartilage, which becomes ossified at a very early period, so that many anatomists describe the sphenoid and occipital as one bone.*

The *lateral angles* (*b b*) are very obtuse, and are received into the retiring angle formed by the union of the parietal with the temporal bone. At these angles the *lateral and posterior fontanelles* are situated.

Connexions.—The occipital articulates with six bones; the two parietal, the two temporal, the sphenoid, and the atlas.

Structure.—The part of this bone which forms the occipital fossæ consists almost exclusively of compact tissue. It is here extremely thin, especially at the inferior fossæ. In the rest of its extent there is spongy tissue between the two tables. The external table is much thicker and less brittle than the internal, which is named *vitreous*, on account of its fragility. The spongy tissue is very abundant in the condyles and in the basilar process.

Development.—The occipital bone is developed from four points: one for the squamous portion, that is, the part of the bone behind the foramen magnum; one for each lateral condyloid portion of the occipital, and one for the anterior or basilar portion. These four parts are considered by some anatomists as so many distinct bones, which they describe under the names of posterior or superior occipital, lateral occipitals, and anterior occipital or basilar bone. The first point of ossification appears in the squamous or back part of the bone, under the form of a small oblong plate, placed transversely in the situation of the protuberances. I have never seen this piece formed by two lateral points. The part of the bone of which we are speaking is always visible towards the middle of the second month. The condyloid portions make their appearance next, and, lastly, the basilar portion, which I have never seen developed from two lateral points. In a fœtus of two months and a half, the ossified part of this process presented the appearance of a linear streak, situated exactly in the median line, and directed from before backward. The four points of ossification are finally united at the foramen magnum.

Anatomists, however, are not at all agreed respecting the number of points of ossification. Meckel admits eight for the posterior part of the bone, two for the condyles, and one for the basilar process. Béclard, on the other hand, admits only four in the posterior part of the bone. His opinion is founded upon the existence of four fissures or divisions at the circumference of this portion; viz., one at the superior angle, which sometimes gives to the posterior fontanelle the lozenge shape of the anterior; one below, which is nothing more than a slight notch in the back of the foramen magnum; and two on each side, corresponding to the posterior lateral fontanelles. The opinion of Meckel is perhaps grounded upon certain abnormal cases, in which this part of the bone is divided into a considerable number of pieces, resembling so many Wormian bones united by suture.

The Frontal or Coronal Bone (*figs.* 11 and 12).

The frontal bone is situated at the anterior part of the scull, and above the face. It is symmetrical, and represents a considerable segment of a hollow sphere. From its shape it has been compared to a shell. The superior three fourths are curved, placed vertically, but more or less inclined from above downward and forward; the inferior fourth is flat and horizontal. It has an anterior, a posterior, and an inferior surface, and three borders.

The *anterior cutaneous* or *frontal surface* is smooth and convex; there is a suture in the median line in young subjects, which in the adult is obliterated, leaving scarcely any trace of its existence, excepting at its termination below. At this spot there is a prominence named *nasal eminence* or *glabella* (or middle frontal eminence) (1, *fig.* 11).

Fig. 11.

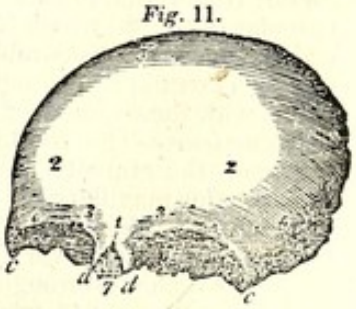

On the sides of the median line, proceeding from above downward, we observe two smooth surfaces; then the *frontal eminences* (2 2), two projections which are most strongly developed in young subjects; and below these, on each side of the glabella, the *superciliary ridge*, an arched elevation which forms the margin of the orbit, and is more prominent towards the nose than externally. Quite at the outside of the anterior surface of the frontal, there is a small, depressed, triangular surface (4), which looks directly outward, and is separated from the frontal eminence by a sort of *crest*, running upward and backward (5): it forms the anterior part of the temporal fossa.

The anterior surface of the frontal bone is separated from the skin by the frontal, orbicular, and corrugator supercilii muscles, and the anterior portion of the cranial aponeurosis.

The *inferior* or *orbito-ethmoidal surface* (*fig.* 12) presents in the middle a large rectan-

* A reference to comparative anatomy would seem to justify this view, for in some inferior animals the basilar process and the sphenoid are but one piece.

Fig. 12.

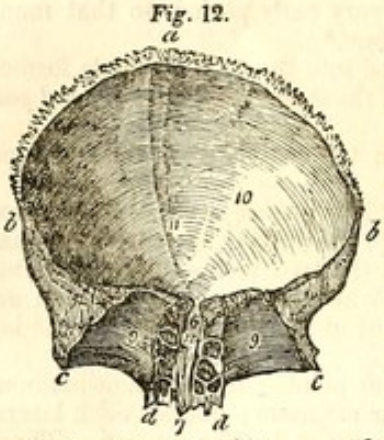

gular notch (6), which extends the whole length of this surface from before backward. This notch, which is named *ethmoidal*, because it receives the ethmoid bone, has, 1. In front, and in the median line, a prolongation, denominated the *nasal spine* (7): this spine is rough in front, for articulation with the proper nasal bones: behind it is marked by two grooves, separated by a vertical ridge; the ridge joins the perpendicular lamella of the ethmoid, and the two grooves form part of the vault of the nasal fossæ. 2. Farther back, and on each side, is the large opening of the frontal sinuses. 3. The two borders of the notch are marked with (*b d*, *b d*) incomplete cells, which join with those of the ethmoid. 4. On the same borders there are two, or sometimes three small grooves, which contribute to form the *anterior and posterior internal orbitary canals.*

On each side of the notch is the *orbital plate* (9 9), triangular and concave, especially towards the external margin, where there is an excavation for the lachrymal gland (*fossa glandulæ lachrymalis*). At the internal margin there is a small depression for the attachment of the cartilaginous pulley, in which the tendon of the superior oblique muscle of the eye is reflected.

The *posterior* or *cerebral surface* is concave, and marked by eminences and depressions corresponding to the sulci and convolutions of the brain, and by furrows for arterial branches. In the median line is a *longitudinal groove*, the sides of which unite below, and form the *frontal ridge*, which terminates in a foramen called *foramen cæcum.* The ridge is sometimes absent, and occasionally the place of the foramen is occupied by a notch, completed by the ethmoid, as already described. On each side of the median line are the *frontal fossæ*, which are deeper than the corresponding eminences on the outside seem to indicate: below are the *orbital prominences*, which look directly upward, *and form a retiring angle** with the frontal fossæ; they are covered with acuminated eminences, which are received into the anfractuosities of the brain.

The *superior* or *parietal border* (*b a b*) is semicircular, denticulated, and cut obliquely at the expense of its internal plate above, and of its external below, and at the sides. In the middle, it forms a very obtuse angle (*a*), which is received into the retiring angle formed by the parietal bones. In young subjects this angle is wanting; in its situation the anterior angle of the anterior fontanelle is placed.

The *inferior* or *sphenoidal border* (*b b b*) is very short, thin, and straight, interrupted by the ethmoidal notch, and adapted to the smaller wings of the sphenoid. It terminates externally at its junction with the superior border, by two triangular surfaces slightly indented, which articulate with the greater wings of the sphenoid.

The *anterior* or *orbito-nasal border* (*c c*, *fig.* 11) presents in the centre the *nasal notch* (*d d*), articulated in the middle with the nasal bones, and at the sides with the ascending processes of the superior maxillæ. At the bottom of this notch is the anterior surface of the nasal spine. On each side we observe the *orbital arch* (*c d*), more sharp and thin towards its outer end. At the junction of the internal with the two external thirds of this arch is situated a foramen (*e*), or, more frequently, a notch converted into a foramen by a ligament; it is called the *superciliary* or *supra-orbital foramen*, and gives passage to the frontal vessels and nerves. At the bottom of this notch there are generally one or more vascular openings, which lead into the diploe, and are the terminations of venous canals, which run for a considerable way within the bone. The orbital arch terminates on each side by a process: the inner one, *internal angular process* (*d*), is broad and thin, and articulates with the os unguis; *the external* (*c*) is thick, and unites with the malar bone.

Connexions.—The frontal is articulated with twelve bones: the two parietal, the sphenoid, the ethmoid, the two nasal and two malar bones, the ossa unguis, and the two superior maxillary.

Internal Structure.—The vertical portion and external orbital processes are very thick; the horizontal part is very thin, and hence the facility with which instruments can penetrate the cranium through the roof of the orbit. It contains large cavities, *frontal sinuses* (*a*, *figs.* 23 and 24), which open in the ethmoidal notch, and add greatly to the thickness of the bone at its lower part. They are separated by a septum, which is often bent to one side, and is generally imperfect. The capacity of these sinuses is very variable; they often extend throughout the whole of the orbital plates, almost to the edge of the sphenoid. The study of these sinuses, which are connected with the organ of smelling, is of great importance in determining the facial angle.

Development.—The frontal bone is developed from two lateral points of ossification, which appear about the middle of the second month, and commence in the orbital arches. At this time the edges are in approximation below, but above are separated by an angular

* This retiring angle measures pretty exactly the facial angle.

interval, which forms the anterior angle of the anterior fontanelle. The two pieces are united by suture during the first year; it is gradually effaced afterward, being longest visible at its inferior termination, though it is uncommon to find it permanent through life. Independently of these general changes which the bone undergoes in the course of its development, there are also certain peculiar alterations in which the sinuses are concerned. These cavities make their appearance during the first year, and gradually increase in size, not only up to the period of manhood, but even to old age.

The Sphenoid Bone (*figs.* 13 and 14).

This bone has received its name from the Greek word σφὴν (a wedge,) because it is inserted like a wedge between the other bones. It is situated at the anterior and middle part of the base of the cranium (*fig.* 23). Almost all anatomists agree in considering it as a separate bone; but Soemmering and Meckel describe it as united with the occipital, under the name of *basilar* or *spheno-occipital bone*. It is a single and symmetrical bone, consisting of a *body* or central part, from which spring, on each side, two horizontal portions, *the greater and lesser wings of the sphenoid*; and below two vertical columns, *the pterygoid processes*. It has been compared to a bat with extended wings. We shall consider it as divided into a body and lateral parts.

Fig. 13.

The *body*, or *central part*, is of a cubical form, and therefore presents six surfaces.

Superior or *cerebral surface* (*o f o d*, *fig.* 13). Proceeding from before backward, we observe, 1. A smooth plane surface (*a*), slightly depressed on each side, over which the olfactory nerves pass. 2. A transverse groove, *optic groove* (*b*), on which the commissure of the optic nerves rests, and which is continuous on each side with the optic foramen (1 1).* 3. A deep quadrilateral fossa (*c*), in which the pituitary gland is lodged, called the *sella turcica*, *supra-sphenoidal*, or *pituitary fossa*. 4. On the sides of this fossa, two grooves, named *cavernous* or *carotid grooves*, because they correspond to the carotid arteries and cavernous sinuses. Anteriorly the cavernous groove gives attachment to the ligament of Zinn, a tendon which gives origin to three muscles of the eye. Near its anterior termination, and between it and the pituitary fossa, is the *middle clinoid process*,† generally nothing more than a simple tubercle, but sometimes sufficiently developed to unite either with the anterior or with the posterior clinoid processes, the former case being the more common. 5. Behind the pituitary fossa we observe a *quadrilateral plate* (*d*), directed obliquely from above downward and backward; its anterior surface forms part of the fossa, its posterior surface is continuous with the basilar groove, its lateral edges are notched for the fourth and sixth pair of nerves, and the superior border, which separates the basilar groove and the pituitary fossa, presents, at each extremity, an angular process (*e*), the *posterior clinoid* (from κλίνη, a bed, from a supposed resemblance of the anterior and posterior clinoid processes to the four corners of a bed). 6. From the lateral and anterior parts of the body of the sphenoid arise two triangular processes (*n o*, *n o*), flattened above and below, extremely thin and fragile, and directed transversely: these are denominated the *orbital* or *lesser wings* of the sphenoid (*alæ minores*), or the *wings of Ingrassius*, from the anatomist who first gave a good description of them. The superior surface of these processes is flat, and corresponds to the anterior lobes of the brain; the inferior surface forms part of the roof of the orbits; the anterior edge is bevelled below, and rests upon the posterior border of the frontal and the ethmoid; the posterior edge is thin and sharp externally, thicker internally, and divides the anterior and middle fossæ of the base of the cranium; the summit (*o*) is pointed, and hence the processes are sometimes called *ensiform* or *xiphoid*; the base presents the internal orifice of the *optic canal* or *foramen* (1), which is directed outward and forward, and gives passage to the optic nerve and the ophthalmic artery. The base of the lesser wing terminates behind in a projecting angle (*n*), which forms the *anterior clinoid process*; and beneath this is a deep notch, sometimes a foramen, for the carotid artery. Occasionally the anterior are united to the posterior clinoid processes by a long bridge of bone.

All the part of the sphenoid in front of the sella turcica, including the smaller wings, forms the *anterior sphenoid* of some modern anatomists. In this portion of the bone the anterior fossæ of the base of the cranium are situated. The remaining portion of the bone, placed inferior to the former, constitutes the *posterior sphenoid*, and in this the middle fossæ are situated. The separation of these two parts, which is but temporary in man, existing only during the early months of fœtal life, is permanent in quadrupeds.

The *inferior* or *guttural surface* of the body (*fig.* 14) presents, in the median line, a ridge or crest, called the *beak of the sphenoid* or *rostrum* (*g*); it is more prominent anteriorly than posteriorly, is received into a groove of the vomer, and is continuous with the

* [The groove is formed on an eminence named the *olivary process*.]

† When the middle clinoid processes are united with the posterior, they are then also joined to the anterior.

Fig. 14.

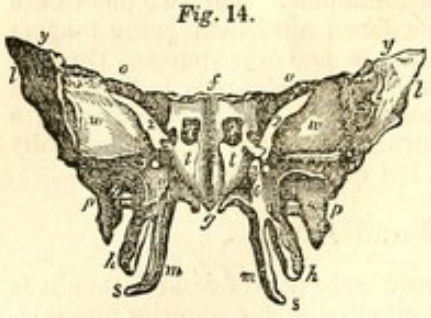

anterior ridge of the body of the bone. On each side is a *deep furrow* concealed by a lamella (on each side of *g*), under which the edges of the vomer are insinuated. At the bottom of this furrow is seen the orifice of a temporary canal, which exists only in young subjects, and which, passing obliquely through the sides of the bone, opens in the sphenoidal fissure. This canal is the trace of the still incomplete union of the anterior and posterior sphenoid; it disappears as soon as the sinuses within the bone are developed. More externally, and on the same surface, is situated a small groove running from before backward, which forms part of the *pterygo-palatine* canal, along which an artery of the same name passes. Still more externally are the *pterygoid processes* (6 *m h*) (*πτέρυξ, ala*), two large projections directed perpendicularly downward. In front their surface is broad above, where it forms part of the pterygo-maxillary fossa, and rough below, for articulation with the palate bone. Behind is a deep fossa, into which the internal pterygoid muscle is inserted: it is named the *pterygoid fossa*, and is formed by two laminæ, named the *external* and *internal pterygoid plates*, of which the *external* (*h*) is the broader, and the *internal* (*m*) the longer. At the upper part of the internal plate is an elliptical depression called the *scaphoid fossa*, which gives attachment to the *circumflexus palati* muscle. The internal surface of the pterygoid process contributes to form the external wall, and posterior opening of the nasal fossa (*h i*, *fig.* 25). The outer surface of the external plate is broad, forms part of the zygomatic fossa, and gives attachment to the external pterygoid muscle. The base of the pterygoid process is pierced from before backward by the *vidian* or *pterygoid canal* (6 6, *fig.* 14); its summit is deeply bifurcated, to receive the tuberosity of the palate bone. The internal branch of this bifurcation (internal pterygoid plate) is very delicate, and is curved into a hook-like process (*s*) (*hamular process*), round which is reflected the tendon of the *circumflexus* or *tensor palati* muscle.

The *anterior* or *ethmoidal surface* of the body of the sphenoid presents, 1. Above and in the median line, a small horizontal projecting angle (*f*, *figs.* 13 and 14), which articulates with the posterior border of the cribriform plate of the ethmoid. 2. Below this, a vertical ridge (*f g*, *fig.* 14), continuous with the septum of the sphenoidal sinuses, and articulating with the perpendicular lamella of the ethmoid. 3. On each side the openings of the sphenoidal sinuses (7 7). These are two in number; they are separated from each other by a septum, which inclines sometimes to the right side, sometimes to the left, and are subdivided into a number of irregular cells. They are wanting in the young subject, but acquire a great size in the adult, occupying the whole body of the sphenoid, and extending into the base of the lesser wings, and even occasionally into the substance of the palate bone. External to the irregular orifice of the sphenoidal sinuses is a rough surface, which articulates above with the lateral masses of the ethmoid, and below with the palate bone. The orifice of the sinus is in a great measure closed by a lamina of very variable shape, curved upon itself, and designated *sphenoidal turbinated*, or *triangular bone* (*cornu sphenoidale, ossiculum Bertini*) (*t t*, and *figs.* 15 and 16, *c c*). This plate, which remains separate for some time, appears as if it arose from the upper part of the palate bone, and formed the anterior and part of the inferior wall of the sinus. It is not unusual to find it united either to the palate bone or to the ethmoid.

The *posterior* or *occipital surface* (*u*, *fig.* 13) is quadrilateral, rugged, and irregular; it articulates with a corresponding surface on the basilar process of the occipital bone, by means of a cartilage, which is very early ossified. On the *posterior aspect* of the bone is situated the posterior orifice of the vidian canal.

The *lateral surfaces* of the body of the sphenoid pass into the base of the *great wings*, which we shall next describe.

Great or *temporal wings* (*y z*). This portion of the bone consists of two large triangular prolongations, on which there are three surfaces: a *superior*, an *anterior*, and an *inferior*; two borders, an *external* and an *internal*; and two extremities, an *anterior* and a *posterior*.

Superior or *cerebral surface* (*y* 2 *z*). This surface, which forms part of the middle fossa of the base of the cranium, is concave, quadrilateral, and marked by cerebral impressions and vascular furrows. Towards its inner part, and proceeding from before backward, we observe, 1. The *superior maxillary foramen* (3), or *foramen rotundum*, directed obliquely forward and outward, which gives passage to the superior maxillary nerve. 2. The *inferior maxillary foramen*, or *foramen ovale* (4), which perforates the bone directly from above downward, and transmits the inferior maxillary nerve. 3. The *foramen spinosum*, or *spheno-spinosum* (5), which is the smallest of the whole, and gives passage to the middle meningeal artery.

External or *temporo-zygomatic surface*. This surface is divided into two parts by a transverse ridge; the superior or temporal (*l*, *fig.* 14) forms part of the fossa of the same name, and gives attachment to the temporal muscle; the inferior (*p*) forms the upper

part of the zygomatic fossa, and gives attachment to the external pterygoid muscle. On this last part we perceive the inferior orifices of the oval and spinous foramina.

Anterior or Orbital Surface.—This surface (*w w*) is four-sided and smooth, and forms the greater part of the external wall of the orbit. Its superior border unites with the frontal bone; the inferior forms part of the *spheno-maxillary fissure*. The internal border contributes to form the *sphenoidal fissure*, and has a small tubercle near its inner termination. The external joins the malar bone.

Internal Border.—This border is convex, and commences in front by a triangular and very rough surface (*y y*, *fig.* 13), which articulates with a corresponding surface on the frontal bone; it then forms part of the *sphenoidal fissure* (2), and finally bends outward, to join the petrous portion of the temporal bone: in this place it is grooved for the lodgment of the cartilaginous portion of the Eustachian tube. The sphenoidal fissure, or *foramen lacerum superius* (2 2, *figs.* 13 and 14), partly formed in the way we have described, is completed by the lesser wing of the sphenoid. Wide at its internal extremity, it becomes narrow at its outer end, where it is closed by the frontal bone at *e*. It gives passage to the third, fourth, the ophthalmic branch of the fifth, and the sixth pair of nerves, to the ophthalmic vein, and to a prolongation of the dura mater. At the internal extremity of the fissure there is a furrow, which is occasionally converted into a foramen for the passage of a recurrent branch of the ophthalmic artery, which goes to the dura mater.

The *external border* is concave, bevelled on the outside superiorly, and on the inside inferiorly, for articulation with the temporal bone.

The *anterior extremity* is very thin (behind *y*, *fig.* 13), and bevelled on the inner side for articulation with the anterior and inferior angle of the parietal.

The *posterior extremity* presents a vertical process (*z*), the *spine* or *spinous process* of the sphenoid, which is received into the angle formed by the union of the squamous and petrous portions of the temporal bone, and gives attachment to the internal lateral ligament of the inferior maxilla, and the external or anterior muscle of the malleus.

Connexions.—The sphenoid articulates with all the bones of the cranium, and with the palatine, vomer, and malar bones of the face.

Structure.—The most remarkable circumstance in the structure of the sphenoid is the presence of the sinuses, which convert the body of the bone into two or more cells (5, *fig.* 22). The compact tissue prevails in the lesser and the greater wings, and in the pterygoid processes, the thick part only of these containing spongy substance.

Development.—In the fœtus, as we have already mentioned, the sphenoid is divided into two quite distinct parts: 1. An anterior sphenoid, consisting of the lesser wings and the portion of the body which supports them; and, 2. A posterior sphenoid, formed of the great wings and the part of the body which corresponds to the sella turcica.

1. The anterior sphenoid is developed from four points of ossification; two for the body, and two for the alæ minores.*

2. The posterior sphenoid is also developed from four points; two for the body, and two for the great wings.

Besides these eight points, there are two others on each side; one for the internal plate of the pterygoid process, and one for the sphenoidal turbinated bone; so that the whole number of centres of ossification of the sphenoid is twelve.

The osseous points of the great wings are the first to appear; they are visible from the fortieth to the forty-fifth day; a short time afterward, those of the lesser wings, which are situated on the outside of the optic foramen. At the end of the second month the osseous points of the body of the posterior sphenoid are distinct; at the end of the third month, those of the body of the anterior sphenoid, and the internal pterygoid plates: the sphenoidal turbinated bones begin to ossify, according to Béclard, in the seventh month of intra-uterine life; according to Bertin, in the second year after birth.

The two points of the body of the posterior sphenoid are united from the third to the fourth month; the great wings are joined to the body in the course of five or six months after birth. The two points of the body of the anterior sphenoid are joined to those of the small wings about the third or fourth month; they then unite together in the median plane from about the eighth to the ninth month. The union of the internal pterygoid plates takes place during the sixth month.† The anterior and posterior sphenoid are united from the eighth to the ninth month. The sphenoidal turbinated bones are not joined to the body of the bone until from the fifteenth to the eighteenth year. The other changes which the sphenoid afterward undergoes are connected with the development of the sinuses. It is united with the occipital bone from the eighteenth to the twenty-fifth year.

* According to Albinus, the anterior sphenoid is formed exclusively by the union of the osseous points of the lesser wings in the median line. Béclard observes, that the process takes place sometimes as described by Albinus, but that occasionally there is a median point; and that at other times there are two points for each of the smaller wings, the internal of which forms the base of the process, and the inner half of the optic foramen; and the external forms, the remainder of the wing. These are the two points which I conceive to form the body of the anterior sphenoid. The very numerous osseous points which some anatomists have described are nothing more than irregular grains, which have been mistaken for constant centres of ossification.

† In the lower animals the two sphenoid bones remain separate during the whole of life. The inner plate of the pterygoid process is also a distinct bone.

The Ethmoid Bone (*figs.* 15 and 16).

The ethmoid is so named from the Greek word ἠθμὸς, a sieve, because it is perforated with a number of foramina; it is placed in the anterior and middle part of the base of the cranium, but belongs rather to the face and nasal fossæ. It is included between the median notch of the orbital part of the frontal and the sphenoid. It is a symmetrical bone of a cuboidal figure, consisting of three parts—*a middle part* or *cribriform plate*, and two *lateral masses*.

Fig. 15.

Cribriform Plate.—This is a lamina situated on the median line, horizontal, quadrilateral, and pierced with numerous foramina. It has two surfaces, and two borders. On the *superior surface* (*a a*, *fig.* 15) we observe in the middle a vertical triangular process, the *crista galli* (*b* and *n*, *fig.* 22); the summit of this eminence gives attachment to the falx cerebri; the anterior border terminates in front in two small processes (*alæ*) (*f*), which articulate with the frontal bone, and often complete the foramen cæcum; the posterior border is very oblique, and is continued to the posterior edge of the cribriform plate by a marked thickening. There are many variations in the size and direction of this process: it is frequently deflected to one side.* On each side is the *ethmoidal groove* (*a*), deeper and narrower in front than behind; it is pierced throughout its whole extent with numerous foramina, which have been very accurately described by Scarpa, and which form two rows; the internal, situated along the base of the crista galli, being the largest. They all transmit filaments of the olfactory nerves; they are funnel-shaped, and are the orifices of canals, which subdivide in traversing the cribriform plate, and terminate in grooves, either upon the turbinated bones or the perpendicular plate of the ethmoid. Among these openings is one which has the form of a longitudinal fissure by the side of the crista galli, and transmits the *ethmoidal* or *nasal branch of the ophthalmic nerve*.

The *inferior surface* of the cribriform plate (*fig.* 16) forms part of the roof of the nasal fossæ; it presents on the median line a vertical plate (*g g*, *fig.* 16), which passes from before backward, and divides it into two equal parts. This is the *perpendicular plate of the ethmoid*, continuous with the base of the crista galli, quadrilateral, often deflected to one side, and forms part of the septum narium (1, 2, 3, 4, *fig.* 22): *in front*, it articulates with the nasal spine of the frontal bone, and with the proper bones of the nose; *behind*, with the anterior crest of the sphenoid; *below*, with the vomer, and the cartilage of the septum; and *above* it is united to the cribriform plate, along the line of the crista galli, which appears to grow out of it. The *anterior border* of the cribriform plate articulates with the frontal. The *posterior* is usually notched for the reception of the spine, or process (*f*, *figs.* 13 and 14), which surmounts the median ridge of the sphenoid.

Fig. 16.

The *lateral masses* are cuboid in figure, and formed of large irregular cells, which together are named the *labyrinth*. They have six surfaces: in the *superior surface* we observe several imperfect cells (*d d*, *fig.* 15), which, in the united state, are completed, and, as it were, roofed in by those we have already described as existing on each side of the ethmoidal notch of the frontal. We find, also, two or three grooves, which join with similar grooves in the frontal bone, and form the internal orbitary canals. On the *inferior surface* we perceive thin, irregularly-twisted laminæ, which narrow the opening of the maxillary sinuses. The most considerable of these has received the name of *unciform* or *great process* of the ethmoid: it is a curved plate which arises from the inferior surface of the transverse septa, which close the anterior ethmoidal cells, and is placed between the anterior extremity of the middle turbinated bone and the *os planum* or *lamina papyracea*, to be afterward described; it sometimes articulates with the inferior turbinated bone. The *anterior surface* presents half cells, which are covered by the os unguis and the ascending process of the maxillary bone. On the *posterior surface* we see the posterior extremities of the superior and middle turbinated bones, and of the superior and middle meatus, and a convex, uneven surface, which corresponds with the posterior ethmoidal cells. This surface articulates with the sphenoid above, and with the palate bone below. The *external surface* is formed by a smooth, quadrilateral plate (*e*, *fig.* 15), placed vertically and very thin, to which the ancients gave the name of *lamina papyracea* or *os planum*. It has an elongated, rectangular form, is slightly curved upon itself, and constitutes a great part of the internal wall of the orbit. The superior border articulates with the frontal, and assists in forming the orifice of the internal orbital canals: the inferior articulates with the maxillary and palate bones, the anterior with the os unguis, and the posterior with the sphenoid and palate bones.

The *internal surface* of the lateral masses constitutes the greatest part of the external wall of the nasal fossæ: on it we observe, in front, a rough, quadrilateral surface, marked

* Morgagni mentions the case of an asthmatic subject, in whom the crista galli was so obliquely placed, that the ethmoidal groove on one side was very much contracted, and considerably enlarged on the other. There was a much greater number of foramina on one side than on the other.

by grooves and canals, which lodge the ramifications of the olfactory nerve; behind, two thin plates, twisted upon themselves like certain shells: they are the *turbinated* or *spongy bones* of the ethmoid, or *conchæ* of the ethmoid. The superior (*b*, *fig.* 35) is the smaller, and is sometimes named *concha of Morgagni*; Bertin has seen it double. The inferior (*c fig.* 37) is larger, and forms the *middle concha*; it articulates by its posterior extremity with the palate bone, and its superior border is continuous with a transverse septum, which stretches across to the lower edge of the os planum, and partially closes the middle or frontal cells. The superior and middle turbinated bones are separated by a horizontal groove called the *superior meatus* of the nasal fossæ (between *b* and *c*, *fig.* 37), at the superior part of which appears an opening of communication with the posterior ethmoidal cells. Below the middle turbinated bone is a similar groove (between *c* and *d*, *fig.* 37) running from before backward, and forming part of the *middle meatus* of the nose. Anteriorly it leads into a cell, the lower part of which is broad and the upper narrow, whence it has received the name of *infundibulum*. This cell communicates directly with the frontal sinuses, and, by a small aperture, with the anterior ethmoidal cells.

Internal Structure.—The ethmoid is composed of extremely thin and fragile plates, arranged in more or less irregular cells, having a hexahedral, pentahedral, or tetrahedral shape. They are disposed in distinct series, which have no communication with each other. The anterior cells are the largest and most numerous; they open into the middle meatus by the infundibulum; the posterior open into the superior meatus. There is a little spongy substance in the crista galli, which is even sometimes hollowed into a small sinus which communicates with the frontal sinuses. There is also spongy substance in the turbinated bones, and here, by a remarkable exception, it occupies the surface. The specific lightness of the ethmoid is such that it floats in water, and its extreme brittleness is readily explained by its spongy structure.

Connexions.—The ethmoid is connected with thirteen bones: the frontal, the sphenoid, the ossa unguis, the superior maxillary, the inferior turbinated, the nasal, the palate bones, and the vomer.

Development.—The ossification of the ethmoid does not commence until the fifth month. It begins in the lateral masses, and more particularly in the os planum; shortly afterward the spongy bones make their appearance. The middle portion is not ossified until after birth. The crista galli and the contiguous part of the perpendicular plate, and the cribriform plate, become bony between the sixth month and the first year. At the end of the first year, the cribriform plate is united to the lateral masses. In the fœtus, at the full time, the lateral masses are so little developed, that their internal and external walls are almost contiguous. The cells are completely formed about the fourth or fifth year.

The Parietal Bones (*figs.* 17 and 18).

The parietal bones are so called because they form the greatest part of the sides of the head. They are two in number, the right and the left; but sometimes in the adult they are united so as to form only one bone. They occupy the summit and sides of the head. In shape they are quadrilateral, and much thicker above than below, so that a force applied to the crown of the head often causes a fracture of the lower parts of these bones. The parietal bones have two faces, four borders, and four angles.

Fig. 17.

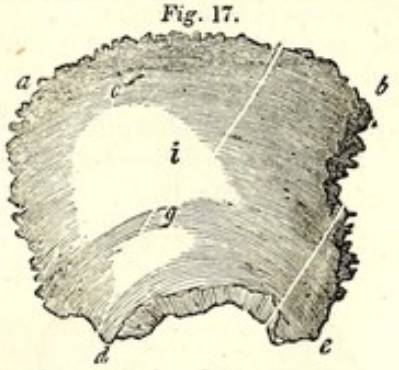

The *external* or *cutaneous surface* (*fig.* 17) is convex and smooth, with a projection in the centre, the *parietal protuberance* (*i*), which is more prominent in the child than in the adult, and corresponds with the point where the breadth of the cranium is greatest. Below this there is a semicircular line (*g*), with the concavity looking downward, which forms the superior boundary of the temporal fossæ, and gives attachment to the temporal aponeurosis; the rest of the surface below this curved line gives attachment to the fibres of the temporal muscle. The rest of this surface is covered only by the cranial aponeurosis and the skin.

The *internal* or *encephalic surface* (*fig.* 18) is concave, and marked with mammillary projections and digital impressions; it is traversed by ramified grooves, resembling the veins of a leaf (*f f*, *fig.* 18), which converge partly to the anterior inferior, and partly to the posterior inferior angle of the bone, and correspond to the branches of the meningeal artery. The *parietal fossa*, a concavity corresponding to the prominence of the same name, is situated in the middle of this surface.

The *superior* or *sagittal border* (*a b*, *fig.* 17 and 18) is the longest: it is thick and denticulated, and, by its union with the opposite bone, forms the sagittal suture. On its internal surface there is a furrow along its whole extent, which, with that in the opposite bone, forms the groove for the longitudinal sinus. Near this border is sometimes

Fig. 18.

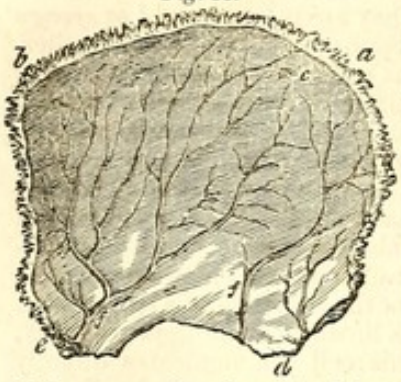

found a foramen (*c*) (*foramen parietale*), of very variable dimensions, which opens into the posterior part of the groove, and transmits a vein which is sometimes very large. We may farther state, that along this surface the impressions made by the pacchionian glands are to be observed. They are more remarkable in the old than young subject.

The *inferior* or *temporal border* (*d e*) is the shortest: it is concave, thin, and very obliquely cut on the outside, so as to resemble a scale with radiated furrows; hence its name (*margo squamosus*): it articulates with the squamous portion of the temporal bone.

The *anterior* or *frontal border* (*b e*) is less thick and less deeply indented than the occipital edge: it is bevelled externally above, and internally below, so as to articulate with the frontal bone, which presents a precisely opposite arrangement.

The *posterior* or *occipital border* (*a d*) is very deeply indented, and articulates with the superior border of the occipital by the lambdoid suture. Of the *four angles*, the two superior are right angles; of the inferior, the *anterior* or *sphenoidal* (*e*) is acute, and rendered very thin by the sloping of the anterior and inferior edges of the bone. Inside this angle is situated the principal furrow, or sometimes canal, which lodges the middle meningeal artery and veins: surgeons, therefore, recommend this angle to be avoided in performing the operation of trepanning. The *posterior* or *mastoid angle* (*d*) is, as it were, truncated, and is received into the retreating angle formed by the union of the mastoid and squamous portions of the temporal bone. Internally, it is grooved for the reception of part of the lateral sinus (*e*, *fig.* 22).

Connexions.—The parietal is articulated with five bones: the frontal, the occipital, the temporal, the sphenoid, and the opposite parietal Above, it is separated from the skin by the cranial aponeurosis only, and consequently it exposes a large extent of surface to the action of external agents: hence fractures of this bone are very common, and they are, more frequently than other fractures, accompanied by effusions of blood, on account of the connexion with the middle meningeal artery and vein.

The *internal structure* is quite similar to that of the frontal. In that bone we find venous canals traversing long tracts in the substance of the diploë.

Development.—The parietal bone is developed from one point of ossification alone, which appears in the situation of the protuberance. Its first traces are observed about the forty-fifth day. The angles are the last parts of the bone which are developed: their absence gives rise to the fontanelles of the cranium.

The Temporal Bones (*figs.* 19 and 20).

The temporal bones are so called from being situated in the locality of the temples. They are two in number, and occupy part of the sides and base of the cranium, below the parietal bones, above the inferior maxillary, in front of the occipital, and behind the sphenoid. The temporal bone contains the complicated apparatus of the organ of hearing.

Its figure is very irregular, and therefore, in order to facilitate the description, we shall consider it as divided into three parts, the *squamous*, the *mastoid*, and the *petrous* portions.

Squamous portion.—The squamous portion has the form of a semicircular scale (*a b c*, *figs.* 19 and 20), bearing a considerable resemblance to one of the valves of certain shell-fish: it occupies the anterior and superior part of the bone. It is by far the thinnest part of the cranium; and hence the common but well-founded notion of the danger of blows upon the temple, although this danger is much lessened by the presence of the zygomatic arch and the temporal muscle.

Fig. 19.

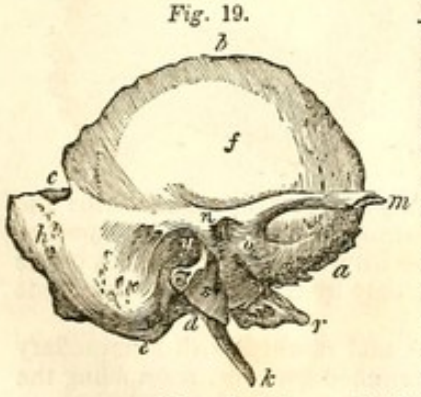

The *external surface* (*f*, *fig.* 19) forms part of the temporal fossa: it is smooth, convex, and marked by vascular furrows. At its lower portion is situated the *zygomatic process* (*m n*) (ζευγνύω, I join), so called because it unites the sides of the cranium to the face: it is also named *ansa capitis*, and is one of the longest processes of the skeleton. At its origin it is broad and directed outward; it then gradually diminishes in size, and bends so as to turn horizontally forward and a little outward: it is flattened from without inward. The external surface is convex, and may be easily traced under the skin; the internal surface is concave; the superior border, which gives attachment to the aponeurosis of the temporal muscle, convex and thin; the inferior, which gives origin to the masseter muscle, concave, thick, and much shorter; and the extremity (*m*) is cut from below upward and forward, and denticulated for attachment with a corresponding surface on the malar bone. The base of this process is

grooved above, and serves as a pulley for the reflection of part of the temporal muscle. Posteriorly, it separates into two portions or *roots*: the *inferior* (*o*) of these is the larger; it is transverse, covered with cartilage, and bounds the glenoid cavity in front, serving also to increase the articular surface in the joint of the lower jaw. The *superior* (*n*) is longitudinal or antero-posterior in its direction: it also is bifurcated, one branch directed upward, and forming part of the temporal semicircular line, the other passing between the auditory meatus and the glenoid cavity. At the point of junction of the two roots there is a tubercle, which gives insertion to the external lateral ligament of the lower jaw. Between the two roots we observe the *glenoid cavity* (behind *o*), divided into two portions: the anterior of which is articular, smooth, and in the fresh state covered with cartilage; the posterior (*s*) does not enter into the formation of the joint. The parts are separated by a fissure, called *glenoidal fissure*, or *fissure of Glasserius* (before *s*), which transmits the corda tympani nerve,* the laxator tympani or external muscle of the malleus, the internal auditory vessels, and lodges the processus gracilis of the malleus (*process of Raw*).

The *internal surface* of the squamous portion (*g*, *fig.* 20) presents a concavity proportionally greater than the convexity on the outside: it is marked by the ordinary inequalities, and is generally traversed, towards the upper part, by a horizontal vascular furrow, running from before backward.

Fig. 20.

The *circumference* (*a b c*) forms about three fourths of a circle; it is very obliquely cut internally in its two posterior thirds, which unite with the parietal; the anterior third is thicker, and bevelled externally: it unites with the sphenoid.

Mastoid Portion (*c e d*, *figs.* 19 and 20).—The mastoid portion is very prominent in adults, but only slightly developed in young subjects: it occupies the posterior and inferior part of the bone.

The *external surface* (*fig.* 19) is convex and rough, terminating below and in front in a nipple-shaped process, the *mastoid process* (*e*). Inside of this is a deep groove called digastric (*fossa digastrica*), because it gives origin to the muscle of that name. Behind the mastoid process we observe the *mastoid foramen*, an opening which transmits the mastoid artery and vein, but which is subject to numerous varieties in its size and position. Above the process is a rough surface, for muscular attachments of the splenius and sterno-cleido mastoideus muscles.

The *internal surface* is concave, and forms part of the lateral and posterior fossæ of the cranium; we observe on this surface a deep and broad semi-cylindrical groove (*h i*, *fig.* 20), which lodges the greater portion of the lateral sinus. At the bottom of this groove the mastoid foramen opens by one or more apertures. There is generally a considerable difference in size between the grooves on the right and left side of the head.

The *circumference*, very thick and indented, unites in front with the circumference of the squamous portion, forming a retiring angle (*c*), which is occupied by the posterior inferior angle of the parietal bone, and then curves round in a semicircle to join the occipital bone by means of a thick, uneven edge.

Petrous Portion; *Rocher* or *Pyramid* (*c i d v*, *fig.* 20) *Petrous Process.*—This part of the bone is placed between the squamous and mastoid portion, resembling a pyramid, projecting forward and inward into the cavity of the cranium. Its name sufficiently indicates the extreme hardness of its osseous structure: a circumstance very important in relation to its functions (for this part of the bone serves as the receptacle of the vibratory apparatus of the ear), and at the same time is calculated to explain the frequency of fractures in this situation. It has the form of a truncated pyramid with three faces, separated by three borders.

The *inferior surface*, which is seen at the base of the cranium, is very irregular, and presents the following objects, in an order from without inward: 1. A long, slender process (*k*), generally from twelve to fifteen lines, sometimes two inches in length. This process, which has been denominated *styloid*, is, in man, usually continuous with the rest of the bone, but occasionally it is articulated by a movable joint, as in the lower animals, where it is always separate, and is known by the name of *styloid bone*.

2. Behind this process, between it and the mastoid, is a sort of fossa, at the bottom of which we find, besides one or two accessory foramina, the *stylo-mastoid foramen* (*y*, *fig.* 21), which forms the inferior aperture of a canal improperly called the *aqueduct of Fallopius*,† which transmits the facial nerve. 3. Inside of the styloid process and the stylo-mastoid foramen is a triangular surface called the *jugular*, which joins with a corresponding part of the occipital bone. 4. A little within and behind the styloid process is a deep depression, which forms part of the *jugular fossa*, and lodges the enlarged commencement or sinus of the jugular vein. 5. The inferior orifice of the *carotid canal* (*v*, *fig.* 21), which is directed at first vertically, then horizontally, running forward and inward, and

* [The corda tympani, according to the author, passes through a special orifice by the side of the glenoid fissure. See description of the ear, *infrà*.]

† [Fallopius knew that this canal transmitted a nerve; he named it *aqueduct* merely on account of its direction.]

again vertically at its termination in the cavity of the cranium. 6. A rough surface, which gives attachment to the levator palati muscle. Lastly, in front of the styloid process is an osseous lamina, in the form of a *vertical crest* (*s*, *fig.* 19), a continuation of the plate which forms both the inferior portion of the auditory canal, and the posterior portion of the glenoid cavity, which it completes. This crest, which has been described by authors under the name of *vaginal process*, because it surrounds the styloid process without adhering to it, extends inward to form part of the carotid canal, and outward to the mastoid process.

The other two surfaces of the petrous portion, of which one is superior and the other posterior, are in the interior of the cranium.

The *superior surface*, which looks forward, has a furrow running from before backward and from below upward, terminating about the middle of the surface in a small irregular opening, the *hiatus Fallopii*, which communicates with the *aqueduct of Fallopius*. The furrow and the hiatus contain the superior or cranial filament of the vidian nerve, and a small artery.

The *posterior surface* shows a canal directed obliquely from within outward and forward. This is the *internal auditory meatus* (*l*, *fig.* 20); it is shorter than the external, and is terminated by a lamina divided into two parts by a transverse ridge; in the superior of these parts there is a single orifice, the commencemnet of the *aqueduct of Fallopius*, which receives the facial nerve; the inferior is perforated by numerous openings, through which the fibres of the auditory nerve pass; it is the cribriform plate of the auditory nerve. Behind the internal auditory meatus is a small opening, which is the orifice of a canal named *aqueductus vestibuli*.

These surfaces of the petrous process are separated by three borders.

On the *superior border* (*m v*) we observe a furrow for the superior petrosal sinus; also a projection which corresponds with the superior semicircular canal of the internal ear, and which is most prominent in the young subject; inside of this projection, a cavity, the depth of which is in the inverse ratio of the age, and is gradually obliterated in the adult, and near the summit a depression, on which the fifth or trifacial nerve rests.

The *anterior* or *sphenoidal border*, in the external half of its extent, is connected with the squamous portion of the bone; at first by a suture which often remains perfect even in adult life, and subsequently in a great measure disappears, but is never completely obliterated. The internal half is free, and forms, by its union with the squamous portion, a retiring angle, at the apex of which are the openings of two canals, placed parallel, like the barrels of a double-barrelled gun, and separated by a small osseous lamina. The *superior canal*, much the smaller, contains the internal muscle of the malleus; the *inferior canal* forms the osseous portion of the *Eustachian tube*. They both communicate with the cavity of the tympanum; the bony lamella, which separates them, is called the *cochleariform process*.

The *inferior*, *posterior*, or *occipital border*, rough, but without indentations, is united to the occipital bone by juxtaposition. It has a deep notch, which forms part of the *foramen lacerum posterius*. This notch, which is continuous with the jugular fossa, already described, is frequently divided into two portions by a tongue of bone, one being anterior, the other posterior. Immediately in front of the notch is a small triangular opening, the *inferior orifice* of the *aqueduct of the cochlea*.

On *the base* (*fig.* 19), which is not distinct from the rest of the bone, the only part to be noticed is the *external auditory meatus* (*y*), which is situated behind the glenoid cavity. It is rough inferiorly for the insertion of the cartilage of the ear; and the canal, which is more contracted in the middle than at either extremity, takes a curved direction, the concavity looking downward and forward: it is chiefly formed by a curved plate, named the *auditory process*, which constitutes the posterior half of the glenoid cavity.

The *summit* of the pars petrosa (*v*, *fig.* 20) is very irregular and truncated: it presents the superior orifice of a carotid canal, and forms part of the *foramen lacerum anterius*.

Connexions.—The temporal articulates with five bones, viz., three of the cranium, the parietal, occipital, and sphenoid; and two of the face, the malar and the inferior maxillary; we might add, also, the os hyoides, which is attached by a ligament to the styloid process.

Internal Structure.—The squamous portion is compact throughout, excepting towards the circumference, where traces of diploë may be seen. The petrous portion is still more compact and hard, resembling in density the teeth, or certain ivory-like exostoses. The mastoid portion is hollowed out into large cells, and is very liable to be affected by caries. In the description of the *organ of hearing* we shall notice the cavities which exist in the petrous portion; the nervous and vascular canals will be described with the nerves and vessels which traverse them. (For the aqueduct of Fallopius, see the description of the Facial Nerve.)

Development.—The temporal bone is developed from five points of ossification: the squamous, petrous, and mastoid portions, the auditory canal, and the styloid process, being each distinct. The first osseous point which appears is situated in the squamous portion, and is visible towards the end of the second month. Immediately afterward

the petrous portion exhibits a bony nucleus, stretching from its base towards its apex. The third point in order is that of the circle of the tympanum, a kind of ring channelled all round for the membrana tympani. This circle, at first almost horizontal, becomes gradually more and more oblique; it is incomplete above, and the two extremities which are applied to the squamous portion cross each other instead of uniting. In many animals the ring of the tympanum constitutes a distinct bone, named the *tympanic bone*. The fourth point of ossification appears in the mastoid portion during the fifth month. The last which becomes visible is that of the styloid process: it also remains distinct throughout life in the lower animals, and is called the *styloid bone*. It is not uncommon to find it in the same condition in the human subject.

The development of these five pieces does not advance with equal rapidity. The petrous portion is most quickly completed. The mastoid, squamous, and petrous portions become united during the first year. The styloid process is attached to the rest of the bone at the age of two or three years; at birth, the glenoid cavity is almost flat, on account of the absence of the auditory canal, and the slight development of the transverse root of the zygomatic process. The ulterior changes which take place in the temporal bone depend on the completion of the auditory canal and glenoid cavity, the increasing size of the mastoid process, and the obliteration of the projections and filling up of the hollows on the surface of the petrous portion.

It is worthy of remark, that traces of the union of the base of the petrous portion with the squamous and mastoid portions, are visible in individuals of the most advanced age.

The Cranium in general.

The different bones which we have described unite in forming the cranium, an osseous cavity which encloses the brain, the cerebellum, and the annular protuberance. It is situated above the face, is the most elevated portion of the skeleton, and forms a continuation of the vertebral column. The form of the cranium is that of an ovoid, flattened below and at the sides, and with the large extremity turned backward. It is never perfectly symmetrical; but a very great deviation has always appeared to me coincident with disease of the brain. From attentive examination of a great number of sculls of idiots and maniacs, I have observed that in these subjects there is a remarkable difference between the two sides.

The *dimensions* of the cranium have been very accurately determined by Bichât. The antero-posterior diameter, measured from the foramen cæcum to the occipital protuberance, is about five inches;* the transverse diameter, measured between the base of the petrous portions of the temporal bones, is *four inches* and a half; the vertical diameter, extending from the anterior edge of the foramen magnum to the middle of the sagittal suture, is rather less than the transverse. In front, and behind the spot where the height and breadth of the cranium are measured, *i. e.*, in front and behind the bases of the petrous bones, the diameters progressively diminish. Hence it follows, that the point where the cranium has the greatest capacity is the junction of the two anterior thirds with the posterior third; that is to say, at the place of meeting, or, if I may use the expression, at the *confluence* of the brain, cerebellum, and spinal marrow.

The cranium, however, presents many varieties, both in regard to its dimensions and shape. The varieties of form of the scull in different individuals appear generally to depend upon the preponderance of one diameter over another; and it may be remarked, that in these cases, where one diameter is much increased, the others are almost invariably diminished in the same proportion, so that the absolute difference in size is by no means considerable.

There are also variations in size and figure peculiar to the crania of different nations, as has been shown by the researches of Blumenbach and Sœmmerring. In the white, or Caucasian race, the cranium is decidedly much larger than in the others, more especially than in the negro. Among certain tribes, the configuration of the cranium is determined by the permanent or frequently-repeated compressions to which the sculls of infants are subjected. It varies also according to age and sex, being proportionally larger in the fœtus than in the adult, and in the male than in the female. It should be remarked that all these varieties are exclusively confined to the vault of the cavity. Since the cranium is exactly moulded upon the brain, great interest has been attached to the exact appreciation of its dimensions, and hence the different measurements which have been adopted for this purpose. The oldest is the one proposed by Camper, under the name of the *facial angle*. This angle is intended to measure the relative proportions of the cranium and face. It is taken by drawing one line from the middle incisors of the upper jaw along the front of the forehead, and another from the same point to the auditory meatus. The angle included between these lines is in the European from 80° to 85°, in the Mongolian race 75°, and in the negro, 70°. This anatomical fact had not escaped the attention of the ancients. We observe that in the statues of their heroes

* [An old Paris inch is =1.065765 inch English.]

and gods they have even exaggerated the facial angle, which is generally 90°, and even more in the case of Jupiter Tonans.

The facial angle gives no information respecting the capacity of the posterior regions of the cranium, and, consequently, Daubenton had this specially in view in his mode of measurement, which bears the name of the *occipital angle of Daubenton*. This, however, like the preceding, and, in fact, all linear measurements applied to the determination of the capacity of the scull, is necessarily inexact. The variable thickness of the walls of the cavity, the greater or less development of the sinuses, and the projection of the alveoli, or their obliteration after loss of the teeth, are all important elements in the estimate, which have been entirely neglected; and, moreover, the facial and the occipital angle can only express the dimensions in one direction. The capacity of a cavity, like the volume of a solid, can only be determined by an estimate of its three dimensions. Hence, measures of surface, and measurements taken in the interior of the cranium, must be employed for this purpose. This is the object proposed by Cuvier, in comparing the *area of the cranium and the area of the face*, cut vertically from before backward.

A section of the cranium represents an oval, with the broad end backward: a section of the face is triangular. In the European, the area of the cranium equals four times that of the face, without the lower jaw; in the negro, the area of the face is increased one fifth. The most general result which can be deduced from a comparison of the cranium and face in man and in mammalia, is that they are developed in an inverse ratio. One appears to augment at the expense of the other.

Division of the Cranium, and Description of its different Regions.

The cranium, considered as one piece, presents *an external surface*, and an *internal*, or *encephalic surface*. Many of the objects seen on these surfaces have been already described with the particular bones to which they belong; these we shall merely point out: others, which result from the union of the bones in one common whole, will be examined more in detail.

External Surface of the Cranium.

The external surface of the cranium offers for consideration a superior region or vault, an inferior, and two lateral regions.

The *superior region* or *vault* is bounded by a circular line, passing from the middle, frontal, or nasal protuberance (*glabella*), along the temporal fossa, to the external occipital protuberance. It is principally covered by the occipito-frontalis muscle, and presents in the median line, 1, the trace of the union of the two primitive halves of the frontal bone; 2, the *bi-parietal* or *sagittal suture* (sagitta, *an arrow*), which forms a right angle, in front, with the *fronto-parietal* or *coronal* suture, and terminates behind at the superior angle of the *occipito-parietal* or *lambdoidal* suture (from the Greek letter lambda).

On each side we observe three eminences, more or less prominent in different individuals, and always most marked in the young. These are the frontal, the parietal, and the superior occipital protuberances. Between the frontal and parietal protuberances, the *coronal* suture is situated; and between the parietal and the occipital, we find the *lambdoid* suture. Besides these, there are a great number of smaller projections, which Gall has also denominated *protuberances*, and to which much importance is attached in his system.

The *inferior region* or *base of the cranium* (*fig.* 21) is flattened and very irregular. It is bounded, behind, by the external occipital protuberance (*a*) and superior semicircular line (*a b*); in front, by the glabella, or nasal eminence; laterally, by a line passing over the mastoid and external orbital processes. I shall content myself by describing in this place the posterior half of the base of the cranium; the other half will be included in the description of the face, with the bones of which it concurs in forming the orbital, nasal, and zygomatic fossæ. The pterygoid processes below, and the posterior edge of the sphenoid above, define the limits of these two portions.

Fig. 21.

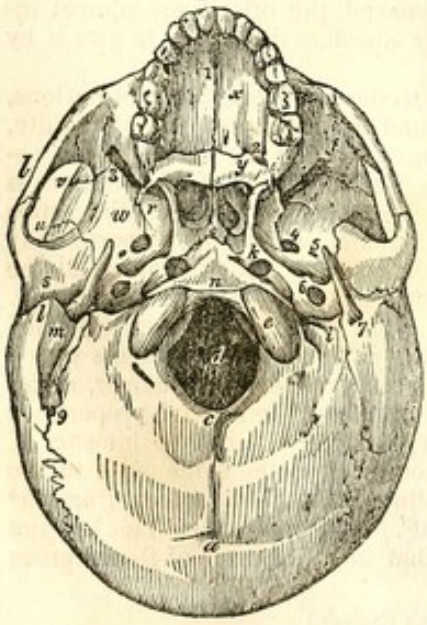

The posterior half of the base of the cranium presents, in the *median line*, and in an order from behind forward, the external occipital protuberance (*a*), the external occipital crest (*a c*), the foramen magnum (*d*), and condyles (*e*), the basilar process (*n*), and the transverse suture, which results from the articulation of the body of the sphenoid with the truncated inferior angle of the occipital bone, the *spheno-occipital suture*.

On *each side* we observe the inferior occipital protuberances, presenting certain variations in size in different subjects, to which Gall has attached great importance in his craniological system. These pro

tuberances are bounded above by the superior semicircular line of the occipital bone (*b*); they are crossed in the middle by the inferior semicircular line (*g*), which is separated from the preceding by muscular impressions. Between the inferior semicircular line and the occipital foramen are also a number of inequalities for the attachment of muscular fibres. Still more anteriorly is the posterior condyloid fossa, and occasionally the posterior condyloid foramen (*g*). Outside the condyles are the jugular surface (*i*), the eminence of the same name, and the *petro-occipital suture*, running obliquely from behind forward and inward (*i k*), without any indentations, or even complete juxtaposition of the bones, and terminating behind in a large irregular opening (before *i*), the *foramen lacerum posterius*, which is divided into two parts by a tongue of bone: the anterior is the smaller, and transmits the eighth pair of nerves; the posterior is larger, and is called the jugular fossa, from its receiving the enlarged commencement (*sinus* or *diverticulum*) of the jugular vein. The petro-occipital suture terminates in front in another irregularly triangular opening, the *foramen lacerum anterius* (*k*), which is closed by cartilage, and forms, in fact, a fontanelle between the edges of the occipital, temporal, and sphenoid bones. In front of the petro-occipital suture is the inferior surface of the petrous bone, with its numerous asperities; then, still proceeding from behind forward, we find the mastoid process (*l*), the digastric groove (*m*), the stylo-mastoid foramen (7), the styloid and vaginal processes, the inferior orifice of the carotid canal (*v*), and the *petro-sphenoidal* suture, at the external termination of which the osseous portion of the Eustachian tube opens by an orifice directed obliquely forward and downward.

Thus all the sutures of the posterior half of the base of the cranium meet in the *foramen lacerum anterius*. From its internal angle, the spheno-occipital suture stretches across to the same part of the opposite foramen. The petro-sphenoidal suture sets out from the external angle, and becomes continuous with the fissure of Glasserius; and the petro-occipital suture extends from the posterior angle to the occipito-mastoid suture, which it joins at an obtuse angle: all these sutures are formed by juxtaposition, and not by mutual reception, as those of the roof of the scull.

The *lateral regions* of the cranium are bounded, behind, by the lambdoid suture; in front, by the external orbital process; and above, by the temporal ridge. This region, more or less rounded in different subjects, is, nevertheless, the flattest part of the vault of the scull. Proceeding from behind forward, we observe, 1, the *mastoid region*, comprehending the mastoid foramen (9, *fig.* 21), the external auditory meatus, the glenoid cavity, and the transverse root of the zygomatic process; 2, the *temporal region* or *fossa*, concave in front, convex behind, bounded below by the zygomatic arch, which projects considerably from the head, more especially in carnivorous animals, and by a ridge which separates it from the zygomatic fossa. The temporal fossa is traversed by numerous sutures, arranged in the following manner: The *fronto-parietal* or *coronal suture* (*c b*, *fig.* 22) descends vertically; from its inferior extremity two others proceed, one in front, the *spheno-frontal*, the other behind, the *spheno-parietal*. Each of these soon divides into two branches. From the spheno-parietal the *spheno-temporal* descends, and terminates in the fissure of Glasserius; the *temporo-parietal* (*b i d*) passes horizontally, and becomes continuous with the lambdoidal suture (*d f*). The spheno-temporal and temporo-parietal sutures are, each, part of the *squamous suture*. From the spheno-frontal suture the two following proceed: the *fronto-jugal*,* running horizontally, and the *spheno-jugal*, which passes downward; the denominations of these sutures indicate at once the bones by which they are formed. The explanation which we have given appears the most likely to facilitate the recollection of these numerous sutures, by connecting them with each other. The following table exhibits a summary of all that has been stated:

Fronto-parietal suture	Spheno-parietal	Spheno-temporal. Temporo-parietal.
	Spheno-frontal	Fronto-jugal Spheno-jugal.

All these sutures are remarkable, from the circumstance that the bones which enter into their formation are cut obliquely like scales, and for the most part the edge of the bone above is overlapped by the edge of the bone below, so that each inferior scale, like the abutment of an arch, prevents the superior one which corresponds to it from being forced outward. (Vide *Mechanism of the Cranium.* SYNDESMOLOGY.)

Internal Surface of the Cranium.

In order to examine the internal surface of the cranium, it is necessary to make two sections, one horizontally from the occipital protuberance to the glabella (*fig.* 23), the other vertically along the median line from before backward (*fig.* 22).

In the *median line*, proceeding from before backward, we observe the frontal crest or ridge, and the *longitudinal groove*, stretching from the frontal crest, along the roof of the scull to the internal occipital protuberance. In this groove, which is of no great depth, we find a line which indicates the place of union of the two pieces of the frontal bone during the early

* The malar bone is often called the jugal bone, and hence the names of fronto-jugal and spheno-jugal.

Fig. 22.

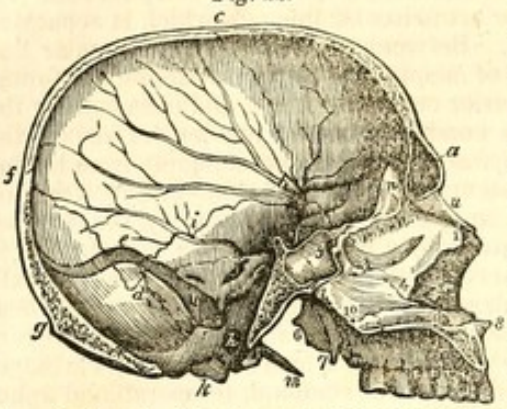

periods of life, and the internal surface of the sagittal suture. It receives the superior longitudinal sinus in its entire extent, and contains the internal orifices of the parietal foramina.

On *each side* are the frontal fossæ, corresponding to the protuberances of the same name, and the internal surface of the fronto-parietal (coronal) suture (*b c*, *fig.* 22); the encephalic surface of the parietal bone (*b d f c*), and the parietal fossa; the lambdoid suture (*d f*), and the superior occipital fossa. We may remark that the *fossæ* are deeper than would seem to be indicated by the external prominences, because they are partly formed at the expense of the bone itself; and that the *sutures* are less deeply denticulated on their internal than on their external aspect.

Lastly, the whole internal surface of the vault of the cranium, but especially that of the parietal bones, is traversed by ramified grooves (*b i*), partly for veins, partly for arteries; the venous grooves, which are not perceptible in all subjects, but which are very large in some, are distinguished from the arterial, as M. Breschet has pointed out, by their being perforated by numerous foramina.

The *base of the cranium* (*fig.* 23), presents three series of fossæ, or three regions, arranged, as it were, in steps upon an inclined plane, from before backward, and from above downward. They are described as the anterior, middle, and posterior regions.

Anterior or *ethmoido-frontal region.* In this region we observe, in the middle, the *ethmoidal fossa*, in which is the foramen cæcum; the crista galli (*a*); the ethmoidal grooves, and the foramina with which they are perforated; the ethmoidal fissure, for the ethmoidal or nasal branch of the ophthalmic nerve; the *ethmoido-frontal sutures*, running from before backward; the orifices of the internal orbitary foramina; and the trace of the *ethmo-sphenoidal suture*, running transversely. Behind the ethmoidal fossa, the surface of the sphenoid is slightly impressed by the passage forward of the olfactory nerves.

Fig. 23.

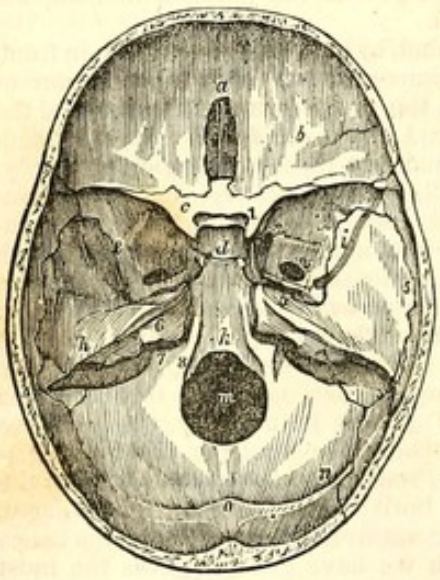

Laterally, we see the orbital plates (*b*), remarkable for the prominence of their mammillary projections, and traversed by small grooves for the ramifications of the middle meningeal artery; and the *fronto-sphenoidal sutures* (before *c*), which mark the union of the lesser wings of the sphenoid (*c*), with the orbital portion of the frontal bone (*b*). The orbital plates support the anterior lobes of the brain.

The *middle region* exhibits in the centre a fossa, in which we observe the depression for the olfactory nerves, the optic groove, and olivary process (before *d*); the *pituitary fossa* (*d*), deeply excavated behind; the quadrilateral plate (behind *d*); the cavernous grooves; and the anterior and posterior clinoid processes. On *the sides* we find very deep fossæ, which correspond with the middle lobes of the brain, called *middle lateral fossæ* of the base of the cranium; they are broad externally, narrow internally, and are bounded in front by the posterior edge of the lesser wings of the sphenoid (*c*), and behind by the superior border of the petrous portion of the temporal bone (*h*). They are formed by the superior surface of the petrous portion, the internal surface of the squamous portion of the temporal, and the superior surface of the great wings of the sphenoid. They present, successively from before backward, the sphenoidal fissure (or foramen lacerum orbitale); the foramen rotundum, or superior maxillary (2); the foramen ovale (3); the foramen spinosum (4); the internal orifices of the foramen lacerum anterius and carotid canal (before 5), and the hiatus Fallopii. We see here, also, the union of the sphenoid with the squamous and petrous portions of the temporal bone, forming the *spheno-temporal* (*i* and *e*) and *petro-sphenoidal sutures*. This fossa is traversed from behind forward and outward by a groove (*i* 4), which commences at the foramen spinosum, passes along the external border of the sphenoid, or, rather, is hollowed out from the spheno-temporal suture, and divides into two branches; the anterior, the larger, proceeds to the anterior inferior angle of the parietal bone, with the anterior ramified groove in which it becomes continuous; the posterior is directed horizontally backward to the posterior inferior angle of the parietal bone. In some cases, the portion of the groove which extends from the foramen spinosum to the summit of the lesser wing of the sphenoid, almost equals in diameter the lateral grooves, and it is then almost always pierced by foramina: it contains the middle meningeal artery, and a large vein.

Posterior region of the base of the cranium. This region presents in the middle the basilar groove (*k*); *the spheno-occipital suture*, the foramen magnum (*m*), the anterior condyloid foramina (8) (*h*, *fig.* 22), the internal occipital ridge, and protuberance (*o*, *fig.* 21). Laterally, the *inferior occipital fossæ*, the deepest in the scull, which are formed by the posterior surface of the petrous portion of the temporal bone, almost the whole of the encephalic surface of the occipital bone, and the posterior inferior angle of the parietal. We find here the *foramen lacerum posterius* (7), the suture which unites the temporal to the occipital bone, and along the petro-occipital suture, a small groove named *inferior petrosal* (on each side of *k*).

The inferior occipital fossa is bounded above by a broad and deep groove (*n*), intended to lodge the lateral sinus, and called the *lateral groove*. It commences at the internal occipital protuberance (*o*), and proceeds horizontally outward to the base of the petrous portion, where it is again enlarged, and passes round, extending downward and inward along the occipital fossa, until it arrives at the occipito-mastoid suture (*r*), where it rises and terminates in the foramen lacerum posterius. The inferior occipital fossa is divided into two parts by this groove: an anterior, formed by the posterior face of the pars petrosa, and a posterior, formed by the occipital bone. In this groove, the *mastoid foramen*, the *posterior condyloid foramen*, when it exists, and the *superior and inferior petrosal grooves* open.

The dimensions of the lateral grooves are extremely variable; most commonly the left is smaller and shallower than the right, especially in its horizontal portion.

Of the eminences and depressions on the internal surface of the cranium, the most deeply marked are those situated upon the base. This is more especially the case with regard to the orbital plates and the middle and lateral fossæ. Since the publication of the works of Gall and Spurzheim, anatomists have re-adopted the opinion of the ancients, who regarded these eminences and depressions as corresponding respectively with the anfractuosities and the convolutions of the brain: the cranium, in fact, is moulded upon the brain; to be convinced of which, it is only necessary to repeat the following experiment, which I have often made for this purpose. Remove the brain from the cavity of the cranium, and supply its place by plaster of Paris; when dry, this substance will present a faithful model of the convolutions and anfractuosities of the brain. In cases of chronic hydrocephalus, where the inequalities of the brain are effaced by the accumulation of fluid, the internal surface of the cranium shows scarcely any vestiges of eminences and depressions. The osseous tissue, notwithstanding its hardness, is easily moulded around organs, and yields with facility to the compression which soft parts exercise upon it. It is very uncommon to open the cranium of a subject, somewhat advanced in years, without observing in some points a more or less considerable absorption of the parietes of the scull, occasioned either by clusters of certain small white bodies, called glandulæ Pacchioni, or by dilated veins.

One anatomical fact worthy of notice is the want of any configuration of the external surface conformable in its details with that of the internal surface: compare, for instance, the roof of the orbit with the cranial surface of the orbital plate of the frontal bone. This difference is due to the circumstance that the digital impressions encroach on the diploë, and are, in part, excavated from the space otherwise occupied by it. The two compact laminæ which form the bones of the cranium are in some measure independent of each other; the internal one belongs, so to speak, to the brain; the external to the locomotive system. The diploë is the limit of these two laminæ. This anatomical fact is at variance with the doctrine of Gall respecting the protuberances; it proves that the cerebral convolutions are not faithfully represented by external prominences.

In order to complete the anatomical history of the cranium, it yet remains to consider, 1. Its general development; 2. The connexion of its several parts. (For this latter subject, see SYNDESMOLOGY.)

As to the analogies which have been so ingeniously established between the cranium and the vertebral column, a detailed analysis of them would be out of place in an elementary work like the present.

Development of the Cranium.

The cranium is remarkable for the early period at which its development commences. As soon as the embryo is sufficiently advanced in growth to exhibit any distinction of parts, the head, under the form of an ovoid vesicle, greatly exceeds the magnitude of the whole body. With regard to the order in which the different parts are ossified, we may remark, that the bones of the roof precede those of the base, in like manner as in the vertebræ the laminæ are ossified before the bodies. In both cases the evolution is most prompt in those parts which are especially destined to protect important organs.

Cranial Bones at Birth.

The bones of the roof of the scull appear before those of the base, but at birth ossification is less advanced in the roof than in the base; accordingly, in a fœtus at the full time, the bones of the base form a solid whole, and are immovable, while those of the

roof are separated by membranous intervals, which permit of pretty extensive movements, so that at this period the roof of the cranium yields, in a great degree, to pressure. At birth, there is nothing resembling the mode of union called suture. Nevertheless, each bone presents denticulations like the teeth of a comb round the circumference. The existence of these indentations before the period when the bones come into contact, proves that they are not the result of any mechanical action produced by their meeting; the only influence of this kind to which they are subjected during their formation, is the deviation of opposing denticulations. The frontal suture is the first developed.

Another peculiarity of this stage of development is the existence of those membranous intervals denominated *fontanelles*. They are produced in the following manner: the process of ossification commences in the centre of the bone, and advances from that point to the circumference, the most distant parts of the bone being, of course, the last to be ossified. These points, in broad or flat bones, are the angles, and, consequently, at the place where several angles of different bones ultimately unite, there must exist an unossified space at this time: these spaces are the fontanelles. They have all been pointed out in the description of the cranial bones; they are of especial importance to the accoucheur, on account of the indications which they furnish for determining the position of the child. All traces of the fontanelles are completely obliterated at the age of four years.

The Wormian Bones.

The Wormian bones should be regarded as supplementary points or centres, developed when the general ossification proceeds somewhat slowly; and we therefore consider it proper to include a description of them in the account of the development of the cranium.

The Wormian bones, so called because the first description of them has been assigned to Wormius, a physician in Copenhagen, are also denominated *epactal bones*, *ossa triquetra*, or *complimentary* bones of the scull. They are extremely variable, both in situation, number, and size; but they are most common in the lambdoid suture, *i. e.*, in the most rugged of all the sutures, the asperities of which they tend to increase. This fact should not be overlooked in examining fractures of the cranium. The most remarkable of all the Wormian bones is the one which sometimes supplies the place of the superior angle of the occipital, and which Blasius has called the *triangular* bone; it is the *epactal* bone properly so called. It is not uncommon to find a Wormian bone in the sagittal suture, and this may be compared to the *inter-parietal* bone of some animals. Bertin has described a quadrangular bone occupying the situation of the anterior fontanelle, and resembling it in figure: I have myself met with such a formation. The anterior inferior angle of the parietal is sometimes formed by a Wormian bone; I have seen one in the squamous suture.

In some sculls the whole of the occipital bone above the occipital protuberance is formed by these bones. Generally both tables of the bone enter into the formation of the Wormian bones; but there are instances in which they are confined to the external, and others to the internal table.

The Wormian bones are not always visible in the interior of the cranium: in some cases they are, as it were, incrusted in the substance of the bone, at the circumference of which they are observed.

Their mode of development resembles that of the broad bones, *i. e.*, it proceeds by radiation from the centre to the circumference. According to Béclard, they are not developed until five or six months after birth: at their junction with the surrounding bones they form sutures, which are the first to become effaced in after life.

From all that has been said regarding this class of bones (which are in a manner *accidental*, for they are neither constant in number nor in their existence), it is evident that they can be only considered as *supplementary points of ossification*, and not as performing an important office in contributing to the solidity of the cranium, as the name *clés de voûte*, given to them by some anatomists, would seem to indicate.

Progress of Development in the Adult and the Aged.

The cartilaginous lamina which separates the bones at first, gradually becomes ossified. The sutures become so serrated that it is almost impossible to separate the bones without breaking some of their teeth. At the same time that the bones increase in breadth, they augment in thickness; the diploë, which at first did not exist, is developed between the two plates. In the adult, several bones already begin to join by osseous union; of this we have an example in the sphenoid and occipital, which at an early period form one bone.

In the aged, the traces of the sutures are in a great measure effaced, so that in certain cases the whole scull would seem to be composed of one entire piece. The continuity of some bones is occasionally such, that the venous canals of the one communicate and open directly into those of the other. It is not uncommon to find the bones of an old subject thin and translucent like horn, in a greater or less extent. This diminution of thickness, added to the increasing fragility of the osseous tissue, affords an ex-

planation of the ease with which the sculls of old people may be broken: and the continuity of the bones explains the possibility of the fracture being much extended.

The greatest variety exists as to the thickness and density of the bones of the scull in old age. Generally they are as brittle as glass, but in some instances they are so soft and spongy that, although easily depressed, they can scarcely be fractured by the blow of a hammer. I have frequently, in old people, seen the teeth of the parietal and lambdoidal sutures soft, placed in juxtaposition, and merely joined by a soft fibrous substance, which admitted of their being separated without difficulty. The lambdoidal suture is the one which the most frequently presents this disposition, and in all the instances of this kind which I have met with, the superior borders of the occipital overlap the corresponding borders of the parietal.

The Face.

The face is tnat very complicated osseous structure, which is situated at the anterior and inferior part of the head, and is hollowed out into deep cavities for the reception of the organs of sight, smell, and taste, and for the apparatus of mastication.

The face is divided into two portions, *the upper and the lower jaw*. The lower jaw is formed by one bone only; the upper jaw consists of thirteen bones. But, although this circumstance tends to establish a great difference between the two, yet it must be remarked, that all the parts of the upper jaw are so immovably united, that in appearance they form only one bone; and, moreover, that it is essentially formed by one fundamental piece, the superior maxillary bone, to which all the others are attached as accessory parts.

Of the fourteen bones which constitute the face, two only are median or single: viz., the vomer, and the inferior maxilla. All the others are double, and form six pairs, viz., the superior maxillary, the malar, palate, and proper nasal bones, the ossa unguis, and the inferior turbinated bones.

The Superior Maxillary Bones (figs. 24 and 25, with the Palate Bones).

They are two in number, united, to a certain extent, in the median line, and form almost the whole of the upper jaw. Their figure is very irregular: they belong to the class of short bones. They have three surfaces, an external, an internal, and a superior; and three borders, an anterior, a posterior, and an inferior.

External or *Facial Surface* (*fig.* 24).—Proceeding from before backward, we observe a small fossa in which the myrtiform muscle (*depressor labii superioris et alæ nasi*) is inserted, and which is bounded externally by the ridge which forms the alveolus of the canine tooth; a deeper fossa, named *fossa canina*, or *infra orbitalis*, surmounted by the orifice of the *infra orbitary canal* (*o*); and, more posteriorly, a vertical ridge, which separates the fossa canina from the *maxillary tuberosity* (*m*). This protuberance, which is most prominent before the appearance of the wisdom tooth, is traversed by small canals, the *posterior* and *superior dental*, which transmit vessels and nerves of the same name. From the anterior part of this region, a long vertical process arises, the *ascending* or *nasal process* (*a b*) of the superior maxilla. It is of a pyramidal shape, and flattened. Its *external surface* is smooth, and presents the openings of certain vascular canals which communicate with the interior of the nasal fossæ, and some inequalities for the insertion of the common elevator of the upper lip and ala of the nose. On the *internal surface* (*fig.* 25) we observe, in succession from above downward, a rough surface, which assists in closing the anterior cells of the ethmoid; a horizontal ridge, to which the middle turbinated bone is attached; a concave surface, which forms part of the middle meatus of the nose; and another horizontal ridge for articulation with the inferior turbinated bone: like the external, this surface also is perforated by foramina, and marked by arterial furrows. Its *anterior edge* (*a b*, *figs.* 24, 25) thin, and bevelled internally, is applied to the nasal bone. The *posterior edge* is thick, and marked by the *lachrymo-nasal groove*, which forms part of the *lachrymal groove* above, and of the *nasal duct* below. It has two edges or lips: the internal, which is very thin, articulates with the os unguis and the inferior turbinated bone; the external, which is rounded, gives attachment to the straight tendon and some fibres of the orbicularis palpebrarum muscle. The direction of the lachrymo-nasal groove is slightly curved; the convexity being internal and in front, the concavity external and behind. The summit of the nasal process is truncated and serrated for articulation with the nasal notch of the frontal bone.

Fig. 24.

Superior or *Orbital Surface* (*e*, *fig.* 24).—This is the smallest of the three surfaces. It forms almost the entire floor of the orbit: it is triangular, and slightly oblique from within outward, and from above downward, and presents a groove behind, which is continuous with the infra-orbitary canal. This last-named passage, at first a mere channel, afterward a complete canal, passes from behind forward and inward, bends down and opens at the upper part of the canine fossa. Before its termination, it gives off a small canal, *the anterior* and *superior dental*, which runs in the anterior wall of the maxillary sinus,

and transmits the vessels and nerves which are distributed to the incisor and canine teeth. Sometimes this branch of the canal opens into the maxillary sinus. In many subjects I have seen it curve backward, and conduct a communicating branch between the infra-orbitary and palatine nerves as far as the maxillary tuberosity. The orbital surface is bounded by an *external edge*, which forms part of the spheno-maxillary fissure; by an *internal edge*, which articulates with the os unguis, the os planum of the ethmoid, and the palate bone; and by an *anterior edge*, which forms part of the rim of the orbit. At the external termination of this edge is a very irregular eminence, appearing as if part of the bone had been broken off: this is the malar process, which corresponds with the summit of the maxillary sinus, and is articulated with the malar bone. At the internal extremity of the orbital edge, we find the ascending process already described.

Internal or *Naso-palatine Surface* (*fig.* 25).—This surface is divided into two unequal parts by a horizontal square plate, which intersects it at right angles. This plate is the *palatine process* (*t*), the superior surface of which, smooth and hollow, is broader posteriorly than anteriorly, and forms part of the floor of the nasal fossæ: its inferior surface is rough, and forms part of the roof of the palate: its internal border (*t*) is very thick in front, and articulates with the corresponding edge of the opposite bone. This border is surmounted by a crest, which contributes to form the furrow into which the vomer is received, and which presents, at the junction of its anterior with the two posterior thirds, a groove (*r*) running obliquely upward and backward. This groove, when united with a similar one on the opposite bone, forms the *anterior palatine* or *incisive canal*, which is single below and double above. The anterior edge of the palatine process is very narrow, and forms part of the anterior opening of the nasal fossæ: the posterior edge, bevelled at the expense of the superior table, supports the horizontal portion of the palate bone.

Fig. 25.

That part (*w*) of the internal surface of the maxillary bone which is situated below the palatine process, is of no great extent: it forms part of the arch of the palate. A furrow more or less deep, and bounded by projecting edges, runs along the external border of the palatine process, and protects the posterior palatine vessels and nerves. The mucous membrane of the palate covers this region of the bone. The part of the internal surface (*n*) of the superior maxillary bone which is above the palatine process, belongs to the nasal fossa: it is covered by the pituitary membrane. We observe here from before backward, 1, the internal surface (*c*) of the ascending process (*a*); 2, below the inferior ridge, a smooth surface which forms part of the inferior meatus of the nose; 3, the inferior orifice (behind *c*) of the lachrymo-nasal groove, sometimes converted into a complete canal by a bridge of bone; 4, the opening of the maxillary sinus (*s*), which appears wide in a detached bone, but in its natural connexion is contracted by prolongations of the palate bone, the ethmoid, the inferior turbinated bone, and the os unguis, all of which are articulated with the circumference of this opening; it is still farther diminished when the bones are covered by their pituitary membrane. At its lower part, this orifice presents a fissure in which a lamina belonging to the palate bone is received: this method of articulation has received the name of *Schindylesis*. At the upper part are small cells, which unite with the ethmoid; behind the orifice is a rough surface, which articulates with the palate bone; and, lastly, a groove, which forms part of the posterior palatine canal.

The orifice which we have just described leads into the interior of a cavity denominated *maxillary sinus*, or *antrum of Highmore*, although it had been before very accurately described by Vesalius. It is hollowed out from the substance of the maxillary bone, and has the form of a pyramid, the base of which corresponds with the internal surface of the bone; the summit with the malar process; the superior wall with the floor of the orbit; the anterior wall with the fossa carina, and the posterior with the maxillary tuberosity. These two last-mentioned walls are traversed by linear projections or ridges, which correspond with the anterior and posterior dental canals. There is also one ridge upon the superior wall: it indicates the passage of the infra-orbitary canal. The extreme tenuity of this superior or orbitary wall is an anatomical fact of great importance, because it explains the influence which tumours developed in the sinus exert upon the organs contained in the cavity of the orbit. The septum between the sinus and the bottom of the alveoli is also so thin, that an instrument can easily penetrate into the sinus in this situation. This remark applies particularly to the alveolus of the canine tooth.

The *anterior border* (*g a*, *figs.* 24 and 25) of the superior maxilla presents, below, a vertical portion (*g d*), surmounted by a small eminence called the *nasal spine* (*a*): it is then hollowed out into a deep notch (*a b*), to form half the anterior orifice of the nasal fossæ; and, lastly, becomes continuous with the anterior edge (*b a*) of the ascending process.

The *posterior border* is vertical and very thick: it articulates below with the pterygoid process, through the medium of the palate-bone: above, it forms part of the pterygo-maxillary fissure.

The *inferior* or *alveolar border* (*g h*) is the thickest and strongest part, being, in some respects, the base of the bone. It is hollowed into conical cavities separated by thin septa. These cavities are the alveoli or sockets of the teeth: they are proportioned in dimensions to the size of the fangs which they are intended to lodge, and in like manner are subdivided into two, three, or four secondary cavities. The bottom of these alveoli is in apposition with the maxillary sinus, into which they occasionally open. This border presents, especially in front, flutings or projections which correspond with the alveoli, and depressions which mark the inter-alveolar septa.

In young subjects we may observe, chiefly behind the incisor teeth, some very remarkable foramina, to which much importance has been attached as connected with the phenomena of dentition.

Internal Structure.—This bone is remarkably light for its size, on account of the large cavity which it encloses. It is more compact than most of the short bones, and has spongy tissue only in the alveolar border, the maxillary tuberosity, and the malar eminence.

Connexions.—The superior maxilla is articulated with two bones of the cranium, the frontal and the ethmoid, and with all the bones of the face. It lodges eight of the teeth of the upper jaw.

Development.—Anatomists are not at all agreed respecting the number and arrangement of the osseous points which concur in forming the superior maxilla.

In the maxillary bone of the fœtus, and sometimes even in that of the adult, there are, as I can attest from observation, two very remarkable fissures, which would seem to indicate the primitive separation of the bone into three pieces.

1. The first fissure, which may be called the *incisive fissure*, is visible on each side of the arch of the palate. It commences at the septum, which divides the alveoli of the canine tooth and lateral incisor, is continued backward to the anterior palatine canal, and is prolonged above on the internal surface of the ascending process. This fissure is apparent only on the internal surface of the superior maxilla: it either does not exist at all upon the external surface, or is so early obliterated that it can scarcely ever be met with. The portion of the maxilla circumscribed by this fissure sustains the incisor teeth, and represents the incisor or inter-maxillary bone of the lower animals. In hare-lip, the solution of continuity is in the situation of this fissure. It is therefore probable that this anterior portion of the maxillary bone is developed from a special point. Bertin asserts this, and Meckel and Béclard admit it. I have not been able to observe such independent development at any period of fœtal life at which I have examined the maxillary bone.

2. A second and equally constant fissure is visible in the situation of the infra-orbital canal, and is prolonged from the edge of the orbit in the form of a small suture to the anterior orifice of this canal: it may be called *the orbital fissure*. This fissure, like the preceding, has always seemed to me incomplete, and not occasioned by the separation of a distinct piece.

The superior maxillary bone is one of the earliest in making its appearance. Ossification commences in it from the thirtieth to the thirty-fifth day, in the situation of the alveolar arch.

At birth the superior maxilla has little height, but a considerable extent from before backward. At this period it is chiefly formed by the alveolar border, which is almost contiguous to the floor of the orbit. The maxillary sinus is already very apparent. In the adult, the vertical dimensions increase by enlargement of the sinus. In the aged, the alveolar process becomes flattened, and diminished in height.

The Palate Bones (*figs.* 24, 25, 26, and 27).

The palate bones are situated at the posterior part of the nasal fossæ and the palatine arch: they are two in number, symmetrical, and each composed of two thin quadrilateral laminæ, one of which is horizontal, the other vertical, and which are joined together at right angles.

Fig. 26.

Fig. 27.

The *horizontal plate* (*b c*, *figs.* 26 and 27), the only one known to the ancients, and named by them the *os quadratum*, presents a *superior surface* (*d f*), smooth and continuous with the floor of the nasal fossæ, of which it forms the broadest part: an *inferior surface* (*b c*), which completes the arch of the palate: it is rough, slightly concave in front, and presents behind and to the outside a transverse ridge for the insertion of the tensor palati muscle; and in front of this ridge is the inferior orifice of the posterior palatine canal. The *anterior edge* of this plate is cut obliquely, so as to rest upon the posterior edge of the palatine process of the superior maxillary. The *posterior edge* is concave, and very thin; it gives attachment to the velum palati. The *internal edge* is surmounted by a crest, which forms one of the sides of the vomer, and terminates behind by a sharp process (*d*), which, when united to the corresponding part of the opposite

bone, constitutes the *posterior nasal spine*, which gives attachment to the levator muscle of the uvula (azygos uvulæ). The *external edge* is united to the vertical portion of the bone.

The *vertical portion*, or *lamina* (*a b*), is slightly inclined inward, quadrilateral, longer, broader, and thinner than the preceding. On it we observe, 1. An *internal surface* (*m f* and 2, *fig.* 25), which contributes to form the external wall of the nasal fossæ, and which presents from above downward a horizontal ridge for articulation with the middle turbinated bone; a groove belonging to the middle meatus; another ridge for articulation with the inferior turbinated bone (*e* and 2, *fig.* 25); and another groove which makes part of the inferior meatus (*e f* and 1, *fig.* 25). 2. An *external surface* (*s b*, *fig.* 26, and *p b*, *fig.* 27), very irregular, which contributes to form the bottom of the zygomatic fossa above, and which is rough in front for union with the superior maxillary. This surface is traversed by a vertical groove, which, by itself, forms almost the entire extent of the *posterior palatine canal* (*g g*, *fig.* 26). 3. An *anterior* or *maxillary border* (*i*, *fig.* 27), very thin and irregular, which advances so far forward as to contract the entrance into the maxillary sinus, and presents a tongue of bone, which is received into the fissure already described as existing at this orifice. 4. A *posterior* or *pterygoid border* (*l*, *fig.* 26), which is applied to the inner plate of the pterygoid process. There is below, at the angle formed by its union with the posterior edge of the horizontal portion, a very considerable process for the size of the bone: this has been called *palatine process*, or *tuberosity of the os palati* (3, *fig.* 25; *l b*, *fig.* 26), but is better named *pterygoid* or *pyramidal process:* its base is continuous with the rest of the bone, and from this point passes downward, and is, as it were, enclosed in the bifurcation of the pterygoid process of the sphenoid. Its upper surface is traversed by three grooves, the middle of which forms part of the pterygoid fossa, and the lateral ones are rough, and receive the summits of the two pterygoid plates. Below, the pyramidal process exhibits the orifices of the *accessory ducts of the posterior palatine canal*. Externally it presents a rough surface, which articulates above with the tuberosity of the superior maxilla, and which is free in the rest of its extent, and forms part of the zygomatic fossa. The middle of this process is grooved in a vertical direction, for the posterior palatine canal. 5. The *inferior border* of the vertical portion is continuous with the external edge of the horizontal plate. 6. The *superior* or *sphenoidal border* is connected with the sphenoid in almost the whole of its extent. It presents a deep notch, forming three fourths or sometimes the entire *spheno-palatine foramen* (6, *fig.* 25; *o*, *figs.* 26, 27; *n*, *fig.* 37), which corresponds with the *spheno-palatine ganglion*, and gives passage to the vessels and nerves of the same name. This border is surmounted by two *processes*, an *anterior* or *orbital* (4, *fig.* 25; *a*, *figs.* 26, 27), and a *posterior* or *sphenoidal* (5, *fig.* 25; *m*, *figs.* 26, 27). The *sphenoidal process* is the broader, particularly at its base, but is not so elevated as the anterior: it presents three facettes—an internal, which forms part of the nasal fossa; an external, which is visible in the zygomatic fossa; and a superior, which articulates with the sphenoid, and presents a groove, which contributes to form the *pterygo-palatine canal*.

The *orbital process*, inclined outward, and supported by a constricted portion or neck, has five facettes. *Three of these are articular*, viz., *the internal* (*n*, *fig.* 27), which is concave, and unites with the ethmoid, covering and completing its cells; *the anterior* (*p*, *fig.* 27), which joins the maxillary bone; and *the posterior* (*q*, *fig.* 26), which is united to the sphenoid by certain asperities surrounding a cell, which exists in the substance of the process, and communicates with the sphenoidal sinus. *The other two are non-articular*, viz., the *superior* (*r*, *fig.* 26), which forms the deepest part of the floor of the orbit, and *the external* (*s*, *fig.* 26), which forms part of the zygomatic fossa, and is separated from the preceding by a small edge, which constitutes a portion of the spheno-maxillary fissure.

Internal Structure.—The palate bone is compact throughout, excepting in the palatine process, where it is thick and cellular.

Connexions.—The palate bone articulates with its fellow on the opposite side, with the maxillary, the sphenoid, the ethmoid, the inferior turbinated bone, and the vomer.

Development.—This bone is developed from a single point of ossification, which appears from the fortieth to the fiftieth day, at the point of union of the vertical and horizontal portions, and the pyramidal process. During its development, the bone appears as it were crushed down, so that the vertical portion is shorter than the horizontal, and there is a marked predominance in the antero-posterior diameter. This disposition is in accordance with the shortness of the vertical diameter of the superior maxilla.

Fig. 28.

The Malar Bones (*fig.* 28).

The *malar bones*, called also *cheek*, *jugal*, or *zygomatic bones*, are situated in the superior and lateral part of the face: their form is that of a very irregular four-sided figure. They have three surfaces, an anterior, a posterior, and a superior; four borders, and four angles.

The *anterior* or *cutaneous surface* (*a*) looks outward, is convex and smooth, and presents the openings of several foramina (*h*),

named malar, which are intended for nerves and vessels. This surface gives attachment below to the *zygomaticus major* muscle. It forms the most prominent part of the cheek, and is covered only by the skin and *orbicularis palpebrarum* muscle: it is, consequently, much exposed to injury.

The *superior* or *orbital surface* (*b*) is supported by a thick curved process, the *orbital process*, which arises from the bone almost at a right angle. This surface is concave, and of small extent: it forms part of the orbit, exhibits the internal openings of one or more malar foramina, and terminates behind by a rough, serrated edge, which articulates above with the frontal and sphenoid bone, and below with the superior maxillary. The same maxillary edge presents in the middle a retiring, smooth angle, which constitutes the anterior extremity of the *spheno maxillary fissure*.

The *posterior* or *temporal surface* is concave, and presents a smooth surface behind, which contributes to form the temporal fossa, and on which one or more malar foramina open; and a rough surface in front, which unites with the malar process of the superior maxilla.

Of the *four borders*, two are superior; of these, the anterior or *orbital* (*d e*) is semi-lunar, rounded and blunt, and forms the external third of the base of the orbit; the posterior or *temporal* (*e f*) is thin, and curved like the letter S, and bounds the temporal fossa in front. Of the two inferior borders, the anterior or *maxillary* (*d g*) is very rough and articulates with the maxillary bone; the posterior or *masseteric* (*g f*) is horizontal, thick, and tubercular, and gives attachment to the masseter muscle.

Of the *four angles*, the *superior* or *frontal* (*e*), which is much elongated, and vertical, is the thickest part of the bone, and articulates with the external angular process of the frontal bone: the *posterior* or *zygomatic* (*f*), broader and thinner than the preceding, is serrated, and slants downward and backward, for articulation with the zygomatic process of the temporal bone, which rests upon it. The *internal* or *orbital* angle (*d*) looks inward and forward, is very acute, and articulates with the superior maxillary near the infra-orbitary canal. The *inferior* or *malar* angle (*g*) looks downward, is obtuse, and unites with the outer part of the malar or jugal process of the superior maxillary.

Internal Structure.—The malar bone is almost entirely compact, possessing spongy tissue only in the anterior and inferior edge, and in the part where the orbital portion is given off. It is constantly traversed by a canal called *zygomatic*. This passage is generally simple, but sometimes double or even multiple, and opens by at least three orifices. The superior or orbital orifice is visible on the surface of the same name; the next or external zygomatic foramen is on the cutaneous surface of the bone; and the third or internal zygomatic on the inner surface of the vertical portion.

Connexions.—The malar bone is articulated with the superior maxillary, the frontal, the sphenoid, and the temporal.

Development.—It is developed from one point of ossification, which appears about the fiftieth day of fœtal life. The ulterior changes which it undergoes do not require particular notice.

The Nasal Bones (*figs.* 29, 30).

The nasal bones are two in number, asymmetrical, and very small in the human subject; they are closely contiguous to each other, sometimes united into one piece superiorly. They are situated at the upper and middle part of the face, and form, as their name indicates, the osseous part of the nose, of which they constitute the root. They are directed obliquely downward and forward, but with various degrees of inclination in different subjects; and hence the varieties in the shape and prominence of the middle or bridge of the nose. Their figure is rectangular and oblong; they are thick and narrow above, broad and thin below; and have two surfaces, an anterior and a posterior, and four edges.

Fig. 29.

Fig. 30.

The *anterior* or *cutaneous surface* (*fig.* 29) is covered only by the skin and pyramidalis nasi muscle, and hence the ease with which these bones are fractured: it is concave above, flat or even convex below: the orifice of a vascular canal is always very distinctly seen, which is variable in its situation, sometimes single, but often accompanied by others of smaller size.

The *posterior* or *pituitary surface* (*fig.* 30) is concave, and forms the anterior part of the roof of the nostrils: it is marked by vascular and nervous furrows, and in the fresh state is covered by the pituitary membrane.

Of the four edges, the *superior* (*a*, *figs.* 29, 30), short, thick, and serrated, articulates with the nasal notch of the frontal bone. The *inferior* (*d*), very thin, and more elongated, has a slight notch in the centre for the passage of a nervous filament, and forms part of the anterior orifice of the nasal fossæ: it unites with the lateral cartilage of the nose. The *internal* (*b*) edge is thick above, and bevelled, so that, when approximated to the other bone, the two constitute a furrow, in which the nasal spine of the frontal and the perpendicular lamella of the ethmoid bone are received. The *external* (*c*) edge is somewhat longer than the internal, is slightly bevelled on the outer table, and indented for articulation with the ascending process of the superior maxilla, which rests upon it.

Connexions.—The two bones are articulated together: they unite also with the frontal, the ethmoid, and the superior maxilla, and likewise with the lateral cartilages of the nose: they afford passage to the vessels which establish a communication between the skin of the nose, and the mucous membrane of the nasal fossæ.

Internal Structure.—The nasal bones are thick and cellular in their upper parts, thin and entirely compact in their lower, and are traversed by nervous and vascular grooves.

Development.—The nasal bone is developed from one single osseous point, which appears before the end of the second month.

Ossa Unguis, or Lachrymal Bones (*figs.* 31, 32).

These are the smallest bones of the face: they are thin, like paper, and have the transparence, tenuity, and even the shape of a nail, from which circumstance one of their names has been derived. They are situated at the internal and anterior part of the orbit: their figure is irregularly quadrilateral: they are two in number, and, therefore, asymmetrical. They have two surfaces and four edges.

Fig. 31. *Fig.* 32.

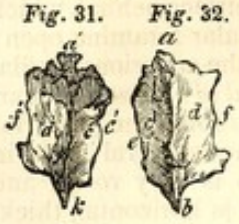

The *external* or *orbital surface* (*fig.* 32) is divided into two unequal parts by a vertical ridge (*a b*), which terminates below in a sort of hook. The portion anterior to the ridge is narrow, and marked by a porous groove (*c*), which, when joined to the channel on the ascending process of the superior maxilla, forms the *lachrymal groove* (hence the name of lachrymal bone).* The portion (*d*) of the os unguis, which is posterior to the ridge, completes the inner wall of the orbit.

The *internal* or *ethmoidal surface* (*fig.* 31) presents a furrow (*a' b*), which corresponds to the external ridge; the portion (*c'*) in front of the furrow forms part of the middle meatus; behind is a rough surface (*d'*), which covers the anterior cells of the ethmoid.

Of the four borders, the *superior*(*a a'*) is rough, and articulates with the internal angular process of the frontal bone; the *inferior* (*b b'*) articulates with the inferior turbinated bone by a small tongue which passes backward, and which contributes to form the nasal canal, and with the internal edge of the orbital surface of the superior maxillary. The *anterior edge* (*e e'*) unites with the ascending process of the maxillary bone; and the *posterior edge* (*f f*), slightly denticulated, joins the orbital portion or lamina papyracea of the ethmoid.

Connexions.—The os unguis articulates with the frontal, the ethmoid, the superior maxillary, and the inferior turbinated bone: they assist in the formation of the lachrymal sac, the nasal canal, and the internal wall of the orbit.

Structure.—The os unguis consists of a very thin layer of compact tissue, and is the most brittle of all the bones. It is of importance to note its tenuity and fragility, because it is concerned in the operation for fistula lachrymalis.

Development.—The os unguis is ossified at the commencement of the third month, from one single point.

The Inferior Turbinated or Inferior Spongy Bones (*figs.* 33, 34, and *d*, *fig.* 37).

The inferior turbinated bones, so called on account of their curved figure, are situated at the lower part of the external wall of the nasal fossæ (*d*, *fig.* 35), below the ethmoid, whence the name *sub-ethmoidal turbinated* bones. They are two in number, asymmetrical, and their greatest diameter is directed from before backward. They have two surfaces, two edges, and two extremities.

Figs. 33, 34.

The *internal surface* (*fig.* 34, and *d*, *fig.* 37) is convex, and looks towards the nose, which it sometimes touches when that part deviates from the straight *direction*; the *external surface* (*fig.* 33) is concave, and forms part of the middle meatus. Both are rough, and, as it were, spongy, which has given rise to the assertion that these bones form an exception to the general rule of the spongy tissue being in the interior of bones: this appearance, however, is owing to the multiplicity of canals intended for nerves, and more particularly for the veins which expand over the bone. The *superior* or *articular edge* (*a b c d*, *figs.* 33, 34) is very irregular, and presents from before backward, 1. A thin edge (*a b*), which articulates with the ascending process of the superior maxilla. 2. A small eminence bearing the name of *nasal* or *lachrymal process* (*b*), which articulates by its apex with the os unguis, and by its two edges with the two lips of the ascending process of the superior maxillary, to complete the nasal canal. 3. A curved plate, called *auricular process* (*e*, *fig.* 33) by Bertin, who compared it to the ear of a dog: this plate is directed downward, and applied partially upon the orifice of the maxillary sinus, which it assists in closing. 4. Behind this process

* The existence of lachrymal bones is subordinate to that of the lachrymal secretion. They are not met with in those animals which live in the water, and which have neither lachrymal glands nor passages.

we find a thin edge (*e d*, *figs.* 33, 34), which articulates with a small ridge on the palate bone. 5. Between the auricular and the lachrymal processes are small prominences which unite with the ethmoid.

The *inferior* or *free* border (*a d*) is convex, and thicker in the middle than at its extremities: it is separated from the floor of the nostrils by an interval (*m o*, *fig.* 37) of uncertain extent, a circumstance to be remembered during the introduction of instruments into the nasal fossæ.

The *anterior extremity* (*a*) is a little less pointed than the *posterior* (*d*), which distinguishes the bone of the right from that of the left side.

Connexions.—The inferior turbinated bones articulate with the superior maxillary, the palate bones, the ethmoid, and the ossa unguis: they have important relations with the inferior orifice of the nasal canal, which they defend from the contact of foreign bodies.

Structure.—Their external spongy appearance depends upon the multitude of canals with which their surface is furrowed, but they are almost exclusively formed of compact tissue.

Development.—Their ossification commences about the fifth month of fœtal life, by a point situated in the centre.

The Vomer (*fig.* 35, and 10, *fig.* 22).

The *vomer* is so called from its supposed resemblance to a ploughshare. It is situated in the median plane, and forms the posterior part of the septum of the nostrils. It is thin, flat, and quadrilateral, and has two surfaces and four edges. The *surfaces* are placed laterally (as at *a*, *fig.* 35), and are generally plane, but they are often bent to one side or the other, and are then convex and concave in opposite directions: they are always smooth, and covered by the pituitary membrane, and present small vascular and nervous furrows. The *superior* or *sphenoidal* border (*b*, *fig.* 35, and 3, *fig.* 22) is the shortest and thickest: it is marked by a deep groove, which receives the inferior crest of the sphenoid; the two lips of the groove are bent outward, and received into furrows on the inferior surface of the same bone, and thus complete a small channel for the passage of vessels and nervous filaments. The *inferior* or *maxillary* (*c*) border is the longest, and is received into the furrow which is formed by the union of the two palate bones behind and of the two superior maxillary in front: it sometimes terminates by a more or less prominent process behind the anterior nasal spine. The *anterior* or *ethmoidal* border (*d*, *fig.* 35, and 3 4, *fig.* 22) presents the continuation of the groove on the superior edge, and receives the inferior border of the perpendicular plate of the ethmoid. There is no groove where it is attached to the cartilaginous septum. The *posterior* or *guttural edge* (*e*, *fig.* 35, and *t*, 10, *fig.* 22) is free: it is thin and sharp, and inclines downward and forward: it separates the posterior openings of the nasal fossæ.

Fig. 35.

Connexions.—The vomer is articulated with the sphenoid, the ethmoid, the superior maxillary, the palate bones, and the cartilage of the septum.

Internal Structure.—The vomer is composed of two very thin compact laminæ, which are distinct above, but united below. Some anatomists have called these plates *alæ of the vomer.*

Development.—It is developed from one point of ossification, which is situated at the lower part of the bone, and appears before the end of the second month. It then presents the form of a deep groove, embracing the cartilage just as, at a future period, it embraces the sphenoidal crest. At birth the vomer is still only a groove; afterward this condition is confined to the sphenoidal and ethmoidal edges of the bone. It is not uninteresting to note the peculiar and uncommon manner in which the ossification proceeds from the surface to the interior of the cartilage.

Inferior Maxilla (*fig.* 36).

While, as we have before observed, a considerable number of bones to enter into the formation of the upper jaw, the lower jaw consists of one bone only. The inferior maxilla occupies the lower part of the face. From the number and importance of the practical points connected with this bone, too much attention cannot be bestowed on the study of its form and connexions. It has the shape of a parabolic curve, the two extremities of which, called *rami*, form a right angle with the middle portion or *body*.

Fig. 36.

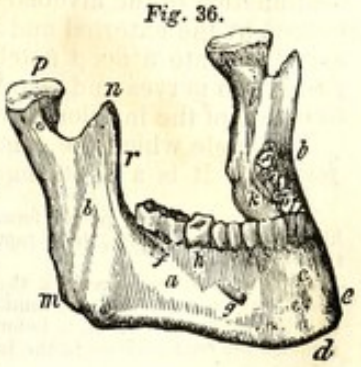

Of the *body* or *middle portion* (*a*).—The body represents a curved plate, convex in front and concave behind. It offers to our notice an anterior and a posterior surface, and a superior and inferior border. The *anterior surface* has in the middle a vertical line, called *symphysis menti* (*c d*); it

marks the place of union of the two pieces of which this bone is composed in young subjects, and which, in a great number of animals, remain distinct through life.*

The mode in which the two halves of the body of the inferior maxilla are united, forming an arch instead of an angle, as in other animals, constitutes one of the distinctive characters of the human species; and the *vertical direction* of the symphysis, compared with its very oblique inclination downward and backward, or almost horizontal position in the lower animals, is a no less characteristic mark of man, who alone can be said to possess a *chin*.†

In front the symphysis terminates by a triangular eminence called *mental process* (*d*). Behind, it presents below four small tubercles, two superior and two inferior, known by the collective appellation of *genial processes* (γένειον, the chin), and give attachment to the genio-hyoid and genio-glossal muscles.

On each side of the *symphysis*, we observe on the *anterior* or cutaneous surface of the body of the inferior maxilla, 1. A small depression for the attachment of muscles, named *mental fossa* (*e e*). 2. A line, which commences at the mental process, passes obliquely upward, and becomes continuous with the anterior edge of the ramus of the jaw: it is named the *external oblique*, or *external maxillary line* (*e f*), and is also intended for muscular insertions. 3. Above this line, the *mental foramen* (*g*), the orifice of the *inferior dental canal*, which transmits the mental vessels and nerves. 4. The anterior surface of the *alveolar arch* (*c h*), marked by a series of projections corresponding to the alveoli, and separated by vertical depressions, which point out the situation of the inter-alveolar septa. 5. Below the external oblique line, a smooth surface (*a*), separated from the skin by the platysma myoides muscle.

The *posterior* or *lingual surface* is in some measure moulded upon the tongue: it presents, 1. The *mylo-hyoidean line* (*k*) (μύλος, *dens molaris*), called also *internal oblique* or *internal maxillary*, which commences at the genial processes, and passes upward and backward, becoming more prominent opposite the last molar tooth. 2. Below this line, a broad but superficial depression, which lodges the sub-maxillary gland. 3. Above the oblique line, and near the symphysis, a *fossa*, which lodges the sub-lingual gland, and a smooth surface covered by the mucous membrane of the mouth and gums.

These two lines, the external and internal oblique, divide the body of the inferior maxilla into two parts, a *superior* or *alveolar*, and an *inferior* or *basilar*. The first named constitutes almost the entire body of the bone in the fœtus and the infant; in the adult it forms only two thirds of the depth of the bone, the other third being the basilar portion: lastly, in the aged, the alveolar portion almost entirely disappears, and the basilar only is left.

The *superior* or *alveolar border* describes a smaller curve than the corresponding alveolar edge of the superior maxilla; so that, in a regular conformation of the parts, the inferior incisor teeth are overlapped by the superior. This border is less thick in front than behind, where it projects inward: it is pierced by a series of sockets or alveoli, resembling those of the superior maxilla, and, like them, variable according to the kind of teeth which they are intended to receive.

The *inferior border* or *base of the jaw* (*d m*) is the thickest part of the bone; it forms part of a larger curve than the superior border, so that the jaw projects forward in some measure at the lower part: this projection varies much in different subjects.

Rami of the inferior maxilla (*b b*).—These are quadrilateral, and present, 1. *An external surface* (*b*) covered by the masseter muscle, which is inserted into it, especially below, where we may observe depressions and ridges, and where the bone itself is more or less bent outward; in front of these ridges is a slight mark, which corresponds with the situation of the facial artery. 2. An *internal* or *pterygoid surface*, also rough, for the attachment of the internal pterygoid muscle, and on which is observed the superior orifice (*l*) of the inferior dental canal, which is wide, and has a sort of spine, to which the internal lateral ligament of the temporo-maxillary articulation is attached: a small groove passes from this orifice in the same direction as the canal, and bears the name of *mylo-hyoidean furrow*, because it lodges the nerve of that name. 3. A *posterior* or *parotid* edge, which is round, and gives attachment below to the stylo-maxillary ligament: it is embraced by the parotid gland. 4. An *anterior edge* (*r*), marked by a groove, which is the continuation of the alveolar border; the anterior and posterior lips of this groove being formed by the external and internal oblique lines. 5. A *superior edge*, very thin, and hollowed out into a deep notch, called *sigmoid notch* (*n o*), on account of its shape, giving passage to nerves and vessels. 6. An *inferior edge*, which is nothing more than a continuation of the inferior border of the body of the bone.

The angle which the rami form with the body of the bone is named the *angle of the jaw* (*m*). It is a right angle in the adult, but very obtuse in the infant, as also in the

* In serpents these pieces form a movable joint; and as a similar arrangement obtains between the two halves of the upper jaw, these reptiles are enabled to swallow an object much larger than their head, or even than their body.

† It is interesting to remark the difference in the dissection of the symphysis in the Caucasian and Ethiopian varieties of the human family. In the former it is placed nearly vertically, slightly oblique from above to below, and from behind to before. In the latter it is oblique from before to behind, and in this respect resembles the conformation in the inferior animals, more especially in the *Simiæ*.

carnivora and some of the rodentia, this disposition enabling its muscles to act with greater power.

The rami of the inferior maxilla are terminated above by two processes: the anterior, called the *coronoid process* (*n*); the posterior, named the *condyle* (*p*).

The *coronoid process* is triangular, and inclined forward; broad at its base, and pointed at its summit; it gives attachment to the temporal muscle. The size of this process in the different species of animals bears an exact and constant proportion, both to the depth and extent of the temporal fossa, and to the strength and curvature of the zygomatic arch.

The *condyle* articulates with the glenoid cavity of the temporal bone; it is an oblong eminence, the greatest diameter of which is directed slightly inward and backward. It is supported by a contracted portion, called the *neck of the condyle* (*cervix*) (*o*). This neck is turned inward in such a manner that the condyle, which it supports, does not project beyond the external plane of the ramus of the jaw; it is also pretty deeply excavated internally, to afford attachment to the external pterygoid muscle. The neck of the condyle is the weakest part of the inferior maxilla.

Connexions.—The inferior maxilla articulates with the temporal bone, and lodges the lower range of teeth.

Structure.—The external surface of the inferior maxilla is composed of compact tissue; the interior of the bone assumes the form of diploe, and is traversed for a great part of its extent by the *dental* or *inferior maxillary canal*, which transmits the vessels and nerves that are distributed upon the teeth of this jaw. This canal commences at the middle of the ramus, by a groove covered with a fibrous lamina, the only use of which, as it appears to me, is to protect the vessels and nerves, and to separate them from the internal pterygoid muscle. From this point it proceeds forward and inward below the mylo-hyoidean line, the curvature of which it follows; it gradually becomes contracted in diameter; and in the situation of the second small molar or bicuspid tooth, it divides into two canals, the larger of which is very short, and opens upon the external surface of the body of the bone at the *mental foramen* already described; the other, very minute, pursues the original track, and is lost near the middle incisor tooth. In its passage the inferior dental canal communicates with the alveoli, by one, and sometimes two foramina, through which the vessels and nerves of the teeth are transmitted. The situation of the dental canal varies much in different periods of life. In the new-born infant, before the appearance of the teeth, it occupies the lowest portion of the jaw; after the second dentition, it corresponds pretty nearly with the mylo-hyoidean line; and after loss of the teeth, it runs along the alveolar border. In the inferior maxilla of the old subject, the anterior orifice of the dental canal, or the mental foramen, is close to the superior border of the bone. The dimensions of the dental canal are no less remarkable for their variations; it is very large in the fœtus, and in the child before the appearance of the second set of teeth; it diminishes during adult age, and is much contracted in the old subject.

Development.—The inferior maxilla is developed by two points of ossification, one for each lateral half. Antenrieth admits, in addition, three complementary points; one for the condyle, one for the coronoid process, and one for the angle; but I have never observed them. The case is different, however, with a point of ossification described and figured by Spix, which forms the inner side of the alveolar border, or, rather, of the dental canal. In a fœtus of about fifty or sixty days, I have seen a kind of bony spiculum, which passed along the internal surface of the body and ramus of the bone; on the one half of the maxillary bone this spiculum was entirely free; but that of the other side adhered by the internal third of its length. The spine which surmounts the dental canal is nothing more than the extremity of this bony spiculum. It follows, therefore, that the inferior maxilla is developed from four points of ossification.

The inferior maxilla takes precedence of all the bones of the head in its development, and, indeed, of all the bones of the skeleton, excepting the clavicle. The inferior edge of the body of the bone appears as early as the thirtieth or thirty-fifth day; this extends backward to form the ramus, and in front to form the portion which supports the incisor teeth; it is probable that the osseous point of the dental canal, mentioned above, appears at the same time. From the fiftieth to the sixtieth day, each half of the bone appears already marked by a groove common to the dental canal and the alveoli. At a later period, the groove becomes very considerable, and is divided into alveoli by septa, which at first are incomplete, but afterward become perfect; the alveoli and their septa occupy at this time the entire depth of the bone.

The point of ossification described by Spix is united to the rest of the bone from the fiftieth to the sixtieth day. (Spix affirms that it remains separate until the fourth month.) The two halves of the maxilla are joined together during the first year after birth. The traces of this union exist for some time, but are afterward effaced; in the lower animals the suture remains throughout life.

The changes which the inferior maxilla undergoes after birth, relate, 1. To the angle which the ramus forms with the body of the bone, which is very obtuse at birth, and becomes a right angle after development is completed. 2. To the alterations effected in

the body of the bone, by the first and second dentitions, the loss of teeth in the aged, and the subsequent absorption and disappearance of the alveoli.

The Face in general.

The fourteen bones which we have described, united to each other, and joined to the bones of the cranium, form a piece of bony sculpture, symmetrical, extremely complicated, destined to lodge the organs of smell, sight, and taste, and to be the instrument of mastication. This bony sculpture forms the face, which is situated below the cranium, above the neck, and in front of the vertebral column, from which it is separated by the pharynx, and is bounded on each side by the zygomatic arches.

Dimensions of the Face.

In order to form a just idea of the dimensions of the face, it is necessary to examine a scull cut vertically from before backward (as in *fig.* 22). We then perceive that the face is comprised within a triangular space, which is bounded above by an irregular line that separates it from the cranium; in front by the face, properly so called; and below, by a line passing below the symphysis menti. If a line be drawn above the inferior maxilla, and under the arch of the palate, when prolonged backward, it will be in the plane of the foramen magnum; for the cranium having much less depth in front than behind, a horizontal line, which touches the cranium behind, is separated from it in front by the entire height of the upper jaw.

The *vertical diameter*, which extends from the frontal protuberance to the chin, is the longest of all the diameters of the face. It gradually diminishes from before backward. The *transverse diameter* is of considerable extent in the situation of the cheeks, but diminishes above and below this point. The *antero-posterior diameter* stretches above from the nasal spine to the basilar process; below it is greatly contracted; and at the level of the chin only measures the thickness of the symphysis.

With regard to the dimensions of the face as a whole, we shall only refer to what has been already stated concerning the inverse proportion of the area of the cranium, and that of the face, in different species of animals.*

The face represents a triangular pyramid, and offers for consideration three surfaces or regions: an *anterior*, a *superior*, and an *inferior*.

Anterior or *Facial Region.*

The numerous anatomical differences which this region presents form distinctive characters, not only of different nations, but also of different individuals.

It is bounded above by the forehead, below by the base of the inferior maxilla, and laterally by a line which passes along the external angular process, the malar bone, and the ridge which separates the canine fossa from the tuberosity of the maxilla. In this region we observe, *in the median line*, the nasal eminence; a transverse suture, formed by the union of the proper nasal bones with the os frontis, the *fronto-nasal suture;* below this suture, the *nose*, a pyramidal eminence, narrow above or at its root, broad below or at its base, and formed by two bones, which are united together by juxtaposition in the median line, and externally to the ascending process of the superior maxilla. Below this eminence is the *anterior orifice of the nasal fossa*, which has the form of a heart on playing cards, and presents at the bottom the anterior nasal spine, and below this a vertical suture, *the maxillary*, the interval which separates the middle incisor teeth, the opening of the mouth, and the symphysis menti. *On each side*, we find the opening or base of the orbit, directed obliquely outward, of an irregular square form, and presenting above the *supra-orbitary foramen;* below, the *infra-orbitary foramen;* on the outside, the *fronto-jugal suture;* and, on the inside, the *fronto-maxillary suture.* Below the opening of the orbit is the canine fossa, then the alveoli and teeth of the two jaws, the external oblique line, the mental foramen, and the base of the inferior maxilla.

Superior or *Cranial Region.*

This region is so united with the inferior surface of the cranium, that the scull and the superior maxilla form only one piece, and cannot be removed from each other. It presents, *in the median line*, counting from behind forward, the articulation of the vomer with the sphenoid, in which articulation there is a mutual reception of parts, the sphenoidal crest being received between the laminæ of the vomer, and these, in their turn, being lodged in corresponding fissures in the sphenoid; the articulation of the vomer with the posterior edge of the perpendicular plate of the ethmoid; the articulation of this perpendicular plate with the nasal spine of the frontal bone; and the articulation of this spine with the proper bones of the nose. *On each side*, proceeding from within outward, we observe, 1. The roof of the nasal fossæ, formed behind by the inferior surface of the body of the sphenoid; in the middle by the cribriform plate of the ethmoid; and in front by the posterior surface of the nasal bones. 2. More externally, the base of the

* *Vide* of the cranium in general; of the facial angle of Camper; the occipital angle of Daubenton, and the measurement of Cuvier, p. 45.

pterygoid processes, the articulation of the palate bone with the sphenoid, the pterygo-palatine canal, and the spheno-palatine foramen. 3. The articulation of the lateral masses of the ethmoid with the sphenoid behind, and with the frontal bone in front. 4. The articulation of the internal angular process of the frontal bone with the os unguis. 5. The articulation of the nasal notch of the frontal bone with the ascending process of the superior maxilla, and the proper bones of the nose. 6. More externally still, the roof of the orbit, bounded externally by the articulation of the frontal with the malar bone and the sphenoid, and by the sphenoidal fissure. 7. The anterior surface of the great wing of the sphenoid, which forms the largest portion of the external wall of the orbit; 8. Outside the orbit, the zygomatic arch.

Inferior or *Guttural Region.*

This region forms part of the pharynx and cavity of the mouth. It presents from behind forward, 1. A vertical portion; 2. A horizontal portion; and, 3. Another vertical portion.

The *vertical portion* (*fig.* 21) exhibits in the median line the posterior edge of the septum narium, formed by the vomer; the posterior extremity of the articulation of the vomer with the sphenoid (*o*, *fig.* 21); and the posterior nasal spine. On each side, the *posterior opening of the nasal fossæ* (*k o*, *y*), which is quadrilateral, longer in its vertical than in its transverse diameter, and formed internally by the vomer, externally by the pterygoid process (*r*), above by the sphenoid united with the palate bone, and below by the palate bone. More externally is the *pterygoid fossa* (*r*), formed by the sphenoid, and a small part of the palate bone. Still more externally, we find a deep fossa, or, rather, a large space bounded internally by the external plate of the pterygoid process and the tuberosity of the maxillary bone, and externally by the ramus of the inferior maxilla; it is known by the name of the *zygomatic fossa*.

The *horizontal portion* is the *arch of the palate* (*i x y*, *fig.* 21). It is of a parabolic form, extremely rough, and, in the fresh state, covered by the palatine mucous membrane. It is constituted by the palatine processes of the maxillary bones (*x*), and by the horizontal portions of the palate bones (*y*), and presents, in consequence, a *crucial suture*, at the central point of which the vomer is attached: hence the piece of anatomical nicety which consisted in asking at what part of the skeleton it is possible to touch five bones at once with the point of a needle. The arch of the palate is pierced by several foramina; we find here the inferior opening of the *anterior palatine canal* (1), which is single below, but double above, so as to open into each nostril separately; the *posterior palatine canals* (2), which open at the posterior and external part of the arch of the palate; and a *groove*, which runs along the external edge of the arch, and lodges the posterior palatine vessels and nerves at their exit from their canals.

The *third portion* is also vertical: it presents, 1. In the median line, the suture of the two superior maxillary bones, the interval between the middle incisor teeth of each jaw, the symphysis menti, and the genial processes. 2. On each side, the posterior surface of the alveolar border of the upper jaw, and the two rows of teeth which lie across each other like the blades of scissors in the middle, but meet posteriorly. 3. The posterior surface of the inferior maxilla, the internal oblique line, the sub-lingual and sub-maxillary fossæ, and, lastly, the base of the inferior maxilla.

Zygomatic or *Lateral Regions.*

These regions are bounded above and on the outside by the zygomatic arch; above and on the inside by the transverse ridge which separates the temporal from the zygomatic fossa. They present first a plane surface, formed by the ramus of the inferior maxilla; when this part is removed, we observe the *zygomatic fossa*, the superior wall of which is formed by the inferior surface of the great wing of the sphenoid, the anterior by the maxillary tuberosity, the internal by the outer plate of the pterygoid process, and the external by the ramus of the inferior maxilla. The posterior and inferior walls are wanting.

At the bottom of this fossa, between the maxillary bone and the anterior surface of the pterygoid process, is a large vertical fissure, named by Bichat the *pterygo-maxillary fissure*; this opening leads into a sort of fossa, denominated by the older anatomists *bottom of the zygomatic fossa*, and by Bichat *spheno-maxillary fossa*, which it is important to study carefully, because five foramina or canals open into it, viz., three behind; the *foramen rotundum*, the *vidian* or *pterygoid*, and the *pterygo-palatine* canals: a fourth on the inside, the *spheno-palatine*; and a fifth below, the superior orifice of the *posterior palatine canal*.

Lastly, the spheno-maxillary fossa presents, at the union of its superior with its anterior wall, the *spheno-maxillary fissure* (*fig.* 21, before 3), which, on the one hand, makes an acute angle with the sphenoidal fissure (or *foramen lacerum orbitale*), and, on the other, a right angle with the pterygo-maxillary fissure. The spheno-maxillary fissure, which is traversed solely by some nerves and vessels, is formed internally by the maxillary and palate bones, externally by the sphenoid, and at its anterior extremity, which is very broad, it is completed by the malar bone.

Cavities of the Face.

The study of those bones which we have been engaged in examining has made us acquainted with the existence of a great number of cavities, which considerably augment the size of the face, and multiply its internal surfaces, without proportionally increasing the weight.

All the cavities of the face may be reduced to three principal: viz., 1. The orbital cavities; 2. The nasal fossæ, of which all the sinuses are dependances; and, 3. The buccal cavity, or mouth.

The Orbits.

These cavities, two in number, have the form of quadrangular pyramids, the axes of which, prolonged backward, would intersect each other in the situation of the sella turcica. It should, at the same time, be remarked, that the internal wall of the orbit does not participate in this obliquity, but is directed straight from before backward. We have to consider in each orbit, a superior, an inferior, an external, and an internal wall; four angles which correspond to the intersection of these surfaces; a base and an apex.

The *superior wall*, or *roof of the orbit*, formed by the frontal bone in front, and by the orbital or lesser wing of the sphenoid behind, is concave, and presents from before backward, 1. Towards the outside, the lachrymal fossa. 2. On the inside, the slight depression in which the pulley for the superior oblique muscle is attached. 3. The suture between the lesser wing of the sphenoid and the orbital plate of the frontal bone. 4. The foramen opticum.

The *inferior wall*, or *floor*, forms a plane inclined outward and downward, and presents from before backward, 1. The infra-orbital canal. 2. A suture which marks the union of the malar bone with the superior maxilla. 3. The orbital surface of the superior maxilla. 4. A suture which marks the union of the superior maxilla with the palate bone. 5. The orbital facette of the palate bone.

The *external wall*, formed by the sphenoid and the malar bone, presents an almost vertical suture, which indicates internally the spheno-jugal suture.

The *internal wall*, formed by the os unguis, the ethmoid, and the sphenoid, presents two vertical sutures: in front, that which unites the os unguis to the ethmoid, and behind, that which unites the ethmoid to the sphenoid. In front of these sutures is the *lachrymal groove*, formed by the union of the os unguis and the ascending process of the superior maxilla; at the lower part of this groove we find the wide and very oblique orifice of the nasal canal or duct, which opens into the middle meatus of the nose, and establishes a direct communication between the orbital and nasal cavities.

Of the four angles, two are superior and two inferior. Of the two superior, one is internal, the other external. The *external superior angle* presents the sphenoidal fissure behind, and the inner aspect of the spheno-frontal and fronto-jugal sutures.

The *internal superior angle* presents the suture of union of the frontal bone with the ethmoid behind, and with the os unguis in front. The orifices of the two internal orbital foramina are seen in the situation of this suture.

Of the two *inferior angles*, the *external* presents the spheno-maxillary fissure, a portion of the malar bone, and the opening of the jugal canal. The *internal* presents an uninterrupted horizontal suture, which unites in front the maxillary bone to the os unguis; more posteriorly, the maxillary bone, and then the palate bone, to the ethmoid. The *base of the orbit* is cut obliquely from within outward, and from before backward; its vertical diameter is, for the most part, quite perpendicular to the horizon, but is sometimes rendered slightly oblique by the projection of the frontal sinuses. At the *apex* of the orbit is the union of the sphenoidal, the spheno-maxillary, and pterygo-maxillary fissures.

The Nasal Fossæ.

These fossæ are two in number, separated from each other by a vertical septum directed from before backward; they are situated in the middle of the face, and are prolonged into the interior of several of the bones of the face and cranium by means of the cavities called *sinuses*. To describe their situation more exactly, we may say that they are placed below the anterior and middle part of the base of the cranium, above the cavity of the mouth, between the orbits, and the canine and zygomatic fossæ of each side. In order to have an exact idea, either of the dimensions or the shape of the nasal fossæ, it is necessary to have recourse to horizontal and vertical sections, of which the latter should be made both from before backward and from side to side.

With regard to their dimensions, the nasal fossæ (see *figs.* 22 and 37) present, 1. A vertical diameter, larger in the middle than before or behind. 2. A transverse diameter much shorter than the other two, and gradually contracted* from the lower to the upper part, on account of the obliquity of the external wall. 3. An antero-posterior diameter, which measures the whole of the interval between the anterior and posterior openings of the nares.

* This progressive contraction of the nasal fossæ from below upward, and the obliquity of the external wall, ought to be remembered during the introduction of instruments into the nose.

The nasal fossæ have a horizontal direction, but are nevertheless slightly inclined backward and downward; this is caused by the sloping of the inferior wall and the obliquity of the body of the sphenoid, which forms part of the superior wall. They are irregular cavities, and have four walls; a superior, an inferior, an internal, and an external; and two orifices, an anterior and a posterior.

The *superior wall* or *roof of the nasal fossæ* presents a concavity looking downward: it is formed, 1. In front by the proper bones of the nose, and in a small degree by the nasal spine of the frontal bone. 2. In the middle, by the cribriform plate of the ethmoid. 3. Behind, by the body of the sphenoid. In this wall are two transverse sutures, namely: before, the suture which indicates the union of the nasal and frontal bones, and behind, that which marks the union of the ethmoid and sphenoid. At the back part of this wall the opening of the sphenoidal sinus is seen.

The *inferior wall* or *floor*, much broader but shorter than the superior, presents a transverse concavity; it is directed from before backward, and slightly from above downward, which arrangement concurs in determining the obliquity of the nasal fossæ. It is formed, in front by the superior maxilla; behind, by the palate bone; a transverse suture marks the union of these bones. Near its anterior extremity, and at the side of the median line, the floor of the nasal fossæ shows the superior orifice of each branch of the anterior palatine canal (*g*, *fig.* 22, and *o*, *fig.* 37).

The *internal wall* (see *fig.* 22) formed by the septum is generally flat, but sometimes concave or convex, according as it is bent to one or the other side.*

We find here the suture which indicates the union of the vomer with the perpendicular plate of the ethmoid (3 4, *fig.* 22); the septum in the skeleton is deeply notched in front, and this notch (1 4 8), which is formed above by the perpendicular plate of the ethmoid, and below by the vomer, is occupied in the fresh state by a cartilage, called the cartilage of the septum.

The *external wall* (*fig.* 37), remarkable for its anfractuosities, is formed by the ethmoid (*b c*), the os unguis, the palate bone (*m y*), the superior maxillary (*s u o*), and the inferior turbinated bone (*d*). It presents from above downward, 1. The *superior turbinated bone*, *superior concha*, or *concha of Morgagni* (*b*), in front of which is a rough square surface. 2. The *superior meatus* (between *b* and *c*), at the back part of which we find the spheno-palatine foramen (*n*), and the opening of the posterior ethmoidal cells. 3. Below the superior meatus, the *middle turbinated bone*, or *middle concha* (*c*). 4. Below, the *middle meatus* (between *c* and *d*), at the back of which is the opening of the maxillary sinus already described (*see* maxillary bone, *fig.* 25); and in front, the infundibulum (*s*, *fig.* 37), which leads into the anterior ethmoidal cells. 5. The *inferior turbinated bone*, or *inferior concha* (*d*). 6. The *inferior meatus* (*m o*), in which we find the *inferior orifice of the nasal canal*.

Fig. 37.

The anterior and posterior openings of the nasal fossæ have been described with the anterior and inferior regions of the face.

General Development of the Face.

The development of the face is not effected solely by an equable increase of its dimensions; for certain regions are at one period of life predominant, at another period relatively smaller, which circumstances give rise to very characteristic differences of form at different ages.

State of the Anterior Region of the Face at different Periods of Life.

In the Fœtus.—The upper part of the face shows a remarkable predominance, dependant upon the early development of the frontal bone and the great capacity of the orbits.

The middle portion, or the superior maxilla, on the contrary, is very much contracted by the absence of the maxillary sinus and canine fossa; the vertical dimensions of the superior maxilla and of the palate bone are so small, that the edge of the orbit and the alveolar border are almost contiguous. We should mention here that the prominence of the alveolar border, which still encloses all the germs of the teeth, is the principal cause of the absence of the canine fossa. Lastly, the inferior maxilla is contracted in its vertical diameter, like the superior, and, like it, presents a decided prominence in front, by reason of its enclosing the germs of the teeth in the alveoli. The inclusion of the dental germs also, by causing the alveolar border to project, produces a degree of obliquity downward and backward of the symphysis; to these causes of the small extent of the vertical dimension of the face, we must add also the inconsiderable height of the ethmoid at this period.

* Sometimes the deviation of the septum is so considerable that the internal touches the external wall, and, consequently, there is great difficulty in the passage of the air. This circumstance has given rise in some cases to a suspicion of the existence of polypus.

The transverse dimensions of the face are very considerable at the level of the orbits; at the lower part of the face, on the contrary, they are proportionally much less than in the adult.

The characteristics, then, of the face of the fœtus are, 1. The smallness of its vertical dimension. 2. The predominance in size of its upper over its lower part.

In the adult, the development of the maxillary sinus, the widening and vertical extension of the alveolar arches, give to the face the expression which characterizes it at that period of life.

In the aged, the loss of the teeth, and the disappearance of the alveolar edge, partly restore to the face the expression which it had in the fœtus; but the elongation and prominence of the chin, which, from the diminution of the vertical diameter, approaches the nose, and the symphysis of which is now oblique from behind forward and downward, impress upon it a peculiar character. The obliquity of the chin, just mentioned, is precisely the reverse of that which exists in the fœtus.

State of the Lateral Regions in different Ages.

These regions undergo the fewest changes of all; for if, on the one hand, the development of the maxillary sinus tends to increase the prominence of the maxillary tuberosity in the adult, on the other, the inclusion of the dental germs in the superior maxilla, during fœtal life, compensates for the want of the sinus.

State of the Posterior Region of the Face at different Ages.

In the *guttural portion*, this region presents, in the fœtus and the infant, the following circumstances: the posterior borders of the rami of the jaw are very oblique, instead of being almost vertical, as in the adult; the pterygoid processes, and the posterior nasal openings, are also directed very obliquely downward and forward, instead of vertically, on account of the absence as yet of the maxillary sinus, which, during its development, carries them backward. From the obliquity of the posterior border of the ramus of the jaw, it follows that the articular surface of the condyle which surmounts it looks backward instead of upward.

In the *horizontal* or *palatine portion*, the inferior region of the face has proportionally less extent from before backward than in the adult, on account of the obliquity of the pterygoid process, and the slight development of the maxillary sinus. We perceive, then, how great an influence the varying conditions of these sinuses exercise over the whole configuration of the face, at the different periods of life.

It may be easily conceived that the cavities of the face must undergo important changes during these alterations in the shape of the face which we have been describing. The most remarkable is the tardy development of the nasal fossæ compared with that of the orbits. It may even be said that they proceed in an inverse ratio. The orbital cavity, intended to receive the globe of the eye, which is already highly developed at the time of birth, is of great capacity. This magnitude it owes entirely to the rapid growth of the frontal and sphenoid bones; because the malar bone and the superior maxilla contribute but little towards it, and the height of the ethmoid is so small, that the vertical diameter of the orbit, which depends upon that of the ethmoid, is less considerable than its transverse diameter. The nasal fossæ, which are very small in the fœtus, gradually acquire an increased extent of surface, by the growth in height of the ethmoid, the palate bone, the superior maxillary, and the vomer, and by the augmented size of the turbinated bones; and their surface is still farther extended by the enlargement of the maxillary, sphenoidal, and frontal sinuses, and the ethmoidal cells. The development of the frontal sinus, it may be observed, is owing chiefly to the separation of the two tables of the bone, the anterior of which is almost always thrown forward, the posterior remaining stationary. There are, however, some examples on record, in which it was evident that the sinus was formed almost exclusively by the retrocession of the posterior table.

THE THORAX, OR CHEST.

The Sternum.—Ribs.—Costal Cartilages.—The Thorax in general.—Development.

The thorax (θώραξ, the chest) is a sort of bony cage intended to contain and protect the principal organs of respiration and circulation. The parts which enter into its composition are twelve dorsal vertebræ behind, the *sternum* in front, and twelve flexible bones named *ribs*, on each side. We have already described the dorsal vertebræ, and have now, therefore, only to notice the sternum and the ribs.

The Sternum (*a b c*, *fig.* 38).

The sternum, so named from the Greek word στέρνον, the breast, is a kind of flattened, symmetrical, bony column, which occupies the anterior and middle part of the thorax. It is situated between the ribs, which support it like props. The clavicles,

and through them the upper extremities, rest upon its upper part as a basis, during their movements. The sternum is not immovably fixed in its place; it is raised and depressed, as we shall point out in describing the mechanism of the thorax.

The length of the sternum, which is proportionally smaller in the female than in the male, varies from 5½ to 7½ inches. At its upper part its breadth is from 1½ to 2 inches; it then becomes contracted, then again expands, and terminates below in a very narrow extremity. Its thickness above is about 6 lines; at its lower part it is much thinner, never exceeding 3 lines.

With regard to figure, the sternum was compared by the ancients to the sword of a gladiator, and from this have arisen the denominations given to its various parts. The upper part (*a*), which is broadest, has been called the *handle* (*manubrium*); the middle part (*b*), the *body* (*mucro*); and the lower extremity (*c*), the *point*; *xiphoid appendix* (*processus ensiformis*). This division of the bone into three parts has been retained by some modern anatomists, who describe the three pieces of the sternum separately as so many distinct bones. We shall adhere to it only, however, in speaking of the development of the bone.

The sternum presents two surfaces, two borders, and two extremities.

1. The *anterior* or *cutaneous surface* is slighly convex, and forms an oblique plane downward and forward; it presents three or four projecting transverse lines, which are traces of the union of the original pieces of the bone, and divide it into surfaces of unequal size. The line which marks the union of the first two pieces of the bone is the most remarkable; it causes a projection of variable size in different individuals, which has been sometimes mistaken for a fracture or exostosis. At the lower part of this surface, we find in some subjects a *foramen* which perforates the bone: sometimes, in place of this foramen, there is a considerable aperture, to which much importance has been attached, as affording a proof of the primitive separation of the bone in the median line. The existence of this opening explains how purulent matter, deposited behind the sternum, may in certain cases make its way outward without any absorption of the bone. The anterior surface of the sternum is covered by the skin, and an interlacement of very numerous aponeurotic fibres.

2. The *posterior*, *mediastinal*, or *cardiac surface* (*a b c*), is slightly concave from above downward, and presents, in young subjects, lines (*e e*) corresponding to those which occupy the anterior; but all which, excepting the one between the first and second pieces of the bone, are effaced at a more advanced age. This surface is in relation with many organs contained in the chest, and especially the heart, in front of which the sternum forms a kind of shield.* At the lower part of this surface are several nutritious foramina.

3. The *borders*, very thick and sinuous, present seven articular cavities (*d d*, &c.), separated from each other by semilunar notches, which are longer above than below, where the facettes closely approach one another. The uppermost of these seven cavities is shallow, triangular, and at an early age becomes ingrained with the cartilage of the first rib; those which follow are deeper, angular, and situated at the extremities of each of the lines (*e e*) above mentioned; they are all intended to articulate with the cartilages of the first seven ribs. When examined in a dried specimen, they appear more angular and deeper in proportion to the youth of the subject.

4. The *superior* or *clavicular extremity* is the broadest and thickest part of the whole bone, presenting a notch, transversely concave, which bears the name of *fourchette* (*f*) of the sternum (or *semilunar notch*); on each side (*g g*) is an oblong articular surface, concave from without inward, convex from before backward, articulated with the clavicle, and surrounded with inequalities for the insertion of muscles and ligaments. It frequently happens that the two clavicular facettes are not at the same height; a fact which was noticed by Morgagni, and which I have attributed to the unequal wearing of the two articular surfaces.

5. The *inferior* or *abdominal extremity* is formed by the *xiphoid appendix* (*c*) (ξίφος, a sword), called also *xiphoid* or *ensiform cartilage*, because it often remains cartilaginous to adult age. In length, shape, and direction, it presents numerous varieties; it is frequently bifid, sometimes pierced by a foramen, and is accasionally bent forward, or to one side, and, in certain cases, much depressed: its summit gives attachment to an aponeurotic structure, called the linea alba; behind, it indirectly corresponds with the stomach, which rests upon it when the body is placed in a prone position.†

* This use of the bone is exemplified in many animals which are provided with a sternum, though they have no ribs; for example, the frog.

This bone has attracted much of the attention of the modern transcendentalists. By them it is regarded as a vertebral column anterior to the intestinal canal in man, and inferior to it in the lower animals. Many of them have conceived that they have found in it a cervical, a dorsal, and a lumbar region, &c., &c.

M. Cruveilhier, in the opinion of the editor, with much propriety, in the first edition of his work, took no notice of the idle and fanciful speculations of the transcendentalists, either in reference to the sternum, or to the analogy which exists between the bones of the cranium and the vertebræ. Although he has, in the second edition, introduced some notices in reference to the analogy which these gentlemen have attempted to establish between the cranium and the vertebral column, believing that they only increase the size of the book without adding to its value, we have excluded them.—Ed.

† In front this appendix is sub-cutaneous, and the skin which covers it is so sensible that the slightest con-

Connexions.—The sternum articulates with sixteen bones, viz., fourteen ribs through the medium of their cartilages, and the two clavicles.

Structure.—It consists of two very thin compact laminæ, with an intervening spongy substance, the cells of which are very large, and have very delicate parietes; it is one of the most spongy bones of the body, and to this circumstance the frequency of its diseases is doubtless attributable.

Development.—The sternum is one of the slowest bones in its ossification; up to the sixth month of fœtal life, the broad cartilage of which it is composed exhibits no bony points. It is also, of all the bones, the one in which the phenomena of ossification proceed with least regularity. For the sake of simplicity, we shall study in succession the development of the three parts which we have indicated, under the names of manubrium, body, and xiphoid appendix.

1. *Ossification of the Manubrium.*—This part of the bone sometimes presents a single nucleus, rounded, and transversely oblong; sometimes it presents two nuclei, and, in this case, they may be either placed one above the other, or side by side. In the former case, the uppermost nucleus is the larger; in the latter, both may be symmetrical and of equal size, or, what is far more common, they may be of unequal magnitude. Lastly, the manubrium occasionally presents more than two osseous points. Albinus found three in one subject and four in another.

It should be remarked, that in the case of plurality of osseous points, the largest are generally situated above: the exceptions to this rule are very rare. The osseous points make their appearance from the fifth to the sixth month of fœtal life.

2. *Of the Body.*—The osseous nuclei which enter into the composition of the body of the sternum have generally a rounded form when they are single, and are situated in the median line; when they exist in pairs, or are placed laterally, they are more elongated, but smaller, and appear to represent only the half of one of the single nodules. These different osseous points are always so arranged as to be situated between two costo-sternal articulations, so that a portion of the sternum is developed in each of the intervals comprised between two ribs. The last piece is the only exception, being common to the articulation of the sixth and seventh ribs.

If there be more osseous points than one in an intercostal space, these, as Albinus has remarked, are invariably placed laterally, not one above the other.

There are, therefore, four primitive pieces in the body of the sternum, and each of these is sometimes formed by one point of ossification; at other times, by two lateral points.

The following is the order in which the ossification of the body of the sternum proceeds: the two upper pieces first appear from the fifth to the sixth month of fœtal life; the third is visible at the sixth month; the fourth most commonly makes its appearance after birth, but sometimes towards the end of gestation.

In the ossification of the body of the sternum, we more frequently find examples of two symmetrical nodules placed on opposite sides of the median line, than in the development of the manubrium.

Union of the Points of Ossification of the Body.—In considering the union of the different parts which compose the body of the sternum, it is necessary to make a distinction between the *lateral conjunction*, that is, the union of the osseous points which are situated on each side of the median line, and the *vertical conjunction*, or the union of the pieces of the sternum properly so called. The lateral conjunction, or the union of those osseous germs which form a pair in the same interval, always precedes the vertical conjunction. The vertical conjunction, or the union of the pieces of the body of the sternum together, commences with the two inferior portions. After this union, the body of the bone consists only of three parts. The second piece then unites with the lower; the sternal foramen is found sometimes at the junction of these last-mentioned parts, sometimes at the place where the two lateral points of the fourth and of the third portion of the body are united. The first piece of the body is not united to the two others until from the twentieth to the twenty-fifth year.

It should be observed, that the union of the divisions of the body of the sternum takes place precisely in the inverse order of their appearance. In fact, the appearance of the osseous points proceeds from above downward, their union from below upward; a fact which verifies an assertion formerly made, viz., that the order of development of osseous points is not always correlative to the order of conjunction.

3. *Ossification of the Appendix.*—This is generally accomplished by one nodule: some-

tusion produces, even in the most powerful men, syncope.* This fact may explain the importance which has been attached to the configuration of this process, and to the names "*pit of the stomach*," "*scrobiculus cordis*," "*præcordium*," which have been given to the region which corresponds to it. Much has been said of the displacement of the xiphoid appendix, and of the accidents to which this has given place; but, in reality, these displacements have never been observed, and the accidents which have been attributed to them have most certainly depended on an injury inflicted on the parts situated behind it.

* We do not believe that the skin situated over this appendix is more sensible than the skin elsewhere. The syncope which follows a blow here is, in our opinion, produced by the impression it produces on the internal organs.—Ed.

times there are two, and then they are rarely symmetrical. The process commences in the upper part of the cartilage, and very rarely extends through the whole. The time of appearance of the osseous point is extremely variable; sometimes it is visible towards the third or fourth year; sometimes not until the twelfth, or even the eighteenth year.

In adult age, the sternum is composed of the three parts the development of which I have just noticed, and which the ancients considered and described as distinct bones. From the fortieth to the fiftieth year, and sometimes later, the appendix becomes united to the body, which very rarely joins the manubrium; when such is the case, the union is more apparent than real; for if the bone be cut vertically, the articulation is apparent, under a very thin layer of osseous matter.

From what has been said of the numerous varieties of ossification, it will be evident that it is impossible to assign to this bone a limited number of osseous points. To those which have been noticed I would add two others, described by Béclard under the name of *supra-sternal points*, which I have seen once only in the sternum of an adult, in the form of pisiform nodules, placed on each side of the semilunar notch of the sternum.

The Ribs (1 to 12, *fig.* 38).

The ribs (*costæ*, from *custodes*, as if, according to the explanation of Monro, they were the guardians of the organs of the chest) are osseous arches stretched from the vertebral column to the sternum. Their posterior four fifths consist of bone; the anterior fifth is cartilaginous. The osseous portion is the rib, properly so called; the cartilaginous portion is named the costal cartilage.

Fig. 38.

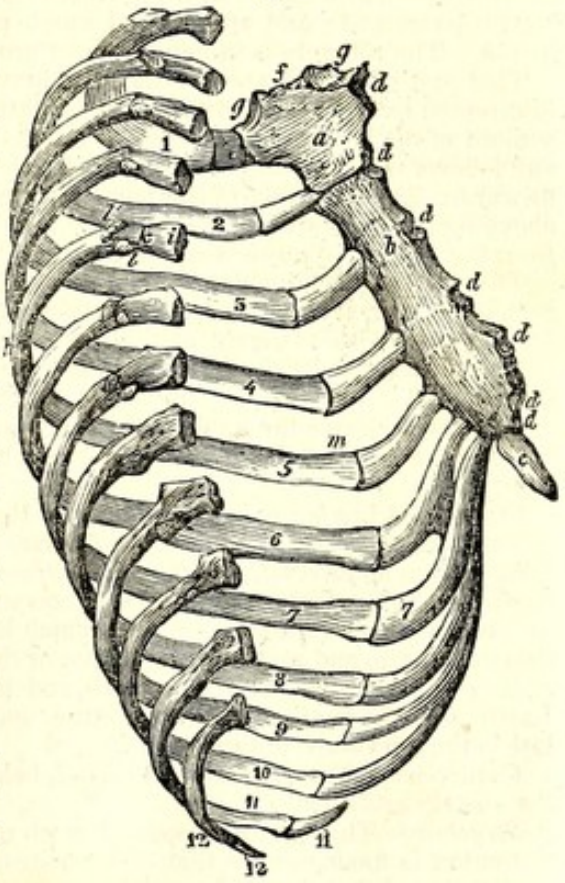

The ribs are 24 in number, 12 (1 to 12) on each side. Sometimes there are 26, thirteen being on each side, and then these supernumerary ribs are formed either from a part of the transverse process of the seventh cervical vertebra, or of the transverse process of the first lumbar, which affords an evident proof of the analogy existing between these parts. Sometimes, but more rarely, there are only 22 ribs, an anomaly pointed out by Galen. In this case, we sometimes find two adjacent ribs united throughout their entire length, sometimes the first rib in a rudimentary state, being properly formed posteriorly, but having its anterior extremity lost in the substance of the scaleni muscles, or united to the second rib, and through it joined to the sternum.*

The ribs are divided into two classes: 1. Those which extend from the vertebræ to the sternum, the *true ribs*, *sternal* or *vertebro-sternal ribs* (1 to 7). 2. Those which do not reach the sternum, the *false*, *asternal*, or *vertebral ribs* (8 to 12). The last two false ribs (11 12) are called *floating*, because their anterior extremity is movable in the fleshy parietes of the abdomen. The ribs are designated numerically *first*, *second*, &c., counting from above downward. It should, however, be observed, that in many surgical works, the ribs are counted from below upward, which is the easiest method on the living subject.

The ribs have certain *general characters* which distinguish them from all other bones, and certain *proper characters*, by which one is known from another.

General Characters of the Ribs.

The ribs resemble flattened bony arches of about six lines in breadth, and one in thickness, and of lengths varying according to their situation. The first rib is almost horizontal, and the others in succession slope gradually more obliquely from behind forward, and from above downward, their anterior extremities being on a much lower plane than the posterior. Considered with regard to their axes, *i. e.*, their absolute direction, the ribs represent portions of a circle which successively increase to the eighth, and dimin-

* In a subject prepared for my lectures, the transverse processes of the second, third, and fourth lumbar vertebræ were elongated, so as to form supernumerary ribs, while the transverse process of the first was unchanged.

ish again to the twelfth; their curvature is not regular, the posterior part representing the segment of a much smaller circle than the anterior. They are generally *twisted* upon themselves, so that their two extremities cannot rest at once upon the same horizontal plane. The point where this torsion exists is marked on the convex surface by an oblique projecting line, called the *angle* (*h*) *of the rib*; but it is not correct to consider the angle of the rib as resulting from this torsion; it appears to me simply intended for muscular insertions.

The ribs have a body and two extremities. The posterior or vertebral extremity is thicker than the rest of the bone, whence it has received the name of *head* (*i*) (*capitulum costæ*), and presents two half surfaces (*c c*, *fig.* 39), of which the upper is smaller than the lower, separated by a horizontal ridge. These two facettes articulate with corresponding surfaces on the bodies of the dorsal vertebræ (*d d*, *fig.* 39). The head is supported by a constricted portion, the *neck* (*k*, *fig.* 38), which is flattened from before backward, and is the weakest part of the bone. It presents behind some inequalities which correspond to the transverse process of the dorsal vertebra below. Externally to the neck is an eminence known as the tubercle (*l l*) of the rib; it is divided into two parts, which are united at an angle, viz., an internal and inferior portion (*l*), smooth and convex, which articulates with the transverse process of the vertebra below the particular rib examined; and an external rough portion (*l*), which gives attachment to ligaments. The tubercle is in general most prominent in the upper ribs.

Fig. 39.

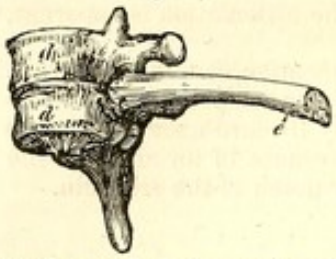

That part of the rib which is included between the head and the tubercle (*neck*, *cervix*) is directed from within outward, and slightly from above downward, so as to reach the summit of the transverse process of the vertebra below. Beyond the tubercle, the rib still follows the same direction for not more than fifteen lines; it is then bent decidedly forward. The situation of this curve, which corresponds with the torsion of the edges above mentioned, is at the angle of the rib. The interval which separates the tuberosity from the angle is the thickest and strongest part of the rib.

The rest of the rib which is before the angle becomes broader and thinner, and is directed forward, so that, as Haller expresses it, the line which it describes represents in some measure the tangent of the posterior curve. The anterior extremity (*m*) has a hollowed oval facette for receiving the cartilage. Besides the objects we have already described, we observe, near the anterior extremity of the rib, an oblique line, analogous to that which forms the angle, but much less marked. This line may be considered as forming the anterior angle of the ribs, and, like the posterior, it is intended for muscular insertions.

From what has been said, we perceive that the ribs present, 1. A posterior extremity or *head*, supported by a *neck*; 2. An *anterior extremity* united to the *costal cartilage*; 3. A *body*, having an *external*, or *cutaneous surface*, which is convex; and an *internal*, or *pulmonary surface*, which is smooth and concave; a *superior edge*, which is curved, thick, and rounded; and an *inferior edge*, which has a greater curvature than the superior, is thin and sharp, and marked by a groove or furrow on the inner surface, called the *groove of the ribs* (*e*, *fig.* 39), which receives and protects the intercostal vessels and nerves. Lastly, the ribs have a double curvature, one of the surfaces, another of the edges; this last is the curvature of torsion.

Connexions.—The ribs are articulated, behind, with the dorsal vertebræ; in front, with the costal cartilages.

Structure.—The external aspect of a rib resembles a long bone; but the internal conformation is analogous to that of flat bones. The compact and spongy substances are so distributed that these bones enjoy a certain degree of flexibility, with great power of resistance. In young subjects, the compact substance is in excess; in the aged, and in certain diseases, the opposite is the case; hence the extreme fragility of these bones, which are then broken by the least effort.

Development of the Ribs.—The ribs are among the earliest developed of the bones, the ossification of their bodies commencing from the fortieth to the fiftieth day after conception. They are developed by three osseous points: one primitive, and two epiphysary. The primitive point by itself forms the body of the bone. Of the two epiphysary points, one is intended to form the head of the rib, the other the tubercle. They appear from the sixteenth to the twentieth year, and they unite with the rest of the bone about the twenty-fifth year. These epiphysary points do not exist in the two lower ribs, which, consequently, have only one point of ossification.

Special Characters of different Ribs.

The differential characters of the ribs have reference, first, to the length, which increases gradually from the first to the seventh, and diminishes again to the twelfth; secondly, to the curvature, the four upper ribs being parts of much smaller circles than the rest, and thus forming the summit of the cone of the chest, while the lower ribs constitute its

base; and, lastly, to certain peculiarities of conformation in the first, second, third, eleventh, and twelfth ribs, which require special description.

The *first rib* (1, *fig.* 38, and *fig.* 40) is the shortest, and proportionally the broadest of all the ribs, thus forming an imperfect lid to the bony case which constitutes the thorax. Its edges are curved, but its surfaces are flat. The curve which it describes forms part of the circumference of a much smaller circle than any of the other ribs. The posterior extremity has a small head with a single convex facette (*a*, *fig.* 40), supported by a long, thin, and cylindrical neck (*b*). The tubercle (*c*) is very prominent; it occupies the external border, and gives an angular appearance to this rib. The anterior extremity (*d*) is broader than that of any other rib. Of the two surfaces, one is directed upward and slightly outward, the other downward and a little inward. The superior surface (*fig.* 40) has two depressions separated by a tuberosity (*e*). The anterior corresponds to the subclavian vein; the posterior to the artery of the same name. The tuberosity which separates them gives attachment to the anterior scalenus muscle. The internal edge (*a e d*) is concave; the external (*a c d*) is convex, and has no groove. The first rib has neither a curvature of torsion, nor an angle; so that the whole of it can rest upon the same horizontal plane. The superior surface presents, also, near its anterior extremity, a depression, which appears to result from pressure by the clavicle, which I have seen, in some cases, immediately articulated with this bone.

Fig. 40.

The *second rib* (2, *fig.* 38) preserves many of the characters of the preceding, but differs essentially in its length, which is at least double; it belongs to a much larger circle: it has no curvature of torsion, and can rest upon the same plane with its two ends; the angle is scarcely visible. The external surface is directed upward; it presents in the middle a very rough eminence for the attachment of the serratus magnus muscle. The internal surface looks obliquely downward; near the tubercle it has a very small groove.

The *third rib* (3, *fig.* 38) differs from the second by its great length, by the presence of the angle, and by a curvature of torsion sufficient to prevent the two ends from resting at once upon the same horizontal plane.

The *eleventh* and *twelfth ribs* (11 12, *fig.* 38) differ from all the others by the following characters: 1. They form segments of much larger circles than any of the others; 2. Their heads have only one articular facette, and this is flattened; 3. They have no neck, properly so called; 4. They have no tubercle: 5. They have no groove; 6. They have a very thin and pointed anterior extremity. These two ribs differ from each other only in length, the twelfth being the shorter.

The Costal Cartilages (1` to 12`, *fig.* 38).

The flexibility and elasticity of the ribs is partly owing to their structure, but more especially to the costal cartilages which prolong them in front. There are twelve costal cartilages, distinguished numerically as first, second, third, &c.; they are separated from each other by intervals, which are very considerable at the upper part of the thorax, but gradually diminish as we proceed downward: it is not very uncommon to meet with thirteen cartilages on one side; at other times there are only eleven. We sometimes find two cartilages which are joined together, and articulated with the sides of the sternum; when there are thirteen cartilages, the supernumerary one generally exists between the third and fourth ribs; it is thin, and, as it were, rudimentary; it does not form the continuation of any rib, and terminates insensibly in the muscles. The first seven cartilages (1 to 7) articulate immediately with the sternum; and hence the name of sternal given to the ribs with which they are connected. Of the other five cartilages, the last two (11 12) have no connexion with those that precede them; and, from this circumstance, the name *floating* has been given to the last two ribs.

General Characters of the Costal Cartilages.

All the costal cartilages are flattened like the ribs, and precisely resemble, in breadth and thickness, the bones to which they are attached. The external end is received into a cavity hollowed out in the anterior extremity of the rib: their internal or sternal extremity, which is much narrower than the external, is angular, and articulates with the corresponding angular facettes of the sternum. Their anterior or cutaneous surfaces are slightly convex, and covered by the muscles of the anterior region of the trunk, to many of which they give attachment. Their posterior or mediastinal surfaces are slightly concave. Their superior and inferior edges bound the intercostal spaces, and give attachment to the muscles of the same name. They are altogether distinct from articular cartilages, and have a peculiar tendency to ossify, this process taking place partly on the surface, and partly from within outward.

Differential Characters of the Costal Cartilages.

The costal cartilages increase in length from the first to the seventh, and sometimes to the eighth, which in this case articulates with the sternum; they diminish in length

from the seventh to the twelfth. This difference depends on the circumstance that the osseous parts of the upper ribs terminate anteriorly in a line directed obliquely from above downward, and from within outward, and that the sternum is only about half the length of the lateral wall of the thorax, so that only the first four or five cartilages could join this bone, did not the others bend upward, so as to reach its sides or join the lower edge of the cartilage above; the first three cartilages alone, therefore, follow the same direction as the bony rib. The *first cartilage* differs from all the others by its shortness, its thickness and breadth, and its tendency to ossify; it is almost always bony in the adult; it is often continuous with the sternum, but is sometimes only contiguous, in which case its articulation to this bone presents a great difference as respects motion. The *second* and *third costal cartilages* cannot be distinguished from each other, but they differ from the rest in being joined at right angles with the sternum, in not being bent, and in being as broad at their sternal as at their costal extremities. The *fourth cartilage* becomes bent upward, after having followed the direction of the rib for a little way. The length and curvature of the cartilages of the fifth, sixth, and seventh ribs progressively increase: the seventh is at least three inches long, while the fifth is not more than thirteen or fourteen lines; their inner ends become successively narrowed, so as to correspond with the diminishing cavities on the edges of the sternum; the borders of the fifth, sixth, seventh, and eighth costal cartilages articulate together, and present, for this purpose, articular facettes, supported by eminences. The cartilages of the eighth, ninth, and tenth ribs gradually diminish in length; externally they have the same breadth as the rib, and decrease as they pass inward, so as to terminate by a pointed extremity, which is applied to the lower edge of the rib above. The cartilages of the eleventh and twelfth ribs are extremely short, especially that of the twelfth, which is only a few lines in length; their internal free extremity loses itself, so to speak, in the substance of the abdominal parietes, so that they are altogether unconnected with the other cartilages.

The Thorax in general.

The sternum, the ribs, and the whole dorsal region of the vertebral column, form the framework of a large visceral cavity, the *thorax*, intended to contain and protect the chief organs of respiration and circulation. It occupies the upper part of the trunk, between the thoracic extremities; its boundaries are very well defined above, but below there is not any line of demarcation in the skeleton between the cavities of the thorax and abdomen; or, rather, the bony thorax is common to the thoracic and abdominal viscera. We shall see afterward, that these two cavities are separated from each other by a movable and muscular septum called the diaphragm.

With regard to capacity, the thorax holds a middle place between the cavity of the cranium and that of the abdomen. In each individual, the capacity of the thorax is exactly proportional to the volume of the lungs; and as, in general, voluminous lungs coexist with a highly-developed muscular apparatus, it follows that the size of the thorax is no equivocal sign of a vigorous constitution. The thorax differs much from the abdominal cavity in regard to its extensibility, being only capable of very limited alternate movements of dilatation and contraction. In the structure of the thorax, we find the twofold condition of solidity and mobility in so perfect a degree, that the framework of which it is composed is equally fitted to serve as a protecting structure and a respiratory apparatus. This limited dilatability contrasts, on the one hand, with the almost indefinite extensibility of the abdominal cavity, and, on the other, with the absolute want of extensibility in the cranium.

We should form a very incorrect idea of the dimensions and shape of the thorax, if we were to judge of them by its external aspect while still covered by the soft parts, and surrounded by that species of girdle which is formed by the shoulder round its upper part; for we should then conclude it to be a truncated cone, with the base above. On the contrary, when the surrounding parts are removed, the thorax represents a cone, the base of which is in precisely the opposite direction, that is, below. The height of the thorax cannot be measured with exactness, because it varies according to the depression or elevation of the muscular septum, which intervenes between the thoracic and the abdominal cavities. We can only say, that the bony framework should be divided into two parts, a superior or supra-diaphragmatic, which belongs to the chest, properly so called, and contains the lungs and heart; and an inferior, which forms part of the cavity of the abdomen, and contains the liver, the spleen, the kidneys, the stomach, the duodenum, and part of the colon. It should be also remarked, that the supra and sub-diaphragmatic portions of the thorax constantly vary in their respective proportions; and that these variations of height principally take place at the sides, the middle remaining always nearly the same. The transverse diameters increase rapidly from the upper to the lower part of the thorax. The same is true of the antero-posterior diameters, and these also sensibly increase opposite the concavity of the dorsal region of the spine. The antero-posterior diameters are much greater laterally than in the median line, where they are diminished by the considerable projection of the bodies of the dorsal ver-

tebræ. This shortness of the antero-posterior diameters between the sternum and the vertebral column is in proportion to the small size of the heart, which is situated in this region, as compared with that of the lungs, which occupy the sides.

Antero-posterior Flattening.—The cone represented by the thorax is flattened from before backward. This flattening appears to be connected with the existence of the clavicle, for we meet with it in all animals provided with this bone, while in those in which it does not exist the flattening is lateral, *i. e.*, from one side to the other.

The shape of the thorax is subject to many varieties, as respects different individuals, age, sex, &c. Of the individual varieties, some are compatible with health, others are pathological, and constitute malformations, the history of which belongs to the subject of diseases of the chest. Sometimes they are congenital; at other times they are the result of accidental circumstances which have modified the primitive conformation.

In some subjects the lateral exceeds the antero-posterior flattening, and the sternum is prominent, as we habitually see it in the thorax of phthisical patients.

Many individual varieties of conformation of the thorax are the effect of frequently repeated, or permanent compressions exercised on the bony cavity. I have seen infants in whom the thorax was perfectly well formed at birth, but had been deformed and flattened on the sides by pressure from the hands of the nurse. If there be, in fact, a time when the slightest external pressure may be productive of permanent deformity, it is during the first years of life. The effects of a strong and permanent constriction are also manifest in a very evident manner, in the alterations of the form of the thorax consequent upon the use of stays. This species of constriction affects principally the lower part of the chest; so that the fifth, sixth, seventh, eighth, ninth, and tenth ribs are pressed forward and inward, because the length and flexibility of their cartilages allow them to yield readily; and all the viscera which correspond to this species of girdle undergo very marked alterations in their direction, and even in their figure and position. Thus the liver, the spleen, and the stomach are forced upward and compress the lungs, which, in their turn, are pushed to the upper part of the chest, and have a tendency to pass considerably beyond the level of the first rib; 2. The stomach becomes more oblique; 3. The transverse arch of the colon is often forced downward; the pregnant uterus acquires an oblique direction. In an old female, whose thorax was so contracted below as to present the appearance of a barrel, and bore witness to the use of a very tight corset, the cartilage of the seventh rib, on the right side, was in contact with that of the opposite rib; the xiphoid appendix was strongly depressed, and pushed behind the cartilages of the seventh and eighth ribs, which touched each other. Some varieties of conformation depend upon deviations of the vertebral column; they evidently belong to pathological anatomy, and need not occupy our attention. In the female, the chest resembles a cone, with a larger base, but of less height than in the male.

There are certain varieties at different ages, which will be noticed in the history of the general development of the thorax.

As the thorax does not form a regular cone, when we speak of its *axis* being directed obliquely from above downward, and from behind forward, we only refer to its anterior wall, the posterior and lateral being altogether devoid of this obliquity.

We shall now consider in detail the external and the internal surface of the thorax; the inferior circumference or base, and the superior circumference or summit, resulting from its conical form.

External Surface of the Thorax.

On this surface we find an anterior, a posterior, and two lateral regions.

The *anterior* or *sternal region*, much wider below than above, forms a plane inclined from above downward, and from behind forward, and more or less projecting according to the general conformation of the thorax. It presents, 1. In the middle, the cutaneous surface of the sternum; 2. On the sides, the series of articulations of the cartilages of the ribs with the sternum; 3. The costal cartilages, those being the longest which appertain to the lower ribs; 4. Between the cartilages, certain intervals named *intercostal spaces*; 5. Externally to the cartilages, an oblique line running from above downward, and from within outward, and marking the series of articulations of the costal cartilages with the ribs; 6. Still more externally, another oblique line, which has not been pointed out, and which is formed by the anterior angles of the ribs; it corresponds in obliquity with the chondro-sternal line, and forms the boundary of the anterior region.

The *posterior* or *vertebral region* presents, in the median line, the series of dorsal spinous processes; on the sides, 1. The vertebral grooves; 2. The series of dorsal transverse processes; 3. Their articulation with the tubercles of the ribs; 4. A series of surfaces, of which the lower are the largest, and which are comprised between the angle and the tubercle of each rib; 5. Lastly, an oblique line, running from above downward, and from within outward, formed by the posterior angles of the ribs.

The *lateral* or *costal regions* resemble a sort of curved grate, more convex behind than in front, and showing the series of ribs and intercostal spaces in the same manner as the anterior and posterior regions. They increase in width from above downward, and

form a sort of inclined plane, with a curved surface, and obliquely directed from above downward, and from within outward. The first two intercostal spaces are both the broadest and the shortest; the third and fourth are broader in front than behind; the following are of almost uniform width through their whole extent: on the whole, the breadth of the spaces diminishes from above downward, or, as Bertin remarks, the edges of the lower ribs are almost in contact. The last two intercostal spaces form the only exception, for they are nine lines in width, while those in the middle of the chest are only about four. It should, moreover, be remarked, that the intercostal spaces are broader in front than behind; a fact which may be easily shown by comparing the distance which separates the anterior extremities of the first and second ribs with that which intervenes between their posterior terminations. The length of the intercostal spaces increases from the first to the sixth; it then diminishes to the last two, where it is very small.

Internal Surface of the Thorax.

This surface, like the external, is divided into four regions. The *anterior region* exactly resembles the anterior region of the external surface, with this difference only, that it is concave instead of being convex.

The *posterior region* presents, 1. In the median line, the dorsal portion of the spinal column, which, like an incomplete septum, forms a projection in the interior of the thoracic cavity, and divides it into two equal parts; 2. On the sides, two deep grooves, which are contracted above, but gradually enlarge towards the lower part. These grooves, which lodge the posterior convex portions of the lungs, exist only in the human subject; they allow part of the weight of the body to be thrown backward—an arrangement which is very advantageous for preserving the equilibrium in standing, and is a proof that man is destined to the erect posture.

The lateral regions form an inclined plane on the inside, resembling that which exists on the outside, only they are concave instead of being convex.

Superior and Inferior Circumferences.

The *superior circumference* or *summit* is narrow in comparison with the inferior, and slopes obliquely from above downward and forward; it is wider transversely than in the antero-posterior direction, and resembles the shape of a heart on playing cards. The circumference of this opening is formed, in front, by the upper end of the sternum; behind, by the first dorsal vertebra; on the sides, by the first ribs and their cartilages. This opening, which is contracted in its dimensions by the clavicles, gives passage to the following organs: the trachea, the œsophagus, the thoracic duct, the large arteries and veins of the head, neck, and thoracic extremities, the apex of the lungs, and several muscles of the neck.

The *inferior circumference* or *base* is very wide, at least four times larger than the preceding, and, like it, broader transversely than from before backward. It presents, 1. In front, a wide notch, the borders of which are formed by the cartilages of the seventh, eighth, ninth, and tenth ribs, but are incomplete between the tenth and eleventh, as also between the eleventh and twelfth; at the apex of this notch is the ensiform cartilage. 2. Behind, we find on each side of the vertebral column a notch of much smaller dimensions than that in front; it is caused by the great obliquity of the twelfth rib, which forms an acute angle with the spine. The inferior circumference of the thorax is connected with muscles by numerous attachments.

The great mobility enjoyed by the lower aperture of the thorax, which, as we have seen, is subjected to alternate movements of dilatation and contraction, contrasts remarkably with the almost absolute immutability of the superior aperture. The lower opening presents certain varieties in dimension which are observed chiefly during inspiration, or are occasioned by accidental causes of dilatation, such as pregnancy or the accumulation of fluids in the abdominal cavity. This variability of its dimensions has reference to the compressibility and dilatability of the abdominal viscera. Such an alteration at the upper opening would have caused serious inconvenience by compressing the trachea and the vessels.

General Development of the Thorax.

The shape and dimensions of the thorax vary considerably at different periods of life; it is of great importance to be well acquainted with these, because they bear constant relation to changes in the organs contained within the cavity.

One of the most remarkable characteristics of the fœtal thorax is the predominance of the antero-posterior over the transverse diameter; at this age we find the sternum very far separated from the spine, and forming a considerable projection in front. This arrangement coincides with the largely-developed state of the heart, and an organ denominated the thymus gland, which are both situated in the middle of the thorax; and also with the small size of the lungs, which are situated laterally. Another marked feature in the chest of the fœtus is the absence, or, at least, the slight depth, of those grooves which we have described as peculiar to man, and intended to lodge the posterior edge of

the lungs. The absence of these pulmonary grooves produces, as a necessary consequence, a want of those external projections on the back of the thorax, which we find in the adult corresponding with the grooves on the interior. These two characteristics, viz., the predominance of the antero-posterior diameter, and the absence of the grooves, both depend on the same cause, viz., the slight degree of curvature of the ribs in the fœtus.

At a more advanced period the curvatures increase, the posterior grooves are gradually developed, the antero-posterior diameter is diminished, and the transverse proportionally increased, so that there is less difference in the absolute capacity of the thorax than would at first sight appear, for the differences we have noticed are in a great measure referrible to the comparative predominance of one or other diameter. We should also remark, that in the fœtus, the vertical diameter, particularly at the sides, is much shorter, on account of the unexpanded state of the lungs, and the elevation of the diaphragm by the abdominal viscera.

The two circumferences likewise present remarkable differences. In the fœtus, the superior opening has a greater extent from before backward than transversely, which is precisely the opposite of what is observed in the adult. The inferior aperture is extremely wide in every direction; and this accords with the large size of many of the abdominal viscera at this age, and particularly of the liver.

At birth there is a sudden enlargement of the chest, because the access of air increases the lungs to a double or threefold extent, which, up to this period, were much contracted. At puberty, the thorax participates in the great development which the respiratory apparatus undergoes. It is at this time, also, that malformations of this cavity most frequently become obvious. In adult age, the thorax still grows, but in an almost insensible manner.

In the aged, the different pieces of the sternum become united by osseous union: the cartilages are ossified; the thorax has a tendency, in some degree, to form only one piece, which does not permit the different parts to move upon one another.

THE LIMBS.

The vertebral column alone, in many animals, is the organ of locomotion, and the jaws the organ of prehension; but all animals so constituted either live in water or crawl on the earth. The vertebral column, however, in man, and in those animals which live in the air, is not constructed in such a way as to allow of the performance of a complete locomotion, and thence the necessity of limbs, which are only connected to the trunk by their superior extremities, and which, along the rest of their length, are completely isolated from the body. They are also denominated *extremities*, because they are the parts which are most distant from the centre of the body. They are four in number: *two superior*, or *thoracic*, so called because they are directly connected with the thorax; and *two inferior*, or *abdominal*, because they are continuous with the abdominal cavity. These last are intended to support the weight of the body like two pillars, and to transport it from place to place: the thoracic limbs are intended to seize objects or to repel them. The extremities present in their structure certain general circumstances which are essentially characteristic. We shall particularly notice the following:

1. As regards their form. The bones of the extremities differ in many respects both from those of the trunk and those of the head. They generally have the appearance of cylindrical and elongated levers, superimposed so as to form a column, the parts of which are movable upon each other.
2. The continuity of the extremities with the trunk is established by means of osseous zones or girdles, viz., the shoulder for the thoracic limbs, the pelvis for the abdominal.
3. The bones of the extremities diminish in size and length from the proximal to the distal, or free end.
4. The number of the bones in the limbs augments as we proceed towards their free extremity.
5. As a necessary consequence of the augmented number of bones, and of their progressively diminished size, the articulations become more numerous and smaller towards the distal end of the limb.

The thoracic and abdominal extremities being constructed upon the same fundamental type, we should never forget, in describing them, that they have numerous analogies, while, at the same time, we notice the differences in each which are connected with its peculiar office.

THE SUPERIOR OR THORACIC EXTREMITIES.

The Shoulder.—Clavicle.—Scapula.—The Shoulder in general.—Development.—Humerus.—Ulna.—Radius.—The Hand.—The Carpus and Carpal Bones.—The Metacarpus and Metacarpal Bones.—The Fingers.—General Development of the Superior Extremities.

The thoracic extremities are divided into four parts, which, proceeding from the central towards the distal end, are, 1. The shoulder; 2. The arm; 3. The fore-arm; 4. The hand.

The Shoulder.

The *shoulder*, situated at the posterior and lateral part of the chest, is composed of two bones, which form by their union a sort of angular lever with a horizontal and a vertical arm. The horizontal arm is represented by the *clavicle*; the vertical, by the *scapula*.

The Clavicle (*fig.* 41).

The clavicle performs so important an office in the mechanism of the thoracic extremity, that, upon its presence in a certain number of animals, and its absence in others, the extremely important distinction between claviculated and non-claviculated animals has been founded.

Fig. 41.

The *clavicle*, so called from its supposed resemblance to a key, occupies the superior and anterior part of the thorax, and forms the anterior portion of the shoulder. It is placed horizontally between the sternum, which is its fulcrum, and the scapula, the movements of which it follows. Its length varies in different individuals, and more particularly in the different sexes; in the female it is generally longer than in the male. It is a long bone, and forms one of a pair, and is consequently asymmetrical; its inner end (*e*, *fig.* 41), which is the larger, is rounded; its outer end (*d*) is flattened from above downward, and it enlarges progressively from without inward like a cone. Its direction should be carefully studied. Proceeding from its outer end, which is very thin, we find it describing a curve with the concavity forward (*d a*); it then changes its direction, and describes a much larger curve with the concavity looking backward (*a e*). The clavicle, therefore, has two alternate curvatures, resembling an italic *S*, an arrangement which has the advantage of giving strength to the bone, since each curve becomes the seat of a decomposition of forces, which greatly diminishes the violence of shocks directed against it from without inward.

The clavicle may be divided into a *body* and *extremities*.

The *body* (*a*) presents two surfaces, one superior and one inferior; and two borders, an anterior and a posterior.

The *superior surface* (*a*) of the body is placed almost immediately under the skin, and offers an extensive and ill-protected surface to the action of foreign bodies; this is one of the causes of the great frequency of fractures of this bone. This surface is covered by the skin, the platysma myoides muscle, and numerous filaments of the cervical plexus of nerves.* Hence, direct blows upon the clavicle are accompanied with severe pain, on account of the compression of the nerves of this plexus. We find on this surface, near its inner end, a tubercle for the insertion of the sterno-mastoid muscle; it has also some inequalities for muscular attachments on the outside.

The *inferior surface*, broad externally, and narrow internally, like the preceding, is marked by a groove, running longitudinally, and lodges the subclavian muscle. Near the inner extremity of this surface there is sometimes a facette, which articulates with the first rib, and, on its inferior surface, inequalities for the insertion of the *costo-clavicular* ligament. Near the outer end there is a very rough tuberosity, and an irregular line, directed obliquely from within outward and from behind forward: they are both intended for the insertion of strong ligaments which unite the clavicle and the scapula, the *coraco-clavicular* ligaments. The internal third of this surface corresponds to the first rib, which it embraces and crosses at a very acute angle. The middle third corresponds to the first intercostal space, from which it is separated by the brachial plexus and the axillary vessels; the external third is in relation to the coracoid process and the articulation of the shoulder with the arm.

The *anterior border* (*b*), which is thin externally, becomes expanded into a surface towards the inner end; its external third is concave, the two internal thirds are convex. This convexity allows the clavicle to resist, like an arch, any violence applied directly from before backward. The external third of this border, where it gives insertion to the deltoid muscle, is rough, but the two internal thirds are less uneven.

The *posterior border* (*c*) is concave in its four inner fifths, and convex and rough in its external fifth, for the insertion of the Trapezius muscle. Its relations are very important; the subclavian vein runs along it, and it also corresponds to the subclavian artery and the brachial plexus. From this it may be conceived how dangerous fractures of the clavicle might become, if the sharp end of the fragments should penetrate among the nerves or the vessels; it may also be imagined how depression of the clavicle, by compressing the vessels which are distributed to the upper extremity, may suspend the circulation there; and, lastly, we can understand how it is easy to apply a ligature to the subclavian artery, by cutting along the middle of the clavicle. There still remains one important relation to be noticed, viz., the propinquity of the apex of the lungs, from which circumstance it becomes possible to ascertain the sonorousness of this portion of the lungs by percussion on the clavicle.

Extremities.—The *external* or *acromial end* (*d*) of the clavicle is thin, and flattened from

* It is not uncommon to find the body of the clavicle itself traversed by a nerve of the cervical plexus.

above downward; it presents a very narrow elliptical facette, which looks downward and outward, and articulates with a corresponding surface on the scapula. This is the weakest part of the bone; it lies almost immediately below the skin, and is much exposed to external violence, by which it is sometimes broken.

The *internal* or *sternal end* (*e*), on the contrary, is the thickest and strongest part of the bone, and might with propriety be named the head of the clavicle; it articulates with the sternum, projecting beyond the concave articular surface of that bone in all directions, a circumstance which renders displacement much more difficult.

There are many varieties both of size and direction in the body and ends of the clavicle. By inspection of the inner or outer ends of the clavicle, even in the living body, we may judge at once whether the individual has been engaged in a laborious manual employment. I have been able, from the simple circumstance of a marked preponderance of size in the inner end of the left clavicle, to declare *à priori*, and correctly, that the individual on whom I observed it was left-handed. In some clavicles the inner half resembles a quadrangular pyramid. In the female the clavicle is much more slender, and the curvatures are less pronounced, than in the male: the strength and degree of curvature of this bone are proportionate to the laborious and continued exercise of the upper extremity. It may, therefore, be easily conceived how much importance should be attached in forensic medicine to the characters of a bone, the examination of which would of itself be sufficient to determine whether the body to which it belonged were male or female, and whether the person had been engaged in a laborious manual occupation, or the contrary.

Connexions.—The clavicle articulates with three bones, the sternum, the scapula, and often with the first rib.

Internal Structure.—With regard to its structure, the clavicle appears to hold a middle place between the long bones and the ribs; like the first, in fact, it possesses a medullary canal; but it approaches the structure of the ribs in the contracted dimensions of this canal, and the spongy nature of its ends. In examining many clavicles belonging to the collections of the Faculty of Medicine, I was never able to meet with one that had traces of a medullary canal extending throughout its entire length.

Development.—The clavicle makes its appearance at a very early period, about the thirtieth or thirty-fifth day; its dimensions, compared with those of the other bones of the thoracic extremities, present considerable variations at different ages. In the second month of fœtal life, the clavicle has already acquired nearly three lines in length; at this time it is at least four times the length of the humerus and femur. After the commencement of the third month it is not more than half as long again as these bones. At the end of the third month it is still longer than the humerus, which does not exceed it until the fourth month. Lastly, in the fœtus at the full period the humerus does not exceed the clavicle in length by more than a fourth, while in the adult it becomes twice as long.

The clavicle has only one primitive osseous point; from the age of fifteen to twenty-eight years, a complementary or epiphysary point is developed, under the form of a very thin plate, at the anterior part of the sternal end.

The Scapula (*fig.* 42).

The *scapula*, or shoulder blade, forms in man the back part of the shoulder; in a great number of animals it constitutes the entire shoulder. Placed like a sort of shield upon the back part of the thorax, for which it serves as a means of protection against external violence, this bone corresponds with the lateral part of the spine, which it approaches or quits according to the different movements of the upper extremity, to which it affords a movable point of attachment.

Fig. 42.

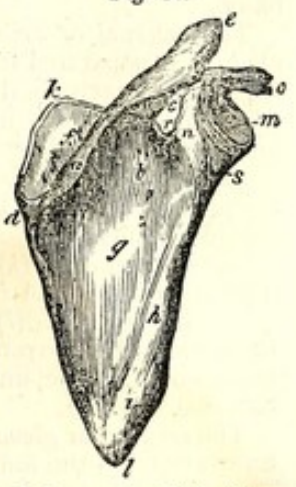

The scapula is proportionally larger in man than in the lower animals. It is an asymmetrical bone, broad, thin, and triangular, presenting two surfaces, three borders, and three angles.

The *anterior* or *costal surface* is moulded, as it were, upon the thorax; it is concave; the concavity being named the *subscapular fossa*, is occupied by the *sub-scapular* muscle. In this we observe ridges directed obliquely from above downward, and from without inward, which receive the insertion of those aponeurotic layers which divide the substance of the muscle.* In a well-formed subject, this surface should be exactly fitted to the surface of the thorax; but when the chest is contracted, as in phthisical patients, the scapula does not participate in an equal degree in this alter-

* The direction of these ridges is not parallel with that of the back part of the ribs, but crosses them at an angle; proving, in opposition to the opinion of some of the older anatomists, that the ridges, and the depressions which separate them, are not the result of pressure exercised by the ribs on the anterior surface of the scapula.

ation, and there is, consequently, a disproportion and change of relative position, to such a degree that the scapulæ form a projection behind, and are in some measure detached from the ribs like wings: hence the expression of *scapulæ alatæ*, applied to the external aspect of the shoulder-blades in phthisical persons.

The *posterior* or *superficial surface* (*fig.* 42) is divided into two distinct parts by a triangular eminence named *the spine of the scapula* (*a*). This spine, situated at the junction of the upper with the three lower fourths of the bone, arises from the posterior surface by a thick edge, which traverses the entire breadth of the scapula; the spine is then directed horizontally backward, outward, and a little upward, and presents for our notice an *upper* and a *lower surface*, which form part of the supra-spinous and the infra-spinous fossæ; an *external border* (*c*), short, concave, thick, and smooth; and a *posterior border* (*a*), very thick and sinuous, which has at its inner end a triangular smooth surface (*d*), over which the trapezius muscle glides. This border is placed almost immediately under the skin, and may be easily traced in the living subject, even in very corpulent individuals. It gives attachment below to the deltoid muscle, and above to the trapezius, which is inserted into nearly the whole of its thickness.

Instead of uniting so as to form an angle, the external and the posterior borders of the spine are continued into a process named *acromion* (*e*), (from ἄκρος, the summit, and ὦμος), because this process forms the highest point of the shoulder. The acromion then forms a continuation of the spine, which appears to be its root. At the place where the spine is continuous with the acromion, there is a contraction, a sort of pedicle, above which the acromion enlarges, and becomes curved into a triangular arch presenting an anterior and a posterior surface, a superior and an inferior edge, a base and a summit. The *posterior surface* of the acromion is convex and rough, and is separated from the skin by fibrous tissue and a synovial bursa. It gives attachment to the trapezius muscle, and to *acromio-clavicular* ligament. The *anterior surface* is concave and smooth, and corresponds to the shoulder-joint. The *upper edge* has a facette, which articulates with a corresponding surface on the clavicle; the *lower edge* is convex and rough; the *summit* forms the highest point of the shoulder; the *base* is continuous with the spine; the narrowness of this base or pedicle of the acromion explains the possibility of fractures at this point.

The whole of the posterior surface of the scapula, above the scapular spine, forms the *supra-spinous* fossa (*f*), which is narrow at it its outer part, and a little enlarged and shallower at the inner, and is filled by the *supra-spinatus muscle*. All that is below the spine forms the *infra-spinous fossa* (*g*), which is occupied by the infra-spinatus muscle. Towards the outer part, this fossa presents a vertical ridge, which marks off a narrow surface, elongated from above downward, and itself divided by an oblique ridge into two smaller surfaces, the superior (*h*) of which gives attachment to the teres minor muscle, and the inferior (*i*) to the teres major.

Of the *three borders* or *costæ* of the scapula, the *internal*, which is also called the *base*, *posterior costa*, *vertebral* or *spinal border* (*k d l*), is the longest of the three in the human subject; in the lower animals it is the shortest. It is thin, slopes from without inward in the upper fourth of its extent, and from within outward in the three inferior fourths, which gives it an angular form. The spine of the scapula meets the base at this angle (*d*).

The *superior* or *cervical border*, or *superior costa* (*k r*), the shortest and thinnest; we observe on it a *notch* (*r*) of variable size, which is converted into a foramen by means of a ligament, and gives passage to the supra-scapular nerve; rarely to the vessels of that name.

The *external* or *axillary border*, or *inferior costa* (*s l*), is the thickest part of the scapula. It is separated from the thorax by an interval, the extent of which determines the depth of the cavity of the axilla. Its thickness increases from the lower to the upper part, where it terminates in the glenoid cavity. There is a depression (*s*) from which the long head of the triceps muscle arises.

Angles.—Two of the three angles of the scapula are intended for the attachment of the principal muscles belonging to this bone; the third enters into the formation of the shoulder-joint.

The *internal angle* (*k*) is that which approaches most to a right angle. In robust subjects it presents a marked impression for the insertion of the levator anguli scapulæ muscle.

The *inferior angle* (*l*) is very acute, and is marked internally by inequalities for the attachment of the serratus magnus. This angle is only covered by the skin and the latissimus dorsi muscle, and is, consequently, more liable than the other two to fracture from external violence.

The *external* or *glenoid angle* (*m*) is the thickest part of the scapula; it is hollowed into an oval cavity, the long diameter of which is vertical, and the small end of the oval uppermost. This cavity, called the *glenoid cavity* (*m*) of the scapula, belongs to the shoulder-joint; it is supported by a contracted portion (*n*) called the *neck* of the scapula, and is surmounted by a strong process (*o*) named *coracoid*, from a fancied resemblance to the bill of a raven. This process is directed outward and forward like a finger in a state of semiflexion; its lower surface, which looks outward, is concave and smooth, and is

curved to correspond with the head of the humerus; its upper surface is convex and rough, and articulates with the clavicle. Its summit is rough, and affords attachment to muscles. The *coraco-acromial* ligament is attached to its posterior border, the *pectoralis minor* muscle and the anterior fibres of the *coraco-clavicular* ligaments to its anterior, while the short head of the biceps and the coraco-brachialis muscles united arise from its summit.

Connexions.—The scapula is articulated with the clavicle and the humerus.

Internal Structure.—There is very little spongy substance in the composition of the scapula, as may be well observed in the supra and infra spinous fossæ, where we can scarcely make use of a file, without breaking through the very thin lamina of compact tissue of which the bone is composed at these points. The spongy tissue occupies the axillary border, the spine, the articular angle, the acromion, and the coracoid process.

Development.—The scapula is developed from six points: one primitive for the body of the bone, and five epiphysary or complementary, viz., one for the coracoid process, two for the acromion, one for the posterior border, and one for the inferior angle.

The osseous point of the body appears towards the end of the second month of utero-gestation, in the infra-spinous fossa, under the form of an irregularly quadrilateral plate of bone, on the surface of which we cannot perceive any vestige of the scapular spine. It is not until the third month that this process becomes apparent; and at that period the ossification has made so little progress towards the upper part of the bone, that the spine, which subsequently is situated below the upper fourth of the scapula, is then sufficiently elevated to project beyond the upper part of that bone. The spine is never developed from a separate point, but sprouts, as it were, from the posterior surface of the bone.

The osseous point of the coracoid process appears sometimes at birth, but generally during the first year.

The osseous germ of the base of the acromion process, which has a rounded form, is developed before the fifteenth year. That of the summit of the acromion does not become visible until from the fifteenth to the sixteenth year; that is the time at which the coracoid process is united to the body of the bone. It is very variable in its shape, being sometimes like a narrow band, sometimes forming, by itself, the greatest part of the process.

The osseous point of the inferior angle of the scapula is developed during the course of the fifteenth year.

The osseous point of the vertebral border extends along the whole posterior costa as a long marginal epiphysis, analogous to that which we shall afterward describe as existing on the haunch bone. It is not formed till the seventeenth or eighteenth year.

The union of these different osseous points does not commence until the fifteenth year, at which time the coracoid process becomes joined to the body of the bone. The other points unite at various periods, which have not yet been determined with much exactness. The osseous point of the vertebral border remains the longest separate of all. The union of all these points is not completed until the time when the growth of the body is terminated.

The Shoulder in general.

Considered as forming only one piece, the shoulder represents a bony girdle intended to serve as a fulcrum to the upper extremities. This girdle is incomplete in front opposite the sternum, and behind in the region of the vertebral column. From this it follows, that the two shoulders are independent in their motions, while the pelvis, which forms an analogous structure for the lower extremities, is a continuous whole, the different parts of which cannot move upon each other. The shoulders are fixed upon the upper part of the thorax, and so greatly increase its apparent dimensions, that the chest, when they are attached, resembles a cone with the base upward, while in its true shape it is a cone with the base below. The shoulder is moulded exactly upon the thorax in front and behind; on the outside it is separated from it by an interval which forms the apex of the axilla.

The circumstance which principally determines the transverse breadth of the shoulders in the female is the length of the clavicle; in the male, it is the breadth of the scapula. The length of the clavicle and the width of the chest in front and at the upper part, in the female, are evidently connected with the large size of the mammæ; and the greater development of the scapulæ in the male evidently corresponds with his greater muscular power.

General Development of the Shoulder.

The development of the shoulder is remarkable for its precocity. For, on the one hand, the considerable length, the well-defined form, and the double curvature of the fœtal clavicle, at a time when all the long bones are still straight, prove the rapidity with which this part of the skeleton is developed. On the other hand, the size of the scapula, which is already considerable, and the very advanced state of ossification of the part that sustains the glenoid cavity, which enables it very soon to afford a sufficient resistance to

the movements of the humerus, equally concur in demonstrating the same fact. This rapid development cannot be attributed to the near vicinity of the heart and great vessels, because the sternum and the cervical vertebræ, which are still more closely approximated to the centre of the circulation, are proportionally much slower in their ossification.

The Arm.

The Humerus (*fig.* 43).

The *humerus*, or bone of the arm, is situated between the shoulder and the forearm, at the side of the thorax. It is the longest and the strongest of all the bones of the upper extremity. It is proportionally shorter in individuals of the Caucasian or white races than in the Ethiopian, which in them, in this respect, presents some analogy to the ape tribes. Its direction is vertical, that is, parallel to the axis of the trunk, but with some degree of obliquity downward and inward. This obliquity is much greater in the femur, the bone of the lower extremity which corresponds with the humerus. The distance between the humeri is much greater in man than in quadrupeds, corresponding with the different shape of the thorax, which, as we have before observed, is flattened from before backward in the human subject, and laterally in quadrupeds. The humerus is not, like the femur, curved as regards its axis, but it presents a very marked *curvature of torsion*, which gives rise to a remarkable groove, that lodges the deep artery and the radial nerve, as they turn round the bone in a part of their course.

Fig. 43.

The humerus is a long, asymmetrical bone, presenting for examination a *body* (*a*) and *two extremities* (*b c*); the upper of these is rounded, and is called the *head* (*b*).

The lower half of the *body of the humerus* is prismatic and triangular; the upper is cylindrical. It has three surfaces, *an external*, *an internal*, and *a posterior*; and three edges, *an external*, *an internal*, and *an anterior*.

The *external surface* (*d e*) presents, 1. A remarkable muscular impression, shaped like the letter V, with the point turned downward; this is the *deltoid impression* (*d*), and is generally situated below the upper third of the bone, but sometimes at the middle; 2. The *groove of torsion* (*f*), directed obliquely downward and forward, the depth of which is always proportional to the prominence of the *deltoid impression*, immediately below which it is placed. Below the groove, the external surface (*e*) looks forward, and is slightly concave, to allow of the origin of the *brachialis internus* muscle.

The *internal surface* (*a*) is an oblique plane, looking forward and inward; the brachial artery runs along it, and therefore it is of importance to be well acquainted with the obliquity of the surface, in order that, when it is necessary to compress the vessel, force may be applied in the proper direction. Its upper part, which looks forward, is broader than the lower, which is turned inward. On this surface we observe, 1. The *bicipital groove* (*g*), which will be particularly noticed afterward; 2. The principal nutritious foramen (*v*) of the humerus, which passes downward into the interior;* 3. An obscurely-marked impression for the coraco-brachialis muscle.

The *posterior surface* is smooth, round, and much broader below than above; it is covered by the triceps.

Of the *three edges*, the *anterior* (*h i*) is a rough ridge, round and blunt below, bifurcated above, so as to form the two borders of the bicipital groove (*g*), which is one of the largest and deepest of all the tendinous grooves in the body, and lodges the tendon of the long head of the biceps. The two borders of this groove, the external (*h*) and the internal (*k*), are very prominent and rough, and afford attachment to powerful muscles; the former to the *pectoralis major*, and the latter to the *latissimus dorsi* and *teres major*. It should be remarked, that the anterior branch of the V represented by the deltoid impression is blended with the anterior edge of the bicipital groove, and greatly increases its prominence.

The other two edges of the humerus, viz., the *external* (*d l*) and the *internal* (*v r*), are blunt, and scarcely distinguishable in their upper two thirds, but sharp and prominent at their lower parts, especially the external edge, which curves forward and gives attachment to a great number of muscles. This edge is also interrupted in its course by the groove of torsion.

The *lower* or *cubital extremity* (*c*) of the humerus is flattened from before backward, with a transverse diameter four times longer than the antero-posterior. It presents a series of eminences and depressions arranged in the same transverse line, viz., counting

* There are some varieties in the situation of the nutritious foramen. I have seen it on the external, or even posterior surface of the bone.

from without inward, 1. An *external tuberosity* (*l*), called *epicondyle* by Chaussier, which forms a continuation of the outer border, and gives insertion to almost all the muscles on the back of the forearm; 2. The *small head* (*m*) of the humerus (*humeral condyle* of Chaussier), a rounded eminence, bent forward and oblong from before backward. The small head articulates with the radius, and is surmounted in front by a superficial depression, intended to receive the rim of the shallow, cup-like cavity on the top of the radius; 3. An articular furrow (*n*), extending obliquely from behind forward, and from without inward, and separating the small head from 4. The *trochlea* (*c*), or *articular pulley of the humerus*, which is also directed from behind forward, and from without inward, is excavated like the groove of a pulley in its long diameter, and the inner border of which descends much lower than the outer. This trochlea articulates with a corresponding surface on the ulna, and is surmounted in front by a small cavity named *coronoid* (*o*), and behind by a much larger depression, the *olecranoid cavity*. These two cavities, the anterior of which receives the coronoid process of the ulna during flexion of the forearm, and the posterior, the olecranon, during its extension, are only separated from each other by a very thin, translucent lamina of bone, which is sometimes perforated, so that they communicate with each other; 5. The *internal tuberosity* or *epitrochlea* (*r*),* which is bent inward, is much more prominent than the external, forming a projection which can be easily felt under the skin, and gives attachment to almost all the muscles situated on the anterior aspect of the forearm.

The *superior* or *scapular extremity* of the humerus, much larger than the inferior, presents, 1. The *head* (*b*), a sphenoidal eminence, forming about one third of a sphere. It articulates with the glenoid cavity of the scapula, and is bounded in the two upper thirds of its circumference by a circular furrow. The constriction resulting from this furrow has been improperly called the *anatomical neck of the humerus* (*s*). The only part which could possibly be considered as the neck, is a portion of the bone which projects on the inner side, and appears to support the head. It is of importance not to confound the circular constriction, which we have mentioned as being called the anatomical neck, with what is denominated the *surgical neck* (at *k*), which is nothing more than that slightly contracted portion of the bone which supports the whole of its upper extremity. The presence of the anatomical neck of the humerus, and the inclination of the articular surface, cause the axis of this surface to form an obtuse angle with the axis of the rest of the bone. 2. Two other eminences, named *greater* (*t*) and *lesser* (*u*) *tuberosities* (*trochiter* and *trochin* of Chaussier), and which might be called the *great* and *small trochanters* of the humerus: they are separated by the bicipital groove. The smaller, which is in front, gives attachment to the sub-scapular muscle; the larger, which is external, presents three surfaces, each of which gives attachment to a muscle, viz., to the *supra spinatus*, *infra spinatus*, and *teres minor*.

Connexions.—The humerus articulates with the scapula, the radius, and the ulna.

Internal Structure.—The two extremities of the humerus are cellular; the middle is compact. It has a very large medullary canal.

Development.—The humerus is developed from seven points; one for the body, two for the upper end, and four for the lower.

The first osseous point appears in the middle of the bone from the thirtieth to the fortieth day, in form of a small solid cylinder, which progressively extends towards both extremities. At birth, and during the course of the first year, the extremities are still cartilaginous. The ossific point of the head of the humerus appears at the commencement of the second year; and that of the great tuberosity from the twenty-fourth to the thirtieth month. It has not, in my opinion, been proved that there is any special point for the lesser tuberosity. The ossification of the lower end of the bone commences after that of the upper. At two years and a half, an osseous point is developed, corresponding to the small head or condyle of the humerus; at seven years, another nodule appears in the epitrochlea; at twelve years, a third point, which forms the inner edge of the trochlea; and, lastly, at sixteen years, a fourth point for the epicondyle.

The two points of ossification of the upper end of the bone unite from the eighth to the ninth year. The four points of the lower end are joined together in the following order: in the twelfth year, the two points of the trochlea; in the sixteenth year, the trochlea, the epicondyle, and the small head. The two extremities are united to the shaft from the eighteenth to the twentieth year. The union of the lower end always precedes that of the upper by one year, although the latter first becomes ossified.

The Forearm.

The Ulna (*fig.* 44).

The *ulna*, or *cubitus*, so called because it forms the elbow, is situated between the humerus and the carpus, on the inner side of the radius, with which it articulates above and below, but from which it is separated in the middle. It is the longer and the larger of the bones of the forearm. When the whole limb is in the vertical position, this

* Epitrochlea, from ἐπὶ, upon, and τροχιλια, a pulley. Epicondyle, from ἐπὶ, upon, and κόνδυλος, an eminence.

Fig. 44.

bone slants a little from above downward and outward. It is a long and asymmetrical bone, much larger above than below, prismatic, triangular, and slightly twisted upon itself: it is divided into a shaft and extremities.

The *body* or *shaft* (*a*) of the bone is larger above than below, is slightly curved forward, and has three surfaces and three edges.

The *anterior surface* (*a*) is broad above, and becomes gradually narrower towards the lower part. On it we observe the nutritious foramen (above *a*), which penetrates from below upward, *i. e.*, in precisely the opposite direction of the nutritious canal in the humerus. This surface is slightly grooved, and gives origin to the *flexor profundus* muscle.

The *posterior surface* (*d*) is slightly convex, and is divided longitudinally by a prominent vertical line into two portions, the inner of which is the broader. A second oblique line placed at the upper part forms a triangular space occupied by the anconeus muscle. The *internal surface* is very broad above, and much smaller at its lower end, which is immediately subcutaneous. It is smooth throughout its whole extent. Of the three edges, the *external* (*e*) is the sharpest, especially in the middle; it commences above, below a small articular surface, the *lesser sigmoid cavity*, and is effaced at the lower part of the bone. It gives attachment to the interosseous ligament, a sort of fibrous membrane stretched between the radius and ulna. The *anterior edge* (*n f m*) is blunt, and is intended for muscular insertions; towards its lower part it bends slightly forward, becomes rough, and terminates in front of a pointed eminence called the *styloid process* (*m*): it commences above by a very marked projection (*n*) on the inside of an eminence named the coronoid process of the ulna. The *posterior edge* commences below the olecranon by a bifurcated extremity; it terminates insensibly towards the lower fourth of the bone; this edge may be felt beneath the skin throughout its whole extent.

The *superior* or *humeral extremity* (*b*) of the ulna presents a considerable enlargement; it is hollowed in front into a hook-like cavity, which articulates with the trochlea of the humerus, to the shape of which it is adapted. This cavity, which forms almost half the circumference of a circle, is called the *great sigmoid cavity* (*b g h*) of the ulna, because it has been compared to the letter sigma of the Greek alphabet. It has a vertical branch, which forms the *olecranon process* (*b*), and a horizontal one named the *coronoid process* (*h*). There is a sort of constriction at the place (*g*) where these two branches meet; this is the weakest point of the upper end of the ulna, and is, consequently, the almost invariable seat of fractures of the olecranon. The *olecranon* (*b*), so named from ὠλένη, the elbow, and κράνον, the head, because it constitutes the most prominent part, or head of the elbow, presents, 1. A posterior surface, smooth above, and rough and irregular below, where it gives insertion to the triceps; 2. An anterior or articular surface, concave, divided by a vertical ridge into two lateral parts of unequal magnitude; this is articulated to the trochlear surface of the humerus; 3. Two borders, more or less rough in different subjects, which afford attachments to the triceps muscle; 4. A base, with the constriction we have before described; 5. The summit, having the form of a curved beak, which is received into the olecranal cavity of the humerus during extension of the forearm.

The horizontal branch of the sigmoid cavity, or the *coronoid process* (*h*), presents, 1. A rough inferior surface (*i*), on which the brachialis anticus muscle is inserted; 2. A superior surface divided into two unequal parts by a ridge, which is a continuation of that which divides the articular surface of the olecranon; 3. An internal rough edge (*n*), bent inward, and giving insertion to the internal lateral ligament of the elbow-joint; 4. An external edge marked by a small cavity, which is oblong from before backward, and slightly concave in the same direction, and is called the *lesser sigmoid cavity* (*k*) of the ulna, to which the head of the radius is articulated; below this small cavity is a rough, triangular, and deeply excavated surface, to which the supinator brevis muscle is attached; 5. An anterior sinuous edge, with a projection or beak, which is received into the coronoid cavity of the humerus during flexion of the forearm.

The *lower extremity* of the ulna presents a small rounded enlargement (*c*), which has been called the *head of the ulna*. We observe on the outside an articular facette (*l*), convex, and elongated from before backward, which is received into a corresponding concave surface on the lower extremity of the radius. On the inner side of this head a vertical cylindrical process arises, called *styloid process of the ulna* (*m*), the point of which gives attachment to the internal lateral ligament of the wrist-joint. The head of the ulna presents below a smooth surface, which articulates with the cuneiform bone, a movable fibro-cartilage being interposed; it is separated from the styloid process behind by a groove for the passage of a tendon, and on the inside by a slight, irregular depression, to which the triangular fibro-cartilage is attached.

Connexions.—The ulna articulates with the humerus, the radius, and the cuneiform bone.

Internal Structure.—The shaft of the ulna is compact; the two extremities are cellular, especially the upper, the olecranon process of which resembles a short bone, both

in form and structure. Sometimes, even, as Rosenmuller has observed, this process constitutes really a short bone, entirely separated from the ulna.

Development.—The ulna is developed from three points; one for the shaft, and one for each extremity. The osseous point of the body appears first from the thirty-fifth to the fortieth day, or a little later than that of the humerus. At birth, the extremities are entirely cartilaginous; they do not begin to ossify until the sixth year, the lower one having the priority. The coronoid process is formed by extension of the ossific point of the shaft. The nodule of the olecranon appears about the seventh or eighth year. The upper extremity is united to the shaft from the fifteenth to the sixteenth year; the lower, from the eighteenth to the twentieth year.

The Radius (*fig.* 45).

The *radius*, so named because it has been compared to the spoke of a wheel, is situated between the humerus and the carpus, on the outside of the ulna, to which it is contiguous above and below, and from which it is separated in the middle by the interosseous space. It is somewhat smaller and shorter than the ulna, and has a vertical direction. It is a long and asymmetrical bone, prismatic and triangular in its shape; its lower end is the larger, and its shaft is slightly curved; it consists of a shaft and extremities.

Fig. 45.

The *shaft* (*o*), smaller above than below, presents a slight curvature with the concavity looking inward: this circumstance increases the distance between the radius and ulna, *i. e.*, the interosseous space. It has three surfaces, an anterior, a posterior, and an external, and three edges. The *anterior surface* (*o*), narrow above and broad below, presents (above *o*) the orifice of the nutritious canal, which, like that of the ulna, runs upward, or in an opposite direction to that of the humerus. It is somewhat grooved, and gives attachment to the *flexor longus pollicis*, and below to the *pronator quadratus* muscles. The *posterior surface*, also slightly hollowed, gives attachment to several of the deep-seated muscles on the back of the forearm. The *external surface*, convex and rounded, is of equal breadth in almost its whole extent, and presents near the middle a rough surface for the insertion of the pronator teres.

Of the three *edges*, one is anterior, the other posterior, and the third internal: the *anterior edge* (*t r s*) is blunt superiorly; it commences below a marked projection, named the bicipital tuberosity, or tubercle of the radius (*t*); from this point it passes obliquely outward, and terminates below, in front of another eminence called the styloid process (*s*) of the radius. The *posterior edge*, less prominent than the anterior, forms a scarcely perceptible demarcation between the two surfaces which it separates; it is pretty well marked in the middle of the bone, but hardly distinguishable above and below. The *internal edge* (*t g*) is sharp, and has the appearance of a ridge; it commences below the bicipital tuberosity, and extends to a small articular cavity (*g*), on the inner side of the lower end of the bone. This edge gives attachment to the interosseous ligament in its whole extent.

The *superior* or *humeral extremity* (*u*), called also the *head of the radius*, expands in form of a shallow but regularly-shaped cup, the cavity corresponding with the small head of the humerus, which it partially receives. It is bounded by a circular border with a vertical articular surface (*v*), varying in breadth in different points, being nearly three lines broad on the inside, where it is in contact with the lesser sigmoid cavity of the ulna. The head of the radius is supported by a constricted portion, or *neck* (*w*), of a cylindrical form, and five or six lines in length, which is obliquely directed from above downward, and from without inward. At the junction of the neck and body of the radius, on the inside, we see a very marked process, called *bicipital tuberosity* (*t*). Its posterior half is rough, where it gives attachment to the tendon of the biceps; the anterior is smooth, and the tendon of the biceps glides over it before reaching its point of insertion.

The *inferior* or *carpal extremity* (*x*), which is the largest part of the radius, is irregularly quadrilateral. Its lower surface is articular, smooth, concave, irregularly triangular, and divided by a small antero-posterior ridge into two parts: an internal, which articulates with the semilunar bone of the wrist, and an external, which articulates with the scaphoid. In the outside of this surface we observe a pyramidal, triangular process, slightly bent outward; this is the *styloid process* (*s*) of the radius, shorter and much thicker than the styloid process of the ulna, and, like it, giving attachment to one of the lateral ligaments of the wrist-joint. The circumference of this end of the bone exhibits *in front* some inequalities, to which the anterior ligament of the wrist is attached; *behind* and on the *outside*, it is marked by the following tendinous grooves, viz., proceeding from without inward, 1. An oblique groove on the external surface of the styloid process, which shows the trace of a longitudinal division marking out two secondary furrows. 2. A groove bounded by projecting edges, and subdivided into two secondary ones by a longitudinal ridge, less elevated than the lateral border. 3. A somewhat deep-

er groove, also divided into two secondary furrows of unequal dimensions by a very prominent line.*

On the *inside* (*g*), the lower end of the radius is slightly excavated, to articulate with the carpal extremity of the ulna.

Connexions.—The radius articulates with the humerus, the ulna, the scaphoid, and semilunar bones.

Internal Structure.—The two extremities of the radius are cellular, and are covered by a very brittle layer of compact tissue: this is more remarkably the case at the lower part of the bone, where fractures most usually occur. The shaft is almost entirely formed of compact tissue, and has a very narrow medullary canal.

Development.—The radius is developed from three points, one for the body, and one for each extremity. The osseous point of the body appears some days before that of the ulna: the lower extremity is developed about the second year; the upper, at nine years. The upper extremity, which is last in beginning to ossify, becomes united to the body of the bone about the twelfth year, while the lower extremity is not joined until from the eighteenth to the twentieth year.

The Hand (*fig.* 46).

The *hand* is the last part of the upper extremity. Accustomed as we are to admire the beautiful and perfect organization of the different parts of the animal body, we are impressed with the most profound admiration when examining the mechanism of the hand. The organ of touch and prehension, performing functions the most opposite; those demanding great force, and those requiring the greatest delicacy. To enable it to fulfil at the same time functions so different, great solidity and great mobility were essential; and to secure these conditions, it was necessary that it should be formed of a great number of bones. It is composed of twenty-seven bones, exclusive of the sesamoid bones. The hand exists only in man and in the ape; and its importance is so great, that it has been considered by naturalists as establishing a fundamental character of the species. Man alone constitutes the class of bimana; the apes form the class quadrumana: but in the hand of the ape, compared with that of man, we find great inferiority. Let us, then, study with the attention it merits this *chef-d'œuvre* of mechanism, which some of the philosophers of antiquity regarded as the distinctive character of man, and even as the source of his intellectual superiority.

Fig. 46.

The hand, considered as part of the skeleton, is composed of five series of small columns. Each series consists of four pieces, excepting the outer one, which has three only. The five series of columns converge so as to unite with a bony mass, composed of eight bones (*a* to *i*) articulated together, and forming by their junction the base of the hand or the wrist. This bony mass is called the *carpus*. The five columns (*k k*), next the carpus, have received the name of *metacarpal bones;* by their union they form the *metacarpus*, which corresponds with the palm of the hand: lastly, the columns which succeed to the metacarpus form appendages which are entirely isolated and independent of each other; these are the *fingers*, which are distinguished by numerical names of first, second, third, fourth, and fifth, counting from without inward, the hand being supine, and the palm turned forward; they are also known by the following appellations: *thumb*, *index* or *indicator*, *middle*, *ring*, and *auricular* or *little finger*. Each finger is composed of three small bones, called *phalanges* (*l m n*), distinguished also successively, from above downward, by the numerical names of first, second, and third. The third bears also the name of *ungual*, because it supports the nail; the thumb has only two phalanges (*l n*); it is also distinguished from the other fingers, by being on a plane anterior to them.

The form of the hand leads us to consider separately a dorsal, convex surface, the *back* of the hand; an anterior or palmar surface, the *palm* (*fig.* 46); an external or *radial* edge (*a n*), formed by the thumb; an internal or *ulnar* edge (*c n*), formed by the little finger; a superior, carpal, or *anti-brachial* extremity; and an inferior or *digital* extremity, composed by the ends of the fingers, which, from their unequal length, form a curve with the convexity downward.

The natural attitude of the hand is that of pronation, *i. e.*, the attitude in which it is placed when the bones of the forearm, instead of being parallel as in supination, are crossed in such a manner that the lower part of the radius is in front of the ulna. The

* In the description of the muscles, we shall point out the tendon which occupies each of these primitive and secondary grooves. All enumerations of this kind, the advantages of which we do not dispute, when the bones and muscles are already known, will find a place in the table at the end of the part devoted to myology. We have noticed here the muscular insertions, because, instead of burdening the memory, they are useful in fixing the attention upon the objects described.

hand is in this position when laying hold of anything, or exercising the sense of touch. It is only for the convenience of description that we shall suppose the hand to be in the state of supination, and the palm turned forward. We shall be obliged to return to pronation, when we draw a parallel between the hand and the foot.

The axis of the hand is almost the same as that of the forearm.

The Carpus (*a* to *f*, *fig.* 46.)

The *carpus* (from καρπὸς, wrist, κάρπειν, to lay hold of) constitutes the bony structure of the wrist; it is of an oblong form, and almost elliptical transversely. The *anterior surface* (*fig.* 46) is concave, and forms a deep groove, in which the tendons of the flexor muscles are lodged. The *posterior surface* is convex, and in contact with the extensor tendons. They are both traversed by waved lines, which indicate the numerous articulations of the component bones. The *upper border* is convex, and articulates with the radius and ulna; the *lower* is irregular and sinuous, and articulates with the metacarpal bones.

At each of the two extremities of the ellipse represented by the carpus, we observe two eminences, which form a projection on the anterior aspect, and contribute to augment the depth of the groove which it forms. The two which occupy the outer edge of the wrist are much smaller than those which are situated on its inner border.

The structure of the carpus is remarkable in this respect; that in proportion to its size, it presents in a given space a much greater number of bones than any other part of the skeleton. It consists, in fact, of eight bones, and is scarcely one inch in height, and two inches and a half in breadth. These eight bones are arranged in two series, or rows; an *upper proximal* or *anti-brachial* (*a b c d*), and a *lower distal* or *metacarpal* (*e i g f*). Each of these ranges is composed of four bones; counting from the external or radial edge towards the internal or ulnar, they are, in the first row, the *scaphoid* (*a*), the *semilunar* (*b*), the *cuneiform* (*c*), (or *pyramidal*), and the *pisiform* (*d*); in the second row, *trapezium* (*e*), the *trapezoid* (*i*), the *os magnum* (*g*), and the *unciforme* (*f*).

I shall not occupy time in describing successively the six surfaces on each of these bones. By simply explaining the law which regulates their configuration, I shall have the double advantage of avoiding prolixity, and of enabling the student to understand more correctly both their forms and relations.

Bones of the first or Anti-brachial Range.

What I have just said of these bones does not apply to the pisiform, which is distinguished from all the others by particular characters, and merits a special notice. With regard to the rest,* viz., the *scaphoid* (*a*), the *semilunar* (*b*), and the *cuneiform* (*c*), it may be remarked, 1. That they articulate by their upper surfaces with the forearm, forming a sort of interrupted condyle, *i. e.*, one consisting of several pieces, which is received into the cavity formed by the lower end of the radius and ulna. Each of the bones contributes to form this condyle, by means of a convex surface; consequently, the *superior surface of the bones of the first rank is articular and convex.* 2. They articulate by their *lower surfaces* with the bones of the second rank, which on the inside oppose to them a large head formed by the os magnum and unciform, and on the outside a shallow concavity, which corresponds to the trapezium and the trapezoid. In accordance with this, the lower surface of the first row presents on the one hand a concavity, which receives the head, and on the other a convexity, which corresponds to the cavity.

Three surfaces, belonging to the scaphoid, the semilunar, and the cuneiform, unite to form the cavity, which receives the head belonging to the second row. There is, therefore, a broken cavity, *i. e.*, one formed of several pieces. The scaphoid being the largest of the bones of the first row, and corresponding by itself to the most convex part of the head of the second row, is more deeply excavated than the two other bones; this has given it the form of a boat, whence the name of scaphoid (σκαφὴ, a boat). The semilunar, which corresponds to the summit of the head, presents from before backward a concavity, which has given it its name; the cuneiform, on the contrary, corresponds to the least convex part of the articular head, and has an almost plane surface.

One bone only, the scaphoid, answers to the concavity formed by the trapezium and trapezoides, and it accordingly presents a convex surface at the point of union. Therefore the *lower surfaces of the bones of the first row are concave, and the lower surface of the scaphoid is partly concave and partly convex.*

3. The bones of the first row of the carpus unite with each other by plane surfaces; those of the scaphoid and semilunar, which join, are very small; the contiguous surfaces of the semilunar and the cuneiform are much larger.

The semilunar and the cuneiform, which occupy the middle of the row, articulate not only with each other, but also with the scaphoid and the pisiform; and each, therefore, has two lateral surfaces, so that the two middle bones of the row have four articular facettes.

* It is necessary, in order to follow this description, and obtain from it all the advantage which it can afford, to study at the same time an articulated carpus, especially one in which the joints are exposed behind, some ligaments remaining in front.

The scaphoid, which is the outer bone of the first row, articulates internally with the semilunar, but externally it has a projecting process, which may be easily felt under the skin, and which increases the depth of the anterior groove of the carpus. This eminence constitutes the *external superior process* of the carpus. 4. The bones of the first row forming part of the concavity in front, and of the convexity behind, have their anterior surfaces much smaller than their posterior; both are rough, and serve for the insertion of ligaments.

The pisiform (*d*) is not in the same rank, and has only one articular surface, which unites with the corresponding surface on the cuneiform. The whole of the rest of its surface is intended for the insertion of ligaments and tendons. Its name is derived from its irregularly rounded form. It is placed on a plane anterior to that of the other bones of the first row, and forms the *internal superior process*, which is the most prominent and the most superficial of all the processes of the carpus. The pisiform receives above the insertion of the *flexor carpi ulnaris*, and below allows of the origin of the *abductor minimi digiti*. It might with propriety be considered as a sesamoid bone.

Bones of the Second or Metacarpal Row.

The bones of the second row are much larger than those of the first; they form, in fact, the support of the metacarpus. In the first row, the outer bone, namely, the scaphoid, is the larger; in the second, the two inner bones, viz., the os magnum (*g*) and unciform (*f*).

Superior Surfaces.—We have already stated, that the surface of the second row, which articulates with the first, presents a head and a cavity. The head is formed almost entirely by a spheroidal eminence, named *head of the os magnum;* this is supported by a constricted portion, or *neck*, below which is the *body*, the largest part of the bone; this head of the os magnum is truncated at its inner part, and appears to be completed by a portion of the os unciforme. The concavity presented by the bones of the second row is constituted by two bones, the trapezium (*e*), situated on the outside of the carpus, and the trapezoid (*i*), placed between the trapezium and os magnum.

The *inferior surfaces* correspond to the bones of the metacarpus. Taken together, these surfaces form a sinuous and angular line, which by itself would seem to prove the impossibility of dislocation of the metacarpus. The *trapezium* supports the first metacarpal bone; the *trapezoid* the second; the os magnum the third; and the *os unciforme* the fourth and fifth metacarpal bones.

The *posterior surfaces* of the bones of the second row form part of the convexity of the carpus; the *anterior surfaces* are narrower, and correspond with its concavity. There is a process on the anterior aspect at each extremity of the second row; the *internal* belongs to the unciform bone, and resembles a hook, the concavity of which looks outward, and corresponds with the flexor tendons; the *external* belongs to the trapezium, and forms a much less prominent hook than that of the unciform; on its inside there is a deep oblique groove for the passage of the tendon of the flexor carpi radialis, and it forms the external inferior process of the carpus.

Lateral Surfaces.—The bones of the second row are joined together by broad plane surfaces, partly articular and partly non-articular. The two middle bones, viz., the trapezoid and the os magnum, have each two lateral articular surfaces, inasmuch as they are articulated with each other, and since the os magnum is united to the unciform, and the trapezoid to the trapezium. The extreme bones of this row have only one side articular. Each of the middle bones, therefore, has four articular surfaces, a superior, an inferior, and two lateral; each of the extreme bones a superior, an inferior, and one lateral.

Development of the Carpal Bones.

All the bones of the carpus, without exception, are developed from single points. The ossific points appear very slowly; all the bones are cartilaginous at birth. Towards the end of the first year, the cartilages of the os magnum and the unciform show a bony point in the centre. The osseous point of the cuneiform appears from the third to the fourth year; those of the trapezium and semilunar, from the fourth to the fifth; and those of the scaphoid and the trapezoid, from the eighth to the ninth year. The pisiform does not become ossified until from the twelfth to the fifteenth year; in fact, it is the latest to ossify of all the bones of the skeleton.

The Metacarpus (k k`, fig. 46).

The five bony columns which rest upon the carpus form the *metacarpus;* they are long bones placed parallel to each other, and constructed on the same model, with very slight differences. Together they form a sort of square grating, the intervals of which are larger, on account of the disproportion existing between the size of the middle part and the ends of these bones. These intervals are denominated *interosseous spaces*, and are occupied by muscles.

The metacarpal bones are five in number, distinguished by the names of first, second, &c. They are not perfectly uniform, either in situation, length, or shape. The meta-

carpal bone of the thumb, for instance, is situated upon a plane anterior to that which the others occupy; instead of being parallel, it is directed obliquely outward and downward, and hence the interosseous space between it and the second metacarpal bone is triangular.

This arrangement is connected with the movement of opposition, which is the characteristic feature of the hand. The metacarpus presents a *palmar* or *anterior surface*, concave transversely, and slightly so from above downward, which corresponds with the *palm of the hand*; a *dorsal* convex surface, the *back of the hand*; an *external* or *radial edge*, which is short, obliquely directed outward and downward, and corresponds to the thumb; an *ulnar* edge, short and straight, which corresponds with the little finger; a *superior* or *carpal extremity*, which presents a very sinuous articular line, to fit the opposite surface of the carpus; and an *inferior* or *digital extremity*, formed by five heads, or, rather, condyles, flattened on the sides, and intended to articulate with the corresponding fingers: this lower extremity forms a broken articular line; it is curved, with the convexity downward, and the first metacarpal bone does not appear to belong to it.

General Characters of the Metacarpal Bones.

The metacarpal bones belong to the class of long bones, having the same form and structure; each consists of a *body* and *two extremities*.

The *body* is prismatic and triangular, and slightly curved, so as to present a concavity on the palmar, and a convexity on the dorsal aspect. Of the *three surfaces* of the body, two are lateral, and correspond to the interosseous spaces; the third is on the back of the hand, and is covered by the tendons of the extensor muscles. Of the *edges*, two are lateral; the third is anterior, and corresponds with the palm of the hand.

The *upper* or *carpal extremity* is large, and has five surfaces, an anterior and a posterior, for ligamentous insertions, and three articular; of the three articular surfaces, one is at the end of the bone, and unites with a corresponding surface on a carpal bone; the two others occupy the sides of the extremity, and unite with corresponding surfaces of the adjoining metacarpal bones. In some metacarpal bones, the lateral facettes are double on each side. It is necessary to distinguish such of these lateral facettes as are intended to unite with bones of the carpus, between which one of the metacarpal bones is, as it were, wedged, from those which are exclusively intended for the articulation of the metacarpal bones with each other.

The *lower* or *digital extremity* resembles a head flattened on the sides, or a *condyle* oblong from before backward, with an articular surface of greater extent on the palmar than on the dorsal aspect, *i. e.*, admitting of greater flexion than extension; it is marked both internally and externally by a depression, behind which is a rough projection for the attachment of lateral ligaments.

Are there any peculiar characters by which the different metacarpal bones may be distinguished? This question we shall now examine.

Differential Characters of the Metacarpal Bones.

The *first* metacarpal bone (*k'*) is distinguished from the others by the following characters: it is the shortest and the largest; its body is flattened in front and behind like the phalanges; so that at times it has been looked upon as one of those bones. We shall regard it as belonging to the metacarpus, because it is not only united to the other metacarpal bones by the interosseous muscles, but its inferior or digital extremity also has an exact resemblance. At the same time, we must acknowledge that there is a circumstance in its development which tends to establish its analogy with the phalanges. The *carpal extremity* of the first metacarpal bone has a particular form; it is concave from before backward, and convex transversely, for articulation with the corresponding surface on the trapezium. The characteristic marks, then, by which the first metacarpal bone may be recognised, are, *its shortness, its greater size, the antero-posterior flattening of the body, the upper articular surface concave and convex in opposite directions, and the absence of lateral articular facettes.*

There are many distinguishing characters of the *second*, *third*, and *fourth* metacarpal bones. I shall content myself with saying, that the second and third are known by their greater length, for they exceed the fourth by the whole of their lower extremity; they are also about a third larger, and heavier.

The third metacarpal bone is distinguished from the second by its greater size, and, accordingly, it gives attachment to one of the most powerful muscles of the hand, the *adductor pollicis*; it is also known by having two lateral facettes on its upper extremity, while the second has only one.

The *fifth* metacarpal bone (*k*) is the shortest of all, excepting the first, from which it is distinguished by its smaller size. It differs from the fourth, which it most resembles, 1. By its shortness. 2. By the presence of an articular facette only on one side of its carpal extremity. 3. By the existence of a very projecting eminence on its inner side, for the insertion of the *extensor carpi ulnaris* muscle.

Connexions.—The metacarpal bones articulate with each other, with the bones of the carpus, and with the first phalanges of the corresponding fingers.

Internal Structure.—They have the same structure as other long bones: their extremities are cellular, and the shafts compact, with a small medullary canal.

Development.—Each metacarpal bone is developed from two points; one for the body and superior extremity, and one for the lower or distal extremity. The first metacarpal bone, which in many respects resembles the phalanges, is similar also in its mode of development. One of its two points appears in the shaft; the other in the upper or carpal extremity, which is the reverse of what takes place in the other bones of the same denomination, and is analogous to that of the phalanges. The ossific point of the body of the metacarpal bone appears from the fortieth to the fiftieth day of fœtal life. At birth the body is almost completely ossified, but the extremities are still cartilaginous. The bony points of the lower ends of the last four metacarpal bones, and of the upper end of the first, do not make their appearance until the third or fourth year. In general, the upper ends of the last four bones, and the lower end of the first, are ossified by an extension of the shaft; but I have occasionally seen separate germs for each of these, so that every metacarpal bone had three osseous nodules. The union of the lower extremities with the bodies of the four metacarpal bones does not take place until the eighteenth or twentieth year; and the same is the case with the ossific point of the upper end of the first metacarpal bone. In those cases where the lower end of the first metacarpal, and the upper ends of the others, are formed from special points, their union takes place at a much earlier period.

The Fingers (l m n, and l′ n′, fig. 46).

The fingers are the essential organs of prehension, and for this purpose have a length, thickness, and mobility that are very remarkable, when we compare them with the toes, which represent them in the lower extremity. Each finger forms a pyramid, composed of three columns placed upon each other; the base of the pyramid corresponds to the metacarpus, and there are two enlargements or knots at the places where the columns (named *phalanges*) unite together. The three columns which compose each finger successively decrease in size, and are known by the numerical appellations of *first*, *second*, and *third*. The first, which articulates with the metacarpus, is also called the *metacarpal phalanx* (*l l′*); the second, the *middle phalanx* (*m*); and the third, which supports the nail, the *ungual phalanx* (*n n′*). The thumb alone has only two phalanges, an ungual and a metacarpal. Chaussier has named the phalanges *phalange*, *phalangine*, and *phalangette*, counting from the base to the ends of the fingers. These denominations he has found very serviceable in the methodical designation of the muscles of the fingers.

The First Phalanx (l l′).

The first phalanx belongs to the class of long bones, and presents to our notice, 1. A body resembling a half cylinder, cut along its axis, and slightly curved upon itself, so as to present a concavity in front; the dorsal surface is cylindrical, and covered by the tendons of the extensor muscles; the anterior surface is slightly channelled for the partial lodgment of the tendons of the flexor muscles; its edges are sharp, and give attachment to a tendinous sheath, which converts the channel above mentioned into an osteo-fibrous canal for the flexor tendons of the fingers. 2. An *upper* or *metacarpal end*, transversely oblong, and presenting a small glenoid cavity for the head of the corresponding metacarpal bone. 3. A *lower end*, forming an articular pulley.

Such are the general characters of the first phalanx, but they are modified in each finger. Thus, the phalanx of the middle finger is the longest; those of the index and ring finger come next. The first phalanx of the thumb is the largest in proportion to its length; the first phalanx of the little finger is the most slender; it is also the shortest, excepting that of the thumb.

The Second Phalanx (m).

The second phalanx differs from the first by its smaller size and the shape of its upper end, which forms two concave articular facettes, separated from each other by a projecting line, which runs from before backward; these are fitted to the trochlea on the lower end of the first phalanx. The edges of this phalanx are thick and rough above, where they give insertion to the tendon of the superficial flexor of the fingers.

The thumb has no second phalanx.

The Third Phalanx (n n′).

This bone, to which so much importance has been attached in natural history,* supports the horny part with which the ends of the digits in animals are armed, and the nails in man. It is shaped thus: the upper end is transversely oblong, exactly resem-

* See the interesting memoir of M. Duméril, entitled *Dissertation sur la dernière Phalange dans les Mammifères*; the ungual phalanx presenting different forms, suited to the different instincts of the animal. This is so remarkable, that, from its examination, the family to which the animal belonged may be ascertained.

bling the upper end of the second phalanx; from this part it contracts like a cone; afterward it becomes much enlarged and flattened from before backward, and ends with the shape of a horse-shoe, rough in front, where it supports the pulp of the finger, smooth behind, and indented on the edges. The ungual phalanx of the thumb is much larger than that of the other fingers; that of the middle one is the next in size; those of the index and ring finger are almost equal, and that of the little finger is the smallest. It is very difficult to distinguish the phalanges of the right from those of the left hand.

Development of the Phalanges.

The phalanges are developed from two points: one for the body and lower end, and one for the upper end. This mode of development is common to the first, second, and third phalanges. The osseous point of the body appears successively in the first, second, and third phalanges, from the fortieth to the fiftieth day. The order of succession is not subjected to any certain rules. Bony points are found at the same time in the ungual and metacarpal phalanges, and prior to those of the middle phalanges. The ossific points of the upper ends of the phalanges appear successively in the first, second, and third phalanges some time after birth, from the third to the seventh year. The epiphysary point of the third phalanx is generally developed before that of the second. The epiphyses do not join the bodies of the bones until from the eighteenth to the twentieth year.

General Development of the Superior Extremity.

The thoracic limb in the fœtus and the infant is remarkable for its dimensions, which are proportionally much greater than in the adult. This early development and size are particularly evident when compared with the slow development of the lower limb; the resulting disproportion is in an inverse ratio of the age, that is, it is greatest in early life. The thoracic limb of the fœtus differs from that of the adult in many other respects besides dimensions. Thus, the two extremities of the humerus are proportionally much larger, and altogether cartilaginous, though the difference does not appear to me so great as has been imagined. The lower end of the bone is especially remarkable for the size of the small head, which forms a very marked protuberance in front, and projects considerably beyond the pulley or trochlea. In the forearm, the upper end of the radius is situated much farther forward than in the adult, which agrees with the position of the small head of the humerus. This circumstance merits careful notice, because it is one of the predisposing causes of dislocation of the head of the radius forward, the ligament which keeps it back being scarcely able to overcome its tendency in that direction. For the same reason, displacements of the head of the radius are much more frequent in the infant than in the adult.

The carpus, almost completely unossified at birth, is composed of the same number of cartilages as there are bones afterward. The metacarpus, on the contrary, is ossified long before birth, but this rapid development, common to the whole thoracic extremity, is most remarkable in the phalanges.

Bichat appears to me to have greatly exaggerated the changes which take place in these bones during the progress of age. I am certain that the torsion of the humerus, and the curvatures of the radius and ulna, and also the interosseous space, exist equally in the new-born infant as in the adult, and in almost the same proportions.

THE INFERIOR OR ABDOMINAL EXTREMITIES.

The Haunch.—Os Coxæ.—The Pelvis.—Development.—Femur.—Patella.—Tibia.—Fibula.—The Foot.—The Tarsus and Tarsal Bones.—The Metatarsus and Metatarsal Bones.—The Toes.—Development of the Lower Extremities.—Comparison of the Upper and Lower Extremities.—Os Hyoides.

The inferior or abdominal extremity is divided, like the superior, into four parts, viz., the *haunch*, the *thigh*, the *leg*, and the *foot*.

Of the Pelvis.

We have seen bony arches growing out from the sides of the dorsal portion of the vertebral column, to form the thorax. In the same way there grows out from the sacral portion of the column two large bones, which form the walls of the pelvic cavity. These are the *ossa innominata* or *haunch* bones. The pelvis forms an appendix to the abdominal cavity, and lodges and protects a number of important organs, viz., a portion of the organs of digestion and of the urinary apparatus, and the whole of the internal organs of generation, together with important vessels and nerves. The pelvis transmits to the inferior extremities the weight it receives from the vertebral column. It is formed by four bones, two of which placed behind on the median line, the sacrum and the coccyx, we have already described; the two placed on the sides, and extending forward to be united on the median line before, the *ossa innominata*, we shall now examine.

The Os Coxæ, or Os Innominatum (*figs.* 47 and 48).

The *haunch bone*, called also *os coxæ*, from *coxa*, the haunch, occupies the lateral and anterior parts of the pelvis. It is the largest of all the broad bones of the skeleton. It is asymmetrical, very irregular in its figure, and twisted upon itself, so that it appears to be composed of two portions; one superior, triangular, shaped like a wing, and flattened from without inward; the other inferior, and flattened from before backward. These two parts are united by a contracted portion. On this bone we have for consideration an *external* or *femoral surface*, which corresponds with the thigh, an *internal* or *pelvic surface*, and a *circumference*.

On the *femoral surface* (*fig.* 47) we observe the following parts: On the contracted portion, which unites the upper and the lower half of the os coxæ, is the *cotyloid cavity* (*a*, *figs.* 47, 48) (from κοτύλη, a cup), or *acetabulum*, which receives the head of the femur. This is of a hemispherical shape, and is the deepest of all the articular cavities; it looks obliquely downward, outward, and a little forward, and has a considerable depression (*b*, *fig.* 47) at the bottom, on its inner aspect. The margin (*c*) of this cavity is sharp and sinuous, and presents three notches, or, rather, one notch and two slight depressions, one of which is superior, and the other inferior, and somewhat external. The notch (*d*) is situated below and on the inside; it is very deep, and converted into a foramen by a ligament, and gives passage to the vessels which penetrate into the cotyloid cavity. Above and below the acetabulum are two horizontal grooves; the upper one is superficial, and gives attachment to a fibrous expansion, one of the origins of the *rectus femoris*; the lower is deeper, and gives passage to the tendon of the *obturator externus*. Above the cotyloid cavity, the os coxæ presents a broad triangular surface, improperly called *external iliac fossa* (*e*). On it we observe, proceeding from behind forward, 1. A convexity: 2. A concavity, occupying about two thirds of the fossa, and on which the principal nutritious foramina are situated: 3. A second convexity: 4. A slight concavity.

Fig. 47.

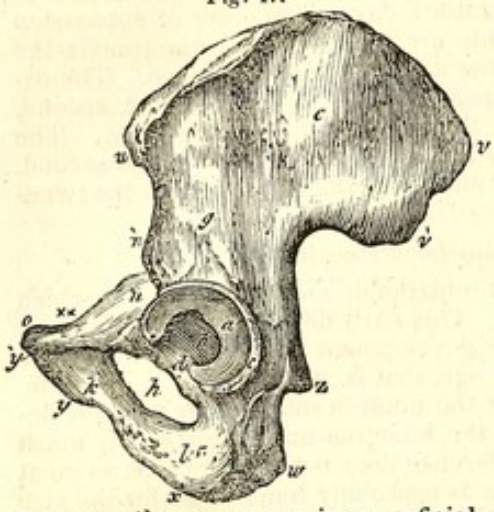

The external iliac fossa is traversed by two curved lines for muscular insertions; one posterior, called the *superior semicircular line* (*f*); the other anterior, and much more extensive, the *inferior semicircular line* (*g*). All the whole surface behind the former gives attachment to the *gluteus maximus*: the portion comprised between the two lines gives attachment to the gluteus medius.

Below the acetabulum we observe proceeding from without inward, 1. The *obturator foramen* (*h*, *figs.* 47 and 48), improperly so called; it is placed more internally than the acetabulum, and has an oval form in the male (hence its name, *foramen ovale*): in the female it is smaller, and triangular. Its longest diameter is vertical, and it slopes a little downward and outward. At its upper part is the *obturator groove* (*i*, *fig.* 48), directed obliquely from behind forward and inward. It gives passage to vessels and nerves, and has two *lips*: an *anterior*, which is continuous with the outer half of the circumference of the foramen; and a *posterior*, which is continuous with the internal half; for the two halves of the circumference of the obturator foramen, instead of being united in front, pass in different directions, the internal backward, and the external forward, leaving between them an interval which constitutes the groove. 2. On the inside of the obturator foramen is a square surface (*k*, *figs.* 47 and 48), broader above than below, oblong in a vertical direction, and rough for the insertion of several muscles of the thigh. This is continuous below with another surface (*l*, *fig.* 47), broader inferiorly than above, which extends obliquely downward and outward, then curves upward, and terminates below the cotyloid cavity. This surface, which bounds the obturator foramen below, is intended for muscular insertions.

The *internal* or *pelvic surface* (*fig.* 48) of the os coxæ is concave. It is divided into two parts: a superior, which looks upward, and an inferior, which looks backward, by a prominent horizontal ridge (*m n o*, *fig.* 48), which forms the lower boundary of the internal iliac fossa. Above this ridge, which we shall afterward see forms the greatest part of the inlet of the pelvis, we find, proceeding from behind forward, 1. A very prominent and rough *tuberosity* (*r*), intended for several ligamentous attachments. 2. An irregular articular surface, broader above than below, and called the *auricular surface* (*s*) of the os coxæ, from a supposed resemblance to the concha of the ear; it looks downward and inward, and articulates with a corresponding surface on the sacrum. 3. More anteriorly, and on a higher plane, a deep and regular excavation, correctly denominated the *internal iliac fossa* (*t*). This fossa, which is broad and smooth, is occupied by the

iliacus muscle. At its lower part there is a nutritious foramen, which does not correspond with that on the outside of the bone.

Below the horizontal ridge, which divides the internal surface of the os coxæ into two halves, we observe, proceeding from without inward, and from behind forward, 1. A smooth quadrilateral surface, broader above than below, slightly concave, and sloping from above downward, inward, and forward: the front of this surface corresponds to the depression at the bottom of the cotyloid cavity. 2. Behind this surface, a large notch, which will be noticed when describing the circumference of the bone. 3. In front, the inner opening of the obturator foramen, at the upper part of which is the commencement of the groove already described. 4. Inside the foramen, a quadrilateral surface, narrower below than above, where it forms a plane, sloping downward and backward, which corresponds to the bladder. 5. Below the same foramen, a smooth surface.

The *circumference* of the os coxæ is very irregular, and consists of a series of alternate projections and notches. We shall describe four borders in this circumference; a superior, an inferior, an anterior, and a posterior.

The *superior border* or *crest of the ilium* (*u v*, *figs.* 47 and 48) is curved like the italic letter *S*; it is directed from before backward, is rough, thick, and convex; we shall describe it as having two lips and an interstice, that we may be able to point out with precision the numerous muscular insertions of which it is the seat. It is not equally thick in its whole extent; the anterior extremity is thick, it is then contracted a little; about two inches behind this extremity it is considerably enlarged; and still more posteriorly there is a second enlargement even greater than the former. The *inferior border* (*w x y*, *fig.* 47), which looks inward, is the shortest; it commences at the most sloping part of the os coxæ by a large rough tuberosity, called *tuberosity of the ischium* (*w x*), which gives attachment to almost all the muscles on the back of the thigh; the weight of the body rests upon it in the sitting posture. Proceeding from this tuberosity towards the inner part of the os coxæ (*x y*), the lower border becomes flexuous, irregular, and slightly twisted upon itself; it passes obliquely inward and upward, and contributes to form the *pubic arch* (*x y x*, *fig.* 48). Above this oblique portion the border presents a vertical elliptic surface, which unites with the corresponding surface on the opposite bone, and forms the *symphysis pubis* (*y y'*, *figs.* 47, 48). The lower border of the os coxæ consists, therefore, of two portions; an oblique, which forms part of the arch, and a vertical, which forms part of the symphysis.

The *anterior border* (*u y'*, *figs.* 47, 48) commences at the anterior extremity of the crest of the ilium by an eminence for muscular insertion, which can be always easily felt under the skin; it is the *anterior superior spinous process of the ilium* (*u*). Below is a notch (*u u'*), which separates this process from another eminence for the insertion of the rectus femoris; it is called *anterior inferior spinous process of the ilium* (*u'*). Below this last process is a notch or angular groove (*u' n*), over which the iliac muscle glides: on this situation the anterior border changes its direction, and, from being vertical, becomes horizontal. The horizontal portion of the anterior border presents then a smooth concave surface inclined forward, and shaped like a triangle, with the base outward. This triangular surface, which is covered by the pectineus muscle, presents, 1. An anterior edge (*, *fig.* 48), continuous with the anterior lip of the obturator foramen. 2. A posterior sharp edge, called *crest of the pubes* (**, *figs.* 47 and 48), a continuation of the horizontal ridge, which we have described as forming the lower boundary of the internal iliac fossa. 3. A base, presenting the *eminentia ileo-pectinea* (*n n*), which corresponds to the femoral artery, and upon which this vessel should be compressed, care being taken to direct the force obliquely downward and backward, that is, perpendicularly to the surface of the bone. 4. The summit of the triangle has a sharp eminence, which, in emaciated subjects, forms a marked projection under the skin. This eminence, called *spine of the pubes* (*o*), gives attachment to the rectus abdominis, and must be distinguished from the *angle of the pubes* (*y'*), which is a right angle formed by the meeting of the anterior and inferior borders.

The *posterior border* (*v w*, *fig.* 48) of the os coxæ commences at the posterior extremity of the crest of the ilium by a sharp eminence, named *posterior* and *superior spinous process of the ilium* (*v*, *figs.* 47, 48); below is a notch, which separates it from another eminence, the *posterior inferior spinous process of the ilium* (*v'*). Below this is a very large notch, the *sciatic notch of the coxa* (*v z*, *fig.* 47), which contributes to form the great sciatic notch, which we shall notice in the general description of the pelvis. This notch is terminated below by a sharp ridge, called the *sciatic spine* (*z*); as this spine sometimes projects inward, can it, as some have imagined, press upon the fœtal head when it is clearing the lower outlet of the pelvis? Between this spine and the tuberosity of the ischium (*z w*) is a small but well-marked groove, over which the tendon of the obturator internus passes.

Internal Structure.—Like all broad bones, the haunch bone is composed of spongy substance contained between two laminæ of compact tissue; at the bottom of the acetabulum, and in the double concavity of the iliac fossæ, it is thin and semi-transparent; it is thick at the circumference, the crest of the ilium, the upper and back part of the ace-

tabulum, the articular portion of the pubes, and more particularly at the tuberosity of the ischium.

Connexions.—The os coxæ unites with its fellow of the opposite side, with the sacrum, and with the femur.

Development.—The os coxæ is developed from three primitive, and five secondary points of ossification. The three primitive points remain distinct until a very advanced period, and therefore both ancient and modern anatomists have incorrectly described them as separate bones, under the names of *ilium*, *ischium*, and *pubes*. The *ilium* (1, *fig.* 48) comprehends the upper part of the acetabulum, and the broad, curved, and triangular surface above it. The *pubes* (2) comprises, 1. The inner part of the acetabulum. 2. The horizontal, prismatic, and triangular column that bounds the obturator foramen above, and which is called the *body of the pubes* (*f*). 3. The vertical descending branch, flattened in front and behind, which bounds the same foramen on the inside, and is called the *descending ramus of the pubes* (*k*, *figs.* 47, 48).

The *ischium* (3, *fig.* 48) comprises, 1. The lower part of the acetabulum. 2. A vertical column, very thick, prismatic, and triangular, which forms the tuberosity below, and bounds the obturator foramen on the outside: this is the *body of the ischium* (*l*, *figs.* 47 and 48). 3. An ascending branch, sloping inward, flattened in front and behind, which bounds the foramen below and on the inside, and joins the descending ramus of the pubes; this is the *ascending ramus of the ischium* (*e*, *fig.* 48). The limits of these three pieces are marked before complete development by three cartilaginous lines, united like the letter Y, at the bottom of the cotyloid cavity (see *fig.* 48), which is the place where the three primitive osseous points meet; and this fact has contributed, in no small degree, to establish that law of osteogony which we noticed in our general remarks, viz., that when an articular cavity exists upon the surface of a bone which is developed from several points, these points always unite in that cavity.

The following are the complementary points: 1. One at the bottom of the acetabulum, pointed out by M. Serres,* and shaped like the letter Y; 2. The *marginal epiphysis*, which occupies and forms the entire length of the crest of the ilium; 3. The epiphysis of the tuberosity of the ischium, which stretches along the ascending ramus; 4 and 5. Two epiphyses, which do not seem constant: one occupies the anterior and inferior spinous process of the ilium; the other, still more rare, occupies the angle of the pubes.

The ossification of the os coxæ commences first in the ilium, in the ischium next, and in the pubes last. The osseous germ of the ilium appears on the fiftieth day, that of the ischium at the end of the third month, and that of the pubes at the end of the fifth month. At birth, the ossification of the os coxæ is not far advanced; the acetabulum is in a great measure cartilaginous. The ascending ramus of the ischium, the descending ramus of the pubes, and the entire circumference of the ilium, are also cartilaginous. These three pieces are united together from the thirteenth to the fifteenth year. At the same time, the secondary points of ossification appear, and successively unite with the primitive. This union is completed from the tenth to the twentieth year; the epiphysis of the crest of the ilium alone remains separate until the age of twenty-two, twenty-four, or even twenty-five years.

The Pelvis in general.

The sacrum, the coccyx, and the haunch bones having now been described, we are enabled to study the bony cavity which they concur in forming. It is called the *pelvis* (*fig.* 48), and forms for the lower extremities an osseous girdle, analogous to that which the shoulders form for the upper extremities. The *pelvis* or *basin*, so named because it has been compared to a vase, is a large, irregular, bony cavity, open above and below, which supports the vertebral column behind, and is itself supported by the thigh bones on the sides and in front. In an adult of ordinary stature, the pelvis divides the body into two equal parts. In the fœtus the part of the body above the pelvis is much longer than that below; in adults of large stature, on the other hand, the part below is considerably longer than that above.

The pelvis is symmetrical, but of a very irregular figure; we may say, upon the whole, that it forms a truncated cone, presenting, 1. An upper part or *great pelvis*, oval transversely, much expanded on each side, and notched in front; 2. A sort of contracted canal, below this upper part, which is called the *little pelvis*. When the pelvis is examined in the skeleton, it has not the horizontal position which it presents when resting on the tuberosities of the ischium and the extremity of the coccyx. It is *inclined* with regard to the axis of the body. The obliquity of the pelvis is not the same throughout, and we have therefore to consider *two axes*, one for the great and one for the little pelvis. The *axis of the great pelvis* is directed obliquely downward and backward, and is represented by a line passing from the umbilicus towards the lower part of the curvature of the sacrum; the *axis of the little pelvis*, on the contrary, is directed downward and forward,

* This point of ossification has been regarded as the vestige of a bone peculiar to marsupial animals, and named *marsupial bone*; but this view is incorrect, for, according to Cuvier, this fourth piece is found in marsupials themselves at the bottom of the cotyloid cavity, whereas the marsupial bone is a superadded portion of the skeleton, which supports the pouch in these animals.

and is represented by a line passing from the upper part of the curvature of the sacrum through the centre of the lower opening or outlet of the pelvis. From the direction of these two axes, it follows that the line of direction of the pelvis is a curve with the concavity forward, and which is pretty correctly represented by the curvature of the anterior surface of the sacrum. This sort of incurvation of the pelvis is an anatomical fact of the greatest consequence, not only on account of the important office which this part of the skeleton performs in the mechanism of standing, but also because, without an acquaintance with it, it is impossible to understand the mechanism of natural labour, the curved canal of the pelvis being the path which the infant has to traverse in passing out of the cavity.

The obliquity of the pelvis varies at different ages and in different individuals: it is pretty exactly measured by the prominence of the sacro-vertebral angle.

In the infant the pelvis deviates greatly from the horizontal direction; its upper aperture looks almost directly forward: in the adult it looks much more upward; and in the aged it again looks forward, as in the infant, but from a very different cause. In the fœtus the superior aperture is turned forward, even when the body is upright: at this age the obliquity of the pelvis is inherent in its form; but in the aged the pelvis looks forward, because the trunk is curved in the same direction, and tends towards a horizontal position as in quadrupeds. Thus in the fœtus the pelvis has an obliquity which depends on form; in the aged the obliquity depends upon attitude.

The human pelvis is much larger than that of any other animal; and this larger size is connected with the important office it performs in maintaining the erect posture of the trunk.

There is no part of the skeleton the form and dimensions of which so readily discriminate the sex of the individual; in the male the height predominates; in the female the breadth. By comparing the distance between the crests and the anterior and the posterior spinous processes of the ilia, and between the obturator foramina, in the two sexes, we find that the transverse dimensions are much greater in the female; the same is observed in the antero-posterior dimensions, which may be easily proved by measuring the distance between the symphysis pubis and the sacro-vertebral angle, and the distance between each obturator foramen and the sacro-iliac symphysis on the opposite side. We should add that, in the female, 1. The iliac fossæ are larger, and turned more outward than in the male; hence the prominence of the hips. 2. The crest of the ilium is not so much twisted in form of the italic *S*. 3. The interval between the symphysis pubis and the acetabulum is greater; this is partly the cause of the great prominence of the trochanters, and the separation of the femora, which gives the female a peculiar gait in walking. 4. The superior strait or brim is wider in every direction. 5. The tuberosities of the ischia are more separated, and the symphysis pubis is not so deep. 6. The obturator foramen is triangular. 7. The arch of the pubis is rounded, wider, and more curved, while in the male it is triangular and narrower. 8. The inner edges of the ascending rami of the ischia are prominent, and look less directly downward than in the male.

Such are the differences of the pelvis as regards sex; we see that, for the most part, they may be comprehended in the following proposition:

The female pelvis exceeds the male in its horizontal diameters; the male pelvis exceeds the female in its vertical diameters.

Regions of the Pelvis.

Under this title we shall examine in succession the external and internal surface of the pelvis, the upper circumference or base, and the lower circumference or summit.

The *external surface of the pelvis* must be examined in front, behind, and on the sides.

Anterior Region.—1. In the median line we observe the symphysis pubis (*y y*, *fig.* 48), varying from fifteen to eighteen or twenty lines in length, always longer in the male, and resembling a vertical column. It is obliquely directed downward and backward, which direction is peculiar to man; in all other animals, as Cuvier has remarked, it is placed horizontally. 2. On each side we find the descending ramus of the pubes (*k*), which is irregularly quadrilateral, and gives attachment to several muscles. 3. Outside the pubic column there is, on each side, the obturator foramen (*h*).

Fig. 48.

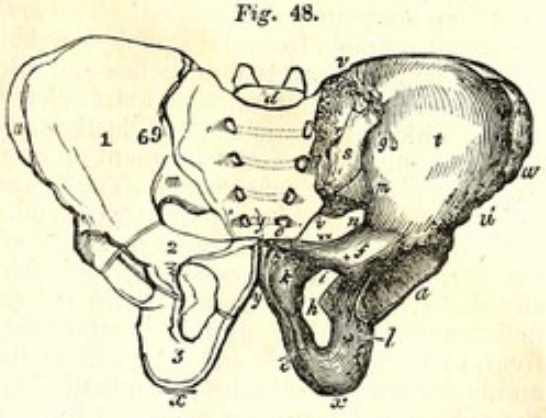

Posterior Region.—On this we observe, 1, the ridge of the sacrum in the median line; 2, and on each side the sacral grooves into which the posterior sacral foramina open; they are much deepened above, because the back part of the ilium projects behind the sacrum: we find here, also, two ranges of eminences, corresponding to the articular and transverse processes, and likewise the back of the sacro-iliac articulation.

Each *lateral region* is formed by the external iliac fossa, the acetabulum, and a considerable portion of the body of the ischium below this cavity.

The *internal surface of the pelvis* is divided into two parts: an upper, which is much expanded, and constitutes the *great* or *false pelvis;* and a lower, more contracted, named the *small* or *true pelvis.* These two portions of the same cavity are separated by a circular prominence, formed in a great measure by the horizontal ridge (*m n o*), which we have described as constituting the lower boundary of the internal iliac fossæ. The whole space circumscribed by this line has been named *the brim, superior orifice,* or *superior strait of the pelvis.*

The *great pelvis* presents, 1. In front, an extensive notch (*u y' u*); 2. Behind, the *sacro-vertebral angle* or *promontory of the sacrum* (below *d*); 3. And on the sides, the internal iliac fossæ (1 and *t*), which form an inclined plane on each side, fitted to direct the weight of the viscera which rest upon them, inward and forward.

The *small pelvis* is a cavity, the apertures of which are contracted, and therefore named *straits,* and the middle portion is expanded, and called *excavation.*

We shall, therefore, examine separately its superior opening or *upper strait,* its inferior opening or *lower strait,* and its middle portion or *excavation.*

The *superior strait* or *brim* is irregularly circular, and has been compared to an oval, an ellipse, or a curvilinear triangle; but none of these descriptions can give any correct idea of its shape. The circumference, commencing behind, at the articulation between the sacrum and the fifth lumbar vertebra, is formed by the projection of the anterior edge (*g d*) of the base of the sacrum, by the horizontal ridge (*m n*), on the inner surface of the iliac bones, by the pectineal line (*n o*), and terminates in the spine of the pubes (*o*). The superior strait has *four diameters, an antero-posterior, a transverse,* and *two oblique.* The *antero-posterior* or *sacro-pubic* diameter (*d y'*) is generally four inches in length; the *transverse* (*m m*), which is the longest, is five inches; and the *two oblique* (*n g*), which are measured from the eminentia ilio-pectinea on one side, to the sacro-iliac symphysis on the other, are four inches and a half. These measures are taken from a well-formed female pelvis, and it is chiefly in the female that they are important, on account of their reference to the process of parturition. In the male, all the diameters of the upper strait are smaller.

The *inferior* or *perineal strait, inferior* orifice or *outlet* of the small pelvis, presents three deep notches separated by three eminences, so that when the pelvis is placed upon a horizontal plane, it appears to rest, as it were, upon three feet. Of these notches, one is anterior, viz., the *arch of the pubes* (*x y x*); the others are lateral, and somewhat posterior; they are the *ischiatic notches* (*v' z, fig.* 47). The *arch of the pubes* is angular in the male, but rounded in the female, forming a true arch, which receives the occipital bone of the fœtus in the great majority of labours; it is formed on each side by the ascending ramus of the ischium, the edge of which is somewhat everted, so that the head of the fœtus when passing under the arch glides over a sort of inclined plane, instead of being in contact with the edge of the bone. The *transverse diameter* of the pubic arch near the upper part has been calculated at one *inch;* that of the lower part (*x x, fig.* 48), at three *inches.* The two lateral notches are formed behind by the sacrum and the coccyx; in front, by the sciatic notch of the os innominatum; they are therefore called also the *sacro-sciatic notches.* They are very deep, and reach almost to the superior strait of the small pelvis. Of the three *eminences* which separate the notches, the posterior is formed by the coccyx, and the two anterior by the tuberosities of the ischia, which are situated on a lower plane than the first; from this peculiar arrangement, the whole weight of the body, in the sitting posture, rests upon the tuberosities of the ischia, and not at all upon the point of the coccyx. The diameters of the lower aperture of the pelvis are, in reference to parturition, of equal importance with those of the upper, and have been accurately determined. The *antero-posterior* diameter, or *cocci-pubic,* so called because it extends from the symphysis pubis to the point of the coccyx, is four inches, but may be increased to four inches and a half by depression of the coccyx. The *transverse* or *bisciatic* diameter, which stretches between the tuberosities of the ischia, is four inches, which is invariable; and, lastly, the *two oblique diameters,* which extend from the middle of the sacro-sciatic ligament on one side to the tuberosity of the ischium on the other, are also four inches each. These dimensions, which are taken from a well-formed female pelvis, are greater than in the male.

Excavation.—The excavation or cavity of the true pelvis is formed, 1. Behind, by the sacrum and coccyx, the concavity of which varies in different individuals, but is generally shallower in the female than in the male. The height of these two bones is four inches and a half; the greatest depth of their concavity from ten to twelve lines. 2. In front, by the symphysis and back part of the pubes, forming a plane inclined downward and backward; outside the pubes is the inner opening of the obturator foramen. 3. On the sides, the excavation is formed by two smooth planes inclined downward and inward; they are about three inches and a half in height, and are bounded behind by the sciatic notch.

It is of great consequence to notice these two inclined planes, because they perform

an important part in the mechanism of parturition. The diameters of the excavation being of little value in an anatomical point of view, the student is referred to works on midwifery for an account of them.

The *superior circumference* or *base of the pelvis* looks forward, and is formed behind by the sacro-vertebral angle; on each side by the upper border of the ilium, and in front by the anterior border of the same bone. It presents, 1. In front, *a vast notch* (*u u*, *fig.* 48), in which we observe *in the median line* the upper part of the symphysis pubis (*y'*); *on each side*, proceeding from within outward, the spine of the pubes (*o*), the pectineal surface (*o n*), the ilio-pectineal eminence (*n n*), and the angular groove for the psoas and iliacus muscles (*n u'*). In all this extent the notch is horizontal, but beyond the groove it slants obliquely upward and outward, to the anterior superior spinous process of the ilium (*u*), where it terminates. 2. Behind, the great circumference of the pelvis presents the sacro-vertebral angle, and on each side a small notch between the vertebral column and the back of the crest of the ilium. 3. Laterally, we observe the crest of the ilium (*u v*), bent much more outward in the female than in the male.

The dimensions of the upper circumference of the pelvis, measured in a well-formed female, are the following: 1. Between the anterior superior spines of the ilia, from eight to nine inches. 2. From the middle of the crest of one ilium to that of the other, from nine to ten inches.

The *inferior circumference* of the pelvis forms the lower strait, which has been already described.

General Development of the Pelvis.

The pelvis in the first periods of life participates in the slow development of the lower extremities. Its dimensions, especially in the fœtus and in infancy, are so small, that it is unable to receive into its cavity many of the organs which are afterward contained in it; this is one of the principal causes of the prominence of the abdomen of the fœtus. The smaller capacity of the pelvis results also from the absence of the iliac fossæ, for these bones are neither twisted nor excavated, but straight and flat. Nevertheless, the upper or iliac portion of the pelvis is proportionally more developed than the lower or cotyloid, doubtless because this latter part belongs especially to the lower extremities, and also serves as a protection to the genital organs, both of which are in a rudimentary state in the fœtus. If we examine in detail the differences in size, considered only with reference to the various diameters, we shall find that the transverse are very small, because in front the cotyloid cavities are scarcely developed, and all the pubic region is contracted; and behind, the iliac bones are more closely approximated to each other, on account of the small size of the sacrum. The antero-posterior diameters appear longer, on account of the shortness of the transverse. But the most characteristic feature of the pelvis in the early periods of life is its much greater inclination than in the adult. In the latter, indeed, a horizontal line drawn from the upper part of the symphysis pubis would fall only a few lines below the base of the sacrum, while in the fœtus a similar horizontal line would fall nearer the lower than the upper part of the sacrum. This, as well as the small capacity of the pelvis, is the cause of the forward position of the bladder, bringing the whole of its anterior surface to correspond with the parietes of the abdomen, and, consequently, rendering it more easily accessible to instruments introduced above the pubes.

We have already remarked, that the obliquity of the pelvis in the aged is not of the same kind as that in the fœtus; and we should add here, that there is no change in the relative position of the bladder, which, as in the adult, corresponds to the back of the os pubis.

The Thigh.

The Femur (*figs.* 49 and 50).

The femur, or thigh bone, situated between the pelvis and the leg, is the longest and largest bone of the skeleton. It is proportionally larger in man than in any other animal; this is connected with the office which it performs, of supporting, by itself alone, the weight of the body in standing, and transmitting it to the leg. It is obliquely directed downward and inward. This obliquity is greater in the female than in the male, on account of the greater distance between the acetabula. Too great an obliquity is injurious both in standing and walking, and constitutes a well-known deformity.

The femur describes a curve in front and behind, the convexity of which looks forward, and leaves a sort of excavation behind, which is occupied by the numerous powerful muscles which bend the leg upon the thigh. This curvature, of which the summit is in the middle of the bone, explains why fractures generally occur here. It is generally very great in subjects affected with rickets. Independently of this antero-posterior curvature, the femur is slightly twisted upon itself. This curvature of torsion seems to me to be connected with the course of the femoral artery, which passes round the shaft of the bone from one surface to the other. Lastly, at its upper part it presents an angular curve, which we shall notice presently.

Like all other long bones, the femur is divided into a body and extremities.

Of the Body.—The body or shaft is prismatic and triangular, with three surfaces and three edges.

The *anterior surface* (*a*, *fig.* 50) is rounded, and has a cylindrical aspect; it is broader below than above.

The *internal surface* (*b*, *fig.* 49) is flat, it becomes much wider below, and then looks backward. The femoral artery corresponds to this surface, and may be compressed upon it towards the middle third of the thigh.

The *external surface* (*c*) is much narrower than the internal, and is slightly excavated throughout its extent.

Of the *three edges*, the *internal* and the *external* are rounded, and scarcely distinguishable from the surfaces which they separate. The *posterior edge* (*e d f*), on the contrary, is very rough and prominent, and has, therefore, been called the *linea aspera:* it is divided into *two lips* and an *interspace*, for the sake of facilitating the description of the numerous muscles to which it gives attachment. It is more rough above than below, and is bifurcated at both ends. Of the two branches of the upper bifurcation, the *external* (*e*), extremely rough, is occasionally surmounted by a considerable eminence, and prolonged to the large process called great trochanter. The *internal branch* is less projecting, and terminates on the inside in a smaller eminence called lesser trochanter. The *outer branch* (*f*) of the lower bifurcation runs towards the outside of the lower extremity of the femur, and terminates in an eminence, below which is a small depression, to which the external head of the gastrocnemius is attached. The *inner branch* (*g*) is nearly effaced at the part where the femoral artery passes over it: below this it appears again, and, like the outer branch, terminates in a well-marked prominence, to which the adductor magnus is attached, and, below it, the inner head of the gastrocnemius. The triangular interval, included between the two branches of the bifurcation, corresponds to the popliteal artery and vein. The nutritious foramen (*h*) is situated in the linea aspera; it passes from below upward.

Fig. 49.

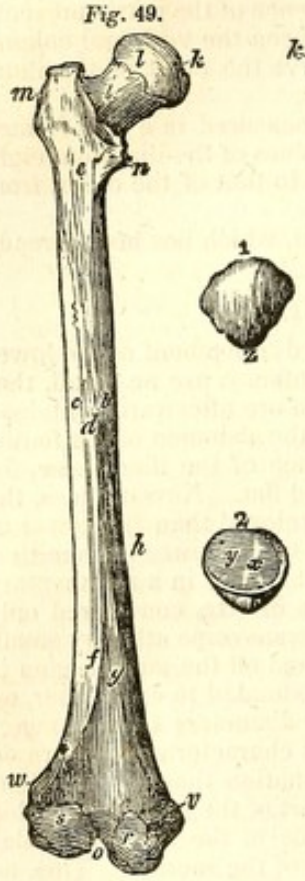

Fig. 50.

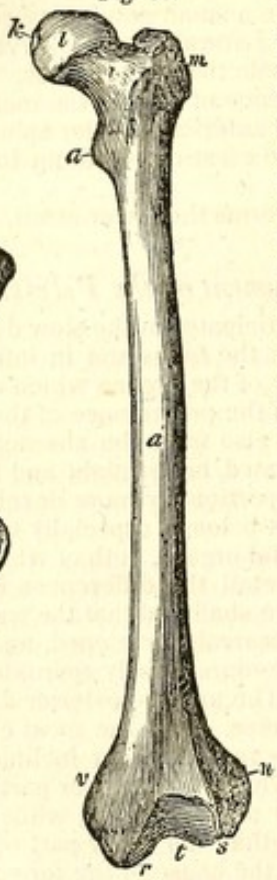

The *superior extremity* of the femur forms an obtuse angle with the body, and presents a *head*, a *neck*, and two unequal eminences, named *trochanters*, the *greater* and *lesser*.

The *head* (*i*, *figs.* 49 and 50) is the most regularly spheroidal of all the eminences in the skeleton, and forms nearly two thirds of a sphere. In the middle of it we observe a rough depression (*k*) of variable dimensions, which gives attachment to the round ligament. The *neck* (*l*), so called because it supports the head of the bone, is obliquely directed upward and inward; it forms an obtuse angle with the body of the femur (*angle of the femur*), retiring on the inside and projecting on the outside, the degree of which varies in different individuals, at different ages, and in the two sexes. In fact, it is sometimes a very obtuse and sometimes a right angle: this last is most common in the female, and is one of the causes of the prominence in her of the great trochanter. The neck, which varies in length in different subjects, is flattened in front and behind, so that its vertical diameter is double the antero-posterior; hence it has more power in resisting force applied from above downward than from before backward, which is a great advantage, since the causes which would produce fractures are almost always applied in the former direction. The anterior surface of the neck is much shorter than the posterior, which is also slightly concave. The upper edge is very short, and presents a great many nutritious foramina; the lower edge is about double the length of the upper. The base of the neck is marked by a number of nutritious foramina; it is bounded in front by some inequalities; behind by the great trochanter above, and the lesser trochanter below; and in the interval between these two, by a projecting ridge, which unites them, and which is called the *inter-trochanteric line*. Behind, at the root of the great trochanter, there is a deep pit, which weakens the neck of the bone in this situation, from which circumstance fractures most generally occur at that point.

The *great trochanter* (*m*) is situated a little behind, at the outer and upper part of the

femur. It is on a lower level than the head, and nearly in the same axis as the shaft, which it prolongs upward. It is of considerable size, and forms a very marked prominence under the skin. It should be carefully studied in its relations, 1. With the crest of the ilium, beyond which it projects on the outside; 2. With the external condyle of the femur; 3. With the external malleolus, because these relations constantly serve as a guide, both in the diagnosis, and the reduction of dislocations of the femur, and of fractures of the neck or shaft of that bone. The great trochanter, which is intended solely for muscular insertions, is of a quadrilateral figure, flattened from without inward, and presents, 1. An *external surface*, which is convex, and terminates below in a projecting ridge for the vastus externus, and is traversed by an oblique line running downward and backward, to which the gluteus medius is attached; 2. An *internal surface*, on which we find a depression called *digital*, or *trochanteric cavity*, where the tendon of the *obturator externus* is inserted; 3. A *superior border*, to which the gluteus minimus, the *pyramidalis*, and *obturator internus* are inserted; 4. An *anterior border*, which is often surmounted by a large tubercle, gives attachment to the *vastus externus;* and, 5. A *posterior border*, which gives attachment to the quadratus femoris.

The *lesser trochanter* (*n*) is situated on the inside, behind, and below the base of the neck of the femur; it is a sort of conoid tubercle, and gives attachment to the common tendon of the psoas and iliacus muscles.

The *lower end* of the shaft of the femur is of considerable size; it is broad, transversely flattened in front and behind, and divided into two convex articular processes, called *internal* (*r*) and *external* (*s*) *condyles* of the femur. The external condyle is in the same line as the shaft of the femur. The internal condyle projects on the inside of the axis of the bone, and below the external condyle, so that when both condyles rest on the same horizontal plane, the femur is directed obliquely downward and inward. The two condyles are separated behind by a deep notch, called *inter-condyloid notch* (*o*, *fig.* 49); in front their union forms a sort of pulley, the *femoral trochlea* (*t*, *fig.* 50), on which the patella rests. That portion of the trochlea which belongs to the external condyle is larger, more prominent, and higher than that which belongs to the internal. Each condyle has three surfaces: 1. The *lower surface*, articular, convex, and rounder behind than in front, is in contact with the tibia and the patella; the lower surface of the internal condyle is more prominent behind than that of the external. 2. The *internal surface* of the external condyle, and the *external surface* of the internal condyle, are deeply excavated, and give insertion to the crucial ligaments. 3. The *internal surface* of the internal condyle and the *external surface* of the external condyle present two enlargements, called *tuberosities of the femur*.

The *internal tuberosity* (*v*) is the larger, and has behind a depression situated above the tubercle for the adductor magnus, already described. The *external tuberosity* (*w*) is less prominent, and presents two depressions separated by a tubercle, which may be easily felt under the skin in emaciated subjects. The inferior groove is distinctly marked, and gives origin to the tendon of the *popliteus* muscle.

Connexions.—The femur articulates with the innominatum, which transmits to it the weight of the body, and with the tibia upon which it rests, and is in contact with the patella.

Internal Structure.—Like all long bones, the femur is compact in its shaft and spongy at the extremities; its medullary canal is the type of canals of that kind.

Development.—The femur is developed from five points: of these, *three are primitive*, viz., one for the shaft, and one for each extremity; *two* are *epiphysary*, one being for each trochanter. A bony point first appears in the shaft, from the thirtieth to the fortieth day; the osseous germ of the lower extremity is visible in the centre of the cartilage, during the last fifteen days of fœtal life. The constancy of the appearance of this point is of great importance in forensic medicine, because its existence proves at once that the fœtus has reached the full term. The third point is seen in the head of the femur, at the end of the first year after birth. The neck has no separate osseous centre; it is formed by an extension of the shaft. The nodule of the great trochanter is developed from three to four years after birth; that of the lesser trochanter, from the thirteenth to the fourteenth year.

The order of union of these parts does not coincide with that of their appearance; it commences after puberty, and does not terminate until after the growth of the body is completed. The lesser trochanter, the great trochanter, and the head, are successively attached to the bone about the eighteenth year. The lower extremity, which appeared first, does not join the shaft until the twentieth year. In old age the spongy tissue is frequently so delicate, that the interior of the neck becomes filled with an adipose tissue like the body of the long bones. This explains the frequency of fractures in this situation in advanced age.

The Patella (*fig.* 51).

The *patella* or *rotula*, so named from its rounded shape, resembling a wheel, is, both from its size, and the functions which it performs, the most important of those bones

which have been called *sesamoid* (from σησάμη), on account of their resemblance to the sesamum seed, and which are found in the neighbourhood of various articulations that are subjected to much pressure. It is situated in front of the knee, and is movable when the leg is extended; but fixed and very prominent when the leg is flexed upon the thigh. Its mobility allows it to escape the injurious effect of external blows, to which it would be subject were it united to the tibia like the olecranon process to the ulna. It is the most variable of all the bones, both in its absolute size, and in the proportion of its different dimensions. It is flattened in front and behind, and presents an interior and a posterior surface, and a circumference.

The *anterior* or *subcutaneous surface* (1, *fig.* 51) is convex, and covered by a very thick layer of fibrous tissue, intimately adherent to the bone.

The *posterior* or *femoral surface* (2, *fig.* 51) corresponds exactly to the pulley on the lower extremity of the femur. We observe on it, 1. An articular ridge (*x*) sloping downward and inward, and corresponding to the groove of the trochlea, which presents the same obliquity. 2. On each side of this ridge, a concave articular surface, which is moulded upon the corresponding condyle of the femur; and as the external condyle of the femur is the larger, the external articular surface (*y*) of the patella is much greater than the internal. From this inequality, it is easy at once to distinguish the right from the left patella.

The *circumference* of the patella resembles a curvilinear triangle; its thick base, directed upward, gives attachment to the tendon of the *rectus femoris* and to the tendons of the extensor muscles of the leg; and its *apex* (*z*), turned downward, and somewhat pointed, gives attachment to the ligamentum patellæ. Its *sides* are thin, and give attachment to some aponeurotic fibres; so that, excepting its posterior surface, which is articular, the whole patella is enveloped in fibrous tissue; a circumstance which is in accordance with its peculiar mode of development, and has an important influence over its reunion when fractured.

Internal Structure.—The patella is entirely composed of spongy tissue, covered in front by a thin layer of compact substance, which renders it very liable to fracture, and which forms a very remarkable exception to the generality of short bones, in presenting well-marked parallel vertical fibres. Between these fibres are numerous vascular openings.

Development.—The patella is developed from one point only. In a few rare cases, as Rudolphi has observed, there are several points. The ossification of the patella commences about the age of two years and a half.

The Leg.

The Tibia (*fig.* 52).

The tibia, the larger of the two bones of the leg, is situated between the femur, which rests upon its upper end, and the foot on which it is supported. Next to the femur, it is the largest and longest bone of the skeleton. Its upper extremity is expanded; the shaft is narrower, and of a triangular prismatic form. The lower extremity is also expanded, but to a much less degree than the upper. The smallest part of the tibia does not exactly correspond with the middle of the shaft as in the femur, but at the junction of the lower with the two upper thirds; and in this place fractures, produced by *contre-coup*, are most frequent. The direction of the tibia is vertical, contrasting thus with the femur, which, as we have seen, slants obliquely downward and inward. In individuals whose thigh bones are very oblique, the tibiæ have a direction downward and outward. In a well-formed skeleton, the two tibiæ are parallel.

With regard to its axis, the tibia presents a double inflection, so that the upper end is turned outward and the lower slightly inward. When this last inclination is excessive, it gives rise to bowed legs. Lastly, it is slightly twisted at its lower part.* Like all long bones, it is divided into a body and extremities.

The *body* or *shaft* has the figure of a triangular prism; and this form, which is observed in almost all long bones, is in none so marked as in the tibia. We have, therefore, to consider three surfaces and three edges.

The *internal surface* (*a*, *fig.* 53) is covered at the upper part by the internal lateral ligament, and by an aponeurotic expansion (called *patte d'oie*,† or *goose's foot*): in the rest of its extent it is immediately under the skin. This superficial situation of the internal surface partly explains the facility with which this bone may be broken by direct violence, and also the frequency of caries, exostoses, and necrosis. It is broad above, and gradually diminishes towards the lower part. Its three superior fourths look inward and forward; its lower fourth looks directly inward.

The *external surface* (*b*) presents in a great part of its extent, but especially above, a longitudinal excavation, the depth of which corresponds to the size of the tibialis an-

* The absence of an antero-posterior curvature and the lateral curves in opposite directions, together with its slight torsion, explains the great solidity of this bone.

† [This *patte d'oie* consists of the expansion formed by the tendons of the sartorius, gracilis, and semitendinosus muscles.]

Fig. 52. Fig. 53.

ticus, to which it gives attachment. Inferiorly, the external surface of the tibia turns forward (*d*), and this deviation corresponds with the altered direction of several tendons, which are placed at first on the outside of the bone, and afterward pass in front of it. There is, in fact, a constant reciprocity between alterations in the direction of bones, and changes in the course of neighbouring tendons.

The *posterior surface* is also broad above, and progressively diminishes downward. On it we observe near the upper part, 1. An irregular line, running obliquely downward and inward; to this line many of the deep-seated muscles on the back of the leg are attached. 2. Above this line a triangular surface covered by the popliteus muscle, which separates it from the popliteal artery. 3. Below the same line, the orifice of the nutritious canal, which runs downward. Into this nutritious canal, which is, perhaps, the largest of any in the long bones, I have seen a nervous twig enter, accompanying the nutritious artery. 4. From the oblique line to the lower end of the tibia, the posterior surface of this bone is smooth, of almost uniform diameter, and divided throughout its length by a more or less marked vertical line.

The *anterior edge* (*c c*) is placed immediately under the skin, beneath which it may be readily felt;* its lower fourth is round and blunt, the upper three fourths are sharp, and hence it has been called the *crest of the tibia*. Its upper part inclines somewhat outward, its lower part inward.

The *external edge* (*g k*) gives attachment to the interosseous ligament; it is bifurcated below, and thus forms the two boundaries of an articular cavity, which we shall notice in describing the lower end of the tibia. The *internal border* (*f l*), much less sharp than the others, affords insertion to several muscles.

The *upper* or *femoral extremity* (*f g*) of the tibia is at least double the size of the lower, and is larger in a transverse direction than from before backward; on it we observe two concave articular surfaces, of an oval shape, with their long diameter directed from behind forward. They have been improperly denominated *condyles*; a more correct name would be *glenoid cavities of the tibia*. These surfaces, which articulate with the condyles of the femur, are not perfectly alike; the internal is longer, narrower, and deeper than the external. They are separated by a pyramidal eminence surmounted by two sharp tubercles. This eminence, which is called the *spine of the tibia* (*e*), is nearer the posterior than the anterior part of the bone. In front and behind this spine are two rough depressions, which give attachment to the crucial ligaments. The glenoid cavities are supported by two considerable enlargements, called *tuberosities of the tibia*.

The *internal tuberosity* (*f*), larger than the external, presents behind a horizontal groove, into which one of the divisions of the tendon of the semi-membranosus is inserted. The *external tuberosity* (*g*), smaller, but more prominent behind than the internal, presents at its back part a small, almost circular facette, which articulates with a corresponding surface on the fibula. The two tuberosities of the tibia are separated behind by a considerable excavation. In front they are separated by a triangular surface, pierced by vascular foramina, and terminating below in an eminence, called *anterior tuberosity of the tibia* (*h*). This tuberosity, below which the crest of the bone commences, is rough and prominent below, where it gives attachment to the tendon of the extensor muscles of the leg, *ligamentum patellæ*,† and smooth above, where it is separated from the same tendon by a synovial bursa. A projecting line runs outward from this tuberosity, and terminates above in a tubercle, which is very prominent in some individuals, and may be easily felt under the skin. It gives origin to part of the tibialis anticus.

The *lower* or *tarsal extremity* (*l k*) of the tibia is almost square, having, like the upper, its greatest diameter transversely. We observe on it a quadrilateral articular cavity (*i*), transversely oblong, broader on the outside than on the inside, and divided by an antero-posterior ridge, into two unequal parts. It articulates with the astragalus. The circumference of this extremity presents, 1. *In front*, a convex surface (*d*), with some inequalities for the insertion of ligaments; it is in contact with the extensor tendons of the toes. 2. *Behind*, an almost plane surface, having a shallow depression, which is hardly visible in some subjects, for the tendon of the long flexor of the great toe, and which must not be confounded with an oblique groove, situated on the inner side, and which will be described with the internal malleolus. 3. On the *outside*, a triangular cavity (*k*), broad and smooth below, narrow and rough in its two upper thirds, which articulates with the fibula. 4. On

* The superficial situation of the anterior edge of the tibia renders it a good guide to surgeons in the diagnosis and coaptation of fractures of the leg. It also greatly exposes the bone to injury from external violence. It is not uncommon to find it broken, or, as it were, notched, by a gun-shot.

† I have seen this tuberosity so large that several practitioners, not familiar in such anatomical varieties, believed it to be an exostosis, and had placed the patient, a lad of 14 years of age, under a course of mercurial frictions.

the *inside*, a thick quadrilateral process, flattened on the outside and the inside, and called the *internal malleolus* (*l*). This eminence, which bends inward, forms a marked prominence at the lower and inner part of the tibia. When the posterior surface of the tibia is laid upon a horizontal plane, the two tuberosities of the upper end of the bone rest upon that plane, while the internal malleolus advances considerably forward; it is therefore upon a plane anterior to that of the internal tuberosity of the tibia: this depends upon the torsion of the lower part of the bone. The *internal surface* (*l*) of the malleolus is convex, and is placed immediately under the skin: its *external surface* forms part of the inferior articular cavity of the tibia. Its *anterior edge* is rough, and gives attachment to ligamentous fibres; its *posterior edge*, which is thicker than the anterior, presents a groove running obliquely downward and inward, and sometimes double, along which the tendons of the tibialis posticus and flexor longus digitorum pass. The *base* of the malleolus, very thick, is united to the shaft of the bone. The *summit*, which is truncated and slightly notched, gives attachment to the internal lateral ligament of the ankle-joint.

Connexions.—The tibia articulates with the femur, the astragalus, and the fibula; it articulates also with the patella, but indirectly by means of the ligamentum patellæ.

Internal Structure.—The shaft consists of compact tissue, and has a large medullary canal. The two extremities are spongy, and are pierced by a great number of vascular foramina.

Development.—The tibia is developed from three points; one for the body, and two for the extremities. Sometimes there are four. Béclard once saw the internal malleolus developed from a separate point. The ossific point of the shaft is the first to make its appearance; it commences between the thirty-fifth and fortieth day, almost at the same time as that of the body of the femur; sometimes it is even earlier, as in one case observed by myself. The bony germ of the upper extremity makes its appearance generally towards the end of the first year after birth. I have never seen it before birth. The ossification of the lower extremity commences during the second year. The internal malleolus is formed by a prolongation of this extremity. The union of all the parts of the bone is not finished until the period of complete development of the body, that is, from the eighteenth to the twenty-fifth year; it always commences with the lower extremity, which is the last to become bony. It is of importance to remark, that the superior epiphysis of the tibia does not form the whole of the upper end of the bone, but only a sort of horizontal plate which supports the articular cavities; and the same is true of almost all articular extremities. It should also be observed, that the anterior tuberosity of the tibia is formed by a vertical prolongation of the plate which forms the superior epiphysis. It would oppear, that in some subjects this anterior tuberosity has a distinct centre of development.

The Fibula (*fig.* 53).

The *fibula* or *perone* (from περόνη) is so named because, according to Sabatier, it has been compared to a sort of clasp or brace in use among the ancients.

In order to understand the description of this bone, it is necessary to place it exactly in the position which it occupies in the skeleton.* It is situated on the outside of the tibia below, on the outside and to the back of the same bone above. It is as long as the tibia, but is extremely slender; it is, indeed, the most slender of all the long bones, and may be at once recognised by this character. Its direction is vertical, with a slight inclination outward at its lower part. It is the most twisted on itself of all the long bones, and is a remarkable exemplification of that law of osteology, viz., that the *torsion of bones is always connected with the changes of direction of tendons, or vessels.* It is divided into a body and two extremities.

The *body* has the form of a triangular prism. In order rightly to comprehend its shape, it is necessary to be aware that the muscles which are placed on its external surface above turn round to the posterior aspect below, from which it is easy to understand how the four upper fifths of the external surface look outward, and the lower fifth backward.

The *external surface* (*n*) is marked by a deep groove which runs along it, and gives attachment to the *peroneus longus*, and *peroneus brevis*. The lower part, which is turned backward, is smooth. The *internal surface* is divided into two unequal parts by a longitudinal ridge, to which the interosseous ligament is attached. The portion of the surface in front of the ridge is narrower than the other, being in some subjects not more than two lines in breadth; it gives attachment to the muscles on the fore part of the leg: the portion behind the ridge is larger, and gives attachment to the tibialis posticus. This surface becomes anterior at its lower part (*o*).

* We have hitherto deemed it unnecessary to indicate the position in which each bone should be studied, because a glance at an articulated skeleton would suffice to enable the student at once to place the bones aright. The fibula, however, forms an exception, on account of its remarkable torsion. In order, then, to study this bone correctly, it is necessary to place the flattened end (*u v*) downward, taking care that the articular surface on that part be turned inward, and that the thin edge (*u*) of the eminence which forms this lower end should look forward.

The *posterior surface* of the fibula is narrow above, and expanded below, where it looks inward, and terminates by a rough part, to which ligaments that unite it to the tibia are attached. The whole of this surface gives attachment to muscles. We observe on it the principal nutritious canal, which passes obliquely downward. This canal is sometimes placed on the internal surface of the bone.

The *three edges* participate in the deviations of the surfaces. Thus, the *outer edge* (*r*) becomes posterior below; the *anterior edge* (*s*) becomes external, and is bifurcated; the *internal edge* becomes anterior, and after being thus changed, forms the continuation of the ridge for the interosseous ligament, which we noticed upon the inner surface.

All the edges give attachment to muscles and aponeurotic processes, and are remarkable for their prominence.

The *superior extremity* or *head* (*t*) of the fibula presents an *articular facette* (near *t*), slightly concave, which unites with a corresponding surface on the tibia: on the outside are some irregular impressions for the insertion of the biceps muscle, and the external lateral ligament of the knee. At the back part of this head we observe the *styloid process of the fibula* (below *t*) for the tendon of the biceps.

The *lower extremity* or *external malleolus* (*u v*) passes much below the inferior articular surface of the tibia; it is longer and thicker than the internal malleolus. It is flattened on the outside and the inside, and presents, 1. An *external surface* (*u v*), convex and sub-cutaneous. 2. An *internal surface*, which articulates with the astragalus by means of a facette, which completes on the outside the sort of mortise formed by the union of the lower ends of the tibia and fibula; below and behind this surface is a deep, rough excavation, which gives attachment to a ligament. 3. An *anterior edge* (*u*) for the insertion of a ligament. 4. A *posterior edge* (*v*), thicker, marked by a superficial groove for the passage of the tendons of the peronei muscles. 5. A *summit*, which gives attachment to one of the external lateral ligaments of the ankle-joint.

Connexions.—The fibula forms the outer part of the leg, and articulates with the tibia and the astragalus.

Internal Structure.—The shaft is compact, and has a very small medullary canal, and the extremities are spongy.

Development.—The fibula is developed from three points: one for the body, and one for each extremity. The osseous point of the body appears a little after that of the shaft of the tibia, from the fortieth to the fiftieth day. At birth, the two extremities are still cartilaginous. An osseous point appears in the lower end during the second year; that of the upper end about the fifth. The extremities are united to the shaft of the bone when the development is completed, viz., from twenty to twenty-five years: the lower end is the first to become joined.

The Foot (*figs.* 54, 55, and 56).

The *foot* is the part of the lower extremity which is analogous to the hand in the upper. They are both but varieties of the same type of organization, with certain differences which have reference to their respective uses. In the foot, for example, which is intended to support the body, the conditions necessary for solidity are principally manifest, while the hand is chiefly remarkable for the mobility of its parts.

The foot is composed of twenty-six bones, which, by their union, form three distinct parts, viz., 1. The *tarsus* (*c i f*, *fig.* 54), a bony mass, consisting of seven pieces closely articulated; 2. The *metatarsus*, composed of five separate columns (*m m`*, *figs.* 54 and 55); and, 3. The *toes*, formed each of three columns (*n o r*), excepting the first, or most internal, which has only two (*n` r`*).

Fig. 54.

Fig. 55.

The size of the foot varies in different individuals. It exceeds the hand in thickness and length, but is not so broad. Its direction is horizontal from before backward, and it forms a right angle with the leg, differing much in this respect from the hand, which is in the same line as the forearm. It is flattened from above downward, is hollow below (*fig.* 56), narrow behind, where it is of considerable height, and thinner and broader in front, at which part also it is digitated. It presents, 1. A *superior* or *dorsal surface*, which is convex, *dorsum pedis*, (*fig.* 54); 2. An *inferior* or *plantar surface*, which is concave transversely, and likewise in the antero-posterior direction, *sole of the foot* (*fig.* 55); 3. An *internal* or *tibial edge* (*fig.* 56), which is very thick, and corresponds to the great toe; 4. An *external* or *fibular edge*, which corre-

sponds to the little toe; 5. A *posterior extremity* or *heel*; 6. An *anterior* or *digital extremity*. We shall describe in succession the tarsus, the metatarsus, and the toes.

The Tarsus (*figs.* 54, 55, and 56).

The tarsus is an analogous structure to the carpus, but differs from it in forming the posterior half of the foot, while the carpus only constitutes about a sixth of the hand. Its antero-posterior diameter surpasses by more than double its transverse, precisely the opposite of what obtains in the carpus. It resembles a vaulted arch, the convexity of which (*c a j*, *fig.* 56) looks upward, and which is excavated below (*d i*) both transversely and from before backward. The weight of the leg falls upon the summit of this arch. This form of the foot is not designed merely for securing the advantages derived from the mechanism of arches, but is especially intended to afford a protecting excavation for the organs which could not with impunity be compressed in standing and progression. The posterior and free extremity of the tarsus is narrow, and progressively enlarges forward.

Fig. 56.

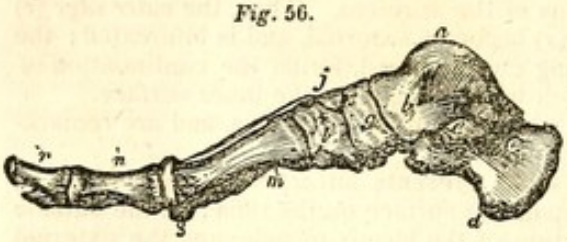

The tarsus is composed of seven bones, disposed in two rows. The *first* or *tibial row* is formed by two bones only, the *os calcis* (*c*) and the *astragalus* (*a*); the *second* or *metatarsal row* consists of five bones, viz., the *scaphoid* (*g*), the *cuboid* (*f*), and the *three cuneiform bones* (*i j l*). The bones of the first row, instead of being placed in the same transverse line, like those of the first row of the carpus, rest one upon the other. The astragalus is the only bone of the tarsus which enters into the formation of the ankle-joint.

First or Tibial Row of the Tarsus.

The Astragalus (*a*).

The *astragalus* is placed below the tibia, above the os calcis, on the inside of the malleolar extremity of the fibula, and behind the scaphoid; it is irregularly cuboid in its figure, is the second largest bone of the tarsus, and has six surfaces: 1. The *superior* or *tibial surface* (*a*, *fig.* 54) is articular, and shaped like a trochlea or pulley, which fits exactly to the lower surface of the tibia. In front and behind the trochlea are inequalities for the attachment of ligaments. 2. The *inferior* or *calcaneal surface* (*a*, *fig.* 55) presents two facettes, separated by a very deep *furrow*, running obliquely backward and inward, and broadest in front, which gives insertion to a ligament. The facette behind the groove is the larger; it is concave and oblong in the same direction as the groove. The facette in front is flat, and often divided into two smaller surfaces. Both articulate with the os calcis. 3. The *internal lateral surface* (*fig.* 56) is articular for a considerable portion of its upper part, and corresponds to the internal malleolus; below, there is a rough depression, which gives attachment to the internal lateral ligament of the ankle-joint. 4. The *external lateral surface* is triangular, like the corresponding surface of the external malleolus, with which it articulates. It should be remarked, that both the lateral articular surfaces of the astragalus are continuous with the trochlea or upper surface, without interruption. 5. The *anterior* or *scaphoid surface* is convex, and has been called the *head of the astragalus*; it is articular, and continuous, below, with the anterior facette of the lower surface of the bone already described. This head is supported by a contracted portion, or *neck* (*b*, *fig.* 54 and 56), to which ligaments are attached. 6. The *posterior surface* is very small; it consists simply of a groove, slanting downward and inward, along which the tendon of the flexor longus pollicis pedis glides.

The Os Calcis (*c*).

The *os calcis*, or *calcaneum*, situated below the astragalus, and at the lower and back part of the foot, is the largest bone of the tarsus. Its form is irregularly cuboid, with the greatest diameter from before backward; it is flattened transversely. Its size and its length have reference to the double office which it serves, of transmitting the weight of the body to the ground, and of acting as a lever for the extensor muscles of the foot. I should remark, that its large posterior extremity forms the *heel* (*d*, *figs.* 55, 56), the horizontal direction of which, in man, is one of the most advantageous arrangements for the vertical position of the body.

The os calcis has six surfaces: 1. The *superior surface* (*fig.* 54) presents, in front, two, or often three, articular facettes, which correspond with those on the lower surface of the astragalus. The posterior facette is the larger, convex, and separated from the anterior by a groove, which is shallower than the corresponding one of the astragalus, but follows the same direction backward and inward. The whole of the non-articular portion of this surface projects behind the astragalus; it is flattened on the sides, and slightly concave from before backward. Its length varies in different individuals, and is the cause of the varieties in the projection of the heel. 2. The *lower* or *plantar surface* (*fig.*

55) is rather an edge than a true surface; it is directed obliquely upward and forward. We observe here, at the back part, *two tuberosities*, the internal of which is much larger than the external; both serve as places of insertion for muscles, but their principal use is to support the weight of the body behind, and they *essentially* constitute the heel (*d*, *fig.* 56) in the human subject. 3. The *external surface* is superficial, which accounts for the frequency of injuries of this bone on its outside, and explains, also, the possibility of reaching it with surgical instruments. It is convex, and narrow in front, where it presents two superficial grooves separated by a tubercle (*s*, *figs.* 54 and 55). These grooves afford a passage to the tendons of the peroneus longus and brevis. On the anterior and superior part of this surface we find, also, another tubercle, which is a guide to the surgeon in the partial amputation of the foot recommended by Chopart. 4. The *internal surface* (*fig.* 56) is deeply grooved for the passage of several tendons, and also for the nerves and vessels which are distributed to the sole of the foot. It presents, in front and above, a projecting eminence, like a blunt hook, in a shallow groove, below which the tendon of the flexor longus pollicis pedis glides. This eminence has been called the *small process of the os calcis* (*e*, *fig.* 56), also *sustentaculum tali*, because the anterior and internal articular surface, which supports the astragalus, is on its upper part. 5. The *anterior* or *cuboid surface* is the smallest. It is concave from above downward, and articulates with the cuboid. It is surmounted on the inside by a short projection, directed horizontally forward,* above which the third articular surface for the astragalus is situated when it exists. The whole portion of the os calcis which supports the anterior or cuboid surface bears the name of *great process of the os calcis* (*t*, *figs.* 54 and 55). 6. The *posterior surface* is shaped like a triangle, with the base downward; its lower part is rough and irregular, and gives attachment to the tendo Achillis, the upper part, over which the same tendon glides, being smooth and polished like ivory.

Second Row of the Tarsus.

The bones of the second row are five in number: on the outside it is formed by the cuboid alone, but on the inside it is subdivided into two secondary rows; a posterior, formed by the scaphoid; and an anterior, composed of the three cuneiform bones. This subdivision of the inner portion of the tarsus, by multiplying the articulations, has the effect of diminishing the violence of shocks, or of pressure upon the foot, especially on the inner side, to which they are principally applied.

The Cuboid Bone (*f*, *figs.* 54 and 55).

The *cuboid*, which ranks as the third bone of the tarsus in point of size, is situated at the outside of the foot, and appears like a continuation of the great process of the os calcis. It is more regularly cuboid than any of the other tarsal bones, and has six surfaces: 1. The *upper* or *dorsal surface* (*fig.* 54) is covered by the extensor brevis digitorum pedis, and looks somewhat outward. 2. The *lower* or *plantar surface* (*fig.* 55) presents on its fore part a deep groove (*f*), running obliquely inward and forward, for the tendon of the peroneus longus. Behind this groove, the posterior lip of which is very prominent, are impressions for the ligament which connects the cuboid and the os calcis. 3. The *posterior* or *calcaneal surface* is sinuous, directed obliquely inward and backward, and adapted to the os calcis in such a way that there is a mutual reception of the surfaces of the two bones. At the inside of this surface, we observe a process which is directed inward and backward, and strengthens the union with the os calcis. It occasionally becomes an obstacle to the disarticulation of the foot, after Chopart's method. 4. The *anterior* or *metatarsal surface* looks obliquely inward and forward; it articulates with the fourth and fifth metatarsal bones. 5. The *internal surface* articulates with the third cuneiform bone, and frequently also with the scaphoid; it presents, besides, some impressions for the insertion of ligaments. 6. The *external surface* is rather an edge; its extent from before backward scarcely equals half the length of the internal surface. We observe on it the commencement of the groove for the tendon of the peroneus longus.

The Scaphoid (*g*, *figs.* 54, 55, and 56).

The *scaphoid* or *navicular bone*, so named from its supposed resemblance to a boat, is situated on the inner side of the tarsus; it is flattened from before backward, and is thicker above than below, irregularly elliptical, with the long diameter placed transversely. It has two surfaces and a circumference: 1. The *posterior surface* is concave, and receives, though incompletely, the head of the astragalus. 2. The *anterior surface* presents three articular facettes, which correspond to the three cuneiform bones. 3. The *circumference* is convex *above*, inclined inward, and rough for ligamentous insertions. It is much smaller *below*, where also it gives attachment to ligaments. On the *inside* it presents, at its lower part, a large process, *process of the scaphoid* (at *g*), which may be easily felt under the skin, and serves as a guide in performing Chopart's amputation. This process gives attachment to the tendon of the tibialis posticus. It is frequently

* This small prolongation, which might be called *small anterior process of the os calcis*, in contradistinction to the one on the internal surface already mentioned, merits notice in the performance of Chopart's operation.

very large, and may, and, indeed, has been mistaken for an exostosis of the bone. On the *outside* the circumference is irregular, gives attachment to some ligamentous fibres, and often presents a small surface which articulates with the cuboid: this surface is continuous with the facettes for the three cuneiform bones.

The Three Cuneiform Bones.

These bones, so named from their shape, are three in number: they are called *first, second,* and *third,* counting from the inside of the foot. They are also distinguished by their size, into the *great, middle-sized,* and *small.**

The First Cuneiform Bone (i, figs. 54, 55, and 56).

The *first* or *internal cuneiform* bone is the largest. It is placed on the inside of the others, in front of the scaphoid, and behind the first metatarsal bone. It is shaped like a wedge with the base below, which is precisely contrary to what obtains with the other two. We observe on it, 1. An *internal surface* (*fig.* 56), which is subcutaneous, and forms part of the inner edge of the foot. 2. An *external surface,* which presents an angular articular facette for union with the second cuneiform bone behind, and the second metatarsal bone before; the non-articular portion of the external surface of the first cuneiform bone is rough, and gives attachment to ligaments. 3. A *posterior surface,* which is concave, and articulates with the most internal and largest facette on the anterior surface of the scaphoid. 4. An *anterior* or *metatarsal surface,* which is plane, or, rather, slightly convex, of a semilunar form, the convexity being to the inside, and the greatest diameter vertical; it is broad below and narrow above, and articulates with the first metatarsal bone. 5. An *inferior surface* (*fig.* 55), which forms the base of the wedge; it is rough, with a tubercle behind for the attachment of the tibialis anticus. 6. An *upper part* (*fig.* 54), which forms the point of the wedge; it is an angular border, running forward and upward, and thicker in front than behind, where it contributes to form the convexity of the foot.

The Second or Middle Cuneiform Bone (j, fig. 54, 55, and 56).

The *second cuneiform bone* is the smallest of the three: it is placed between the two others, and corresponds to the scaphoid behind, and the second metatarsal bone in front. The wedge which it represents has the base turned upward; its length from behind forward is very inconsiderable. It presents, 1. An *internal surface,* which is triangular, and articulates with the first cuneiform bone: 2. An *external surface,* which articulates with the third or external cuneiform bone: 3. A *posterior* or *scaphoid surface,* which is concave, and articulates with the middle facette on the anterior surface of the scaphoid: 4. An *anterior* or *metatarsal surface,* which is triangular, and narrower than the posterior; it articulates with the second metatarsal bone: 5. A *superior surface* (*fig.* 54), or *base* of the wedge, which is irregularly square, and rough for the attachment of ligamentous fibres: 6. An *apex* (*fig.* 55), which is very thin, and gives attachment to some ligaments.

The Third or External Cuneiform Bone (l, figs. 54 and 55).

This bone, which is the third as regards position, and the second in point of size, has, like the preceding, the form of a wedge with the base turned upward. Its *internal surface* articulates behind with a corresponding surface on the preceding bone, and in front with the second metatarsal. This last portion completes the kind of recess or mortise into which the head of the second metatarsal bone is received; its inner side being formed by the first cuneiform bone, and the bottom by the second. The *external surface* articulates with the cuboid: the *posterior surface* is continuous with the two lateral ones, and articulates with the most external of the three facettes on the scaphoid: the *anterior surface* is triangular, and articulates with the end of the third metatarsal bone: the *base* (*fig.* 54) is rough, and forms part of the convexity of the foot: the *apex* (*fig.* 55) is more obtuse than the same part of the second cuneiform bone, and passes considerably below it.

Structure of the Bones of the Tarsus.—The bones of the tarsus present the structure common to all short bones, viz., a mass of spongy tissue surrounded by a layer of compact substance. I have remarked, that in some cases of white swelling of the ankle-joint, the os calcis contained in its interior a cavity analogous to the medullary canal of long bones. This cavity, however, must be looked upon as altogether abnormal.

Development of the Tarsal Bones.—With the exception of the os calcis, which has two osseous germs, all the bones of the tarsus are developed from single points. The os calcis first becomes ossified. A bony nodule appears in the centre of its cartilage, about the middle of the sixth month of fœtal life, according to most osteogonists; in the fifth, or even the fourth month, according to others. It is placed much nearer the anterior than the posterior extremity of the future bone. Another osseous germ is formed in the posterior extremity of the os calcis, from the eighth to the tenth year, and is much thicker at its lower than at its upper part. The astragalus is developed from one point,

* Also, by position, into *internal, middle,* and *external.*

which appears from the fifth to the sixth month of intra-uterine life. According to Béclard, the cuboid is not ossified until some months after birth; I have observed the process to be already commenced in a fœtus at the full term. Meckel says that it begins after the eighth month of fœtal life. Blumenbach, on the contrary, makes the time of its ossification a year and a half, or two years after birth; and Albinus, who has been followed in this respect by the generality of anatomists, affirms that in the fœtus at the full period, all the bones of the tarsus, excepting the os calcis and the astragalus, still remain cartilaginous.

The cuneiform bones are developed in the following order: The first is ossified towards the end of the first year; the second and the third appear almost simultaneously about the fourth year; the os calcis being the only bone of the tarsus which has more than one point of ossification, is also the only bone in which we have to examine the order of union. The two points which form it are not united until the fifteenth year.

The Metatarsus (*m m'*, *figs.* 54, 55, and 56).

The metatarsus forms the second portion of the foot. Like the metacarpus, its analogous part in the hand, it consists of five long bones, parallel to each other, forming a sort of quadrilateral grating, the intervals of which, called *interosseous spaces*, are increased by the disproportion between the ends and the shafts of the bones. The metatarsus presents, 1. An *inferior* or *plantar surface* (*fig.* 55), with a marked transverse concavity; 2. A *superior* or *dorsal surface* (*fig.* 54), which is convex, and answers to the back of the foot; 3. An *internal* or *tibial edge* (*m'*, *fig.* 56), which is very thick, and corresponds to the great toe; 4. An *external* or *fibular edge*, which is thin, and corresponds to the little toe; 5. A *posterior* or *tarsal extremity*, which presents a waved articular line; 6. An *anterior* or *digital extremity*, presenting five heads flattened on the sides, which assist in forming five separate articulations. The bones of the metatarsus have certain characters which distinguish them from all others, besides some peculiar marks by which they may be known from each other, and from the metacarpal bones, with which they have many analogies.

General Characters of the Metatarsal Bones.

The metatarsal bones belong to the class of long bones, both in shape and structure. Each consists of a *body* and *two extremities*. The *body* is prismatic and triangular, and slightly curved, with the concavity below. Two of its surfaces are lateral, and correspond to the interosseous spaces; the third, so narrow that it resembles an edge, is on the dorsum of the foot. Two of the edges are lateral; the third is below, on the plantar aspect of the foot.

The *posterior* or *tarsal extremity* is much expanded, and presents five surfaces, *two of which are non-articular*, and *three articular*. Of the two non-articular surfaces, one is superior, and the other inferior; both give attachment to ligaments. Of the three articular surfaces, one is posterior, that is, on the extremity of the bone; in general it is triangular, and articulates with a corresponding surface on one of the tarsal bones. The other two are lateral, partly articular, and partly non-articular. The articular surfaces are small, and often consist of more than one; they join the contiguous metatarsal bones. The tarsal extremity is wedge-shaped; the upper or dorsal surface being very broad, represents the base of the wedge; the lower surface, being narrow, forms the point.

The *anterior* or *digital extremity* presents a head or *condyle*, flattened on the sides, and oblong from above downward; the articular surface extends much farther on the lower aspect, or in the direction of flexion, than on the upper, or the direction of extension. On the inside and outside of the condyle there is a depression, and a projection behind it for the lateral ligament of the joint.

Characters of the different Metatarsal Bones.

The *first* or *metatarsal bone* of the great toe (*m'*, *figs.* 54, 55, 56) is remarkable for its great size. It is the only one which, in this respect, resembles the tarsus; *its body* is shaped like a triangular prism; its *digital extremity* is marked on the plantar aspect by a double furrow for two sesamoid bones (*s*, *fig.* 56). (Vide *Articulation of the Foot.*) Its tarsal extremity presents a semilunar concave surface, with its greatest diameter vertical, which articulates with the internal cuneiform bone. There is no articular surface on the circumference of the first metatarsal bone. In this point it resembles the first metacarpal bone, and by this and its great size it is distinguished from all the others.

The *fifth metatarsal bone* (*m*, *fig.* 54, 55) is the shortest after the first; it has only one lateral articular face on its tarsal extremity. On the opposite side of this extremity, viz., on the outside, we observe a large process, *process of the fifth metatarsal bone*, shaped like a triangular pyramid, and directed obliquely backward and outward, into which the peroneus brevis is inserted. This process may be easily felt under the skin, and serves as a guide in the partial amputation of the foot at the tarso-metatarsal articulation. Another characteristic of the fifth metatarsal bone is the great obliquity outward and backward of the articular face on its posterior extremity.

The second, third, and fourth metatarsal bones are distinguished from each other by the following characters.

The *second* is the longest, and also the largest after the first; it articulates with the three cuneiform bones by its posterior extremity, which is dovetailed with them. The *third* and the *fourth metatarsal bones* are of almost equal length; their apparent difference in an articulated foot depends chiefly on the fact that the articulation of the fourth with the cuboid is on a plane posterior to that of the third with the external cuneiform bone. Lastly, they may be known from each other by the presence of two surfaces, on the inside of the posterior extremity of the fourth metatarsal; one being for the external cuneiform bone, and the other for the third metatarsal bone.

Development.—The metatarsal bones are developed from two points; one for the body, and one for the anterior or digital extremity. The first metatarsal bone is the only exception to this rule, for its epiphysary point is situated at the posterior extremity.* The osseous point of the body appears first during the third month, according to the majority of authors, but about the forty-fifth day, according to the observations of Blumenbach and Béclard. It is completely developed in the fœtus at the full period. The epiphysary point makes its appearance during the second year. The union of these parts does not take place until the eighteenth or nineteenth year, and is not simultaneous in all the bones of the metatarsus. The epiphysis of the first metatarsal bone is the first to unite with the body. An interval of a year sometimes intervenes between the union of this epiphysis and those of the other four metatarsal bones.

The Toes (*n o r, n r, figs.* 54, 55).

The resemblance between the phalanges of the fingers and those of the toes is so complete, that we cannot do better than refer to the description already given of the former for details respecting the latter. At the same time, it should be remarked, that the phalanges of the toes appear, as it were, atrophied, or stinted in growth, when compared with those of the fingers, excepting the great toe, which, in all its parts, preserves the large dimensions of the inner side of the foot.

The *first* or *metatarsal phalanx* (*n* to *n'*) resembles closely the metacarpal phalanx of the fingers. The *middle phalanx* (*o*) is remarkably small and short; it would almost appear to consist of the extremities alone, the body being absent. At first sight it might be taken for a pisiform bone, or, rather, for one of the pieces of the coccyx; but the presence of anterior and posterior articular faces is sufficient to mark the distinction.

The *ungual phalanges* (*r r'*) of the toes resemble in form, but are much smaller than the corresponding parts of the fingers. This remark, however, only applies to the last four, for the ungual phalanx of the great toe is in size at least double that of the thumb. I cannot conclude this description without remarking, that the articular surface of the posterior extremity of the metatarsal phalanges, as well as of the anterior extremity of the metatarsal bones, is prolonged farther upward than the corresponding surfaces on the metacarpal bones and phalanges of the fingers; this arrangement allows a greater extension of the toes, and is an important element in the mechanism of progression.

Development.—The first, second, and third phalanges are developed from two points of ossification; one for the body, and one for the metatarsal extremity. The epiphysary points of the second and third phalanges are so small, that their existence has been doubted by many anatomists. The osseous points of the bodies of the first phalanges are much later in appearing than those of the metatarsal bones, not being visible, in general, until from the second to the fourth month; the first phalanx of the great toe is an exception, its ossification commencing from the fiftieth to the sixtieth day. The epiphysary point of the first phalanges does not appear until the fourth year. The bodies of the second phalanges are ossified almost at the same time as those of the first; the epiphysary point of their posterior extremity is not visible until from the sixth to the seventh year. The bodies of the third phalanges are ossified before those of the second and the first; an osseous point appears in them about the forty-fifth day, excepting in the little toe, where it is much later. The ungual phalanx of the great toe is remarkable as being ossified before all the other phalanges of the toes. It is developed from a point which does not occupy the centre, but the summit of the phalanx. The epiphysary point of the posterior extremity appears about the fifth year in the great toe, and about the sixth year in the other four. The epiphysary points of the phalanges are nct united to the bodies until the age of seventeen or eighteen years.

General Development of the Inferior Extremity.

The most characteristic feature of the lower extremity in the fœtus is the comparative lateness of its development, which is most remarkable at the early periods. We have

* This exception corresponds entirely with that observed in the hand, and renders the analogy between the metatarsal bone of the great toe and the metacarpal of the thumb extremely close; for the same reason, both of these bones resemble the first phalanges of the fingers. I may add, that, in some subjects, it has appeared to me that there was a very thin epiphysary point at the digital extremity of this bone, which soon united to the body

already stated the periods at which each point of ossification appears in the different bones, and the times at which they are united, and it now only remains for us to point out some peculiarities of development which have not been included in the description of the bones.

From the observations of Bichat, it is generally admitted that the neck of the femur in the fœtus and the newly-born infant is proportionally shorter than in the adult, and forms almost a right angle with the shaft of the bone; that the body of the femur is almost straight; and that its extremities are proportionally much larger than they become subsequently. As we before observed with regard to the upper extremities, all these assertions are at variance with the results of our observations. The same reflections apply equally to the bones of the leg, the torsion of which we believe to exist to the same degree in the fœtus and in the new-born infant as in the adult.

After birth, the development of the lower limbs proceeds more rapidly than that of the upper, and the final proportions are not attained until the age of puberty. In the aged, the phalanges of the toes are often anchylosed; but this union, like the dislocations of the toes, and some deformities of the tarsus and metatarsus, are the results of pressure upon the foot occasioned by tight shoes, and the more or less complete immobility in which the parts are maintained.*

Comparison of the Superior and Inferior Extremities.

We have hitherto omitted the applications of that species of comparative anatomy by which different organs of the same animal are compared with one another. Those analogies which exist between the various parts that compose the trunk could not, with propriety, be included in a work on descriptive anatomy. But we do not deem it proper to apply the same rule to the parallel between the upper and lower extremities; for that is founded on such numerous and striking points of analogy, and has become so much a subject of instruction, that we should consider it a serious omission did we here neglect giving a brief notice of it.

The upper and the lower extremities are evidently constructed after the same type, but present certain modifications corresponding to the difference of their functions. I should remark in this place, that some of these analogies are very manifest and satisfactory, and greatly facilitate the remembrance of important anatomical details; while others are far-fetched, and wholly destitute of useful application: these will be passed over with a simple notice. We shall now compare in succession the shoulder and the haunch, the humerus and the femur, the forearm and the leg, the hand and the foot.

Comparison of the Shoulder and the Pelvis.

Before the time of Vicq-d'Azyr, anatomists were in the habit of considering the clavicle and the scapula among the bones of the upper extremity, but regarded the os innominatum or haunch as belonging to the trunk; and yet the most simple reflection is sufficient to establish the analogy between the shoulder and the haunch. In order the more readily to appreciate the points of resemblance and difference between these parts, it is advisable to follow the method adopted by Vicq-d'Azyr, of studying the shoulder reversed; or, what is the same thing, to compare the aspect of the shoulder which corresponds to the head, with that of the pelvis which answers to the coccyx; remembering, at the same time, that, for a long period after birth, the haunch bone is formed of three distinct pieces, the ilium, the ischium, and the pubes.

1. The shoulders form an osseous girdle, intended to form a point of support for the upper extremities, in the same manner as the haunch does for the lower extremities. The girdle formed by the shoulders is interrupted in front in the situation of the sternum, and behind, opposite the vertebral column; hence there are two shoulders, while the haunch bones constitute one united whole. The shoulder, therefore, and, consequently, the arm of one side, are completely independent of those of the other, but the two lower extremities have a solid bond of union.

2. The second point of difference relates to the comparative dimensions of the pelvis and the shoulder. The great size of the pelvis, the thickness of its edges, the depth of its notches, and the prominence of its eminences, contrast strongly with the slender construction of the shoulder, and the thin edges of the scapula, and are in harmony with the uses of the lower extremities.

3. The broad portion of the scapula is analogous to the iliac portion of the os innominatum; the internal iliac fossa is analogous to the subscapular fossa.

4. The supra and infra-spinous fossæ correspond to the external iliac fossa; but the ilium has no part analogous to the spine of the scapula.

5. The axillary border of the scapula answers to the anterior edge of the os innominatum. The spinal border is analogous to the crest of the ilium. The superior border

* On this subject the reader may consult a very curious memoir, by Camper, on the inconveniences arising from tight shoes, to which he attributes, 1. The shortening of the second toe; 2. The partial luxation of some of the tarsal bones. To this we may add the luxation, outward, of the first phalanx of the great toe; and the luxation, inward, of the first phalanx of the second, and sometimes of the third toe.

of the scapula corresponds to the posterior border of the os innominatum; and the coracoid notch on this border, with the coracoid ligament which converts it into a foramen, are analogous to the sciatic notch, and the sacro-sciatic ligaments.

6. The glenoid cavity is evidently analogous to the acetabulum; according to Vicq-d'Azyr, the coracoid and the acromion processes are represented by the tuberosity of the ischium and the pubes, with this remarkable difference only, that the two processes of the shoulder are separated from each other by the large acromio-coracoid notch, while in the pelvis the ischium and the pubes are united, and, instead of including a notch, form the circumference of a foramen, the obturator. This analogy is not universally admitted; for the ischium, being intended to sustain the weight of the body when sitting, bears no resemblance in this respect to the shoulder. One of the most striking analogies between the shoulder and the pelvis is that of the clavicle and the horizontal portion of the pubes; with this difference, that the clavicle is articulated with the scapula, while the pubes is united by bone to the ilium. Without forcing an analogy, we may trace a similitude between the symphysis pubis, and the union of the clavicles by means of the interclavicular ligament.

Comparison of the Arm Bone and the Thigh.

In order to make the parallel exact, we must remember the relative situation of these two bones, and compare the right femur with the left humerus; and the side of flexion, that is, the posterior aspect of the first, with the side of flexion, or the anterior aspect of the second. This being determined, we must place the linea aspera of the femur in front, and the humerus in its natural position. The humerus is much smaller than the femur, being about a third shorter, and only half the weight and bulk. The humerus is placed vertically, and almost parallel to the axis of the trunk; in this it contrasts with the marked obliquity of the thigh bones, which touch each other at their lower ends. The humeri are separated from each other by a greater distance than the femora; this difference depends on the conformation of the human thorax, which is flattened in front and behind, while in quadrupeds it is flattened on the sides, and permits the approximation of the humeri, which serve as pillars of support to the fore part of the trunk.

The humerus is not curved like the femur, but, on the other hand, it is much more twisted, and presents an oblique groove, which does not exist in the femur. We shall compare in succession the shafts and the extremities of these bones.

1. *Comparison of the Shafts.*—The posterior surface of the humerus exactly corresponds to the anterior surface of the femur, being, like it, smooth and rounded. The external surface resembles the external plane of the femur, with some differences; the impression for the gluteus maximus is evidently analogous to the deltoid impression. The internal surface is in contact with the brachial artery, as is the internal surface of the femur with the femoral artery. The anterior edge is a sort of linea aspera, analogous to that of the femur, and, like it, terminating by a bifurcation at its upper part.

2. *Comparison of the Lower Ends of the Bones.*—Although the differences between these parts are very marked, we can yet detect, in the one bone, traces of all the more important points of structure observed in the other. Thus, the internal and external tuberosities of the humerus evidently resemble those of the femur, and they are both intended for the insertion of muscles and ligaments. The trochlea of the humerus resembles that of the femur, with this difference, that, in the femur, the two borders of the pulley diverge from each other behind, while in the humerus they are parallel throughout. In front and behind the femoral trochlea, we find depressions, which are manifestly analogous to the coronoid and olecranal fossæ of the humeral trochlea. Lastly, without admitting any fundamental difference, we may explain the existence of the small head of the humerus, for which there is no representative in the femur, by a reference to the fact, that both bones of the forearm unite with the humerus, while only one bone of the leg articulates with the femur.

Comparison of the Upper Ends.—As in the femur, we find in the humerus a segment of a spheroid, or a head, supported by a neck, of which, however, there is only a trace; and two tuberosities, which are analogous to the trochanters, and, like them, give attachment to the rotator muscles of the limb. In the humerus, however, the two processes are much more closely approximated, being only separated by the bicipital groove. Lastly, the great tuberosity of the humerus causes the prominence of the shoulder, in the same manner as the great trochanter causes the prominence of the hip.

Comparison of the Leg and Forearm.

The forearm is that portion of the upper extremity which is represented by the leg in the lower. Each is composed of two bones; but while the leg is essentially constituted by the tibia, which alone enters into the formation of the knee-joint, and the greater part of the ankle-joint, both the radius and the ulna contribute, almost in an equal degree, to that of the forearm; and although the ulna forms the greater part of the elbow-joint, the radius, by a sort of compensation, is the chief bone of the wrist-joint.

Although the general analogy between the forearm and leg is sufficiently striking, it is

not so easy to trace the corresponding parts in detail. Anatomists are much at variance on this subject, particularly as to which bone of the forearm corresponds to the tibia.

Vicq-d'Azyr, from a consideration of the elbow and the knee joints, came to the conclusion that the ulna is analogous to the tibia, and the radius to the fibula. M. de Blainville, on the contrary, reflecting on the relations between the leg and foot, and the forearm and hand, and considering that the tibia is placed on the same line with the great toe, and the radius with the thumb, and also that in the forearm the radius constitutes the chief part of the wrist-joint, and that in the leg the tibia is most concerned in the ankle-joint, is of opinion that the tibia and the radius are analogous parts.

We shall adopt what is true in either opinion, and reject what appears to us too unconditionally stated or incorrect; and, therefore, considering, 1. That neither of the bones of the leg resembles, by itself, one of the bones of the forearm; 2. That each bone of the leg has some characters, both of the ulna and of the radius; 3. That the natural position of the forearm being that of pronation, and that the leg being in a state of constant pronation, it is incorrect to compare the forearm when supinated with the leg when in the opposite position; 4. That comparative anatomy has shown, in ruminating animals, the upper extremity of the ulna to be blended with the radius, and a slender process on the external aspect of the forearm resembling the fibula, we are inclined to believe that the upper end of the tibia is represented by the upper half of the ulna, and the lower half of the tibia by the lower half of the radius; while the fibula is represented by the upper part of the radius and the lower part of the ulna. If we enter into details, we shall see how plausible this comparison is in reality.

Comparison of the Upper Half of the Ulna and the Upper Half of the Tibia.

The horizontal portion of the great sigmoid cavity of the ulna is represented by the upper end of the tibia, and the crest which separates the two surfaces of the cavity is analogous to the spine of the tibia. The patella and the olecranon are constructed after the same type; the mobility of the first, and the fixture of the last, are not essential differences. The body of the ulna is prismatic and triangular, like that of the tibia; its internal surface is superficial and almost subcutaneous, like the anterior surface of the tibia; its posterior edge (crest of the ulna) is prominent, and represents the crest of the tibia; it is equally superficial, and serves as a guide in the diagnosis and coaptation of fractures. As in the tibia, the crest of the ulna is continuous with a triangular tuberosity, which may be called the posterior tuberosity of the ulna, and is analogous to the anterior tuberosity of the tibia.

Comparison of the Lower Part of the Radius and the Lower Part of the Tibia.

The quadrangular lower end of the radius corresponds to the equally quadrangular lower extremity of the tibia. The inferior articular surface of both is divided into two parts, by an antero-posterior ridge. The ulnar side of the lower end of the radius is hollowed into an articular cavity, in the same way as the fibular side of the lower end of the tibia. The styloid process of the radius answers to the internal malleolus of the tibia. Both extremities exhibit furrows for the passage of tendons.

Comparison of the Hand and Foot.

The back of the foot corresponds with the back of the hand, the sole with the palm, the tibial edge of the one with the radial edge of the other; the fibular and the ulnar borders are analogous; the tarsal extremity of the foot corresponds with the carpal extremity of the hand, and each has a digital extremity. But amid these features of resemblance, which are sufficient to establish the old adage, *pes altera manus*, we find also great differences. Thus the foot exceeds the hand both in size and weight, being longer and thicker, though it is narrower: this excess of volume does not affect the toes, which are incomparably smaller than the fingers; nor the metatarsus, but is confined to the tarsus, of which the carpus seems little more than a vestige. A second characteristic difference is the absence of the power of opposition in the great toe. As far as regards function, indeed, it may be truly said, that the want of this power constitutes a foot, and the possession of it a hand. A third difference results from the mode of articulation of the leg with the foot, for the leg does not articulate with the posterior extremity of the tarsus, but with its upper surface, so that a part of the tarsus projects behind the joint, and the axis of the foot forms a right angle with that of the leg. These remarks will suffice to show the general differences between the hand and the foot.

Comparison of the Bones of the Carpus and Tarsus.

While the carpus scarcely forms the eighth part of the hand, the tarsus constitutes half the foot. Its antero-posterior diameter, which is five or six inches, is three times greater than the transverse diameter, precisely contrary to what is the case in the hand. The tarsus resembles a vault, concave below, both in the antero-posterior and transverse directions, and receives the leg upon its summit. The carpus is nothing more than a groove for tendons. It is manifest that the carpus is only the rudiment of the tarsus, which is not surprising, if we consider that the former is truly the fundamental part of

the foot, and the basis of support to the whole body. We shall examine in detail the analogies and the differences of these two constituent parts of the foot and the hand. They differ in the following respects: 1. There are eight bones in the carpus: there are only seven in the tarsus. 2. Each of the two rows of the carpus is composed of four bones: the first row of the tarsus consists of two bones, and the second of five; 3. The bones of the first row of the tarsus are placed one above the other, not arranged side by side as in the first row of the carpus. 4. One tarsal bone only enters into the formation of the ankle-joint, while three of the carpal bones are concerned in the wrist-joint: lastly, the second row of the tarsus is subdivided into two secondary rows on the inside, a posterior, formed by the scaphoid, and an interior, formed by the three cuneiform bones.

We shall now compare the bones of these two regions, and for the want of their resemblance in shape, we shall have recourse to that of their mode of connexion—a method which is, perhaps, more constant and important than that which is founded upon a character so variable as figure.

Comparison of the Metatarsal Row of the Tarsus with the Metacarpal Row of the Carpus.

The metatarsal and the metacarpal rows are evidently more analogous to each other than the first rows of each region, and have, therefore, been chosen for the purpose of establishing the parallel.

1. The cuboid is manifestly analogous to the os unciforme; their relative positions are the same; their forms are, in a great measure, similar; and while the cuboid is attached to the last two metatarsal bones, the os unciforme articulates with the last two metacarpal. This analogy being admitted, we shall find in the three cuneiform bones the representatives of the three other bones of the second row of the carpus, viz., the trapezium, the trapezoid, and the os magnum.

2. We must admit here that the analogies now become much less evident. Nevertheless, the third cuneiform bone, which, from being in contact with the cuboid, should represent the os magnum, which is contiguous to the os unciforme, does so far agree, that it articulates with the third metatarsal bone, as the os magnum does with the third metacarpal; and, what is sufficiently remarkable, the third cuneiform has a slight connexion with the second metatarsal, as the os magnum has with the second metacarpal. Although, therefore, we do not find in the third cuneiform bone anything approaching to the size of the os magnum, or resembling the remarkable head of that bone, we should not, on that account, hastily conclude that they have no analogy. We shall explain afterward how this fact should be interpreted: we only wish it to be admitted in this place, that the base or metacarpal portion of the os magnum is represented by the third cuneiform bone.

3. The second cuneiform bone, which corresponds to the trapezoid, supports the second metatarsal, as the trapezoid supports the second metacarpal.

4. The first cuneiform bone, which supports the first metatarsal, corresponds to the trapezium, which supports the first bone of the metacarpus. All these analogies, it must be confessed, are very imperfect, and founded rather upon the connexions than the forms of the different bones. In fact, what resemblance is there between the three large cuneiform bones all cut into facette-like wedges, and all so like each other in shape, and the bones of the carpus, to which we have compared them? Above all, what comparison can be established between the third cuneiform, which exactly resembles a wedge, and the os magnum, which has a rounded head? There is nothing in the metatarsal range of the tarsus which represents the rounded head which belongs to the metacarpal row of the carpus; but the following considerations, which did not escape the notice of Vicq-d'Azyr, will serve to solve the difficulty.

1. It is an observation which applies with sufficient generality to the whole skeleton, that when two bones move upon each other, one being provided with a head, and the other with a cavity, the head moves upon the cavity, not the cavity on the head. Thus, the femur moves upon the os innominatum; the humerus upon the scapula. 2. The hand, in the performance of its functions, almost always moves upon the forearm. In the movements of the hand, the metacarpal row of the carpus moves upon the first row, and therefore the metacarpal row presents the head. On the contrary, in the movements of the bones of the tarsus during progression, the bones of the first row always move upon those of the second or metatarsal row; and consequently, instead of finding a rounded head in the second row, we meet with it in the first.

Proceeding thus by the method of exclusion, it now only remains for us to establish the analogy between the bones of the first row of the carpus on the one hand, and the scaphoid, the os calcis, and astragalus on the other. The analogies here are very equivocal, and are not agreed upon among anatomists.

Comparison of the First Row of the Tarsus with the First Row of the Carpus.

As there are only three bones in the posterior row of the tarsus which correspond to the antibrachial or superior row of the carpus, it might be supposed, *à priori*, that one of these would correspond to two of the bones of the first row of the carpus. A very slight

examination of the tarsus and the carpus in a quadruped will show at once that the pisiform bone is represented by that part of the os calcis which projects behind the astragalus. The os calcis is the only bone of the tarsus which is developed from two points; and this establishes a strong presumption in favour of the opinion that it represents two bones. If we admit the analogy of the back part of the os calcis with the pisiform bone, the anterior portion of this bone would represent the cuneiform or pyramidal bone of the carpus; and as this last articulates with the os unciforme, so the anterior portion of the os calcis unites with its representative, the cuboid. The os calcis, then, may be considered as representing the cuneiform and the pisiform bones blended together, and much augmented in size.

It remains, then, to establish the analogy between the scaphoid and semilunar bones of the hand, and the astragalus and scaphoid of the foot.

The scaphoid of the hand resembles the scaphoid of the foot, both in form and connexions. The similarity of shape has led to the identity of name; and, with regard to connexions, we find that the scaphoid of the foot is attached to the three cuneiform bones, and that of the hand to the trapezium, the trapezoid, and the os magnum, which represent the three cuneiform bones; and, lastly, we observe that the scaphoid bone of the foot is placed on the same side as the great toe, and that the scaphoid bone of the hand is placed on the same side as the thumb. There is, however, one remarkable difference between them, viz., that the scaphoid bone of the hand articulates with the forearm, while that of the foot has no connexion with the leg.

We have now only to discover in the tarsus the representative of the semilunar bone. All the rest of the bones being now excluded, we can only conclude, with Vicq-d'Azyr, that the astragalus is its counterpart, with the mere addition of a rounded head.

Comparison of the Metacarpus and the Metatarsus.

Five small long bones, arranged parallel to each other, form both the metacarpus and the metatarsus. In both there are four interosseous spaces: these are larger in the hand than in the foot, because there is a greater disproportion between the bulk of the extremities and shafts of the metacarpal than of the metatarsal bones: the metacarpus, from being shorter, appears broader than the metatarsus. The most distinguishing character of the metacarpus is the fact, that the metacarpal bone of the thumb is the shortest of the whole, and is situated on a plane anterior to the others, and that its direction is oblique, all which circumstances bear reference to the movement of opposition, which is peculiar to the hand. The characteristic mark of the metatarsus is the size of the first metatarsal bone, which greatly exceeds that of all the others. The great size of the tarsus is continued in this bone and the great toe, on account of the important part they perform in the mechanism of standing. There is so great a resemblance between the other metacarpal and metatarsal bones, that some attention is necessary in order to distinguish between them. 1. The metatarsal bones gradually diminish in size from their tarsal to their digital extremities; the metacarpal bones, on the contrary, are most expanded at their digital ends. The metacarpal are shorter and thicker; the metatarsal longer and more slender. The shaft of the metacarpal bones is pretty regularly prismatic and triangular; that of the metatarsal, on the contrary, is compressed or flattened on the sides. 2. There are no well-marked differences between the carpal extremities of the metacarpal bones and the tarsal extremities of the metatarsal; but the latter are larger than the former, which agrees with the greater dimensions of the tarsus. 3. The tarsal extremities are more regularly cuneiform than the corresponding ends of the metacarpal bones.

The most characteristic differences, however, of these two series of bones are found in the digital extremities, which are incomparably larger in the metacarpus than in the metatarsus, the fingers being the chief part of the hand, while the tarsus is the principal portion of the foot. We should also remark, that the convex articular surfaces of the digital ends of the metatarsal bones are prolonged farther on the dorsal aspect than the corresponding surfaces of the metacarpal bones.

Comparison of the Phalanges of the Fingers and Toes.

The fingers, being the essential organs of prehension and the fundamental part of the hand, greatly exceed the toes both in length and thickness, and the latter may be looked upon as representing in rudiment the former, being precisely analogous in structure.

The phalanges of the toes may, therefore, be regarded as phalanges of the fingers in a state of atrophy; but the great toe forms a remarkable exception to this rule, for its phalanges are much larger in proportion to the other toes than the phalanges of the thumb are to the other fingers. This magnitude of the great toe corresponds to the size of its metatarsal bone, and accords with its destination, as constituting the principal support for the weight of the body in front. The first phalanx of the toes exactly resembles the first phalanx of the fingers in all things but volume. The middle phalanx of the toes can scarcely be recognised, from its diminutive size: it may be said to want the shaft altogether, the extremities being in contact. As we have already remarked, it might at

first sight be confounded with a pisiform, or a sesamoid bone, or still more readily with a piece of the coccyx.

Comparison of the Upper and Lower Extremities with regard to Development.

The development of the lower extremities is proportionally less rapid than that of the upper. The clavicle and the scapula are ossified before the os innominatum. The ossification of the skeleton commences in the clavicle; in this bone, the osseous nodule is visible from the twenty-fifth to the thirtieth day; it appears in the scapula about the fortieth day. The osseous point of the ilium is visible about the forty-fifth day, that of the ischium in the third month, and that of the pubes in the fifth month. The scapula is completely ossified at the age of twenty years; the marginal process of the crest of the ilium is scarcely united until the twenty-fifth year. The bony centres of the shafts of the femur and humerus are almost simultaneous in their appearance. The germ of the lower end of the femur always exists at birth; that of the lower end of the humerus does not appear until the end of the first year; but this latter unites with the bone at eighteen years, while the former is still separate at twenty years. The tibia is ossified a little before the bones of the forearm, the fibula a little after them. The ossification of the leg and the forearm is completed almost about the same time. The ossification of the bones of the tarsus precedes that of the carpus by a considerable period. Thus, at from four and a half to five months of fœtal life, a bony point is visible in the os calcis, and some days after in the astragalus; the os magnum and os cuneiforme (which, however, are not the representatives of the preceding) do not show ossific points until a year after birth. The pisiform bone is not ossified until the twelfth year; while the latest of the tarsal bones, the scaphoid, is converted into bone at the fifth year. Nevertheless, the epiphysary point of the os calcis (which we have shown to be analogous to the pisiform bone) does not become visible until the tenth year; this fact strengthens the analogy between the pisiform bone and the epiphysary lamina of the os calcis.

The metatarsal bones are developed in exactly the same manner as the metacarpal, only at a somewhat later period. The union of the epiphyses takes place a little earlier in the metatarsus than in the metacarpus. The toes are ossified at a later period than the fingers; especially the ungual and the second phalanges, which are much later than those of the fingers.

It is, no doubt, impossible to state the precise reason for these differences; but it is sufficient to find a positive relation between the rate of development of these parts, and the offices they are intended to fulfil.

The Os Hyoides, or the Hyoid Apparatus (fig. 57).*

The *os hyoides* has a parabolic form, resembling the upsilon of the Greeks, whence its name. It is the only bone which is detached from the rest of the skeleton; it is connected only by ligaments and muscles, and is situated between the base of the tongue and the larynx. It is larger in the male than in the female. It is placed almost horizontally, the concavity of its curve looking backward, and the convexity forward.

Fig. 57.

This bone is divided into five parts; viz., *a body* or middle part (*a*), and *four cornua*, two large (*b*) and two small (*c*). This multiplicity of parts, which is much greater in some animals, especially fishes, justifies the name of "*hyoid apparatus*," which we have adopted.†

The *body of the os hyoides* (*a*) is quadrilateral, elongated, and curved, with the cavity behind. Its *anterior surface* looks upward, and presents a crucial projection, the vestige of a process which in many animals is prolonged into the substance of the tongue. This projection gives attachment to several muscles, the insertions of which are marked by transverse lines, interrupted by tubercles. The *posterior surface*, more or less excavated in different individuals, is sometimes connected with a yellow cellular tissue, which separates it from the epiglottis, and is sometimes covered by a synovial membrane. Its excavation, which is never very great in man, is the vestige of the enormous cavity which exists in the hyoid of the Howler monkey. The *lower edge* gives attachment to the thyro-hyoid muscle only. The *upper edge* gives insertion to a yellow membrane, a sort of ligament which stretches into the tongue; and also to the yellow thyro-hyoid ligament, which has been incorrectly stated to be inserted into the lower edge of the bone. The *extremities* of the body of the os hyoides are covered by cartilage for articulation with the great cornua.

The *great cornua* or *rami* (*b*) are much longer than the body, and flattened above and below, while the body is compressed from before backward. They are expanded at the place where they articulate with the body, pass backward, and, after being contracted

* I have introduced the description of the os hyoides into this place, because, although chiefly belonging to the tongue, it gives attachment to several muscles, and, therefore, should be previously known to the student.

† Vide M. Geoffroy Saint-Hilaire, on the anterior bones of the chest.—(*Philos. Anat.*, vol. i., p. 139.)

and flattened, terminate in a rounded tubercle, which is sometimes surmounted by an epiphysis.

The *little cornua* (*c*) are called also *styloid cornua*, because they are connected with the styloid process by means of a ligament. They are two pisiform nodules at the point of junction of the great cornua with the body of the hyoid (*ossa pisiformia lingualia* of Sœmmering). They surmount the upper edge of the bone, and are directed upward and outward; their length is very variable. In the lower animals, the prolongations which correspond to these little cornua are much longer than the great cornua in man. They articulate by their lower end with the body and the great cornua. Their upper part gives attachment to a ligament, which unites it with the styloid process. This ligament, which is sometimes ossified in man, is always a bony connexion in the lower animals.*

Internal Structure.—The hyoid bone is composed chiefly of compact tissue; but there is a small quantity of spongy tissue in the thick parts of the body and the great cornua.

Development.—The os hyoides is developed from five points; one for the body, two for the great cornua, and two for the little cornua. Some anatomists admit two points for the body, and make the whole number six.

The ossification of the great cornua precedes that of the body, which becomes bony soon after birth; the little cornua are not ossified until some months after. All the pieces are at first separated by considerable portions of cartilage, afterward by a very thin layer, which sometimes remains during life, and gives the different parts of the bone a great degree of mobility.

THE ARTICULATIONS, OR ARTHROLOGY.

General Observations.—Articular Cartilages.—Ligaments.—Synovial Membranes.—Classification of the Joints.—Diarthroses.—Synarthroses.—Amphiarthroses, or Symphyses.

The bones are united together by the *joints* or *articulations*. The study of these parts is the object of *syndesmology*, or, more properly, of *arthrology* (ἄρθρον, a joint). In examining each joint, it is necessary to consider, 1. The contiguous surfaces of the bones, or the *articular surfaces*; 2. The uniting medium, or the *ligaments*; 3. The means or conditions which facilitate the motion of the parts, the *synovial membranes*; and, 4. The movements of which the joint is capable.†

It is impossible to insist too much upon the importance of a careful study of the articulations. There is no part of anatomy a thorough knowledge of which is more indispensable both to the physiologist and the surgeon; without it the former cannot form a correct idea of the animal mechanism, nor can the latter appreciate the nature of those numerous injuries and diseases of which the articulations are the seat.

Before describing the forms and the motions of the different joints, it is necessary to give a general idea of the articular cartilages, the synovial membranes, the ligaments, &c.; in short, of all the means which contribute to secure the solidity and mobility of the articulations.

The Articular Cartilages.

It has been observed,‡ that when two osseous surfaces in immediate contact rub upon each other, they are gradually absorbed in such a manner as to render the movements between them difficult and painful. In order to avoid these injurious effects in the joints, the contiguous surfaces of the bones are covered by a layer of cartilage (the *incrusting* or *articular cartilage*), a substance which unites in itself the qualities of solidity, pliability, and elasticity in a high degree, yielding when compressed, and returning to its former state when the pressure is removed. These articular cartilages exist in all the movable joints. The extent of surface which they cover is generally proportioned to the extent of motion in the joints. Their thickness is generally greatest when the bones which they cover are most movable, and most subjected to pressure. An articular cartilage is not of uniform thickness throughout. Thus, on convex surfaces, the cartilaginous layer is thicker in the centre than at the circumference; and, on the other hand, the cartilages of articular cavities are thickest at the circumference. The most perfect coaptation results from this arrangement. It should also be remarked, that the most violent shocks are applied to the centre of the heads of the bones, and to the circumference of the cavities.

The articular cartilages present, 1. A *free surface*, perfectly smooth and polished, which is in the interior of the articulation; 2. An *adherent surface*, which is so closely attached

* In the lower animals, the styloid process is detached from the cranium, and forms one of the hyoid chain of bones, which is composed, 1. Of the five pieces of the os hyoides; 2. Of the bones which supply the place of the styloid ligaments; 3. Of the styloid processes, or, rather, bones: nine pieces in all.

† Three of these, viz., the configuration of the articular surfaces, the ligaments, and the movements of the joint, are essentially related to each other; so that we may deduce, *à priori*, the means of union, and the movements of any joint, from the shape of the articular surfaces, and *vice versâ*.

‡ Absorption of the cartilages is a frequent disease of the joints, and obliges the individuals affected by it to maintain constant rest.

to the tissue of the bone, that it is impossible to separate it excepting in cases of disease. In some cases of white swelling, I have been able to remove the articular cartilages with great facility, and in these it appeared that the adherent surface of the cartilage was very irregular, and that the fibres of the bone were implanted in it by innumerable small prolongations.

There is another kind of cartilage existing in certain joints, in the form of thin plates, having both surfaces free, and being interposed between two articulating bones. These are generally found in such joints as are exposed to the most violent shocks, and subjected to the most frequent movements; they are known by the name of *inter-articular cartilages*. Their use is to adjust the contact of the surfaces on the bones, to moderate the intensity of the shocks to which they may be submitted, to increase in some cases the depth of the articular cavities, and to impart solidity to the joints. They are almost always bi-concave, from which circumstance the name of *meniscus* is sometimes applied to them (from *μήνη*, *luna*); they are thick at the circumference, and very thin in the centre, which is sometimes perforated.

These two kinds of cartilage are found only in those joints the surfaces of which are simply in contact.

The articulations of continuous surfaces are provided with cartilages very different from the above, and which should be looked upon as non-ossified portions of the original cartilage of ossification. The progress of ossification always encroaches upon them, while the regular articular cartilages are never affected in this way. It will be seen afterward that the articular cartilages are inorganic, like the enamel of the teeth, and the horny tissues, which are worn away by attrition, and are not susceptible of any lesions, excepting such as arise from mechanical injury or chemical action.*

The Articular Ligaments.†

The *ligaments* constitute a very important division of the fibrous tissue, which is met with in all parts where great resistance and great flexibility are required, and in no part of the body are these requisites more necessary than in the joints. They consist of bundles of flexible and inextensible fibres of a pearly-white lustre, sometimes parallel and sometimes interlaced. Sometimes they are placed between the osseous surfaces, and are then named *interosseous;* sometimes, on the contrary, they occupy the circumference of the surfaces, and are then called *peripheral* or *capsular*. The peripheral ligaments present two surfaces: a *deep surface*, lined by the synovial membrane, which is intimately united to it, and which is so delicate that were it not from its development in disease, its existence here might be doubted; and a *superficial*, which is in contact with the muscles, tendons, nerves, vessels, and cellular tissue, in a word, to all the structures which surround the articulations; and also *two extremities*, which are attached to the bones, at a greater or less distance from the cartilage. The adhesion of these parts is so intimate, that it is easier to break either the ligament or the bone than to separate them at the precise place of their union.

The ligaments may be classed under two very distinct heads: 1. The fasciculated, or those which exist in bundles; and, 2. The membranous or capsular. The ligaments, properly so called, belong to the first class; the fibrous capsules belong to the second. We may admit a third form, which consists of scattered fibres, too far separated to form fasciculated ligaments, and too few in number to constitute articular capsules. We should include, also, in the class of articular ligaments, two very remarkable modifications of the fibrous tissue: 1. The *articular borders;* these are circlets of fibres which surmount the margins of articular cavities, belonging to that class of joints denominated enarthroses; they augment the depth of the cavities, and act as a kind of pad to break the force of impulsion of the articular head against the brim of the cavity, and prevent this edge from breaking. 2. The *yellow* or *elastic ligaments*, which are characterized by their yellow colour, extensibility, and elasticity; hence the name of *yellow elastic tissue* has been given to them, on account of their colour and chief property.

The Synovial Membranes, or Capsules.

In every part of the body where fibres move, they are surrounded by cellular tissue, which secretes a lubricating fluid to facilitate their motions; and, where surfaces move upon each other, they are covered by a membrane which exudes a fluid, varying in its nature according as the motions are confined to simple gliding, or are accompanied by a certain amount of friction. In the first case, the membranes secrete a watery or serous fluid, and are, consequently, denominated *serous membranes;* in the second, the liquid is of an unctuous nature, resembling white of egg; it is called *synovia* (*σὺν*, with, and *ὠὸν*, an egg), and the membrane *synovial membrane*. All the movable articulations are pro-

* [Though the articular cartilages may be non-vascular, it is scarcely correct to say that they are unorganized.]

† The word ligament, *σύνδεσμος* of the Greeks, *copula* or *vinculum* of the Latins, is applied, in anatomy, to any structure which serves to unite different parts to each other. In this sense we speak of the *broad* and the *round ligaments of the uterus, the ligaments of the bladder and of the liver*. Taken in its most limited sense, this name applies exclusively to the articular ligaments.

vided with a synovial membrane or capsule, by means of which the parts are constantly lubricated with a viscid, unctuous fluid, that favours the exact adaptation of the articular surfaces, obviates the effects of friction, and maintains them in contact. This is the cause of the noise or cracking which results from the sudden separation of the articular surfaces.

The synovial capsules, which have been well described by Monro, are thin, transparent membranes, forming shut sacs, which cover the heads of the bones without admitting them into the interior of the cavity. In fact, it is their *external surface* which adheres more or less intimately to the ligaments and other parts which surround the joint, while their *internal surfaces* are in contact with each other, and are constantly lubricated by the synovia. It is a question among anatomists whether the synovial membrane covers also the articular cartilages. It can only be traced by the knife as far as the circumference of these cartilages, and if it exists on them, which analogy would lead us to believe, it is so completely modified as not to be recognisable. Without admitting or denying the fact, for the sake of facility in description, we shall assume the continuity of this membrane over the cartilages. In many joints the synovial membrane is raised from the surface of the parts by a subjacent cushion of fat, which projects into the joint, and which Clopton Havers imagined to be a gland for secreting the synovia. I believe that this, which may be called synovial fatty tissue, is only intended to fill up the spaces which would otherwise be formed in many articulations during the performance of certain movements. The synovial fringes, described by the same author as the excretory ducts of these glands, are nothing more than folds of the membrane.

Classification of the Joints.

The multiplicity of the articulations, and the analogies and differences which they present, have induced anatomists to arrange them in a determinate number of groups, having well-marked characteristics. The shape of the articulating surfaces in each joint, the arrangement of the uniting media, and the variety and extent of motions, being necessarily correlative, either of these three circumstances may be taken as the basis of classification. Most of the older anatomists, attending specially to the means of union, divided the articulations into four classes: 1. *Synchondroses* (σὺν, with, and χόνδρος, a cartilage), when the bones are united by means of cartilage; 2. *Syneuroses* (σὺν, with, and νεῦρον, a nerve, the synonyme of ligament among the ancients), when the connexion is established by ligaments; 3. *Syssarcoses* (σὺν, with, and σὰρξ, flesh or muscle), those joints in which muscles form the uniting medium; 4. *Meningoses* (μήνιγξ, a membrane), when membranes serve as ligaments, as in the bones of the cranium in infants. This classification can only be regarded as a rough sketch.

Bichat, fixing his attention entirely upon the movements, has divided the movable joints according to the variety of motions of which they are capable. There are four kinds of motion: 1. *Gliding;* 2. The *movement of opposition*, when a bone is alternately moved in opposite directions, as in flexion and extension; 3. The movement of *circumduction*, when the bone which is in motion describes a cone, the apex of which is at the joint, and the base is traced by the opposite end of the bone;* 4. The *movement of rotation*, in which a bone rolls on its axis without changing its place.

Proceeding on this classification of the movements, Bichat arranged the articulations in two great classes, the movable and the immovable. The latter he divided according to the nature of the articular surfaces, the former according to the number of motions, in the following order: 1*st class*, those joints which are capable of every kind of motion, viz., gliding, opposition, rotation, and circumduction; 2*d class*, those joints which are capable of all the motions, excepting rotation; 3*d class*, those joints which are only capable of opposition, or alternate motions in the same plane; 4*th class*, those joints which admit only of rotation; 5*th class*, those joints which are only capable of a gliding motion. We should observe that gliding occurs in all the preceding forms of articulation.

This classification, which is almost exclusively founded upon a consideration of the movements, is eminently physiological. For this reason we shall reject it, because, in the study of anatomy, the consideration of functions is of secondary importance, compared to that of structure. The motions of a joint are also evidently the consequence of the shape of its articular surfaces.

The classification now generally adopted is that of Galen, with some modifications. Taking the presence or absence of mobility as the primary ground of division, the articulations are divided into the *movable* or *diarthroses*, and the *immovable* or *synarthroses*. To these two great divisions Winslow has added a third, under the name of *mixed articulations*, or *amphiarthroses* (ἀμφὶ, both), because they partake of the characters of both, viz., mobility, and continuity of surfaces.†

For the determination of the secondary divisions, regard has been had both to the shape of the articular surfaces, and to the movements of which the joint is capable.

* All the joints which possess the four movements of opposition necessarily possess those of *circumduction*.

† This kind of articulation was known to Galen, and named by him *neuter*, or *doubtful articulation*.

Thus, the *diarthroses* have been subdivided into, 1. *Enarthroses*, when the head of one bone is received into the cavity of another; 2. *Arthrodia*, when the articular surfaces are plane, or nearly so; 3. *Ginglymus*, when the joint is only capable of opposition, that is, of alternate movements in opposite directions in the same plane. This latter class is again subdivided into (*a*) *angular ginglymus* or *hinge-joints*, when the movements are angular, as in flexion or extension: the angular ginglymus is said to be *perfect*, when these movements alone are possible, as in the elbow; and *imperfect*, when a slight degree of lateral motion may take place, as in the knee: (*b*) *lateral ginglymus* (or diarthrosis trochoides), when rotation is the only possible movement. It also is subdivided into *simple*, when the bones touch only by one point; and *double*, when they have two points of contact.

The *synarthroses*, or immovable joints, have been divided, according to the nature of their articular surfaces, into, 1. *Suture*, when they are furnished with teeth, by means of which they are locked together, as in the *squamous suture*; 2. *Harmonia*, when the surfaces are nearly smooth, and are merely in juxtaposition; 3. *Gomphosis*, when one part is implanted in another, as the teeth in the alveoli; 4. *Schindylesis*, when a plate of one bone is received into a groove of another: in this way the osseous projection of the anterior edge of the palate bone is attached to the opening of the maxillary sinus.*

There are many advantages in the above classification, but many imperfections also. I would characterize, as especially objectionable, the class arthrodia, which comprises the most dissimilar articulations, as the shoulder-joint, the articulations of the lower jaw, of the wrist, of the bones of the carpus, and of those of the tarsus. We should also notice, as another cause of imperfection, the want of unity in the basis of the classification, which is sometimes founded upon the shape of the surfaces, sometimes on the motions.

By adopting the shape of the articular surfaces alone as a basis, we shall find the arrangement of the ligaments and the motions to be in some measure dependant upon this. On this principle, we shall divide all the joints into three classes: 1. The *diarthroses* (*διαρθρον*†), or those which are formed by bones the surfaces of which are contiguous, but free; 2. *Synarthroses* (*σὺν*, with), or all the joints whose surfaces are continuous; 3. *Amphiarthroses*, or *symphyses* (*ἀμφω*, both), or those joints whose surfaces are partly contiguous, and partly continuous by means of fibrous tissue.

I. *Diarthroses.*

Characters.—Contiguous or free articular surfaces, shaped so as to fit exactly upon each other, and each provided, 1. With an incrusting layer of cartilage; 2. With synovial membranes; 3. With peripheral ligaments; joints always movable. This class is divided into six subdivisions:

1. *Enarthrosis.*

Characters.—A head, or portion of a sphere, more or less completely received into a cavity. Examples: *hip and shoulder joints* (*fig.* 76, and *figs.* 69 and 70).

Ligaments.—A fibrous capsule.

Motions.—In every direction; viz., flexion, extension, abduction, adduction, circumduction, and rotation.

2. *Articulation by mutual Reception.*

Characters.—Articular surfaces, concave in one direction, convex in the direction perpendicular to the first, and so fitted as to embrace each other reciprocally. Example: *articulation of the trapezium with the first metacarpal bone* (*m*, *fig.* 75).‡

Ligaments.—Two or four ligaments, or, rather, an orbicular or capsular ligament.

Motions.—In all directions, like the enarthroses, excepting rotation.

3. *Articulation by Condyles, or Condylarthrosis.*

Characters.—An elongated head, or *condyle*, received into an elliptical cavity. Examples: *articulation of the forearm and hand* (*fig.* 75), *of the lower jaw and the temporal bone* (*fig.* 65).

Ligaments.—Two or four ligaments.

Motions.—In four directions; viz., flexion, extension, abduction, and circumduction, but no rotation. There are always two principal movements in these joints, and, consequently, two which are limited.

4. *Trochlear Articulation, or Ginglymus.*

Characters.—A mutual reception of the articular surfaces. The pulley or trochlea belongs to this mode of articulation. Examples: *the elbow* (*figs.* 71 and 72), *the knee* (*fig.* 78), *the joints of the phalanges* (*figs.* 73 and 74).

* [The rostrum of the sphenoid, and the descending plate of the ethmoid, are united in this manner to the vomer, and afford, perhaps, a better example.]

† The particle *διὰ* always signifies separation.

‡ The cervical vertebræ of the swan present a beautiful specimen of this kind of articulation. This gives to the movements of the neck of these birds that elegance and grace for which they are so remarkable.

Ligaments.—Two lateral ligaments generally placed nearer the side of flexion than that of extension. Sometimes there are likewise anterior and posterior ligaments, but they are always weak, and are often replaced by tendons.

Motions.—Two motions in opposite directions.

5. *Trochoid Articulations.**

Characters.—An axis received into a ring, which is partly osseous and partly fibrous. Examples: *articulation of the atlas and axis* (*e, fig.* 64), *of the radius and ulna* (*figs.* 71 and 72).

Ligaments.—An annular ligament.

Motions.—Rotation.

6. *Arthrodia.*

Characters.—Articular surfaces, plane, or nearly so.† Examples: *articulations of the carpal and tarsal bones* (*figs.* 75 and 84), *and of the articular processes of the vertebræ* (*g, figs.* 61 and 63).

Ligaments.—Fibres placed irregularly round the joint.

Motions.—Gliding.

II. *Synarthroses.*

Characters.—Articular surfaces armed with teeth or other inequalities, which are mutually dovetailed, and from which the name of *suture* is derived. Examples: *articulations of the bones of the cranium* (*figs.* 21, 22, and 23).

Means of Union.—Remnant of the cartilage of ossification, which is gradually encroached on during the progress of age.‡

There are no incrusting cartilages, synovial membranes, ligaments, nor motions.

Monro enumerates seven kinds of sutures, and these might still be multiplied, if we regarded all the varieties presented by the articular surfaces. Three kinds may be admitted with propriety: 1. *Indented sutures;* 2. *Squamous sutures;* and, 3. *Harmonic sutures;* the distinctions depending upon the articular surfaces being provided with teeth, or overlapping like scales, or being simply rough and in juxtaposition. These even are only unimportant varieties. Monro added the schindylesis, or ploughshare articulation of Keil. We shall content ourselves with simply mentioning it; and we also omit the division gomphosis (γόμφος, a nail), which is appropriated to the mode of implantation of the teeth; because the teeth are not bones, and are lodged in the jaw, not articulated with it.

III. *Amphiarthroses, or Symphyses.*

Characters.—Flat, or nearly flat, articular surfaces, which are partly in contact, and are partly continuous, by means of fibrous tissue. Examples: *articulation of the bodies of the vertebræ* (*b, fig.* 58), *symphysis pubis* (*e, fig.* 77), *sacro-iliac symphysis* (*b, fig.* 76).

Means of Union.—Interosseous and peripheral ligaments.

Motion.—Very slight, gliding; an arthrodia is a necessary element of an amphiarthrosis. Thus, in the symphysis pubis the bones are partly in contact, partly continuous.

ARTICULATIONS OF THE VERTEBRAL COLUMN.

Articulations of the Vertebræ with each other.—Those peculiar to certain Vertebræ.—Sacro-vertebral, Sacro-coccygeal, and Coccygeal Articulations.—Articulations of the Cranium—Of the Face—Of the Thorax.

The articulations of the vertebral column (*figs.* 58, 59, and 60) are divided into the *extrinsic* and the *intrinsic*. The first comprise the articulations of the vertebral column with the head, the ribs, and the ossa innominata. The intrinsic comprise the articulations of the vertebræ with each other. These last are also divided into those which are *common* to all the vertebræ, and those which are *peculiar* to some. We shall describe each in succession.

Articulations of the Vertebræ with each other.

Mode of Preparation.—Remove completely all the soft parts which surround the vertebral column; saw off vertically all that part of the head which is in front of the column, and separate the bodies of the vertebra from the posterior arches by dividing the pedicles. When the section reaches the axis, carry the instrument behind the superior ar-

* The trochoid (τρέχω, to turn), or pivot-joint, corresponds to the simple or double lateral ginglymus of modern anatomists, or the rotatory diarthrosis of the ancients.

† These articular surfaces are very variable in the *arthrodial* articulations. Sometimes they are angular, sometimes spheroidal. As respects the ligaments, they are sometimes loose, sometimes firm.

‡ Some anatomists have rejected this kind of articulation, adopting the opinion of Columbus, who affirms that there can be no joint where there is no motion.

ticular processes of this vertebra, and of the atlas, and behind the condyles of the occipital cone: remove the spinal marrow and its membranes. In this way the vertebral column will be divided into two parts: an anterior, formed by the series of the bodies of the vertebræ, on which we find the *anterior* and *posterior common ligaments*, and the *intervertebral substances*; and a posterior, formed by the series of laminæ, and the articular and spinous processes. The intervertebral substances require a special preparation, which consists in making vertical and horizontal sections of a portion of the column, or which may be more simply effected by maceration in diluted nitric acid, which allows the bodies of the vertebræ to be removed without injuring the intervertebral substance. The vertebræ are united, 1. By their bodies; 2. By their articular processes; 3. By their laminæ; and, 4. By their spinous processes.

Articulation of the Bodies of the Vertebræ.

The bodies of the vertebræ are united together by *amphiarthrosis*. The arthrodial portion, or the contiguous surface, is represented by the articular processes.

The *articular surfaces* are the upper and under surfaces of the body of each vertebra. It follows, from the concavity of these surfaces, that, instead of fitting each other exactly, they leave considerable lenticular spaces between them; these appear to be the vestiges of the biconical cavity between the vertebræ of fishes. The depth of these spaces is not the same throughout the entire column; it exactly measures the thickness of the intervertebral substance. By measurement, I have ascertained that the height of the intervertebral substance in the loins is one half of that of the bodies of the vertebra, in the back one third, and in the neck a little more than the half. From the size of the bodies of the vertebra, it follows that the interval between the bodies is largest in the lumbar region. The articular surfaces of the bodies of the vertebra are covered by a very thin layer of cartilage intermediate between the bones and the fibrous tissues.

The *means of union* are of two kinds, as in all the amphiarthroses: 1. They surround the joint; 2. They proceed from one articular surface to the other: in one word, some are peripheral, and the others interosseous.

1. *Peripheral Ligaments.*—The most general idea which can be formed of these ligaments is that of a fibrous sheath, surrounding the column formed by the bodies of the vertebræ, and uniting in one whole the different pieces of which it is composed. The part of the sheath which covers the anterior aspect of the bones is called the *anterior common ligament of the vertebræ*; and that which covers the posterior surface is called the *posterior common ligament of the vertebræ*.

The *anterior common vertebral ligament* (*a*, *figs.* 58, 60) presents the appearance of a white pearly-looking membrane stretched from the axis to the upper part of the sacrum. This ligament, which is thicker in the dorsal region than in the neck or the loins, is composed of three very distinct parts: a thick one in the middle, and two lateral, which are separated from it by a series of openings that give passage to some vessels (see *fig.* 58). Its *anterior surface* is in contact with the organs of the neck, the thorax, and the abdomen, and united with them by very loose cellular tissue. The tendons of the longi colli and anterior recti muscles, and the pillars of the diaphragm, mix their fibres with this ligament. The psoæ muscles correspond to its lateral portions below. Its *posterior surface* adheres more closely to the intervertebral substances, and to the projecting rims of the bodies of the vertebræ, than to the transverse grooves of the bodies. This ligament is composed of several planes of fibres, of which the most superficial are the longest. The deepest pass from one vertebra to the next, and are lost on the periosteum. The superficial stretch over four or five vertebræ.

Fig. 58.

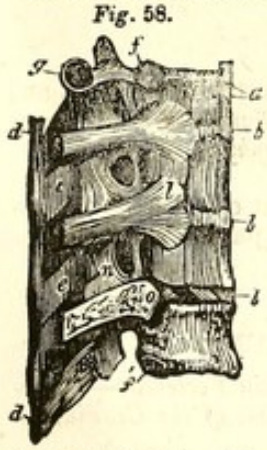

Posterior common vertebral ligament (*a*, *fig.* 59). This is thicker than the anterior, but has the same white pearly appearance. It commences at the occipital bone, and terminates at the sacrum. It resembles a fibrous band, which expands at the intervertebral substances, and is contracted over the bodies of the vertebræ; hence it has a regular festooned appearance. Its *posterior surface* is united to the dura mater at its upper part, but is separated from it by a delicate cellular tissue throughout the rest of its extent. Its *anterior surface* adheres intimately to the intervertebral substances; it is separated from the middle of the bodies of the vertebræ by the veins, which pass from the interior of the bone into the vertebral venous sinuses which run along the edges of the ligament. Like the anterior common vertebral ligament, it is composed of several planes of fibres, the posterior of which are the longest. It is formed of more compact tissue than the anterior.

(Fig. 59.)

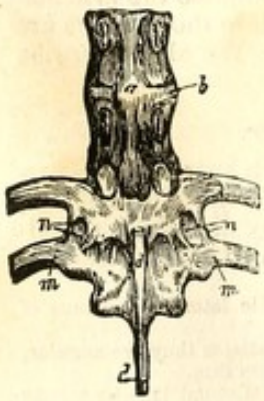

2. The *intervertebral substance* or *interosseous ligament* (*b*, *figs.* 58,

59, 60, and 68) consists of a kind of disc, which fills up the lenticular space between the bodies of the vertebræ, and might, with propriety, be called *intervertebral disc.*

Each disc has the form of a double convex lens, and is so closely united by its *upper* and *under surfaces* to the corresponding vertebræ, that it is easier to break the bones than to destroy this connexion. Its *circumference* adheres to the anterior and posterior common ligaments, and contributes to form the intervertebral foramina. In the dorsal region it also forms part of the angular facette which articulates with the ribs. The *thickness* of the intervertebral substance is not the same in all the regions of the spinal column, being greatest at the lower parts. The proportion between the thickness of the discs and the bodies of the vertebræ is exactly measured by that of the intervertebral space, and is not the same in all the regions. In the lumbar region the thickness of the disc is half that of the corresponding vertebræ; in the dorsal region it is a third; and in the cervical region it is a little more than a half.*

The intervertebral substance is not equally thick throughout. From its lenticular form, it must be thicker at the centre than at the circumference; in the neck and in the loins it is thicker in front than behind; in the back the opposite prevails, and by this inequality the discs concur in producing the alternate curves of the vertebral column. Abnormal curvatures are in a great measure caused by unequal thickness of these dics, and I have often had opportunities to convince myself that compression of this substance on the side towards which the inclination takes place is the most common origin of the deformity. The thickness of the discs varies in different circumstances. Thus, after prolonged standing in the erect posture, the height of the body becomes diminished from eight to ten lines, which is owing to compression of the intervertebral substances.

Each disc is composed of concentric layers (*figs.* 60 and 68) closely pressed together at the circumference, but more separate towards the centre, where we find a soft spongy substance, moistened by a viscid fluid resembling synovia. This soft substance is nearer the posterior than the anterior aspect of the body of the vertebra; it escapes, and forms, as it were, a hernia, when the parts are cut either horizontally or vertically. It varies much at different ages. It is moist, soft, spongy, and white in the infant and in youth, which accords with the suppleness of the vertebral column at that period of life. Where this substance is situated, we may inflate an irregular cellular cavity in it, which may be regarded as the rudiment of the large synovial cavity which these parts exhibit in fishes. M. Pailloux believes that this cavity is lined by a synovial membrane. In old age it becomes dry, friable, and yellowish, or brown. Monro attributes the elasticity of the vertebral column to the displacement of this soft central substance in the different movements; for, according to his theory, the movements of the bodies of the vertebræ take place upon it as upon a movable pivot or a liquid fulcrum.

The intervertebral substance is called a *cartilaginous ligament* by Vesalius; by others, a *cartilage;* and by Bichat, a *fibro-cartilage;* but they evidently belong to the fibrous tissues. This may be shown by macerating a portion of the spinal column for some days, or even by rubbing the surface with a rough cloth. It will then appear that this pretended fibro-cartilage is nothing more than a series of concentric fibrous layers, strongly compressed together; that each layer is formed of parallel fibres, directed very obliquely from the lower surface of the vertebra above to the upper surface of the vertebra below, and regularly crossing with the fibres of the next layer (*b', fig.* 58). This regular crossing, which we shall meet with in other parts, is evidently very conducive to solidity.

Union of the Articular Processes.

These articulations are *arthrodiæ.*

Articular Surfaces.—The corresponding surfaces are covered by a thin layer of cartilage. The means of union consist of some irregular ligamentous fibres (*d d, fig.* 60), which surround the outside of the joint, and are more numerous in the dorsal and cervical regions than in the loins, the internal side of the articulation being occupied by the yellow ligament. These articulations are provided with synovial membranes of greater extent in the cervical than in the other regions.

Union of the Laminæ.

The spaces between the vertebral laminæ are occupied by ligaments of a particular description, which are called *yellow ligaments, ligamenta subflava,* on account of their colour. They are composed of two halves united at an angle like the laminæ (*c c, fig.* 60). Their *lower edge* is implanted upon the upper edge of the laminæ below, and their *upper edge* is attached to the anterior surface of the corresponding laminæ. From this it follows, that the *height* of the ligamenta subflava is much greater than would be necessary to reach from one lamina to another; it is almost equal to that of the corresponding vertebral lamina.

Their length is measured by that of the laminæ, and is, consequently,

Fig. 60.

* A curious preparation may be made by taking away all the bodies of the vertebræ in a spine softened by nitric acid. A column then remains, formed by the series of discs, which may be compared with a column formed by the bodies of the vertebræ.

greater in the neck than in the back and loins. They are of greater *thickness* in the loins than in the back and the neck, and the thickest part corresponds to the base of the spinous process. There are also some re-enforcing bundles, which constitute a sort of median yellow ligament. Their *anterior surface* is separated from the dura mater by cellular tissue, and by veins. It is remarkable for its smooth and polished appearance. Their posterior surfaces are in contact with the vertebral laminæ, which cover them almost completely, except in the cervical region, where they may be seen between the laminæ, when the head is slightly inclined forward; this circumstance renders it possible for a penetrating instrument to enter between the cervical laminæ, while it is almost impossible in the dorsal and lumbar regions.

Structure.—These ligaments are composed of parallel vertical fibres very closely arranged. They are extensible, and, when stretched, immediately recover themselves, and are therefore very elastic. They are as strong as ordinary ligaments. Their extensibility is brought into action during flexion of the vertebral column, and their elasticity during extension. They have great effect in maintaining the erect posture, which would otherwise have required a constant expenditure of muscular power.

Union of the Spinous Processes.

The spinous processes are united by the supra-spinous and the inter-spinous ligaments. The *supra-spinous ligament* (*d d, figs.* 58 and 59) is a fibrous cord, which extends from the seventh cervical vertebra to the sacrum, along the summit of the spinous processes of the dorsal and lumbar vertebræ. This ligament can be only distinguished from the aponeurotic fibres, which are inserted into the spinous processes, by the longitudinal direction of its fibres. It is larger in the lumbar than in the dorsal region. It is expanded, and becomes even sometimes cartilaginous in the interval between the processes. It is inextensible. I regard a fibrous cord which extends from the seventh cervical vertebra to the external occipital protuberance as a continuation of the supra-spinous ligament; it appears to be the vestige of the *posterior cervical ligament* of quadrupeds, and is of considerable size in some subjects; from its anterior surface, prolongations are given off to the spinous processes of all the cervical vertebræ, excepting the first.*

The *inter-spinous ligaments* (*e e, fig.* 58) do not exist in the neck, where their place is supplied by small muscles; they are very thin in the back, where each has the form of a triangle with the base looking backward. They are thick and quadrilateral in the loins. Their upper and lower edges are attached to the corresponding spinous processes. Their surfaces are in contact with the muscles of the vertebral grooves. M. Mayer speaks of synovial capsules, which he has met with between the lumbar spinous processes, and especially between the third and the fourth in this region; these membranes are by no means constant.

Articulations peculiar to certain Vertebræ (*figs.* 61 to 64).

Although the articulations of the atlas and of the axis, with the occipital bone, do not properly belong to the articulations of the vertebral column, yet the connexion between these articulations and that of the atlas with the axis is so intimate, that it is impossible to separate them. We shall describe these three articulations in succession; first noticing the articulation of the atlas with the occipital bone (*occipito-atlantoid articulation*).

Occipito-atlantoid Articulation.

Preparation.—Remove the part of the scull which is in front of the vertebral column, taking care to leave the basilar process. The muscles which surround the joint, being closely applied to the ligaments, should be very carefully detached.

The atlas unites with the occipital bone, 1. By its anterior arch; 2. By its posterior arch; 3. By the base of its transverse processes; 4. By its two articular surfaces.

1. The anterior arch of the atlas is united to the circumference of the foramen magnum by two *anterior occipito-atlantal ligaments*. One of these, the *superficial* (*a, figs.* 61 and 64), is a very strong cylindrical cord situated in the median line, where it forms a very marked projection, and stretches from the basilar process of the occipital bone to the anterior tubercle of the atlas. The other (*b, fig.* 61), which is *deep-seated*, is pretty thick, consists of several layers, and extends from the upper edge of the anterior arch of the atlas to the occipital bone.

Fig. 61.

2. Most anatomists admit the existence of a ligament stretching from the posterior part of the foramen magnum to the upper edge of the posterior arch of the atlas, the *posterior occipito-atlantal ligament* (*b, figs.* 62

* This ligament is the result of the intersection of the aponeuroses, of the trapezius, splenius, &c. I shall refer more particularly to this point in myology, when on the subject of the posterior cervical aponeurosis.

and 64). But it can scarcely be distinguished, consisting only of a few ligamentous fibres among the fat of this region.

3. *Lateral Occipito-atlantal Ligaments* (*c*, *fig.* 61).—A fibrous cord passes from the base of the transverse process of the atlas to the jugular process of the occipital bone. In connexion with a similar bundle from the pars petrosa, it forms a very remarkable fibrous canal, which gives passage to the internal jugular vein, the internal carotid artery, the hypoglossal, pneumogastric, glosso-pharyngeal, and accessory nerves.

Fig. 62.

4. The union of the condyles of the occipital bone with the superior articular surfaces of the atlas is a *double condyloid articulation*. The articular surfaces of the occipital bone are the two condyles, convex, oblong, looking downward and outward, and directed forward and inward, so that their axes, if prolonged, would meet in front of the basilar process. The articular surfaces of the atlas are concave and oblong, and look upward and a little inward, so as to fit exactly upon the convexity of the condyles. Both are covered by a thin layer of cartilage. The *ligaments* are vertical fibres which surround the joint, but are most numerous in front and on the outside, for they scarcely exist on the inside and behind. There is also a very loose *synovial membrane* which passes beyond the articular surfaces on all sides, but especially to the outside.

Atlanto-axoid Articulation.

Preparation.—After having studied the superficial ligaments, remove the laminæ of the axis, the posterior arch of the atlas, and the back part of the foramen magnum. Detach with care that portion of the dura mater which corresponds to the first two vertebræ and the foramen magnum, and turn it upward. Lastly, in order to obtain a good view of the articulation of the odontoid process with the atlas, disarticulate the occipital bone.

This articulation is formed between, 1. The odontoid process of the axis, and the anterior arch of the atlas; 2. Between the superior articulating processes of the axis and the inferior articulating processes of the atlas; 3. In addition, the anterior and posterior arches of the atlas are united to the axis by two ligaments—the anterior and the posterior *atlanto-axoid ligaments*.

The *anterior atlanto-axoid ligament* (*b*, *figs.* 61 and 64) is a thick vertical bundle composed of several layers, which extends from the tubercle and the lower edge of the anterior arch of the atlas in front of the base of the odontoid process of the body of the axis. It is continuous below with the anterior common ligament.

The *posterior atlanto-axoid ligament* (*c*, *figs.* 62 and 64) is a very loose and thin membrane, extending from the posterior arch of the atlas to the upper edge of the laminæ of the axis; it is a little thicker in the median line than at the sides, and represents the ligamenta subflava in a rudimentary state.

Articulation of the Odontoid Process with the Atlas.—This is a *pivot* joint, the odontoid process being received into a ring formed in front by the anterior arch of the atlas, on the sides by the lateral masses of the same bone, and behind by the transverse ligament. We have, therefore, to consider, 1. The articulation of the anterior arch of the atlas with the odontoid process (*atlanto-odontoid articulation*); 2. The articulation of this same process with the transverse ligament (*syndesmo-odontoid articulation*).

1. *Atlanto-odontoid Articulation* (*e*, *fig.* 64).—The articular surfaces are an oval and slightly concave facette on the posterior surface of the anterior arch of the atlas (1); and a slightly convex, vertically oblong facette, on the fore part of the odontoid process (2). Both surfaces are incrusted with cartilage, and there is also a very loose synovial membrane with subjacent adipose tissue. The joint is strengthened by some ligamentous fibres, arranged in the form of a capsule.

2. *Syndesmo-odontoid Articulation.*—This joint is formed by means of the *transverse* or *annular ligament* (*f*, *figs.* 63 and 64), a very thick and compact bundle of fibres, flattened before and behind, and stretched transversely between the lateral masses of the atlas, passing behind the odontoid process, and closely embracing it like a half ring. The *anterior surface* of this ligament is concave, and polished like cartilage; it is in contact with the posterior surface of the odontoid process (2, *fig.* 64), which is covered with cartilage, and is almost always furrowed transversely, *i. e.*, in the direction of its movements. There is a very loose synovial membrane in this joint, which is prolonged on the sides of the odontoid process, as far as the odontoid ligaments. The *posterior surface* is covered by the posterior occipito-axoid ligaments* (*o*, *fig* 64; see *figs.* 63 and 64). From its *upper edge* a

Fig. 63.

* If the student is only provided with one preparation for the examination of all these joints, it is necessary to study these ligaments before dividing them, in order to expose the transverse ligaments.

fibrous band is detached, which is fixed to the occipital bone, in front of the occipito-axoid ligament, by a narrow extremity. Another fibrous band (see *figs.* 63 and 64), of greater length than breadth, proceeds from its *lower edge*, and is attached to the posterior surface of the axis; hence the name *crucial* has been given to the annular ligament by some authors. The extremities are inserted into two tubercles on the inside of the lateral masses of the atlas.

There is a very remarkable circumstance connected with this ligament, viz., that its *lower circumference* belongs to a smaller circle than its *upper*, so that the odontoid process is very firmly retained in the ring which this ligament contributes to form, and this arrangement accords with a sort of constriction at the base of the odontoid process.

Union of the Articular Processes of the Atlas and the Axis.

This is a double *arthrodia*. The *articular surfaces* of the atlas are plane, circular, and horizontal, but looking slightly inward; those of the axis are also plane and horizontal, looking slightly outward, and of greater extent than the preceding. They are retained in their place by a *fibrous capsule* (*g*, *figs.* 61 and 63), which is very strong, especially in front, and sufficiently loose to permit the extensive motions which take place at this joint: it is formed of vertical and parallel fibres. The *synovial capsule* is very loose, and projects beyond the surfaces of the bones in every direction, but particularly in front. It almost always communicates with the synovial membrane of the joint between the transverse ligament and the odontoid process.

Union of the Occipital Bone and the Axis.

Although the occipital bone and the axis are nowhere contiguous, and are not, therefore, articulated, yet they are united very firmly by means of strong ligaments, extending from the occipital bone to the body of the axis, and also to the odontoid process.

Preparation.—Remove with care that portion of the dura mater which corresponds to the first two vertebræ; the occipito-axoid ligaments lie under it. Then detach the transverse ligaments, remove the anterior arch and lateral masses of the atlas, so that nothing remains excepting the occipital bone and the axis.

1. The *occipito-axoid ligaments* are three in number, a middle and two lateral. The *middle occipito-axoid ligament* (*o*, *fig.* 64) is thick, and forms at its upper part a single band, the fibres of which are separated below into three very distinct layers. The most posterior of these is continuous with the posterior common ligament; the second is attached to the posterior surface of the body of the axis; and the deepest, which is very thin, and shaped like a tongue pointed above, is that which we described with the transverse ligament. The *lateral occipito-axoid ligaments* (*r*, *fig.* 64) arise from the sides of the basilar groove by a broad extremity, and are attached to the posterior surface of the axis by a pointed end. They correspond in front with the odontoid and transverse ligaments, and behind with the dura mater.

Fig. 64.

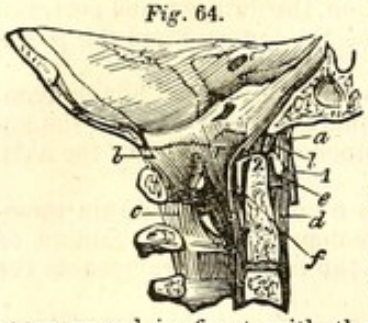

2. The *odontoid ligaments* are three in number, a middle and two lateral. The *middle* (*l*, *fig.* 64) consists of ligamentous fibres, which extend from the apex of the odontoid process to the fore part of the foramen magnum, between the condyles; the *two lateral* (*l*, *fig.* 63) are two bundles of fibres, very strong, short, and cylindrical, which stretch between the sides of the apex of the odontoid process, and two small fossæ on the inside of the condyles; their direction is horizontal, so that they represent the horizontal limbs of the letter T, of which the odontoid process forms the vertical portion; they are almost always united by a bundle, which passes above the odontoid process without adhering to it, so that, at first sight, they might be declared to be one and the same ligament.

Sacro-vertebral, Sacro-coccygeal, and Coccygeal Articulations.

Sacro-vertebral Articulation.—This resembles in every point the articulations of the other vertebræ. We shall only remark, 1. The great thickness of the intervertebral substance, particularly in front, a vertical section of it resembling a hatchet with the broad part turned forward; 2. The *sacro-vertebral ligament* (*a*, *fig.* 76), which is proper to this articulation, a very short, thick, and strong bundle stretched obliquely from the transverse process of the fifth lumbar vertebra to the base of the sacrum, where it crosses with some ligamentous fibres of the sacro-iliac articulation.

Sacro-coccygeal Articulation.—This is an amphiarthrosis, or symphysis, analogous in every repect to that of the bodies of the vertebræ; a fibrous disc resembling the intervertebral substances, but of a more loose texture, unites the corresponding articular surfaces. In some subjects the coccyx is very movable, and there is a synovial capsule in the centre of the disc. The other means of union are, 1. The *anterior sacro-coccygeal ligament* (*a fig.* 77), composed of parallel fibres extending from the anterior surface of the sacrum to the anterior surface of the coccyx, and often divided into two lateral bundles;

2. The *posterior sacro-coccygeal ligament*, which is fixed above to the edges of the notch which terminates the sacral canal, and is prolonged upon the posterior surface of the coccyx. This ligament, which completes the sacral canal, gives attachment to the glutæi maximi muscles by its posterior surface. It is composed of several layers, the most superficial of which reach the apex of the coccyx, while the deepest extend only to the first piece of that bone.

The *coccygeal articulations* are also amphiarthroses, which become synarthroses during the progress of life. The articulation of the first with the second piece is the only one which remains to an advanced age. It is sometimes extremely movable.*

Mechanism of the Vertebral Column.

The vertebral column being at once an enclosing and protecting cylinder for the spinal marrow, a column for transmitting the weight of the trunk and the upper extremities to the legs, and an organ of locomotion, its anatomical structure must be examined in reference to these three uses.

The Vertebral Column considered as the Protecting Cylinder of the Spinal Cord.

The vertebral column performs the office of a protecting cylinder, by virtue of its solidity, ensured by the bodies of the vertebræ in front, by the projection of the spinous processes behind, which ward off, so to speak, all external objects, and by the prominence of the transverse processes at the sides. By means of these arrangements, the spinal cord is inaccessible, excepting by a sharp instrument, which might penetrate either in front through the intervertebral substances, or on the sides through the intervertebral foramina, or, lastly, behind through the intervals between the spinous processes, and between the laminæ. Another condition of solidity, in so far as this can be obtained with mobility, is provided by the number of pieces of which the vertebral column is formed. For, in all cases where the column is subjected to shocks, each articulation becomes the seat of a decomposition of the force; a part is employed in producing a slight displacement of the articular surfaces, and is therefore entirely lost, as far as regards the transmission of the shock. If, on the contrary, the vertebral column had been formed of one single piece, the transmission of shocks would have been unbroken, and thus the frequent cause of concussion and fracture. Lastly, the breadth of the articular surfaces by which the bodies are united, the strength and pliability of the intervertebral substances, the vertical direction of the articular processes, contrasted with the horizontal direction of the articular surfaces of the body, and the species of dovetailing which results from it, are also most favourable conditions for the protection of the spinal marrow. Indeed, I do not see how, in our system of organization, the protection to the spinal cord could be increased.

The Vertebral Column considered as an Organ for transmitting the Weight of the Trunk.

The anatomical arrangements adapted to this purpose are the following:

1. The progressive increase in size of the vertebral column, from the apex to the base. This disposition is particularly observable in the first two pieces of the sacrum, which are proportionally much larger in man than in the lower animals.

2. The articulation of the vertebral column with the posterior part of the pelvis, by which the centre of gravity of the trunk is carried backward, and the maintenance of the equilibrium is aided, by counterbalancing the weight of the thoracic and abdominal viscera, which, instead of uniformly surrounding the column, are all placed in front.

3. The alternate inflections of the vertebral column, which allow more extensive oscillations of the centre of gravity of the column than would have been practicable had its direction been altogether rectilinear, and which also augment its power of resistance in the vertical direction.

4. The length of the spinous processes, which thus afford a more favourable, because a longer lever to the extensor muscles, which maintain the column erect. The absence of these processes in infancy is one of the causes of the difficulty of standing at that period.

5. The existence of the soft matter in the centre of the intervertebral discs, which prevents compression of the column by affording a liquid, and therefore almost incompressible *point d'appui*, as Monro has remarked; the truth of this may be proved by submitting a portion to powerful compression. We have before remarked that this soft matter is not placed in the centre, between the bodies of the vertebræ, but nearer to the posterior border, and, consequently, it occupies the centre of their movements. It diminishes the violence of shocks, changes its position as we change our attitudes, and fills up the vacancies resulting from the approach of the bodies on one side, and their separation on the other. It is generally believed, it is true, that the diminution of height which follows upon prolonged standing or walking is the result of mechanical compression of the intervertebral discs, and an absolute diminution of their thickness; but it appears

* I have met with an instance in which this joint was very movable: there was a synovial membrane and a fibrous capsule. The extent of the motion was so great, that the two pieces could be made to form a right angle with the cavity looking backward.

more conformable to the laws of physics to admit that the diminution in the height of the vertebral column depends upon the increase of the curvatures, unless we admit Monro's hypothesis of the absorption of part of the liquid contained within the discs.

6. The presence of the yellow ligaments, which, by their elasticity, continually oppose the causes which tend to bend the body forward, and which are for each of the vertebræ what the posterior cervical ligament is for the head.

7. The existence of the vertebral canal, which has the same advantage as the cylinder of long bones, of increasing the strength without increasing the weight.

8. The mode of articulation of the vertebral column with the head, which is doubly advantageous, both as regards the place occupied by the articular surfaces, and their direction: 1. The articular surfaces correspond to the point of junction of the posterior with the two anterior thirds of the head. The posterior third of the head contains a large portion of the encephalic mass, while the two anterior thirds are chiefly formed by the face, which, in comparison to its size, is of little weight. From this it follows, that the weight of the posterior third almost counterbalances that of the two anterior thirds of the head. 2. The almost horizontal direction of the condyles in the human subject permits the head to rest upon the summit of the vertebral column, without having a necessary tendency, or at least a very slight one, to incline forward, as invariably takes place in animals whose occipital condyles are vertical, and situated entirely on the back of the head. Yet, notwithstanding these advantageous conditions of the atlantal articulation, the part in front of the condyles is somewhat heavier than that behind; and this difference, though slight, is sufficient to cause flexion of the head, when left to itself, either during sleep or after death. Indeed, in spite of all the arrangements above referred to, considerable efforts are required to maintain the biped position; and to secure this, we have the vertebral grooves filled up with powerful muscles. In the human subject, the muscles which occupy the cervical portion of the column, and which are destined to support the head, are not nearly so strong as the corresponding muscles in the quadruped, while those of the loins are proportionally much stronger. Standing in the erect position is, therefore, very far from being a state of rest, and requires a constant muscular effort to sustain it.

The Vertebral Column considered as an Organ of Locomotion.

The vertebræ perform upon each other certain oscillatory or balancing movements in all directions, by means of the pliability of the intervertebral substances;* but they are so obscure, that their existence can scarcely be recognised, or their character examined on a small portion of the column. In order to understand them, the entire spine must be examined.

Movements of the entire Column.—These are, 1. Flexion, or the movement forward. 2. Extension. 3. Lateral inclination. 4. Circumduction, in which the column describes a cone, of which the apex is below, and the base above. 5. Rotation on its axis, or torsion of the vertebral column.

In the analysis of the motions of the column, it is necessary to distinguish carefully between the actual and the apparent motions; the first are much less extensive than would be imagined at first sight, the greater part of the apparent movements taking place at the articulations of the pelvis with the thighs. In these movements of the whole, the column represents a lever of the third order, an elastic arch in which the resistance is at the upper extremity, the fulcrum at the lower end, and the power applied in the middle. Each vertebra, on the contrary, represents a lever of the first order, in which the power and the resistance are at the anterior and posterior extremities of the bone, and the fulcrum in the middle.

1. *In the movement of flexion*, which is the most extensive of all, the anterior common ligament is relaxed; the anterior part of the intervertebral substances is compressed; the soft central portion is pushed backward; the posterior fibres of the discs are slightly stretched, as are also the posterior common ligament, the supra-spinous, inter-spinous, and yellow ligaments. The inferior articular processes of each vertebra move upward upon the superior articular processes of the vertebra below. The laminæ are separated, so that the rachidian canal, especially in the cervical region, becomes accessible to penetrating instruments.

2. *In extension*, the anterior common ligament and the anterior fibres of the intervertebral discs are stretched; the posterior fibres of the disc are relaxed; the soft central matter is pushed forward; the yellow, supra-spinous, and inter-spinous ligaments are relaxed. The lower articular processes glide downward upon the superior articular processes of the vertebra below. This motion is not extensive; it is limited by the anterior common ligament, and the meeting of the spinous processes.

3. In the movements of *lateral inclination*, the discs are compressed on the side to which the inclination takes place, and the central pulp is forced to the other side. These motions are limited, not only by the meeting of the transverse processes, but even be-

* Thus the uniting media of the vertebræ serve also as means of locomotion.

fore these touch, by the resistance of the intervertebral substances, and of the lateral bundles of the anterior common ligament.

4. *Circumduction.*—This motion, the centre of which is in the lumbar region, appears at first sight very extensive, because a portion of the movement at the hip-joint is generally ascribed to it. In reality, it is very limited, and results from a succession of the preceding motions.

5. The movement of *rotation* is effected by the twisting of the intervertebral substances. Although the motion of each disc is very slight, yet the simultaneous twisting of them all produces a general movement, by which the anterior surface of the column is turned slightly to the sides. It is, however, upon the whole, very limited; and although in the erect posture the trunk of the body can describe a semicircle, the greatet part of this motion takes place at the hip-joint.

All the regions of the vertebral column do not equally participate in these general motions. They are most extensive in the *cervical region*, where we observe, 1. *Flexion*, which may be carried so far as to make the chin touch the upper part of the sternum; 2. *Extension*, so that the neck may be turned backward; 3. *Lateral inclination*, until the head nearly touches the shoulder; 4. *Rotation*, which is greater here than in any of the other regions, notwithstanding the presence of the lateral hook-like processes or ridges.* These motions may be to such an extent as to cause luxation, which can only take place, without fracture, in the cervical region, on account of the almost horizontal direction of the articular processes.

The general movements are most limited in the *dorsal region*. 1. Flexion is rendered impossible by the presence of the sternum. The presence of this bone in the different species of animals attests the immobility of the dorsal portion of the column, in the same manner as its absence is an indication of its mobility. 2. Extension is prevented by the meeting of the spinous processes, which are longer and more closely imbricated in this than in any other of the regions. 3. Lateral movements are rendered impossible by the ribs, which would be forced against each other if this motion took place. 4. As all the preceding motions are the elements of circumduction, it may be easily conceived that this can scarcely take place. 5. The same obstacles oppose the movement of rotation, which is also prevented by the position of the articular processes, which are directed vertically, and whose surfaces on the right and left sides are not upon the same plane. The thinness of the intervertebral substances in the dorsal region accords with all these arrangements in limiting mobility.

What has been said regarding the immobility of the dorsal region applies only to the upper part of this region. The dispositions at the lower part are more favourable to mobility. We know that the last two dorsal vertebræ are remarkable for the shortness of their spinous and transverse processes; and that the ribs with which they articulate are very movable, and could not oppose the motions of the vertebræ in any degree.

The *lumbar region* participates much more in the general motions than the dorsal. The articular processes in this region are much more advantageously adapted for rotation than in either the dorsal or cervical, for the lower pair of each vertebra forms a solid cylinder, which is received into the hollow surface of the superior articulating processes of the vertebra below. This arrangement permits a motion resembling that of the hinges of a door.

It should be remarked, that in all the regions the lower articular processes of each vertebra are placed behind the superior articular processes of the succeeding vertebra, and form a sort of imbrication. Each vertebra, then, is retained in its place by a species of dovetailing, so that it cannot be dislocated forward without breaking the superior articular processes of the vertebra below, nor backward, without breaking the inferior articular processes of the vertebra above. This remark does not apply rigorously to the cervical region, the articular processes of which are oblique, and can permit dislocation without fracture.

Mechanism of the Articulations of the Vertebral Column and the Head.

The movements of the head upon the vertebral column are shared between two articulations: viz., 1. The occipito-atlantal, to which all the motions of flexion, extension, lateral inclination, and circumduction belong; 2. The atlanto-axoid, which only performs one movement, viz., rotation.

Mechanism of the Occipito-atlantal Articulation.

The movements of flexion and extension of the head upon the atlas are very limited; when the head is decidedly bent or inclined, the effect is produced by motion of the whole cervical region. It is possible to distinguish flexion at the occipito-atlantal articulation from that which is produced by the entire cervical region. In the first case, the chin approaches the vertebral column, and the skin on the upper part of the neck is

* We should form an incorrect notion of the obstacle resulting from the lateral ridges on the bodies of the vertebræ, in the performance of rotation, if we were to study them only on the disarticulated skeleton. In the recent subject they scarcely touch the vertebra above, on account of the intervertebral disc.

wrinkled transversely; in the latter, the spine bends at the same time as the head, consequently the interval between it and the chin remains the same, and there are no transverse wrinkles of the skin.

During flexion the condyles glide backward; the odontoid, the occipito-axoid, and the posterior ligaments are stretched, but in extension the gliding takes place in an opposite direction.

The occipito-atlantal articulation is deprived of the power of rotation by the direction of the condyles, which mutually obstruct this movement. In birds, which have only one condyle, the articulation of the head admits of very extensive rotation. In the human subject there is a slight movement of rotation at this joint, when the head is previously inclined upon one of the condyles, which then serves as a pivot.

Mechanism of the Atlanto-axoid Articulation.

In the movements of this articulation, we should regard the atlas and the head as forming only one piece. There are no movements either of flexion or extension. The inclusion of the odontoid process in the syndesmo-atlantal ring prevents even the slightest motion of the atlas, either forward or backward; for in the forward motion, or flexion, the atlas is fixed by the transverse ligament, which presses upon the odontoid process; and in the backward motion, or extension, the atlas is fixed by its own anterior arch, which is brought in contact with the same obstacle. There is, moreover, no lateral inclination at this joint, for this is prevented by the odontoid ligaments. Rotation is, therefore, the only movement which remains. In this motion, in which the head describes the arc of a large circle upon the vertebral column, the syndesmo-atlantal ring turns upon the axis as a wheel upon its axle. Of the two plane surfaces of this joint, one glides forward, and the other backward; one of the odontoid ligaments is stretched, and the other relaxed. These ligaments, it should be observed, limit the extent of rotation, which explains the necessity for their great strength; but, great as this is, their resistance is occasionally insufficient, and the odontoid process breaking one of them, slips below the transverse ligament, and occasions death by compressing the spinal cord, Luxation, therefore, of this articulation is to be dreaded, not merely for the same reasons as other dislocations, but as being a cause of compression of the spinal marrow.

The entire movement by which the face is turned to either side should not be attributed to this articulation alone, for it extends to the fourth of a circle on each side, and such a degree of motion would dislocate the articular surfaces of the atlas and the axis.

ARTICULATIONS OF THE CRANIUM.

All the bones of the cranium are united together by synarthroses. We have here to examine, as in all other articulations, 1. The articular surfaces; 2. The means of union. As the bones of the cranium form a complete cavity, closed in every direction, they unite by their entire circumferences or by their edges; and as the solidity of joints is in a direct ratio to the extent of the articular surfaces, the bones of the cranium, which are only in contact by their edges, would have been very slightly connected, had it not been for the following provisions: 1. The cranial bones are generally thicker at the circumference than in the centre; 2. They are almost all provided with marginal denticulations that multiply three or four fold the points of contact; 3. The edges, instead of being cut perpendicularly, are bevelled so as to overlap each other, and thereby present much more extensive corresponding surfaces; 4. We should observe, also, the number of projecting and retreating angles that are formed by these bones; and, 5. The sinuous arrangement of their edges, all of which arrangements are most favourable to the increase of solidity.

We should remark, however, that these different modes of ensuring solidity are not employed indiscriminately over the whole scull. In the vault of the cranium, for example, firmness is attained by the mutual adaptation of the serrated margins of the bones at the upper and at the back parts, and by their overlapping at the sides; in the base, on the contrary, the solidity chiefly depends upon the breadth of the contiguous surfaces, and upon the reception of projecting into corresponding retreating angles. Examples of this double arrangement may be seen in the articulation of the occipital and sphenoid bones, which is accomplished by means of broad surfaces, and in the articulation of the projecting angle formed by the petrous portion of the temporal bone with the retreating angle formed by the occipital bone behind and the sphenoid in front.

This description will suffice to give a general idea of the mode of union between the bones of the cranium. It would evidently exceed the limits of this work to dilate upon the form of each of the sutures, and to follow Monro in distinguishing fourteen or fifteen different kinds. Nevertheless, we do not think a few words regarding the principal forms of the indentations will be out of place. We would therefore observe, that the tooth-like projections are sometimes four or five lines in length, and are themselves indented on their edges, secondary denticulations being thus formed. They are generally straight, but are sometimes alternately bent towards the external and the internal surface. Some of the teeth are, as it were, pediculated, and are enclosed between the others, thus holding a middle place between the Wormian bones and the ordinary denticulations.

We should remark that the name suture, properly speaking, belongs more especially to those sutures in which the bones are dovetailed; that those sutures, the uniting surfaces of which are broad and oblique, are generally called squamous; and that the *suturæ harmoniæ* are those in which the indentations are scarcely perceptible. We must also observe, 1. With regard to the sutures, that their indentations are much deeper on the external than on the internal surface of the bones of the cranium; 2. With regard to those sutures which are bevelled, that they often present alternate oblique sections, having opposite directions, so that of two bones, the one that overlaps the other at one part of the suture is, at another part, itself overlapped: of this we have an example in the fronto-parietal suture.

Means of Union of the Bones of the Cranium.

We have remarked, in speaking of the development of the bones, that those which are subsequently united by immovable articulations are formed in a piece of cartilage that is common to them all. Portions of this cartilage, not yet encroached upon by ossification, serve as the uniting media. It is evident, therefore, that these cartilages of the sutures are broader when the amount of ossification is less, viz., in the earlier periods of life. The pericranium, on the outside, and the dura mater, on the inside, although they adhere more firmly to the bones along the lines of the sutures, cannot to any considerable extent contribute to strengthen the union of the bones of the cranium.

Mechanism of the Cranium.

While the vertebral column performs four offices, 1. A cylinder or canal of protection; 2. A column of support; 3. The central lever of locomotion; and, 4. An organ movable on itself in its different parts, the cranium only performs two: 1. An organ of locomotion; 2. An organ of protection. As an organ of locomotion we have already fully studied it, when examining the movements of the vertebral column, and, consequently, it only remains for us to examine its mechanism as protecting the nervous mass which it encloses.

The cranium is nothing more than a bony envelope added to the fibrous one which encloses the brain, and is exactly moulded, on its inner surface, to the external surface of the organ it encloses. Before its complete ossification, the cranium may experience an enlargement or diminution in size in proportion as the organ it contains is enlarged or diminished in volume; but so soon as its ossification has been completed, its capacity is independent of the volume of the brain. If that organ is atrophied, the vacancy is filled up by serous fluid; if hypertrophied, a fatal pressure is the consequence. The statements which have been made by some, that the capacity of the interior of the cranium increases in men of genius, and that the head of Napoleon increased wonderfully in size during the progress of his reign, we consider as mere vagaries of the imagination. As the cranium encloses the brain, it is evident that any motion between the bones which form this case would be attended with fatal consequences. They are, therefore, immovably articulated to each other. It might be supposed that this solidity could have been better secured, had the brain-case been formed of one instead of a number of bones. But, independently of the other important objects obtained by its being made up of a number of separate pieces, its power to resist fractures is increased by this arrangement, seeing that forces applied to it, in being transmitted through its different articulations, are weakened, and operate much less violently than they would have done without this arrangement.

What has been said above of the immobility of the bones of the cranium is not equally true at all periods of life. During fœtal existence, and the first few years after birth, the intervals between the bones of the cranium are occupied by a flexible, cartilaginous substance, which permits those of the roof to move pretty extensively upon each other. Since, therefore, the conditions of solidity are not the same at this period as in the adult, we must examine the mechanism of the cranium both in the fœtus and in the adult.

1. In the fœtus, the conditions of solidity must be studied both in the roof and in the base of the cranium.

In the roof of the cranium, the incomplete ossification allows the bones to move upon each other, and in this respect the encephalon is imperfectly protected. But, on the other hand, the presence of these cartilaginous intervals diminishes the momentum of a violent force applied to the cranium, and thus prevents, in some degree, both fractures of the cranium and concussions of the brain. The mobility of the bones is principally displayed at birth, in their overlapping, when the head of the fœtus is passing through the pelvis. The base of the cranium is incompressible at the same period, and the bones are immovable, because ossification has so far advanced that they are only separated by very thin layers of cartilage. This arrangement is well adapted for the protection of the most important parts of the encephalon, which are in the vicinity of the base of the cranium.

2. In the adult, the roof and the base of the cranium form one piece. The roof being most exposed to violence, we shall examine the mechanism of resistance in the cranium to blows directed vertically upon the top of the head; and it will be easy to apply what is said in explanation of the effects of a force so directed, to cases in which violence is applied in other directions.

The effects which may be presumed to follow a violent blow on the top of the scull, are, 1. Concussion of its bony parietes, succeeded by their elastic reaction; 2. Disjunction of the pieces entering into the formation of the scull; and, 3. Fracture of those pieces. We shall examine the method in which these results may be produced.

1. *Concussion and Compression of the Cranium without Fracture.*—The cranium may be looked upon as a hollow sphere, endowed with a certain degree of elasticity, depending partly upon the osseous tissue itself, and partly upon the cartilaginous laminæ which separate the bones; and it cannot, therefore, be doubted that, from pressure, or violent blows on the top of the head, the scull may undergo a flattening, and then recover its original condition, like a hollow ball of ivory when struck vertically. The truth of this explanation may be shown at once by projecting a scull against a resisting surface, when it will be found to rebound like an elastic ball. However slight this flattening may be, and the recovery which follows it, the known laws of physics will not allow us to deny its possibility.

2. *Tendency to Disjunction of the Bones of the Cranium.*—This separation has never been observed as the consequence of external blows. The following is the manner in which displacement is prevented in cases of blows on the top of the head. It is evident that violence applied in this direction would have a tendency to depress the upper edge of the parietal bones; but this cannot take place without forcing the lower edge outward; and as, from the peculiar formation of the squamous suture, the parietal bones are overlapped by the temporal and the sphenoid, this edge cannot be driven outward without giving the temporal bones such a motion as will tighten the articulations of the base of the cranium. All these articulations are remarkable in this respect, that the projecting angles of some of the bones are received into the retiring angles of others. This is exemplified in the articulation of the petrous portion of the temporal bone with the sphenoid and the occipital bone, and in the basilar process of the occipital bone with the two temporals and the sphenoid. The result of all these arrangements is, that blows upon the top of the head, instead of separating the bones of the cranium, tend to render their union still closer.

3. Another effect of blows on the top of the head may be fracture of the cranial bones; and it will be impossible to comprehend the nature of many of these fractures, without a knowledge of the following points of structure: 1. The cranium is of unequal thickness in different parts. This circumstance explains how a round body, striking the cranium in a spot of sufficient strength to resist the impulse, may cause a fracture of a more or less distant part, where the parietes are thinner, and consequently weaker. It may be conceived that this kind of fracture may take place either in the bone struck, or in other bones, and that it may affect the internal table only, the external remaining uninjured. 2. The cranium is so constructed, that a shock impressed upon the top is concentrated at the base, being propagated on the sides to the temporal bones and their petrous portions, as well as to the great wings of the sphenoid and the body of that bone; behind, by the occipital bone to the basilar process and the body of the sphenoid; and in front, by the frontal bone and the roof of the orbits, to the smaller wings and body of the sphenoid. It will thus be seen how blows upon various parts of the scull may concentrate their effects upon the base of the cranium; and this explains the production of fractures at the base, in consequence of violence inflicted on the roof of the scull. 3. Most of the cranial bones are bent and angular. This disposition, which is observed at the union of the orbital and frontal portions of the frontal bone, and at the junction of the squamous and petrous portions of the temporal bone, explains how these bones may be broken by the transmission of shocks from the roof. For we may conceive, when violence is applied to a bone which is bent at an angle, that this angle will be the seat of a decomposition of the force, one portion of which is transmitted to the part of the bone below the angle, while the remaining portion acts against the angle itself in the original direction, and may thus determine a fracture of that part of the bone.

Although the roof of the cranium is most exposed to injury, yet some parts of the base may be reached by penetrating weapons, as the roof of the orbits and the cribriform plate of the ethmoid. It should be remarked, also, that these are the thinnest parts of the scull.

Articulations of the Face.

The articulations of the face comprise those of the upper and of the lower jaw.

Articulations of the Bones of the Superior Maxilla with each other, and with the Cranium.

All these articulations are sutures, but they have not such large indentations as the bones of the cranium; almost all are united by harmonia or juxtaposition. At the same time, it should be remarked that a true dovetailing exists in these articulations, as may be seen in the junction of the superior maxillary bones (the fundamental articulation of the face), which is effected by means of thick furrowed surfaces, mutually and firmly adapted to each other.

No suture in the whole scull is stronger than that between the malar and the maxillary bones; indented sutures are most common on the sides of the face. The manner

in which the vertical portion of the palate bone is received into the furrow in the opening of the maxillary sinus, affords an illustration of the suture by reception. There are some well-marked indentations in the articulations of the bones of the face with those of the cranium; as in the articulation of the nasal bones; of the ascending processes of the superior maxillæ; and of the malar bones with the frontal; in that of the sphenoid with the malar bones; and of the latter with the zygomatic processes of the temporal bones. Simple juxtaposition is met with in the junction of the ethmoid with the roof of the orbit; of the palate bone with the pterygoid processes; and of the vomer with the ethmoid; but there is a mutual reception in the articulation of the vomer with the sphenoid.

With regard to the means of union, in addition to the firm union resulting from the configuration of the articular surfaces, there is also a thin layer of cartilage, continuous with that which formed the matrix of the bones, and which is itself afterward obliterated during the progress of ossification.

Mechanism of the Articulations of the Upper Jaw.

As the mechanism of the face is adapted both to resist force applied from below through the medium of the lower jaw, and also the effects of external violence, it is necessary to analyze the conditions of solidity resulting from the configuration of the upper jaw; and in order to appreciate these correctly, we must analyze the framework of the face.

The upper jaw, considered as a whole, forms inferiorly a sort of parabola, circumscribed by the alveolar border, which is the strongest part of the bone, and receives the direct impulse of the lower jaw; it curves backward, and forms the roof of the palate, which gradually diminishes in thickness; and, not receiving the impulse of the lower jaw directly, its construction is not so solid as the alveolar border. The upper jaw becomes broader and flattened above, and separates into different parts or prolongations, which, after enclosing certain openings, unite with the cranium by means of several processes, that form, as it were, so many columns for resisting any impulses transmitted from below.

These columns are, 1. The fronto-nasal, constituted on each side by the ascending process of the superior maxillary bone. These columns, which correspond to the canine teeth, are remarkably strong in carnivorous tribes; and to their great size may be attributed the lateral position of the orbits in these animals. The interval between these columns is occupied above by the nasal bones; but an opening is left between them, below, shaped like a heart on playing cards. The whole of that portion of the alveolar edge situated beneath this opening is weaker; but it should be remarked, that it corresponds to the incisor teeth, which, being adapted for cutting, divide instead of bruising or tearing the food, and are, consequently, not subject to such powerful efforts as the canine and molar teeth.

2. The second pair of columns is formed by the malar eminences, which are continuous with the alveolar border, by the vertical ridge separating the canine from the zygomatic fossa. These columns, which correspond to the second great molar teeth, may be called the zygomato-jugal, because they are subdivided into two other secondary columns, the vertical, malar, or jugal, and the horizontal or zygomatic. The *jugal columns* are much stronger than the fronto-nasal, and are continuous with the external orbital processes of the frontal bone, and with the anterior thick and indented edges of the great wings of the sphenoid: the second, or horizontal, articulate with the zygomatic processes of the temporal bones, and with them constitute the *zygomatic arches*. From this arrangement, it may be understood how effectually the bevelling of the end of the zygomatic process that rests upon the malar bone is adapted for resisting impulses communicated from below. The zygomatic arches, also, form props that oppose all transverse displacements. The mode of articulation of the zygomatic processes with the malar bones is such, that the zygomatic arches, although horizontal, are well calculated to resist any force from below. In carnivora, where there are no jugal columns, the zygomatic arches are enormously large.

The fourth pair of columns are the *pterygoid*, intended to support the face in the antero-posterior direction, being articulated with the maxillary bones through the medium of the palate bones; these also oppose any displacement upward, and, moreover, serve to support the back part of the alveolar border.

There are, therefore, four pairs of columns, viz., the *fronto-nasal*, the *jugal*, the *zygomatic arches*, and the *pterygoid columns*. They are almost entirely composed of compact tissue. The principal columns are situated immediately above the first great molares, where the jugal, zygomatic, and pterygoid columns are concentred, and where the most violent impulses are received. The fronto-nasal columns correspond to the canine teeth; their strength is proportioned to that of these teeth, and hence, in carnivorous animals, the ascending processes of the superior maxillæ are very large and thick. The fronto-nasal and jugal columns are near each other below, and only leave a small space between them, which is occupied by the two small molares; but they are separated to a considerable distance above, and enclose the orbital fossæ.

In this manner the deep fossæ in the face are formed without being prejudicial to its strength. Even the maxillary sinus does not much diminish the solidity of the face,

because it is situated in the interval between the columns, and because only a small portion of it corresponds to the alveolar border.

These details will suffice to show that the upper jaw has been framed to resist external impulses, but especially forces communicated from below by the lower jaw; that the alveolar border, being intended to receive the impulse directly, is most strongly constructed; that the whole force applied to the upper jaw is transmitted by the fronto-nasal columns to the internal orbital processes, by the malar columns, partly to the external orbital processes, and partly to the zygomatic arches, and by the palate bone to the pterygoid columns of the sphenoid; that the vomer transmits little or nothing either to the ethmoid or the sphenoid; and that the cranium, on its part, opposes very unyielding structures to the sustaining pillars of the face. To forces directed from before backward, the zygomatic arches and the pterygoid processes offer great resistance; against lateral violence each malar bone resists like an arch, and transmits the impulse it has received to the superior maxillary bone, the frontal and the sphenoid. The greatest part of the impulses communicated to the face are then ultimately transmitted to the cranium; and were it not for the multiplicity of its constituent parts, and the great number of articulations which absorb part of the force, the brain contained within it would be frequently exposed to dangerous violence. The upper jaw is concerned in the process of mastication merely as a means of support; for though it may be raised when the mouth is opened, and depressed when the mouth is shut, these movements belong to the entire head, and result from the action of its extensor muscles, which thus become powerful auxiliaries of mastication in the carnivorous animals.

Temporo-maxillary Articulation (*figs.* 65, 66, and 67).

This joint, the centre of all the movements of the lower jaw, is a double *condyloid articulation*. The *articular surfaces* are, 1. The two condyles of the lower jaw, transversely oblong, and directed somewhat obliquely inward and backward, so that their axis, if prolonged, would intersect behind: 2. The glenoid cavity of each temporal bone, and the transverse root of its zygomatic process. These surfaces are covered with cartilage.

The glenoid cavity is remarkable both for its depth and its capacity. Its depth is increased by several eminences on its borders: viz., on the inside, by the spine of the sphenoid; and behind, by the styloid and the vaginal processes, the latter of which is nothing more than the anterior lamina of the auditory meatus. The capacity of the glenoid cavity is no less remarkable, being double or triple that which would be necessary to receive the condyle; moreover, the whole of this cavity is not articular, the part situated behind the glenoidal fissure being extraneous to the joint. This disproportion between the cavity and the condyle is only observed in man and in ruminantia: in rodentia and carnivora, the one is exactly proportioned to the other. The portion of the glenoid cavity posterior to the fissure affords an example of those *supplementary cavities* that, in certain circumstances, increase or replace the principal cavity. All that part of the glenoid cavity situated anteriorly to the fissure belongs to the joint, and is, therefore, covered with cartilage.*

The *transverse root* of the zygoma, convex from before backward, and concave transversely, is also articular, and covered by a cartilage, which is a continuation of that lining the glenoid cavity. This articulation presents the only example in the body of two convex surfaces moving upon each other.

The means by which motion is facilitated and union maintained in this articulation are an inter-articular cartilage, an external lateral ligament, and two synovial membranes; the internal lateral ligament of some authors, and the stylo-maxillary ligament, do not belong to this joint.

1. *Inter-articular Cartilage* (*a*, *fig.* 65).—This cartilage is interposed between the articular surfaces; it is thick at the circumference, and sometimes perforated at the centre, and resembles a bi-concave lens, with this peculiarity, that its upper surface is alternately convex and concave, to correspond with the glenoid cavity and the transverse root of the zygoma; while the lower surface is concave, and adapted to the condyle. Its circumference is free, excepting on the outside, where it adheres to the external lateral ligament, and on the inside, where it gives attachment to some fibres of the external pterygoid muscle. This circumstance is of great importance in regard to the mechanism of the joint. The existence of an inter-articular cartilage in a joint which is subjected to such considerable pressure, and is so often put in motion, agrees with the general law already pointed out. (Vide THE ARTICULATIONS IN GENERAL).

Fig. 65.

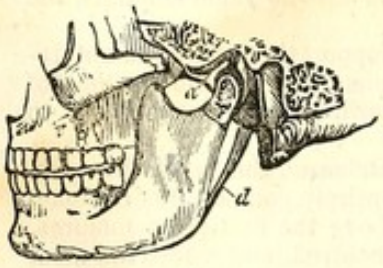

* The study of the condyle and the glenoid cavity is of very great importance in comparative anatomy; for by the characters which they present, we may easily recognise the head of one of the rodentia, carnivora, or ruminantia. 1. In carnivora, the condyles are transversely oblong, the long axes of both being in the same line; they are received into very deep cavities. 2. In rodentia, on the contrary, the long diameter of the condyles is directed from before backward. 3. In ruminantia, the glenoid cavity is flat, as well as the head of the condyle, while the transverse root of the zygoma is scarcely discernible.

2. *External Lateral Ligament* (*b*, *fig.* 66).—This ligament extends from the tubercle situated at the junction of the two roots of the zygoma to the outside of the neck of the condyle: it is directed obliquely downward and backward, and forms a thick band covering the whole of the outside of the articulation: it is in contact with the skin externally, and internally with the two synovial capsules, and the inter-articular cartilage.

Fig. 66.

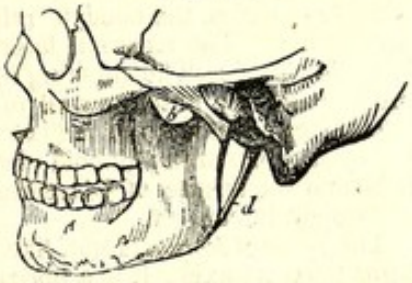

Anatomists have described, under the name of the *internal lateral* or *spheno-maxillary ligament* (*c*, *fig.* 67), an aponeurotic band, which, neither as regards its position or its use, can be considered as properly belonging to the joint; it is extended from the spinous process of the sphenoid to the spine situated on the inside of the orifice of the inferior dental canal. It is a very thin band, which covers the inferior dental vessels and nerves, and separates them from the pterygoid muscles. Since the band just described has no effect in giving strength to the joint, it may be wondered that there is only one ligament for the articulation; but it should be observed that, as the lower jaw is articulated in the same manner at both its extremities, the external lateral ligament of the one exactly performs the functions of an internal lateral ligament to the other.

Fig. 67.

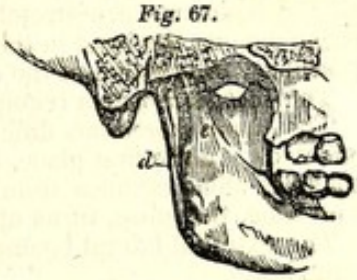

The *stylo-maxillary ligament* (*d*, *figs.* 65, 66, and 67) appears to me to hold the same place as the preceding; it is a fibrous band extending from the styloid process to the angle of the inferior maxilla. It has no relation to the union of the articular surfaces. Its use appears to be that of giving attachment to the stylo-glossus muscle. Meckel calls it the stylo-mylo-hyoid ligament.

3. There are two synovial capsules in this joint, one on the upper and the other on the lower surface of the inter-articular cartilage (see *fig.* 65). Sometimes they communicate by an opening in the cartilage; the superior is looser than the inferior; and thus the articular cartilage is more closely united to the condyle of the lower jaw than to the glenoid cavity.

These two synovial capsules are in contact on the outside with the external lateral ligament, and elsewhere with a thin layer of fibrous tissue.

Mechanism of the Temporo-maxillary Articulation.

In considering the action of this joint, the lower maxilla may be regarded as a hammer which strikes against the anvil represented by the upper jaw; it is a double angular lever, the axis of its motion being represented by a horizontal line that would pass through the middle of the rami. This articulation, which belongs to the class of condyloid joints, has been ranged among the angular ginglymi, on account of the great extent of its movements in two opposite directions, during its elevation and its depression; but it differs from them in being so constructed as to admit of slight lateral movements. It can also be moved forward and backward.

1. *Depression.*—In this movement each condyle rolls forward in its glenoid cavity, and then passes upon the transverse root of the zygoma, with a sudden jerk, which may be easily felt by placing the finger on the condyle while the mouth is being opened; at the same time the angle of the jaw is moved backward. The condyle carries with it the inter-articular cartilage; for the union of these two parts is of such a nature that, even in dislocation of the jaw, they are never separated. This depends not only upon the comparative tightness of the lower synovial capsule, but also on the mode of insertion of the external pterygoid muscle, which, being attached both to the neck of the condyle and the inter-articular cartilage, acts simultaneously upon them. The other parts of the joint are affected in the following manner: During depression of the lower jaw, the external lateral ligament is stretched; the upper synovial capsule is distended behind, but readily yields on account of its laxity. The spheno-maxillary band, or internal lateral ligament, which is inserted at an almost equal distance from the condyle, which is carried forward, and from the angle of the jaw, which is carried backward, remains unaltered, being neither stretched nor relaxed.

When the depression is carried too far, either from the effect of a blow upon the bone, or during a convulsive yawn, the condyle is dislocated into the zygomatic fossæ, tearing the superior synovial capsule, and carrying with it the inter-articular cartilage.* This mode of displacement is impossible in the infant; for, from the obliquity of the ascending ramus of the jaw, the upper part of the condyle looks backward, and, in order to be

* This luxation would be much more common were it not for the inter-articular cartilage, which, by always accompanying the condyle, presents a smooth surface, over which the latter may glide in returning into its proper cavity.

luxated forward, would have to traverse a much larger space than it does even when the mouth is opened to the greatest possible extent.

2. *In elevation*, the condyle rolls backward, upon the transverse process, into the glenoid cavity. The external lateral ligament is relaxed. The obstacles to too great an elevation are, 1. The meeting of the dental arches. 2. The presence of the vaginal process and the anterior wall of the auditory meatus; and it is very probable that the extensive movements of the jaw in the old subject, when the teeth are lost, are permitted by the size of the glenoid cavities. Without that portion of the glenoid cavity which is behind the fissure of Glasserus, the toothless alveolar edges of the aged could never be brought in contact.

The *forward motion* is not, like the preceding, the motion of a lever in which the jaw turns upon its axis; it is a horizontal movement, in which the condyle is brought under the transverse root of the zygoma. A preliminary and indispensable condition to this movement is a slight depression of the whole of the lower maxilla. In this movement all the ligaments are stretched; if it were carried too far, the coronoid process would strike against the bone in the zygomatic fossa, and this circumstance would prevent the possibility of luxation of the condyle.

The *backward motion* requires no special remark.

The *lateral movements* differ from the preceding in the mechanism by which they are effected. In the first place, the whole bone does not move from its place. One of the condyles alone escapes from its socket, while the other remains in the glenoid cavity. The bone, therefore, turns upon one of the condyles as on a pivot.

The external lateral ligament of that articulation in which the condyle moves is much stretched.

The lateral motions would have been much more extensive had not the two condyles mutually obstructed each other in all movements but that of depression, by reason of their opposite directions. This may be shown by sawing a maxilla through the middle, and moving each of the halves. Moreover, the styloid and vaginal processes, and the spine of the sphenoid, prevent displacement inward.

Articulations of the Thorax.

The articulations of the thorax comprehend, 1. The costo-vertebral articulations; 2. The chondro-sternal; 3. The articulations of the cartilages of the ribs with each other; 4. The junction of the cartilages and the ribs.

The Costo-vertebral Articulations (*figs.* 58 to 60, and 68).

Preparation.—Saw the ribs across at their posterior angles. Remove with care the pleura and the subjacent cellular tissue in front, and the muscles of the vertebral grooves behind. After having studied the superficial ligaments, expose, 1. The costo-transverse interosseous ligament by a horizontal section of the rib, and the transverse process to which it is attached; 2. The costo-vertebral interosseous ligament by a similar horizontal section, including one vertebra and one rib, and passing above the angular part of the joint. This last ligament may be also exposed by a vertical section of the rib and the two vertebræ with which it is connected. The costo-vertebral articulations have some characters which are common to them all, and others that are peculiar to a few.

General Characters of the Costo-vertebral Articulations.

Articular Surfaces.—In this joint, the head of the rib is applied to the angular surface formed by the two half facettes (*f f*, *fig.* 58) upon the sides of the bodies of the dorsal vertebræ, so that each rib is articulated with two vertebræ (*costo-vertebral articulation, properly so called*); and, in addition, the tubercle of the rib is applied to the facette (*g*, *figs.* 58, 60, and 68) on the fore part of the transverse process (*costo-transverse articulation*).

With regard to the costo-vertebral articulation, it is to be remarked, 1. That it affords an example of a projecting angular facette received into a retreating angular facette, which has given rise to the mistaken notion that this joint is an angular ginglymus; and, 2. That in each articulation the lower half facette is twice as large as the upper.

The surfaces of the costo-transverse articulation are, a convex facette belonging to the tubercle of the rib, and a concave one belonging to the tranverse process. Sabatier affirms that the articular surfaces of the transverse processes look forward and upward in the upper vertebræ, and forward and downward in the lower, and directly forward in those which occupy the middle of the column. This arrangement has been referred to in explanation of the mechanism of the dilatation of the thorax, by depression of the lower, and elevation of the upper ribs; but this explanation is unfounded.

In addition to the costo-vertebral and costo-tranverse articulations, the neck of the rib (*c*, *fig.* 68), without being in immediate contact with the tranverse process, is, in some degree, united with it by symphysis.

Means of Union.—These joints are examples both of symphysis and arthrodia. Some of the ligaments are external to the articulation, the remainder are interosseous.

The ligaments external to the articulation are, the anterior costo-vertebral or stellate lig-

ament, the superior and the inferior ligaments, the posterior costo-transverse, and the superior costo-transverse.

1. *The anterior costo-vertebral*, or *stellate ligament* (*l*, *fig.* 58), arises from the two vertebræ with which the rib is connected, and from the corresponding intervertebral substance. From these points its fibres converge, and are inserted in front of the extremity of the rib.

2 and 3. Besides the stellate ligament there are two small ligamentous bundles, a *superior* and an *inferior*, which extend from each of the vertebræ, concurring to form the articulation, to the extremity of the rib.

4. The *posterior costo-transverse ligament* (*m*, *fig.* 59 : *transverse ligament* of Boyer, *posterior costo-transverse ligament* of Bichat) is a fibrous band stretched from the apex of the transverse process, in an oblique direction, to the non-articular portion of the tubercle of the rib.

5. The *superior costo-transverse ligament* (*n*, *figs.* 58, 59 : *costo-transverse* of Boyer, *inferior costo-transverse* of Bichat) consists of a band, which arises from the lower edge of each transverse process, passes obliquely, and is inserted, not into the rib, which articulates with that process, but into the upper edge of the neck of the rib below. At the place of this insertion, we always find a crest or spine. This ligament is sometimes divided into two or three bundles ; it forms the continuation of a thin aponeurosis, which covers the external intercostal muscle, and completes the external wall of the opening through which the posterior branches of the intercostal vessels and nerves are transmitted. This ligament is interposed between the anterior and posterior branches of these vessels and nerves.

The *interosseous ligaments* are two in number. 1. A costo-vertebral interosseous ; 2. A costo-transverse interosseous.

1. The *costo-vertebral interosseous ligament* (*o*, *fig.* 58) is a small bundle of fibres, very short and very thin, extending horizontally from the projecting angle on the head of the rib to the retreating angle of the vertebral facette, where it is continuous with the intervertebral substance.

2. The *costo-transverse interosseous ligament* (*a*, *fig.* 68) is formed by some ligamentous bundles intermixed with reddish adipose tissue, which stretch from the anterior surface of the transverse process to the posterior surface of the neck of the rib. An idea of the strength of this ligament may be formed by attempting to separate the rib from the transverse process, after the anterior costo-vertebral and the posterior costo-transverse ligaments have been divided.

Fig. 68.

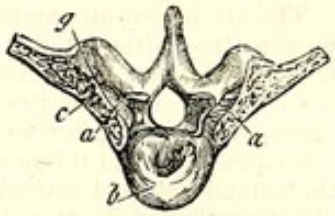

There are three *synovial capsules* in the articulations of the ribs with the vertebræ : one between the tuberosity and the transverse process, and two small ones for the two surfaces which are separated by the costo-vertebral interosseous ligament.

Characters peculiar to certain Costo-vertebral Articulations.

The articulations of the first, eleventh, and twelfth ribs alone present peculiarities.

1. *Costo-vertebral Articulation of the First Rib.*—The rounded head of the first rib is received into a cavity on the side of the body of the first dorsal vertebra ; the articulation is, therefore, a species of enarthrosis ; there is neither a costo-vertebral interosseous ligament, nor a superior costo-transverse ligament ; the synovial membrane is much looser than in the corresponding articulations.

2. The *costo-vertebral articulations of the eleventh and twelfth ribs* present the same characters as the preceding in this respect, that the articular cavity for the head of the bone is situated upon one vertebra alone. The head of the rib is flattened, or very slightly convex, and there is no interosseous costo-vertebral ligament. The superior costo-transverse ligament is much broader and stronger than in the other articulations. As the eleventh and twelfth ribs have no tuberosities, and the transverse processes of the corresponding vertebræ are but little developed,* it follows that there is no costo-transverse articulation ; but yet there is a costo-transverse interosseous ligament. All these ligaments are much more loose than in the other articulations.

The Chondro-sternal Articulations (*fig.* 69).

There are seven in number on each side, formed by the internal angular end of the cartilages, which are received into the angular cavities on the side of the sternum. The means of union are, 1. A *radiated* or *anterior chondro-sternal ligament* (*a*, *fig.* 69), which is tolerably strong : it crosses in the median line with the corresponding ligament of the opposite side, and is blended both with the periosteum and the aponeurotic insertions of the greater pectoral muscles, in the thick fibrous layer which covers the sternum ; 2. Two small ligaments, a *superior* and an *inferior* ; 3. A *radiated* or *posterior chondro-sternal ligament*, much weaker than the anterior. The existence of a synovial membrane is

* Sometimes, however, the transverse process of the eleventh dorsal vertebra is enlarged, and articulated to the eleventh rib.

merely inferred from analogy, for it cannot be demonstrated. (*Vide* ARTICULATIONS IN GENERAL.)

The first, second, sixth, and seventh chondro-sternal articulations present some peculiarities. 1. The cartilage of the first rib is sometimes continuous with the sternum, and is sometimes articulated like the cartilages of the other ribs. I found in one subject the first rib excessively movable, because its cartilage, instead of being continuous with the sternum, had its upper edge applied to the side of that bone to which it was united by ligaments, and was ultimately articulated by a narrow extremity immediately above the second rib. 2. The second cartilage (*b*) is much more angular at its inner extremity than any of the others; it is received into the retreating angle formed by the union of the first two pieces of the sternum. Sometimes there is an interosseous ligament in this joint, running from the angle of the cartilage to the bottom of the cavity, and there are then two synovial capsules: in other cases there is only one (*c*), but it is always more marked than in the other joints. 3. The articulations of the sixth and seventh cartilages, besides the anterior ligaments, have also a *chondro-xiphoid ligament* more or less strong, which crosses with the ligament of the opposite side in front of the ensiform cartilage and the lower end of the sternum. Sometimes this ligament only exists for the seventh cartilage; it is intended not only to strengthen the chondro-sternal articulations, but also to maintain the xiphoid appendix in its place.

The Chondro-costal Articulations.

The cartilages are immovably united to the ribs; the anterior extremity of the rib is hollowed to receive the external end of the cartilage: there is no ligament. The periosteum is the only bond of union between the costal cartilage and the rib, as in the articulations of the cranial bones.

The Articulations of the Costal Cartilages.

The first, second, third, fourth, and fifth costal cartilages do not articulate together, unless the aponeurotic laminæ, sometimes very strong, which form the continuation of the external intercostal muscles, and occupy the whole length of the cartilages, be considered as uniting media.

The sixth, seventh, and eighth cartilages, frequently the fifth, and sometimes the ninth, present true articulations. Some cartilaginous processes arise from the neighbouring edges, and come in contact with each other: there are sometimes two articular facettes between the sixth and the seventh cartilages. The means of union are some vertical fibres united in bundles so as to form two ligaments, the one anterior and thicker, the other posterior and thinner. There is a much more distinct synovial membrane than in the chondro-sternal articulations. The seventh, eighth, and tenth cartilages have not always articular facettes, but are simply united by vertical ligaments.

Mechanism of the Thorax.

As the thorax performs the double office of protecting the organs which it encloses, and of assisting by its movements in the function of respiration, we must consider its mechanism with reference to both these ends.

Mechanism of the Thorax for the Protection of the contained Organs.

1. The following is the mechanism by which the thorax is enabled to resist pressure or violent blows directed from before backward. The sternum is supported by the fourteen ribs, which, like buttresses, oppose their united strength to any causes of displacement or fracture; it is therefore very rare to find the sternum driven backward, and all the ribs broken, however great the violence may have been. The elasticity of the cartilages and of the ribs, and the number of articulations which exist in the thorax, are all circumstances most favourable to strength, because they diminish the intensity of external blows by neutralizing a certain amount of impulse: yet I have met with one case in which all the sternal ribs were broken by a fall, as completely as if the anterior wall of the thorax had been divided for an anatomical preparation. I should remark, also, that the flexibility of the ribs and their cartilages permits great depression of the sternum without fracture; and this explains the possibility of contusion, and even rupture of the heart, lungs, or great vessels, without fracture of the bones of the thorax. The degree of resistance of the anterior wall of the thorax may be also considerably varied by the state of relaxation or contraction of the muscles, which should be considered as active and contractile supports to the arch, of which the sternum forms the key-stone.

2. In the case of lateral pressure or blows, the thorax resists, like an arch, the vault of which is represented by the convexity of the twelve ribs, and its pillars by the sternum in front and the vertebræ behind. External violence cannot act upon the whole side of the chest at once, as it does upon the front, and therefore the ribs offer a more partial resistance laterally, and are accordingly much more easily broken by direct blows. In this case, also, as in the former, when the elevator muscles of the ribs are in action, the resistance is considerably increased; and individuals have been then able to bear

enormous weights, which would, in all probability, have fractured the ribs, had the muscles been relaxed.

What has been said above of the manner in which the ribs withstand violence is not, however, applicable to the false ribs, which, having no fixed point on the sternum, are depressed into the abdominal cavity.

Mechanism of the Thorax with reference to Mobility.

The thorax is not equally movable throughout. The middle portion, which corresponds to the heart, and which is formed by the sternum and vertebral column, has a very limited degree of mobility, while the sides which correspond to the lungs are endowed with the power of extensive motion.

The movements of the thorax consist of alternate dilatations and contractions, from which its mechanism has been compared to that of a pair of bellows. They result from the motions which take place at the costo-vertebral and chondro-sternal articulations, and at the articulations of the cartilages with each other. We cannot explain the movements of each rib, and of the entire thorax, without first analyzing the motions at each of the above joints.

Movements of the Costo-vertebral Articulations.

These articulations permit only very limited gliding motions. In these movements, each rib represents a lever, which moves upon the fulcrum afforded by the vertebral column. It may describe the movements, 1. Of elevation; 2. Of depression; 3. It may be carried inward; 4. It may be carried outward; 5. It may perform a revolving motion around the cord of the arc which it represents. These different movements, which are very obscure in the immediate neighbourhood of the joint, are more evident the greater the distance is from the posterior end of the rib. The means of union between the ribs and vertebræ are so strong, that luxation of the ribs is impossible; and the causes which would tend to produce it would break the neck of the rib.

Each rib is capable of performing all these motions; but, as they vary in degree in the different ribs, we must examine them comparatively in the series of costo-vertebral articulations. The eleventh and the twelfth ribs possess the most extensive power of motion. They owe this, 1. To the circumstance of their being scarcely at all united to the very small transverse processes; 2. To the loose state of their ligaments; and, 3. To the almost perfect flatness of their articulated surfaces. The extent of their movements inward and outward should also be noticed. We shall find these movements but less pronounced, in the eighth, ninth, and tenth ribs, they scarcely exist in the first seven ribs.

The shape of the head of the first rib is undoubtedly favourable to mobility, and has suggested the idea that it is the most movable of all the ribs; but the articulation of its tubercle with the transverse process of the first dorsal vertebra, and the tightness of its ligaments, sufficiently explain why this opinion is erroneous.

The movements which take place in the second, third, fourth, fifth, sixth, and seventh costo-vertebral articulations do not differ sufficiently to require any special mention.

Movements of the Chondro-sternal Articulations.

In these articulations there is even less gliding than in the preceding. The anterior extremity of the first rib, or, rather, of the cartilage which forms its continuation, is the least movable of all; more commonly, it is completely fixed on account of its continuity with the sternum, a circumstance which neutralizes the favourable conditions for mobility presented by its posterior extremity. The eleventh and twelfth ribs, whose anterior extremities are connected only to soft parts, are the most movable. The mobility of the ribs in front decreases from the lower to the upper part of the thorax; to this rule the second rib is an exception, chiefly on account of the two synovial membranes at its chondro-sternal articulation, which permit of greater motion. This, however, is variable, depending as it does on the absence or presence of an articulation between the first and second bones of the sternum, and upon the more or less variable mode in which these two pieces are articulated.

Movements of the Cartilages upon each other.

The movements of this kind are restricted to the sixth, seventh, eighth, ninth, and tenth ribs, the cartilages of which alone are articulated to each other. They are simple, gliding motions, and this gliding is proportionate to the looseness of the ligaments. Hence it follows, that the ribs which I have just mentioned are always moved simultaneously as they glide slightly upon each other; whereas the superior ribs are independent in their movements. This independence, however, is not as great as it might appear at first sight, on account of the interosseous aponeuroses, the interosseous muscles, and the superior transverso-costal ligament, which is very narrow above, and forms below large and shining aponeurotic laminæ.

It results, from the facts above stated, that the most movable ribs are the twelfth and the eleventh, which may be moved upward and downward, and, at the same time,

enjoy, in the highest degree, the movements of projection inward and outward; that the first rib is the least movable of all; that the superior ribs may be moved isolatedly; that the inferior ribs are moved all together.

Movements of the entire Rib.

Since we now know all the elements of which the movement of the ribs is composed, we shall easily comprehend the play of each of those bones isolatedly, and the play of the whole thorax.

The movements of the entire rib are composed, 1. Of those which take place at the sternal and vertebral articulations; and, 2. Of those which result from its own flexibility and elasticity. We shall endeavour to reduce the subject to its most simple elements. Let us suppose, then, that the ribs are straight, inflexible levers: from their oblique position in reference to the vertical axis of the spinal column, their elevation will increase the width of the intercostal spaces; for it is a law of physics, that lines which are oblique with regard to another line, and parallel to each other, become farther separated when they are placed perpendicularly to that line. Hence it follows, that the contact or the overlapping of the ribs is impossible during the movement upward of these bones. A second effect of the elevation of this oblique lever is the advancement of the anterior extremity of the rib, which movement increases proportionately to the length of the lever; hence results an increase of the antero-posterior diameter of the thorax. But as the ribs are curved levers, and not rectilinear, in assuming the horizontal position, their concavity must come to be directed perpendicularly to the median plane formed by the mediastinum. It may be shown, geometrically, that the concavity of an arc which falls perpendicularly upon a plane includes a greater space than when it falls obliquely. From the elevation of the ribs results, therefore, an increase of the transverse diameter of the thorax.*

The arcs of the ribs, however, have not all the same curvature: each rib has its own peculiar perimeter, and it may be proved that the more curved the rib, the greater is the projection outward which it forms when elevated. Lastly, as in some ribs the upper border forms the segment of a smaller circle than the lower, the movement of projection outward is proportionally greater in these than in the other ribs. This assertion may be experimentally proved by imitating the movements of elevation and depression on the second rib.† The greater the disproportion between the curvature of the superior and that of the inferior border, the more marked will be the projection outward. This is the reason why the elevation of the second and third ribs, when they are bent at once, both by their faces and their borders, produce such a remarkable increase of the thoracic capacity.

If the ribs and their cartilages were inflexible levers, the movements of elevation would be much restrained; but, by a mechanism, of which we find no instance elsewhere, the flexibility of these levers introduces into the problem a power which is most important and very variable, so that their movements are much more marked than would arise from the mobility of the articular surfaces. These movements cannot be determined by calculation. Now this flexibility, whence results a movement of torsion in the rib, or of rotation round an axis, represented by the cord of the arc which the rib forms, is in a direct ratio to the length of the ribs and their cartilages, and the flexibility of either. Indeed, the movements of the ribs are much more considerable in children and women than in old men; and the deficiency of mechanical power in regard to breathing, which corresponds to the smallness of the power of locomotion in old men, explains the severity which characterizes asthma and all the diseases of the lungs at this age.

We shall now examine the movements of the thorax in general.

Movements of the Thorax in general.

The general movements of the thorax, which result from those partial motions we have been engaged in considering, are, 1. A movement of dilatation, corresponding with the act of inspiration; 2. A movement of contraction, corresponding with that of expiration.

1. The dilatation of the thorax is caused by the elevation of the ribs. By this movement, the anterior extremity of each rib is carried forward, and the antero-posterior diameter of the thorax is thus increased; the most eccentric portion of the rib is carried outward, and the transverse diameter of the thorax is thereby augmented. There is a sort of antagonism between the upper and lower part of the thorax, with regard to the direction in which the increase of its capacity is effected: in the upper part the transverse diameter is most augmented; in the lower, the antero-posterior diameter.

The most movable point in the superior ribs is at the centre of the curvature; the most movable point of the inferior ribs is at the junction of the ribs and the cartilages. But the columns to which the extremities of the ribs are attached are not equally mo-

* Borelli, t. ii., p. 177.

† From measurements taken by Haller, it appears that the second rib is the most elevated during inspiration; and if this may be doubted, it cannot be denied that its eccentric movement is greater than that of any of the other ribs.

vable: if the posterior extremity is fixed, the anterior extremity may be moved from its place. This circumstance does not oppose the transverse enlargement being produced by the elevation of the arcs of the ribs, though it introduces a new condition into the problem, to wit, the elevation of the anterior column or the sternum. So long as the movement of elevation of the ribs is limited to the costo-vertebral articulations and a slight flexibility of the ribs and their cartilages, the sternum scarcely participates in the motion; but when the elevation is carried beyond a certain point, when all the powers of inspiration are in activity, when there is an integral movement of the thorax, which has not been sufficiently distinguished from the partial movement, then the sternum is carried upward with the ribs, then the first two ribs, which we have represented as the essential props of the sternum, are themselves elevated, and this elevation must be the same as that of all the other ribs, and must, therefore, be proportionately more considerable. Does the sternum perform an angular motion during its elevation, as Haller imagined? On placing the thorax between two parallel planes, and on executing a forcible movement of inspiration, we feel at the inferior portion a pressure, which seems to indicate, in this inferior portion, a movement of projection forward. The lever formed by the inferior ribs being longer, it seems, indeed, as though there ought to be an angular motion; but it will be observed that there is no pression tending to diminish the curve which is described by the ribs; that therefore the two halves of the arc which the curves represent do not recede from each other, and that the powers of elevation simply draw all the anterior extremities of the ribs upward; indeed, the sternum is simply elevated near the cervical region, retaining its primitive direction, as Borelli had previously well pointed out; considering the flexibility of the cartilages, the angular motion is almost impossible.

The enlargement of the thorax is effected by the elevation of the ribs, and takes place either transversely forward or backward. The enlargement of the thorax in a vertical direction is produced by a totally different mechanism, the contraction of the diaphragm, of which we shall speak hereafter.

2. Let us now speak of the contraction of the thorax. This contraction is effected by the depression of the ribs. In the first stage, the contraction is passive, because it results from the elasticity of the cartilages, which, on account of the relaxing of the elevator muscles, cease to be maintained in a state of torsion, and therefore react and restore the rib to its primitive position, so that the rib and cartilage, according to the ingenious remark of Haller, are alternately the cause of their respective movements. It ought to be remarked, that the movement of depression is much more limited than the movement of elevation; and I may justly regard the superior transverso-costal ligament as being destined to impose particular limits to that depression, during which the intercostal spaces are narrowed. We may regard as a powerful auxiliary of the depression and the contraction of the thorax the movement of projection inward, especially in the last five ribs, which are in certain respects depending upon each other. This movement of projection inward is opposed to the transverse dilatation or the movement of projection outward, which takes place especially at the superior portion, as has been seen above, and as is shown every day by the use of the corsets. Afterward we shall see that the great inspiratory powers, or powers of elevation, occupy the superior portion of the thorax, as the great expiratory powers occupy the inferior portion. To the integral elevation of the thorax, in the most considerable degree of contraction, corresponds an integral depression, and this depression of the ribs is directly produced by muscles which bear the name of *expiratory* muscles.

ARTICULATIONS OF THE SUPERIOR OR THORACIC EXTREMITIES.

Articulations of the Shoulder.—Scapulo-humeral.—Humero-cubital.—Radio-cubital.—Radio-carpal.—Of the Carpus and Metacarpus.—Of the Fingers.

Articulations of the Shoulder.

The two bones of the shoulder are articulated together; the clavicle is also united with the sternum and the first rib. There are, therefore, two orders of articulations: 1. The intrinsic articulations of the shoulder, viz., the acromio- and coraco-clavicular articulations; 2. The extrinsic, or the sterno- and costo-clavicular.

The Acromio- and Coraco-clavicular Articulations.

The clavicle is articulated, 1. With the acromion by its external extremity, the *acromio-clavicular articulation*; 2. With the coracoid process by its lower surface, the *coraco-clavicular articulation.*

Preparation.—Remove the skin, the cellular tissue, and the muscles which surround the joints; separate the acromion from the spine of the scapula; remove, in succession, the different layers of the superior acromio-clavicular ligament, so as to be able to judge of its thickness. Make a vertical section of the acromio-clavicular articulation, so as to be able to observe the thickness of the ligaments and articular cartilages.

Acromio-clavicular Articulation (*fig.* 69).

Articular Surfaces.—The clavicle and the acromion process oppose to each other a plane, elliptical surface, with its greatest diameter directed from before backward. The articular surface of the clavicle looks somewhat obliquely downward and outward, the acromial facette looks obliquely upward and inward. The extent of these surfaces varies greatly in individual cases, dependant on the degree of exercise to which the joint is subjected.*

Means of Union and Provision for facilitating Motion.—These are, 1. An *inter-articular cartilage*, first pointed out by Weitbrecht; it is by no means constant, and, when it does exist, occupies only the upper half of the articulation. 2. An *orbicular fibrous capsule* (*d*, *fig.* 69), which is very thick above and behind, and very thin below. It is composed of distinct bundles, which are much longer behind than in front, and are strengthened by some fibres belonging to the aponeurosis of the trapezius muscle; it is not only attached to the upper edge of the articular surface, but also to some inequalities upon the upper surface of the acromion. It is composed of several layers, the deepest being the shortest. 3. A *synovial membrane*, of a very simple construction, supported below by adipose tissue.

Coraco-clavicular Articulation (*fig.* 69).

There can be no doubt concerning the existence of an articulation, where two surfaces are contiguous, and capable of a gliding motion on each other; one of them, the coracoid, being almost always covered with cartilage and a synovial membrane; and the other, the clavicular, presenting sometimes a considerable process for this articulation.

Fig. 69.

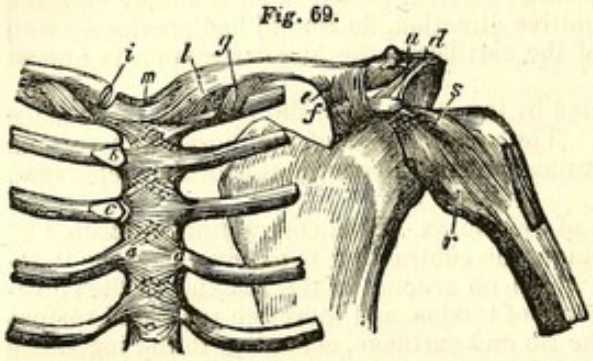

The *means of union* are two ligaments, or, rather, two distinct ligamentous bundles, a posterior and an anterior: they are called coraco-clavicular.

1. The *posterior ligament*, named also the *conoid* or *radiated* (*e*, *fig.* 69), is triangular, and directed vertically; it commences by a narrow extremity, at the base of the coracoid process, and is inserted into a series of tubercles on the posterior edge of the clavicle, near its outer extremity.

2. The *anterior ligament* (*f*) (*trapezoid ligament* of Boyer) arises from the internal edge of the coracoid process, and from the whole extent of the rough projection on the base of this process: from this it proceeds very obliquely to the ridge on the lower surface, near the external end of the clavicle.

The two coraco-clavicular ligaments are continuous, and can only be distinguished by the direction of their fibres.

We might with propriety range among the means of union of this joint an aponeurotic lamina, to which much importance has been attached in surgical anatomy, and which is known by the name of the *costo-clavicular aponeurosis*, or costo-coracoid ligament. It may be easily felt under the pectoralis major in emaciated individuals: it extends from the inner edge of the coracoid process to the lower surface of the clavicle, and converts the groove for the subclavius muscle into a canal.

Mechanism of the Acromio- and Coraco-clavicular Articulations.

The acromio- and coraco-clavicular articulations perform well-marked gliding movements; and, in addition, the scapula rotates forward and backward upon the clavicle to a considerable extent. In order to have a correct idea of these motions and their mechanism, it is necessary to procure a shoulder with the ligaments still attached, and to rotate the scapula backward and forward. It will be then seen that the scapula turns round an imaginary axis passing through its middle. The looseness of the posterior half of the orbicular and of the coraco-clavicular ligaments permits this rotatory motion; of the two coraco-clavicular ligaments, one limits the rotation forward, while the other, which, as we have observed, runs in an opposite direction, limits the rotation backward. Although these motions are pretty extensive, they never give rise to dislocation, which can only be produced by falls on the top of the shoulder, the coraco-clavicular ligaments being lacerated if the luxation be complete. Incomplete luxations may, however, take place without laceration of these ligaments.

The Sterno-clavicular Articulation (*fig.* 69).

The articulation of the inner end of the clavicle is composed of the sterno-clavicular and the costo-clavicular articulations.

Preparation.—Saw through the clavicles vertically at their middle, and also the first ribs at corresponding points; and meet these two sections by a horizontal division of the

* In individuals who have exercised the upper extremities very much, these surfaces are uneven, and unequally incrusted with newly-formed cartilage.

sternum. In order to see the interior of the sterno-clavicular joint, open the fibrous capsule along the edge of the sternum above, or, rather, make a horizontal cut, which will divide it into two parts, an upper and an under.

In order to examine the costo-clavicular articulation, open the synovial membrane behind.

The *sterno-clavicular articulation* belongs to those which are formed by *mutual reception.*

Articular Surfaces.—The *articular surface* of the *sternum* is transversely oblong, concave in the same direction, and convex from before backward; it looks obliquely upward and outward, and is situated on the side of the notch on the upper part of the sternum.

1. The *articular surface* of the *clavicle* is oblong from before backward, slightly concave in the same direction, and convex transversely. From the respective configuration of these surfaces a mutual jointing results, and the short diameter of the one corresponds to the long diameter of the other; so that the end of the clavicle overlaps the surface of the sternum in front and behind, and the surface of the sternum projects beyond that of the clavicle on the inside and the outside.*

2. There is an *inter-articular lamina* of *cartilage* (*i*, *fig.* 69) between the articular surfaces, which is moulded upon them, and is very thick, especially at the edges. It is sometimes perforated in the centre.† It is so closely united by its circumference to the orbicular ligament that it is impossible to separate them: it adheres below to the cartilage of the first rib, and above and behind to the clavicle.

Means of Union.—These are, 1. The *orbicular ligament* (*l*, *fig.* 69). This name may be given to the fibrous capsule which surrounds the joint in all directions. The fibres which compose it have been regarded as forming two distinct bundles, known by the name of anterior and posterior ligaments; but it is impossible to distinguish between them. Fibres proceed from all parts of the circumference of the articular surface of the clavicle, obliquely downward and inward, to the circumference of the articular surface of the sternum. The capsule is not of equal thickness throughout; it is thinner, and somewhat looser, in front than behind, which may partly account for the more frequent luxations of the clavicle forward than backward.

2. The *inter-clavicular ligament* (*m*, *fig.* 69), consisting of a very distinct bundle stretching horizontally above the fourchette of the sternum, from the upper part of the inner end of one clavicle to the inner end of the other. This ligament, which is much nearer the posterior than the anterior part of the joint, establishes a sort of continuity between the clavicles. It is the only direct means of union between the two shoulders.

3. There are *two synovial capsules* in this joint. That which is between the sternum and the inter-articular cartilage is more loose than that between the cartilage and the clavicle.

The Costo-clavicular Articulation (*fig.* 69).

The articulation between the clavicle and the cartilage of the first rib is an arthrodia. It is formed between an articular surface, which almost always exists on the lower surface of the clavicle, and a corresponding facette on the upper surface of the inner end of the first rib, at its junction with the cartilage. There is, in this articulation, a synovial membrane, which is loose, especially behind. There is only one ligament, the *costo-clavicular* (*g*, *fig.* 66), a thick, strong bundle of fibres, quite distinct from the tendon of the subclavius muscle, which is placed in front of it. It is fixed to the inner part of the first costal cartilage, and is directed very obliquely upward and outward, to be inserted into the under surface of the clavicle, to the inner side of the articular facette.

Mechanism of the Sterno-clavicular Articulation.

This articulation is the movable centre of the motions of the shoulder and of the whole upper extremity; and hence the utility of an inter-articular cartilage, to obviate the effects of blows or pressure: hence, also, the wearing away of this cartilage, the deformity and wasting of the articular surfaces, the depression of the right sternal facette, and, lastly, the difference in the size of the sternal extremities of the right and left clavicles.

This articulation, like all those effected by mutual reception, admits of motions in every direction: viz., upward, downward, forward, backward; and of circumduction, resulting from the preceding, but not of rotation.

1. *Movement of Elevation.*—In this the sternal facette of the clavicle glides downward upon the corresponding surface of the sternum; the inter-clavicular ligament is relaxed; the cartilage of the first rib comes in contact with the inner extremity of the clavicle, limits the degree of elevation, and prevents displacement.

2. *Movement of Depression.*—In this the sternal end of the clavicle glides in the opposite direction; the articular surfaces of the costo-clavicular articulation press strongly

* Bichat considers that this arrangement of the articular surfaces predisposes to luxation; it appears to me to have a precisely opposite effect, as it permits the surfaces to move upon each other to a considerable extent without being separated.

† In a great number of cases this ligament is found partially wasted by the continued pressure to which the joint is subjected.

against each other, and limit the extent of this movement. It should be remarked, that in this movement the subclavian artery is compressed between the clavicle and the first rib, sometimes so completely as to arrest the circulation in the limb.

3. In the movement of the shoulder *backward*, the inner end of the clavicle glides forward upon the surface of the sternum; the anterior part of the orbicular capsule is stretched; and if the movement is carried beyond a certain point, the capsule is torn, and the clavicle dislocated forward.

4. In the *forward* movement of the shoulder, the inner end of the clavicle glides backward. The anterior part of the orbicular ligament is relaxed, and the posterior part stretched; as, also, the inter-clavicular ligament, which, as we have seen, is nearer the back than the front of the joint. In this motion luxation may take place backward. It may be remarked that, of all the movements of the shoulder, the one described, in which the clavicle is likely to be dislocated backward, is the most uncommon.

The *movement of circumduction* is more extensive forward and upward than backward. The motions at the sterno-clavicular articulation are very circumscribed in themselves; but when transmitted by the lever of the clavicle, they become very considerable at the apex of the shoulder.

Mechanism of the Costo-clavicular Articulation.

This articulation, which may be regarded as a dependance of the sterno-clavicular, admits of very limited motions, subordinate to those of the joint last described.

The Scapulo-humeral Articulation (*figs.* 69 and 70).

Preparation.—Separate the upper extremity from the trunk, either by disarticulating the clavicle at its sternal end, or by dividing it through the middle; 2. Detach the deltoid from its origin; 3. Detach the supra and infra spinati muscles, the teres minor and subscapularis, proceeding from the scapula to the humerus; 4. Observe the adhesion of the tendons of these muscles to the capsular ligament; 5. Divide the capsule transversely, after having studied its external aspect.

The scapulo-humeral articulation belongs to the class of *enarthroses*.

Articular Surfaces.—These are the *glenoid cavity* of the scapula, slightly concave, of an oval form, with the large end downward, and looking directly outward; and the *head* of the humerus, consisting of about a third of a sphere, and presenting a surface three or four times more extensive than the glenoid cavity. The axis of the head of the humerus forms a very obtuse angle with that of the shaft of the bone.*

These two surfaces are covered by a layer of cartilage, which, on the head of the humerus, is thicker at the centre than at the circumference; while the reverse obtains in the glenoid cavity.

Glenoid Ligament (*a*, *fig.* 70).—This is a fibrous circle, which surrounds the margin of the glenoid cavity, and appears to be formed by the bifurcation of the tendon of the long head of the biceps; but it is also partly composed of fibres proper to itself, which stretch along the margin, arising from one point and terminating in another. Notwithstanding this addition, the head of the humerus is still too large to be received into the cavity, so that a portion of it is always in contact with the capsular ligament; an inconvenience that is obviated, in some measure, by the existence of a supplementary cavity, as we shall presently see. The *scapulo-humeral* articulation is therefore one formed by juxtaposition, and not by reception; from which arrangement it has lately been classed among the *arthrodial articulations*.

Fig. 70.

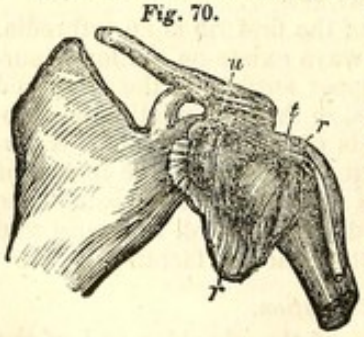

Means of Union.—Like all enarthroses, there is here a *fibrous capsule*, or *capsular ligament* (*r*, *figs.* 69 and 70), a sac with two openings, which extends from the margin of the glenoid cavity to the anatomical neck of the humerus.† This capsule is remarkable for its laxity. In fact, it is so capacious that it could lodge a head twice as large as that of the humerus, and is so long that it will allow the articular surfaces to be separated for more than an inch; the only example of so great a separation without laceration of the ligament.‡

There is this peculiarity in the fibrous capsule of the shoulder-joint, that it is incomplete in one part, its place being there supplied by the tendons of the surrounding muscles. In no joints, in fact, have the muscles and tendons more effect in strengthening the articulation: they are, in a manner, identified with it. There are a great many varieties in this respect. The fibrous capsule is so much stronger, as it is less adherent to the

* Such is the shortness of the neck of the humerus, that its head, which looks upward and inward, would be almost entirely included between the prolonged planes of the body of the humerus.

† It should be remarked, however, that the fibrous capsule does not terminate directly at the anatomical neck of the humerus, but is prolonged a little downward, and becomes blended with the insertions of the tendons of the supra and infra spinati and subscapularis.

‡ In paralysis of the deltoid, the head of the humerus is so far separated from the glenoid cavity that two fingers may be inserted between the articular surfaces.

surrounding tendons. The following are the relations of the capsule: 1. Below, in the variable space between the subscapularis and teres minor, it corresponds to the cellular tissue of the axilla, or, rather, to the thin edges of the muscles just mentioned: the head of the humerus may, therefore, be easily felt by the fingers introduced deeply into the axilla. 2. Above and on the outside, it is in contact with the tendon of the supra-spinatus, from which it is difficult to separate it, and is also in relation, though not immediately, with the arch formed by the acromion and clavicle with the deltoid muscle. 3. In front, it corresponds to the subscapular muscle, from which it may be easily separated. 4. Behind, it corresponds to the tendons of the supra and infra spinatus, which are more or less adherent to it, and the teres minor, which does not adhere to it. As to its structure, it is composed of fibres stretched irregularly from the neck of the humerus to the circumference of the glenoid cavity. Its thickness is not great, nor is it equal throughout, being most considerable below and in front; but the capsule is strengthened above by a considerable bundle of fibres (*s*, *fig.* 69), called the *coracoid ligament*, *coraco-humeral ligament*, or *accessory ligament of the fibrous capsule*, which arises from the anterior edge of the coracoid process, and spreads out on the capsule. This capsule always presents an opening or an interruption above and before,* on a level with the superior border of the subscapularis, which covers the opening in part; or, rather, between this border and the coracoid process. This opening is of an oval form; its greatest diameter is horizontal; its large extremity is turned outward, and its small extremity inward. The circumference of this opening, which is large enough to admit the point of the index finger, is perfectly smooth, thick, and looks like mother-of-pearl, especially in its inferior half. This opening is traversed by a considerable prolongation of the synovial membrane, which reaches the basis of the coracoid process, and then extends between the tendon of the subscapularis and the cavity which bears the same name. This cone-shaped prolongation is variable with respect to its extent, and appears to have no other object except to facilitate the gliding of the tendon of the subscapularis under the coracoid arch and against the border of the glenoid cavity. By distending the articular capsule in several subjects, Mr. Bonamy has demonstrated this disposition to my perfect satisfaction. I have been able to see that the synovial prolongation is sometimes divided into several cells by incomplete walls, by which this distended prolongation acquires a crimpled aspect. Sometimes several of these cells are totally distinct from the synovial membrane.

Inter-articular Ligament.—This name may, with propriety, be applied to the tendon (*t*, *fig.* 70) of the long head of the biceps, which, arising from the upper part of the glenoid cavity, turns like a cord over the head of the humerus, and passes along the bicipital groove. It acts by keeping the head of the humerus applied to the glenoid cavity, and forms a sort of arch that supports the bone when it is forced upward. In two subjects, I found this tendon terminating by a strong adhesion in the bicipital groove, and thus justifying the name of inter-articular ligament, which I have applied to it: the tendon for the long head of the biceps took its origin from the same groove. I consider this division of the tendon to have been accidental, for the bicipital groove was depressed, and the inter-articular ligament flattened, and, as it were, lacerated.

The *synovial capsule* is the simplest of all in regard to its disposition. It lines the fibrous capsule and the tendons which replace it, and is reflected, on one side, on the neck of the humerus, and, on the other, upon the border of the glenoid cavity, to be lost upon the circumference of the articular cartilages. It is remarkable, inasmuch as, 1. It forms a fold round the tendon of the biceps, which is prolonged into the bicipital groove, and terminates below by a cul-de-sac or circular fold, which prevents the effusion of the synovia; 2. It is open in one or two points,† and presents two prolongations communicating with the synovial bursæ of the subscapularis and infra-spinatus.

Supplementary Cavity.—We may regard as a dependance of the scapulo-humeral articulation the vaulted arch formed by the coracoid and acromion processes, and the ligament which unites them. In shape it corresponds to the head of the humerus, and is so constructed that the coracoid process prevents displacement inward; the acromion prevents it upward and outward; and the ligament between them opposes dislocation directly upward. This provision evidently compensates for the incomplete reception of the head of the humerus in the glenoid cavity. A circumstance which proves the usefulness of this vault, and the frequent contacts which it must have with the humerus, is the presence of a synovial capsule, situated between the coraco-acromion vault on one

* I have seen this opening divided into two unequal portions by a fibrous bundle, strong, looking like mother-of-pearl, and resembling a little tendon. Often I have met a second interruption of the fibrous capsule on a level with the concave border of the acromion process, which concave border acts as a real return-pulley for the infra-spinatus muscle, and is analogous to the return-pulley presented by the basis of the coracoid process to the subscapularis muscle. When the capsule is perforated at this point, the synovial membrane gives off a prolongation, which serves as a gliding capsule for the tendon of the infra-spinatus.

† [Although the synovial capsule of the shoulder-joint is thus occasionally prolonged into the bursæ mucosæ connected with the tendons of these muscles, it must not, therefore, be supposed that it is an exception to the general rule that membranes of this nature always form shut sacs; in such cases, the three structures constitute one continuous cavity.]

side, and, on the other, the tendon of the infra-spinatus and the great trochanter of the humerus. The study of the coraco-acromion vault cannot, therefore, be separated from the study of the scapulo-humeral articulation, either under an anatomical and physiological or surgical point of view.

The Coraco-acromial Ligament.

This ligament (*u*, *figs.* 69 and 70) forms part of the vault we have described: it is a triangular bundle of radiating fibres, which extends from the apex of the acromion to the whole length of the posterior edge of the coracoid process. Its external edge becomes thinner, and is continued into an aponeurotic lamina below the deltoid muscle, and separating that muscle from the joint. Its anterior and its posterior bundles are very thick, folded upon each other, and look like mother-of-pearl; its middle bundles are much less thick. It is lined below by a synovial membrane, and is separated from the clavicle by fatty tissue.*

Mechanism of the Scapulo-humeral Articulation.

The scapulo-humeral articulation admits of the most extensive movements of any joint in the body: it is capable of every kind of motion, viz., forward and backward, and also those of adduction, abduction, circumduction, and rotation.

Forward and Backward Motions.—In these the head of the humerus rolls upon the glenoid cavity, and moves round the axis of the neck of the humerus, while the lower extremity of the bone describes the arc of a circle, of which the centre is at the joint, the radius being represented by the humerus.† The forward movement is very extensive, and may be carried so far that the humerus may take a vertical direction exactly opposite to the natural one. The motion backward is produced by the same mechanism; the head of the humerus turns upon its axis. This movement is limited by the contact of the head of the humerus with the coracoid process, without which dislocation forward would be very easily produced. It should be remarked that, in any considerable movement of the humerus forward, the scapula is also moved, performing that sort of rotation which we spoke of when considering the mechanism of the shoulder. And this combination of the movement forward of the arm and the movement of rotation of the shoulder renders every kind of displacement extremely difficult in exercising the movements of the arm forward.

The movement outward, or *abduction*, is the most remarkable. It belongs exclusively to animals possessed of a clavicle. In it the head of the humerus does not turn upon an axis; it glides downward upon the glenoid cavity, and presses upon the lower part of the capsule. The shape of the glenoid cavity, which has its long diameter vertical, and its broad part below, is advantageous as regards this motion. When abduction is carried so far that the humerus forms a right angle with the axis of the trunk, a great part of the head of the bone is below the glenoid cavity. If, while in this condition, the arm be moved forward or backward, the great tuberosity of the humerus rubs against the coraco-acromial arch, and forms with it a sort of supplementary articulation, lubricated by the bursa situated between the coraco-acromion vault and this great trochanter.‡ The movement of abduction may be carried so far as to allow the arm to touch the head without dislocation; for the capsular ligament is sufficiently loose, especially below, to receive almost the whole head of the bone without being torn. It should be remarked, that during abduction the scapula is fixed, which explains the frequency of luxations of the humerus downward.

Adduction is limited by the arm meeting with the thorax. When it is combined with the forward motion, the upper and back part of the capsule, and the muscles which cover it, are considerably stretched. The scapula does not participate in this movement, during which luxation can be occasioned only by a very strong impulse on the arm upward and backward.

Circumduction is nothing more than the transition of the humerus from one to another of these motions. The cone which it describes is much more extensive in front than behind, a circumstance tending greatly to facilitate the prehension of external objects, which is the chief purpose of the upper extremities. This predominance of the forward motions has been already noticed in the sterno-clavicular articulation, and will be found also in many others.

* [This is the *ligamentum proprium anterius* of authors; but the author has taken no notice of another ligament proper to the scapula, viz., the *ligamentum proprium posterius*, a thin band of fibres stretched across the notch at the base of the coracoid process, which it thus converts into a foramen. The supra-scapular nerve generally passes below, and the artery above it.]

† It is through this ingenious and simple mechanism, of which we shall soon see another example in the articulation of the femur with the *os innominatum*, that the movement forward of the humerus may be carried far enough to describe a demi-circle, without the bone being displaced.

‡ If theory has led us to believe that the coraco-acromion vault contributed to luxation, by offering a point of support to the lever represented by the humerus abducted from the body, a more careful observation, on the contrary, has demonstrated that this supporting of the humerus was impossible, as the anterior border of the coraco-acromion ligament is alone pressing against the humerus in the forcible abduction, and luxation is always produced in a middle abduction of the arm.

Rotation.—In this movement the humerus does not turn upon its own, but upon an imaginary axis, directed from the head of the humerus to the epi-trochlea, parallel to the bone. The manner in which the rotatory muscles embrace the head of the humerus is highly favourable to this motion, by compensating for the shortness of the neck, which serves as a lever for the rotatory movements.

THE HUMERO-CUBITAL ARTICULATION, OR ELBOW-JOINT (*figs.* 71 and 72).

Preparation.—1. Remove carefully the brachialis anticus muscle; 2. Detach the tendon of the triceps from above downward, without opening the synovial capsule; 3. Remove the muscles which are attached to the internal and external tuberosities, keeping in mind that the lateral ligaments are intimately connected with the tendons of these muscles. This articulation belongs to the class of *trochlear joints* (angular ginglymi).

Articular Surfaces.—On *the humerus* we find, 1. An almost perfect trochlea or pulley, presenting two edges, of which the internal is the more prominent, so that, when the end of the bone rests upon a horizontal plane, its shaft is directed very obliquely from above downward and inward; 2. The small head, or articular condyle, separated from the trochlea by a furrow, which is also articular; 3. Two cavities, a posterior, which is very deep, and is intended to receive the olecranon process, and an anterior, which is shallower, and receives the coronoid.

Fig. 71.

Fig. 72.

The articular surfaces of the *forearm* are, 1. The greater sigmoid cavity of the ulna, which exactly embraces the trochlea;* 2. The glenoid cavity of the radius, which receives the small head of the humerus.

The *means of union* consist of four ligaments, two lateral, an anterior, and a posterior. 1. The *external lateral ligament* (*a*, *figs.* 71, 72) is blended with the tendon of the supinator brevis; it is of a triangular form, and stretches from the external tuberosity of the humerus to the annular ligament, with which it becomes continuous, and which seems to be in part formed by it. Some fibres of this ligament are also inserted into the outer part of the sigmoid cavity of the ulna. This connexion of the lateral with the annular ligament is of great importance with reference to the production of luxations of the upper end of the radius.†

2. The internal lateral ligaments are two in number: one internal, properly so called, or *humero-coronoïdian*; the other internal and posterior, *humero-olecranian*.

The former, or humero-coronoïdian, which is partly confounded with the aponeurotic tendon of the superficial flexor muscle of the fingers, is a thick, rounded bundle, which arises below the internal tuberosity of the humerus, and is inserted into the whole internal side of the coracoid process, and more especially in its tubercle.

The second, or humero-olecranian, which might be described as a posterior ligament of the articulation, is thin and radiating; it arises from the posterior portion of the epi-trochlea, and irradiates to be inserted into the whole extent of the internal border of the olecranon; the inferior bundles are the strongest, and come in part from the *humero-coronoïdian* ligament. The superior bundles are thin and slender, and reach beyond the olecranon, in order to expand over the synovial membrane.

3. The *anterior ligament* (*c*) is a very thin layer, in which, however, three orders of fibres can be recognised. The first, directed vertically, form a bundle which extends from the upper part of the coronoid cavity to the lower part of the coronoid process; the second are transverse, and intersect the first at right angles; and, lastly, the third are obliquely directed downward and outward to the annular ligament.‡ We shall see, hereafter, that the brachialis anticus renders an anterior resisting ligament entirely useless; moreover, the most inferior and deepest fibres of this muscle are directly inserted in this anterior ligament.

* There is here, indeed, a hinge: it is the most remarkable example of a hinge in the system; it is the most perfect angular ginglymoid. The two articular surfaces present a sinuous surface, which is alternately concave and convex, a sort of catching which is seen nowhere else.

† These relations between the annular ligament and the external lateral ligament are so intimate that these two ligaments are seldom torn independently of each other; hence the consecutive dislocation of the radius upon the cubitus in the luxations of the elbow; hence, also, the luxations of the radius upon the humerus, the ulna remaining in its place. (See an example of the luxation backward of the radius upon the humerus, the ulna remaining in its place, *Anat. Pathol.*, with plates, 8th number.)

‡ It should be remarked, that none of these ligaments of the elbow-joint are attached directly to the radius, but that the fibres which are directed towards this bone join the annular ligament. This arrangement allows the radius to rotate with perfect freedom within its ring, which would have been impossible had the fibres been directly inserted into the bone.

4. The *posterior ligament* (*d*, *fig.* 72). The place of the posterior ligament is occupied by the olecranon and the tendon of the triceps. There are some fibres, however, which extend from the external to the internal tuberosity of the humerus, which are in relation with the synovial membrane in front, and the tendon of the triceps behind. The principal posterior ligamentous fibres are those which seem to arise from the humero-olecranian ligament.

The *synovial membrane* covers the posterior surface of the anterior ligament; from this it is reflected upon the coronoid cavity, covers the olecranon cavity behind, and is prolonged a little between the tendon of the triceps and the back of the humerus. In this place it is widest and most loose. Below, it forms a prolongation, which extends into the radio-cubital articulation, covering the whole inner surface of the annular ligament, and forming a circular cul-de-sac below it, which prevents the effusion of the synovia.* There is some synovial adipose tissue round the points of reflection, and also at the margin of the coronoid and olecranon cavities.

Mechanism of the Humero-cubital Articulation.

Extension and flexion, the only motions performed by this joint, are executed by it with remarkable precision and rapidity. The precision of these movements depends, 1. Upon the exact fitting of the articular surfaces; 2. Upon the great extent of the transverse diameter, round which the movements of flexion and extension are performed as round an axis; 3. Upon the shortness of the antero-posterior diameter of the inferior extremity of the humerus, and, consequently, on the smallness of the circle to which the curve of the humeral trochlea belongs.

1. *Flexion.*—In this motion, which is very extensive, the radius and ulna move as a single bone from behind forward, on the small head and trochlea of the humerus. It should be observed that, in this movement, the obliquity of the trochlea from behind forward, and from without inward, throws the forearm, when bent, in front of the thorax, and the hand in front of the mouth. This motion is limited by the meeting of the coronoid process with the coronoid cavity. When this motion is carried to the greatest extent, the upper end of the olecranon descends to the level of the lowest part of the trochlea, and is, consequently, below the line which passes through the two tuberosities, or condyles, of the humerus. In this motion, the back part of the trochlea and the olecranal fossa are covered only by the tendon of the triceps, so that instruments can readily enter the joint at this place. The flexion of the elbow, which constitutes a fundamental movement in prehension of bodies, may be carried as far as possible, even so far as to cause the forearm to meet the arm, without any risk of luxation, as any sort of dislocation here is impossible, however extensive this movement may be.

2. *Extension.*—In this movement, the radius and ulna roll backward upon the humerus. This motion can only be carried so far that the forearm and the arm form a right line, for then the upper part of the olecranon comes in contact with the bottom of the olecranal fossa. The anterior ligament and the anterior and middle bundles of the internal lateral ligament are put on the stretch, and thus concur in limiting the movement of extension, which is already limited by the olecranon coming in contact with the bottom of the olecranon cavity. There is no appreciable lateral motion of this joint, the exact fitting of the articular surfaces effectually preventing it.†

THE RADIO-CUBITAL ARTICULATIONS (*figs.* 71 to 75).

In these articulations, the radius and the ulna are united, 1. By their upper ends (*superior radio-cubital articulation*); 2. By their lower ends (*inferior radio-cubital articulation*); 3. By the interosseous ligament through a great part of their extent.

Superior Radio-cubital Articulation.

Preparation.—Remove with care the anconeus and the supinator brevis, and separate the forearm from the arm.

The *articular surfaces* are the edge of the head of the radius, which is of unequal height in different parts, and the lesser sigmoid cavity of the ulna, which is oblong from before backward, broader in the middle than at the ends, and which forms the bony portion of the *osteo-fibrous ring* in which the head of the radius rolls.

The *means of union* consist of the *annular ligament of the radius* (*e*, *figs.* 71 and 72).

* [According to the common opinion, the articular surfaces of the radius and ulna are, of course, also covered by the synovial membrane.]

† A glance at the articulation of the elbow, surrounded by its ligaments, is sufficient to convince us of the facility with which the dislocation of the humerus forward takes place, favoured as it is by the smallness of the antero-posterior diameter of the articulation, and by the deficiency in the resistance of the anterior ligament. This dislocation is, next to that of the humerus, the most frequent, notwithstanding the resistance of the brachialis anticus, which, being an active ligament, supports the anterior portion of the articulation, with which it is so closely identified, that, in this dislocation, it is always torn, at least incompletely. This dislocation forward is, moreover, favoured in the movement of extension by the point of the olecranon meeting the bottom of the olecranon cavity of the humerus. In a fall upon the wrist, the forearm being extended, the humerus becomes a lever of the first kind, whose point of support is represented by the olecranon cavity of the humerus strongly pressed against by the point of the olecranon; the lever of power is represented by the whole length of the humerus; the lever of resistance, by the short portion of the humerus below the olecranon cavity.

This ligament is a band forming three fourths of a ring, which is completed by the lesser sigmoid cavity of the ulna; it is attached, by its two ends, to the fore and back part of this cavity. Its internal surface, which is smooth and shining like mother-of-pearl, is in contact with the articular border of the head of the radius. The external lateral ligament is attached to its outer surface, and evidently becomes continuous with its posterior half. This arrangement has doubtless given rise to the assertion, that the external lateral ligament is attached to the ulna. Those fibres of the anterior ligament which are directed obliquely downward and outward are also inserted into the annular ligament. All these ligamentous attachments retain the annular ligament in its proper position; when they are divided, it is manifestly retracted towards the neck of the radius, and exposes the articular edge of the bone. The breadth of the annular ligament is from three to four lines, and its upper circumference is wider than the lower, which construction tends to maintain the head of the radius in its situation more accurately. With regard to its structure, I would observe, that it is much thicker behind, where it receives the insertion of the external lateral ligament, than in front, where it may be much more easily ruptured; and I am persuaded that, in luxation of the elbow, it is not the external lateral ligament which is most commonly torn, but rather the anterior portion of the annular.

The *synovial capsule* is a sort of diverticulum from that of the elbow-joint, which is prolonged upon the inner surface of the annular ligament, and is reflected upward from its lower margin, so as to form a sort of cul-de-sac below it.

Inferior Radio-cubital Articulation.

Preparation.—1. Remove the muscles on both aspects of the forearm. 2. Separate the hand from the forearm so as to expose the lower surface of the triangular ligament, or fibro-cartilage. 3. In order to examine the interior of the joint, saw through the middle of the forearm; divide the anterior and posterior ligaments; separate the two bones of the forearm; cut through the triangular ligament at its insertion into the ulna.

The *articular surfaces* are a small sigmoid cavity on the radius, analogous to that which we have described at the upper end of the ulna, and the external two thirds of the circumference of the head of the ulna. This articulation, therefore, is precisely the reverse of the upper, since in this the ulna furnishes the head, and the radius the sigmoid cavity, while a precisely opposite arrangement obtains in the upper joint.

The *means of union are*, 1. Some fibres stretched in front and behind the joint, and called anterior (*f*, *figs.* 71 and 75) and posterior (*g*, *figs.* 72 and 74) ligaments. They form a very imperfect annular ligament. They extend from the anterior and posterior margins of the sigmoid cavity of the radius to the anterior and posterior surfaces of the little head of the ulna, in the neighbourhood of its styloid process.

2. The *triangular ligament*, or, rather, *cartilage** (*i*, *figs.* 71 and 73). This is a triangular lamina of cartilage, the apex of which is fixed into the angle formed by the head and styloid process of the ulna, and its base into the lower edge of the sigmoid cavity of the radius. It is thin at the base and the centre, and thick at the apex and the circumference. It concurs in maintaining the union of the radius and ulna, and performs the office of those inter-articular cartilages which we have noticed as peculiar to such joints as are most exposed to shocks and friction; and, above all, it restores the level of the inferior radio-cubital surface by filling up the vacancy caused by the projection of the radius below the ulna.

There is a separate *synovial membrane* for this joint (see above, *i*, *fig.* 75), (often called *membrana sacciformis*). It covers the upper surface of the triangular ligament, and the sort of incomplete ring which circumscribes the head of the ulna. It forms very loose folds at the places of reflection, which admit of very extensive rotation. This synovial membrane is common to the articulation of the ulna with the radius, and to the articulation of the ulna with the inter-articular cartilage; it is entirely independent of the synovial membrane of the wrist-joint.

Middle Radio-cubital Articulation, or Interosseous Ligament.

The *interosseous ligament* (*l*, *figs.* 71, 72), improperly so called, is an aponeurosis which occupies the interval between the radius and ulna, and which appears to serve principally for the insertion of muscles. It is broader in the middle than at the ends, and does not reach the extremities of the interosseous space, for there is an interval above and below, which serves the purpose of giving passage to nerves and vessels, and also permits more free motion between the two bones. The fibres which compose it are directed obliquely downward and inward, *i. e.*, from the radius to the ulna. We generally observe on its anterior aspect several bundles running downward and outward; the supe-

* This is the only example in the system of an inter-articulary cartilage serving as a means of union between the bones. Can its principal use be to prevent the dislocation of the ulna in the movements of rotation? The following experiment will show that this cartilage does not oppose the forcible movements of pronation and supination: Saw the bones of the forearm at their middle line, separate the forearm from the wrist, rotate with the utmost force the radius upon the ulna, and it will be seen that, during these movements, the inter-articular cartilage remains unstrained in all its points. This cartilage is attached to the groove of the styloid process of the ulna by fibrous tissue; what is called the summit of the triangular cartilage is, therefore, nothing else than a very short and strong little ligament, by which the cartilage is attached to the ulna.

rior and the strongest of these is called the *round ligament*, or the *ligamentous cord of Weitbrecht* (*m*, *fig.* 71). It extends obliquely downward and outward, from the outside of the coronoid process of the ulna to the lower part of the bicipital tuberosity of the radius. Its direction is, therefore, precisely the inverse of that of the fibres of the interosseous ligament.

Mechanism of the Radio-cubital Articulations.

These articulations, like all trochlear joints, only admit of one kind of motion, viz., rotation, which is here called by a peculiar name. Rotation forward is denominated *pronation*; rotation backward is called *supination*. We must examine these in both the upper and the lower radio-cubital articulations.

Mechanism of the Superior Radio-cubital Articulations.

Pronation.—In this movement, the inner part of the head of the radius rolls backward upon the lesser sigmoid cavity of the ulna, and may be carried so far that the radius may describe half a circle upon its axis. Notwithstanding the obstacles to displacement resulting from the strength of the back part of the annular ligaments, and the presence of the two little hooks, one in front and the other behind the lesser sigmoid cavity of the ulna, and, lastly, notwithstanding the advantage produced by the reception of the small head of the humerus in the cup-like cavity of the upper end of the radius, in violent pronation the head of the radius is frequently luxated backward. Perhaps no dislocation is more common in infancy than the incomplete luxation backward of the upper end of the radius, on account of the greater looseness of the annular ligament, and the less complete reception of the small head of the humerus in the cupula of the radius. The cause occasioning this displacement is forced pronation, so frequent when infants are held by the hand, in attempting to save them from falling.

In *supination*, the head of the radius turns upon its axis in a different direction, *i. e.*, its inner part glides forward upon the lesser sigmoid cavity of the ulna. If it be carried too far, dislocation forward may be the consequence.*

Mechanism of the Inferior Radio-cubital Articulations.

The movements of pronation and supination, at the lower radio-cubital articulation, are produced by a mechanism which is precisely the inverse of the former; for the radius, instead of rotating upon its own axis, turns round the head of the ulna by a movement of circumduction. This difference results partly from the curvature of the radius, and partly from the great transverse diameter of its lower end, which forms the radius of the arc of the circle which it describes round the ulna. In pronation, the little sigmoid cavity rolls forward on the articular edge of the head of the ulna; in supination, it glides in the opposite direction, that is, backward. We see, then, that in the lower articulation, a concave surface moves upon a convex, while the contrary takes place at the upper.

Does the inter-articular cartilage limit these motions, as it has been asserted? The experiment which I have indicated above shows that this cartilage is in the same conditions in regard to the articular surfaces, both in pronation and supination, and that the small ligament which attaches it to the groove of the styloid process of the ulna, experiences neither tension nor relaxation. The anterior and posterior ligaments alone are able to limit the movements of rotation by their resistance; but, in forcible pronation, these may be broken, and the head of the ulna dislocated backward; in forcible supination, it may be dislocated forward. It should be remarked that, in cases of luxation of the ulna, the head of this bone does not lacerate the capsule, but the capsule is torn upon it; for, as we shall afterward see, the ulna is immovable at the cubito-carpal joint, and takes no share in the partial motions of the forearm.

Mechanism of the Radio-cubital Articulations, considered with reference to the Bodies of the two Bones.

In the movement of pronation, the radius crosses the ulna at an acute angle, so that its lower part is carried in front of the ulna, while the upper remains on the outside. The movement of supination consists in the return of the radius to its state of parallelism with the ulna. In pronation, the interosseous ligament is relaxed; in supination, it is stretched: its absence at the upper part of the forearm, where its place is supplied by the ligament of Weitbrecht, allows more extensive rotatory movements.†

* This displacement is very uncommon, on account of the hook-like projection at the anterior extremity of the sigmoid cavity, and doubtless, also, because forcible supination is very rare. Professor Dugès informs me that he has seen an instance of this dislocation of the radius, and proved its existence by inspection after death. I have myself recently met with a case of an incomplete dislocation forward in a child: a slight pressure from before backward upon the superior extremity of the radius was sufficient to reduce the dislocation, which took place on a sudden, while the child was being dressed.

† If the interosseous ligament, the fibres of which pass downward from the radius to the ulna, had been prolonged to the upper part of the interosseous space, it would have much impeded the motions of supination, by limiting the movements of the bicipital tuberosity, into which one of the supinator muscles of the forearm, viz., the biceps, is inserted; but the round ligament being inserted below the bicipital tuberosity, and passing downward from the ulna to the radius, can have no effect in limiting the extent of rotation.

The existence of the interosseous space is an indispensable condition for the performance of pronation and supination; and, therefore, every curative plan for the treatment of fractures of the forearm which does not provide for the preservation of this space should at once be rejected.

In the explanation we have given of the mechanism of the radio-cubital articulations, the ulna has been considered as an immovable axis, round which the radius executes below certain movements of circumduction; but many authors have maintained the opinion that the ulna also takes part in these motions. Without discussing the different theories which have been successively proposed on this subject, we shall mention an experiment which is at once decisive of the question. If all the articulations of the arm be exposed from the shoulder to the hand, and the humerus be immovably fixed in a vice, it will be seen that, when the forearm is pronated or supinated, the radius moves upon thc ulna, which remains altogether undisturbed; and, also, that any lateral motion of the ulna is absolutely impossible, from its perfect jointing with the humerus at the elbow. When the humerus is not completely fixed, it also rotates in conjunction with the bones of the forearm.

Lastly, it should be observed that, when the radius is rotated during semiflexion of the forearm, the motion is accompanied by slight degrees of flexion and extension at the elbow-joint.

Radio-carpal Articulation (*figs.* 73 to 75).

Preparation.—Divide the fibrous sheaths of the flexor and extensor tendons, and carefully remove those tendons; bearing in mind the fact that the fibrous sheaths closely adhere to the ligaments, or, rather, are identified with them, and may be considered as an appurtenance of the ligamentous apparatus of the joint.

This articulation belongs to the class of *condylarthroses.*

The articular surfaces (*fig.* 73) are those of the scaphoid, the semilunar, and the cuneiform, which together form a condyle, oblong transversely, and covered by articular cartilages, which are prolonged farther on the posterior than on the anterior aspect of the bones, and the transversely oblong concave, articular surface, formed by the lower ends of the radius and ulna. The radius, which forms by itself two thirds of the surface, corresponds to the scaphoid and semilunar, and presents an antero-posterior ridge, and a slight contraction from before backward, opposite the interval between these two bones. The ulna corresponds to the cuneiform bone, with the intervention of an inter-articular cartilage, viz., the triangular cartilage already described, which performs the part both of a ligament and an inter-articular cartilage. The concave surface presented by the lower part of the forearm is completed at the sides by the styloid processes of the radius and ulna.

Means of Union.—There are for this joint an external lateral ligament, an internal lateral, two anterior, and one posterior ligament.

The *external lateral ligament* (*a*, *figs.* 73, 74, 75) stretches from the summit, and forms the neighbouring parts of the styloid process of the radius to the outer part of the scaphoid, where it is inserted by a broad attachment immediately on the outside of the radial articular surface of that bone. This ligament, which is not very thick, is continuous with the anterior and the posterior ligament, without any line of demarcation being perceived.

The *internal lateral ligament.* It is uncovered immediately after the tendinous sheath of the extensor carpi ulnaris has been divided. It is lined by the synovial membrane of this sheath. It is a cylindrical chord, commencing at the styloid process, of which it seems to be a continuation, and dividing inferiorly into two fasciculi, one of which is attached to the pisiform, the other, which is more considerable, to the posterior surface of the cuneiform bone. This chord first appears very thick; but, on dividing it, it is seen perforated by a cavity communicating inferiorly with the radio-carpal articulation, and its superior extremity is not attached to the summit of the styloid process of the ulna, but to the middle point of this process, in the form of a demi-capsule. The summit of this process is articular, and surrounded with a thick layer of cartilage; it is farther contained in the synovial membrane of the wrist, and is in direct relation with the cuneiform bone. The styloid process of the ulna is therefore the only portion of this bone which enters directly into the wrist-joint.

The *anterior ligaments* are two in number, one radial, the other ulnar.

The radio-carpal ligament forms a broad layer resembling mother-of-pearl, which appears as soon as the flexor tendons have been removed. It is composed of bundles, which are often separated by adipose cellular tissue and vessels, so that I considered it necessary, in the former edition of this work, to describe three anterior radial bundles, an external, a middle, and an internal; I have abandoned this distinction, because it does not appear of any use. This ligament arises from the whole breadth of the anterior border of the inferior extremity of the radius around the articular surface; it also arises from the anterior border of the styloid process of this bone. Hence its fibres stretch from above downward, and from without inward, approximating to a horizontal position, in proportion as they are more elevated. The most external fibres go to the os unciforme and the os magnum; those which come next are inserted into the scaphoid bone; others, again, into

the cuneiform and the pisiform bones. The most elevated fibres, which are the most internal, seem to be continuous with the anterior ligament of the inferior radio-cubital articulation. The most external bundles of this ligament are the thickest. This ligament is composed of several layers of fibres, the most superficial of which are the longest.

The *ulnar-carpal* ligament has probably been confounded by authors with the internal lateral ligament; or perhaps it may have escaped their notice altogether, on account of its being deeply seated. This ligament arises, by a narrow extremity, from the groove which separates the styloid process from the little head of the ulna, in front of the small ligament which forms the summit of the inter-articular cartilage; thence it goes downward and outward, passes under a few fibres of the anterior radio-carpal ligament, and is lost by irradiating. The horizontal superior fibres describe a curve beneath the head of the ulna, and are inserted into the anterior border of the radius, where they are confounded with the fibres of the radio-carpal ligament; the inferior fibres descend almost vertically downward, externally to the pisiform bone, and terminate in the os cuneiforme.

The *posterior* ligament cannot possibly be separated from the fibrous sheath of the extensor and radial tendons, with which it is continuous. There is but one posterior ligament; it is much weaker and narrower than the anterior radio-carpal ligament, and stretches obliquely from the posterior border of the radius to the posterior faces of the cuneiform and the semilunar bones. The bundle which goes to the cuneiform is the stronger. This ligament covers about the third portion of the joint, while the radio-carpal ligament covers the whole of the anterior surface. It should be observed, that there is a marked predominance of the anterior over the posterior ligaments, both in the articulation of the hand with the forearm, and in the articulations of the carpus.

With regard to the anterior and posterior ligaments of the radio-carpal articulation, I shall make an observation which may be of some interest: it is, that all these ligaments, with the exception of the cubito-carpal, come from the radius, and closely unite the inferior extremity of that bone to the first range of the carpus, and, consequently, to the hand.

The *synovial membrane* (see *fig.* 73) is loose behind, where it is only partially covered by the ligaments we have described; throughout the whole of the remaining circumference of the joint it is strengthened by scattered ligamentous fibres, which some anatomists have described as a capsular ligament. This synovial membrane sometimes communicates with that of the lower radio-cubital articulation, by an opening at the place o union of the triangular cartilage with the lower edge of the sigmoid cavity of the radius. It also sometimes communicates with the general synovial membrane of the carpus, by the interosseous spaces which separate the bones of the first carpal row.

Besides the means of union which we have described, the flexor tendons in front, and the extensor tendons behind, should be noticed, as serving to increase the strength of the joint.

Mechanism of the Radio-carpal Articulation.

This articulation belongs to the condyloid class, and has, therefore, four motions, viz., flexion, extension, abduction, and adduction, and by passing from one of these to the other, it can perform circumduction.

1. *Flexion.*—In this motion, the condyle formed by the first row of the carpus glides backward upon the lower end of the forearm. The posterior ligaments and the extensor tendons are put on the stretch. When the movement of flexion is carried too far, luxation may take place by laceration of the posterior ligament, and then the lower end of the two bones of the forearm pass in front of the articular surface of the bones of the first row of the carpus. The possibility of dislocation of this joint has been doubted; but I have seen two instances of this kind of dislocation, which were incontestable.

2. In *extension*, the condyle formed by the carpus rolls forward upon the lower end of the forearm; and as the articular surface of the carpus reaches farther on the back than in front, it follows that extension may be carried farther than flexion: it is limited by the strong anterior ligaments, and also by the lateral ligaments, which, as is generally observed, are attached nearer to the side of flexion than to that of extension.

It should also be remarked, that extension is the easiest motion of the hand upon the forearm: this may be readily understood from the great power which the hand possesses when it forms a right angle behind with the forearm.*

3. In *abduction*, the condyle formed by the carpus rolls in the direction of its length, *i. e.*, transversely and from without inward, while the radial edge of the hand is inclined towards the radial edge of the forearm: this motion is limited by the mutual meeting of the styloid process of the radius, and the external process of the scaphoid.

4. In *adduction*, the ulnar edge of the hand is bent towards the ulnar edge of the forearm; the motion is limited by the meeting of the summit of the styloid process of the ulna and the cuneiform bone, and also by the tension of the external lateral ligament.

It may be easily conceived, that in the lateral movements, which are performed in

* We should observe that it is almost impossible to separate the mechanism of the carpal articulations from that of the radio-carpal joint; the latter is noticed here by itself only in order to conform with the anatomical divisions.

the direction of the long diameter of the articular surfaces, dislocation must be very difficult, and that, when it does occur, it must be incomplete.

The *movement of circumduction* is nothing more than a succession of the different motions which have been already pointed out. The hand describes a cone, of greater extent behind, that is, in the direction of extension, than in front, or in the direction of flexion. It is also still more restricted in adduction and abduction.

Articulations of the Carpus (*figs.* 73 to 75).

These articulations comprise, 1. The articulations of the bones of each row together; and, 2. The articulations of the two rows.

Articulations of the Bones of each Row.

Preparation.—1. Remove the extensor and the flexor tendons; 2. Separate the hand from the forearm, then the first row from the second, and, lastly, the bones of both rows from each other, examining their means of union before completing the separation.

Articular Surfaces.—The articulations of the bones of each row are *amphi-arthroses*, and, consequently, present one part continuous and another contiguous. The bones of the first row correspond to each other by oblique surfaces, those of the second row by vertical and more extensive surfaces.

Means of Union.—Two classes of ligaments belong to these joints: the one is extended between the corresponding surfaces, the *interosseous ligaments;* the other set are *peripheral*, and are divided into *palmar* and *dorsal.*

The *palmar* and *dorsal ligaments* are fibrous bundles, stretched transversely or obliquely from each of the bones of the carpus to those which are contiguous to it. The dorsal are much thinner than the palmar.

The *interosseous ligaments* are not disposed in an exactly similar manner in the two rows, and we shall, therefore, examine them separately. 1. The interosseous ligaments of the first row (*e e*, *fig.* 73) occupy only the upper part of the corresponding facettes; they are nothing more than small fibrous bundles, one extending from the scaphoid (1) to the semilunar (2); the other from the semilunar to the cuneiform (3); they are sometimes partially interrupted, and present openings, which establish a communication between the general synovial membrane of the carpus and that of the radio-carpal articulation. These interosseous ligaments are reddish, scarcely fasciculated, very loose, so as to admit of pretty extensive gliding motions. 2. The *interosseous ligaments* (*d d d*) of the second row are much thicker than those of the first; the whole non-articular portion of the corresponding facettes gives insertion to these ligaments, which are very compact, and of a much more dry and close texture than the reddish tissue connecting together the bones of the first row. It follows, therefore, that the bones of the second row are more firmly united than those of the first, whose interosseous ligaments are loose, and permit a certain degree of mobility. The articulation of the pisiform bone with the cuneiform merits a special description.

Fig. 73.

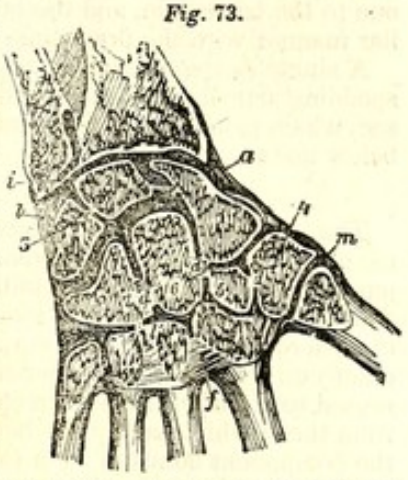

Articulation of the Pisiform and Cuneiform Bones.

For this articulation, the pisiform bone presents a single articular surface, which unites with the anterior facette of the cuneiform bone. There are four ligaments in this little joint, which is nothing else but a *loose arthrodia*: 1. *Two inferior* (*e*, *fig.* 75), which are very strong, viz., *an external*, stretched obliquely from the pisiform to the hook-like process of the unciform bone; and *an internal*, vertical, which is inserted into the upper end of the fifth metacarpal bone. These two ligaments appear partly to result from the bifurcation of the tendon of the flexor carpi ulnaris, this tendon being in the place of the *superior ligament*, which is wanting. The internal lateral ligament of the radio-carpal articulation may also be considered as entering into the structure of the superior ligament. 2. An *anterior* and a *posterior* ligament, thin and radiating, which strengthen the synovial capsule in front and behind.

The synovial capsule is, most commonly, a small isolated pouch; and sometimes it is a prolongation of the radio-carpal synovial membrane. This capsule is very loose, and the ligaments are not very tight; hence the great mobility of the articulation.

Articulation of the two Rows of Carpus together.

The articulation of the two rows of the carpus together presents an enarthrosis in the middle, and an arthrodia on each side.

The *articular surfaces* consist of a head or spherical eminence received into a cavity, constituting the *enarthrosis*, and of plane surfaces on the inside and the outside, which form a double *arthrodia*. The head is formed by the os magnum (6, *fig.* 73) and the su-

perior process of the os unciforme (7): the cavity is constituted by the inferior surfaces of the scaphoid (1), the semilunar (2), and the cuneiform (3) bones. This cavity, which is deeply notched in front and behind, is completed in these situations by two ligaments, an *anterior* and a *posterior*, which might be called *glenoid ligaments*, considering their position on the edge of a cavity, and their use in increasing its depth.

The *posterior glenoid ligament* is composed of transverse fibres, which are inserted into the first row, closing up the posterior notch.

The *anterior glenoid ligament*, much stronger than the other, belongs to the second row; it is confounded with the anterior ligaments of the articulation, between the two rows, and extends transversely from the os unciforme to the trapezium, passing in front of the neck and the head of the os magnum. Besides these ligaments, we also find, 1. *An anterior ligament* (*i*, *fig.* 75), which is very thick, and stretches from the anterior surface of the os magnum, by diverging rays, to those three bones of the first row that form the enarthrodial cavity, in which the head of the os magnum is received, viz., the scaphoid, the semilunar, and the cuneiform. 2. *A posterior ligament* (*i*, *fig.* 74), which consists merely of some fibres extending obliquely from the bones of the first row to those of the second.

On the inside and the outside of this carpal enarthrosis we find an arthrodia. On the *inside* is the articulation of the cuneiform (3, *fig.* 73) with the unciform (7) bone, constituted by plane surfaces, and strengthened by a very thin posterior ligament, an anterior ligament, much thicker than the preceding, and an internal lateral ligament (*c*). On the *outside* is the articulation of the scaphoid with the trapezium and the trapezoid. The articular surface of the *scaphoid* (1) is a sort of head or elongated convexity, and those of the *trapezium* (4) and the *trapezoid* (5) are two facettes, that unite in forming a concavity, into which the convexity of the scaphoid is received. This small articulation is strengthened by *two anterior ligaments*, both of which proceed from the scaphoid, and are connected one to the trapezium, and the other to the trapezoid; and *two posterior*, arranged in a similar manner with the preceding, but much thinner.

A single *synovial capsule* (see *fig.* 73), very loose, especially behind, covers the corresponding articular surfaces of the two rows. But it is also provided with small culs-de-sac, which penetrate into the intervals between the bones of each row, there being three below and two above.

Mechanism of the Carpus.

The mechanism of the carpus must be considered as providing both for strength and mobility. The conditions favourable to strength are, 1. The number of bones in the carpus; 2. The reciprocal dovetailing of the two rows, the anti-brachial row joining in this fashion the metacarpal, and *vice versa*; 3. The numerous ligaments connecting the bones of each row together. The carpus, therefore, has power to resist the most violent shocks, chiefly on account of the expenditure of force at each of its numerous articulations. With regard to *mobility*, the movements between the bones of each row must be distinguished from those which take place between the two rows. 1. The partial movement between the component bones of each row is scarcely appreciable, and requires no consideration. 2. The mobility of the two rows upon each other is, however, more marked. The enarthrodial articulation of the head of the os magnum can only perform forward and backward motions, for the arthrodial joints on each side prevent any lateral movements.

Mechanism of the Carpal Enarthrosis.—The movement of *extension* is very limited, on account of the resistance of the anterior ligaments. The movement of *flexion*, on the contrary, is much more considerable: it may be carried sufficiently far to cause luxation of the head of the os magnum backward. The slight structure and the looseness of the posterior ligaments, and also the looseness of the synovial membrane behind, explain the facility which this articulation enjoys in the movements of flexion. It is of importance to remark, that the carpal enarthrosis performs a more active part in the flexion of the hand than even the radio-carpal articulation; a circumstance of the highest interest in relation to the mechanism of the carpus.

Metacarpal Articulations.

The metacarpal bones are united at their extremities, but separated along their shafts. We shall examine the articulations, 1. Of their carpal; and, 2. Of their digital extremities.

1. *Articulations of the Carpal Ends of the Metacarpal Bones.*

These are *symphyses* or *amphi-arthroses*. The *articular surfaces* (see *fig.* 73) occupy the sides of the carpal ends of the metacarpal bones, and are partly contiguous and partly continuous. The contiguous portion consists of a facette covered with cartilage, and is, in fact, an extension of the surface that articulates with the carpus. The part intended to become continuous is rough.

The *means of union* are the *interosseous*, the *dorsal*, and the *palmar ligaments*. The interosseous ligaments (*ff*, *fig.* 73) are short, close, and very strong bundles of fibres, interposed between the rough portions of the lateral facettes of two neighbouring metacarpal bones. They constitute the principal means of uniting these bones, as may be seen by attempting

Fig. 74.

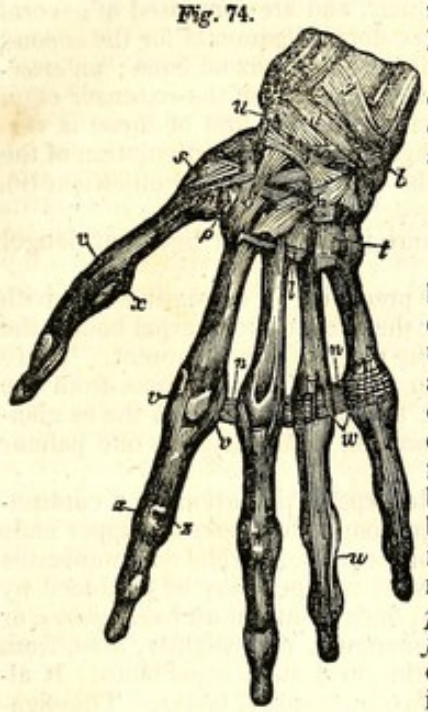

to separate them after dividing the dorsal and palmar ligaments.

The *dorsal* (*l*, *fig.* 74) and *palmar ligaments* (*m*, *fig.* 75) consist of fibrous bundles, stretched transversely from one metacarpal bone to another. The palmar ligaments are much larger than the dorsal.

2. *Articulation of the Digital Ends of the Metacarpal Bones.*

Although the digital extremities of the metacarpal bones are not, properly speaking, articulated together, yet as they are contiguous, and move upon each other, their surfaces are covered by a synovial membrane, which facilitates their movements; moreover, a *palmar ligament* (*n*, *figs.* 74, 75) is stretched transversely in front of these extremities, and unites them loosely together. This ligament (called also *transverse*) is common to the last four metacarpal bones, but it does not reach the metacarpal bone of the thumb. It may be considered as formed by the union of all the anterior ligaments of the metacarpo-phalangal articulations, and as being destined to render these ligaments continuous. In order to expose this ligament, and to study with attention its connexions with the anterior ligaments of the metacarpo-phalangal articulation, it is sufficient to open the fibrous sheaths of the flexor tendons of the fingers, and to remove the small lumbricales muscles, together with the nerves and vessels of the fingers.

Fig. 75.

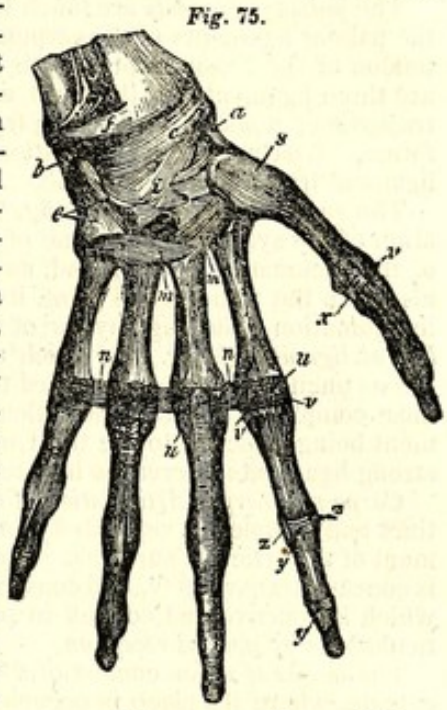

We may consider the *interosseous palmar aponeurosity* as representing, in respect to the shafts of the metacarpal bones, the aponeurosis called the interosseous ligament in the forearm. Strictly speaking, the thickened inferior border of the dorsal interosseous aponeurosis, which is continuous with the tendons of the extensor muscles, might be considered as a dorsal transverse ligament, much weaker than the preceding.

The interosseous muscles, as we shall afterward see, complete the means of union of the metacarpal bones.

Carpo-metacarpal Articulations.

The *articular surfaces* are the inferior facettes on the bones of the second row of the carpus, and the facettes on the upper ends of the metacarpal bones. We may consider all the carpo-metacarpal articulations as forming only one joint with a broken surface. The articulation of the trapezium with the metacarpal bone of the thumb, and that of the fifth metacarpal bone with the os unciforme, require each a special description.

Articulations of the Second, Third, and Fourth Metacarpal Bones with the Carpus.

Articular Surfaces (see *fig.* 73).—The articulation of the second, third, and fourth metacarpal bones with the carpus presents a sinuous line, which might, perhaps, be subjected to certain rules of disarticulation, if this disarticulation seemed to be of the least use. It constitutes a tight arthrodia, with an angular surface. Proceeding from within outward, the fourth and third metacarpal bones form a regular curve, with the concavity looking upward; but the second, which unites by three facettes with the trapezium, the trapezoid, and os magnum, presents an angular surface. The second metacarpal bone is jointed, by its transversely concave surface, with a facette on the trapezoid, which is concave, but in the opposite direction, and by two lateral facettes, with the os magnum and the trapezium, so that it enters, as it were, into the carpus by two angular projections, which are received into the intervals between the three bones with which it is articulated. From this it follows, that the carpo-metacarpal articulations present not only concave and convex surfaces, favourable to mobility, but also angular surfaces that evince the immobility of these joints.

Means of Union. — Some ligaments, distinguished as *dorsal* and *palmar*, both very strong, short, and compact, retain the articular surfaces as immovably in contact as if the joints were symphyses.

The *dorsal ligaments* are much stronger than the palmar, and are composed of several layers, the deepest being the shortest. There are three dorsal ligaments for the second metacarpal bone: a *median* (*o*, *fig.* 74), stretched to it from the trapezoid bone; an *external* (*p*), which comes from the trapezium, and covers the insertion of the extensor carpi radialis longior; and an *internal*, arising from the os magnum: the first of these is vertical, the last two are oblique. There are two dorsal ligaments in the articulation of the third metacarpal bone: a *vertical*, which comes from the os magnum; and an *oblique* (*r*), from the os unciforme.

In the articulation of the fourth metacarpal bone there is one dorsal ligament, longer and looser than the preceding.

The *palmar ligaments* are much less marked than the preceding; contrasting thus with the palmar ligaments of the carpus. There is none for the second metacarpal bone; the tendon of the flexor carpi radialis appears to supply the place of this ligament. There are three ligaments for the third metacarpal bone: an *external*, which comes from the trapezium; a *middle*, proceeding from the os magnum; and an *internal*, from the os unciforme. Lastly, for the articulation of the fourth metacarpal bone, there is one palmar ligament from the os unciforme.

The *synovial membrane* (see *fig.* 73) of the carpo-metacarpal articulations is a continuation of the synovial membrane of the carpus, and is prolonged between the upper ends of the metacarpal bones; and, as the synovial membrane of the carpus communicates also with the radio-carpal joint, it can be conceived what ravages may be produced by inflammation attacking any one of these parts. I must here point out an *interosseous*, or *lateral ligament* (*l*, *fig.* 73), which arises from the os magnum, and slightly, also, from the os unciforme, and is attached to the inner side of the third metacarpal bone. It almost completely isolates the articulations of the last two metacarpal bones. This ligament being attached to the third metacarpal bone, which is already provided with very strong ligaments, increases in a remarkable manner the strength of the joint.

Carpo-metacarpal Articulation of the Thumb.—This joint (*m*, *fig.* 73), which is very distinct and completely separated from all the others, is remarkable, also, for the arrangement of the articular surfaces. There is a mutual jointing between the trapezium, which is concave transversely, and convex from behind forward; and the first metacarpal bone, which is concave and convex in precisely opposite directions. It is the type of all articulations by *mutual reception*.

The *means of union* consist of a *capsular ligament* (*s*, *figs.* 74 and 75), imperfect on the outside, where its place is occupied occasionally by the tendon of the abductor longus pollicis (extensor ossis metacarpi pollicis): it is much thicker behind than in front, and is sufficiently loose to permit extensive motions in all directions. There is a separate *synovial membrane* for this joint, which is remarkable in respect of its relations: viz., 1. Behind, with the extensor muscles of the thumb; 2. On the outside, with the expanded tendon of the abductor pollicis; 3. On the inside, with the interosseous muscles and the radial artery, where that vessel penetrates into the palm of the hand, to form the deep palmar arch; and, 4. In front, with the muscles of the ball of the thumb.

Carpo-metacarpal Articulation of the fifth Metacarpal Bone (see *fig.* 73).—The articulation of the fifth metacarpal bone with the os unciforme is, in many respects, analogous to the preceding; for there is here, also, a sort of mutual reception between their corresponding articular surfaces. There is, also, a kind of capsular ligament (*t*, *fig.* 74), very strong in front and thin behind, and incomplete on the outside, on account of the presence of the fourth metacarpal bone: it is rather loose, and maintains the relation of the articular surfaces. The tendon of the extensor carpi ulnaris strengthens this joint behind, in the same manner as the tendon of the long abductor of the thumb strengthens the articulation of the trapezium and the first metacarpal bone.

The *synovial membrane* of this joint belongs also to the fourth metacarpal bone. The fourth and fifth metacarpal bones may, indeed, be strictly considered as forming only one joint, and the lateral interosseous ligament as completing the capsular ligament. On the other hand, the second and third metacarpal bones form a very distinct articulation with the os magnum, the trapezoid, and a small facette upon the trapezium; lastly, there is another joint peculiar to the first metacarpal bone and the trapezium. There are thus three distinct joints (see *fig.* 73) in the carpo-metacarpal articulation, in one of which the articular surfaces are simple, while in the two others they are broken.

Mechanism of the Carpo-metacarpal Articulations.

The mechanism of the carpo-metacarpal articulations should be studied, both as regards strength and mobility.

1. *With regard to strength*, the metacarpal bones mutually support each other, and resist in common the action of external agents: they can only be broken, therefore, by violence sufficient to fracture several at the same time. In order that any one should be broken alone, the violence must be applied directly to it. In this manner I have seen the third metacarpal bone fractured by the stick of a rocket.

The great strength of the metacarpus depends not only on the simultaneous resistance

of its component parts, but also on the intervening articulations, each of which becomes the seat of a certain expenditure of force; for part of this being employed in moving the articular surfaces upon each other, is necessarily lost as far as its direct transmission is concerned.

With regard to mobility, these articulations, which might be called tight angular arthrodias, are only possessed of slight gliding motions, on account of the angular disposition of the articular facettes, the sinuosity of the common articular line, and the strength and shortness of both the external and the interosseous ligaments. At the same time, the mobility of all the metacarpal bones is not equal. Thus, the articulation of the trapezium with the first metacarpal bone holds the first rank; it is in some degree different from the others in this respect as well as in position, and merits particular description. The articulation of the fifth metacarpal bone holds the second place, and that of the fourth the third. The articulations of the second and third metacarpal bones are as immovable as symphyses.

Mechanism of the Articulation of the Trapezium and the first Metacarpal Bone.—From the mutual reception of the articular surfaces, this articulation permits four motions, viz., flexion, extension, abduction, and adduction, and, as a consequence of these, circumduction.

Flexion is not performed directly, but obliquely inward and forward. This oblique motion produces the *movement of opposition*, which characterizes the hand; it is very extensive, and, when carried too far, may produce luxation backward with the greater facility, because the capsular ligament is very thin in that direction. *Extension* may be carried so far that the first metacarpal bone may form a right angle with the radius. It is conceivable that luxation forward might be produced by this motion; but there are very few causes that would tend to increase extension to such a degree, and, moreover, the anterior part of the capsular ligament is extremely strong, so that no example of this luxation has ever been recorded.

Abduction is very extensive; when carried beyond a certain point, it may give rise to dislocation inward, for the trapezium, being situated on a plane anterior to the root of the metacarpus, the neighbouring metacarpal bones offer no obstacle to such a displacement.

Lastly, direct *adduction* is limited by the meeting with the second metacarpal bone.

Mechanism of the Articulation of the fifth Metacarpal Bone with the Cuneiform.—This articulation in some degree resembles the preceding, and, like the last, it would be liable to dislocation, were it not for its intimate connexions with the other metacarpal bones, so that the same cause that would tend to displace the fifth metacarpal bone would also tend to displace the fourth.

Articulations of the Fingers (*figs.* 74 and 75).

These comprise, 1. The articulations of the fingers with the metacarpal bones. 2. The articulations of the phalanges together.

Metacarpo-phalangal Articulations.

These belong to the class of condyloid articulations.

The *articular surfaces* in each are formed by the head of the metacarpal bone, flattened from side to side, increasing in breadth from the dorsal to the palmar aspect, and prolonged much farther in the latter direction, where it presents the trace of a division into two condyles; and by the shallow *glenoid cavity* of the first phalanx, which is transversely oblong, and, consequently, has its long diameter at right angles to that of the head of the metacarpal bone, which is oblong from before backward. We see, then, that an articular head, elongated from before backward, is adapted to a transversely oblong cavity. This arrangement favours the movements of flexion and extension, as well as the lateral motions, which are as extensive as they would have been had all the diameters of the articular surfaces been equal to those which are actually the longest.

It is on account of the lateral flattening of the heads of the metacarpal bones that, in amputations at these joints, surgeons make choice of lateral, in preference to anteroposterior flaps.

Means of Union.—On account of the disproportion just noticed as existing between the articular surfaces of this joint, the glenoid cavity of the first phalanx not being equal to more than one half of the articular surface on the metacarpal bone, this cavity is provided with a ligament called the *anterior ligament* (*u*, *fig.* 75), which was confounded by the older anatomists with the fibrous sheaths of the flexor tendons. This ligament I have called the glenoid ligament, and its use is to complete the cavity of reception of the metacarpal condyle. It is situated on the palmer aspect of the joint, and is grooved anteriorly, to correspond with the flexor tendons. It is concave, forming, so to say, a demi-capsule behind, to correspond with the metacarpal condyle. By its edges it is continuous not only with the transverse metacarpal ligament, which is one of its appurtenances, but also with the sheath of the flexor tendons, and with the lateral ligaments of the joint. By its superior border this ligament is continuous with the palmar interosseous aponeurosis, and with the digital bands of the palmar aponeurosis. By its lower edge it is firmly fixed to the anterior part of the margin of the first phalangal articular

surface; its upper edge is loosely connected by some ligamentous fibres to the contracted neck which supports the head of the metacarpus, and is accurately adapted to that neck. The anterior or capsular ligament is very thick, unyielding, formed of fibres that cross each other, and look like mother-of-pearl, and is as compact as cartilage. Several times I have found a sesamoid bone in the substance of the anterior ligament of the index and the middle finger. The whole tendinous sheath of the tendons of the flexor muscles may be considered as making part of this anterior ligament, and we ought not to overlook these tendons in estimating the solidity of the joint with regard to flexion. This joint has two *lateral ligaments*, which are extremely unyielding, an internal and an external; they are inserted into a marked tubercle existing posteriorly on each side of the lower extremities of the metacarpal bones, and into a very remarkable depression below and before this tubercle; hence these ligaments extend very obliquely from behind forward and from above downward, in the shape of a strong and flat band, looking like mother-of-pearl, which continually expands and irradiates, and finally terminates, 1. In a tubercle existing anteriorly, and on each side of the margin of the upper end of the first phalangal bone. 2. By its superior fibres into the borders of the anterior ligament.

These lateral ligaments extend, therefore, obliquely from the posterior tubercle of the lower end of the metacarpus to the anterior tubercle of the upper end of the first phalangal bone; they are stretched by flexion, which cannot be extended beyond the right angle without the ligaments being torn; and they are relaxed by extension, except that portion of these ligaments which goes to the anterior ligament, and which limits the extension by its resistance. It may be interesting to remark, that the external lateral ligament is much stronger than the internal; the former of these ligaments is inserted not only into the tubercle, but also into the whole extent of the subjacent depression.

There is no dorsal ligament properly so called; its place is evidently supplied by the corresponding extensor tendon (*w*, *fig.* 74). This extensor tendon, after having reached the level of the joint, becomes narrow, and contracts, as it were, upon itself, in order to form a thick and extremely compact cord. From each edge of this ligament an aponeurotic expansion arises, which is inserted into the sides of the joint.

The *synovial capsule* is extremely loose, especially on the aspect of extension; it does not adhere to the tendon, but is folded upon itself during extension, and is stretched during flexion: it lines the inner surface of the lateral ligaments, and is reflected upon the articular cartilages.

Metacarpal-phalangal Articulation of the Thumb.—Two sesamoid bones (*x*, *figs.* 73 and 75) are annexed to this articulation in front, and are constantly found in the glenoid ligament; they afford insertion to the lateral ligaments and to all the short muscles of the thumb.

If we examine these articulations in connexion, we shall find that they are disposed in a curved line, with the convexity looking downward. This curvature is slightly interrupted at the articulation of the fourth metacarpal bone, which is not on a level with those of the index and the middle fingers.

Mechanism of the Metacarpo-phalangal Articulations.

We shall take as an example the metacarpo-phalangal articulation of the middle finger. From the arrangement of the articular surfaces, it is evident that this articulation can execute movements in four principal directions, and, consequently, those of circumduction also. From a simple inspection of the surfaces, it might be inferred that the movement of flexion must be very extensive, while that of extension (or flexion backward) and the lateral motions of abduction and adduction are exceedingly limited. The arrangement of the ligaments amply confirms these suppositions. It should be noticed, as a rare exception, that in the movements executed by this joint, it is not the head that moves upon the cavity, but the cavity that moves upon the head.

In *flexion*, the first phalanx glides forward upon the head of the corresponding metacarpal bone; the extensor tendon and the back of the synovial capsule are stretched by the projecting head of this bone: the posterior fibres of the lateral ligaments are also stretched; they limit the movement of flexion, allowing it only to proceed so far that the phalanx forms a right angle with the metacarpal bone. Lastly, flexion can be carried somewhat farther by the thumb, the ring, and the little fingers, than by the others. In *extension*, the phalanx glides backward upon the head of the metacarpal bone supporting it: this head corresponds almost entirely with the anterior ligament, which, as we have seen, is disposed in the shape of a fibrous demi-capsule. The posterior fibres of the lateral ligaments are relaxed, and the anterior stretched. The motion is evidently limited by the anterior or capsular ligament, and by the anterior fibres of the lateral ligaments, which are inserted into this anterior ligament. I may remark, that the upper border of this anterior ligament forms a sort of ring or collar, which surrounds almost entirely the neck of the corresponding metacarpal bone, without adhering to it.

According to the relative size of this ring, and the comparative looseness of the glenoid ligament, will the movement of extension be more or less considerable. In all persons it may be carried so far as to form an obtuse angle behind; in some, until a right angle

is formed; and in a few, even so far as to produce an incomplete luxation, reducible by the slightest muscular effort. If extension be carried beyond these limits (for which, however, considerable violence is necessary), the head of the metacarpal bone will escape from the kind of collar formed by the superior border of the capsular ligament and the anterior fibres of the lateral ligaments, sometimes by extensively lacerating it, but at others only by stretching it very much; in both cases the first phalanx is dislocated backward, or the metacarpal bone forward. When the collar is not torn, reduction is almost impossible, because the glenoid ligament is always interposed between the articular surfaces. It should be remarked, that the metacarpo-phalangal articulation of the thumb is the only one which is not capable of flexion backward. This is probably owing to the want of looseness in its anterior or capsular ligament. In this joint, the movement of extension does not go beyond the straight line; in this respect it resembles the articulations which the phalanges form with each other.*

Adduction and *abduction* consist of simple lateral glidings, limited by the meeting of the other fingers.

Articulations of the Phalanges of the Fingers.

These are pulley-like joints, or perfect angular ginglymi. There are two articulations of this kind in each finger, but only one in the thumb.

Articular Surfaces.—The lower end of the first phalanx, flattened from before backward, presents a trochlea, broader on the palmar than on the dorsal aspect, and prolonged much farther in front than behind. The trochlea of the phalanx resembles the lower end of the femur, with this difference, that its two condyles are not separated from each other. The upper end of the second phalanx, also flattened from before backward, presents two small glenoid cavities, separated by an antero-posterior ridge. The ridge corresponds to the groove of the pulley, and the glenoid cavities to the two condyles.

Means of Union.—1. An *anterior ligament* (*y*, *fig.* 74), grooved anteriorly, to serve the tendon as a sheath, and exactly resembling what exists in the metacarpo-phalangal articulations, and performing the same office of deepening the glenoid cavity, which by itself only imperfectly receives the pulley of the first phalanx. 2. Two *lateral ligaments*, an *internal* (*z*) and an *external* (*z'*), arranged precisely in the same manner as the lateral ligaments of the metacarpo-phalangal articulations. They are attached to tubercles situated behind the lateral depressions, on the lower end of the first phalanx, and pass obliquely forward, to be inserted both into the glenoid ligament and the second phalanx. There is no posterior ligament, its place being supplied by the extensor tendon. This tendon is disposed in a peculiar manner: it gives off constantly a prolongation (*w*) from its anterior aspect, which is inserted into the upper end of the second phalanx, so that this bone presents a somewhat similar arrangement behind, as it does in front, with the flexor tendon. This prolongation has a cartilaginous aspect.

The *synovial capsule* is precisely similar to that of the metacarpo-phalangal joints. The foregoing description applies equally well to the articulation of the second with the third phalanx. There is often a sesamoid bone in the substance of the glenoid ligament of the two phalangal joints of the thumb.

Mechanism of the Phalanges.

The fingers are essentially the organs of prehension and of touch. In the mechanism of touch, the fingers are moved over the surfaces of bodies, and are moulded upon even their slightest inequalities, sometimes acting together, sometimes separately, seizing and moving between them, as between the blades of sentient forceps, even the most delicate objects. For the performance of this function, great mobility must be conjoined with great precision of movement. On the other hand, for the purpose of seizing bodies, of retaining, repulsing, or breaking them, as well as of acting as the means of attack and defence, considerable power is required; all which qualities are united in the mechanism of the hand. Observe the number of the fingers and their complete isolation, so that they can act either together or separately, and even in opposite directions. Notice the number of the phalanges, their successive decrease in size, and the facility with which they can be separated or made to approach each other, so as to be applied around spherical bodies. Note, also, the inequality of the fingers in length and power, enabling each to act a determinate part in prehension; and, above all, remark the shortness of the thumb, which only reaches the base of the first phalanx of the index finger; but which, placed as it is upon a plane anterior to the rest, and endowed with a greater degree of mobility, can be opposed to all the fingers together, to each finger separately, and to every phalanx of each, thus constituting the principal blade of the sentient forceps represented by the hand; for, being more strongly constructed, and provided with more powerful muscles than the other fingers, it in some degree counterbalances them all.

* This is, I believe, the anatomical reason why a reduction of the dislocations forward of the metacarpo-phalangal articulations of the thumb and the other fingers is difficult, and sometimes impossible. The most skilful practitioners have sometimes failed in this reduction, and especially in dislocations of the thumb; gangrene and death have often taken place in consequence of the violent attempts at reduction. I am certain that the vertical section of the anterior ligament would obviate the difficulty at once.

Mechanism of the Phalangal Articulations.

From the shape of the articular surfaces, which form a miniature representation of the knee, it is evident that the only motions of which these joints are capable are flexion and extension. The *flexion* of the second upon the first phalanx is as extensive as it could possibly be, for it is only limited by the meeting of the anterior surfaces of these bones. The amount of *flexion* of the third phalanx upon the second is less considerable. The *extension* of the second phalanx upon the first, and that of the third upon the second, are limited, as in the metacarpo-phalangal joints, by the anterior glenoid and the lateral ligaments. This motion of the phalanges is extremely slight; I have never seen them carried farther back than to form a straight line.

From what has been observed, it follows that, as regards its movements, each finger represents a shortened or miniature limb; that, at its articulation with the metacarpus, it is capable of motions in every direction, and also of circumduction; that, from the joints between the phalanges, it is endowed with the power of strong, extensive, and accurate flexion; and that, from the double bending of the second upon the first, and the third upon the second phalanges, the fingers represent a true hook for seizing and clinging to external objects.

ARTICULATIONS OF THE INFERIOR OR ABDOMINAL EXTREMITIES.

Articulations of the Pelvis.—Coxo-femoral.—Knee-joint.—Peroneo-tibial.—Ankle-joint.—Of the Tarsus.—Tarso-metatarsal.—Of the Toes.

Articulations of the Pelvis (*figs.* 76, 77).

The articulations of the pelvis are, 1. The sacro-iliac symphysis; 2. The symphysis pubis; and, 3. The sacro-coccygeal articulation. The last has been already described with the other articulations of the vertebral column.

Sacro-iliac Symphysis.

Preparation.—1. Detach the pelvis from the rest of the trunk; 2. Saw through the horizontal ramus and arch of the pubes at the distance of about eighteen lines on each side of the symphysis; 3. Dislocate the os innominatum of one side; 4. Dissect the anterior ligaments of the sacro-iliac symphysis upon the other; 5. Then make a horizontal section of that articulation, dividing it into an upper and a lower half.

The sacro-iliac articulation belongs to the class of symphyses or amphi-arthroses.

The *articular surfaces* are formed on the sacrum and os innominatum, and are partly contiguous and partly continuous. The contiguous surfaces of these two bones are anterior to the others, and are shaped like an ear, with the convex edge turned forward; hence they are called the auricular surfaces. The parts which are rendered continuous by means of ligamentous fibres consist of the entire space comprised between the auricular portion and the posterior border of the os innominatum, and of all the lateral surface of the sacrum not occupied by the auricular facette. The continuous portions are both marked with very rugged eminences and depressions. These articular surfaces are also remarkable from being sinuous and alternately concave and convex, and from their presenting a well-marked obliquity in two directions, viz., from above downward, and from before backward and inward, so that the sacrum is, as it were, wedged between the ossa innominata both in a vertical and an antero-posterior direction.

Means of Union.—The auricular surfaces are covered with cartilage, which is thicker upon the sacrum than on the os innominatum, and is remarkable for the roughness of its surface, which contrasts with the smooth appearance of other articular cartilages. There is a distinct synovial membrane in this joint in the infant and pregnant female, but it can scarcely be detected in the adult and the aged. The ligaments are, 1. An *anterior sacro-iliac ligament* (*b*, *figs.* 76, 77), a very thin layer which passes in front of this articulation, and composed of fibres stretched transversely from the sacrum to the ilium. 2. A *superior sacro-iliac ligament* (4, *fig.* 52), a very thick bundle, extending transversely from the base of the sacrum to the contiguous portion of the ilium. 3. An *interosseous ligament*, which forms the strongest bond of union in this joint, composed of a great number of ligamentous fibres, stretched horizontally from the ilium to the sacrum, crossing each other, and filling up almost the whole of the deep excavation comprised between the two bones; these fibres leave small inter-

Fig. 76.

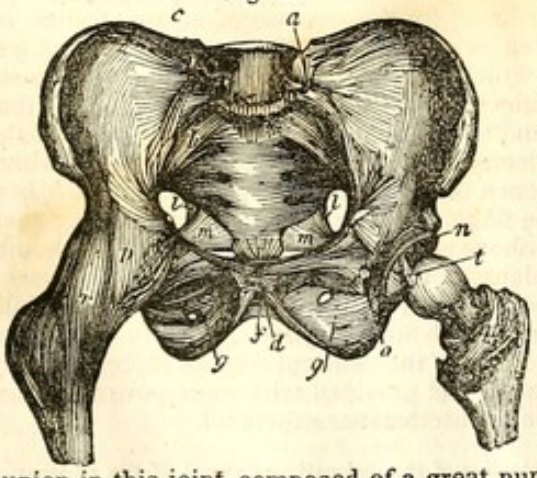

vals between them, which are occupied by fat, and traversed by numerous small veins. One of these bundles merits a special description : it consists of a long and strong band extending almost vertically from the posterior superior spinous process of the ilium to a thick tubercle on the third sacral vertebra ; it may be called the *posterior vertical sacro-iliac ligament*. 4. The *ilio-lumbar ligament* (*c, figs.* 76, 77) may be considered as belonging to this joint ; it extends from the summit of the transverse process of the fifth lumbar vertebra to the thickest part of the crest of the ilium, that is, to the enlargement situated about two inches in front of the posterior superior iliac spine. It is a thick and very strong triangular bundle.

Symphysis Pubis.

Preparation.—This requires no special direction : only, in order to become acquainted with the respective extent of the contiguous and continuous portions, it is necessary to make two sections, a horizontal section, and also a vertical one from before backward.

The *articular surfaces* (*e, fig.* 77) are oval, having their longest diameters directed vertically ; they are flat, and obliquely cut from behind forward and outward. They are, therefore, separated by a triangular interval, the base of which is directed forward, and the apex backward. We should observe, concerning this articulation, that there are many varieties in the respective extent of the contiguous and continuous portions of the articular surfaces. Sometimes they are almost wholly continuous ; at other times, on the contrary, they are nearly altogether contiguous. I have observed this latter disposition in a very remarkable degree in the symphysis of a young woman who died in the sixth month of pregnancy.

The *means of union* are the following : 1. An *anterior pubic ligament* (*d, fig.* 76), a very thin fibrous layer, the posterior portion of which is blended with the interosseous ligament : it is composed of fibres extending from the spine of each os pubis obliquely to the anterior surface of the opposite pubic bone ; those from the left side pass in front of those from the right. 2. A *posterior pubic ligament*, extremely thin, and covering the prominence formed by the ossa pubis behind, at the place of their articulation. This prominence, which is very marked in old subjects, seems to be produced by a jutting out of the posterior table of the bone backward, apparently caused by the pressure of one articular surface upon the other ; these surfaces being, as we have described, in contact behind, but separate in front. In a female who died of peritonitis soon after delivery, I found this posterior prominence of the pubes forming a sort of spine of some lines in diameter from before backward. 3. A *superior pubic ligament* (*e, fig.* 76), very thick, and continuous on each side, with a fibrous cord, that covers the upper edge of the os pubis, and effaces its irregularities. 4. An *inferior pubic* or *triangular ligament* (*f, fig.* 76), which is exceedingly strong ; it forms a continuation of the anterior and interosseous ligaments, and is composed of interlacing fibres : this ligament renders the angle formed by the ossa pubis obtuse, and gives to the arch of the pubes that regular curve presented by it to the head of the fœtus during labour. 5. An *interosseous ligament* (*e, fig.* 77), which occupies the whole non-contiguous portion of the articular surfaces, and varies greatly in thickness in different individuals. This ligament forms the principal means of union between the bones of the pubes ; it fills up the vacant space of a line and a half to two lines, which exists between the articular surfaces, and is composed of fibres, which cross each other like those of the intervertebral substances.*

Of the Sub-pubic or Obturator Membrane, and the Sacro-sciatic Ligament.

We place the description of the obturator and sacro-sciatic ligaments next to that of the articulations of the pelvis, simply remarking that they can scarcely be considered true ligaments, but rather aponeuroses, which serve to complete the parietes of the pelvis, without contributing anything to the strength of the pelvic articulations. In trying to account for the great obturator foramen and the great sciatic notch, I have asked myself the question whether these great openings, independently of their transmitting vessels, nerves, and muscles, did not result from that law of osteology, by means of which the bones, the levers of the muscular power, are formed with the least possible weight and volume. How much heavier would the pelvis have been, if the obturator foramen and the great sciatic notch had been filled with osseous tissue. It would have been useless, for the strength of the pelvis would not have been increased in any way by such an arrangement. Perhaps these strong but flexible membranes are also useful during the progress of labour, by diminishing the pressure of the soft parts of the mother between the head of the child and the bones of the pelvis.

* From analogy, we may infer an identical disposition in the pubic and vertebral symphysis. Thus it will be seen that the articular surfaces in these two articulations are not fitted to each other. In the symphyis pubis, however, we discover an additional degree of mobility ; the articular surfaces are contiguous to a greater extent, and the synovial membrane is so perfect that no anatomist has yet doubted it. The symphysis pubis might, therefore, be regarded as the transition between the movable articulations and the mixed or symphyses. The obliquity in an inverse direction of the articular surfaces is the cause why the symphysis pubis is much larger in front than behind ; hence, in *symphyseotomy* or a *section of the symphysis*, the knife must be applied to the anterior portion of the symphysis, so that the articulation may be entered into with more safety. It is clear that a trocar could not be thrust into the bladder through the symphysis, on account of its being too narrow behind to admit of its passage.

Sub-pubic or *Obturator Membrane* (*g*, *figs.* 76, 77).—This membrane closes the obturator (sub-pubic) foramen, excepting at its upper part, where we find a notch, by which the groove for the obturator vessels and nerves is converted into a canal. The external half of its circumference is attached to the corresponding margin of the obturator foramen, and the internal half to the posterior surface of the ascending ramus of the ischium; its two surfaces give attachment to the obturator muscles. The obturator membrane is composed of aponeurotic bundles, which look like mother-of-pearl, and are interlaced in every direction. An interesting point of its structure is its being formed of several layers of fibres, and small bristle-shaped collections of fibres arising constantly from the internal half of the margin of the obturator foramen, which expand upon the anterior surface of the membrane, and afterward intermingle with the periosteum. There is also to be found a very strong parcel arising from a sort of spine upon the margin of the obturator foramen, immediately above the level of the great cotyloid notch.

Sacro-sciatic Ligaments.—These are divided into the *great* and the *small*: we apply the term ligaments to them rather on account of their fasciculated shape than from their use, which scarcely has reference to the union of the bones of the pelvis.

The *great sacro-sciatic ligament* (*l*, *figs.* 76, 77) arises from a ridge situated on the internal lip of the tuberosity of the ischium, and also from the ascending ramus of the same bone, by a curved margin of considerable extent, having its concavity directed upward, which, with the inner surface of the tuberosity of the bone, forms a groove for the protection of the internal pubic vessels and nerves. The most superficial fibres of this ligament are partly continuous with the common tendon of the biceps and the semi-tendinosus. Immediately after its origin, from its fibres being collected together, it becomes very narrow and thick, and is directed upward and inward; it then expands considerably, and is inserted into the edges of the sacrum and coccyx, and more slightly into the posterior part of the crest of the ilium, as far as the posterior and superior spinous process of this bone. Its upper edge, or, rather, its external, is vertical, and is continuous with the aponeurosis, extending over the pyriformis muscle. Its internal edge, which forms a curve, and which is almost horizontal, makes part of the inferior circumference of the small pelvis; it lines the small sacro-sciatic ligament, to which it adheres at its insertion into the coccyx, and from which it is separated externally by a triangular space, where it is in relation with the internal obturator muscle; it is covered by the gluteus maximus, to which it furnishes a great number of aponeurotic insertions. This disposition increases the thickness of this ligament considerably, and gives to its posterior surface the rugged, rough, and, as it were, lacerated aspect, which is a characteristic of that surface. The great sacro-sciatic ligament is composed of bundles, several of which, on a level with the narrowest portion of this ligament, are interlaced in the shape of the letter X. Several of these ligaments, which are external at their sciatic insertion, become internal at their insertion into the coccyx, and vice versa. The great sacro-sciatic ligament and the posterior and superior sacro-iliac ligaments constitute a fibrous plane in the shape of bundles, arising from the superior posterior spinous process of the ilium, and extending in various directions.

Fig. 77.

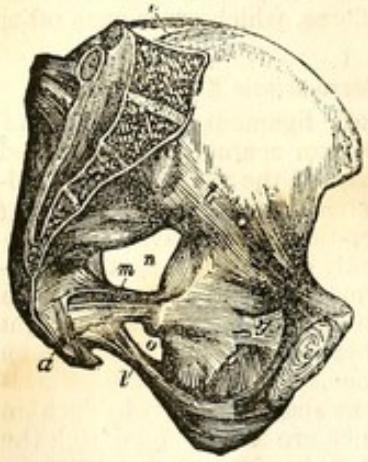

The *small sacro-sciatic ligament* (*m*, *figs.* 76, 77), placed in front of the preceding, and extremely thin, arises from the summit of the spine of the ischium, passes inward, and, becoming thinner, is lost upon the anterior surface of the great sacro-sciatic ligament. The two sacro-sciatic ligaments divide the great sacro-sciatic notch into two distinct foramina: the upper (*n*, *fig.* 77) is very large, and shaped like a triangle with the angles rounded off, and is in a great measure filled up by the coccygeus and pyriformis muscles; it gives passage also to the great and small sciatic nerves, to the ischiatic vessels, and to the gluteal and internal pudic vessels and nerves, and to a large quantity of cellular tissue. That form of hernia which is called *sciatic* takes place through this foramen. The lower (*o*, *fig.* 77) is much smaller; it is situated between the spine and tuberosity of the ischium, and gives passage to the obturator internus muscle, and to the internal pudic vessels and nerves.

Mechanism of the Pelvis.

The mechanism of the pelvis should be regarded in four distinct points of view: 1. As affording protection to the contained viscera; 2. In relation to the part which it performs in the mechanism of standing and progression; 3. In connexion with the phenom ena of parturition; and, 4. In reference to the motions which take place at its articula tions with other bones, and those between its own component parts.

1. *Mechanism of the Pelvis considered as a Protecting Structure.*—The following are the conditions in the structure of the pelvis, having reference to its office as a protector of the contained viscera: 1. Behind; the presence of the sacrum, which is itself protected,

as well as the nerves that pass through it, by the great prominence of the posterior iliac tuberosities, which project considerably beyond it; 2. On the sides, by the crest of the ilium, and the prominence of the trochanters, which so often preserve the pelvis from external violence. With regard to the large notch in front, which leaves the viscera situated on a level with it, unprotected, it may be remarked, that the viscera contained in the small pelvis, being liable to considerable changes of volume, require to leave the osseous and unyielding space which contains them when empty, in order that they may extend into a cavity the walls of which are soft, and may be dilated almost indefinitely; 3. In front the means of protection are much less efficacious, in consequence of the vast notch which is situated in this region.

The partial absence of the bony parietes in front has reference to the great variations in size which the viscera of the pelvis can undergo, and which would have been incompatible with the existence of an osseous cincture, incapable of dilatation. The absence of bony walls in the situation of the three great notches, presented by the outlet of the pelvis, is also unfavourable to its solidity; but it has many other important uses, particularly in the mechanism of labour. The pelvis, especially at its upper part, where it is most exposed to injury, is enabled to resist external violence by virtue of its vaulted construction. Part of the impulse, also, is lost in producing the slight degree of gliding motion permitted at the symphysis pubis. Where, however, the power of resistance possessed by the pelvis is overcome, it will be seen at once that the parts most liable to fracture are the ascending rami of the ischia at their junction with the descending rami of the ossa pubis.

2. *Mechanism of the Pelvis with regard to Standing and Progression.*—The part performed by the pelvis in *standing* is connected with the transmission of the weight of the trunk to the lower extremities; this is effected by means of the sacrum, which rests upon the ossa innominata. We should add, that a small portion of the weight is directly transmitted to the femurs by the iliac bones, which support the viscera of the abdomen.

The following arrangements should be noted, as being concerned in the transmission of the weight by means of the sacrum: 1. The great size of that bone, affording evidence of the destination of man for the erect posture. 2. The obtuse angle at which the sacrum unites with the vertebral column, peculiar to the human species, and which becomes the seat of a decomposition of the force transmitted by the spine. Part of the momentum acting in the direction of the axis of the column has no other effect than that of increasing the sacro-vertebral angle, at the expense of the flexibility of the inter-articular cartilage; the rest is transmitted to the sacrum, and then to the lower extremities. 3. The double wedge shape of the sacrum itself. In order to understand the advantage arising from this form, it is necessary to remark, first, that the weight of the trunk is transmitted in the axis of the upper half of the sacrum, and, consequently, in the direction of a line sloping downward and backward; from this it follows, that the sacrum must have a tendency to be displaced either downward or backward, but the displacement downward is prevented by the position of the ossa innominata, which are nearer to each other below than above. The displacement backward is obviated by the oblique direction of the articular surfaces of the same bones backward and inward, while the obliquity of the sacrum itself is in the opposite direction, for it is broader in front than behind.* 4. The distance intervening between the sacro-iliac and the coxo-femoral articulations. The articulation of the vertebral column with the pelvis being situated at the back part of that cavity, while those of the femurs are situated towards the front and the side, the distance between them increases the space in which the centre of gravity can oscillate, without being carried so far forward as to pass beyond the perpendicular let fall from the coxo-femoral articulation to the base of support. In man alone is found a large pelvian basis of support, and thus the erect posture has been rendered possible in him, without an excessive extension in front.

In quadrupeds, the antero-posterior diameter of the bones of the ilium is rather short, and their haunch bones are elongated behind, and placed in almost the same plane as the vertebral column. The fœtus and new-born infant somewhat resemble the lower animals in this respect, and, therefore, in the human subject there is a great tendency to assume the attitude of a quadruped during the first year of existence.

The weight received by the sacrum and transmitted to the haunch bones is divided, sometimes equally and sometimes unequally, between the sacro-iliac symphyses. One portion of the impulse calls into action the mobility of the symphyses, and the remainder is transmitted to the cotyloid cavities. It should be remarked, that this transmission is effected along the triangular prismatic columns, which form the sides of the inlet of the pelvis, and are the thickest and strongest parts of that structure. At the foot of these

* Without admitting that the influences to which the sacrum is subjected have a tendency to force it backward as well as downward, it is impossible to explain either the use of its being shaped like a wedge, with the base turned forward, or of that powerful apparatus of posterior ligaments which can only resist its dislocation backward. The idea that these forces tend to press it forward is manifestly at variance with the nature of the uniting media; for the sacro-iliac symphyses are only maintained in front by a very thin ligamentous layer, and the breadth of the space between the iliac bones is also greater in front than behind; circumstances that would evidently facilitate displacement forward.

columns, which form curves, we find, dug, as it were, into their substances, the cotyloid cavities, to which the weight of the trunk is transmitted. During the sitting posture, the weight of the body is transmitted to the tuberosities of the ischia, which, from their great size, are well fitted to support it. As these processes are a little anterior to the cotyloid cavities, and, therefore, situated in a plane very near the front of the pelvis, the centre of gravity of the trunk has a tendency to fall behind the basis of support represented by them; and, therefore, it is easy to push an individual backward when in the sitting posture, inasmuch as in front the basis for the support of the pelvis is increased by the length of the femurs and the length of the foot while man is seated on a chair, and the whole length of the abdominal extremity while he is seated on a horizontal plane. The mode in which the pelvis resists violence applied to the tuberosities of the ischia in falls, is somewhat connected with its mechanism as adapted to the sitting posture. The shock is, in these cases, transmitted directly upward in the direction of the acetabula, the lower hemispheres of which offer resistance like two arches: from the acetabula the impulse is communicated backward, by the thick columns extending from behind these cavities, to the sacro-iliac symphyses; and forward, to the symphysis pubis; so that falls upon the tuberosities are almost always accompanied with painful concussion both of the sacro-iliac and pubic symphyses.

In order to complete our account of the mechanism of the pelvis in standing, we must examine its mode of resistance in falls upon the knees or soles of the feet. In this case, the shock is communicated from below upward to the upper halves of the cotyloid cavities, which are supported by the prismatic columns already described. The anterior part of each acetabulum presents a large notch, and is altogether unconcerned in the transmission of these shocks; so, also, is the very thin lamina constituting the bottom or inner wall of the cavity, which can only suffer compression in falls upon the great trochanter. The great difference existing between a fall upon the knees and the tuberosities of the ischia, and the fall upon the points of the feet, with regard to a commotion of the brain and the spinal marrow, may be easily conceived. While standing on one foot the weight of the trunk is transmitted to the femur by the sacro-iliac symphyses, and by the curve-shaped column of the side which bears upon the ground. In this position a fall readily takes place, on account of the facility with which the centre of gravity passes the basis of support.

During progression, the pelvis affords to each thigh alternately a solid fulcrum, and receives itself a fixed point of support from the femur of that leg which rests upon the ground. While one side of the pelvis is thus supported upon one of the thigh bones, the other side is projected forward. These alternate movements of projection of either side of the pelvis take place at the coxo-femoral articulation of the extremity which rests upon the ground. The alternate movements of projection increase in proportion to the breadth of the pelvis. It is for this reason that women, in walking, move the hips more than men. The remark of a witty author, that "running is the only thing which women are unable to do gracefully," is an allusion to this rather awkward motion of the pelvis. We may form a correct idea of the share which the pelvis takes in the act of walking by studying the mode of progression of persons with wooden legs. In these unfortunate beings the lateral inclinations of the pelvis are sufficient for progression by transporting the centre of gravity alternately to the two inflexible columns substituted for the lower extremities.

3. *Mechanism of the Pelvis with regard to Parturition.* — The art of midwifery depends, in a great measure, upon the study of the pelvis; it is impossible to form a true conception of the mechanism of natural labour without being acquainted with the axes of the pelvis, its dimensions as compared with the size of the fœtus, the sacro-vertebral angle, the inclined planes of the true pelvis, the diameters of the brim and the outlet, and the malformations to which it is liable. Any lengthened details upon these points would be out of place here. I shall only remark, 1. That the existence of the arch of the pubes is peculiar to the human species; and, 2. That the sciatic notches and the obturator foramina are not only useful from economizing weight, but also because, corresponding as they do to the oblique diameters of the head of the fœtus during parturition, they render less painful the pressure attendant upon that process; 3. That the pyramidales, the internal obturators, and the psoæ and iliaci muscles perform, so to speak, the office of mattresses in the pelvic cavity; 4. That parturition, consisting in the expulsion of the fœtus along the line of the pelvis, natural parturition, provided the expulsive power exists in its normal conditions, depends partly on a true conformation of the pelvis, and partly on a true conformation and position of the fœtus; 5. That a general idea of all the defects which may occur in the conformation of the pelvis may be expressed by stating, that this cavity is liable to all the malformations which may result from a pressure upon its whole brim or only a part of it, from above downward, from below upward, from before backward, or from side to side.

4. *Mechanism of the Pelvis with regard to its own Movements.*—The intrinsic movements of the pelvis are very obscure, being confined to mere gliding or swinging motions, the production of which destroys part of the momentum from any external violence. By

some admirable contrivance, the mobility of the intrinsic articulations of the pelvis is considerably increased during the latter periods of pregnancy, so that the coccyx may be pressed backward, causing an increase of five or six lines in the antero-posterior diameter of the outlet; while the symphysis pubis* becomes susceptible of a slight separation, which increases (in a very slight degree, it is true, but sufficiently to merit notice) the dimensions of the brim of this cavity. This mobility, which is especially remarkable in a narrow pelvis, favours the process of labour in a singular degree. The natural mobility of the symphysis pubis has suggested the operation of symphyseotomy, by which the diameters of the pelvis, however, are but little increased, unless the severing of the bones of the pubes should be carried far enough to result in a separation of the sacro-iliac symphysis. A relaxation taking place in the symphysis of the pelvis may give rise to strange errors in diagnosis.

The extrinsic movements of the pelvis are those of flexion, extension, lateral inclination, and rotation: these motions, which are all very limited, have been indicated in describing the mechanism of the vertebral column. The motions of the pelvis upon the thighs are very considerable: they will be examined with the mechanism of the hip-joint.

Coxo-femoral Articulation (*fig.* 76).

Preparation.—Remove with care all the muscles that surround the joint, preserving the reflected tendon of the rectus femoris. The psoas and iliacus muscles, the synovial capsule of which so often communicates with the articular synovial membrane, must be removed with particular care. After the fibrous capsule has been studied upon its external surface, a circular division should be made round its middle portion, for the purpose of uncovering the deep-situated parts. This articulation is the type of the order *enarthrosis*, being a true *ball and socket* joint.

The *articular surfaces* are the *globular head* of the *femur*, and the *cotyloid cavity* of the os innominatum. There is a striking difference between this joint and that of the shoulder, as far as regards the size of the articular head and the depth of the articular cavity. While the head of the humerus and the glenoid cavity are simply in juxtaposition without any reception of the former into the latter, so that the scapulo-humeral articulation has for a long time been, and is now considered as an arthrodia, there is a deep and complete fitting of the head of the femur into the cotyloid cavity, which we have pronounced to be the deepest articular cavity of the body. Both of the surfaces above named are covered with cartilage, with the exception of two depressions, one of which is situated on the head of the femur, the other at the bottom of the cotyloid cavity: the latter is filled with a reddish adipose tissue, improperly called the *cotyloid gland*. It is analogous to the adipose tissue found in the neighbourhood of all the joints; its use is not well known. I have often asked myself the question, Why should there be this posterior cotyloid cavity? On submitting the joint to an antero-posterior vertical section, slightly encroaching on the margin of the posterior cotyloid cavity, it will be seen that the object of this cavity is to protect the round ligament in all the possible positions of the head of the femur; and that, without this cavity, the round ligament could not have existed without its being compressed between the articular surfaces. Now, as the intra-articular vessels enter this cavity, and go to the head of the femur along the round ligament, it is not impossible but that the exclusive use of this posterior cotyloid cavity should be to protect the vessels destined to the head of the femur, and that the round ligament itself should have no other use than to support these vessels, and to transmit them to the head of the femur. The cotyloid adipose tissue does not seem to have any other object, except to fill the empty space of this posterior cavity.

It appears to me that the round ligament of the coxo-femoral articulation of the posterior cotyloid cavity serves the same purpose as the space between the condyles of the lower end of the femur and the crucial ligaments of the knee-joint.

Means of Union.—The *cotyloid ligament* (*n*, *fig.* 76). This band, improperly called *cotyloid ligament*, is attached to the margin of the acetabulum, which it, as it were, completes; it augments the depth of the cavity, and renders smooth its sinuous and notched circumference. It is of greater size at the notches than in any other part: by its means the irregularities of the edge of the acetabulum are effaced, and the deep notch in front and below is converted into a foramen for the passage of vessels to the fatty tissue, the inter-articular ligament, and the head of the femur.

The cotyloid band is much thicker above and behind than below and in front, and it is precisely against the first two points that the head of the femur constantly presses. It is also remarkable, in this respect, that the diameter of its free borders is smaller than that by which it is attached; and this circumstance assists, in some degree, in retaining the head of the femur in the cotyloid cavity.† It consists of fibres which arise succes-

* In a female seventy-nine years of age, the mother of nineteen children, I found the symphysis pubis extremely movable: the two articular surfaces of the pubes were contiguous; the interosseous ligament had disappeared; and a very thick, fibrous capsule, of recent formation, surrounded the articular surfaces in front, above and below, being inserted at some distance from them. It was a symphysis changed to a loose arthrodia.

† I have never seen this disposition better exhibited than in a subject in which the cotyloid band was ossified in its whole extent, except at the place on a level with the anterior and inferior notch. The head of the

sively from all points of the circumference of the acetabulum, and interlace at very acute angles. This interlacement is especially visible in the situation of the great anterior notch, where the fibres may be seen arising from each side of the notch, and passing across each other.

The *orbicular ligament*, or *fibrous capsule* (*p*, *fig.* 76). This represents a fibrous sac, having two openings, by one of which it embraces the acetabulum, outside the cotyloid ligament, while the other surrounds the neck of the femur. The femoral insertion of the capsular ligament requires to be carefully studied, for the purpose of explaining the difference between fractures within, and fractures beyond, the capsule. This insertion is so arranged, that at the upper part and in front of the joint it corresponds with the base of the neck of the femur, while beneath and behind it is situated at the junction of the external with the two internal thirds of the neck. The insertion of the capsule in front takes place not only at the base of the neck of the femur, but also internally to this base, to the extent of several lines, as may be ascertained by an incision being made along this insertion in the direction of the axis of the neck. The length of the orbicular ligament is exactly equal to the distance between its insertions, excepting at the inner part, where it is much more loose. Hence the extent of the motion of abduction, which is so remarkable in some jugglers, that they are able to separate their legs until they form right angles with the body, without producing dislocation.

The thickness of this ligament is not equal throughout: it is greatest above and on the outside, where the reflected tendon of the rectus muscle is situated; it is yet very considerable in front and above; it is less thick behind, and still thinner on the inside. In some subjects the thickness of the superior part of the capsule is to that of the inferior as five to one. In front, the capsule is strengthened by a bundle of fibres stretched obliquely, like a sling, from the anterior inferior spinous process of the ilium to the inside of the base of the neck of the femur. It is called by Bertin the *anterior* and *superior ligament* (*r*, *fig.* 76). This band, which serves as a re-enforcement to the capsule, lies under that portion of the iliacus muscle which arises from the anterior spinous process of the ilium, and follows the direction of this muscle; it is composed of parallel fibres, and closely adheres to the capsule, without adhering in the least to the muscle. Within this bundle the capsule is often imperfect, and permits a communication between the synovial membrane of the joint and the bursa of the psoas and iliacus muscles. This last synovial membrane may be considered as a prolongation of the articular synovial membrane; this prolongation is analogous to the one which we have described at the scapulo-humeral articulation for the subscapularis muscle. In one subject that I dissected, the communicating orifice was so large, that the common tendon of these muscles was in immediate contact with a considerable portion of the head of the femur; the tendon itself being split into several bands, some of which had been lacerated, and, as it were, worn away by friction.

The *external surface* of the capsular ligament is in relation with the psoas and iliacus muscles in front, being separated from them by a bursa at the upper part, in those cases where the fibrous capsule is not interrupted, and giving insertion to many of their fibres below. On the inside, it is in relation with the obturator externus and the pectineus; on the outside, with the gluteus minimus; behind, with the quadratus femoris, the gemelli, the pyriformis, and the obturator internus. Several of these muscles send fortifying bundles of fibres to the capsule. I may point out an aponeurotic expansion coming from the gluteus minimus, which establishes a close connexion between this muscle and the capsule; a second expansion, furnished by the pyriformis and the gemelli; and a third, which is furnished to the capsule by the tendon of the vastus externus. The *internal surface* is lined by the synovial membrane.

The orbicular ligament of the hip-joint differs from the generality of such structures in being of a dull white instead of a pearly white colour, and in being composed of irregularly interlaced fibres, except the superficial fibres, which are disposed in parallel lines. I have also observed a very remarkable fact, apparently overlooked by anatomists, viz., that it is extremely thin at its inferior orifice, but especially behind; and that near this insertion it is strengthened by some circular fibres which embrace the neck of the bone like a collar, but without adhering to it; and that in its different movements this sort of collar rolls round the neck, but is retained in its place by small bundles of fibres, reflected from the capsule upon the neck of the bone, which raise the synovial membrane from the surface.

The *inter-articular*, which is improperly called *round ligament* (*t*, *fig.* 76). This ligament arises, under the form of a fibrous band, folded backward upon itself, from the depression on the head of the femur, which depression is not entirely filled by it. It is twisted around this head, and is divided into three bands, one of which, after having again been subdivided, traverses the adipose tissue and is fixed into the bottom of the cotyloid cavity, while the two others are attached to the two edges of the cotyloid notch, below the cotyloid band, by which this insertion, with which it is often continuous, is concealed.

femur was mechanically and solidly retained in the acetabulum, whose bottom, being partly worn out and pressed inward, formed a prominence in the interior face of the pelvis.

In one case a prolongation of this ligament traversed the cotyloid notch, and was attached to the part nearest the capsule. The thickness and the strength of this inter-articular ligament are extremely variable: sometimes it is extremely strong, sometimes very weak; sometimes it adheres to one edge only of the notch; sometimes it consists merely of a few ligamentous fibres, contained within the substance of the reflected synovial membrane; sometimes in its place is found a fold of that membrane, which may be torn by the slightest force; and, lastly, it is not uncommon to find that it is altogether wanting.

The *synovial membrane* lines the whole internal surface of the capsular ligament, the two non-adhering surfaces of the cotyloid ligament, and that part of the neck of the femur contained within the joint; it embraces the round ligament, and sends off a prolongation from it to a quantity of fatty matter at the bottom of the acetabulum;* an arrangement which led the older anatomists to believe that the round ligament was inserted into the bottom of the cotyloid cavity.

Mechanism of the Coxo-femoral Articulation.

Like all enarthroses, the coxo-femoral articulation can execute movements of flexion, extension, abduction, adduction, circumduction, and rotation.

1. In *flexion*, the head of the femur rolls in the cotyloid cavity around an imaginary axis corresponding with that of the neck of the bone, while the lower end of the femur is carried from behind forward, and describes the segment of a circle, whose radius is represented by the shaft of the bone. In the mechanism of this movement, the neck of the femur has the effect of substituting a rotatory motion of the head of that bone upon a fixed point, without changing the relation of the head with the acetabulum, and, consequently, without any tendency to displacement, for a very extensive movement backward and forward, which would otherwise have been necessary, and in which the surfaces would have been liable to separation from each other. We can, indeed, scarcely believe that luxation would be possible during this motion, although it can be carried so far that the front of the thigh and the fore part of the abdomen may be brought in contact.

2. *Extension* is effected by the same mechanism, the head and the neck of the femur rolling upon themselves from behind forward, while large arcs of a circle, from before backward, are described by the body of the bone; but such is the obliquity of the acetabulum, which looks both forward, outward, and downward, that when the femur is in the vertical direction, the head projects and carries forward the fibrous capsule. The anterior re-enforcing bundle is stretched. The psoas and iliacus muscles perform the office of an active ligament. Luxations of the femur forward are not common, for the movement of extension is limited by the meeting of the edge of the acetabulum and the back part of the neck of the femur; and the ligament and muscles above named also tend to counteract it.

3 and 4. The mechanism of *adduction* and *abduction* is altogether different from that of the preceding movements, where the articulation forms the centre of a circle described by the femur, the radius of which is measured by a line stretched from the head of the bone to the space between the condyles. In *abduction*, the head of the femur presses against the inner part of the capsular ligament; and, on account of the looseness of this ligament, the obliquity of the acetabulum, and the arrangement of the inter-articular ligament, this movement may be carried very far without displacement, and is only limited by the meeting of the upper edge of the neck of the femur with the rim of the cotyloid cavity. But this very meeting may itself become the cause of luxation, and then the edge of the cotyloid cavity may be regarded as the fulcrum of a lever of the first order with unequal arms, the whole length of the femur being the arm, to which the power is applied, and the neck of the bone, that by which the resistance acts.

In *adduction*, the femur moves in precisely the opposite direction: this motion is limited by the mutual contact of the two thighs, but, by means of slight flexion, it may be carried so far as to throw one over the other. The great depth of the upper and external part of the cotyloid cavity, and the strength of the capsular ligament in the same directions, would seem to oppose all displacement. But it should be observed, that falls upon the knees almost always happen during adduction of the thighs, for this is an instinctive movement of preservation. However slight the adduction may be, the inter-articular ligament is of necessity stretched; and from this it follows, as my colleague, M. Gerdy, has ingeniously remarked, that the head of the femur is detached from the bottom of the cavity by a kind of rolling of the round ligament upon it, and comes to press against the fibrous capsule. The rupture of the inter-articular ligament is not always necessary in luxation. I have seen several instances of a so-called incomplete luxation inward, without this ligament being torn.

5. *Circumduction* consists in the transition from one of these motions to another. The

* The synovial membrane is often seen, being interposed and descending between the adipose substance and the posterior cotyloid cavity. I may also point out semilunar folds, which are often formed by the synovial membrane round the neck of the femur. These folds are supported by some detached fibres of the capsule, so that the neck, on a level with those fibres, is lined with synovial membrane only in the neighbourhood of the head of the femur. The synovial folds appear to me destined to conduct vessels to the margin of the head of the femur. Round the head of the femur, at its point of union with the neck, are constantly found very small adipose bundles.

femur circumscribes a cone, of which the apex is in the joint, while the base is described by the lower end of that bone. The axis of the cone is represented by a line drawn from the head of the femur to the interval between the condyles; and the length of the femur accounts for movements which are scarcely felt at the coxo-femoral articulation, being so considerable at the lower end of the bone.

6. Independently of the movements above described, the coxo-femoral articulation performs *motions of rotation*, arising by no means from its enarthrodial shape, but from the presence of the neck of the femur. Generally no movement appears to require a greater expenditure of power on the part of nature than the rotatory movements, and these movements are not always regulated by the same mechanism. We have already seen an example of this movement in the atlo-axoidian articulation, where a cylinder formed by the odontoid process rolls in the partly osseous and partly fibrous ring of the atlas, as an axle-tree in a wheel. Here the arrangement is quite different; the rotatory movement is obtained simply by the lever being bent like an elbow in such a manner as to make the rotatory movements of the femur upon its axis result from the movements forward or backward of the bent portion. This movement should be studied both at the upper and at the lower part of the femur. At the upper part it is a motion of horizontal displacement, the radius being represented by the head and neck of the bone; at the lower part it is a rotatory motion of the femur, not precisely upon itself, but upon an imaginary axis placed on the inside of, and parallel to, the shaft. It follows that there can be no rotation in cases of fracture of the neck of the bone, and this is one of the diagnostic signs of that accident. Lastly, it may be observed that rotation is performed from *without inward*, or from *within outward*: the latter is the more extensive and more natural movement; it is produced by a great number of muscles, and, therefore, during repose, the point of the foot is slightly inclined outward.

The Knee-joint (*figs.* 78 to 81).

Preparation.—1. Make a crucial incision in front of the knee and dissect back the flaps. 2. Detach the aponeurosis of the thigh, preserving the fibrous band, which forms the continuation of the *tensor vaginæ femoris*, and which forms, as it were, a superficial ligament. 3. Remove the aponeurosis of the triceps on the sides of the patella, taking care to avoid opening the synovial capsule. 4. Remove the tendon of the biceps, and turn downward the tendons of the sartorius, gracilis, and semitendinosus. 5. Remove the popliteal vessels and nerves behind, and also the gastrocnemii. 6. After having studied the ligaments situated around the synovial capsule, isolate the latter as much as possible by dissecting off the lateral ligaments, and the ligamentum patellæ. 7. Open the synovial capsule above the palate. 8. Make a horizontal section of the femur immediately above the condyles, and a vertical section from before backward between the condyles. These two sections are intended to expose the crucial ligaments.

The articulation of the knee belongs to the class of *angular ginglymi*; it is the largest and most complicated joint in the human body; it is, perhaps, the most important, both in regard to the part which it plays in the mechanism of the animal economy, and the frequency and the gravity of the maladies which it is liable to.

Articular Surfaces.—The lower end of the femur and the upper end of the tibia are the essential constituents of this joint, which is completed in front by the patella. The articular surface of the femur is formed in front by the trochlea, and behind by the two condyles, separated by the intercondyloid fossa; the articular surface of the tibia consists of the glenoid cavities, separated by the spine of the tibia, in front of and behind which are some irregular projections. The patella presents two concave surfaces, separated from each other by a vertical ridge corresponding to the groove of the trochlea. These surfaces are all covered with a thick layer of cartilage. It should be remarked, with regard to the knee-joint, 1. That the articular surfaces are rather placed in juxtaposition than jointed together; 2. That the articulation is in some measure double, since two very distinct condyles correspond to two equally distinct cavities. These two condyles being turned in opposite directions, viz., the external backward and outward, the internal backward and inward, they are opposed to each other; like the articulation of the two condyles of the occipital bone with the atlas, which are opposed both to the lateral and the rotatory motions, and, in regard to these motions, constitutes an angular ginglymus, so in the case in the knee, its two condyles constituting, as it were, a double condylian articulation, transformed into an angular ginglymus.

Inter-articular Cartilages.—Like all joints that are exposed to much pressure, the knee is provided with inter-articular cartilages. They are two in number, and are named, from their figure, *semilunar* or *falciform cartilages* (*a*, *b*, *fig.* 78). Their upper surfaces, corresponding to the convexity of the condyles, are concave; their external circumference is very thick, and the internal sharp and thin: they therefore assist in deepening the concave surfaces of the tibia. The section of these cartilages forms an elongated isoscele triangle, with its base outward. The external inter-articular cartilage (*a*) covers almost the whole of the external glenoid cavity of the tibia, forming nearly a complete circle; while the internal cartilage (*b*), which is, indeed, semilunar, leaves a great

part of the corresponding cavity uncovered.* In this respect the inter-articular cartilages of the knee differ from all others of the same kind, for they do not establish a complete separation of the articular surfaces, between which they are placed. These falciform cartilages are inserted into the tibia by means of ligaments, which deserve a particular description.

Fig. 78.

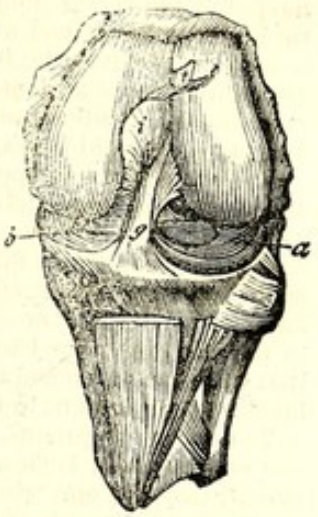

Ligaments of the External Semilunar Cartilage.—These are two: the one anterior, and the other posterior; both of them are very strong. The anterior is inserted in front of the spine of the tibia, outside of the anterior crucial ligament, into a deep depression situated near the external glenoid cavity of the tibia. This anterior ligament of the external semilunar cartilage sends off a bundle which intermingles with the anterior crucial ligament. The posterior is inserted into the spine of the tibia, in the unequally-divided interval situated between the two prominences of the spine. The posterior ligament sends off a considerable bundle of fibres to be inserted into the posterior crucial ligament. The circular form of the external semilunar cartilage is owing to the insertions of the two anterior and posterior ligaments being separated from each other only by a few lines.

Ligaments of the Internal Semilunar Cartilage.—These are much weaker than the former. The anterior is inserted a good deal before its fellow, the anterior ligament of the external semilunar cartilage, and the posterior is inserted a good deal behind the corresponding ligament of the external semilunar cartilage; hence the semilunar shape of the internal semilunar cartilage, which does not send off any fibrous prolongation to the anterior or posterior crucial ligaments. The ligaments of the inter-articular cartilages being inserted into the tibia, these cartilages follow the tibia throughout its course.

Means of Union of the Knee-joint are two lateral ligaments, a posterior and an anterior, two crucial ligaments, and a synovial capsule.

1. *Lateral Ligaments.*—The external lateral ligament (*a*, *figs.* 79 and 80) appears as a rounded cord; it is inserted into the external tuberosity of the femur, at the point of union of the five anterior sixths with the first posterior, on the prolongation of the line of the fibula; the precise point of this insertion is a small eminence surmounting a depression which is destined to the tendon of the popliteus muscle, and is situated in front of another depression destined to the external gemellus; thence this ligament descends, in a vertical line, to be inserted into the external face of the head of the fibula. This ligament has the appearance of a tendon; it extends along the anterior border of the tendon of the biceps, with which it may be readily confounded.

Fig. 79.

Fig. 80.

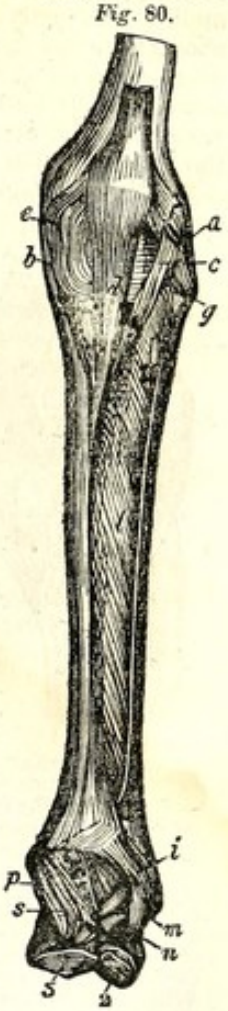

We should have but an incomplete idea of the means of union which the knee-joint possesses on the outside, if we did not add to the number of its ligaments the tendon of the biceps, which unites in some sort its inferior insertions with those of the external lateral ligament, and the small band of the fascia lata inserted into the anterior tubercle of the tibia, and sending to the external edge of the rotula an expansion, which unites with the tendon of the vastus externus.

The internal lateral ligament (*b c*, *figs.* 79 and 80), which is much longer than the external, has the shape of a broad, thin, pearly-coloured band, arising from the posterior part

* On asking myself the question why there should be this difference between the two semilunar cartilages, I have come to the conclusion that the external condyle of the femur, pressing much more upon the tibia than the internal, on account of the external following the axis of the femur, while the internal is turned away from it to the inside, the external inter-articular cartilage had to protect a greater portion of the articular surface of the tibia

of the internal tuberosity of the femur, on a level with the external lateral ligament, immediately below the tubercle into which the third adductor muscle is inserted; it is turned downward, and a little outward; it widens in its course, and is inserted, by a broad surface, into the internal border and the anterior surface of the tibia: at this insertion, which is at least an inch wide, it is covered by the tendons of the sartorius, gracilis, and semitendinosus muscles, which glide over this ligament by means of an intervening synovial bursa.

Its deep surface is applied to the anterior or reflected tendon of the semi-membranosus, to the internal semilunar cartilage, to which it intimately adheres, and to the internal inferior articular vessels, which are protected by it.

When the layers of this ligament are removed in succession, it will be seen that the deepest fibres are attached to the superior part of the internal tuberosity of the tibia, and adhere to the synovial membrane. The lateral ligaments are situated much nearer to the flexing or the back part, than to the extending or the fore part of the joint, so that they are stretched during extension, and assist in limiting that motion, but are relaxed during flexion, to the performance of which they offer no obstacle.

The posterior ligament, or *ligament of Winslow* (*c*, *figs.* 79 and 81), is much complicated, and is composed, 1. Of a fibrous capsule for each condyle; 2. Of a median posterior ligament, the only one which has been described by authors.

1. *Fibrous Capsule of the Condyles.*—Each condyle is enveloped with a fibrous husk; that of the external condyle is covered by the external origin of the gemellus, and that of the internal condyle by the internal. The fibrous capsule of the internal condyle is completed by the internal origin of the gemellus turning around the highest and most internal portion of this condyle. The semi-membranosus muscle sends a fibrous expansion from above downward to this same internal capsule; the external head of the gemellus is still much more than the internal identified with the corresponding fibrous capsule, which furnishes a great number of insertions to that muscle. When there is a sesamoid bone in the external gemellus, it is found in the substance of the external capsule.

2. *The Median Posterior Ligament.*—It is composed of several sets of fibres: 1. Some pass obliquely upward and outward, being formed by a considerable expansion of the semi-membranosus; 2. Others proceed from the tendons of the popliteus and the gemelli; and, lastly, 3. Some fibrous bundles, partly vertical and partly oblique, arise from above the condyles of the femur, and are attached to the tibia. From this collection of fibres running in different directions, there results an irregularly-interwoven ligament, perforated by foramina that transmit the ramifications of the middle articular artery; several of the most deeply-seated ligamentous bundles are inserted into the edges of the inter-articular cartilages.

3. *Anterior Ligament*, or *Ligamentum Patellæ* (*d*, *figs.* 80 and 81).—This name is given to that portion of the tendon of the extensor muscles which extends from the patella to the tibia. This ligament has the shape of a very broad, thick, almost triangular band. Its fibres arise by a broad insertion, of from five to six lines, from the apex of the patella and from the anterior surface of this bone; they are parallel, pearly-white, and become nearer to each other as they approach the most prominent and lower portion of the anterior tuberosity of the tibia, to which tuberosity they are attached. It should be remarked, that this ligament is by no means inserted into the rugged projections which are found on the back part of the apex of the patella. Behind this ligament is a considerable mass of adipose tissue (*e*, *fig.* 81), which separates the ligament from the articular synovial capsule, a synovial bursa (*f*, *fig.* 81) separates it from the anterior portion of the tuberosity over which it glides. This synovial bursa sometimes communicates with the articular synovial capsule, and sometimes is totally distinct from it.*

Fig. 81.

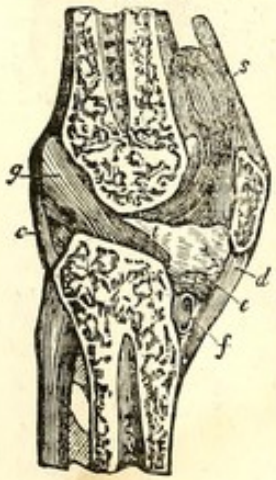

Crucial or *Interosseous Ligaments.*—In the interior of the knee-

* I should remark that this bursa extends partly over the ligament, which it covers from side to side, and partly over the anterior tuberosity of the tibia, which is at this point completely deprived of inter-articular cartilage; so that the facility with which the synovial membrane of the tibia is removed contrasts with the difficulty which is experienced in dissecting the synovial membrane which covers the inter-articular cartilages, provided it exists there. The ligamentum patellæ forms only a part of the anterior ligament of the knee-joint; this anterior ligament is completed by the rotula and by the united tendons of the rectus femoris, the vastus internus and externus, of which united tendons the ligamentum patellæ is evidently a continuation. We see here a very remarkable application of this law, by means of which the articular ligaments are fortified by tendons, and sometimes completely replaced by them; and I have taken care to observe that it is generally the trochlear joints which exhibit examples of this replacing of ligaments by tendons in regard to extension, because, in the movement of extension, a ligament, being a purely passive means of union, was not sufficient. What would take place if an ordinary ligament were to be substituted for the tendon of the extensor muscles? In the first place, this ligament would have to be extremely long to permit flexion; but in case it should be long enough for flexion, what would become of it in the movement of extension? Unless it were endowed with the extensibility and the elasticity of the yellow ligaments, it would become folded, and would thrust itself between the articular surfaces. It is for this reason that a ligament was required which might be short-

joint there are two interosseous ligaments (*g i*, *fig.* 78), so arranged as to admit of the most extensive flexion, but to limit the movement of extension. They are called *crucial*, because they cross each other like the letter X. They are situated in the deep inter-condyloid fossa, whose sole destination appears to be that of protecting them. The *anterior* (*g*, *figs.* 78 and 81) arises from the external condyle, and passes to the fore part of the spine of the tibia. The *posterior* (*i*, *fig.* 78) arises from the internal condyle, and is fixed to the back part of the spine. Both are continuous, by a distinct bundle, with the external inter-articular cartilage; never with the internal. The names anterior and posterior have been given these ligaments, from their inferior insertion; for superiorly they arise on the same level. Here follows a more minute description of their insertions above and below, and of their direction.

The anterior crucial ligament arises, as a little band flattened from side to side, from the semilunar depression, which is concave superiorly, and is situated on the internal or median surface of the external condyle; thence it extends from above downward, from without inward, and from behind forward, flattens from before backward, and is inserted in front of the spine of the tibia, upon which spine it encroaches a little by means of some insertions which it takes between the two articular projections constituting the spine. From the external edge of this ligament a few fibres are given off, which extend into the external part of the semilunar cartilage.

The posterior crucial ligament arises from the external or median surface of the internal condyle in a semilunar depression, entirely similar to the one which is destined to the anterior crucial ligament; like the latter, it presents a threefold obliquity from above downward, from before backward, and from within outward; it sends a considerable expansion to the external inter-articular cartilage, and is inserted back of the spine of the tibia.

Thence it follows that the crucial ligaments present a double crossing: 1. A crossing in an antero-posterior direction, and this alone has been observed with attention; 2. A crossing in a transverse direction; when the tibia is rotated from within outward, the crossing of these two ligaments increases to such an extent that these two ligaments, strongly pressed against each other, limit the motion; in the movement of rotation from without inward, on the contrary, as the crossing diminishes, they become relaxed and parallel; both are stretched during extension, and relaxed during flexion; there is an exception for the most anterior fibres of the anterior crucial ligament, which are relaxed in the middle state of extension, and stretched during flexion; but when the extension is considerable, the anterior crucial ligament is also stretched in its anterior fibres, which, being pressed by the condyles, describe a curve anteriorly concave.

The *synovial capsule* of this joint is the largest and the most complicated of all that exist in the body. In tracing it from the upper edge of the patella, we find, behind the tendon of the extensor muscles, a large cul-de-sac (*s*, *fig.* 81), sometimes replaced by a distinct synovial capsule, interposed between that tendon and the surface of the femur. In many subjects, this bursa communicates with the synovial capsule of the knee-joint by a more or less considerable opening, and in such cases a circular constriction forms the only trace of separation. On each side of the patella the synovial membrane extends beneath the two vasti, and is sometimes elevated from one and a half to two inches above the articular surfaces; the prolongation under the vastus externus is much more considerable than that under the vastus internus. The existence of these two prolongations affords an explanation of the swellings observed at the sides of the knee in dropsy of this joint; and the greater extent of the external prolongation explains, also, the greater size of the prominence on the outside. In the inter-condyloid notch the synovial membrane envelops the crucial ligaments; then it is reflected upon the posterior ligament, the lateral ligaments, the semilunar cartilages, the articular surfaces of the tibia, and, lastly, the back of the ligamentum patellæ; it next sends off a prolongation, containing a few ligamentous fibres, and extending from the lower border of the patella to the front of the inter-condyloid notch. This fold has been incorrectly termed the *adipose ligament*

ened or elongated as might be necessary, a tendon being the continuation of a muscle, that is, of an organ at once capable of extension, contraction, and endowed with elasticity. Besides this, a bone was required that might complete the articulation on the outside, that might fill the large space which, during the movement of flexion, would have remained empty between the articular surfaces, and might glide without injury over osseous surfaces, and facilitate, at the same time, standing upon the knees. This threefold object has been attained by the patella, a sesamoid bone, which is developed in the substance of the tendon of the extensor muscle of the leg, viz., of the triceps femoris, whose parallelism, at its insertion into the rotula, is destroyed by this bone.

Independently of the anterior ligament, the knee-joint exhibits a large aponeurotic surface, formed by the femoral aponeurosis, by an aponeurotic expansion of the fascia lata, and by another aponeurotic expansion furnished by the tendons of the sartorius, gracilis, and semi-tendinosus muscles; to this latter expansion is joined a fibrous lamina, given off by the tendon of the vastus externus and internus, which is attached to the tibia. This large anterior aponeurotic surface exhibits, on a level with the tendon of the triceps, a saltier-shaped interlacing, which closely adheres to this tendon, and seems destined to serve it as a bridle; on a level with the patella it exhibits a thin layer, which is sometimes interrupted, and, so to say, lacerated, in consequence of the sub-cutaneous synovial capsule being present; and on a level with the ligamentum patellæ it exhibits fibres running obliquely from above downward and from without inward.

Finally, I shall point out as appendages of the anterior ligament two proper ligaments of the patella, one internal, the other external, extending from the edges of the patella to the posterior part of each tuberosity; these ligaments are broad and thin, and strongly adhere to the synovial capsule.

(ligamentum mucosum, *t*, *figs.* 78 and 81). After having furnished this fold, the synovial membrane lines the posterior surface of the patella, and becomes continuous with the cul-de-sac behind the extensor tendon. Sometimes the prolongation, known as the adipose ligament, does not exist; at other times there is more than one. I have seen a fold of the same nature extending from that part of the synovial membrane which lines the extensor tendon to the surface of the femur above the trochlea. No other synovial membrane in the body is provided with so large a number of villous prolongations, which, in some subjects, may be said to give it a shaggy appearance; they are especially met with around the patella* and the semilunar cartilages. To these prolongations Clopton Havers has given the name of *synovial fringes*. Some deep fibres of the triceps cruris have been regarded as a special tensor muscle of the synovial capsule. (Vide *Triceps Cruris*, MYOLOGY.)

Sub-synovial Adipose Tissue.—From the abundance of this tissue in the knee-joint, its disposition requires some special notice. It is chiefly met with behind the ligamentum patellæ (*e*, *fig.* 81), where it forms a very thick layer, filling up the interval between the patella and the synovial membrane. This adipose mass, which raises the ligamentum patellæ in the extension of the knee, and which, during flexion, fills the empty space which the movement of flexion produces between the condyles of the femur and the tibia, is situated to the outside of the joint, between the ligamentum patellæ and the synovial capsule, which is raised by the mass. This mass, on being examined on the side which is contiguous to the joint, exhibits several prolongations, which are somewhat similar to the fatty appendages of the epiploon. These appendages are all lined by a fold of the synovial capsule; one of these appendages, supported by a fibrous bundle, is attached to the inter-condyloid space, under the name of ligamentum mucosum patellæ, which ligament is sometimes multiple, and has no other object except to draw to it the fatty matter between the tibia and the femur during flexion of the knee, and to keep that matter in its place during the movement of extension. A large quantity of fatty matter is also found behind the tendon of the triceps above the condyles, where that matter fills the interval between this tendon and the corresponding part of the femur. Bundles of fatty matter are, lastly, found all around the condyles, as well as in the inter-condyloid notch, and around the insertions of the crucial ligaments. This fat, which may be observed even in individuals in a state of marasmus, except that, under those circumstances, it is more serous and infiltrated, is nowhere more evidently than in the knee-joint, destined to fill the intervals produced between the articular surfaces by certain attitudes.

Mechanism of the Femoro-tibial Articulation.

1. *With regard to Strength.*—The strength of articulations is generally in direct proportion to the extent of the articular surfaces, and there is no joint more advantageously constructed in this respect than the one we have been examining. The reception of the spine of the tibia into the inter-condyloid fossa also tends greatly to increase the strength of the joint, although it forms but an imperfect kind of dovetailing. A third and last condition conducive to strength is, the multiplicity of the ligaments, and of the tendons, supplying, in some respects, the deficiencies in the fitting.

2. *With regard to Mobility.*—The knee, being a hinge-joint, has two principal movements, in opposite directions, viz., *flexion* and *extension*; but, as the mutual reception of the surfaces is very imperfect, it is also capable of some slight *rotatory motions*.

In *flexion*, the surfaces of the tibia, defended by their inter-articular cartilages, glide backward upon the condyles of the femur; and, from the great extent of the articular surfaces of the last bone in that direction, the movement can be carried so far as to permit the leg and thigh to touch. In this movement, the lateral, the posterior, and the crucial ligaments are relaxed, except the anterior fibres of the crucial ligament, which are stretched; the ligamentum patellæ is stretched; the patella is firmly applied to the front of the joint, and can neither be moved to the right nor to the left, as may be done during extension. In the position of flexion, the patella fills up, as it were, the great hiatus then existing at the front of the joint between the femur and the tibia. Luxation is impossible during this movement, which is only limited by the mutual contact of the leg and the thigh.

In *extension*, the tibia and the inter-articular cartilages glide in the opposite direction. The movement is arrested when the leg is in the same line as the thigh, and whatever muscular effort be then made, the leg never will pass that limit, excepting from malformation of the parts. A greater amount of extension is rendered impossible, both by the shape of the articular surfaces, and by the stretching of all the ligaments, excepting that of the patella, which is completely relaxed, and permits of a great mobility of that bone in all directions. One circumstance in the shape of the articular surfaces, which appears to be opposed to any extension beyond the straight line, is the small extent of the trochlea in front; for, could such extension take place, the glenoid cavities of the tibia would then be applied to a portion of the trochlea, much smaller than themselves. The crucial ligaments are especially intended to limit the movement of extension, as the

* [Two slight folds of the membrane formed at the sides of the patella have been particularly described under the very inappropriate name of the *alar ligaments*.]

following experiment will at once demonstrate. Divide all the external ligaments of the joint; the crucial ligaments will then alone remain; then endeavour to extend the leg beyond the ordinary limits; this will be found impossible until these ligaments are divided. That both the crucial ligaments oppose the extension of the limb beyond a certain limit, is proven by dividing these ligaments separately. So long as one remains, no matter which, the extension is limited. An analogous experiment, in which all the ligaments of the joint (even including the crucial) are divided, excepting the lateral, proves that these are not only opposed to lateral movements, but also limit extension with much force; this they are enabled to do from being situated nearer to the back than to the front of the joint. Complete luxation can only be effected after laceration of all the ligaments which limit extension. An interesting remark, which has been suggested to me by M. Martin, is, that the crucial ligaments are not only destined to limit the movement of extension, but also—and this is, perhaps, their principal object—to prevent the articular surfaces from leaving each other in the anterior posterior direction during a forcible extension. Thus, the anterior crucial ligament will prevent, in a movement of extension, both the displacement of the tibia backward, and that of the femur forward, and the posterior crucial ligament will prevent both the displacement of the tibia forward, and that of the femur backward. It is also important to remark, that while standing upon the feet, the ham-strings being stretched, these extensor muscles of the leg, which are situated upon the thigh, the rectus femoris, and the vastus externus and internus, are entirely inactive, as is proved both by the extreme mobility of the patella and the relaxed state of these muscles in a standing position, and by the absence of all sensation of lassitude in these muscles after the vertical position upon the feet has been continued for a long time. The extension of the knee, therefore, takes place without any co-operation on the part of the muscles, simply through the articular surfaces being juxtaposed in all their breadth, and by the tension of the lateral and crucial ligaments, which keeps the articular surfaces mechanically upon each other.*

In all these motions the patella is fixed; it is the femoral trochlea which glides upward or downward upon the posterior surface of that bone. This almost invariable position of the patella depends on the inextensibility of its ligament. The existence of the patella has no effect in limiting the movements of extension; its only uses, as far as the joint is concerned, are to protect it in front, and to prevent painful pressure in the kneeling posture. Its other and chief uses are connected with the functions of the triceps extensor muscle, in the tendon of which it is developed; it removes the axis of the muscle from the parallel direction of the lever which it is destined to move. It is movable and depressed during extension of the leg, but during flexion it becomes prominent and fixed.†

Rotation.—When the leg is semi-flexed upon the thigh, it can be very slightly rotated inward and outward. These movements are performed, not upon the external, but upon the internal condyle as a pivot, so that the external part of the head of the tibia glides forward during rotation inward, and backward during rotation outward. The difference in the part performed by the two condyles in the movement of rotation does not depend upon any peculiarity of structure in the joint, but exclusively upon the arrangement of the acting forces, as we shall see when treating of the muscles. Rotation inward is limited by the mutual contact of the crucial ligaments, whose decussation is increased during this movement. Rotation outward is more extensive, because in this movement the ligaments are uncrossed, and become parallel. We shall see *hereafter* that the biceps is the agent of rotation outward, and the popliteus of rotation inward.

Peroneo-tibial Articulations (*figs.* 79 and 80).

Preparation.—1. Remove carefully the muscles of the anterior and posterior regions of the leg, which will expose the interosseous ligament, and the anterior and posterior ligaments of these joints. 2. In order to see the interior of the articulations, saw through the two bones in the middle, and then separate them. 3. To gain an idea of the interosseous

* M. Robert, one of our most distinguished young surgeons, has observed a fact which sustains these ideas, which had already been demonstrated by the artificial legs of M. Martin. An individual in whom the patella was fractured, had recovered with a distance of about ten centimeters. The movement of extension by muscular contraction was impossible; but when the limb was extended, it maintained itself in that position with the same force as the limb upon the healthy side. The patient had succeeded, by a sort of artifice, in executing spontaneously the movement of extension; he brought the trunk and the pelvis forcibly forward: the femur followed the pelvis, and extension being once effected, this inferior limb, being very strong and immovable, assisted in the standing position just as much as the healthy limb.

† It is during flexion of the leg, and, consequently, when the patella is most immovable, that this bone may be displaced in consequence of some external violence, and in this case, the displacement always takes place to the outside. However, one should suppose that the external condyle of the femur, being much more prominent than the internal, would be opposed to the luxation outward, and favour the luxation inward. But we may remark, that the patella, when displaced inward, cannot remain in this position, in which nothing maintains it, and from which the oblique direction of the triceps tends, on the contrary, to bring it back to its natural place; whereas, when the patella is displaced outward, the prominence of the external condyle opposes the reduction of the patella, which can only be effected by artificial means. It should be remarked, that the obliquity downward and inward of the femoral trochlea gives a tendency to the patella of being continually drawn outward by the tendon of the extensor muscles, which is slightly oblique in the same direction as the trochlea. This is so true, that in white swellings of the knee-joint, the spontaneous displacement of the patella always takes place outward.

ligament of the inferior articulation, saw perpendicularly through the lower ends of the bones of the leg, so as to divide them into an anterior and a posterior portion.

The tibia and the fibula, which are contiguous at their extremities, are separated from each other along their shafts, the interval being occupied by an aponeurosis, improperly called *the interosseous ligament*. We have, then, a superior and an inferior peroneo-tibial articulation, and an interosseous ligament or aponeurosis.

1. *Superior Peroneo-tibial Articulation.*

This articulation is an *arthrodia*. The articular facette of the tibia, looking downward and outward, is situated behind its external tuberosity. The facette of the fibula looks upward and inward; it occupies the inner part of the upper end of the bone. The *means of union* are two ligaments: an anterior (*g*, *fig.* 80) and a posterior (*d*, *fig.* 79). They are composed of parallel fibres, directed obliquely downward and outward from the external condyle of the tibia to the head of the fibula. There is generally a distinct synovial membrane for this joint, but sometimes it is a prolongation from the capsule of the knee. This communication frequently existing between the synovial capsule of the knee and the peroneo-tibial articulation, should condemn, in an amputation of the leg, the practice of extirpating the superior extremity of the fibula. The formidable accidents which might be consequent upon such an extirpation may readily be conceived, and should forbid the operation, although it has been accomplished without any accident. Its only object is to prevent the fibula from pressing upon the soft parts.

2. *Inferior Peroneo-tibial Articulation.*

This articulation is an *amphi-arthrosis*, that is, it is formed between surfaces that are partly contiguous and partly continuous. The former consists of two articular facettes, narrow from above downward, and oblong from before backward; of these, one is convex, and situated upon the internal surface of the lower end of the fibula above the malleolus; the other is concave, and continuous with the inferior or tarsal articular surface of the tibia. They are both covered with cartilage. The continuous surfaces are rough, and much more extensive; they are triangular in shape, having their bases directed downward: the one situated upon the fibula is convex, that upon the tibia is slightly concave.

The *means of union* are, two ligaments external to the joint, and an interosseous ligament connecting the two triangular surfaces just mentioned. Of the two external ligaments, one is *anterior* (*i*, *fig.* 80) and the other *posterior* (*e*, *fig.* 79). They are both very strong, and composed of thick, shining, parallel fibres, which pass obliquely downward and outward from the tibia to the fibula. They are almost always divided into two distinct bundles. They are both remarkable from descending beyond the articular surfaces, so that they increase the depth of the cavity for the reception of the astragalus. The *synovial membrane* of this articulation is a prolongation from that of the ankle-joint. The interosseous ligament consists of fibrous bundles, mixed with adipose tissue, which unite the two triangular surfaces so firmly that the fibula is sometimes fractured in attempting to rupture the ligaments.

3. *Interosseous Aponeurosis.*

The name of interosseous ligament is given to an aponeurotic septum (*b*, *figs.* 79 and 80) placed between the muscles of the anterior and those of the posterior aspect of the leg; it should rather be regarded as serving to multiply the points of insertion for fibres of those muscles, than as a means of union between the bones of the leg. It is narrower below than above, and is composed of fibres running obliquely downward and outward from the outer edge of the tibia to the longitudinal crest on the inner surface of the fibula. As in the interosseous ligament of the forearm, we find some other fibres crossing the former at an acute angle. The septum thus formed is interrupted above and below for the passage of the tibial vessels; the peroneal artery and veins traverse the lower opening; the anterior tibial artery and veins pass through the upper.

Mechanism of the Peroneo-tibial Articulations.

The fibula is only capable of almost imperceptible gliding movements upon the tibia. This arrangement is directly connected with the mechanism of the ankle-joint.

Ankle, or Tibio-tarsal Joint (*figs.* 79 and 80).*

Preparation.—Cut and turn back the tendons that are reflected round the joint, and remove the sheaths of those tendons by which most of the ligaments are covered. The peroneo-calcanean ligament is seen after the tendons of the peroneal muscles have been removed; the synovial membrane of these tendons only covers it. The peroneo-astragalian ligament is the most difficult to uncover, on account of its being deeply seated, and separated from the sheath of the muscles of the posterior region by a large quantity of adipose tissue. The internal lateral ligament is seen immediately beneath the sheaths of the tibialis posticus, the common flexor tendon of the toes, and the proper flexor of the

* We should remark that, in order to study this as well as all the other articulations efficiently, it is a great advantage to be provided with two joints, of which one is opened, while the other has its ligaments untouched.

great toe. In order to see the deep layer of this ligament, the superficial layers must be removed one after the other.

The tibio-tarsal articulation belongs to the class of *angular ginglymi*.

Articular Surfaces.—Both bones of the leg participate in this joint, their lower extremities being united to form a transversely oblong socket, of which the tibia constitutes by far the greater part. On this articular surface there is an antero-posterior ridge, corresponding to the groove of the trochlea on the astragalus, and separating two shallow cavities. The socket is bounded by the malleoli on each side. The internal or tibial malleolus corresponds to the internal lateral articular surface of the astragalus; and the external or fibular malleolus, to the external lateral facette of the same bone. The tibio-peroneal cavity is completed forward and backward by the lower part of the anterior and posterior peroneo-tibial ligaments. The superior articular surface of the astragalus is a trochlea; it is oblong from before backward, thus contrasting with the cavity on the lower extremity of the leg,* which is transversely oblong. This trochlea presents a shallow depression, running from before backward, and having an external and an internal edge, the external being the more elevated of the two. The pulley of the astragalus is continuous with its lateral articular surfaces, of which the external is by far the larger.

The *means of union* are three external lateral ligaments, two internal lateral ligaments, an anterior (*r*, *fig.* 80) and a posterior (*s*, *fig.* 79) ligament, and a synovial capsule.

The *external lateral* or *peroneo-tarsal ligaments* are three in number; they all proceed from the fibula, either to the astragalus or the os calcis.

1. The *external lateral ligament*, properly so called (ligamentum fibulæ medium vel perpendiculare, *m*, *figs.* 79 and 80), is situated beneath the sheath of the peroneus longus and brevis. It arises from the summit of the external malleolus, is directed downward and slightly backward, to be attached to the outside of the os calcis. It is rounded, and composed of parallel fibres.

2. The *anterior external lateral ligament* (ligamentum fibulæ anterius, *n*, *fig.* 80) arises from the anterior edge of the external malleolus, and proceeding downward and forward, is fixed to the astragalus in front of its external malleolar facette. It is very short, and broader below than above: it forms one of the two anterior ligaments described by Bichat in this joint.

3. The *posterior lateral ligament* (ligamentum fibulæ posterius, *o*, *fig.* 79) is very deeply seated behind; it extends from the excavation on the inside and behind the external malleolus to the posterior border of the astragalus, immediately above the pulley of this bone. It is directed almost horizontally, or in a slight degree obliquely downward and inward, and is almost parallel to the posterior ligament of the lower peroneo-tibial articulation. It is composed of very distinct parallel fibres, which are arranged in several layers, the deepest of which are attached to the astragalus behind the facette of the external malleolus. The posterior peroneo-astraglagean ligament is very strong. Bichat calls it the posterior ligament of the joint.

The *internal lateral ligament* is much stronger than the three external ligaments taken together. It is composed of two very distinct layers: 1. A *superficial layer*, consisting of fibres stretched from the apex and the anterior and posterior borders of the internal malleolus to the os calcis, and the upper edge of the lower calcaneo-scaphoid ligament, which it maintains in a state of constant tension. The fibres are long and slightly divergent, but still sufficiently so to have given origin to its name of the *deltoid ligament* (*p*, *figs.* 79 and 80). The fibres which are most anterior pass directly forward to the neck of the astragalus, and to the scaphoid; they form a very thin layer, which has been improperly called the anterior ligament of the ankle-joint. 2. Below the above is a *deep layer* of much greater extent, composed of short and strong bundles, passing downward and outward from the summit and sides of the internal malleolus, to the inner surface of the astragalus, below the articular facette.†

Synovial Capsule.—The external surface of this membrane is brought into view in front and behind by removing the tendons and their sheaths; and if the external and internal lateral ligaments be divided, it will be seen to extend into the inferior peroneo-tibial articulation. It will also be observed that it is tense at the sides, but very loose behind, and more particularly so in front. A great quantity of adipose tissue covers its external surface in these situations.

Mechanism of the Ankle-joint.

This articulation not only constitutes the point at which the weight of the body is

* Hence, the longest diameter of the astraglagean cavity is from before backward; the longest diameter of the tibio-peroneal cavity is transversely. The extent of the movements of flexion and extension of the foot depends upon the disproportion between the antero-posterior diameter of the pulley of the astragalus and the socket of the leg.

† [The author has omitted, perhaps intentionally, to give a special description of the anterior and posterior ligaments of the ankle-joint, already alluded to by him. The former extends from the anterior margin of the articular surface of the tibia to the corresponding border of the astragalus, and is called the *tibio-tarsal ligament*; it is very thin, and covered by the tendons of the extensor muscles. The posterior can scarcely be said to exist as a distinct ligament.]

transmitted to the foot, but also performs a very active part in the movements of progression; it is therefore so constructed as to unite great strength with the capability of tolerably extensive motion.

With regard to strength, the following arrangements should be noticed as especially advantageous: 1. The leg being articulated with the foot at a right angle, transmits the weight of the body directly to it, and this transmission being effected in the perpendicular direction, *i. e.*, in a direction in which the articular surfaces mutually oppose each other, has no tendency either to produce fatigue or to rupture the ligaments. The perpendicular position of the leg upon the foot during standing is worthy of notice, because of itself it proves that man was intended for the erect posture, since in this attitude alone does the entire inferior surface of the foot rest upon the ground. It should be also remarked, that there is no other articulation, excepting that of the head upon the vertebral column, in which the parts united are habitually perpendicular to each other. 2. The dovetailing effected at this joint, by the reception of the astragalus into the socket, formed by the bones of the leg, is also highly conducive to its strength. This dovetailing results both from the pulley-like surface of the astragalus, and from the angular form of the tibio-fibular socket; and it should be observed, that this latter condition is, as it were, peculiar to the ankle-joint, for in no other do we meet with such abrupt angles.

With regard to mobility, the tibio-tarsal articulation admits of flexion and extension. There is no lateral motion, the movements of the foot in this direction being almost exclusively performed at the tarsal joints.

In flexion, the astragalus glides backward upon the tibia and fibula, and the back part of the pulley projects behind. Luxation, from an excess of this movement, is almost impossible, for it is limited by the meeting of the neck of the astragalus and the anterior edge of the tibio-fibular sockets. In this movement, the posterior external lateral ligament, and the middle and posterior fibres of the internal lateral ligament, are put upon the stretch.

In extension, on the contrary, the trochlea of the astragalus glides forward upon the corresponding surface; the synovial membrane is borne upward in front; the anterior external lateral ligament, and the anterior and middle fibres of the internal lateral ligament, are stretched. Luxation is possible during this motion, but is very rare.

Lateral Movements.—Although the shape of the joint is opposed to movements of this kind, yet it cannot be doubted that the elasticity of the fibula, by allowing the external malleolus to yield a little, may permit them in a slight degree. Nevertheless, the fibula must be fractured, if any force, exerted by the astragalus against the external malleolus, be carried so far as to thrust it much outward.

Articulations of the Tarsus (*figs.* 80, 82, 83, 84).

The intrinsic articulations of the tarsus comprise, 1. The articulations of the component bones of each row. 2. The articulation of the two rows together.

Fig. 82.

Preparation.—1. Remove the tendons situated upon the dorsum of the foot, and also the extensor brevis digitorum muscle. 2. Remove all the muscles of the plantar region. 3. Rub off, by means of a rough cloth, the adipose tissue covering the ligaments (a subject much infiltrated with serum is best adapted for this purpose). 4. In order to gain a clear comprehension of the articulation of the two rows together, remove the astragalus from the sort of box in which it is contained, by dividing the interosseous ligament which unites it to the os calcis. 5. For the examination of the interosseous ligaments, it is necessary to separate the bones by laceration or section of those ligaments; the resistance experienced in doing this, and the portions of the ligaments remaining attached to the bones, will give a good idea of their strength and situation. 6. In order to obtain a correct notion of all the ligaments together, it is necessary, while studying each, at the same time to examine a foot in which all the joints have been opened above, while the bones are still retained in their situations by means of the plantar ligaments.

Articulation of the Component Bones of the First Row, or Articulation of the Astragalus with the Os Calcis.

This is a double arthrodia, in which each of the bones presents two articular facettes, separated by a furrow deeper on the outer than on the inner side. The posterior surface of the astragalus (1, *fig.* 84) is concave, that of the os calcis (2) is convex; in front (1) the opposite obtains, so that there is a mutual reception of parts. The means of union, properly speaking, consist only of an extremely strong *interosseous ligament* (*a*,

fig. 84) formed by ligamentous bundles, of which some are vertical, and others oblique; they are mixed with fat, and occupy the considerable interval formed by the grooves of the two bones, and which is larger towards the outer end. To form a complete idea of this ligament, it is necessary to make a vertical section from before backward, through the middle of the astragalus and os calcis (as in *fig.* 84). A loose synovial membrane lines the *posterior articulation*, which is strengthened on the inside by the fibrous sheaths of the tendons of the tibialis posticus, the flexor longus digitorum, and the flexor longus pollicis. There are also about this joint two very small fibrous bundles, one of which is posterior (*t*, *fig.* 80; *a*, *fig.* 83), and the other external (*b*, *fig.* 83): some anatomists have described them by the names of *posterior* and *external ligaments*. The *anterior* portion of this articulation is often double, from the division of the anterior articular surfaces into two smaller facettes: it forms part of the astragalo-scaphoid articulation, with which it will be described.

Articulations of the Component Bones of the Second Row.

All these joints are very compact, for the five bones which constitute this row act as one only in the movements performed by the foot at its tarsal articulations. They present for the most part angular facettes; they have also interosseous ligaments, and are true symphyses or amphiarthroses.

Fig. 83.

Articulations of the Cuneiform Bones with each other.

Articular Surfaces.—The corresponding surfaces of the first and second cuneiform bones present contiguous as well as continuous portions. The contiguous portions are square, and situated at the upper and back part of each surface. The continuous portions are placed in front of the preceding. The corresponding articular surfaces of the second and third cuneiform bones are smooth and contiguous behind, but rough and irregular in front.

Means of Union.—1. By *dorsal ligaments* (*c c*, *fig.* 83). This name is given to some very compact fibrous bands stretching transversely from one bone to the other. By their upper surfaces, on which the longest fibres may be seen, they are in relation with the extensor brevis digitorum and with the tendons of the other extensor muscles. Their lower surfaces, the fibres of which are shorter, correspond to the articulations, and to the periosteum of the cuneiform bones, with which they interlace. 2. By *plantar ligaments*. This name may be given to some of the fibres of the interosseous ligaments. 3. By *interosseous ligaments*. These, which are very strong, constitute the principal means of union of these joints, and occupy all the rough portions of the corresponding facettes. They so closely unite the bones, that, even when the dorsal ligaments are removed, it is not easy to open the joints.

The *synovial membrane* is merely a portion of the general synovial membrane of the tarsus.

Articulations of the Scaphoid with the Cuneiform Bones.

Articular Surfaces.—The scaphoid presents the only example in the body of a single articular surface being divided into three facettes by well-marked ridges. Each of these facettes is triangular, and corresponds to a surface of the same form on one of the cuneiform bones. The base of the triangular facette for the first cuneiform bone is below; the bases of the other two are above (3, *fig.* 80).

Means of Union.—1. *Dorsal ligaments.* There are two for the first cuneiform bone, a superior (*d*, *fig.* 83), and an internal (*e*, *figs.* 83 and 84); and only one for each of the others (*f f*, *fig.* 83). The dorsal ligaments of the first cuneiform bone pass directly backward; those of the other two are stretched obliquely forward and outward. 2. *Plantar ligaments.* A very strong plantar ligament (*a*, *fig.* 82) extends from the tubercle of the scaphoid to the corresponding tubercle of the first cuneiform bone; it is blended with the tendon of the tibialis posticus, which furnishes a considerable expansion that crosses the direction of the tendon of the peroneus longus, and extends to the third cuneiform, and the corresponding metatarsal bone; it may be considered as an inferior ligament of the tarsus. The name of *plantar ligaments* can scarcely be given to some irregular fibres (*b*, *fig.* 82) passing from the lower surface of the scaphoid to the second and third cuneiform bones.

A *synovial membrane*, common to the three articulations, is continuous with that of the three cuneiform bones.

Articulation of the Third Cuneiform Bone with the Cuboid.

This articulation resembles in every respect those of the cuneiform bones. The means of union are a *dorsal ligament* (*g*, *fig.* 83), consisting of a very strong transverse bundle; an *interosseous ligament*, which occupies the entire non-articular portion of the corresponding surfaces; and an ill-defined *plantar ligament*, consisting of some irregular transverse fibres. The *synovial membrane* communicates with that of the cuneo-scaphoid articulations.

Articulation of the Scaphoid with the Cuboid.

The scaphoid and the cuboid often unite by a small facette. The means of union are an *oblique dorsal ligament* (*i*, *fig.* 83), a very strong *interosseous ligament*, occupying the whole of the corresponding surfaces of the bones, excepting the small portions which are contiguous; and a very thick transverse *plantar ligament*, extending somewhat obliquely from the tuberosity of the scaphoid to the cuboid. These ligaments exist even when there are no articular facettes.

Articulation between the two Rows of the Tarsal Bones.

The articulation between the two rows consists of the articulation of the astragalus with the scaphoid and os calcis, the articulation of the os calcis with the cuboid, and, lastly, the union of the os calcis to the scaphoid by means of several ligaments.

1. *Articulation of the Astragalus with the Scaphoid.*

The articular surface on the *head* of the astragalus (1, *fig.* 84), elongated from without inward, and from above downward, is larger than the *glenoid cavity* of the scaphoid (3), and projects considerably below it, where it articulates with the anterior facette, or the two anterior semi-facettes of the os calcis. The cavity of reception is completed by a ligament called the *inferior calcaneo-scaphoid* (*b*), which occupies the triangular interval between the small tuberosity of the os calcis and the scaphoid, and forms by itself the inner side of the cavity of reception. In order to obtain a good view of this ligament, it is advisable to remove the astragalus by cutting and tearing the interosseous ligament that unites it to the os calcis; it will then be seen that the ligament we are describing is very strong and triangular, and that it covers not only the lower, but the inner part also of the head of the astragalus. It is often divided into two parts: one being external, narrow, and shaped like a band; the other internal, much broader and thicker, in relation below with the sesamoid bone of the tendon of the tibialis posticus, and presenting a cartilaginous thickening at the corresponding point.

Fig. 84.

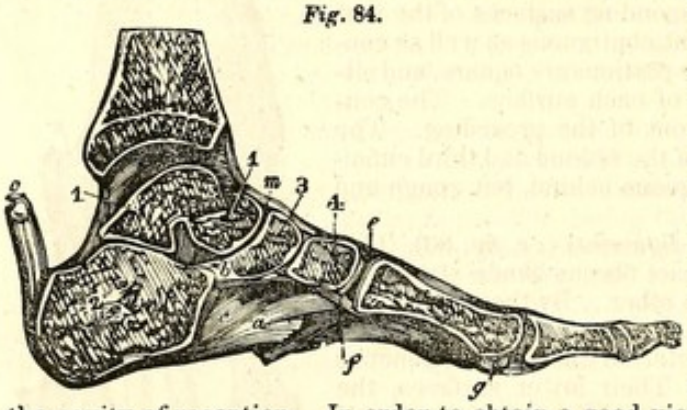

Another ligament, called the *superior calcaneo-scaphoid* (*l*, *fig.* 83), must also be regarded as contributing to wedge in the astragalus; it extends from the inside of the anterior extremity of the os calcis to the outside of the scaphoid. It is situated upon the dorsum of the foot, in the deep hollow occupied by fat, on the outer side of the astragalus. These two ligaments (the inferior and superior calcaneo-scaphoid) constitute the means of union between the os calcis and the scaphoid. These bones are in no part contiguous; but occasionally we find the os calcis continued into the scaphoid, through the medium of an osseous lamina, which replaces the lower calcaneo-scaphoid ligament.*

The os calcis being very securely articulated with the astragalus, and at the same time very firmly connected with the scaphoid, it follows that the articulation between the scaphoid and astragalus possesses great strength, although the ligaments directly uniting them are by no means powerful; just as the atlas, which is but slightly connected with the occipital bone by means of its own ligaments, is very firmly fixed by the ligaments stretching from the occipital bone to the axis. Nevertheless, the absence of any very strong and direct means of union between these bones renders it possible for the astragalus to be forced by external violence out of the sort of osseo-fibrous socket in which it is placed.

The *superior astragalo-scaphoid* ligament (*s*, *fig.* 80; *m*, *figs.* 83 and 84) is the only one proper to this joint; it is semicircular in form, and extends somewhat obliquely forward and outward, from the neck of the astragalus to the margin of the facette on the scaphoid. It is thin in texture, and consists of parallel fibres; it is covered by the extensor brevis digitorum above, and is lined below by the synovial membrane of the articulation between the scaphoid and the astragalus.

* I have represented a case of this nature (vide *Anat. Pathol.* avec Planches, liv. ii., pl. iv.).

2. *Calcaneo-cuboid Articulation.*

This articulation is upon the same line as the astragalo-scaphoid; an anatomical fact which has suggested the ingenious idea of a partial amputation of the foot between the two rows. It belongs to the class we have designated articulations by *mutual reception*, and of which we have found examples in the sterno-clavicular joint, and the carpo-metacarpal articulation of the thumb.

Articular Surfaces (2, *fig.* 80).—The facette of the os calcis is concave from above downward, while the surface of the cuboid is concave transversely, that is, in a direction at right angles to that of the former. At the lower part of the facette of the os calcis there is a horizontal projection, which sometimes stops the knife during the disarticulation of the two rows.

The *means of union* consist of three ligaments: an inferior or plantar, an internal, and a superior. The *inferior plantar*, or *calcaneo-cuboid ligament* (ligamentum longum plantæ, *c d*, *figs.* 82 and 84), is the strongest of all the tarsal ligaments, forming a broad band of pearly-white fibres, directed from before backward. These fibres constitute a very thick bundle, and extend from all the under surface of the os calcis, excepting the posterior tuberosities, to the posterior margin of the groove of the cuboid. If the fibres of this ligament be removed layer by layer, we soon arrive at a more deeply-seated ligament, separated from the first by some fatty tissue: it extends obliquely inward, from a tuberosity at the forepart of the under surface of the os calcis, to all that portion of the inferior surface of the cuboid, situated behind its groove. There are, therefore, two inferior calcaneo-cuboid ligaments: a deep (*c*) and a superficial (*d*).

The *internal calcaneo-cuboid ligament* (*n*, *fig.* 83) is short, narrow, quadrilateral, and very strong; it is placed at the side of the superior calcaneo-scaphoid ligament, in the deep excavation between the astragalus and the os calcis. These two ligaments are separated in front, but blended together behind, so as to resemble the letter Y. They may be considered as in some measure forming the key of the articulation of the two rows of tarsal bones; for, during disarticulation, the articular surfaces are easily separated as soon as they are divided.

The *superior calcaneo-cuboid ligament* (*o*, *fig* 83) is only a very thin, small band of fibres, extending directly forward, from the os calcis to the cuboid.

Mechanism of the Tarsal Articulations.

We should examine the mechanism of the tarsal articulations both as regards their strength and their mobility.

With regard to Strength.—The tarsus forms the fundamental part of the foot; one might, in fact, consider the metatarsus and the toes as superadded structures, for, even when they are removed, the foot fulfils its office as a basis of support very efficiently. Surgeons avail themselves of this fact in performing partial amputations of the foot at the tarsal and tarso-metatarsal articulations.

The construction of the tarsus is, in every respect, adapted to ensure strength; the number of its pieces, the breadth of the articular surfaces, the strength of the interosseous ligaments, and even the mobility of its component bones, all conduce to this end. Suppose, for example, that a single bone had occupied the place of the seven bones in the tarsus, how liable would this long and cancellated lever have been to fractures from the violent shocks to which it is constantly exposed, or from the influence of muscular contraction? The tarsus is narrow behind, but enlarged before, so as to increase the transverse extent of the supporting base in that direction; it is articulated with the leg at a right angle, and, therefore, receives directly the weight of the body, and as directly transmits it to the ground. In order to provide the arm of a lever for the power which raises the weight of the body, it projects behind the leg; indeed, the fitness of an individual for running and leaping may be, in some degree, calculated from the length of his heel, or, what is the same thing, from the prominence of the tendo Achilles. In standing upon the sole of the foot, the weight of the body is transmitted by the tibia to the astragalus, and from thence to the os calcis. Part of the momentum is lost at the articulation between these bones, and it is easy to comprehend why they are super-imposed, and not arranged in mere juxtaposition. But the astragalus is not placed horizontally above the os calcis, for it inclines inward, downward, and forward; and from this circumstance, even in standing upon the soles of the feet, the weight of the body is distributed between the os calcis and the anterior range of the tarsus, which is itself subdivided into two rows, but only on the inside, because it is there chiefly that the weight of the body is transmitted by the astragalus. In one attitude, this weight is communicated by the astralagus exclusively to the front row, viz., in standing upon the point of the foot; and it is then that the division of the tarsus into several bones is especially useful in preventing the injurious effects of shocks transmitted from below. There is an immense difference, also, as regards their effects on the system, between falls upon the heels and those upon the points of the feet.

The mechanism of the tarsal articulations with respect to *mobility* should be first studied in the two ranges separately, and afterward in the articulation of the two rows together.

1. The bones of the first range, viz., the astragalus and the os calcis, *glide* upon each other from before backward and from side to side. The *lateral glidings* assist in the *torsion* of the foot, which, however, is chiefly performed at the articulation between the two rows. The *antero-posterior glidings* take place under the following circumstances: when the weight of the body presses upon the upper part of the astragalus this bone slips a little forward, and the foot has a tendency to become elongated, or flattened from above downward, as Camper has remarked. When the pressure ceases, the astragalus returns to its original position. The truth of the assertion, that the foot is an elastic arch, is chiefly established by reference to the nature of the astragalo-calcanian joint.

2. The bones of the second row are capable of such very slight gliding movements, that they may be considered as forming but a single piece. However, the articulation between the scaphoid and the cuneiform bones is somewhat more movable than those of the cuneiform bones with each other and with the cuboid.

3. The chief movements of the tarsus take place between the two rows, and the articular surfaces are there very favourable to mobility; for there is in one part a head received into a cavity (at the astragalo-scaphoid articulation), and in another a mutual reception (at the calcaneo-cuboid articulation). These movements consist of a *sort of torsion* or *rotation*, by means of which the sole of the foot is carried either inward or outward. Assisted by slight lateral motions of the astragalo-calcanian joint, they constitute what is called *adduction* and *abduction* of the foot. They are generally attributed to the ankle-joint; but, as we have seen, that articulation is limited to flexion and extension; the sprains, therefore, which result from too extensive movements, either outward or inward, take place at the articulation of the two tarsal ranges, and not at the ankle-joint. When the movement of torsion is carried too far, the external malleolus is forced somewhat outward; slight gliding motions occur at the tibio-fibular articulations; the elasticity of the fibula is called into play; and, if the violence be immoderate, the fibula is fractured.

Tarso-metatarsal Articulations (*figs.* 82 to 84).

In the formation of these joints, the wedge-shaped tarsal extremity of each metatarsal bone is opposed to one of the bones of the tarsus, the corresponding surfaces being plane and triangular. The first metatarsal bone articulates with the first cuneiform; the second metatarsal with the second, and slightly with the first and the third cuneiform bones; the third metatarsal with the third cuneiform; the fourth and fifth metatarsal with the cuboid. From this there results an angular articular line, commencing on the outside, at the projection formed by the tuberosity of the fifth metatarsal bone. This line is directed obliquely forward and inward; it forms an angle at the third, and again more particularly at the second metatarsal bone, because the third cuneiform bone projects, and is wedged in between the second and fourth metatarsal bones, while the second metatarsal bone projects into the tarsus between the first and the third cuneiform bones. The articular surfaces are held together by dorsal, plantar, and interosseous ligaments. We shall now study each of these articulations separately.

Articulation of the First Metatarsal Bone with the Tarsus.—There are two semilunar facettes in this articulation, one belonging to the first metatarsal, the other to the first cuneiform bone; the long diameter of these surfaces is directed vertically. The strength of the joint is maintained by a very strong *plantar* (*f*, *figs.* 82 and 84), and a thinner *dorsal* (*p*, *fig.* 83, and *e*, *fig.* 84) ligament. Both these consist of bands directed from before backward. There is a distinct synovial membrane for this joint. We may include among the ligaments of this articulation the aponeurotic expansion given off by the peroneus longus to the first cuneiform bone, and also that derived from the tibialis anticus, and attached to the first metatarsal bone.

The *articulation of the second metatarsal bone with the tarsus* is effected by the reception of the posterior extremity of that bone within the recess formed by the three cuneiform bones. We met with a similar arrangement, though less perfectly developed, in the carpo-metacarpal articulation of the second metacarpal bone. It is the strongest of all the joints of this kind, and is provided with, 1. *Three dorsal ligaments*, as in the corresponding articulation in the hand; one *median* (*r*, *fig.* 83), broad, and constantly divided into two bands, which proceed from the second cuneiform bone; a very strong *internal* ligament, extending from the first cuneiform bone, the third being *external*, thin, and attached to the third cuneiform bone. 2. With *two plantar ligaments*, one of which (*g*, *fig.* 82) is very strong, extends obliquely from the first cuneiform to the second metatarsal bone, and is prolonged upward, so as to become interosseous; the other is very small, and proceeds from the sharp edge of the second cuneiform to the second metatarsal bone. 3. With an *interosseous* or *lateral ligament*, extending from the external lateral surface of the first cuneiform bone to the internal lateral surface of the second metatarsal bone.

The *articulation of the third metatarsal bone with the tarsus* is maintained by a *dorsal ligament* (*s*, *fig.* 82) from the third cuneiform bone. There is no plantar ligament, properly so called, unless an oblique bundle of fibres from the first cuneiform bone be considered as such; but the fibrous layer, which, after forming the sheath of the tendon of the pe-

roneus longus, is prolonged to the third metatarsal bone, appears to me to act as a plantar ligament. There is also an *external lateral* or *interosseous ligament*, which separates the articulations of the third and fourth metatarsal bones.

The *fourth* and *fifth metatarsal bones* together present a slightly concave surface, which articulates with the convex surface of the cuboid. The means of union consist of a *dorsal ligament* (*t*, *fig.* 83) for the fourth, and an *oblique ligament* (*u*), running outward and forward, for the fifth metatarsal bone: they are both loose, but especially the latter. There is no plantar ligament, excepting the sheath of the tendon of the peroneus longus, and a very strong tendinous expansion of the tibialis posticus. The tendon of the peroneus brevis acts as an external lateral ligament; and, besides this tendon, there exists a very strong fibrous band, derived from the external plantar aponeurosis, which extends from the os calcis to the process of the fifth metatarsal bone; and, moreover, an expansion of the tendon of the peroneus longus, given off as it passes over the cuboid. The articulation of the fifth metatarsal bone is very loose. There is a very strong *interosseous ligament*, stretched from the external lateral facette of the third cuneiform bone to the internal lateral facette of the fourth, and the external lateral facette of the third metatarsal bones. This ligament is analogous to one that separates the articulation of the fourth and fifth metacarpal bones from the other carpo-metacarpal articulations, and it fulfils a similar purpose here; so that there are three distinct articulations between the tarsus and the metatarsus, and, therefore, three separate synovial membranes; one for the fourth and fifth metatarsal bones, one for the second and third, and another for the first.

Articulations of the Tarsal Extremities of the Metatarsal Bones.—These are true *amphiarthroses*. The corresponding surfaces are partly contiguous and partly continuous. The contiguous part is nearer to the tarsus; it is flat, and presents on each bone two small secondary facettes. Contrary to what obtains in the metacarpus, the continuous portions are larger than the articular surfaces. There are *interosseous*, *dorsal*, and *plantar* ligaments. The *interosseous* consist of very strong, short, and compact bundles of fibres, which extend between the rough surfaces of two neighbouring metatarsal bones. The *dorsal* (*b*, *fig.* 83) and *plantar* (*i*, *fig.* 82) pass transversely from one metatarsal bone to another, the plantar being much the larger.

Articulations of the Digital Extremities of the Metatarsal Bones.—Although the digital ends of these bones do not articulate together, yet, as they are in contact and move upon each other, a synovial membrane covers the continuous surfaces and facilitates their movements; a ligament, also, the *transverse ligament of the metatarsus* (*x*, *figs.* 82 and 83), is stretched transversely in front, and unites them loosely together. This ligament is common to the five metatarsal bones; it is formed by the junction of all the anterior ligaments of the metatarso-phalangal articulations, by means of small bundles passing from one to another. It is exposed by opening the sheaths of the flexor tendons.

Mechanism of the Metatarsal Articulations.

With regard to Strength.—1. The five component bones of the metatarsus are so strongly united that it is very uncommon for one of them to be broken by itself; the metatarsus, therefore, can be only fractured by violence sufficient to crush it. 2. The slight mobility of the bones also concurs in increasing the strength of this part of the foot, by permitting it to yield slightly to external impulse. 3. The metatarsus is not uniformly strong throughout; the first of its bones is the strongest, and upon it a great portion of the weight of the body rests during standing.

The *mobility* possessed by the tarsal and the digital extremities of the metatarsal bones requires to be separately noticed.

1. In the tarsal extremities, the angular arrangement, the mutual wedging of the tarsus and the metatarsus, as well as the strength and shortness of the external and interosseous ligaments, admit of only very obscure gliding movements; a proof of which exists in the fact, that no example of the luxation of these bones upon the tarsus has, perhaps, ever been recorded. 2. Obscure, however, as these movements may be, they give rise to considerable motions in the digital ends of the bones, where the mobility is favoured by the looseness of the transverse metatarsal ligament, and the presence of a synovial membrane between the heads of the bones. The first metatarsal bone is not more movable than the others, contrasting remarkably in this respect with the first metacarpal bone.

Articulations of the Toes (*figs.* 82 to 84).

Metatarso-phalangal Articulations.

These articulations belong to the class *condyloid*, and offer a nearly perfect similarity to the metacarpo-phalangal joints.

Articular Surfaces.—The head of each metatarsal bone is flattened on the sides, and elongated from above downward, so that it forms a *condyle*. Each phalanx presents a shallow cavity, the greatest diameter of which, contrary to that of the metatarsal surface, is transverse.

Means of Union.—1. There is an *inferior* or *glenoid ligament* (*l*, *fig.* 82), situated on the plantar aspect of the joint; it is very thick, of the density of cartilage, and consists of interlacing fibres: its edges are continuous, partly with the sheath of the flexor tendons, partly with the transverse metatarsal ligament, but especially with the lateral ligaments of the joint. It is grooved below for the flexor tendons, concave above, to correspond with the convexity of the head of the metatarsal bone, and completes the cavity in which that head is received. Its anterior edge is very firmly fixed to the plantar border of the cavity of the phalanx, of which it seems a continuation; its posterior edge is free, or, rather, is loosely connected by some ligamentous fibres to the inequalities behind the head of the metatarsal bone, upon the contracted neck of which it is moulded very exactly, so that, while protecting the lower part of the joint, it serves also to increase the extent of the surfaces included in the articulation. 2. There are two very strong *lateral ligaments* (*y*, *figs.* 82 and 83), an internal and an external, inserted, not into the depressions on each side of the head of the metatarsal bone, but into tubercles situated behind them; from this origin they proceed very obliquely forward and downward, like flat bands, spreading out as they advance, and terminating partly in the inferior ligament, and partly on the sides of the phalanx. There is no dorsal ligament, properly so called, but the corresponding extensor tendon evidently occupies its place. It is not uncommon to observe a prolongation from the anterior surface of this tendon united to the metatarsal end of the first phalanx.

Synovial Capsule.—Under the extensor tendon we find a very loose *synovial capsule*; it covers the internal surface of the ligaments as well as the articular cartilages.

The *metatarso-phalangal articulation of the first metatarsal* bone presents some peculiarities which merit special description. 1. The articular surfaces are much larger than in the other similar joints. 2. The head of the first metatarsal bone presents two pulleys on its plantar aspect, separated from each other by a prominent ridge directed from before backward. This construction is connected with the presence of two sesamoid bones (*g*, *fig.* 84), developed in the substance of the inferior ligament, which is three or four times thicker than in the other joints. The lateral ligaments are almost exclusively fixed into these sesamoid bones. This joint has also a sort of fibrous ring surmounting the border of the glenoid cavity of the phalanx.

Articulations of the Phalanges of the Toes.

These are perfect *angular ginglymi*. Each toe has two such joints, with the exception of the great toe, which has only one.

Articular Surfaces.—The anterior extremity of the first phalanx, flattened from above downward, presents a trochlea, which is broader, and prolonged farther on the plantar than on the dorsal surface. On the second phalanx there are two small glenoid cavities separated by a ridge, the cavities corresponding to the small condyles, and the ridge to the groove of the trochlea just described.

Ligaments.—1. As the articular pulley of the first phalanx projects considerably below the second, it is covered in this direction by an *inferior* or *glenoid ligament* (*m*, *fig.* 82), exactly resembling those of the metatarso-phalangal joints, and perfoming the same functions. 2. The two *lateral ligaments* (*y*, *figs.* 82 and 83) are fixed precisely like the corresponding ligaments of the metatarso-phalangal joints, viz., into the tubercle above the lateral hollow on the anterior extremity of the first phalanx; and they extend obliquely forward to the glenoid ligament and the second phalanx. 3. There is no *superior ligament*, its place being supplied by the extensor tendon. This tendon is arranged in a particular manner, for it frequently sends off a prolongation (*z*, *fig.* 83) from its anterior surface, which is attached to the upper end of the second phalanx. 4. The *synovial capsule* is arranged as in the metatarso-phalangal articulations. There is often a sesamoid bone in the inferior ligament of the phalangal articulation of the great toe.

Mechanism of the Metatarso-phalangal Articulations.

Like all condyloid joints, these admit of movements in four principal directions, and, therefore, are also capable of circumduction. Extension or flexion backward can be carried much farther than in any other similar joints. The lateral movements of abduction and adduction are very limited. Let us examine what takes place during each of these movements, in which the glenoid cavity of the first phalanx glides upon the head of the corresponding metatarsal bone. In *flexion*, the first phalanx glides downward upon the head of the metatarsal bone; the extensor tendon and the upper part of the synovial capsule are stretched by the projecting head; the upper fibres of the lateral ligaments are also stretched; these fibres then limit the motion, which, nevertheless, may be carried so far that the phalanx may make a right angle with the metatarsal bones. In *extension*, the phalanx glides upward upon the head of the corresponding metatarsal bone; the superior fibres of the lateral ligaments are relaxed, while the inferior are stretched: these latter and the inferior ligament evidently limit the motion. In all subjects it may be carried so far as to make an obtuse angle behind; in some so as even to form a right angle. The movements of *abduction* and *adduction* are limited by the meeting of the toes.

Mechanism of the Phalangal Articulations.

As the mechanism of these joints is in every respect identical with that of the fingers, we shall refer to what has been said upon that subject, merely remarking that, either from original construction, or from the continued confinement of the toes in tight shoes, their movements, which consist exclusively of flexion and extension, are much more limited than those of the fingers.

Note on Arthrology.—[It has been considered advisable to include in a single note the following observations on the general anatomy of the several tissues that enter into the construction of the articulations:

Cartilages (p. 111).—The substance of the *articular* cartilages, in many joints, appears to be arranged in masses placed side by side, and perpendicularly to the surface of the bone; and hence the fibrous character presented by them after slight maceration: nevertheless, they are composed of pure cartilage, unmixed with fibrous tissue. When viewed under the microscope, cartilage is found to consist of a transparent substance, in which are imbedded numerous corpuscles, either placed singly or aggregated in groups. The intermediate substance is homogeneous in youth, but becomes more or less laminated as age advances. The corpuscles, which are, in fact, metamorphosed primitive cells, are of irregular forms, contain nuclei and nucleoli, and are somewhat flattened near the surface of the cartilage. Occasionally, several are seen occupying a distinct cavity in the intermediate substance. Their average size is $\frac{1}{1350}$th of an inch in length, by $\frac{1}{1350}$th in breadth. Neither nerves, bloodvessels, nor lymphatics are found in the articular cartilages, which, although non-vascular, can scarcely be considered unorganized. Cartilage contains 66 per cent. of water; its principal solid constituent is an animal matter, resolved by boiling into a peculiar variety of gelatin, called chondrin; it also contains salts of soda, lime, magnesia, and potash.

The *inter-articular cartilages* having free surfaces (as those of the knee-joint), are composed of true cartilage interwoven with fibrous tissue, which particularly abounds at their attached margins. The inter-vertebral substances, and all other *interosseous cartilages*, have a similar structure, but contain a greater proportion of fibrous tissue. From the two anatomical elements of which these structures consist, they are called *fibro-cartilages*.

The *articular borders* surrounding the glenoid and cotyloid cavities, generally described with the ligaments, are also composed of fibro-cartilaginous tissue.

Ligaments (p. 112).—The *articular ligaments* consist entirely of fibrous tissue, the obvious component fibres of which are divisible into parallel microscopic filaments, exactly similar to those of cellular tissue (see note on APONEUROLOGY, *infrà*). They are supplied with but very few vessels and nerves; they contain 62 per cent. of water, the remainder being almost entirely converted into gelatin by boiling.

The *yellow elastic tissue*, of which the ligamenta subflava are composed, differs in minute, as well as in obvious characters, from the white fibrous tissue of ordinary ligaments. It consists chiefly of peculiar filaments, intermixed with a few of those of cellular tissue. The proper elastic filaments, examined with the microscope, are yellowish and transparent, have a bright aspect and dark outline (very unlike the delicate appearance of the cellular filaments), and are usually curved or bent at their torn extremities. The peculiar character of dividing and uniting again, often assigned to them, is thought to be rather apparent than real, and to depend on an imperfect separation of the larger into their component filaments. The elastic is more vascular than the fibrous tissue. It contains less water (only 29 per cent.), and yields much less gelatin when boiled; the insoluble residue somewhat resembles coagulated albumen.

Synovial Membranes (p. 112).—The basis of an articular synovial membrane is cellular tissue, which becomes more and more condensed towards the free surface of the membrane. The smoothness of this surface is due to a covering of flattened scales (metamorphosed primitive cells) lying upon it, and constituting what is termed an epithelium. The recent discovery of this epithelium upon the surface of the articular cartilages is sufficient to establish the continuity of the synovial membrane over them; a fact which, though doubted by many, is assumed by M. Cruveilhier upon analogical grounds. No nerves have been traced into these membranes, and the vessels existing in the sub-synovial tissue cease at the margin of the cartilage. The synovia secreted by these membranes is an aqueous solution of albumen and saline matters. It contains more albumen than the fluid of serous cavities, the lining membranes of which (as we shall hereafter notice) have a similar structure to those just described.

Besides the *articular* synovial membranes, two other kinds are usually mentioned, viz., the *bursal*, including the various bursæ, erroneously called bursæ mucosæ; and the *vaginal*, examples of which are met with in the sheaths of tendons. These two forms will be again referred to in the note on APONEUROLOGY, *infrà*.

Adipose Tissue.—The constant occurrence, especially in the larger articulations, of masses of fat beneath the synovial membranes, affords an opportunity of alluding in this place to the minute anatomy of the *adipose tissue* generally. It may be briefly stated to consist of an aggregation of distinct spherical or oval vesicles, containing the adipose substance, and having numerous vessels ramifying on their transparent and homogeneous parietes. They are held together by the branches of those vessels, and by cellular tissue. In man, the adipose substance is liquid during life, but separates, when obtained in any quantity, into an oily fluid called elaine, and a solid residue, consisting of two fatty substances, stearine and margarine.]

ODONTOLOGY.

Circumstances in which the Teeth differ from Bones.—Number.—Position.—External Conformation.—General Characters.—Classification—Incisor—Canine—Molar.—Structure.—Development.

THE TEETH, the immediate instruments of mastication, are those ossiform concretions which surmount the edges, and are implanted in the substance of both jaws. The teeth are not bones, though, from possessing an apparent analogy to them, they have long been considered as such. They differ from bones in many respects.

1. With regard to *position*. The teeth are naked and visible at the surface, while the bones, and this is one of their most important characters, are covered by periosteum.

2. In *anatomical characters*. The teeth consist of a bulb or thick papilla, surrounded by a calcareous envelope, composed of two substances, the enamel and the ivory. This calcareous envelope is not traversed by vessels, nor can any trace of cellular tissue be discovered in it.

3. In regard to their *mode of development*. In the teeth, the formation of the hard or ossiform matter takes place by successive depositions, from the circumference to the cen-

tre; while bones are developed in a precisely opposite direction. No nutritive changes are carried on in the teeth as in bones. Moreover, the teeth are renewed by means of the second dentition; but there is no analogous phenomenon in the development of bone.

4. In *physiological relations*. The teeth do not participate in the diseases of bone, being susceptible only of chemical and physical alterations; nor is the period of their existence, like that of the bones, of equal duration with the life of the individual.

5. In regard to *chemical composition*. They contain a much larger proportion of saline matters, and the enamel is entirely destitute of gelatine.

All these circumstances prove that the teeth are not bones. We shall now show that they belong to the epidermoid system, and are analogous to the nails and hair.

1. When examined in the lower animals, they are found to present an uninterrupted series, from such as closely resemble horns or nails to such as present the most perfectly characteristic appearances of bone. 2. They have a lamellated structure, like the nails and hair: in some animals this is very manifest, but is rendered obscure in others from the abundance of calcareous deposite. 3. They are developed in the same manner as horns, nails, and hair. 4. Like them, they present no nutritive phenomena; they are formed layer after layer, and undergo no renewal of their constituent parts; they are* inorganic bodies, the products of transudation. 5. According to M. Geoffroy St. Hilaire, the beak of birds, which is evidently a horny structure, belongs to the dental system.

Number.—In young subjects, at the period of the first dentition, there are twenty teeth, ten in each jaw: in the adult there are thirty-two, sixteen in each jaw. Man, therefore, during the course of his life, has fifty-two teeth, twenty temporary, and thirty-two permanent.

The varieties in the number of the teeth are either the result of a deficiency or an excess.

The varieties *from deficiency* consist, 1. In the absence of all teeth, examples of which have been recorded by Fox and Sabatier; 2. In the absence of a great number of teeth, as occurred in an individual who had only the four incisors in each jaw. These deficiencies are chiefly observed to affect the posterior molares, and frequently they are merely apparent in them from the teeth remaining concealed within the alveoli for a much longer period than usual. Besides, Fox remarks, that there is no tooth which has not occasionally been observed to be wanting, either alone or in conjunction with others.

The varieties *from excess* are observed in the existence of *supernumerary teeth*, which may or may not range with the ordinary teeth. The supernumerary teeth either exist in distinct alveoli, or are blended with some other teeth. There are two varieties of this latter condition; for the supernumerary tooth may either appear to grow upon a primitive or parent tooth (*dens prolifer* of Bartholin), or several teeth may seem as if united into one.

Position.—The teeth are arranged in two parabolic curves, constituting the dental arches, and corresponding to the alveolar arches, which support them. Into these arches the teeth are fixed, not by articulation, but by the implantation of their roots into the alveoli, which are moulded exactly upon them. This arrangement induced those anatomists who regarded the teeth as true bones to admit a peculiar mode of articulation for them, called *gomphosis* (γόμφος, a nail).

The teeth are mechanically fixed in their alveoli; but yet we must consider the *gums* and the *alveolo-dental periosteum* as also forming uniting media. The importance of the latter will be acknowledged, if we consider the effects of scurvy in loosening the teeth, and the ease with which they drop out from the skeleton.

Each dental arch forms a regular, uninterrupted curve, an arrangement peculiar to man, for in the lower animals the teeth are of unequal length, and the dental arches have irregular edges; moreover, instead of their teeth being uninterruptedly contiguous, very considerable intervals, at some points at least, are left between them. Each dental arch presents an *anterior* convex, and a *posterior* concave surface; an *adherent* or alveolar border, which is regularly scalloped; and a *free edge*, thin and cutting at the middle, thick and tubercular at the sides; in the latter situations it has two lips, of which the external is sharper in the upper teeth, and the internal in the lower. The free edge is so arranged that all the teeth are upon a level.

As the superior dental arch forms a greater curve than the inferior, it necessarily follows that the two arches meet like the blades of a pair of scissors; but the mode in which they meet is not the same in the middle region, occupied by the incisor teeth, as on the sides, where the molares are placed. Thus, the upper incisors pass in front of the lower, while the external tubercles of the superior molares pass to the outside of the external tubercles of the inferior molares, so that these latter tubercles are applied to the furrow formed between the two rows of tubercles of the upper molares.

The teeth of the upper jaw, with the exception of the great molares, are larger, in general, than those of the lower. I should also remark, that no tooth is placed quite perpendicularly to its fellow in the other jaw; for the summit of a tooth in one jaw always corresponds to the interval between the summits of two in the other; so that the two rows of teeth are not simply in contact, but are really locked together.

* See note, p. 183.

External Conformation.—The teeth, considered in reference to their form or configuration, present some *general characters* which distinguish them from all other organs of the body; and also certain *specific characters*, by which one tooth may be distinguished from another.

General Characters (*figs.* 85 to 92).—Each tooth is composed of two very distinct parts: a free portion, projecting beyond the alveolus, named the *crown* or *body* (*a*, *figs.* 85, &c.), and a portion implanted in the bone called the *root* or *fang* (*b*), the constricted portion between these two constituting the *neck* (*c*). The rim of the alveolus or socket does not exactly correspond to the neck of the tooth, but rather to the root, at some distance from the neck, the intervening space being occupied by the gum.

The *axis* of the teeth is vertical. This direction is peculiar to the human species. The projection of the teeth forward gives a disagreeable aspect to the countenance, and is almost invariably connected with a diminution of the facial angle. The axis of all the teeth is slightly inclined, so as to converge somewhat towards the centre of the alveolar curve.

The *length* of the teeth (that is, of their crowns) is very nearly uniform. The advantage of this arrangement, in preventing one tooth from projecting beyond another, is very obvious. When the teeth are not equal in length, mastication is evidently imperfect; and therefore the principal object, in cases of fracture of the lower jaw, is to prevent the inconvenience that would arise from irregularity of the dental edge, and which is actually observed when the fragments unite in a wrong position.

The teeth are only separated from each other by very small triangular intervals, so that they are almost contiguous. When the intervals are very considerable, mastication is imperfect.

The *general form* of the teeth is that of a slightly elongated cone, flattened in opposite directions, the base of which is formed by the crown and turned towards the free edge of the dental arch, while the summit, formed by the simple or compound root, presents an opening that penetrates into the cavity of the tooth. The conical form of the root, and the accuracy with which the alveolus is moulded upon it, have a twofold result, viz., that the effort of mastication is disseminated over all points of the socket, and that no pressure is ever experienced at the extremity which receives the vessels and nerves.

The differences presented by the teeth, more especially in the crown, have led to their arrangement into three classes, viz., *incisors*, *canine*, and *molars*: the latter have been subdivided into the *great* and *small molars*.

The crown of the *incisor* teeth (*figs.* 85, 86) resembles a wedge with the sharp border shaped like a chisel; as their name implies, they serve the purpose of cutting the food. The crown of a *canine* tooth (*figs.* 87, 88) forms a cone with a free pointed apex; these teeth serve to tear the food, whence their name of *laniaires*: Hunter called them *cuspidati*, from their having only one point. The crown of a *molar* tooth (*figs.* 89 to 92) is cuboidal, the free extremity being provided with tubercles or points, intended to bruise the food as in a mill. The small molars, which have only two tubercles, are called by Hunter *bicuspides* (*figs.* 89 and 90). Man alone, of the entire animal series, is possessed of the three kinds of teeth in an almost equal state of development.

The Incisor Teeth (*figs.* 85 and 86).

These are eight in number, four in either jaw. They occupy the middle of the dental arches, and, consequently, the anterior extremity of the lever of the third order, represented by each half of the jaw. Their position is unfavourable, and, consequently, they are intended only to divide substances that offer but little resistance. This class of teeth attain their utmost development in rodentia; as in the rabbit, beaver, &c.

General Characters.—The *crown* (*a*) is wedge-shaped; its anterior surface (*fig.* 85) is convex, and the posterior concave; its sides (*fig.* 86) are triangular; its base is thick and continuous with the root, and its free edge sharp, somewhat broader than the base, and cut obliquely upward and backward in the upper teeth, and downward and forward in the lower. This obliquity of the surfaces, by which the incisors of the two jaws correspond, is the result of their constant friction upon each other, for they cross like the blades of scissors. The cutting edge of an incisor tooth, before it is worn down, is marked by three small denticulations. The *root* (*b*) has the form of a cone flattened on the sides; the anterior border is thicker than the posterior. A small vertical furrow (see *fig.* 86) occasionally exists on each side, appearing to indicate an *original* division; and sometimes the point of the root is bifid. Two curved lines, having their concavities directed downward, and united on the sides of the tooth, separate the root from the crown.*

Fig. 85. *Fig.* 86.

Differential Characters.—The *upper* incisors are distinguished from the *lower* by their much greater size, the former being almost twice as large as the latter. In the upper jaw, the *middle* are distinguished from the *lateral* incisors, also, by their well-marked su-

* [It may be well to observe, that the illustrations are all taken from teeth of the upper jaw, in which the general characters of each class are more strongly marked than in those of the lower.]

periority in size. In the lower jaw, on the contrary, the lateral incisors are the larger, though the difference is but slight.

The Canine Teeth (*figs.* 87, 88).

These are *four* in number, *two* in each jaw. They are situated on either side externally to the incisors, and therefore are nearer to the fulcrum, so that they can overcome a greater resistance. These teeth are most completely developed in the carnivora. The tusks of the boar and of the elephant are also canine teeth.

General Characters.—They are the longest of all the teeth, both in the crown and in the root; they therefore project a little beyond the incisors, particularly in the upper jaw. Their *crown* (*a*) is thick and irregularly conoid; it is somewhat enlarged immediately above the neck, and terminates in a blunt point cut obliquely at the sides (see *fig.* 88), and grooved behind. The anterior surface (*fig.* 87) is convex, the posterior concave. The canine teeth have much longer and larger roots (*b*) than any other, and their alveoli are remarkably prominent. The root is flattened on the sides, each of which presents a vertical groove traversing its entire length (see *fig.* 88).

Fig. 87. *Fig.* 88.

Differential Characters.—The superior canine teeth are distinguished from the inferior by their greater length and thickness. The roots correspond to the ascending process of the superior maxilla, and in some subjects are prolonged to the base of that process. The length of their root explains the difficulty of extracting them, and the accidents by which this operation is sometimes followed. There are several preparations in the museum of the Faculty of Medicine, in which the canine teeth are seen developed in the substance of the ascending process, and reversed, so that the crown is turned upward and the root downward.

The Molar Teeth (*figs.* 89 to 92).

The molar teeth are twenty in number, ten in each jaw. They occupy the last five alveoli on either side, and, consequently, are nearer to the fulcrum than all the other teeth: they are, therefore, most advantageously placed for exercising a powerful pressure upon any substances we may desire to break between the teeth. The instinctive motion by which, in order to crush a very hard body, we place it between the molars, is evidently connected with this arrangement. These teeth are most highly developed in herbivora.

The *general characters* which belong to all the molars are the following: 1. The great extent of their grinding surfaces, which far exceed those of the incisors and canine; 2. The absence of all obliquity at their summit, the anterior and posterior surfaces being parallel, instead of approaching each other, so as to form a cutting or angular border: this character is evidently connected with the preceding one; 3. The inequalities of their grinding surfaces, which are marked by eminences and depressions; 4. The round or even cubical form of the crown; 5. The shortness of the vertical diameter of the crown; 6. The multiplicity of roots.

The molars are divided into two classes, according to their difference in size, and the number of tubercles upon their grinding surfaces. The smaller are called *small molars*, or *bicuspides*; the larger, *great molars*, or *multicuspides*. It should be remarked, that in the first dentition, all the molars, without exception, are multicuspides.

The *small molars* or *biscuspides* (*figs.* 89 and 90) are eight in number; four in each jaw, two on the right, and two on the left side. They are distinguished by the names first, second, &c. They are situated between the canine teeth and the great molars. The small molars of the upper jaw correspond to the canine fossæ.

General Characters.—The *crown* (*a*) is irregularly cylindrical, flattened from before backward, with its long diameter directed transversely. The anterior and posterior surfaces, which correspond to the two neighbouring teeth, are plain (see *fig.* 90). The internal and external (*fig.* 89) surfaces are convex; the free or grinding surface is armed with two tubercles or points, separated from each other by a furrow. Of the two tubercles the external is the larger. The crown of the small molars has been compared to that of two small canine teeth united. The *root* (*b*) is generally simple, but sometimes double or bifid. When simple, it has a deep vertical groove upon each side; when it is bifid, the separation is never so deep as in the great molars.

Fig. 89. *Fig.* 90.

Differential Characters.—The lower bicuspides are distinguished from the upper by their smaller size, by a slight projection of the crown inward, and by the external tubercle being worn down. In the upper bicuspides, the two tubercles are separated by a deep furrow; in the lower, on the contrary, the furrow is more shallow, and the tubercles are sometimes united by a ridge. The second upper bicuspid has generally two roots (*figs.* 89 and 90), by which it is distinguished from the others. The first lower bicuspid, somewhat smaller than the second, has most commonly but one tubercle, viz., the external. This gives it more resemblance to a canine tooth.

The *great molars* or *multicuspides* (*figs.* 91 and 92) are twelve in number; six in each jaw, three on one side, and three on the other. They are named numerically, proceeding from before backward, first, second, and third. The last is also called *dens sapientiæ*, on account of its tardy appearance. They occupy the most remote part of the alveolar border.

Fig. 91. *Fig.* 92.

General Characters.—The *crown* (*a*) is pretty regularly cuboid. The anterior and posterior surfaces (see *fig.* 92), by which these teeth correspond, are flat; the external and internal surfaces (*fig.* 91) are rounded. The grinding surface is armed with four tubercles (*dentes quadricuspides*), separated by a crucial furrow, which is occasionally replaced by small depressions. In some teeth a fifth tubercle may be found. In almost all the tubercles are of unequal size, and cut into facettes. The crown of the great molars resembles two small molars united. The *root* (*b*) is always compound; it is most commonly double or triple, and, in this case, one of the roots has a longitudinal furrow. Sometimes it is divided into four or five parts, variable both in length and direction. The roots are either divergent or parallel; and occasionally, after separating, they approach each other again, curving like hooks, so as to embrace a more or less considerable portion of the jaw bone. Such teeth (which are called *dents barrées*) it is impossible to extract without pulling away the included portion of the jaw also. Each root of these teeth exactly resembles the single roots of the teeth already described, with the exception of being smaller.

Differential Characters of the Upper compared with the Lower Molars. — 1. Contrary to what was observed with regard to the other teeth, the crowns of the lower great molars are a little larger than those of the upper. 2. They are slightly bent inward, while those of the upper great molars are quite vertical. 3. The lower great molars have only two roots, an anterior and a posterior. These roots are very strong and broad, flattened from before backward, deeply grooved longitudinally, and bifurcated at the points. The upper great molars have at least three roots (*figs.* 91 and 92), one internal and two external. It is very easy, then, to distinguish between the molar teeth of the two jaws.

Individual Characters of the Great Molars.—1. The first great molar is distinguished from the other two by its size, in which it generally exceeds them. 2. The third great molar, or wisdom tooth, is distinguished from the first and second by its evidently smaller size; by its crown having only three tubercles, two external and one internal; by its shortness; and by its roots being, in certain cases, more or less completely joined together. However, even where the roots of these teeth are united, we always find the trace of the characters proper to the series of molar teeth to which they belong; *i. e.*, the vestige of three roots, an internal and two external for the upper wisdom teeth, and of two roots, an interior and a posterior for the lower.

No teeth present so many varieties as the last molares, which occasionally even remain buried in the substance of the maxillary tuberosity.

Structure of the Teeth.

The crown of each tooth contains a cavity (*d*, *figs.* 93, 94) corresponding with it in shape. This cavity is prolonged with contracted dimensions into the centre of the root, and opens by an orifice of variable size at the apex of the simple or compound cone, represented by the fang. The dimensions of this cavity are in an inverse proportion to the age of the tooth; so that it is largest at the earliest periods, but during the progress of years it becomes entirely obliterated. It contains a soft substance constituting the *dental pulp*. A tooth, therefore, is composed of two substances, an external *hard* or *cortical portion*, which is unorganized,* and an internal organized pulp.

Fig. 93. *Fig.* 94.

The *dental pulp*, contained in the cavity of the tooth as in a mould, has the same form as the tooth to which it belongs. This pulp is connected with the dental vessels and nerves by means of a nervous and vascular pedicle, which, after penetrating the dental cavity through the orifice in the apex of the root, and traversing the small canal, becomes continuous with it. From analogies, the accuracy of which will be seen in studying the development of the teeth, the pulp may be regarded as a *bulb* or *large papilla*, and appears to consist of a nervous expansion traversed by a great number of vessels. Its arteries are derived from the internal maxillary; the nerves belong to the superior and inferior maxillary branches of the fifth pair. A membrane, rather difficult of demonstration on account of its tenuity, envelops the pulp, which is extremely sensitive, is the seat of toothache, and to it alone must be referred all that has been said regarding the vitality and sensibility of the teeth.

The *hard* or *cortical portion* is composed of two substances, one of which covers the

* See note, p. 183.

crown, and has been called the *enamel* (*e*, *figs.* 93 and 94), from a comparison with the vitreous layer or glaze of porcelain; the other, constituting the entire root and the interior of the crown, is the *ivory* (*f*), improperly designated the *bony portion* of the tooth. The enamel is thickest on the grinding surface of the tooth; it diminishes in thickness as it approaches the neck, at which part it terminates abruptly. The prominence of the curved line, indicating the termination of the enamel, gives rise to the constriction called the *neck*.

By comparing, and, in some degree, contrasting the peculiar characters of the enamel and the ivory, we shall be better able to assign to each their respective properties.

1. The enamel is of a bluish-white, milky colour, and semi-transparent; the ivory is yellowish-white, and has an appearance like satin.

2. The enamel, examined in fragments of the crown, exhibits fibres perpendicularly implanted upon the ivory, and pressed closely to each other. The ivory, on the contrary, is formed of concentric layers,* the fibres of which are generally parallel to the long diameter of the tooth.

3. Both substances are excessively hard; but in this respect the enamel is superior to the ivory, for it will strike fire with steel, and is much less easily worn down by use; it can even turn the edge of a file. This excessive hardness, a principal element of immutability, explains how the teeth are preserved uninjured as long as the enamel remains entire, and, on the other hand, the facility with which they decay when once it has been removed. The great brittleness of the enamel, which is one of its most characteristic properties, is also owing to this extreme hardness.

4. In chemical composition, the enamel and ivory present important differences, indicated in the following tables:

Ivory.	
Phosphate of lime	61·95
Fluate of lime	2·10
Carbonate of lime	5.30
Phosphate of magnesia	1·25
Soda and chloride of sodium	1·40
Cartilage and water	28·00

Enamel.	
Phosphate of lime	85·3
Fluate of lime	3·2
Carbonate of lime	8·0
Phosphate of magnesia	1·5
Membranes, soda and water	2·0

It follows, therefore, that the principal chemical distinction between these substances depends on the existence of cartilage, that is, of an animal matter in the ivory, and on its absence in the enamel. The presence of cartilage in ivory forms a trace of resemblance between this substance and bone; and this is farther strengthened by the result of the action of heat, by which both are similarly affected. Between the true bones and the ivory there is, however, all that difference by which a living tissue is distinguished from a solidified product of secretion. I admit, then, a complete want of vitality both in the ivory and the enamel of the tooth; nevertheless, there are some phenomena which appear to contradict such an opinion.

1. The cortical substance of the tooth affords a much more perfect sensation of such bodies as come in contact with it than either the nails or hair.

2. Weak acids, particularly vegetable acids, cause a peculiar sensation when they are applied to the teeth, rendering the slightest touch extremely painful; a sensation generally expressed by saying that the teeth are set on edge.

But if, on the other hand, we reflect that the substance of the teeth is never affected by inflammation, that it never becomes the seat of any tumour or diseased product, and that it is worn away by rubbing and by the file, in the same way as an inorganic body, without any attempt at reparation or any evidence of the existence of a nutritive process, we must be led to admit the absence of vitality in these organs, and to explain the foregoing facts as dependant simply upon transmission.

Lastly, the hardness, fragility, and mutability of the enamel and ivory vary in different individuals; hence the difference in the durability of the teeth, and their liability to change. It must not be imagined that the ivory, when exposed, is susceptible of caries or necrosis; its changes are entirely of a chemical nature. The contrary opinion prevailed only so long as the teeth were considered true bones, and yet it has exercised an influence over the language of surgery which is not yet removed; thus, we are in the habit of speaking of a carious or necrosed tooth, and to describe them as affected with exostosis, and even with spina ventosa.

It follows, from all that has been said, that the human teeth are *simple*, *i. e.*, formed by one centre of ivory covered with one layer of enamel. *Compound teeth* exist only in herbivora, in which animals mastication consists of a most extensive grinding movement; nor are they met with except among the molar teeth. The characteristic feature of a compound tooth is the division of the crown into a greater or smaller number of lesser crowns, each of which consists of a centre of ivory covered by a layer of enamel. All these crowns are united into one by a third substance, called the *cement* or *crusta petrosa*, of which the tartar of the human teeth will afford a sufficiently good idea.†

* See note, *infrà*.

† [Recent researches into the structure of the teeth have brought so many interesting facts to light, that it is necessary to notice the result of these discoveries.

Development of the Teeth, or Odontogeny.

The study of the development of the teeth is one of the most interesting parts of their history. It embraces the description of the phenomena that precede, accompany, and follow the eruption of the first and second sets of teeth.

First, Temporary, or Provisional Teeth.

*Phenomena which precede their Eruption.**—If the jaws of a fœtus of two or three months be examined, it will be seen that they are marked by a broad and deep groove, divided by very thin septa into so many distinct sockets for the reception of the dental germs. The alveolar groove is closed at its free border by the *membrane* of the gum, which is stretched over a sort of thin, and, as it were, indented *crest*. This crest is formed by a tissue to which some anatomists have given the name of dental cartilage; it is a pale, very strong fibrous tissue, and does not extend either upon the anterior or posterior surface of the bone, which are only covered by the mucous membrane, the gum being as yet confined to the alveolar border. The gingival fibrous tissue sends a prolongation into each alveolus (*alveolo-dental periosteum*), that forms a fibro-mucous sac upon

Three different structures at least enter into the formation of the human teeth, viz., the *ivory*, the *enamel*, and the *cortical substance*.

The *ivory* (*a*, *fig.* 95) consists of a hard, transparent substance, traversed by numerous tubes, about $\frac{1}{3\,8\,5}$th of a line in diameter, which commence by open orifices at the cavity of the pulp, and extend in an undulating, but nearly parallel direction, towards the surface of the ivory. In this course the tubes present secondary and smaller undulations, undergo a dichotomous division, diminish in size, at first gradually, then rapidly, give off numerous lateral twigs, and, finally, divide into extremely minute ramifications, of which some anastomose together, others communicate with small irregular dilatations called calcigerous cells, situated in the transparent inter-tubular substance, while the remainder appear to be lost at or near the surface of the ivory. The cells and tubes both contain calcareous matter, and seem to be analogous to the corpuscles of bone and the ramified lines radiating from them. In human teeth the cells are very minute; but in those of many animals they are much more distinct, and present a striking analogy to the osseous corpuscles.

Fig. 95.

The hard inter-tubular substance is not homogeneous, but, as may be clearly seen in young and growing teeth, is composed of fibres arranged parallel to the tubes, which appear to have distinct parietes. It consists of animal tissue, combined with a large amount of calcareous salts; and it is the seat of by far the greater proportion of the earthy matter contained in the *ivory* of the tooth.

The *enamel* (*b*, *fig.* 95) is composed of hexagonal and transversely striated fibres, about $\frac{1}{4\,8\,0}$th of a line in diameter, arranged parallel to each other, and applied by their internal extremities to numerous corresponding depressions on the surface of the ivory, a delicate intervening membrane serving to connect the two structures. Near the neck of the tooth, the enamel fibres rest almost perpendicularly, near the apex of the crown, more or less obliquely upon the surface of the ivory; moreover, they are often slightly waved or curved. Previously to the eruption of the tooth, each fibre contains an appreciable quantity of organic matter, which, at later periods, almost entirely disappears.

The *cortical substance* (*c*, *fig.* 95) consists of a thin osseous layer developed on the external surface of the fangs, and, as life advances, extending even into their interior, and encroaching upon the cavity of the pulp. It differs in no essential particular from true bone, containing the characteristic corpuscles, and anastomosing tubuli of that tissue. It has been found, also, on the fangs of the teeth of most mammalia, and of a few reptiles and fishes; in some instances, direct communications have been discovered between the tubes of the ivory and the cells and tubuli of the cortical substance. The cement, or crusta petrosa, existing on the crowns of the compound teeth of the lower animals, also contains corpuscles and tubuli like those of bone, and may, perhaps, be regarded as an analogous deposite to the preceding, differing from it only in situation.

From a perusal of the preceding summary, it will be seen that not only has much additional knowledge been acquired regarding the structure of the teeth, but that many of the statements of M. Cruveilhier must now undergo considerable modification. Thus, 1. The crusta petrosa bears no resemblance to the tartar of the teeth, which is merely a deposite from the saliva. 2. Even simple teeth contain a third element in their structure, besides the ivory and enamel. 3. Instead of being inorganic bodies, the teeth are possessed of a complex organization, which, we may add, is uniform throughout each species, and often sufficiently characteristic to be of the highest utility to the zoologist, &c. 4. A remarkable affinity has been established between the teeth and bone, as far as regards the structure of the cortical substance and the ivory.]

* [The earliest stage in the development of the teeth, described in the text, is that in which the dental pulps are situated at the bottom of closed sacs; it has long been familiar to anatomists, and is now called the saccular stage. A condition antecedent to this, in which the future sacs are as yet open follicles, was first described by Arnold, but we are indebted to Mr. Goodsir (*Edin. Med. and Surg. Journ.*, No. cxxxviii.) for the following connected history of the origin of the pulps and sacs of the temporary and permanent teeth:

Origin of the Pulps and Sacs of the Temporary Teeth.—In the upper jaw of a fœtus, about the sixth week, between the lip and a semicircular lobe constituting the early condition of the palate, is situated a depression of the form of a horseshoe. During the seventh week, this begins to be divided by a ridge (commencing from behind) into two grooves, of which the outer forms the recess between the lip and the future external alveolar process, while the inner constitutes the *primitive dental groove*. The mucous membrane along the floor of this groove is then thickened, and from it a single papilla is developed, and subsequently four others arise from the external lip of the groove, in either half of the jaw. In the mean time, membranous laminæ projecting from the external lip, and at first only partially surrounding the papillæ, unite with similar but smaller processes from the internal lip, so that each papilla (*p*, 3, *fig.* 97) becomes enclosed in a separate follicle (*f*, 3, *fig.* 97), communicating with the cavity of the mouth, and lined by its mucous membrane. The papillæ now increase in size, and gradually assuming the form of the future temporary teeth, sink within the yet open follicles. At this period, the edges of the latter appear to be developed into opercula (*o*, 4, *fig.* 97), which differ in number and arrangement according to the shape of the crowns of the different teeth, there being two for the incisors, three for the canine, and four or five for the molars. The formation of the bony alveoli, by the development of an external and internal alveolar process, and of inter-alveolar septa, closely follows the preceding changes in the soft parts.

The *order* and *time* of appearance of these ten papillæ in the upper jaw are as follow: First, those of the

each follicle, perforated at the bottom of the socket for the passage of the dental vessels and nerves. As these prolongations or sacs are intimately connected to the gingival

(*Fig. 96, magnified three diameters.*)

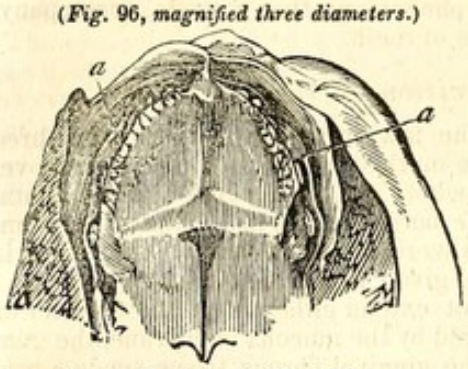

anterior temporary *molars* during the seventh week; of the *canine* teeth at the eighth; of the *central*, and then of the *lateral incisors*, about the ninth; and in the tenth week those of the *posterior molars*. The formation of the inter-follicular septa, and the other changes in the papillæ, follicles, and alveolar borders described above, proceed in the same order, and are completed about the thirteenth week. The condition of the upper jaw at that period, constituting the end of the follicular stage in the development of the temporary teeth, is seen in *fig.* 96, in which the follicles are shown as if held open; the diagrams 1 to 5 in *fig.* 97, representing perpendicular sections across the jaw, may serve to illustrate the successive changes in the mucous membrane, from the commencement of the groove to the completion of the follicles.

During the fourteenth week, a small crescentic *depression* (*c*, 5, *fig.* 97) is formed immediately behind each of the follicles, the mouths of which are now closed by their opercula, but without adhesion; the lips of the groove, which at this time is called the *secondary dental groove*, are now applied to each other (6, *fig.* 97). With the exception of the ten depressions just mentioned, and a small portion situated beyond the posterior temporary molar follicle, adhesion of every part of the groove now takes place, proceeding from before backward. The follicles are thus converted by the fifteenth week into shut sacs (*s*, 7, *fig.* 97), while the enlarged papillæ constitute the dental pulps (*p*, 7). The relation of the parts in this, the saccular, stage in the development of the temporary teeth, is represented at 7, *fig.* 97.

Independently of a few subordinate differences, the changes in the lower jaw are similar, and occur in the same order, each step in the process being somewhat later than the corresponding one in the upper.

Origin of the Pulps and Sacs of the Permanent Teeth.—It has been stated above, that during the general adhesion of the dental groove occurring at the fifteenth week, the part posterior to the second temporary molar follicle (in either half of the jaw) still remains open; in this situation, a papilla, sunk in an open follicle, appears during the sixteenth week. At the twentieth, the fundus of this follicle is converted into a sac, and the papilla into the pulp of the *anterior permanent molar* tooth, which is thus the earliest to appear of those of the second set, and is farther characterized by being developed (like the papillæ of the temporary teeth) from the *primitive dental groove*, and on the same level with them. At the end of this week the hitherto open portion of the groove is entirely closed by adhesion of its lips, but its walls still remain disunited, and a cavity is thus formed, situated between the sac of the anterior permanent molar and the surface of the gum; this is the *posterior cavity of reserve*, from which the pulps and sacs of the second and third molars are subsequently developed.

The ten depressions (*c*, 6) formed behind the follicles of the temporary teeth during the secondary condi-

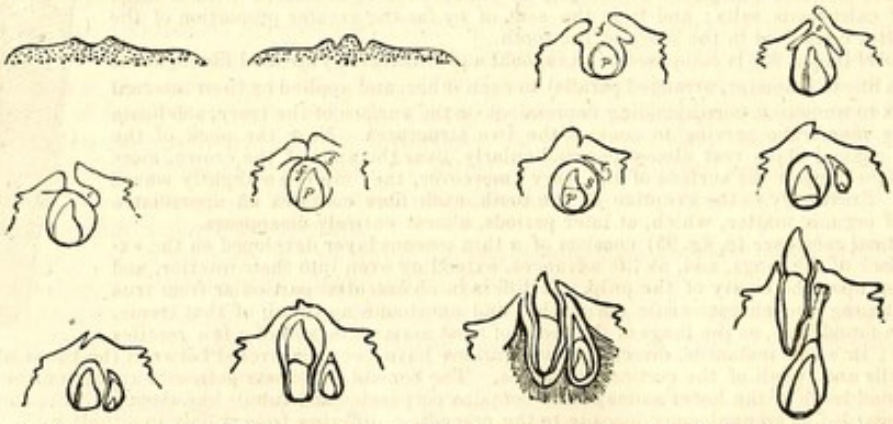

tion of the dental groove (6, *fig.* 97), in consequence of their escaping the general adhesion of its lips and sides,

Fig. 98.

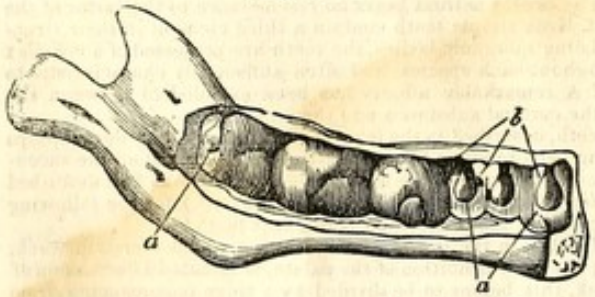

Fig. 98.*

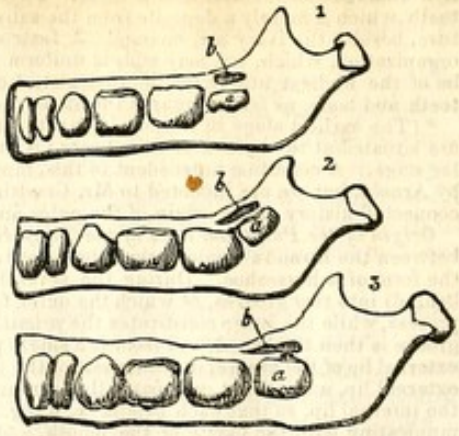

are converted into as many cavities, called the *anterior cavities of reserve* (*c*, 7), which gradually elongate and recede into the substance of the gum. Pulps and folds (analogous to the opercula of the temporary follicles) are developed within them, appearing first in the anterior cavities; and they eventually become the sacs of the *ten anterior permanent teeth*, assuming a position behind and above those of the milk teeth in the upper, and behind and below them in the lower jaw (see 7 to 12, *fig.* 97; also *fig.* 98, and *a*, *figs.* 101, 102), each occupying corresponding recesses (*a*, *fig.* 102) in the alveolar border.

At this time, owing to the great relative increase in the size of the dental sacs, that of the anterior permanent molar (*a*, 1, *fig.* 98*) is forced backward and upward into the maxillary tuberosity of the upper, and into the coronoid process of the lower jaw (*a* 2); and the large posterior cavity of reserve (*b* 2) is drawn in the same direction. At birth, the length of the alveolar border increases relatively, and this sac again sinks to a level with those of the temporary teeth (*a* 3). The cavity of reserve (*b* 3), having now resumed its former position

membrane, by pulling gently upon the latter we can raise the follicles from their receptacles, and completely lay bare the alveoli.

The *follicle* or *dental germ* consists essentially of a *membrane*, containing a sort of pediculated papilla, known as the *bulb* or *dental pulp*.

1. The *membrane* of the *follicle*, after having clothed the sac just described as lining the alveolus, is reflected upon the vessels and nerves which form the pedicle of the bulb, and appears to be prolonged upon the bulb itself: this, however, has not yet been demonstrated. The membrane of the follicle, therefore, resembles the serous membranes in forming a shut sac, the inner surface of which is free and smooth, and the outer adherent. A transparent viscid fluid occupies the space between the bulb and the alveolar portion of the membrane.

The following is the order in which the follicles of the first set of teeth appear. Towards the middle of the third month of fœtal life there are four distinct follicles in each jaw; at the end of the third month a third follicle appears in each half of the jaw, and a fourth and a fifth towards the end of the fourth month.

2. Of the *dental bulb*. In the earliest stages the membrane of the dental follicle only contains a fluid, which is at first reddish, and afterward yellowish-white; but towards the third month a small body makes its appearance, rising as a papilla from the bottom of the alveolus.* This papilla is abundantly supplied with vessels and nerves, and progressively increases in firmness and in size. A very thin pedicle, consisting of the dental vessels and nerves, affords attachment to it, so that it is suspended like a grape. This papilla, *dental bulb*, or pulp, gradually acquires the characteristic form of some particular tooth, of which it presents an exact model, constituting the nucleus around which the tooth itself is deposited. The first part developed upon this papilla is the crown of the tooth, on which we already find indications of the various eminences and depressions subsequently exhibited by it.

The development of the hard portion commences towards the middle of pregnancy. The production of the ossiform matter upon the surface of the bulb is effected by a process of secretion;† it begins by the deposition of some small laminæ, or very delicate scales (1, *fig.* 99), upon each projection of the pulp: they are at first pliable and elastic, but gradually become more consistent. These laminæ or scales constitute so many formative points for the tooth, and have been compared to the points of ossification in bones. The incisor and canine teeth have only one scale; the bicuspides have two, and the great molares as many as there are tubercles. These small scales so intimately embrace the pulp upon which they are moulded, that it requires some force to detach them; and yet their inner surface, as well as the outer, is very smooth. It should be remarked, that the pulp has a much more vividly red colour at the points covered by the scales. The scales are visible in the lower jaw at an earlier period than in the upper.

The following is the order in which they appear: the middle incisors are visible from the fourth to the fifth month; they are soon followed, 1. By the lateral incisors. 2. By the first or anterior molar, which appears from the fifth to the sixth month. 3. At a short

and shape, elongates backward, and a pulp is developed in its fundus, which is converted before the fourth year into the sac of the *second permanent molar*. About the sixth or seventh year, the remaining part of the cavity once more elongates backward, and forms the pulp and sac of the *third permanent molar*, or wisdom tooth. Each of these sacs undergoes changes in its relative position in the jaws, similar to those experienced by the anterior permanent molar, at first receding backward and upward, and then descending behind, and on a level with the sac immediately anterior to it.

From the preceding observations, it follows that the pulps and sacs of both the temporary and permanent teeth have a common origin from the gastro-intestinal mucous membrane; that a *papilla* is first formed, afterward surrounded by and sunk into a *follicle*, which latter is then converted into a closed *sac;* and hence the origin of the terms *papillary follicular*, and *saccular*, applied to these several conditions.

It moreover appears that all the temporary teeth, and also the anterior permanent molar, originate from the *primitive dental groove;* and that all the permanent teeth, except the anterior molar, are developed from cavities of reserve commenced during its *secondary* condition.

For an account of the changes occurring in the pulps and sacs of the two sets of teeth during the saccular and eruptive stages, the reader may now refer to the text, remembering, however, that the term *follicle* is there applied to the entire dental germ in its saccular condition, consisting of a closed sac and its contained pulp.]

* [The papilla of a temporary tooth appears even before the formation of the open follicle, and therefore long prior to its conversion into a shut sac. (See note, p. 183.)]

† [The *ivory* is no longer regarded, by the best authorities, as a *secretion* from the surface of the dental pulp, nor the *enamel* as a similar product from the parietal layer of the lining membrane of the sac. A microscopic examination of these two structures in their perfect condition is, indeed, alone sufficient to throw considerable doubt on the old opinion adopted in the text. The researches of Schwann into their mode of development have again elucidated the subject. It has been observed that the globules in the centre of the dental pulp are primitive nucleated cells, analogous to those found in the early condition of all organic tissues; that at the surface of the pulp these cells assume a cylindrical form and a perpendicular arrangement, but still contain nuclei; that they adhere in places to the ossified scales, and correspond in size (not to the tubuli) but, to the fibres of the inter-tubular substance in a growing tooth. From these facts Schwann concludes that the formation of the *ivory*, like that of all other organized tissues, is effected by a metamorphosis of primitive nucleated cells; in other words, that it is developed by a progressive transformation and ossification of the superficial cells of the dental pulp—a theory which recent observations in Great Britain would seem to have confirmed.

Similar evidence is advanced by him to prove that the *enamel* is formed in a similar manner from the pulpy enamel membrane, occupying the upper portion of the sac. The hexagonal fibres, of which the surface of this membrane consists, are, in fact, prismatic, nucleated cells, resting perpendicularly on a tissue, in which are other cells of a vesicular form. The hexagonal fibres correspond, therefore, both in form and direction, with those of the perfect enamel; and, moreover, they are found to agree in size with the membranous remains of the enamel fibres of a growing tooth, after the removal of their earthy matter by means of a dilute acid.]

interval from each other, by the canine and the second molar: the scales of all the teeth of the first set have made their appearance by the seventh month, according to the observations of Meckel; but at the eighth month, according to Blake.

As development advances the scales enlarge, and gradually uniting (2, *fig.* 99), form a *sheath* or *shell of ivory*, which, during its growth, encloses the pulp, and, by degrees, extends to the vascular and nervous pedicle at the part where it penetrates the alveolus.* The outermost sheath being formed, a second is deposited within it, then a third within that, and so on. The external surface of the bulb secretes the ivory. The enamel is formed from the parietal or alveolar layer of the follicular membrane: at the commencement of its formation it is so soft that, in a fœtus at the full time, it can be very easily separated from the ivory. It has been asserted by some that the enamel, as well as the ivory, is the product of a secretion from the bulb, from which it has transuded in a liquid state through the different layers of the ivory, and has then solidified upon its surface; others affirm that the enamel is a sort of crystalline deposite from the fluid surrounding the tooth; but the greater number of anatomists admit, with Hunter, that the enamel is a product of secretion from the parietal layer,† as the ivory is from the layer of the follicular membrane, reflected upon the bulb. This opinion appears to me the more probable, because, on examining with attention the parietal layer, we find on its inner surface, near the crown of the tooth, a sort of pulp, or very evident enlargement, particularly in the follicles of the molar teeth. This external pulp becomes atrophied as soon as the enamel is formed; and hence the fang is not covered with enamel, although, after the eruption of the tooth, that part occupies the former position of the crown. This external pulp does not exist in some of the dental follicles of certain animals, and we cannot, therefore, be astonished that such teeth have no enamel. Lastly, when this external pulp remains after the eruption of the teeth, the secretion of the enamel also continues, like that of the ivory. This is the case with the incisors of the rabbit and the beaver. In these animals the enamel occupies only the anterior surface of the tooth; consequently, the edge always remains sharp, from the unequal wearing of the anterior and posterior surfaces.

From what has been said concerning the phenomena of the formation of the provisionary teeth before their eruption, we may draw the following conclusions: 1. Of the two constituent parts of a tooth, viz., the corticle or hard portion, and the medullary portion or pulp, the latter is first developed; and of the two distinct elements of the hard portion, viz., the ivory and the enamel, the formation of the ivory is first commenced. 2. The deposition of the cortical substance of the tooth begins at the crown; the roots are not formed until a subsequent period. 3. The bulb being enclosed within the solidified products which it has furnished, diminishes gradually in size as these press upon it.

Phenomena which accompany the Eruption of the First or Temporary Teeth.—At the time of birth all the teeth are still contained within their alveoli. Exceptions to this rule have been met with in cases where infants have been born with one or two teeth. If the anterior wall of the alveoli be removod at this time, the teeth will already be found considerably, but unequally developed, none having yet reached the bottom of the socket. But after birth, and at periods to be presently indicated, the extremity of the root having reached the bottom of the alveolus, and the farther growth of the tooth in that direction being impossible, it is effected in the direction of the gum, which is compressed, becomes inflamed, and is perforated; this perforation, however, is not exclusively the result of distension, for the gum is but very slightly stretched when it opens; and in other cases where it is greatly distended, as by polypi or other tumours, it is not lacerated at all.

The tooth gradually rises, and the gum moulds itself successively upon the different portions of the crown, and, lastly, upon the neck of the tooth. The division of the gum is a severe process, but still it cannot altogether explain those serious symptoms which frequently accompany the first dentition.

The eruption of the teeth does not take place simultaneously, but in succession, and in a regular order that admits of but few exceptions. 1. The teeth of the same kind appear in pairs, one on the right side, the other on the left; 2. The teeth of the lower jaw

* [The vascular pulp of either a temporary or permanent tooth having more than one fang is, after the formation of the crown, divided into as many processes by the advancement into it of the gray membrane of the sac. The dental substance still continuing to be produced on every part of the surface of the divided pulp, a bridge of ivory is thus formed across the area of the cavity of the tooth between each process (3, 4, *fig.* 99),

(*Fig.* 99.)

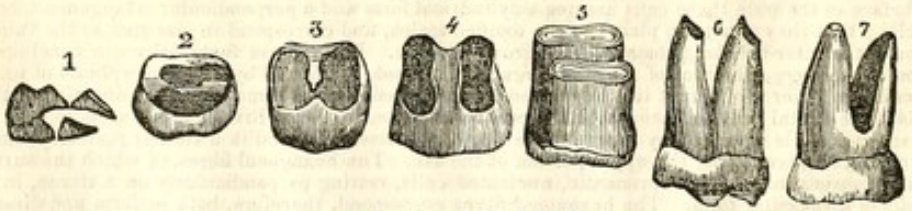

around which separate fangs are subsequently developed (5, 6, 7), in the same manner as that around the undivided pulp of an incisor tooth.]

† See note, p. 184.

precede those of the upper in their appearance;* 3. The middle incisors are cut before the lateral, these before the first molars; after these come the canine, and then the second molars. The eruption of the first set of teeth commences towards the sixth month after birth, and terminates at the end of the third or the commencement of the fourth year. The middle lower incisors appear from the fourth to the tenth month, and, soon afterward, the upper middle incisors; the inferior lateral incisors appear from the eighth to the sixteenth month, and then the superior lateral incisors. The first lower molars are cut from the fifteenth to the twenty-fourth month; the lower canine from the twentieth to the thirtieth; and the upper first molars and canine soon afterward. In some cases the eruption of the canine and the first molar teeth takes place simultaneously; sometimes even the canine teeth take the precedence. The second great molars appear from the twenty-eighth to the fortieth month, and thus complete the twenty teeth of the first set.

Second or Permanent Teeth.

Phenomena which precede the Eruption.†—The second dentition consists of the eruption of the teeth called permanent, to distinguish them from the temporary teeth. They are thirty-two in number, so that there are twelve additional teeth in the second set. In this dentition, as in the former, we have to study the phenomena which precede, accompany, and follow the eruption of the teeth.

The follicles or germs of the second set of teeth correspond to the row of teeth already formed, bony septa intervening between them. They have the following relations with the follicles of the provisionary teeth: 1. The follicles of the additional teeth in the second set, viz., the last three molars, are situated in the same curve as the milk teeth, but they occupy, of necessity, the lateral extremities of these curves (*fig.* 100). 2. The follicles of those teeth of the second set that replace others of the first are, on the contrary, situated precisely behind the teeth to which they correspond (*a*, *figs.* 100, 101, 102).

These follicles are at first contained in the same alveoli as the temporary teeth; but, after a certain time, septa are gradually formed between them, proceeding from the bottom of each alveolus towards its orifice (*figs.* 101, 102). Nevertheless, for a long time after the formation of these septa, the temporary (*a` a`*, *fig.* 102) and the permanent (*`b `b*) alveoli communicate by tolerably large orifices (*c' c'*, *figs.* 101, 102), through which proceed the cords (*c*, *fig.* 102) connecting the two teeth. The follicles of the permanent teeth do not sensibly differ in their mode of development from those of the provisionary teeth, only the increase of the vascular system of the former coincides with the progressive atrophy of the vessels of the latter.

Fig. 100.

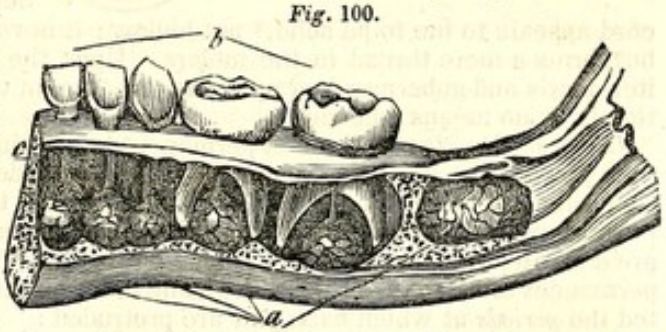

Phenomena which accompany their Eruption.—As long as the development of the permanent teeth can be effected in a direction towards the bottom of their sockets, the temporary teeth remain uninjured; but when the growth of the permanent teeth influences their upper edges, the alveoli of the first set are compressed, and afterward destroyed at the parts corresponding to the crowns of the permanent teeth (see *fig.* 101). After this time the alveoli of the first and second sets form common cavities: the roots of the milk teeth being compressed by the crown of the permanent teeth, undergo a loss of substance, become loosened, and may be detached by the slightest effort, each tooth being retained in its place only by the sort of ring formed by the gum around its neck.

Fig. 101.

The shedding of the milk teeth is not always effected in the way we have described, viz., by a previous destruction of their root. Sometimes, in fact, the permanent tooth does not penetrate into the alveolus of the corresponding milk tooth; but this alveolus is gradually wasted away by the constantly increasing development of the neighbouring permanent socket. In this case, the milk teeth may fall without destruction of their roots, which, however, are then almost always slender, and, as it were, atrophied. Some compression, either exercised upon the parieties of the temporary sockets, or upon the roots of the milk teeth, is almost indispensable for their expulsion. When, in fact, the permanent tooth deviates from its natural direction, and, consequently, does not press upon the milk tooth, this latter remains, and forms a *supernumerary tooth*. We cannot, then, doubt the influence of this compression upon the fall of the milk teeth; but anatomists are not agreed as to the immediate cause of the destruction of the temporary alveoli, and of the roots of the teeth contained within

* [Although the papillæ, it will be remembered, appear *earlier* in the upper jaw.]

† See note, p. 183.

them. How does this compression act? Does it produce the fall of the milk teeth in a purely mechanical manner, or does it effect this indirectly by the destruction of the dental vessels and nerves? One author believes the latter to be the principal cause; but what we have already said regarding the want of vitality in the teeth will abundantly prove that the wearing away of the alveolus and the milk tooth is the result of mechanical pressure.

At the same time it should be observed, that, since the destruction of the roots of the milk teeth leaves no *débris*, a process of absorption must, therefore, be performed, the exciting cause of which is, undoubtedly, the compression above alluded to. It is not necessary, as some authors have believed, to assume the existence of a peculiar absorbent apparatus, appropriated to this office.

The teeth of the first dentition are shed in the space comprised between the sixth and the eighth year, the fall of each tooth taking place in the same order as its appearance. Blake was the first to point out the existence of a cord (*c*, *fig.* 102) passing from the follicle of the permanent tooth, along a small, long canal (*c′ c′*), behind the alveolus of the milk tooth, and becoming continuous with the gum. It has been supposed that the canal, and the cord placed within it, were intended to direct the tooth during the progress of its eruption. Hence the name of *iter dentis* given to the canal, and *gubernaculum dentis* applied to the cord, which has been ingeniously compared by M. Serres to the *gubernaculum testis*. This cord appears to me to be solid,* not hollow; it is very well marked in the incisor teeth, but forms a mere thread in the molars. Upon the whole, the influence exerted by the iter dentis and gubernaculum upon the direction of the permanent teeth during its eruption is by no means constant.

Fig. 102.

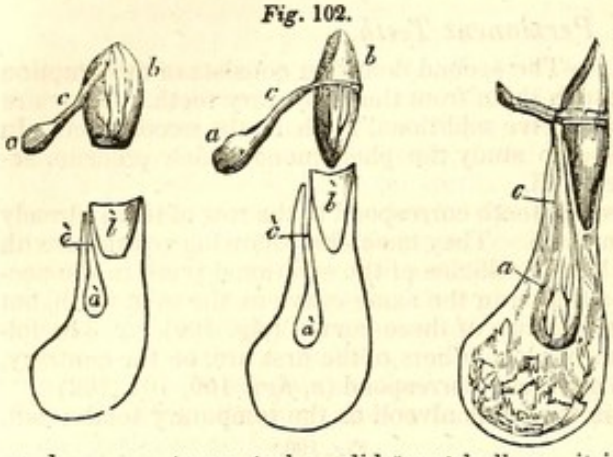

Order of Eruption.—The first permanent teeth which appear are the first great molars; they precede the other permanent teeth by a considerable interval, and immediately succeed the milk teeth, coexisting with them for some time; they have been, therefore, improperly classed among the first set of teeth in some anatomical treatises. The first great molars are known by the vulgar name of *seven years' teeth*. The eruption of the permanent teeth takes place in the same order as that of the milk teeth. Below are stated the *periods* at which each pair are protruded:

Middle lower incisors	from	6 to	8 years.
Middle upper incisors	"	7 "	9 "
Lateral incisors	"	8 "	10 "
First small molar	"	9 "	11 "
Canine teeth	"	10 "	12 "
Second small molar	"	11 "	13 "
Second great molar	"	12 "	14 "
Third great molar	"	28 "	30 "

The greatest irregularity exists in the eruption of this last molar tooth, which is often wanting, and frequently remains, during the whole of life, either partially or entirely enclosed within the substance of the jaw.

The incisor and canine teeth of the second set are much larger than the corresponding milk teeth. The opposite is the case with regard to the first two permanent molars, viz., the small molars, or bicuspides. It was ascertained by the inquiries of Hunter, that, in this way, there is such a compensation, that the twenty teeth of the first set occupy precisely the same space as the twenty corresponding teeth of the second. This is not a purely speculative question, but one of singular interest in relation to the practice of extracting the milk teeth. The truth of Hunter's assertion may be confirmed by measuring with a thread the space occupied by the twenty temporary teeth, and comparing it with the space occupied by the corresponding teeth of the second set. M. Delabarre has done this upon the same individual at the period of the two dentitions.

Phenomena which follow the Eruption of the Permanent Teeth.—These relate, 1. To their growth; 2. To their decadence.

1. *Growth of the Teeth.*—The teeth of man are not, like those of some animals, the rodentia in particular, susceptible of unlimited growth. The enamel of the crown wears away without ever being reproduced. All the facts brought forward in support of the idea of its reproduction are either erroneous observations, or may be interpreted in a different manner. Nevertheless, some changes take place in the interior of the tooth which are worthy of notice. New layers of ivory continue to be secreted; and the cavity of the

* [Arising from the adhesion of the sides of the elongated part of the cavity of reserve.]

tooth is gradually encroached upon, and finally obliterated. Thus the teeth of the aged have neither pulp nor dental cavity.

2. *Decadence of the Teeth.*—The fall of the teeth in aged persons is the effect of a contraction of the alveoli, produced in the following manner: The teeth are dependances of the buccal mucous membrane, and are, as it were, only accidentally placed in the alveolar borders, which, from the tonicity or elasticity of their bony tissue, have a constant tendency to displace them. In one word, the tooth is to the alveolus like a foreign body, of which it is incessantly tending to free itself. This tendency to contract on the part of the alveolus is effectually resisted, so long as the root of the tooth has a tendency to increase towards the bottom of the socket; but it acts with full force when this resistance ceases in consequence of atrophy of the pulp. Then the alveolus, shrinking upon itself, expels the tooth by a mechanism similar to that by which, during the progress of syphilitic affections, the most healthy-looking teeth are displaced, solely in consequence of the vitality of the pulp being destroyed by the influence of the virus.

The fall of the teeth in the aged is regulated by no law, either as regards the time or the order in which it is effected.

Differences between the First and Second Sets of Teeth.—The teeth of the first dentition are distinguished from those of the second by the following characters: 1. Their colour, instead of being white, like ivory, or clear yellow, is of a bluish or azure white hue. 2. The temporary incisor and canine teeth are always distinguished from the corresponding permanent teeth by their smaller size and the shortness of their roots. 3. The two molars of the first set differ from the two small permanent molars or bicuspids which take their place, and approach nearer in character to the great molars; from these, however, they are distinguished, by the shortness of their crowns, and by the number of tubercles on them, viz., five; three on the outside, and two on the inside. 4. Comparative chemical analyses of the teeth of the two sets have shown that the milk teeth contain somewhat less phosphate of lime than the permanent, and to this circumstance their greater susceptibility of change is due.

General Observations.—From the description we have given of the teeth, it will be seen that these organs should be looked upon merely as large vascular and nervous papillæ, covered by an unorganized calcareous sheath, which is formed by a species of crystallization.* The diseases of the teeth offer nothing incompatible with this theory, for, with the exception of toothache, and the sensation of being set on edge, which are evidently seated in the pulp, the other alterations of which the teeth are susceptible are either mechanical lesions, such as splitting, cracking, wearing, &c., or chemical changes, as the dry or moist caries, or, lastly, alterations appearing to have their seat in the hard substance of the tooth, but which are really situated elsewhere. Of this nature are the incrustations with tartar, the product of a vitiated secretion, attributed by several anatomists, and especially by M. Serres, to some small follicles, the function of which, before the eruption of the teeth, is to produce a fluid to soften the gum preparatory to its perforation by the teeth. Again, exostosis and spina ventosa of the teeth evidently depend upon irregular secretion of the enamel and ivory. The consolidation of fractures of the teeth is explained by the formation of new layers, resembling those which have been seen surrounding bullets in the substance of an elephant's tusk. Lastly, the coloration of the teeth, from the action of madder, is only observed in the layers deposited during its use, and therefore does not prove the existence of any nutritive process in these organs, such as takes place in bone.

With regard to the evolution of the teeth in two distinct sets, it may be inquired what is the object of such an arrangement. Without entering here into the discussion of final causes, it cannot be denied that the second set of teeth would not accord with the comparatively small size of the jaws in the fœtus.

Use.—1. The teeth are the immediate agents of mastication. The incisors cut, the canine tear, and the molars grind the food, the position of each being regulated by the resistance they have to overcome. 2. The teeth form a kind of elevated border, which prevents the constant escape of saliva from the mouth. 3. They assist in rendering sounds articulate, by affording a fixed point to the tongue in the pronunciation of certain consonants, called by grammarians dental. 4. The teeth furnish important characters for zoological classifications. Indeed, as they bear a necessary relation to the mode of feeding in different animals, a circumstance that exercises so great an influence over their entire organization, it may easily be conceived that the form of the teeth is, to a certain extent, one of the characters by which a summary idea is conveyed of the nature of that organization. At the same time, it is necessary to guard against the evidently erroneous conclusions which some philosophers have delighted in deducing from the arrangement of the dental apparatus in man with regard to his fitness for a purely animal or exclusively vegetable diet. Above all, it should be remembered that the mechanical ingenuity of mankind must always form an indispensable element in the solution of every problem of this nature.

* [It is necessary, in some degree, to modify this definition of the hard portion of the teeth, which, though *extra-vascular*, and, on that account, probably subject neither to interstitial absorption nor nutrition, cannot be regarded with propriety as *unorganized* or *crystalline* bodies.

MYOLOGY.

The Muscles in general.—Nomenclature.—Number.—Volume and Substance.—Figure.—Direction.—Relations.—Attachments.—Structure.—Uses.—Preparation.—Order of Description.

The active organs of locomotion are called *muscles*.* They are composed of bundles of red or reddish fibres, consisting of fibrin as their *basis*, and possessing the essential property of *contractility*, that is, the power of contracting or shortening upon the application of a stimulus.†

Nomenclature of Muscles.

The names applied to the various muscles have not been founded upon uniform principle. Before the time of Sylvius the muscles of any region (of the thigh, for example) were designated numerically, first, second, &c., in the order of their super-position or of their uses. Sylvius first gave particular names to the greater number of the muscles; and he was followed by almost all succeeding anatomists, especially by Riolanus. In this nomenclature, which is still generally adopted, the names of the muscles are derived, 1. From their situation, as radialis, ulnaris, peroneus, &c.; 2. From their size, as glutæus maximus, minimus; palmaris longus, brevis, &c.; 3. From their direction, as rectus abdominis, obliqui capitis; 4. From their shape, which is generally an imperfect representation, either of certain geometric figures, as rhomboideus, pyramidalis, and scalenus, or of well-known objects, as deltoideus, lumbrici, and soleus (from *solea*, the sole fish); 5. From their divisions or complications, as digastricus (from having two bellies), triceps (from having three heads), biceps, complexus, &c.; 6. From their insertions, as sterno-hyoid, sterno-thyroid, &c.; 7. From their uses, as flexors, abductors, &c.

In modern times many attempts have been made to substitute in the place of these vague and generally arbitrary denominations, a uniform nomenclature, derived from the most important consideration, viz., the attachment of the muscles. The nomenclature of Chaussier, however, which is undoubtedly superior to all others, has not been adopted; first, because a knowledge of the old names cannot be neglected, since they are the only ones employed in a great number of works on medicine and surgery; and, secondly, because even the most imperfect denominations, when they have been long in use, are, from this circumstance alone, preferable to any new appellations.

Number of the Muscles.

Upon this point, likewise, authors are but little agreed. According to most, the number of muscles is four hundred. Chaussier reduced it to three hundred. These differences arise partly from the fact that the natural limits of the different muscles are not so well marked as those of the bones, for example, and partly because the grounds of demarcation between the various muscles have not been sufficiently established. The following rules may be adopted with advantage: 1. When a number of fasciculi unite, and form a mass, which is isolated both in its body and at its extremities, and fulfils distinct and determinate uses, such a collection should be considered a separate muscle. 2. A muscle should also be regarded as distinct when it is separated from others at one portion only of its body, and at the most movable of its attachments. On the whole, whatever be the mode of demarcation adopted, it will be seen that the number of the muscles greatly exceeds that of the bones; the reason of this is, that each bone acts as a lever in a great variety of movements, while each muscle acts only in a very limited number of motions.

Volume and Substance of the Muscular System.

Of all the systems of organs in the body, the muscular is predominant both in substance and in volume. This great mass of muscular apparatus is a necessary consequence of the unfavourable position of most of the levers represented by the bones. There is very great variety in different individuals, as regards both the volume and substance of the muscular system. Compare, in this respect, the glutæus maximus of a robust man, and the same muscle in a thin, nervous individual, much emaciated, but yet in perfect health, for still greater differences are produced by disease: size and strength of the muscular system may also be natural or acquired, partial or general. Partial preponderance is most usually acquired, and is commonly the result of exercise. To be convinced of this, it is only necessary to inspect the muscles of certain regions, in individuals whose employment requires the special exercise of those parts. The preponderance of the muscles on the right side is produced solely by the habit of using this side more than the other; it is not, as has been alleged, the result of congenital difference.

Lastly, the size of one or the other region of the muscular system, in different animals,

* From μυών, a muscle, or μυς, a mouse.

† It will be seen that, in constructing this definition, the only object has been to distinguish the muscles generally from other organs, by pointing out their two characteristic properties, viz., their fibrinous composition and their contractility.

is in relation either with their instinctive propensities, their mode of feeding, or their natural attitude, or with some other important peculiarity in their organization. Hence we find, 1. In the lion, the tiger, and other carnivorous animals that tear their prey in pieces, the muscles connected with the inferior maxilla, the most highly developed; 2. In the bear, which is a climbing animal, the muscles of the back; 3. In the hare, whose mode of progression is by successive leaps, the muscles of the hind limbs; 4. The muscles of the wing in birds; and, 5. Those of the lower extremities and the vertebral grooves in man, to whom the erect position is peculiar.

Figure of the Muscles.

The figure of the muscles is determined upon the following data: 1. From a comparison of them with geometric figures or with familiar objects. 2. From the respective arrangement of their surfaces, edges, and angles. 3. From their being symmetrical or otherwise. In this latter respect there is a remarkable difference between the osseous and the muscular systems: many bones are symmetrical, or azygos, while almost all the muscles, on the contrary, are asymmetrical, and arranged in pairs. 4. From the relative proportion between their three dimensions; from this latter consideration, muscles have been divided into three classes, viz., *long*, *broad*, and *short*, concerning each of which we shall make some general remarks.

The *long muscles* are chiefly met with in the limbs. Their length is sometimes considerable; and the longest are always most superficial. Very long muscles generally pass over several articulations, and can therefore assist in moving them all. This great length of certain muscles has also another advantage, viz., that it enables them to obtain a fixed point of attachment upon a less movable part, as the trunk, from which they can then act upon the more mobile parts: such is the case with the muscles that move the thigh or the leg. Long muscles are either simple or divided. Sometimes the division occurs at the more movable attachment; sometimes at that which is habitually fixed.

The *broad muscles* occupy the parietes of cavities; they are quadrilateral when all their points of attachment are on the trunk, and triangular when they extend from the trunk to the extremities. When several broad muscles are super-imposed, the fibres of one always cross those of another at an angle; and this arrangement, by forming a sort of interweaving, greatly augments the strength of the parietes which they assist in forming. This is particularly well shown in the broad muscles of the abdomen.

The *short muscles* are generally met with in the same situations as the short bones. It is not the shortness of its fibres, but of its fleshy body that characterizes a short muscle. It is important to notice, with regard to these muscles, that a number of them are often arranged in succession, so as to resemble a long muscle. Of this we shall find many examples in the muscles of the vertebral grooves.

Direction of the Muscles.

The *direction* of the muscles is one of the most important points in their history, since, without a knowledge of this, it is impossible to appreciate their uses. Each muscle has an *axis* or middle line, in which the general action of its fibres takes effect. Few muscles are altogether rectilinear; most are angular or curved; and almost all undergo certain deviations or reflections in passing round the joints: some, indeed, take a direction at right angles to their primitive course, when they pass over pulleys or hook-like processes. In muscles of this kind the action is in the direction of the reflected portion.

The direction of muscles must be studied with reference to the axis of the body, but especially to the axis of the limb or lever, *in relation to which they represent the moving power*. Many muscles are almost parallel to the axis of the lever upon which they act; but it should also be remarked that, in certain positions, these same muscles form greater or smaller angles with their corresponding levers, and may even become perpendicular to them. In this respect the direction of the muscles is not absolute, but is subordinate to the position of the levers.

Some muscles are constantly perpendicular to the levers upon which they act.

The angles of incidence of the muscles upon their points of attachments are very variable, but generally they are more nearly parallel than perpendicular to those points. As the axis of a muscle is not the same as that of its component fibres, it is necessary to study, in each muscle, not only the direction of the fleshy belly, but that of the fibres also.

Relations or Connexions of the Muscles.

In reference to surgery, the relations or connexions of the muscles are among the most important circumstances in their history.

Relations of the Muscles to the Skin.—Those muscles only which are called cutaneous are immediately connected with the skin; the remainder are separated from it by aponeuroses of greater or less density, so that the skin does not participate in the movements of the muscles, and *vice versâ*. Nevertheless, the changes produced in the form and size of the muscles during their contraction are so decided, that those which lie near the surface are more or less defined through the integuments; but the projections

corresponding to the bodies of the muscles and the depressions at their attachments are, in a measure, obliterated by adipose tissue, the quantity of which varies in the two sexes and in different individuals. To this latter circumstance are due the differences in the outward characters of the muscular system of the female, as compared with the male; and of a fat individual, as compared with the one who is emaciated.

Relations of the Muscles to the Bones.—In the limbs where the muscles form several parallel layers around the bones, the belly or thickest part of the muscle always corresponds with the shaft or most slender portion of the bone; while the ends of the muscle, where it is thinnest, correspond with the expanded extremities of the bone. The relations of the bones with the muscles vary, according as the latter are deep-seated or superficial. The superficial are only in contact with the bones by their extremities or their tendons: the deep-seated muscles alone correspond to the bones by their entire length.

Relations of the Muscles to each other.—The muscles are arranged upon each other in successive layers; each muscle is covered by a sort of fibro-cellular sheath; and a loose and moist cellular tissue is interposed between the different sheaths, so as to facilitate the gliding movement and independent contraction of each muscle. This isolation of the muscles does not exist throughout their entire length; several are often blended together in one common insertion, from which they proceed as from a centre, afterward separating from each other. This community of attachment is principally observed in those muscles that perform analogous offices, or that, usually at least, act simultaneously. Most muscles are enclosed in a separate fibrous sheath, which isolates them in their actions, and also in their diseases. Of this we shall find remarkable examples in the rectus abdominis and sartorius. With regard to the relations of their edges, the muscles are sometimes contiguous throughout their entire course, and sometimes separated by intervals, generally of a triangular figure; and principally important in surgical anatomy, because incisions, for the exposure of vessels, are almost always made in such intervals.

Relations of Muscles to the Vessels and Nerves.—The muscles serve to protect the vessels and nerves, not only in consequence of the thickness of the layers which they form in front of them, but also by the resistance they oppose during their contraction to external violence. Near the centre of a limb there is generally a considerable cellular interval between the muscular layers, which is intended for the principal vessels and nerves. The existence of such spaces prevents the injury which these vital parts would sustain from compression during the contraction of the muscles. It is also worthy of notice, that whenever a vessel passes through the body of a muscle, we find an aponeurotic arch or ring, which is non-contractile, and in some degree, therefore, obviates the danger of compression during the action of the muscular fibres. I say in some degree, because, in order to render compression of the vessels impossible, the muscular fibres attached to these rings must have proceeded from them as from a centre, diverging in all directions. In this case, the action of the muscles would not change the form of the rings, but would tend to increase their diameters in every direction. It is found, however, that they are invariably elongated in one direction and diminished in another, when the fibres of the muscle contract. Bernouilli, indeed, has shown that it is impossible to change the form of a circle, by making one of its diameters greater than the others, without, at the same time, diminishing its capacity; because, within a given periphery, the most regular figures have the greatest capacity, and the circle is more regular than either the oval or the ellipse. On the whole, however, it must be understood that the contraction of the fibrous rings does not, in any material degree, impede the circulation.

It should also be remarked, that a distinct fibrous sheath surrounds the vessels and the nerves, serving to isolate and protect them amid the various muscles by which they are surrounded.

Most of the arteries have accompanying muscles, which may be called their respective satellites: thus, the sartorius is the satellite muscle of the femoral artery, the biceps of the brachial, the sterno-mastoid of the carotid, &c.

Attachments or Insertions of Muscles.

The *attachments* or *insertions* of muscles constitute one of the most important points in their history, and one which requires to be studied with the greatest care, because the uses of a muscle can be determined from a knowledge of its insertions alone. These insertions should be considered in two points of view: 1. As to the direct insertion of the muscular fibres into the tendons, aponeuroses, or other structures; 2. As to the insertion of the tendons and aponeuroses into the levers represented by the osseous system.

The *muscular fibres* themselves are attached, 1. To the *skin*, of which mode there are numerous examples in the muscles of the face; 2. To other muscular fibres, as in many muscles of the face and of the tongue; 3. To *cartilages*, as in several of the muscles of the chest and larynx; 4. To *aponeuroses*, of which they act as tensors, and whose power of resistance they thereby increase; lastly, to *tendons* or *aponeuroses*,* that are themselves attached to the bones.

The fleshy fibres are inserted into, or become continuous with, the tendons and apo-

* [The tendons afford examples of the fascicular form of fibrous tissue, for a notice of which see note, *infrà*.]

neuroses in the following manner: The tendon is prolonged under the form of a membrane, either upon the surface or in the substance of the muscle. The results of this arrangement are, 1. An increase of surface for the attachment of the muscular fibres, which the tendon gathers up, as it were, in order to concentrate their efforts upon one point; 2. An obliquity in the insertion of the fibres, in reference to the axis of the entire muscle, by which the direction of the power is represented. It may easily be conceived that this obliquity is of the greatest interest as regards the dynamic relations or active property of the muscles.*

One of the most curious circumstances respecting the continuity of a tendon or an aponeurosis with a muscle is the very intimate union between the muscular and fibrous tissues, which is so complete that they are scarcely ever separated by external violence, which, moreover, tends to lacerate the muscle rather than the tendinous fibres.

It is a fact worthy of notice, and one which we have already had frequent occasion to remark, that the adhesion of any two organic tissues is stronger than the respective cohesion of each; so that the tissues themselves will sooner break than admit of separation from one another.

Insertion of the Aponeuroses and Tendons into the Bones.—A tendon or an aponeurosis forms a species of ligament, by means of which the action of a very large muscle is transmitted to the lever intended to be moved, by a fibrous cord or aponeurotic lamina of small size. A great advantage arises from this mode of economizing the extent of bony surface required for muscular attachments; for, notwithstanding the extent of surface afforded by the expanded ends of the bones, and by the eminences and ridges with which they are covered, it would be evidently insufficient, were the muscular fibres to be directly attached.

The existence of tendons and aponeuroses produces also this remarkable result, viz., that the muscular insertions are much stronger than they would otherwise have been. The aponeurotic tissue acts as a *transition* structure, being in some points of its organization analogous to bone, and in others approaching that of muscle. The analogy between the bony and fibrous tissues is confirmed by the frequent occurrence of ossification in the latter, even under normal conditions, as may be observed in the formation of the sesamoid bones, and also in the mode by which tendons are attached. It has been observed, in fact, that at the point of junction of the tendons with the bones there is a sort of mutual fusion of the tissues, from which so intimate a connexion results, that the proper substance of the tendons always gives way before they can be separated from the bones, their attachments to which even maceration will scarcely destroy.

Of the different bones with which a muscle is connected, some remain immovable during its contraction, while others are put in motion; hence the distinction between *fixed* and *movable* attachments. But this eminently useful distinction must not be taken in an absolute sense; it is only rigorously true of a very small number of muscles, which, like some of those found in the face, being connected by one extremity with the skin, and by the other with the bones, can give rise to movements only at their cutaneous attachments. In the greater number of muscles, on the contrary, although one of the attachments is most commonly fixed and the other movable, yet their relative condition may be changed, and they may become alternately fixed and movable; it is therefore necessary, in explaining the action of a muscle, carefully to notice the supposed mobility or fixedness of the different attachments at the time.

In comparing such attachments as are habitually fixed with those that are constantly movable, we shall observe that the former are either numerous or spread out by means of aponeuroses, whereas the latter consist of very accurately-circumscribed tendons. The figurative expressions of *head* and *tail*, given to the ends of a muscle, refer to this arrangement. The fixed attachment of a muscle is usually blended with those of several others, while the movable one is distinct.† In order to facilitate our description, we shall invariably designate the fixed attachment of a muscle, its *origin*, and the movable attachment, its *termination* or *insertion*.

Structure of Muscles.

Muscles are composed of two kinds of fibres: 1. Of *red* or *contractile fibres*, which form the muscular tissue properly so called; 2. Of *white*, *strong*, and *non-contractile fibres*, constituting the tendons and aponeuroses. In speaking of the ligaments, we mentioned the general properties of tendons and aponeuroses as belonging to the fibrous tissues; we shall now make a few remarks on the peculiar characters of muscular tissue.

1. *Colour.*—Muscular tissue is of a reddish colour, the intensity of which varies in different muscles and in different individuals. This colour is not an essential character even in the human subject, for the contractile fibres of the intestinal canal are very

* In fact, as the tendon, and the aponeuroses by which it is continued into the muscle, represent the direction of the power, the fleshy fibres must necessarily be attached to it more or less obliquely. It is not our intention to examine here the great loss of power which this arrangement involves.

† [This assertion must be taken with some limitation. We shall find many exceptions to this general rule, as we proceed in the description of the muscles.]

pale;* still less is it so in the lower animals, some of which have the entire muscular system perfectly colourless. The red colour of the muscular fibre is independent of the blood contained within the vessels of the muscle.

2. *Consistence.*—The consistence of the muscular fibres varies in different subjects: in some it is soft and easily torn; in others it is firmer and more resisting, and retains for some time after death a degree of rigidity which yields with difficulty to forcible extension.

Structure.—The muscles may be divided into bundles or fasciculi of different orders, and these, again, into distinct fibres, which are visible to the naked eye, and rendered more apparent, either by dissection, or by the action of alcohol, of diluted nitric acid, or even of boiling water. They are of a variable shape, resembling prisms of three, four, five, or six surfaces, but are never cylindrical. Their length also varies in different muscles, in but a few of which do they extend parallel to each other throughout the entire length of the fleshy belly.

Each muscle is surrounded by a sheath of cellular tissue, which also penetrates into its substance, and surrounds both the fasciculi and fibres. This cellular tissue permits the free motion of the different fasciculi upon one another, while it serves, at the same time, to isolate each and combine the whole.†

The chemical analysis of muscular tissue shows that it is composed of a small quantity of free lactic acid (*Berzelius*); gelatin; some salts; osmazome in greater or less quantity, according to the more or less advanced age of the individual; and leucine, a substance extracted from this tissue by the process described by M. Braconnot. (*Ann. de Chim. et de Phys.*, tom. viii.)‡

In addition to the tendinous and fleshy fibres, vessels, nerves, and cellular tissue also enter into the composition of muscles. We have already described the disposition of the cellular tissue *contained in these organs*; the mode of distribution of their vessels and nerves will be more appropriately alluded to in the description of the vascular and nervous systems.§

Uses of Muscles.

The muscles are the active organs of motion, constituting the source of the power

* [The involuntary muscular tissue, of which the above-named fibres afford examples, are, with the exception of the heart, of a much paler colour than the voluntary muscles, to which this division of the present work exclusively refers.]

† [In reference to the microscopic structure of the voluntary muscles, or those of animal life, it has been ascertained that the smallest *fasciculi* (corresponding with the prismatic fibres of our author, and with the secondary fasciculi of Müller), the size of which varies in different muscles, are divisible into *transversely-striated fibres* (the primitive fasciculi of Müller), having a uniform diameter in all muscles in the same species, and being themselves composed of still smaller elementary parts named *filaments* (the primitive fibres of Müller). All these elements of the muscular tissue extend parallel to each other, from one tendinous attachment to another, never having been seen to bifurcate or coalesce.

In man the *fibres* vary from $\frac{1}{400}$th to $\frac{1}{600}$th of an inch in diameter; the transverse striæ upon them are parallel, generally straight, but occasionally slightly waved or curved; they are situated at intervals of from $\frac{1}{15000}$th to $\frac{1}{12000}$th of an inch.

The *filaments* are varicose or beaded, *i. e.*, alternately enlarged and contracted; their diameter is from $\frac{1}{18000}$th to $\frac{1}{15000}$th of an inch. According to the general opinion, they are held together in each fibre by means of a glutinous substance, which latter, according to Skey, constitutes the entire centre of the fibre, the circumference alone being occupied by the filaments. In the larvæ of insects, a delicate membranous sheath, sometimes observed projecting beyond the filaments, has been described by Schwann as forming a proper investment of the fibre; and, by analogy, this is also presumed to exist in man and the other vertebrata. Be this as it may, it is certain that the fibres have no separate sheaths of cellular tissue derived from the common sheath of the muscle, the prolongations of which appear to extend only so far as to enclose the smallest fasciculi.

The cause of the striated appearance has, perhaps, not been quite satisfactorily ascertained; but since the enlargements on the varicose filaments are darker than the constricted portions, and since they are situated at intervals precisely similar to those between the transverse striæ of the corresponding fibre, and from some other additional considerations, it has been supposed, with great probability, to result from the enlarged and dark portions of the filaments being arranged side by side.

For an account of the microscopic characters of the involuntary or organic muscular fibres, see the notes on the structure of the several viscera, &c., in which they are found, viz., the alimentary canal, trachea, genito-urinary organs, and iris. We may remark here, that the muscular fibres of the heart and of the upper part of the œsophagus are striated, and approach very closely in character to those of animal life.]

‡ [The following analysis of the muscles of the ox is on the authority of Berzelius:

Water	77·17
Fibrin (with vessels and nerves)	15.8
Cellular tissue convertible into gelatin	1·9
Albumen and colouring matter	2·2
Alcoholic extract, or ozmazome, with lactic acid and lactates	1·8
Watery extract, with phosphate of soda	1·05
Phosphate of lime	·08
	100·

The inadvertent omission, on the part of M. Cruveilhier, of *fibrin* as one of the proximate principles of muscle, will serve to impress on the mind of the reader its importance as a constituent of that tissue, in which it exists in greater abundance than in any other.

The substance called leucine, mentioned in the text, is a *product* resulting from the action of concentrated sulphuric acid on muscular fibre, and therefore must not be regarded as previously existing in it.]

§ As it is our intention to introduce, after Myology, an account of the Aponeuroses, we shall be content at present with the general ideas that have been already stated regarding this important division of the fibrous tissues.

that is applied to the various levers represented by the component parts of the skeleton. The movements produced are the result of that peculiar property possessed by the muscles of shortening themselves, which is called *muscular contractility* (*myotilité*). The shortening of a muscle is termed its *contraction*, and the opposite state its *relaxation*.

Phenomena of Muscular Contraction.—During contraction the muscular fibres become folded in a zigzag manner throughout their entire length; the muscle itself becomes hardened, and broader and thicker in proportion to the amount of shortening. There is no oscillation in a muscular fibre during a normal contraction.*

The aponeuroses and the tendons take no part in the contraction; they are entirely passive. The degree of shortening of which the muscular fibre is susceptible cannot be precisely determined; as far as we know, the shortening, and, consequently, the extent of the resulting movement, is proportional to the length of the fibre. A distinction should be drawn between the *force* and the *velocity* or rapidity of muscular contraction. Again, the velocity is very different from the extent of motion: the latter depends upon the length of the fibres; the former has no connexion with it, but varies according to the constitution of the individual, and is probably dependant on a more or less rapid influx of nervous influence.

The *muscular force* is composed of a great number of elements. According to Borelli, an *intrinsic* and an *effective force* may be distinguished in each muscle. The intrinsic force is that power which the muscular fibres would exert if they were in the most favourable position for contraction: the effective force is measured by the result. The estimation of the force of a muscle presupposes a knowledge, 1. Of the number of its fibres. 2. Of ther quality or constitution. 3. Of the nature of the lever upon which it acts. 4. Of the angle of incidence of the muscle upon that lever; and, 5. Of the angle of incidence of the fibres with respect to the imaginary axis of the muscle.

1. Each muscular fibre, being distinct from those around it, may be considered as a small power; it may, therefore, be easily conceived that the greater the number of fibres in any muscle, the more energetic will be its contraction.

2. The quality and constitution of the fibre, and the intensity of the stimulus, have no less an influence upon the contractile force of a muscle than the number of its fibres. To be convinced of this, it is sufficient to compare the energy of movement in an individual excited by anger with that in one who is calm.

3. The determination of the kind of lever† represented by the bone upon which the muscle acts, is a fundamental point in studying muscular action. It is a law in mechanics, that the power acts with greater effect in proportion as its arm of the lever exceeds in length that of the resistance. The most common lever in the human body is that of the third order, in which the power, being applied between the fulcrum and the weight, is therefore most disadvantageously situated for action.

4. As far as regards energy of movement, the lever to which the power is applied is as unfavourable as possible, because the muscles are generally inserted near the fulcrum.

* The observations of Rogerus tend to show that rapid contractions and relaxations are *constantly* taking place in muscles, especially during their contraction.—(*Tr.*)

"De Perpetua Fibrarum Muscularium Palpitatione," 1760.

† A lever, in mechanics, signifies an inflexible rod capable of turning round a point. The point upon which the lever turns is called the *fulcrum* (*f*, *figs.* 103, 104, 105); the cause of motion is called the *power* (*p*); and the obstacle to be surmounted is the *resistance* (*r*); the space between the fulcrum and the power is the *power-arm of the lever*; the space between the fulcrum and the weight is the *resistance-arm of the lever*. There are three kinds of levers, distinguished by the respective arrangement of the three parts: 1. A *lever of the first order* (*fig.* 103) has the fulcrum between the power and the resistance. 2. A *lever of the second order* (*fig.* 104) has the resistance between the fulcrum and the power. 3. A *lever of the third order* (*fig.* 105) has the power between the resistance and the fulcrum

Fig. 103.

Fig. 104.

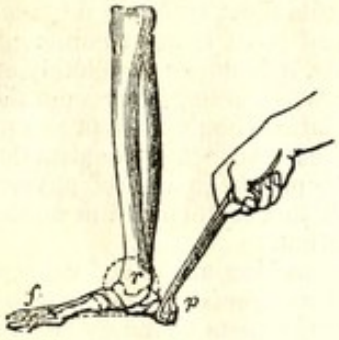

Fig. 105.

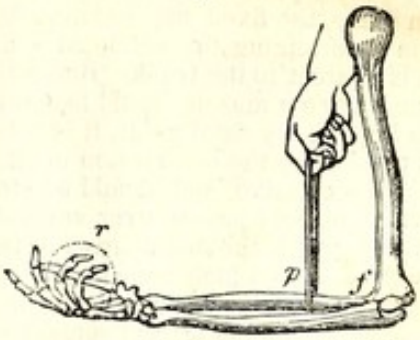

But, as a sort of compensation, an advantage peculiar to animal mechanics, the motions gain in velocity and extent what they lose in force, which, however, may still be obtained by an increase in the number of muscles, and of the fleshy fibres of each muscle. Nevertheless, levers of the most favourable construction, and of the most advantageous position, are met with in situations where considerable force is required; as in the articulation of the foot with the leg, presenting an example of a lever of the second order; and in the articulation of the head with the vertebral column, forming a lever of the first order.

The angle of *incidence* most favourable to the power is the right angle; but in the human body, as the muscles are arranged in layers upon the bones which they are intended to move, they are for the most part inserted at very acute angles. Their incidence would be still more unfavourable were it not for the enlargement of the articular extremities of the bones, which disturb the parallelism of the muscles. Besides, in certain cases, the angle of incidence more or less approaches, or even attains to a right angle, and is combined with an extremely advantageous lever, when such an arrangement is required: as in the articulation of the foot with the leg.

It is of importance to notice, in determining the action of a muscle, that its incidence upon the bone varies at different periods during its action; so that a muscle which is almost parallel to the lever when it begins to contract, becomes perpendicular to it at a given moment during that process. It may be said that the *momentum of a muscle* occurs at that period of its action when its perpendicular incidence gives it the utmost energy of which it is capable: thus, the momentum of the action of the biceps femoris takes place when the leg forms a right angle with the thigh. In a certain number of muscles the momentum coincides with the commencement of action, such as the gastrocnemii and the solei. In some muscles the angle of incidence remains the same throughout the whole time of their action, and, consequently, they have no momentum: this is the case with the deltoid.

The angle of incidence of the muscular fibres, with regard to the imaginary axis of the muscle or the terminating tendon, involves a loss of power proportional to the amount of the angle. In some muscles the aponeuroses form a continuation of the fleshy fibres; in others, the angle of incidence of the muscular fibre is so acute that it may be left out of consideration.

Estimation of the Action or Uses of the Muscles.—Since the contraction of a muscle consists in its shortening, it follows that its action may be determined, *à priori*, from a knowledge merely of its attachments and direction. It may also be ascertained experimentally, by placing a limb in such a position that the muscle in question shall be perfectly relaxed. As the same muscle generally performs several uses, it is necessary to place the limb in several different positions, so as to determine those in which the muscle becomes relaxed. Let us take, for example, the glutæus maximus. If we desire to relax this muscle completely, it is necessary, 1. To extend the thigh upon the pelvis. 2. To abduct it. 3. To rotate it outward: hence it follows that the glutæus maximus is at once an extensor, an abductor, and a rotator outward of the thigh. As a counterproof, the limb must be placed in such a condition that the muscle becomes completely stretched. The successive positions in which a muscle becomes stretched will be the very reverse of those which the limb assumes during the contraction of the muscle. Thus, the glutæus maximus is slightly stretched by rotation inward, more so by adduction, and most completly by flexion of the thigh upon the pelvis.

In determining the action of a muscle that is reflected over any angle of a bone, it is necessary to put out of consideration all that portion of the muscle intervening between its origin and its angle of reflection, and to suppose the power to operate directly from the latter points.

The action of sphincter muscles is to close the orifices around which they are placed. A curvilinear muscle assumes a rectilinear direction at the very commencement of its action.

The insertions of a muscle are neither equally fixed nor equally movable. The *fixed point of a muscle* is that extremity which remains immovable during contraction; but, in certain cases, the fixed may become *the movable point:* this must be taken into consideration in determining the action of a muscle. The fixed point is most commonly that which is nearest to the trunk. But, with few exceptions, it is never completely stationary; and since a muscle would lose much of its power when acting between a movable and an imperfectly fixed point, it is necessary that the latter should be kept as immovable as possible by the contraction of other muscles. These consecutive contractions are often very extensive, and should be familiar both to the physician and the physiologist.

When a muscle passes over several articulations, it moves them all in succession, commencing with the one nearest to the movable insertion.

Those muscles which concur in producing the same motion are called *congenerous;* those which execute opposite movements are termed *antagonists:* thus all the flexor muscles of any region are congenerous, and they are antagonists to the extensors.

Two muscles may be congenerous at one time, and act as antagonists at another: when they contract simultaneously, their individual and opposite effects are destroyed,

and a common and intermediate effect results; thus, when the flexor carpi ulnaris, which is both an adductor and a flexor, acts in conjunction with the extensor carpi ulnaris, which is an adductor and extensor, the hand is neither flexed nor extended, but is merely adducted. We shall constantly have occasion to notice this arrangement, which appears to me calculated to give much greater precision of motion than if two perfectly congenerous muscles had been employed.

There are also certain compound motions, which are, as it were, the results of two different movements; thus, when the flexors and the adductors of the thigh act simultaneously, the femur passes in the intermediate direction. It is from this kind of combination that the movement of circumduction is produced by the action of the four orders of muscles situated at the extremities of the antero-posterior and transverse diameters of the joint. These four orders of muscles are known by the names of *flexors*, *extensors*, *adductors*, and *abductors*.

Lastly, muscles may contract without producing any motions, as when antagonist muscles act with equal energy. The result of such a simultaneous contraction is an *active immobility* or *tonic movement*, as the older writers termed it, which is of very great importance.

Preparation of Muscles.

Dissection.—The end to be attained in the dissection of a muscle is to isolate it accurately from all the surrounding parts, leaving only those connexions which are compatible with that object. Since, however, it is sometimes impossible to preserve the relations, and at the same time isolate the muscle, it then becomes necessary to be provided with two preparations for the demonstration or study of the same muscle.

In order to isolate a muscle, the surrounding cellular tissue, which often forms a very adherent sheath, must be removed; and to do this completely, 1. Make a section of the skin parallel to the fibres of the muscle, deep enough to reach the muscle through the sheath; 2. As soon as the flap of skin can be grasped by the hand, stretch and separate it from the muscle by cutting with the scalpel in the angle formed by these two parts; 3. When the superficial surface is exposed, proceed to separate the deep surface, preserving as much as possible all its important relations; 4. Then dissect the extremities, marking out their limits with the greatest care.

In the study of the muscular system, great importance should be attached to the choice of subjects. Robust and tolerably fat subjects are best adapted for this purpose.

Preservation of Muscles in Liquids.—Alcohol, oil of turpentine, a mixture of equal parts of these, or solutions of the bichloride of mercury, or persulphate of iron, may be employed for the preservation of muscles, though they alter many of their properties, such as their colour, consistence, &c.

Preparations by Desiccation.—As this kind of preparation requires a peculiar method, we refer to the special treatises upon anatomical preparations for an account of them. (Vide *the works of MM. Marjolin and Louth.*)

Order of Description of the Muscles.

Before passing to the description of the particular muscles, it is necessary to determine in what order they shall be studied. Galen divided the body for this purpose into regions, and described the muscles of each in their order of super-imposition. In place of this arrangement, which is purely topographical, Vesalius substituted a physiological one, founded upon a consideration of the uses of the muscles. This order was adopted by Winslow, who named the different muscular regions in the following manner: *Muscles which move the shoulder upon the trunk; muscles which move the arm upon the scapula*, &c. Albinus revived the method pursued by Galen, and divided the muscles into forty-eight regions in the male and forty-six in the female. He was followed by Sabatier, and by Vicq-d'Azyr, who brought the arrangement to perfection by establishing some subdivisions in the groups formed by Albinus. Thus modified, it has been adopted by most modern anatomists. It is evidently preferable in many respects, since it is essentially anatomical, and is best calculated to exhibit the relations of the different muscles and regions. In regard, also, to economy of subjects and facility of dissection, it has many advantages over the physiological order, with which, however, in many regions it may be made to coincide. We shall, therefore, adopt this arrangement, modifying it so far as to permit all the muscles to be dissected upon one subject; and, after having described all the muscles according to their topographical relations, we shall give a table in which they will be grouped in a physiological order.

MUSCLES OF THE POSTERIOR REGION OF THE TRUNK.

The Trapezius.—Latissimus Dorsi and Teres Major.—Rhomboideus.—Levator Anguli Scapulæ.—Serrati Postici.—Splenius.—Posterior Spinal Muscles.—Complexus.—Inter-spinalis Colli.—Recti Capitis Postici, Major et Minor.—Obliqui Capitis, Major et Minor. —General View and Action of the Posterior Spinal Muscles.

The muscles situated on the posterior region of the trunk form several layers, which, proceeding from the skin to the bones, consist, on either side, of the trapezius, the latissimus dorsi and teres major, the rhomboideus and levator anguli scapulæ, the serrati postici, superior and inferior, the splenius, the long muscles of the back, viz., the sacro-lumbalis and longissimus dorsi; the transversalis colli and the complexus (which I regard as two series of accessory fasciculi to the longissimus dorsi); the complexus major, the inter-spinales colli, the recti capitis postici, major et minor, and the obliqui capitis, major et minor.*

The Trapezius.

Dissection.—1. Render the muscle tense by placing a block under the chest; 2. Make an incision through the skin from the occipital protuberance to the twelfth dorsal vertebra, and another horizontally from the seventh cervical vertebra to the external end of the clavicle; 3. Reflect the two flaps, together with the cellular membrane adhering intimately to the muscle; 4. Dissect very carefully the insertions into the occipital bone, which consist of a very thin aponeurosis closely united to the skin.

The *trapezius* (cucullaris, *Albinus, a, figs.* 106, 113), the most superficial muscle on the posterior region of the trunk, covers the nape of the neck and the back. It is a broad triangular, rather than trapezoid muscle, thick in the middle, thin and elongated at its superior and inferior angles.

Fig. 106.

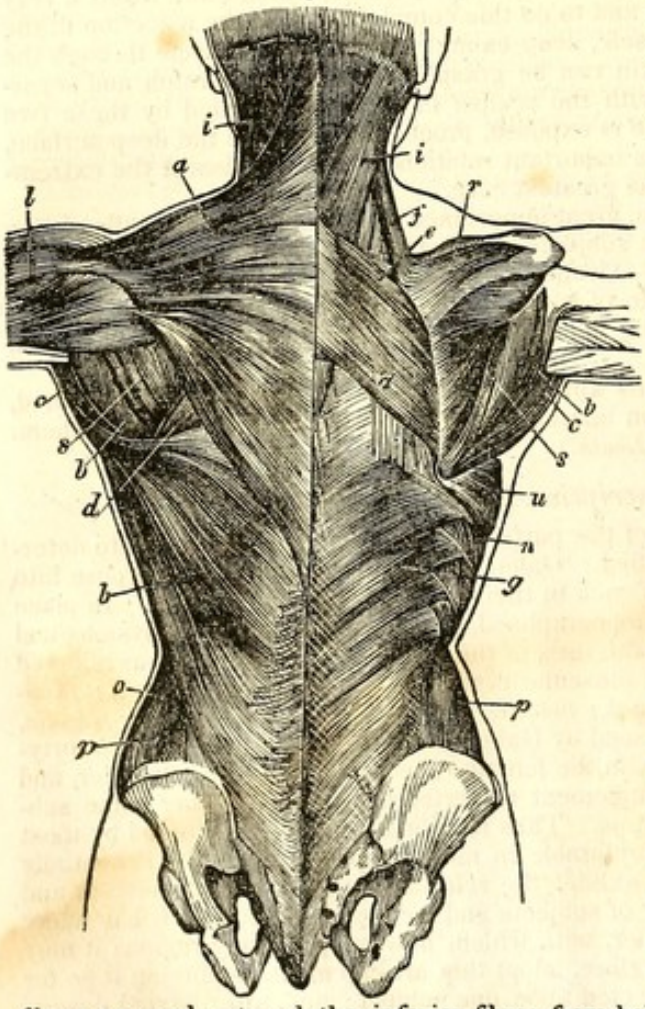

Attachments.—It *arises* from the spinous processes of all the dorsal and the seventh cervical vertebræ, from the corresponding supra-spinous ligaments, from the posterior cervical ligament (ligamentum nuchæ), and from the internal third of the superior occipital line, and is *inserted* into the entire length of the spine of the scapula, into the posterior border of the acromion, and into the external third of the posterior border of the clavicle. The fixed attachments or origins of this muscle present, 1. A broad, semi-elliptical aponeurosis, which, when united to the one on the opposite side, forms an ellipse, occupying the space between the sixth cervical and the third dorsal vertebræ; 2. A very thin fibrous lamina, not having the ordinary shining appearance of an aponeurosis, which is firmly adherent to the skin, and forms the truncated occipital angle of the muscle; 3. A great number of tendinous fibres, constituting all those attachments to the vertebræ that are independent of the two preceding aponeuroses. From these origins all the fleshy fibres proceed *outward*, the inferior fibres from below upward, the superior from above downward, and from behind forward, and the middle ones horizontally. They terminate in the following manner: the lower or ascending fibres are collected together, and attached to a triangular aponeurosis, which, gliding over the small facette at the internal extremity of the spine of the scapula, is inserted into the tubercle immediately connected with it; the middle or horizontal fibres terminate at the posterior border of the spine of the scapula, by tendinous fibres which are very distinct, especially towards the acro-

* [The *transverso-spinalis* muscle includes the semi-spinalis colli, the semi-spinalis dorsi, and the multifidus spinæ of Albinus.]

mion; the upper or descending fibres are inserted into the convex portion of the posterior border of the clavicle, many of them being also attached to the upper surface of that bone.

Relations.—The trapezius is covered by the skin, from which it is separated by an aponeurotic lamina, except at the upper part, where the muscle and integuments are intimately adherent. It covers the complexus, splenius, rhomboideus, and levator anguli scapulæ, in the neck; and the serratus posticus superior, the supra-spinatus, the posterior spinal muscles, and the latissimus dorsi, in the back. The most important relations of this muscle are those of its superior and external or occipito-clavicular margin: this forms the posterior boundary of the supra-clavicular triangle, which is limited in front by the sterno-mastoid muscle, and below by the clavicle. It should be observed in reference to the indications regarding the supra-clavicular space, furnished by this margin of the trapezius, that it sometimes advances as far as the middle of the clavicle, and has even been observed to become blended with the posterior edge of the sterno-mastoid.

Action.—1. The upper or descending portion elevates the clavicle, and, consequently, the apex of the shoulder; but if the shoulder be fixed, this portion of the muscle inclines the head to one side and extends it, and, moreover, rotates it, so that the face is turned to the opposite side. 2. The middle or horizontal portion carries the shoulder backward, but, from the obliquity of the spine of the scapula, it also rotates that bone, so that the apex of the shoulder is carried upward. 3. The lower or ascending portion draws the posterior costa of the scapula inward and downward; and, by a species of rotation, which was alluded to when treating of the scapulo-clavicular articulations, also elevates the apex of the shoulder. 4. When the whole of the muscle contracts at once, the scapula is drawn inward, and the apex of the shoulder is raised.

The Latissimus Dorsi and Teres Major.

Dissection.—1. Render the latissimus dorsi tense by the same means as were employed for the trapezius, and also by withdrawing the arm from the side. 2. Make an incision in the median line from the tenth dorsal vertebra to the sacrum, and another transversely from the same vertebra to the posterior border of the axilla, dividing in the latter incision a fibro-cellular membrane, which adheres very firmly to the fleshy fibres. 3. Dissect the humeral insertion very carefully, and at the same time prepare the teres major, which is very intimately related to this extremity.

The Latissimus Dorsi.

The *latissimus dorsi* (*b*, *fig.* 106, *p*, *figs.* 109, 110) occupies the lumbar and part of the dorsal region, and the posterior border of the axilla. It is the broadest of all the muscles, and shaped like a triangle, having its inferior angle truncated, and its upper and external angles considerably elongated.

Attachments.—It *arises* from the spinous processes of the last six or seven dorsal, of all the lumbar, and of the sacral vertebræ, from the posterior third of the crest of the ilium, and from the last four ribs, and is *inserted* into the bottom of the bicipital groove of the humerus, not into its posterior border.

Its origin from the crest of the ilium and from the vertebræ is effected through the medium of a triangular aponeurosis, narrow and thin above, broad and very strong below, where it is blended with the aponeuroses of the serratus posticus inferior and obliquus internus abdominis, and with the posterior layer of the aponeurosis of the transversus abdominis. This aponeurosis assists in forming the sheath of the sacro-lumbalis, longissimus dorsi, and transverso-spinalis. The costal origins consist of fleshy tongues or digitations, which are interposed between similar processes of the external oblique. From this threefold origin the fleshy fibres proceed in the following manner: the upper pass horizontally, the middle are directed obliquely, and the lower vertically upward; they all converge, so as to form a thick fasciculus, directed towards the inferior angle of the scapula, from which it often receives some accessory fibres. The muscle is then twisted upon itself, so that the inferior or vertical fibres become first anterior and then superior, while the superior or horizontal fibres become first posterior and then inferior. This torsion may perhaps be intended to prevent displacement of the fibres. They all terminate in a flat quadrilateral tendon, which is inserted into the bottom of the bicipital groove, above the insertion of the tendon of the pectoralis major. This tendon furnishes a fibrous expansion continuous with the fascia of the arm, and also a band which extends to the lesser tuberosity of the humerus.

Relations.—This muscle is covered by the skin (from which it is separated by a closely-adherent fibro-cellular sheath), and by the inferior angle of the trapezius. It covers the posterior spinal muscles, the serratus posticus inferior, the external intercostals, the serratus magnus, the lower angle of the scapula, the rhomboideus, and, lastly, the teres major, by which muscle it is itself covered in its turn. Its external margin is in relation with the posterior border of the external oblique, from which it is separated below by a small triangular interval. The upper part of the external margin, together with the teres major, forms the posterior border of the axilla; and from the same margin a muscular fasciculus occasionally extends beneath the axilla to the lower edge of the pectoralis major.

The Teres Major.

This muscle (*c c, fig.* 106), which, both in its uses and its anatomical arrangements, should be considered an accessory to the latissimus dorsi, is situated behind the shoulder.

Attachments.—It *arises* from the quadrilateral surface, situated at the inferior angle of the scapula, to the outer side of the infra-spinous fossa, and is inserted into the posterior border of the bicipital groove. The scapular attachment consists of short tendinous fibres, some of which are fixed directly to the bone, and some into the fasciæ, which separate this muscle from those of the infra-spinous and subscapular fossæ. The fleshy fibres arising from these different attachments form a thick fasciculus, flattened from before backward, not cylindrical, and about two or three fingers in breadth, which is *directed* outward and upward, and becomes slightly twisted, so as to be inserted by a broad and flat tendon into the posterior border of the bicipital groove.

Relations.—The latissimus dorsi at first covers its scapular extremity, and then, turning round its lower edge, becomes anterior to it. The tendon of the latissimus dorsi is, therefore, applied to the anterior surface of the tendon of the teres major; but since the former is attached to the bottom, and sometimes even to the anterior border of the bicipital groove, and the latter to the posterior border of the same groove, they are separated at their insertions by an interval, in which there is almost always a synovial membrane, and which forms a true cul-de-sac below, for the lower margins of the two tendons are blended together.

The posterior surface of the teres major is covered by the skin, from which it is separated on the inside by the latissimus dorsi, and externally by the long head of the triceps. Its anterior surface is in relation with the subscapularis, the coraco-brachialis, the short head of the biceps, the brachial plexus, the axillary vessels, and the cellular tissue of the axilla. Its upper margin is at first in contact with the teres minor, from which it is separated above by the long head of the triceps; its lower margin forms, in conjunction with the latissimus dorsi, the posterior border of the axilla.

Action of the Latissimus Dorsi and Teres Major.—The latissimus dorsi adducts the arm, rotates it inward, and at the same time draws it backward (hence its name, *ani scalptor*). When only the upper or horizontal fibres contract, the arm is carried inward and backward; when the lower fibres act alone, it is carried downward.

The uses of the teres major are precisely similar to those of the latissimus dorsi, to which it is congenerous and accessory, and with which it is always associated in action, drawing the humerus inward, backward, and downward. When the humerus is the fixed point, the latissimus dorsi raises the trunk, and with the greater facility, because it is attached to the ribs, the spine, and the pelvis. In consequence of its costal attachments, the latissimus dorsi is a muscle of inspiration; and it should be observed, that the direction of its fibres, which is almost perpendicular to the ribs, enables it to act with great power.

The Rhomboideus.

Dissection.—Divide the trapezius by an incision extending from the third dorsal vertebra to the lower angle of the scapula: dissect back the flaps, taking care to remove a fibro-cellular layer which adheres closely to the trapezius.

The *rhomboideus* (*d d, fig.* 106), situated in the dorsal region, on the posterior aspect of the trunk, approaches closely to the form of a rhomboid or lozenge; it is broad and thin, but thicker below than above, and is almost always divided into two parts.

Attachments.—It *arises* from the bottom of the ligamentum nuchæ, from the spinous processes of the seventh cervical and five superior dorsal vertebræ, and from the corresponding interspinous ligaments, and is *inserted* into all that part of the posterior costa of the scapula situated below its spine. The *spinal* or internal attachments consist of tendinous fibres, the most inferior of which are the longest. From these points the fleshy fibres proceed, parallel to each other, downward and outward, to a very thin tendon, which runs along the posterior costa of the scapula, but only adheres to it above and below: the greater number of fibres are inserted into the lower angle of the scapula by a very strong tendon, which forms the principal attachment of the muscle, and to which the tendon mentioned above is merely subordinate. The upper part of this muscle (*e, fig.* 103), which arises from the ligamentum nuchæ and the seventh cervical vertebra, is inserted by itself opposite the spine of the scapula. It is distinct from the remainder of the muscle, and from this fact Vesalius, Albinus, and Sœmmering gave it the name of *rhomboideus minor* or *superior*.

Relations.—This muscle is covered by the trapezius, the latissimus dorsi, and the skin. It covers the serratus posticus superior, part of the posterior spinal muscles, the ribs, and the intercostal muscles.

Action.—The rhomboid raises the scapula and draws it inward. As it acts principally upon the lower angle of that bone, it rotates it in such a manner that the anterior angle, and, consequently, the apex of the shoulder, is depressed. It assists the trapezius in carrying the entire shoulder inward, and is also associated with the upper fibres

of the same muscle in raising that part; but, on the other hand, it antagonizes the trapezius by depressing the apex of the shoulder.

The Levator Anguli Scapulæ.

Dissection.—Detach the trapezius from the spine of the scapula with care; divide the upper part of the sterno-mastoid, so as to expose the transverse processes of the three or four superior cervical vertebræ.

The *levator anguli scapulæ* (levator scapulæ, *Albinus, f, figs.* 106, 110, 113, 114), *situated* at the posterior and lateral part of the neck, is an elongated bundle, having its upper portion flattened from without inward, and divided into three or four fasciculi, while the lower part is flattened from behind forward.

Attachments.—It *arises* from the posterior tubercles of the transverse processes of the three or four superior cervical vertebræ, externally to the splenius, and behind the scalenus posticus; it is *inserted* into the superior angle of the scapula (whence its name), and into all that portion of its internal costa situated above the spine.

The cervical attachments of this muscle consist of four tendons, to which succeed an equal number of fleshy fasciculi, at first distinct, but afterward united into one bundle, which proceeds downward, backward, and outward, and spreads out to be inserted into the scapula by short aponeurotic fibres.

Relations.—It is covered by the trapezius, the sterno-mastoid, and the skin; and it lies superficially to the splenius, the sacro-lumbalis, the transversalis colli, and the serratis posticus superior.

Action.—When its upper attachment is fixed, this muscle carries the posterior angle of the scapula upward and forward, and, consequently, rotates that bone, so as to depress the apex of the shoulder. It conspires with the rhomboid and the trapezius in elevating the entire shoulder, and with the rhomboid in depressing its apex, in this respect acting as an antagonist to the trapezius. When the fixed point is below, which must be very rarely, it inclines the neck backward and to its own side.

The Serrati Postici.

These are two in number, a superior and an inferior.

Dissection.—1. To expose the *superior* muscle, divide and reflect the trapezius and the rhomboid, and draw the scapula forward; 2. To display the *inferior*, raise the latissimus dorsi with great care, as its deep aponeurosis is blended with that of the serratus posticus inferior; 3. Preserve the thin aponeurosis extending between the two serrati muscles.*

1. The *serratus posticus superior* is *situated* at the upper and back part of the thorax, and is of an irregularly-quadrilateral figure.

Attachments.—It *arises* from the ligamentum nuchæ and the spinous processes of the seventh cervical and of the two or three upper dorsal vertebræ, and is *inserted* into the upper borders of the second, third, fourth, and fifth ribs. The vertebral attachment consists of a very thin aponeurosis, the fibres of which are parallel, and inclined downward and outward. From this aponeurosis, which constitutes at least the inner half of the muscle, the fleshy fibres proceed in the same direction, and almost immediately divide into four digitations, which are inserted into the ribs by means of short tendinous fibres. The superior digitation is attached near the angle of the corresponding rib, and each of the others at successively greater distances from it.

2. The *serratus posticus inferior* (lumbo-costalis, *Chaussier, g, fig.* 106) is also of an irregularly-quadrilateral form, and is situated at the lower part of the back and the upper part of the loins. It *arises* from the spinous processes of the two lower dorsal and three upper lumbar vertebræ, and is *inserted* into the inferior borders of the last four ribs. The vertebral or internal attachment consists of an aponeurosis similar to that of the preceding muscle, but its fibres have an inverse direction, *i. e.*, obliquely outward and upward. From this aponeurosis, which forms the internal half of the muscle, the fleshy fibres proceed in the same direction, and divide into four flat digitations, progressively decreasing in size from above downward, which are inserted into the ribs by means of tendinous laminæ, the superior digitation near the angle of its corresponding rib, and the others, successively, farther beyond it.

Relations.—These two muscles have certain relations in common, and there are some peculiar to each. They both cover the longissimus dorsi, the sacro-lumbalis, the transverso-spinalis, the ribs, and the corresponding intercostal muscles. The superior is covered by the rhomboideus, the trapezius, and the serratus magnus, and covers the splenius and transversalis colli. The inferior is covered by the latissimus dorsi, with the aponeurosis of which muscle its own aponeurotic lamina is so closely united that it is impossible to separate them completely; and it covers the posterior layer of the aponeurosis of the transversalis.

Action.—Besides certain common uses, each muscle has its own peculiar action. One

* [This exceedingly thin and semi-transparent lamella has received the name of the *vertebral aponeurosis.* See APONEUROLOGY.]

important common use is, to retain in the vertebral groove those muscles of the back which, from their extreme length, are the most liable to displacement. This effect is produced by their fleshy portions rendering tense their aponeurotic expansions.

With regard to the actions proper to each, 1. The superior elevates those ribs into which it is inserted, and is, consequently, a muscle of inspiration; 2. The inferior, on the other hand, is a depressor of the ribs, and, therefore, a muscle of expiration.

The Splenius.

Dissection.—Merely remove the trapezius, the rhomboid, and the serratus posticus superior.

The *splenius* (*i, figs.* 106, 113, 114), so named because it has been compared to the spleen (σπλὴν), is *situated* at the posterior part of the neck and upper part of the back. It is a broad muscle, terminating in a point below, and dividing into two portions above.

Attachments.—It *arises* from the spinous processes of the four or five superior dorsal and the seventh cervical vertebræ, from the corresponding supra-spinous ligaments, and also from the ligamentum nuchæ, between the seventh and the third cervical vertebræ; it is *inserted*, 1. Into the transverse processes of the first, second, and often the third cervical vertebræ; 2. Into the external surface and posterior border of the mastoid process, and the external third of the rough space beneath the superior semicircular line of the occipital bone. The spinal attachments consist of tendinous fibres, the most inferior of which are the longest. From these the fleshy fibres proceed obliquely upward and outward, the lower being longer and more vertical, and form a broad, flat muscle, which is much thicker externally, and soon becomes divided into two portions: one smaller, inferior and external; the other much larger, superior and internal. The former is called the splenius colli; it is sometimes distinct, even from its origin, and soon subdivides into two or three fasciculi, which terminate in as many tendinous processes, that are inserted into the atlas, the axis, and often into the third cervical vertebra. The fasciculus proceeding to the atlas is usually the largest. The second, or the upper and internal portion of the muscle, is connected with the head, and is called the *splenius capitis.*

Relations.—The splenius is covered by the trapezius (the rhomboid and the serratus posticus superior intervening below), by the sterno-mastoid, and by the levator anguli scapulæ. It covers the complexus, the longissimus dorsi, the transversalis colli, and the trachelo-mastoid. The levator anguli scapulæ is in contact with its outer border, and rests upon it above, the cervical insertions of the two muscles being blended together; below they are separated by the transversalis colli and sacro-lumbalis. The internal edge is very thin, and separated from the muscle of the opposite side by a triangular interval, in which the complexi are visible.

Actions.—The splenius extends the head, inclines it to its own side, and rotates it so that the face is turned to the same side. This action of the splenius depends on its attachments to the occipital bone, the mastoid process, and the atlas. By its insertions into the second and third cervical vertebræ it tends to rotate these in the same direction. When the two muscles act together, the head is drawn directly backward. The splenius is therefore an *extensor* and *rotator* of the head and of the neck; it assists in supporting the head in the erect position, and prevents it from inclining forward in obedience to the force of gravity.

The Posterior Spinal Muscles.

As these muscles are arranged in a peculiar manner, we shall adopt a method of description in some measure different from that which we have elsewhere employed.

The posterior spinal, or long muscles of the back (see *fig.* 107), are three in number, viz., the *sacro-lumbalis*, the *longissimus dorsi*, and the *transverso-spinalis muscle.*

These three muscles, which extend the entire length of the spine, form a very large muscular mass, completely filling up the corresponding vertebral groove. This mass is small at the lower part of the sacral groove, becomes much enlarged in the loins, then diminishes in the back, and again acquires a considerable size in the neck. Chaussier has given a description of them under the collective name of the *sacro-spinal* muscle; and they have also been denominated the *erector spinæ.*

I shall describe the three muscles together; but, in order to adopt some arrangement in a matter so complicated, I shall divide them into three portions, viz., a lumbro-sacral, a thoracic, and a cervical.

Lumbro-sacral Portion of the Posterior Spinal Muscles.

Dissection.—1. Render this portion of the muscle tense, by placing a block under the abdomen. 2. Divide by a vertical incision the trapezius, splenius, rhomboideus, latissimus dorsi, and serrati postici; reflect the divided portions inward and outward. A young subject, from ten to twelve years of age, is best adapted for the study of these muscles, from the facility with which the different fasciculi may be separated. For the same reason, one that is much infiltrated with serum is preferable to one in which the parts are dry.

The lumbo-sacral portion is usually called the *common mass of the sacro-lumbalis and longissimus dorsi*. It forms the fleshy part of the loins, and is called the *fillet* in the lower animals: it is the most highly developed in man, in whom it exerts a constant and powerful action during the erect posture: it appears to be the common origin of the posterior spinal muscles, whence the name of *common mass:* it fills up entirely the lumbo-sacral groove, and even projects backward and laterally in robust subjects.

It is of small size in the sacral region, is much enlarged at the middle of the lumbar region, at the upper part of which it again diminishes, so as to resemble two cones united by their bases.

Attachments. — The common mass *arises* from the whole extent of the sacro-iliac groove, and from the anterior surface and external border of an extremely strong aponeurosis, formed of parallel vertical fibres, and strengthened by a superficial layer directed obliquely. This *aponeurosis of origin for the posterior spinal muscles* (*d*, *fig.* 107) is inserted *on the inside* to the sacral ridge, to the summits of the spinous processes of the lumbar and three lower dorsal vertebræ, and to the corresponding supra-spinous ligaments: *on the outside*, to the series of eminences representing the transverse processes of the sacral vertebræ, and to the back part of the crest of the ilium: it gives attachment to many of the fibres of the glutæus maximus. It is short on the outside, and very long on the inside, reaching in the latter direction to the middle of the dorsal region, under the form of parallel and regular bands (*d*, *fig.* 107).

Arising from these different origins, the common mass appears at first extremely simple in its composition, consisting of fibres passing vertically upward. But if the aponeurosis be detached from its spinal insertions, and turned outward, it will be seen that the common mass is essentially composed of two portions: one internal and anterior, the *lumbo-sacral portion of the transverso-spinalis*; and the other external and posterior, the *lumbo sacral portion of the sacro-lumbalis and longissimus dorsi.*

1. The *lumbo-sacral portion of the transverso-spinalis** occupies all the sacral groove, and that part of the lumbar groove situated within the articular processes. It is perfectly distinct in the loins, being separated from the common mass by loose cellular tissue traversed by vessels and nerves. It *arises* from the *articular processes* of the lumbar vertebræ by flat tendons, directed obliquely inward and upward, and terminating upon the posterior surface of the muscle: by the union of their contiguous edges an aponeurosis is formed, which is itself blended along one of its borders with the deep surface of the common aponeurosis of origin. From these tendons the fleshy fibres arise, and having united into bundles, terminate by other tendons at the spinous processes of the vertebræ above. In the sacral region this portion of the transverso-spinalis is less distinct, but it may be easily seen that it occupies the whole of the sacral groove, and that the corresponding portion of the aponeurosis of origin affords attachments to it alone.

Fig. 107.

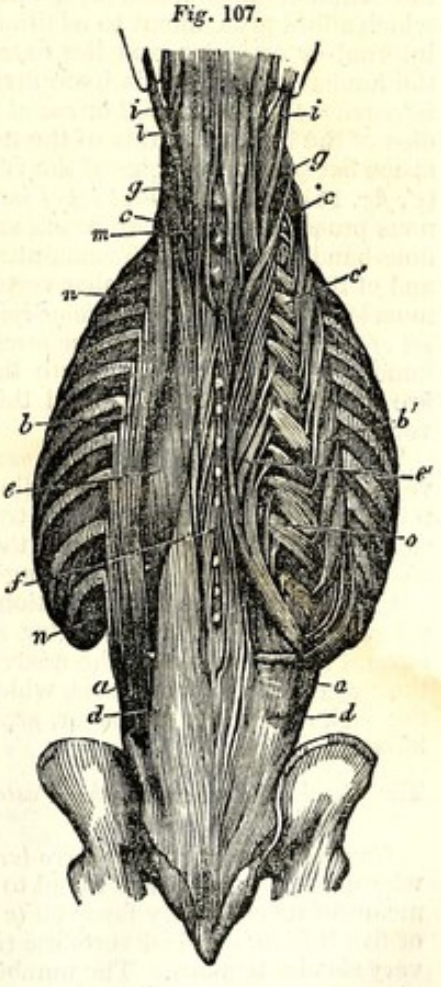

2. The external and posterior portion of the common mass, or *lumbo-sacral portion of the sacro-lumbalis and longissimus dorsi*, is entirely without the sacral groove, but occupies that part of the lumbar groove situated on the outer side of the articular processes.

It *arises*, 1. From all the lumbar portion of the common aponeurosis. 2. From an extremely strong tendon, which is attached to the posterior superior spinous process of the ilium. 3. From the posterior fourth of the crest of the ilium, internally by tendinous, and externally by muscular fibres. The thick fleshy mass proceeding from these different origins is disposed of in the following manner: the greater part of the fibres pass directly upward to the dorsal region, forming the proper commencement of the sacro-lumbalis (*a a*, *fig.* 107). The remaining fibres are directed forward, and are arranged into two sets of bundles, one of which is inserted into the summits of the transverse processes, forming the *external* or *transverse* fasciculi; and the other into the tubercles of the articular processes, forming the *internal* or *articular* fasciculi. These two sets of fibres constitute the proper origin of the *longissimus dorsi* (*d d*, *fig.* 107).

Relations.—The common mass is covered behind

* [This corresponds to the inferior or lumbo-sacral fasciculi of the multifidus spinæ.]

by the united aponeuroses of the latissimus dorsi and serratus posticus inferior, and by the posterior layer of the aponeurosis of the transversalis; in front, it corresponds to the lumbar groove, the inter-transversales muscles of the loins, and the middle layer of the aponeurosis of the transversalis, which separates it from the quadratus lumborum; on the inside, it corresponds to the spinous processes; and on the outside, to the angle of union between the posterior and middle layers of the aponeurosis of the transversalis. In this way it is completely enclosed in an osteo-fibrous sheath.

Thoracic Portion of the Posterior Spinal Muscles.

The transverso-spinalis muscle may be completely isolated from the others in this region. We have seen the distinction between the sacro-lumbalis and longissimus dorsi commenced at the upper part of the lumbar region; in the back they are completely separated by some loose cellular tissue and the posterior branches of the dorsal nerves and vessels.

The *thoracic portion of the sacro-lumbalis* (*b b'*, *fig.* 107) consists of a continuation of the vertical or external fibres of the common mass; as it proceeds upward it becomes more and more slender, and is divided into a series of fasciculi, which are inserted successively into the angles of the ribs, by means of tendinous prolongations, that extend for a considerable distance upon the posterior surface of the muscle. It was the existence of these aponeurotic processes, the contiguous edges of which are often united, that induced Winslow to compare the muscle to a palm leaf. In this manner the muscular fasciculi are soon expended, terminating at about the sixth rib, but the muscle itself is continued into the neck by means of *accessory fibres*, which may be exposed by turning the muscle outward, after separating it from the longissimus dorsi (as at *b'*): twelve long, thin tendons will then be seen to arise from the upper portion of the angles of the twelve ribs, and to pass outward and upward: to these succeed fleshy fasciculi, which terminate in aponeurotic processes, situated on their posterior surfaces, and having precisely the opposite direction. These accessory bundles (*c c'*, *fig.* 107; *i*, *fig.* 108) have been very well described by Diemerbroëk under the name of *cervicales descendens*, and by Steno under that of *musculus accessorius ad sacro-lumbalem*; the four or five superior bundles form the *transversaire grêle* of Winslow, and the *cervicalis descendens* of Albinus.

The *thoracic portion of the longissimus dorsi* (*e e'*, *fig.* 107) is larger than the preceding muscle, to the inner side of which it is situated: it diminishes much less rapidly, because the common aponeurosis (*d*) is extended in the form of bands upon its posterior aspect, which afford attachment to additional fleshy fibres. This muscle is a continuation of the internal or articular, and the external or transverse fasciculi, described as existing in the lumbar region, and is itself divided into three orders of fasciculi, one *external* and two *internal*. 1. The *external* or *costal* fasciculi form the continuation of the transverse bundles of the lumbar portion of the muscle, and are inserted by very thin tendons into the space between the angles of the ribs and the summits of the dorsal transverse processes (*e'*, *fig.* 107). 2. The *first set of internal*, or *the spinous fasciculi*, are inserted into the spinous processes of the five or six superior dorsal vertebræ; and as they arise from tendinous bands attached to the summits of the spinous processes of the lower dorsal vertebræ, and of that of the first lumbar vertebra, Winslow considered them as forming a separate muscle, which he called *le long épineux du dos* (spinalis dorsi, *f*, *fig.* 107). 3. The *second set of internal*, or *the transverse fasciculi*, are a continuation of the articular fasciculi of the lumbar region; they constitute the principal termination of the longissimus dorsi, and are attached by very long and thin tendons to the transverse processes of the dorsal vertebræ.

The *thoracic portion of the transverso-spinalis** (partly seen in *fig.* 108) is reduced to a very narrow band, concealed by the longissimus dorsi: it *arises* by very long and delicate tendons from the lower dorsal transverse processes, and is *inserted* by others equally similar, long and slender, into the summits of the superior dorsal spinous processes, some pale fleshy fibres connecting the two series of tendons.

Connexions.—The dorsal portion of the posterior spinal muscles entirely fills the dorsal groove, limited on the outer side of the angles of the ribs. They are covered by several muscular layers, the nearest of which is formed by the two serrati postici and their connecting aponeurosis, which completes the sheath enclosing the long muscles of the back: they are, moreover, separated from the skin by the rhomboid, trapezius, and latissimus dorsi.

The Cervical Portion of the Posterior Spinal Muscles, the Transversalis Colli, and the Trachelo-mastoideus.

Cervical portion of the sacro-lumbalis, or *cervicalis descendens*. The sacro-lumbalis, whose original fibres are found to terminate at and upon the sixth rib, is continued, by means of its accessory fasciculi (*c c'*, *fig.* 107), up to the transverse processes of the four or five inferior cervical vertebræ (*i*, *fig.* 108), into the summits of which it is inserted by very slender tendons. The number of these terminating fasciculi varies in a remarkable

* [This corresponds to the semi-spinalis dorsi, and to the dorsal portion of the multifidus spinæ of Albinus.]

manner. Indeed, the splenius, the transversalis colli, the sacro-lumbalis, and even the levator anguli scapulæ, are so closely connected, that, upon examining their cervical insertions only, these might all be ascribed to a single muscle. The cervical portion of the sacro-lumbalis is covered by the levator anguli scapulæ, and can only be exposed by turning this muscle outward.

The *cervical portion of the longissimus dorsi*, or the *transversalis colli*, and the *trachelo-mastoid*. The extent of the longissimus dorsi is limited to the back; its highest internal or spinous fasciculus seldom reaches the spinous process of the first dorsal vertebra: its highest external or costal fasciculus is attached to the second, sometimes even to the fourth rib, and its highest transverse fasciculus is inserted into the transverse process of the first dorsal vertebra. In some very rare cases, a few internal fasciculi reach the cervical vertebræ: I have seen one of them terminate by becoming attached both to the transverse process of the third cervical vertebra and to the complexus. The longissimus dorsi is, however, prolonged by accessory fasciculi as far as the third cervical vertebra. These fasciculi can only be identified by their direction (for they can never be completely separated from this muscle): they form a distinct muscle, known as the *transversalis colli* (transversalis cervicis, *Albinus*, *g g*, *fig.* 107).

By reflecting outward the upper part of the longissimus dorsi, they may be exposed, varying in number, and arising from the summits of the transverse processes of the third, fourth, fifth, sixth, and sometimes seventh and eighth dorsal vertebræ, by long, thin tendons, and inserted by other tendons into the posterior tubercles of the transverse processes of the five inferior cervical vertebræ (*l*, *fig.* 108): the transversalis colli is covered by the longissimus dorsi, the splenius, and levator anguli scapulæ, and rests upon the trachelo-mastoid and complexus.

The *trachelo-mastoideus* (complexus minor, *i i*, *fig.* 107) may be regarded as another accessory muscle to the longissimus dorsi, which it continues up to the head. In order to expose its origin, the transversalis colli must be reflected outward (as in *fig.* 107). It *arises* from the angles between the transverse and articular processes of the four inferior cervical vertebræ, by four small tendons, or sometimes by a continuous aponeurotic plane. From thence the fibres proceed upward, and form a small muscle, which is inserted into the mastoid process, in a small furrow to the inside of the digastric groove. This small muscle is almost always interrupted by a tendinous intersection near its mastoid insertion.

The *cervical portion of the transverso-spinalis*.* While the preceding muscles present only a few fasciculi in the neck, the transverso-spinalis† undergoes an enlargement in this region, so as to occupy the entire cervical groove (*a* and *b*, *fig.* 108). In carnivora, this portion of the muscle is enormously developed (much more so than in man), in consequence of those animals using the head and neck in seizing or struggling with prey. In mammalia, as in man, the dorsal portion of the transverso-spinalis is, as it were, but a rudiment in the lumbo-sacral region; the muscle is larger in man than in other animals, on account of his erect posture. Albinus described the enlarged cervical portion as a separate muscle, viz., the *spinalis cervicis*.

In the neck, as in the other regions, the transverso-spinalis is a collection of superimposed fasciculi, which *arise* from the transverse processes of the five or six upper dorsal, and from the articular processes of the five lower cervical vertebræ, and are *inserted* into the spinous processes of the six lower cervical vertebræ: the highest and the largest fasciculus is attached to the axis. This muscle, which would have been much better named *articulo-spinalis*, is composed of several layers of fasciculi, placed one above the other, and extending from the whole length of the articular processes and laminæ of the vertebræ below to the whole length of the spinous processes and laminæ of the vertebræ above. The length of these layers diminishes progressively from the more superficial (*a*, *fig.* 108) to the deep-seated ones (*b*); the latter extend only from one vertebral lamina to another, and might be considered as proper muscles of the laminæ, and not as a part of the transverso-spinalis muscle. The most superficial layer is composed of radiating fasciculi, diverging from one articular process to the summits of several of the spinous processes.

The Complexus.

Dissection.—Divide the splenius perpendicularly to the direction of its fibres, and reflect the two parts upward and downward; turn outward the upper portions of the longissimus dorsi, the transversalis colli, and the trachelo-mastoid (see *fig.* 107).

The *complexus* (*l*, *fig.* 107) is situated beneath the splenius at the posterior part of the neck and upper part of the back. It is a flat muscle, broad above, but terminating in a point below.

Attachments.—It *arises*, 1. From the transverse processes of the five or six superior

* If we were to follow the order of super-imposition rigorously, the complexus should be described before this muscle, which cannot be brought into view until the former is removed.

† [This portion of the transverso-spinalis corresponds to the semi-spinalis colli (*a*, *fig.* 108), and the cervical fasciculi (*b*) of the multifidus spinæ of Albinus.]

dorsal vertebræ; 2. From the articular tubercles and the angular depression formed between them and the transverse processes of the four inferior cervical vertebræ; 3. Sometimes from the spinous processes of the seventh cervical and two upper dorsal vertebræ: it is *inserted* upon the side of the external occipital crest into the inner half of the rough space comprised between the two semicircular lines. The origins of this muscle consist of tendons, from which the inferior fleshy fibres pass vertically upward, the superior ones obliquely inward and upward, becoming gradually shorter and more nearly horizontal. The muscular fibres are interrupted by some very remarkable tendinous intersections. Thus, on the inside, the fleshy fasciculus arising from the sixth, fifth, and fourth dorsal vertebræ, gives origin to a tendon, which proceeds along the inner edge of the muscle, and, at the distance of an inch and a half or two inches, becomes the origin of another fleshy fasciculus, which is attached to the side of the occipital crest; hence the name of *biventer cervicis*, given by Eustachius to the whole complexus, and by Albinus to this inner portion only (*m*, *fig.* 107). More externally, there is another flat tendon extending along the posterior surface of the muscle, from the outer edge of which an aponeurotic intersection passes in a zigzag course obliquely outward and upward. It is not uncommon to find another small digastric fasciculus with a separate tendon, on the anterior surface of the muscle.

Relations.—The complexus is covered by the trapezius, splenius, longissimus dorsi, transversalis colli, and trachelo-mastoid, and covers the transverso-spinalis and the recti and obliqui capitis. Its inner edge is separated from the muscle of the opposite side by a considerable quantity of adipose tissue, and by a prolongation of the ligamentum nuchæ.

The Inter-spinales Colli.

The inter-spinales muscles are distinct in the neck only. It is generally admitted that there are five pairs, the first of which extends between the axis and the third cervical vertebra, and the last between the seventh cervical and first dorsal vertebræ. They are small quadilateral muscles, extending from one of the borders of the groove in the spinous process below to the corresponding lip of the next process above. Externally, they are in relation with the transverso-spinalis, and are separated from each other internally by cellular tissue and an aponeurotic lamina.

Fig. 108.

The Recti Capitis Postici, Major and Minor.

The *rectus capitis posticus major* (*e*, *fig.* 108) may be regarded as an *axoido-occipital*, and the *rectus minor* (*d*) as an *atloido-occipital inter-spinalis* muscle. They both *arise* tendinous, the smaller from the tubercle on the posterior arch of the atlas, and the greater from the superior tubercle of the spinous process of the axis (2); and, increasing in size, they both pass obliquely upward and outward. The rectus major, which is much the larger and more oblique, is *inserted* to the outer side of the inequalities situated below the inferior semicircular line of the occipital bone; the rectus minor is *inserted* to their inner side. The name of *recti* is not, therefore, very appropriate, for both of them (but more especially the larger one) are directed obliquely; but they are so called in contradistinction to two neighbouring muscles which are much more oblique. The obliquity of these muscles (by increasing their length) allows of more extended movements, and, at the same time, enables them to assist in rotating the head.

The Obliquus Capitis Major or Inferior, and Obliquus Minor or Superior.

The *obliquus major* or *inferior* (*f*, *fig.* 108), as far as its insertions are concerned, may be called the axoido-atloid spino-transversalis; it resembles, in fact, a thick fasciculus of the longissimus dorsi. The *obliquus minor* or *superior* (*g*) may, for the same reason, be called the atloido-occipital transverso-spinalis, resembling a thick fasciculus of that muscle. The *obliquus major* arises from the apex of the spinous process of the axis, on the outer side of the rectus major (*e*), and above the transverso-spinalis (*i. e.*, the semi-spinalis colli and multifidus spinæ conjoined, *a* and *b*); it forms a thick, cylindrical bundle, passes almost horizontally outward, and is *inserted* behind and below the transverse process of the atlas, which is excavated for this purpose. It is the axoido-atloideus of Chaussier. The *obliquus minor* (atloido-sub-mastoideus) *arises* by some very long tendinous fibres from the upper part of the transverse process of the atlas, proceeds at an angle of about 45° towards the occipital bone, into which it is *inserted* not far from the mastoid process, by some tendinous fibres, less distinctly marked than those of its origin.

From this difference of direction, it follows that the rectus major and the two obliqui form on each side an equilateral triangle; in the interval between the two triangles a considerable part of the recti minores is seen.

Relations.—The recti and obliqui capitis are covered behind by the complexus, from which they are separated by a very strong aponeurotic lamina and much cellular tissue;

they cover the posterior arch of the atlas, with the posterior ligaments of the atloido-occipital and atloido-axoid articulations.

General View of the Posterior Spinal Muscles.

After the preceding description, it will now be easy to comprehend the general guiding principles in the arrangement of the innumerable, and, at first sight, inextricable fasciculi which constitute the fleshy mass known by the general name of the posterior spinal muscles. We shall first recall to mind, that the levers to which all these muscles are ultimately attached are, 1. The row of spinous processes; 2. The row of articular processes; and, 3. The row formed by the transverse processes and the ribs, which, for many reasons, may be regarded as extensions of those processes.

We shall suppose these three series of levers, and therefore the several points of insertion, to be represented by three vertical lines.

We must remember, also, that the dorsal transverse processes are upon the same line as the lumbar and cervical articular processes, and that the ribs are upon the same line as the lumbar transverse processes and the anterior roots of the cervical transverse processes. (See OSTEOLOGY, p. 5.) These data being admitted, we can now reduce all the posterior spinal muscles into the four following orders of fasciculi, two being vertical and two oblique.

1. The *internal vertical* or *spinous* muscles, comprising the spinalis dorsi (*i. e.*, the internal and superficial portion of the longissimus dorsi), the inter-spinalis of the neck, and the recti postici of the head. 2. The *external vertical lateral*, or *transverse* muscles, connected with the transverse or costiform processes. They comprise the sacro-lumbalis and the inter-transversales, among which the quadratus lumborum may be included. 3. The *spino-transverse* and *spino-articular* oblique* muscles, including the longissimus dorsi, with its accessories, the transversalis colli and trachelo-mastoid, the splenius and the obliquus major. 4. The *transverso-spinous* and *articulo-spinous* oblique* muscles, viz., the transverso-spinalis, the complexus, and the obliquus capitis minor.

Action of the Posterior Spinal Muscles.

Having once established the general principles according to which the posterior spinal muscles are arranged, it is very easy to determine the mode of action of each, and to reduce to very simple elements a mechanism to all appearance so complicated.

1. The long and short spinous fasciculi being vertical, directly extend the vertebral column; such is the action of the spinalis dorsi and inter-spinalis colli; the recti capitis, at the same time that they extend the head, rotate it also to the side on which the muscles are acting. When the recti muscles of both sides act simultaneously, the head is drawn directly backward.

2. The fasciculi of the sacro-lumbalis being vertical and lateral, erect the vertebral column, and incline it to one side, when only one set of muscles acts; when both sets act together, they extend it directly backward.

3. As the fasciculi of the longissimus dorsi, belonging to the spino-transverse and spino-articular group, have their fulcra upon the spine, and are inserted into the articular and the transverse processes or ribs, they conspire in erecting the vertebral column, and keeping it in that position. But, from their obliquity, they produce a slight movement of rotation, those fibres which are attached to the articular processes having less effect than those connected with the transverse processes. In this movement, the front of the body is turned to the side on which the muscles are situated. When the muscles of both sides act together, the spine is extended directly backward. The splenius, which is the representative of the longissimus dorsi for the neck and head, acts in the same way, but with greater effect. Thus, by the contraction of the left splenius, the face is turned to the left side, and the head is drawn backward and to the right side. The obliquus inferior also acts in the same direction. When the two splenii and the two inferior oblique act together, the head is inclined directly backward.

4. The fixed insertions of the transverso-spinalis being at the articular or transverse processes, and their movable points at the spinous processes, besides the common effect of erecting the vertebral column, they are also able to rotate it, so that the anterior region of the trunk is turned to the opposite side. From its obliquity, this muscle is the principal rotator of the vertebral column. The complexus, which is its representative in the neck, acts upon the head in the same manner, but in a more remarkable degree. Thus, by the contraction of the complexus of the left side, the face is turned to the right side, and the head is inclined backward upon the left side, so that, in rotation, it acts in a precisely opposite direction to the splenius. When all these muscles act together, the trunk is simply drawn erect. The superior oblique assists the complexus in the movements of the head.

Lastly, we may now understand the successive actions which take place along the

* [The terms spino-transverse and spino-articular are applied to fasciculi passing *upward from* the spinous *to* the transverse and articular processes; transverso-spinous and articulo-spinous, to such as proceed *upward from* the transverse and articular *to* the spinous processes.]

whole extent of the posterior spinal muscles. The sacrum and the iliac bones furnish a fulcrum for the fasciculi which move the lumbar region: this latter being fixed, then becomes the fulcrum for those that move the dorsal region, and so on to the head, which alone has independent muscles. It is impossible to extend backward the dorsal region, and the lower part of the cervical, without at the same time erecting the lumbar region; but the head may be moved at will, independently of the vertebral column.

The posterior spinal muscles maintain in equilibrium the weight of the whole trunk; hence the lassitude experienced in the back, but especially in the loins, by long-continued standing, walking, or even sitting without a support to the back; and hence the relief afforded by the recumbent posture.

Rotation, we have seen, scarcely exists in the loins, the back, or the lower part of the neck; but at the upper part of the neck it is very extensive, and here the rotator muscles are proportionally strong, and directed very obliquely.

MUSCLES OF THE ANTERIOR ABDOMINAL REGION.

The Obliquus Externus Abdominis.—Obliquus Internus and Cremaster.—Transversalis Abdominis.—Rectus Abdominis.—Pyramidalis.

The muscles of the anterior abdominal region are, the *external oblique*, the *internal oblique*, the *transversalis*, the *rectus*, and, occasionally, the *pyramidalis*; being ten in the whole, five on each side.

The Obliquus Externus Abdominis.

Dissection.—1. Make an incision through the skin of the abdomen extending from the cartilage of the eighth rib obliquely downward and inward, dividing, at the same time, the very firm layer of cellular tissue which immediately covers the muscle. 2. During the preparation of this, as well as all the other abdominal muscles, place a block under the loins, and in the dissection follow exactly the direction of the muscular fibres.

The *great* or *external oblique* muscle of the abdomen (*o*, *fig.* 106, and *a*, *fig.* 109), so called from the direction of its fibres (obliquus descendens), forms the most superficial muscular layer of the abdominal parietes, on the sides and front of which it is situated: it is very broad, quadrilateral, and curved upon itself.

Fig. 109.

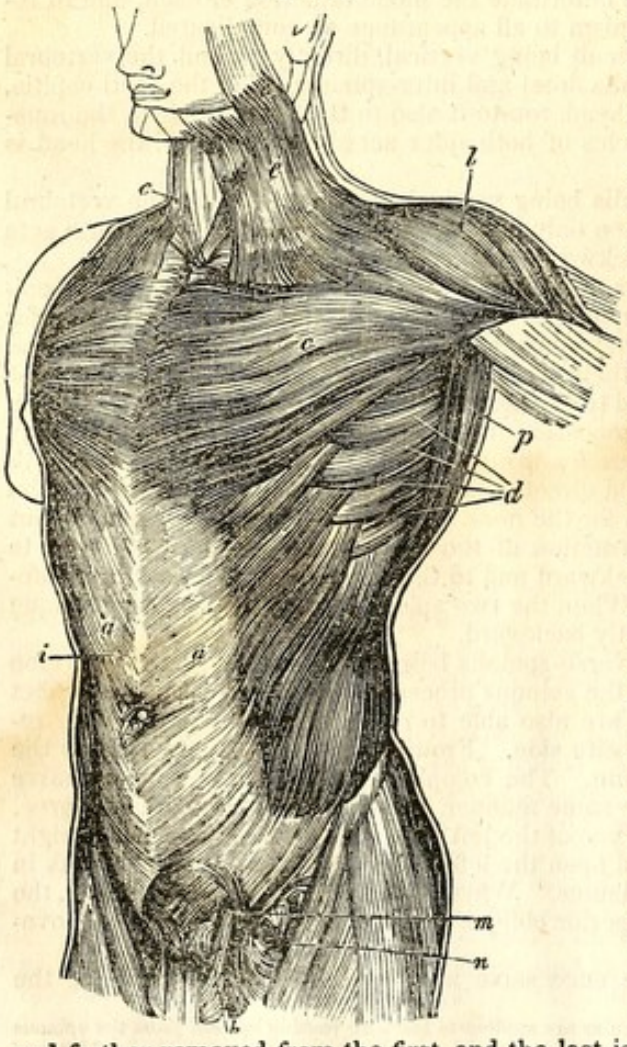

Attachments.—It *arises* from the external surfaces and lower borders of the seven or eight inferior ribs, and is *inserted* into the anterior half of the external lip of the crest of the ilium, into the external edge of the anterior abdominal aponeurosis, and by it into the linea alba. The upper or costal attachments consist of seven or eight angular tongues, or *digitations*, fleshy and tendinous in their structure, and arranged in an oblique line, running downward and backward.

These digitations increase in size from above downward, as far as the eighth rib, and then diminish to the twelfth. The four or five superior digitations are interposed, like the fingers of the two hands (whence the name), between similar prolongations of the serratus magnus. The three or four lower digitations between those of the latissimus dorsi, by which they are covered. This series of costal attachments constituting the upper edge of the muscle, represents a serrated curved line, the convexity of which is directed upward and backward.

The first digitation is attached close to the cartilage of the corresponding rib, the succeeding ones are farther and farther removed from the first, and the last is inserted into the apex of the cartilage of the last rib.

From these attachments the fleshy fibres proceed in different directions: the posterior pass nearly vertically downward, the middle obliquely downward and inward, and the upper almost horizontally inward; the posterior terminate by short tendinous fibres at the crest of the ilium; the anterior at the external concave edge of a broad aponeurosis, which forms the superficial layer of the anterior abdominal aponeurosis, and, by interlacing with the corresponding structure of the opposite side, concurs in forming the linea alba, and is folded upon itself below, to form the crural arch, or Poupart's ligament. (See APONEUROLOGY.)

It should be remarked, that the fibres of the external oblique follow exactly the same direction as those of the external intercostal muscles.

Relations.—The external oblique is covered by the skin, a considerable quantity of adipose tissue, and behind by a small portion of the latissimus dorsi. It covers the internal oblique, the anterior extremities, and the cartilages of the seven or eight inferior ribs, together with the corresponding external intercostal muscles. The most remarkable relation is that of its posterior border with the outer edge of the latissimus dorsi. Most commonly this border is covered by the latissimus dorsi; but sometimes a triangular space exists between them, which has been much noticed since Petit described a hernial protrusion in it, which he called lumbar hernia.

Action.—The external oblique performs a threefold action: 1. It compresses the abdominal viscera during any exertion, or in expulsion of the fæces, in labour, &c.; 2. It depresses the ribs, and thus indirectly flexes the vertebral column; 3. From its obliquity, it rotates the vertebral column, through the medium of the ribs, so that the fore part of the trunk is turned to the opposite side. When the two muscles act together, the thorax is inclined directly forward. Hitherto we have supposed that the movable point of the muscle is at the ribs; if, on the contrary, the thorax be fixed, it then draws the pelvis upward, and rotates the vertebral column, so that the fore part of the pelvis is turned to the same side as the contracting muscle.

The Obliquus Internus, and the Cremaster.

Dissection.—Divide the external oblique across the direction of its fibres, *i. e.*, downward and backward.

The *small* or *internal oblique of the abdomen* (obliquus ascendens, *p*, *fig.* 106, and *a*, *fig.* 110) is a broad, irregularly-quadrilateral muscle, much broader in front than behind, and smaller and thinner than the preceding. It occupies the anterior, lateral, and posterior parts of the abdomen.

Fig. 110.

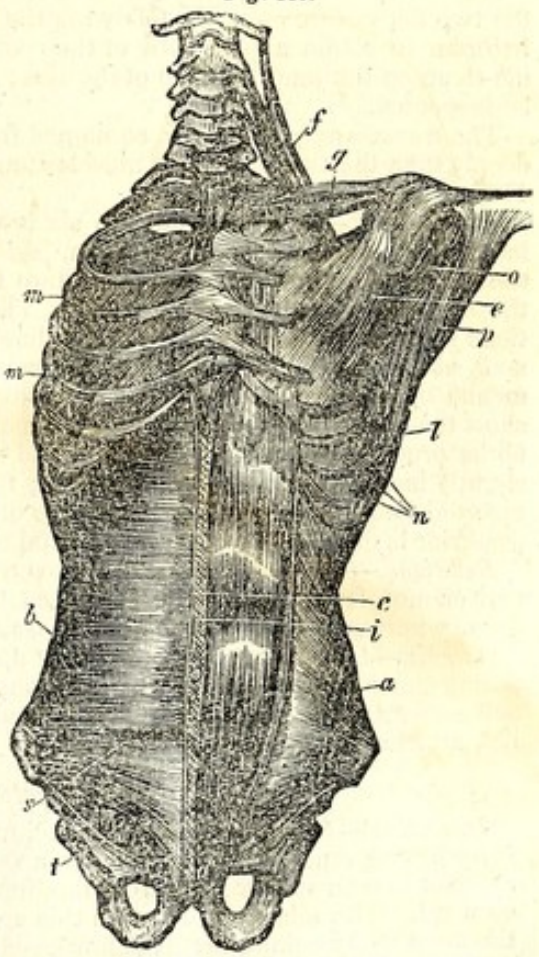

Attachments.—It *arises* from the spinous processes of the lumbar vertebræ, from the anterior three fourths of the interval between the borders of the iliac crest, and from the crural arch (Poupart's ligaments). It is *inserted* into the lower edges of the cartilages of the ninth, tenth, eleventh, and twelfth ribs, and into the linea alba by means of the middle layer of the anterior abdominal aponeurosis. The spinal fibres take their origin through the medium of the posterior abdominal aponeurosis: they are few in number. The iliac portion of them arise by very short tendinous fibres, and those which proceed from the crural arch arise from the sort of groove situated on its upper surface. From this threefold origin the fibres proceed in different directions: the posterior almost vertically upward; those which arise from the crest of the ilium obliquely upward and inward, becoming longer and more oblique anteriorly; those which proceed from near the anterior superior spinous process of the ilium are horizontal; and, lastly, those which arise from the crural arch pass obliquely downward and inward. The posterior fibres terminate at the lower edge of the cartilages of the four inferior ribs, and are continuous with the internal intercostal muscles, in the intervals between the tenth and eleventh and eleventh and twelfth ribs, indicating the analogy between these muscles. I have often observed the insertion into the last rib to be wanting. The middle fibres, which are the most numerous, terminate at the external

edge of the middle layer of the anterior abdominal aponeurosis. The fibres arising from the crural arch are few in number, pale, and fasciculated; some terminate at the pubes, passing behind the inguinal or external abdominal ring; others proceeding from the ring, in the male, form the cremaster muscle.

Relations.—It is covered by the external oblique, and behind by a small portion of the latissimus dorsi; and it lies superficially to the transversalis. The most important relations are those of its inferior edge with the inguinal ring of the external oblique, which it partly closes on the inner side, as Scarpa and Bichat have well pointed out, and with the spermatic cord, which passes beneath it, and, during the descent of the testicle, draws with it some of the lower fibres of the muscles; and hence the looped arrangement they assume.

The *cremaster*. The loops so well described by M. Jules Cloquet are very variable, and do not always appear to me to constitute the entire muscle. According to this anatomist, the cremaster is nothing more than the lower fibres of the internal oblique, that had been entangled with the testicle during its descent, forming loops in front of the cord, the concavity of which is directed upward, and which may be traced to the bottom of the scrotum. But I have often been convinced, from the examination of subjects in which the cremaster was much developed, that this muscle (*b*, *figs.* 109, 137) consists principally of a longitudinal fasciculus, partly derived, it is true, from the lower fibres of the internal oblique, but consisting partly, also, of proper fibres arising from the crural arch, near the external pillar of the ring; and that this fasciculus is lost upon the proper sheath of the cord, to which it is intimately united. The office of this muscle is to raise the entire testicle. The slow vermicular motion observed in the scrotum during the venereal orgasm, or from the action of cold, is not at all connected with it.

The *actions of the internal oblique* are, 1. Compression of the abdominal viscera; 2. Depression of the ribs, and, consequently, flexion of the trunk; 3. Rotation of the trunk, so that the fore part of the body is turned to the same side. The right internal oblique, therefore, co-operates with the left external oblique; when it acts with its fellow, the thorax is drawn directly towards the pelvis; but if the chest is fixed, they move the pelvis upon the loins.

The Transversalis Abdominis.

Dissection.—1. Make a horizontal section of the internal oblique; 2. Dissect with care the two flaps of this muscle, following the direction of the fibres of the transversalis; 3. In order to obtain a good view of the costal attachments, open the abdomen and examine them on the inner surface of the ribs; this may be omitted until the diaphragm is to be inspected.

The *transversalis abdominis*, so named from the direction of its fibres, is situated more deeply than the two preceding muscles, and, like them, is irregularly quadrilateral (*b*, *fig.* 110).

Attachments.—It *arises* from the six lower ribs, from the anterior three fourths of the internal lip of the crest of the ilium, and from the spinous and transverse processes of the lumbar vertebræ. It is *inserted* into the linea alba by means of the deep layer of the anterior abdominal aponeurosis. The costal attachments consist of fleshy digitations interposed between those of the diaphragm, the two muscles being actually continuous at the two inferior intercostal spaces; the vertebral attachments are effected by means of the posterior abdominal aponeurosis; and from the ilium it arises by very short tendinous fibres internally to the small oblique. From these three origins the fleshy fibres proceed parallel to each other and horizontally inward; the lower ones alone are slightly inclined downward and inward; the middle fibres are the longest. They are all inserted into the external convex edge of a tendinous expansion, which constitutes the posterior layer of the anterior abdominal aponeurosis.

Relations.—The transversalis is covered by the internal oblique, and rests upon the peritoneum, from which it is separated by a fibrous lamina, which is very distinct in front, where it is named the *fascia transversalis*.

Actions.—1. It acts more powerfully upon the abdominal viscera than any of the preceding muscles, compressing them strongly, like a girth, against the vertebral column, and assisting greatly in the process of defæcation. 2. It draws inward the rib to which it is attached, and thus materially assists in expiration.

The Rectus Abdominis.

Dissection.—1. The subject being laid upon its back, place a block under the loins; 2. After having removed the skin, make a vertical incision through the strong aponeurosis, at about two fingers' breadth from the linea alba; 3. Dissect off the two flaps inward and outward. The adhesions between this aponeurosis and the muscle are, however, so intimate at many points, that it is impossible to separate them.

The *rectus abdominis* (*c*, *fig.* 110) is *situated* at the anterior and middle part of the abdomen on each side of the linea alba, and occupies the space between the pubes and the cartilage of the fifth rib. It is flattened like a riband in front and behind; it is about

three or four fingers' breadth wide above, and only two below. Its breadth is generally in an inverse proportion to its thickness.

Attachments.—It *arises* from the upper edge of the os pubis, in the space between the spine and the symphysis; and is *inserted* in front of and below the cartilage of the seventh rib and costo-xiphoid ligament, to the cartilages of the fifth and sixth ribs, and sometimes to the bone also.

The pubic attachment is a flat tendon, consisting of two very distinct portions, of which the external is the larger. This tendon is continuous by its external border with the fascia transversalis. It is separated from its fellow of the opposite side by a very narrow and thick fibrous septum, which forms the lower part of the linea alba. Sometimes the internal tendinous fibres intersect with those of the opposite side in front of the symphysis pubes; and some fleshy fibres often arise from the sides of the linea alba. The presence or absence of the pyramidalis affects the size of the lower part of this muscle. From this tendinous origin the fleshy fibres proceed vertically upward (whence the name of *rectus*). At the upper part, where they are prolonged in an expanded form upon the thorax, they are slightly oblique from within outward, and divided into three unequal portions: the internal, the smallest, is attached to the cartilage of the seventh rib and to the costo-xiphoid ligament; the middle, which is larger, is fixed to the cartilage of the sixth rib; and the external, by far the largest, to the cartilage of the fifth rib. Very often a small portion of the muscle is inserted into the base and edges of the xiphoid cartilage, thus justifying the name of *sterno-pubien* given to it by Chaussier. It is not uncommon to find this muscle give off a fourth bundle to the fourth rib, and even an aponeurotic expansion to the sterno-cleido-mastoid. The rectus is interrupted by two, three, four, or five *tendinous intersections*, which pass transversely or obliquely across the muscle in a flexuous or zigzag course, seldom occupying either the entire thickness or width of the muscle, which they divide into so many smaller muscles. There are always more intersections above than below the umbilicus.

Relations.—This muscle is contained in a very strong tendinous sheath, which is formed by the anterior abdominal aponeurosis, is thicker in front than behind, much stronger below than above, and completely isolates the muscle. Below and behind, this sheath is deficient, in which situation the muscle (passing through the openings, *fig.* 110, in the aponeurosis of the transversalis) rests directly upon the peritoneum; the upper and posterior part of the sheath is also wanting, so that the muscle is in immediate contact with the cartilages of the fifth, sixth, seventh, eighth, and ninth ribs, and with the corresponding intercostal muscles. The linea alba occupies the interval between the two muscles, which is much larger above than below the umbilicus; but the most important of all the relations of the rectus is that of its posterior surface with the epigastric artery, which we shall hereafter notice.

Actions.—This muscle, having its fixed point below, and its movable attachments divided between the fifth, sixth, and seventh ribs, depresses the whole thorax, and, consequently, the vertebral column. Few muscles are so favourably situated as the rectus, which both acts upon a very long lever, and is inserted at right angles to the part to be moved.

As the rectus forms a curve, the convexity of which is directed forward, and cannot contract without becoming rectilinear, it follows that the first effect of its contraction is the compression of the abdominal viscera; hence it assists in expelling the contents of the bladder, rectum, and uterus; it aids in expiration, by depressing the ribs, and, by keeping them fixed when the thorax is dilated, it assists in the performance of any effort. When the fixed point is above, the rectus becomes a flexor of the pelvis.

What are the uses of the intersections? It is generally stated that their effect is to increase the number of fibres, and thereby augment the force of the muscle; and in support of this a principle is adduced, which is incontestable in itself, viz., that the power of a muscle is in a direct ratio to the number of its fibres; for if each fibre represent one partial power, the more of these the greater must be the total power. But it has been overlooked, that this law only applies to fibres arranged side by side, not to those which are placed end to end. In fact, it may be experimentally shown that, when two equal forces are applied to a lever, parallel to each other, they produce double the effect either would have done separately; but if one be made continuous with the other, and both are then applied to the same lever, they only produce an effect equal to that of either *per se*. These intersections, therefore, do not increase the power of the muscle; nor do they diminish the extent of motion, for the sum of the contractions of the small muscles into which they divide the recti is equal to that of an undivided muscle. What, then, are the uses of these intersections? Can it be intended, as Bertin has said, to associate the oblique muscles with the recti by means of the intimate adhesions existing between them and the aponeuroses?*

* Bertin considers these adhesions as true points of attachment for the muscles of the abdomen, so that when the rectus contracts, it acts not only upon the pubes, but also upon the crests of the ilia, through the medium of the abdominal aponeuroses. Professor Bérard, who brings forward this forgotten opinion of Bertin (*Répert. Génér. des Sc. Méd.*, art. ABDOMEN), correctly observes, that the obliquus internus only adheres to the rectus. In the same article M. Berard declares he is not satisfied that the intersections increase the power of the recti muscles.

The Pyramidalis.

The *pyramidalis* (*d*, *fig.* 110), a small triangular muscle which is often deficient, occupies the lower part of the abdomen on each side of the linea alba. It *arises* from the pubis and the anterior ligament of the symphysis by tendinous fibres, from which the fleshy portion proceeds upward, the internal fibres vertically, the external obliquely upward and inward, and terminates by a pointed extremity, which is attached to the linea alba, and forms the apex of the muscle, the base being at the os pubis. It is covered by the aponeuroses of the obliqui and transversalis muscles, and rests upon the rectus. The lower part of the rectus and the pyramidalis are united together. When the latter is wanting, the lower end of the rectus is proportionally increased in size, and *vice versâ*. There are sometimes two pyramidales on one side, and one on the other; sometimes the two are of unequal size. In a negro I found them extending beyond the middle of the space between the pubis and the umbilicus.

Action.—It is a tensor of the linea alba.

DIAPHRAGMATIC REGION.

The Diaphragm.

Dissection.—Description.—Attachments.—Relations.—Action.

Dissection.—In order to expose this muscle, it is necessary to open the abdomen and remove all the abdominal viscera, taking great care in detaching the liver, stomach, and kidneys. Tie the œsophagus and vena cava where they pass through the diaphragm, and cut them below the ligature. Raise the peritoneum with the fingers or forceps, and tear it gently away; thus exposing the lower surface of the muscle without using the scalpel. All the insertions of the diaphragm are well seen on this surface. In order to study the convex surface of the muscle, another subject should be provided, and the thorax opened before the abdomen. This is the only method by which a good idea of it can be obtained; for when the abdomen has been previously opened, the muscle becomes relaxed as soon as the thorax is cut into, and affords no idea of its naturally vaulted form.

The *diaphragm* (septum transversum, *a a*, *fig.* 111), which exists in mammalia only, is, according to the expression of Haller, with the exception of the heart, the most important muscle of the body. It is a muscular septum, *situated* obliquely at the junction of the upper with the two lower thirds of the trunk. It separates the thorax from the abdomen, constituting the floor of the former and the roof of the latter. All other muscles are placed on the outside of, or around, the levers which they are intended to move; but the diaphragm alone is situated within those levers, like the muscles of animals having an external skeleton.

Fig. 111.

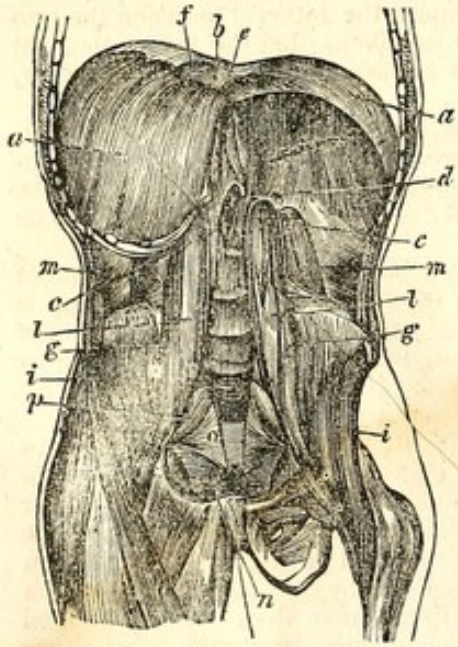

The diaphragm divides the body into two unequal parts: an upper, or *supra-diaphragmatic*; and a lower, or *infra-diaphragmatic*. It is placed on the median line, but is not symmetrical. It is elliptical in form, its longest diameter being from side to side, thin and flattened, and resembles an arch, or, rather, a fan, the broad and circular portion of which is horizontal, while the narrow part is vertical, and at right angles to the former. The older anatomists, therefore, divided it into two portions: the upper, or *great muscle of the diaphragm*; and the lower, or *small muscle of the diaphragm*.

Attachments.—It *arises* partly from the lumbar region of the vertebral column, in front of the bodies and intervertebral substances of the second, third, and fourth lumbar vertebræ; partly from the posterior surface of the sternum and the base of the ensiform cartilage; and partly from the posterior surface and upper edge of the cartilages and contiguous bony portions of the seventh, eighth, ninth, tenth, eleventh, and twelfth ribs. Sometimes it is attached also to the sixth rib.

The *vertebral origin* consists of two tendons, formed by several smaller vertical tendons, situated in front of each other, which are blended with the anterior common ligament of the spine. To these tendons two thick, fleshy bundles succeed, which pass vertically upward, become gradually thicker and broader, give off a fasciculus to each other, and are *inserted* into the posterior notch in the aponeurosis, having the form of a trefoil leaf, which forms the centre of the muscle, and is therefore called the *central aponeurosis of the diaphragm* (*b*, *fig.* 111), or *cordiform tendon*. These two fleshy bundles and their tendons (*c c*) are named the *pillars*, *crura*, or *appendices* of the diaphragm. The right crus

is anterior, larger, ...s lower down than the left. Each pillar is occasionally divided into two very ...t secondary pillars, and the trace of this division is always visible in the opening which gives passage to the great splanchnic nerve. The two pillars of the diaphragm leave between them an interval, divided into two portions or rings by the fleshy fasciculi which they mutually give to each other. The communicating fasciculus from the right pillar is anterior, and larger than that from the left. Of the two openings or rings between the pillars of the diaphragm, the *lower* or *aortic* (*d*) is parabolic, and gives passage to the aorta, the vena azygos, the thoracic duct, and sometimes, also, to the left great sympathetic nerve. Like all orifices through which arteries pass, it is aponeurotic in its structure, being formed by the tendons of the pillars of the diaphragm at the sides, and above by a fibrous prolongation of those tendons, which arches over and completes the ring: the *upper* or *œsophageal* opening (*e*) gives passage to the œsophagus and the pneumo-gastric nerves; it is elliptical, and altogether muscular. In one subject, however, I found the upper part tendinous; and in another, a small muscular fasciculus proceeded from the edge of the orifice, and was lost upon the coats of the œsophagus. Haller has twice observed the same peculiarity.

A fibrous prolongation proceeds outward from the tendon of each crus, and is fixed to the base of the corresponding transverse process of the first lumbar vertebra, so as to form an arch on each side (*fig.* 111), under which the upper end of the psoas muscle passes (*ligamentum arcuatum proprium*). Another aponeurotic arch, which has been improperly called ligamentum arcuatum (*ligament cintré du diaphragme*), for it is nothing more than the upper edge of the anterior layer of the aponeurosis of the transversalis muscle folded upon itself, extends from the outer extremity of the preceding arch to the lower border and apex of the last rib; under it passes the superior portion of the quadratus lumborum muscle (*fig.* 111). From both these arches muscular fibres pass forward, and are *inserted* into the corresponding part of the cordiform tendon. Indeed, the five tendinous arches which we have just described, viz., the aortic in the middle, and the two on each side for the psoas and quadratus lumborum muscles, give origin to all the fleshy fibres which terminate at the posterior notch of the central tendon of the diaphragm. The existence of these arches led Haller and Sœmmering to reckon three or four crura on each side. The cordiform tendon in which the preceding muscular fibres are inserted serves, in its turn, as the origin of other fibres, which constitute the vault of the diaphragm. This central aponeurosis (*b*), to which so much importance was attached by the ancients, under the name of the *phrenic centre*, and which some modern anatomists regard as the central point of the entire aponeurotic system of the human body, occupies the middle of the vault of the diaphragm, immediately below the pericardium, with which its circumference is blended in adults, but from which it may be easily separated in young subjects: it is a sort of aponeurotic island, surrounded on all sides by muscular fibres, and converting the diaphragm into a true digastric muscle. In form, it resembles a trefoil leaf, with a notch in the situation of the pedicle; each division is called a *wing* or *leaflet*; the middle leaflet is the largest, the right the next, and the left the smallest. Between the right and the middle leaflet is an opening (*f*), sometimes converted into a canal for the inferior vena cava. This orifice is entirely tendinous, and of a quadrangular shape when the vena cava is removed. It is bounded by four tendinous fasciculi, which meet at right angles. The cordiform tendon is itself composed of several planes of fibres; the principal of which consists of a diverging series, running forward, and uniting into irregular, straight, or curved bundles, which intersect each other at various angles; an arrangement that gives great strength to the tendon. The fleshy fibres are attached to all points of the circumference of this tendon, and radiate from it in all directions. The anterior, very short, and sometimes aponeurotic, proceed to the base of the ensiform cartilage, describing a slight curve, with the concavity directed downward. A triangular interval, or else several small spaces, are often left between these fibres, establishing a communication between the cellular tissue of the thorax and that of the abdomen. Hence, diaphragmatic herniæ occasionally occur; and pus, formed in the neck or mediastinum, may ultimately point at the epigastrium. It is not uncommon to find the sternal attachment of the diaphragm partially or entirely deficient.

The lateral muscular fibres, which are much longer than the anterior, describe very well-marked curves, and form an arch, with the concavity downward, but more convex and projecting on the right than the left side. They then divide into six or seven digitations on each side, which are attached to the ribs, intersecting with the costal insertions of the transversalis abdominis. It is not uncommon to find considerable intervals between the digitations of this muscle, opposite which the pleura and peritoneum are in contact: this more especially occurs between the eleventh and twelfth ribs. The fasciculus for the twelfth rib is sometimes deficient, its place being occupied by a tendon. The *direction* of the fibres of the diaphragm is then *radiated* and *curvilinear* in the horizontal portion, but *radiated* and *rectilinear* in the vertical portion.

Relations.—1. The *inferior* or *abdominal surface*, concave in the middle, and much more concave on the right side, where it corresponds to the convex upper surface of the liver, than on the left, where it is in contact with the spleen and the large extremity of the

stomach, is covered by the peritoneum throughout the greater part of its extent, excepting at the situation of the coronary ligament of the liver, and also behind, where it is in relation with the third portion of the duodenum, the pancreas, the kidneys, the suprarenal capsules, and the solar plexus.

2. *Thoracic*, or *upper surface*. The middle portion is convex, and covered by the pleuræ and pericardium; it is flat, and serves as a floor to support the heart, the inferior surface of which rests upon it; hence the pulsations of the heart felt in the epigastrium. The lateral portions are convex, and contiguous to the lungs. The convexity is greater on the right than on the left side: the highest point to which the right side reaches, in the natural condition, is the level of the fourth rib; the highest point which the left side attains is opposite the fifth rib. Hence the surgical rule of operating for empyema higher on the right than on the left side.*

The height to which the diaphragm is raised varies remarkably; it reaches very much higher in the fœtus than in the adult. Should the muscle be only slightly vaulted, it is considered by medical jurists as one of the presumptive proofs that the infant has respired.

3. *Circumference*.—With the exception of the crura, the diaphragm is connected by its circumference only with one muscle, viz., the transversalis, which presents exactly corresponding attachments, so that, indeed, these two muscles may be considered as forming one contractile sac, interrupted by the costal insertions.

Action.—The diaphragm forms an active septum between the thorax and abdomen, which affects the viscera of both cavities. The two pillars act like the long muscles; the body of the diaphragm after the manner of the hollow muscles. When the pillars contract, they take their fixed point upon the lumbar vertebræ, and their movable point upon the notch at the back of the cordiform tendon, which is carried backward and downward. This aponeurosis, in its turn, becomes a fixed point for all the other curved radiated fibres that are attached to the ribs. The first effect of the contraction of a curved fibre is its becoming straight; and, in this process, the highest part of the curve is drawn down towards a level with its extremities: the vertical diameter of the thorax is, therefore, increased, and that of the abdomen proportionally diminished; but, during contraction, the fibres act equally upon both their points of insertion, and, as the cordiform tendon is fixed, and the costal attachments are movable, the ribs are drawn inward, and the transverse diameter of the thoracico-abdominal cavity thereby diminished. The anteroposterior diameter would be equally diminished, were it not for the inclination of the diaphragm downward and backward, in consequence of which the abdominal viscera are pressed downward and forward. Some experimentalists, among whom we may mention Haller and Fontana, have asserted that the diaphragm may become convex below during a forced contraction, but I believe this can only take place when air has been admitted into the cavity of the pleura.

We shall now consider the effects of the contraction of the diaphragm upon the openings by which it is perforated.

The elliptical, or, rather, oval opening for the œsophagus, being entirely muscular, is contracted during the action of the diaphragm, in the same manner as the mouth by that of the orbicularis muscle: hence the œsophagus is compressed. From this it has been concluded that vomiting cannot take place during inspiration, but experience proves the contrary, vomiting being favoured by this compression.

It is generally said that the orifice for the vena cava is not affected by the contraction of the diaphragm; but if we draw upon the muscular fibres in the neighbourhood of this opening, we see at once that it is diminished in size; Haller has even witnessed this in a living animal during inspiration. The arch, or, rather, the parabolic canal, which gives passage to the aorta, is also contracted, and the vessel slightly compressed; hence, doubtless, arises the frequency of aneurisms of this artery, where it passes through the pillars of the diaphragm.

LUMBAR REGION.

The Psoas and Illiacus.—Psoas Parvus.—Quadratus Lumborum.

The lumbar region includes the psoas and iliacus, the psoas parvus (when it exists), and the quadratus lumborum.

The Psoas and Iliacus.

I consider that, since the psoas and iliacus muscles have a common insertion, they should be described as a single muscle, having a double origin, which we shall term the psoas-iliac muscle.

Dissection.—Having opened the abdomen, tear away with the fingers the peritoneum covering the iliac fossæ and the lumbar regions. Remove, at the same time, the intes-

* This rule should be disregarded: the object of it is to open the thorax at the lowest part, so as to give a more easy exit to the liquid; but the lowest portion would be behind, in the deep groove formed by the diaphragm with the parietes of the thorax. It is of little importance to find the most depending part; it is sufficient to establish an outlet; the fluid will always flow to it.

tines, the stomach, the pancreas, the kidney, the liver, and the spleen; detach the iliac fascia. In order to see the femoral insertion of this muscle, divide the crural arch through the middle. Dissect with care the muscles at the anterior and superior part of the thigh, especially the pectineus, with which this muscle is in immediate relation. Remove the adipose cellular tissue which surrounds the crural vessels and nerves.

The *psoas-iliac* muscle is deep-seated, and extends from the sides of the vertebral column and front of the iliac fossa to the lesser trochanter of the femur. It *arises* above by two very distinct muscular masses: an internal, long, or lumbar portion (lumbaris, sive psoas, *Riolanus*), the *great psoas* of authors; and an external, broad, or iliac portion, constituting the *iliacus* (iliacus internus, *Albinus*).

1. The *lumbar portion* (psoas magnus, from ψόαι, the loins, *g g*, *fig.* 111) *arises* from the sides of the bodies of the five lumbar and last dorsal vertebræ, and of the corresponding inter-vertebral substances, and from the base of the transverse processes, by means of aponeurotic fibres, united by tendinous arches, which correspond to the grooves on the bodies of the lumbar vertebræ, so that the muscle is, in reality, only attached to the upper and lower borders of the bodies of the vertebræ, and to the inter-vertebral substances. From this double origin the fleshy fibres proceed in the form of a conoid bundle, compressed on the sides, and directed obliquely downward and outward; the summit of the cone is flattened, and embraced by the ligamentum arcuatum; the body is thicker and rounded, and diminishes in size inferiorly, as its constituent fibres are gradually attached to a tendon, which, though at first concealed in its centre, afterward advances towards the anterior and external surface, receives the fibres of the iliacus, and is *inserted* into the lesser trochanter of the femur. The great psoas, therefore, resembles a double cone or spindle.

Its component fibres are not fasciculated, but are united by a very delicate cellular tissue. The complete absence of fibrous tissue explains the weakness of this muscle, which may be torn with the greatest facility, and perhaps, also, the frequency of its diseases. Its tenderness in the ox causes it to be a favourite joint for the table, under the name of short ribs (*aloyau*): perhaps this delicacy of texture is connected with the presence of a large plexus of nerves in the substance of the muscle.

2. The *iliac portion* (iliacus muscle; iliacus internus, *Alb.*, *i i*, *fig.* 111) fills the internal iliac fossa. It *arises* from the whole of this fossa, from the crest of the ilium, the ilio-lumbar ligament, and the base of the sacrum, and from the anterior superior iliac spine, the notch below, the anterior inferior iliac spine, and even the capsular ligament of the hip-joint. The fleshy fibres converge, and are immediately attached to the external edge of the common tendon, which we have described as originating in the substance of the psoas. This tendon, which receives on its inner side all the fibres of the psoas, and even those fibres of the iliacus which arise from the brim of the pelvis, runs along the side of the brim, diminishing its transverse diameter, and emerges from the pelvis under the crural arch, passing through a remarkable groove between the anterior inferior spinous process of the ilium, and the eminentia ilio-pectinea. In this situation all the fibres of the psoas terminate; those that remain of the iliacus are successively attached to the outside of the tendon, like the barbs of a feather to the shaft, and form a triangular fleshy bundle, which immediately changes its direction, passes backward, inward, and downward among the muscles of the thigh, turns slightly round, so that its anterior surface looks somewhat inward, and its posterior surface outward, and is *inserted* into the lesser trochanter, which it embraces on every side, even to its base. It is not uncommon to find the fasciculus which comes from the anterior inferior spinous process of the ilium and the capsular ligament forming a very distinct muscle, which has been often described separately, under the name of the *ilio-capsulo-trochantericus*; it is inserted separately below the lesser trochanter into the oblique line which extends from this process to the linea aspera.

Relations.—1. The lumbar portion (*psoas magnus*) is in relation anteriorly with the diaphragm, the kidney, the ascending colon on the right side, the descending colon on the left, the peritoneum, and the psoas parvus, when it exists. The external iliac artery and vein run along the anterior surface. On the inside it corresponds to the bodies of the lumbar vertebræ and the lumbar vessels; behind, to the transverse processes of the lumbar vertebræ and the quadratus lumborum. The lumbar plexus is situated posteriorly in the substance of the psoas magnus; this explains the violent pain in the loins experienced during repeated contractions of this muscle, and, during pregnancy, from the pressure of the gravid uterus. 2. The iliac portion lines the iliac fossa; it is covered by the peritoneum, the cæcum, and the end of the small intestines on the right side, and by the sigmoid flexure of the colon on the left. These two muscles form a projection on the inside, which reduces the transverse diameter of the brim of the pelvis from five inches to four and a half. 3. The psoas and iliacus exactly fill that portion of the crural arch in which they are placed, so that herniæ never take place in this situation. 4. In the thigh, the common tendon is separated anteriorly from the cellular tissue of the groin by the deep femoral fascia; it is in relation with the crural nerve, which passes out of the pelvis in the same sheath as, but below, the psoas, in a groove between the

latter and the iliacus, between which parts it forms the only separation. Behind, it is in contact with the anterior border of the os coxæ and the hip-joint, a large bursa intervening, which often communicates with the synovial capsule of the joint, by an opening of variable size.* The inner edge of the psoas-iliac muscle is in relation with the outer edge of the pectineus, and with the femoral artery, which it sometimes covers. The external edge is at first in relation with the sartorius, and afterward with the rectus femoris. The psoas-iliac is also covered by the lumbo-iliac fascia (*fascia iliaca*), which will be described hereafter. (Vide APONEUROLOGY.)

Actions.—The psoas-iliac muscle *flexes* the thigh upon the pelvis; this action is the more energetic from the fact of the fixed points of insertion being both on the vertebral column, and on the iliac fossa. The two portions of the muscle do not act in the same direction; but when they contract simultaneously, the opposite forces are destroyed, and the traction upon the common tendon becomes direct. This muscle affords a remarkable example of the reflection of a muscle over a pulley, which greatly increases the power, by changing the direction of insertion nearly to the perpendicular. The action of this muscle, therefore, must only be calculated from the point of reflection, *i. e.*, the anterior edge of the ilium. It is in semiflexion that the muscle becomes perpendicular to the femur, and acts with the greatest power; and, therefore, the *momentum* of the muscle occurs at that period. The psoas-iliac is at the same time a *rotator outward* of the femur, on account of the obliquity of its insertion at the inner and back part of that bone. When the femur is fixed, as in standing, it draws the lumbar portion of the spine and the pelvis forward; and its iliac portion rotates the pelvis so as to turn the front to the opposite side. When the muscles of each side act together, the trunk is inclined directly forward.

The Psoas Parvus.

This muscle (*l l, fig.* 111) lies in front of the preceding; it *arises* from the twelfth dorsal vertebra, the first and sometimes the second lumbar vertebræ, and the corresponding inter-vertebral substances. It forms a small, flat bundle, at first appearing to be a dependance of the psoas magnus, but soon becoming isolated; it terminates in a broad, shining tendon, which crosses the psoas magnus at a very acute angle, and is *inserted* into the upper part of the ilio-pectineal eminence, and the corresponding portion of the brim of the pelvis. This small muscle receives the lumbo-iliac aponeurosis (*fascia iliaca*) on its outer edge. It is often absent; we have sometimes seen it double. Its *use* is evidently to render the iliac fascia tense, and to tie down and prevent displacement of the lumbar portion of the psoas magnus. It may assist in flexing the pelvis upon the thorax, as in climbing; in the recumbent and supine position, if one muscle acts alone, it inclines the pelvis to its own side; but if its fixed point be below, it inclines the trunk to the same side.

The Quadratus Lumborum.

Dissection.—Expose the posterior surface, by carefully detaching the common mass of the posterior spinal muscles; and to view the anterior, open the abdomen and remove the viscera. This muscle is enclosed in a sheath formed by the anterior and middle layers of the posterior aponeurosis of the transversalis abdominis; divide this sheath, and the muscle will be completely laid bare.

The *quadratus lumborum* (*m m, fig.* 111) is quadrilateral in shape, and broader below than above; it is *situated* in the lumbar region, on the sides of the vertebral column, between the crest of the ilium and the last rib.

Attachments and Direction.—It arises from the ilio-lumbar ligament, and from about two inches of the adjacent part of the iliac crest, by aponeurotic fibres, which, on the outer side especially, are very long. These fibres are bound down by others, crossing t at right angles, and give origin to the fleshy part of the muscles, which proceeds d and a little inward, in the following manner: 1. Some of the fibres pass vertically upward, and are *inserted* into the last rib, to an extent which varies in different individuals. 2. Others are directed very obliquely inward, and divide into four fleshy bundles, *inserted*, by means of a similar number of tendons, into the summits of the transverse processes of the four superior lumbar vertebræ. 3. There is most commonly a third plane, anterior to the preceding, and consisting of fibres, which arise from the summits of the transverse processes of the third, fourth, and fifth lumbar vertebræ, and are *inserted* into the lower edge of the last rib.

Connexions.—The quadratus lumborum somewhat resembles the rectus abdominis, in being enclosed and bound down in a very strong tendinous sheath; it has, therefore, no direct relations. In front are the kidney, the colon, the psoas, and the diaphragm; behind is the common mass of the spinal muscles, beyond which its outer border somewhat projects, especially below. Its most important relations are with the kidney and the colon. It is the guide for the necessary incisions in operations performed in this region, particularly in nephrotomy.

* See note, p. 206.

Action.—With its fixed point at the crest of the ilium, this muscle depresses the last rib, by means of its costal insertions, thus acting as a muscle of expiration; and it inclines the spine to its own side, through the medium of its vertebral attachment. With its fixed point above, it inclines the pelvis to its own side.

LATERAL VERTEBRAL REGION.

The Inter-transversales and Rectus Capitis Lateralis.—Scaleni.

The lateral muscles of the vertebral column are the inter-transversales of the neck and loins, the rectus capitis lateralis, and the scaleni. The quadratus lumborum, already described, belongs also to this region.

The Inter-transversales and Rectus Capitis Lateralis.

The inter-transversales muscles exist only in the neck and the loins; in the back they are represented by the intercostals, an additional proof of the analogy between the ribs and the cervical and lumbar transverse processes. Many celebrated anatomists, however, admit the existence of inter-transverse muscles in the back, but they are nothing more than deep-seated fasciculi of the transverso-spinalis.

1. *Inter-transversales of the Neck* (*a* to *a*, *fig.* 112).—There are two of these muscles in each inter-transverse space, an interior and a posterior. They are small quadrilateral muscles, one arising from the anterior, the other from the posterior margin of the groove on the transverse process below: from these origins the fibres proceed vertically upward, and are *inserted* into the transverse process of the vertebra above. They are separated from each other by the anterior branches of the cervical nerves and by the vertebral artery, the canal for which they serve to complete. Behind, they are in relation with the posterior spinal muscles, the splenius, the levator anguli scapulæ, the transversalis colli, and the cervicalis descendens; and in part with the rectus capitis anticus major.

Fig. 112.

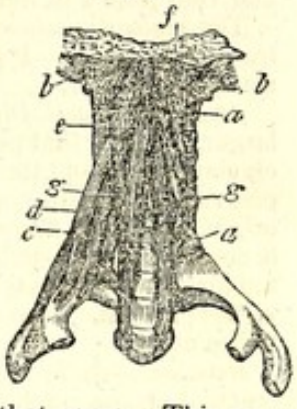

2. *Rectus Capitis Lateralis* (*b*, *fig.* 112).—This muscle may be regarded as the first posterior inter-transversalis of the neck, and the rectus capitis anticus minor, which we shall presently describe as the first anterior inter-transversalis. The comparative size of the rectus lateralis is not opposed to this view, for it is connected with the increased development of the corresponding cranial vertebra. It *arises* from the transverse process of the atlas, and proceeds directly upward, to be inserted into the jugular surface of the occipital bone, immediately behind the fossa of that name. This muscle separates the jugular vein, with which it is in contact in front, from the vertebral artery, to which it is contiguous behind.

3. *Inter-transversalis of the Loins.*—The absence of any groove upon the lumbar transverse processes would lead us at once to infer that in this region there must be only one muscle in each inter-transverse space. There are, therefore, five on each side. The first extends from the transverse process of the last dorsal to that of the first lumbar vertebra; and the last from the transverse process of the fourth to that of the fifth lumbar vertebra.

Action.—These little muscles, by drawing the transverse processes towards each other, incline that portion of the vertebral column with which they are connected towards their own side; that is, the cervical muscles with the rectus lateralis incline the head and neck, and those of the lumbar region act upon the loins.

The Scaleni.

Dissection.—These muscles are, in a great measure, displayed in the ordinary dissection of the anterior and posterior cervical regions. In order specially to expose them upon an entire subject, it is sufficient to dissect off the skin on the sides of the neck, and to remove the omo-hyoid, the nerves, the cellular tissue, and the sub-clavicular lymphatic glands. But in order to demonstrate the inferior attachments of these muscles, the upper limb must be scarified by disarticulating the clavicle at its sternal end, or, still better, by sawing the clavicle through the middle, dividing the great and small pectoral muscles, raising the sterno-cleido-mastoid, detaching the serratus magnus, and drawing the apex of the shoulder forcibly backward.

The scaleni occupy the sides and lower part of the neck, extending from the two upper ribs to the six lower cervical vertebræ, sometimes to the atlas also. They are, therefore, fasciculated like all the other vertebral muscles. Anatomists are not agreed concerning their number. Albinus enumerated five on each side; Sabatier reduced these to three; but we agree with M. Boyer, and modern anatomists, in admitting the existence of two only, an anterior and a posterior. M. Chaussier has followed the example of Riolanus, in describing only one, which he calls *costo-trachelien*.

1. The *scalenus anticus* (*c*, *figs.* 112, 113, and 114) might be termed the *anterior long inter-transversalis colli.* Its name sufficiently indicates its triangular shape, though it rather resembles a cone with the base below and the apex above.

Attachments and Direction.—It *arises* from the inner margin and upper surface of the first rib, near its middle, the point of attachment being indicated by a tubercle, with which it is highly important that we should be acquainted, because it serves as a guide in placing a ligature upon the subclavian artery, which passes over the upper surface of the first rib. It arises by means of a tendon that expands into an aponeurotic cone, from the interior of which the fleshy fibres take their origin. These unite, form the body of the muscle, and proceed upward and inward, to be *inserted* by so many separate tendons into the anterior tubercles of the transverse processes of the sixth, fifth, fourth, and third cervical vertebræ, and more especially into the notches between the two tubercles at the extremities of these processes. It is not uncommon to find one or two fasciculi inserted into the posterior tubercles.

Relations.—*In front and on the outside*, this muscle is in relation with the clavicle, from which it is separated by the subclavian muscle and vein; higher up, with the sterno-mastoid, the omo-hyoid, the phrenic nerve, and the transverse and ascending cervical arteries. *Behind*, it is separated from the posterior scalenus by a triangular space, which is wide below to receive the subclavian artery, and narrow above, where it corresponds to the brachial plexus of nerves, by the first two branches of which the muscle is sometimes perforated. On the *inside*, it is separated from the vertebral artery by the longus colli. The relations of the scalenus anticus to the subclavian vein and artery are of the highest importance to the surgeon, and, in order to impress them upon the memory, I propose to designate it *the muscle of the subclavian artery.* I have seen both the artery and vein placed in front of this muscle.

The *scalenus posticus* (*d*, *figs.* 112, 113, and 114) may be termed the *posterior long inter-transversalis colli.* It is situated behind the preceding muscle, is of the same shape, but somewhat larger.

Attachments and Direction.—It has two perfectly distinct origins: one, anterior and larger, from all that part of the first rib intervening between the depression for the subclavian artery and the tubercle; and another, posterior, from the upper edge of the second rib. The latter attachment is sometimes wanting. Proceeding from this double origin, the fleshy fibres form two small muscular bodies, which either remain distinct, or become blended together, and pass upward and inward, to be inserted by six separate tendons into the posterior tubercles of the transverse processes of the six inferior cervical vertebræ. It is not uncommon to find a fasciculus extending from the second rib to the atlas.

Relations.—It is separated from the anterior scalenus by the subclavian artery and brachial plexus; and is in relation, behind, with the cervicalis descendens, transversalis colli, splenius, and levator anguli scapulæ: on the outside, with the serratus magnus, the transverse cervical artery, and the sterno-mastoideus: on the inside, with the first intercostal, the first rib, the inter-transversales of the neck, and the cervical vertebræ.

Action.—The scaleni are powerful flexors of the neck, when their fixed points are below; but when their upper attachments are fixed, they tend to elevate the first rib, and in a slight degree the second also.

DEEP ANTERIOR CERVICAL, OR PREVERTEBRAL REGION.

The Recti Capitis Antici, Major et Minor.—Longus Colli.—Action of these Muscles.

This region includes three pairs of muscles placed immediately in front of the cervical and three superior dorsal vertebræ, viz., the *rectus capitis anticus major*, the *rectus capitis anticus minor*, and the *longus colli.* Their arrangement is extremely complicated and very difficult of elucidation, unless we consider them in the same general manner already adopted with regard to the disposition of the posterior spinal muscles. Let us suppose, then, that there exists in the median line of the basilar process of the occipital bone and the anterior surface of the bodies of the cervical vertebræ a series of spinous processes (a supposition which is realized in some animals); then the rectus capitis anticus major would be a *transverso-spinalis*, the rectus minor an *anterior inter-transversalis* between the occipital bone and the atlas, and the longus colli would be a compound muscle, its lower fibres forming a *spino-transversalis*, its upper fibres a *transverso-spinalis*, and its internal fibres a *spinalis.* All this will be rendered apparent from the following description.

Dissection.—Remove the face and all the parts which cover the cervical portion of the spine by the vertical section, called the *section of the pharynx*, because it is also employed in demonstrating that part. In order to separate the face from the cranium, remove the roof of the scull by a horizontal section, and then make a vertical cut either from above or from below; if we cut from above, we may adopt the usual plan of directing the saw transversely, so as to emerge immediately in front of the auditory meatus: in doing this,

however, we are in danger of injuring the superior attachments of the recti, or of cutting into the pharynx. We prefer, therefore, the following method: make two sections with the saw obliquely forward and inward in the course of the occipito-mastoid and petro-occipital sutures, and having arrived at the basilar process, cut it across with a chisel, a little in front of the anterior condyloid foramina. In separating the face from the cranium from below upward, a great number of muscles must be scarified: the preceding section is therefore preferable, although it is somewhat more difficult.

The Rectus Capitis Anticus Major.

This muscle (*e*, *figs.* 112 and 114), the transverso-spinalis anterior (rectus capitis internus major, *Alb.*), is the most external of those in the prevertebral region.

Attachments and Direction.—It *arises* from the anterior tubercles of the transverse processes of the sixth, fifth, fourth, and third cervical vertebræ, by small tendons, to which as many fleshy fasciculi succeed; these pass obliquely upward and inward, overlying and blending with each other, and terminate on the posterior surface and edges of a shining aponeurosis, that occupies almost entirely the anterior aspect of the muscle. This aponeurosis itself becomes a surface of origin, dividing into two laminæ, from the borders of and interval between which a fleshy bundle ascends, to be inserted into the basilar process in front of the foramen magnum. The fasciculus arising from the third cervical vertebra does not join the common insertion, but is attached directly, and in a very distinct manner, to the basilar process within and behind the common fasciculus. The muscle must be turned outward in order to display this structure.

Relations.—It is covered by the pharynx, the internal carotid artery and jugular vein, the superior cervical ganglion and trunk of the great sympathetic nerve, and the par vagum, being separated from all these parts by some loose cellular tissue and the prevertebral aponeurosis. It covers the corresponding vertebræ, the articulation of the occipital bone with the atlas, and that of the atlas with the axis, a portion of the longus colli, and also of the rectus minor.

The Rectus Capitis Anticus Minor.

This muscle (*f*, *fig.* 112), the inter-transversalis anterior (rectus capitis internus minor, *Alb.*), extends from the base of the transverse process and from the adjacent part of the lateral mass of the atlas, to the basilar process of the occipital bone. It is partially covered by the rectus major, which is nearer the mesial plane: the superior cervical ganglion of the sympathetic rests upon it, and it covers the atloido-occipital articulation. It may be regarded as an anterior inter-transversalis between the occipital bone and the atlas, the rectus lateralis constituting the posterior inter-transversalis.

The Longus Colli.

Attachments, Direction, and Relations.—The longus colli (*g*, *g*, *figs.* 112 and 114), as before stated, is composed of three very distinct sets of fasciculi: 1. The *transverso-spinalis*, which, *arising* by flat tendons from the anterior tubercles of the transverse processes of the fifth, fourth, and third cervical vertebræ, unite so as to form a considerable fleshy bundle directed upward and inward, occupy the hollow on each side of the median line of the axis, and are *inserted* into the anterior tubercle of the atlas, which may be regarded as the representative of an anterior spinous process: 2. The *anterior spino-transversalis*, the least numerous of all, *arise* from the bodies of the three superior dorsal vertebræ by very slight tendinous expansions, proceed upward and outward, and are *inserted* into the anterior tubercles of the transverse processes of the fourth and third cervical vertebræ: 3. The spinalis which *arise*, to the inner side of the preceding fasciculi, from the bodies of the three upper dorsal and four lower cervical vertebræ, and from the intermediate ligaments, and having described a slight curve, are inserted into the crest of the axis and into the third cervical vertebra. The longus colli is elongated and fusiform in shape; it supports the pharynx, the œsophagus, the internal carotid artery, the internal jugular vein, and the pneumogastric and great sympathetic nerves: it covers the vertebræ to which it is attached.

Action of the Muscles of the deep Anterior Cervical Region.

When the head is thrown back, these muscles restore it to its original position. The rectus anticus major tends to flex the head, and from its obliquity to rotate it, so as to turn the face to its own side. The rectus minor inclines the head to its own side. The longus colli flexes the atlas upon the axis, and rotates it so as to turn the face to its own side. The same muscle also rotates the lower part of the neck, so as to turn the face to the opposite side · and, lastly, it is a direct flexor of the cervical region.

THORACIC REGION

The Pectoralis Major.—Pectoralis Minor.—Subclavius.—Serratus Magnus.—Intercostales —Supra-costales.—Infra-costales.—Triangularis Sterni.

The Pectoralis Major.

Dissection.—Separate the arm from the side. Make a horizontal incision from the top of the sternum to the front of the arm on a level with the lower border of the axilla, including in this incision a fascia which adheres closely to the fleshy fibres. Reflect one of the flaps upward and the other downward, by dissecting parallel to the fibres, *i. e.*, transversely to the axis of the body.

The *pectoralis major* (*c c, fig.* 109) is a broad, thick, triangular muscle, situated at the upper and fore part of the thorax and axilla. It *arises* from the anterior border of the clavicle and anterior surface of the sternum, from the cartilages of the second, third, fourth, and more particularly those of the fifth and sixth ribs, from the osseous portion of the last-mentioned rib, and from the abdominal aponeurosis: it is *inserted* into the anterior margin of the bicipital groove of the humerus.

The *clavicular origin* consists of short tendinous fibres attached to the entire breadth of the anterior border of the clavicle, for about the inferior third, or half of its extent.

The *sternal attachment* consists of aponeurotic fibres, which, intersecting with those of the opposite muscle, form, in front of the sternum, a very thick fibrous layer, sometimes almost completely covered by the muscular fibres, which, in certain individuals, advance nearly to the median line.

The *costal origins* consist of very thin tendinous laminæ, and the attachment to the abdominal aponeurosis is blended with that of the rectus abdominis.

From these different origins the fleshy fibres proceed *outward* in different directions; the upper fibres obliquely *downward*, the middle *transversely*, and the lower fibres *obliquely*. These last are *folded* backward, so as to form a sort of groove, which embraces the lower border of the pectoralis minor. It appears, then, that the pectoralis major is composed of three very distinct portions, which are sometimes separated by a greater or less quantity of cellular tissue. These three portions, in converging, are so disposed that the upper overlaps the middle, and this, again, the lower portion, the fibres of which are twisted upon themselves, so that the lowest in front become the highest behind, and vice versâ.* They are all inserted into the anterior lip of the bicipital groove by means of a flat tendon, about fifteen lines in breadth, which is continuous with the anterior edge of the tendon of the deltoid. The structure of this tendon commands particular attention, and can only be examined after having divided the muscle across, and turned the external half outward. It will then be seen that it is composed of two laminæ, placed one before the other, sometimes blended together, but generally distinct, or united only by their lower edges, so that they form a groove opening upward. The anterior lamina is the thicker, and receives the clavicular and middle portions of the muscle; the deep layer affords attachment to the lower portion. It is not uncommon to find the two laminæ separated by the tendon of the long head of the biceps, the groove for which they then contribute to form. The entire tendon is broader and thicker below than above, and gives off, both forward and backward, an aponeurotic expansion, constituting one of the chief origins of the fascia of the arm.†

Relations.—It is covered by the platysma myoides, the mammary gland, and the skin. Its deep relations are of the greatest importance. On the *thorax* it covers the sternum, the ribs and their cartilages, the pectoralis minor, the subclavius nauscle, the serratus magnus, and the intercostals. It forms the anterior wall of the axilla, and is in relation with the brachial plexus and axillary vessels, and with the cellular tissue and lymphatic glands of that region. Its *external border* is nearly parallel to the anterior edge of the deltoid, being separated from the latter by a linear or triangular cellular interval, in which are situated the cephalic vein and acromial artery. Its *lower border* is thin towards the median line, thick and tendinous externally; it forms the anterior border of the axilla, and gives rise to a projection under the skin, proportionate to the development of the muscle. Its *inner border* intersects in the median line with the muscle of the opposite side, and is continuous below with the linea alba.

Uses.—The pectoralis major is essentially an *adductor of the arm*; at the same time it rotates it inward, and draws it forward. It is by the action of this muscle that the forearms are crossed, and that one hand is placed on the opposite shoulder. Its upper or clavicular portion conspires with the anterior fibres of the deltoid and with the coracobrachialis in elevating the humerus, and carrying it forward.

* I believe that this overlapping and folding of the muscular fibres tend, reciprocally, to prevent the displacement of any individual portion of the muscle.

† I have once observed a very slender muscular fasciculus, arising from the abdominal aponeurosis, proceed along the inferior border of the pectoralis major, from which it was perfectly distinct, and terminate in a small tendon opposite the humeral insertion of that muscle. This tendon was continued along the inner side of the arm, adhered to the aponeurotic inter-muscular septum, from which it received a small fleshy fasciculus, and was ultimately inserted into the epitrochlea

If the arm be at a moderate distance from the side and its lower extremity be fixed, as is the case in falling on the elbow when the arm is directed outward, this muscle acts upon the humerus as upon a lever of the third order, of which the fulcrum is below, the power in the middle, and the resistance above; and it then tends to dislocate the head of the humerus with great force, because in this position its insertion is perpendicular to the lever.

When the humerus is fixed, the pectoralis major acts upon the ribs, the sternum, and the clavicle, and raises the trunk upon the arm. It is, therefore, one of the chief agents in climbing. Its action upon the ribs renders it an important auxiliary in cases of laborious inspiration. Hence the attitude of an asthmatic patient, who always places himself so as to keep the humeri fixed.

The Pectoralis Minor.

Dissection.—Detach the clavicular insertion of the pectoralis major, and divide that muscle in the middle by a verticle incision; reflect the two flaps, taking care to remove, at the same time, the loose cellular tissue which invests its deep surface.

The *pectoralis minor* (*e*, *fig.* 110) is a thin, flat, triangular muscle, having its internal edge serrated (serratus anticus, *Albinus*), and occupying the anterior and upper part of the thorax and shoulder. It *arises* from the third, fourth, and fifth ribs, by three delicate, shining, tendinous prolongations, lying superficially to the intercostal muscles; to these succeed three fleshy fasciculi, which unite and converge, so as to be *inserted* by a flat tendon into the anterior margin of the coracoid process, near its summit.

Relations.—It is covered by the pectoralis major, from which it is separated by the thoracic vessels and nerves: its posterior surface is in relation with the ribs, the intercostal muscles, the serratus magnus, the cavity of the axilla, and, therefore, with the axillary vessels and nerves. This last relation is of great importance, and sometimes renders the section of this muscle necessary for the ligature of the axillary artery. Attention should also be directed, 1. To its upper border, which is separated from the clavicle by a triangular interval, broad on the inside and narrow on the outside, in which the same artery may be tied; and, 2. The lower border of the muscle extends downward beyond the pectoralis major.

Action.—Most commonly it acts upon the scapula (musculus qui scapulam antrorsum agit, *Vesalius*). With its fixed point at the ribs, it evidently draws the scapula forward and downward, and forcibly depresses the apex of the shoulder. As a *depressor of the shoulder*, it acts in conjunction with the levator anguli scapulæ and rhomboideus, but antagonizes those muscles considered as elevators of the entire scapula: it is also opposed to the rhomboideus when moving the scapula forward. With its fixed point at the scapula, this muscle *elevates the ribs* to which it is attached.

The Subclavius.

Dissection.—Raise the clavicle by carrying the apex of the shoulder upward; divide the pectoralis minor, and remove the fibrous membrane, descending from the clavicle, and immediately investing the muscle. In order to expose its external or clavicular insertion, saw through the clavicle in the middle, divide the muscle at the same point, and reflect the external half with the corresponding portion of the clavicle.

The *subclavius* (*g*, *fig.* 110) is a long, thin, fusiform muscle, applied to the lower surface of the clavicle, by which it is concealed (musculus qui sub clavicula occultatur, *Fabricius Hildanus*). It *arises* from the cartilage of the first rib, and is inserted into the inferior and external surface of the clavicle. Its costal attachment consists of a cervical tendon, from which the fleshy fibres proceed outward, backward, and upward, and are inserted into the clavicle by short, tendinous fibres.

Relations.—It is covered above by the clavicle, which is grooved beneath for its reception; it is in relation below with the first rib, being separated from it by the axillary vessels and the brachial flexus; in front, it is enveloped by a very strong aponeurosis, completing the osteo-fibrous canal in which it is included. Its relation with the brachial plexus and axillary vessels prevents the direct compression to which these parts would have been otherwise exposed between the clavicle and the first rib.

Action.—When its fixed point is at the first rib, it depresses the clavicle, and is, therefore, a *depressor of the shoulder*; it tends also to press the inner end of the clavicle forcibly against the sternum; so, also, in fracture of the clavicle, it occasions the external fragment to ride upon the internal. When its fixed point is at the clavicle, it assists in elevating the first rib, and is, therefore, arranged among the muscles that act in impeded inspiration.

The Serratus Magnus.

Dissection.—Having removed the two pectorals, saw through the clavicle at its middle; press the scapula backward, directing its axillary edge outward; remove with care the cellular tissue occupying the axilla, especially that against the axillary vessels and nerves, and near the intercostal attachments of the muscle itself, in order to see the internal surface of which the subject must be turned, and the vertebral costa of the scapula drawn outward.

The *serratus magnus* (*u*, *fig.* 106, *d*, 109, and *l*, 110), very broad, quadrilateral, and serrated along one of its borders, occupies the side of the thorax, and extends, like a muscular girth, from the ten upper ribs to the vertebral costa of the scapula. Its *costal attachments* consist of nine or ten digitations arranged in a curve, having its concavity directed backward. The first digitation, which is very large, arises both from the first and second ribs, and from an aponeurotic arch between them; from thence the fibres proceed upward, outward, and backward, and are inserted into the inner surface of the posterior and superior angle of the scapula, near the levator anguli. This digitation is the narrowest part of the muscle; it differs in direction from the remainder, and is separated from them by a cellular interval; hence it has been termed the *superior portion of the serratus magnus*. The second, third, and fourth digitations *arise* in an oblique line, running downward and forward from the second, third, and fourth ribs. These are the largest and the thinnest of all the digitations; they proceed horizontally backward, and are *inserted* separately, by short tendinous fibres, into the entire length of the vertebral costa of the scapula, anterior to the rhomboid; they are distinguished from the remaining digitations both by their direction and by an intervening cellular space; they form the *middle portion of the serratus magnus*.

The fifth, sixth, seventh, eighth, ninth, and tenth digitations arise from the outer surface of the corresponding ribs along oblique lines, resembling the fingers crossed, and are interposed between corresponding prolongations of the external oblique. These digitations are at first tendinous; they soon become fleshy, and, converging towards each other, form a radiated fasciculus, which passes upward, outward, and backward, to be inserted into the internal surface of the inferior angle of the scapula. This is the *inferior portion of the serratus magnus*.

Relations.—The serratus magnus is partially covered by the two pectorals before, by the subscapularis behind, and above by the axillary vessels and nerves; its deep surface rests upon the ribs and the intercostal spaces, all these parts being united by a quantity of loose cellular tissue. A considerable portion of the lower part of the muscle is subcutaneous, and, therefore, the inferior digitations are important studies for the painter and the sculptor, and sometimes even for the surgeon, as indications of the arrangement of the corresponding ribs.

Action.—From the disposition of its different fasciculi, the serratus magnus occasions a compound movement of the scapula, which it will be well to analyze. The upper portion depresses and brings forward the apex of the shoulder; the middle portion draws the entire scapula directly forward; while the lower portion depresses it, and, moreover, rotates it, so that the apex of the shoulder is carried upward. As the lower part of the muscle is composed of six or seven of the converging fasciculi, which act with greater energy than the others, it follows that their action predominates even when the whole muscle contracts. The serratus magnus is, then, a *depressor of the entire shoulder*, and an *elevator of its apex*. It is more especially concerned than any other muscle in supporting a burden upon the shoulder.

In order that the action of the serratus may be directed upon the scapula, its costal attachments must be fixed: this requires the simultaneous contraction of the oblique muscles of the abdomen to maintain the ribs in a depressed position, and of the diaphragm and transversalis to prevent their projection outward. This simultaneous contraction occurs during all great efforts.

When the fixed point of the serratus magnus is at the scapula, its upper portion becomes a muscle of inspiration, its middle one of expiration, and its lower one of inspiration. The greater power of the latter has been the cause of the antagonizing action of the middle portion being overlooked; and the serratus magnus is, with great justice, regarded as the most powerful accessory muscle of inspiration: hence the various attitudes of asthmatic persons, who instinctively take a position which fixes the scapula, either by seizing a cord suspended from the top of the bed, or by bending forward, and leaning on their elbows and forearms, or by resting their upper extremities on two lateral supports.

The Inter-costales, Externi and Interni; the Supra costales and the Infra costales.

Dissection.—In order to examine the external intercostals and the supra-costales (levatores costarum), the scapula and all the muscles which cover the thorax must be removed; to expose the internal inter-costales and the infra-costales, it is necessary to saw through the middle of the dorsal vertebræ and the sternum in a vertical direction, and to tear off the pleura from one side of the thorax, which may be very easily accomplished by the fingers.

The *intercostal muscles*, as their name implies, occupy the intervals between the ribs: there are two in each intercostal space, and, therefore, as many pairs as there are spaces.

They are divided into *external* and *internal*. They represent two very thin muscular layers, of exactly the same width as the spaces to which they belong; taken together,

they also occupy the entire length of those spaces, but not separately, for the external intercostals extend only from the costo-vertebral articulations to the commencement of the cartilages of the ribs, while the internal intercostals commence at the angles of the ribs behind, and extend forward to the sternum. A very thin aponeurosis is prolonged from the free margin of the one forward and of the other backward to the end of the intercostal space. The external muscles, which I have generally found thicker than the internal, *arise* from the lip of the groove on the lower border of one rib, and the internal from the inner lip of the same groove, as well as from the corresponding costal cartilage; they are both *inserted* into the upper border of the rib below. The superior attachments consist of fleshy and tendinous fibres and lamellæ, all of which proceed downward to the rib below; those of the external layer obliquely forward, and those of the internal layer much less obliquely backward. The inferior attachments are similar in structure. The tendinous fibres of the intercostal muscles are very long, and much more numerous than the fleshy fibres: hence the intercostal spaces possess considerable strength, to which the crossing of the two layers also contributes.

Relations.—The external intercostals are covered by the two pectorals, the serratus magnus, the serrati postici, the latissimus dorsi, the sacro-lumbalis, and the external oblique; they are superficial to the internal intercostals, and are separated from them by the intercostal vessels and nerves, and by a very thin fibrous layer. The internal intercostals are covered by the external and by the aponeurotic layer continuous with them anteriorly. Internally they are in relation with the pleura, which, from the angles to the tuberosities of the ribs, is in apposition with the external muscles.

The *infracostal* muscles of Verheyen consist of small muscular and aponeurotic tongues, variable in number and length, which extend from the inner surface of one rib to the inner surface of the next, and sometimes, also, to the second or third rib below. They are sometimes vertical, but often oblique, like the internal intercostals, of which they may be regarded as portions.

Supra-costales (levatores breviores costarum of *Albinus*, *o* to *o*, *fig.* 107). These are small triangular muscles, situated at the back part of the intercostal spaces. They are accessories of the external intercostals, resemble them in being half tendinous and half fleshy, and appear to form a continuation of them. There are twelve on either side. Each *arises* from the summit of the transverse process of a vertebra, and proceeds in a radiated manner downward, to be *inserted* into the back part of the upper border and external surface of the rib below.

The fibres of these muscles have the same direction as those of the external intercostals, but they are more oblique, especially on the outside. The first arises from the transverse process of the seventh cervical vertebra, the last from that of the eleventh dorsal. Some of these muscles have two digitations, one disposed in the ordinary manner, the other attached to the next rib below. The latter, called the *long supra-costals* (levatores longiores, *Albinus* and *Haller*), form a transition between the levatores breviores and the serrati. Morgagni met with all the levatores united together, so as to form a very regular serrated muscle. They are covered by the longissimus dorsi and sacro-lumbalis, and they cover the external intercostals.

Action.—The contraction of the intercostal muscles tends to approximate the ribs; and, according as the upper or the lower ribs are fixed, they act as muscles of inspiration or of expiration. It has never been denied that the external intercostals are muscles of inspiration, but the crossing of the two muscular layers has given rise to the opinion that they oppose each other in action; and hence arose the celebrated dispute between Hamberger and Haller. It is easy to understand that the slight difference existing between their attachments, with regard to their distance from the fulcrum, could not counterbalance the effect of a difference in the relative fixedness of the ribs, and that the intercrossing of these muscles has no other object than to increase the strength of the parietes of the thorax.

As the first rib is much more fixed than the last, it follows that it must serve as a fixed point for the first intercostal muscle, which will consequently raise the second rib; this will then become the fixed point for the third rib, and so on. The scaleni often take their fixed point upon the vertebræ, and then assist in elevating the first rib. The quadratus lumborum depresses the last rib, which may then serve as a fixed point for the others during expiration.

The levatores act very effectually in raising the ribs; for, being attached so near to the fulcrum, the slightest movement produced in the posterior extremity of the rib becomes very sensible at the other end. I agree with Borelli (*De Motu Animal.*, tom. ii., p. 158), that the intercostals act even during the most easy respiration. This can be observed upon our own persons, and also in individuals in deep sleep. The ribs will be seen distinctly carried outward, and the sternum raised.

The Triangularis Sterni, or small Anterior Serratus.

Dissection.—Divide the ribs vertically at their junction with the cartilages, and tear off the pleura with the fingers.

The *triangularis sterni* represents the levatores costarum in front, or, rather, the serrati postici, with this difference, that it occupies the internal instead of the external surface of the thorax. Like them, it is serrated. It *arises* from the sides of the posterior surface of the sternum, from the ensiform cartilage and the inner ends of the cartilages of the ribs. From this origin the fleshy fibres proceed, dividing into three, four, five, and sometimes six digitations, which are inserted by tendinous fibres into the posterior surface and borders of the sixth, fifth, fourth, third, sometimes of the second, and even of the first costal cartilages. The lower fibres pass horizontally and parallel to the upper fibres of the transversalis, with which they are continuous. The succeeding *fibres* are directed upward and outward, proceeding more and more obliquely upward: hence the triangular shape of the muscle, to which its name refers.

Relations.—It is covered by the sternum, the internal intercostal muscles, and the costal cartilages, from which it is separated by the mammary vessels and some lymphatic glands; it is lined internally by the pleura, and rests upon the diaphragm below.

Its *use* is evidently to depress the costal cartilages, into which it is inserted, or to oppose their elevation.

Remarks concerning the Intercostal Muscles.—The muscles we have just described, viz., the intercostals and their accessories, are essential elements in the construction of the chest; they are found in all animals possessed of a thorax. Their use is to dilate and contract this cavity in its antero-posterior and transverse diameters. The first rib, being fixed by the contraction of the scaleni, serves as a fulcrum for the agents of inspiration; and the last rib, when fixed by the quadratus lumborum, serves the same purpose for those of expiration; so that these muscles, whose most common action is to incline to one side the neck and the loins, do not, on that account, act the less upon the ribs. I cannot, by any means, agree with Winslow, who denies that the scaleni have any action upon the ribs, and maintains that the articulation of the first rib with the first dorsal vertebra is intended for the movement of the vertebra on the rib, not for that of the rib on the vertebra. (Winslow, *Expos. Anat.*, t. ii., p. 360.)

SUPERFICIAL ANTERIOR CERVICAL REGION.

The Platysma Myoides.—Sterno-cleido-mastoideus.

The Platysma Myoides.

Dissection.—Stretch the muscle by inclining the head backward and placing a block under the shoulders of the subject; make a horizontal incision through the skin from the angle of the jaw to the symphysis menti, another from the symphysis to the inner end of the clavicle, and a third along the clavicle. These incisions should be very superficial, scarcely dividing the entire thickness of the skin. The muscle must be very cautiously dissected by taking care to commence at its upper part, to turn the edge of the scalpel towards the skin, and to follow exactly the direction of the fleshy fibres which pass obliquely downward and outward.

The *platysma myoides* (*e*, *fig.* 109), called *le peaucier* by Winslow, *latissimus colli* by Albinus, is a broad, very thin, and irregularly-quadrilateral muscle lining the skin at the fore part of the neck, and adhering to it like the cutaneous muscles of the lower animals. It extends from the skin covering the anterior and upper part of the thorax to the side of the face, where it terminates thus: at the base of the lower jaw, at the commissure of the lips, upon the masseter muscle, and at the skin of the face. From its lower attachment, which is almost always prolonged as far as the shoulder, and loses itself in the subcutaneous cellular tissue, the fibres proceed obliquely upward and inward; the pale muscular fasciculi which they form are separated from each other, and sometimes strengthened by additional fasciculi to the posterior border of the muscle: they terminate in the following manner above: the posterior fibres are lost under the skin of the face near the masseter muscle, the lower end of which they cover; those next in front are partly continuous with the triangularis oris, and partly with the quadratus menti; the anterior fibres terminate at the external oblique line of the lower jaw, and the most internal intersect with those of the opposite side. The posterior fibres, which are lost upon the skin of the face, are the rudiments of a remarkable fasciculus, an accessory of the platysma found in some subjects. It is directed obliquely downward, from the region of the parotid gland to the angle of the lips. Santorini described it under the name of *risorius novus*.

Relations.—These two muscles occupy the whole anterior region of the neck, excepting the median line, where they leave a triangular interval, having its base below, and occupied by a very dense fibrous tissue, forming a species of raphé, which is found in the median line throughout the body. This is the *linea alba* of the neck, from which the different component layers of the cervical fascia take their origin.

The platysma is intimately connected with the skin, but it does not adhere equally throughout; it is united closely below, but much more loosely above, where the inter-

vening cellular tissue is always adipose, and capable of containing a large quantity of fat, as we find in individuals who have what is called a double chin. There are no lymphatic glands between this muscle and the skin; they are all situated beneath the muscle. The relations of the deep surface of the platysma are very numerous. It covers the supra and sub-hyoid, and the supra-clavicular regions, being separated from all the structures beneath it by the cervical fascia, to which it is united by loose cellular tissue, seldom containing any fat. If we examine these relations in detail, we find, proceeding from below upward, that it covers, 1. The clavicle, the pectoralis major, and the deltoid; 2. In the neck, the external jugular vein, and also the anterior jugulars where they exist, the superficial cervical plexus, the sterno-mastoid, the omo-hyoid, the sterno or cleido hyoid, the digrastic, and the mylo-hyoid muscles, the sub-maxillary gland, and the lymphatic glands at the base of the jaw. In front of the sterno-mastoid, it covers the common carotid artery, the internal jugular vein, and the pneumogastric nerve; behind the sterno-mastoid, it covers the scaleni muscles, the nerves of the brachial plexus, and some of the lower nerves of the cervical plexus. 3. In the face, it covers the external maxillary or facial artery, the masseter and buccinator muscles, the parotid gland, &c.

Action.—The platysma is the most distinctly marked vestige in the human body of the panniculus carnosus of animals; and it can produce slight wrinkles in the skin of the neck. Its anterior border, especially at its insertion near the symphysis menti, is the thickest part of the muscle, and therefore projects slightly during its contraction. It is one of the depressors of the lower jaw; it also depresses the lower lip, and, slightly, the commissure of the lips. It therefore assists in the expression of melancholy feelings, but it is antagonized by the accessory portion, which draws the angle of the lips upward and a little outward, and thus concurs in the expression of pleasurable emotions; hence its name, *risorius*.

The Sterno-cleido-mastoideus.

Dissection.—Divide the skin and the platysma from the mastoid process to the top of the sternum, in an oblique line, running downward and forward; reflect the two flaps, one forward and the other backward, taking care to remove at the same time the strong fascia which covers the muscle. In order to obtain a good view of the superior attachments, make a horizontal incision along the superior semicircular line of the occipital bone.

The *sterno-cleido-mastoid* (*b*, *fig.* 113) occupies the anterior and lateral regions of the neck. It is a thick muscle, bifid below, and narrower in the middle than at either end. It *arises*, by two very distinct masses, from the inner end of the clavicle, and from the top of the sternum in front of the fourchette, and is inserted into the mastoid process and the superior semicircular line of the occipital bone. The sternal origin consists of a tendon prolonged for a considerable distance in front of the fleshy fibres. The clavicular origin consists of very distinct parallel tendinous fibres, attached to the inner side of the anterior edge and upper surface of the clavicle, to a very variable extent, an important fact in surgical anatomy. There is often a considerable cellular interval between these two origins; sometimes this interval scarcely exists, but, in all cases, the two portions of the muscle can be readily separated. From this double origin the fleshy fibres proceed, forming two large bundles, which remain distinct for some time. Many anatomists, therefore, Albinus in particular, have considered it as consisting of two separate muscles, which they describe as the *sterno-mastoid* and the *cleido-mastoid*; a division that is sanctioned by the comparative anatomy of this muscle. The sternal portion of the muscle is the larger, and passes upward and outward; the clavicular portion proceeds almost vertically upward, behind the other, and is entirely concealed by it at the middle of the neck; the two portions still remain separate, although approximated; ultimately they become united, and are inserted into the apex and anterior surface of the mastoid process by a very strong tendon, which runs for some distance along the anterior border of the muscle, and also into the two external thirds of the superior semicircular line of the occipital bone, by a thin aponeurosis. The *direction* or axis of the sterno-mastoid passes obliquely upward, backward, and outward.

Fig. 113.

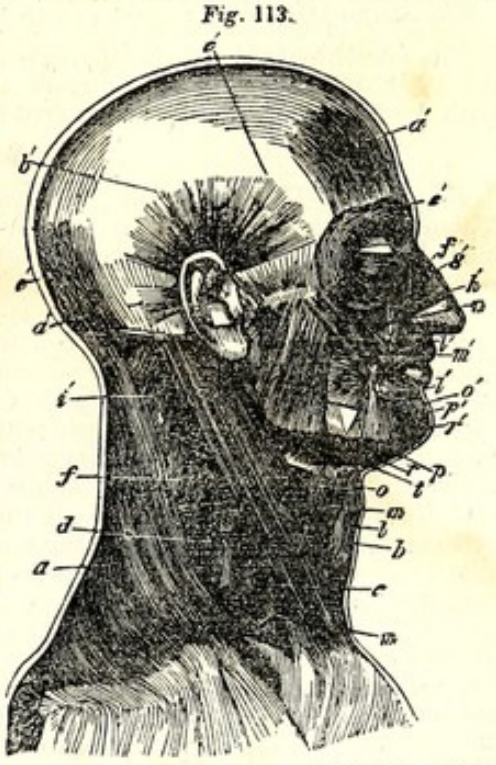

The *relations* of this muscle are very important. Its *superficial* or *external* surface is covered by the skin and platysma, from which it is separated by the external jugular

vein, and the branches of nerves, constituting what is improperly termed the superficial cervical plexus. Its *deep* or *internal surface* covers, 1. The sterno-clavicular articulation; 2. All the muscles of the sub-hyoid region, and also the splenius, the levator anguli scapulæ, the digastricus, and the scaleni; 3. The accessory nerve of Willis, which crosses beneath its superior third, the pneumo-gastric nerve, the great sympathetic, the loop of the hypoglossal nerve, and the cervical nerves; 4. The internal jugular vein; 5. The lower portion of the common carotid artery. Its *anterior border* produces a ridge under the skin, which it is important to study, because the first incisions for ligature of the common carotid, and for œsophagotomy, should be made along it. The parotid gland rests upon the upper part of this border, which is separated from the corresponding border of the muscle of the opposite side by a triangular interval, of which the apex is below and the base above. Its *posterior* border forms the anterior limits of the lateral triangle of the neck, which is bounded behind by the external margin of the trapezius, and below by the clavicle.

Action.—When the sterno-cleido-mastoid of one side acts alone, it flexes the head, inclines it to its own side, and rotates it so that the face is turned to the opposite side. It is, therefore, both a *flexor* and a *rotator of the head.* When both muscles act together, they flex the head directly upon the neck, and the neck upon the chest. Their action is particularly manifested in an attempt to raise the head while lying upon the back. Still, there is a position in which this muscle may become an extensor of the head, viz., when it is thrown very far backward; and this effect is owing to the nature of the upper insertion, which is situated somewhat behind the fulcrum of the lever represented by the head.

This muscle affords one of the most remarkable examples of the co-operation or simultaneous action of several muscles, in order to give effect to the action of one. Thus, in order that the sterno-cleido-mastoid may act most advantageously upon the head, it becomes necessary that the sternum, being the fixed point, should be maintained as immovable as possible, and this can only be effected by the contraction of the recti muscles of the abdomen. These latter, in their turn, require a fixed point at the pelvis, and this renders necessary the contraction of the glutæi, the semi-tendinosus, the semi-membranosus, and biceps femoris on either side; and, lastly, for the action of these, the legs require to be fixed by means of their extensor muscles.

This remarkable simultaneous contraction of so many muscles, necessary for the action of but one, has been extremely well illustrated by Winslow. It has many important results both in physiology and in pathology.

MUSCLES OF THE INFRA-HYOID REGION.

The Sterno-hyoideus.—Scapulo- or Omo-hyoideus.—Sterno-thyroideus.—Thyro-hyoideus.

The muscles of the infra-hyoid region are four in number on each side, viz., the sterno, or, rather, cleido-hyoid, the omo-hyoid, and the sterno-thyroid, which is continuous above with the fourth muscle, viz., the thyro-hyoid.

The Sterno-hyoideus.

Dissection.—This is extremely easy, and is the same for all the muscles of this region. The only caution necessary is, that the clavicular and sternal attachments of these muscles should be studied from their posterior aspect only, and that the trapezius must be removed in order to expose the scapular attachments of the omo-hyoid.

The *sterno-hyoid* (*l*, *figs.* 113 and 114) is a flat, thin, riband-like muscle, which is sometimes double on each side. It *arises* from the inner end of the clavicle, and is *inserted* into the os hyoides. Its inferior attachment is liable to some variations; most commonly it is connected with the back part of the inner extremity of the clavicle and with the inter-articular cartilage; sometimes with the outer side of that extremity; and sometimes with the circumference of the clavicular surface of the sternum. From this origin the fleshy fibres proceed parallel to each other, upward and inward, to be inserted by short tendinous fibres into the lower edge of the body of the os hyoides on the side of the median line, and to the inside of the omo-hyoid, with which it is often blended. Immediately above the clavicle this muscle is often divided by an aponeurotic intersection, which is united to that of the opposite side, and forms, as it were, a transverse bridle.

Relations.—It is covered by the platysma, the sterno-mastoid, and the cervical fascia. It covers the deep-seated muscles, the thyroid body, the crico-thyroid and thyro-hyoid membranes, from which it is often separated by a bursa mucosa, the crico-thyroid muscle, and the superior thyroid artery. The inner edges of the two sterno-hyoid muscles are generally separated by a fibrous raphé, but they are sometimes blended together, and thus render the operation of tracheotomy more difficult. This impediment may, however, be overcome by keeping accurately in the median line.

The Scapulo- or Omo-hyoideus.

This muscle (coraco-hyoideus, *Albinus*, *m m*, *figs.* 113 and 114) is longer and more

slender than the preceding; it is a digastric reflected muscle, composed of two small fleshy bellies, united by an intermediate tendon. It *arises* from the superior border of the scapula behind the coracoid notch, over an extent varying from a few lines to an inch, and is *inserted* into the lower part of the body of the os hyoides, externally to the sterno-hyoid. From its origin, which is sometimes tendinous, it proceeds for a variable distance behind and parallel to the clavicle, and is then reflected upward and inward, at an obtuse angle. At the point of reflection it becomes entirely or partially tendinous, and gives origin to another fleshy bundle larger than the former, which is inserted into the os hyoides.

The angular direction of this muscle is maintained by means of an aponeurosis, first described by Sœmmering, which extends between the inner borders of the two muscles, and is fixed to the clavicle: it is one of the layers of the cervical fascia, an important structure, to be again alluded to hereafter, and of which the omo-hyoid muscles are tensors. These muscles are occasionally wanting; sometimes they are double. In one case of this kind the accessory muscle was larger than the normal one, and arose from the upper and internal angle of the scapula.

Relations.—This small muscle, before reaching the sub-hyoid region, traverses two others, the supra-clavicular and the sterno-mastoid. It is covered by the trapezius, the subclavius, the clavicle, the platysma, the sterno-mastoid, and the skin; it covers the scaleni, the brachial plexus, the internal jugular vein, and the common carotid artery, and it is in contact with the outer border of the sterno-hyoid muscle.

The Sterno-thyroideus.

The *sterno-thyroid* (*n*, *fig.* 114) closely corresponds with the sterno-hyoid, from which it differs only in being shorter and broader. It extends from the posterior surface of the sternum to the thyroid cartilage. It *arises* from the sternum opposite the first rib; it is often blended with its fellow, so that their origins form a line reaching the entire breadth of the sternum, and often to the edges and posterior surface of the cartilage of the first rib.

From this origin the fleshy fibres proceed directly upward parallel to each other, and are *inserted* into the thyroid cartilage by a tendinous arch running obliquely downward and inward, which embraces the thyro-hyoid muscle, and is attached by its extremities to two very prominent tubercles on the external surface of the cartilage. It is sometimes continued as far as the os hyoides by a small lateral prolongation, and at other times it is continuous with the thyro-hyoid. The sterno-thyroid is interrupted by a tendinous intersection analogous to those of the rectus abdominis. It is not uncommon to find the two sterno-thyroid muscles united together by an intervening aponeurosis shaped like the letter V, opening upward, and corresponding to the fourchette of the sternum.

Relations.—It is covered by the sterno-hyoid and omo-hyoid muscles, and it covers the trachea, the lower part of the subclavian and internal jugular veins, the common carotid artery, and the arteria innominata on the right side, the thyroid body and the thyroid vessels. The middle thyroid vein runs along its inner border, an important relation in regard to the operation of tracheotomy.

The Thyro-hyoideus.

This is a small quadrilateral muscle (hyo-thyroideus, *Albinus*), which may be considered a continuation of the sterno-thyroid (*o*, *figs.* 113 and 114). It *arises* from the oblique line, and the tubercles of the thyroid cartilage, where it is embraced by the tendinous arch of the preceding muscle, passes vertically upward, and is *inserted* into the posterior surface of the body and part of the great cornu of the os hyoides.

Relations.—It is covered by the two muscles of the superficial layer, and covers the thyroid cartilage, and the thyro-hyoid membrane.

Action of the Muscles of the Sub-hyoid Region.—These muscles are the most simple, both in structure and in action: they all concur in depressing the lower jaw; but if the lower jaw is fixed, they produce flexion of the head. The fixed points of all are below, viz., at the sternum on the inside, at the clavicle in the middle, and at the scapula on the outside. This arrangement not only bestows particular uses upon each, but renders the common action of all more certain. Thus, the omo-hyoid, at the same time that it depresses the os hyoides, carries it backward and towards its own side. Where the two omo-hyoid muscles act together, the os hyoides is directly depressed, and forced backward against the vertebral column. The sterno-hyoid and the sterno-thyroid, prolonged by the thyro-hyoid, draw the os hyoides directly downward. The principal use of the thyro-hyoid is, to move the os hyoides upon the thyroid cartilage, in which movements the upper part of the cartilage is carried behind the os hyoides, the curve described by which is always greater than that formed by the cartilage. The muscles of the sub-hyoid region never assume as their movable points either their sternal, clavicular, or scapular attachments.

MUSCLES OF THE SUPRA-HYOID REGION.

The Digastricus.—Stylo-hyoideus.—Mylo-hyoideus.—Genio-hyoideus.—Their Action.

The muscles of this region, taken in the order of super-imposition, are the digastric, the stylo-hyoid, the mylo-hyoid, and the genio-hyoid.

The Digastricus.

Dissection.—Remove the platysma, reflect the mastoid insertion of the sterno-mastoid; detach and raise the sub-maxillary and the lower extremity of the parotid gland.

Fig. 114.

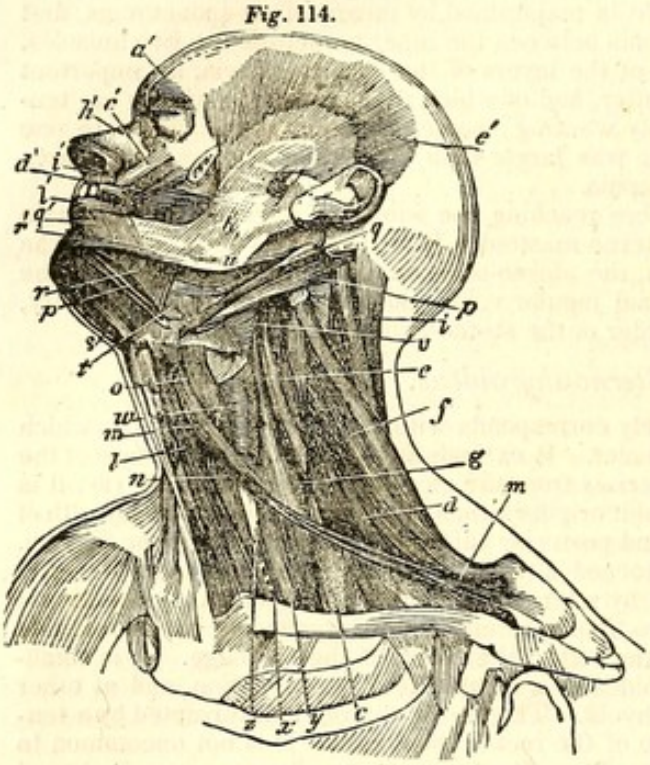

The *digastric* muscle (biventer maxillæ inferioris, *Albinus, p p, figs.* 113 and 114), so named because it consists of two fleshy bellies, united by an intermediate tendon, reaches the whole extent of the supra-hyoid region, from behind forward. It is, in some respects, the type of digastric muscles. It is curved upon itself, forming the arc of a circle, with the concavity directed upward.

It *arises* from the digastric groove in the mastoid process, and from the anterior edge of that process, in front of the sterno-mastoid; it it *inserted* into the side of the symphysis menti, below the sub-mental tubercles, into the whole extent of the digastric fossa. It is also attached to the os hyoides by means of an aponeurotic expansion.

Its *origin* from the mastoid process is partly fleshy and partly tendinous, the tendon being prolonged for some distance upon the upper border of the muscle. The fusiform fleshy belly produced in this manner passes forward, inward, and downward, into the interior of a sort of fibrous cone, forming the commencement of the intermediate tendon. This tendon, which is about two inches in length, follows at first the direction of the muscle, almost always perforates the stylo-hyoid muscle, and is then received into a fibrous ring attached to the os hyoides, and lined by a synovial capsule. This fibrous ring is often wanting. A broad aponeurotic expansion proceeds from the intermediate tendon, and is fixed to the os hyoides. When this is united to the corresponding structure on the opposite side, they form a very strong, triangular aponeurosis, called the *supra-hyoid aponeurosis*, which occupies the interval between the two muscles, and serves as a kind of floor for the other muscles of the supra-hyoid region. After having passed through the fibrous ring, the tendon changes its direction, and is reflected at an obtuse angle upward and forward, to terminate in another tendinous cone. From the interior of this cone the fleshy fibres of the anterior belly take their origin. This belly is not so strong as the posterior, and is inserted by separate tendons, sometimes intersecting those of the opposite side, into the whole extent of the digastric fossa, below the sub-mental tubercles. Some fibres are often blended with those of the mylo-hyoid. It is not uncommon to see a small fasciculus arising from the os hyoides, and strengthening the anterior belly. The two anterior bellies are sometimes united by a raphé, and by a small transverse fibrous bundle.

Relations.—It is covered by the platysma and sterno-mastoid, the parotid and the submaxillary glands, the latter of which it embraces by the concavity of its upper border: it covers the muscles which arise from the styloid process, the mylo-hyoid muscle, the internal jugular vein, the external carotid artery, and its labial and lingual branches, the internal carotid, and the hypo-glossal nerve, which lies parallel with, and beneath the intermediate tendon of the muscle.

Its *action* is very complicated: when the posterior belly contracts alone, the os hyoides is carried backward and upward; the anterior belly carries it forward, and also upward. When the two bodies of the muscle contract at the same time, these opposite effects are destroyed, and the os hyoides is carried directly upward. In all these motions, the lower jaw must be fixed. If the os hyoides is fixed, the posterior belly becomes a depressor of the jaw, on account of the reflection of the muscle; the anterior and the posterior bellies can incline the head backward, but this inclination of the head backward during mastication, and when the jaws are separated, depends on the action of the posterior exten-

sor muscles of the neck; lastly, the anterior belly of the digastric is the tensor of the supra-hyoid fascia.

The Stylo-hyoideus.

Dissection.—Detach the posterior belly of the digastric. This is a small and very thin muscle (*q*, *fig.* 114; *q q*, *figs.* 143 and 147), like all those which are attached to the styloid process.

It *arises* from the back of the styloid process, at a short distance from the apex, and opposite the insertion of the stylo-maxillary ligament. This origin consists of a small tendon, which terminates in a fibrous cone, from the interior of which the fleshy fibres commence. These proceed downward, forward, and inward, and form a bundle, which is almost always perforated by the tendon of the digastric. Occasionally the fibres pass only in front of that tendon. They are *inserted* into the body of the os hyoides, at a short distance from the median line. Sometimes the tendon of insertion is reflected upon itself, and forms the pulley for the digastric.

Relations.—It is covered by the posterior belly of the digastric, and has the same relations as that muscle. It is not uncommon to find a second stylo-hyoid muscle, extending from the styloid process to the little cornu of the os hyoides. This muscle takes the place of the stylo-maxillary ligament; it was described by Santorini under the name of the *stylo-hyoideus novus*, and was noticed also by Albinus.*

The Mylo-hyoideus.

Dissection.—Detach the anterior belly of the digastric at its maxillary insertion; dissect the sub-maxillary gland, and turn it outward.

This muscle (*r*, *figs.* 113 and 114), situated immediately below, *i. e.*, deeper (as regards the surface) than the anterior belly of the digastric, is thin and quadrilateral. It *arises* from the whole extent of the mylo-hyoid line, from opposite the last molar to the symphysis menti, by short aponeurotic fibres. The fleshy fibres arising from these pass in different directions: the internal (or anterior), very short, proceed inward to a median fibrous raphé, which traverses the whole supra-hyoid region; the external (or posterior) pass much less obliquely to the upper part of the body of the os hyoides. The median raphé is sometimes wanting, and the muscular fibres of the opposite sides are continuous with each other. Some of the fibres are often lost in the digastric, and are even continuous with the sterno-hyoid. The two mylo-hyoid muscles may, with great propriety, be regarded as a single muscle, divided by a tendinous intersection in the median line.

Relations.—It is covered by the anterior belly of the digastric, the supra-hyoid fascia, the platysma, and the sub-maxillary gland; and it covers the genio-hyoid, the hyo-glossus, and stylo-glossus muscles, the lingual and hypo-glossal nerves, the Whartonian duct, the sublingual gland, and the buccal mucous membrane.

The Genio-hyoideus.

This muscle (*s*, *fig.* 114, 143, 147) is situated below, *i. e.*, deeper than the preceding, which must be divided very carefully, in order to avoid raising the two together. It is a small, round, fleshy bundle, described by anatomists as consisting of two very minute muscles, separated from each other by an extremely delicate cellular tissue. Sometimes it is impossible to separate them; at other times the two bundles are very distinct. They *arise* from the inferior sub-mental tubercle, and proceed downward and backward, to be *inserted* into the upper part of the os hyoides.

Relations.—They are covered by the mylo-hyoids, and cover the hyo-glossal muscles.

Actions of the Muscles of the Supra-hyoid Region.

These are of two kinds, relating to the depression of the lower jaw, and to the elevation of the os hyoides.

The os hyoides being fixed by the muscles of the sub-hyoid region, all the supra-hyoid muscles, with the exception of the stylo-hyoids, depress the lower jaw; and it should be observed that they are situated in the most favourable manner for this purpose; for, on the one hand, they are almost perpendicular to the lever, and, on the other, they are attached as far as possible from the fulcrum. The obliquity of their direction has also this advantage, that the lower jaw is carried backward as well as depressed, and thus the orifice of the mouth is greatly increased in size.

But the most important action of these muscles relates to the elevation of the os hyoides. This elevation is an indispensable element in the act of deglutition, and also in the protrusion of the tongue. Thus, the os hyoides is carried upward and backward by the stylo-hyoid muscles and by the posterior belly of the digastric, upward and forward by the anterior belly of the digastric and by the mylo- and genio-hyoids, and directly upward by the combined action of all these muscles. The base of the tongue, of which the os hyoides constitutes, in some degree, the framework, is associated with it in all

* Albinus termed it *stylo-hyoideus alter.*

these movements, which take place at different periods of deglutition: thus, the movement upward and forward is effected during the period when the alimentary mass is driven from the cavity of the mouth into the pharynx, which enlarges for its reception. The direct elevation takes place when the mass is passing, and the movement upward and backward occurs after it has passed, so as to prevent its return into the mouth. When the lower jaw is fixed against the upper, and the os hyoides is also fixed by the sub-hyoid muscles, the muscles of the supra-hyoid region assist in flexing the head. Lastly, the os hyoides is elevated during the production of acute, and depressed during that of grave, vocal tones.

MUSCLES OF THE CRANIAL REGION.

Occipito-frontalis.—Auricular Muscles.

The muscles of the cranial region are the occipito-frontalis and the auricular muscles.

The Occipito-frontalis.

Dissection.—Shave the head, and make a horizontal incision above the superciliary arch; make a second incision in a vertical direction from before backward, and reaching from the former to the superior semicircular line of the occipital bone; be very careful not to dissect away the epicranial aponeurosis, nor the fibres of the muscle; commence the dissection at the fleshy fibres, which adhere less intimately to the skin than the aponeurosis.

The *occipito-frontalis* (epicranius, *Albinus*, *a' a'*, *fig.* 113) is sometimes regarded as one muscle with two bellies; sometimes as a combination of two separate muscles, the *occipital* and the *frontal*. It covers the roof of the scull. We shall describe the occipital and frontal portions only; the aponeurosis will be elsewhere noticed. (Vide Aponeurology.)

1. The *occipital portion*, or *occipital muscle*, covers a great part of the occipital bone, and is situated over the superior occipital protuberance. It is thin and quadrilateral. It *arises* from the two external thirds of the superior semicircular line, and from the neighbouring part of the mastoid process of the temporal bone, and is *inserted* into the posterior border of the cranial aponeurosis, of which it may be regarded as the tensor. The occipital attachment is composed of tendinous fibres, the fleshy fibres proceeding from which pass upward in a parallel direction, and, after a short course, terminate in the aponeurosis.

2. The *frontal portion*, or *frontal muscle*, is placed at the front of the cranium; it is thin, and irregularly quadrilateral, like the preceding. It is attached above to the cranial aponeurosis, and terminates below in the following manner: 1. The internal or median fibres are prolonged into a fleshy band, which constitutes the pyramidalis nasi; 2. The fibres next on the outside are continuous with those of another muscle, viz., the levator labii superioris alæque nasi—to the outside of these fibres, the muscle is attached to the internal orbital process; 3. The greater number of the fibres are blended with those of the orbicularis palpebrarum. The upper border of the muscle, which is attached to the aponeurosis, forms a semicircular line, that, in many individuals, causes a projection under the skin.

Relations.—The occipito-frontalis covers the roof of the scull; hence the name of epicranius (*Albinus*). It rests upon the pericranium (the periosteum of the cranial bones), being separated from it by a quantity of moist cellular tissue, which admits of a considerable degree of mobility of the integuments, and is so elastic that it returns to its original situation after being displaced by any movements of the hairy scalp. The superficial surface of this muscle is covered by the skin, and is united to it by a very dense, almost fibrous cellular tissue, in which are ramified the numerous vessels and nerves of the cranial integuments.

Action.—The occipital portion is a tensor of the epicranial aponeurosis, which, when stretched, affords a fixed point for the frontal portion. This latter raises the upper half of the orbicularis palpebrarum, elevates the eyebrows and the skin over the root of the nose, and has a great effect in the expression of emotions of delight. This muscle produces the transverse wrinkles on the forehead, which give to the countenance of individuals who are habitually gay a peculiar expression, that is often imitated by painters. These transverse wrinkles do not extend over the triangular interval, which separates the two fleshy bellies of the muscle in the centre of the forehead.

The occipito-frontalis must be regarded as an elevator of the upper eyelids; it is blended with the orbicularis palpebrarum in the same manner as the labial muscles with the orbicularis oris. In this respect the occipito-frontalis is assisted by the levator palpebræ superioris, and antagonized by the corrugator supercilii and orbicularis palpebrarum. Can this muscle erect the hairs on the head? It is certain that it can move the entire hairy scalp, for many individuals are able to do this at will; but it appears to me that the expression, *the hairs stand on end*, as regards man, is merely figurative, and is derived from what occurs in the lower animals, in which this erection of the hair is very

manifest. Perhaps, however, the skin itself may produce this effect by the same mechanism as that which gives rise to *goose skin*.

The Auricular Muscles.

Dissection.—Be very careful in dissecting the superior and anterior auricular muscles, which are extremely thin, and consist only of a few colourless fibres. To render them as tense and prominent as possible, it is necessary to draw the ear away from the muscle to be examined.

All these muscles are rudimentary in man, in whom the external ear is almost immovable. They may all be considered as dilators of the auditory meatus, to which there is no constrictor or sphincter in the human subject: certain animals, however, possessing a very delicate sense of hearing, have constrictor muscles, which draw together and move the different pieces forming the cartilaginous portion of this canal.

The auricular muscles are three in number: a superior, an anterior, and a posterior.

The Auricularis Superior.

This muscle, which is extremely thin and of a triangular form (*b'*, *fig.* 113), oocupies the temporal fossa. It *arises* from the external border of the epicranial aponeurosis, of which it seems to be a dependance; from this origin its fibres converge, and are *inserted* into the upper part of the concha. It is covered by the skin, and lies upon the temporal fascia.

Action.—To raise the ear (attollens auriculam, *Albinus*).

The Auricularis Anterior.

This muscle (*c'*, *fig.* 113) is still thinner and less marked than the preceding, with which it is continuous. It is also triangular, and *arises* from the outer edge of the occipito-frontalis and the cellular tissue covering the zygomatic region; the fibres converge from their origin, and are *inserted* into the front of the helix. It is covered by the skin, and lies upon the temporal fascia, from which it is separated by the temporal artery and vein.

Action.—To draw the auricle forward and upward (anterior auriculæ, *Albinus*).

The Auricularis Posterior.

This muscle (*d'*, *fig.* 113) is much more decidely marked than the preceding, and is composed of two or three distinct fleshy fasciculi (tres retrahentes auriculam, *Albinus*), which extend from the base of the mastoid process, and sometimes also from the occipital bone to the lower part of the concha.

Action.—To draw the auricle backward.

MUSCLES OF THE FACE.

All the muscles of the face are arranged in groups around its several openings, and may be classed either as dilators or constrictors. The nostrils alone have no constrictors.

The eyelids must be opened and closed entire, without the production of any folds; the nostrils must remain constantly open, for the skin around these orifices has within it a corresponding lamina of cartilage, which gives it the necessary tension, strength, and elasticity, and into which the muscles are inserted. There is no such arrangement at the orifice of the mouth, the muscles being there inserted into other muscles.

From the three openings around which the muscles of the face are grouped, these may be arranged into three distinct regions, viz., the palpebral, the nasal, and the buccal.

Muscles of the Palpebral Region.

Orbicularis Palpebrarum.—Superciliaris.—Levator Palpebræ Superioris.

The muscles of the eyelids are divided into constrictors and dilators. There is one constrictor, viz., the orbicularis palpebrarum, to which the corrugator supercilii is an accessory; there is also one elevator, viz., the levator palpebræ superioris.

The Orbicularis Palpebrarum.

Dissection.—Make an elliptical incision through the skin round the base of the orbit; dissect successively the upper and lower half of the muscle, proceeding from the adherent towards the free border of each eyelid. It is of more importance here than in any other situation to dissect the skin parallel to the fleshy fibres. When the external surface of the muscle has been studied, detach it carefully from the subjacent parts, and reflect it inward.

The *orbicularis palpebrarum* (*e'*, *fig.* 113) forms an elliptical zone of variable size round the eyelids, and also an extremely thin layer upon them. It is a sphincter, and, like all muscles of this kind, is composed of circular fibres; but, as a special exception, it is also provided with a remarkable tendon of origin, named the *straight tendon of the orbicularis*; this is about two lines in length and half a line in breadth, arises from the ascending process of the superior maxilla, anteriorly to the lachrymal groove, and passes in front of

the lachrymal sac, where it divides into two unequal parts, an upper and smaller, and a lower more capacious; sometimes it corresponds entirely to the upper part of the sac. At first it is flattened from before backward, but is then twisted upon itself, so as to present one surface upward and another downward. Opposite the inner angle of the eyelids, this tendon, which is also called the *palpebral ligament*, becomes bifurcated, and each division is attached to the inner end of the corresponding tarsal cartilage; from the posterior surface of the tendon a very strong aponeurotic lamina is given off, and forms the outer wall of the lachrymal sac: this is the *reflected tendon of the orbicularis palpebrarum*. Fleshy fibres proceed from the anterior and posterior surfaces, and from the borders of the straight tendon, and also from the anterior border of the reflected tendon; but the greater number arise by well-marked tendinous prolongations from the external orbital process of the frontal bone, from the ascending process of the superior maxilla, and from the internal and lower third of the base of the orbit. From these origins the fleshy fibres pass outward, dividing into two halves, an upper, which describes concentric curves with the concavity directed downward, and a lower, also describing concentric curves, but with the concavity directed upward (duo palpebrarum musculi, *Vesalius*). Each of these halves is subdivided into two sets of fibres: an external set, surrounding the base of the orbit; and an internal or palpebral, belonging to each eyelid: hence the distinction drawn by Riolanus between the *orbicularis* and the *ciliaris* or *palpebralis* muscles. The external fibres (forming the orbicular portion) describe a complete ellipse. I have never met with the fibrous intersection at the outer part of the eye, mentioned by some anatomists. The palpebral or ciliary fibres, forming the proper palpebral portion, arise from the bifurcation of the tendon, and describe concentric arcs, which are united on the outside at an acute angle to a cellular raphé.

Relations.—The orbicular portion is closely united to the skin by means of a fibrous and adipose tissue, which is very compact over the upper, and loose over the lower portion of the muscle; it is connected with the skin of the eyelids by a serous cellular tissue, remarkably susceptible of infiltration. It covers the lachrymal sac, the corrugator supercilii muscle, the orbital arch, the maxillary bone, the temporal muscle, and the superior attachments of the zygomaticus major, of the levator labii superioris alæque nasi, and of the levator labii superioris.

It is separated from the conjunctiva by a fibrous membrane and the tarsal cartilages. Its circumference is blended with the pyramidalis nasi on the inside, with the occipito-frontalis and corrugator above, but is free below; occasionally it gives off a few fibres from its outer border, some of which form the zygomaticus minor, and others of a paler colour terminate in the skin.

Actions.—The orbicularis acts in the same manner as all other sphincters, that is to say, the circular fibres of which it is composed contract towards the centre; but, as the fleshy fibres have their fixed point at the straight tendon, and still more at the internal insertions, it follows that, during the contraction of this muscle, it is thrown in some measure inward, and by it the integuments of the forehead, the temple, and the cheek are drawn towards the inner angle of the eye. The intimate adhesion between the skin and the upper half of the muscle explains why, during its contraction, that part is rendered more apparent beneath the skin than the lower. The palpebral portion contracts independently of the orbicular, a fact that confirms the distinction made by Riolanus. Nor is this all: the contraction of this palpebral portion, or *palpebralis muscle*, properly so called, is habitually involuntary, while the contraction of the orbicular portion is subject to the will. The palpebral fibres are pale, and resemble the muscular fibres of the alimentary organs;* the orbicular fibres are red, like those of the muscles of animal life. When the palpebral fibres contract, they do not produce the occlusion of the eye, by a concentric approximation of the fibres, but by bringing together the free edges of the eyelids, the only method permitted by the tarsal cartilages. The curve described by the muscular fibres of the lower being smaller than that formed by those of the upper eyelid, it follows that the closing of the eyes depends principally upon the latter.

The Superciliaris.

Dissection.—Make a vertical incision in the median line between the frontal muscles; turn back carefully the frontal and the orbicularis muscles from within outward.

The *superciliaris* (corrugator supercilii, *Albinus*, *a'*, *fig.* 114) is a narrow and tolerably thick fasciculus, generally of a deeper red than the orbicularis, and situated along the superciliary arch, with the direction of which it corresponds. It *arises* by one, often by two or three portions, from the internal portion of this arch; proceeds upward and outward, describing a slight curve, having its concavity downward, and is blended with the orbicularis palpebrarum at about the middle of the arch of the orbit. From this arrangement, Albinus described it as a root of the orbicularis. According to some authors, it terminates in the skin of the eyebrow (cutaneo-surcilier, *Dumas*); but I have always found it attached to the deep layer of the orbicularis muscle.

* See note *, p. 238.

Relations.—It is covered by the pyramidalis nasi, the orbicularis palpebrarum, and the occipito-frontalis, and it covers the os frontis, the supra-orbital and frontal arteries, and the frontal branch of the ophthalmic nerve.

Action.—This muscle corrugates the eyebrow, and draws it downward and inward. It is, therefore, regarded as the principal agent in the expression of grief. The repeated contraction of these muscles in irascible individuals gives a character of severity to the countenance, from the constant approximation of the eyebrows, and the permanence of the vertical wrinkles formed between them.

The Levator Palpebræ Supreioris.

Dissection.—Remove the roof of the orbit by two cuts with a saw, meeting at an acute angle opposite the foramen opticum; detach the bone with care, so as to leave the periosteum untouched; cut the periosteum from before backward, and separate the frontal nerve which passes above and parallel to the muscle, which may then be separated carefully from the superior rectus muscle of the eye.

The *levator palpebræ superioris* (see description of the eyelids) is an elongated, flat, triangular, and very thin muscle, placed in the orbital cavity, directed horizontally from behind forward, and curved at its anterior extremity, so as to form a concavity directed downward. It *arises* from the inferior surface of the lesser wing of the sphenoid, immediately above the optic foramen, and from the sheath of the optic nerve, and is *inserted* into the upper border of the tarsal cartilage. Its sphenoidal origin consists of a small tendon, and its attachment to the sheath of the optic nerve is a fibrous ring common to all the muscles of the eye. From these points the fleshy fibres proceed forward, forming a broad, thin bundle, increasing in width and diminishing in thickness towards its tarsal insertion, which is effected by means of a broad aponeurosis.

Relations.—Covered by the periosteum of the orbit, from which it is separated by the frontal branch of the ophthalmic nerve; covered, also, by some adipose tissue and by the fibrous membrane of the upper eyelid, it covers the superior rectus of the eye and the conjunctiva.

Action.—It raises the upper eyelid. Its reflection over the globe of the eye explains that peculiar motion of the eyelid by which its upper edge is buried below the orbital arch. The relaxation of this muscle suffices for the depression of the upper eyelid in passive closure of the eyes, while the active occlusion depends on the contraction of the orbicularis.

There is no analogous muscle for the lower eyelid, which scarcely concurs either in opening or shutting the eyes.

NASAL REGION.

The Pyramidalis Nasi.—Levator Labii Superioris Alæque Nasi.—Transversalis, or Triangularis Nasi.—Depressor Alæ Nasi.—Naso-labialis.

The muscles of this region are the pyramidalis nasi, the levator labii superioris alæque nasi, the transversalis or triangularis nasi, the depressor alæ nasi, or myrtiformis, and the naso-labialis of Albinus.

The Pyramidalis Nasi.

Dissection.—Trace down upon the dorsum of the nose the internal fibres of the occipito-frontalis, directing the scalpel parallel to these fibres, which have a vertical course.

The *pyramidalis nasi* (*f*, *fig.* 113) is a prolongation of the internal fibres of the occipito-frontalis, of which it may be regarded as a prolongation (frontalis pars per dorsum nasi ducta, *Eustachius*). It lies upon the bridge of the nose on each side of the median line. It is separated from the muscle of the opposite side by a thin layer of cellular tissue. It is narrower at its origin than at its termination, which takes place in the aponeurosis of the transverse muscle of the nose.

Relations.—It is covered by the skin, to which it closely adheres, especially below, and it covers the nasal bones and lateral cartilages.

Action.—This small muscle has been regarded as an elevator of the ala, and, consequently, a dilator of the nose; but I believe it rather acts in depressing the inner angle of the eyebrow, and the skin between the eyebrows. In this respect it has considerable influence upon the expression of the countenance.

The Levator Labii Superioris Alæque Nasi.

Dissection.—Make a vertical or somewhat oblique incision from the ascending process of the superior maxilla to the upper lip. Reflect outward the inner and lower part of the orbicularis muscle.

This muscle (*g'*, *fig.* 113) is thin, triangular, and divided into two portions below. It extends from the ascending process of the superior maxilla to the ala of the nose and the upper lip. It *arises* by a narrow extremity from the internal orbital process of the frontal bone, immediately below the tendon of the orbicularis palpebrarum, passes obliquely

downward and outward, becomes much broader, and is *inserted* partly into the cartilage of the ala of the nose, or, rather, into the very dense skin which covers it, and partly into the orbicularis oris, or, rather, into the skin of the upper lip. The cutaneous portion of this muscle is distinguished by its paleness, compared with the red colour of the rest.

Relations.—It is covered by the skin, and a small portion of the orbicularis palpebrarum; and it covers the ascending process of the superior maxilla, and the transverse muscle of the nose.

Action.—It elevates both the ala of the nose and the upper lip. I consider it the most important of all the muscles of the nose, because the elevation of the alæ dilates the nostrils, and thus aids most essentially in cases of impeded respiration. It is a respiratory muscle of the face, and has, also, great influence over the countenance, producing the expression of contempt. Its action upon the upper lip is of much less importance than that upon the nose.

The Transversalis, or Triangularis Nasi.

Dissection.—Remove with great care the skin covering the ala of the nose, and then follow this muscle below the inner edge of the common elevator; or, what is better, remove all the soft parts covering the ala of the nose, and dissect the muscle from its deep surface.

The *transversalis nasi* (compressor narium, *h'*, *figs.* 113, 114), which I regard as a dependance of the muscle next to be described, is a small and very thin triangular muscle, stretching from the inner part of the canine fossa to the bridge of the nose. It *arises* by a narrow extremity from the canine fossa, passes forward, enlarging as it proceeds along the ala of the nose, and terminates by a very thin aponeurosis, which is blended in the median line with that of the opposite side, and with the pyramidalis. It is covered by the skin, to which it closely adheres, and by the common elevator; and it covers the cartilage of the ala, and a small part of the superior lateral cartilage of the nose.

Action.—The action of this small muscle is not yet well determined. Some have agreed with Riolanus in considering it a dilator (qui alam naris dilatat sine elevatione nasi, *Riolanus*); others think, with Spigelius and Albinus, that it is a constrictor of the nose (primi paris constringentium alas, *Spigelius*; compressor naris, *Albinus*). It is probable that its action *varies* according to the shape of the ala: if this be concave outward, it is a dilator; if convex outward, it is a constrictor. Its action is very slight.

The Depressor Alæ Nasi, or Myrtiformis.

Dissection.—Evert the upper lip, and remove the mucous membrane on each side of the frænum. The two myrtiformes may then be separated by a vertical incision in the median line. It will be apparent that the myrtiformis and transversalis form only one muscle, which arises from the alveolar border near the lateral incisor, the canine and the anterior bicuspid teeth, and is distributed to the orbicularis oris, the alæ, and the septum of the nose.

This muscle (*i'*, *fig.* 114) is short and radiated, and *arises* by a narrow extremity from the incisive or myrtiform fossa of the superior maxilla, opposite the canine and two incisor teeth (incisif moyen, *Winslow*). Its fibres diverge upward and outward, and are *inserted* thus: the lower, or descending, behind and in the substance of the orbicularis oris; and the upper or ascending, into the ala and septum of the nose. Its upper border is not distinct from the lower border of the transversalis. Chaussier, on account of its termination in the upper lip, regarded it as one of the origins of the orbicularis oris.

Relations.—It is covered by the buccal mucous membrane, by the orbicularis oris, and the common elevator, and it lies upon the maxillary bone. It is continuous, without any line of demarcation with the transversalis nasi. The inner border of the muscle of one side is separated from that of the other by an interval, corresponding to the frænum of the upper lip.

Action.—It depresses the ala of the nose, and has also been considered a depressor of the upper lip (depressor labii superioris,* *Cowper*). I regard it rather as an elevator of that lip.

The Naso-labialis of Albinus.

This consists of a fasciculus which it is difficult to demonstrate in many subjects. It *arises* from the anterior extremity of the septum of the nose, passes horizontally backward, is then reflected downward, and terminates like the preceding in the orbicularis, of which it may be considered a root.

MUSCLES OF THE LABIAL REGION.

The Orbicularis Oris.—Buccinator.—Levator Labii Superioris.—Caninus.—Zygomatici, Major et Minor.—Triangularis.—Quadratus Menti.—Levator Labii Superioris.—Movements of the Lips and those of the Face.

No region has so many muscles as the orifice of the mouth: seventeen, nineteen, and

* Depressor labii superioris alæque nasi of other writers.

often twenty-one muscles, are grouped round it, viz., the orbicularis oris, the common elevators of the alæ and lip already described, the proper elevators of the lip, the great zygomatics, the canine, the buccinators, the triangulares, the quadrati or the levatores menti; and often two muscles on each side, viz., the *risorius* of Santorini, and the *small zygomatic*.

The Orbicularis Oris.

Dissection.—Make an elliptical incision round the opening of the mouth, and dissect back the skin with great care, the mouth being previously distended by the introduction of tow between the lips and alveolar borders.

The *orbicularis oris* (*l' l'*, *figs.* 113 and 114) is the sphincter of the orifice of the mouth; it is essentially the constituent muscle of the lips, occupying the entire space between the free edge of the upper lip and the nose, and the free edge of the lower lip and the transverse furrow above the chin.

We shall consider, with Winslow, the orbicularis to be composed of two halves, each constituted by a demi-zone, of semi-elliptical concentric fibres, terminating on either side at the commissures of the lips. These fibres, which are all fleshy, do not become continuous opposite the commissures of the lips, but only intersect each other, those of the upper half being continuous with the lower fibres of the buccinator, and those of the lower half with the upper fibres of the same muscle.

The thickness of the two halves varies in different individuals, particularly around the free borders of the lips, where the fasciculi of the muscle are somewhat everted. In the negro this is very remarkable. The thickness of the lips depending upon this circumstance must be distinguished from that which is the effect of a scrofulous habit.

Relations.—These muscles are covered by the skin, to which they adhere intimately, and hence the facility of bringing together the entire depth of the surface of wounds in the lips, by retentive applications to the skin only. They cover the mucous membrane, but are separated from it by the labial glands, the coronary vessels, and a great number of nervous filaments. Their outer circumference receives all the extrinsic muscles of the lips, which terminate in these as in a common centre. Their inner circumference circumscribes the opening of the mouth. The differences in the dimensions of this opening occasion the varieties observed in the size of the mouth, but the capacity of the buccal cavity is in no way influenced by these variations.

Actions.—These are exceedingly various, and may be studied as connected with the closing of the mouth, with the prehension of aliments by suction, with the playing upon wind instruments, and with the expression of the countenance. I shall here only notice the shutting of the mouth.

This may be accomplished simply by the approximation of the jaws, which is followed by a corresponding motion of the lips. In active occlusion, or that dependant on the orbicularis, two things may happen: either the lips may be closely drawn against the teeth, and their free edges applied to each other, or they may be pushed forward and puckered; in the latter case, the buccal opening, which is usually represented by a transverse line, resembles a circular, or, rather, a lozenge-shaped orifice.

The Buccinator.

Dissection.—Distend the cheeks by stuffing the mouth with tow; make a transverse incision through the skin, from the commissure of the lips to the masseter muscle, and dissect back the flaps: in order to gain a good view of the posterior border of the muscle, turn downward the zygomatic arch and the masseter, and then divide with the saw the inferior maxilla in front of the ramus.

The *buccinator* (*fig.* 113, and *b*, *figs.* 114 and 147) is the proper muscle of the cheek; it is broad, thin, and irregularly quadrilateral. It is attached *above* to the external surface of the superior alveolar arch, along the space between the first great molar and the tuberosity of the maxilla; *below*, to the external surface of the inferior alveolar arch, or, rather, to that part of the external oblique line of the lower jaw which corresponds with the last two great molars; and *behind*, to an aponeurosis existing between this muscle and the superior constrictor of the pharynx (see *fig.* 147). This aponeurosis, to which the name of buccinato-pharyngeal has been given (*pterygo-maxillary ligament*), extends from the apex of the internal pterygoid process to the posterior extremity of the internal oblique line of the lower jaw. From these different origins the fleshy fibres proceed forward, the upper somewhat obliquely downward, the lower obliquely upward, and the middle fibres horizontally. In consequence of this arrangement, the fibres intersect each other opposite the commissure of the lips, from which points the lower fibres of the muscle proceed to terminate in the upper half of the orbicularis, while the upper fibres end in the lower half of the same muscle.

Relations.—It is situated deeply behind, where it is covered by the ramus of the lower jaw, the masseter, and a small part of the temporal muscle; from all these parts, however, it is separated by a considerable quantity of adipose tissue, and by a mass of fat which exists even in the most emaciated individuals. More anteriorly it is covered by

the zygomaticus major and the zygomaticus minor, and the risorius of Santorini, where the two latter exist; and at the commissure it is covered by the canine muscle (*levator anguli oris*) and the triangularis. The Stenonian duct runs along this muscle before passing through it; the buccal nerves and the branches of the transverse facial artery lie parallel to its fibres; the external maxillary (*i. e.*, the facial) artery and vein pass perpendicularly across it, near the commissure. A peculiar aponeurosis, called the *buccal* fascia, is closely united to it, and intervenes between it and all these parts. It covers the mucous membrane of the cheek, from which it is separated by a dense layer of the buccal mucous glands.

Action.—It is the most direct antagonist of the orbicularis. When the cheeks are not distended, its contraction elongates the opening of the mouth transversely, and, consequently, renders the lips tense, and produces a vertical fold upon the skin of the cheek. This fold becomes permanent in the aged, and constitutes one of their most prominent wrinkles.

When the cheeks are distended by air, or any other substance, the buccinator becomes curved instead of flat, and acquires all the properties of the former class of muscles. Thus the first effect of its contraction is, that its fibres become straight, or have a tendency to become so; gaseous, liquid, or solid bodies, are then expelled from the mouth, rapidly if the orbicularis offer no obstacle, and gradually should that muscle contract. The buccinator, therefore, fulfils an important office in performances upon wind instruments, and hence its name (*buccinare*, to sound the trumpet). In mastication it is of no less importance, since it pushes the food between the teeth, and expels it from the sort of groove existing between the cheeks and the alveolar arches.

The Levator Labii Superioris.

Dissection.—Reflect the lower half of the orbicularis palpebrarum upward, and dissect with care the lower extremity of the muscle about to be described, which adheres closely to the skin. It can be best studied from the inner surface.

This muscle (*c'*, *fig.* 114) is thin and quadrilateral. It is situated upon the same plane as the common elevator, of which it appears to be a continuation, and extends from the base of the orbit to the skin of the upper lip.

It *arises* from the inner half of the lower edge of the base of the orbit, on the outer side of the common elevator: from this origin, which is sometimes bifid, the fibres converge downward and inward, and are *inserted* successively into the skin, probably into the bulbs of the hairs, as in animals which have mustaches; so that this muscle would deserve the name of *mustachie*, which is given by some anatomists to the naso-labial of Albinus.

Relations.—Its two upper thirds are deeply seated; its lower third adheres closely to the skin. It is worthy of notice, that almost all the muscles of the face are deeply seated at one of their extremities, and terminate by the other in the skin. It is covered by the orbicularis palpebrarum and the skin, and it covers the infra-orbital vessels and nerves, as they escape from the infra-orbital canal. It is also in relation with the canine muscle, from which it is separated by a quantity of adipose tissue, with the transversalis nasi, and with the orbicularis oris, being interposed between the latter muscle and the skin.

Action.—It raises the upper lip, and draws it a little outward.

The Caninus.

Dissection.—Merely reflect the levator labii superioris.

The canine muscle (levator anguli oris, *Albinus*, *d*, *fig.* 114), so named from its origin, arises from the canine fossa by a broad attachment, from which it proceeds downward and a little outward, diminishing in size, and becoming gradually more superficial, to the commissure of the lips, where it terminates by uniting with the zygomaticus major, and becoming continuous with the triangularis oris. We often find some accessory fibres arising from this muscle, and attached to the skin opposite the commissure.

Relations.—Above, it is concealed by the levator labii superioris and the infra-orbitary vessels and nerves; below, it is quite superficial, being only covered by the skin. It covers the superior maxilla, the buccinator, and the buccal mucous membrane.

Action.—It raises the angle of the mouth, and, from its oblique position, draws it inward.

The Zygomatici Major et Minor.

Dissection.—Make an oblique incision from the malar bone to the commissure of the lip, and remove carefully, from the great zygomatic, the fatty tissue which surrounds it.

The Zygomaticus Major.

This muscle (*m'*, *fig.* 113) is a cylindrical, fleshy fasciculus, extending from the malar bone to the commissure of the lip. It *arises*, by tendinous fibres, from the entire length of a horizontal furrow, situated above the lower edge of the malar bone. The fleshy fibres approach each other so as to form a fasciculus, which passes obliquely downward

and inward towards the commissure, where it is closely united to the canine muscle, and, like it, is continuous with the triangularis or depressor anguli oris.

Relations.—It is covered by the skin, from which it is separated above by the orbicularis palpebrarum, and below by a large quantity of adipose tissue; it covers the malar bone, the masseter and buccinator muscles, a great collection of fat, and the labial vein.

Action.—It draws the angle of the mouth upward and outward; by carrying the commissure upward, it assists the canine muscle, but in drawing it outward, it antagonizes the same. When the zygomatic and canine contract together, the commissure is drawn directly upward.

The Zygomaticus Minor.

This small muscle (*n'*, *fig.* 113), which is often wanting, may be regarded as a dependance of the proper elevator of the upper lip. It arises from the malar bone, above the great zygomatic, passes downward and inward to the outer border of the levator labii superioris, with which it is blended. It is not uncommon to find this muscle enlarged by fasciculi given off from the outer and lower circumference of the orbicularis muscle of the eyelids. It is covered by the skin and the orbicularis palpebrarum; and it covers the canine muscle and the labial vein.

Action.—It assists the common elevator in raising the upper lip and drawing it somewhat outward.

The Triangularis, or Depressor Anguli Oris.

Dissection.—Make a vertical incision of the skin, from the commissure of the lips to the base of the jaw; then follow the course of the muscular fibres as they are successively exposed.

This muscle (*o'*, *fig.* 113) is of a triangular shape, as its name implies, and belongs to the inferior maxillary region. It *arises*, by a broad base within, from the lower border of the inferior maxilla on the side of the median line, and sometimes from the median line itself; and without, from the external oblique line: from these points the fibres pass in different directions, the external almost vertically upward, the internal obliquely upward and outward (the obliquity increasing as we proceed inward), and describing a curve with the concavity looking inward. All these fibres are concentrated into a narrow and thick fasciculus, which terminates at the commissure, on a plane anterior to the fibres of the buccinator and the orbicular oris, being evidently continuous with the canine and the great zygomatic.

Relations.—It is covered by the skin, beneath which it is clearly discernible, and it covers the quadratus menti, the platysma, and the buccinator. Some colourless fibres, which intersect those of the quadratus at a right angle, and, moreover, follow the same direction as those of the triangularis, may be regarded as a dependance of that muscle, to the inside of which they are situated. They terminate in the skin, like those of the quadratus.

Action.—It depresses the angle of the mouth, thus antagonizing the canine muscle and the great zygomatic, with which it is continuous. The continuity of these muscles is so manifest, that they may be regarded as constituting a single muscle, broad and triangular below; bifid above, to form the canine and zygomatic; and narrow in the middle, where it corresponds to the commissure. The internal fibres of the triangularis, from their oblique direction, are directly opposed to those of the canine muscle; but its external fibres have not a similar relation to those of the zygomaticus major.

The Quadratus Menti, or Depressor Labii Inferioris.

Dissection.—Dissect back the skin covering this muscle, cutting obliquely downward and outward.

The *quadratus menti* (*p'*, *fig.* 113; *q'*, *fig.* 114), situated to the inside of the preceding, is of a square, or, rather, lozenge shape. It *arises* from the external oblique line of the lower jaw, and is in a great measure continuous with the platysma, the fibres of which pass behind, and sometimes through the triangularis. From this origin it proceeds obliquely upward and inward, therefore in an opposite direction to the triangularis, and is *inserted* into the skin of the lower lip, on a plane anterior to the corresponding half of the orbicularis oris. It is closely united to the skin, and covers the lower jaw, the mental nerve and vessels, the lower half of the orbicularis oris, and the muscle next to be described, with which it is intimately connected. It is separated from the muscle of the opposite side by the prominence of the chin below, but is blended with it above.

Action.—It depresses the lower lip: from the obliquity of this muscle, it also draws outward and downward each half of the lower lip, which is therefore stretched transversely.

The Levator Labii Inferioris.

Dissection.—Evert the lower lip; divide the mucous membrane at its reflection upon the lip from the lower jaw, so as to expose the origin of the muscle. In order to show its cutaneous insertion, carefully dissect off the skin covering the chin. As the muscles of each side are blended in the median line, it is necessary to make a vertical incision from before backward, opposite the symphysis, in order to separate them.

This muscle (levator menti, *Alb.*, *r'*, *fig.* 114) is a small conoid fasciculus, which forms, in a great measure, the prominence of the chin. It *arises* from the facette on the side of the symphysis menti, opposite the incisor teeth, whence the name incisif inférieur, *Winslow*, which is also given to this muscle. From this point the fibres expand like a tuft, downward and forward, to be *inserted* into the skin. It is red and fasciculated at its origin above, but pale, intermixed with fat, and not fasciculated below, where it is blended on the inside with the opposite muscle, and on the outside with the quadratus menti. Its upper fibres form a concavity above, which partially embraces the great circumference of the lower half of the orbicularis oris.

Action.—It raises and wrinkles the skin of the chin, and, consequently, raises the lower lip, and projects it forward. It appears somewhat singular at first that an elevator of the lip should be situated below it.

General Considerations regarding the Movements of the Lips, and those of the Face in general.

If we take a general view of the muscles of the face, we shall observe, 1. That no region is provided with so great a number of muscles; 2. That all these muscles are attached to a bone by one extremity, while the other is implanted into the skin, or into other muscles; 3. That the cutaneous portion of these muscles is colourless and non-fasciculated, presenting all the characteristics of involuntary muscles;* 4. That those portions which are attached either to the bone or to other muscles have, on the contrary, all the characters of the voluntary muscles.

All these muscles are arranged around the several openings of the face, and, consequently, they are either constrictors or dilators; the orifice of the mouth, however, is peculiar† in having the greater number of the muscles of the face specially intended for it. Indeed, the orbicularis oris, or sphincter of the mouth, is antagonized by the buccinators or transverse dilators; by the proper elevators of the upper lip, and the common elevators of that and the alæ of the nose; by the depressors of the lower lip, or quadrati; by the elevators of the angle of the mouth, viz., the canine muscles, the zygomatici majores, and, where they exist, the zygomatici minores, and the two risorii of Santorini; and, lastly, by the depressors of the commissure, or triangulares oris.

The lips fulfil a great number of uses, all requiring a considerable degree of mobility. They serve for the prehension of aliments, for suction, and for the articulation of sounds, whence the name *labial* given to consonants specially produced by the action of the lips, as *b*, *p*, *m*: they modify the state of the expired air so as to produce in it vibrations of a peculiar character, constituting the act of whistling; and, in this respect, they illustrate the mechanism of the glottis: they assist in mastication, by retaining the food and constantly forcing it between the teeth: they are also employed, during performances upon wind instruments, in regulating the volume of the column of air which strikes upon the body to be thrown into vibrations. The mechanism of their action varies according to the kind of instrument: sometimes, for example, they assist in graduating the rapidity of the column of air, by influencing the orifice through which it issues, as occurs in playing upon the flute; and sometimes they represent vibrating cords situated at the mouth of an instrument, and determining the different tones by their various degrees of tension. In this case, the lips themselves become the vibrating bodies, and propagate their oscillations to other bodies with which they are in contact, independently of the effect produced in the instrument from the passage of a column of air. Examples of this are observed in playing on the horn, trumpet, &c.

If we examine the muscles of the face in connexion with their influence in producing emotional expressions, we shall find that they are often almost completely removed from the influence of the will, as, for example, where those emotions are not simulated; but that sometimes, on the contrary, their contraction is altogether voluntary, as in those individuals who, either by profession or habit, are accustomed to imitate feelings which they do not really experience. Nevertheless, it should be remarked that, although the outward expression of every passion may be produced at will upon the face, yet there is always a great difference between the natural emotion and the fictitious representation.

On the whole, the general expressions of the countenance may be regarded as varieties of two great types, viz., those of the cheerful and those of the melancholy emotions.

* This similarity is limited, however, to the colour and general aspect of the two kinds of muscles; for even the palest muscular fasciculi of the face are found to consist of *striated* fibres, precisely similar to those of the other voluntary muscles; but the fasciculi into which they are collected are neither so evident nor so large.

† Man greatly exceeds all animals in the number of muscles attached to his lips. The ape, which is remarkable for the great mobility of its physiognomy, has, properly speaking, only one muscle for the entire face, which is a dependance of the platysma (or cutaneous muscle); therefore, the play of its countenance is confined to a grimace, which is always the same, only differing in intensity, and which does not permit it to express different and even opposite passions, such as are often depicted upon the human countenance.*

* [The platysma myoides in monkeys is certainly extended, as a single muscle, over the entire cheek, and forms a muscular layer, covering the lateral pouches appended to the mouth in some of that tribe of animals. In addition to this, however, monkeys have precisely the same number of muscles attached to their lips as in the human subject: they possess, indeed, all the facial muscles found in man; and, like him, they appear to be capable of expressing, by changes in their features, a variety of internal emotions.]

The cheerful emotions are expressed by the expansion of the features, *i. e.*, their retraction from the median line, a movement that is due to the occipito-frontalis, the levatores palpebrarum, and especially to the great zygomatic muscles. The melancholy passions, on the contrary, are expressed by the approach or concentration of the features towards the median line, which is chiefly effected on either side of the face by the corrugator supercilii, the depressor anguli oris, the common and proper elevators of the upper lip, the levator labii inferioris, and the quadratus menti.

On account of the intimate connexion between the skin of the face and the facial muscles, which, from the nature of their insertions, are in some measure identified with it, the frequently-repeated contraction of one or more of these muscles occasions folds or wrinkles of the skin that remain during the intervals of those contractions, and after they have entirely ceased. And thus the continual experience of grave or cheerful emotions, with their characteristic expressions of countenance, at length impresses a peculiar and permanent stamp upon the features, so that those who are in the habit of closely observing such circumstances may in some degree judge of the disposition of an individual from an examination of his physiognomy. This is the only foundation of the system of Lavater.

MUSCLES OF THE TEMPORO-MAXILLARY REGION.

The Masseter and Temporalis.

The muscles of this region are four in number; two on each side, viz., the masseter and the temporal.

The Masseter.

Dissection.—Make a horizontal incision along the zygoma, and a vertical one from the middle of this to the base of the jaw; dissect back the flaps, taking care not to divide the Stenonian duct, which passes over the muscle. In order to see the deep surface, saw through the zygoma in two places, and turn it outward.

The *masseter* (*s*, *fig.* 113) is a short and very thick muscle, of an irregularly-quadrilateral form, situated upon the side of the face.

Attachments.—It *arises* from the lower edge of the zygoma, and is *inserted* into the outer surface of the angle and ramus of the lower jaw. Its origin from the zygoma consists of a very thick aponeurosis, which embraces the anterior borders of the muscles, and is composed of several planes of super-imposed fibres, which are prolonged upon its surface and in its substance for a considerable distance. The fleshy fibres proceed from the inferior surface and the borders of this aponeurosis, obliquely *downward* and *backward*, and are inserted into the angle of the jaw either directly or by means of very strong tendinous fibres. Not unfrequently a small triangular fasciculus is detached forward to the inferior border of the body of the bone. The fleshy fibres arising from the posterior portion of the zygoma constitute a short, small, and almost entirely fleshy bundle, which passes *vertically* downward, and is inserted behind the preceding into the external surface of the ramus of the jaw. Lastly, the zygomatic arch being reversed, we see a still smaller fleshy fasciculus, arising directly from its internal surface, and passing *forward*, to be inserted into the outer surface of the coronoid process, and into the tendon of the temporal muscle.

Relations.—It is covered by the skin, from which it is separated by a small fascia, and sometimes by a prolongation of the platysma; behind, it is covered by the parotid gland, and by the orbicularis palpebrarum and zygomaticus major above. It is crossed at right angles by the divisions of the facial nerve, the transverse artery of the face, and the Stenonian duct. It covers the ramus of the jaw, the temporal and the buccinator muscles, from the latter of which it is separated by a collection of fat. Its anterior edge, which is prominent beneath the skin, has an important relation below to the facial artery, which may be compressed against the bone immediately in front of it. The parotid gland embraces its posterior border.

Action.—The action of this muscle is very powerful. Its strength in different animals may be in some degree measured by the size of the zygomatic arch, and by the prominence of the lines and projections on the angle of the jaw.

Its momentum, *i. e.*, its period of most powerful action, occurs when the jaws are slightly separated, because its angle of incidence with regard to the lever is then nearly perpendicular. The general direction of the fibres of the masseter muscles, obliquely downward and backward, is highly advantageous as regards the trituration of the food, for during the contraction of the two muscles the lower jaw is moved upward and forward. This same obliquity explains the action of the muscle in producing luxation of the jaw; for as its insertion is farther back than it would have been had the fibres been vertical, it follows that, however slightly the jaws may be separated, the condyle is placed in front of the axis, to which all the fibres of the masseter may be referred; and when this muscle contracts, it increases the peculiar movement performed by the condyle in becoming dislocated forward.

The Temporalis.

Dissection.—Having sawn through and turned back the zygoma, remove the fascia covering the temporal region, and the fat surrounding the insertion of the muscle into the coronoid process. In order to gain a view of the deep surface, detach the muscle, either from above downward, by scraping the periosteum from the temporal fossa, or from below upward, after having sawn through the base of the coronoid process.

The *temporal* muscle (*e'*, *fig.* 114), or *crotaphyte*, so named because it occupies the whole of the temporal fossa (κρόταφος, the temple), is a broad, radiated muscle, resembling a triangle with the base turned upward.

Attachments.—It *arises* from the whole extent of the temporal fossa, and from the inner surface of the superficial temporal fascia, and is *inserted* into the edges and summit of the coronoid process. The fleshy fibres all arise directly, either from the temporal fossa, or from the inner surface of the fascia, which, being attached above to the entire length of the temporal semicircular line, and below to the upper edge of the zygomatic arch, is very tense, and thus affords a solid and very strong surface of origin. From these two parts the fleshy fibres converge, and proceeding downward, the anterior obliquely backward, the posterior obliquely forward, and the middle vertically, form a fleshy mass, which gradually increases in thickness until its fibres are attached, partly to the external, but chiefly to the internal surface and borders of the terminal aponeurosis. The fibres of this aponeurosis, which are very strong, and radiated at its commencement, are collected into the form of a very thick tendon, inserted into the coronoid process, and called the *coronoid tendon.* The temporal muscle, in its course from the temporal fossa to the coronoid process, undergoes a sort of reflection over the groove at the base of the zygoma. I have often seen a very strong muscular fasciculus arising from the lower part of the temporal fossa and the ridge bounding it below, and inserted by a separate tendon into the internal border of the anterior surface of the ramus of the jaw.

Relations.—It is covered by the skin, the aponeurosis of the occiplto-frontalis, the anterior and superior auricular muscles, the superficial temporal arteries, veins, and nerves, and more immediately by the superficial temporal aponeurosis, the zygomatic arch, and the masseter. It covers the temporal fossa, the external pterygoid muscle, a small part of the buccinator, the internal maxillary artery, and the deep temporal vessels. Its thickness is in proportion to the depth of the temporal fossa and the strength of the coronoid process.

Action.—The strength of the temporal muscle, therefore, may be in some degree measured by the depth of the temporal fossa and the size of the coronoid process. This fact may be demonstrated by an examination of these regions in the skeletons of carnivorous animals, in which the elevators of the lower jaw are most highly developed. The use of the temporal muscle, like that of the masseter, is to elevate the lower jaw, but the mechanism of its action is different. In fact, the masseter raises the jaw by a direct action; the temporal muscle, on the contrary, raises it by a sort of *swing motion*, acting principally upon the back part of the coronoid process. In a word, the temporal muscle acts upon the vertical arm of the bent lever represented by the maxillary bone, while the masseter, on the contrary, acts upon its horizontal arm, the movement depending on the action of the temporal muscle: the lower jaw resembles the curved lever represented by the *hammer* of a bell.

THE PTERYGO-MAXILLARY REGION.

The Pterygoideus Internus.—The Pterygoideus Externus.

The muscles of this region are the external and the internal pterygoids.

Fig. 115

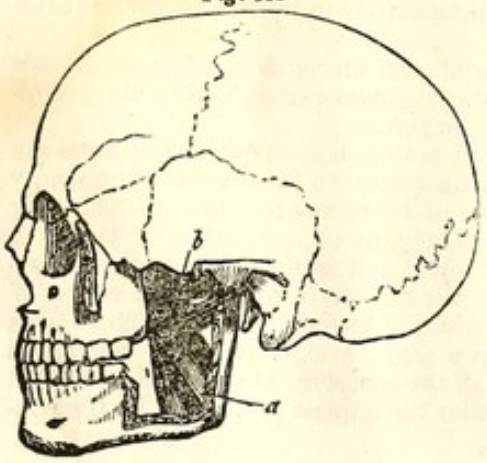

The Pterygoideus Internus vel Magnus.

Dissection.—Separate the face and that part of the cranium which is situated anterior to the vertebral column from the remainder of the scull, and divide the face into two lateral halves by an antero-posterior section.

This muscle may also be dissected in the following manner: saw through the lower jaw vertically at the junction of the body and ramus; remove the zygomatic arch; cut through the base of the coronoid process and the neck of the condyle, and then disarticulate the latter.

The *internal pterygoid* (*a*, *fig.* 115) is deeply seated in the zygomatic fossa, along the inner surface of the ramus of the jaw (tertius musculus qui in ore latitat, *Vesalius*). It is thick and quad-

rilateral, and in its form, structure, and direction, bears a remarkable resemblance to the masseter; hence Winslow called it the *internal masseter*.

Attachments.—It *arises* from the pterygoid fossa, from the hamular process, at the apex of the internal pterygoid plate, and from the lower surface of the pyramidal process of the palate bone; and is *inserted* into the inner surface of the angle of the lower jaw. Its origin consists of a tendon resembling that of the masseter, prolonged upon the internal surface, and into the substance of the muscle. From this the fleshy fibres proceed *downward*, *outward*, and *backward*, to be inserted, by very strong tendinous laminæ, into the lower jaw.

Relations.—On the inside it is in relation with the external peristaphyline muscle (*tensor palati*), and with the pharynx, a triangular interval existing between it and the latter, occupied by a considerable quantity of cellular tissue, vessels, nerves, and the sub-maxillary gland: on the outside it corresponds with the ramus of the lower jaw, from which it is separated above by the dental and lingual nerves, the inferior dental vessels, and the so-called internal lateral ligament of the temporo-maxillary articulation.

Action.—As this muscle is inserted almost perpendicularly into the lever upon which it acts, it has very great power. Most of the remarks already made concerning the massetor apply to this muscle, which is a true internal masseter. It has only this peculiarity, that as its origin is nearer the median line than that of the external masseter, it assists in producing a slight lateral movement of the jaw, which is very useful in bruising the food.

The Pterygoideus Externus vel Parvus.

Dissection.—This, like the preceding muscle, may be exposed by two opposite methods.

The *external pterygoid* (*b*, *fig.* 115) is very short, thick, and conoid, smaller than the preceding, and situated in the zygomatic fossa, extending horizontally from the outer surface of the external pterygoid plate to the neck of the condyle of the lower jaw. It *arises* from the whole outer surface of the external plate of the pterygoid process, and from the facette of the palatine process, at which it terminates below, from the ridge separating the temporal and zygomatic fossæ, and from a spinous process at the extremity of this ridge, which appears to me worthy of notice. It is *inserted* into the fossa in front of the neck of the condyle of the lower jaw, and into the border of the interarticular cartilage. Its origin consists of a strong tendon, prolonged into the substance of the muscle. From this the fleshy fibres proceed horizontally *outward* and *backward*, forming, at first, two distinct portions, between which the internal maxillary artery often passes: these two portions then converge, are blended together, and terminate by some small tendinous fibres, which form the truncated summit of the cone represented by the muscle, and are attached to the neck of the condyle and to the inter-articular cartilage.

Relations.—This muscle is deeply situated, and is in relation on the outside with the ramus of the lower jaw, the temporal muscle, and the internal maxillary artery; on the inside with the internal pterygoid, and above with the upper wall of the zygomatic fossa.

Action.—The axis of the external pterygoid being directed outward and backward, and its origin being at the pterygoid process, it may be readily imagined that its contraction will produce a horizontal motion in two directions, viz., forward and to the opposite side from that on which the muscle is acting. When the two external pterygoids act together, the jaw is carried directly forward. From the insertion of this muscle into the inter-articular cartilage, the latter is never separated from the condyle during these several movements. It is principally this muscle which causes displacement of the condyle in cases of fracture of the neck of the bone, and it is also the chief agent in bruising the food.

MUSCLES OF THE UPPER EXTREMITIES

The muscles of the upper extremities may be divided into those of the shoulder, of the arm, of the forearm, and of the hand.

MUSCLES OF THE SHOULDER

The Deltoideus.—Supra-spinatus.—Infra-spinatus and Teres Minor.—Subscapularis.

The muscles of the shoulder are the deltoid, the supra-spinatus, the infra-spinatus and teres minor (which I regard as only one muscle), and the subscapularis. The teres major, generally arranged among the muscles of this region, has already been described with the latissimus dorsi, of which it may be regarded as an accessory.

The Deltoideus.

Dissection.—Make a horizontal incision through the skin, round the summit of the shoulder, extending from the external third of the clavicle to the most distant point of the spine of the scapula: from the middle of this incision let another be made, descend-

ing vertically half way down the humerus; dissect back the two flaps, taking care to raise at the same time a very thin aponeurosis, which is closely applied to the fibres.

The *deltoid* (*l*, *figs.* 106, 109), so named from its resemblance to the Greek *delta*, Δ, reversed, is a thick, radiated, triangular muscle, bent in such a way as to embrace the scapulo-humeral articulation before, on the outer side and behind. It is the muscle of the top of the shoulder.

Attachments.—It *arises* from the entire length of the posterior border of the spine of the scapula, from the external border of the acromion, and from the external third, *i. e.*, from the concave part of the anterior border of the clavicle: it is *inserted* into the deltoid impression on the humerus. The scapulo-clavicular origin of the deltoid corresponds exactly to the inferior attachment or the insertion of the trapezius, so that these two muscles, although separate and distinct in man, appear to form a single muscle divided by an intersection: a view that is perfectly confirmed by a reference to comparative anatomy. The origin consists of tendinous fibres; of these the posterior are the longest, and are blended with the infra-spinous aponeurosis, which also gives origin to some of the fibres of the deltoid. Three or four principal tendinous laminæ, attached at regular intervals to the clavicle and the acromion, penetrate into the substance of the muscle, and give origin to a great number of fleshy fibres. The largest of these laminæ extends from the summit of the acromion, and its situation is sometimes indicated by a prominence of the skin, particularly during contraction of the muscle. From this very extensive origin the fleshy fibres proceed downward, the middle vertically, the anterior backward, and the posterior forward: they form a thick, broad mass, moulded over the top of the shoulder, and, gradually converging, are at length inserted into the deltoid impression of the humerus by three evry distinct tendons, the two principal of which, the anterior and posterior, are attached to the bifurcations of that V-shaped impression. Not unfrequently some fibres of the pectoralis major are connected with the front of this tendon.

Relations.—It is covered by the skin, the platysma intervening between them, by some supra-acromial nerves, and by a thin fascia extending from the infra-spinous aponeurosis, the spine of the scapula and the clavicle, and becoming continuous with the fascia of the arm. It covers the shoulder-joint, from which it is separated by a tendinous layer continued from the infra-spinous and coraco-acromial ligaments, and which terminates on the sheaths of the coraco-brachialis and biceps muscles. Between this lamina and the greater tuberosity of the humerus there is a quantity of filamentous cellular tissue, and frequently a synovial bursa. The deltoid, therefore, is enclosed in a proper fibrous sheath, and glides over the articulation. It also covers the upper third of the humerus, the coracoid process, the tendons of the pectorales, coraco-brachialis, biceps, supra-spinatus, infra-spinatus and teres minor, teres major, and biceps muscles, also the circumflex vessels and nerves. The anterior border of the deltoid, directed obliquely downward and outward, is separated from the external margin of the pectoralis major by a cellular interval, but is frequently in contact with it. The cephalic vein and a small artery define the limits of the two muscles. The posterior border is thin above, where it is applied to the infra-spinatus muscle, and becomes thick and free below. The inferior angle of the deltoid is embraced by the brachialis anticus. Issues are generally established over this situation.

Remark.—The structure of this muscle has been patiently investigated by some anatomists, who have counted the exact number of its component fasciculi. These are separated by fibro-cellular prolongations, like the fasciculi of the glutæus maximus; sometimes, even, the muscle is divided into three distinct portions above, viz., a clavicular, an acromial, and a spinal. Eighteen or twenty small penniform fasciculi, the bases of which are generally turned upward, are collected into a small space by mutually overlapping each other, and are united by their terminating tendons. Albinus admits ten of these bundles, which he has described separately.

Action.—The deltoid elevates the shoulder (*elevator, attollens humerum*). From the threefold direction of its fibres, it has a different action, according to the particular set of fibres employed. The middle fibres raise the humerus directly, the anterior raise and carry it forward, the posterior raise and carry it backward. When the arm is raised, Bichat states that the anterior and posterior fibres can depress it; but I do not think this possible. There has been no example recorded of luxation from the over-action of this muscle. When the arm is fixed, as in the act of climbing, the shoulder is moved upon the head of the humerus. The trapezius must be regarded as the most powerful antagonist of the deltoid, since the scapulo-clavicular attachments of both muscles are the same. Thus, we have seen that the diaphragm and the transversalis abdominis are separated only by their costal insertions. The most complete antagonism follows from such an arrangement, for then one fibre is, as it were, opposed to another, having exactly an opposite direction.

The action of the deltoid is, however, less powerful than might have been supposed from its size; it is, in fact, parallel to the lever on which it acts. While almost all other muscles have a *momentum*, occurring at the period when their fibres are inserted at the

most favourable angle, the deltoid, properly speaking, has none; it is parallel to the lever during the entire period of its action. This is the reason why the elevation of the arm is so feeble a movement, and why contraction of the deltoid is always accompanied by considerable fatigue.

The Supra-spinatus.

Dissection.—Take off the trapezius, and, in order to see the whole extent of the muscle, remove the clavicle, and saw through the base of the acromion.

The *supra-spinatus* (*r*, *fig.* 106) is a thick, triangular muscle, broad on the inside, narrow without, occupying the supra-spinous fossa, and retained therein by a strong aponeurosis, which completes the osteo-fibrous sheath in which the muscle is enclosed.

Attachments.—It *arises* from the internal two thirds of the supra-spinous fossa, and is *inserted* into the highest of the three facettes on the greater tuberosity of the humerus. Its origin from the supra-spinous fossa is partly tendinous and partly fleshy, and some fibres arise from its aponeurotic investments. From these points the fleshy fibres converge to a tendon, which is found among them where the muscle reaches the upper part of the joint, and which is slightly reflected over the head of the humerus before reaching its insertion. This has not the shining appearance of other tendons, but has the dull aspect of many ligaments; it is blended with the fibrous articular capsule, from which it cannot be separated near its insertion. It may even be regarded as forming the upper part of the capsular ligament.

Relations.—It is covered by the trapezius, the clavicle, the coraco-acromion ligament, and the deltoid; and it covers the supra-spinous fossa, the supra-scapular vessels and nerves,* and the upper part of the shoulder-joint. Its tendon is often blended with that of the infra-spinatus, and is separated from that of the sub-scapularis by the long head of the biceps, and the accessory ligament of the capsule.

Action.—It raises the humerus, and therefore assists the deltoid. Notwithstanding the number of its fibres, and its perpendicular insertion into its lever, it has very little power, on account of the proximity of that insertion to the fulcrum. Its principal action appears to me to have reference to the joint, affording a support to it above, and forming a sort of active arch, the resisting power of which is in proportion to the force tending to thrust the humerus upward against the osteo-fibrous arch, composed of the acromion and coracoid processes and their connecting ligament. There is no muscle, then, to which the name of *articular* can be more correctly applied. The use of the deep fibres in preventing the folding of the fibrous and synovial capsules, and their compression between the two articular surfaces, though much insisted on by Winslow, appears to me very problematical.

The Infra-spinatus and Teres Minor.

Dissection.—Detach the scapular origin of the deltoid, and saw through the base of the acromion.

The *infra-spinatus* (*s*) and *teres minor* (*t*, *fig.* 106) constitute a single, thick, triangular muscle, broad on the inside and narrow externally, and occupying the infra-spinous fossa, in which it is retained by an aponeurosis, exactly resembling that of the supra-spinatus muscle.

It *arises* from the internal two thirds of the infra-spinous fossa, from a very strong fascia interposed between it and the teres major and long head of the triceps, and by a few fibres from the infra-spinous aponeurosis: it is *inserted* into the middle and inferior facettes on the greater tuberosity of the humerus, below the insertion of the supra-spinatus. It arises from the infra-spinous fossa, directly by fleshy fibres, and also by means of tendinous fibres attached along the ridges of that fossa. One of these laminæ is constantly found attached to the ridge situated on the outer side of the infra-spinous groove: this has doubtless given rise to the division of the muscle into two parts, called the infra-spinatus and the teres minor. From these origins the fleshy fibres proceed, the superior horizontally, the next obliquely, and the inferior almost vertically outward: they form a thick, triangular, fleshy body, and become attached to the anterior surface and margins of a flat tendon, which glides upon the concave humeral border of the spine of the scapula, to be inserted into the humerus. Not unfrequently we find the lower fibres of the portion called the teres minor, arising from the posterior surface of the tendon of the triceps, becoming applied to the under part of the capsular ligament, and inserted into the humerus immediately below the great tuberosity.

Relations.—These two united muscles are covered by the deltoid, the trapezius, the latissimus dorsi, and the skin; and they cover the infra-spinous fossa, from which they are separated by the supra-scapular nerves and vessels; they also cover the capsular ligament of the joint, and a small portion of the long head of the triceps. Their lower or external border corresponds internally or inferiorly with the teres major, an aponeurotic septum intervening between them, and externally or superiorly with the long head of the triceps.

* The supra-scapular nerve generally passes through the coracoid notch by itself, and the supra-scapular artery above the ligament.

Action.—This muscle rotates the humerus outward and a little backward. When the arm is raised, it assists in keeping it in this position, and carries it backward. But an important use of this muscle is that of retaining the head of the humerus in its place, preventing its displacement backward, and protecting the posterior part of the articulation.

The Sub-scapularis.

Dissection.—Detach the upper extremity, including the shoulder, from the trunk of the body; remove from the inner surface of the muscle the cellular tissue, the lymphatic glands, the brachial plexus, the axillary vessels, and the serratus magnus; and dissect off, with care, the thin fascia which invests it.

The *sub-scapularis* (*o*, *figs.* 110, 116) is a thick triangular muscle, occupying the whole of the sub-scapular fossa, beneath the axillary border of which it passes: by itself it represents the supra and infra spinatus and teres minor, upon the posterior scapular region. We not unfrequently meet with tendinous laminæ dividing it into three parts, which correspond to those three muscles.

Attachments.—It *arises* from the internal two thirds of the sub-scapular fossa, by tendinous laminæ attached to the oblique ridges already described as existing on that part of the scapula; also from the anterior lip of the axillary border of the scapula by an aponeurosis, which separates this muscle from the teres major and the long head of the triceps. Very frequently the lowest fibres arise from the anterior surface of this head of the triceps, just as we have seen that the lower fibres of the teres minor take their origin from the posterior surface of the same head of that muscle. From these different origins the fleshy fibres all proceed outward, the upper horizontally, and the lower obliquely, gradually approaching more and more to the vertical direction. The muscle, therefore, becomes progressively narrower and thicker, until its fibres are attached to the two surfaces and borders of a tendon which is *inserted* into the entire surface of the lesser tuberosity of the humerus. Some of the muscular fibres are inserted below the tuberosity; and I have seen the inferior fibres of the muscle attached for a certain extent to a fibrous prolongation that completes the bicipital groove behind.

Relations.—The posterior surface of this muscle lines the sub-scapular fossa, which it entirely fills, and from which it is separated at the outer third by some cellular tissue and the sub-scapular vessels and nerves; more externally, it covers the upper and anterior part of the capsular ligament of the shoulder-joint, turning around it, and becoming identified with it at its insertion. Its *anterior surface* is in relation with the serratus magnus, the sub-scapular fascia, and some very loose cellular tissue intervening between them; also with the axillary vessels and nerves, and with the coraco-brachialis and deltoid muscles. The *upper border* of its tendon glides in the hollow of the coracoid process, which serves as a pulley, and forms with the coraco-brachialis and the short head of the biceps a sort of ring, partly bony and partly muscular, in which the tendon is retained. Between this tendon and the coracoid process there is also a synovial bursa, which sometimes extends over the tendons of the biceps and coraco-brachialis, and always communicates with the synovial capsule of the shoulder-joint.*

Action.—It is essentially a rotator inward of the humerus. In proof of this, we find that the muscle is stretched when the arm is rotated outward, and relaxed when it is rotated inward. The movement of rotation is much more considerable than the length of the neck of the humerus would lead us to imagine, and this arises from the muscle turning round the head of the bone. As a rotator muscle, then, it is congenerous with the latissimus dorsi. When the humerus is raised, the sub-scapularis tends to draw it downward. And farther, this muscle, as well as the supra-spinatus, infra-spinatus, and teres minor, is essentially an articular muscle, and is sometimes completely identified with the anterior part of the fibrous capsule: in all cases it offers an active resistance to displacement forward, and is, therefore, always torn in this kind of dislocation.

MUSCLES OF THE ARM.

The Biceps.—Brachialis Anticus.—Coraco-brachialis.—Triceps Extensor Cubiti.

THE muscles of the arm have been divided into those of the *anterior region*, viz., the biceps, the coraco-brachialis, and the brachialis-anticus; and those of the *posterior region*, which constitute the single muscle called the triceps.

ANTERIOR BRACHIAL REGION.

The Biceps.

Dissection.—Make a vertical incision through the skin from the middle of the clavicle to the middle of the bend of the elbow; dissect back the flaps, and divide longitudinally the brachial fascia, which is united to the biceps by very loose cellular tissue; preserve the vessels and nerves which lie along the inner border of the muscle. Expose the upper part of the muscle by detaching the pectoralis major and deltoid from their clavicu-

* See note, p. 22.

lar origins, and turning them inward and outward. In order to trace the whole extent of the long head of the biceps, open the capsular ligament above; and to see the radial insertion of the muscle, flex the forearm to a right angle upon the arm, and supinate it forcibly; it is better, however, to wait until the muscles of the anterior region of the forearm are dissected.

The *biceps flexor cubiti* (*a*, *fig.* 116) is a long muscle forming the superficial layer of the anterior region of the arm; it is divided above into a *short* and *long* head;* and hence its name *biceps*.

Fig. 116.

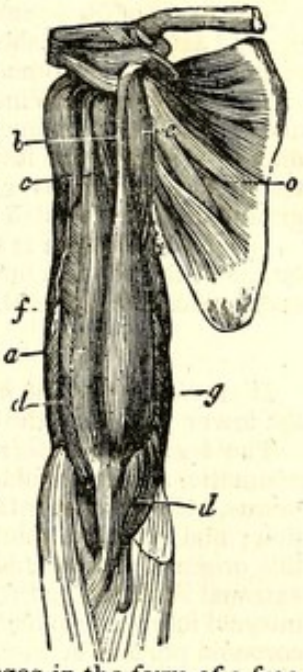

Attachments.—It *arises* by its short head from the apex of the coracoid process, and by its long head from the top of the glenoid cavity; and is *inserted* into the bicipital tuberosity of the radius.

The origin of the *short* or *coracoid* head (*b*, *fig.* 116) consists of a flat and very thick tendon, common to it and the coraco-brachialis, and terminating in front of this part of the muscle in an aponeurosis, from which is given off a tendinous septum, between the biceps and the coraco-brachialis. The *long*, *glenoid*, or *reflected* head arises by a tendon apparently forming a continuation of the glenoid articular border, which penetrates into the interior of the joint, turns over the head of the humerus, upon which it is reflected, and thus reaches the bicipital groove. It is retained in this groove by a sort of fibrous bridge or canal, traverses the whole of its extent, and ends in a sort of tendinous cone open behind, from the interior of which the fleshy fibres take their origin. These fibres are collected into a rounded belly, which, about the middle of the arm, is applied to the muscular belly of the short portion, equally rounded and of variable size, and ultimately becomes identified with it. The single muscle (*a*, *fig.* 116) thus formed is very thick, flattened from before backward, and directed vertically like the two original fasciculi. Its fibres are attached to the surfaces and edges of an aponeurosis, which gradually becomes narrower and thicker, until it emerges in the form of a free tendon opposite the lower end of the humerus, a little nearer to the outer than the inner side. This flattened tendon sinks downward and backward into the triangular space between the supinator longus and the pronator teres, and is then so folded and twisted upon itself that its anterior surface becomes posterior, its internal margin becomes anterior, and its external margin at first posterior and then superior. This folding and torsion are of extreme utility in preventing displacement of the muscle, which thus fastens down itself. The tendon of insertion having given off from its anterior surface and external margin a broad aponeurosis, constituting the principal origin of the fascia of the forearm, glides over the bicipital tuberosity of the radius, from which it is separated by a bursa, and is inserted into the posterior part of that process.

Relations.—The upper third of the two heads of the biceps, as well as the coraco-brachialis, and the axillary vessels and nerves, are contained in the cavity of the axilla, between the pectoralis major and the deltoid in front, and the latissimus dorsi and teres major behind. In this part of its course, the short head of the biceps is in relation with the coraco-brachialis on the inside, and behind with the sub-scapularis, which separates it from the shoulder-joint; a bursa intervenes between these two muscles. The tendon of the long head is in contact with the head of the humerus, and surrounded by the synovial membrane, which isolates it from the cavity of the joint, and accompanies it, for a greater or less distance, along the bicipital groove. Below the axilla the biceps is subcutaneous *in front*, the brachial fascia intervening between it and the skin, through which it is very clearly defined; *behind*, it is in relation with the musculo-cutaneous nerve, and the coraco-brachialis and brachialis anticus muscles; *on the inside*, with the brachial artery and its accompanying veins, and with the median nerve, all of which lie along its internal border, by the projection of which they are protected. The tendon is embraced at its insertion by the supinator brevis, and it is separated from that of the brachialis anticus by a bursa. Great attention should be paid to the relation of this muscle to the brachial artery. I am accustomed, when speaking of the surgical anatomy of these parts, to call the biceps the satellite muscle of the brachial artery. It is worthy of remark, that the relative positions of the long and the short head are altered as the humerus is rotated inward or outward; in rotation inward, the long head is placed behind the other, or even crosses to the inner side of it; but in rotation outward, the interval between the two heads is considerably increased.

Action.—The biceps flexes the forearm upon the arm, and at the same time supinates it. This last effect results from the insertion of the muscle into the inner and back part of the bicipital tubercle of the radius. The *momentum* of the biceps occurs during semi-

* Not unfrequently the biceps is trifid above. The supernumerary head is internal, and arises from the inner border of the humerus, below the coraco-brachialis, which may be regarded as the continuation of this head, for they correspond in size. This supernumerary portion is attached to the inner edge and posterior surface of the lower tendon of the biceps. I have twice seen this disposition of parts.

flexion of the forearm; its insertion being at that period perpendicular to the lever, the disadvantage arising from its proximity to the fulcrum is then counteracted. The length of its fibres explains the extent of the movement of flexion. By means of its scapular attachments, the biceps acts upon the arm, either secondarily, after bending the forearm, or primarily, when the forearm is extended. By means of both its heads, it carries the arm forward, and thus co-operates with the anterior fibres of the deltoid and coraco-brachialis. The two heads also assist in strengthening the shoulder-joint. The long head forms a sort of fibrous arch, which supports the head of the humerus, and retains it in the glenoid cavity. The short head, together with the coraco-brachialis, forms a continuation of the hook of the coracoid process, and protects the anterior and inner part of the joint.

The biceps is, as Winslow first showed, one of the principal supinators of the forearm; and it is in this movement that the tendon glides over the bicipital tuberosity of the radius by means of the intervening bursa. This tuberosity is almost entirely intended for the tendon to glide over; it is, therefore, incrusted with cartilage. Dense and reddish granulations, as pointed out by Haller, are found upon the synovial bursa of the tendon.

When the forearm is fixed, as in climbing, the biceps flexes the arm upon the forearm, and the scapula upon the arm. Lastly, it is a tensor of the fascia of the forearm. upon which the internal fibres of the muscle often terminate.

The Brachialis Anticus.

Dissection.—Cut the biceps across, opposite the insertion of the deltoid, and turn down the lower part upon the forearm.

The *brachialis anticus* (brachialis internus, *Alb.*, *d d*, *fig.* 116; *d*, *fig.* 117) is a thick, prismatic, and triangular muscle, situated behind the preceding. It *arises* from the humerus, below the insertion of the deltoid, which it embraces by a well-marked bifurcation; and since the point of insertion of the deltoid is not always the same, it follows that this origin of the brachialis anticus is also variable; it also arises from the internal and external surfaces, and from the three borders of the humerus, and from the external and internal inter-muscular septa. It is *inserted* into the rough surface on the fore part of the coronoid process of the ulna. The different origins from the humerus are fleshy, the fibres being of very various lengths, and proceeding in different directions; the middle pass vertically downward, the external somewhat obliquely inward, and the internal outward; they all terminate on the posterior surface of an aponeurosis, which is broad and thin above, and thick below, especially on the outer side, where it turns round so as to embrace the outer border of the muscle, and forms a deep aponeurotic lamina. The fleshy fibres, therefore, are received into a semi-cone of tendinous substance, open on the inside, the fibres of which are collected together, and finally inserted into an oblique line, running downward and outward, below the coronoid process of the ulna.

Relations.—The *anterior surface* of the brachialis anticus is in relation with the biceps, the musculo-cutaneous nerve, the brachial fascia, the brachial artery and veins, and the median nerve; its *internal surface*, with the pronator teres muscle, the ulnar nerve, and the triceps, from which it is only separated by the internal inter-muscular septum; its *external surface*, with the supinator longus and the extensor carpi radialis longior, which are received into a sort of groove presented by it, the radial nerve establishing the limit between these two muscles and the brachialis anticus. The *posterior surface* embraces the internal and external surfaces of the humerus, to which it is attached; below, it embraces, and effectually protects the front of the elbow-joint, into the anterior ligament of which many of its fibres are inserted.

Action.—The brachialis anticus flexes the forearm upon the arm, and, reciprocally, the arm upon the forearm. Its *momentum* takes place, like that of the biceps, during semi-flexion. It is worthy of remark, that this muscle acts with greater precision than the biceps upon the forearm, because it arises from the humerus only, and, besides that, it belongs more especially than that muscle to the elbow-joint. I have already said that it may be regarded as the active anterior ligament of this articulation. In fact, it so completely limits the movement of extension, that we cannot imagine the possibility of luxation of the forearm backward without rupture of this muscle. From the insertion of the biceps into the radius, and of the brachialis anticus into the ulna, it follows that the flexor muscles of the forearm are divided between the two bones, in the same manner as those of the leg are distributed to the tibia and fibula Thus, the contraction of the brachialis anticus has a tendency to carry the forearm outward as well as to flex it, while that of the biceps tends to draw it inward. When the two muscles contract simultaneously, direct flexion is the result.

The Coraco-brachialis.

Dissection.—The upper part is exposed as soon as the deltoid is detached; the middle is situated between the pectoralis major and the latissimus dorsi; and the lower part is seen upon the inner surface of the humerus, near the tendon of the deltoid.

The *coraco-brachialis* (*e*, *figs.* 116, 117) is the smallest muscle of the arm. It is situated at the inner and upper part of the arm, and was confounded by most of the older

anatomists with the short head of the biceps, with which, indeed, it is intimately united at its upper part.

Attachments.—It *arises* from the apex of the coracoid process, and is *inserted* towards the middle of the internal surface and border of the humerus. It arises from between two tendinous layers, the most superficial of which is common to it and the short head of the biceps, and also from the septum between these two muscles. From this origin the fleshy fibres proceed, forming an elongated, thin, and flat bundle, the size of which is always in an inverse ratio to that of the short head of the biceps; this bundle passes downward, backward, and a little outward, to be inserted into the humerus, between the brachialis anticus and the triceps. Its insertion is effected by means of a flat tendon, which receives the fleshy fibres successively upon its edges and external surface, and is accompanied by them even to its attachment to the bone. The precise situation of the attachment varies like that of the deltoid, and hence the different statements of authors regarding this point. According to Winslow, the coraco-brachialis is inserted at the upper part of the middle third of the humerus; according to M. Boyer, in the middle of the bone; and according to Bichat, a little above its middle. I have found it inserted at the junction of the lower with the two upper thirds.

Relations.—It is covered by the deltoid, the pectoralis major, and the biceps, and it covers the sub-scapularis, the latissimus dorsi, and the teres major. Its relations to the axillary and brachial arteries, and the median and musculo-cutaneous nerves, are the most important. Above, it covers these parts, and then it is in relation with the outer side of the brachial artery and median nerve, so that its tendon alone separates the vessel from the bone. The musculo-cutaneous nerve passes through it; hence the name of *perforatus Casserii* has been given to this muscle. It is also very frequently perforated by one of the branches of origin or roots of the median nerve.

Action.—It carries the arm forward and inward, and, at the same time, elevates it. It co-operates with the anterior fibres of the deltoid, and the superior fibres of the pectoralis major. If the arm be fixed, it depresses the top of the shoulder; when the arm is carried backward and turned inward, it draws it forward again, and rotates it outward.*

Posterior Brachial Region.

The Triceps Extensor Cubiti.

Dissection.—It is exposed by simply removing the skin and the fascia from the back of the arm, by removing the deltoid, or turning it upward, and by tracing the long head of the muscle between the teres major and minor to the axillary border of the scapula. In order to render it tense, and thus facilitate the dissection, the forearm must be flexed and the humerus abducted.

The *triceps extensor cubiti* (*i f g*, *fig.* 117) is a very large muscle, divided above into three portions, named the external, internal, and middle, or long heads. It constitutes by itself the entire muscular apparatus of the posterior region of the arm.

Fig. 117.

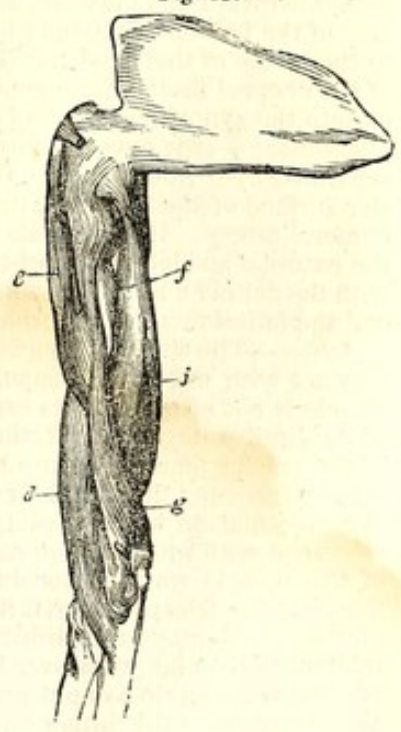

Attachments.—It *arises*, 1. By its *long head*, from the lower part of the glenoid cavity of the scapula, and from a rough, triangular depression existing on the contiguous portion of its axillary border; 2. By its *external head* (vastus externus), from all that portion of the posterior surface of the humerus which is above the groove for the radial nerve, from the external border of that bone, and from the external inter-muscular septum; 3. By its *internal head* (vastus internus), from the whole of the posterior surface of the humerus below the groove for the radial nerve, from the internal border of the bone, and from the internal inter-muscular septum. It is *inserted* into the back of the olecranon.

The origin of the middle or long head (which we shall find to be analogous to the rectus cruris)† consists of a tendon that is blended with the glenoid ligament, nearly in the same manner as the long tendon of the biceps. This tendon is flattened from before backward, and soon splits into two layers, united by their outer edges, the posterior of which is thin and short, while the anterior is very thick, especially at its outer edge, and prolonged to the middle of the muscle. The head of the humerus, therefore, is bound by the long head of the triceps below, in the same manner as by the long tendon of the biceps

* I have seen a small supernumerary coraco-brachialis extending from the base of the coracoid process to below the lesser tuberosity of the humerus, immediately beneath the insertion of the sub-scapularis: the same arrangement existed on both sides. This small muscle described a curve in front of the sub-scapularis.

† The older anatomists regarded this long portion as a separate muscle: longus (*Riolanus Albinus*), cubitum extendentium primus (*Vesalius*), le grand anconé (*Winslow*).

above. The fleshy fibres arise from between the two layers above mentioned, and form a bundle flattened in front and behind, which immediately turns upon itself, so that its anterior surface becomes posterior, and *vice versâ*. From this sort of torsion the strongest layer of the tendon, which was originally in front, eventually occupies the posterior surface of the muscle. The fleshy fibres arising from between the two layers, and especially from the anterior surface and borders of the *now* posterior tendon, pass downward and a little outward, to be inserted, some into the anterior, but the greater number into the posterior surface of an aponeurotic expansion, the external border of which is continuous with a similar structure belonging to the external division of the muscle. The aponeurotic fibres are collected together into a very thick tendon, which is folded into a semi-cone, within which the fleshy fibres terminate ; the tendon itself is inserted by a thick mass into the inner and back part of the olecranon, on the outer side of the internal portion of the muscle, and closely united with the posterior aponeurosis of the external portion. A synovial capsule intervenes between this tendon and the olecranon.

The origins of the external and internal portions from the humerus divide between themselves, so to speak, the posterior surface of that bone, to which the long head has no attachments.

The *external head* (*f*, *figs.* 116, 117), which is larger than the internal, and, from analogy, may be termed the *vastus externus* of the triceps brachii (cubitum extendentium secundus, *Vesalius ;* anconé externe, *Winslow*), arises partly by fleshy and partly by tendinous fibres. They are bounded above by a rough line, which is very well marked in powerful individuals, extending obliquely from the lower part of the head of the humerus to its external border. From these different origins the fleshy fibres proceed downward and inward, become partly blended with the internal head, and are almost all attached to the anterior surface of the terminal aponeurosis of the long head, and to the anterior surface and external edge of a very broad and strong tendon, which occupies the posterior aspect of the muscle. This latter tendon is united internally with the tendon of the long head, is folded upon itself, and receives the fleshy fibres as far as its insertion into the olecranon, on the outside of the long head. The inferior fleshy fibres of this portion of the muscle are very short and horizontal, and seem to be continued by the anconeus.

The *internal head* of the triceps (tertius cubitum extendentium, *Vesalius ;* anconé interne, *Winslow*, *g*, *figs.* 116, 117), which we denominate the *vastus internus* of the triceps brachii, might be called *the deep and internal portion* of this muscle, for, as we find with regard to the vastus internus of the thigh, it is almost entirely covered by the other two portions. Its origins are partly fleshy and partly tendinous. The fibres pass in different directions, the external downward and inward, a few to the anterior surface of the aponeurosis of the external head, by which they are concealed, but the greater number directly to the olecranon, in front of the insertion of the other portions. The internal pass downward and outward, and terminate, some upon the inner edge and anterior surface of the tendon of the long head, but the greater number directly upon the olecranon, to the inside of that tendon. The lowest of these fibres are almost horizontal. Some of the deepest fasciculi are generally given off from the body of the muscle, to be inserted into the synovial capsule of the elbow-joint.

Relations.—It is covered through nearly its whole extent by the brachial fascia, and separated by it from the skin, through which it is distinctly defined ; it covers the posterior surface of the humerus, the back of the elbow-joint, the radial nerve, and the deep humeral artery. It is separated from the muscles of the anterior region of the arm by the external and internal inter-muscular septa. Its long or scapular portion is in relation with the deltoid and the teres minor behind, and with the sub-scapularis, the teres major, and the latissimus dorsi in front.

Action.—The triceps extends the forearm upon the arm, but in order that its long head may act with effect, the scapula must be fixed by other muscles. The power of this muscle is not so great as its size and the number of its fibres would indicate, on account of its disadvantageous insertion near the fulcrum. It is true that here, as in the case of the triceps femoris, nature has, as much as possible, counterbalanced this disadvantage by inserting the muscle, not into the apex, but into the back part of the olecranon. We even find, as we have said, a synovial bursa between the tendon and that part of the olecranon with which it is in contact. It would appear, at first sight, that the *momentum* of this muscle would occur during semi-flexion, but a little consideration would show that, like the triceps femoris, it has, properly speaking, no momentum ; and that the olecranon, which may be regarded as the ossified tendon of the muscle, always has the same relation to the ulna, whatever be the position of the forearm. It should also be observed, that this muscle has not nearly so much power during semi-flexion as during extension, because, in the former case, it is opposed by the flexor muscles, which, in that position, act with the greatest possible effect ; while in the latter, when the arm and forearm form an obtuse angle, the extensor muscle has the advantage. Lastly, the predominance of the extensor over the flexors is less marked in the arm than in the thigh ; and even supposing the extensor to possess more intrinsic power, it has less active force, in consequence of the insertions of the flexors being much more favourable, both as

regards their distance from the fulcrum, and their nearer approach to a perpendicular direction. Thus flexion evidently predominates at the elbow, and extension at the knee. This, indeed, ought to be the case, for in the upper extremities the flexion of the elbow is the movement of attraction and prehension; while in the lower extremities, the extension of the knee is an essential position in standing, walking, running, and leaping.

We might suppose the possibility of rupture of the olecranon at its junction with the coronoid process, during violent extension of the forearm, an accident that would be analogous to fracture of the patella, or rupture of its ligament. The long head of the triceps assists in drawing the humerus backward, and slightly adducts the arm. By means of its tendon of origin from the scapula, and especially by the outer edge of that tendon, which is thick, and, as it were, arched, so as to fit the head of the humerus, the long head also forms a cord which supports the bone during abduction, and tends to prevent its displacement; but, as the glenoid cavity is directed forward, and as its inferior extremity is situated almost at the junction of the two anterior thirds with the posterior third of the cavity, it follows that this tendon is well calculated to prevent dislocation backward, but offers no resistance to displacement forward. Sometimes the lower extremity of the triceps becomes its fixed point, and then it extends the arm upon the forearm, and the shoulder upon the arm.

MUSCLES OF THE FOREARM.

The Pronator Teres.—Flexor Carpi Radialis.—Palmaris Longus.—Flexor Carpi Ulnaris.—Flexor Sublimis Digitorum.—Flexor Profundus Digitorum.—Lumbricales.—Flexor Longus Pollicis.—Pronator Quadratus.—Supinator Longus.—Extensores Carpi Radialis, Longior et Brevior.—Supinator Brevis.—Extensor Communis Digitorum.—Extensor Digiti Minimi.—Extensor Carpi Ulnaris.—Anconeus.—Abductor Longus Pollicis.—Extensor Brevis Pollicis.—Extensor Proprius Indicis.

The muscles of the forearm are divided into those of the anterior, the external, and the posterior regions.

Muscles of the Anterior Region.

These muscles form four very distinct layers. The first consists of the pronator teres, the flexor carpi radialis, the palmaris longus, and the flexor carpi ulnaris; the second is formed by the flexor sublimis digitorum; the third by the flexor profundus digitorum and the flexor longus pollicis; and the fourth by the pronator quadratus.

The Pronator Teres.

Dissection.—This muscle is exposed when the inner and anterior part of the fascia of the forearm is removed. Its origin should be carefully studied.

The *pronator teres*, or *rotundus* (*a*, *fig.* 118), the most superficial muscle on the anterior and inner aspect of the forearm, forms an oblique ridge under the skin, upon the inner side of the bend of the elbow. It is *attached* above to the inner condyle of the humerus, or epitrochlea (*a*, *fig.* 119), and is *inserted* below into the middle of the radius (*a'*). It arises from the lower part of the inner border of the humerus, from the inner condyle, from a large inter-muscular septum, separating it from the flexor carpi radialis and the flexor sublimis, and from the coronoid process of the ulna on the inner side of the brachialis anticus, by means of a tendinous and fleshy bundle, which is separated from the rest of the muscle by the median nerve. From these origins the fleshy fibres proceed obliquely downward and outward (pronateur oblique, *Winsl.*), surrounding a flat tendon, which appears first on the anterior surface of the muscle, and then turns over the anterior and external surfaces of the radius, to be inserted at the middle of that bone. The muscle, therefore, turns spirally around the radius, but not so completely as the supinator brevis. Its insertion may take place opposite any point in the middle third of the bone.

Fig. 118.

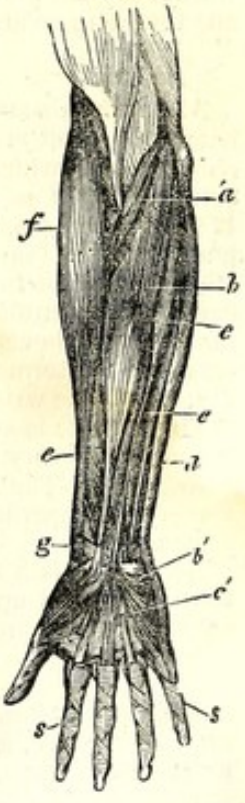

Relations.—It is covered by the fascia of the forearm, by the supinator longus and extensor carpi radialis, and by the radial artery and musculo-spiral nerve: it covers the brachialis anticus and flexor sublimis, the median nerve by which it is first perforated, and the ulnar artery.

Action.—The greater the amount of supination of the forearm, the more effectual is the action of this muscle as a pronator, because then it is much more completely rolled around the radius. I may remark that, on account of its obliquity, it is inserted into the radius at an angle of 45°; and that, consequently, the direction in which it operates is rather favourable. It acts with greater advantage in proportion as it is inserted nearer to the upper end of the radius; and, for this reason, its

power must vary considerably in different individuals. When pronation is carried as far as possible, the muscle then becomes a flexor of the forearm. After the preceding examination of this muscle, we need no longer be surprised at the great energy of the movement of pronation, which is much more powerful than that of supination; nor yet that it is the most natural position of the forearm, for the pronator teres can more than counteract the two supinators taken together. In fracture of the bones of the forearm, this muscle tends to obliterate the interosseous space.

The Flexor Carpi Radialis.

Dissection.—It is sufficient to divide and dissect off the anterior part of the fascia of the forearm, in order to expose this muscle, which may be recognised by the following description:

The *flexor carpi radialis* (radialis internus, *Albinus*, *b*, *fig.* 118) is situated immediately within the pronator teres, occupying the superficial layer of the anterior aspect of the forearm, and being, as far as its tendon is concerned, the most superficial of all these muscles. It *arises* from the lower part of the internal border and from the inner condyle of the humerus (*b*, *fig.* 119), and is *inserted* (*b'*) into the second metacarpal bone. Its origin consists of a tendon common to it and to the pronator quadratus, palmaris longus, flexor sublimis, and flexor carpi ulnaris. The fleshy fibres immediately arise from within a sort of pyramidal aponeurosis given off by this common tendon, and from the body of the muscle, at first slender, then increasing in size, and again tapering towards its attachment to the two surfaces and edges of a tendon, which forms the lower two thirds of the muscle, and passes obliquely outward and downward to the level of the os scaphoides; it there penetrates into a groove formed by the scaphoid and the trapezium, is reflected inward along this oblique groove, and terminates upon the second metacarpal bone, spreading out so as to embrace its upper extremity; it also gives off a tendinous expansion to the trapezium, and sometimes one to the third metacarpal bone.

Relations.—It is covered by the fascia and the skin, through which it is very clearly defined: it is in relation behind with the flexor sublimis; on the outside, with the tendon of the flexor pollicis, over which it passes at an acute angle, so as to bind it down; and lower down, with the wrist-joint. A very strong tendinous sheath, concealed by the abductor brevis and opponens pollicis, completes the groove formed by the scaphoid and trapezium for its tendon, the movements of which are facilitated by a well-marked synovial membrane.* Its most important relation is that of the external border of its tendon with the radial artery. The superficial position of the tendon prevents our feeling the artery when the muscle is contracted.

Action.—It flexes the second row of the carpus upon the first, and this, again, upon the forearm. Moreover, on account of its reflection, it is a pronator, and, according to Winslow, it is a more powerful supinator than the supinator longus. Its obliquity downward and outward explains why it inclines the hand to the radial border of the forearm, and thus acts as an abductor.

The Palmaris Longus.

Although this small muscle is rather a tensor of the palmar fascia than a flexor of the hand, I have yet judged it proper to describe it in this place, in connexion with the flexor carpi radialis, which, in contradistinction to this muscle (*le petit palmaire*), has also been called *le grand palmaire* (*Bichat*). It is a small fusiform, slender, fleshy bundle (*c*, *fig.* 118), of about four inches in length, *arising* (*c*, *fig.* 119) from the inner condyle of the humerus to the inner side of the preceding muscle, and from a small tendinous cone, which isolates it from that muscle, the flexor sublimis, and the flexor carpi ulnaris. The fleshy fibres terminate around a flat tendon, which constitutes the lower two thirds of the muscle (whence the name *palmaris longus*), proceeds vertically downward and a little outward, and terminates by expanding in front of the anterior annular ligament (*g*, *figs.* 118, 119) of the wrist, and becoming continuous with the middle palmar fascia (*c'*, *fig.* 118).

This muscle is subject to a great many varieties, and is often wanting; its fleshy belly is sometimes very long, and occasionally occupies the middle of the muscle.

Relations.—The same as those of the preceding muscle (*flexor carpi radialis*); its tendon is very superficial. It is separated from the neighbouring muscles by a very strong sheath.

Action.—It is a tensor of the palmar fascia. When this effect has been produced, it flexes the hand upon the forearm. According to Winslow, it would assist the flexor carpi radialis in pronation.

The Flexor Carpi Ulnaris.

Dissection.—Remove the superficial layer of the fascia covering the inside of the forearm, taking care, in dissecting this as well as the other muscles of the forearm, to stop at the points where that fascia adheres intimately to the fleshy fibres.

* See note, p. 296.

This is the most deep-seated of all the muscles of the superficial layer of the forearm (ulnaris internus, *Albinus*; cubital interne, *Winslow*, *d*, *figs.* 118, 119, 121, 122).

It *arises* from the inner condyle of the humerus and from the inner edge of the olecranon, these two origins forming an arch under which the ulnar nerve passes. It also arises sometimes, though slightly, from the coronoid process of the ulna, from the upper half of the posterior border of the ulna, through the medium of the fascia of the forearm, and from the septum between itself and the flexor sublimis. It is *inserted* into the pisiform bone. The origin from the ridge on the ulna is remarkable; it consists, indeed, of the fascia of the forearm, which becomes thickened and divided into two layers, one deep and very thin, the other superficial and very thick; in the interval between these the fleshy fibres arise. These fibres are attached to the surfaces and edges of a very strong tendon, which then appears upon the anterior border of the muscle, and continues to receive the fleshy fibres on its posterior edge until its insertion into the pisiform bone. This takes place upon the anterior surface of the bone, like those of the triceps muscles of the arm and thigh into the olecranon and patella. The tendon then becomes continuous with the inferior vertical ligament of the articulation between the pisiform and cuneiform bones, so that the muscle may, in fact, be regarded as inserted into the fifth metacarpal bone.

Relations.—It is covered by the fascia, and is intimately united with it for a considerable extent: it covers the ulnar artery and nerve, the flexor sublimis, the flexor profundus, and the pronator quadratus. The most important of all its relations is that with the ulnar artery, which is at first under it, and then lies along the external edge of its tendon, which protects the artery, and serves as a guide in the application of a ligature to it. I have, therefore, been in the habit of calling this muscle the *satellite* of the ulnar artery.

Action.—This muscle acts as if it were inserted into the upper extremity of the fifth metacarpal bone. Were it not for the peculiar mode of its attachment to the pisiform bone, it would have been inserted parallel to its lever; whereas it is really inserted at an angle of about 45°. It flexes the second row of the carpus upon the first, and this upon the forearm; at the same time it inclines the hand towards its ulnar side. Its *momentum*, as well as that of the preceding muscle, occurs during semi-flexion of the hand upon the forearm.

The Flexor Sublimis Digitorum.

Dissection.—The portion of this muscle, situated in the forearm, is exposed by cutting across the middle, and turning aside the pronator teres, the flexor carpi radialis, and the palmaris longus, which form a superficial layer in front of it. With a little care, the origin of this muscle may be separated as far as the inner condyle of the humerus. In removing the pronator teres, it is necessary to be extremely careful to avoid dividing the radial origin of the flexor sublimis, which forms a very thin prolongation under the pronator. The dissection of the palmar and digital portions of the muscle is the same as that of the flexor profundus.

Fig. 119.

Divide the anterior annular ligament of the carpus vertically, and remove the palmar fascia; examine the disposition of this structure opposite the heads of the metacarpal bones, and also the relations of the tendons of the flexor sublimis and flexor profundus in the palm of the hand; then dissect the digital sheaths, which must be divided in order to display the singular manner in which the tendons of the flexor sublimis bifurcate and turn round, so as to embrace the corresponding tendons of the flexor profundus.

The *flexor superficialis*, *sublimis*, or *perforatus* (*e e*, *fig.* 118; *e*, *fig.* 119), is a broad, flat, thick muscle, divided into four portions below. It *arises* from the internal condyle or epitrochlea of the humerus, and from the ulnar and radius, and is *inserted* into the second phalanges of the fingers. It arises from the epitrochlea by the common tendon, from a rough surface on the fore part of the inner side of the coronoid process of the ulna, and also from about two inches of the radius. This latter origin consists of tendinous fibres attached to that oblique portion of the anterior border of the bone which extends inward towards the bicipital tuberosity, and from which arise the supinator brevis above, the flexor longus pollicis below, and the muscle we are now describing in the middle. A great number of fibres also arise from the broad aponeurotic septa which divide this muscle from the flexor carpi ulnaris, and from the other muscles of the superficial layer, viz., the pronator teres, the flexor carpi radialis, and the palmaris longus.

From these different origins the fleshy fibres proceed vertically downward, forming a broad and thick belly, which is almost immediately divided into four portions. These at first are in juxtaposition, but soon become arranged in two layers, like the tendons of

the extensor communis, viz., one anterior and larger, consisting of the divisions for the median and ring fingers (the latter not being so strong as the former), and another posterior, formed by the divisions for the index and little finger. Each division is, indeed, a small muscle, having its own particular tendon, around which the fleshy fibres are arranged, at first regularly, and afterward on one side only: they are thus semi-penniform muscles. The two posterior divisions are not so distinct as the anterior, and have a peculiar arrangement: they generally constitute two small digastric muscles; that is to say, a fleshy belly terminates upon a flat tendon, which, becoming enlarged, gives origin, in its turn, to a new fleshy belly. The four tendons, after emerging from the fleshy fibres, pass together under the annular ligament (*g*) of the carpus, in conjunction with the median nerve, which lies on their outer side, and is often mistaken for a tendon, and with the tendons of the flexor profundus digitorum and the flexor longus pollicis. This thick bundle of tendons having reached the palm of the hand, is then distributed in a manner to be noticed after the description of the flexor profundus, with the tendons of which those of the flexor sublimis are intimately connected.

Relations.—It is covered by the pronator teres, the flexor carpi radialis, the palmaris longus, the flexor carpi ulnaris, and the fascia of the forearm; and it covers the flexor profundus digitorum, from which it is separated by the ulnar vessels and nerves; it also covers the median nerve and the flexor longus pollicis, to which it generally sends a tendinous and fleshy prolongation.

The Flexor Profundus Digitorum.

Dissection.—This muscle is exposed by cutting across the flexor sublimis and the flexor carpi ulnaris.

The *flexor profundus* or *perforans* (*i*, *figs.* 119, 120) is situated under the superficial flexor, which it exceeds in size, but resembles it in being divided below into four portions.

Fig. 120.

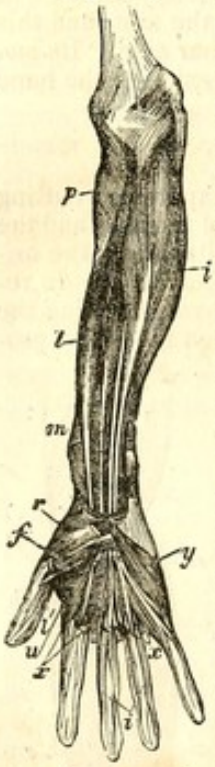

Attachments.—It *arises* from the upper three fourths of the internal and anterior surfaces of the ulna, from a well-marked cavity situated on the inner side of the coronoid process behind the rough eminence which gives attachment to the internal lateral ligament of the elbow, from the inner two thirds of the interosseous ligament, from that part of the fascia of the forearm which covers the inner surface of the ulna, and, lastly, by a few fibres, from within and below the bicipital tuberosity of the radius. It is *inserted* into the front of the bases of the last phalanges of the fingers (*i*, *figs.* 119, 120).

The fleshy fibres arise directly from these numerous origins, and proceed vertically downward, the internal fibres alone being directed somewhat obliquely forward and outward. The belly of the muscle thus formed continues to increase in size, and is then divided into four unequal portions, each constituting a semi-penniform muscle. These four small muscles are in juxtaposition, and terminate in as many flat tendons, which occupy the lower two thirds of the anterior surface of the entire muscle, and are remarkable for being divided into very regular and closely-united parallel bands of a nearly white colour. The four tendons emerging from the fleshy fibres at various heights, but always above the anterior annular ligament of the carpus, pass under this ligament conjointly with the tendons of the flexor sublimis, the flexor pollicis longus, and the median nerve. In this situation they are placed behind the tendons of the flexor sublimis, which are arranged in two layers, as we have already seen. The tendons of the flexor profundus are always in juxtaposition, and, moreover, are united together by means of dense cellular tissue and tendinous bands passing from one to the other: the fasciculus for the index finger alone remains distinct; and, therefore, the flexion of this finger is almost as independent of that of the others as its extension, for which latter movement it receives a special muscle. Immediately below the annular ligament the tendons separate from each other; the two anterior tendons of the flexor sublimis no longer cover the two posterior, but all four become situated in front of the corresponding tendons of the flexor profundus, and arrive together at the metacarpo-phalangal articulations: here they are received, at first, into a very strong fibrous sheath, resulting from the division of the palmar fascia, and afterward into another sheath (*s*, *figs.* 118, 119), which converts the groove in front of the phalanges into a canal. If we divide any of these digital sheaths, we find the tendon of the superficial flexor becoming flattened and hollowed underneath, as it were, into a groove, which is exactly moulded upon the tendon of the deep flexor. About the middle of the first phalanx the tendon of the sublimis (*e*, *fig.* 119) bifurcates, and gives passage to that of the profundus, which it embraces by turning round it like the thread of a screw, and becoming posterior instead of anterior, as it was before. The two halves of the tendon then reunite to form a groove having its concavity directed forward, and again separate

to be inserted into the rough edge of the groove on the second phalanx. The tendon of the flexor profundus (*i' i'*, *figs.* 119, 120), on the contrary, passes directly through the sheath formed by that of the flexor sublimis, and is inserted into the third phalanx. The tendons of the flexor profundus, moreover, present in their whole course very slightly apparent traces of division. From the relation of the tendons of the two flexors to each other, the superficial muscle has been called the *perforatus*, and the deep one the *perforans*.

Relations.—These should be examined in the forearm, in the palm of the hand, and along the fingers.

In the *forearm* the flexor profundus is covered by the flexor sublimis, from which it is separated by an incomplete tendinous septum, and by the median nerve. It covers the ulna, the interosseous ligament, and the pronator quadratus; it corresponds within to the flexor carpi ulnaris, and without to the flexor longus pollicis. The ulnar vessels and nerves are at first situated between this muscle and the flexor sublimis, and afterward separate it from the flexor carpi ulnaris.

In the *palm* its tendons are subjacent to those of the flexor sublimis, and cover the interosseous muscles and the adductor pollicis. The lumbricales muscles take their origin from them.

Along the *fingers* its tendons are in relation behind with the grooves of the phalanges, and with the metacarpo-phalangal and phalangal articulations, and in front with the tendons of the sublimis and the fibrous sheaths of the fingers.

Action of the two Flexors.—These muscles flex the third phalanx upon the second, the second on the first, this, again, upon the corresponding metacarpal bone, and, lastly, the hand upon the forearm. The flexor sublimis has no action upon the third phalanges. Its origin from the internal condyle of the humerus enables it to act upon the forearm, and to assist in flexing it upon the arm. It is scarcely necessary to say that the bifurcation of the tendons of the flexor sublimis is intended to afford a sheath to, and bind down, those of the flexor profundus. The flexor profundus flexes the third phalanx upon the second, the second upon the first, the first upon the corresponding metacarpal bone, and, lastly, the hand upon the forearm.

The Lumbricales.

The *lumbricales* (*x*, *figs.* 119, 120) are small fleshy tongues, which may be regarded as accessories of the flexor profundus. They are four in number, distinguished as the *first*, *second*, &c., counting from without inward. They extend from the tendons of the flexor profundus to the first phalanges of three or four fingers. They *arise* from the tendons after these have passed through the annular ligament: the first and the second in front of the tendons for the index and middle fingers, the third in the interval between those for the middle and ring fingers, and the fourth in the interval between those for the ring and little fingers. From these origins they proceed, those near the median line vertically, and those at either side obliquely downward to the outer side of the metacarpo-phalangal articulations of the corresponding fingers, where they terminate by a broad tendinous expansion *inserted* into the edges of the extensor tendons, and completing the sheath which those tendons form on the back of the first phalanges. The tendon of the third lumbricalis appears to me to be almost always inserted, not into the outer side of the ring finger, but into the inner side of the middle finger: an arrangement that cannot well be accounted for. It is not uncommon to find this third lumbricalis bifurcated, and attached, not only to the inner side of the middle, but to the outer side of the ring finger.

Relations.—They are placed between and upon the tendons of the flexor profundus, and have, therefore, the same relations as those tendons in the palm of the hand; they are also in relation with the sides of the metacarpo-phalangal articulations, and the tendons of the interosseous muscles.

Action.—It is difficult to determine their actions precisely. Vesalius has described them as adductors, and Spigelius as flexors. I agree with Riolanus in regarding them as specially intended to keep the extensor tendons closely applied to the phalanges, and to serve instead of a proper sheath. They are of use also in binding together the extensor and flexor tendons, and preventing the displacement of either.

The Flexor Longus Pollicis.

Dissection.—The same as that of the flexor profundus.

The *flexor longus pollicis* (*l*, *figs.* 119, 120) is situated upon the same plane as the flexor profundus digitorum, of which it may be considered a division; it is thick, elongated, and penniform.

Attachments.—It *arises* from the upper three fourths of the radius, from the contiguous portion of the interosseous ligament, from the anterior border of the radius, and not unfrequently by a prolongation, tendinous at its extremities and fleshy in the middle, from the flexor sublimis digitorum. It is *inserted* into the upper end of the second phalanx of the thumb. The fleshy fibres arise directly from these origins, pass vertically downward, and are attached to the posterior surface of a flat tendon, which forms a continuation of the series of tendons of the flexor profundus on the outside, and, like them, is

divided into bands. The fleshy fibres accompany the tendon as far as the anterior annular ligament of the carpus; it then passes beneath this ligament, is reflected over the inside of the trapezium, and proceeds obliquely outward along the first metacarpal bone. When it reaches the metacarpo-phalangal articulation of the thumb, it is received in an osteo-fibrous sheath, resembling in every respect that of the tendons of the other fingers, and, like them, is inserted in front of the upper extremity of the ungual phalanx of its corresponding finger (*l*, *fig.* 120).

Relations.—It is covered by the flexor sublimis, the flexor carpi radialis, the supinator longus, and the radial artery; it covers the radius and the interosseous ligament, from which it is separated above by the interosseous vessels and nerves, and below by the pronator quadratus. Its tendon is the most external of those which pass under the anterior annular ligament of the carpus, after leaving which it is received into a deep muscular groove formed by the muscles of the ball of the thumb, and is ultimately enclosed in its own osteo-fibrous sheath.

Action.—It flexes the last phalanx of the thumb upon the first, this upon the first metacarpal bone, and then the hand upon the forearm. In order to understand its action precisely, we must suppose the muscular force to be concentrated upon the upper end of the reflected portion; it is then easy to see that it draws the phalanges inward, while flexing them. It is, therefore, an opponens muscle.

The Pronator Quadratus.

Dissection.—Cut across all the tendons occupying the lower part of the anterior region of the forearm, and this muscle will be exposed.

This small muscle (le petit pronateur, *Bichat*, *m*, *figs.* 119, 120) is situated at the lower part of the anterior region of the forearm, and forms the deepest layer of this region. It is regularly quadrilateral, and thicker than at first sight it appears to be.

Attachments.—It *arises* from the lower fourth of the internal border of the ulna, which is directed so decidedly backward inferiorly, that the muscle is rolled round the bone; also, from an aponeurotic layer much thicker below than above, directed obliquely upward and outward, and occupying the inner third of the muscle, upon which it terminates in a number of elegant intersections; lastly, from all that portion of the anterior surface of the ulna upon which it lies. From these origins the fibres proceed horizontally outward (le pronateur transverse, *Winslow*), becoming longer as they are more superficial, to the lower fourth of the external border, anterior surface, and internal border of the radius.

Relations.—It is covered by the flexor profundus digitorum, the flexor longus pollicis, the flexor carpi radialis, and the radial and ulnar arteries, and it partially covers the two bones of the forearm and the interosseous ligament.

Action.—The pronator quadratus tends to approximate the two bones of the forearm; but as it is rolled around the ulna, which is immovable, it causes the radius to turn upon that bone, and is therefore a pronator. Its action is much more energetic than would at first sight appear: this depends on the number of its fleshy fibres, which are arranged in several layers, the most superficial being the longest.

The Muscles of the External Region of the Forearm.

The muscles of this region are, the supinator longus, the extensores carpi radiales, longior and brevior, and the supinator brevis.

The Supinator Longus.

Dissection.—The brachial portion of this muscle is exposed in the dissection of the brachialis anticus and the triceps, and the portion situated in the forearm, by removing the fascia from the outer and anterior aspect of the muscles of this region.

The *supinator longus* (*f*, *figs.* 118, 121), which is the most superficial muscle of the external and anterior aspect of the forearm, belongs both to the arm and the forearm (brachio-radialis, *Sœmmering*), and constitutes, in a great measure, the oblique ridge forming the external boundary of the bend of the elbow. It is a long, flat muscle, fleshy in its upper two thirds, and tendinous in its lower third.

Attachments.—It *arises* from the outer border of the humerus, and from the external inter-muscular septum of the arm; the extent of its humeral attachment varies from the lower fourth to the lower third of that bone, and is limited above by the groove for the musculo-spiral nerve. It is *inserted* into the base of the styloid process of the radius. The fleshy fibres proceed from their origins downward, forward, and a little inward, to form a fleshy belly, which is flattened from *without inward*, and is applied to the brachialis anticus. After reaching the lower end of the humerus, the fleshy belly becomes flattened from *before backward*, and passes vertically downward. At first it is thick, but, during its progress, it expands, and becomes thin, until its fibres terminate successively upon the anterior surface of an aponeurosis, which becomes entirely free from fleshy fibres above the middle of the forearm, and is gradually contracted into a flat tendon, that is inserted into the styloid process of the radius.

Relations.—It is covered by the fasciæ of the arm and forearm: in the arm it is en-

closed in the same sheath with the brachialis anticus, from which it is separated by the radial or musculo-spiral nerve; in the forearm it has a sheath proper to itself: it is in relation with the brachialis anticus, which is at first within, and afterward behind it; then with the extensor carpi radialis longior, the tendon of the biceps, the supinator brevis, the pronator teres, the flexor carpi radialis, the flexor digitorum sublimis, the flexor longus pollicis, the radial artery and veins, and the radial nerve. Its inner border limits the bend of the elbow on the outside: the radial artery emerges from beneath this border, and then lies parallel to it. Its outer border is separated from the extensor carpi radialis longior by cellular tissue, and, inferiorly, is in contact with the dorsal branch of the radial nerve, which, at first, was situated beneath it. The most important of all these relations is that with the radial artery, of which the long supinator may be considered the satellite muscle, and might be designated the *muscle of the radial artery*.

Action.—It might be asked, Why does the supinator longus form an exception to the general rule, in being inserted into the lower end of the lever which it is intended to move? for, while the forearm is in a state of supination, the axis of the muscle is vertical, and its action appears limited to that of flexing the forearm; but if the limb be pronated, the direction of the muscle becomes oblique from without inward, and, therefore, supination is the result of its contraction. After this effect has been produced, if the muscle still continues to act, the forearm is flexed upon the arm. It is needless to state that the distance of its insertion from the fulcrum gives the muscle great power, notwithstanding its disadvantageous angle of incidence.

The Extensor Carpi Radialis Longior.

Dissection.—This muscle, as well as the succeeding one, will be exposed at the same time as the supinator longus, beneath which it is placed. The lower end of its tendon occupies the dorsum of the wrist, and should also be exposed.

The *extensor carpi radialis longior* (le premier ou long radial externe; radialis externus longior, *Albinus*, *n*, *figs.* 119, 121) is situated on the external and posterior aspect of the forearm, below the supinator longus, of which it seems to be a continuation at its origin from the humerus: like that muscle, it is flattened from within outward in the arm, and from before backward in the forearm: it is fleshy in its upper third, and tendinous in its lower two thirds.

Attachments.—It *arises* from the rough triangular impression terminating the external border of the humerus, from the external inter-muscular septum, and from the anterior surface of the common tendon. It is *inserted* into the back of the upper end of the second metacarpal bone. The fleshy fibres arising directly from the parts mentioned constitute a bundle, at first flattened on the sides, and forming a continuation of the supinator longus, from which it is often difficult to separate it: it afterward becomes flattened from before backward. The fibres pass vertically downward, and are attached to the anterior surface of a tendon, a little beyond the upper third of the forearm. The tendon then becomes narrower and thicker, proceeds along the outer border of the radius, passes under the tendons of the abductor longus and extensor brevis pollicis, which cross it obliquely, and turns a little outward, and then backward, to arrive at a groove common to it and the extensor carpi radialis brevior; it is then crossed at an acute angle by the tendon of the extensor longus pollicis, and is finally inserted, by an expanded termination, into the second metacarpal bone (*n'*, *fig.* 121).

Relations.—It is covered by the supinator longus and the fascia of the forearm; on the outside of the forearm, it is covered and crossed obliquely by the abductor longus and extensor brevis pollicis, and in the wrist by the tendon of the extensor longus pollicis. It covers the elbow-joint, the extensor carpi radialis brevior, and the back of the wrist-joint.

The Extensor Carpi Radialis Brevior.

The *extensor carpi radialis brevior* (le second ou court radial externe; radialis externus brevior, *Albinus*, *o*, *figs.* 119, 121, 122) is thicker, but shorter, than the preceding, below which it is placed. It *arises* from the external condyle or epicondyle of the humerus, by a tendon common to it and the extensor muscles of the fingers; also, from a very strong aponeurosis, situated upon its posterior surface; and from another tendinous septum, which divides it from the extensor communis digitorum. It is *inserted* into the back part of the upper end of the third metacarpal bone. The fleshy fibres, thus arising from the external condyle by means of an aponeurotic pyramid, are attached to the posterior surface of a tendon, which becomes gradually narrower and thicker as it receives them. The fibres themselves terminate about the middle of the forearm, and then the flat tendon passes backward into the same groove on the radius as that of the last-named muscle, the two tendons being retained in it by the same fibrous sheath, and lubricated by the same synovial membranes, but separated from each other by a small vertical ridge of bone. After leaving the common sheath, the tendon of the short separates from that of the long radial extensor, passes still more posteriorly, and is inserted into the third metacarpal bone (*o'*, *figs.* 121, 122).

Relations.—It is covered by the preceding muscle, and, like it, is crossed obliquely on

the outside by the long abductor, the short, and then the long extensor muscles of the thumb: it covers the external surface of the radius, from which it is separated by the supinator brevis above, and the pronator teres in the middle. Its tendon covers and protects the back of the wrist. In consequence of the different length of their fleshy fibres, the supinator longus and the two radial extensors of the carpus are arranged one above the other, the highest being the supinator longus, and the lowest the extensor carpi radialis brevior.

Action of the two Radial Extensors.—These two muscles, which, from their insertions, might be called the *posterior* radials, extend the second row of the carpus upon the first, and this upon the forearm; they are also abductors of the hand, for they incline it towards the radial side of the forearm. The extensor carpi radialis longior being attached to the humerus, can assist in flexing the forearm.

The Supinator Brevis.

Dissection.—Pronate the forearm forcibly. In order to expose this muscle completely, divide the two radial extensors of the carpus, and even some of the muscles of the superficial layer, on the back of the forearm.

The *supinator brevis* (*p*, *figs.* 119, 120, 122) is a broad muscle curved into the form of a hollow cylinder, and rolled round the upper third of the radius: it forms by itself the deep layer of the external region of the forearm.

Attachments.—It *arises* from the external lateral ligament of the elbow, with which it is blended, and by this means from the external condyle; from the annular ligament of the radius; from the external border of the ulna, which is provided with a projecting ridge for this purpose; from *a deep triangular excavation, in front of this ridge, and below the lesser sigmoid cavity of the ulna*; and, lastly, from the deep surface of an expansion of its tendon of origin and the external lateral ligament, which covers the greater part of the muscle. From these different origins (*fig.* 122) the fleshy fibres pass round the radius, into the posterior, external, and anterior surfaces of which bone they are inserted, embracing in front the bicipital tubercle and the tendon of the biceps (*figs.* 119, 120). I have seen a fleshy prolongation of this muscle, covering the anterior half of the annular ligament of the radius, of which it might be regarded an extensor.

Relations.—The supinator brevis is covered by the radial extensors, the supinator longus, the pronator teres, the extensor communis digitorum, the extensor digiti minimi, the extensor carpi ulnaris, the anconeus, and the radial artery and vein: it covers the upper third of the radius, and also its annular ligament, the elbow-joint, and the interosseous ligament. It is perforated by the deep branch of the radial nerve, which is distributed to all the muscles on the back of the forearm.

Action.—No muscle in the body is so completely rolled around the lever that it is intended to move, for it forms five sixths of a cylinder; it is, therefore, the chief agent in supination, and the supinator longus can only be regarded as an accessory.

Muscles of the Posterior Region of the Forearm.

The muscles of the posterior region of the forearm constitute two very distinct layers: one *superficial*, comprising the extensor communis digitorum, the extensor digiti minimi, and the extensor carpi ulnaris; the other *deep*, comprising the abductor pollicis longus, the extensor brevis and extensor longus pollicis, and the extensor indicis

Muscles of the Superficial Layer.

One mode of *dissection* is common to all these muscles. Make a circular incision through the skin at the lower part of the arm; pronate the arm, and make a perpendicular incision from the external condyle of the humerus to the third metacarpal bone, entirely dividing the sub-cutaneous cellular tissue down to the fascia; remove this fascia by careful dissection, except where it is very adherent. Trace the tendons of the extensor muscles along the back of the fingers.

The Extensor Communis Digitorum.

The *extensor communis digitorum* (*b*, *fig.* 121), situated at the back of the forearm, simple above and divided into four portions below, *arises* from the external condyle of the humerus, and is *inserted* into the second and third phalanges of the four fingers. Its origin consists of a tendon common to it, and to the extensor carpi radialis brevior, extensor digiti minimi, and extensor carpi ulnaris. This tendon consists of a four-sided pyramid, and is formed by the fascia of the forearm, by a lamina separating this muscle from the extensor carpi radialis longior, by another lamina separating it from the extensor digiti minimi and the extensor carpi ulnaris, and, lastly, by another situated between it and the supinator brevis. The fleshy fibres arising from the interior of this pyramid form at first a thin, but afterward a much larger muscle, which becomes flattened from before backward, and soon divides into four fasciculi. The two middle fasciculi, intended for the middle and the ring fingers, are stronger than those destined for the index and little fingers, *i. e.*, the two extreme fasciculi, which, lower down, become placed in front of

the middle fasciculi. In this manner they all pass under the dorsal ligament (*r*, *fig.* 121) of the carpus in a proper sheath. After leaving this sheath, in which they are provided with a synovial capsule,* extending both above and below the dorsal ligament, the four tendons become situated on the same plane, and diverge from each other; the two middle tendons proceed along the backs of the corresponding metacarpal bones; the external and internal tendons (*b' b'*, *fig.* 121) correspond to the interosseous spaces, which they cross obliquely, in order to assume a position behind the heads of the metacarpal bones, to which they belong. Having reached the metacarpo-phalangal articulations, the tendons become narrower and thickened, and give off on each side a fibrous expansion, attached to the sides of the joint; they then enlarge again so as to cover the dorsal surface of the first phalanges, receive and are reenforced by the tendons of the lumbricales, and opposite the articulation of the first with the second phalanx, they divide into three portions, one median, which is implanted upon the upper end of the second phalanx, and two lateral, which pass along the sides of the second phalanx, approach each other at the lower half of the dorsal surface of the second phalanx, unite by their neighbouring edges, and are inserted into the upper end of the third phalanx. Opposite the metacarpal bones they sometimes split into two or three small juxtaposed tendons, and at the lower end of these bones the tendons for the little, ring, and middle fingers communicate with each other by expansions of variable size, and sometimes by a true bifurcation (see *fig.* 121). The tendon for the index finger is alone free. The communication of the tendon of the little with that of the ring finger takes place opposite the metacarpo-phalangal articulation, by means of a transverse band, which forms a projection under the skin. Lastly, we not uncommonly see a tendinous prolongation arising from the anterior surface of these tendons, and inserted into the upper end of the first phalanx.

Fig. 121.

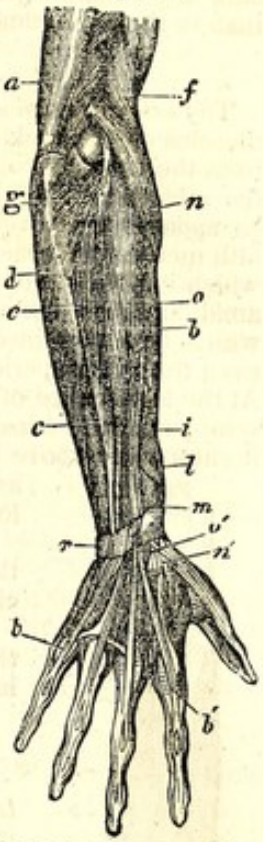

Relations.—The extensor communis digitorum is covered by the fascia of the forearm, from which a great number of its fibres arise superiorly, by the dorsal ligament of the carpus and the dorsal fascia of the metacarpus, which separate it from the skin: it covers the supinator brevis, the three long muscles of the thumb, the extensor proprius indicis, the lower radio-cubital articulation, the carpus, the metacarpus, and the fingers.

Action.—This muscle extends the third phalanx upon the second, the second upon the first, the first upon the corresponding metcarpal bone, then the carpus, and, lastly, the radio-cubital articulation. It is necessary for me to mention the independence of the muscular fasciculi proceeding to each finger: this is peculiar to man, and is much more remarkable in some individuals than in others. By continual exercise, the faculty of extending one finger without the others may be acquired. The tendon for the index is generally the only one not united to the others, and therefore the movements of this finger are by far the most independent.

The Extensor Digiti Minimi.

This is a very slender muscle (extensor proprius auricularis, *Albinus*, *c*, *fig.* 121) placed on the inner side of the common extensor, to which it appears to be an appendix. It is difficult to trace its origin as far as the common tendon, with which it is connected only by an aponeurotic prolongation. Its fleshy fibres *arise* from this prolongation, and from a fibrous pyramid which separates it from the muscles of the deep layer, from the extensor communis digitorum externally, and internally from the extensor carpi ulnaris, and is completed superficially by the fascia of the forearm. The fibres constitute a small, fusiform, fleshy belly, which accompanies the tendon (at least on one side) as far as the head of the ulna; there the tendon enters a special fibrous sheath formed behind the head of that bone; it is then reflected inward to the fifth metacarpal bone, behind which it is retained in a thinner sheath, which, like the preceding, is lined by a synovial membrane.† The tendon then splits into two bands, of which the external (or radial) receives the inner bifurcation of the extensor communis. The three tendinous prolongations becoming united, envelop, as in a sheath, the dorsal aspect of the first phalanx of this finger; having reached the articulation of the first with the second phalanx, they divide into three portions, which are attached precisely in the same manner as the tendons of the extensor communis.

Action.—As its name indicates, this muscle extends the little finger. It might at first sight be imagined that this finger might be moved independently, since it receives a separate muscle; but the connexion of its tendon with that of the extensor communis ren-

* See note, p. 296.

† See note, p. 296.

ders any such independent action as difficult as in the other fingers, and much more so than in the index finger.

The Extensor Carpi Ulnaris.

The *extensor carpi ulnaris* (*e*, *fig.* 121), the most superficial and the most internal* of the muscles on the back of the forearm, *arises* from the external tuberosity of the humerus; from the posterior surface of the ulna, which is a little excavated for this purpose; from the middle third of the posterior border of that bone; and from the anterior surface of an aponeurosis covering the muscle behind. It is *inserted* behind the upper end of the fifth metacarpal bone. Its origin is effected by means of a fibrous pyramid, the apex of which is attached to the outer tuberosity of the humerus. From the interior of this pyramid, and from the other origins above mentioned, the fleshy fibres proceed to a tendon, which, by a very uncommon arrangement, extends through the substance of the muscle, even from its superior attachment, without commencing in the form of an aponeurosis. At the lower third of the forearm, this tendon appears on the posterior border of the then semi-penniform muscle, and continues to receive fleshy fibres on its anterior edge until it enters the groove intended for it on the ulna. This oblique groove is continued as far as the insertion of the tendon into the metacarpal bone, by means of a long, fibrous sheath, and is lined throughout by a synovial membrane.

Fig. 122.

Relations.—The extensor carpi ulnaris is covered by the fascia of the forearm: it covers the ulna, the supinator brevis, and the muscles of the deep layer.

Action.—It extends the second row of the carpus upon the first, and this upon the forearm. It is, at the same time, an adductor of the hand, which it inclines towards the ulnar border of the forearm.

The Anconeus.

The *anconeus* (brevis anconeus, *Eustachius;* le petit anconé, *Winslow*, *g*, *figs.* 121, 122) is a short, triangular muscle, so named from its situation (ἀγκὼν, the prominence of the elbow). It appears to be a continuation of the external portion of the triceps, from which it is only separated by a very slight cellular interval.

Attachments.—It *arises* from the back part of the outer tuberosity of the humerus, and is *inserted* into the outer side of the olecranon, and a triangular surface bounded internally by the posterior border of the ulna. Its origin from the condyle consists of a tendon quite distinct from that common to the muscles on the back part of the forearm. This tendon splits into two diverging bands. The fleshy fibres arising from these proceed inward, the upper horizontally, the lower obliquely downward, and are inserted directly into the outer side of the olecranon, so as to be continuous with the triceps, and into the surface of the ulna.

Relations.—It is covered by a prolongation from the fascia of the triceps, and it covers the radio-humeral articulation, the annular ligament of the radius, the ulna, and a small portion of the supinator brevis.

Action.—It extends the forearm upon the arm, and *vice versâ;* from its oblique direction, it can also rotate it inward.

Muscles of the Deep Layer.

Dissection.—This is the same for all the muscles of the deep layer of the forearm, and consists in removing the muscles of the superficial layer, especially the extensor communis digitorum and the extensor digiti minimi.

The Abductor Longus Pollicis.

The *abductor longus pollicis* (extensor ossis metacarpi pollicis, *i*, *figs.* 121, 122) is the broadest, thickest, and most external muscle of the deep layer (le grand abducteur, *Bichat*).

Attachments.—It *arises* from the ulna below the origin of the supinator brevis, from the interosseous ligament, from the radius, and from a tendinous septum between it and the extensor longus pollicis. It is *inserted* into the upper end of the first metacarpal bone. From the above-mentioned origins the fleshy fibres proceed obliquely downward and outward, constitute a flattened fusiform belly, and are successively attached to the posterior surface of an aponeurosis, which becomes condensed into a flat tendon; this tendon turns round the radius, crossing over the radial extensors of the carpus, and, at the same time, ceasing to receive any fleshy fibres; it is then received into the outer groove on the lower end of the radius, conjointly with the tendon of the extensor brevis

* It is needless to remark that this internal situation presupposes the supination of the forearm. In pronation, this muscle may be correctly termed ulnaris externus, and le cubital externe, according to *Albinus* and *Winslow*.

pollicis, a small fibrous septum intervening between them, and, finally, is inserted into the first metacarpal bone. This tendon is almost always divided longitudinally into two equal parts, and not unfrequently the division extends up to the fleshy portion. Of these two divisions, one is inserted into the first metacarpal bone, the other furnishes attachments to the abductor brevis pollicis.

Relations.—It is covered by the extensor communis digitorum and extensor digiti minimi: it lies immediately under the fascia, from the outer side of the radius to its termination. It covers the interosseous ligament, the radius, the tendons of the radial extensors of the carpus, and the outer side of the wrist-joint, where it may be easily distinguished under the skin.

Action.—It extends and abducts the first metacarpal bone: for a long time it was called the extensor of the thumb; but its chief use is, as Albinus first remarked, in abduction. Winslow observes that, from its obliquity, it can act as a supinator; lastly, it assists in extending the hand.

The Extensor Brevis Pollicis.

This muscle (extensor primi internodii pollicis, *l*, *figs.* 121, 122) is situated internally to the preceding, which it exactly resembles in figure and direction, and with which it was for a long time confounded (partie du premier extenseur du pouce, *Winslow*). It is, however, shorter and more slender (petit extenseur du pouce, *Bichat*).

It *arises* from the radius, occasionally from the ulna, and from the interosseous ligament; and is *inserted* into the upper end of the first phalanx of the thumb. Its origin consists of short, tendinous fibres, the fleshy fibres proceeding from which constitute a slender fasciculus, having a similar arrangement to that of the preceding muscle; its tendon is received into the same fibrous sheath, but is divided from the other by a small septum, and passes on, to be inserted into the first phalanx.

Relations.—The same as those of the abductor longus.

Action.—It extends the first phalanx upon the first metacarpal bone, and then becomes an abductor and extensor of the metacarpal bone of the thumb.

The Extensor Longus Pollicis.

This muscle (extensor secundi internodii pollicis, *m*, *figs.* 121, 122) is much larger than the extensor brevis, within and parallel to which it is situated. It *arises* from a considerable extent of the ulna, from the interosseous ligament, and from the tendinous septa, dividing it from the extensor carpi ulnaris, and the extensor proprius indicis: it is *inserted* into the upper end of the second phalanx of the thumb. The fleshy fibres form a flat fusiform bundle, directed obliquely like the preceding muscle; they terminate in succession around a tendon, which emerges from them at the carpal extremity of the ulna, enters a special osteo-fibrous sheath, and crosses obliquely over the tendons of the two radial extensors, being separated from the tendons of the abductor longus and extensor brevis pollicis by an interval which may be readily distinguished through the integuments, and gives rise to the hollow on the outer side of the wrist, commonly called the salt-cellar. The tendon next crosses obliquely over the first interosseous space, gains the inner edge of the first metacarpal bone, and then that of the first phalanx, upon which it is expanded, and proceeds to be inserted into the second or ungual phalanx of the thumb.

Relations.—Its general relations are the same as those of the preceding muscle.

Action.—Its uses are also the same; but it acts in a special manner upon the second phalanx of the thumb, which it extends upon the first before exerting any influence upon this last-mentioned bone. It has less power in abduction than the preceding muscles.

The Extensor Proprius Indicis.

This is an elongated fusiform muscle (indicator, *Albinus*, *r*, *fig.* 122) like the preceding, below and parallel to which it is situated. It *arises* from the ulna, the interosseous ligament, and a septum intervening between it and the extensor longus pollicis: it is *inserted* into the last two phalanges of the index finger. The fleshy fibres proceed obliquely from their origins and terminate around a tendon, which they accompany as far as the sheath of the extensor communis digitorum: into this sheath the tendon enters, and, having escaped from it, crosses obliquely over the carpus and the second interosseous space, becomes situated on the inside of the tendon given off to the index finger by the extensor communis, unites intimately with that tendon opposite the lower end of the metacarpus, and terminates with it in the manner already indicated. Its *relations* are the same as those of the preceding muscles.

Action.—It enables the index finger to be extended independently of the others, and hence, without doubt, arises the particular use of that finger. I should add, that the union of its tendon with the one furnished by the common extensor is so intimate, that its independence of action would have been much less, had not the fleshy fasciculus of the common extensor destined for it been itself almost isolated.

MUSCLES OF THE HAND.

The Abductor Brevis Pollicis.—Opponens Pollicis.—Flexor Brevis Pollicis.—Adductor Pollicis.—Palmaris Brevis.—Abductor Digiti Minimi.—Flexor Brevis Digiti Minimi.—Opponens Digiti Minimi.—The Interosseous Muscles, Dorsal and Palmar.

The muscles of the hand occupy the entire palmar region. They are divided into those situated on the outer side, viz., the muscles of the *thenar* eminence, or ball of the thumb; those on the inner side, viz., the muscles of the *hypothenar* eminence, or of the little finger; and those which occupy the interosseous spaces.

All the muscles of the thenar eminence belong to the thumb; they are, in the order of their superposition, the abductor brevis, the opponens, the flexor brevis, and the adductor pollicis. Those of the hypothenar eminence all belong to the little finger, and are the abductor, the flexor brevis, and the opponens. The palmaris brevis may be included in this region.

The interosseous muscles are seven in number—four dorsal and three palmar. The lumbricales, which belong to this region, have been already described with the tendons of the flexors of the fingers.

Muscles of the Thenar Eminence, or Muscles belonging to the Thumb.

I divide these into three muscles inserted into the outer side of the first phalanx of the thumb, or into the first metacarpal bone, and a single muscle inserted into the inner side. The former are the abductor brevis, the opponens, and the flexor brevis; the latter consists of the adductor, in which I include a part of the flexor brevis of authors generally.

Muscles inserted into the Outer Side of the First Phalanx of the Thumb, or into the First Metacarpal Bone.

Dissection.—Make an oblique incision from the middle of the annular ligament of the carpus to the outer side of the first phalanx of the thumb, and a circular incision round the wrist; detach the flaps, raise the external and middle palmar fasciæ, and then cautiously separate the muscles of this region, which are recognised by the following characters.

The Abductor Brevis Pollicis.

This is the most superficial of the muscles constituting the ball of the thumb (*q*, *fig.* 119). It *arises* by tendinous and fleshy fibres from the os scaphoides, from the upper, anterior, and external part of the anterior annular ligament of the carpus, and almost always from an expansion of the tendon of the abductor longus pollicis. It is a small, thin, flat muscle, passing outward and downward, and *inserted* by a flat tendon into the outer side of the first phalanx of the thumb. A very narrow cellular line separates it on the inside from the flexor brevis, which is situated on the same plane. It is covered by the external palmar fascia, and it covers the opponens muscle, from which it is distinguished by the direction of its fibres, and by a thin intervening aponeurosis.

Action.—It draws the thumb forward and inward, and therefore might be termed the superficial opponens. From its attachments, it might be called *scaphoido-phalangal.*

The Opponens Pollicis.

The *opponens pollicis* (*r*, *figs.* 119, 120), a small triangular muscle, *arises* from the trapezium, and the anterior and external part of the anterior annular ligament of the carpus, in front of the sheath of the flexor carpi radialis. From these origins, which are partly fleshy and partly tendinous, the fleshy fibres radiate downward and outward, the highest being the shortest and the most horizontal. They are *inserted* into the entire length of the outer border of the first metacarpal bone.

This muscle is covered by the abductor brevis, which projects a little beyond it on the outside, and from which it is separated by a more or less distinct aponeurosis. It covers the first metacarpal bone, and its articulation with the trapezium.

Action.—It draws the first metacarpal bone inward and forward, thus opposing it to the others, as its name indicates. From its attachments, it may be called *trapezio-metacarpal.*

The Flexor Brevis Pollicis.

It is difficult to point out the limits of this muscle, or, rather, they have hitherto been quite arbitrary. Its inferior attachment has been usually divided between the external and the internal sesamoid bones (Boyer, *Traité d'Anatomie*, tom. ii., p. 307; Bichat, *Anatomie Déscriptive*, tom. ii., p. 272); but we shall consider that portion only which is attached to the external sesamoid bone as belonging to this muscle, referring the entire fleshy mass that is inserted into the internal sesamoid bone to the adductor pollicis.*

* The arrangement I have adopted is founded upon the inferior attachments of the muscles, for at their origins they are so blended that their division is more or less arbitrary. I divide the muscular fasciculi connected with the thumb, therefore, into two sets, viz., those proceeding from the carpus to the first metacarpal

This division is, moreover, established by the tendon (*l*, *fig.* 120) of the flexor longus pollicis. Proceeding then from below upward, in the dissection of the flexor brevis (*t*, *figs.* 119, 120), we shall see that it is triangular, much larger than the preceding two muscles, bifid above, and channelled in front. It arises by tendinous and fleshy fibres from a process on the trapezium, from the lower edge of the annular ligament, from all the reflected portion of that ligament forming the sheath of the flexor carpi radialis, and extending as far as the os magnum, and from the os magnum itself by a portion which is usually distinct. From these different origins the fleshy fibres proceed downward and outward, the internal being the most oblique; and, converging so as to form a thick fasciculus, are inserted, through the medium of the external sesamoid bone, into the first phalanx.

Relations.—It is covered by the external palmar fascia, which is prolonged in front of it; it covers the tendon of the flexor longus pollicis, and more internally those of the common flexor. It also covers a small portion of the outer border of the adductor pollicis, and the tendon of the flexor carpi radialis. Its outer border, or, rather, side, is in relation with the short abductor, from which it is easily separated, and with the opponens, sometimes being continuous with it. Its inner border is distinct from the adductor below, but is confounded with it at its origin. Its tendon of insertion into the phalanx is covered by that of the short abductor, which lies externally to it. From its attachments, it might be called *trapezio-phalangal*, and, from its uses and position, the *opponens internus*.

Action.—It is evidently not a flexor pollicis, but, like the preceding muscles, it draws the thumb forward and inward, and it acts more decidedly in producing the latter effect, because it is inserted in a more favourable manner than the other muscles. This, therefore, is also an opponens muscle.

Muscle inserted into the Inner Side of the First Phalanx of the Thumb.

The Adductor Pollicis.

This is the largest of all the muscles of the thumb (*u*, *figs.* 119, 120); it is very irregularly triangular, and *arises* from the entire extent of the anterior border of the third metacarpal bone, from the anterior surface of the os magnum, from the anterior and upper part of the trapezoides, from the anterior part of the trapezium by a tendinous and fleshy fasciculus, and from the palmar interosseous fascia, near the third metacarpal bone. From these different origins the fleshy fibres proceed, the lower horizontally, the rest more and more obliquely outward; they all converge to form a thick fleshy bundle, which is inserted through the medium of the internal sesamoid bone into the first phalanx of the thumb.

Relations.—Its inner two thirds are deeply situated, and covered by the tendons of the flexor profundus digitorum, by the lumbricales, and by an aponeurosis, which, becoming continuous with the deep interosseous fascia, constitutes the sheath of the muscle. It is sub-cutaneous near its lower border. It covers the first two interosseous spaces, from which it is separated by a very strong aponeurosis. It is again sub-cutaneous behind, also along its lower border, which may be easily felt under the fold of skin, extending from the thumb to the index finger.

Action.—It is an adductor; it draws the thumb towards the median line or axis of the hand, represented by the third metacarpal bone.

Muscles of the Hypothenar Eminence, or Muscles belonging to the Little Finger.

These muscles correspond exactly to those of the thumb: the reason that three only are described is, that the one which represents the adductor of the thumb is situated in the fourth interosseous space, and is, therefore, classed with the interosseous muscles, to be hereafter described. All the muscles of the hypothenar eminence are inserted into the inner side of the first phalanx of the little finger, or into the third metacarpal bone. We find also a cutaneous muscle in this region, viz., the palmaris brevis.

The Palmaris Brevis.

This is a very thin square muscle (caro quædam quadrata, *b*, *fig.* 118), situated in the adipose tissue covering the hypothenar eminence. It *arises* from the anterior annular ligament of the carpus, and the inner edge of the middle palmar fascia, by very distinct tendinous fasciculi, succeeded by equally distinct fleshy bundles, which pass horizontally inward, and terminate in the skin.

Relations.—It is covered by the skin, to which it adheres intimately, especially by its inner extremity (le palmaire cutané, *Winslow*); it covers the muscles of the hypothenar

bone and to the outer side of the first phalanx of the thumb, and those extending from the carpus to the inner side of the same phalanx. The first set, which might be regarded as a single muscle, comprises the abductor brevis, the opponens, and the flexor brevis; the other constitutes the abductor pollicis, which I regard as the first palmar interosseous muscle. The action of the first set is common, viz., to carry the thumb forward and inward; they are, therefore, all muscles of opposition (perhaps no muscles are so badly named as those of the thenar eminence); the muscle formed by the second set is really an adductor, as its name implies, and so are all the palmar interossei, among which it should be included.

eminence and the ulnar artery and nerve, from all of which it is separated by the internal palmar fascia.

Action.—It corrugates the skin over the hypothenar eminence.

The Abductor Digiti Minimi.

It *arises* from the pisiform bone, and from an expansion of the flexor carpi ulnaris, by tendinous fibres; these are succeeded by a fusiform fleshy belly (*v*, *fig.* 119), which passes vertically along the internal (or ulnar) surface of the fifth metacarpal bone, and is inserted by a flat tendon into the inner side of the first phalanx of the little finger.

Relations.—It is covered by the external palmar fascia, and covers the opponens digiti minimi.

Action.—As it name denotes, it abducts the little finger from the axis of the hand.

The Flexor Brevis Digiti Minimi.

This muscle (*w*, *fig.* 119) is situated on the outer or radial border of the preceding, from which it is distinguished by *arising* from the unciform bone. The two muscles are separated by the ulnar vessels and nerves, which pass between them, in order to penetrate into the deep palmar region. In other respects, as in direction, insertions, and relations, the muscles resemble each other; they have accordingly been described by Chaussier as a single muscle, under the name of *le carpo-phalangien du petit doigt*. This muscle is often wanting, but the fleshy fibres which usually constitute it are then always found in some measure blended with the other muscles.

Action.—It produces slight flexion of the little finger.

The Opponens Digiti Minimi.

This muscle (*y*, *fig.* 119) is generally distinct from the preceding, and is the representative of the opponens pollicis. It *arises* from the hooklike process of the unciform bone, and from the contiguous part of the annular ligament: from these points the fibres proceed downward and inward (*i. e.*, towards the ulnar border of the hand), the highest being the shortest and the most horizontal: they are *inserted* into the whole length of the inner or ulnar margin of the fifth metacarpal bone.

Relations.—It is covered by the preceding muscles and by the internal palmar fascia: it covers the fifth metacarpal bone, the corresponding interosseous muscle, and the tendon of the superficial flexor proceeding to the little finger.

Action.—It opposes the little finger to the thumb by drawing it forward and outward.

The Interosseous Muscles.

Dissection.—Remove the tendons of the extensor muscles behind, and those of the flexor muscles in front, together with the lumbricales, preserving, at the same time, the digital insertions of these small muscles. Dissect and study the deep palmar fascia, a fibrous layer covering the interosseous muscles in the palm of the hand, which sends prolongations between the two kinds of these muscles, and is inserted into the anterior borders of the metacarpal bones, enclosing each interosseous muscle in a proper sheath. After having studied the palmar and dorsal fascia, separate the bones of the metacarpus by tearing their connecting ligaments, and the interossei will then be completely exposed.

The *interossei*, so named from their position, and distinguished from each other by the numerical appellations first, second, third, &c., are divided into *palmar* (*p p p*, *fig.* 123) and *dorsal* (*d d d d*), according as they are situated nearer to the palm or to the back of the hand. They are also distinguished into *adductors* and *abductors* of the fingers.

There are two in each interosseous space, one occupying its dorsal, the other its palmar aspect; and, as there are four interosseous spaces, it would seem that there should be eight interosseous muscles; nevertheless, seven only are admitted by modern anatomists, in consequence of the first palmar interosseous muscle, which belongs to the thumb, being separately described as the adductor pollicis. This separation is founded upon the peculiar arrangement presented by that muscle, which is not attached from the first to the second, but extends from the first to the third metacarpal bone; an important fact, that explains the great extent to which the thumb can be adducted.

A minute description of the interosseous muscles would be both useless and tedious. I shall content myself with pointing out their general conformation, and the law which regulates their arrangement.

In taking a general view of the interosseous muscles, they must be considered with regard to the adduction or abduction of the fingers; but these terms must not be understood in reference to the axis of the skeleton, but to the axis of the hand, which is represented by a line passing through the third metacarpal bone and the middle finger. This being admitted, all the dorsal interossei will be found to be abductors, and all the palmar interossei adductors.

Thus, the first dorsal interosseous muscle proceeds from the first and second metacarpal bones to the *outer* or *radial side* of the first phalanx of the index finger: it is therefore an abductor of that finger. The second extends from the second and third meta-

carpal bones to the *outer* or *radial side* of the first phalanx of the middle finger, and is an abductor of that finger. The third extends from the third and fourth metacarpal bones to the *inner* or *ulnar side* of the phalanx of the middle fingers, and is also an abductor of the same, because it separates it from the supposed axis of the hand. The fourth extends from the fourth and fifth metacarpal bones to the *inner* or *ulnar side* of the first phalanx of the fourth finger, and it again is an abductor of that finger from the axis of the hand, although, as well as the preceding muscle, it is an adductor as regards the axis of the body. In order to render this view more intelligible, I have been accustomed to represent the five fingers by five lines (see diagram *d*), to prolong the middle line for the axis of the hand, and then to draw other lines (the four fine lines) representing the *axes* of the muscles; the demonstration is thus rendered complete.

d

In the same manner, all the palmar interossei are adductors as regards the axis of the hand. Thus the first, which is represented by the adductor pollicis, and extends from the third metacarpal bone to the *inner* or *ulnar side* of the first phalanx of the thumb, is an adductor as regards the axis of the hand as well as that of the body; the second, extending from the second metacarpal bone to the *inner* or *ulnar side* of the first phalanx of the index finger, is an adductor both as regards the axis of the hand and that of the body; the third, extending from the fourth metacarpal bone to the *outer* or *radial side* of the first phalanx of the ring finger, is an adductor as regards the axis of the hand; and, lastly, the fourth, extending from the fifth metacarpal bone to the *outer* or *radial side* of the first phalanx of the little finger, is an adductor as regards the axis of the hand, but an abductor in reference to the axis of the body. A similarly-constructed figure, as that employed for the dorsal interossei, will always keep this arrangement in the memory (see diagram *p*; the four fine lines represent the *axes* of the palmar muscles). The general disposition of the interossei may be summed up in the following very simple law: All the dorsal interossei have their fixed attachments *farther* from the axis of the hand than their movable one; all the palmar interossei have their fixed attachments *nearer* to the axis of the hand than their movable one.

p

We may now consider the general arrangement of these little muscles.

The Dorsal Interossei.

These are short, prismatic, and triangular muscles (*d* to *d*, *fig.* 123), extending from the two metacarpal bones, between which they are placed, to the first phalanx and the extensor tendon of one of the corresponding fingers. They *arise* by a double origin, between which the perforating arteries pass. But while one of these origins is limited to the back part of the lateral surface of one of the metacarpal bones, the other occupies the whole length of the corresponding lateral surface of the other metacarpal bone. From this double origin the fleshy fibres pass obliquely forward round a tendon, which only emerges from them near the metacarpo-phalangal articulation; it then expands, and is inserted partly to the upper end of the first phalanx and partly to the outer edge of the corresponding extensor tendon.

Fig. 123.

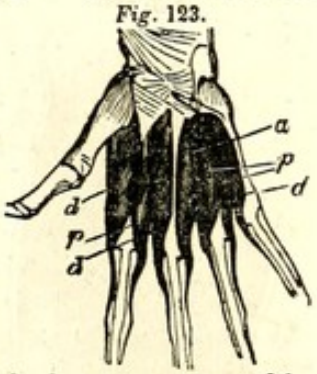

Relations.—The dorsal interossei correspond behind with the dorsal surface of the hand and the extensor tendons, from which they are separated by a very thin aponeurosis; in front, they are visible in the palm of the hand by the sides of the palmar interossei, and, like the latter, are covered by the muscles and tendons of the palmar region, being separated from those parts by the deep palmar fascia. A distinct cellular line, or, rather, an aponeurotic septum, intervenes between one of their lateral surfaces and the corresponding palmar interosseous muscle; the other lateral surface is in relation, through its entire length, with the metacarpal bone on which it is implanted.

Action.—These muscles are evidently abductors of the first phalanges of the fingers, the axis of the hand being taken as the point of departure. Their insertion into the extensor tendons explains why previous extension of the fingers is necessary to the movement of abduction.

The *first dorsal interosseous muscle* merits a special description. It is larger than the others, on account of the greater size of the space occupied by it; it is flat and triangular, and *arises* by two origins, separated, not by a perforating branch, but by the radial artery itself. A fibrous arch completes the half ring formed by the interval between the first two metacarpal bones for the passage of this artery. The external head of the muscle arises from the upper half of the inner border of the first metacarpal bone; the internal from the entire length of the external surface of the second metacarpal bone, and from the ligaments which unite it to the trapezium. From these points the fleshy fibres proceed, forming two thick bundles, which are perfectly distinct above, and converge to a tendon that is attached to the outer side of the first phalanx of the index finger.

Relations.—It is covered behind by the skin; it corresponds in front to the adductor and flexor brevis pollicis, excepting below, where it is sub-cutaneous. Its lower edge, directed obliquely downward and inward, is immediately sub-cutaneous, and crosses the corresponding edge of the adductor pollicis at a very acute angle.

The Palmar Interossei.

These, like the preceding, are short, prismatic, triangular, and penniform muscles. They are three in number (*p p p, fig.* 123) according to most authors, but four if we include the adductor pollicis. They all occupy the palm of the hand, as their name indicates, and extend from the entire length of one of the metacarpal bones bounding the interosseous space in which they are situated to the first phalanx of one of the corresponding fingers, and to its extensor tendon.

They arise from about the anterior two thirds of the lateral surface of only one metacarpal bone; they are, therefore, covered behind by the dorsal interossei, which, being attached to the entire lateral surface of the other metacarpal bone, project equally into the palm. Lastly, their insertions into the phalanges and their extensor tendons correspond precisely with those of the dorsal interossei.

Relations.—They are covered by the flexor tendons and by the muscles of the palmar region: each is in relation behind with a dorsal interosseous muscle; on one side with the dorsal muscle of the corresponding finger, and on the other with the metacarpal bone from which it arises.

Action.—They are evidently adductors, as regards the axis of the hand, and, like the dorsal interossei, they bind down the extensor tendons; they can only act effectually when the fingers have been previously extended.

MUSCLES OF THE LOWER EXTREMITIES.

The muscles of the lower extremities may be arranged in four groups, viz., those of the pelvis, of the thigh, of the leg, and of the foot.

MUSCLES OF THE PELVIS.

The Glutæi, Maximus, Medius, et Minimus.—Pyriformis.—Obturator Internus.—Gemelli, Superior et Inferior.—Quadratus Femoris.—Obturator Externus.—Action of these Muscles.

Fig. 124.

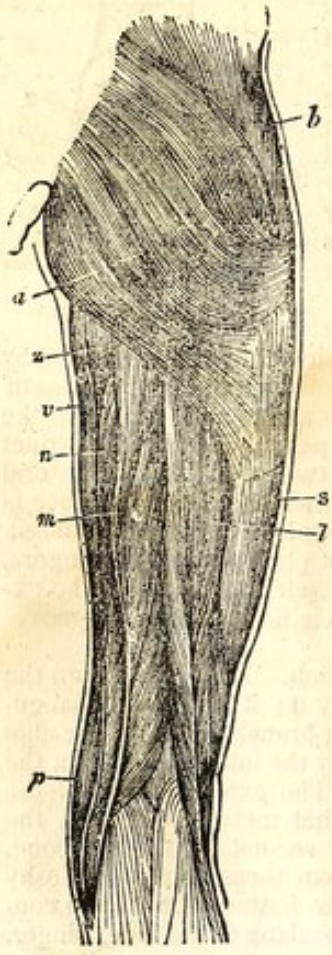

The muscles of the pelvis are divided into those occupying the posterior and those occupying the anterior region. The former are very numerous, consisting of the three glutæi, maximus, medius, and minimus, the pyriformis, the obturator internus, the gemelli, the quadratus femoris, and the obturator externus.

The iliacus, which may with propriety be considered as belonging to the pelvis, and as forming its anterior region, has been already described, together with the psoas, under the name of the *psoas-iliac* muscle.

The Glutæus Maximus.

Dissection.—Having placed the subject on its face, raise the pelvis by a block, flex the leg forcibly, and rotate it inward; then make an oblique incision along the middle of the buttock, from the sacrum towards the great trochanter, dividing both the skin and fascia covering the muscle: dissect up the two flaps, one from below upward, the other from above downward, following the direction of the muscular fibres.

The *glutæus maximus* (*a, fig.* 124) is the most superficial of the muscles on the posterior aspect of the pelvis; it is broad, thick, and pretty regularly quadrilateral; it is the largest muscle of the human body, in this respect coinciding with the great size of the pelvis and femur in man; it causes the prominence of the buttocks. Its great size is one of the most distinctive characters of the muscular system of man, and has reference to his biped position.

Attachments (see *a, fig.* 125).—It *arises* from the posterior semicircular line of the ilium, and the portion of the bone behind that line; from the vertical sacro-iliac ligament, and the outer margin of the common aponeurosis of the posterior spinal muscles; from the crest of the sacrum, sometimes only from the tubercles which form a continuation of the transverse processes of the vertebræ on the outside of the posterior

sacral foramina; from the edges of the coccyx, and the notch terminating the crest of the sacrum below, this origin being often effected by means of a tendinous arch, under which the last posterior sacral nerves pass; from the posterior surface of the great sacro-sciatic ligament; and, lastly, from the posterior surface of the aponeurosis of the glutæus medius. It is *inserted* (*a*, *fig.* 125) into the rough line leading from the great trochanter to the linea aspera of the femur.

The fleshy fibres arise either directly or by short tendinous fibres, and proceeding parallel to each other outward, and a little downward, unite into large distinct fasciculi, capable of being separated through their entire length, and constituting an extremely thick, quadrilateral, and very regular muscle, which, having reached the outside of the thigh, terminates by tendinous fibres. These are received between two layers of the fascia lata, which is here very thick; in passing downward they converge, escape from the fascia lata, curve round the base of the great trochanter, or, rather, the tendon of the vastus externus, from which they are separated by a synovial bursa, and are successively inserted by so many large fasciculi into the series of tubercles and depressions, extending from the great trochanter to the linea aspera, and from the external bifurcation of that line. The lower fleshy fibres are attached directly to the linea aspera, and a certain number are inserted merely into the fascia lata. In order to obtain a good view of the femoral insertions of this muscle, its tendon must be separated from the fascia lata.

Relations.—It is covered by a large quantity of fat, being separated from it by an expansion from the aponeurosis of the glutæus medius, from which are given off the cellular prolongations that divide the muscle into thick, parallel, and easily separable fasciculi.

It covers the glutæus medius, the pyriformis, the gemelli, the obturator internus, the quadratus femoris, the great sciatic notch, and the tuberosity of the ischium, together with the muscles attached to it, viz., the semi-tendinosus, the semi-membranosus, and the long head of the biceps. It covers also the great trochanter, the adductor magnus, and the triceps femoris, the glutæal, ischiatic, and internal pudic vessels and nerves, and the great sciatic nerves. Its upper border is very thin, and rests upon the glutæus medius; its lower border forms a very marked prominence beneath the skin, that affords the surgeon very precise indications, both in the diagnosis of many diseases of the hip-joint; in operations performed for the purpose of reaching the tuberosity of the ischium, when it is either carious or necrosed; in those for the relief of sciatic hernia; or, lastly, in searching for the sciatic nerve, whenever it becomes necessary to operate upon it. Several bursæ mucosæ, which have been well described by Monro, separate the glutæus maximus from the eminences which are covered by it. One of these separates it from the great trochanter, and is almost always multi-locular: I have seen it filled with a sanguineous synovia. A second exists over the tuberosity of the ischium, but is often wanting; and a third between the tendon of this muscle and the vastus externus.*

Action.—The glutæus maximus is an *extensor*, an *abductor*, and a *rotator* of the thigh outward. When the femur is fixed, as in standing, it acts upon the pelvis, which it draws backward and to its own side, and rotates so that the anterior surface of the trunk is turned to the opposite side. Besides this, it is easy to see that the lower fibres can act as adductors. By its connexions with the fascia lata, it is one of the principal tensors of this structure; by its attachment to the coccyx, it tends to prevent that bone from being thrown backward, forward, or to one side.

The Glutæus Medius.

Dissection.—Make a vertical incision through the middle of the glutæus maximus, or detach that muscle from the pelvis; remove the adipose tissue from the sub-cutaneous portion of the muscle, and also the fascia lata; dissect the tensor vaginæ femoris, which covers the anterior fibres of this muscle.

The *glutæus medius* (*b*, *figs.* 124 to 127) is intermediate to the other two glutæi, both as regards size and position; it is a broad, thick, radiated muscle, situated more deeply than the preceding, beyond which it projects upward and forward (*fig.* 124). The glutæus maximus is attached to a small portion only of the iliac fossa: the glutæi medius and minimus share almost the whole of it between them.

Attachments.—It *arises* from the whole extent of the curved triangular surface included between the superior semicircular line behind, the anterior three fourths of the crest of the ilium above, and the inferior semicircular line below; from the anterior superior spine of the ilium and the notch immediately below it; from the deep surface of a dense aponeurosis, which is inserted into the outer lip of the crest of the ilium, covers all the upper portion of the muscle, and becomes continuous with the fascia lata: opposite the junction of the anterior with the middle third of the crest of the ilium, at which point a large tubercle exists upon the bone, this aponeurosis is so dense as to resemble a tendon. The muscle also arises from a deep aponeurosis, extending from the anterior part of the inferior semicircular line, and giving attachment, on its external surface, to a great number of fleshy fibres; and, lastly, from the fascia lata internally to the tensor vaginæ femoris. It is *inserted* into the external surface of the great trochanter (*figs.* 125, 127).

* See note, p. 296.

From these numerous origins the fleshy fibres proceed in different directions; the posterior forward, the middle vertically, and the anterior backward, becoming more and more horizontal in front. They all terminate upon the two surfaces and edges of a radiated aponeurosis, the fibres of which are gradually concentrated, and folded upon themselves, so as to form a flat tendon, inserted, not into the upper border, as it is generally said, but into the external surface of the great trochanter, along an oblique line running downward and forward, so that the anterior fibres of the muscle are inserted into the anterior extremity of the lower border of the great trochanter, and the posterior fibres into the back part of the upper border; at this latter point a well-marked projection sometimes exists, the size of which generally indicates the power of the glutæus medius. A synovial bursa intervenes between the tendon and that part of the great trochanter over which it passes.*

Relations.—It is covered by the glutæus maximus, the tensor vaginæ femoris, and the skin: it covers the glutæus minimus, with which its outer border is blended, and the glutæal vessels and nerves. Its lower border is parallel with the pyriformis (*fig.* 125).

Action.—The glutæus medius is both an *extensor* and an *abductor of the thigh*. Moreover, the anterior fibres rotate the femur inward, and the posterior outward; but the former have the greater power, for they are more numerous, the muscle being twice or thrice as thick in front as behind; it is, therefore, an *extensor*, an *abductor*, and a *rotator inward of the thigh*. Winslow denies that it is an extensor, and considers it only as an abductor; this is only true in the position of standing upon both feet. In the sitting posture, again, this muscle in some degree loses its power as an extensor and abductor, and acts merely as a rotator. When the femur is fixed, as in standing, the glutæus medius extends the pelvis, draws it to its own side, and rotates it, so that the front of the trunk is turned towards the same side. It co-operates with the glutæus maximus in the first two motions, but antagonizes it in the last. Finally, its anterior fibres appear to me calculated to flex the thigh upon the pelvis, especially when the flexion has been already commenced by other muscles.

The Glutæus Minimus.

The *glutæus minimus* (*c*, *fig.* 127) is exposed by simply cutting across the preceding muscle, beneath which it lies; it is thinner, and more regularly radiated. It *arises* from the anterior part of the crest of the ilium, below the glutæus medius, from the outside of the sciatic notch, and from all that part of the external iliac fossa situated below the inferior semicircular line: from these points the fibres converge, the middle passing vertically, the posterior forward, and the anterior backward, to the deep surface of a radiated aponeurosis, the fibres of which are collected together into bands, that are *inserted* separately into the anterior border and anterior half of the upper border of the great trochanter. Most commonly the posterior band is intimately attached to the tendon of the pyriformis.

Relations.—It is covered by the glutæus medius, with which its anterior fibres are blended; it covers the external iliac fossa, the reflected tendon of the rectus femoris, and the upper part of the hip-joint, from which it is separated by some fatty cellular tissue.

Action.—It is much more directly an abductor than the preceding muscles. Its anterior half rotates the thigh inward, and its posterior half outward. If the femur be fixed, it extends the pelvis, inclines it to its own side, and turns the anterior aspect of the trunk to the same side; by its anterior fibres it assists slightly in producing flexion.

General Remarks upon the Action of the Glutæi.—The three muscles we have just examined generally have their fixed points upon the pelvis; and, in this point of view, are of the greatest importance in the standing posture. By their means the pelvis, firmly held down from behind, is enabled to resist the effects of the weight of the trunk, which tends to throw it forward: hence the enormous development of these muscles in man, evidently proving his destination for the erect position. These same muscles are the principal agents in the position of standing upon one foot, inclining the pelvis to their own side, and balancing the entire weight of the opposite side of the trunk. They also rotate the trunk when the individual is standing upon one foot. They are all extensors and abductors; the glutæus maximus is a rotator outward; the other two are rotators inward. Hence we may understand how the thigh can be so powerfully rotated inward, although there are no direct muscles for that purpose; while a great number are specially intended to produce rotation outward, which movement, indeed, is performed much more energetically than rotation inward.

The Pyriformis.

Dissection.—Detach the glutæus maximus, and separate the pyriformis from the lower border of the glutæus medius, to which it is parallel. In order to see the sacral attachments of the muscle, make an antero-posterior section of the pelvis.

The *pyriformis* or *pyramidalis* (*d*, *fig.* 125) is sometimes double: it is a flat muscle, of a pyriform, or, rather, pyramidal shape, lying almost horizontally along the lower margin of the glutæus medius, with which it seems to be continuous, and is sometimes intimately

* See note, p. 296.

united: it is partly situated in the cavity of the pelvis, and assists in filling up the sciatic notch.

Attachments.—It *arises* from the anterior surface of the sacrum (*p, fig.* 111), in the intervals between the grooves forming the continuations of the anterior sacral foramina, and also opposite those grooves, by three or four digitations, which are sometimes traversed by the great sciatic nerve: these origins are sometimes concentrated into a small space around the second and third anterior sacral foramina. It also arises from the anterior surface of the great sacro-sciatic ligament, and from the upper part of the sciatic notch. It is *inserted* into the back part of the upper edge of the great trochanter. The fleshy fibres pass from their origins almost horizontally outward and a little backward, and form a muscle which fills up the upper part of the great sciatic notch, and, becoming much narrower immediately after emerging from the pelvis, from the convergence of its fibres, terminates on the posterior surface and edges of an aponeurosis, which is afterward converted into a round tendon, and is fixed to the upper border of the great trochanter, behind the glutæus minimus, and above the gemelli and obturator internus, with which it is almost always intimately connected.

Relations.—Its anterior surface is in relation with the rectum, the sciatic plexus, and the hypogastric vessels within the pelvis, and with the hip-joint outside that cavity; its posterior surface, with the sacrum and the glutæus maximus; its upper margin, with the glutæal vessels and nerves, which separate it from the glutæus medius; its lower margin, with the ischiatic vessels, and with the great and small sciatic nerves. Sciatic herniæ take place between the upper margin of this muscle and the sciatic notch. Sometimes the muscle reaches the summit of the notch; occasionally, a considerable interval exists between them; in such cases, there is a predisposition to this species of herniæ.

The Obturator Internus.

The *obturator internus* (*e, fig.* 125) is a triangular reflected muscle, extending from the inner surface of the margin of the obturator foramen to the digital cavity of the great trochanter. Its course and direction are alike remarkable.

Attachments.—It *arises* from the posterior surface of the obturator ligament, from the pelvic fascia lining the inner surface of this muscle, and from the tendinous arch which converts the *sub-pubic groove* into a canal; also, from the entire circumference of the obturator foramen, viz., from the internal surface of the descending ramus of the pubes and the ascending ramus of the ischium, and from the whole extent of the quadrilateral surface situated between the obturator foramen and the sciatic notch; and, lastly, by a few fibres from the brim of the pelvis. It is *inserted* into the digital cavity of the great trochanter. The fleshy fibres arise directly from this extensive surface, and, converging downward and outward, pass out of the pelvis through a triangular opening formed by the spine of the ischium and lesser sacro-sciatic ligament above, by the great sacro-sciatic ligament on the inside, and by the body of the ischium on the outside. At its exit from the pelvis the muscle becomes much narrower, is reflected at a right angle over the body of the ischium as over a pulley, is next received into a groove formed for it by the gemelli, and proceeds horizontally outward, to be inserted into the digital cavity of the great trochanter below the pyriformis. In order to obtain a good view of the structure of this muscle, it must be detached from its insertion and turned inward. We shall then perceive that the tendon divides into four or five diverging portions upon the deep surface of the muscle, which are lost in its interior. A well-marked synovial membrane* intervenes between the tendon and the trochlear surface on the body of the ischium, which is covered with cartilage that is streaked, as it were, in the direction of the movements. Cowper and Douglas alluded to the presence of this bursa when they named the muscle *marsupialis vel bursalis.*

Relations.—In the pelvis the obturator internus is in relation with the obturator ligament and the circumference of the obturator foramen, by its anterior surface; and with the pelvic fascia and levator ani muscle, which separates it from the bladder, by its posterior surface. During its passage through the orifice I have described, it is in relation with the internal pudic vessels and nerves; externally to the pelvis, it is covered by the great sciatic nerve and the glutæus maximus, and it covers the hip-joint.

From the great extent of the pelvic origins of this muscle, almost the whole of the anterior and lateral parietes of the pelvis are covered internally by a layer of muscular tissue; the posterior wall is also in a great measure covered by the pyriformis.

The origins of the muscular fibres from the tendinous arch of the obturator ligament are so arranged, that the contraction of the muscle can have no effect in diminishing the size of the sub-pubic foramen intended for the passage of vessels and nerves. There are sometimes two small tendinous arches; one for the nerve, the other for the artery and vein.

The Gemelli, Superior et Inferior.

The *gemelli* (gemini, *Albinus;* les petits jumeaux, *Winslow, f* and *g, fig.* 125), two small

* See note, p. 296.

fleshy fasciculi, accessories to the obturator internus, are generally distinguished by anatomists into the *superior* (*f*) and the *inferior* (*g*); they are separated from each other by the tendon of the obturator internus, for the reception of which they form a groove. Above and below this groove they take their origin; the *superior* from the spine of the ischium, and the *inferior*, which is the larger, from the tuberosity of that bone, immediately above the attachment of the great sacro-sciatic ligament, and even slightly from the ligament itself. They both pass horizontally outward, are sometimes united either behind or in front of the tendon of the obturator internus, which they then completely embrace, and with which they are entirely or partially blended, being *inserted* with it into the digital cavity of the great trochanter.

Their *relations* are the same as those of the reflected portion of the obturator internus. The gemellus superior is often wanting, and the inferior is frequently double. I have several times seen the superior terminate in the tendon of the pyriformis, and the inferior in the tendon of the obturator internus.

Action.—They rotate the thigh outward. Their relations with the synovial capsule of the obturator internus led to their being designated marsupiales by *Cowper*, and by *Portal*, le muscle capsulaire de la capsule du tendon de l'obturateur interne.

The Quadratus Femoris.

This muscle (*i*, *fig.* 125), shaped like a parallelogram, is situated immediately below the gemellus inferior. It *arises* from the external border of the tuberosity of the ischium, in front of the semi-membranosus, from which it is separated by adipose tissue. From this point the fibres proceed horizontally outward, parallel to each other, and are *inserted* into "an oblong ridge* projecting partly from the back of the root of the great trochanter, and partly from the femur immediately below it;" but above the attachment of the adductor magnus, with which, at first, it appears to be continuous, but from which it is always separated by the internal circumflex vessels.

This muscle is sometimes wanting; but very frequently its pelvic attachments are prolonged as far as the ascending ramus of the ischium; in which cases it is twisted inferiorly upon itself, so as to oppose a surface, not a border, to the adductor magnus. Its relations behind are the same as those of the preceding muscles; in front, it covers the obturator externus and the lesser trochanter, from which it is often separated by a synovial capsule.

The Obturator Externus.

Dissection.—The lower or horizontal portion of the obturator externus is exposed, by dividing the quadratus femoris into two equal parts by a vertical incision. In order to see the upper or pelvic portion, it is necessary to detach the gracilis, pectineus, psoas, iliacus, and adductor brevis.

This is a triangular, flat muscle (*e*, *fig.* 127), of the same shape, but thinner and smaller than the obturator internus, and, like it, reflected, though at an obtuse angle. It *arises* from the circumference of the obturator foramen, from the obturator ligament, and from the tendinous arch which completes the sub-pubic canal for the vessels and nerve. It is *inserted* into the deepest and lowest part of the digital cavity of the great trochanter. The fleshy fibres arise directly, the lower ones proceed horizontally outward, and the upper obliquely downward, backward, and outward; thus converging, they form a fleshy belly, which turns round the neck of the femur, and terminates in a tendon that passes horizontally outward, to be *inserted* into the digital cavity, below the gemelli and the obturator internus.

Relations.—Its outer and anterior surface is in relation with the pectineus, the adductors, the psoas and iliacus muscles, and more externally with the neck of the femur and the lower part of the capsular ligament of the hip-joint. Its inner and posterior surface is in contact with the obturator foramen and the quadratus muscle.

Action of the preceding Muscles.

The last six muscles are evidently rotators of the thigh outward. The pyriformis, the gemelli, and the obturator internus, which are almost always united at their insertions, would deserve the name of *quadri-gemini*, given by the older anatomists to the gemelli, the pyriformis, and the quadratus. When they take their fixed point upon the femur, as, for example, in standing upon one foot, they become rotators of the pelvis, and turn the anterior surface of the trunk to the opposite side. They are only rotators when the limb is extended; in the sitting posture, they become abductors. Winslow, who first demonstrated their use in abduction in the semiflexed position, attached great importance to the connexion of so many of these muscles with the capsular ligament, which he believed prevented pinching of the capsule during the different movements of the joint.

The insertion of these muscles is exceedingly favourable. Moreover, we shall find, that besides the glutæus maximus and the posterior fibres of the glutæus medius and

* [M. Cruveilhier states the *insertion* of the quadratus femoris to be into the inter-trochanteric line. The description in the text, copied from Albinus, gives a more accurate idea of the insertion of this muscle.]

minimus, they have many other muscles as accessories in rotation. The effects produced by the contraction of the two obturators can be easily understood, if we bear in mind that the action of a reflected muscle is to be calculated from the point of reflection, leaving the rest of the muscle out of consideration. Thus, with regard to the obturator internus, the sciatic notch acts as a pulley, and may be regarded as the fixed point.

MUSCLES OF THE THIGH.

The Biceps Cruris.—Semi-tendinosus.—Semi-membranosus.—Tensor Vaginæ Femoris.—Sartorius.—Triceps Extensor Cruris.—Gracilis.—Adductor Muscles of the Thigh.

The muscles of the thigh are divided into those of the *posterior region*, viz., the biceps, the semi-tendinosus, and the semi-membranosus; those of the *external region*, viz., the tensor vaginæ femoris and the vastus externus; those of the *anterior region*, viz., the sartorius, the rectus, and the triceps extensor cruris of authors; and, lastly, those of the *internal region*, viz., the gracilis, the pectineus, and the three adductors.

Posterior Region.

The Biceps Cruris.

Dissection.—This is the same for the biceps, the semi-tendinosus, and the semi-membranosus. Place the subject upon its face, with a block under the pelvis, and allow the leg to hang over one side of the table. Make an incision from the middle of the space between the tuberosity of the ischium and the great trochanter to the interval between the two condyles of the femur. Both the skin and the fascia of the thigh must be divided in this incision. Cautiously remove the cellular and adipose tissue surrounding the subjacent muscles, the relations of which with the popliteal vessels and nerves must be carefully studied. In preparing the superior attachments of these muscles, the glutæus maximus must be divided in the middle, perpendicularly to its fibres.

The *biceps femoris* (biceps cruris, *Albinus*, *l*, *figs.* 124, 125), so named because it consists of two fleshy bodies or heads above, is a long, large muscle, situated on the posterior and external aspect of the thigh.

Attachments.—It *arises* from the tuberosity of the ischium and the linea aspera of the femur, and is *inserted* into the head of the fibula, and slightly into the external tuberosity of the tibia. Its origin from the ischium (*l*, *fig.* 125) is common to it and the semi-tendinosus; it takes place, not from the tuberosity properly so called, but from the highest and most external part of the tuberosity, above and behind the adductor magnus, and immediately below the gemellus inferior. It arises by a tendon which is seldom completely free from muscular fibres. This tendon, at first very thick, and separated from the tuberosity of the ischium by a synovial bursa, expands into an aponeurosis, which gives origin to the fleshy fibres of the biceps by its external edge and posterior surface, and to those of the semi-tendinosus by its internal surface. Up to this point the biceps and semi-tendinosus are blended together so as to form a single fleshy belly, which, after extending from two to four inches, is divided into two portions: one posterior and external, constituting the *long head*, or *ischiatic portion of the biceps*; the other anterior, forming the origin of the semi-tendinosus, which we shall next describe. Arising thus in succession, the fleshy fibres of the long head of the biceps form a fusiform belly *passing obliquely downward and a little outward*, and terminating on the anterior surface of an aponeurosis, which extends for a considerable distance on the posterior surface of the muscle, and which gradually becomes contracted, so as to form the terminal tendon. Just where these fleshy fibres are about to terminate (*l*, *fig.* 125), the aponeurosis receives upon its anterior surface and external edge the fleshy fibres of the *short head*, or *femoral portion* of the biceps. This portion of the muscle (*l'*, *fig.* 125) arises from the greater part of the interval between the two margins of the linea aspera, and the posterior surface of the external inter-muscular septum of the thigh; it passes downward, inward, and backward, to be attached to the common tendon, almost as far as its insertion. This insertion is not confined to the head of the fibula, but extends also to the external tuberosity of the tibia by means of a strong division of the tendon, which, at the same time, gives off an expansion to the fascia of the leg. The insertion into the fibula is ef-

Fig. 125.

fected on the outer side, in front of and behind the external lateral ligament of the knee-joint, which ligament it embraces in a bifurcation.

Relations.—The biceps is covered by the glutæus maximus and the femoral fascia. It covers the semi-tendinosus, semi-membranosus, and vastus externus. It is in relation, also, with the great sciatic nerve, which is placed at first externally, then in front, and, lastly, on the inside of the muscle; finally, its short head is in relation with the popliteal vessels.

The biceps forms the external border of the popliteal space; near its termination it is in relation with the outer head of the gastrocnemius and with the plantaris longus muscle.

Action.—The biceps flexes the leg upon the thigh. When this movement is completed, its long portion extends the thigh upon the pelvis. From its obliquity downward and outward, it rotates the leg outward during semi-flexion; but this rotation is impossible when the leg is extended, in consequence of the tension of the crucial ligaments. The fixed point of this muscle is as often below as above, and it then performs an important part in the mechanism of standing; for it tends to prevent the individual from falling forward, because it holds back the pelvis. When the pelvis is thrown quite backward, this muscle can then flex the thigh upon the leg.

The Semi-tendinosus.

The *semi-tendinosus* (*m*, *figs.* 124, 125), so named on account of the great length of its tendon, is situated on the posterior and internal aspect of the thigh.

Attachments.—It *arises* from the tuberosity of the ischium, and is *inserted* into the anterior tuberosity of the tibia. Its origin (*m*, *fig.* 125) consists of a tendon common to it and the long head of the biceps, which is prolonged in the form of an aponeurosis, upon the external (or popliteal) border of the muscle. Some of the fleshy fibres are attached directly to the tuberosity of the ischium. Having arisen in this manner, it enlarges and constitutes a fusiform bundle, which passes at first vertically downward, and then obliquely inward. About four or five fingers' breadth above the knee-joint it terminates in a long, thin tendon, which turns round the internal tuberosity of the tibia, describing a curve having its concavity directed forward, and is then reflected horizontally forward, to be inserted into the anterior teberosity of that bone, behind the tendon of the sartorius, and parallel with the lower edge of that of the gracilis, to which it is united. The union of these three tendons constitutes the *patte d'oie* (goose's foot).

The length of its tendon of insertion is the most characteristic feature of the muscle; and hence its name, semi-nervosus (*Spigelius*), and le demi-nerveux (*Winslow*), for which the term semi-tendinous has now been substituted. The structure of this muscle is remarkable. The fleshy fibres are interrupted across the middle by a tendinous intersection, analogous to that of the great complexus, which gives origin to new fleshy fibres.

Relations.—It is covered by the glutæus maximus and the femoral fascia, and it covers the semi-membranosus and part of the upper portion of the adductor magnus. Its tendon is first placed behind the semi-membranosus, and then, before it turns round the internal tuberosity of the tibia, between the tendon of that muscle and the inner head of the gastrocnemius.

Action.—The same as that of the biceps. It is a very powerful flexor, on account of the reflection of its tendon. Its oblique direction enables it to rotate the tibia inward du ring semi-flexion of the leg. It is, therefore, a congener of the popliteus.

The Semi-membranosus.

The semi-membranosus (*n*, *figs.* 124, 125) is situated upon the posterior aspect of the thigh, thin and aponeurotic above, thick and fleshy below.

Attachments.—It *arises* from the upper and outermost part of the tuberosity of the ischium, in front of the biceps and semi-tendinosus; and is *inserted* into the internal tuber osity of the tibia, and also, by an expansion of its tendon, into the femur. It arises by means of a very thick tendon, which becomes wider immediately after its origin. From its inner border is given off an aponeurotic lamina, that splits into two layers, from the interval between which the superior fleshy fibres arise. Lower down, the muscular fibres proceed directly from the tendon itself, which runs along the outer (or popliteal) border of the muscle, as far as the lower fourth of the thigh, but is afterward buried in its substance. The union of all these fibres constitutes a very thick, four-sided, fleshy belly, which is received into a tendinous semi-cone, open on its outer side, and soon becoming converted into a thick tendon, which, after a passage of a few lines, separates into three divisions, terminating in the following manner: the *posterior* division passes inward and upward, forms the chief part of the posterior ligament of the knee-joint, and is inserted into the femur; the *middle* division is attached to the back of the internal tuberosity of the tibia, below the articular surface; the *third* is horizontal, and turns round the internal tuberosity of that bone in the horizontal furrow existing there, and is inserted on the inner side of the tuberosity. A synovial bursa intervenes between it and the bone.

Relations.—The semi-membranosus is covered by the glutæus maximus, the semi-ten-

dinosus, the biceps, and the femoral fascia: it covers the quadratus femoris, the adductor magnus, and the inner head of the gastrocnemius. A synovial membrane separates it from the knee-joint. It also covers the popliteal artery and vein, which soon come into relation with its outer or popliteal border. The sciatic nerve lies parallel with its outer border through the whole of its extent; the gracilis is in contact with its inner border. I shall remark here, that the biceps on the outside, and the semi-membranosus and semi-tendinosus on the inside, constitute the lateral boundaries of a cellular interval which extends along the whole of the back of the thigh, and is continuous with the popliteal space. This large cellular interval communicates above with the cellular tissue of the pelvis at the sciatic notch, and below with the fossa of the ham. It is in this direction that purulent matter so readily escapes from the pelvis. The greater part of this interval is destined for the great sciatic nerve, which, however, is soon accompanied by the popliteal vessels.

Action.—Precisely similar in nature to that of the preceding muscle, but much more powerful. The *momentum* of all these flexor muscles occurs, on the one hand, during semi-flexion of the leg upon the thigh; and, on the other (*i. e.*, when their lower attachments are fixed), during semi-flexion of the thigh upon the pelvis.

External Region.

The Tensor Vaginæ Femoris.

Dissection.—In order to expose this muscle, it is sufficient to make a vertical incision through the thick, tendinous layer given off from the anterior portion of the crest of the ilium, and to dissect back the two flaps of that aponeurosis.

The *tensor vaginæ femoris* (le muscle du fascia lata, *o*, *fig.* 126) is the largest of all the extensor muscles of aponeuroses: it is a short, flat, quadrilateral muscle, contained within the substance of the fascia lata, and occupying the upper third of the external region of the thigh. It *arises* from the anterior part of the outer margin of the crest of the ilium, and from the outer border of the anterior superior spinous process of the ilium, between the sartorius and the glutæus medius, by means of a tendon, which also furnishes some points of attachment to the anterior fibres of the last-named muscle. From these points the fleshy fibres proceed downward and a little backward, and, at about the upper fourth or third of the thigh, terminate in a series of small tendinous bundles, the anterior of which become continuous with the fascia lata, while the posterior cross obliquely over the vertical fibres of the fascia, with which they are very soon blended.

Relations.—It lies between two layers of the fascia lata, the external layer being much thicker than the internal. It is covered by the skin, and it covers the glutæus medius, the rectus, and the vastus externus. Its anterior border is in contact with the outer edge of the sartorius, but is soon separated from it by a triangular space, in which the rectus femoris may be seen.

Action.—It is a tensor, not only of the entire femoral fascia, but particularly of the very dense portion or band of the fascia lata, which, being continuous with it, may be regarded as an aponeurotic tendon to this muscle (muscle aponeurotique de la bande large, *Winslow*), and which is inserted into the outer tubercle of the anterior tuberosity of the tibia, and into the adjacent part of its external tuberosity. When the tensor vaginæ is in action, this band compresses the vastus externus, which has so great a tendency to displacement; by means of this band, also, the muscle acts upon and extends the leg. Lastly, on account of its slight obliquity downward and backward, it may be regarded as a rotator of the thigh inward; it is but little concerned, however, in the production of this movement, which, as I have already said, is chiefly effected by the anterior fibres of the glutæi medius and minimus.

Anterior Region.

The Sartorius.

Dissection.—This is common to all the muscles of the anterior and inner regions of the thigh. Make a horizontal incision along the femoral arch, and another perpendicularly from the middle of that to the anterior tuberosity of the tibia. Dissect the fascia of the thigh with care. As all the muscles of the anterior and inner region are separated from each other by distinct sheaths, their dissection consists simply in opening these sheaths successively, and removing the cellular tissue that fills up the inter-muscular spaces. It is necessary to preserve the vessels, in order to obtain a good view of their relations: avoid opening the vena saphena, as it generally contains a large quantity of blood, the escape of which will impede the dissection. If the vein should be opened, it must be tied above and below the orifice, and then cut across. When the superficial muscles have been studied, they must be divided in the middle, in order to expose the muscles of the deep layers.

The sartorius (*p*, *fig.* 126), so named on account of its uses, crosses diagonally over the anterior, and then the inner part of the thigh, to the top of the leg. It is the longest muscle in the body, both as regards its total length, and more especially in reference to the

Fig. 126.

length of its fibres; whence the name of *longus*, given to it by Riolanus. This is the case even although it be measured by a line stretched directly between its two extremities.

Attachments.—It *arises* from the anterior superior spinous process of the ilium, from the upper half of the notch below that process, and from a tendinous septum between the muscle and the fascia lata. It is *inserted* into the inner margin of the crest of the tibia, situated beneath the ligamentum patellæ. Its origin consists of some tendinous fibres, which are more marked behind and on the outer side than in front and within. The fleshy fibres commence almost immediately, and form a flat, riband-like muscle (fascialis, *Spigelius*), which in reality is prismatic and triangular, as well as the tendinous sheath in which it is enclosed. The muscle increases in breadth as far as the lower third of the thigh, and passes obliquely downward, inward, and a little backward; it becomes internal and vertical at the lower third (*p*, *figs.* 124, 125), and reaches the back part of the inner condyle of the femur, to turn round the knee-joint, tendinous fibres having already commenced on the anterior edge of the muscle. The fleshy fibres terminate precisely where the muscle changes its direction to pass forward. The flat tendon by which they are succeeded is at first narrow, but becomes considerably expanded, to be inserted into the crest of the tibia, in front of the tendons of the semi-tendinosus and gracilis muscles, with which it is united, so as to form what is called the *patte d'oie* (goose's foot). A synovial membrane separates it from the tendons of these muscles. A considerable tendinous expansion is given off from its lower edge, and contributes to form the inner part of the fascia of the leg.

Relations.—The sartorius is the most superficial muscle in the anterior aspect of the thigh; it lies beneath the femoral fascia, and covers the psoas and iliacus, the rectus, the vastus internus, the adductor longus, the gracilis, the adductor magnus, and the internal lateral ligament of the knee-joint. The borders of this muscle deserve particular attention, because incisions for ligature of the femoral artery must be made along them. Its most important relation, indeed, is with the femoral artery and vein; it is the *satellite* muscle of the femoral artery. Thus, in the upper third of the thigh, it forms, with the adductor longus and femoral arch, an isosceles triangle, having its base turned upward, and the femoral artery represents a perpendicular drawn from the apex to the base of the triangle. In the middle third of the thigh, the artery is in relation, first, with the inner border, then with the posterior surface, and, lastly, with the outer border of the muscle. In the lower third, the sartorius occupies a deep groove, formed by the gracilis and vastus internus; from the latter muscle it is separated below by an interval containing adipose tissue, of which circumstance advantage may be taken in the application of issues. It also covers the saphenus nerve (*a deep branch of the anterior crural*), which emerges from beneath its anterior border, opposite the lowermost point of insertion of the adductor magnus. Near the knee-joint, the saphena vein is in relation with the posterior border of the muscle.

The structure of the sartorius is very simple. The fleshy and tendinous fibres are all parallel, and the former correspond exactly with the length of the muscle.

Action.—The sartorius flexes the leg upon the thigh, which it draws inward, so as to cross one leg over the other. When this movement is produced, it flexes the thigh upon the pelvis. If the fixed point of the muscle be at the leg, it then flexes the pelvis upon the thigh, and rotates it, so that the anterior surface of the trunk is directed to the opposite side.

The Rectus Femoris and Triceps Extensor Cruris, or the Triceps Femoralis.

I have included under the name *triceps femoralis* the two muscles, or, rather, the two parts of the same muscle, which are described separately in most anatomical works. The reasons for this arrangement will be understood after the following description of the muscle:

I shall consider the triceps femoralis as composed of three portions, viz., a *middle* or long portion, the *rectus femoris* of authors; an *external* and an *internal* portion, which constitute together the *triceps cruris* of authors; for these I shall retain the names of *vastus internus* and *externus*, including in the former the middle portion or *crureus*, properly so called, of most anatomists.

The *long portion of the triceps femoralis*, or the *rectus femoris* (*r*, *fig.* 126), is situated in the anterior region of the thigh, extending from the anterior inferior spinous process of the ilium to the patella: it is vertical in its direction, thick and broad in the middle, and narrower at its extremities

It *arises* by a very strong tendon (*r*, *fig.* 127), which embraces the anterior inferior spinous process of the ilium, and is proportioned to the power of the muscle. This tendon receives on its outer side another flat tendon, arising from a groove upon the rim of the cotyloid cavity, and following its curvature; this is the *reflected tendon*, which is blended with and strengthens the *straight tendon*. It then expands into a broad aponeurosis, the outer portion of which is very thin and prolonged over the anterior surface of the muscle as far as the middle, while the inner portion is very thick, and penetrates into its substance nearly as far as its insertion. The fleshy fibres arise from the posterior surface and edges, and also from the anterior surface of the inner portion of this aponeurosis; they all pass downward and backward, the internal inward and the external outward, and form a fleshy belly, which increases as it proceeds downward, and then terminates on the anterior surface of a broad, thick, and shining aponeurosis, occupying the lower two thirds of the posterior surface of the muscle, and soon becoming contracted into a flat tendon, which receives upon its inner edge the superficial fibres of the vastus internus, again expands, and is finally blended with the common tendon of the two vasti.

Triceps Femoris of Authors, or *Vastus Internus and Externus*.—This is a voluminous mass of muscular tissue, situated behind the preceding muscle, and extending from the three surfaces of the shaft of the femur to the patella and tibia. It is commonly but erroneously considered to be divided above into three heads, which are described under the names of *vastus internus*, *vastus externus*, and *crureus*. I have searched in vain for the middle portion, but have never been able to find more than two separate parts: one external, very large and superficial, viz., the *vastus externus*; the other internal, anterior, and even external, viz., the *vastus internus*; it is much smaller than the vastus externus, and is partly covered by it and by the rectus.

The *external portion*, or *vastus externus* (*s*, *figs.* 124 to 127). This is the largest portion of the triceps femoralis. It *arises* from a projecting border or horizontal crest, situated at the base of the great trochanter, and from a vertical edge in front of that trochanter, which forms a continuation of its anterior border, and sometimes presents a very prominent tubercle: in the angle formed by these two attachments is situated the tendon of the glutæus medius. It also arises along a line running from the great trochanter to the linea aspera, and from the whole extent of the external lip of the linea aspera itself. All the preceding origins are effected by means of a broad aponeurosis which covers the superior three fourths of the muscle, and from the deep surface of which almost all the fleshy fibres proceed. Lastly, some of these arise from the tendon of the glutæus maximus, and from the tendinous septum intervening between the vastus externus and the short head of the biceps. From these origins the fleshy fibres proceed, some vertically downward, the others somewhat obliquely downward and forward, the lowest being the shortest and the most oblique; they form a large bundle, which partially covers the anterior portion of the vastus internus, but is separated from it by vessels, nerves, and cellular tissue. After a course of variable length, some of the fleshy fibres are attached to the deep, but the greater number to the superficial surface of another equally strong aponeurosis: this becomes thickened and contracted into a flat tendon, which is sometimes divided into thick parallel bands, emerges from the fleshy fibres at the external margin of the rectus, and is *inserted* into the outer half of the upper border of the patella, being blended on the inner side with the rectus and the vastus internus. The lower fleshy fibres which arise from the inter-muscular septum are attached directly to the outer border of the patella.*

The *internal* or *anterior portion*, *vastus internus* (*t* and *u*, *fig.* 127), is much smaller than the external, and surrounds the femur. Its inner portion lies immediately under the fascia, and is the only part which is generally described as the *vastus internus* (*t*, *figs.* 126, 127). Its anterior portion is covered by the rectus, or long portion, and is usually called the *crureus* (cruralis, *Alb.*, *u*, *fig.* 127). Its outer portion is covered by the vastus externus, with which many of its fibres are blended; but they may always be separated by cutting along the outer margin of the middle aponeurosis. Thus defined, the vastus internus *arises* from a rough oblique line, extending from the front of the neck of the femur to the linea aspera, and from the internal lip of the linea aspera itself, in front of the adductor muscles: both of these origins are effected by means of an aponeurosis, which is weaker and smaller than that of the vastus externus, and is blended with that of the adductors, concurring with it in the formation of a canal for the femoral artery. It also arises from almost the whole of the internal, anterior, and external surfaces, and from the two anterior borders of the femur; lastly, the lower fibres arise from the internal inter-muscular septum. From these different origins the fleshy fibres pass in various directions; the external inward, the middle vertically, and the internal, which are the most numerous, downward, forward, and outward; they thus form a fleshy belly, thicker below and within than above and without, and are successively attached to both surfaces, and especially to the posterior surface of a broad aponeurosis, which is covered by the tendon of

* The anterior border of this tendon is free, and perfectly distinct from the tendon of the rectus, which is lined by it; and also from the expanded tendon of the vastus internus.

the vastus externus, but can be easily separated from it. The inner fibres are attached to the anterior surface of the aponeurosis, and terminate very regularly opposite a vertical line, running parallel to the inner margin of the rectus femoris.

The aponeurosis extends over the anterior surface of the middle portion of the muscle, which lies behind the rectus: this fact has, doubtless, given rise to its division into two parts, viz., a middle, or the *crureus*, and an internal, called the *vastus internus*. The superficial layer of the internal fleshy fibres is attached below to the inner margin of the rectus, or long portion of the triceps femoralis: the lowest of these fibres, which arise from the inner and inferior bifurcation of the linea aspera, and from the corresponding inter-muscular septum, are almost horizontal, and accompany the tendon as far as its insertion into the inner border of the patella. Lastly, the terminating aponeurosis is prolonged inward to the internal tuberosity of the tibia, below which it is inserted, being covered by the tendons of the semi-tendinosus, semi-membranosus, and gracilis muscles, on the inner side of the internal lateral ligament of the knee. This very strong aponeurotic insertion represents the fascia lata on this aspect of the limb, and forms an accessory internal lateral ligament.

From the above description, it follows that the triceps femoralis is composed of three muscles and three tendons, super-imposed upon each other, viz., the rectus femoris, the vastus externus, and the vastus internus.

Relations.—The long portion of the triceps, or the rectus femoris, is covered by the fascia lata in its lower three fourths. Its upper part is covered by the sartorius, by the anterior fibres of the glutæus medius, and by the psoas and iliacus. It covers the hip-joint, the anterior circumflex vessels, and the two vasti muscles. The vasti surround the femur as in a muscular sheath, and have relations with all the muscles of the thigh. They are superficial in a great part of their extent: in front, they are in relation with the psoas and iliacus, the rectus femoris, and the sartorius, and they lie immediately under the fascia, in the triangular spaces left between these muscles: behind, they are in relation with the biceps and semi-membranosus; on the inside, with the adductors, with the femoral artery, the sheath of which the vastus internus contributes to form, and with the sartorius; on the outside, with the glutæus maximus, which glides over the upper end of the vastus externus, and is separated from it by a synovial bursa; and, lastly, with the tensor vaginæ femoris, and the fascia lata. It is necessary to allude here to a small fleshy bundle, formed by the deepest and lowest fibres of the vastus internus, which is always distinct from the rest of the muscle, and is inserted into the upper part of the synovial membrane of the knee. This bundle has been regarded by Winslow as an articular muscle, intended to prevent the synovial membrane from being pinched between the surfaces of the joint.

Action.—This muscle extends the leg upon the thigh; its action is facilitated by the existence of the patella, which serves to increase the angle of insertion, and which we have described as a sesamoid bone, developed in the substance of the tendon. We must, therefore, regard the triceps as inserted into the anterior tuberosity of the tibia, or, rather, into the lower part of that tuberosity. It should be observed, that the tendon is inserted into the patella, in front of its base, and not into the base itself, in the same manner as the ligamentum patellæ is attached to the anterior surface of that bone, and not to the rough mark on its posterior surface: this important arrangement increases the angle at which the moving power operates. The triceps femoralis is the most powerful muscle in the body, no other having such large surfaces of origin, and, consequently, so great a number of fibres. By itself it supports, in a state of equilibrium, the entire weight of the body in standing, and may be adduced as a striking example of the predominance of the extensors over the flexors; it is also this muscle which raises the whole trunk in progression and in the act of leaping. We cannot, therefore, be astonished at rupture of the patella, of its ligament, or of the common tendon, during a violent contraction of this muscle, notwithstanding its disadvantageous insertion so near to the fulcrum. The rectus necessarily acts with the two vasti, but it can also flex the thigh upon the pelvis. The somewhat oblique direction of the tendon of the triceps downward and inward, and of the ligamentum patellæ downward and outward, so that they form an obtuse angle, open to the outside (see *fig.* 126), and more especially the predominance of the vastus externus over the vastus internus, sufficiently account for the occurrence of luxation of the patella outward, and for the impossibility of its being dislocated inward.

When the patella is forced inward by external violence, the contraction of the vastus externus draws it back into its original position: on the other hand, the action of this muscle has a tendency to displace it outward; and when this is accomplished, the same muscle keeps it in its abnormal position. Luxations of the patella, therefore, if not altogether irreducible, can only be temporarily replaced; whenever the hand ceases to retain the bone in its proper place, the contraction of this muscle again dislocates it. Professor Ant. Dubois has informed me of an individual whose knees were bent very much inward, who could not contract the triceps femoralis with any force without dislocating the patella outward.

INTERNAL REGION OF THE THIGH.

The muscles of the internal region of the thigh are the gracilis and the adductors, among which I include the pectineus.

The Gracilis.

The *gracilis* (le grêle interne, ou droit interne, *Winslow*, *v*, *figs.* 124, 125, 126) is a long, straight, and slender muscle, and the most superficial of those situated on the inside of the thigh.

Attachments.—It *arises* from the symphysis pubis, between the pubic spine and the ascending ramus of the ischium, and is *inserted* into the spine of the tibia. It arises by some long, shining, and parallel tendinous fibres, which bind down a perpendicular fibrous bundle that lies on the inner side of the line of attachment. The fleshy fibres succeeding to these are at first parallel, and form a broad, thin bundle; they then converge towards each other, so that the entire muscle resembles a much elongated isosceles triangle. It is rounded below, and terminates in a long, thin tendon, which runs for a considerable distance upon its posterior border, and receives all the fleshy fibres in succession. This tendon becomes free immediately above the knee-joint, is then situated behind the internal condyle of the femur, turns round this process and the corresponding tuberosity of the tibia, and is inserted into the spine of the last-mentioned bone, behind the tendon of the sartorius, and above that of the semi-tendinosus, with both of which it is united so as to form the trifid aponeurotic interlacement, denominated *la patte d'oie* (goose's foot).

Relations.—The gracilis is covered by the femoral fascia, and slightly by the sartorius at its lower part: it covers the three adductors, the inside of the knee-joint, and the internal lateral ligament, from which it is separated by a synovial bursa common to it and the semi-tendinosus: the vena saphena interna crosses the inner surface of this muscle obliquely, near its lower extremity.

Action.—It flexes the leg, and carries it slightly inward, at the same time, by means of its reflection round the knee; in this part of its action it assists the sartorius; it also adducts the thigh. In the position of standing, its movable point is at the pelvis.

The Adductor Muscles of the Thigh.

There are three muscles on the inner aspect of the thigh which are called *adductors*; with these the older anatomists were acquainted under the collective name of the *triceps* adductor. Modern writers, however, describe them either in the order of their superimposition, as the *first*, *second*, and *third* (*Boyer*); or in the order of their size, as the middle, small, and great adductors (*Bichat*). These vague denominations are the source of much confusion, for the one which occupies the middle place as regards size is the first as regards its position. I have therefore thought it right to modify these names, and have, at the same time, included the pectineus among the adductor muscles. I consider, therefore, that there are four adductors, which I shall divide into *superficial* and *deep*; the two superficial are the pectineus and the first or long adductor; these I shall term the *first* and *second*.

Superficial Adductors.—The two deep are the short and the great adductors, which I shall denominate the *small deep adductor* and the *great deep adductor*. Strictly speaking, we could only admit the existence of two adductors, one *superficial*, the other *deep*; and this mode of division would perhaps be preferable.

Dissection.—This is common to all the adductors. Abduct the thigh so as to render these muscles tense. Make an incision through the integuments from the middle of the femoral arch to the patella, and a semicircular incision at either end of this; preserve the vessels and nerves, in order to examine their relations; tie and cut across the vena sephena where it enters the femoral vein; divide the fascia lata, and dissect the muscles, which will then be brought into view.

The First Superficial Adductor, or Pectineus.

The pectineus (*pecten*, the pubes) is a square muscle (*w*, *fig.* 126) situated at the upper anterior and inner aspect of the thigh, on the inner side of the psoas and iliacus (*c*).

Attachments.—It *arises* (*w*, *fig.* 127) from the spine and crest of the pubes, from the triangular surface in front of this crest, and from the lower surface of a very strong tendinous and arched prolongation of Gimbernat's ligament, which is attached to the crest of the pubes, and is continuous with the fascia covering the muscle. It is *inserted* (*w*, *fig.* 127) below the lesser trochanter, into the ridge extending from that process to the linea aspera. With the exception of the spine of the pubes, where there are always some well-marked tendinous attachments, the fleshy fibres commence directly from the several origins: they proceed downward, backward, and outward, and constitute a bundle, which is at first flattened from before backward, and afterward from without inward: the fibres of this after a short course converge, and are inserted into the internal bifurcation of the linea aspera, in part directly, and partly through the medium of an aponeurosis which occupies the anterior surface of the muscle.

Fig. 127.

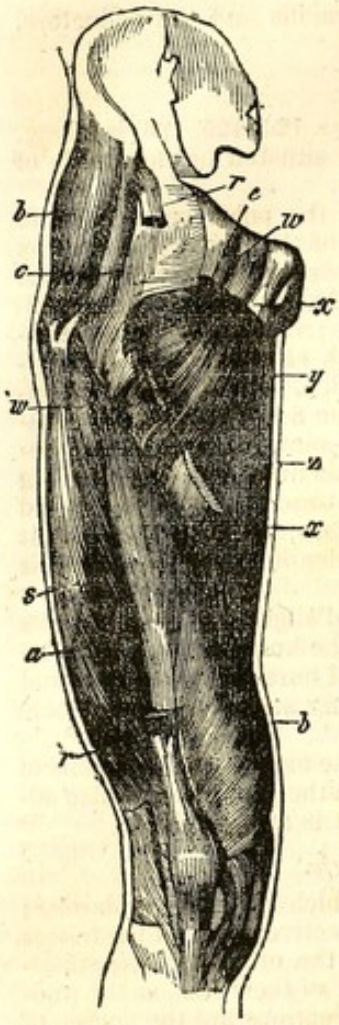

Relations.—The pectineus is covered by the deep layer of the femoral fascia, and by the femoral vessels. It covers the capsular ligament of the joint, the small deep adductor, and the obturator externus, from which it is separated by the obturator vessels and nerves. Its outer border is parallel with the inner border of the conjoined portions of the psoas and iliacus, and is separated from them by a cellular interval, over which the femoral artery passes; so that, were it not for the projection of this outer border, this vessel would be in immediate contact with the bone. Its inner border is in relation with the second superficial adductor, and is sometimes blended with it, except below, where it is separated by an interval in which the small deep adductor may be seen. It has an important relation with the anterior orifice of the sub-pubic canal, which corresponds with the posterior surface of the muscle. When hernial protrusions, therefore, take place at the foramen ovale, the displaced parts are always covered by the pectineus muscle.

The Second Superficial Adductor, or Adductor Longus.

The adductor longus of *Albinus* (le premier adducteur, *Boyer*; le moyen adducteur, *Bichat*, *x*, *fig.* 126) is a flat, triangular muscle, situated on the same plane as the pectineus, of which it seems to be a continuation, and with which it is often blended above. For this reason, Vesalius made of these two muscles his eighth pair of muscles of the thigh, under the name of *pars octava femur moventium*. It is certain that there is a sort of consolidation between these two muscles, and that a small pectineus is always observed in conjunction with a large adductor longus.

Attachments.—It *arises* (*x*, *fig.* 127) from the spine of the pubes, and is *inserted* (*x*) into the middle third of the linea aspera of the femur. Its origin consists of a narrow, flat tendon, which expands anteriorly, and gives origin to a thick and broad fleshy belly; this passes downward, backward, and outward, and is inserted into the middle third of the linea aspera of the femur, between the triceps femoralis in front, and the great deep adductor behind: with the latter of these muscles it becomes blended at its insertions. It is attached to the bone by means of two tendinous layers, between which the fleshy fibres are received. A number of foramina, intended for the perforating arteries, are observed in the neighbourhood of this attachment.

Relations.—Its upper part lies immediately under the fascia, and it becomes gradually deeper as it passes downward. It is in relation with the sartorius, from which it is separated by the femoral artery and veins. This relation is one of great importance, as I shall hereafter have occasion to point out.

The Small Deep Adductor, or Adductor Brevis.

The adductor brevis of *Albinus* (le seconde of *Boyer*; le petit of *Bichat*, *y*, *fig.* 127) is of the same form as the preceding muscle, and is the second in the order of super-imposition, but the smallest in size. It *arises* below the spine of the pubes on the outer side of the gracilis and the inner side of the obturator externus, from a variable extent of surface. The fibres proceed outward, downward, and a little backward, and form a thick bundle, at first flattened from within outward, and then from before backward, which increases in breadth, and terminates at the middle of the linea aspera of the femur, in front of the great deep adductor, and behind the two superficial adductors, with which it is blended at its insertion.

Relations.—It is covered by the superficial adductors, and it covers the great deep adductor, or adductor magnus. Its outer border has a relation with the obturator externus, and the conjoined psoas and iliacus muscles; its inner border is at first in contact with the gracilis, and is then applied to the adductor magnus, from which it is sometimes difficult to separate it.

The Great Deep Adductor, or Adductor Magnus.

Dissection.—In order to obtain a good view of this muscle, it is not sufficient to study its anterior surface only, which is exposed after the preceding muscles have been divided; its posterior surface must also be examined; and for this purpose it is necessary to remove the three muscles of the posterior region of the thigh, viz., the biceps, the semi-tendinosus, and the semi-membranosus.

The adductor magnus of *Albinus* (le troisième of *Boyer*; le grand of *Bichat*, *z*, *z'*, *figs.* 124 to 127) is a very large, triangular muscle, extremely thick internally, where it constitutes almost the entire substance of the inside of the thigh (*fig.* 127). It *arises* from the whole extent of the ascending ramus of the ischium, from a small part of the descending ramus of the pubes, and from the apex, *i. e.*, the lowest portion, of the tuberosity of the ischium. It is *inserted* into the whole extent of the interval between the two lips of the linea aspera, and into a very prominent tubercle upon the inner condyle of the femur, above the depression for the insertion of the tendon of the inner head of the gastrocnemius. Its origins, especially those from the ischium, which are the principal, can only be seen on the posterior surface of the muscle (see *fig.* 125). They consist of tendinous bundles, giving origin immediately to fleshy fibres, which form an extremely thick mass, directed downward and outward, and presenting coarse bundles, almost as large and as easily separable as those of the glutæus maximus. The muscle soon divides into two portions, or, rather, into two distinct muscles, an internal and an external.

The internal portion (*z*, *figs.* 125, 127) forms the inner border of the adductor magnus, the original course of which it follows. About the lower third of the thigh, its fibres are received into a tendinous semi-cone, open on the outside, and terminating in a shining tendon, which is inserted into a well-marked tubercle on the upper and back part of the internal condyle of the femur. Throughout its whole course, this tendon lies close to the aponeurosis of the vastus internus.

The external portion (*z'*, *fig.* 125), abandoning the primitive direction of the muscle, is directed outward, and separates into thick bundles, which are inserted into the whole extent of the interval between the lips of the linea aspera by means of a very large aponeurosis, which is intimately united to the tendons of the other adductors, and forms a series of arches (see *fig.* 125) for the passage of the perforating arteries.

These two divisions of the adductor magnus are separated below by the femoral artery and veins and their sheath, and are generally distinct for a considerable extent, and sometimes entirely so. I have met with a case of this kind. That portion of the muscle which was inserted into the internal condyle arose entirely from the apex of the tuberosity of the ischium; while the origin of that portion which was attached to the linea aspera took place from a prominence situated on the external side of that tuberosity, and projecting outward from it, and also from the ascending ramus of the ischium, and the descending ramus of the pubes, externally to the gracilis muscle. The superior fibres (*fig.* 125) are horizontal, and, forming a distinct, and, as it were, a radiated bundle, turn in front of the succeeding fibres, and are inserted into the line leading from the great trochanter to the linea aspera, internally to the glutæus maximus.

Relations.—The adductor magnus is covered by the superficial adductors and by the small deep adductor: it covers the semi-tendinosus, the biceps, the semi-membranosus, and the glutæus maximus. Its inner border is bounded by the gracilis above, and by the sartorius below: its upper border is in contact with the obturator externus (*e*, *fig.* 127) on the inside, and with the quadratus femoris (*i*, *fig.* 125) more externally. Its most important relation is that with the femoral artery and vein, which pass through it before reaching the popliteal space. At the place where this perforation occurs we observe a tendinous arch, or, rather, canal, into which the fleshy fibres are inserted; and so, also, where the perforating arteries pass through this muscle.

Action of the Adductor Muscles.—The muscles we have just described are both flexors and rotators outward; but their principal office, as their name indicates, is to perform adduction, a very energetic movement, as might be anticipated from the strength of the muscles concerned in its production. We have seen, indeed, that the line of origin extends from the ilio-pectineal eminence as far as and including the tuberosity of the ischium, and that the insertions occupy the entire length of the linea aspera, the two branches of its superior bifurcation, and the inner condyle of the femur. These muscles are powerfully exerted during equestrian exercise; it is by their means that the horse is firmly grasped between the knees. The two superficial adductors and the adductor brevis are also flexors, because their insertions are posterior to their origins. All the adductors are, as it were, rolled around the femur during rotation inward.

MUSCLES OF THE LEG.

The Tibialis Anticus.—Extensor Communis Digitorum.—Extensor Proprius Pollicis.—Peroneus Longus and Brevis.—Gastrocnemius, Plantarus, and Soleus.—Popliteus.—Tibialis Posticus.—Flexor Longus Pollicis.

The muscles of the leg may be divided into those of the anterior, those of the external, and those of the posterior regions.

Muscles of the Anterior Region of the Leg.

The muscles of the anterior region of the leg are the tibialis, the extensor communis digitorum, and the extensor proprius pollicis pedis. The anterior peroneus, or peroneus

tertius, when it exists, is nothing more than an accessory fasciculus of the extensor communis.

The Tibialis Anticus.

Dissection.—Make a vertical incision through the skin from the anterior tuberosity of the tibia to the middle of the inner border of the foot; dissect back the two flaps of skin, and expose the fascia of the leg; divide this fascia vertically, commencing from the middle of the leg, and terminating at the lower end of the tibia, taking care to preserve the annular ligament; prolong the dissection and separation of the fascia as far upward as possible; lastly, remove the fascia on the dorsum of the foot, which covers inferiorly the tendon of the tibialis anticus.

Fig. 128

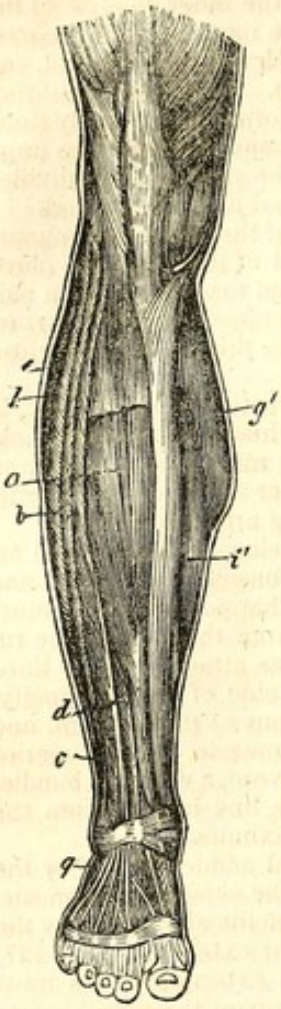

The tibialis anticus (*a*, *fig.* 128) is a long, thick, prismatic, and triangular muscle, placed superficially along the outer side of the tibia.

Attachments.—It *arises* from the crest which bounds the anterior tuberosity of the tibia on the outside, and from the tubercle terminating this crest above; from the external tuberosity of the tibia, and the superior two thirds of its external surface, which presents a depression proportioned to the strength of the muscle; from all that portion of the interosseous ligament situated to the inner side of the anterior tibial vessels and nerves; from the deep surface of the fascia of the leg; and, lastly, from a tendinous septum intervening between this muscle and the extensor communis digitorum. It is *inserted* into the tubercle on the first or internal cuneiform bone, and sends off a tendinous expansion to the first metatarsal bone.

It *arises* from the internal surface of an osteo-fibrous quadrangular pyramid formed by the tibia, the fascia of the leg, the interosseous ligament, and the inter-muscular septum; from these points the fleshy fibres proceed vertically downward, and terminate around a tendon which commences in the substance of the muscle above its middle third; the anterior fibres cease at the lower third of the muscle, the posterior accompany the tendon to the point where it passes under the dorsal ligament of the instep (seen in *fig.* 128). As soon as the tendon appears on the anterior border of the muscle, it is deflected forward in a similar manner to the external surface of the tibia, and follows the same oblique course, after having left the common sheath of all the muscles of the anterior region of the leg. Another sheath, which is nothing more than the condensed dorsal fascia of the foot, receives the tendon at the point where it passes vertically downward, to be inserted into the tubercle of the first cuneiform bone.

Relations.—The tibialis anticus is covered by the fascia of the leg and the dorsal fascia of the foot; on the inside it is in relation with the external surface of the tibia; on the outside, at first with the extensor communis digitorum, and then with the extensor proprius pollicis, from which it is separated behind by the anterior tibial vessels and nerves.

Action.—It flexes the foot upon the leg; and, from the obliquity of its tendon, it raises the internal border of the foot, and, consequently, produces that sort of rotation inward at the articulation of the two rows of the tarsus which we have already alluded to. It tends, also, to adduct the ankle-joint, and is, consequently, opposed to dislocation outward. The absence of a proper sheath for this muscle explains the considerable projection formed by its tendon during contraction, which may serve as a guide to the preliminary incisions in ligature of the dorsal artery of the foot. Spigelius called this muscle the *musculus catenæ*, because fetters applied around the ankles of criminals press chiefly upon the projection formed by its tendon.

The Extensor Longus Digitorum Pedis, and the Peroneus Tertius vel Anticus.

Dissection.—Remove the fascia of the leg and the dorsal fascia of the foot.

This is an elongated, semi-penniform, and reflected muscle (*b c*, *fig.* 128), flattened from within outward, single above, and divided into four or five tendons below.

Attachments.—It *arises* from the external tuberosity of the tibia, on the outer side of the tibialis anticus; from the whole of the internal surface of the fibula in front of the interosseous ligament, and slightly from that ligament; from the upper part of the fascia of the leg, and from the tendinous septa interposed between this muscle and the tibialis anticus within, and the peroneus longus and brevis without. It is *inserted* into the second and third phalanges of the last four toes.

From these numerous origins the fleshy fibres proceed in different directions; the su-

perior vertically downward, the rest obliquely downward and forward, the lowest being the most oblique; they all terminate around a tendon, which appears upon the anterior border of the muscle below the upper third of the leg. This tendon soon divides into two portions: one internal, and itself subdivided into three tendons for the second, third, and fourth toes; the other external, and generally split into two tendons, one of which is intended for the fifth toe, while the other is fixed to the posterior extremity of the corresponding metatarsal bone. This last subdivision is often wanting: it is but imperfectly separated from the fasciculus belonging to the fifth toe, to which it almost always sends off an accessory tendon: it has been generally described as a separate muscle, under the name of the peroneus tertius or anticus (*c*, *fig.* 128). I have thought it right, however, to connect this muscle with the extensor longus digitorum (*b*), from which it can be so imperfectly separated that it has been designated by *Cowper*, pars extensoris digitorum pedis longi; and by *Morgagni*, quintus tendo extensoris longi digitorum pedis.

The extensor communis is directed vertically as far as the ankle-joint, where it enters a sheath common to it and the flexor proprius pollicis, is next reflected under this sheath, becomes horizontal, passes obliquely inward and opposite the tarsus, is received into a much stronger proper sheath, after leaving which the five tendons separate so as to cover the dorsal surface of the metatarsal bone of the toes, to which they correspond. In this course they cross the extensor brevis digitorum at a very acute angle, reach the dorsal surface of the metatarsal phalangal articulations, apply themselves to the inner edges of the corresponding tendons of the extensor brevis, receive some expansions from the interossei and lumbricales, and are arranged in precisely the same manner as the extensor tendons of the fingers, forming a fibrous sheath on the dorsal surface of the first phalanx of the toes; and like these, having arrived at the articulations of the first with the second phalanges, each divides into three portions: one median, attached to the posterior extremity of the second phalanx; and two lateral, which unite upon the dorsal surface of the second phalanx, to be inserted into the posterior extremity of the third.

Relations.—Internally this muscle is in relation with the tibialis anticus, from which it is soon separated by the extensor proprius pollicis, and externally with the peroneus longus and brevis. It is covered by the fasciæ of the leg and foot, and it covers the fibula, the interosseous ligament, the ankle-joint, the extensor brevis digitorum, which separates it from the tarsus and metatarsus; lastly, it covers the toes.

Action.—As in all reflected muscles, we must suppose the power to be exerted immediately after its reflection, and in the direction of the reflected portion: in this way, it will be seen that it extends the third phalanges upon the second, and the second upon the first; and having produced this effect, it flexes the foot upon the leg. From its obliquity, it also draws the toes outward, and turns the sole of the foot inward.

The Extensor Proprius Pollicis.

The extensor proprius pollicis (*d*, *fig.* 128) is an elongated, thin, flat muscle, placed in front of the leg, between the extensor longus digitorum and the tibialis anticus.

Attachments.—It *arises* from the internal surface of the fibula, and slightly from the adjacent part of the interosseous ligament, within and behind the extensor communis. This origin is situated at variable heights, but commonly not above the middle third of the leg. It is *inserted* into the posterior extremity of the second phalanx of the great toe. The fleshy fibres arise directly from the fibula and the interosseous ligament, and proceed at first vertically around, and then obliquely behind a tendon, which occupies the anterior border of the muscle, and to which the fleshy fibres are all attached in a sloping manner, like the barbs of a feather, as far down as below the proper sheath formed for it at the tarsus. From thence the tendon is reflected at a right angle, proceeds obliquely and horizontally forward and inward upon the dorsum of the foot, passes along the dorsal surface of the first metatarsal bone and first phalanx of the great toe, to the latter of which it gives off a prolongation on each side, and is then inserted into the second phalanx.

Relations.—Internally, it is in relation with the tibialis anticus, from which it is separated behind by the anterior tibial nerve and vessels; and externally, with the extensor longus digitorum. Its anterior border, at first concealed between the preceding muscles, is soon situated immediately beneath the fascia, and during its contraction forms a projection, which it is important to know, because it serves as a guide in searching for the dorsal artery of the foot, which will always be found on the outer margin of the tendon: it may be called the *muscle of the arteria dorsalis pedis*. In the foot it crosses superficially to the extensor brevis digitorum.

Action.—It extends the second phalanx of the great toe upon the first, and that upon the metatarsus; when this is accomplished, it flexes the foot upon the leg. In consequence of its obliquity, it tends, like the preceding muscle, to turn the toes outward, and slightly to elevate the inner border of the foot.

External Region of the Leg.

In this region are found the peroneus longus and peroneus brevis muscles.

The Peroneus Longus.

Dissection.—This is common to both muscles. Remove the skin on the outer side of the leg; make a vertical incision through the fascia; reflect the two flaps, in order to arrive at the tendinous septa dividing the peronei from the muscles of both the anterior and posterior regions of the leg. To expose these muscles in the foot, remove the outer portion of its dorsal fascia, and divide obliquely inward and forward all the muscles of the plantar region, from the groove of the cuboid to the posterior extremity of the first metatarsal bone.

The peroneus longus (*e, figs.* 128 to 130) is a long, thick muscle, prismatic and triangular at its upper part, and superficially situated on the outer side of the leg (peroneus primus, *Spigelius*).

Attachments.—It *arises* externally from the outer and anterior part of the head of the fibula; from a small portion of the contiguous part of the external tuberosity of the tibia; from the upper third of the external surface of the fibula; and from the anterior and posterior borders of that bone, by means of very strong tendinous septa, interposed between it and the anterior and posterior muscles of the leg; lastly, from the fascia of the leg superiorly. It is *inserted* into the posterior extremity of the first metatarsal bone, on the outer side of which a process exists for this purpose.

From these very numerous origins, the fleshy fibres proceed vertically and form a bundle (*e, fig.* 130), thick above, thin and flat below, and terminating in a tendon which is at first concealed in the substance of the muscle, but appears in the form of a band on its outer side, a little above the middle of the fibula, and becomes narrower and thicker as it proceeds. The tendon soon leaves the fleshy fibres, and accompanies the external surface of the fibula as it turns backward (peroneus posticus, *Riol*), then passes behind the external malleolus in a groove common to it and to the peroneus brevis, and is reflected forward and downward to the outer side of the os calcis, upon which it is held by a separate sheath. Having reached the outer side of the cuboid bone, it is again reflected, enters a groove running obliquely inward and forward upon the lower surface of that bone (*e, figs.* 132, 133), where it is retained by a very strong and compact sheath, and continues its oblique course, without any deviation, along the lower surface of the tarsal bones; as far as the posterior extremity of the first metatarsal bone. In this way the tendon of the peroneus longus undergoes a double reflection: first, behind the external malleolus, in which situation a thickening or knot is often seen; and, secondly, at the cuboid bone, opposite which a sesamoid bone almost always exists. There are also three fibrous sheaths, and three synovial membranes belonging to this tendon, one behind the external malleolus, one upon the outside of the os calcis, and a third under the cuboid bone.

Relations.—In the leg, the peroneus longus is covered by the skin and the fascia of the leg: it covers the peroneus brevis. In front, a tendinous septum intervenes between it and the extensor longus digitorum: behind, another inter-muscular septum exists between it and the soleus above, and the flexor proprius below. On the outside of the foot, its tendon corresponds to the skin externally, and to the os calcis internally. In the plantar region, it is covered below by the entire thickness of the soft parts, and corresponds above to the inferior tarsal ligaments.

Action.—As we have already so frequently observed, a reflected muscle acts as if the power were applied at the point of reflection. In this way, by transferring the power to the outer end of the groove on the cuboid bone, we shall find that the foot is abducted, or, rather, rotated outward by this muscle; by next supposing the power to act from the other point of reflection, *i. e.*, from behind the external malleolus, we may observe that the foot is extended upon the leg, and its outer border turned upward. In this movement, the lower end of the external articular surface of the astragalus tends to carry the external malleolus outward, and to increase the curvature of the fibula, which is sometimes fractured in consequence. It may be easily conceived that if the fibula be fractured, the contraction of this muscle will no longer be counteracted, and accordingly will turn the sole of the foot outward, and may luxate the astragalus inward. This is the mechanism of luxation of the foot occurring after fracture of the fibula, the only species of lateral dislocation of this part which has ever been observed.*

The Peroneus Brevis.

The peroneus brevis of *Albinus* (peroneus secundus, *Spigel*; le petit péronier, *Winslow, f, figs.* 129, 130) is a flat, penniform, and reflected muscle, smaller and shorter than the preceding, beneath which it lies.

Attachments.—It *arises* from the lower half, sometimes from the lower two thirds of the external surface of the fibula, which is more or less excavated for this purpose; from the anterior and posterior borders of the same bone, and from the tendinous septa existing between this muscle and those of the anterior and posterior regions of the leg.

It is *inserted* into the posterior extremity of the fifth metatarsal bone, and sometimes

* See the admirable memoir by M. Dupuytren, on fracture of the fibula.

even, by a tendinous expansion, into the fourth metatarsal bone; it often gives off a prolongation to the extensor tendon of the little toe.

The fleshy fibres proceed successively from their different origins to the internal surface and edges of a tendon, situated upon the outer surface of the muscle; the bundle which they form gradually increases in size, and then diminishes, is at first penniform, and afterward semi-penniform, and accompanies the tendon as far as the fibrous sheath behind the external malleolus: after leaving the sheath, the tendon enters another, proper to itself, upon the outer side of the os calcis, above that for the tendon of the peroneus longus, and passes somewhat obliquely downward and forward, to be inserted into the base of the fifth metatarsal bone.

Relations.—It is covered by the peroneus longus, and covers the fibula and the outer side of the os calcis. It is, therefore, only in comparison with the peroneus longus that Riolanus and others have called this muscle the *anterior* peroneus.

Action.—The same as that of the peroneus longus, with the exception of that of its subtarsal portion. Thus, supposing the power to be applied at the external malleolus, we have extension of the fifth metatarsal bone upon the cuboid; extension and rotation inward of the second row of the tarsus upon the first; rotation of the calcaneum upon the astragalus; extension, and a tendency to abduction of the entire foot, which is therefore considerably everted when the fibula is fractured.

Posterior Region.

There are two layers in this region: one superficial, formed by the gastrocnemius and soleus (or triceps suralis) and the plantaris; the other deep, consisting of the popliteus, the tibialis posticus, the flexor longus digitorum, and the flexor longus pollicis.

The Gastrocnemius and Soleus, or Triceps Suralis, and the Plantaris.

Dissection.—Make a vertical incision from the upper part of the popliteal space to the heel; at right angles to this, above, make another horizontal and semicircular incision, embracing the back part of the thigh; divide and dissect the fascia of the leg. The gastrocnemii will then be exposed, and must be dissected very carefully at their origins. In order to study the structure and attachments of these muscles properly, they must be cut transversely in the middle, and the superior half turned upward. In dividing the outer head of the gastrocnemius, be careful not to cut the plantaris, which seems to be merely a small fasciculus detached from that muscle. The soleus is exposed by simply removing the gastrocnemius; but, in order to study its structure and attachments, it must be divided vertically from behind forward at the side of a median tendinous raphé, and the fibres which conceal this median aponeurotic lamina of the muscle must be scraped away. From this division we have a fibular and a tibial portion of the soleus.

Fig. 129.

The gastrocnemius (*g g*) and the soleus (*i i'*, *fig.* 129) together constitute a very powerful triceps muscle (musculus suræ, *Sœm.*), which, by itself, forms the fleshy part of the leg, commonly called the calf. The great development of these muscles is one of the most marked characteristics of the muscular apparatus of the human subject, and is connected with his destination for the erect position. The three portions of the *triceps suralis* are united together below in a common tendinous insertion, constituting the *tendo Achillis* (*t*, *fig.* 129), but are divided above into two very distinct planes: one, anterior or deep, formed by the soleus; the other, posterior or superficial, consisting of the two heads of the gastrocnemius. We shall describe these in succession.

Gastrocnemius.

The *gastrocnemius*, from γαστὴρ, a belly, and κνῆμη, the leg (gemellus, *Albinus*; primus pedem moventium, cum secundo, *Vesalius*), is the most superficial muscle on the back of the leg: it consists of two heads above (*g g'*, *fig.* 129), but forms a single fleshy belly, which is thick and flattened from before backward.

It *arises* from the condyle of the femur by two perfectly distinct but similar heads, viz., an outer or smaller, called the gemellus externus (*g*), and an inner or larger, named the gemellus internus (*g'*). They take their origin from the bone, by two very strong and flat tendons, which are attached on the outer side, and behind the condyle of the femur, to two well-marked digital impressions, that for the outer head being situated above a much deeper impression for the popliteus muscle, and that for the inner head immediately behind the tubercle into which the adductor magnus is inserted, so that the inner head is situated upon a plane a little posterior to that of the outer head. They also arise, by tendinous fasciculi, from

the rough triangular surfaces surrounding the digital impression, and terminating at the inferior bifurcation of the linea aspera. Each tendon of origin (that for the inner being much larger than that for the outer head) expands into an aponeurosis upon the posterior surface of that portion of the muscle to which it belongs. The aponeurotic expansion of the inner head is, moreover, thicker and longer than the other, and embraces the inner border of that part of the muscle, like a tendinous semi-cone. The fleshy fibres arise from the anterior surface of these tendinous expansions, and are disposed in the following manner: those in the middle, which are few in number, are strengthened by fleshy fibres proceeding from the rough projections of the bifurcation of the linea aspera, pass inward and downward, and are united together like the limbs of the letter V opening upward, upon a median raphé, which consists either of a simple thickening of the terminating aponeurosis, or of a small tendinous septum: the other fibres, constituting almost the entire muscle, arise from the anterior surface of the tendons of origin, and from the aponeurosis in which they terminate, and proceed vertically downward to the back of another very dense aponeurotic expansion, which covers the whole anterior surface of the muscle. This last aponeurosis commences above by two very distinct portions; at first it is of equal breadth with the muscle, then becomes narrower and thickened, and, finally, closely united with the terminal tendon of the soleus. At the lower part of the calf the fleshy fibres terminate suddenly upon the posterior surface of this aponeurosis, forming a V opening downward. Although the two portions of the gastrocnemius become intimately united shortly after their origin, they are not confounded together, and the internal portion forms on the inside of the tibia the greatest part of the fleshy mass called the calf of the leg.

Relations.—The gastrocnemius is covered by the fascia of the leg, and it covers and adheres intimately to the capsular ligament, which envelops the back part of the condyles of the femur. It is also in relation with the popliteus and the soleus.

The tendon of the inner head corresponds to the posterior surface of the internal condyle; that of the outer head to the outer side of the external condyle. We often find at the upper part of the tendon of each head, but most commonly in the substance of that of the outer head, a sesamoid bone, that glides upon the back of the condyle, and belongs to the sort of fibrous capsule or hood by which the back of each condyle is covered. (Vide SYNDESMOLOGY, Articulation of the Knee.)

The Plantaris.

This little muscle (le plantaire grêle, *l l'*, *fig.* 129) should be regarded as an accessory of the outer head of the gastrocnemius, or, rather, as a rudimentary muscle in the human subject. Its small fusiform, fleshy belly, varying much in size, is found beneath the outer head of the gastrocnemius.

It *arises* (*l*) from the fibrous capsule covering the external condyle, and sometimes from the lower part of the external bifurcation of the linea aspera. From these points, it passes obliquely downward and inward, and after a course of from two inches and a half to three inches, ends in a long, flat, and slender tendon, which is at first situated between the gastrocnemius and soleus, and afterward (*l'*) lies parallel with the inner edge of the tendo Achillis, and is *inserted* into the os calcis, either at the side, or in front of that tendon. Sometimes, however, it is lost in the sub-cutaneous adipose tissue. This muscle, which is often wanting, is occasionally double.*

The Soleus.

The *soleus* (partly seen at *i i'*, *fig.* 129) is so called because it has been compared to the fish called a sole, or to the sole of a shoe.

Attachments.—It *arises* from the fibula and tibia, and is *inserted* into the os calcis. Its *fibular origins* (*i*) consist, first, of a tendon attached behind, and on the inner side of the head of that bone; this tendon is extremely strong, especially on the inside, opposite a process existing on the fibula for its attachment; it is prolonged within the substance, and along the anterior surface of the muscle: and, secondly, of some tendinous fibres attached to the upper half of the external border of the fibula, and the upper third of the posterior surface of the same bone.

The *tibial origins* (*i'*) take place from the oblique line on the posterior surface of the tibia below the popliteus, and from the contiguous portion of the aponeurotic expansion of that muscle; from an aponeurosis which arises from the middle third of the inner border of the tibia, and is prolonged upon the anterior surface, within the substance of the muscle; and, lastly, by a few fleshy fibres from a tendinous arch extending between the head of the fibula and the oblique line on the posterior surface of the tibia. From these different origins, the fleshy fibres pass in different directions to the anterior surface and edge of an aponeurosis, which covers the posterior surface of the muscle, becomes narrower and thickened as it proceeds downward, unites with the terminal tendon of the gastrocnemius about the middle third of the leg, and is soon blended with it to form the tendo Achillis.

* Fourcroy, in his sixth memoir upon the bursæ mucosæ, states that the plantaris, whose tendon, according to Albinus, is received into a groove along the inner border of the tendo Achillis, is the tensor muscle of the synovial capsule of that tendon. This is an error.

In order to study accurately the structure of the soleus, divide it longitudinally at the side of the raphé or tendinous septum existing in the middle of the lower half of this muscle, and then, by scraping off some of the fleshy fibres, it will be seen that a dense, fibrous septum given off by the terminal aponeurosis, separates the muscle into two equal halves, and forms with that aponeurosis two tendinous semi-cones, in the interior of which the fleshy fibres are received. It will now be understood why Douglas, who had designated the gastrocnemius the two external and superficial heads of the *great extensor* of the tarsus, should call the soleus the two internal and deep heads of the same muscle. There are, in fact, two principal aponeuroses of origin, and two hollow tendons of insertion; each aponeurosis of origin covers almost the entire anterior surface of the corresponding half of the muscle.

Relations.—It is covered by the gastrocnemius, which projects beyond it on both sides, but especially on the inner side, and from which it is separated by the plantaris. It is thickest immediately below the largest part or belly of the inner portion of the gastrocnemius, and, consequently, it prolongs the swelling of the calf downward. It covers the muscles of the deep layer, viz., the flexor communis digitorum, the flexor proprius pollicis, and the tibialis posticus; it also covers the posterior tibial and the fibular vessels and nerves.

The Tendo Achillis.—The tendo Achillis (*l*, *figs.* 129, 130) results from the union of the tendons of the gastrocnemius, plantaris, and soleus. It is formed in the following manner: the terminal aponeurosis of the gastrocnemius, shortly after leaving the fleshy fibres, is intimately united to that of the soleus, which still continues to receive fleshy fibres upon its anterior surface and its edges, and gradually becoming narrower, is soon joined by the antero-posterior septum of this muscle. All these tendinous fibres are collected together to form the strongest and largest tendon in the body, known by the name of the *tendo Achillis*, which, after a course of about an inch and a half or two inches, glides over the smooth surface presented by the superior two thirds of the back of the os calcis, with the intervention of a synovial bursa, and is expanded a little, in order to be inserted into the rough surface on the lower part of the same bone.

Action of the Gastrocnemius and Soleus.—These muscles extend the foot upon the leg. In no other part of the body do we find so advantageous an arrangement for an immense development of power. 1. These muscles are very large, and particularly remarkable for the number of their fleshy fibres, in which respect they exceed all other muscles in the body. 2. The mode of insertion is nowhere else so favourable, for it is absolutely perpendicular. 3. We have here a lever of the second order, in which the fulcrum is at the ball of the toes, the resistance in the middle of the foot, being represented by the weight of the body resting upon the ankle-joint, and the power at the extremity of the heel (see *fig.* 104). The length of that portion of the lever which projects behind the joint varies much in different individuals; it scarcely exists in the peculiar malformation denominated *flat-foot*. These muscles are the principal agents in walking and leaping; they raise the weight of the whole body, even when loaded with heavy burdens. Hence it is not surprising, that occasionally an energetic contraction of these muscles may rupture the tendo Achillis, or fracture the os calcis. Frequent exercise appears to be necessary for these muscles; for when they remain inactive, they become atrophied, and are speedily affected with fatty degeneration. The action of the soleus, which reaches only from the leg to the heel, is limited to extension of the foot; but the gastrocnemius, which is attached to the femur, after having extended the foot, can flex the leg upon the thigh; but, from its proximity to the fulcrum, this last action is very slight. When the foot is fixed, as, for example, in standing, the soleus acts upon the leg, and tends to prevent one from falling forward, to which there is a constant tendency from the weight of the body; the action of the gastrocnemius, on the contrary, is to flex the thigh, and in this respect it is altogether independent of the soleus.

The plantaris can only be regarded as rudimentary in man; in the lower animals it is a tensor of the plantar fascia; it has been, as it were, cut short in man, in consequence of his destination for the erect position. Sometimes, as we have already stated, it is lost upon the fatty tissue covering the os calcis.

The Popliteus.

This is a small, triangular, and very thin muscle (*m*, *fig.* 130), situated in the popliteal space.

It *arises* from a deep fossa, resembling a groove running from behind forward, on the back of the external condyle of the femur, below the origin of the outer head of the gastrocnemius. It is *inserted* into the entire extent of the triangular surface, on the upper part of the posterior aspect of the tibia.

It arises by a very strong tendon, which bears no proportion to the diminutive size of the muscle. This tendon, at first concealed by the external lateral ligament, contained, as it were, in the cavity of the joint, and completely enveloped by the synovial membrane, passes obliquely behind the articulation, and, after extending for about one inch,

divides, like the tendon of the obturator internus, into four or five small diverging bundles, which soon surround the fleshy fibres on all sides. The latter then become attached in succession to the triangular surface of the tibia, the lowest being the longest and the most oblique. The superficial fibres are inserted into a tendinous expansion from the semi-membranosus, which covers the posterior surface of the popliteus muscle, and forms a very strong sheath for it.

Fig. 130.

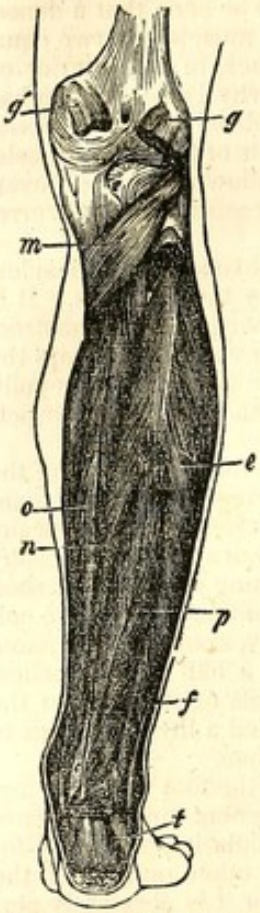

Relations.—It is covered by the gastrocnemius and the plantaris, from which it is separated by the popliteal vessels, and the internal popliteal branch of the sciatic nerve. It covers the tibio-fibular articulations and the back of the tibia.

Action.—It flexes the leg upon the thigh, and, at the same time, rotates it inward (oblique movens tibiam, *Spigelius*). In this last respect it antagonizes the biceps.

The Tibialis Posticus.

Dissection.—Remove the gastrocnemius and soleus; separate the tibialis posticus from the flexor longus digitorum, which partially covers it; carefully remove from the posterior surface of the tibialis posticus a very broad aponeurosis, together with a portion of the long flexor of the toes, which arises from the posterior surface of that aponeurosis; completely separate the tibialis posticus from the interosseous ligament, and the adjacent portions of the tibia and fibula; lastly, be careful to preserve the tendinous expansions always given off by this muscle to the fourth and fifth metatarsal bones.

The *tibialis posticus* (*n*, *fig.* 130) is the most deeply seated of all the muscles on the back of the leg; it is very thick, and occupies the whole depth of the excavation between the tibia, fibula, and interosseous ligament.

Attachments.—It *arises* from the tibia, the fibula, and the interosseous ligament, and is *inserted* into the scaphoid bone. Its tibial and fibular origins form a bifurcation for the passage of the posterior tibial artery. Its tibial attachment takes place on the oblique line situated below the popliteus, soleus, and flexor longus digitorum. Its fibular origin is from the inner border of that bone, below the soleus, and from all that portion of its inner surface which is behind the interosseous ligament. It also arises from the entire posterior surface of this ligament. Lastly, a few fibres take their origin from the deep surface of an aponeurosis which separates the deep from the superficial layer of muscles, and from the tendinous septa interposed between this muscle itself and the flexor longus digitorum on the inside, and the flexor proprius pollicis on the outside. From these numerous origins the fleshy fibres proceed vertically downward, around a tendon which may be distinguished near the upper extremity of the muscle, under the form of a tendinous sheaf, which afterward appears along its posterior border, and receives the fleshy fibres on its anterior surface, like the barbs of a feather upon the shaft. This tendon, however, is nothing more than the thickened posterior edge of an aponeurosis occupying the entire substance of the muscle from before backward, and receiving the fleshy fibres upon its two lateral surfaces as far down as opposite the internal malleolus. The thick tendon resulting from the union of these aponeurotic fibres then becomes free, and enters a proper sheath on the outer side of that belonging to the tendon of the flexor longus digitorum, in front of which it then passes behind the internal malleolus, where it is also enclosed in a separate sheath (*n*, *fig.* 129). On the inner side of the internal lateral ligament of the ankle, and below the lower calcaneo-scaphoid ligament, it enters another sheath, and is finally inserted (*n*, *fig.* 133) into the tubercle of the scaphoid bone, a very thick sesamoid bone existing near its insertion. In some subjects this sesamoid bone is found at the point of insertion; in others it is situated opposite the calcaneo-scaphoid ligament. Besides this, the tendon of the tibialis posticus gives off a very strong expansion to the first cuneiform bone, and on the outside an oblique expansion to the second and third cuneiform bones, and even to the third or fourth metatarsal bones.

Relations.—It is covered by the flexor longus digitorum, slightly by the flexor proprius pollicis, and entirely by the soleus: it covers the interosseous ligament and the adjacent parts of the tibia and fibula.

Action.—The tibialis posticus extends the foot upon the leg. As it is a reflected muscle, all the fibres must be considered as acting from the point of reflection that is behind the inner ankle. It is evident, then, that this muscle extends the foot, both by its action upon the astragalo-scaphoid articulation, and also by that upon the ankle-joint. It also tends to turn the sole of the foot inward; and, consequently, it co-operates with the tibialis anticus in this respect, and antagonizes the peroneus longus and brevis. It may also be understood why some persons, in whom the tendo Achillis has been cut or

ruptured, are yet capable of walking, and why the foot can in all cases be extended after this accident; but under these circumstances the lever formed by the foot is changed, and the power represented by the tibialis posticus is applied between the fulcrum and the resistance; so that we have, then, a lever of the third, not of the second order, as when the tendo Achillis is uninjured.

The Flexor Longus Digitorum Pedis.

This is a penniform, elongated, and reflected muscle (*o*, *figs.* 130, 132), situated along the posterior surface of the tibia and in the sole of the foot; it is the most internal muscle of the deep layer, is flattened from before backward, and terminates below in four tendons.

Attachments.—It *arises* from the tibia, and is *inserted* into the last phalanges of the last four toes. It arises from the oblique line of the tibia, below the popliteus and the soleus, and from the middle three fifths of the posterior surface of the same bone. Some fibres also proceed from the tendinous septum intervening between it and the tibialis posticus. From these different origins the fleshy fibres proceed obliquely backward and downward, to the anterior surface and edges of a tendon which commences near the upper end of the muscle, and gradually disengages itself from the fleshy fibres, being accompanied by them anteriorly as far as the internal malleolus. It passes behind this projection in the same sheath as the tendon of the tibialis posticus, from which it is separated by a fibrous septum; it soon leaves that tendon, passing to its outer or fibular side (*o*, *fig.* 129), and is then reflected at an obtuse angle upon the internal malleolus. It now becomes horizontal, and is buried under the astragalus and the small anterior tubercle of the os calcis, where it is contained in a proper sheath. Having thus reached the sole of the foot (*o*, *figs.* 131, 132), it passes obliquely outward and forward, crosses *under* the tendon of the flexor longus pollicis at a very acute angle, receives from it a strong tendinous communication, and at the same time becoming expanded, is joined by its accessory muscle, and finally divides into four tendons for the last four toes. The tendon for the second toe proceeds directly forward. The tendons for the other toes in succession pass more and more obliquely. Having reached the metatarso-phalangal articulations, these tendons are received, together with those of the flexor brevis digitorum, into the sheaths upon the first and second phalanges; and they have precisely the same relations to the tendons of the last-mentioned muscle as the flexor profundus is observed to have with regard to the flexor sublimis digitorum in the hand; and hence the name of *perforans* given by Spigelius to the long flexor of the toes. The tendons are finally inserted into the posterior extremities of the third phalanges. The tendinous parts of this muscle are lubricated by synovial membranes where they pass through the different sheaths.

Relations.—It is covered by the soleus, the posterior tibial vessels and nerves, and it covers the tibia and the tibialis posticus. In the foot, it is covered below by the flexor brevis digitorum and the adductor pollicis.

Action.—It flexes the third phalanges upon the second, the second upon the first, and the first upon the corresponding metatarsal bones. When these movements have been accomplished, it extends the foot upon the leg. From the obliquity of its reflected portion, it would turn the toes and the sole of the foot slightly inward, if the accessory muscle did not, as it were, rectify its action, as well as co-operate with it. In standing, it opposes flexion of the leg forward.

The Flexor Longus Pollicis.

The *flexor longus pollicis* is the most external and the largest muscle in the deep region of the leg: it is prismatic and quadrangular, vertical and fleshy in the leg (*p*, *figs.* 129, 130), tendinous and horizontal in the foot (*p*, *figs.* 131, 132).

Attachments.—It *arises* from the fibula, and is *inserted* into the last phalanx of the great toe. Some of the fibres arise directly from the inferior two thirds, and from the internal and external borders of the fibula; others arise from the fascia covering the tibialis posticus (its origin from the fibula, and that from the fascia of the tibialis muscle, are separated from each other by the peroneal vessels); from a tendinous septum between it and the peroneus longus and brevis; and from a small portion of the lower part of the interosseous ligament. From these numerous points of origin the fleshy fibres pass obliquely downward and backward, around a tendon which occupies the entire length of the muscle, and may be seen at the lower part of the leg, through a thin layer of muscular fibres. These fibres terminate abruptly behind the ankle-joint, at the oblique groove on the astragalus, in which the tendon is lodged; it then turns into a groove on the os calcis, forming a continuation of the preceding (*fig.* 133), and situated below that for the tendon of the flexor longus digitorum, and dips into the sole of the foot. It is retained in these two grooves, which run obliquely downward, inward, and forward, by a very strong and continuous sheath (*fig.* 132). In the sole of the foot, the tendon is deeply situated (*p*, *fig.* 131), passes forward, and crosses (*p*, *fig.* 132) at an acute angle above the tendon of the flexor longus digitorum, to which it gives off a considerable fibrous

prolongation. It is then received in a groove formed between the flexor brevis digitorum and the oblique adductor of the great toe, passes below the anterior glenoid ligament of the metatarso-phalangal articulation of that toe, between the two sesamoid bones, and is received into the osteo-fibrous sheath of the first phalanx, to be inserted into the posterior extremity of the second.

Relations.—It is covered by the soleus, being separated from it by a fascia, which increases in thickness as it passes downward; it is also covered by the tendo Achillis; it covers the fibula, the tibialis posticus, the peroneal artery, and the lower part of the interosseous ligament. Externally, it is in relation with the peroneus longus and brevis; internally, with the flexor longus digitorum.

Action.—It flexes the second phalanx of the great toe upon the first, and this upon the first metatarsal bone; having produced these movements, it then extends the foot upon the leg. From the obliquity of its fleshy belly, it has a tendency to turn the great toe and the foot outward. In this respect it antagonizes the flexor longus digitorum and the tibialis posticus. The very strong tendinous expansion which unites it to the long flexor of the toes consolidates the two muscles; in fact, it is very uncommon to find either of them acting independently.

MUSCLES OF THE FOOT.

The Extensor Brevis Digitorum.—Abductor Pollicis Pedis.—Flexor Brevis Pollicis Pedis.—Adductor Pollicis Pedis.—Transversus Pollicis Pedis.—Abductor Minimi Digiti.—Flexor Brevis Minimi Digiti.—Flexor Brevis Digitorum.—Flexor Accessorius.—Lumbricales.—Interossei.

The muscles of the foot are divided into those of the dorsal and plantar aspects and the interossei. The muscles of the plantar aspect may be again subdivided into three regions, viz., those of the *middle plantar region*, those of the *internal plantar region*, and those of the *external plantar region*. A single muscle occupies the dorsum of the foot, viz., the extensor brevis digitorum. The muscles of the internal plantar region are four in number, viz., the abductor, the flexor brevis, and the oblique and transverse adductors of the great toe. The last two muscles may be regarded as forming part of the middle plantar region.

The muscles of the external plantar region are the abductor and the flexor brevis of the little toe.

The muscles of the middle region are the flexor brevis digitorum, the flexor accessorius, and the lumbricales.

The interosseous muscles are seven in number, and are divided into the dorsal and plantar.

Dorsal Region.

The Extensor Brevis Digitorum.

Dissection.—Remove the dorsal fascia of the foot, and the tendons of the muscles of the anterior region of the leg.

The *extensor brevis digitorum* (*q*, *fig.* 128) is a thin, flat, quadrilateral muscle, situated on the dorsum of the foot; it is divided into four portions anteriorly, and is an accessory of the extensor longus digitorum. It *arises* from the os calcis, and is *inserted* into the first four toes.

It arises, by a rounded extremity, from a small excavation on the outside of the foot, formed by the os calcis and the astragalus (*the astragalo-calcanean fossa*), and from the os calcis, in front of that excavation. Its origin from these parts is both fleshy and tendinous. The muscle then passes forward and inward, and soon divides into four fleshy fasciculi, each representing a little penniform muscle, and terminating quickly in a small tendon, the size of which is proportioned to the strength of the fasciculus. The internal tendon is the largest, because it is intended for the great toe; it is situated below the tendon of the extensor proprius pollicis, which it crosses at a very acute angle, and is inserted into the dorsal surface of the proximal end of the last phalanx. The second, third, and fourth tendons, intended for the second, third, and fourth toes, are subjacent to the corresponding tendons of the extensor longus digitorum, which they cross at a very acute angle. Having reached the metatarso-phalangal articulations, the tendons of the short extensor are situated to the outside of those of the extensor longus, and are blended with them, so as to complete the fibrous sheath on the dorsal surface of the first phalanx, and to terminate in a similar manner.

Relations.—It is covered by the dorsal fascia of the foot, by the tendons of the extensor longus digitorum and extensor proprius pollicis; it covers the second row of the tarsal bones, the metatarsus, and a small portion of the interosseous muscles and the phalanges. The arteria dorsalis pedis runs at first along the inner border of this muscle, which overlaps the artery, where the latter perforates the first interosseous space, in order to reach the sole of the foot.

Action.—It extends the first four toes; it acts upon the first phalanx only of the great toe. Its obliquity enables it to correct the contrary oblique movement communicated to the toes by the contraction of the extensor longus digitorum; so that the opposite actions of these two muscles are mutually destroyed, and the foot is extended directly. Not uncommonly, the extensor brevis presents a fifth fasciculus, which is lost upon some one of the metatarso-phalangal articulations.

Internal Plantar Region.

The muscles of the ball of the great toe may be divided, like those of the thumb, into two orders, viz., those which pass from the tarsus to the inner side of the first phalanx, and those which pass from the tarsus to the outer side of the same phalanx. Here, as with the muscles of the thumb, the tendon of the flexor longus divides the flexor brevis pollicis pedes of authors into two parts: one internal, forming the flexor brevis of the great toe, properly so called; the other external, which is found to be connected with the oblique adductor of this toe.

Muscles inserted into the Inner Side of the First Phalanx of the Great Toe.

Dissection.—In order to expose the abductor brevis, it is sufficient to remove the internal plantar fascia; the flexor brevis will be found under, *i. e.*, deeper than the tendon of the abductor brevis.

The muscles inserted into the inner side of the first phalanx of the great toe are the abductor brevis and the flexor brevis. They are distinct at their origins, but are often blended at their insertions; so that Winslow united them together under the name of *le thénar du pied.*

The Abductor Pollicis Pedis.

This muscle (le court adducteur,* *Cruveilhier*, *r*, *fig.* 131) is the most superficial in the internal plantar region; it *arises* on the inside, from the internal posterior tuberosity of the os calcis; from the internal annular ligament under which the posterior tibial vessels and nerves pass; from the upper surface of the internal plantar fascia; and from the lower surface of a tendinous expansion, which occupies the entire extent of the deep or superior surface of the muscle. From these points the fleshy fibres proceed to the circumference of a tendon (*r*, *figs.* 132, 133), which emerges from them inferiorly near the first cuneiform bone, but is often accompanied by them superiorly as far as its *insertion* into the internal sesamoid bone, opposite the first phalanx of the great toe.

Relations.—It is covered below by the internal plantar fascia, and is divided from the muscles of the middle plantar region by a tendinous septum, which gives attachment to some of its fleshy fibres. It is superficial to the flexor brevis pollicis, the flexor accessorius, the tendons of the flexor longus digitorum, and that of the flexor longus pollicis, the tarsal insertions of the tibialis anticus and posticus, the plantar vessels and nerves, and the internal articulations of the tarsus.

Action.—It is, properly speaking, a flexor of the great toe.

Fig. 131.

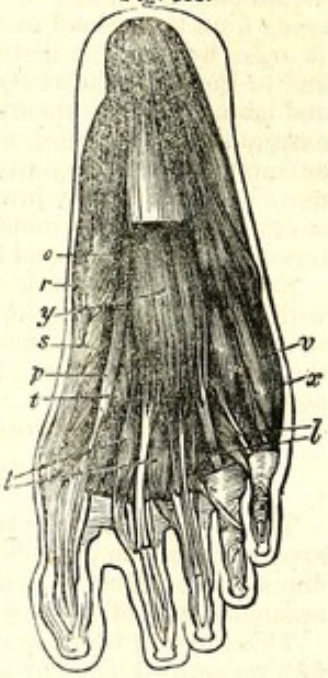

The Flexor Brevis Pollicis Pedis.

Adopting a similar plan in the definition of this muscle as in that of the short flexor of the thumb, I shall describe as the short flexor of the great toe that portion (*s*, *fig.* 133) only of the flexor brevis of authors which extends from the second row of the tarsus to the internal sesamoid bone of the metatarso-phalangal articulation of the great toe, and shall refer to the oblique adductor that portion (*t*) which is attached to the external sesamoid bone. This change appears to be warranted by the rule already laid down for the distinction of muscles. Community of the fixed points of origin is not sufficient to establish the unity of two muscles, provided their movable insertions are distinct. A cellular interval and the tendon of the flexor longus pollicis establish anteriorly the line of demarcation between the flexor brevis and the adductor obliquus pollicis.

According to this view, the flexor brevis pollicis (*s*, *figs.* 131, 132, 133) *arises* from the second row of the tarsus, particularly from the cuboid and the third cuneiform bones, by some tendinous fibres which are formed by a continuation of the inferior ligaments of the tarsus, and are common to this muscle and the internal portion (*t*) of the oblique adductor of the great toe. The tendon of the tibialis posticus (*n*, *fig.* 133), or, rather, the prolongation which this tendon gives off to the fourth metatarsal bone, also furnishes some points of origin. The fleshy fibres proceeding from these different attachments form a bundle that gradually increases in size, becomes separated from the oblique ad-

* See note, next page.

ductor, and terminates in a tendon which is *inserted* into the external sesamoid bone, and also into the glenoid ligament of the metatarso-phalangal articulation. Not unfrequently the greater number of the fleshy fibres are attached to the tendon of the abductor brevis, and thus constitute the short head of a biceps muscle.

Relations.—The flexor brevis pollicis is in relation below with the internal plantar fascia, and with the tendon of the abductor brevis pollicis, being moulded upon it, and usually separated from it by a tendinous sheath, except in those cases where the two muscles are blended together. Observe that, at the point where the fleshy belly of the abductor terminates, the flexor brevis is in relation above with the tendon of the peroneus longus (*e*, *fig.* 133) and the first metatarsal bone.

Action.—The same as that of the preceding muscle, but it is much less powerful, and less extensive.

Muscles inserted into the External Side of the First Phalanx of the Great Toe.

These are the oblique and transverse adductors.*

Dissection.—They are exposed by cutting across, and turning forward the flexor brevis digitorum, the tendons of the flexor longus digitorum, and the flexor accessorius: particular care should be taken, when the dissection has extended as far as the heads of the metatarsal bones, to avoid cutting the small transverse adductor.

The Adductor Pollicis Pedis.

This (l'abducteur oblique, *Cruveilhier*, *t t'*, *fig.* 133) is the largest of all the plantar muscles; it is prismatic and triangular, and occupies the great hollow formed by the last four metatarsal bones, and is bounded by the first metatarsal bone on the inner side. It extends from the second row of the tarsus to the external sesamoid bone of the great toe. It *arises* by two very distinct portions: the smaller (*t*, *figs.* 131, 132, 133), common to it and to the flexor brevis, proceeds from the cuboid bone; the other (*t'*) is much larger, and arises from the sheath of the tendon of the peroneus longus (*e*), from the posterior extremities of the third, fourth, and fifth metatarsal bones, and from the transverse ligaments by which they are united. From these different origins the fleshy fibres pass more or less obliquely inward, and are *inserted* by a tendinous bundle into the external sesamoid bone of the metatarso-phalangal articulation of the great toe, and into the posterior edge of the glenoid ligament of the same joint.

Relations.—Its inferior surface is in relation with the long and short flexors of the toes, with the flexor accessorius, the lumbricales, and the plantar fascia; its *superior surface*, with the interosseous muscles and the external plantar artery; and its *inner surface*, with the first metatarsal bone, the tendon of the peroneus longus, and with the flexor brevis pollicis.

Action.—It is a powerful adductor and flexor of the great toe.

The Transversus Pollicis Pedis.

This small transverse bundle (l'abducteur transverse, *Cruveilhier*, *u*, *fig.* 133) forms an appendage of the preceding muscle, and is represented in the hand by the transverse fibres of the adductor pollicis; it extends from the fifth metatarsal bone to the external sesamoid bone of the metatarso-phalangal articulation of the great toe.

This muscle, which is of variable size, *arises* externally from beneath the head of the fifth metatarsal bone, by a tendinous and fleshy tongue, which is directed transversely inward, is strengthened by other fibres arising from the anterior transverse ligament of the metatarsus, and from the interosseous aponeurosis, and is *inserted* into the outer side of the first phalanx of the great toe, where it is often blended with the attachment of the oblique adductor.

Relations.—It is in relation below with the tendons of the long and short flexors of the toes and with the lumbricalis, and above with the interosseous muscles. It is lodged in the anterior part of the deep concavity of the metatarsus, and is provided with a proper sheath.

Actions.—It adducts the great toe, and draws the head of the metatarsal bones towards each other.

* [The terms adductor and abductor are applied by M. Cruveilhier to the muscles of the great toe, from their respective actions upon it, in reference to the axis of the body; the muscle attached to the inner side of that toe being called its adductor, and those to the outer side its abductors. In the translation, however, the nomenclature of Albinus has been adopted, in which the terms adductor and abductor have reference to the *axis of the limb*: first, because it is followed by the majority of authors; and, secondly, because it is in accordance with the principle observed by M. Cruveilhier himself, in describing not only all the muscles of the hand, but some even of those of the foot, viz., the interossei, which are classed by him as abductors or adductors, according as they draw the several toes from or towards an imaginary axis passing through the *second* toe. By this change much risk of perplexity will be avoided, and a uniform principle of nomenclature preserved as regards all the muscles of the hand and foot.

In the description of each muscle of the great toe, the synonymes of Cruveilhier are given between brackets; but in all instances, both here and hereafter, where these muscles have incidentally to be mentioned, the names adopted from Albinus will be strictly adhered to.

It is scarcely necessary to observe that the *abductor* of the little toe will still retain its name.]

EXTERNAL PLANTAR REGION.

The Abductor Digiti Minimi.

Dissection.—This is common to the abductor and the flexor brevis. The first is exposed by simply removing the external plantar fascia, and the second by removing or reflecting down the first.

The *abductor digiti minimi* (*v*, *fig.* 131) is of the same form, the same structure, and almost the same size as the abductor pollicis, and extends from the os calcis to the first phalanx of the little toe. It *arises* by tendinous and fleshy fibres from the external posterior tuberosity of the os calcis, from the outer side of the internal posterior tuberosity, and from an aponeurosis occupying the upper surface of the muscle. The fleshy fibres having arisen in succession from these different points, proceed obliquely round a tendon, from which they emerge, opposite the posterior extremity of the fifth metatarsal bone. The fleshy belly of the muscle appears to end at this point, but it is continued by other fibres, arising from the upper surface of the external plantar fascia, and inserted either into the common tendon, or separately, by the side of this tendon, into the outer part of the first phalanx of the little toe. A small fleshy bundle is frequently detached from the body of the muscle, and implanted into the posterior extremity of the fifth metatarsal bone, together with a prolongation of the external plantar fascia, which serves as a tendon for it.

Action.—It is an abductor and flexor of the little toe.

The Flexor Brevis Digiti Minimi.

Fig. 132.

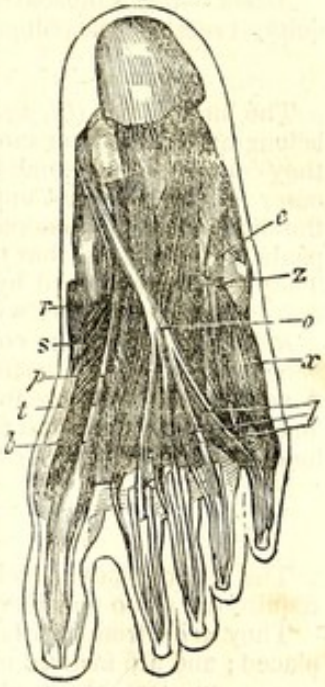

This is a small fleshy fasciculus (*x*, *figs.* 131, 132, 133), situated along the external border of the fifth metatarsal bone, and forming a continuation of the series of interosseous muscles, with which it was for a long time confounded (interosseus, *Spigelius*): it extends from the second row of the tarsus, and from the fifth metatarsal bone, to the first phalanx of the little toe. It *arises* from the ligamentous layer covering the plantar surface of the metatarsal row of the tarsal bones, and from the posterior extremity of the fifth metatarsal bone; it is *inserted* into the outer side of the first phalanx of the little toe, or, more correctly, into the posterior edge of the glenoid ligament of the metatarso-phalangal articulation of that toe. Some of the fleshy fibres will be found attached to the entire length of the external border of the fifth metatarsal bone; and these sometimes form a small and very distinct muscle, representing the opponens digiti minimi of the hand.

Relations.—It is covered below by the plantar fascia, which is here very thin, and also by the tendon of the abductor digiti minimi; it is in relation above with the fifth metatarsal bone and the first plantar interosseous muscle.

Action.—The same as that of the preceding muscle with regard to flexion, but its action is less powerful and less extensive.

MIDDLE PLANTAR REGION.

The Flexor Brevis Digitorum.

Dissection.—Remove the plantar fascia, which is intimately united to this muscle posteriorly.

The flexor brevis digitorum (*y*, *fig.* 131) is a short, thick muscle, narrow behind, and divided into four tendons in front. It *arises* from the inside of the external tuberosity of the os calcis, from the upper surface of the middle plantar fascia, from a special tendinous expansion occupying the lower surface of the muscle, and appearing to be a dependance of the plantar fascia; and, lastly, from an aponeurotic septum, situated between it and the muscles of the external plantar region. It forms a fleshy belly, which is narrow and thick behind, passes directly forward, increases in breadth, and soon divides into four, sometimes only into three fasciculi, constituting as many small and perfectly distinct penniform muscles, the long and delicate tendons of which emerge from the fleshy fibres before reaching the metatarso-phalangal articulations, become flattened, and are then situated below and in the same sheath with the tendons of the flexor longus. Opposite the first phalanx each tendon of the short flexor bifurcates, to allow the passage of the corresponding tendon of the flexor longus, is formed into a groove, becomes reunited above the latter tendon, and once more bifurcates, in order to be *inserted* along the borders of the second phalanx (hence it was named perforatus by *Spigelius*, and le perforé du pied by *Winslow*). The short flexor of the toes is, therefore, analogous to the superficial flexor of the fingers.

Relations.—It is covered below by the plantar fascia and the skin; it is in relation

above with the plantar vessels and nerves, with the tendon of the flexor longus digitorum, and with the flexor accessorius and the lumbricales, from which it is separated by a tendinous lamina. On its outer and inner side it is completely isolated from all the adjacent muscles by prolongations of the plantar fascia.

Action.—It flexes the second phalanges of the last four toes upon the first phalanges, and these upon the corresponding metatarsal bones.

The Flexor Accessorius.

This is a flat, quadrilateral muscle, forming a considerable fleshy mass (massa carnea, *Jacobi Sylvii*, *z*, *fig.* 132); it *arises*, by a bifurcated extremity, from the lower part of the groove of the os calcis, and a small part of the calcaneo-scaphoid ligament by fleshy fibres, and by means of a tendon from the lower surface of the same bone, this tendon sometimes extending as far as the external posterior tuberosity of the os calcis. From these points the fleshy fibres pass directly forward, and terminate in the following manner: the lower fibres become *inserted* into the outer margin, and a small portion of the inferior surface of the tendon of the flexor longus digitorum; while the upper are *inserted* into several small fibrous bundles, which unite together, receive a considerable expansion from the tendon of the flexor longus pollicis, and are ultimately blended with, and increase the size of the divided tendon of the flexor longus digitorum.

Relations.—This muscle is in relation *below* with the flexor longus digitorum and the plantar vessels and nerves, and *above* with the os calcis and the inferior calcaneo-cuboid ligaments.

Action.—It is a muscle of re-enforcement, and assists in flexing the toes; from its obliquity, it rectifies the oblique action of the flexor longus digitorum in the opposite direction.

The Lumbricales.

The lumbricales (*l l*, *figs.* 131, 132), which form a second class of accessory muscles belonging to the flexor longus digitorum, exactly resemble the lumbricales of the fingers; they consist of four small fleshy tongues, decreasing in size from within outward, the two outer of which are not unfrequently atrophied; they extend from the angles formed by the division of the tendons of the flexor longus to the inner or tibial borders of the first phalanges of the last four toes, and to the corresponding margins of the extensor tendons. They are distinguished by the numerical names of *first*, *second*, *third*, and *fourth*. The first is situated parallel with the flexor tendon of the second toe.

Relations.—They are covered below by the flexor brevis digitorum; they emerge from beneath the plantar fascia, in the interval between the sheaths furnished by it to the flexor tendons, gain the inner side of the corresponding metatarso-phalangal articulation, and terminate upon the first phalanx and inner margin of the tendons of the extensor longus digitorum. They have the same *action* as the lumbricales of the hand.

Interosseous Region.

The Interossei.

The interosseous muscles of the foot correspond exactly with those of the hand, and require the same consideration.

They *arise* from the lateral surfaces of the interosseous spaces in which they are placed; and are *inserted* into the sides of the first phalanges and the corresponding margins of the tendons of the extensor muscles. They are seven in number, viz., four dorsal (three of which are seen at *d d d*, *fig.* 133), and three plantar (*p p p*); to the latter, however, the oblique adductor of the great toe may be added, for it is nothing more than a very large plantar interosseous muscle.

Fig. 133.

As in the hand, the dorsal interossei are abductors, their origins being situated externally to the axis of the foot; the plantar interossei, again, are adductors; but the axis of the foot must be supposed to extend through the *second*, and not through the middle toe. As we observed in the hand, the dorsal interossei project into the plantar region, by the side of the plantar muscles; and so narrow are the interosseous spaces in the foot, that these dorsal muscles are much more completely situated in the plantar than those of the hand in the palmar region. The palmar interossei corresponding to the fourth and fifth toes, arise not only from the lower two thirds of the internal or tibial side of the corresponding metatarsal bone, but also from the lower surface of the posterior extremity of the same bone. It follows, therefore, that the interosseous muscles, viewed from below, appear one continuous muscle, in which it would be difficult to separate the muscles of each space, if the interosseous plantar fascia did not give off prolongations between them; elsewhere, a cellular line defines the limit between each plantar and dorsal muscle.

Again, as in the hand, the dorsal interossei arise from two corresponding metatarsal bones at once, but more especially from the lateral surface of that metatarsal bone which is directed *from* the axis of the foot: as in the hand, also, their posterior extremities are perforated by the posterior perforating arteries, the first being perforated by the arteria dorsalis pedis. The plantar interossei arise from only one of the metatarsal bones, and from the lateral surface that is directed *towards* the imaginary axis of the foot; moreover, they do not arise from the entire thickness of the bone, but only from its inferior two thirds, since the upper third is covered by the dorsal muscle.

The following are the general *relations* of the interossei: they are separated above from the tendons of the extensors by a layer of fibrous tissue, and by the dorsal interosseous fascia; and below from the proper muscles of the foot, by the deep plantar interosseous fascia, which is much stronger than the corresponding structure in the hand, and gives off septa between the *different pairs* of interosseous muscles.

PHYSIOLOGICAL ARRANGEMENT OF THE MUSCLES.

However important it may be to become acquainted with the order of super-imposition, or the topographical arrangement of the muscles, it is no less necessary to study the retrospective uses, in other words, the physiological arrangement of these organs.* In order to obtain, as much as possible, the advantages of each of these two methods, having already described each muscle in its topographical order, I shall now give a table of the muscles, arranged according to their physiological relations. It is important to observe that the terms *muscles of the arm, of the thigh, &c.*, have not the same acceptation in the two arrangements. Thus, by the term muscles of the arm, in the topographical order, we mean the muscles which occupy the region of the arm, as the deltoid, biceps, &c.; but, in the physiological arrangement, the same term is applied to the muscles which move the arm, viz., the pectoralis major, latissimus dorsi, &c.

Muscles of the Vertebro-cranial Column.

These are divided into the extensors, the flexors, and the lateral muscles or lateral flexors, which incline the vertebral column to one side or the other. There are no rotators, for rotation is performed by the extensor muscles.

Extensors.—These occupy the posterior region of the vertebral column. They consist, on each side, of, 1. The posterior spinal, or long muscles of the back, divided into the sacro-lumbalis, longissimus dorsi, and transverso-spinalis; 2. Of the transversalis colli and the trachelo-mastoideus, which may be regarded as accessory fasciculi to the longissimus dorsi; 3. Of the splenius, or representative of the longissimus dorsi of the neck and head; 4. Of the complexus, or *transverso-spinalis* of the head; 5. Of the inter-spinales, in which the two recti postici of the head may be included; 6. Of the obliquus major, or *spino-transversalis* of the atlas; 7. Of the obliquus minor, or *transverso-spinalis* of the head.

Flexors.—These are situated on the anterior region of the vertebro-cranial column. The most important of these muscles are carried forward, and attached to the sternum, and to those long transverse processes called the ribs. They are on each side, 1. The rectus abdominis; 2. The sterno-cleido-mastoideus. The other muscles that co-operate in flexion occupy the deep anterior cervical region, viz., 1. The rectus capitis anticus major; 2. The rectus capitis anticus minor; 3. The longus colli.

Lateral Muscles.—These are, 1. The inter-transversales of the neck and loins, among which I include the rectus capitis lateralis; 2. The scaleni anticus et posticus; 3. The quadratus lumborum.

Muscles of the Ribs, or of the Thoracico-abdominal Parietes.

These are, 1. The inter-costales, externi and interni, which are both elevators and depressors; 2. The small accessory muscles, viz., the infra-costales of Verheyen and the supra-costales, or levatores costarum, the latter being always *elevators;* 3. The serrati postici superiores, which are *elevators;* 4. The serrati postici inferiores, *depressors;* 5. The triangularis sterni, or small anterior serratus, also a depressor; 6. The diaphragm, a muscular septum, the contraction of which increases the vertical diameter of the thorax, and draws the ribs inward. The muscles of the abdominal parietes are so intimately connected in action with those of the thorax, that the description of the former naturally follows that of the latter. The abdominal muscles, then, may be regarded as muscles of expiration, and are all *depressors* of the ribs. There are, 1. The obliquus exter-

* Custom, rather than conviction, has induced me to prefer the topographical to the physiological arrangement. The only objection which can be urged against the latter is, that it does not permit all the muscles to be dissected upon the same subject; but this objection applies only to a few regions; and as these regions exist in pairs, the superficial muscles on one side might surely be sacrificed. Moreover, there is no reason why the examination of the deep-seated muscles should not be postponed until the superficial ones have been studied. I therefore direct students to dissect these parts sometimes according to their topographical, and at others after their physiological order

nus, which is nothing more than a large external intercostal muscle, extending between the ribs and the pelvis; 2. The obliquus internus, which may be regarded as a large internal intercostal muscle, of which the cremaster is a dependance; 3. The transversalis, which we may consider as forming with the diaphragm a single muscle, interrupted by its costal attachments.

Muscles which move the Lower Jaw.

As the bones of the upper jaw are immovably articulated together and to the cranium, they have no proper muscles. The muscles of the face do not belong to them, but are true cutaneous muscles, attached to the different bones only for the purpose of having fixed origins. The lower jaw, on the contrary, is provided with two principal orders of muscles, *elevators* and *depressors*, to which are added *diductors* (from *diduco*, to draw aside). The elevators and diductors preponderate; the only office of the depressors is to bring down the jaw into a position from which it may then be raised.

1. *Elevators.*—These are the masseters, the temporales, and the pterygoidei interni.
2. *Diductors*, viz., the pterygoidei externi.
3. *Depressors*, consisting of the muscles of the supra- and infra-hyoid regions, and more particularly of the two digastrici.

Muscles which move the Os Hyoides.

These are divided into elevators and depressors.

All the *elevators* belong to the supra-hyoid region, and are, 1. The stylo-hyoidei; 2. The mylo-hyoidei; 3. The genio-hyoidei.

The *depressors* consist of the muscles of the infra-hyoid region, viz., 1. The sterno-hyoidei; 2. The sterno-thyroidei; 3. The thyro-hyoidei; 4. The omo-hyoidei.

Muscles which move the Pelvis.

There are no muscles proper to the pelvis. The ischio-coccygeus is the only intrinsic muscle. The extrinsic muscles attached to the pelvis do not belong to its cavity, but merely take their fixed points from its parietes. It is only under particular circumstances that the pelvis changes its usual office, and becomes the movable point; for example, in the horizontal position, in the action of climbing, and in the reversed attitude of a tumbler, the pelvis is moved upon the vertebral column on the one hand, and upon the femur on the other.

Muscles which move the Shoulder.

The muscles of each shoulder are divided into elevators and depressors, both of which are also rotators. The *elevators* are, 1. The trapezius; 2. The rhomboideus; 3. The levator anguli scapulæ. The *depressors* are, 1. The pectoralis minor; 2. The subclavius; 3. The serratus magnus. The elevators and depressors of the entire shoulder must be carefully distinguished from those which raise or depress its apex.

Muscles which move the Thigh upon the Pelvis.

These muscles are divided into extensors, flexors, adductors, abductors, and rotators.

The *extensors* and *abductors* are the same, viz., the three glutæi.

The conjoined psoas magnus, iliacus, and psoas parvus constitute the only *flexor*.

Adduction is performed by four muscles, viz., the pectineus and the three adductors.

Rotation outward is performed by six muscles, viz., the pyriformis, the two gemelli, the obturator internus, the quadratus femoris, and the obturator externus.

Rotation inward is performed by the tensor vaginæ femoris, and especially by the anterior fibres of the glutæi, medius et minimus.

Muscles which move the Arm upon the Shoulder.

These muscles are divided into *abductors*, which are at the same time *flexors*, and into *adductors* and *rotators*. There are no proper muscles for the movement forward or *flexion*, nor for the movement backward or *extension*, both of which motions are effected by the adductors and abductors.

The *abductors* are, 1. The deltoideus; 2. The coraco-brachialis; 3. The supra-spinatus.

The *adductors* are, 1. The pectoralis major; 2. The latissimus dorsi; 3. The teres major.

The *rotators* are, 1. The external, viz., the infra-spinatus and the teres minor; 2. The internal, viz., the sub-scapularis.

Muscles which move the Leg upon the Thigh.

These are divided into flexors and extensors. The *flexors* are, 1. The biceps femoris; 2. The semi-tendinosus; 3. The semi-membranosus; 4. The popliteus; 5. The sartorius; 6. The gracilis.

Extension is performed by one muscle only, viz., the triceps femoralis, the long head

of which is formed by the rectus femoris, and the other two heads by the triceps cruris of authors, viz., the vastus externus and vastus internus, including the crureus.

I should remark, that all these muscles which arise from the pelvis perform the double function of moving the leg upon the thigh, and the thigh upon the pelvis.

Muscles which move the Forearm upon the Arm.

These are divided into flexors and extensors. The *flexors* are the biceps and the brachialis anticus. The *extensors* are, 1. The triceps (of which the long head resembles the rectus femoris); 2. The anconeus.

Muscles which move the Radius upon the Ulna.

These are rotators inward, or *pronators*, viz., 1. The pronator teres; 2. The pronator quadratus; and rotators outward, or *supinators*, viz., 1. The supinator longus; 2. The supinator brevis. The pronators occupy the anterior region, the supinators the posterior region of the forearm.

Muscles which move the Hand upon the Forearm.

These are divided into flexors and extensors. The *flexors* are, 1. The flexor carpi radialis; 2. The palmaris longus; 3. The flexor carpi ulnaris. The *extensors* are, 1. The extensores carpi radiales, longior et brevior; 2. The extensor carpi ulnaris.

Adduction and *abduction* are also performed by these muscles.

Muscles which move the Fingers.

These are divided into extensors, flexors, adductors, and abductors. The *extensors* are, 1. The extensor communis digitorum; 2. The extensor digiti minimi; 3. The abductor longus pollicis; 4 and 5. The extensor brevis and extensor longus pollicis; 6. The extensor proprius indicis.

The *flexors* are, 1. The flexor sublimis digitorum; 2. The flexor profundus digitorum, and its accessories, the lumbricales; 3. The flexor longus pollicis.

The extensors and the flexors of the fingers are all situated in the forearm; the *adductors* and *abductors* belong to the hand: they consist of the interossei, which are seven in number, four dorsal, constituting the abductors, and three palmar, which are adductors.

Other muscles are also *superadded* to the thumb and the little finger. The muscles superadded to the thumb are, 1. Those which constitute the thenar eminence (ball of the thumb), viz., the abductor brevis, the opponens, and the flexor brevis; 2. The adductor pollicis, which is nothing more than a palmar interosseous muscle. The muscles superadded to the little finger constitute the hypothenar eminence (ball of the little finger), and form, as it were, a repetition of those of the thenar eminence, viz., the abductor brevis, the flexor brevis, and opponens. But although three only are thus described, it is because the palmar interosseous muscle of the little finger, which represents the adductor pollicis, presents no peculiarities, and is, therefore, classed with the other palmar interossei.

Muscles which move the Foot upon the Leg.

These are divided into flexors and extensors: the same muscles also produce, at the articulation of the two rows of the tarsal bones, movements of rotation, which correspond to *adduction* and *abduction*.

The *extensors* are, 1. The gastrocnemius and soleus, or the triceps suralis, with which we describe a small rudimentary muscle, the plantaris. 2. The tibialis posticus. 3. The peroneus longus et brevis.

There is only one *flexor*, viz., the tibialis anticus. The peroneus tertius, when it exists, is merely a dependance of the extensor longus digitorum.

There are no muscles in the leg analogous to the pronators and supinators of the forearm.

Muscles which move the Toes.

These are divided into extensors and flexors.

The *extensors* are, 1. The conjoined extensor longus digitorum and peroneus tertius. 2. The extensor proprius pollicis. 3. The extensor brevis digitorum. The *flexors* are, 1. The flexor longus digitorum, and its accessories, the lumbricales. 2. The flexor brevis digitorum; the flexor longus pollicis.

Contrary to what we have seen with regard to the fingers, many of the flexors and extensors of the toes form part of the intrinsic muscles of the foot. As in the hand, the *adductors* and *abductors* of the toes occupy the thenar, hypothenar, and interosseous regions.

The interosseous muscles are adductors and abductors of the toes; they are seven in number, four dorsal, being the abductors, and three plantar, acting as adductors.

The *superadded* muscles of the great toe are, 1. The muscles of the thenar eminence, viz., the abductor brevis and the flexor brevis. 2. The adductor obliquus, and the adductor transversus. The muscles *superadded* to the little toe are the muscles of the hypothenar eminence, viz., the abductor and the flexor brevis.

Cutaneous Muscles.

These muscles, which are inserted into the skin by one of their extremities at least, are in the human subject concentrated round the openings in the face, with a single exception, viz., the palmaris brevis.

The *cutaneous muscles of the ear* belong to the orifice of the external auditory meatus, and are all rudimentary in man. They form the three auricular muscles.

The *muscles of the eyelids*, on either side of the face, are divided into constrictors and dilators. There is only one *constrictor*, the orbicularis palpebrarum, of which the corrugator supercilii may be considered an accessory.

There are two *dilators*, viz., the levator palpebræ superioris and the occipito-frontalis.

The *cutaneous muscles of the nose* consist of four or five pairs, *i. e.*, on each side of the face, of the pyramidalis nasi, the levator labii superioris alæque nasi, the transversalis nasi, the depressor alæ nasi or myrtiformis, and the naso-labialis of Albinus.

The *cutaneous muscles of the lips* are, 1. A *constrictor*, viz., the orbicularis oris. 2. Nine pairs of *dilators*, consisting, on each side, of the levator labii superioris alæque nasi already mentioned, the levator labii superioris, the zygomaticus major, the caninus, the buccinator, the triangularis oris, the quadratus menti, the levator labii inferioris, the platysma myoides; and often of two accessory muscles, viz., the risorius of Santorini, and the zygomaticus minor.

APONEUROLOGY.

General Observations on the Aponeuroses.—Structure.—Uses.

The *aponeuroses* are fibrous membranes, arranged in the form of inextensible textures, which constitute sheaths for the muscles, and, at the same time, afford them broad surfaces for attachment. The aponeuroses are generally known, at the present day, by the name of *fasciæ* (*fascia*, a band), an expression which was at first applied exclusively to the strong, broad aponeurotic band, forming the termination of the tensor vaginæ femoris, and part of the fascia lata of the thigh.

The aponeuroses constitute important adjuncts to the system of locomotion. They were for a long time neglected, or, rather, studied independently of each other, and then only partially, until Bichat gave a general view of them, in his division of the fibrous system, including the membranous forms of that tissue, of which the aponeuroses form the greatest part.

As the aponeuroses have now become the object of numerous researches, and even the subject of some special treatises,* I have considered that it would be useful to offer a description of all the aponeuroses of the human body under the head of Aponeurology. This grouping together of analogous parts will have the double advantage of simplifying the description of the particular aponeuroses, by making them elucidate each other, and of bringing into prominent notice a system of organs, the study of which is generally neglected in anatomical lectures.

General Observations.—The aponeuroses are divided by Bichat into two distinct classes, one serving for the insertion of muscles, viz., the *aponeuroses of insertion*; the other for investing or containing the muscles, called the *investing* or *confining aponeuroses*. Many aponeuroses serve both these purposes at the same time; but, in general, one or the other function predominates in each.

The *aponeuroses of insertion*† are subdivided into those formed by the expanded continuations of tendons, and those which do not originate in tendons. The aponeuroses of the gastrocnemius and soleus belong to the first class; those of the broad muscles of the abdomen are examples of the second: in the latter case, the aponeuroses serve both for the insertion and investment of the muscles. Sometimes the aponeurosis occupies the middle of a muscle; as, for example, the cordiform tendon of the diaphragm, and the aponeuroses of the occipito-frontalis. The use of the aponeuroses of insertion evidently has reference to the great number of muscular fibres, all of which could not have been attached to the limited superficies of the skeleton.

The *investing aponeuroses* occasionally form a sheath for the entire limb, sometimes for only a single muscle, and at others for several muscles. The first set are called *general*, the other two *partial* aponeuroses.

The aponeuroses are found not only in the extremities where they perform such important offices, but also in the trunk. As a general rule, wherever there exists a muscle fulfilling any special purpose, and susceptible of displacement during its contraction, we find an aponeurosis, or, rather, an aponeurotic sheath; and the thickness of this sheath is proportioned to the length and strength of the muscle, and especially to its tendency to displacement.

* Godman, of Philadelphia, published in 1824 a special work upon the fasciæ; and Paillard a treatise upon the aponeuroses of the human body in 1827.

† See note, p. 296.

Each aponeurosis presents for our consideration an *external* and an *internal surface*, a superior border or *circumference*, sometimes termed its *origin*, and an inferior border or *circumference*, sometimes called its *termination*.

1. The *external surface* of the general investing aponeuroses is in contact with the subcutaneous cellular tissue, from which it is separated by the superficial veins, lymphatics, and nerves. The skin is therefore movable upon these aponeuroses, excepting in some situations, as in the palms of the hands and soles of the feet, where it is intimately united to the fasciæ by prolongations from the inner surface of the cutis. What, indeed, would be the consequences with regard to the sense of touch, or in the attitude of standing, if the skin over those regions were as movable as it is upon the thigh? The same adhesion is also observed between the hairy scalp and the subjacent aponeurosis.

The mobility of the skin upon the aponeuroses depends upon the following contrivance: From the inner surface of the skin are given off a great number of prolongations, which, having intercepted the areolæ containing the adipose tissue, unite together, and expand into a membrane, which glides over the aponeuroses and the superficial vessels and nerves: the sub-cutaneous membrane thus formed bears the name of the *fascia superficialis:* it is only distinctly seen in regions that are traversed by superficial vessels and nerves, as in the lower part of the abdomen, and on the extremities.

2. The *deep surface* of a general investing aponeurosis presents fibrous prolongations passing between the different layers of muscles, and even between the muscles of which these layers are composed. Moreover, this surface and its several prolongations sometimes afford attachments to the superficial muscles, and sometimes it glides over the muscles and their tendons by means of a very loose filamentous cellular tissue—an arrangement that prevails throughout the greater part of the extent of this surface. Lastly, amid all these sheaths for the muscles, there exists a proper sheath for the principal vessels of the extremities.

These aponeurotic sheaths are not so exactly moulded upon the muscles as not to admit of the accumulation of a certain quantity of fat in their interior; nevertheless, their capacity is so far proportioned to the size of the muscles, that the latter, during their contraction, experience a degree of pressure from them which is highly favourable to their action, at the same time that it prevents all displacement.

In emaciated individuals, these sheaths are no longer filled by their respective muscles; and, without doubt, the want of a due compression upon the muscles has some influence in producing the weakness experienced by convalescents, or by those wasted by some chronic disease.

3. The *borders* or *circumferences* of aponeuroses, incorrectly named their origin and termination, are either continuous with the aponeuroses of the adjacent regions, or are attached to the processes on the articular extremities of the bones, or result, in part, from the expansion of tendons.

The aponeuroses are perforated by vessels and nerves, which, in such cases, are guided and protected by arches, rings, or canals of fibrous tissue: of this nature are the sheaths of the femoral artery and vein, and of the brachial artery and veins, the femoral arch, the canal and arch of the adductor muscles of the thigh, the arch of the obturator foramen, and the aortic arch of the diaphragm; these canals and arches tend to prevent any injury to the vessels and nerves by which they are traversed during the contraction of the muscles. We must not suppose, however, that the vessels are exempt from all pressure; for experience has proved that arteries are particularly liable to become affected with aneurism in the neighbourhood of such arches; as, for example, the popliteal and femoral arteries and the aorta. The muscular fibres, in fact, are not attached to these arches in such a manner as to dilate them in all directions during their contraction, but rather in such a way as to elongate them in one direction and contract them in another.

All the aponeuroses, whether of insertion or investment, have their tensor muscle. With regard to the aponeuroses of insertion, this requires no proof; for the action of the muscle or muscles to which they afford attachment must necessarily render them tense. It is no less true, however, of the investing aponeuroses, some of which have even a separate muscle for this purpose. Thus, the occipital and frontal muscles are tensors of the occipito-frontal aponeurosis. The fascia lata is rendered tense by the tensor vaginæ femoris, the palmar fascia by the palmaris longus, &c.

The aponeuroses of both kinds are inextensible, resisting, and insensible membranes, their thickness and strength being exactly proportioned to the resisting power and strength of the muscles which are invested by them, or to which they afford the means of insertion. Thus, the fascia of the thigh is very much stronger than that of the arm: the thickness of the aponeuroses increases from the upper to the lower part of the limbs; and, again, the powerful vastus externus is provided with a much stronger sheath than the muscles of the posterior, or of the internal region of the thigh. We may, then, consider it as a general law, without exception, that the aponeurotic system invariably presents a corresponding degree of development to that of the muscular system. We should, therefore, study the aponeuroses, as well as the muscles, upon robust subjects; their pearly aspect is destroyed in individuals wasted by chronic diseases. The aponeurotic and

muscular systems are both most fully developed in carnivora, in which class of animals the pearly appearance is peculiarly well marked, and the cellular tissue is often replaced by a fibrous texture; a transformation which proves the analogy of the cellular and fibrous tissues in organization, vitality, and function.*

The thinner fasciæ are composed of a single layer of parallel fibres, which have between them intervals of different sizes: stronger aponeuroses are composed of several planes, the fibres of which intersect each other at various angles. The vessels and nerves of the aponeuroses are little known; but I believe that I have traced nerves into them. I have certainly done so with regard to the dura mater.*

I shall include among the aponeuroses the *fibrous sheaths of tendons*,* which are sometimes presented under the form of imperfect rings, or canals of different lengths, which retain the tendons in contact with the bones. They serve to confine the tendons, to keep them applied against the bones, and to favour their reflection.

The *periosteum** must also be annexed to the aponeurotic system; it is a true aponeurosis, covering every part of the bones, and constituting a fibrous sheath for them. We may consider the periosteum as the central point of the aponeurotic system, proceeding from which, we find either tendons expanding upon the surface or in the substance of muscles, and constituting the aponeuroses of insertion; or else those fibrous cones or pyramids, from the interior of which the fleshy fibres take their origin. From the periosteum, or, rather, from the ridges or clefts by which the surfaces of bones are marked, both the partial and general investing aponeuroses arise. In this way the muscles of the extremities are situated between two fibrous layers; the deep layer consisting of the periosteum, the superficial layer of the general investing fascia: numerous septa pass from one to the other, and divide the limb into a number of compartments, intended to isolate, confine, and protect the different muscles.

Use of the Aponeuroses.—Forming, as they do, an important division of the fibrous textures, they partake of the physical, chemical, anatomical, physiological, and pathological properties of that tissue.

1. From their great strength, they are enabled to resist the powerful traction and distension exercised upon them by the muscular fibres. Their division or destruction is accompanied by displacement of the parts which they are intended to bind down. Between the different layers of the regions of the body they establish very precise limits, a knowledge of which is of the greatest importance, in enabling us accurately to account for many morbid phenomena, and in guiding us in the performance of surgical operations.

2. They are inextensible; hence the resistance which they oppose to the development of subjacent parts, and the tension produced by inflammation of organs situated beneath them. They yield to gradual distension, but then become thinner and weaker, and can only imperfectly fulfil their proper offices.

3. They are totally inelastic, and, therefore, when distended beyond a certain point, never return to their original dimensions. Of this we have an example in the condition of the abdominal parietes after utero-gestation, or ascites.

4. The low degree of vitality they possess explains why they are so slightly involved in inflammation or other morbid conditions of the adjacent structures, and also the fact of their establishing limits beyond which these diseases seldom pass. They are insensible to all ordinary stimuli, but become painful when they are violently overstretched. The plantar fascia, under such circumstances, becomes extremely sensitive.

Having made these general remarks, we shall now describe, in succession, the principal aponeuroses of the human body.†

* See note, *infrà*.

† *Note on Aponeurology.*—[The analogy existing between the cellular and aponeurotic investments of various organs renders it advantageous to consider in this place the general anatomy of the *cellular* and *fibrous* tissues.

The ultimate elements of both these kinds of tissue are precisely similar, though somewhat differently arranged in each; they consist of delicate transparent filaments, varying in diameter from $\frac{1}{20000}$th to $\frac{1}{13000}$th of an inch, and having a peculiar sinuous or undulating direction; they are insoluble in cold water, but by long-continued boiling are almost entirely converted into gelatine.

In *cellular tissue* these undulating filaments are arranged side by side, either into larger compound and flexuous fasciculi, or into thin, transparent laminæ, which cross and intersect one another in all directions, so as to leave interstitial cavities or areolæ, freely communicating with each other, and moistened by an albuminous fluid. The tissue thus formed, more properly called areolar, or filamentous, is of a grayish aspect, and highly elastic; the latter property depending not on any innate elasticity in the ultimate filaments, but on the sinuous disposition of those filaments, and of the fasciculi into which they are collected. But few vessels, and still fewer nerves, are believed to terminate in this tissue. It is continuous over the whole body; hence the great extent to which it may be affected with diffuse inflammation; it also invests and isolates parts, forms the matrix of nearly all organs, and the basis of many membranes; and is called, according to its position, investing, intermediate, penetrating, parenchymatous, or sub-membranous. The characters above described are most strongly marked in the loose cellular tissue, examples of which are met with in the axilla, under the sub-scapular muscle, between the free surfaces of muscles and their sheaths, behind the kidneys, &c. In other situations it is more condensed, as in the sub-serous, sub-mucous, and sub-cutaneous cellular tissues; in the latter of these, or the superficial fascia, and also in the cutis itself, it approaches to the fibrous tissue both in density and in the mode of arrangement of its elementary filaments, and is therefore termed *fibro-cellular tissue*. From this variety the transition is natural to the fibrous tissues, properly so called.

In *fibrous tissue* the undulating primitive filaments are also arranged side by side into fasciculi, which differ from those of cellular tissue in being much larger, more dense and more opaque, and in being straight instead of flexuous. They are white, shining, strong, and almost inelastic, qualities depending on the compact

PARTICULAR APONEUROSES.

Superficial Fascia.—Aponeuroses of the Cranium—of the Face—of the Neck—of the Thorax—of the Abdomen—of the Pelvis—of the Thigh, Leg, and Foot—of the Shoulder, Arm, Forearm, and Hand.

The Superficial Aponeurosis, or Superficial Fascia.

From every point of the deep surface of the skin fibrous cellular lamellæ arise, which intersect each other in various directions, so as to form meshes or areolæ, containing adipose tissue in ordinary circumstances, and a serous fluid in œdema.* The cutaneous muscle (*panniculus carnosus*) of the lower animals is developed in these laminæ; and among them are situated the sub-cutaneous vessels and nerves, and the lymphatic glands. The name of *fascia superficialis* has been of late applied to this assemblage of lamellæ.

It was pointed out in a particular manner by Glisson, who described it under the name of the general investment of the muscles, proceeding from the spine, and covering the whole body; Camper, Cowper, Scarpa, Hesselbach, Lawrence, J. Cloquet, &c., have described it upon the abdomen, in its relation with herniæ; Godman has spoken of its existence over the entire surface of the body: M. Paillard, in his inaugural dissertation, traced it with still greater exactness; MM. Velpeau and Blandin, in their *Traités d'Anatomie Chirurgicale*, consider it as existing in almost all regions of the body.

But if the word aponeurosis be employed in its ordinary acceptation, it will be found that a fascia superficialis, consisting of a fibrous texture capable of anatomical demonstration, exists only in two kinds of situations, viz., in those where the skin is extremely movable, and in those where there is a layer of sub-cutaneous vessels and nerves: in both these cases the fibrous prolongations from the skin are expanded into a thin lamina, constituting a superficial covering for these vessels and nerves, and separated from the fibrous investment of the muscles by a layer of cellular and adipose tissue, of variable thickness. In all other parts, the fibro-cellular prolongations of the skin become continuous either with the investing aponeuroses, or with the proper fibro-cellular sheaths of the muscles, or are lost in the sub-cutaneous cellular tissue. So true is this, that this thin areolar layer, which can with difficulty be separated from the skin in emaciated persons, disappears altogether in those whose cellular tissue is distended by fat or serous effusion.

Having made these remarks, I shall describe the superficial fascia in those regions only where it can be easily demonstrated, viz., in the lower part of the abdomen, and in the extremities.

The Superficial Fascia of the Abdomen.

This aponeurosis, from its constituting the first sub-cutaneous covering of herniæ, has particularly engaged the attention of authors who have specially treated of the pathological anatomy of those diseases.

It becomes evident in the neighbourhood of the umbilical region, but is much more distinct at the fold of the groin, where it divides into two layers, one of which is attached to the femoral arch, and the other is prolonged upon the lower extremity. It is bounded on the inside by the median line, and on the outside by another line, extending perpendicularly upward from the anterior superior spinous process of the ilium. It is prolonged over the inguinal ring, and over the spermatic cord in the male subject.

parallel disposition of the component filaments, and the slight amount of elasticity in particular on the absence of sinuosity in the compound fasciculi. According to the manner in which these fasciculi or fibres (as they are termed) are arranged and combined, we have either the membranous or the fascicular form of fibrous tissues.

In the *membranous* form there are some which closely resemble the fibro-cellular membranes already alluded to, and consist of the shining fibres crossing each other in all directions (without anastomosis), and intermixed with more or less condensed cellular tissue; for example, the thinner investing aponeurosis, the capsular ligaments, the pericardium, tunica albuginea, periosteum, and dura mater. In others, again, the fibres are more parallel, though still intersected, and combined with cellular tissue, as in the fascia lata of the thigh, and in other strong investing aponeuroses. In the aponeuroses of insertion of the broad muscles, and in the expanded terminations of tendons, there is scarcely any cellular tissue, while the parallel arrangement is yet more perfect; and, finally, the latter attains its utmost perfection in the round ligaments, and in tendons, which constitute the *fascicular* form of fibrous tissue, and the type of the tissue itself.

These textures contain but few nerves and vessels. The distribution of a branch of the fourth cranial nerve to the dura mater, alluded to in the text, has been confirmed by other anatomists. Bloodvessels abound in the periosteum, but they merely divide in that membrane, so as to enter the bone at a great number of points.

The *sheaths of tendons* (classed among the fibrous tissues by M. Cruveilhier) display a tendency to become fibro-cartilaginous, especially at and near their attachments to the bones. They have hitherto been described (ex. gr., p. 250, 257) as if lined by vaginal synovial membranes (note, p. 177). According to Dr. Henlé, however, their interior is not covered by an epithelium. The bursæ, or so-called bursal synovial membranes, formed between the tendons of muscles (p. 265), between tendons and bones (p. 265, 266, 267), and between the skin and projecting parts of bones, as over the patella, the olecranon, &c., according to the same authority, are also destitute of epithelium. It would appear, therefore, that although these cavities resemble in function the true synovial membranes, they differ anatomically from them, and consist merely of shut sacs formed in the general cellular texture of the body. Such bursæ, however, as communicate with the synovial capsules of joints (p. 216, 244), are probably lined by an epithelium.]

* [Adipose tissue is never deposited in the sub-cutaneous tissue of the eyelids, nor in the male organ of generation. These parts, however, may become much distended from serous infiltration.]

It has been said that in the fœtus, before the descent of the testicle, the superficial fascia dips into the inguinal canal, and forms an infundibuliform prolongation, reaching up to the lower part of that gland; and the dartos has been supposed to result from the expansion of this fascia—a description which can be regarded only as an ingenious speculation, which has not been confirmed by actual dissection.

Lastly, the external surface of the superficial fascia of the abdomen is in relation with the skin, separated from it, however, by a layer of adipose tissue of variable thickness, in which the sub-cutaneous vessels and nerves are situated. Its deep surface corresponds with the aponeurosis of the external oblique muscle, and with a portion of its fleshy fibres: from these parts it is separated by a layer of serous cellular tissue, which enables it to be moved easily upon this muscle and the sub-cutaneous vessels and nerves.

The Superficial Fascia of the Upper and Lower Extremities.

These are thin fibrous sheaths, separated from the skin by a greater or less quantity of adipose tissue, and from the investing aponeurosis of the muscles by the sub-cutaneous vessels and nerves. It does not exist around the joints, nor in the palms of the hands and soles of the feet, for in these places the skin adheres to the subjacent aponeuroses

The Aponeuroses of the Cranium.

The Occipito-frontal or Epi-cranial Aponeurosis.

This is a sort of tendinous or cutaneous cap (*galea capitis*), stretched between the two frontal and two occipital muscles. Its *superficial surface* is intimately adherent to the skin by means of very short and strong fibrous prolongations, between which the fatty matter is deposited: the frontal, occipital, temporal, and auricular vessels and nerves traverse this adipose tissue. Its *deep surface* glides upon the periosteum of the scull (*pericranium*) by the intervention of a very delicate cellular tissue, in which fat is never found. Its anterior margin receives the fibres of the frontal muscles, forming a triangular point between them; its posterior margin receives the fibres of the occipital muscles, and also occupies the interval between them. These two muscles act as tensors of the aponeurosis. Its outer margin gives attachment to the superior and anterior auricular muscles. It is composed behind of shining fibres, which seem to form a tendon of insertion to the occipitalis muscle, but it soon loses its pearly appearance, and becomes more adherent to the skin: it is thick and strong at the upper part of the head, but thin and almost cellular at the sides: it may be regarded as a dependance of the superficial fascia. It gives rise to the tension which is so common and so dangerous in inflammations of this region. Its adhesion to the skin explains the shallow character of ulcers, and the flatness of the small abscesses occurring in these parts.

The Temporal Aponeurosis.

Besides the tendinous origin of the temporal muscle, which has been already described, there is also a very strong investing aponeurosis, arising from the upper border of the zygomatic arch, and inserted into the curved line bounding the temporal fossa above. This aponeurosis completes the sort of case in which the muscle is contained; and the space between it and the temporal fossa corresponds with the thickness of the muscle.

It differs from the epicranial aponeurosis, which is more superficial and covers it superiorly, in not adhering to the skin, which glides very easily upon it. Its deep surface adheres to the upper part of the muscle, and furnishes it with numerous points of attachment; below it becomes free, and is separated from the fleshy fibres by a considerable quantity of fat; hence the depression formed in this situation in emaciated persons.

It increases in thickness from above downward; it divides below into two layers: one superficial and thinner, inserted into the outer edge of the upper border of the zygoma; the other deep and thicker, attached to the inner surface of that process. In tolerably stout persons, a considerable quantity of fat is situated between these two layers, and a remarkable branch of the temporal artery also occupies the same situation. This fat must not be confounded with the larger mass which lies beneath the aponeuroses. The resistance of this fascia explains the reason why abscesses in the temporal fossa never point outward, but rather tend downward into the zygomatic fossa.

The Aponeuroses of the Face.

The Parotid Aponeurosis.

This is a sheath of great thickness, especially that part which covers the outer surface of the gland; it is continuous below with the cervical fascia. It belongs especially to the gland, for which it forms a framework by means of fibrous prolongations from its deep surface. The density of this sheath explains both the pain caused by inflammation of the gland, and the difficulty with which pus makes its way from within it to the surface.

The Masseteric Aponeurosis.

This is a thin tendinous layer covering the masseter muscle, and continuous below with the cervical fascia; it appears to divide behind into two layers, one of which con-

stitutes the parotid fascia, and the other penetrates between that gland and the masseter; above and anteriorly, it becomes merged into the cellular tissue. Purulent matter situated beneath this fascia tends downward into the neck, but when situated superficially to it, points towards the skin.

The Buccinator Aponeurosis.

The buccinator is covered by a closely adherent fibrous layer, which is regarded as the expansion of the fibrous sheath of the Stenonian duct; it is thickest behind, where it is termed the buccinato-pharyngeal aponeurosis, because it gives attachment behind to the superior constrictor of the pharynx, and to the buccinator in front. This aponeurosis prevents superficial abscesses from opening into the mouth, and is also opposed to the extension outward of diseases attacking the mucous membrane.

The Cervical Aponeurosis, or Cervical Fascia.

In the cervical region we find, 1. The cervical fascia; 2. The prevertebral aponeurosis.

The Cervical Fascia.

The cervical aponeurosis covers the whole anterior region of the neck; it extends from the base of the lower jaw to the sternum and clavicles, and is insensibly lost on either side in the sub-cutaneous cellular tissue. It is thick in the median line, and forms a sort of *cervical linea alba*. From this linea alba two layers proceed in the supra-hyoid region, and four in the infra-hyoid region, which are arranged in the following manner:

1. The *superficial layer*, or the *superficial cervical fascia*, covers the whole anterior and lateral regions of the neck, is prolonged downward in front of the clavicle, to become continuous with the proper aponeurosis of the pectoralis major, is attached above to the masseteric and parotid fasciæ, and, internally to the masseter muscle, is fixed to the base of the lower jaw.

It fills up the interval between the two platysmata, and is prolonged behind these muscles to form the anterior layer of the sheath of the sterno-mastoid. The external jugular vein is superficial to this layer in the sub-hyoid, and lies beneath it in the supra-hyoid region.

2. The *deep layer* passes beneath the sterno-mastoid, on the outer border of which it unites with the preceding layer, and completes the sheath for that muscle. It covers the internal jugular vein, the common carotid artery, the pneumogastric nerve, the great sympathetic, and its cervical ganglia. Its upper margin is attached to the base of the lower jaw; its lower margin to the posterior surface of the clavicle, and to the posterior edge of the fourchette of the sternum. It is necessary to examine this deep layer, both in the supra and sub hyoid region.

In the supra-hyoid region its middle portion is very strong, and occupies the triangular space between the anterior bellies of the digastric muscles; it is fixed by its lower margin to the os hyoides, and on each side to the tendon of the digastricus. The lateral portions of this aponeurosis pass beneath the sub-maxillary glands, and are attached to the rami of the lower jaw. Externally to these glands they join the parotid aponeuroses, and form a tolerably thick septum between the sub-maxillary and parotid glands of either side.

In the *sub-hyoid region* this deep layer is divided into three very distinct parts, a middle and two lateral. The middle is the stronger; it occupies the triangular space between the two omo-hyoid muscles, and becomes continuous with their median tendons: the muscles may, therefore, be regarded as the tensors of this facia. It binds down the muscles of the infra-hyoid region: its arrangement explains why abscesses situated in front of it discharge their contents through the skin, and not into the thorax, as those do that are subjacent to it. The lateral parts of the aponeurosis constitute the *supra-clavicular fascia*, a very strong layer, in which the superficial layer already described, and the two which yet remain to be noticed, all terminate. It occupies the whole triangular space between the trapezius and the sterno-mastoid, is continuous with the fibro-cellular sheath of the former muscle, and adheres below to the clavicle. The latter circumstance is of great importance in relation to surgical anatomy.

The superficial and deep layers which we have now described are common to both the supra and sub hyoid regions. In the sub-hyoid region there are *two other aponeurotic layers:* one, very thin, separating the superficial from the deep muscles, *i. e.*, the omo and sterno hyoidei from the sterno-thyroidei and thyro-hyoidei; the other, thicker, passing between the sterno-thyroidei and the trachea. The latter is the fourth layer, which Godman incorrectly describes as continuous with the pericardium.

The Prevertebral Aponeurosis.

This aponeurosis covers the muscles of the prevertebral region, viz., the longi colli, and the great and small anterior recti: it is prolonged on each side upon the scaleni, the levator anguli scapulæ, and the brachial plexus; and is attached to the upper border of the scapula, and to the outer half of the posterior border of the clavicle. It completely

separates the axilla from the neck, and is perforated by several vessels. It prevents large abscesses of the neck from opening into the axilla; and, in caries of the cervical vertebræ, it retains the pus poured out against it, so as to form abscesses by accumulation.

The Thoracic Aponeuroses.

The Intercostal Aponeurosis.

Independently of the semi-tendinous structure of the intercostal muscles, we find several fibrous layers in each intercostal space: one layer in front, continuous with the external intercostal muscle; another behind, continuous with the internal intercostal muscles; and, situated within these muscles, a third layer, which lines them and separates them from the pleura. The existence of this sub-serous aponeurosis accounts for the rare occurrence of the bursting of an external abscess of the chest into the cavity of the pleura; and, on the other hand, of the escape of collections in the pleura by external openings.

The Aponeurosis of the Serrati Postici.

In the dorsal region of the trunk, we find a very thin fibrous layer (sometimes called the vertebral aponeurosis), extending between the two serrati postici. It is of a quadrilateral form; its inner margin is attached to the summits of the dorsal spinous processes; its outer margin to the angles of the ribs, and its lower margin to the upper border of the serratus posticus inferior; it seldom terminates at the lower border of the serratus posticus superior, but generally passes beneath it, and becomes the investing aponeurosis of the splenius. The use of this aponeurosis is evidently to confine the posterior spinal or long muscles of the back.

The Abdominal Aponeuroses.

The parietes of the abdomen are partly muscular and partly aponeurotic: the muscular portions are situated at the sides of the abdomen. The aponeurotic portions occupy the anterior and posterior regions, and form the *anterior* and *posterior abdominal aponeuroses*. The extensibility, elasticity, and, above all, the contractility of the abdominal parietes, depend on the three intersecting muscular layers; while to the aponeuroses must be attributed their capability of resistance and want of extensibility.

The Anterior Abdominal Aponeurosis.

The anterior abdominal aponeurosis forms the greater part of the anterior wall of the abdomen. It consists, 1. Of a fibrous column, which is continuous with the osseous column of the sternum; and, 2. Of two perfectly corresponding halves, one right, the other left. These two halves are united in the *linea alba*, which may be regarded as their common origin.

The Linea Alba.

The linea alba (*i, figs.* 109, 110) is a tendinous raphé, extending from the ensiform cartilage to the symphysis pubis; it constitutes the anterior median line of the abdomen. In a theoretical point of view it may be regarded as a continuation of the sternum, which, in some animals, is prolonged as far as the pubes.*

Anatomists are not agreed as to the acceptation of the term linea alba. According to some, it is a mathematical line produced by the intersection of the aponeuroses of one side with those of the other: according to others—and this meaning appears to me preferable—it consists of the tendinous band comprised between the inner borders of the recti.

Thus defined, the breadth of the linea alba corresponds to the interval between these muscles, and, as they are directed somewhat obliquely upward and outward, it follows that the upper or supra-umbilical portion of the linea alba is broader than that portion which is below the umbilicus. This remarkable arrangement, by which the strength of the lower part of the abdomen is secured, affords an explanation of the uniform occurrence of herniæ through the linea alba above, not below, the umbilicus. It should also be observed that, during exertion, the viscera are chiefly forced against the lower part of the abdominal parietes, and also that the gravid uterus rests upon it.

The sub-umbilical portion of the linea alba forms a mere line, while the supra-umbilical is about a quarter of an inch in breadth. Its transverse dimensions are much increased in persons whose abdomen has been greatly distended. Thus, during and after pregnancy and certain dropsies, it in some cases acquires a considerable breadth, and does not return to its original size, even after the distension has ceased to exist. In a female who died a short time after delivery, I found the linea alba three inches across at the umbilicus, and fifteen lines in the narrowest part. In cases of this kind, the linea alba forms a sort of long pouch, which receives the intestines, and becomes very prominent during the contraction of the recti.

The linea alba presents several elliptical openings for the passage of nerves and ves-

* The analogy has even been carried so far, that the tendinous intersections of the recti have been compared to the ribs, for they seem to come off from the linea alba like abdominal ribs.

sels. In these foramina, round masses of fat are developed, which dilate them, and draw down the peritoneum into them, or are absorbed in consequence of emaciation, and thus open an easy way for the production of hernia of the linea alba. Of all these orifices, the most remarkable is the *umbilical ring*, which gives passage to the umbilical vessels in the fœtus, but becomes cicatrized after birth, at least in the majority of subjects.*

The situation of the umbilicus varies at different ages. The middle point of the length of the body is situated above the umbilicus before the sixth month of fœtal existence, and corresponds with it after that period. In the adult it is situated below the umbilicus. Its situation with regard to the abdomen varies in different individuals. Thus, the umbilical cicatrix, which is generally a little below the middle of the abdomen, is sometimes exactly in the middle. I have even seen it at the point of junction of the lower with the upper two thirds.

This cicatrix, moreover, is much stronger than the neighbouring parts. Thus, an umbilical hernia, which, in a new-born infant, always occupies the navel itself, in an adult is almost invariably situated a little above the umbilicus. Still it occasionally yields, either in cases of dropsy or of hernia; and I have records of several instances of hernia in the adult, that have occurred through the umbilical ring.

The linea alba is in relation, *in front*, with the skin, which adheres more closely to it than to the neighbouring parts, especially opposite the umbilicus. In the male, it is separated from the skin below by the suspensory ligament of the penis, which sometimes extends as far as the middle of the space between the pubes and the umbilicus: *behind*, it is in relation with the peritoneum, separated from it, however, by the remains of the urachus, and by the bladder itself, when that viscus is distended. It is, then, through the linea alba that the bladder is punctured in cases of retention of urine, and that the incision is made in the high operation of lithotomy. The peritoneum does not adhere more closely to the umbilicus than to the other parts of the abdomen, and therefore umbilical herniæ, like all others, are invariably provided with a proper sac.

The *upper extremity* of the linea alba is attached to the ensiform appendix, a flexible, elastic, cartilaginous body, constituting, as it were, a transitional structure between the sternum and the part we are now describing.

The *lower extremity* corresponds to the symphysis pubis.

If we examine the structure of the linea alba, we shall see that it is formed by the intersection of the layers of the anterior abdominal aponeuroses. One remarkable circumstance is, that the intersecting fibres do not stop at the median line, but pass from one side to the other; so that the tendinous fibres of the external oblique of the right side become the tendinous fibres of the internal oblique of the left; and, again, that the intersection occurs not only from side to side, but also from before backward. Below the umbilicus the point of intersection is elevated by some longitudinal fibres, constituting a small and very distinct cord, which appears to form a septum between the recti muscles; it increases in thickness as it proceeds downward from the umbilicus to the symphysis, and may be easily felt under the skin in emaciated individuals. We may add, that the fibres of the linea alba have no resemblance to the yellow elastic tissue; they are neither extensible nor elastic, at least in the human subject. Its uses entirely refer to its capability of offering resistance.

The pyramidales are its tensor muscles.

The Four Layers of the Anterior Abdominal Aponeurosis.

From each side of the linea alba (*a*, *fig.* 134, a diagram representing a horizontal section of the abdominal parietes) two fibrous layers proceed outward, one anteriorly, the other posteriorly, to the rectus muscle (*r*).

Fig. 134.

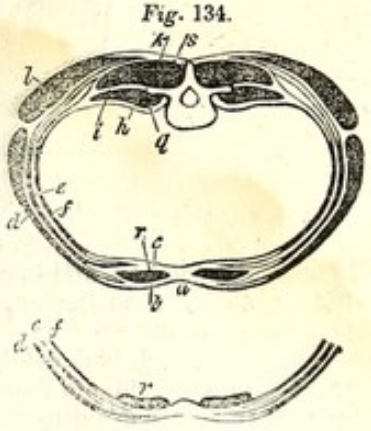

The anterior layer (*b*), having arrived near the outer border of the muscle, subdivides into two other layers: one *superficial*, constituting the aponeurosis of the external oblique (*d*); the other *deep*, forming the anterior layer of the aponeurosis of the internal oblique (*e*). The posterior layer (*c*) is also simple as far as the outer border of the rectus, and then separates likewise into two layers: one *anterior*, which becomes united with the aponeurosis of the internal oblique (*e*), and is regarded as the posterior layer of that aponeurosis; the other *posterior*, which continues its course outward from the rectus, and forms the aponeurosis of the transversalis muscle (*f*). We shall describe these different parts in succession.

The Aponeurosis of the External Oblique.—This is the most superficial layer, and is of a quadrilateral figure (*a*, *fig.* 109); it is broad below, where it corresponds to the in-

* Some cases are on record of the persistence of the umbilical vein, and, consequently, of the umbilical ring. I have narrated a case where a sub-cutaneous abdominal vein, prodigiously developed, became continuous with the vena cava, which was also very large.—(*Anat. Path.*, l. xvi., pl. 6.)

terval between the anterior superior spinous process of the ilium and the linea alba, becomes narrower immediately above, and again expands at the upper part, but to a less extent than below.

It is covered by the skin and the superficial fascia, and it covers the aponeurosis and the anterior portion of the fleshy fibres of the internal oblique. It adheres intimately to the aponeurosis of the internal oblique, as far as the vicinity of the outer border of the rectus, excepting below, where the two fasciæ are perfectly distinct, and can be easily separated throughout their entire extent.

Its *external margin*, slightly concave and denticulated, presents irregular prolongations, with which the fleshy fibres become continuous. A line extending from the anterior superior spinous process of the ilium to the extremity of the cartilage of the eighth rib, will indicate with tolerable accuracy the direction of this margin, which appears to be divided into two layers, one superficial, very thin, and continuous with the proper cellulo-fibrous sheath of the muscle; the other deep, and giving origin to fleshy fibres.

Its *upper margin* is narrow, and cannot be exactly defined; it often gives attachment to some fibres of the pectoralis major.

Its *lower margin* consists of two very distinct portions: one, extending from the anterior superior spinous process of the ilium to the spine of the os pubis, is called the *femoral arch* (*p p'*, *figs.* 136, 137); the other, stretching between the spine and the symphysis pubis, offers for consideration the pillars and the cutaneous orifice of the *inguinal canal* (*m*, *figs.* 109, 136, 137).

The aponeurosis of the external oblique is composed of tendinous fasciculi, directed obliquely downward and inward, like the fleshy fibres with which they are continuous. It is also perforated, especially in the neighbourhood of the linea alba, by a considerable number of bloodvessels and nerves. Not unfrequently the component fasciculi have between them, especially near the femoral arch, linear or triangular spaces of variable size, through which the fibres of the internal oblique are visible. The component fasciculi are also intersected at right angles, and, as it were, bound down by other tendinous fibres, which are more or less developed in different individuals, and are most usually situated in the neighbourhood of the femoral arch.

Having made these preliminary observations, we shall now describe in detail, 1. The lower margin of the aponeurosis of the external oblique, or the *femoral arch*; and, 2. The *inguinal ring* and *canal*.

The Femoral or Crural Arch.—When the aponeurosis of the external oblique has arrived opposite a line extending from the anterior superior spinous process of the ilium to the spine of the pubes, it suddenly terminates, becomes thickened, and is reflected (*a a'*, *fig.* 137) from before backward upon itself. The reflected border (*p p'*, *figs.* 136, 137) has been variously denominated the *femoral* or *crural arch*, the *reflected margin of the tendon of the external oblique*, *Poupart's ligament*, and the *ligament of Fallopius*. This arch, which is stretched like a cord, corresponds to the fold of the groin, and defines the limits of the abdomen and the lower extremity: it forms the anterior border of a considerable triangular space, which is completed by the ilium (1, *fig.* 136) on the outside, and by the os pubis (2) behind. This space establishes a communication between the lower extremity and the abdomen, and is occupied (proceeding from without inward) by the psoas and iliacus muscle (*i* to *i*), the crural nerve (*n*), the femoral artery (*a*) and vein (*v*), and the pectineus muscle.*

Fig. 136.

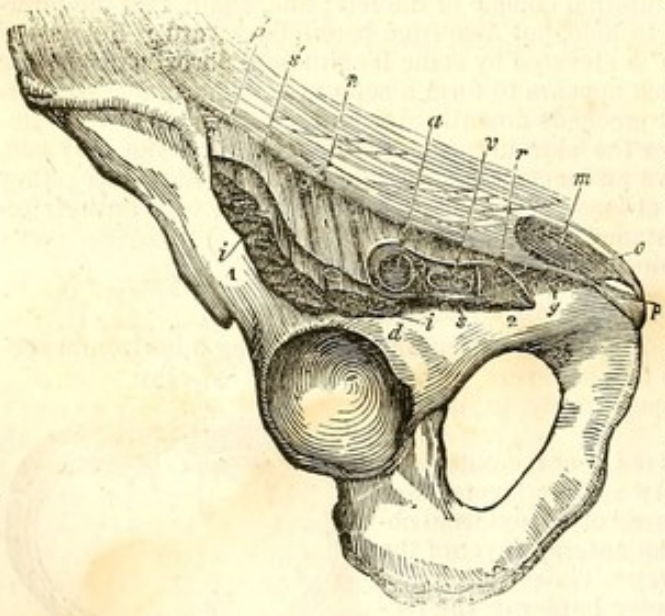

The crural arch is *directed* somewhat obliquely downward and inward; and as its outer third is more oblique than the inner two thirds, it describes externally a slight curve, having its concavity directed upward. Its *lower* or *reflected* border is continuous with the fascia of the thigh. This adhesion occasions the tension of the arch, as may be shown by cutting the femoral fascia at the point of its junction with the arch: hence the precept of Scarpa, who recommended incisions to be made in this situation, in order to relieve the constriction in femoral herniæ.

The free margin of the reflected portion of the aponeurosis, of which the femoral arch

* This is not represented in the woodcut.

consists, is continued backward into the iliac fascia (*s'*) externally; and internally, into the fascia transversalis (*t*).

Externally near the psoas and iliacus (beyond *a'*, *fig.* 137), the posterior or reflected portion of the arch is closely blended with its anterior or direct portion, as well as with the iliac fascia and the fascia of the thigh, so that, in this situation, there is a thickening rather than an actual reflection of the aponeurosis. Internally to the psoas and iliacus, however (at *a*), the direct and reflected portions are perfectly distinct, and form a groove with its concavity upward, which we shall find to assist in the formation of the inguinal canal. These two separate portions of the inner part of the femoral arch require a special description.

The *direct portion* (part of which is shown turned downward at *d*, *fig.* 137) passes on to be attached to the spine of the pubes (*p*, *figs.* 136, 137), becoming more and more prominent, so that it can be easily felt under the skin, especially when the thigh is extended upon the pelvis. The *reflected portion*, externally, is narrow, and, as it were, folded; but internally it becomes expanded, from its fibres slightly changing their direction, and diverging, so as to be inserted into the spine of the pubes behind the direct portion, and also into the pecten or crest of the pubes.

This reflected and expanded portion, described even in the oldest anatomical works, has become celebrated in recent times under the improper name of *Gimbernat's ligament* (*g*, *fig.* 136), from a Spanish surgeon, who pointed out its importance as the seat of stricture in femoral hernia. It is triangular in shape; its anterior margin corresponds to the crural arch; its posterior margin to the crest of the pubes; its outer margin is free, concave, tense, and sharp, and forms the inner part of the circumference of the crural ring (*r*). This concavity, against which the protruded intestine becomes strangulated, has obtained for the ligament the name of the *falciform ligament* or *fold*.* Its strength is very considerable; but, occasionally, intervals are left between its fibres, through which hernial protrusions may take place.†

From the lower surface of Gimbernat's ligament a fibrous prolongation is given off, which sometimes represents a second arch below the femoral arch, and assists in forming the superficial layer of the fascia lata of the thigh. This tendinous expansion has a great effect in rendering the arch tense. We may add, that there is considerable variation in different subjects, both in the strength and development of Gimbernat's ligament; varieties that must have great influence on the position of crural herniæ, and on the seat of strangulation in that disease. Behind the femoral arch, on the outer side of Gimbernat's ligament, is an opening (*a* to *r*, *fig.* 136) or ring, intended to give passage to the femoral artery (*a*) and vein (*v*), and to a great number of lymphatic vessels and glands: this is the *crural ring*.‡ The sub-peritoneal cellular tissue sometimes acquires great strength opposite this ring, and constitutes what is called the *crural septum* (situated at *r*). The form of the crural ring is that of an isosceles triangle, the base of which is very long, and formed by the crural arch, the inner border by the pectineus, and the outer by the psoas and iliacus muscles. Of the three angles, the internal is rounded, and corresponds to the concave margin of Gimbernat's ligament; the external angle, opposite which the epigastric artery is situated, is very acute, and corresponds to the point at which the femoral arch separates from the iliac fascia; the posterior angle is very obtuse, and corresponds to the ilio-pectineal eminence (*d*).

The femoral vein is in relation with the inner or pectineal border of this triangular space; the femoral artery with the ilio-pectineal eminence and the outer border. The crural nerve (*n*) lies behind and externally to the artery, being separated from it only by the iliac fascia (*s'*). Crural herniæ descend through the inner portion of the crural ring.◊

The femoral arch is formed by proper fibres, arising from the anterior superior spinous process of the ilium; and also by those fibres of the aponeurosis of the external oblique, which, after having arrived at the arch, change their direction, become reflected inward, and are collected together, so as to form a strong and tense cord.

The Inguinal Ring and Canal.—On the inner side of the spine of the os pubis, between the spine and the symphysis, the aponeurosis of the external oblique divides into two almost parallel, or at least very slightly diverging, bands, which leave between them an opening for the passage of the spermatic cord in the male, and of the round ligament in the female. This opening is the *inguinal ring* (*m*, *figs.* 109, 136, 137), and the bands which form its limits are called the *pillars* (*o p*, *figs.* 136, 137). The inguinal ring is oval or triangular; its greatest diameter has the same direction as the fibres of the external oblique, viz., obliquely downward and inward. Its base corresponds to the interval be-

* [This term is now generally applied (after Burns) to the external margin of the saphenous opening (*n*, *fig.* 137) in the fascia lata.]

† M. Laugier has lately recorded a case of hernia through the fibres of Gimbernat's ligament. I have since had an opportunity of seeing, in an old woman at the Salpêtrière, two hernial sacs near each other, one of which protruded through the crural ring, and the other internally to the ring; the necks of these sacs were separated by a fibrous band, which appeared to me to be formed by the external fibres of Gimbernat's ligament.

‡ [The term "crural ring," it must be remembered, is limited by British anatomists and surgeons to the small space (*r*), bounded internally by the free margin of Gimbernat's ligament, and externally by the femoral vein. It is through this space, and therefore through the internal portion only of the "crural ring" of M. Cruveilhier, that crural herniæ descend.]

◊ See note, *suprà*.

Fig. 137.

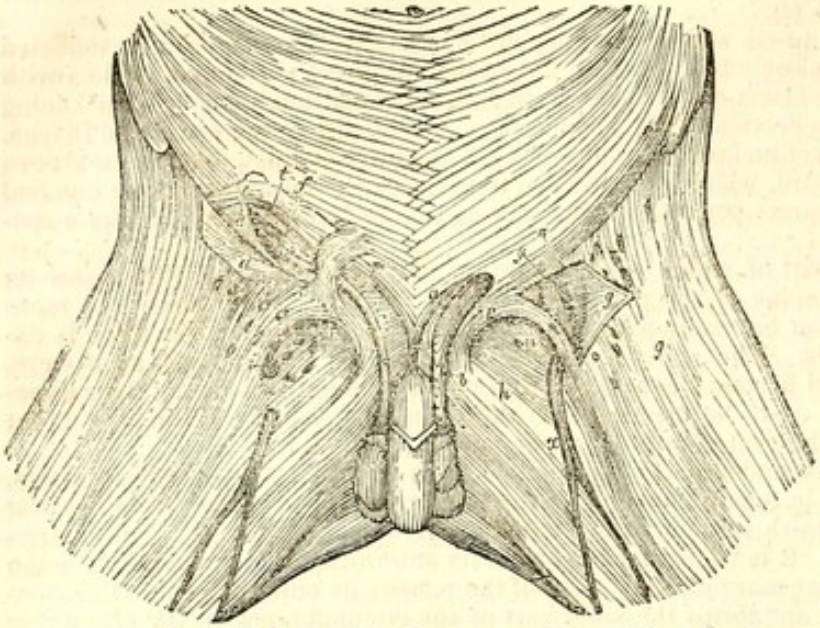

tween the spine and symphysis pubis. Its apex is not always well defined, and is generally truncated by fibres which pass at right angles to its pillars. From the upper part of the margin of the ring a tendinous prolongation is given off, which accompanies the spermatic cord in the male, and the round ligament in the female.

Of the pillars, one is *external* or *inferior*, the other *internal or superior*. The *external pillar* (*p*) is attached, not to the spine of the os pubis, but into the fore part of the symphysis: this pillar is nothing more than the internal extremity of the direct portion of the femoral arch. Moreover, some anatomists consider Gimbernat's ligament as the reflected portion of the external pillar. The *internal pillar* (*o*) is broader than the external, and intersects the corresponding structure of the opposite side in front of the symphysis, not unfrequently some fibres of the right internal pillar intersecting those of the left external pillar.

Inguinal Canal or Passage.—The inguinal *ring* (*m*) is the anterior or cutaneous orifice of an oblique passage, formed in the substance of the lower edge of the inferior parietes of the abdomen opposite the crural arch, and destined to transmit the cord (*s*) of the spermatic vessels in the male, and the round ligament of the uterus in the female. This passage, which modern writers only have correctly described, has been styled by them the inguinal *canal* (*t c m*). Its length varies from an inch and a half to two inches and a half; it is directed obliquely downward, forward, and inward.

The inguinal canal is formed, in reality, by the groove resulting from the reflection backward of the aponeurosis of the external oblique (at *a*), the posterior border of which groove is continuous with the fascia transversalis, and its anterior border with the aponeurosis of the external oblique itself. We may, then, consider this passage as having an *inferior concave wall* (at *a*) formed by the groove of reflection; an *anterior wall*, formed by the aponeurosis of the external oblique (shown turned downward at *d*); and a *posterior wall*, formed by the fascia transversalis (*c*). There is no *superior wall*, or, rather, it is supplied by the lower margins of the internal oblique (*e*) and transversalis (*f*) muscles, which occupy the groove of the crural arch, and receive from it externally numerous points of attachment. Internally the margins of these muscles are separated from the groove by the spermatic cord, or the round ligament. It has been supposed that this canal is lined by a funnel-shaped prolongation of the fascia transversalis. The *peritoneal* or *internal orifice* (*t*, *figs.* 110, 137) of the inguinal canal is much less accurately defined than the external, or, rather, its inner border alone is well defined, consisting of a concave fibrous edge formed by the fascia transversalis, and somewhat analogous to the concave edge of Gimbernat's ligament. The strangulation of the intestine in inguinal hernia sometimes occurs against this edge. The peritoneal orifice of the inguinal canal is closed by the peritoneum, and the epigastric artery runs along its inner border.

The testicle, which is originally situated within the abdomen, descends through the inguinal canal; so, also, do those herniæ, commonly called oblique inguinal herniæ, in order to distinguish them from the direct or internal inguinal herniæ.

The Anterior Aponeurosis of the Obliquus Internus and Transversalis.—The *aponeurosis of the internal oblique* commences at the linea alba, and immediately divides in its upper three fourths into two layers, one of which passes in front, and the other behind the rectus (*r*, *fig.* 134). The lower fourth passes entirely in front of the same muscle without division (as shown in *fig.* 135). The *anterior layer* is very closely united with the aponeurosis of the external oblique (at *b*), from which it can be distinguished only by the direction of its fibres. In some parts there is even a true interlacement between the tendinous fibres of these two muscles; the lower or undivided portion of the aponeurosis of the internal oblique may, on the contrary, be easily separated from that of the external oblique. The *posterior layer* of the aponeurosis of the internal oblique is no less intimately blended with that of the transversalis (at *c*), from which, also, it is to be distinguished by the direction of its fibres only. At the outer border of the rectus muscle the anterior layer of the apo-

neurosis of the internal oblique separates from that of the external oblique, and the posterior layer from that of the transversalis, and then immediately unite together, and give origin to the fleshy fibres. The outer margin, therefore, of the aponeurosis of the internal oblique exactly corresponds to the outer border of the rectus, and is directed vertically.

The *aponeurosis of the transversalis* (*f*, *figs.* 134, 135) is the deepest layer of the anterior abdominal aponeurosis: it is very narrow above, increases in breadth as far down as opposite the crest of the ilium, and then progressively diminishes towards its lower portion. It commences at the linea alba, and is divided into two portions: one inferior (below *s*, *fig.* 110), consisting only of the lower fourth of the aponeuroses, and passing in front of the rectus (as in *fig.* 135); the other superior (above *s*, *fig.* 110), which passes behind the rectus (as in *fig.* 134), and is formed by the upper three fourths of the aponeurosis. Its external margin is convex, and gives origin to the fleshy fibres of the muscle. Its anterior surface is closely united to the aponeurosis of the internal oblique, beyond which it passes on the outside: its posterior surface is loosely connected with the peritoneum, excepting in its lower fourth, which, as already stated, passes in front of the rectus muscle. The tendinous fibres of the transversalis, which have the same direction as its fleshy fibres, are occasionally found not to terminate abruptly behind the lower part of the rectus; but the aponeurosis merely becomes thinner, and its fasciculi separated from each other.

The Fascia Transversalis and Sub-peritoneal Aponeurosis.

In order to complete the description of the anterior abdominal aponeurosis, it only remains for me to describe the *fascia transversalis*, which I regard as a thickened portion of the *sub-peritoneal fascia*.

The *fascia transversalis* (seen at *a'* and *c*, *fig.* 137) was first pointed out by Sir Astley Cooper, but has been more correctly described by Lawrence and J. Cloquet: it commences below at the reflected border (*a a'*) of the crural arch, so that it may be regarded as a thin prolongation of the reflected portion of the tendon of the external oblique. It also frequently arises from the brim of the pelvis, as well as from the crural arch. From these points it passes upward, becoming more and more attenuated as it approaches the umbilicus, at which point it cannot be distinguished from the sub-peritoneal aponeurosis.

The fascia transversalis is situated between the abdominal muscles and the peritoneum. Its internal margin is continuous with the outer border of the rectus muscle; and its external margin, which gradually becomes thinner, is blended with the sub-peritoneal aponeurosis. The only part deserving a special description is that portion which lies between the outer border of the rectus muscle and the abdominal opening of the inguinal canal. In this situation it assists in strengthening the parietes of the abdomen, which are here remarkably weak; and it is to the existence of this fascia that we may attribute the extreme rarity of direct inguinal herniæ*, which, in fact, can only result from a congenital weakness, or a relaxation of this fascia.

A very interesting portion of the fascia transversalis is an infundibuliform prolongation, given off from it to the spermatic cord. It is impossible, indeed, to conceive the descent of the testicle to occur without its pushing before it a portion of the fascia, which then constitutes the immediate investment of the cord upon which the cremaster muscle (*b*, *fig.* 137) is spread out. The peritoneal orifice of the inguinal canal is, therefore, the superior opening of the infundibuliform process, furnished by the fascia transversalis to the testicle and its cord.

The Sub-peritoneal Aponeurosis.

The peritoneum, throughout the whole extent of the abdominal parietes, is strengthened on its outer surface by a very thin tendinous layer, the existence of which may serve to explain why abscesses, formed in the parietes of the abdomen, so seldom open into the cavity of the peritoneum; and, on the other hand, why collections within the peritoneal cavity so seldom open externally.

The Posterior Abdominal Aponeurosis.

The *posterior abdominal aponeurosis* is much smaller and of less importance than the anterior: it consists of three layers, one *anterior* (*h*, in diagram, *fig.* 134), and very thin, which commences at the base of the transverse processes of the lumbar vertebræ, and passes in front of the quadratus lumborum (*q*); another, *middle* (*i*), and much stronger, commencing at the summits of the same transverse processes, and passing behind the quadratus lumborum; and a third, *posterior* (*k*), which arises from the summits of the lumbar spinous processes, and passes behind the sacro-lumbalis, longissimus dorsi, and transverso-spinalis muscles (*s*). This last-mentioned layer is connected both with the internal oblique (*e*) and with the transversalis muscle (*f*), and is blended with the aponeuroses of the serratus posticus inferior, and of the latissimus dorsi (*l*). The two an-

* [*I. e.*, herniæ occurring *directly* downward and forward through the inguinal *ring* (*m*, *fig.* 137), and not descending along the inguinal *canal*.]

terior layers are connected with the transversalis only. The posterior abdominal aponeurosis has, therefore, nearly the same relation to the quadratus lumborum and the common mass of the sacro-lumbalis, longissimus dorsi, and transverso-spinalis muscles, that the anterior aponeurosis has to the rectus muscle.

The Lumbo-iliac Aponeurosis.

The *lumbo-iliac aponeurosis*, or *fascia iliaca* of modern authors, forms the tendinous sheaths of the abdominal portion of the psoas and iliacus muscles, and is, therefore, bifurcated at its upper part. That portion which invests the psoas commences at the tendinous arch of the diaphragm, already described as embracing the upper end of this muscle. The iliac portion arises from the whole extent of the inner border of the crest of the ilium. The circumflex ilii artery is situated in the substance of this iliac portion, at its origin. The internal margin of the fascia iliaca is attached to the sides of the lumbar vertebræ, and, lower down, to the brim of the pelvis; it is arranged in arches, which give passage to the lumbar vessels and to the nervous cords, establishing a communication between the lumbar plexus and the lumbar ganglia of the sympathetic nerve. The centre of each arch is opposite to the groove on one of the bodies of the lumbar vertebræ, the intervals between the arches corresponding with the intervertebral substance. The largest arch extends from the last lumbar vertebra to the brim of the pelvis, and is opposite to the base of the sacrum. The obturator and lumbo-sacral nerves pass under it.

Opposite the femoral arch, the fascia iliaca adheres intimately to the *outer* part of Poupart's ligament; but towards the median line it separates from that ligament, passes behind the femoral vessels, and forms the posterior half (*s*, *fig.* 136) of the crural ring.

Below the femoral arch, the fascia is prolonged upon the thigh; on the outside (*s'*) it completes the sheath of the psoas and iliacus, accompanies them as far as the lesser trochanter, and becomes continuous with the iliac portion (*g*, *fig.* 137) of the femoral fascia; on the inside, it forms the posterior wall (*s*, *fig.* 136) of the canal for the femoral vessels, and forms the deep layer or pubic portion (*h*, *fig.* 137) of the femoral fascia.

Relations.—It lies beneath the peritoneum, to which it is united by a very loose cellular tissue; it covers the psoas and iliacus, but is not adherent to them, in consequence of the interposition of some equally delicate cellular tissue. All the nerves from the lumbar plexus are subjacent to this fascia, excepting one very small cord, which perforates it at the side of the sacrum, and becomes situated in the sub-peritoneal cellular tissue. The femoral vessels are situated on the inner side of the fascia, and are separated by it from the crural nerve, which lies on its outer side, and underneath it.

Structure.—The upper part of the fascia is extremely thin, but it increases in thickness as it approaches the femoral arch. It is formed of well-marked transverse fasciculi, intersected perpendicularly by the tendon of the psoas parvus, when that muscle exists. This tendon is blended with the fascia, and is distinguished from it only by the different direction of its fibres; it is inserted by spreading out, at the side of the pelvic brim, into a tendinous arch which lines this brim, and with which the psoas parvus and the iliac fascia are continuous above, and the pelvic fascia below.

Few aponeuroses are more deserving the attention of anatomists than this, on account of the practical consequences resulting from its arrangement. In fact, notwithstanding its tenuity, it forms a boundary between the sub-peritoneal and sub-aponeurotic cellular tissue, which is very rarely passed by inflammatory action. When inflammation terminates in suppuration, the pus, whether it be beneath the peritoneum or beneath this fascia, descends towards the femoral arch; but if the inflammation be sub-peritoneal, the femoral vessels lie behind the purulent collection; and should it be sub-aponeurotic, the vessels will be in front of it. The latter is especially the case in abscesses following caries of the vertebræ.

The Aponeuroses of the Pelvis.

The *aponeuroses of the pelvis* should be distinguished into the *pelvic*, properly so called, and the *perineal:* the former constitute essential parts of the pelvis, and are deeply seated. The others belong to that part of the floor of the pelvis which is called the perineum. I shall commence with the description of the latter.

The Aponeuroses of the Perineum.

These are two in number; one *superficial*, the other *deep*.

*The Superficial Perineal Fascia.**

Dissection.—Remove tne sub-cutaneous adipose tissue very cautiously, layer by layer, commencing the dissection along the edges of the pubic arch.

This aponeurosis (which is very distinct from the fibrous laminæ, intercepting spaces filled by fat, and forming what is called the fascia superficialis) is of a triangular shape, and consists of well-marked transverse fibres. The *outer margin* of each half of the fascia is attached to the descending ramus of the os pubis and the ascending ramus of the ischium: its *inner margin* is lost at the raphé, along the median line: its *posterior mar-*

* M. Bouvier, in his thesis, and M. Blandin, in his *Traité d'Anatomie Chirurgicale*, first described this fascia

gin is bounded by a line extending from the tuberosity of the ischium to the anus; it corresponds with the posterior edge of the transversus perinei muscle, and appears to be reflected behind it, so as to line the corresponding perineal or ischio-rectal fossa.*

Relations.—It is covered by a prolongation of the dartos, to a greater extent in the median line than on each side; also by the sub-cutaneous adipose tissue, which is thicker behind than in front, and by the sphincter ani, above which it terminates in the median line: it covers the transversus, the bulbo-cavernosus, and the ischio-cavernosus muscles, the fibrous sheaths of which may even be regarded as a prolongation of this aponeurosis. It also covers the superficial perineal vessels and nerves, which are sometimes lodged within its substance. The existence of this membrane explains why, in cases of perforation of the urethra, the urine is infiltrated forward, and very rarely backward.

The Deep Perineal Aponeurosis.

Dissection.—Remove with great care the ischio- and bulbo-cavernosus and the transversus perinei muscles.

This aponeurosis, which was well described by M. Carcassone under the name of *perineal ligament*, and called by modern writers the middle perineal fascia, appears to me perfectly distinct from the aponeuroses of the pelvis. It is an extremely strong triangular layer (*b a*, *fig.* 138†), occupying the pubic arch, and apparently forming a continuation of the sub-pubic ligament (*b*). It is vertical near the arch, as far as the ball of the urethra, below which it becomes horizontal, or, rather, oblique, from before backward. Its *lateral margins* are attached to the descending rami of the ossa pubis, and the ascending rami of the ischia (*d d*), above the attachment of the ischio-cavernosi muscles. Its *posterior margin* becomes blended with the posterior margin of the superficial perineal fascia, behind the transversi muscles, in front of the perineal fossæ, of which it forms the anterior boundary.

Fig. 138.

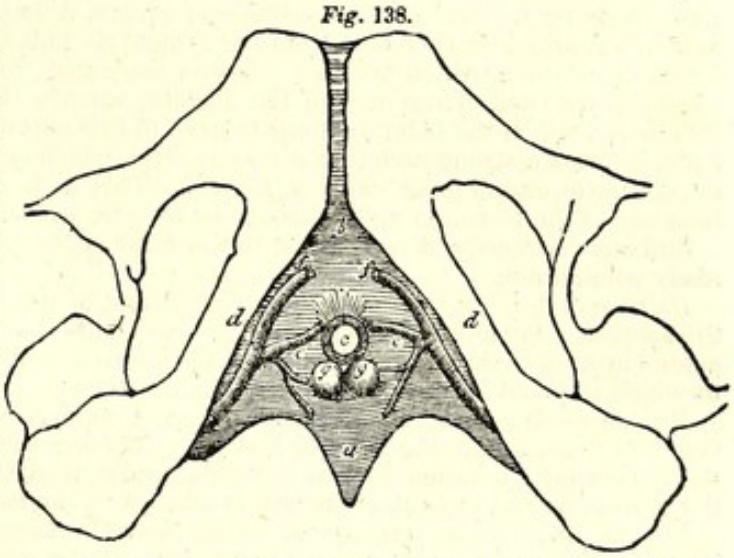

Relations.—Its lower surface is in relation with the ischio- and bulbo-cavernosus muscles, and gives off, in the median line, a fibrous septum, which passes between these muscles, and affords them points of attachment. Its upper surface is in relation with the artery or arteries (*e e*) of the bulb, which are sometimes contained within its substance: it is also in contact with a very remarkable plexus of large veins, with which it is very closely united, so that, when divided, they remain open: these veins are also frequently enclosed within its substance. It is also in relation with the levator ani.

There constantly exists another transverse muscle, very distinct from the transversus perinei generally described, which is situated farther behind. This muscle (transversus perinei alter, *Alb.*) is applied to the lower surface of the perineal fascia, and passes transversely inward to the bulbous portion of the urethra.

The deep fascia of the perineum is perforated (at *c*) by the posterior part of the bulb of the urethra, or, rather, by the point of union (*c*, *fig.* 181) between its bulbous and membranous portions: it gives off prolongations upon the sides of the bulb, and serves to support the membranous portion of the urethra: whence the name, *triangular ligament of the urethra*, given to it by Colles. It is also perforated, beneath the arch of the pubes, by a great number of veins, and by some arteries.

Uses.—This remarkable aponeurosis evidently supports the canal of the urethra. It has been correctly regarded as an obstacle to the introduction of the catheter, the point of which strikes against it, however slightly it may deviate from the direction of the canal. The prostate gland is situated above it.

The Pelvic Aponeuroses.

From the sides of the pelvis, and from the entire circumference of the brim (which, as

* See note, p. 309.

† [The triangular ligament consists of two layers, which approach each other more nearly above than below; in *fig* 138, the anterior layer has been removed. Between the two layers are situated the sub-pubic ligament (*b*), perforated by the venæ dorsales penis, the pudic arteries (*f f*), the arteries of the bulb (*e e*), the great part of the membranous portion of the urethra, with its compressor muscle, to be described hereafter, and lastly, Cowper's glands (*g g*). In the female, the triangular ligament is perforated by the vagina, as well by the urethra.]

we have seen, is covered and rendered smooth by a thick layer of fibrous tissue, that forms a limit to the lumbo-iliac aponeurosis), a tendinous lamina is given off, which passes into and lines the pelvis, and is soon divided into two distinct layers: one *external*, the *lateral pelvic* or *obturator fascia*, which continues to line the sides of the pelvis, and covers the obturator internus muscle; the other *internal*, or superior, which passes inward upon the side of the prostate gland, bladder, and rectum, in the male, and of the bladder, vagina, and rectum, in the female, in order to form the floor of the pelvis. This is the *superior pelvic aponeurosis*, with the description of which we shall commence.

The Superior Pelvic Aponeurosis, or Recto-vesical Fascia.

Dissection.—This aponeurosis must be studied both from the cavity of the pelvis and from the perineum. It is exposed in the pelvis by removing the peritoneum, and the loose cellular tissue beneath that membrane: this should be done without any cutting instrument. To view this fascia from the perineum, it is necessary to take away the adipose tissue that occupies the perineal fossæ, and also the levator ani muscle.

The *superior pelvic aponeurosis* forms a complete floor for the pelvis. Anteriorly it is remarkable for its strength and shortness; in fact, it does not reach the inlet in this situation, but arises on each side from the symphysis pubis, presenting the appearance of bands or columns, which are more or less separated from each other, and become attached to the front of the neck of the bladder, whence the name of *anterior ligament of the bladder*, which the older anatomists gave to this part of the aponeurosis. *More externally*, it forms a strong arch (the *sub-pubic arch*), which completes the posterior orifice of the obturator or sub-pubic canal (*i*, *fig.* 48). This arch is not unfrequently double, and then one of the foramina gives passage to vessels, and the other to nerves.

Still *more externally*, it is attached to the brim of the pelvis, in the manner I have already pointed out.

Posteriorly it is extremely thin, passes in front of the sciatic plexus, and is lost upon the sacrum. Sometimes it appears to be divided into two laminæ, the posterior of which passes in front of the sciatic plexus, and the anterior in front of the internal iliac vessels, to which it would seem to furnish sheaths.

Relations.—Its *upper* surface is concave, and connected with the peritoneum by loose cellular tissue, containing more or less fat. Its *lower* surface is convex, and covered by the levator ani: it forms part of the great perineal excavation, and is in relation with the pyriformis and obturator internus mucles, with the sacral plexus, &c.

This aponeurosis is perforated by a great number of openings: in the male it is pierced by the prostate (*i*, *fig.* 181) and the bladder (*h*), on the sides of which it is prolonged, and reflected on to the rectum, whence the name of the *recto-vesical aponeurosis*, given to it by M. Carcassone. In the female it is also perforated by the vagina. On each side of the bladder and prostate it is strengthened by two tendinous bands, which run from before backward. These are sometimes very strong; they extend from the symphysis pubis (*b*) to the spine of the ischium (*e*), pass along the bladder and the prostate, and are reflected upon their sides.

In front, it has some openings for the vesical and prostatic vessels.

Behind it presents a considerable opening, which corresponds to the outlet of the pelvis, and gives passage to the lumbo-sacral nerve and the gluteal vessels. The extremity of the arch formed by it corresponds to the anterior border of the sciatic notch. It is through this opening that sciatic herniæ protrude.

We not uncommonly find larger or smaller openings in this fascia, of an oblong or circular shape, leading into conical culs-de-sac, which are filled with fat. Lastly, it is perforated behind by the ischiatic and internal pudic vessels. It does not appear to be intended for the passage of the vessels which are distributed in the interior of the pelvis, for it seems to invest these in fibrous sheaths.

Uses.—The superior pelvic aponeurosis forms the floor of the pelvis; it is pushed downward by the action of the diaphragm and abdominal muscles, and tends to prevent the occurrence of perineal herniæ, which otherwise would be extremely common: it forms a boundary between the sub-peritoneal and the perineal cellular tissue, and also limits the progress of inflammation and infiltrations. Infiltration of urine above the fascia can only be caused by rupture of the bladder itself. The prostate (*i*, *fig.* 181) is almost entirely below the fascia, and therefore, in the lateral operation for stone, in which this gland is the principal structure to be divided, inflammation and infiltration of the cellular tissue are extremely rare. When they do occur, the section or laceration must have been prolonged into the body of the bladder.

The Lateral Pelvic Aponeurosis, or Fascia of the Obturator Muscle.

Dissection.—This aponeurosis is more advantageously studied, at least in its most important part, from the perineum, than from the cavity of the pelvis: it is exposed on either side by removing the adipose tissue, which fills up the perineal fossa. This aponeurosis, which is quite distinct from the obturator ligament, commences at the upper part of the circumference of the obturator foramen, and at the brim of the pelvis, in connexion with

the superior pelvic aponeurosis, which it soon leaves, and is applied to the obturator internus muscle: it then unites below with the reflected portion of the great sacro-sciatic ligament, and is prolonged upon that portion of the anterior surface of the glutæus maximus which projects beyond the ligament, and also upon the coccygeus muscle.

Relations.—On the inner side and above, it is only separated from the superior pelvic aponeurosis by the levator ani, which is applied to that aponeurosis; lower down, the two aponeuroses are separated by a considerable interval, which is occupied by fat: this interval forms the *perineal fossa*. On the outside it is in contact with the obturator internus, and lower down with the internal pudic vessels and nerves.

Uses.—It binds down the obturator internus muscle, and protects the internal pudic vessels and nerves, which are, therefore, rarely cut in operations in the perineum. It forms the external boundary of the perineal fossa.

The Perineal Fossæ.—Situated between the superior pelvic aponeurosis (which is lined below by the levator ani) and the lateral pelvic aponeurosis, there is found on each side of the anus a conical space, the base of which is directed downward, and corresponds to the skin: it is formed behind by the lower border of the glutæus maximus; in front, by the transversus perinei muscle; on the inside, by the levator ani and the superior pelvic aponeurosis; and on the outside, by the tuberosity of the ischium.* Each of these fossæ is filled by a large quantity of fat, and traversed by fibrous laminæ, some of which extend vertically from the apex to the base, and divide the contained adipose cellular tissue into several distinct portions. When an abscess occurs in either of these fossæ, it may be easily conceived how difficult it is for the inner surface of its parietes to come into opposition: hence the pathology of fistulæ, and the modes of cure which are adopted.

The Aponeuroses of the Lower Extremity.

The aponeuroses of the lower extremity comprise the *femoral fascia*; the *fascia of the leg*; the *annular ligaments*, which bind down the tendons of the muscles of the leg, as they are passing upon the dorsal or plantar surface of the foot; *the plantar* and *dorsal fasciæ* of the foot; and, lastly, the fibrous *sheaths*, which maintain the tendons in contact with the phalanges of the toes. We shall describe these in succession.

The Femoral Aponeurosis, or Fascia Lata.

After the remarks which we have already made upon the aponeuroses generally, it may be easily conceived that the muscles of the thigh, which are so numerous, of such great length, and so loosely united together, and almost all of which are reflected to a greater or less amount over the knee, require to be kept in close contact with each other and with the bones; hence the necessity for the *femoral aponeurosis*, consisting of a large fibrous sheath, that confines without compressing the muscles, and the strength of which is directly proportioned to the force of the muscles, and their tendency to displacement. Its superficial or sub-cutaneous surface (*g h*, *fig.* 137) is separated from the skin by a very thin fibrous layer, the *fascia superficialis* (not shown in *fig.* 137), which can be more easily demonstrated immediately below the femoral arch, and along the saphenous vein. Between the femoral aponeurosis or fascia lata and this superficial fascia, which results from the union of the fibrous prolongations given off by the deep surface of the skin, the sub-cutaneous vessels and nerves take their course, and communicate with the deep vessels and nerves, either by simple openings or by fibrous canals, of variable length. Under this fascia, also, are situated the superficial lymphatic vessels and glands of the groin.

A great number of the superficial nerves of the thigh have special sheaths, which are hollowed out, as it were, in the substance of this aponeurosis.

The femoral aponeurosis is perforated with a great number of foramina opposite the femoral vessels, from Poupart's ligament to the entrance of the vena saphena (*x*) into the femoral vein (*y*). These foramina, which occupy a triangular space, of which the base is above and the apex below, are intended for the passage of a great number of lymphatic vessels, which pass through it to join the deep set. This has been called the *sieve-like portion* of the fascia lata, or the *fascia cribriformis* (*v*): it has been said by some, that the aponeurosis is altogether wanting in this situation.† We not unfrequently find a lymphatic gland occupying one of the foramina.

* [These spaces are the *ischio-rectal fossæ* of Velpeau; they are described by him as if lined by an aponeurosis (the ischio-rectal) composed of two layers, one external or ischiatic, corresponding to the *lateral* pelvic aponeurosis of M. Cruveilhier, and another internal or rectal, which covers the lower surface of the levator ani from the coccyx to the posterior border of the transversus perinei, and unites with the other layer before, above, and behind. This latter layer is very thin, and continuous with the united margins of the superficial perineal fascia and the triangular ligament, behind the transverse muscle, and is alluded to by M. Cruveilhier (p. 307) as a reflection of the superficial fascia.]

† [And *then* the cribriform fascia is regarded, not as belonging to the fascia lata, but as formed by a *deep* layer of the superficial fascia, situated *beneath* the sub-cutaneous vessels, adherent to the borders of the saphenous opening in the fascia lata, and perforated by those vessels. The saphenous opening is, according to this view, not the foramen (*i*) through which that vein passes, but the aperture (*n*) left between the iliac (*g*) and pubic (*h*) portions of the fascia lata, and is bounded externally by the crescentic margin of the iliac portion, or the falciform process of Burns (see the left side of *fig.* 137, where the cribriform fascia has been entirely removed).]

The most remarkable of all these openings is undoubtedly that (*i*) for the vena saphena interna, where that vessel enters the femoral vein, at the upper part of the thigh, eight or ten lines below Poupart's ligament. The margin of this opening, which has been improperly called the *inferior orifice of the crural canal*, can only be demonstrated in its lower half, on account of the almost complete absence of the aponeurosis above it: this is the reason of the semilunar form of the portion of the fascia over which the vein passes.

The *deep surface* of the fascia lata gives off a great number of prolongations, which pass between the muscles, and form their proper investments or sheaths.

The largest of these prolongations form two lateral septa, called the *inter-muscular septa*, which extend from the fascia to the linea aspera; each has the form of a triangle, having its base directed downward and its apex upward; they are extremely thick, especially below.

The Inter-muscular Septa of the Femoral Aponeurosis.

Of these there are two, one *internal* and the other *external*.

The Internal Inter-muscular Septum.—This serves at once as a septum, an aponeurosis of insertion, and a sheath for the vastus internus: it extends from the anterior intertrochanteric line to the inner condyle of the femur.

Its anterior surface affords attachments to the vastus internus throughout its whole extent: its posterior surface is in opposition with the adductors, and is intimately united to their aponeuroses. Its outer margin is attached to the linea aspera: its inner margin is very thick, and prominent below, where it is strengthened by the inferior tendon of the adductor magnus, and may be felt under the skin like a cord. It appears to become continuous below with the internal lateral ligament of the knee.

It is composed of very strong vertical fasciculi, passing somewhat obliquely downward and inward. These fasciculi are bound together above the inner condyle by others passing transversely, and are crossed almost at right angles by the tendinous fibres of the adductors.

Lastly, the internal septum is perforated, near the linea aspera, by a number of orifices destined for the passage of vessels, and forming communications between the anterior and the internal sheath of the muscles of the thigh.

The External Inter-muscular Septum.—This serves as a septum, an aponeurosis of insertion, and as a sheath for the vastus externus.

It extends from the great trochanter to the external condyle, above which it forms a projecting cord: it affords attachments to the vastus externus in front, and to the short head of the biceps behind. Its inner margin is attached to the linea aspera: its outer margin forms a prominent cord, especially below.

It consists of fibres directed vertically, or somewhat obliquely outward, and strengthened by transverse fibres above the condyle. Like the internal septum, it is perforated, especially above and below: above, for the passage of the circumflex vessels; below, for the passage of the articular vessels of the knee.

We shall now examine the different sheaths furnished by the femoral aponeurosis. One of the most important of these is, as it were, hollowed out of the sides of the others, and belongs to the femoral vessels.

The Sheath of the Femoral Vessels.

The femoral artery (*z*, *fig.* 137) and vein (*y*) are enclosed in a prismatic and triangular tendinous canal, which protects them in their course amid the muscles of the thigh. The portion of the canal (laid open in *fig.* 137) included between the femoral arch and the point where the vena saphena opens into the femoral vein, has received the name of the *crural canal*, a term to which I have always objected, since it was first introduced into anatomical nomenclature, because it establishes a false analogy between the inguinal canal and this upper portion of the sheath of the femoral vessels; for, while an oblique inguinal hernia traverses the entire length of the inguinal canal, crural herniæ, as far, at least, as my own observation extends, never protrude through the saphenous opening, but escape immediately below the femoral arch, and lift up the cribriform portion of the fascia lata.*

The *anterior wall* of the sheath of the femoral vessels is formed above by the cribriform portion of the femoral fascia (*g'*, *fig.* 137), then by the fascia itself, and, lastly, by the posterior layer of the sheath of the sartorius, in which place it is thin and transparent.

The *internal wall* is formed above by the very strong layer covering the pectineus; below, by the weaker layer investing the adductors.

The *external wall* consists of the very strong sheath (*s'*, *fig.* 136) of the psoas and iliacus: externally to this wall is situated the crural nerve, a branch of which perforates

* [The term "crural ring" is, in this country, commonly limited to the space (*r*, *fig.* 136) situated internally to the femoral vein. By the term "crural canal" is generally understood that portion only of the canal described by M. Cruveilhier as the "crural canal," which is situated on the *inner side* of the femoral vein, and is occupied by cellular tissue, lymphatic vessels, and sometimes by a lymphatic gland. If the term crural canal be thus defined, if the cribriform fascia be regarded as a part of the superficial fascia, and the saphenous aperture as the space between the iliac and pubic portions of the fascia lata (see note, p. 309), the analogy between the crural and inguinal canals will not be so very remote.]

the sheath and joins the vessels. Lower down, the external wall is formed by the aponeurosis of the vastus internus.

The three great Muscular Sheaths of the Femoral Aponeurosis.

By means of the internal and external inter-muscular septa, the muscles of the anterior region of the thigh are separated from those of the posterior and internal regions; a weaker septum than the preceding intervenes between the muscles of the internal and posterior regions. It follows, then, that the femoral aponeurosis presents three great tendinous sheaths: an *anterior*, an *internal*, and a *posterior*.

The *great posterior sheath* is undivided: it is common to the biceps, the semi-tendinosus, and the semi-membranosus.

The *great anterior and internal* sheaths are subdivided into a number of secondary sheaths, in most cases corresponding with the number of the muscles.

The great Anterior Sheath.—The sartorius has a proper sheath, remarkable for its prismatic and triangular form. The rectus femoris, or long head of the triceps, is separated from the two vasti by a tendinous layer, very thin below, but strong above, and composed of vertical fibres.

The tensor vaginæ femoris is contained in the strongest sheath in the human body, for it is formed by the fascia lata itself. The deep layer of this sheath is much thinner than the superficial; it commences at the anterior inferior spinous process of the ilium, below the rectus, and may be regarded as the deep origin of the broad band in which the tensor vaginæ femoris terminates: it is composed of vertical fibres, prolonged between the rectus and the vastus externus. Lastly, above and on the outside, we find the sheath of the psoas and iliacus (*s'*, *fig.* 136), which forms a continuation of the lumbo-iliac aponeurosis, or fascia iliaca.

The *great internal sheath* furnishes a number of tendinous lamellæ, which separate the different muscles of this region. Thus, there is a proper sheath for the gracilis, a common one for the pectineus and the adductor longus, one for the adductor brevis, and another for the adductor magnus. The sheath of the obturator externus is continuous with that of the adductor brevis; it commences by a very strong fibrous lamina or arch, which arises from the anterior edge of the pubes, and is directed obliquely outward to the fibrous capsule of the hip-joint. This arch conceals the anterior orifice of the obturator canal, and protects the obturator vessels and nerves.

Lastly, the two vasti, which extend into all the regions of the thigh, have sheaths formed by the femoral fascia, where they are superficial, and by the internal and external inter-muscular septa, and the posterior laminæ of the other sheaths in their more deeply-situated portions.

In the midst of the sheaths of the anterior and internal regions we find the sheath of the femoral vessels already described.

The Superior Circumference of the Femoral Aponeurosis.

In *front* the femoral aponeurosis arises from the femoral arch, with which it is so perfectly continuous as to render the arch tense: hence the plan, already mentioned as proposed by Scarpa, of endeavouring to remove the constriction in cases of strangulated crural hernia, by puncturing the femoral aponeurosis.

But the mode of origin and continuity of this fascia with the femoral arch is not the same on the inner and outer sides. On the *outside*, the *iliac portion* of the femoral aponeurosis (*g*, *fig.* 137) arises by a single very thick layer; more *internally*, in the situation of the femoral vessels, it arises by two layers, one *superficial*, thin, and perforated by foramina (the cribriform portion, *v*); the other deep, called its *pubic* portion (*h*), which is continuous with the fascia iliaca (*s*, *fig.* 136), covers the pectineus, and sends off a prolongation between that muscle and the psoas. This deep layer forms the posterior wall of the canal of the femoral vessels.

On the *inside* of the thigh, the femoral aponeurosis arises from the body of the os pubis and the ascending ramus of the ischium.

On the *outside and behind*, it arises from the crest of the ilium by very numerous vertical fibres, which are strengthened, especially behind, by other horizontal fibres. Between the posterior superior spine of the ilium and the crest of the sacrum there is a tendinous arch, which is common to the femoral fascia and the aponeurosis of the long muscles of the back.

The Glutæal Aponeurosis.

The glutæal aponeurosis forms the upper and back part of the femoral fascia. It covers the glutæus medius, in which situation it is extremely thick, and is continuous with the broad band of the tensor vaginæ femoris. Having reached the upper border of the glutæus maximus, it is divided into two layers: one superficial and very thin, which covers the outer surface of the glutæus maximus, becomes thinner below, and continuous with the femoral fascia; the other deep and thicker, especially above and behind, where it affords attachment to the glutæus maximus, and is blended with the great sacro-sciatic ligament. It becomes very thin where it separates the glutæus maximus

from the deep-seated muscles. A synovial capsule intervenes between this fascia and the great trochanter, and another between it and the tuberosity of the ischium.

It presents a very remarkable opening called the *glutæal arch*, for the passage of the glutæal vessels and nerves. Lastly, over that portion of the glutæus maximus which enters into the formation of the corresponding perineal fossa, it acquires a great degree of thickness, and, at the lower border of the muscle, is blended with the superficial layer of the glutæal fascia.

The Inferior Circumference of the Femoral Aponeurosis.

The femoral aponeurosis terminates below, around the knee-joint, where it becomes continuous, partly with the fascia of the leg, and partly with the fibrous structures covering this articulation. Concerning the arrangement of these fibrous laminæ we shall offer a few remarks.

Behind, the femoral aponeurosis passes over the popliteal space, and is continuous with the fascia of the leg.

In front, it is prolonged over the patella, from which it is separated by a synovial bursa; it is very thin, and is continued in front of the ligament of the patella, upon which it forms a thin layer of transverse fibres.

On the inside, it is at first blended with the sheath of the sartorius, and then with the horizontal portion of the tendon of this muscle; it crosses the fibres of that portion perpendicularly, and becomes continuous with the fascia of the leg.

Under this layer of fibrous tissue we find, on the inside of the knee, another very dense layer, formed by vertical tendinous fibres derived from the vastus internus, and inserted into the upper part of the inner surface of the tibia, beneath the tendon of the sartorius. This fibrous layer, which may be regarded as the lower or tibial insertion of the vastus externus, occupies the interval between the internal lateral ligament of the knee-joint and the patella. Its vertical fibres are crossed by others at right angles, extending from tne internal tuberosity of the femur to the corresponding margin of the patella.

Lastly, under this we find another very thin layer, belonging to the synovial capsule.

On the outside, the femoral aponeurosis is blended with the broad band of the tensor vaginæ femoris, from which it can be distinguished only by the horizontal direction of its fibres.

Beneath this very thick layer we find a thin one, composed of fibres stretching from the external tuberosity of the femur to the patella; and, lastly, another thin layer belonging to the synovial membrane.

Structure of the Femoral Aponeurosis.

It is thin behind and on the inside, thicker in front, and extremely thick on the outside of the thigh, where, indeed, it may be said to exceed all other fibrous membranes in thickness and in strength. This thickened portion is bounded in front by a line extending vertically downward from the anterior superior spinous process of the ilium. Its limits behind are no less distinctly defined; hence the name given to it of *the broad band* (*fascia lata*).

This great density is owing to some very strong vertical fibres, arising from the front of the crest of the ilium. It is connected with the great force and tendency to displacement of the vastus externus.

We may add, that the femoral aponeurosis is composed of horizontal fibres, sometimes regularly parallel, as in its thinnest portions, and sometimes intersecting each other. These horizontal fibres are even seen opposite the broad band on the outer side, from which they are distinguished by their direction.

There is a very beautiful preparation of this aponeurosis in the Museum of the Faculty of Medicine: similar preparations should be made by those who wish to obtain a good idea of the tendinous sheaths, and the shape of the muscles of the thigh. It is to be made by removing all the muscles from their sheaths by means of longitudinal incisions, and substituting for them a quantity of tow, which must be taken out when the aponeuroses are completely dried. The form of the sheaths exactly represents that of the corresponding muscles. A tolerably accurate idea of these sheaths may also be obtained by cutting across each sheath and the muscle which it contains, in a fresh subject. The circumference of the section of the portion of the sheath that becomes visible after the retraction of the muscle will give an excellent idea of the figure of the different sheaths, which are all angular and polyhedral like the muscles, but never rounded: during health they are completely filled by the muscles, which in emaciated persons, on the contrary, do not occupy more than a half, a third, or a sixth of the area of their sheaths.

Such is the femoral fascia. Its tensor muscles consist of the tensor vaginæ femoris and the glutæus maximus, the tendon of which is received between two layers of this fascia.

Aponeuroses of the Leg and Foot.

Aponeurosis of the Leg.

The *aponeurosis of the leg* forms a strong general investment for the whole leg, except-

ing the internal surface of the tibia, which is covered by it only at its lower part, a little above the malleoli.

Its *external surface* is separated from the skin by the superficial vessels and nerves, several of which perforate it, either directly, or after having run for a short distance in its substance. The external saphenous vein and nerve receive from it a complete sheath.

Its *internal surface* covers all the muscles of the leg, and does not adhere to them excepting above and in front, where it gives attachment to the tibialis anticus and the extensor communis digitorum. From the internal surface there proceeds on the outer side of the leg two principal tendinous septa, one situated between the muscles of the anterior tibial region and the peronei, the other between the peronei and the muscles of the posterior region of the leg. There are, therefore, three principal sheaths in the leg, an anterior, an internal, and a posterior. The latter is subdivided into two other sheaths by a very strong transverse lamina, becoming still stronger below, which separates the muscles of the deep posterior layer and the posterior tibial and peroneal vessels and nerves from the superficial layer of muscles, or the triceps suralis. Lastly, some tendinous laminæ, more or less complete, are interposed between the different muscles of each region. Thus, a tendinous layer separates the tibialis anticus, at first from the extensor communis digitorum, and then from the extensor proprius pollicis: this layer disappears in the middle of the leg. Another very strong tendinous lamina separates the tibialis posticus from the flexor longus digitorum on the one hand, and from the flexor longus pollicis on the other.

Superior Circumference.—If we now examine the manner in which the aponeurosis of the leg becomes continuous with that of the thigh, we shall find that, posteriorly, the femoral fascia is prolonged directly upon the leg, in order to form the posterior part of its aponeurosis, which, in this situation, also receives an expansion from the tendons of the biceps, sartorius, gracilis, and semi-tendinosus, and from the broad band of the fascia of the thigh. *Anteriorly* the fascia of the leg is continous with that of the thigh over the patella, and appears also to arise directly from the outer edge of the anterior tuberosity of the tibia, from the head of the fibula, and from the tendon of the biceps, which, as we have already seen, gives off an aponeurotic expansion backward.

By its *lower circumference* this fascia is continuous with the annular ligaments of the ankle, which we shall presently describe.

Structure.—On examining the direction of the fibres and the thickness of the fascia of the leg, it is found that it is much thicker in front than on the outer side of the leg, and still more so than behind; that, in the first situation, in the *upper* three fourths of its extent, it is composed of obliquely interlaced fibres, some of which descend from the spine of the tibia, and others from the anterior angular surface of the fibula; and that in the lower fourth of the anterior region of the leg, and in the whole extent of the posterior region, it is composed of circular fibres.

At the point where the muscles of the leg become tendinous, and are reflected over the ankle, they require very strong sheaths to keep them in contact with the joint; the fascia of the leg, therefore, forms, opposite this part, the *anterior*, *internal*, and *external annular ligaments*.

The Annular Ligaments of the Tarsus.

The annular ligaments of the tarsus are three in number: an *anterior* or *dorsal*, an *internal*, and an *external*.

The *dorsal annular ligament of the tarsus*. The aponeurosis of the leg is thicker at the lower and anterior part of the leg, and binds down the corresponding portion of the muscles in that region. But there is, in addition to this, a dorsal annular ligament of the tarsus (see *fig.* 128), which arises, by a narrow but thick extremity, in front of the astragalo-calcanean fossa, becomes broader as it extends inward, and is divided into two bands. The *superior* band passes upward and inward above the internal malleolus, and is split into two layers, in such a way as to form two complete sheaths: one internal, for the tibialis anticus; the other external, for the extensor longus digitorum and the peroneus tertius. Between these two complete sheaths, which are separated from the synovial capsule of the joint by a layer of cellular tissue, we find an incomplete sheath (for the annular ligament is not split into two layers in this situation), intended for the extensor proprius pollicis and the anterior tibial vessels and nerves: the internal sheath is the higher, and situated opposite the lower extremity of the tibia; the external sheath is lower, and corresponds to the ankle-joint. The *inferior band*, or the lower bifurcation of the annular ligament, passes forward and inward to the front of the tarsus, and becomes continuous with the internal plantar aponeurosis. This lower band forms a second annular ligament, which furnishes to each of the three preceding muscles, upon the dorsum of the foot, a less powerful sheath than that afforded by the upper band: it keeps the tendons closely applied to the bones.

The *external* and *internal annular ligaments* of the tarsus are two fibrous bands, continuous with the fascia of the leg on the one hand, and with the plantar aponeurosis on the other.

The *internal annular ligament* arises from the borders and summit of the internal malleolus, and proceeds in a radiating manner to the inner side of the os calcis, and the inner margin of the internal plantar aponeurosis. Beneath this sheath, which is thicker below than above, and closes in the concavity on the inner surface of the os calcis, proceed the posterior tibial vessels and nerves, and also the tendons of the tibialis posticus, the flexor longus digitorum, and the flexor longus pollicis. For these several parts there are four very distinct sheaths: the most superficial is that for the vessels and the nerves; two sheaths, placed one over the other (see *fig.* 130), and behind the internal malleolus, belong, the anterior to the tibialis posticus (*n*), and the posterior or more superficial to the flexor longus digitorum (*o*). These two sheaths soon separate as the two tendons diverge from each other towards their insertions: as the sheath of the tibialis posticus is continued as far as the insertion of that muscle, the sheath of the flexor longus digitorum accompanies it to where it gets beneath (*i. e.*, deeper from the surface than) the plantar fascia. The sheath of the flexor longus pollicis (*p*) is lower than the preceding, and extends obliquely along the astragalus and os calcis, to be covered by the internal plantar fascia.

The *external annular ligament* forms a common sheath for the two peronei, longus et brevis: it extends from the border of the external malleolus to the os calcis, and is completed on the inside by the external lateral ligaments. It is at first single, but soon becomes subdivided into two other sheaths, one of which is destined for the tendon of the peroneus brevis, and the other for that of the peroneus longus.

The Aponeuroses of the Foot.

These are divided into the *dorsal* and *plantar*.

The Dorsal Aponeuroses of the Foot.

These comprise the *dorsal aponeurosis*, properly so called, the *pedal aponeurosis* (*l'aponeurose pédieuse*), and the *dorsal interosseous apaneuroses*.

Dorsal Aponeurosis of the Foot.—While the upper margin of the annular ligament is blended with the fascia of the leg, which appears to be inserted upon it, the anterior margin of the same ligament becomes continuous with the dorsal aponeurosis of the foot. This dorsal aponeurosis is a thin layer, which forms a general sheath for all the tendons situated upon the dorsum of the foot: it gradually disappears in front, opposite the anterior extremities of the metatarsal bones, and is attached at the sides to the borders of the foot, becoming continuous with the plantar fascia. These tendons, again, are separated from the extensor brevis digitorum by another and still thinner layer, which invests that muscle: this is the *pedal aponeurosis*; lastly, upon the same surface of the foot we find the four *dorsal interosseous aponeuroses*, viz., one for each interosseous space.

The Plantar Aponeuroses.

The plantar aponeuroses or fasciæ are three in number: one *middle*, the other two *lateral*.

The *middle plantar aponeurosis* is very strong, is attached to the inner of the posterior tubercles of the calcaneum, becomes suddenly contracted, and afterward gradually expands without diminishing perceptibly in thickness. Opposite the anterior extremities of the metatarsal bones, it divides into four bands, which are themselves bifurcated almost immediately, so as to embrace the flexor tendons of the four outer toes. Becoming moulded on the sides of these tendons, they furnish those of each toe with an almost complete sheath, which is attached to the upper and lateral borders of the anterior glenoid ligament of the corresponding metatarso-phalangal articulation, and becomes continuous with the tendinous sheath of the corresponding toe. These four sheaths are separated by three arched openings, through which proceed the lumbricales and interosseous muscles, and the plantar vessels and nerves. There is a perfect analogy between the middle plantar and the middle palmar aponeurosis; but the former is by far the stronger. It constitutes, indeed, a true ligament for the foot, offers a powerful resistance to the forced extension of the phalanges upon the bones of the metatarsus, and supports the antero-posterior arch of the sole of the foot. I have known exceedingly violent pain to be produced by distension, and, probably, laceration of some of the fibres of this aponeurosis. The margins of the middle plantar aponeurosis are curved upward, so as to embrace the flexor brevis digitorum on each side; they become continuous with the external and internal plantar aponeuroses, and form septa between the muscles of the middle and those of the external and internal plantar regions: in front these septa are complete, but only partial behind. The upper surface of this fascia gives attachment, posteriorly, to the short flexor of the toes: the proper tendinous expansion of this muscle appears to be given off from the upper surface of the plantar aponeurosis.

Some transverse fibres strengthen this fascia in front, and I shall also notice some other transverse fibres, perfectly distinct from the preceding, which form a true transverse ligament for the four outer toes: it is situated opposite the middle of the lower surface of the first phalanges, and is admirably adapted for opposing their dislocation.

The External and Internal Plantar Aponeuroses.—The *external plantar aponeurosis*, very

thick behind and thin in front, gives attachment by its upper surface to the abductor muscle of the little toe, and is bifurcated at the posterior extremity of the fifth metatarsal bone. The external division of this bifurcation is very strong, is inserted into the enlarged posterior extremity of the fifth metatarsal bone, and may be regarded as a powerful medium of connexion between that bone and the cuboid. The *internal plantar aponeurosis* is thin in comparison with the external; it commences behind by an arch, extending from the inner malleolus to the os calcis; its inner margin is attached to the corresponding border of the tarsus, and is continuous with the dorsal annular ligament and with the dorsal fascia of the foot; its outer margin is blended with the middle plantar fascia, or, rather, is reflected upward, to complete the sheath for the internal muscles of the foot.

These three plantar fasciæ just described form three sheaths, which are quite distinct in their anterior five sixths, but communicate with each other behind.

The *internal plantar sheath* includes the abductor and the short flexor* of the great toe, which are separated from each other by a layer of fibrous tissue; it also contains the internal plantar artery and nerves.

The *external plantar sheath* includes the abductor and the flexor of the little toe, which are also separated by a tendinous layer. Lastly, the *middle* plantar sheath includes the short flexor of the toes, the tendon of the flexor longus digitorum, the flexor accessorius, the lumbricales, the tendon of the flexor longus pollicis, the oblique adductor,† the transversus pedis, and the external plantar vessels and nerves. The sheath of the flexor brevis digitorum is completed above by an aponeurotic layer, which separates it from the tendons of the long flexor and from the accessorius. A proper sheath exists for the oblique adductor,† and a subdivision of the same sheath for the transverse adductor. It is formed above by the interosseous aponeuroses, and below by a thin layer attached to the circumference of the deep hollow in which the adductors are lodged. Lastly, the *inferior interosseous aponeurosis* is remarkable for its thickness, and for the septa which it gives off between the interosseous muscles.

The sheaths into which the flexor tendons of the toes are received opposite the phalanges resemble so exactly those of the fingers, that I shall not anticipate what will be said hereafter regarding the latter. We find the same system of synovial membranes, and the same loose, membranous, and extensible cellular tissue for the flexor tendons of the toes as for those of the fingers. In all sheaths that are partly osseous and partly tendinous, we find a synovial membrane;‡ but, on the other hand, there is nothing more than a loose cellular tissue in situations where a tendon or muscle glides in the interior of a confining aponeurosis.

The Aponeuroses of the Upper Extremity.

These comprise the aponeuroses of the shoulder; the brachial aponeurosis; the aponeurosis of the forearm; the dorsal and anterior annular ligaments of the carpus; the palmar aponeurosis; and, lastly, the sheaths for the tendons of the flexor muscles of the fingers.

The Aponeuroses of the Shoulder.

These are the *supra-spinous*, the *infra-spinous*, the *sub-scapular*, and the *deltoid aponeuroses.*

The *supra-spinous aponeurosis* is a thick layer of fibrous tissue, attached to the entire circumference of the supra-spinous fossa, and converting it into a sort of osteo-fibrous case, that serves as a sheath for the supra-spinatus muscle, to which it also affords several points of attachment. This tendinous layer is gradually lost, externally, under the acromio-coracoid arch.

The *infra-spinous* aponeurosis is an equally dense and strong fibrous lamina, attached to the entire margin of the infra-spinous fossa, and completing the osteo-fibrous sheath of the infra-spinatus muscle: it is continuous on the outside with the brachial fascia, and gives off from its anterior surface a thick septum intervening between the scapular attachments of the teres major and those of the teres minor, and also some thinner septa interposed between the teres minor and the infra-spinatus, and between the different portions of the infra-spinatus muscle itself.

The *deltoid aponeurosis.* The infra-spinous aponeurosis having reached the posterior border of the deltoid muscle, splits into two layers: of these, the superficial layer invests the deltoid, and terminates in the brachial aponeurosis; the deep layer continues to cover the tendon of the infra-spinatus, and becomes attached to the tendon of the short head of the biceps. Some very loose cellular tissue, or even a synovial bursa, separates this aponeurosis from the head of the humerus, and the tendons inserted around it.

The *sub-scapular aponeurosis* is a very thin membrane, which completes the sheath of the sub-scapularis, and gives the muscle some points of attachment. It is fixed to the entire margin of the sub-scapular fossa.

* [*I. e.*, the inner half of the flexor brevis pollicis of anatomists generally.]

† [Including the outer portion of the flexor brevis pollicis of most anatomists.]

‡ See note on APONEUROLOGY, p. 296.

The Brachial Aponeurosis.

The *brachial aponeurosis* commences above at the clavicle, the acromion, and the spine of the scapula, and is continuous with the infra-spinous aponeurosis: on the inner side it arises from the tendons of the pectoralis major and the latissimus dorsi; and, in the interval between them, from the cellular tissue of the axilla; it envelops the arm as far down as the elbow, where it becomes continuous with the fascia of the forearm, and is attached to the different bony projections presented by the surface of that joint. Its *superficial surface* is separated from the skin by vessels and nerves, to which it furnishes sheaths of greater or less extent. We may admit the existence of a superficial fascia between the vessels and the skin.

Its *deep surface* presents various septa, dividing its interior into a certain number of thin sheaths for the several muscles. It is composed almost entirely of circular fibres, some of which have a somewhat spiral direction: these fibres are intersected at right angles by others passing vertically downward to the fascia of the forearm.

The brachial aponeurosis is so loose as to permit the free exercise of the muscles contained within it, yet sufficiently tense to prevent their displacement.

It is slightly thickened on either side, along the outer and inner borders of the humerus, and gives off in those situations two very strong inter-muscular septa: one external, the other internal. These septa are in every respect analogous to those of the femoral fascia, and divide the brachial sheath into two great compartments: *an interior*, containing the muscles on the anterior aspect of the arm, viz., the biceps, the brachialis anticus, and the coraco-brachialis, also the upper or brachial portion of the supinator longus, and the extensor carpi radialis longior; the *posterior* compartment belongs to the triceps.

The *external inter-muscular septum* arises from the anterior border of the bicipital groove, by a narrow and very thick extremity, blended with the posterior margin of the tendon of the deltoid; it reaches the outer border of the humerus, expands and becomes somewhat thinner, and separates the anterior from the posterior muscles, more especially the triceps from the brachialis anticus, affording attachments to them both. It is perforated very obliquely by the musculo-spiral or radial nerve, and the superior profunda artery, which at first lie behind, but are afterward in front of it. The sheath of this nerve and artery establish a free communication between the anterior and posterior compartments already alluded to.

The *internal inter-muscular septum*, broader and thicker than the preceding, but, like it, of a triangular form, arises from the posterior border of the bicipital groove, below the teres major, is continuous with the tendon of the coraco-brachialis, crossing it at a very acute angle, and becoming partially united to and blended with it, proceeds along and adheres closely to the inner border of the humerus, and terminates at the inner condyle or epitrochlea of that bone. Both of these septa are formed by bands and fibres given off in succession from the corresponding borders of the humerus, and they both afford attachments to the brachialis anticus in front, and to the triceps behind. The ulnar nerve is anterior to the internal septum in the upper part of the arm, but perforates it, and remains in contact with its posterior surface, passing between the attachments of the triceps.

From these two great sheaths the proper sheaths of the muscles proceed. First, the deltoid has its proper sheath: another thin aponeurotic layer, gradually becoming thicker from above downward, consisting almost entirely of vertical fibres, and forming one of the origins of the aponeurosis of the forearm, separates the biceps from the brachialis anticus; again, the brachial vessels and the median nerve have a special sheath, which also receives at its upper part the basilic vein, and the ulnar and internal cutaneous nerves; this is the *brachial canal*, the counterpart of the femoral canal; it establishes a communication between the cellular tissue of the axilla, and that in the bend of the elbow; lastly, a tendinous layer separates the upper half of the long head of the triceps from the other portions of that muscle: the sheath of the coraco-brachialis is given off from the inner edge of the biceps.

We must consider as dependances of the common brachial investment the several sheaths furnished by it to the cephalic, basilic, and median veins, to the branches of the internal cutaneous nerve, and to the superficial ramifications of the musculo-cutaneous nerve. When an artery or a vein previously situated under an aponeurosis becomes sub-cutaneous, the perforation in the aponeurosis is almost always of an arched form.

The brachial aponeurosis has no muscle analogous to the tensor vaginæ femoris; the pectoralis major and the latissimus dorsi are sufficient to effect its tension.

The Aponeurosis of the Forearm and Hand.

The Aponeurosis of the Forearm.

Dissection.—Make a circular incision through the skin, immediately above the elbow, and from this let two vertical incisions be carried downward to the wrist, one in front and the other behind; let the incisions extend through to the fascia, without dividing it: then cautiously remove the skin, being careful to take with it the sub-cutaneous adipose

tissue; the superficial veins and nerves may be preserved. The external surface of the fascia may be studied first, and its several sheaths afterward opened in succession.

The aponeurosis, or *fascia of the forearm*, forms a general sheath, entirely surrounding or embracing that portion of the upper extremity, with the exception of the posterior border of the ulna. It is semi-transparent, and hence can be seen to be traversed by white lines, generally vertical in their direction, which indicate a corresponding number of thickenings of the sheath, and inter-muscular septa given off from them.

It is separated from the skin by the superficial veins and nerves; by its upper part it gives numerous attachments to the subjacent muscles, and this renders the dissection very difficult. By making a vertical incision, however, along the separate sheath which it furnishes to each of the muscles, and then carefully removing the latter, a good idea may be formed of the numerous angular compartments into which the common cavity of the fascia is subdivided. In the first place, it will be seen that this fascia, like all other investing aponeuroses, is composed of proper and superadded fibres; that the proper fibres are nearly or quite circular, are more or less oblique, and more or less interlaced, but the superadded fibres are vertical. It will be found that it is twice as thick upon the dorsal as upon the palmar surface of the forearm; that its thickness and its strength increase from above downward; and that it is strengthened by a great number of superadded fasciculi, consisting of aponeurotic expansions from the tendons of the adjacent muscles. Thus, the brachialis anticus on the outside, the biceps on the inside and in front, and the triceps behind, give off tendinous expansions to this aponeurosis: of these the most remarkable is, without doubt, that given off from the biceps, which muscle may be regarded, indeed, as the tensor of the anterior portion of the fascia. This expansion constitutes, in fact, one of the terminations of the biceps, with the external fasciculi of which it is continuous, and, moreover, arises from the outer edge and the anterior surface of its tendon. This expansion, so important in consequence of its relations with the brachial artery, passes obliquely inward and downward, and, as it expands, intersects at right angles the vertical fasciculi proceeding from the epithrochlea and epicondyle of the humerus. These last-mentioned fasciculi also appear to me to be supplementary; they are continuous with the common tendons of origin of the external and internal muscles of the forearm, and constitute the anterior walls of those two multilocular pyramids, of which one is on the inner, the other on the outer side of the forearm, or of that series of trumpet-shaped cavities (*cornets*), as M. Gerdy calls them, from each of which the muscles of these regions take their origin. I must not omit to mention the thick tendinous band, which arises from the entire length of the posterior border of the ulna, divides into two layers to give origin to the flexor carpi ulnaris, and by its internal or deep surface affords attachment to the flexor sublimis.

In the fascia of the forearm there are numerous foramina for the passage of vessels and nerves, but I shall direct attention to one very large orifice existing in front, at the bend of the elbow, and bounded on the inside by the outer margin of the tendinous expansion of the biceps. This opening establishes a free communication between the subcutaneous and the sub-aponeurotic cellular tissue at the bend of the elbow, and leads into a sort of fossa, in which are found the tendon of the biceps, the brachial artery, the commencement of the radial artery, and the median nerve. This fossa is lined by aponeurotic laminæ: on the *outside*, by the layer which covers the inner surface of the supinator longus, the radial extensors, and the flexor sublimis; on the *inside*, by the layer which completes the sheath of the pronator teres: it communicates above with the canal of the brachial artery, and below with the canals through which the radial, ulnar, and interosseous arteries and the median nerve proceed downward to the forearm.

From the internal surface of this fascia a number of laminæ are given off, to form the following muscular sheaths:

In the *anterior region of the forearm*, a transverse septum, thicker below than above, divides the superficial layer of muscles from the middle layer, consisting of the flexor sublimis, and also from the deep layer, composed of the flexor profundus digitorum and the flexor longus pollicis. Other septa, passing from before backward, divide the muscles of the superficial layer from each other. Lower down the sheaths of the flexor carpi radialis and palmaris longus, which are perfectly distinct from each other, are situated in front of the remainder of the fascia; and this has led to the statement of some anatomists, that the fascia is perforated by the tendons of these muscles, especially by that of the palmaris longus. The radial artery has a special sheath throughout its whole extent; the ulnar artery and nerve have a proper sheath only in the lower part of the forearm.

In the *posterior region of the forearm*, the fascia is much stronger than in the anterior. A transverse layer separates the muscles of the superficial from those of the deep layer; and septa, passing from behind forward, subdivide these common sheaths into several smaller ones, corresponding in number to that of the muscles. Thus, we find a sheath for the extensor communis digitorum, a second for the extensor digiti minimi, a third for the extensor carpi ulnaris, and a fourth for the anconeus. The supinator longus and the two radial extensors of the wrist appear to be in the same sheath; but a more or less distinct membrane surrounds the first of these muscles: the supinator brevis has

also a proper sheath. We find a common sheath for the extensor longus pollicis and the extensor proprius indicis. The abductor longus and the extensor brevis pollicis, which, properly speaking, constitute but one muscle, have also a common sheath accompanying them as far as the dorsal annular ligament of the wrist.

The Dorsal Annular Ligament of the Wrist, and the Dorsal Aponeurosis of the Metacarpus.

The *dorsal annular ligament of the wrist* (*r*, *fig.* 121) may be considered as a dependance of the fascia of the forearm, which in this situation is strengthened by a great number of fibres. It is a band of six or eight lines in width, passing obliquely inward and downward over the extensor tendons of the hand, perforated by a number of openings for the passage of vessels, and distinguishable from the fascia of the forearm only by its somewhat greater thickness and by the parallel arrangement of its fasciculi. It arises internally from the pisiform bone and the palmar fascia, passes first over the ulnar side, and then the posterior surface of the carpus, is interrupted by the outer margin of the groove for the two radial extensor muscles, takes a fresh origin from that margin, covers the radial side of the wrist, and is inserted partly into the radius, and partly into the fascia of the forearm. From the anterior surface of this thick fibrous band arise several small prolongations, which are interposed between the numerous tendons passing over the dorsal and radial aspects of the carpus, and convert the grooves upon the lower extremities of the radius and ulna into canals. Thus, proceeding from without inward, and from before backward, we find, 1. A sheath for the united tendons of the abductor longus and extensor brevis pollicis; 2 and 3. Two distinct sheaths opposite the radius: one for the two radial extensors of the carpus, the other for the extensor longus pollicis, which sheaths become blended together lower down into a single completely fibrous sheath; 4. A fourth sheath, stronger than the preceding, for the extensor communis digitorum and the extensor proprius indicis; 5. An entirely fibrous sheath for the extensor digiti minimi; 6. A very strong sheath for the extensor carpi ulnaris, which is prolonged below the ulna, and accompanies the tendon as far as the fifth metacarpal bone. All these sheaths are lined by synovial membranes,* which extend some distance above the dorsal annular ligament, and, on the other hand, accompany the tendons very far down, sometimes even to their insertions.

The *dorsal aponeurosis of the metacarpus* is a continuation of the dorsal annular ligament: it is composed of a very thin layer of transverse fibres, and separates the extensor tendons from the sub-cutaneous vessels and nerves. A very loose, extensible, and elastic cellular tissue takes the place of the synovial membranes over these tendons, and greatly facilitates their movements.

The Anterior Annular Ligament of the Carpus.

The deep groove upon the anterior surface of the carpus is converted into a canal by a very thick fibrous band, viz., the *anterior ligament of the carpus* (*g*, *fig.* 118). It commences internally by two well-marked origins, separated from each other by the ulnar nerve, one being from the pisiform bone and the tendon of the flexor carpi ulnaris, the other from the unciform bone. The first bundle passes downward, the second transversely, and their united fibres, some of which are transverse and others interlaced, terminate at the trapezium and the scaphoid, giving off an expansion to the fascia covering the ball of the thumb, with which they are continuous. This ligament is continuous above with the fascia of the forearm, which is much thickened in this situation: it receives in front the expanded tendon of the palmaris longus, and terminates below in the palmar fascia. Its anterior surface gives attachment to most of the muscles of the thenar and hypothenar eminences. A small portion only of this ligament is generally seen and described, viz., the free portion. If it is wished to obtain a perfect conception of it, the muscles attached to its anterior surface should be carefully removed; it will then be seen that, on the outside, it describes a curve having its concavity directed inward, in order to be attached to the scaphoid and the trapezium, and that the sheath of the flexor carpi radialis is contained in its substance: this sheath is entirely fibrous above, and partly fibrous and partly osseous below, where it converts into a canal the groove on the trapezium.

While there are almost as many synovial membranes as there are sheaths under the dorsal ligaments of the carpus, on the palmar aspect nine tendons with the median nerve form but a single bundle, which is lubricated by one or two synovial membranes. This synovial membrane* presents a curious arrangement, subject, moreover, to numerous varieties. It lines the posterior surface of the anterior annular ligament of the carpus is prolonged above and below that ligament, and is reflected (without passing between the different tendons) upon the anterior surface of the bundle formed by them and by the median nerve, which is to their outer side. In order to obtain an accurate idea of the termination of this synovial membrane, cut across the tendons at the lower part of the forearm, and turn them forward upon the palm of the hand: it will then be seen that the

* See note, p. 296.

synovial membrane is reflected upon the ulnar border of the bundle of tendons; that it lines the posterior surface of this bundle, passing more or less between the tendons, and separating them from each other in a rather irregular manner; that it is reflected upon the groove of the carpus, prolonged upward and downward much farther than it was in front, and divided below into four small prolongations corresponding to the flexor tendons of each finger. Nor is this all, for there is a special synovial membrane for the flexor longus pollicis. In order to expose this, the synovial membrane must be cut through where it is reflected, on its radial side, from the annular ligament on to the median nerve and the anterior surface of the bundle of tendons: a special and very extensive synovial membrane will then be seen to pass high up along the tendon of the flexor longus pollicis, and to be prolonged downward as far as the last phalanx of the thumb.

The Palmar Aponeurosis.

The *palmar fascia* (*c*, *fig.* 118) forms a common sheath for all the muscles of the palm of the hand, and is divided into three portions, a *middle* and two *lateral*.

The *middle portion*. This is the only part generally described as the palmar fascia; it is triangular and strong, but of variable thickness: it binds down the numerous subjacent tendons. It arises from the anterior surface and lower margin of the anterior annular ligament of the carpus, and from the tendon of the palmaris longus, which may be regarded as its tensor muscle. Between these two origins the ulnar artery penetrates into the palm of the hand. Not unfrequently the expanded tendon of the palmaris longus forms a fibrous layer in front of the proper palmar fascia. This fascia is narrow and thick at its origin, but expands as it proceeds from above downward, and, opposite the heads of the metacarpal bones, divides into eight prolongations for the four inner fingers. At the seat of this division we find very strong transverse fibres binding the prolongations together, and preventing disjunction of the fingers and laceration of the fascia. By this arrangement four arches are formed, under which the tendons of the flexor muscles pass: between these four arches there are three smaller ones, giving passage to the collateral vessels and nerves of the fingers, and to the lumbricales, so that altogether there are seven arches. These arches are true fibrous canals. In order perfectly to understand their structure, make a vertical incision through the palmar fascia; it will then be seen that, opposite the arches, tendinous prolongations or tongues are detached from the deep surface of the fascia: these prolongations turn round the sides of the tendons so as to embrace them, and become continuous with the anterior or glenoid ligament of the metacarpo-phalangal articulations: the same arrangement obtains with regard to the three small arches for the vessels and nerves situated between the four principal tendinous arches. The palmar fascia is, moreover, intimately united to the skin by very numerous prolongations: its deep surface covers the superficial palmar arch of the arteries of the hand, the median and ulnar nerves, and the flexor tendons; a very loose and extensible cellular tissue separates it from these parts, and facilitates the movements of the tendons. From its inner margin is given off a very strong layer, which becomes continuous with the interosseous aponeurosis, and separates the middle from the internal palmar region; a thinner layer proceeds from its outer margin, and passes down between the muscles of the thenar eminence and the first lumbricalis muscle. This small muscle, called the *palmaris brevis* (*b*, *fig.* 118), arises from the inner margin of the middle palmar fascia, and is merely a cutaneous muscle.

The *external and internal palmar fasciæ*, or the *thenar and hypothenar aponeuroses*. These consist of two rather thin fibrous layers, forming the sheaths of the muscles of the ball of the thumb and those of the little finger: they are both continuous with the middle palmar fascia: the external appears to consist, in a great measure, of an expansion from the tendon of the abductor longus pollicis; and the internal, of an expansion from that of the flexor carpi ulnaris. At the limits between these aponeuroses and the middle fascia are formed two septa, passing from before backward, and dividing the palm of the hand into three distinct sheaths: one median, completed by the interosseous aponeurosis, and intended for all the flexor tendons and the principal vessels and nerves of the hand; the other two placed on either side, and binding down the muscles of the thenar and hypothenar eminences.

The Sheaths of the Flexor Tendons of the Fingers, and their Synovial Membranes.

After leaving the arches, or, rather, the curious sheaths, formed by the palmar fascia immediately above the corresponding metacarpo-phalangal articulation, each pair of flex or tendons is received into a special sheath, by which they are accompanied down to the last phalanx. It will be remembered that the anterior surfaces of the first and second phalanges are marked by a longitudinal groove; to the two borders of this groove is attached a very regular semi-canal of fibrous tissue, which is exactly large enough to contain the two flexor tendons. This very strong sheath preserves its shape when the tendons have been removed; and a correct idea of its importance may be obtained by observing the effects of contraction of the flexor muscles after it has been divided. This

sheath is formed of parallel semicircular laminæ, placed one above the other, densely aggregated over the bodies of the phalanges, and, for the most part, forming a continuous sheath, but becoming more and more separated, and sometimes even completely disappearing opposite the articulations and the articulating extremities of the bones. It appears to me that, in the movements of flexion, these articular rings are pushed into each other. The sheath ceases altogether above the articulation of the second with the terminal phalanx.

A very remarkable synovial membrane,* which is prolonged upward beyond the arches formed by the palmar fascia, lines the whole lenth of each osteo-fibrous sheath *on the one hand*, and *on the other* is reflected upon the two flexor tendons, affording each of them a sheath, and forms two, often three or four triangular folds, having their bases directed upward, and being perfectly analogous to the so-called adipose ligament of the knee-joint. Of these folds, the superior is situated opposite the upper extremity of the first phalanx, and extends from the tendon of the flexor sublimus to that of the flexor profundus; the inferior fold passes from the bifurcation of the superficial tendon to the deep tendon; the others are intermediate, and proceed from the phalanx to the two tendons. These synovial folds can be very well seen by raising and separating the flexor tendons from the phalanges. Not unfrequently the synovial membrane forms a hernia between two of these tendinous rings, either opposite the body of a phalanx, or, still more commonly, over one of the articulations. We may add, that these synovial folds are probably intended to support the nutritious vessels of the tendons, and not to connect these tendons together.

SPLANCHNOLOGY.

General Observations on the Viscera.—External Conformation.—Structure.—Development.—Functions.—Dissection.

Splanchnology (from σπλάγχνον, *viscus*) is that division of anatomy which treats of organs more or less compound in their structure. Some of these are contained within the three great visceral cavities (*the viscera*), while others are situated without these cavities (*organs*, properly so called).†

The brain, the spinal cord, the heart, and the organs of the senses, are generally included in this division. I have thought it advisable, however, to confine myself here to the description of the digestive, respiratory, and genito-urinary apparatus. The organs of the senses, the brain, and the spinal cord will be studied more advantageously in connexion with the rest of the nervous system, and the heart with the other organs of the circulation.

As the organs we are about to examine have few relations with each other, they do not admit of such extended and important general remarks as those which preceded the osteological and myological divisions. I shall content myself with explaining briefly the method in which the description of each organ should be pursued.

Every organ presents for consideration its external conformation, its internal conformation or its structure, its development, and its functions.

The External Conformation of Organs.

The description of the external conformation of organs includes that of their nomenclature, number, situation, direction, size, shape, and relations.

Nomenclature.—The nomenclature of organs has not been subjected to so many changes as that of the bones and muscles: the names adopted by the oldest authors have been retained in modern science, and are even used in common language.

The names of organs are derived, 1. From their uses, as the *œsophagus* (from οἴω, I convey, and φάγω, I eat); also, the *lachrymal* and the *salivary* glands. 2. From their length, as the *duodenum*. 3. From their direction, as the *rectum*. 4. From their shape, as the *amygdalæ* (the tonsils). 5. From their structure, as the *ovaries*. 6. From the name of the authors who have best described them, as the *Schneiderian membrane*, the *Fallopian tubes*. Lastly, they are conventional words; for example, the *tongue*, the *liver*, &c.

Number.—Some organs are single; others exist in pairs. Varieties in number are very common, both by excess and by defect. Thus, three kidneys have been found in the same individual, and there is often only one. Examples have been recorded of individuals having three testicles; one is uncommon. Lastly, varieties by excess almost always result from the division, and those by defect, from the union or fusion of organs.

Situation.—This must be considered with regard to the region of the body occupied by an organ, *i. e.*, its *general* or *absolute situation*; and also with regard to its relations with neighbouring organs, *i. e.*, its *relative situation*. Thus, when it is stated that the stom-

* See note, p. 296.

† All the viscera are organs, but all the organs are not viscera. The word viscus is probably derived from *vescor*, I eat, because a great number of the viscera are engaged in the functions of nutrition.

ach occupies the left hypochondrium and the epigastrium, its absolute or general situation is indicated; but when it is added that this viscus is situated between the œsophagus and duodenum, below the diaphragm, and above the transverse mesocolon, its relative situation is implied.

Many of the organs are subject to varieties of position; and this constitutes an important point in their history. These varieties of position depend upon congenital or upon accidental displacement, either affecting the particular organ only, or consequent upon displacement of the neighbouring organs; or they may result from a change in the size of the organ itself.

Size.—The *absolute* size of an organ is determined by linear measurements, by the quantity of water which it displaces, and by its weight; *its relative size*, by comparison with bodies of a known size, or with other organs.

The size of organs is subject to a great number of varieties. These depend either on age, as in the *liver*, *testicles*, and *thymus gland*; on sex, temperament, or on individual peculiarities; also on the state in which an organ is found: for example, the *uterus*, *penis*, and *spleen*. Lastly, there are some pathological variations, which should not be omitted in a treatise upon descriptive anatomy.

Figure.—The figure of the organs treated of in splanchnology appears to follow these rules. The double organs do not exactly resemble each other on the right and left sides of the body. The single organs, occupying the median line, are symmetrical; but most of those which are removed from that line are not symmetrical. Nevertheless, symmetry is not so completely wanting in the viscera belonging to nutritive life, as stated by Bichat, for the *stomach* and the *small* and *great intestines* may be divided into two equal halves.

In regard to their forms, organs are compared, in general, either with familiar objects, or with geometric figures. Thus, a *kidney* is said to resemble a kidney-bean, and either *lung*, a cone. In very irregular organs, we merely describe the surfaces and the borders. We shall not find in the viscera the same constancy of form as exists in the organs of relation.

Direction.—The direction of an organ is determined in the same manner as that of the bones and muscles, viz., by its relations with the imaginary planes surrounding the body, or with the mesial plane.

Relations.—The figure of an organ being determined, its surface is then divided into *regions*, the relations of which are accurately ascertained. These regions are generally termed *surfaces* and *borders*. As the situation of many organs is subject to great varieties, their relations must also vary. Too much cannot be said of the value of an accurate knowledge of these relations, from which a number of the most important practical inferences may be derived.

The Internal Conformation or Structure of Organs.

The surface of an organ being well understood, we next proceed to the study of its structure, comprising its colour, its consistence, and its anatomical elements.

Colour.—The colour both of the surface and the substance of an organ requires to be studied. All variations of colour should be very carefully noted. Age and disease have much influence over it; and it is often difficult to distinguish positively between its physiological and pathological condition.

Consistence.—The *consistence*, *density*, and *fragility* of organs are connected with their structure. The specific gravity or density of a single organ only, the *lung*, has been accurately studied, and that in a medico-legal point of view. In estimating the consistence and fragility of organs, we can only approximate the truth. It is desirable that some more methodical and accurate means should be devised for the estimation of these qualities.

Anatomical Elements.—The determination of the immediate anatomical elements, or tissues, which enter into the composition of an organ, together with their proportions and their arrangement, constitutes the knowledge of its structure. Every organ has either a cellular, fibrous, cartilaginous, or bony framework. Some organs are provided with muscular fibres, or even with distinct muscles; they all contain the several kinds of vessels, viz., arteries, veins, and lymphatics; and they all possess nerves. The glandular organs have excretory ducts.

In explaining the structure of organs, we shall, generally, confine ourselves to a brief enumeration of their constituent parts, referring to works on the anatomy of textures for details which would be misplaced in an elementary treatise.

The Development of Organs.

The study of the development of organs, and the changes which they undergo at the different periods of intra- and extra-uterine life, is of the greatest interest, at least as regards some among them. The formation of the soft parts, however, is not nearly so well understood as that of the hard tissues, because the most important phenomena of development occur during the first weeks after conception. The remarks upon this subject will, therefore, generally point out some hiatus to be filled up.

The Functions of Organs.

The functions or uses of organs flow so naturally from their anatomical description, that we shall follow the example of the greater number of anatomists, in adding to such description a short account of the functions of an organ. We shall only notice particularly those uses of organs which depend immediately upon their structure, referring to physiological works for the details and discussions of yet disputed points in the science of functions. No part of anatomy excites so much curiosity and interest as splanchnology, in consequence of the importance of the organs of which it treats. Without a knowledge of this department of anatomy, it is impossible to understand the mechanism of functions the most indispensable to life; and as the organs themselves are the seat of the greater part of the lesions which are assigned to the physician, as well as of many of those which fall under the care of the surgeon, most of the fundamental questions of the healing art require a profound knowledge of these organs.

The Dissection of the Viscera.

The dissection of organs does not consist in merely isolating them from surrounding parts, which, as far as regards those contained in the visceral cavities, is done by simply laying open the latter, but in the separation of their anatomical elements or tissues. For this purpose, injections of the most delicate kind, maceration, boiling, preservation in alcohol, desiccation, the action of acids, in short, all the resources of his art, are employed by the anatomist.

Having made these preliminary observations, we shall now describe in succession the organs of digestion, the organs of respiration, and the genito-urinary apparatus.

THE ORGANS OF DIGESTION AND THEIR APPENDAGES.

ALIMENTARY OR DIGESTIVE CANAL.

General Observations.—Division.—Mouth and its Appendages.—Lips.—Cheeks.—Hard and Soft Palate.—Tonsils.—Tongue.—Salivary Glands.—Buccal Mucous Membrane.—Pharynx.—Œsophagus.—Stomach.—Small Intestine.—Large Intestine.—Muscles of the Perineum.—Development of the Intestinal Canal.

The organs of digestion form a long canal, the *alimentary* or *digestive canal*, extending from the mouth to the anus, which receives alimentary substances, induces in them a series of changes, by which they are rendered fit to repair the losses incurred by the body, and, moreover, presents a vast absorbent surface for the action of the lacteal vessels. The entire series of these organs constitutes the *digestive apparatus*.

The existence of an alimentary canal is one of the essential characters of an animal. In consequence of possessing it, animals may be detached from the soil, so as to move from place to place. In the lowest species, the entire animal is nothing more than an alimentary sac, having a single opening, and formed by a reflection of the skin; so that, according to the beautiful observation of Trembley, when polypes are turned inside out, the digestive process is performed as well by their external as by their internal surface. Ascending in the scale of animals, the canal soon presents two openings, acquires larger dimensions, becomes more or less convoluted, and is distinct from other systems of organs. A skeleton clothed by muscles is interposed between it and the skin. It becomes more and more voluminous, in proportion as the nutritive materials and the textures of the body differ more widely in their chemical composition. What a difference there is, in this respect, between certain fishes, in which the alimentary canal is not nearly so long as the animal, and some herbivora; the ram, for example, in which it is twenty-seven times the length of the body. Carnivorous animals, again, have a short and narrow alimentary canal. Man, being destined to live both upon animal and vegetable substances, occupies, as it were, a middle station between the herbivora and carnivora.

General Situation.—The digestive canal is situated in front of the vertebral column, with the direction of which the straight portion of the canal accurately corresponds, while its tortuous part is distant from, though invariably connected with it by means of membranous attachments. It commences at the lower part of the face, traverses the neck and the thorax, penetrates into the abdominal cavity, which is almost exclusively intended for it, and the dimensions and mechanism of which bear strict relation to the functions of the alimentary canal; and it terminates at the outlet of the pelvis, anterior to the coccyx, by the anal orifice. Its upper part is in immediate relation with the organs of respiration; its lower, with the genito-urinary apparatus.

Dimensions.—The length of the digestive canal has been calculated to be seven or eight times that of the body of the individual. Its diameter is not equal through its whole extent; and its alternate expansions and contractions establish very distinct limits between its several portions. The largest portion is, undoubtedly, that which receives the name of the stomach; the narrowest parts are the cervical portion of the œsophagus, the pyloric opening of the stomach, and the ileo-cæcal orifice. It is impor-

tant to remark, that the transverse dimensions of an alimentary canal have, to a certain extent, an inverse ratio to its length. Thus, a very wide intestinal canal is generally less remarkable for length. This remark is illustrated by comparative anatomy in the fact that, in the horse, an herbivorous animal, the intestinal canal is shorter, but, at the same time, of a much greater calibre than in the ruminantia, which are also herbivorous.

Direction.—The upper or supra-diaphragmatic portion of the alimentary canal, through which the food merely passes, is straight; the sub-diaphragmatic portion is very much convoluted upon itself, but again becomes straight before its termination.

General Form.—The digestive apparatus forms a cylindrical continuous canal, in which we have to consider an external and generally free serous surface, and an internal mucous surface.

Structure.—The digestive canal is composed of four membranes or tunics: 1. The most external is the *serous* or *peritoneal coat*, also named the *common tunic*, because it is common to almost all the organs in the abdominal cavity. This membrane, which may be regarded as an accessory tunic, is often incomplete, and even entirely wanting throughout the supra-diaphragmatic portion of the digestive canal. At the same time that it constitutes the external covering of this canal, it separates it from the neighbouring parts, facilitates its movements, and forms certain bands, which maintain the several portions of the canal more or less fixedly in their proper situations. The serous membranes, of which this external tunic is only a dependance, are shut sacs, which, on the one hand, line the walls of the cavities to which they belong, and, on the other, are reflected upon the organs contained therein,* without, however, including them within their own proper cavity.

A serous membrane may be compared to a balloon, or, rather, to a double nightcap; its internal surface is free, smooth, always moistened with serosity, and its parietal and visceral portions are in contact with each other: its external surface is adherent.†

2. Beneath the serous coat is situated the *muscular coat*, consisting of two layers: one superficial, composed of longitudinal fibres; the other deep, and composed of circular fibres. These fibres are colourless, like almost all the muscles of nutritive or organic life.‡

3. The *fibrous coat*, interposed between the muscular and mucous coats, may be regarded as constituting the framework of the alimentary canal. It consists of dense areolar cellular tissue.◊

4. The *mucous coat* or *membrane* forms the internal lining of the digestive canal. Every cavity having a communication with the exterior is lined by a mucous membrane, so called on account of the mucus with which it is constantly lubricated.

In mucous membranes generally, we find, 1. A *dermis* or *chorion*. 2. *Papillæ* or *villosities*, which give them a velvety appearance; hence the designation *papillary*, *villous*, or *velvety* membrane frequently given to them. 3. On the outer surface of the dermis we find a very dense *network of capillary* vessels, which may be completely injected from the veins, but less easily and less completely from the arteries. 4. Either follicles or small closed sacs are seen here and there in the substance of mucous membranes; but they are not essential, as the name *follicular*, given to these membranes by Chaussier and some other anatomists, would seem to indicate.

* [Hence the terms parietal and visceral, applied to these two portions of a serous membrane (see *fig.* of the testis, letters *p* and *v*).

In consequence of the existence of an aperture in the free extremity of each Fallopian tube, the peritoneal cavity in the female is an exception to the general rule, that serous membranes form shut sacs, not communicating with the external medium.]

† [Serous membranes are transparent, colourless, extremely thin, and highly distensible and elastic. They are composed of a basis of cellular tissue, loose and connected to the adjacent tissues externally, more or less condensed towards the inner and free surface of the membrane, and covered with an extra-vascular epithelium, consisting of a single layer of nucleated cells, flattened into the form of scales, and arranged parallel to that surface. Cilia have been detected on many serous membranes, as on the peritoneum and pericardium of the frog; on the same parts, and also on the pleura and lining membrane of the ventricles of the brain in certain mammalia; and in the latter situation in man. Bloodvessels ramify in the sub-serous cellular tissue, but do not penetrate far towards the free surface, where they are entirely wanting. Lymphatics also exist in the sub-serous tissues, but have not been found in the membranes themselves; nor have nerves been traced into them. The fluid secretion found in serous cavities appears to be of an albuminous nature.]

‡ [The involuntary muscular fibres of the alimentary canal (according to Dr. W. Baly) consist of bands, varying from $\frac{1}{2500}$th to $\frac{1}{3600}$th of an inch in diameter, apparently formed of flattened tubes, in the parietes of which are seen, at irregular intervals, numerous transparent oval or linear bodies, sometimes very difficult of detection: they are believed to be the nuclei of the primitive cells, from which the fibre itself is developed. These fibres contain no varicose filaments, nor do they present any transverse striæ, like those of animal life (see p. 194). Moreover, although they have a parallel arrangement in the fasciculi into which they are collected, the fasciculi themselves are irregularly interlaced, at the same time that they all pursue a common direction.

The muscular coat of nearly the entire alimentary canal consists essentially of these involuntary or organic muscular fibres; but at the commencement and termination of the canal, where the muscular systems of animal and organic life come into relation with each other, this tunic appears also to consist of fibres resembling those of the voluntary muscles. Thus, at the upper part of the œsophagus, fibres containing varicose filaments, and possessing the cross striæ, were detected by Schwann; and it has been shown by Valentin and Ficinus, that these exist all along the œsophagus, and that indistinctly striated fibres are found even at the cardiac end of the stomachs of many mammalia, and of man. Similar fibres were observed by Ficinus in the rectum, near the sphincter ani.]

◊ [It is frequently called the *cellular* coat; and, from its white appearance, has been termed (like all other white textures) the *nervous* tunic.]

All mucous membranes are covered by an extremely delicate pellicle, which may be readily detected by means of a simple lens. Injections made by the arteries and veins never penetrate it, nor is it reddened by inflammation. I have accidentally injected it, however, by means of a tube containing mercury, used for injecting the lymphatics by pricking the mucous membrane in different places as superficially as possible. The vascular network, thus injected, is exceedingly delicate; the small globules of mercury traversing it in all directions, so as to form rapidly a silvery areolar layer. I have seen this in the mucous membrane of the nose; on the conjunctiva, both over the sclerotic and over the cornea; on the mucous membrane of the vagina, of the tongue, and of the cheeks. It is very remarkable that the mercury never passes from this network either into the veins or the arteries; and, moreover, that if the tube pierces a little too deeply, the veins are injected, but not the epidermic capillary network. It is evident, therefore, that this network has no communication either with the arteries or the veins. It probably belongs to the lymphatic system, although I have never observed the lymphatic vessels filled from it.*

Vessels and Nerves.—Vessels and nerves also enter into the formation of the alimentary canal: for example, we find a very abundant supply of branches from the adjacent arterial trunks; an immense number of veins, of which those from the sub-diaphragmatic portion of the canal terminate in the vena portæ; absorbent vessels, divided into lymphatics and lacteals; and, lastly, nerves, almost all of which proceed from the ganglionic system, excepting the pneumogastric and glosso-pharyngeal nerves.

Fig. 139.

Division of the Digestive Canal.—The digestive canal has been divided into several parts, from differences both in their anatomical characters and their functions. One principal division, which deserves to be retained, is into a *supra-diaphragmatic* and a *sub-diaphragmatic portion*. The *supra-diaphragmatic portion* comprehends the *mouth*, the *pharynx*, and the *œsophagus*. The *infra-diaphragmatic* portion includes the *stomach* (*a b*, *fig.* 139), the *small intestine*, subdivided into the *duodenum* (*b c*), and the *jejunum* and *ileum* (*c d*); and the large intestine, somewhat arbitrarily divided into the *cæcum* (*d e*), the *colon* (*d h*), and the *rectum* (*h i*). The appendages of the digestive canal consist of the *salivary glands*, connected with the mouth; of the *liver* and the *pancreas*, connected with the duodenum; and of the *spleen*, which may be regarded as an appendage of the liver.

The Mouth and its Appendages.

The *mouth*† is a cavity situated at the entrance of the digestive passages. It occupies the lower part of the face, and is situated between the two jaws, below the nasal

* [The lining membrane of the digestive apparatus, forming part of the gastro-pulmonary system of the mucous membranes, extends not only throughout the entire alimentary canal, but also along the ducts of the various glands which pour their secretions into it.

Structure in general.—Mucous membranes are usually soft, pulpy, incapable of great distension, easily lacerated, somewhat opaque, and when free from blood, of a pale grayish or ashy hue. The dermis or chorion (analogous to that of the skin) is a basis of cellular tissue, of very variable thickness; its attached surface is connected to the subjacent textures, either immovably, as in the nasal cavities and on the tongue, or loosely, as in the gullet and stomach. The pellicle or epithelium with which its surface is always covered (corresponding to the epidermis of the skin) also varies much in thickness in different situations; it consists of transparent nucleated cells, according to the form and arrangement of which it receives its name. Thus, in the *squamous* epithelium, there are generally (as in the mouth and gullet) several layers of cells; of these the deepest are vesicular, and contain a comparatively large nucleus; those on the surface are flattened out into polygonal *scales*, from the centre of which the nucleus has nearly disappeared, while the intermediate cells present intermediate transitional forms. The nucleated cells of the *columnar* epithelium (found, for example, in the stomach and intestines) are developed into oblong cylinders, arranged in a single series, like basaltic columns, perpendicularly to the surface of the dermis. In some situations, as in the nasal cavities and air passages, cilia are attached to the free extremities of the cylinders of the columnar epithelium, but no cilia have been detected in any part of the *alimentary canal* of man, or the warm-blooded animals: the superficial cells of the epithelium of mucous membranes are continually being thrown off by a process of desquamation. The different mucous membranes differ in vascularity; the network of capillary vessels in the dermis becomes closer or denser near its surface; the lymphatic vessels also form a network in the same situation; but the epithelium, though organized, is, as stated in the text, perfectly extra-vascular.

Mucous membranes are also more or less abundantly supplied with nerves.

When boiled they yield no gelatine, or, rather, only as much as would proceed from the cellular tissue and vessels they contain. The fluid secreted by them, or mucus, is viscid, transparent, and colourless, miscible with, but not soluble in water, and not coagulated by heat. It contains, besides the desquamated epithelium scales, proper granular globules, $\frac{1}{1500}$ inch in diameter, and having a very close resemblance to the globules of pus. According to Berzelius, mucus consists of water, a few salts, albumen, and a peculiar animal substance, which he calls mucous matter. This latter, when dried, swells on being placed in water, but, like fresh mucus, is insoluble in that fluid, either hot or cold; it is slightly soluble in dilute acetic and nitric acids, and in caustic alkalies.

The peculiarities presented by particular portions of the mucous membranes, and the structure of the papillæ, villi, follicles, &c., found in some parts of them, will be separately noticed, as opportunity offers.]

† The meaning of the word *mouth*, in anatomy, differs from the ordinary acceptation of the term, which is usually applied, not to the buccal cavity, but to its orifice.

fossæ, between the cheeks, behind the lips, and in front of the pharynx. It constitutes a very complicated apparatus, in which are performed the several acts of mastication, tasting, and insalivation, the commencement of the act of deglutition, and the articulation of sounds.

Fig. 140.

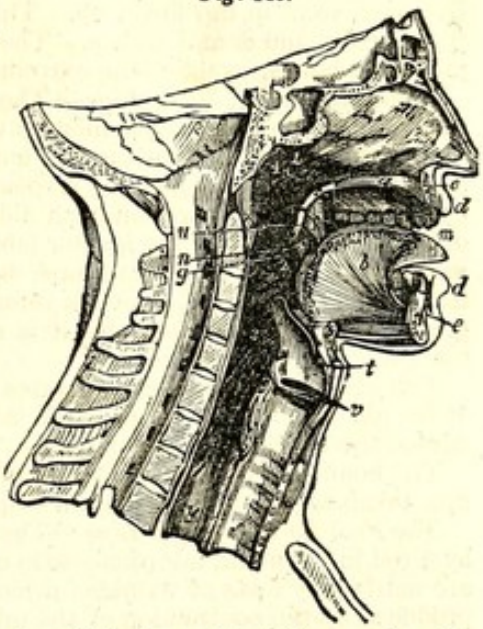

The dimensions of the buccal cavity are greater than those of the succeeding portion of the alimentary canal; hence bodies may be introduced into it which are too large to pass through the constricted parts of that canal.* The size of the mouth presents every intermediate degree between complete closure with the jaws in contact and leaving no interval between them, and extreme expansion, when the buccal cavity represents a quadrangular pyramid, the base of which is directed forward, and the apex backward. An increase in the capacity of the mouth may also be effected in the transverse direction by the distension of the cheeks, and in the antero-posterior direction by a projection of the lips forward.

In studying the relative proportions of the several diameters of the buccal cavity, it is found that none of them predominates in man, while, in the lower animals, the antero-posterior is by far the longest: this depends partly on the great size of their nasal cavities, and partly on the length of their jaws. In connexion with this subject, we may remark, that in the animal series there is an inverse ratio between the size of the cavity of the cranium and that of the gustatory and olfactory cavities.

In man, the *direction* or *axis* of the mouth is horizontal—an arrangement which is connected with his destination for the biped position. If man assumed the attitude of a quadruped, the axis of his mouth would be vertical; whereas, in the lower animals, it is directed obliquely to the horizon.

Form.—The mouth (*fig.* 140) represents a perfectly symmetrical oval cavity, the great extremity of which is in front. It has an *upper wall*, viz., the arch of the palate (*a*); a *lower wall*, consisting principally of the tongue (*b*); a *posterior wall*, formed by the velum palati (*c*); an *anterior wall*, composed of the lips (*d*) on one plane, and of the alveolar arches and the teeth (*e*) on another; and two *lateral walls*, formed by the same arches, by the teeth, and by the cheeks. It has two openings: one *anterior* (*m*), constituting the orifice of the mouth; the other *posterior* (2, *figs.* 140, 141), establishing a communication between the buccal cavity and the pharynx, and, on account of its narrowness, called the *isthmus of the fauces*.

We shall now describe these parts in succession, excepting the maxillary bones and the teeth, which have been already treated of. The salivary glands, which pour their secretions into the buccal cavity, will be described as appendages to it.

The Lips.

The *lips*, forming the anterior wall of the mouth, are two movable, extensible, and contractile curtains, which circumscribe its orifice. They are distinguished into *upper* and *lower*. Their *direction* is vertical, like that of the alveolar and dental arches, upon which they are applied. This direction is peculiar to the human species, and is more marked in the Caucasian race; lips projecting forward, like those of the lower animals, and not placed upon the same vertical plane, give a mean expression to the physiognomy. The depth of the lips is measured by that of the alveolar and dental arches. The upper is deeper than the lower lip.

The two lips offer for our consideration an anterior or cutaneous surface, a posterior or mucous surface, an attached and a free border, and two commissures.

The Anterior Surface.—In the *upper lip* this surface presents along the *median line* a vertical furrow, the *sub-nasal groove*, commencing at the septum of the nose, and terminating below in a tubercle, which is more or less prominent in different individuals. This furrow is the vestige of a division in the lip, natural to many mammalia. The malformation, termed single *hare-lip*, always occupies one of the edges of this groove; in double hare-lip both of them are affected. *On each side*, the upper lip is convex, and covered with a slight down in the female, and before puberty in the male, but after that period with long and stiff hairs directed obliquely outward. The aspect of the anterior surface of the *lower lip* is inclined a little downward; the middle portion only of this lip, which presents no median depression, is covered with hairs.

* As a general rule, the proportion between the different parts of the alimentary canal is such, that the upper portion will not admit bodies too large for the lower; and though the buccal cavity forms an exception to the rule, it is because the food, while it remains in that situation, is under the influence of the will.

The Posterior Surface.—Each lip is free behind, excepting in the median line, where we find a small fold of mucous membrane called the *frænum labii :* it is more marked in the upper than in the lower lip. This surface is always moist, and is in contact with the alveolar and dental arches. The complete independence of the lips, as regards the maxillary bones, explains the extreme mobility of these membranous organs.*

Adherent Borders of the Lips.—The lips are bounded at their posterior surface by the reflection of the mucous membrane upon the jaw, so that there is a deep and very remarkable furrow between the lips and the maxillary bones, which may be regarded as an *anterior buccal cavity*, or the *vestibule* of the mouth. The upper lip is bounded in front by the base of the nose ; on each side it is separated from the cheeks by the projection of the inner margin of the levator labii superioris alæque nasi ; the lower lip is bounded in the median line by a transverse depression situated between it and the chin, called the *mento-labial* furrow, which is remarkable for the perpendicular direction of the hairs growing upon it ; on each side it is separated from the cheeks by the projecting inner margin of the triangularis oris.

The line or furrow which separates on either side the lips from the cheek commences at the ala of the nose, and is called the *naso-labial line :*† it would be more appropriately named the *bucco-labial line* or *furrow.*

The boundaries between the lips and the cheeks are, then, entirely artificial ; the two lips, taken together, represent an ellipse, the longest diameter of which is transverse.

The Free Borders of the Lips.—The free borders of the lips are rounded, are covered by a red integument, intermediate in character between skin and mucous membrane, and are marked by folds or wrinkles directed at right angles to the length of the lips, and produced by the contraction of the orbicularis oris muscle. These free borders, which are, as it were, everted, especially that of the lower lip, present anteriorly a well-marked line of separation between the skin and the mucous membrane ; they describe an undulating line, which attracts the attention of the painter more than that of the anatomist.

The chief characters of the free margin of the upper lip are, a slight projection in the middle line, and a slight depression on either side : those of the free border of the lower lip are a median depression and two lateral projections ; on meeting together, these borders come into accurate contact, and completely close the opening of the mouth. The free margins of the lips are, moreover, their thickest part, and they are thicker in the middle than at each extremity ; their thickness also varies greatly in different individuals. In general, thick lips are regarded as indicating a scrofulous diathesis ; but in forming an opinion upon this subject, it is necessary to distinguish carefully between size resulting from hypertrophy of the muscular layer, and that which is caused by an excess of skin and cellular tissue. In the Ethiopian race, the size of the lips is entirely due to the great development of the muscles.

The Commissures.—The lateral extremities of the free margins of the lips are thin, and by their union form the *angles* or *commissures* of the lips (from *committo*, to join together).

The Anterior Orifice of the Mouth.—The free edges of the lips intercept a transverse fissure, viz., the *anterior opening of the mouth.* The variable size of this orifice in man has given rise to the distinctions of *middle-sized*, *large*, and *small* mouths : the difference, however, is confined to the opening, and does not at all affect the buccal cavity properly so called. The anterior opening of the lips is also exceedingly dilatable, and, accordingly, admits the introduction of very large bodies, and renders the exploration of every part of the cavity of the mouth comparatively easy.

Structure of the Lips.—The lips are composed of two tegumentary layers, one cutaneous, the other mucous ; of a muscular layer ; of a series of glands ; and of vessels, nerves, and cellular tissue.

The Cutaneous Layer.—This is remarkable for its density and thickness, for the size of the hair follicles, which are partially situated beneath it, and for its intimate adhesion to the muscular layer ; so that it is impossible to separate them by dissection without encroaching upon one or the other. This layer may be regarded as the framework of the lips. It is endowed with an exquisite sensibility, and, in many animals, possesses so delicate a sense of touch, that the slightest movement of the extremities of the long hairs with which it is provided at once warns the animal of the presence of approaching objects.

The Mucous Layer.—This is remarkable from the existence of an epithelium upon it, which can be very easily demonstrated. It covers the free edge of the lips, so that, by a rare exception, a portion of this mucous membrane is habitually exposed to the external air. It adheres more firmly at the free edge of the lip than elsewhere.‡

The Glandular Layer.—This is a thick layer, situated between the mucous and the

* Mammalia alone have lips that are movable, independently of the jaws ; but this independence is still more marked in man.

† Much importance is attached to this furrow in semeiology. It is termed the abdominal line, because it becomes remarkably distinct in diseases of the abdomen.

‡ [The mucous membrane upon the free borders of the lip is provided with papillæ. Its epithelium, and, indeed, that of the entire mouth, is *squamous.*]

muscular layers, and causing an elevation of the former. It consists of small spheroidal glands of unequal size, placed close to each other, but perfectly distinct; when examined with a lens, they resemble small salivary glands, each being provided with an excretory duct, opening by a separate orifice upon the posterior surface of the mucous membrane.* These are true *labial salivary glands*, and not muciparous follicles.

The Muscular Layer.—This is composed essentially of a single proper muscle, the orbicularis oris, into which almost all the muscles of the face are inserted, viz., the levator labii superioris alæque nasi, the levator labii superioris, the depressor alæ nasi, the nasolabialis, and the zygomaticus minor (where it exists) for the upper lip; the quadratus menti and the levator labii inferioris for the lower lip; the buccinator (which we have regarded as forming the orbicularis by its bifurcation extending to both lips), and the zygomaticus major, the triangularis oris, the levator anguli oris, and the risorius of Santorini (where it exists) to the commissures. Including the orbicularis oris, there are twenty-five muscles. The differences presented by the free edges of the lips in different individuals depend upon variations in the thickness of the corresponding portion of the orbicularis.

No fibrous tissue enters into the composition of the lips and their commissures, which are exclusively formed of fleshy fibres: hence they are extremely extensible, a circumstance of which the surgeon avails himself in operating upon parts situated in the buccal cavity and pharynx.

Vessels, Nerves, and Cellular Tissue.—Few parts are so abundantly provided with vessels and nerves as the lips. The *arteries* of the lips are derived from two principal sources: the *coronary arteries* arise from the facial; the buccal, infra-orbital, and alveolar arteries destined for the upper lip, and the mental artery for the lower lip, arise from the internal maxillary. The sub-mental artery, a branch of the facial, and the transversalis faciei, a branch of the temporal, also give off some ramifications to the lips. The *veins* bear the same names, and follow the same direction as the arteries; the lymphatic vessels, which are little known, terminate in the glands at the base of the jaw. The *nerves* are derived from two distinct sources, viz., from the fifth and the seventh pairs of cranial nerves.

The *cellular tissue* contained in the substance of the lips is essentially of a serous nature. It is liable to a considerable amount of serous infiltration; but even in the fattest individuals it contains only a very small quantity of adipose tissue.

Development.—According to Blumenbach and most modern anatomists, the upper lip is originally developed from three points or three distinct parts: one median and two lateral. Some have even gone farther, and have maintained that the median point itself is originally formed of two lateral halves, which become united at a very early period. This hypothesis is founded partly upon the nature of the divisions in simple and double hare-lip, each of which has been assumed to be nothing more than an arrest of development; also, upon the mode of development of the superior maxillary bones, the alveolar border of which, it is said, is composed of four pieces: two median or incisor, and two lateral; and, lastly, upon the permanent existence of these divisions in some animals. In opposition to this view, however, we may state, first, the absence in the human fœtus of distinct bony pieces, corresponding to the ossa incisiva of the lower animals, for all that can be distinguished is a fissure, the mere trace of a separation (see *Development of the Superior Maxilla*, p. 51); and, secondly, that at no period of fœtal life can we demonstrate the existence of any division in the upper lip. This lip has always appeared to me to consist of a single piece from the earliest period of its formation. The same may be said of the lower lip, which, according to authors, is developed from two lateral halves. At no period of fœtal life can any such division be detected.† I do not even know an example of malformation in which such an arrangement existed.

The length of the lips of the new-born infant is well adapted for the act of sucking, and depends upon the absence of the teeth. To the same cause, and to the wasting of the alveolar borders, the length of the lips in advanced age must be referred.

Uses.—The lips, constituting the anterior wall of the mouth, form a sort of barrier in front of the teeth and alveolar arches, by which the saliva is retained within that cavity. So great is the importance of the lips in preventing a continual escape of the saliva, that in cases where they have been destroyed, the constant draining away of that fluid may become a cause of exhaustion, and even of death.‡

They are employed, also, in drinking, sucking, and blowing; in playing upon wind-instruments, and in uttering articulate sounds. They are also of great importance in the expression of the passions, which, as we have seen, influence all the muscles of the face. Pride, contempt, joy, grief, anger, and every possible gradation of feeling, are depicted in a striking manner upon the outline of the lips. The mouth is more particularly the

* When these orifices are obliterated, the dilated excretory ducts are transformed into salivary cysts, which may acquire a very large size.

† The admirable researches of M. Velpeau upon embryology fully confirm the results at which I have arrived.

‡ This use is principally confined to the lower lip, and it is remarkable that this lip is never affected by congenital fissure. Another singular, and also totally inexplicable fact, is, that cancer, which is so common a disease, never affects the upper, but invariably the lower lip.

seat of grimaces, which are nothing more than the expression of passions ridiculously exaggerated.

The Cheeks.

The *cheeks* form the lateral walls of the mouth and the sides of the face. They are bounded internally by the reflection of the mucous membrane upon the maxillary bones; externally their limits are much less defined, and are thus determined on each side of the face; in front, by the *bucco-labial* furrow, which separates them from the lips; behind, by the posterior border of the ramus of the lower jaw; above, by the base of the orbit; and below, by the base of the lower jaw. The cheeks, then, comprise three very distinct regions: the malar, the masseteric, and the buccal, properly so called. Each cheek is quadrilateral in form, and presents, 1. An *external* or *cutaneous surface*, on which is observed, above, the projection of the cheek, called the *malar eminence*, and lower down, a surface, which is convex and smooth in stout persons, but hollow and wrinkled in the emaciated; 2. An *internal* or *mucous surface*, free, and corresponding to the alveolar and dental arches. On this surface is situated the orifice of the Stenonian duct, opposite the interval which separates the first from the second upper large molar tooth.

Structure.—Each cheek, properly so called, is composed of the following parts: the malar bone and the ramus of the lower jaw; a cutaneous layer, increased in thickness by a great quantity of fat; a mucous, a glandular, a muscular, and an aponeurotic layer; some vessels and nerves, and an excretory duct. We shall make a few remarks upon these different layers, commencing with the skin.

The *skin* is remarkable for its firmness and vascularity over the cheek bone, and also for the facility with which it is injected, or becomes pale under the influence of the moral feelings; it is covered with hair on the lower and back part in the adult male.

The *mucous membrane* is a continuation of that of the lips, and presents the same characters.

The *glandular layer* is formed by the *buccal salivary glands*, which exactly resemble the labial glands, but are smaller, and, like them, cause projections of the mucous membrane, upon which they open by distinct orifices. Two of these glands have obtained a particular appellation, because they are not subjacent to the mucous membrane, but are situated between the buccinator and the masseter muscles: they are called the *molar glands*. Their excretory ducts open opposite the last molar tooth.

The *muscular layer* is formed, in the masseteric region, by the masseter and a part of the platysma; in the malar region, by the orbicularis palpebrarum; in the buccal region, properly so called, by the buccinator, and the two zygomatici.

The *aponeurotic layer* is formed by the aponeurosis of the buccinator muscle.

The *adipose layer* is thin in the malar and masseteric regions, and very thick in the buccal region, properly so called. Bichat has, moreover, pointed out a *mass of fat* in the substance of the cheek, between the buccinator and the masseter. It is highly developed in the infant, and vestiges of it are found even in the most emaciated individuals, and in extreme old age.

The *arteries* of the cheeks come partly from the facial and the transverse artery of the face, and partly from the internal maxillary: the branches from the internal maxillary belong to the infra-orbital, the inferior dental, the buccal, the masseteric, and the alveolar arteries.

The *veins* bear the same name, and follow the same course, as the arteries.

The *lymphatic* vessels pass into the cervical and parotid lymphatic glands.

The *nerves* of the cheeks, like those of the lips, are derived from two sources, viz., the buccal and malar nerves, from the portio dura of the seventh pair, and the buccal, masseteric, infra-orbital, and mental branches of the fifth pair.

The cheek is perforated by the *duct of Steno* (*s*, *fig.* 144), which runs horizontally forward, below the malar bone.

Development.—The absence of the teeth, the presence of a large quantity of fat (more especially the great size of the mass above noticed), the want of height in the superior maxilla from the non-development of the sinus, and, lastly, the obtuse angle of the lower jaw, give to the cheek of the infant its characteristic fulness. The loss of the teeth, and the wasting of the alveolar borders in the aged, diminish the inter-maxillary space; so that their emaciated cheeks become disproportionately long, and, consequently, display a looseness which forms one of the chief peculiarities in their physiognomy. At puberty, the cheeks of the male are covered with hair.

Uses.—The cheeks form lateral active walls of the mouth, which, closely applying themselves against the alveolar arches and teeth, force the food between the latter, and thus assist in mastication. They are employed, also, in suction, in the articulation of sounds, and in playing upon wind-instruments. In the expression of the passions, they assist rather by changes in their colour than by any distinct movements.

The cheeks and the lips constitute the outer wall of a supernumerary buccal cavity, of which the inner wall is formed by the alveolar borders and the teeth. This cavity, a sort of vestibule to the buccal cavity, properly so called, is very dilatable. It may be

considered as a kind of reservoir, in which the food is deposited, in order to be submitted in successive portions to the action of the masticatory organs. This vestibular buccal cavity is provided with labial and buccal salivary glands. It is also interesting to find that the parotid glands, the largest of all the salivary glands, pour their secretion into this cavity.

The Palatine Arch and the Gums.

The *palatine arch*, or the hard *palate* (*a*, *fig*, 140), constitutes the upper wall of the buccal cavity. It has the form of a parabolic arch, bounded in front and on either side by the teeth, and behind by the velum palati, into which it is continued without any distinct line of demarcation. Upon it we observe, in the median line, an antero-posterior *raphé*, at the anterior extremity of which is a tubercle corresponding to the lower orifice of the anterior palatine canal. This tubercle has been incorrectly stated by physiologists to be endowed with a peculiar sensibility ; on each side and in front there are transverse ridges, more or less marked in different individuals, which represent the still more highly-developed ridges, bars, or calcareous concretions, which render the surface of the roof of the palate in some animals so rugged. Posteriorly, the roof of the palate is perfectly smooth.

Structure.—The constituent parts of the palatine arch are an osseous framework, a fibro-mucous membrane, a layer of glands, with vessels and nerves.

The framework consists of the bony palate already described : it is thicker in front than behind, and is held up in the middle by the sort of column formed by the vomer and the perpendicular plate of the ethmoid, and behind and on each side by the vertical portions of the palate bones, and by the pterygoid processes. We have already noticed the asperities which it presents, and which appear to have no other object than to secure the intimate adhesion of the fibro-mucous membrane to the bones.

The Palatine and Gingival Membrane.—This mucous membrane is remarkable for its whitish colour ; for the thickness of its epithelium, especially in front ; for the thickness and density of its chorion, which even approaches to that of the corresponding tissue in the skin ; for its close adhesion to the bones, into which the chorion sends off well-marked fibro-cellular prolongations ; and, lastly, for the great number of orifices with which it is perforated, especially behind. This excessive thickness of the palatine membrane, however, is observed only anteriorly, and most particularly so behind the incisor teeth.

The Glandular Layer.—In the median line the palatine membrane is blended with the periosteum of the bones, but on each side it is separated from it by a very thick layer of glands, which are sometimes arranged in regular rows along the antero-posterior groove presented by the palatine arch. These *palatine salivary glands* are exactly similar to the labial and buccal glands already described ; they are much more numerous behind than in front, and open upon the membrane by a number of orifices visible to the naked eye. There are often two openings much more distinctly marked than the rest, situated one on either side of the posterior extremity of the median raphé.

The Gums.—The description of the peculiar tissue of the *gums*, to which some allusion has been made in speaking of the teeth, naturally follows that of the palatine membrane. The term gums (*οὐλὰ*) is applied to those portions of the buccal mucous membrane which surround the teeth. They are distinguished from the rest of that membrane by their intimate adhesion to the periosteum, by their thickness, and especially by their almost cartilaginous density, which enables them to resist the shocks of hard bodies during mastication. In this latter respect, and in regard to their want of sensibility, the gums closely resemble the contiguous portions of the palatine membrane. They commence about a line from the base of the alveoli, their limits being marked by a scalloped ridge. Having reached the free margins, *i. e.*, the base of the alveoli, the gums continue their course for the space of about a line beyond that point, as far as the neck of the teeth, where they become reflected upon themselves. The point of reflection is a free border of a semilunar shape, corresponding to the indented, and, as it were, festooned border of each alveolus. The denticulations or longest portions of the gums correspond to the intervals between the teeth, in which situation the processes of the gum, covering the anterior and posterior surfaces of the alveoli, communicate with each other.

The *reflected portion* of the gum, though not adhering to, is in contact with, all that portion of the root of the tooth which projects above the alveolus ; it then dips into the cavity of the latter, so as to form the *alveolo-dental periosteum*, which, as we have already seen, is a powerful means of connecting the fang of the tooth to its socket. The tissue of the gums appears to be provided with particular follicles for the secretion of the tartar.* It varies much in different individuals, both in colour and in density. One of its most peculiar characters is the singular effect produced on it by scurvy and by mercury, under the influence of which agents it becomes softened and fungous, easily bleeds, and furnishes a large quantity of tartar.* Another, but purely anatomical character, consists in its largely-developed openings or pores, which, in a particular light, are even visible

* [These are mucous follicles : the tartar is now known to be merely a deposite from the saliva ; its increased amount during mercurial salivation is, therefore, readily accounted for.]

to the naked eye. The gums are almost insensible when divided by cutting instruments; but the pressure exerted upon them by the teeth, during the eruption of the latter, often gives rise to the most serious affections.

Vessels and Nerves of the Roof of the Palate and the Gums.—The *arteries* arise, some from the internal maxillary, viz., the posterior palatine, the alveolar, the infra-orbital, and the mental branches; others from the facial, viz., the superior coronary for the gums of the upper, and the sub-mental branches for those of the lower jaw; the sub-lingual artery also supplies the latter. The *veins* bear the same name. All the *nerves* proceed from the fifth pair, viz., the palatine and the superior and inferior dental branches. The naso-palatine nerve sends ramifications to the small median tubercle upon the roof of the palate. Few parts have so little cellular tissue as the gums.

Development.—According to the best authorities, the bony and membranous portions of the hard palate are developed from two lateral points, which unite along the median line, so that the malformation known by the name of harelip with cleft palate, is said to be an arrest of development. The fissure may be either single or double in front. If the cleft be double, that portion of the upper jaw which supports the incisor teeth is separated on both sides from the rest of the bone. Such divisions always seem to me to be absolutely departures from nature,* for at no period of its growth can such separations or clefts be detected in a naturally-formed fœtus.

Uses of the Gums and Hard Palate.—The hard palate separates the buccal cavity from the nasal fossa. It serves as a fulcrum for the tongue in the act of tasting, in mastication, deglutition, and the articulation of sounds. Before the eruption of the teeth, the gums completely close the alveoli, and serve as the immediate instruments of mastication; and they become hard, and supply the place of the teeth after the loss of those organs. The gums have great influence in fixing the teeth within their sockets, and hence the loosening of the former from scurvy or from the abuse of mercury. We may consider the gums as that portion of the mucous membrane in which the dental follicles are situated.

The Velum Palati and Isthmus Faucium.

Dissection.—The lower surface of the velum palati may be seen by forcibly depressing the lower jaw, or still better by sawing it across in the median line, and separating the two halves. In order to see its upper surface, the pharynx must be removed entire, and its posterior wall divided vertically (as in *fig.* 141). The dissection of the different layers which enter into the formation of the velum palati, and of its extrinsic and intrinsic muscles, will be understood from the following descriptions:

External Conformation.—The *velum palati*, or *soft palate* (*c*, *fig.* 140), is a muscular and membranous valve, which prolongs the palatine arch backward, and, therefore, might be called the *membranous palatine arch*. It is a sort of incomplete septum (septum staphylin, *Chauss.*), dividing the buccal cavity from the nasal fossæ and the pharynx.

Its *direction* is curved: its upper portion is horizontal, but it soon becomes curved, and passes almost directly downward (velum *pendulum* palati). In the act of deglutition, the velum becomes horizontal during the passage of the alimentary mass, but immediately afterward returns to its oblique and pendulous position, and thus tends to prevent the return of the food into the mouth. In several pathological conditions the velum is thrown backward and upward, and adheres to the posterior orifices of the nasal fossæ. All these changes of direction affect the oblique, and not the horizontal portion of the velum. The velum palati is broad, quadrilateral, and perfectly symmetrical. Its *inferior* or *buccal surface* is concave, and continuous with the hard palate, without any line of demarcation. This surface is very well seen when the mouth is opened, and is, therefore, easily accessible to the surgeon. In the median line it presents a white raphé, which is a continuation of the median raphé of the hard palate; it is formed by a small fibrous cord, causing a projection under the mucous membrane.

The *superior* or *nasal surface* of the velum (*fig.* 141) is convex: it prolongs the floor of the nasal fossæ, and, from its obliquity, directs the mucus into the pharynx. This surface presents a median projection produced above by the palato-staphylin muscles (azygos uvulæ, *a*), and below by a mass of glands. Congenital division of the velum is always situated in the median line, and is followed by so great a retraction of its two halves, that, in some cases, the entire absence of the velum has been suspected.

Its *upper border* is thick, and firmly united to the posterior border of the hard palate.

Its *lower border* is free, extremely thin and concave, and forms the upper boundary of the isthmus (*t*, *fig.* 141) of the fauces: it presents, in the middle line, a sort of appendix or prolongation, called the *uvula* (*u*, *fig.* 140): this is of a conical shape, and of very variable size and length; it is capable of considerable elongation, and may then reach the base of the tongue, but not, as has been supposed, the upper orifice of the larynx.† It is not very uncommon to find it bifid, and sometimes it is entirely wanting.

* [*I. e.*, not mere arrests of development.]

† In consultation upon a case of chronic laryngitis, I was much surprised to hear the medical attendant state that the disease was the result of irritation produced by the uvula upon the superior orifice of the larynx. The position of the uvula is always a few lines in advance of the epiglottis.

The two *lateral* borders of the velum limit it on each side, and separate it from the cheek. This boundary is indicated (on each side) by a prominent ridge (before *f*, *fig.* 140), extending from the posterior extremity of the upper to the corresponding part of the lower alveolar border. This prominence corresponds to the anterior margin of the internal pterygoid muscle, and is formed, in a great measure, by a series of small, glandular structures, which are collected behind the last great molar tooth of the lower jaw into a considerable mass resembling a small gland.

The *pillars* of the *velum palati*. These are two *lateral* columns or *pillars*, having an arched form, and distinguished into *anterior* (behind *f*, *fig.* 140) and *posterior* (*g*), which pass down on either side from the uvula. Each of the *anterior pillars* (the two forming together the anterior arch of the fauces) proceeds from the base of the uvula outward, and then vertically downward, describing a curve with its concavity directed inward, and terminates at the sides of the tongue, opposite the anterior extremities of the V-shaped series of papillæ vallatæ found upon that organ. Each of the *posterior pillars* (which together form the posterior arch of the fauces) commences at the apex of the uvula, and immediately curves into an arch, having a smaller diameter than that represented by the anterior pillar, and then passes obliquely downward, backward, and outward, to its termination on the sides of the pharynx. The two posterior pillars constitute the free margin of the velum. They project much farther inward than the anterior pillars, so that when the base of the tongue is depressed in the living subject, both sets of pillars can be seen at the same time, like double curtains, placed on different planes. Each of these pillars represents a triangle, having its base below and its apex above.

The Amygdaloid Fossa.—From the direction of the anterior and posterior pillars, they approach each other above, and are separated by a considerable interval below. This interval, which is partly occupied by the tonsil (*n*), may be called the *amygdaloid excavation*. In order to have a good idea of it, it is necessary to make a vertical section of the head from before backward. A sort of recess will then be observed, narrow and shallow above, but very broad and deep below, especially when the tonsil (*n*) is small. The base of this fossa corresponds anteriorly to the base of the tongue (*b*), then to the epiglottis (*i*), the larynx, and the walls of the pharynx: the bottom of the fossa corresponds to the angle of the lower jaw and the lateral portion of the supra-hyoid region, where it is separated from the skin only by a thin layer of soft tissues. The dimensions of this fossa always remain the same above, but are very variable below, according as the tongue is retained in the mouth or protruded.

The Isthmus Faucium.—The posterior orifice of the buccal cavity is called the *isthmus faucium* (2, *figs.* 140, 141). It is a sort of passage between the buccal and the pharyngeal cavities, bounded below by the base of the tongue, above by the free margin of the velum palati, divided into two arches by the uvula in the middle, and the two pillars on each side. This posterior orifice of the mouth, though very dilatable, is less so than the anterior opening of the same cavity. It may be contracted, and even completely closed, not only from inflammation of the tonsils and arches of the fauces, but also from the contraction of the muscles which enter into the formation of the velum and its pillars. This may be seen by watching the movements of the isthmus of the fauces in a person who will submit to such an examination. These differences in the dimensions of the isthmus are concerned not only in deglutition, but also in the modulations or articulations of the voice.

Structure.—In the velum palati we find an aponeurotic framework; also certain muscles by which it is moved, which are either extrinsic or intrinsic. The intrinsic muscles are those constituting the azygos uvulæ, viz., the palato-staphylini; and the extrinsic muscles are four on each side, two descending, viz., the levator palati, and the circumflexus or tensor palati, and two ascending, viz., the palato-glossus, and the palato-pharyngeus. We also find in the soft palate a thick layer of glands, vessels, nerves, and cellular tissue; and, lastly, a covering of mucous membrane.

The Aponeurotic Portion.—The aponeurotic portion, or, rather, the principal aponeurosis, is extremely dense, and continues the hard palate backward: it is generally regarded as an expansion of the reflected tendons of the tensores palati, but it is, in a great measure, formed of proper fibres continuous with the fibrous tissue, which prolongs backward the septum narium, the outer borders of the posterior orifices of the nasal fossæ, and the fibrous portion of the Eustachian tube. Below this aponeurotic membrane there is another *fibrous lamella*, continuous with the fibrous tissue found in the hard palate. The framework of the upper half of the velum palati may, therefore, be said to be formed of two fibrous layers, one superior, the other inferior, between which the glandular layer is situated. Lastly, a small fibrous band extends from the nasal spine to the uvula, along the median raphé, upon the lower surface of the velum, producing a slight elevation of the mucous membrane. This little band sends off a prolongation between the glands of the velum, which separates the right half of the soft palate from the left.

The Muscles of the Velum Palati.

Dissection.—This is common to all the muscles of the soft palate. It is merely necessary to remove the mucous membranes and the subjacent glands, in order to study the

arrangement of these muscles, and to follow the ascending and descending fibres which emerge from or enter into the velum.

The Azygos Uvulæ, or Palato-staphylini.

The palato-staphylini (*a, fig.* 141) are two small, fleshy, cylindrical bands placed in contact, one on each side of the median line, and extending from the posterior nasal spine, or, rather, from the aponeurosis continuous with it, to the base of the uvula. They are covered by the mucous membrane of the nose, under which they form a projection, and they cover the levatores palati. The two muscles, from their juxtaposition, appear, at first sight, to form a single rounded muscle, to which the names *azygos uvulæ, columellæ musculus teres*, have been given.

Fig. 141.

Action.—To raise the uvula.

The Levator Palati, or Peristaphylinus Internus.

Dissection.—Remove the mucous membrane from a vertical ridge which exists along the outer border of the posterior orifice of one of the nasal fossæ, behind the Eustachian tube; then remove the mucous membrane covering the upper surface of the soft palate.

The vertical portion of the *levator palati* (le petro-salpingo staphylin, *Winslow*; petro-staphylin, *Chauss.*, *c, figs.* 141, 146) is situated upon the outer side of the posterior orifice of the corresponding nasal fossa; its horizontal portion is in the substance of the velum; it is thick, narrow, and rounded above, expanded and triangular below. It *arises* by short tendinous fibres from the lower surface of the petrous portion of the temporal bone, near its apex, and from the contiguous part of the cartilage of the Eustachian tube. From these points its fibres pass obliquely downward and inward, turning round the outer side of the tube. At the outer border of the velum palati the muscle becomes horizontal, and its fasciculated fibres diverge, so as to cover the whole extent of the antero-posterior diameter of the velum.

The anterior fleshy fasciculi are *inserted* by short tendinous fibres into the posterior border of the aponeurosis of the soft palate. The others also terminate by very short tendinous fibres, which are blended in the median line with those of the opposite side, immediately below the azygos uvulæ.

Relations.—It is covered by the mucous membrane of the pharynx and soft palate; its vertical portion is in relation, on the outside, with the circumflexus palati and the superior constrictor muscles, and its horizontal portion with the palato-pharyngeus. It forms the uppermost muscular layer of the soft palate.

Action.—It raises the velum (elevator palati mollis, *Albin.*, *Sœmm.*). The length of its fibres, its direction, and its shape, render it well fitted for this purpose. It should be remarked, that the tendinous portion of the velum scarcely participates in the movement of elevation.

The Circumflexus or Tensor Palati, or the Peristaphylinus Externus.

This is a thin, flat, and reflected muscle (le pterygo or spheno salpingo staphylin, *Winsl.*; pterygo-staphylin, *Chauss.*), and is tendinous for a considerable part of its extent; its vertical portion (*d, fig.* 141, 146) is situated along the internal plate of the pterygoid process, to the inner side of the internal pterygoid muscle (*b*), and its horizontal portion (*d*) in the substance of the velum.

Attachments.—It *arises* from the fossa navicularis, at the base of the internal pterygoid plate, from the contiguous part of the great wing of the sphenoid, and from a small portion of the cartilage of the Eustachian tube. From these points the muscle, which forms a thin fasciculus, flattened at the side, passes vertically downward: near the hamular process of the internal pterygoid plate it becomes a shining tendon, which changes its direction, and is reflected at a right angle under that process: it is retained in this situation by a small ligament, and its motions are facilitated by a synovial membrane. The tendon then passes horizontally inward, expands, and becomes blended with the aponeurotic membrane.

Relations.—Its vertical portion is in relation on the outside with the internal pterygoid, and on the inside with the levator palati, from which it is separated by the superior constrictor of the pharynx (*g, fig.* 141) and by the internal pterygoid plate. Its horizontal or aponeurotic portion is anterior to the levator palati, and has the same relation as the aponeurotic portion of the velum.

Action.—It is a tensor of the aponeurotic portion (*tensor palati*), but does not otherwise move the velum. As Haller has remarked, when its fixed point is below, it can dilate the Eustachian tube.

The Palato-pharyngeus, or Pharyngo-staphylinus.

This muscle (thyro-staphylinus, *Douglas, e e, fig.* 141) is narrow and fasciculated in the

middle, where it is situated in the posterior pillar of the fauces, broad and membranous at its extremities, one of which is in the velum and the other in the pharynx.

Attachments.—It arises from the whole extent of the posterior border of the thyroid cartilage. From this point it passes vertically upward, and forms a broad and thin muscular layer, the fibres of which are first collected into a fasciculus or muscular column, which enters the posterior pillar of the fauces, and then, again expanding, occupy the whole extent of the antero-posterior diameter of the velum, and unite in the median line with the muscle of the opposite side, so as to form an arch. The anterior fibres are *inserted* into the posterior border of the aponeurosis of the velum.

Relations.—It forms the lowest muscular stratum of the velum: it is separated from the mucous membrane below by the layer of glands: it is in relation above with the muscular layer formed by the expansion of the levator palati. In the posterior pillar it is in relation with the mucous membrane, which covers it in all directions, excepting on the outside. In the pharynx it forms the innermost muscular layer, *i. e.*, it lies between the constrictors and the mucous membrane.

Action.—The two palato-pharyngei draw the velum downward, and press it strongly against the alimentary mass during deglutition; they therefore form a constrictor of the isthmus of the fauces. When they take their fixed points above, they raise the posterior wall of the pharynx. They are important agents in deglutition.

The Palato-glossus, or Glosso-staphylinus.

This is a small fleshy bundle (*o*, *fig.* 141) situated in the anterior pillar of the fauces, narrow in the middle, and broad at the extremities. Its lower extremity is expanded upon the side of the tongue, and is united with the stylo-glossus. Its upper extremity spreads out in the velum palati, and becomes blended with that of the palato-pharyngeus. Its middle portion is very slender; it forms the anterior pillar, and is visible through the thin mucous membrane by which it is covered.

Action.—The two muscles depress the velum palati, and raise the edges of the base of the tongue; they consequently constrict the isthmus faucium.

The Glandular Layer of the Velum Palati.—Under the mucous membrane covering the upper surface of the velum palati, there are some scattered glands, which are more numerous on the sides than along the middle; but on the lower surface of the velum there is a much more obvious collection of glands, particularly dense, opposite the aponeurotic portion of the velum, and forming a continuation of the glandular layer of the hard palate. Similar glands are found in the uvula, the size, and, in some measure, the form of which they determine. These small glands in the velum exactly resemble the salivary glands already described as existing in the lips, the cheeks, and the roof of the palate.

The Mucous Membrane.—Both surfaces of the velum are covered by mucous membrane, which constitutes, as it were, its integuments. These two mucous layers are remarkable, inasmuch as each presents the peculiar characters of the cavity to which it belongs. Thus, the lower layer preserves the characters of the buccal mucous membrane, and the upper layer those of the nasal.* The two layers are continuous with each other along the free margin of the velum palati; the fold of mucous membrane forming this margin passes beyond the other constituent tissues, so that, for the space of half a line or a line, the two mucous layers are in contact. The same occurs in the uvula, the apex, and sometimes the lower half of which consists of a duplicature of mucous membrane, containing some loose cellular tissue, which is very susceptible of infiltration. Either serous or sanguineous infiltration of the uvula produces an elongation of this part, called *relaxation* of the uvula. I should not omit to mention the great difference, in regard to sensibility and liability to inflammation, that exists between the mucous membrane of the free and adherent borders of the velum palati.

Vessels and Nerves.—These are very numerous in proportion to the size of the part. The *arteries* arise from the palatine and the superior and inferior pharyngeal. The *veins* are similarly named, and follow the same course. The *lymphatic vessels*, which have been little studied, enter the lymphatic glands at the angle of the jaw. The *nerves* are derived from the palatine branches given off by Meckel's ganglion, and from the glosso-pharyngeus.

Development.—We have here again the question, whether the velum is formed originally from two halves, which afterward become united in the median line; in favour of this view we may adduce those cases in which the uvula and the velum are bifid, either with or without fissure of the hard palate and lip. In the youngest embryos which I have examined, I have always found the velum undivided.

Uses.—The velum palati is a contractile valve, which fulfils very important functions in deglutition, in the utterance of articulate sounds, and in the modulation of the voice; it is capable of being elevated and depressed. Elevation affects its muscular, but not its

* [According to the recent researches of Dr. Henlé, the ciliated columnar epithelium (like that of the nasal mucous membrane) is found upon the upper surface of the velum, only in the neighbourhood of, and a short distance below, the expanded orifice of the Eustachian tube; the remaining portion of the upper surface, as well as the free border, and the whole of the lower surface, are covered with the squamous epithelium, similar to that of the buccal mucous membrane.]

tic portion: this movement cannot be carried so far as to revert the velum upepression may be carried to such an extent as to close the isthmus faucium by ximation of the velum and the base of the tongue. The contraction of the pangei, which are curved muscles, may be so complete as to bring the posterior pillars of the fauces into contact, and thus close the isthmus in a transverse direction. The uvula moves independently of the velum. When the aponeurosis of the velum palati is rendered tense, the velum itself is enabled to resist both elevation and depression.

The Tonsils, or Amygdalæ.

The terms *amygdalæ* (*ἀμυγδαλέα*, an almond), or *tonsils*, are applied to a group of mucous follicles (*n*, *fig.* 140) which occupy the interval between the pillars of the fauces on each side. They are placed there on account of the necessity of lubricating the isthmus during the passage of the alimentary mass. Their form pretty nearly resembles that of an almond; they are directed obliquely downward and forward, and their size is exceedingly subject to either congenital or accidental variation. In some subjects they can scarcely be said to exist; in others they fill up the whole amygdaloid fossa, and project more or less into the isthmus of the fauces, so as to impede deglutition, or even respiration.

The compound tonsil results from its component follicles being collected into several distinct masses.

The *internal surface* is free, and may be seen when the base of the tongue is depressed; it is perforated by foramina, like the ligneous shell of an almond. These foramina, which vary in number and size, have been frequently mistaken for syphilitic ulcerations. They lead into small cells, in which mucus sometimes collects, and is then ejected in hard fetid lumps, which have been erroneously supposed to be pulmonary tubercles. Its *external surface* is covered immediately by the aponeurosis of the pharynx,* and then by the superior constrictor.

The tonsil corresponds to the angle of the lower jaw. Compression behind this angle, therefore, affects it at once, and causes pain in cases where it is inflamed. It has an important relation with the internal carotid artery, especially when that vessel, describing a curve with the convexity directed inward, touches the tonsil. In front the tonsil is in relation with the anterior pillar of the fauces, and, therefore, with the palato-glossus muscle; behind, with the posterior pillar, and, accordingly, with the palato-pharyngeus muscle.

Structure.—In structure the tonsils are intermediate between mucous follicles and glands; they consist of an agglomeration of follicles, continuous with those at the base of the tongue. Groups of these follicles open into small cells or lacunæ, which again open upon the internal surface of the tonsil by the foramina already described. The mucous membrane covers the inner surface of the tonsil, and, penetrating through the foramina, lines the interior of all the cells.

The *arteries* are very large, considering the size of the organ. They are derived from the labial, the inferior pharyngeal, the lingual, and the superior and inferior palatine. The *veins* form a plexus round this organ, called the *tonsillar* plexus; it is a dependance of the pharyngeal plexus. The *lymphatic vessels* terminate in the glands found near the angle of the jaw; hence the inflammation or enlargement of those glands in consequence of inflammation of the tonsil. The lingual and glosso-pharyngeal *nerves* form a plexus outside the tonsil, which gives off some branches to it.

The Tongue.

The *tongue*, the principal organ of taste, is situated within the buccal cavity, and, consequently, at the commencement of the digestive passages (*b*, *fig.* 140) behind the lips, which in many animals are organs of prehension; also behind the teeth, the organs of mastication, and below the organ of smell, which possesses the sense of taste in the lower tribes, and is necessary in all animals for the perception of flavours. It is a muscular organ, free and movable above, before, and on the sides. It is retained in its position by ligaments which attach it to the os hyoides; and, by muscles connecting it to the same bone, to the styloid processes and to the lower jaw; so that it appears to me anatomically impossible for persons to have been destroyed by swallowing their tongues, as some historians have related. Nor do I believe, notwithstanding the authority of J. L. Petit, that division of the frænum in infants may be followed by a similar accident.

The *size* of the tongue, though variable in different individuals, is always proportional to the curve described by the lower jaw; it is not large enough to fill the buccal cavity completely when the jaws are closed. It has not been satisfactorily proved that too large a tongue is the cause of certain defects in speech. However, a natural size is not absolutely necessary for the exercise of its functions, for these are performed even when considerable portions have been removed from its apex and sides.

Direction.—Its anterior portion is horizontal; behind, it slopes downward and backward, and curves abruptly, so as to become vertical and reach the os hyoides, which in some measure constitutes its base. This direction, which is maintained so long as the

* The existence of this aponeurosis explains why the tonsil always becomes enlarged internally, and also why abscesses of this part never open externally.

tongue is within the mouth, is somewhat altered when it is protruded, the tongue then becoming horizontal, and the os hyoides raised.

Figure.—Examined without any anatomical preparation, the tongue appears of an oval figure, having its great end behind. Its form is determined, and, as it were, measured, by the parabolic curve of the lower jaw, by which it is circumscribed. When separated from the neighbouring parts, it represents an ellipse, with its long diameter from before backward. It is perfectly symmetrical, flattened above and below, narrow and thin in front, and increasing in thickness and in breadth from before backward. Its figure, which has itself become a term of comparison, does not appear to be essential for the articulation of sounds, a function that would at first appear to be peculiarly connected with this form.

The tongue presents for our consideration an upper and a lower surface, two edges, a base, and an apex.

Fig. 142.

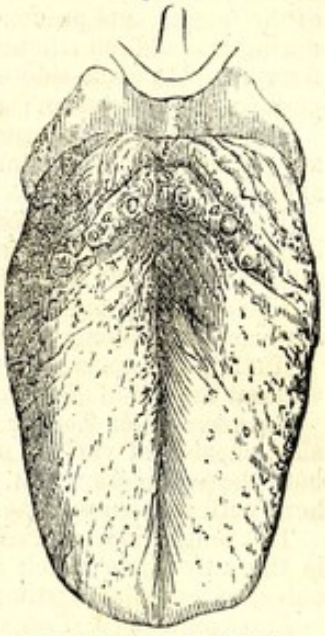

The Upper Surface or Dorsum of the Tongue. — This is free in the whole of its extent, corresponds to the roof of the palate, and is divided into two lateral halves by a median furrow, which often limits the progress of disease. It is covered by innumerable eminences, which render it very rough; these should be distinguished into such as are perforated, viz., the glandular eminences, and such as are entire, and have no orifice, viz., the *papillæ* (*papilla*, a nipple).

The *perforated eminences*, or *lingual glands*, improperly classed among the papillæ, and known under different names, may be distinguished by their circular openings, which are perfectly visible to the naked eye; by their being situated only at the base of the tongue; by their rounded form, and their having no pedicle; by the arrangement of the mucous membrane, which passes over without adhering to them;* and, lastly, by dissection, which most distinctly reveals their glandular nature. These lingual glands, moreover, are not follicles, but true glandular organs, analogous to the labial and buccal glands. They form a V-shaped ridge, strongly marked in some subjects, and bounded in front by the ridge (*a a*, *fig.* 142) of the same shape, formed by the caliciform papillæ.

All the other eminences of the tongue are papillæ, which we may describe as the *large* and the *small*.

The *large papillæ* are called *caliciform:* they are arranged in two lines (*a a*, *fig.* 142), united like the limbs of a V, open in front. Their number varies from sixteen to twenty, some of which are placed irregularly. Haller has seen them forming two rows on each side. Their size is also variable, but they are larger than all the other papillæ. Each papilla forms a truncated and inverted cone, the base of which is free, and the truncated apex adherent (papillæ truncatæ, *Haller*; papilles boutonnées ou à tête, *Boyer*). They are placed in a sort of calyx or cup, or surrounded by a circular trench: hence the name of papillæ circumvallatæ (papilles caliciformes, *Cuvier*). The border or rim of this cup is itself a circular papilla.†

At the angle of union of the two rows of these glands is a *blind opening* (*b*), which is frequently wanting, and generally known as the foramen cæcum of *Morgagni* (lacune de la langue, *Chaussier*). Several anatomists of the last century affirmed that certain supposed salivary ducts, which were afterward shown to be merely veins, had their termination in this foramen; it is now generally considered to be a cul-de-sac for the reception of the secretion from several follicles; but it appears to me to be only the cavity of a calyx, the papilla corresponding to which is very imperfectly developed. When the papilla is more developed, or the calyx less deep than usual, the foramen cæcum is said to be wanting.

The Small Papillæ.—These occupy all that part of the dorsal surface of the tongue which is in front of the V-shaped ridge, formed by the papillæ circumvallatæ; they present many varieties. Some of them are *conical*, others *filiform;* some are pointed like a reed, and others are *lenticular* or *fungiform*, that is, flattened at the top, and supported by a narrow pedicle; but the conical or filiform are evidently the most numerous, for they occupy of themselves the anterior portion and the apex of the tongue, while all the other varieties are disseminated between them. They are directed obliquely backward,

* [*I. e.*, without being closely united to their *outer* surface, as it is to that of the papillæ. The mucous membrane, as in all glands, is really prolonged into their interior.]

† The want of a uniform nomenclature for the papillæ of the tongue has occasioned great obscurity. I do not know two authors who agree in this respect. M. Boyer calls the lingual glands *papilles lenticulaires;* the caliciform papillæ, *papilles boutonnées ou à tête;* and applies the term *papilles coniques* to the papillæ generally known by that name. Gavard called the glands *papilles muqueuses;* and the caliciform papillæ, *papilles fungiformes*. M. H. Cloquet appears to have confounded both the glands and the caliciform papillæ under the name of *papilles lenticulaires;* the *papilles fungiformes*, according to him, are irregularly disseminated over the edges and apex of the tongue. The use of the term conical papillæ is the only point in which they are all agreed.

so that, by rubbing the tongue slightly from behind forward, they may be brushed up, and their exact shape and length ascertained. This oblique direction is much more marked in the lower animals than in man.

The conical papillæ are sometimes arranged in regular or irregular lines, so as to give the tongue a fissured appearance. Sometimes even several papillæ are united in a line, so as to form a jagged ridge. We may add, that there is very great variety both in the shape and arrangement of the lingual papillæ.*

The *lower surface* of the *tongue* is free only in its anterior third, the muscles which connect the tongue to the neighbouring parts being attached to the posterior two thirds. On the free portion, which we shall alone notice here, is observed a median furrow, more distinct than that on the upper surface. At the posterior part of this furrow is a fold of mucous membrane, called the *frænum linguæ*, which is sometimes prolonged to the apex of the tongue, and prevents the movements of that organ, both in the act of sucking and during articulation: hence the necessity for the operation known as the division of the frænum. On each side of this furrow are seen the ranine veins, on which the ancients performed venesection; also an antero-posterior projection formed by the lingual muscle.

The *edges* of the tongue are thick behind and thinner towards the point. The papillæ are prolonged in a regular manner upon their upper half in a series of vertical and parallel lines.

The actual *base* is fixed to the os hyoides: the apparent base, which is seen at the back of the dorsal surface, presents three *glosso-epiglottid* folds, of which the median (above *b*, *fig.* 142) is much larger than the other two.

The *apex* is situated immediately behind the incisor teeth; the median furrows of both surfaces are prolonged upon it.

Having thus examined the peculiarities offered by the external surface of the tongue without the aid of dissection, we shall now examine its structure.

Structure of the Tongue.—The tongue being the organ of one of the senses, and being, also, capable of various movements, we must examine its structure with reference to both these objects. But, after the example of Haller,† we shall be principally occupied here with its structure as a movable organ.

The tongue is essentially composed of muscular fibres, and, in this respect, the heart is the only organ which can be compared to it. Its framework consists of the os hyoides, of a median cartilaginous lamina, and of its papillary membrane.

Framework of the Tongue.—The os hyoides, already described (seen in *fig.* 143), is truly the bone of the tongue: hence it has been called the lingual bone by some anatomists. In man it is not prolonged by a process into the substance of the tongue, as in the lower animals, but is united to it by the hyo-glossal membrane, which commences at the posterior lip of the body of this bone; and, again, since the os hyoides is united to the thyroid cartilage (*t*) by ligaments, it follows that all the movements of this bone are communicated both to the tongue and to the larynx, between which parts it is situated. From the middle of this fibrous membrane, the *median cartilaginous lamina* of the tongue, described by M. Blandin, proceeds. This lamina, which is perfectly distinct from the cartilage described by M. Baur in the dog and the wolf,‡ is situated in the median line; it is directed vertically, and gives attachment to some muscular fibres by its two lateral surfaces; its upper edge is thin, and reaches the middle of the dorsal region of the tongue; its lower edge is seen between the genio-hyo-glossi, where it is either free or covered by a few muscular fibres which interlace below it. It is thick behind, but thin in front, where its fibres have a number of intervals between them, like those in the septum of the corpora cavernosa penis.

I regard the *papillary membrane* as part of the framework of the tongue, on account of its density, which is so great that it is with difficulty cut by the scalpel. Moreover, a great number of the muscular fibres terminate in it.

The Muscles of the Tongue.

These are either intrinsic or extrinsic.

The Intrinsic Muscles.—The ancients regarded the tongue as a single muscle, the structure of which they did not attempt to unravel. Columbus was the first to consider this organ as composed of two juxtaposed muscles. If the texture of the tongue be examined by means of sections made in different directions, it will be found to be composed of an interlacement of muscular fibres, which will, indeed, appear to be inextricable. Among these different sections, I would principally call attention to a vertical section, made at right angles to the axis of the tongue. This section presents a pale muscular

* [All these kinds of papillæ are extensions of the mucous membrane, and are, therefore, composed of similar elements. The papillæ vallatæ contain many loops of vessels, the papillæ conicæ, in general, only a few; all are abundantly supplied with nerves.]

† Haller treats of the muscles of the tongue when describing the organ of voice (lib. ix., sect. ii., p. 421), and of the papillary membrane with the organs of the senses (lib. xiii., sect. i., p. 99).

‡ The cartilage described by Baur is a fibrous cord, subjacent to the mucous membrane, and occupying the median line on the lower surface of the tongue. It extends from the apex of the latter, where it is very well marked, to the base, where it terminates in a cellular raphé.

tissue in the centre, in which successive layers of vertical and transverse fibres may be distinguished. A soft, fatty substance, the *lingual adipose tissue*, is interposed between these muscular fibres; it is analogous to the fat formed at the base, or, sometimes, among the fibres of the ventricles of the heart; it increases in quantity towards the base of the tongue, but is entirely wanting at the apex. Around this central part of the tongue, which may with propriety be called, after M. Baur, the *lingual nucleus* (*noyau lingual*), we find a very thin layer of red fibres situated above, a somewhat thicker layer on each side, and a much thicker layer below; the lateral and inferior layers belong to the extrinsic muscles.

A *transverse vertical section*, therefore, demonstrates the presence of vertical and transverse fibres in the tongue: an *antero-posterior vertical section* shows that there are fibres running from one end of the organ to the other, and will also display the vertical fibres already mentioned. Thus, by means of simple sections, we can demonstrate the existence of *longitudinal* fibres running from the base to the apex of the tongue; of *vertical* fibres passing from the upper to the lower surface; and of *transverse* fibres extending from one side to the other; and other dissections will confirm this statement. Though Malpighi,* in a memoir of great interest, had very exactly described and figured the arrangement of the three orders of fibres in the tongue of the calf; though Steven proved their existence in the human tongue, and Bidloo had carried his observations still farther; and although Massa had recommended that, to facilitate this investigation, the tongue should be previously boiled, or should be examined after putrefaction had commenced; still, almost all anatomists, including Haller, neglected this subject, until MM. Baur, Gerdy, and Blandin directed attention to it almost at the same time. From the examination of the boiled tongues of the ox, the sheep, and man, I have observed the following facts:

1. Under the papillary membrane, which, as I have said before, has almost the density of cartilage, there is a series of fibres running from before backward. These fibres appear to rise in succession from the papillary membrane, and form a layer, which is thicker in front, where the fibres are collected into a small space, than it is behind, where they are scattered and pale. In the ox they traverse the yellowish glandular-looking substance found at the base of the tongue. This thin layer is described by Malpighi, and has been called the superior or *superficial* lingualis muscle.

2. On the lower surface of the tongue, between the genio-hyo-glossus and the hyo-glossus, we find a longitudinal bundle, reaching from the base to the apex. This thick bundle was first described by Douglas under the name of the *lingualis muscle*; it might be called the *inferior lingualis*. The *lingual* muscle of authors generally† is a small muscular fasciculus, situated on the lower surface of the tongue, between the stylo-glossus (*u*, *fig.* 143) and the genio-hyo-glossus (*a*). It arises from the base of the tongue, in an indistinct manner, amid an intricate mass of muscular fibres; from thence it passes forward, and terminates at the apex of the tongue, where it unites with the fibres of the stylo-glossus. It shortens the tongue, and depresses its point.

3. On either side of the tongue we find two layers of oblique and very thin fibres, crossing each other. The superficial layer consists of fibres passing forward and downward, the deep layer of fibres running obliquely forward and upward. These two layers can only be seen towards the base. They are more easily shown in the ox than in man. We also find along each side some antero-posterior fibres, continuous both with the stylo-glossus and the palato-glossus.

4. Lastly, the dissection of the lingual nucleus of a boiled tongue enables us most distinctly to separate the vertical and transverse fibres already noticed as being seen in the different sections of the tongue. The transverse fibres form a slight concavity above: the vertical fibres converge a little from above downward. In the substance of the lingual nucleus, near the base of the tongue, a soft, liquid, adipose matter is interposed between the muscular fibres.

Fig. 143.

The Extrinsic Muscles.—The extrinsic muscles are three on each side, viz., the stylo-glossus, the hyo-glossus, and the genio-hyo-glossus.

The Stylo-glossus.

The *stylo-glossus* (*u*, *figs.* 114, 143, 146) is a small, slender muscle, cylindrical above, thin, triangular, and bifid below. It *arises* from the styloid process by some tendinous fibres surrounding the lower half of that process, and slightly also from the stylo-maxillary ligament. The fleshy fibres proceeding from these points form a rounded fasciculus, which passes downward, inward, and forward. At the margin of the tongue, opposite the anterior pillar of the fauces, the muscle becomes flattened, expanded, and trian-

* It is not unworthy of notice, that Malpighi commenced upon the tongue that series of researches into the structure of organs which has made him, as it were, the founder of textural anatomy.

† [From this statement Albinus must be excepted; the *lingualis* of that anatomist corresponds exactly with the muscle described by Douglas.]

gular, and divides into two parts: one external, which runs along the corresponding margin of the tongue, from the base to the apex; the other internal, which passes between the two portions of the hyo-glossus, assumes a transverse direction, and is blended with the transverse fibres of the tongue.

Relations.—On the outside it is in relation, successively, with the parotid gland, the internal pterygoid muscle, the sub-lingual gland, the lingual branch of the fifth nerve, and the mucous membrane of the tongue. On the inside it has relations with the stylo-hyoid ligament, the tonsil, the superior constrictor of the pharynx, and the hyo-glossus muscle.

Action.—The stylo-glossus draws the corresponding edge of the tongue, and, consequently, the entire organ, upward, and to its own side. When the two stylo-glossi act together, the tongue is increased in breadth, and carried upward and backward: it therefore assists in retraction of the tongue.

The Hyo-glossus.

This is a thin, quadrilateral muscle (*t*, *figs.* 113, 114, 146), *arising* from the os hyoides by two very distinct origins: one from the body of the bone, near the great cornu; the other from the whole extent of the anterior border of the great cornu, and also from its point.

From this double origin the fleshy fibres pass upward parallel to each other, forming a quadrilateral muscle, which expands a little, in order to terminate upon the sides of the tongue, between the stylo-glossus and the lingualis. There is an evident continuity between this muscle and the vertical fasciculi of the tongue.

The *direction* of this muscle varies according to the positions of the tongue. It is vertical when the organ is contained in the buccal cavity, and is directed obliquely upward and forward when the tongue is protruded.

The hyo-glossus is almost always divided into two portions corresponding to its double origin, which are separated below by a cellular interval, and above by the posterior fasciculus of the stylo-glossus. Albinus described them as two distinct muscles: the portion arising from the body of the os hyoides, as the *basio-glossus*; and under the name of the *cerato-glossus*, the portion arising from the great cornu. He also admitted a third portion, under the name of the *chondro-glossus*, described as proceeding from the small cornu. Haller, who considered this latter fasciculus a distinct muscle, states that he has always been able to find it.

Relations.—On the outside it is in relation with the stylo-glossus, the mylo-hyoideus, the digastricus, the sub-lingual gland, the hypo-glossal nerve, and lingual branch of the fifth. On the inside, it corresponds to the lingual artery, which never passes between the two portions of the muscle, to the genio-hyo-glossus, and to the middle constrictor of the pharynx.

Action.—It depresses the corresponding edge of the tongue, and draws it towards the os hyoides. When the tongue has been protruded from the mouth, it assists in drawing it backward. When the two muscles act together, the tongue is depressed and contracted in its transverse diameter.

The Genio-hyo-glossus.

This is the largest of the extrinsic muscles of the tongue: it is thick, triangular, and, as it were, radiated (*a*, *fig.* 143). It *arises* from the superior genial process of the inferior maxilla by a sort of tendinous tuft, from which the fleshy fibres immediately proceed as from a centre, radiating backward in different directions. The posterior fibres are attached to the os hyoides, either directly or through the medium of a membrane. They constitute the superior *genio-hyoideus* of Ferrein. The more anterior fibres expand upon the sides of the pharynx, occupy the interval between the os hyoides and the stylo-glossus, and immediately cover the corresponding portion of the pharynx, or, rather, the amygdaloid excavation. These fibres, which are very distinct (I was acquainted with them before I was aware that they had been described by others), constitute the *genio-pharyngiens* of Winslow. The fibres which are next in order, proceeding forward, all belong to the tongue, and traverse the whole length of that organ. The most anterior fibres, which are the shortest of all, having reached the lower surface of the tongue, curve forward, and terminate near its point. All the others pass perpendicularly upward and turn a little outward, so as to terminate in the papillary mucous membrane at the side of the median line.

Relations.—On the *inside* it corresponds to its fellow, being separated from it by cellular tissue frequently loaded with fat. The two muscles are perfectly distinct, and separable until they enter the substance of the tongue, beyond which point they cannot be separated from each other. On the *outside* it is in relation with the sub-lingual gland, the mylo-hyoideus, hyo-glossus, stylo-glossus, and lingualis muscle. The hypo-glossal nerve perforates this muscle between its genio-pharyngeal and lingual portions. Its *lower margin* corresponds to the genio-hyoideus, from which it is separated by a very delicate layer of cellular tissue. Its *upper margin* is subjacent to the mucous membrane, of which it occasions a prominence on each side of the frænum.

Action.—By its hyoid fibres it raises the os hyoides and carries it forward; by its pharyngeal fibres it draws the pharynx forward and compresses its sides; by its posterior lingual fibres, as well as the hyoid, it carries the base of the tongue, and, consequently, the whole organ, forward. This is the muscle by which we are enabled to protrude the tongue from the mouth. By means of its anterior or reflected fibres, the tongue, when protruded, is drawn back into the mouth; lastly, by its median lingual fibres, the tongue is made into a groove; when one muscle acts alone, it is protruded to the opposite side.

Such, including the palato-glossus, already described, are the extrinsic muscles of the tongue: I shall not include among them the *mylo-glossus* of the older anatomists, and described, also, by Heister and Winslow, because it appears to be nothing more than that portion of the superior constrictor of the pharynx which is inserted into the mylo-hyoid ridge; nor yet the *glosso-epiglottideus*, a very large muscle existing in the lower animals, which has been described by Albinus in the human subject as a dependance of the genio-hyo-glossus. After the most careful examinations, I have never been able to meet with it.

Vessels, Nerves, and Cellular Tissue.—The cellular tissue of the tongue receives arteries and veins, and from it issue both veins and lymphatics.

The *arteries* consist of the proper lingual, which are very large in comparison to the size of the organ, the palatine, and the inferior pharyngeal.

The *veins* form two sets, as in the limbs, and for the same reason: a superficial set, independent of the arteries; and a deep set, accompanying those vessels.

The *lymphatics* enter the deep lymphatic glands of the supra-hyoid region.

The *nerves* are very large, and are derived from three sources, viz., from the ninth pair, or hypo-glossal; from the lingual branch of the fifth pair; and from the glosso-pharyngeal division of the eighth pair.*

The *cellular tissue* of the tongue is partly serous and partly adipose; the serous portion is chiefly situated in front, the other is more abundant behind.

The Tegumentary Membrane and Glands.—The *tegumentary membrane* of the tongue is a continuation of the mucous membrane of the mouth. It is thin and slightly adherent in almost all its non-papillary portion, and becomes very thick and strongly adherent wherever the papillæ exist. The edges of the tongue are occupied by numerous small glands, continuous with the sub-lingual glands, and opening upon the lower wall of the mouth by small excretory ducts.

Development.—The tongue is visible in the youngest embryos. Its early development has reference to its functions, for it is an essential agent in suction, and is, consequently, brought into use immediately after birth. The tongue is not double or bifid at first; in the earliest embryos it presents the appearance of a single tubercle.

Uses of the Tongue.—The tongue has two very distinct uses. It is the organ of taste, and it is also a movable organ. In this place we shall consider it in the latter capacity only. The movements of the tongue are concerned in the prehension of food, in suction, in mastication, in tasting, in deglutition, in articulation, and in playing upon wind-instruments.

In order to fulfil such a variety of uses, it is organized so as to be capable of moving in every direction. Its movements are either *extrinsic* or *intrinsic*. The extrinsic movements, or those of the whole tongue, may be ascertained from our knowledge of the single or combined actions of its extrinsic muscles. Thus, it may be protruded from the mouth, drawn back into that cavity, inclined to the right or to the left side, directed upward or downward, or carried into any intermediate position. In its intrinsic movements it may be contracted transversely by the transverse fibres, diminished in length by its longitudinal fibres, and contracted vertically and rendered concave by its vertical fibres; lastly, its apex can be carried upward by the superior, and downward by the inferior longitudinal fibres.

By far the most varied, precise, and rapid motions of this organ are required in the articulation of sounds, in which it is one of the chief agents. In consequence of this use, which is by no means the result of a special conformation (for, by constant practice, animals, whose tongues are very different from ours, may be taught to articulate), the tongue is associated with, and becomes one of the principal instruments of the mind. It is the organ by which thought is most commonly expressed. This use is peculiar to man.

* The ninth nerve is distributed to the muscles, the lingual nerve to the mucous membrane of the anterior part and sides, and the glosso-pharyngeal to that of the base of the tongue. (See ORGAN OF TASTE.)

I have lately seen a considerable branch of the facial nerve terminating in the tongue; it was given off from the facial nerve at its exit from the stylo-mastoid foramen, crossed obliquely in front of the styloid process with which it was in contact, passed in front of the stylo-pharyngeus muscle externally to the tonsil and parallel to the glosso-pharyngeal nerve, which was situated behind it, communicated with that nerve by several arches, and divided into two branches at the base of the tongue, one of which ran along the edge of that organ, and the other anastomosed by a loop with the glosso-pharyngeal: from this loop some filaments passed off, to be distributed in the usual manner.

The opposite side did not exhibit a corresponding arrangement.

The Salivary Glands.

Besides the labial, buccal, and palatine glands found in the cavity of the mouth, which, by most anatomists, have been confounded with the follicles or muciparous crypts, there exists around this cavity a particular glandular apparatus, forming a sort of chain or collar, symmetrically extended along the rami and body of the lower jaw. This chain is interrupted so as to form six glandular masses, three on each side, named, from their situation, the *parotid*, *sub-maxillary*, and *sub-lingual glands*.*

The Parotid Gland.

The *parotid gland* (*p*, *fig.* 144), so called from being situated below and in front of the external auditory meatus (*παρὰ*, near, *οὖς*, *ὠτὸς*, the ear), fills the parotid excavation. It is bounded in front by the posterior edge of the ramus of the lower jaw; behind, by the external auditory meatus and the mastoid process; above, by the zygomatic arch; below, by the angle of the lower jaw; and on the inside, by the styloid process and the muscles which proceed from it. This gland has given its name to the region occupied by it.

Fig. 144.

It is the largest of all the salivary glands, and even exceeds all the rest put together. Its form is irregular, and is determined by that of the surrounding parts, upon which it is moulded like a piece of soft wax. Its superficial portion is broad, but it suddenly becomes contracted when it dips behind the ramus of the jaw.

In order to obtain a good idea of the size and shape of this gland, it must be removed entire from the irregular mould in which it is lodged. It has been compared to a pyramid, of which the base is directed outward, and the apex inward.

Relations.—Its *external surface*, or base, is broad, oblong from above downward, irregularly quadrilateral, and lobulated at the edges; it is sub-cutaneous, being separated from the skin, however, by the parotid fascia and the risorius of Santorini, when that muscle exists.†

Its *anterior surface* is grooved so as to embrace the posterior edge of the ramus of the lower jaw. A bursa, or some loose cellular tissue, facilitates the movements of these parts. This surface is also in relation with the internal pterygoid muscle, the stylo-maxillary ligament, and the masseter muscle, on the external surface of which it is prolonged to a greater or less extent (see *fig.* 144) in different individuals, and is separated from it anteriorly by the ramifications of the facial nerve, by some loose cellular tissue, and by the transverse artery of the face.

Its *posterior surface* is in relation with the cartilaginous portion of the external auditory canal, being moulded upon its convexity, and adhering to it by very dense cellular tissue: it corresponds also to the mastoid process, the sterno-cleido-mastoid and digastric muscles, and indirectly to the transverse process of the atlas. This surface is extremely irregular, adheres by means of dense cellular tissue, and is dissected off with great difficulty in an attempt to remove the entire gland.

On *the inside* it is reduced to a mere border, which corresponds to the styloid process, and the muscles and ligament connected with it. It sends off a considerable prolongation into the space which separates the styloid process and its muscles from the internal pterygoid: but the most important relation of this border is with the external carotid artery, for which it furnishes a groove, and sometimes, even, a complete canal.

Its *upper extremity* corresponds to the zygomatic arch and the temporo-maxillary articulation.

Its *lower extremity* fills up the interval between the angle of the jaw and the sterno-mastoid, and is separated from the sub-maxillary gland (*m*) by a very thick fibrous septum.

Besides the relations already indicated, the parotid has others with the vessels and nerves which traverse it at different depths: these may be called its *intrinsic* or *deep* relations. Thus, the external carotid artery almost always perforates the gland near its inner side; the temporal artery (see *fig.* 144), the transversalis faciei, and the anterior auricular, which commence in the substance of the gland, also traverse it in various directions. We also find within it the temporal vein, which is a communicating branch between the external and internal jugulars; the trunk of the facial nerve is at first placed behind the gland, then penetrates it, and divides into two or three branches, which again subdivide and traverse it in all directions. The auricular nerve, a branch of the cervi-

* The continuity of this glandular chain, admitted by some anatomists, is only apparent. A fibrous septum always intervenes between the sub-maxillary and the parotid glands.

† In a female in whom I dissected the parotid gland, the risorius arose from the superior semicircular line of the occipital bone by two distinct fasciculi, which, passing downward and forward, united opposite the apex of the mastoid process, and then proceeding horizontally, expanded upon the parotid gland. Some of the fibres reached the commissure of the lips, but the greater number were lost upon the parotid fascia.

cal plexus, also passes through it very superficially.* The parotid gland, by a remarkable exception, always contains in its substance, a little below the surface, several lymphatic glands, which may be readily distinguished by their red colour from the proper tissue of the gland. It may be imagined that a morbid development of these glands may have often been mistaken for disease of the parotid itself.

Structure.—A thick fibrous membrane covers the parotid glands, and sends prolongations into it which divide it into lobes, and these, again, into glandular lobules. The actual structure of the gland, therefore, depends upon the nature of these lobules; and, without entering into details which belong more properly to general anatomy, it may be stated that it has been shown, by the aid of the simple microscope, that each lobule is a porous, spongy body, something like the pith of the rush, and provided with afferent vessels, viz., the *arteries*; and efferent vessels, *i. e.*, the *veins* and *excretory ducts*.† The relations of the nerves and lymphatic vessels with these granules have not been accurately determined.

The parotid *arteries* are very numerous; some of them arise directly from the external carotid; others from its branches, more particularly from the superficial temporal, the transversalis faciei, and the anterior and posterior auricular.

The *veins* have similar names, and follow the same direction as the arteries. There is a parotid venous plexus.

The *lymphatic vessels* are little known: they terminate partly in the glands at the angle of the jaw, and partly in those which lie in front of the auditory meatus. I have already said that one or more lymphatic glands are always situated in the parotid gland, a few lines below its surface.

The *nerves* are derived from the anterior auricular (a branch of the cervical plexus) and from the facial nerve: they seem to be lost in the substance of the gland.

The Parotid Duct.—A small excretory duct (resulting from the union of its terminating vesicles) proceeds from each lobule, and unites almost immediately, at a very acute angle, with the ducts of the adjacent lobules. From the successive union of all these ducts a single canal results, which emerges from about the middle of the anterior margin of the gland: this is the *parotid duct* (*s*, *fig.* 144), called also the *duct of Steno*, although it had been previously described by Casserius. It passes horizontally forward, about five or six lines beneath the zygomatic arch, across the masseter, and at right angles to its fibres. At the anterior border of the masseter it changes its direction, curves in front of a mass of fat situated there, dips perpendicularly into the fat of the cheek, perforates the buccinator in the same direction, and glides obliquely, for the space of several lines, between that muscle and the mucous membrane of the mouth, which it pierces opposite the interval between the first and the second upper great molar teeth, almost on a level with the middle of their crown.

The mode in which the Stenonian duct opens into the buccal cavity does not appear to me to have been sufficiently well understood. It exactly resembles the manner in which the ureters enter the bladder. Thus, it glides obliquely for a certain distance beneath the mucous membrane, a fact that may be easily determined by perforating the cheek at the point where the duct passes through the buccinator, and then measuring the interval between this perforation and the buccal orifice of the canal: this interval varies from two to three lines in extent. Again, the buccal orifice is oblique, like the vesical opening of the ureter, so that it is extremely easy to pass a fine probe into it.

The duct of Steno is often accompanied by an *accessory gland*‡ (glandula socia parotidis, see *fig.* 144), situated between it and the zygomatic arch. The duct of this little gland opens into the main canal. I have seen two small accessory glands situated above the canal, one at the middle and the other at the anterior part of the masseter. Lastly, as the parotid duct is passing through the buccinator, it is surrounded by a series of glands continuous with those of the cheeks, called *molar glands*, the ducts of some of which appear to open into the canal, and those of others directly into the mouth. Although it is not flexuous, the canal, when separated from the surrounding parts, will be found much longer than it appears at first sight.

Fig. 145.

Magnified fifty times.

* These relations prove the almost absolute impossibility of extirpating this gland by a cutting instrument, and of compression after Desault's method, for the cure of salivary fistulæ. Compression, which is extremely painful, on account of the number of nerves passing through it, can only affect its superficial portion.

† [Weber has succeeded in distending with mercury the ducts (*d*, *fig.* 145) of the parotid gland in the infant, and has shown that they terminate in closed vesicular extremities (*c*) about $\frac{1}{1200}$ of an inch in diameter, three times that of the capillary vessels ramifying upon them. See *Müller's Physiology*, translated by Baly, p. 447; and *Müller on the Glands*, translated by Solly, p. 69.—(*Tr.*)

In the early embryo of the sheep, this gland consists of a canal which opens into the mouth by one extremity, but is closed at the other, and has numerous short hollow branches projecting from it into a granular blastema: as development advances, the blastema is absorbed, and the ramified canal, increasing in length, becomes still more ramified, so as to form the ducts with their closed vesicular terminations.]

‡ Desault found this gland very large in a subject where the corresponding parotid was atrophied.

Relations.—The Stenonian duct is sub-cutaneous and superficial where it passes over the masseter; it is protected by a large quantity of fat, and, in front of the masseter, by the zygomaticus major. A considerable branch of the facial nerve, and some arteries derived from the transversalis faciei, run along this canal.

Structure.—An exaggerated idea is generally entertained of the thickness of the duct of Steno; it is only thick at its anterior part, where it is strengthened by an expansion of the aponeurosis of the buccinator muscle. When freed from the surrounding fat, it is not thicker than most other ducts, the ureters, for example. The notion that it is inextensible is also incorrect. It is true, however, that the diameter of its canal is not in proportion to the size of the gland. It is formed by two membranes: one external, the nature of which is not well known; the other internal, consisting of a prolongation of the mucous membrane of the mouth. Its arteries and veins are very large.

The Sub-maxillary Gland.

The sub-maxillary gland (*m*, *fig.* 144) is situated in the supra-hyoid region, and partly behind the body of the lower jaw; it is bounded by the reflected tendon of the digastricus, below which it almost always projects.

Size and Figure.—It is much smaller than the parotid, but larger than the sub-lingual. It is oblong from before backward, elliptical, irregular, and divided into two or three lobes by some deep fissures.

Relations.—On the *outside* and *below*, it corresponds to a depression on the inferior maxillary bone, in which it is completely lodged when the jaw is depressed. When, on the other hand, the head is bent backward upon the neck, the gland appears almost entirely in the supra-hyoid region, and is in relation with the platysma, being separated from it by the cervical fascia, to which it is united by cellular tissue of so loose a texture, that it may be called a synovial bursa. This surface of the gland is also in relation with the internal pterygoid muscle and the numerous lymphatic glands situated along the base of the jaw. On the *inside* and *above*, it corresponds to the digastric, mylo-hyoid, and hyo-glossus muscles, and to the hypo-glossal and lingual nerves.

The sub-maxillary gland almost always forms a prolongation of variable size and shape above the mylo-hyoideus. Sometimes the lobules of which it is composed are situated in lines, so as to appear like the Whartonian duct, or, rather, a second canal running parallel to it. Most commonly, this prolongation is of considerable size and irregular, and forms, as it were, a second sub-maxillary gland.

The most important relation of the gland is to the facial artery (*a*), which runs in a groove on its posterior border, and upon the contiguous part of its external surface. Sometimes this groove is prolonged forward, and divides the gland into two unequal parts. We cannot avoid seeing the great analogy between this arrangement and that of the external carotid artery, with regard to the parotid gland.

Structure.—This is identical with that of the parotid. Its investing fibrous membrane is weaker, and still more difficult of demonstration. The *arteries* are numerous, and arise from the facial and the lingual. The *veins* correspond to them. The *lymphatic vessels* are little known, and enter the neighbouring glands. The *nerves* are derived from the lingual and the myloid branch of the dental. I should remark, that all the nerves proceeding from the sub-maxillary ganglion are destined for this gland.

The *excretory duct* of the sub-maxillary gland is called the *Whartonian duct*, although it was really discovered by Van Horne. It is formed by the successive union of all the small ducts proceeding from the lobules; it leaves the gland at the upper bifurcation of its anterior extremity, and, consequently, above the mylo-hyoideus, and is directed obliquely upward and inward, parallel to the great hypo-glossal and lingual nerves. It is at first placed between the mylo-hyoid and hyo-glossus muscles, and then glides between the genio-hyo-glossus and the sub-lingual gland, to the inner surface of which it is attached.* I have never succeeded in determining whether it receives any excretory duct or ducts from this gland. Having reached the side of the frænum linguæ, the duct, which is sub-mucous in the whole of the portion corresponding to the sub-lingual gland, changes its direction, passes forward, and opens by an extremely narrow orifice upon the summit of a prominent and movable papilla found behind the incisor teeth. This orifice, which can scarcely be seen by the naked eye, was found to admit a hog's bristle in a particular case presented to the Anatomical Society by M. Robert.† Bordeu has correctly described the appearance of this orifice by the term *ostiolum umbilicale*.

The duct of Wharton is remarkable for the thinness of its coats, which are not thicker than those of a vein; for its great calibre, which exceeds that of Steno's duct; for the extensibility of its coats, the canal sometimes acquiring an enormous size; and, lastly, for its proximity to the mucous membrane of the mouth, which causes it, when much dilated, to project into the buccal cavity.

* [See *fig.* 146, in which the gland itself (*m*) hangs down, resting upon the hyo-glossus; the digastric and mylo-hyoid muscles and half the lower jaw have been removed.]

† This was observed in a shoemaker; the bristle had become the nucleus of a salivary calculus.

The Sub-lingual Gland.

The *sub-lingual gland* (*l*, *fig.* 146), which may be regarded as an agglomeration of smaller glands analogous to those of the lips and palate, is situated in the sub-lingual fossa of the lower jaw, at the side of the symphysis menti: it is much smaller than the preceding gland, with which it is sometimes continuous. Its shape is oblong, like that of an olive flattened at the sides. The following are its relations: It is subjacent to the mucous membrane, beneath which its upper edge forms a prominent ridge, running from before backward along the sides of the frænum; its lower edge rests upon the mylo-hyoid muscle; its external surface corresponds partly to the mucous membrane and partly to the sub-lingual fossa; its internal surface is in relation with the mucous membrane, with the genio-hyo-glossus (from which it is separated by the lingual nerve), with the Whartonian duct (which, we have seen, closely adheres to it), and with the ranine vein. Its anterior extremity touches the gland of the opposite side. Its posterior extremity and its lower edge are embraced by the lingual nerve, which gives numerous filaments to it. A small glandular prolongation also proceeds from its posterior extremity, and runs along the edge of the tongue.

Fig. 146.

Structure.—Precisely similar to that of the other salivary glands. Its arteries arise from the sub-mental and sub-lingual. Its veins bear the same name. Its nerves are numerous, and are derived from the lingual.

Its *excretory ducts*, called also the *ducts of Rivinus*, from their discoverer, are seven or eight in number. They open along the sub-lingual crest: their orifices may be shown by placing a coloured fluid in the mouth. Most anatomists state, that several of the ducts of this gland open into the Whartonian duct.

General Characters of the Salivary Glands.—The salivary glands present the following general characters:

1. They are situated around the lower jaw, extending along its body and rami, from the condyles to the symphysis; they are in relation, on the one hand, with the maxillary bone, and on the other with numerous muscles, so that they are subjected to considerable compression during the movements of the lower jaw. 2. They all have direct relations with large arteries, which communicate their pulsations to them. 3. They receive vessels from a great number of points, and the vessels themselves are very numerous. 4. They are penetrated by many of the cerebro-spinal nerves, of which some only pass through, but a certain number terminate in them. 5. In structure they resemble the pancreas and the lachrymal glands; they have no special fibrous investment to isolate them completely from the surrounding parts; they have no precise form, and they are subdivided into lobes and lobules. 6. Their excretory ducts pour their secretion into the mouth, *i. e.*, the parotids between the cheeks and the teeth, the sub-maxillary and the sub-lingual glands behind the lower incisors, on each side of the apex of the tongue. This distribution of the means of insalivation between the two cavities into which the mouth is divided deserves the attention of physiologists.

The Buccal Mucous Membrane.

The buccal mucous membrane is continuous with the skin at the free edges of the lips; it lines their posterior surface, and is reflected from them upon each of the maxillary bones, forming a cul-de-sac or trench, and in the median line a small fold, called the frænum of the lips. About a line and a half or two lines from the free border of the lips, it changes its character, and constitutes the gums, which are reflected upon themselves, so as to become continuous with the fibro-mucous membrane, called the alveolo-dental periosteum.

In the lower jaw the mucous membrane passes from the alveolar border to the lower wall of the mouth, and from it to the under surface of the tongue. At the point of reflection in the median line, it forms the frænum linguæ. From the under surface of the tongue, the mucous membrane passes over its edges and upper surface, where it presents the peculiarities already described; and in being reflected from the base of the tongue to the epiglottis, it forms three folds, the glosso-epiglottid, so as to become continuous on the one hand with the mucous membrane of the larynx, and on the other with that of the pharynx.

In the *upper jaw* it is extended from the upper alveolar border upon the roof of the palate, passing over the anterior and posterior palatine canals, which it closes, but does not enter. From the roof of the palate it passes upon the velum, and is continuous with the nasal mucous membrane at its free edge. On the sides it forms two large folds for the pillars of the fauces, lines the amygdaloid excavation, covers the tonsil, and becomes continuous with the mucous membrane of the base of the tongue and of the pharynx.

At the sides of the buccal cavity the mucous membrane is reflected from both the alveolar borders upon the inner surface of the cheeks, and thus forms two trenches. At the anterior edge of the ramus of the jaw, behind the molar teeth, it is elevated by a salivary gland, which marks the limit between the cheeks and the pillars of the fauces. Inside this prominence it forms a cul-de-sac.

The buccal mucous membrane sends off prolongations into the numerous canals which open into the mouth. Thus, on the floor of the mouth there are two for the Whartonian ducts, and several for the small ducts of the sub-lingual glands. Two others are seen on the inner sides of the cheeks for the ducts of Steno; and it is also clear that it must penetrate into the thousands of other orifices with which the mouth is studded (those of the buccal, labial, palatine, and other glands). But in all these prolongations its structure is modified, and it becomes exceedingly thin. It has been proved that it lines not only the larger ducts, but even their minutest subdivisions. Thus, there is a kind of parotitis, which consists in inflammation of the lining membrane of the excretory ducts of that gland; and then all the canals are filled with muco-puriform secretion, which escapes by the buccal orifice when the gland is compressed. The numerous openings on the surface of the tonsil are formed by the prolongations of this membrane into the cavities situated in its interior.

Although the different parts of the buccal mucous membrane are continuous, they do not all possess the same characters. Compare, for instance, in regard to their density, thickness, and closeness of adhesion to the subjacent tissues, the mucous membrane of the gums and palate with that of the lips and cheeks, or the membrane covering the lower with that upon the upper surface of the tongue, or the mucous membrane of the free edge of the velum palati with that of the arches and the amygdaloid excavation.

The two principal characters of the buccal mucous membrane are the following: 1. The presence of an epidermis or *epithelium** (as it is called in mucous membranes). This can be distinctly demonstrated by maceration, or by the action of boiling water or some acid; by any of these means a pellicle is raised, having all the characters of an epidermis. It is very thick upon the gums, the roof of the palate, and upon the tongue, where it forms a horny sheath to each papilla. To the existence of this membrane, and of the fluid with which it is constantly kept moist, we must attribute the possibility of applying, or, rather, running, a red-hot iron over the surface of the tongue without burning the part. 2. The multiplicity of small subjacent glands, so near to each other in some parts as to form a continuous layer. These glands should be carefully distinguished from the muciparous follicles or crypts, with which many modern anatomists have commonly confounded them. To these two characteristics a third may be added, peculiar to some portions of the buccal mucous membrane, viz., that it is supported by a very dense fibrous tissue, with which it is completely united. This fibrous layer is perfectly distinct from the periosteum, and from its presence the mucous membrane should be arranged among the *fibro-mucous membranes*.

The Pharynx.

The *pharynx* (*φάρυγξ*, the throat,† 1, 2, 3, *fig.* 140), long confounded with the œsophagus, under the common name of *gula* or *œsophagus*, is a muscular and membranous semi-canal, perfectly symmetrical, and situated in the median line: it is a sort of vestibule, common to the digestive and the respiratory passages, intermediate between the buccal and nasal cavities on the one hand, and between the œsophagus and larynx on the other. It is situated deeply in front of the vertebral column, extending from the basilar process of the occipital bone to opposite the fourth or fifth cervical vertebra and the cricoid cartilage. It therefore corresponds to the parotid, and partly to the supra-hyoid regions.

Its *dimensions* deserve particular attention. It is smaller than the mouth, but larger than the œsophagus, which, compared to it, resembles the tube of a funnel. Hence it follows, that foreign bodies, which have been able to pass along the mouth and pharynx, may be arrested in the œsophagus.

In *length* it is from 4 to 4½ inches, which may be increased to 5½, or even 6½, by distension, and reduced to 2½ by the greatest possible contraction, which is limited only by the contact of the base of the tongue with the velum palati rendered horizontal. The length of the pharynx, therefore, may be made to vary about 4 inches.

The pharynx undergoes these extreme variations both in deglutition and in modulating the voice; in effecting which latter purpose, it acts in the same way as the tube of a clarinet or flute. Thus considered, the entire length of the pharynx may be divided into three parts, a nasal (1, *fig.* 140), a buccal or guttural (2), and a laryngeal (3) portion. It may be easily seen that the variations in length affect almost exclusively the buccal portion, into which the air is received after escaping from the larynx. Now these variations in the length of the pharynx have the same influence over the compass of the hu-

* [The existence of an epithelium is *common* to all mucous membranes; that of the buccal cavity is of the *squamous* variety.]

† The term pharynx had no well-defined meaning among the ancients: they sometimes used it to designate the pharynx, properly so called; sometimes the larynx.

man voice as the differences in the lengths of the tubes of wind-instruments have upon the sounds produced by them.

The *breadth* of the upper or nasal portion of the pharynx is measured by the interval between the posterior margins of the internal pterygoid plates: it is about one inch, and is invariable. In the buccal portion the same diameter is measured by the interval between the posterior extremities of the alveolar borders, and is about two inches: it may be diminished to one inch by the contraction of the constrictor muscles. The breadth of the laryngeal portion is measured, first, by the interval between the summits of the great cornua of the os hyoides, where it is about one inch and near two lines; then by the interval between the superior cornua of the thyroid cartilage, which is an inch and two or three lines; and, lastly, by the interval between the inferior cornua of the same cartilage, about eleven or twelve lines. The contraction of this laryngeal portion may be carried to complete obliteration of the cavity.

Both the buccal and laryngeal portions, therefore, are capable of contraction, and this always takes place in deglutition, in order to force down and compress the alimentary mass. Contraction of the buccal portion also takes place in the modulation of sounds: it exerts the same influence over the compass of the human voice as the contraction of the tubes of the flute or clarinet does over the notes of those instruments.

The *antero-posterior dimensions of the pharynx* are not subject to the same variations as the transverse and vertical, on account of the presence of the vertebral column. Its enlargement in this direction is produced during that period in the act of deglutition when the larynx and os hyoides are carried forward and upward, and its diminution at the time when the same parts are carried upward and backward. The antero-posterior diameter of the pharynx depends upon the length of the basilar process of the occipital bone.

Figure.—The pharynx does not form a complete cavity with distinct and separate walls, but, rather, half or two thirds of a canal, which is completed in part by several organs otherwise not belonging to it. Moreover, the pharynx, from its commencement down to the larynx, is habitually open, and in a state of tension; its walls are never in apposition: an important circumstance in reference to the continual passage of air through its nasal and buccal portions. This tension depends on its attachment to the basilar process, and to the fixed points at its sides, and also upon the tendinous structure of its upper portion. Opposite the larynx the tension ceases to exist.

The pharynx, as well as all other hollow organs, presents an external and an internal surface.

The External Surface.—This is in relation *behind*, by a plane surface, with the vertebral column (see *fig.* 140), from which it is separated by the long muscles of the neck and the anterior recti of the head. It glides, by means of some very loose cellular tissue, upon the fascia covering the muscles of that region; and when, from the effect of inflammation, this cellular tissue becomes dense, the movements of deglutition cannot be performed, and dysphagia is the result. The relation of the pharynx to the vertebral column accounts for congestive abscesses of the neck sometimes opening into the pharynx.

At the sides the pharynx is separated from the internal pterygoid muscle by a triangular space, broad below and narrow above, occupied by the internal carotid artery, the internal jugular vein, and the pneumogastric, glosso-pharyngeal, hypo-glossal, and spinal accessory nerves, all being surrounded by very loose cellular tissue. The sides of the pharynx are also indirectly in relation with the parotid gland and the styloid muscles. Lower down, the pharynx corresponds to a great number of lymphatic glands, and to the external carotid artery and its branches.

The Internal Surface.—In order to examine this surface, it is necessary to open the pharynx from behind by a vertical incision. We shall then perceive that this structure only exists behind and at the sides, but that *in front* it presents a great number of openings (see *figs.* 140, 141), the arrangement of which is of great interest.

Proceeding from above downward, we find, 1. The two posterior openings of the nasal fossa (1), quadrilateral in form, having their longest diameter vertical, and separated from each other by the posterior edge of the septum. On looking into them, we see the posterior extremities of the turbinated bones and the terminations of the several meatuses. 2. The upper surface of the velum palati (*c a*), forming an inclined plane, which directs the mucous secretions into the throat. 3. The isthmus of the fauces (2), of a semicircular form, divided into two arches, and exhibiting the pillars, the amygdaloid excavation, and the prominence of the tonsils. 4. The superior opening of the larynx (3), the plane of which is directed obliquely upward and forward (see *fig.* 140); the epiglottis (*i*, *fig.* 140), which is ordinarily erect, closes this opening by becoming depressed like a valve. 5. The posterior surface of the larynx, with its two lateral and triangular grooves, broad above and narrow below, which have been regarded as specially intended for the swallowing of liquids, which thus pass on each side of the laryngeal opening.

It is extremely curious and highly important to study all the objects displayed in the complicated mechanism of the pharynx: by so doing, we learn how the air passes from the nasal fossa and mouth into the pharynx, and thence into the larynx, into which it is drawn by the active expansion of the thorax, without ever entering the œsophagus;

how the mucous secretions of the nose, or blood, can pass from the nose down into the mouth and throat; how instruments may be introduced from the nasal fossæ and buccal cavity into the œsophagus and larynx, or drawn from the nose into the mouth; and, lastly, how solids and liquids can pass into the œsophagus without entering the air-passages, or why they sometimes take this irregular course.

The *posterior wall of the pharynx* is broader in the buccal region than either above or below: it may be partially seen through the isthmus of the fauces in the living subject. There is no folding of the membrane upon any part of this wall: we only find a few glands forming projections beneath the lining membrane.

On each *lateral wall* is seen the expanded orifice of the corresponding Eustachian tube (4, *fig.* 140), and a groove leading from it downward and inward. This orifice corresponds precisely to the posterior extremity of the lower turbinated bone: an important relation, because it serves as a guide in the now common operation of introducing a catheter into the Eustachian tube.

The roof of the pharynx corresponds to the basilar process: it may be reached by the finger introduced into the mouth, if it be curved directly upward.

There is no very distinct line of demarcation, either internally or externally, between the pharynx and the œsophagus (*y*, *fig.* 140). Their limits are established by a sudden narrowing of the tube,* by a change of colour in the lining membrane, and by a change in the direction and colour of the muscular fibres, which are red in the pharynx and much paler in the œsophagus.

Structure of the Pharynx.—The pharynx is composed of an aponeurotic portion, of muscles, of vessels and nerves, and of a lining mucous membrane.

The *aponeurotic portion*, or framework of the pharynx, is composed of the cephalo-pharyngeal aponeurosis and of the petro-pharyngeal aponeurosis.

The *cephalo-pharyngeal*, or posterior aponeurosis of the pharynx, arises from the lower surface of the basilar process, from the Eustachian tubes, and from the contiguous parts of the petrous portions of each temporal bone: it is continuous above with the thick periosteum which covers the basilar process, is prolonged vertically downward, and, gradually diminishing in thickness, is lost after extending about an inch and a half or two inches. On this membrane the constrictor muscles of the pharynx terminate.

The *petro-pharyngeal*, or lateral aponeurosis of the pharynx, arises from the petrous portion of the temporal bone, internally to the inferior orifice of the carotid canal, by a very thick tendinous bundle, continuous, at a right angle, with the cephalo-pharyngeal aponeurosis;† it then descends along the sides of the pharynx, and splits into bundles, which are inserted into the pterygoid fossa between the internal pterygoid muscle and the circumflexus palati, separating these muscles from each other. From thence it gives off to the posterior extremity of the inferior alveolar border a fibrous prolongation, to the front of which the buccinator muscle is attached. This aponeurosis covers the tonsil, to which it is closely united. It is prolonged downward as far as the upper border of the os hyoides, in order to form the framework of the side and lower part of the pharynx.

Muscles of the Pharynx.

The muscles of the pharynx are divided into intrinsic and extrinsic.

The Intrinsic Muscles.

The intrinsic muscles have a membranous form, and are arranged in three successive imbricated layers. Santorini described a great many muscles in the pharynx, on account of their numerous attachments; but Albinus has reduced them to three on each side, named *constrictors*, distinguished into an inferior, a middle, and a superior. Chaussier united all the muscles which enter into the composition of the pharynx under the collective name of *les stylo-pharyngiens*. The division of Albinus has been generally and justly preferred.

Fig. 147.

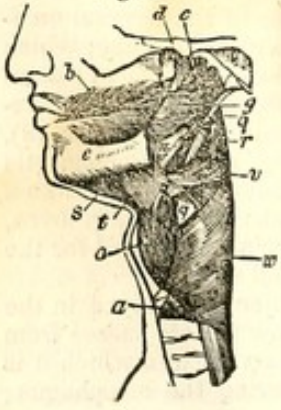

The Inferior Constrictor.

This is a membranous muscle (*w*, *figs.* 141, 147), of a lozenge, or, rather, a trapezoid shape, the most superficial and the thickest of all the muscles of the pharynx, and is situated at the lower part of that cavity. It is attached, *on the one hand*, to the cricoid and the thyroid cartilages, and, *on the other*, to the fibro-cellular raphé, along the posterior median line of the pharynx (crico-pharyngien and thyro-pharyngien, *Valsalva*, *Winslow*, and *Santorini*). It might be called the *crico-thyro-pharyngeus*. It *arises* upon the side of the cricoid cartilage, from a triangular space bounded in front by the crico-thyroideus (*a*, *fig.* 147),

* [This occurs exactly opposite the cricoid cartilage.]

† The superior cervical ganglion of the sympathetic nerve lies upon the angle formed by these two aponeuroses.

from which it often receives some fibres, and behind by the crico-arytenoideus posticus (*i*, *fig.* 141).

Its *thyroid origins* are much more extensive, and take place from an imaginary oblique line on the outer surface of that cartilage, from the two tubercles at the extremities of that line, and from the entire surface behind it; also from the upper and posterior borders, and from the corresponding inferior cornu of the same cartilage. Having thus arisen by two very distinct digitations, the fleshy fibres pass in different directions: the inferior fibres, short and horizontal, proceed directly inward; the superior become longer, and are directed more obliquely upward, in proportion as they approach the upper part of the muscle: they terminate by an expanded border of much greater extent than the outer border, and the upper extremity of which rarely extends above the middle of the pharynx. The transverse direction and the shortness of the inferior fibres have obtained for them the name of the *œsophageal muscle* (*Winslow*, *Santorini*).

Relations.—Covered by a dense cellular membrane, which surrounds the entire pharynx, and which might be regarded as the proper sheath of its muscles, the inferior constrictor has the same relations posteriorly as the pharynx itself. Externally it is covered by the sterno-thyroid muscle and the thyroid body. It covers the middle constrictor, the stylo-pharyngeus, and palato-pharyngeus, and, for a great part of its extent, it is in contact with the mucous membrane of the pharynx (see *figs.* 141, 147). The recurrent laryngeal nerve passes under the *lower margin* of this muscle, near its cricoid attachment, in order to enter the larynx. Its *upper margin* is well defined from the other constrictors by a tolerably distinct ridge, and by the passage of the superior laryngeal nerve beneath it. Winslow states that he has seen some fibres of the muscle arise from the thyroid body; and Morgagni, that he has traced some from the first ring of the trachea.

Action.—It is simply a constrictor in its lower portion: its upper fibres act as a constrictor, a depressor, and a tensor of the posterior wall of the pharynx; it can also raise the larynx, and carry it backward.

The Middle Constrictor.

This is a membranous triangular muscle (*v*, *figs.* 141, 147), situated in the middle of the pharynx, upon a plane anterior to the preceding.

It *arises* from the os hyoides, and is *inserted* into the posterior median raphé (*hyo-pharyngeus*). It arises from the os hyoides in the following manner: 1. From the whole extent of the upper surface of the great cornu below the hyo-glossus (*t*), from which it is separated by the lingual artery; a great many fibres arise by a tendinous origin from the apex of this cornu. 2. From the lesser cornu and the contiguous part of the stylo-hyoid ligament. From these different origins, which form the external truncated angle of the muscle, the fleshy fibres diverge in various directions; the inferior passing downward, the middle transversely, and the superior upward: the latter are much more oblique and more numerous than the others, and terminate in a pointed extremity, which never reaches as high as the basilar process.

Relations.—Its *external surface* is in a great measure superficial, and is in relation with the muscles of the præ-vertebral region, through the medium of the cellular investment of the pharynx. It is covered, in the rest of its extent, by the inferior constrictor and the hyo-glossus. It covers the mucous membrane of the pharynx, the superior constrictor, the stylo-pharyngeus, and the palato-pharyngeus. Its upper margin may be distinguished from the superior constrictor by its projecting slightly behind that muscle, and by the stylo-pharyngeus (*r*), which lifts up this border in penetrating into the pharynx.

Action.—It is a constrictor of the pharynx, and can draw the os hyoides upward and backward.

The Superior Constrictor.

This is a quadrilateral muscle (*g*, *figs.* 141, 147), occupying the upper part of the pharynx; it *arises* from the pterygoid process, the mylo-hyoid ridge, and the base of the tongue, and is *inserted* into the posterior median raphé (*ptérygo-pharyngeus*, *buccinato-pharyngeus*, *mylo-pharyngeus*, and *glosso-pharyngeus*, Santorini).

It arises, 1. By tendinous fibres, from the lower third of the margin of the internal pterygoid plate and its hamular process. 2. From the contiguous portion of the palate bone, and the reflected tendon of the circumflexus palati. 3. From the buccinato-pharyngeal aponeurosis, which extends from the pterygoid process to the posterior extremity of the inferior alveolar arch.* 4. From the posterior extremity of the mylo-hyoid line. 5. The fibres which are said to arise from the base of the tongue are nothing more than those fibres of the genio-hyo-glossus, which Winslow has described as le genio-pharyngien. These are the same fibres, so difficult to demonstrate, which Valsalva and Santorini have regarded as forming a particular muscle, denominated by them the glosso-pharyngeus.

From these different origins the fleshy fibres curve backward, and then pass trans-

* As this same aponeurosis gives attachment to the buccinator, it may be conceived that the contraction of that muscle cannot be altogether without effect upon the pharynx.

versely inward; the superior form a sort of arch, having its concavity directed upward (see *figs.* 141, 147), and are inserted into the cephalo-pharyngeal aponeurosis: they form the *cephalo-pharyngeus* muscle of some authors, which is said to be continued from one side to the other without any intermediate raphé. This muscle forms a very thin layer, the fibres of which are paler and less distinct than those of the other constrictors.

Relations.—Its *external surface* is partly covered by the preceding muscle, and has behind, and on the sides, the same relations as the pharynx. This muscle forms the inner side of a triangular space already described (p. 345) (the *maxillo-pharyngeal*), the outer side of which is formed by the ramus of the lower jaw and the internal pterygoid muscle (*b*, *fig.* 141), and which is occupied by the internal carotid artery, the internal jugular vein, and the pneumogastric, hypo-glossal, and spinal accessory nerves.

Its *internal surface* (*fig.* 141) is in relation with the pharyngeal mucous membrane, with the levator palati (*c*), which it separates from the circumflexus palati (*d*), and with the palato-pharyngeus (*e*).

Action.—It is a constrictor.

Remarks.—From the preceding description, it follows, 1. That the constrictors of the pharynx form three super-imposed or, rather, imbricated muscular layers. This imbrication, or overlapping, is so arranged that the projections (very slight, it is true) formed by the upper margins of the constrictors are on the outer, not on the inner surface of the pharynx; and this has, perhaps, some relation to the downward course of the alimentary mass.* 2. That the thickest part of the muscular layer formed by the constrictors is opposite the buccal portion of the pharynx, where the lower and middle constrictors overlap; and that the thinnest part is in the nasal portion, which is formed by the superior constrictor alone. 3. That the pharyngeal insertions of all the constrictors are upon a single line, the median raphé, while their points of origin are exceedingly numerous, viz., commencing from below, the cricoid cartilage, the thyroid cartilage, the great and lesser cornua of the os hyoides, the base of the tongue, the mylo-hyoid line, the buccinato-pharyngeal aponeurosis, and, lastly, the pterygoid process.

The Extrinsic Muscles.

The extrinsic muscles of the pharynx are generally two in number, the stylo-pharyngeus and the palato-pharyngeus. The latter has been already described among the muscles of the velum palati. It is by no means uncommon to find several supernumerary muscles

The Stylo-pharyngeus.

This muscle (*r*, *figs.* 143, 147), which is round above and broad and thin below, *arises* by tendinous and fleshy fibres from the inner side of the base of the styloid process, or, rather, from the vaginal process surrounding that base. From this point it passes downward and inward, becomes wider and flattened as it enters the pharynx between the middle and superior constrictors, to spread out beneath the mucous membrane. Its upper fibres ascend, the middle are transverse, and the lower fibres descend to terminate along the posterior border of the thyroid cartilage† (see *fig.* 143). These fibres, together with those of the palato-pharyngeus, form the fourth muscular layer of the pharynx.

Relations.—*Before entering the pharynx*, the stylo-pharyngeus is in relation on the outside with the stylo-glossus muscle (*u*), the external carotid artery, and the parotid gland; on the inside, with the internal carotid and the internal jugular vein. Its most interesting relation is with the glosso-pharyngeal nerve, which runs along its outer side. Some branches of the nerve often pass through it. *In the pharynx* it is covered by the middle constrictor, and it lies outside the superior constrictor, the palato-pharyngeus, and the mucous membrane.

Action.—It raises the larynx and the pharynx.

Supernumerary Muscles of the Pharynx.

Among the supernumerary extrinsic muscles of the pharynx, I shall notice, 1. A fasciculus pointed out by Albinus, which I have often met with: it *arises* from the petrous portion of the temporal bone, and passes into the walls of the pharynx; it is the *petro-pharyngeus* of some authors. 2. A very strong fasciculus, arising from the basilar process in front of the foramen magnum, passing downward and inward, and interlacing with its fellow of the opposite side in the median line: it may be called the *occipito-pharyngeus*. 3. A small muscle, which I have seen arising by well-marked tendinous fibres from the summit of the hamular process of the internal pterygoid plate, passing obliquely inward and downward, and expanding on the walls of the pharynx; it may be called the *extrinsic pterygo-pharyngeus*. 4. Riolanus has described a *spheno-pharyngeus* arising from the spinous process of the sphenoid, and Santorini and Winslow have noticed a *salpingo-pharyngeus* arising from the cartilaginous portion of the Eustachian tube and the contiguous bone, and blended in the pharynx with the palato-pharyngeus.

* In the construction of pipes or tunnels for the conveyance of water, &c., each piece is received into that below it; an opposite arrangement would facilitate the blocking up of the pipe.

† Some anatomists affirm that they have seen fibres from this muscle reaching the base of the tongue, the epiglottis, and the os hyoides.

Such, then, are the muscles of the pharynx. They are all, as we have seen, constrictors, and at the same time elevators, in consequence of their fibres rising to a greater height internally upon the median line than they do externally; the stylo-pharyngeus alone can be regarded as a dilator. Indeed, dilatation is chiefly effected by the muscles of the os hyoides, by the action of which the larynx is carried upward and forward; we may, therefore, with Haller, consider them as extrinsic muscles of the pharynx.

Pharyngeal Mucous Membrane.—The muscular semi-canal of the pharynx is lined by a mucous membrane continuous with the buccal and nasal mucous membranes on the one hand, and with those of the larynx and œsophagus on the other. This membrane, which is of a reddish colour, presents some peculiarities at different parts of its extent. Above, near the basilar process, it is thick, and, as it were, fungous, and closely united to the periosteum, from which, indeed, it cannot be separated; in this region it is very liable to become the seat of fibrous polypi. Near the posterior orifices of the nasal fossæ and the openings of the Eustachian tubes, it is, in some respects, similar to the pituitary membrane.* It forms a sort of rim around the trumpet-shaped orifice of the Eustachian tube, into which it is prolonged in a remarkable manner, gradually becoming thinner, and at length continuous with the lining membrane of the cavity of the tympanum. This continuity of the mucous membrane of the pharynx and Eustachian tube explains the close sympathy between these parts, and also the deafness which so frequently follows chronic sore throats and coryzæ, in consequence of the obstruction of these tubes.

In its buccal portion it exactly resembles the mucous membrane, upon the lower surface of the velum palati: the part covering the posterior surface of the larynx is pale, and forms several folds.

The mucous membrane of the pharynx adheres to the subjacent muscles only through the medium of very loose cellular tissue, which is never loaded with fat, nor infiltrated with serosity. It is still less intimately adherent to the posterior surface of the larynx.

Its surface is raised by a great number of small glands, chiefly occupying the upper part of the pharynx, near the posterior nares: we shall divide them into *agglomerated* and *solitary*. Two agglomerated glands are always situated around the orifices of the Eustachian tube; they open upon the mucous membrane, either separately or together. These glands are sometimes arranged in a line, sometimes in several parallel rows. Haller believes that the salpingo-pharyngeus of Santorini and Winslow is nothing more than a series of these glands united together by fibrous tissue. The solitary glands are scattered over the whole extent of the pharynx. Lastly, the pharyngeal mucous membrane is provided with a thin epithelium,† which can be easily demonstrated by maceration and the action of acids.

Vessels and Nerves.—The pharynx receives a principal *artery* on each side, viz., the inferior pharyngeal, a branch of the internal carotid. The superior pharyngeal branch of the internal maxillary, and some small twigs from the palatine and the superior thyroid, complete its arterial system.

Its *veins* form a very considerable plexus around it (the *pharyngeal venous plexus*), and terminate in the internal jugular and superior thyroid. The *lymphatic vessels* are little known; they pass into the glands lying along the internal jugular vein. Its *nerves* are very numerous, and form a remarkable plexus—the *pharyngeal*, which I regard as one of the largest in the body. They are derived from two sources: 1. From the cerebro-spinal axis, viz., the *pharyngeal nerve*, a branch of the pneumogastric, which appears to be principally distributed to the muscular layer; the *glosso-pharyngeal*, which appears to be chiefly destined for the mucous membrane; and, lastly, some branches of the superior laryngeal and the spinal accessory. 2. From the ganglionic system, several large, gray, and soft branches being distributed to it from the superior cervical ganglion.

This abundance of nerves, and also the sources from which they are derived, will serve to explain, 1. The great sensibility of the pharynx, to which part we refer the feeling of thirst, which some have, therefore, proposed to term the *pharyngeal sense*; 2. The part which it performs in the perception of certain flavours, for example, those of acids; 3. The sympathy between the pharynx, the base of the tongue, and the stomach; 4. The feelings of constriction and strangulation, so common in the pharynx; 5. The spasms with which it is affected in tetanus and hydrophobia; and, 6. The nature of the globus hystericus, &c.‡

Development.—The development of the pharynx offers no remarkable phenomena; still, it is an exception to the general law of bilateral development, laid down by some anatomists.

Uses of the Pharynx.—The pharynx is one of the principal organs of deglutition. It

* See note, *infrà*.

† [According to Dr. Henlé, the upper part of the mucous membrane of the pharynx is covered with a ciliated columnar epithelium, as far down as a horizontal line extending from the lower border of the atlas to the floor of the nasal fossæ; below that line the epithelium assumes the squamous form, and is not ciliated. In the Eustachian tube it is also columnar, and provided with cilia; but in the cavity of the tympanum it is squamous, and destitute of those organs.]

‡ We cannot explain why the syphilitic virus has so serious a predilection for the mucous membrane of the pharynx.

serves also for the passage of air in respiration, and as a tube for modulating the voice. The importance of the pharynx in this last point of view, and the influence which its different degrees of shortening and constriction exercise upon the compass of the voice, do not appear to me to have sufficiently engaged the attention of physiologists.

The Œsophagus.

The *œsophagus* (οἴσω, I will convey, and φάγω, I eat) is a musculo-membranous canal, an organ of deglutition, intended to convey the food from the pharynx into the stomach. It occupies the lower part of the cervical region and all the thoracic region, and perforates the diaphragm, in order to terminate in the stomach.

Directions.—It is situated in the median line, resting against the vertebral column; its general direction is straight, for the food does not remain in it; nevertheless, it presents several slight curves; at its commencement it is exactly in the middle line, but inclines somewhat to the left side in the neck; in the upper part of the thorax it deviates slightly to the right side, then again becomes median, and, lastly, inclines to the left, where it passes through the diaphragm. The general direction of the œsophagus permits the introduction of straight probangs into the stomach. The inflection which it undergoes at its entrance into the thorax explains the reason why these instruments are sometimes arrested opposite the first rib.

Dimensions.—The length of the œsophagus corresponds to the interval between the pharynx and the stomach, *i. e.*, the space between the fifth cervical vertebra, or the cricoid cartilage, and the tenth dorsal vertebra. In regard to its calibre, or *diameter*, the œsophagus is the narrowest part of the alimentary canal. Its diameter is not uniform throughout, the cervical portion* being certainly the narrowest; and, therefore, foreign bodies which are too large to pass through the alimentary canal, are generally arrested in the neck. The widest portion of the œsophagus is its lower end.

The œsophagus is capable of a certain degree of dilatation, as is proved by the passage of large foreign bodies for a considerable distance through it (*Mém. d'Hévin, Acad. Roy. de Chirurgie*), sometimes even as far as the stomach. That this dilatability, however, is very limited, may be inferred from the pain caused by swallowing too large a morsel, and also from the stoppage of foreign bodies in the gullet. Nevertheless, in some cases, from external pressure upon, or from stricture of, some part of this canal, it becomes greatly enlarged above the seat of obstruction, and forms a sort of ampulla or dilatation resembling the crop in gallinaceous birds. In one case I found a sort of pouch, or diverticulum, of the mucous membrane, of considerable size, protruding between the separated muscular fibres, and at first sight resembling the crop of gallinaceous birds. An example has been recorded of dangerous suffocation occasioned by the pressure of alimentary matters in a cavity of that kind.

Figure.—The œsophagus is cylindrical, and differs from the rest of the alimentary canal in never containing any air, so that (when at rest) its parietes are always in contact. It is somewhat flattened, and, as it were, compressed, at its upper part; but below it always presents the appearance of a solid cylinder, or a dense firm cord. This appearance exists through its whole extent in some animals, the horse, for example.

Like all hollow organs, the œsophagus presents two surfaces, an external and an internal.

The *external surface.* In its long course the œsophagus has many relations, all of which are of great importance, and must be examined in the neck, in the thorax, and in the abdomen.

In its *cervical portion* (*y, figs.* 114, 140), the œsophagus is in relation *in front* with the membranous portion of the trachea (*x*), beyond which it projects a little on the left side. The cellular tissue uniting these two canals is most condensed above. All that portion which projects beyond the trachea comes into relation with the left sterno-thyroid muscle (*n, fig.* 114), the thyroid body (*z*), the left recurrent laryngeal nerve, and the inferior thyroid vessels, which cross it at right angles. The relation of the œsophagus to the trachea explains how foreign bodies arrested in the former passage may compress the trachea, and impede or even prevent respiration. The deviation of the œsophagus to the left is the reason for selecting that side for the performance of œsophagotomy. *Behind*, it corresponds to the longi colli muscles and to the vertebral column, being united to them by loose cellular tissue, so that it is enabled to execute those movements which are necessary for the performance of its functions. *Laterally*, it corresponds to the thyroid body, the common carotid artery, and the internal jugular vein; but these relations are somewhat modified on each side, in consequence of the deviation of the œsophagus. Thus, the relations of the œsophagus with the left common carotid are much more immediate than those with the right. The left recurrent nerve lies in front of the œsophagus, the right nerve a little behind it.

Its *thoracic portion* (*o, fig.* 161) is situated in the posterior mediastinum, and is in relation in *front*, commencing from above, with the trachea, then with its bifurcation, and slightly also with the left bronchus, which crosses it obliquely, and which may be com-

* [Opposite the cricoid cartilage.]

pressed by it during the retention of a foreign body (an example of this accident has been recorded by Habicot); lastly, it is situated opposite and behind the ascending portion of the arch of the aorta, and the base and posterier surface of the heart, from which parts it is separated by the pericardium. *Behind*, it is in relation with the longus colli and the vertebral column, to which, however, it is not so closely applied as in the neck; nor does it follow the curvature of the spine in the dorsal region, but is separated from it by a space filled with cellular tissue, lymphatic glands, the vena azygos, and the thoracic duct, the latter being placed to its right side, at the lower part of the thorax, but passing behind it above, so as to reach the left side. Below, at the point where the œsophagus deviates to the left side, in order to gain the opening of the diaphragm, it lies in front of the aorta. On each side it forms a projection along the wall of the mediastinum, which is thus brought into relation with the corresponding lung; it is much more prominent on the right than on the left side. On the *left side* it is also in contact, in its entire extent, with the thoracic aorta (*h*, *fig.* 161), which is situated a little behind it. Above, it has immediate relations with the arch of the aorta, as that vessel is passing backward and to the left side of the vertebral column. It is commonly, at this point, that aneurisms of the aorta open into the œsophagus.

In all this region the œsophagus is enveloped by a serous cellular tissue, extremely loose and very abundant; it is surrounded by a great number of lymphatic glands, which have been improperly named œsophageal. These glands, when enlarged, sometimes compress the gullet so much as completely to arrest deglutition. Lastly, the two pneumogastric nerves run along each side of the œsophagus; inferiorly the left comes in front, and the right retires behind the canal: they communicate with each other throughout their course by loops or arches, which, perhaps, explains the pain caused by swallowing too large a mass of food.

In its *abdominal portion* (if such can be said to exist), the œsophagus is in relation with the œsophageal opening of the diaphragm, below which it is entirely covered by the peritoneum. On the right side and in front it is embraced by the left extremity of the liver; behind, by the lobulus Spigelii. In some subjects the abdominal portion of the œsophagus is an inch in length, but this, I think, is occasioned by descent of the stomach.

The *internal surface* is remarkable for its pale colour, which contrasts strongly with the rosy hue of the stomach and the upper part of the pharynx, for the wrinkling of its parietes and their contact with each other, and, lastly, for its longitudinal folds, which seem to have reference to the necessity for its momentary distension during the mere passage of the food through it.

Structure.—The œsophagus is essentially composed of two cylindrical membranes, one internal or mucous, the other external or muscular.

The *muscular coat* is remarkable for its thickness, which greatly exceeds that of any other part of the alimentary canal, and is connected with the necessity for the rapid passage of the alimentary mass from the pharynx into the stomach. It is susceptible of hypertrophy, as we find in cases of stricture of the lower part of the gullet. I have seen it five or six lines thick. In all herbivorous animals in which the œsophagus is almost incessantly in action, in those in which the food is carried upward in opposition to gravity during the act of deglutition, in the horse and in ruminants, the muscular coat is still more developed than in man.

The muscular coat is of a red colour immediately below the pharynx, and rosy through the rest of its extent, but of a darker tint than in the succeeding portion of the alimentary canal. It is of a vivid red in herbivora.*

This coat is composed of two very distinct layers, the external consisting of longitudinal fibres regularly disposed upon all sides of the œsophagus; the internal, of circular fibres, in which we shall in vain seek for the spiral arrangement described by some anatomists as existing in animals and in man.† The longitudinal fibres seem to arise, at least in part, from the posterior surface of the cricoid cartilage, in the median line, between the two posterior crico-arytenoid muscles; they evidently become continuous below with the longitudinal muscular fibres of the stomach. The first muscular ring of the œsophagus appears to arise from the cricoid cartilage; it has been designated the *crico-œsophageus*. There is no sphincter, as some anatomists have affirmed, round the lower extremity of the œsophagus.

The Mucous Membrane.—As Bichat has remarked, the mucous membrane of the œsophagus is, perhaps, next to the buccal, the thickest in the alimentary canal. By a remarkable exception (also observed in the rectum), its outer surface is united to the adjacent membrane by a very loose cellular tissue; so that the whole mucous cylinder may be removed entire from the sort of muscular sheath in which it is contained. It has even been said that the muscular coat can force the mucous membrane downward by its contraction, so as to produce a projecting rim around the cardiac orifice of the stomach, analogous to that which is formed at the anus in prolapsus. The *longitudinal folds* of

* [It consists of involuntary muscular fibres (note, p. 323), intermixed with fibres possessing transverse striæ.]

† [These fibres are obviously spiral in the ruminant, and many other mammalia.]

the mucous membrane are not caused by the contraction and elasticity of the circular fibres of the muscular coat, but depend upon a peculiarity of structure. If the first hypothesis be correct, why should not the mucous membrane also present transverse folds from the action of the longitudinal fibres? for the extremities of the œsophagus are not so fixed, nor is its tension so great that it could not be shortened by the action of these fibres.

Besides the longitudinal folds, there are also in the œsophagus a number of *wrinkles* analogous to those of the skin, and, therefore, irregular; they appear to me to be caused by the elasticity of the muscular fibres.

The mucous membrane of the œsophagus has a thick *epithelium*, which may be easily shown by maceration and the action of acids, or even without preparation, and which terminates at the cardiac orifice of the stomach by an irregularly fringed or festooned border.*

When examined by the microscope, the free surface of the mucous membrane presents a number of small linear ridges, running vertically, and united together by other oblique ridges, so that the whole surface has a reticulated aspect. These ridges are formed by papillæ or villosities, the arteries and veins of which have been accurately figured by Bleuland.

The surface of the mucous membrane is raised in various places by small, oblong, and flat glands found here and there over the entire œsophagus. They were first described by Steno, and should be carefully distinguished from the œsophageal lymphatic glands: the latter are external to the œsophagus, and, in certain animals, frequently contain small entozoa: they have been supposed to open into the œsophagus, and to deposite within it a fluid containing these animalcules, which some physiologists have regarded as the chief agent in digestion. Any communication, however, between these lymphatic glands and the cavity of the gullet is purely accidental. The true œsophageal glands are very numerous.†

In the œsophagus, there is only a trace of the *fibrous membrane*, which forms the framework of the alimentary canal; it adheres to the muscular coat, and is, therefore, but loosely attached to the mucous membrane.

There is no external *serous* membrane; it would not have yielded to the instantaneous dilatation required in the œsophagus. The two laminæ of the posterior mediastinum corresponding to its sides may be regarded as forming the rudiment of a serous coat.

Vessels and Nerves.—The *œsophageal arteries* are numerous, and arise from several sources. They may be distinguished into the *cervical*, proceeding from the inferior thyroid; the *thoracic*, given off either directly from the aorta or from the bronchial and intercostal arteries, and sometimes from the internal mammary; and, lastly, the *abdominal*, arising from the coronary artery of the stomach, and the inferior phrenic.

The *veins* terminate in the inferior thyroid, the superior cava, the azygos, the internal mammary, the bronchial, the phrenic, and the coronary of the stomach.

The *lymphatic vessels* enter the numerous glands which surround the œsophagus.

The *nerves* are very numerous, and are derived from the pneumogastrics, which surround the œsophagus with a series of loops; these are joined by some branches from the thoracic ganglia of the sympathetic.

The *development* of the œsophagus presents nothing worthy of notice.

Functions.—The œsophagus is intended to convey the food rapidly from the pharynx to the stomach. This function is performed by its longitudinal fibres shortening the passage, and by its circular fibres contracting it successively from above downward during deglutition; in vomiting or regurgitation, the contraction proceeds from below upward.

Fig. 148.

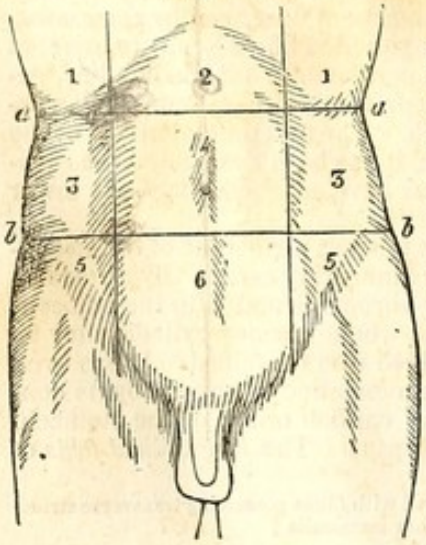

The Stomach.

The *stomach* (γαστὴρ, *ventriculus*), one of the principal organs of digestion, is that wide dilatation (*s*, *fig.* 139) of the alimentary canal, intervening between the œsophagus (*a*) and the duodenum (*b c*), in which the food is collected and converted into chyme.

Situation.—It is situated at the junction of the upper tenth with the lower nine tenths of the alimentary canal, between the organs of deglutition and those of chylification. It occupies the upper part of the abdominal cavity (*s*, *figs.* 155, 161), almost entirely fills the left hypochondrium, and advances into the epigastrium, as far as the limits of the right hypochondrium.‡

* [The epithelium is, in fact, continued on through the rest of the alimentary canal, but becomes thinner, and assumes a different character: in the œsophagus it is squamous.]

† [Especially around the lower extremity of the gullet.]

‡ [In order to facilitate the description of the viscera contained in the abdominal cavity, anatomists have adopted the following artificial division of that cavity into several regions: The abdomen is first divided into three zones by two horizontal lines, one (*a a*,

It is maintained in its place by the œsophagus and duodenum, and also by some folds of the peritoneum, which connect it with the diaphragm, the liver, and the spleen. The stomach is, therefore, less subject to displacement than most of the abdominal viscera. It may even be generally stated, that almost all the changes in the relative situation of this organ are the results of displacements or alterations in the size of those organs which are connected with it. I do not here refer to examples of complete transposition of the viscera, nor to those cases of malformation of the diaphragm, in which the stomach has been found in the thorax.

Direction.—The stomach is directed obliquely downward to the right side, and a little forward; this direction affords some explanation of the almost constant habit of lying on the right side during sleep, and why the rest is disturbed and digestion rendered difficult in those who lie upon the left side. Changes in direction of the stomach depend upon the same causes as changes in its situation. Thus, dragging produced by displacement of the small intestine or the omentum, enlargements of the liver or spleen, or the use of too tight stays,* must necessarily affect the direction of this organ. We not unfrequently find stomachs having a vertical direction.

Number.—The stomach is single in the human subject as well as in the greater number of animals. The examples of double or triple stomachs in the human subject are merely cases of single stomachs having one or more circular constrictions.† The essential character of a double stomach is not an accidental or even a congenital contraction, but a difference in structure. *Bilocular* stomachs, indeed, are very common; but this form (resembling that of some kinds of calabash-gourds), though sometimes extremely well marked when the stomach is empty, disappears almost entirely when it is much distended by inflation.

Size.—In all animals, the stomach is the most capacious part of the alimentary canal; so that, in many species, where its limits are not so clearly defined as in man, the existence of a stomach is determined only by the presence of a dilatation. It is of considerable size in herbivora, but comparatively much smaller in carnivora. The human stomach is intermediate between these extremes—a fact which affords evidence of its adaptation to both vegetable and aliment diet. The human stomach, however, presents innumerable varieties in size, from a state of extreme contraction, in which it scarcely exceeds the duodenum, to such an enormous degree of dilatation that it occupies a third, a half, or even almost the whole, of the abdominal cavity. These differences depend less upon original variations, than upon its peculiarly dilatable and elastic structure, which enables it to contain a large quantity of food, and to contract more or less completely upon itself when empty. Thus, the stomach has a much greater capacity in those who adopt the bad habit of eating only one very full meal in the twenty-four hours, than in those who eat more frequently, but less abundantly. In some cases of stricture at the pylorus, it becomes enormously distended. Long-continued abstinence occasions such an amount of contraction, that it has even been asserted, that pain resulting from the rubbing of its parietes together gives rise to the feeling of hunger; but this completely mechanical hypothesis should be rejected. In a great number of cholera patients, the stomach was found to be exceedingly small. In a female, who died a month after having voluntarily swallowed a small quantity of sulphuric acid, the contracted stomach was not larger than a moderately-sized gall-bladder.

Figure.—The stomach resembles a flattened cone, curved upon itself backward and upward, and having a rounded base; it has been compared to the bladder of a bagpipe. Sections made at right angles to its axis represent circles gradually decreasing in size from the entrance of the œsophagus to the pylorus. We have to examine its external and its internal surface.

The *external surface.* From the peculiar form of the stomach, we are enabled to consider an anterior and a posterior surface, a convex border or great curvature, and a concave border or lesser curvature, a great cul-de-sac or tuberosity, an œsophagal extremity, and a pyloric extremity.

The *anterior surface* (*upper surface* of some anatomists, *s*, *fig.* 155) is directed forward, and a little upward. When inflated in the dead body with the abdomen open, it is turned directly upward; but such cannot take place, either in the living or dead subject,

fig. 148) extending between the most prominent points of the cartilages of the ribs, and the other (*b b*) between the crests of the iliac bones. The superior zone is called the epigastric; the middle, the umbilical; and the inferior, the hypogastric. These three zones are then subdivided by two vertical parallel lines drawn from the cartilages of the eighth rib down to the centre of Poupart's ligament. The epigastric zone is thus divided into two hypochondriac (1 1), and a middle epigastric region (2); the umbilical into two lumbar (3 3), and a middle umbilical region (4); and the hypogastric into two iliac (5 5), and a middle hypogastric region (6).]

* It is impossible to insist too strongly upon the influence of too tight stays on the situation, and even the form, of the viscera occupying the base of the thorax. Thus, changes in the situation and direction of the stomach are much more frequent in females than in males. Sœmmering observed, but without stating the cause, that the stomach is more rounded in the male, and more oblong in the female.

† It may, strictly speaking, be stated that ruminants have only one stomach, the *rennet* or *obomasum*; and that the first three, viz., the *paunch*, the *reticulum*, and the *manyplies* or *omasum*, are nothing more than dilatations of the œsophagus, in which the food undergoes a preparatory elaboration. The same observation applies to birds, in which the crop and the gizzard are not organs of chymification, the first being merely an organ of insalivation, the second one of trituration.

when the abdominal parietes are entire; in which case the distended stomach passes in the direction of the least resistance, *i. e.*, forward and downward, and its anterior surface cannot then be completely turned up.

This surface is in relation with the diaphragm, and is separated by it from the heart; with the liver, which is prolonged upon it to a greater or less extent;* with the last six ribs, being separated from them by the diaphragm; and with the abdominal parietes in the epigastrium: hence the name given to that region. It is not uncommon to find the great omentum turned upward between the stomach and the liver. When distended, the stomach has much more extensive relations with the epigastrium, or, rather, with the abdominal parietes, both in a vertical and transverse direction.

All these relations are of the greatest importance; and, with the exception of those which concern the epigastrium, they are constant. In fact, it rarely happens that the stomach precisely corresponds to the sub-sternal or xiphoid depression, which has been called the pit of the stomach, or the *scrobiculus cordis*, but which belongs neither to the heart nor the stomach. In exploring this depression, it is almost always the liver which is felt; the stomach lies lower down, and is generally below the ensiform appendix.

The *posterior surface* (*inferior surface* of some anatomists, seen turned up at *s*, *fig.* 154) is directed downward and backward, and is seen in the sac of the omentum, of which it forms the anterior wall.

It has relations with the transverse mesocolon, which serves as a floor for it, and separates it from the convolutions of the small intestines; with the third portion of the duodenum (*e'* to *b*), by some of the older anatomists called the pillow of the stomach (*ventriculi pulvinar*); and, lastly, with the pancreas (*o*). The duodenum, the pancreas, the aorta (*a*), and the pillars of the diaphragm (*d d*), separate it from the vertebral column, upon which it rests obliquely. These relations are modified by the emptiness or fulness of the stomach.

The *great curvature* (the *inferior* or *anterior border* of some anatomists, *c a d*, *fig.* 149) is convex, and directed almost vertically downward in the empty condition of the organ, and almost directly forward when it is full; it gives attachment to the two anterior layers of the great omentum. It is in relation with the abdominal parietes and the cartilages of the lower ribs, and lies along the transverse arch of the colon (*t*, *fig.* 155), in front of which it advances when considerably distended; hence it was termed the colic border by Chaussier. In the distended state its relations with the abdominal parietes become much more extensive; but even then I can scarcely believe the assertions of some, that the pulsations of the gastro-epiploic arteries can be felt by the finger in emaciated individuals.

Fig. 149.

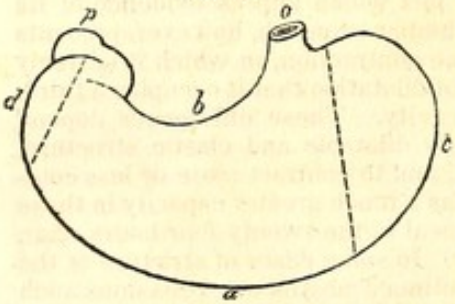

The *lesser curvature* (the *superior* or *posterior border* of some anatomists, *o b p*, *fig.* 149) is concave, and extends from the œsophageal orifice to the pylorus; it gives attachment to the small or gastro-hepatic omentum; it is directed upward when the viscus is empty, upward and backward when it is full; and it then embraces the vertebral column in its curvature, being separated from it by the aorta and the pillars of the diaphragm (see *fig.* 154); it also embraces the small lobe of the liver or the lobulus Spigelii, the cœliac axis (*t*), and the solar plexus of nerves.

The *great extremity* or *great cul-de-sac of the stomach* (the *bottom* or *great tuberosity*, from *c* to the dotted line, *fig.* 149) comprises all that portion which is to the left of the cardiac or œsophageal opening; it is a sort of semi-spheroid, applied to the base of the cone formed by the rest of the stomach; it is the highest and the largest portion of that organ; it is almost entirely absent in carnivora; it is very large in herbivora, and of a medium size in man. There are also many individual varieties in the size of this portion of the stomach; I have met with some instances in which it was not larger than it is in carnivora.

It is in contact with the spleen (*k*, *fig.* 154) (hence it is called the *splenic extremity* by Chaussier), with which it is connected by a fold of the peritoneum, called the *gastro-splenic omentum*, and by the vasa brevia. When the stomach is distended it comes into close contact with, and is, as it were, moulded upon, the spleen (see *fig.* 161). From this relation a great number of physiological inferences may be deduced.† The great cul-de-sac occupies the left hypochondrium, and corresponds also, in the greater part of its

* The relations of the anterior surface of the stomach with the liver are very variable in extent; it sometimes reaches even to the gall-bladder. I have seen a case in which the gall-bladder adhered to the anterior surface of the stomach, and, therefore, to the left of the pylorus, and communicated with it by an orifice, through which bile and biliary calculi were discharged.

† The great end of the stomach is so closely connected with the spleen, that it necessarily follows all displacements of that organ. I have met with a case in which the spleen, three or four times its natural size, was situated in the umbilical region, and had dragged down the great end of the stomach with it. The left extremity of the transverse colon, and the upper part of the descending colon, occupied the place of the great extremity of the stomach. The patient had long suffered from indigestion, which had been attributed to chronic gastritis.

extent, to the left half of the diaphragm, which is in accurate contact with it, and separates it from the lungs above and from the last six ribs in front. It is more or less elevated, according to the degree of distension of the stomach; and from this we can easily understand that difficult respiration may be caused by too large a meal.

Lastly, it may be stated that the great extremity of the stomach has relations behind with the pancreas, and with the left kidney and supra-renal capsule.

The *œsophageal extremity* (*o*, *fig.* 149). The œsophagus opens into the stomach at different angles, according to the emptiness or fulness of that organ. The situation of this opening, which is improperly denominated the *cardia* (*cor*, heart), is at the left extremity of the lesser curvature, to the right of the great cul-de-sac, and opposite the œsophageal opening in the diaphragm. It is embraced (*c*, *fig.* 154) in front by the left extremity of the liver, which sometimes forms a half circle round it, and behind by the lobulus Spigelii. It is surrounded by a circle of vessels and some nerves. Examined externally, the lower end of the œsophagus is continuous with the stomach, without any other line of demarcation than that depending upon a difference in size and direction. The peritoneum is directly reflected from the diaphragm upon the œsophagus and the stomach, and forms the gastro-diaphragmatic fold (ligamentum phrenico-gastricum, *Sœmmering*).*

The *pyloric extremity* (*pylorus*, from πύλη, a gate, and οὖρος, a keeper, *p*, *figs.* 149, &c.) is situated at the right extremity of the stomach. It forms the apex of the cone, and presents a circular constriction or strangulation, which exactly defines the limits between the stomach and duodenum. About an inch from this constriction the stomach is much curved, so as to form a decided *bend*, and presents a dilatation, on the side of the great curvature corresponding to an internal excavation, called by Willis the *antrum pylori*, and by others the *small cul-de-sac of the stomach* (from *d* to the dotted line *e*). Not uncommonly we find a second dilatation near the first, and a third, still smaller, on the side of the lesser curvature, resulting from the bend formed by the stomach. The pyloric extremity of the stomach is directed to the right side, backward and upward, and sometimes even a little to the left, when the stomach is much distended.

The relations of the pyloric extremity with the abdominal parietes are very variable, for the changes in the situation of the stomach chiefly affect this extremity. It corresponds to the limit between the epigastrium and the right hypochondrium; sometimes it is in relation with the gall-bladder, and hence may become stained; in some cases it passes to the right of the gall-bladder, to the extent of an inch or an inch and a half. I have seen it occupying the horizontal fissure of the liver, the edges of which were separated for its reception. Very commonly we find the pylorus in the umbilical region. I have seen it in the hypogastrium in a female who was affected with schirrus of the pylorus, and I have also found it in the right iliac fossa. It is, therefore, extremely difficult to determine the seat of an organic lesion of the pylorus from external examination.

The relations of the pylorus with the abdominal viscera are more constant: above, it corresponds to the liver and the lesser omentum; below, to the great omentum; in front, to the abdominal parietes; and behind, to the pancreas. It is not uncommon to find it adhering to the gall-bladder.

The Internal Surface.—This presents the same regions as the external surface; all its peculiarities may be referred to the mucous membrane, which will be noticed when the structure of the stomach is described. Besides these, however, we observe here the two orifices of the stomach.

The *œsophageal orifice* (cardiac, left, or superior orifice, *ostium introitus*, *o*, *fig.* 150) is remarkable for its radiated folds (ad stellæ similitudinem, *Haller*), which are effaced by distension; for the irregularly fringed border and the change in colour which mark the limits between the mucous membrane of the œsophagus and of the stomach; for its size and its capability of dilatation; and, lastly, for the total absence of any valve or sphincter.

Fig. 150.

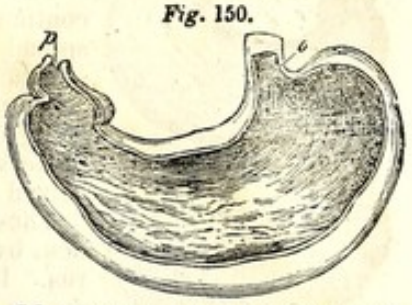

The *duodenal* or *pyloric orifice* (right or anterior orifice, *janitor*, *sphinctor*, *ostium*, *exitus*, *p*) is remarkable for an internal rim, or *circular valve*, which in a distended and dried stomach forms a sort of diaphragm (in speciem diaphragmatis, qualia sunt in tubis telescopicis, *Morgagni*); for the narrowness of the passage, which, with difficulty, admits the little finger in most subjects; for its slight dilatability; and, lastly, for the existence of a muscular ring, which may be regarded as a true sphincter. It is of importance to remark, that this orifice, independently of any disease, presents a great number of varieties in its dimensions, and it is probable that these congenital or acquired variations may have some influence upon its diseases.

The relative position of these two orifices is an important anatomical point. Upon this we should observe, 1. That they are but little apart from each other, considering

* [Hence this extremity is comparatively fixed.]

the size of the stomach, and that the interval between them does not increase in proportion to that size; 2. That the œsophageal orifice is directed upward, the pyloric opening backward and a little upward; 3. That the two openings are not upon the same plane, the œsophageal being higher and more posterior than the pyloric.

The Structure of the Stomach.—In order to study the structure of the stomach, it is necessary, in the first place, to distend it. Two stomachs are indispensable for this purpose, one to be dissected from without inward, and the other from within outward. One of the stomachs should be everted, and then inflated.

The parietes of the stomach are formed by the super-position of *four membranes* or coats, differing in texture and properties. These, proceeding from without inward, are the serous, the muscular, the fibrous, and the mucous coats. We must also examine the vessels, nerves, and cellular tissue, which enter into the composition of these parietes.

1. The *serous* or *peritoneal coat.* Like almost all the movable viscera of the abdomen, the stomach receives a complete covering from the *peritoneum* (*membrana communis* of the ancients; la membrane capsulaire, *Chauss.*). It is formed in the following manner: Two layers of the peritoneum, in contact with each other, pass from the transverse fissure of the liver to the lesser curvature of the stomach: there they separate, so as to leave between them a triangular space, the base of which corresponds to the lesser curvature; the anterior layer then passes over the anterior surface of the stomach, and the posterior covers it behind; they again approach each other at the great curvature, along which they form another triangular space, exactly resembling that which we have already described as existing at the lesser curvature, and then unite so as to form the two anterior layers of the great omentum (see description of *Peritoneum*). The same arrangement takes place at the great extremity of the stomach. Bloodvessels pass round the stomach, along the line where the two layers of the peritoneum are applied to each other at its two curvatures.

The peritoneum, therefore, forms a complete covering for the stomach, excepting at the curvatures, where we find triangular spaces, into which the stomach is forced during its distension. I doubt whether these triangular spaces can afford sufficient space for the stomach when greatly distended, and I believe that, in such cases, the two anterior layers of the great omentum separate, and are applied upon that organ. It is evident, besides, that distension of the stomach chiefly affects its great curvature.

The peritoneal coat does not adhere firmly to the subjacent tissues of the stomach, in the neighbourhood of either curvature; but it is closely united to them at the middle points of both surfaces. The imperfect extensibility of the peritoneal coat requires such an arrangement as exists along the curvatures. I have observed some small fibrous bands in the sub-serous cellular tissue along the lesser curvature, which must be intended to maintain the shape of that part. The uses of the peritoneal coat, in reference to the stomach itself, are merely mechanical; it strengthens, preserves the shape, and facilitates the movements of this organ.

The Muscular Coat.—This coat has engaged much of the attention of anatomists since the time of Fallopius, who was the first to give a correct description of it; and to whom Morgagni (*Advers. Anat.*, iii., p. 6) has attributed the honour of discovering it, in opposition to the claims of Willis. Helvetius made it the subject of a special work (*Hist. Acad. Roy. des Sciences*, 1719).

We shall describe, in accordance with Haller (*Elem. Phys.*, tom. vi., lib. xix., sect. i., p. 126), and the majority of anatomists, three layers of muscular fibres.

Fig. 151.

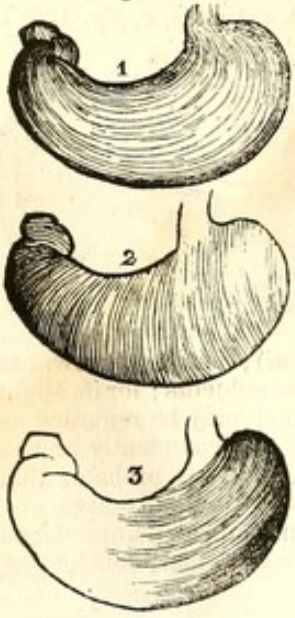

The *superficial* or *longitudinal layer* (1, *fig.* 151) is formed by a continuation of the longitudinal fibres of the œsophagus, which spread out in a radiated manner from the cardiac orifice of the stomach. They are scattered thinly over its surfaces, the great curvature, and the great extremity, but are collected into a band along the lesser curvature, the shape of which they assist in preserving. On account of this arrangement, they have received the name of *cravate de Suisse.*

These fibres form a continuous plane of considerable thickness over the contracted portion of the stomach, near the pylorus. In this situation they are stronger, and fasciculated, and appear partly to terminate in the pyloric constriction, and partly to be continued upon the duodenum.

The *second* or *circular layer* (2, *fig.* 151) is composed of fibres which cross the axis of the stomach at right angles, so as to form a succession of rings from the œsophagus to the pylorus. They are few in number at the great extremity of the stomach, but become much more numerous towards the pylorus, throughout all the contracted portion of the stomach. At the pylorus itself they form a thick ring, which forms a sort of rim, projecting in the interior. I have always found this more developed

in old age than at any other period of life. It is a true sphincter, which, by its contraction, effectually opposes the passage of food and gas from the stomach into the duodenum. It is not uncommon to find the whole of this ring, or a half, or two thirds of it, increased to the thickness of three or four lines, independently of any organic lesion.

The older anatomists admitted also an œsophageal ring (or *œsophageal sphincter*), similar to that at the pylorus, and having the power of closing the œsophageal orifice. This, however, does not exist; the last circular fibres of the œsophagus do not form a thicker layer than the others.

Lastly, the different rings formed by the circular fibres of the stomach intersect each other obliquely at very acute angles. The spiral arrangement admitted by Santorini cannot be demonstrated.

The *third muscular layer* (3, *fig.* 151), which I have only been able to see distinctly upon hypertrophied stomachs, is composed of *looped* or *parabolic fibres*, the middle portions of which embrace the great end of the stomach, extending from the left side of the cardiac orifice obliquely downward towards the great curvature, while their anterior and posterior extremities are situated upon the corresponding surfaces of this viscus. The superior loops reach the lesser curvature, the inferior the great curvature, and the intermediate loops seem to be lost upon either surface, or, rather, to become blended with the circular fibres. This layer of fibres appears intended to compress the great extremity of the stomach, and to push the food into the body of the organ, towards the pylorus.

From what has been stated, it follows that, excepting in the vicinity of the pylorus, the muscular layers of the stomach do not form a continuous plane, but have an areolar disposition: the areolæ, or spaces between the different fibres, are of considerable size; hence the necessity for a strong membrane, like the fibrous coat, which, as we shall find, constitutes the framework of the stomach.

The muscular fibres of the several layers are much paler than those of the œsophagus.* They have a pearly appearance when seen through the peritoneal coat, which has led to the supposition that they are tendinous. Hence the error of Helvetius, Winslow, and others, who regarded the two white lines running along the two surfaces of the stomach, between the curvatures, as *ligaments of the pylorus;* they are nothing more than longitudinal muscular fibres. Other authors have merely admitted some tendinous intersections of these fibres.

The muscular coat is not uniformly thick at all points. It is very thin at the great cul-de-sac, and becomes much thicker towards the pylorus. It also presents many varieties in different subjects; it is but slightly developed in large stomachs, and much more so when this organ is contracted. There is a physiological as well as a pathological hypertrophy of the muscular coat. In the latter it has been found seven or eight lines thick.

The Fibrous Coat.—This coat, the existence of which has been alternately admitted and denied, is situated between the muscular and the mucous coats, and is quite distinct from both. It was known by the ancients as the *membrana nervosa*;† it constitutes, properly speaking, the framework of the organ. In order to demonstrate this coat, it is sufficient to remove the peritoneal and muscular tunics, and then to evert the stomach and remove the mucous membrane. This experiment will also very clearly show the great strength of the fibrous coat, which, even thus unsupported, can bear considerable distension; while, on the other hand, when this coat has been divided, the remaining membrane or membranes burst through the opening thus made.

This coat should not be confounded with the dermis of the mucous membrane, for it adheres much more strongly to the muscular coat, into which it sends numerous prolongations, than to the mucous membrane, with which it is connected only by loose cellular tissue.

The fibres of this coat have not a parallel arrangement like those of aponeuroses and fibrous sheaths, but they form a very dense network, the filaments or lamellæ of which can be separated by inflation or infiltration. It is concerned in a very important manner in chronic diseases of the stomach; it is very liable to hypertrophy; and, in certain cases, acquires a thickness of several lines.

The Mucous Membrane.—The history of this membrane is curious. It was for a long time confounded with the mucus by which it is covered, being regarded as merely a dried layer of that secretion.‡ It was pointed out by Fallopius, who applied to it the very appropriate appellation of the *velvet-like tunic;* but it was first described as a separate membrane by Willis, under the title of the *glandular tunic.* The discovery was confirmed by the beautiful injections of Ruysch, who gave it the name of *epithelium;* to which term, however, he did not attach the same meaning as modern authors. It was afterward regarded as an epidermic membrane, analogous to the epidermis of the skin,◊ and capable

* [They are principally of the involuntary class, but have a few striated fibres among them (see note, p. 323)]

† [So called from its *white* appearance.]

‡ Riolanus states positively (*Anthropol*, l. ii., c. xii., p. 171) that the stomach, like the intestines, is composed of three coats, viz., a common external membrane, a nervous, and a muscular coat; and that a closely adherent mucus, consisting of the thickest part of the chyle, lines it on the inside.

◊ Such was the opinion of Haller, lib. xix. p. 132.

of being thrown off and renewed. In recent times it has been supposed to be concerned *tanquam omnium lerna malorum*, and has become in the present day the object of a great number of most interesting researches.

The mucous membrane of the stomach presents an adherent and a free surface. The *adherent surface* is united to the fibrous coat by cellular tissue, so loose as to permit very free motions. The *free surface* has the following characters: When the stomach is strongly contracted, it forms a number of folds (see *fig.* 150), the principal of which are longitudinal; these folds disappear when the organ is distended, as may be shown in an everted stomach. Their only use is to allow of the rapid distension of this organ, a condition that could not have been attained in any other mode, in consequence of the slight elasticity of the mucous coat.

These longitudinal and temporary folds, which are perfectly distinct from the permanent folds observed in other parts of the alimentary canal, are most strongly marked near the pyloris; they are extremely regular, sometimes straight and sometimes flexuous; and they proceed parallel to each other from the cardiac towards the pyloric orifice. They are intersected more or less obliquely by other winding folds of different degrees, which often give an areolar appearance to the internal surface of the stomach.

From this arrangement, it follows that dilatation of the stomach occurs principally in a direction across its long axis; the resources for dilatation in the direction of its axis are much less numerous. Of all the folds of the mucous membrane, the most important is undoubtedly that called the *pyloric valve*, which is often nothing more than a mere elevation of the membrane by the sphincter muscle.* This cellular fold is equally opposed to the regurgitation of food from the duodenum into the stomach, and to its passage from the stomach into the duodenum; it is completely effaced by distension, and it belongs as much to the duodenum as to the stomach. Its upper half has the characters of the gastric; the lower half offers those of the duodenal mucous membrane. Diseases are sometimes observed to stop at the line of separation. We may add, that the folds upon the internal surface of the stomach are formed by the mucous membrane alone; the fibrous coat does not enter into them.

Besides these folds, the mucous membrane presents numerous slight and tortuous *furrows*, dividing it into small spaces or compartments, which are either lozenge-shaped, hexagonal, polygonal, circular, oblong, or irregular.

Examined by the naked eye, the mucous membrane has a soft, spongy, tomentose, or velvety appearance; hence the name of *villous* or *velvet-like membrane*, by which it is still generally known. It is covered by a layer of mucus of variable thickness, which may be detached by friction with a coarse cloth. In order to avoid the inconveniences arising from this method, which is more or less injurious to the texture of the membrane, I have been accustomed to use a gentle stream of water, which, at the same time that it completely washes away the mucus, clearly displays the papillary structure of the surface of the membrane.

There are some stomachs which might be called *granular* or *glandular*, because the mucous membrane has a granular appearance, so that at first sight it might be imagined that some small glandular bodies (like the salivary glands) were scattered over the internal surface of the stomach; but this glandular aspect is merely apparent, depending upon the circular or semicircular direction of the furrows in the mucous membrane, which give a spheroidal character to the kind of islets that are intercepted between them. This granular appearance is seldom observed over the entire stomach; it rarely exists at the great extremity. I have found it limited to the great curvature; most frequently it occurs in the vicinity of the pylorus; sometimes it is observed over all that part of the stomach which is to the right of the œsophagus. These granulations are particularly developed in the stomach of the pig.

There is one remark upon which too much importance cannot be placed; and that is, the difference in the appearance of the mucous membrane of the great extremity of the stomach, and of the part situated to the right of the œsophagus. Sometimes the line of separation forms a perfect circle; and this is a very remarkable fact, because in man, who has a single stomach, it may be considered as a rudiment of the division into the compound stomachs found in the lower animals; for a multiple stomach results rather from some difference in the structure of the mucous membrane, than from the existence of different compartments or distinct cavities. It will not be uninteresting to connect this remark with what has been already stated regarding bilocular stomachs.

We shall now examine the characters of the mucous membrane in the *œsophageal* and in the *pyloric* portion of the stomach.

In the œsophageal portion it is thinner, softer, and more vascular, and can only be separated in flakes from the subjacent parts. When the stomach contains any liquid after death, this part is converted into a sort of pulp, which becomes of a blackish colour, from the action of the acids in the gastric fluid upon the blood contained in the vessels of the stomach. This is the *pultaceous softening*, which I regard as a post-mortem change,

* [It usually consists of the mucous membrane, the cellular coat, and the *circular* muscular fibres.]

but which has been erroneously confounded with the *gelatiniform softening*. This second portion of the mucous membrane, *i. e.*, the part situated to the right of the œsophagus, is thicker, stronger, and whiter, and may be separated entire from the other coats. Diseases often observe the line of separation between the right and the left portions of the stomach.

Modern pathologists having attached great importance to the condition of the gastric mucous membrane, it has become highly interesting to determine its characters in the healthy state; these characters relate to its colour, its consistence, and its thickness.

Colour.—It is extremely difficult to determine what *is the natural colour of this mucous membrane.* The opinion generally maintained by the best authorities, that it is either primarily or secondarily affected in the majority of diseases, compels us to reject all observations made upon persons who have died from acute or chronic diseases, or even from wounds or injuries of long standing. We are, therefore, obliged to have recourse to cases of accidental death in persons previously in health. In such cases, for example, in criminals who are executed while the stomach is empty, the mucous membrane is found of a grayish-white colour, with a slight tint of yellow and pink.* When death has occurred during digestion, the mucous membrane is found to vary from a delicate pink to the most vivid red. After putrefaction has made some little progress, we find a red or port wine colour, or a brownish black tint prevailing over the great extremity of the stomach, and at the free edges of the folds or wrinkles to which the vessels correspond; again, it is often found marked with blackish patches, or marbled; but these discolorations are the result of post-mortem transudation.

In the pultaceous and blackish softening of the mucous membrane, the colour is owing to the action of the acids in the gastric juice. When the stomach contains bile, the mucous membrane is tinged with yellow or green, and the stain sometimes remains after the longest maceration.

If the mucous membrane be rubbed with a rough cloth, so long as the vessels contain blood, we may produce a red punctuated appearance, which has been often mistaken for a sign of inflammation. Lastly, in the aged we not unfrequently observe a slate gray colour, either in points or in patches, or diffused over the surface. This colour occupies the papillæ, and may afford proof of some former irritation, but is certainly not due to any diseased action during the later periods of life. These different discolorations of the stomach must not be confounded with the alterations in its colour resulting from disease.

Thickness.—It is difficult to estimate the exact thickness of the gastric mucous membrane. Like the muscular coat, it varies in different individuals; in chronic inflammation it is twice or three times its natural thickness. In determining the thickness of this membrane, it is important to bear in mind the difference in this particular between the œsophageal and pyloric portions; the former being extremely thin, and the latter twice or three times as thick as that.

Consistence.—The same remarks apply to its consistence, for there are many individual varieties in this respect. The œsophageal portion may be torn with great ease; but the pyloric portion is so dense, that the back, and even the edge of a scalpel, may be drawn over it with considerable force without wounding it. If there has been any liquid, or even food in the stomach, in however small quantity, the mucous membrane of the œsophageal portion, when macerated, is converted into a pulp; moderate distension will then rupture the walls of the stomach, which may be broken through by the point of the finger.

From want of sufficient reflection upon this subject, men of great merit have committed serious errors in the appreciation of morbid lesions. In the gelatiniform softening, the gastric mucous membrane, as well as the other coats of the stomach, become dissolved, and resemble a solution of gelatine. In many old people, and in some adults, I have found the mucous membrane so thick and so strong, that it could be dissected off entire, and removed in one piece. This condition coexisted with the slate colour, either accompanied or not with chronic inflammation.

The Papillæ.—If we examine the mucous membrane of the stomach, placed under water, and exposed to the direct rays of the sun by the aid of a powerful lens, we shall find that its surface is very irregular, mammillated, and furrowed, so as to present an appearance very like the convolutions of the small intestine. The eminences, which are much more distinct towards the pylorus than near the œsophagus, are studded with holes, or, rather, with small pits resembling the cells of a honeycomb (*figs.* 152, 153). These alveolar depressions are well described by Home, who states that they exist only in the great cul-de-sac, while the villi occupy the

Fig. 152.

Magnified 32 diameters.

Fig. 153.

Magnified 32 diameters.

* In a great number of individuals who have died from acute or chronic diseases, the gastric mucous membrane is found in the same state as in those who have died accidentally; it is, therefore, not always affected, either primarily or secondarily, in disease

rest of the stomach. The truth is, that a precisely similar structure is observed over the whole stomach. The alveoli, or pits, are separated from each other by small projections, or *papillæ* (*fig.* 153), of which the papillæ of the tongue convey an excellent idea.*

Should these papillæ be distinguished from other projections that have been termed *villi*, by Ruysch, for example, who called the entire membrane *villoso-papillaris?* After the most minute examination, I have only detected one order of eminences,† viz., the *papillæ*, the existence of which I regard as the essential character of all tegumentary membranes, whether mucous or cutaneous, which might all, therefore, be designated *papillary membranes.* We shall return again to the structure of the papillæ.

If we examine with a lens or simple microscope a perpendicular or oblique section of the mucous membrane of the stomach, we shall perceive that it consists essentially of a strong membrane, the mucous dermis, from which arise an immense number of small eminences closely pressed together, and of unequal lengths, like the pile of velvet. These eminences are the papillæ; they are liable to great enlargement in cases of hypertrophy, and then the structure just described becomes very apparent.

The Follicles.—The follicles of the stomach can be very easily demonstrated in the pig‡ and in the horse. In the last-mentioned animal, entozoa are frequently found in the centre of these follicles, which then become developed into hard, and sometimes very large tumours. It is so difficult to demonstrate them in the human subject, that, with most anatomists, I, for a long time, doubted their existence. Haller only saw them once or twice;◊ but in some individuals they are very distinct. I found them well marked in a great number of cholera patients.‖ They are not situated in the sub-mucous cellular tissue, as is generally stated, but in the substance of the membrane itself, so as to form a projection on the inside of the stomach, but not on the outer surface. They are rounded, flattened, and perforated by a central foramen, which is usually visible to the naked eye. I have observed them upon all points of the mucous membrane, but they appear to be most numerous near the œsophageal orifice, and along the lesser curvature.¶

The Vessels and Nerves of the Stomach.—The *arteries* are very large and numerous in proportion to the size of the stomach; they must, therefore, assist in the performance of some function besides the mere nutrition of the organ; this function is the secretion of the gastric juice. They all arise from the cœliac axis, and are the coronary, the superior pyloric and right gastro-epiploic branches of the hepatic, and the left gastro-epiploic and vasa brevia, which are branches of the splenic artery. These arteries anastomose, so as to form around the stomach a vascular zone, which is in close contact with that organ during distension, but at some distance from it when empty. From this arterial circle branches are given off, which at first lie between the peritoneal and the muscular coats, but, after a certain number of divisions and anastomoses, perforate the muscular and fibrous coats, and again subdivide and anastomose a great number of times in the loose sub-mucous cellular tissue, until, having become capillary, they penetrate the mucous membrane.

The *veins* bear the same name, and follow the same direction as the arteries; they contribute to form the vena portæ. Schmiedel (*Variet. Vasorum*, No. xix., p. 26) has seen the coronary vein of the stomach anastomose with the renal vein, the pyloric with the vena azygos, and one of the venæ breves with the phrenic vein.

The *lymphatic vessels* are very numerous, and terminate in the lymphatic glands, situated along the two curvatures of the stomach. The peculiar ducts, said to proceed from the spleen to the stomach, and supposed by the ancients to be passages for the *atra bilis*, are purely imaginary.

The *nerves* are of two kinds, some being derived from the eighth pair, and others from the solar plexus.

The nerves of the eighth pair form a plexus around the cardiac orifice, the left nerve being distributed upon the anterior, and the right upon the posterior surface of the stom-

* [The alveoli are from $\frac{1}{350}$th to $\frac{1}{200}$th of an inch, and, near the pylorus, $\frac{1}{100}$th of an inch in diameter. At the bottom of each alveolus is seen a group of minute apertures (*fig.* 152), which are the open mouths of small tubes placed perpendicularly to the surface of the membrane, and closed at the other end. In a vertical section of the membrane, these tubes, which average about $\frac{1}{300}$th of an inch in diameter, are seen to rest upon the sub-mucous tissue by their closed extremities. In the cardiac portion of the stomach they are short and straight; near the pyloric end they are longer, and convoluted, or irregularly dilated, and are sometimes bifurcated. Bloodvessels pass up between these tubes, and form a capillary network round the borders of the alveoli. The membranous projections sometimes found between the alveoli (*fig.* 153) form irregular fringes, broader than the lingual papillæ, and seem rather to be imperfectly developed villi (see note, p. 361), and are usually so called. The epithelium covering the entire mucous membrane of the stomach consists of a single layer of minute columnar cells; it is very delicate, and invisible, except by a high magnifying power; hence its existence was formerly denied.]

† Upon this subject see the Memoir of Helvetius.—(*Hist. Acad. Roy. des Sciences*, 1720.)

‡ [In the pig these follicles appear to be nothing more than prolongations of the mucous membrane, or small diverticula; so that, after having detached the mucous membrane, they may, by slight pressure, be turned inside out.]

◊ "Neque rejici debent, etsi non semper possint ostendi."—(*Haller*, l. vi., lib. xix., p. 140.)

‖ Vide Anat. Path. avec planches, liv. xiv., pl. 1.

¶ [In the neighbourhood of the œsophageal orifice there are also several small compound glands, analogous to Brunner's glands in the duodenum.—(W. S.)]

ach. They may be followed as far as the muscular coat, where they seem to be lost; division of them paralyzes this coat. By means of the nerves of the eighth pair, the stomach is connected with the œsophagus, the lungs, the pharynx, the larynx, and the heart. Through the nerves derived from the central epigastric plexus, and named after the arteries that support them, the stomach is connected with the ganglionic system, and is brought into relation with the numerous viscera of the abdomen.

Lastly, a very delicate *serous cellular tissue* unites the different coats of the stomach. There are three layers of this tissue, viz., one between the peritoneal and the muscular coats, another between the muscular and the fibrous, and a third between the fibrous and the mucous coats. The last of these is the most distinct; it is liable to both serous and sanguineous effusions, and may become the seat of diffuse inflammation. I have lately seen it infiltrated with pus to a considerable extent, the mucous and the fibrous coats being both perfectly healthy.

Development of the Stomach.—The stomach of the fœtus is remarkable on account of its vertical position, which is due to the great development of the liver, especially of its left lobe. An unnatural development of that lobe will also occasion a similar position of the stomach in the adult. The relative smallness of the stomach, and the slight development of its tuberosity, are also characteristic of its fœtal condition.* Nevertheless, from the first moment of its appearance, it is distinguished from the rest of the alimentary canal by its greater size. The changes which the adult stomach undergoes, and the variations in size which it presents, are, perhaps, less dependant upon congenital differences than upon particular habits. The differences in the two sexes are manifestly due to the pressure to which the stomach of the female is subject, either from the use of stays or from the gravid uterus. I may here advert to the development of the muscular ring of the pylorus, and of the neighbouring part of the stomach in aged persons.

Function.—The stomach is the organ of chymification, or of that process by which the food is converted into a homogeneous gray pulp, called *chyme*. For that purpose it is evidently necessary that the food should remain for some time in this organ, and the elasticity of the muscular coat of the œsophagus and of the ring at the pylorus are sufficient to prevent its regurgitation into the gullet, or its passage into the duodenum. When the process is completed, however, the peristaltic contraction of the muscular fibres of the stomach overcomes the resistance of the pylorus; in eructation, regurgitation, and vomiting, the same peristaltic movements are assisted by the contraction of the diaphragm and the abdominal muscles.

Chymification is a chemical, or, at least, a molecular action, and is effected by means of the gastric juice, mixed with the salivary and œsophageal secretions. These fluids are acid.†

The influence of the nerves upon digestion has been ascertained by ingenious experiments, the results of which, however, have been interpreted in various ways.

The Intestines in general.

The term *intestine*, in its widest signification, is applied to the whole alimentary canal; but, in a more limited sense, it means that long and frequently-convoluted tube, extending from the pylorus to the anus, and occupying almost the whole of the abdominal cavity. The intestines have been divided, according to their calibre, into the *small* (*b* to *d*, *fig.* 139) and the *large* (*e* to *i*); this distinction, which is applicable to most animals, is anatomically established in man by a difference in size, by the sacculated character of the large intestine, by a difference in direction, by the presence of a valve, by the existence of a cæcum and of a vermiform appendix, and, lastly, by a difference in structure, especially in the muscular and mucous coats. The same distinction is recognised in physiology, and upon equally good grounds, for the small intestine is essentially concerned in the formation and absorption of the chyle, while the large intestine is the organ of defæcation.‡ These differences will be rendered more apparent from the description of these two important parts of the alimentary canal.

The Small Intestine.

The *small intestine* includes all that part which is situated between the stomach and the large intestine (*b* to *d*, *fig.* 139). According to Haller, Bichat, and their followers, the upper portion, called the *duodenum* (*b* to *c*), should be abstracted from the small intestine, which, according to them, would commence at the termination of the duodenum. It appears to me that the former definition should be adhered to, on account both of the

* [At early periods of fœtal life, villi are found on the mucous membrane of the stomach generally, afterward on the pyloric portion only; and, subsequently to birth, the only traces of these are the irregular fringes observed here and there between the alveoli.]

† [The saliva, though sometimes acid, is usually alkaline.]

‡ The division into a small and large intestine exists among all vertebrated animals; but no animals, excepting the ourangs and the wombat, have both a cæcum and an appendix vermiformis. In some we find one cæcum, or several cæca; in others, one or more vermiform appendices; others have neither cæcum nor appendix, but a valvular fold and a well-marked change in diameter indicate the limit between the small and large intestines. In some, again, the only difference consists in a change of diameter.

absence of any real line of separation between the duodenum and the rest of the small intestine, and of their similarity in structure and function.

The small intestine is divided into three parts, the *duodenum*, the *jejunum*, and the *ileum*. The division between the duodenum and the rest of the small intestine is definite, but that between the jejunum and the ileum is altogether arbitrary; so that we shall follow the example of Haller, Sœmmering, and others, in describing the jejunum and ileum together (*c* to *d*), under the name of the small intestine, properly so called.

The Duodenum.

Dissection.—When the abdomen is opened, the first portion only of this intestine is visible; the second is hid by the ascending colon; the third is seen in the cavity of the omentum. The second is brought into view by turning aside the colon. The third portion, which is the most difficult to demonstrate, may be exposed in two ways: either by cutting through the inferior layer of the transverse mesocolon, or by turning the stomach upward, after having divided the lavers of the grest omentum, which are attached along its greater curvature.

Fig. 154.

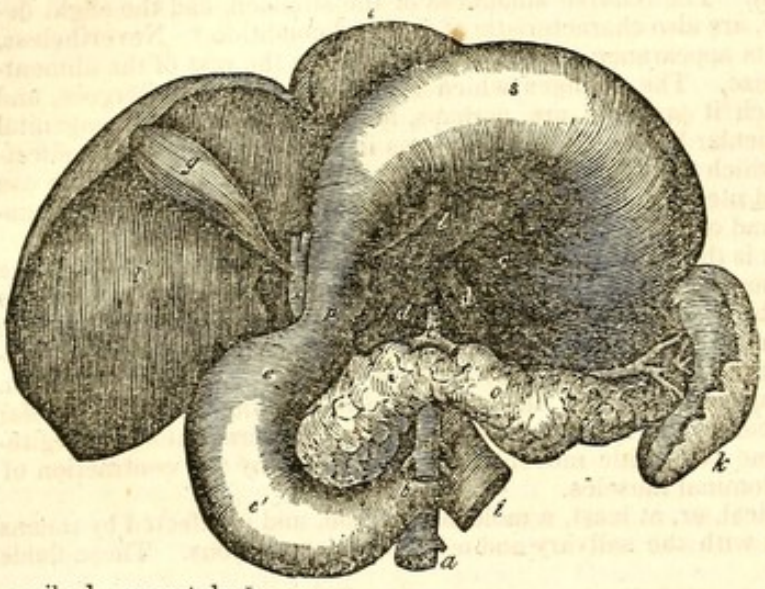

The *duodenum* (δώδεκα δάκτυλον, *p b*, *fig.* 154), so called by Herophilus (Galen, *Administr. Anat.*, lib. vi., c. 9) on account of its being about equal in length to the breadth of twelve fingers, commences at the pylorus, and terminates, without any precise line of demarcation, to the left of the second lumbar vertebra, at the point where the small intestine enters into the mesentery, or, rather, opposite the superior mesenteric artery (*m*) and vein, which pass in front of it. Its fixed position, its structure, and its curvatures, have led to its being described separately.*

It is difficult to determine its precise situation with regard to the abdominal parietes. It is not exclusively confined to any one region, but occupies in succession the adjacent borders of the right hypochondrium and the epigastrium, of the right lumbar and the umbilical regions, and of the epigastric and umbilical regions.

The duodenum is found more deeply situated in proportion as we recede from the pylorus, and hence the difficulty of exploring it through the parietes of the abdomen. It is fixed firmly in its place by the peritoneum, by the mesenteric vessels and nerves, which bind it down, and by the pancreas. This fixedness is one of its principal peculiarities, and is indispensable in consequence of its relations with the ductus communis choledochus; for had it been movable like the rest of the small intestine, incessant obstructions to the flow of the bile would have occurred. It follows, also, that the duodenum can never form part of a hernia; its first portion may, indeed, be displaced, for it is less firmly fixed than the remainder, and is sometimes dragged out of its proper situation by the pyloric extremity of the stomach.

Dimensions.—It is eight or nine inches in length; its calibre is somewhat greater than that of the rest of the small intestine, but the difference is not so decided as to warrant the names of *second stomach*, or *ventriculus succenturiatus*, which have been given to it. I have even met with subjects in whom the duodenum, when moderately distended, was five inches, while the succeeding portion of small intestine was six inches in circumference. It has been supposed that this part is more dilatable than the rest of the small intestine; this has been attributed to the absence of the peritoneum. The fact and the explanation are equally without foundation. It is the fibrous membrane, and not the peritoneal coat, which is opposed to dilatation of the intestines.

Direction.—This is very remarkable. Commencing at the pylorus, the duodenum passes upward to the right side and backward; having reached the neck of the gall-bladder, it suddenly changes its direction, and becomes vertical, forming an acute angle with the former portion; this is its *first curvature* (*c*): then, after proceeding vertically through a variable space, it passes transversely from the right to the left side, and becomes continuous with the rest of the small intestine. This change in its direction takes place at a right angle, and is, therefore, less abrupt than the former; the point at which it occurs is called the *second curvatare* (*c'*).

* Glisson considered the insertion of the ductus communis choledochus as the lower limit of the duodenum.

It follows, then, that the duodenum describes a double curve, or, rather, one single curve, of which the concavity is directed towards the left, and the convexity to the right side. Haller has ingeniously compared the course of the duodenum to two parallel lines, intersected by a perpendicular. This double change in the direction of the duodenum, which is probably intended to retard the passage of the food, enables us to consider it as composed of *three portions*, distinguished as the *first* (*p e*), *second* (*e e'*), and *third* (*e' d*).

Relations.—These should be studied in each of the three portions.

Relations of the First Portion.—*Above*, with the liver (*l'*, *fig.* 154*) and the gall-bladder (*g*), to the neck of which it is united by a fold of the peritoneum. It is not uncommon to see the gall-bladder and the duodenum closely adherent to each other, and to find an opening through which biliary calculi have passed into the gut. *In front*, with the gastro-colic omentum and the abdominal parietes. *Behind*, with the hepatic vessels, and the gastro-hepatic omentum. This portion of the duodenum, which may be denominated the hepatic, is about two inches in length.

Relations of the Second Portion.—*In front*, with the right extremity of the arch of the colon (*t*, *fig.* 161, *e* being the duodenum), which crosses it at a right angle. *Behind*, with the concave border of the right kidney, along which it descends to a greater or less distance, together with the vena cava inferior and the ductus communis choledochus. Sometimes this portion is not in relation with the kidney, but rather with the vertebral column. The ductus communis choledochus (*c*, *fig.* 169) and the pancreatic duct (*u*) enter the intestine at the posterior and inner surface, and below the middle of this portion of the duodenum. The relations of the duodenum behind are direct, *i. e.*, without the intervention of the peritoneum. *On the right*, this portion of the duodenum is in relation with the ascending colon (*a*, *fig.* 161). *On the left*, with the pancreas (*o*, *fig.* 154), which is closely united to it, and embraces it in a sort of half groove. This second portion is two or three inches in length; it may be called the renal portion.

Relations of the Third Portion.—The third portion is situated in the substance of the adherent border of the transverse mesocolon. *Below*, it rests upon the lower border of that fold. *Above*, it is bounded by the pancreas, which adheres closely to it. In *front*, it corresponds to the stomach, from which it is separated by the layer of peritoneum which lines the sac of the great omentum. *Behind*, it corresponds to the vertebral column, from which it is separated by the aorta (*a*), the vena cava, and the pillars of the diaphragm (*d d*).†

As the internal surface and the structure of the duodenum are very analogous to those of the jejunum and ileum, I shall postpone the description until I have noticed the external conformation of the rest of the small intestine.

The Small Intestine, or the Jejunum and Ileum.

The *small intestine*, properly so called (*c d*, *fig.* 139; *i i i*, *fig.* 155), or the *jejunum* and *ileum*, consists of that portion of the alimentary canal which fills almost the whole of the abdomen, occupies the umbilical, hypogastric, iliac, and lumbar regions, and is surrounded, as it were, more or less completely, by the large intestine (*e f g h*, *fig.* 139; *a t d*, *fig.* 155). Its upper extremity (*j' fig.* 161) is continuous, without any line of separation, with the duodenum. The distinction between the two parts is established by the angle which the mesentery forms with the mesocolon, or, rather, by the point where the superior mesenteric vessels cross over the small intestine. Its lower extremity (*d*, *fig.* 139; *i*, *fig.* 161) enters at a right angle into the large intestine. The old division of the small intestine into the *jejunum* and *ileum* should be banished with other anatomical niceties, for it is founded only upon trivial distinctions; and although the upper part of this intestine differs in many respects from the

Fig. 155.

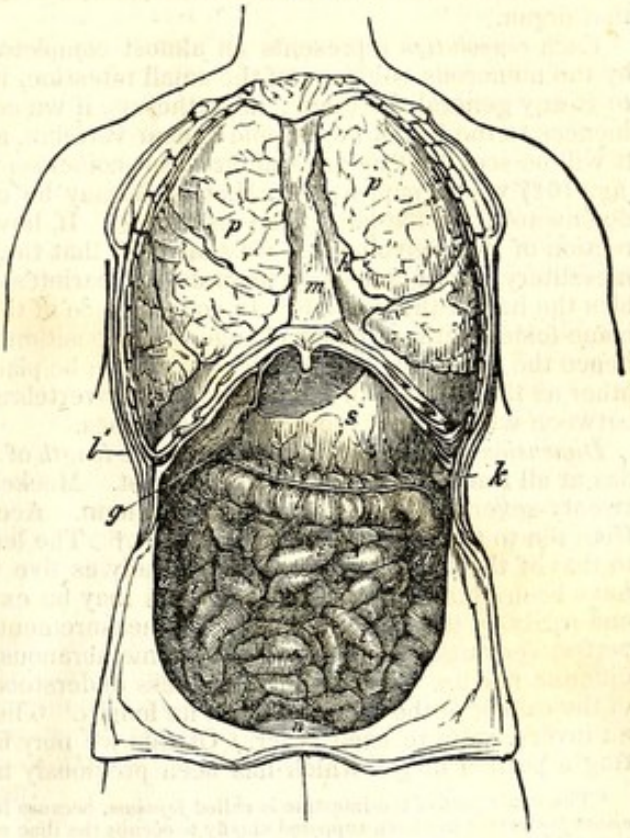

* In which figure the liver and stomach are turned upward.

† In one subject I found a fourth portion which passed upward, and was about one inch in length, so that the duodenum described a third curve, with its concavity directed to the right.

lower, still the alteration takes place by imperceptible gradations.* So that Winslow, unable to find any real difference, established a purely conventional distinction, by proposing to call the upper two fifths the jejunum, and the lower three fifths the ileum.

No portion of the alimentary canal is so movable as the small intestine, properly so called. It is exceedingly loosely attached, or, as it were, suspended from the vertebral column, by a large fold of the peritoneum, called the *mesentery* (the attached portion of which is seen at *m*, *fig.* 161), which, being broader in the middle than at either extremity, gives an unequal mobility to the different parts supported by it. The small intestine is displaced with great facility.

The circular boundary described around it by the large intestine is only exact above, where the mesocolon and the arch of the colon (*t*, *fig.* 155) completely separate it from the stomach (*s*), the liver (*l*), the spleen (*k*), and the duodenum. But below, between the cæcum (*c*, *fig.* 161) and the sigmoid flexure of the colon (*f*), it descends into the pelvis, and, extending laterally, passes in front of the colon in both the right and left lumbar regions.

This excessive mobility is one of the most characteristic and important facts regarding the small intestine, which, in some measure, floats in the abdominal cavity, yielding to the slightest impulse or concussion. Of all the viscera, it is the most frequently involved in hernia. It is liable to invagination, *i. e.*, one portion may be received, as into a sheath, into that immediately succeeding it. When any organ in the abdomen becomes enlarged, the small intestine yields, and passes in the direction where there is least resistance. It appears to partake of the mobility of fluids. It collects together, or spreads out; it moulds itself upon the adjacent parts, and fills up every space, so as to elude all causes of compression; and, by means of this admirable contrivance, the abdomen accommodates itself without inconvenience to the occasional enormous development, either natural or diseased, of the organs contained within it.

Direction.—We have seen that the upper or supra-diaphragmatic portion of the digestive canal is straight. The stomach presents one slight curve. The duodenum has two decided curves, and the rest of the small intestine pursues a not less flexuous course. The following is the direction of this intestine: commencing at the duodenum (*j*, *fig.* 161), it passes forward and to the left side; it is then folded a great number of times upon itself, and, at its lower part, it passes transversely from the left to the right side, and a little upward, in order to enter at a right angle (*i*) into the great intestine.

The numerous foldings or turnings (*gyri*) of the small intestine upon itself have received the name of *convolutions*; they are moulded upon each other, without intermixing or becoming entangled, so as to form a mass, which so closely resembles the surface of the brain, that the term convolutions has also been applied to the winding eminences of that organ.

Each *convolution* represents an almost complete circle. In the complexity presented by the numerous windings of the small intestine, it appears to be very difficult to assign to it any general direction; nevertheless, if we consider that the small intestine commences to the left of the second lumbar vertebra, and terminates in the right iliac fossa, it will be seen that its general direction coincides with that of the membranous fold (*m*, *fig.* 161) which supports it; that is, it may be expressed by an oblique line running downward from the left to the right side. If, however, we examine the particular direction of the convolutions, we shall find that they all present a concavity towards the mesentery, and a convexity towards the parietes of the abdomen, so that each resembles the half of the figure 8. In consequence of this arrangement, the intestine may become folded without much change in its position, either in advance or otherwise; and hence the great number of folds which can be placed between two points so near each other as the left side of the second lumbar vertebra and the right iliac fossa, the distance between which is not more than four inches.

Dimensions.—The determination of the *length* of the small intestine, properly so called, has at all times been a subject of interest. Meckel says that it varies from thirteen to twenty-seven feet, including the duodenum. According to my observations, it varies from ten to twenty-five feet in the adult.† The length of the small intestine, compared to that of the large intestine, is generally as five to one. The different results which have been obtained by various authors may be explained partly by individual varieties and partly by the mode in which the measurements were made. Thus, a more or less perfect separation of the gut from the membranous folds which support it would lead to different results. But another, and less understood cause of difference, is the influence of the caliber of the intestine upon its length. The caliber and the length have always an inverse ratio to each other. Of this we may be easily convinced, by strongly inflating a portion of gut which has been previously measured. I have often been struck

* The upper part of the intestine is called *jejunum*, because it is generally found empty; the second, *ileum*, either because it has been supposed chiefly to occupy the iliac regions, or on account of its convoluted disposition, which, however, is common to it with the other (εἱλεῖν, to turn, to twist).

† The average length of the small intestine, including the duodenum, is 20 feet. I have lately measured several: in a female affected with chronic peritonitis, it was only 7 feet long; in another, 14; in a third, 18; in a fourth, 20; and in a fifth, 22.

with the shortness of the small intestine in cases of hernia, accompanied with retention of the contents of the gut above the strangulation.

Some authors have attempted to establish a relation between the length of the intestine and the stature of the individual; and it has been affirmed that the former is four or five times the height of the body. But differences in stature have not a uniform relation to the length of the alimentary canal.

Lastly, individual varieties in the length of the small intestine do not appear to have any influence upon the activity of the digestive process.

Caliber.—The caliber of the small intestine, properly so called, is not the same throughout. It is greater at the commencement than at the termination of the intestine. When moderately distended by inflation, I have found it six inches and four lines in circumference at its commencement, four inches and two lines at the middle, and three inches and a half a little above its entrance into the large intestine; but at the point of entrance itself it is dilated to about four inches and a half.

The small intestine, therefore, is funnel-shaped, a form which must facilitate the rapid passage of its contents, by causing them to proceed from a wider into a narrower space.

Lastly, the caliber of the small intestine presents many varieties. When any obstruction occurs to the passage of its contents, it may attain the caliber of the large intestine. In certain cases of marasmus, when it contains no gases, it becomes so contracted that the tube is completely obliterated.

Figure and Relations.—The small intestine is cylindrical; a section of it is almost circular. Its *posterior border*, to which the mesentery is attached, is concave; it is thrown into slight folds, as every straight cylinder must be when it is bent into a curve. Its *anterior border* is convex, free, and corresponds to the abdominal parietes, being separated from them by the great omentum,* which seems intended to contain the whole mass of the intestinal convolutions. When the omentum is wanting, as in the fœtus, or in cases of displacement from its being rolled up into a cord, the small intestine is in immediate contact with the parietes of the abdomen.

The *lateral surfaces* of the different convolutions of the small intestine are in contact with each other. As these surfaces are convex, they intercept triangular spaces before and after them, in which either effused blood, or serum, or pus, or false membranes, are sometimes collected.

The small intestine corresponds to all the regions of the abdomen, excepting those of the upper zone. Not uncommonly, we find it escaped from under the omentum, and situated between the liver and the abdominal parietes, or reaching into the left hypochondrium. It is immediately forced, as it were, in any direction in which there may be an opening.†

More or less of the small intestine is always found in the pelvis; in the male, between the bladder and the rectum; in the female, between the bladder and the uterus, and between the uterus and the rectum. In several persons who were emaciated from chronic diseases, and in whom the vertebral column could be plainly felt through the parietes of the abdomen, I have found almost the whole, and, in some cases, even the whole, of the small intestine within the pelvis, contracted, and almost entirely void of air. When one portion only of the small intestine is in the pelvis, it is invariably the lower part.

When any large mass is developed in the abdomen, as in pregnancy, or in encysted dropsy of the ovarium, the small intestine passes upward and laterally, becomes diffused, fills up every space, and almost always escapes compression in the most remarkable manner.

It is not uncommon to find, in the small intestine, appendices or diverticula, like the fingers of a glove, which are sometimes two or three inches in length, and have been found in the sacs of herniæ. These diverticula are usually much nearer the lower than the upper part of the small intestine. They are formed by all the coats of the bowel, and are very different from mere protrusion of the mucous membrane through the muscular coat, of which I have seen one example in the duodenum, and which I have often met with in other parts of the small intestine. In a subject which I recently examined, the small intestine presented about fifty spheroidal tumours of unequal size, all situated along the mesenteric side of the gut, and formed by protrusions of the mucous membrane through the muscular fibres.

Structure of the Small Intestine.

Dissection.—This structure must be studied upon a distended and moist portion of intestine, upon a distended and dried specimen, and also upon one inverted and distended. It is also of importance to study the mucous membrane under water, with the assistance of a strong lens. Injections thrown in first by the veins, and then by the arteries, are also useful in developing its structure.‡

* [In *fig.* 155, the great omentum has been removed.]

† The small intestine is found in diaphragmatic herniæ; it constitutes perineal hernia; and it is this portion of the bowels which escapes from the pelvis when the lower wall of that cavity is divided.

‡ The *internal surface of the small intestine* will be noticed with the mucous membrane.

The small intestine, as well as the stomach, is formed of four coats or membranes, which, proceeding from without inward, are the *serous*, *muscular*, *fibrous*, and *mucous coats*.

The Serous Coat.—The arrangement of this coat upon the duodenum differs from that upon the rest of the small intestine.

The peritoneum is applied to the first portion of the *duodenum* in the same way as upon the stomach, *i. e.*, it covers it entirely, excepting in front and behind, where there is a triangular space devoid of this coat. Like the stomach, this first portion gives attachment to the great omentum in front, and to the small omentum behind. The fold of peritoneum which passes from the liver to the duodenum has been improperly called the *hepatic ligament of the duodenum*. The peritoneum merely passes over the front of the second and third portions of the duodenum, so that the posterior surface of the intestine is in immediate contact with the parts with which it is in relation, and is very perfectly fixed.

The peritoneum forms a complete sheath for the *small intestine*, properly so called, excepting along its concave border, where the two layers which constitute the mesentery separate from each other, so as to include the bowel. In this situation we find a triangular cellular space, exactly resembling those which we have already described along the curvatures of the stomach, and performing a similar office, viz., that of remedying the slight extensibility of the peritoneum, and permitting the intestine to undergo sudden dilatation to a great extent. We should have a very incorrect notion of the dilatability of the intestine if we imagined that it is limited by the triangular space along its concavity, for when the bowel is much distended, the mesentery itself becomes separated into its two layers to allow of such distension. Of this I am convinced from having measured the antero-posterior diameter of the mesentery both before and after inflation of the bowels.

The cellular tissue which unites the peritoneal to the muscular coat is extremely delicate, and its adhesion to the latter coat increases in proceeding from the concave to the convex border of the intestine. Although the peritoneal coat is very thin, and so transparent that the muscular fibres may be seen through it, yet it has considerable strength.

The *muscular coat* is composed of two layers of involuntary muscular fibres, one superficial, the other deep. The *superficial layer* is the thinner; it consists of longitudinal fibres placed around the bowel in a very regular manner, and forming a continuous plane. I have never found these fibres more numerous at the mesenteric than at the convex border. This layer of fibres is almost always removed with the peritoneal coat, to which it adheres very intimately. From their white colour and shining appearance under the serous membrane, they have been supposed to be of a tendinous nature.

It is difficult, though by no means important, to determine exactly whether the same fibres reach the whole length of the intestine, or whether they are interrupted at intervals. It is generally admitted that they are interrupted, and that their extremities are received in the spaces between other fibres.

The *deep layer* of muscular fibres is thicker than the preceding, and consists of circular fibres, either parallel or crossing each other at very acute angles. They appear to me to describe complete circles, and to have their ends united. They have no tendinous intersections.

The *fibrous coat* is intermediate between the muscular and mucous tunics, and presents the same characters as in the stomach.

The Mucous or Papillary Membrane.—Its *external surface* adheres to the fibrous membrane by a loose cellular tissue, which is liable to serous, sanguineous, and purulent infiltration. The emphysematous or œdematous condition may be imitated in the dead body, by everting a portion of bowel and distending it either with air or water. The tenuity of the mucous membrane displayed in these experiments has led to the opinion that this coat is nothing more than an epithelium, a continuation of the epidermis of the skin, and that the fibrous coat represents the cutaneous dermis. Its *internal surface* is free, and is covered with more or less mucus; it is remarkable for its duplicatures or valves, called *valvulæ conniventes;* for its highly-developed *papillæ*, and for the arrangement of its *follicles*.

The Valvulæ Conniventes (Valvulæ Intestinales).

Dissection.—Evert the small intestine, so that its external surface becomes internal, and then plunge it in water; or, what is better, lay open the bowel, and examine its internal surface under water. Also study a portion of intestine inflated and dried.

Hitherto the mucous membrane of the alimentary canal has only presented to our notice certain folds which are intended to facilitate the dilatation of that canal, as in the œsophagus and stomach, and which are completely effaced by distension. The folds of the mucous membrane of the small intestine fulfil another purpose; and although they must, undoubtedly, in some measure assist in the elongation and dilatation of the bowel, yet they are never entirely effaced, however far this extension in length or width may be carried. These folds deserve a special description. They are called *valvulæ conniventes* or the *valves of Kerkringius*, although Fallopius had given a complete description

of them before that anatomist. Kerkringius gave them the name of conniventes (*conniveo*, to close partially). They commence in the duodenum (see *fig.* 169), an inch, or sometimes two inches, from the pylorus; and it is not uncommon to find them preceded by some vertical folds. They are few and small at first, but become very numerous and very large towards the end of the duodenum and the commencement of the small intestine, properly so called. From the upper two fifths of that intestine they gradually diminish in number, and become less regular and less marked towards the lower part of the small intestine; sometimes they are altogether wanting in the last two or three feet of the bowel. In some rare cases, I have seen valvulæ conniventes as far down as the ileo-cæcal valve; in no part are they sufficiently numerous to have a true imbricated arrangement. These valves are placed perpendicularly to the axis of the intestine, and describe one half, two thirds, or three fourths of a circle; but they seldom form a complete ring. They are broader in the middle, being from two or three lines in width, than at their extremities, which are slender. In order to ascertain their dimensions, they must be placed under water, or studied upon a fresh portion of intestine. They are generally parallel, incline towards each other by their extremities, bifurcate, and send off small verticular oblique prolongations. Sometimes we find small valves placed between the larger ones. Some of them are suddenly interrupted, so that they might be supposed, at first sight, to have undergone some loss of substance. Several of them are alternate, and seem to be disposed in a spiral manner; but there is no general rule in this respect; their free edge is sometimes directed towards the pylorus, and sometimes towards the ileo-cæcal valve. Their direction is very irregular; they yield to any impulse that may be communicated to them, and their free edge passes either upward or downward, according to circumstances. When examined upon a dried specimen, they resemble very much the diaphragms in optical instruments.

The valvulæ conniventes are formed by folds of mucous membrane, within which we find some loose cellular tissue, different kinds of vessels and nerves. Inflation, by raising the mucous membrane, completely effaces them. The fibrous coat presents a slight thickening opposite the bases of these valves. The valves, notwithstanding the ease with which they are moved, must in some manner retard the passage of the food, without offering any decided resistance to it, for that would become a cause of obstruction, and give rise to serious accidents. Their chief use, perhaps, is to increase the extent of surface; according to Fabricius, they double the surface of the intestine; Fallopius says they increase it three times, and Kew six times. Sœmmering has given the somewhat conjectural opinion, that the surface of the intestinal mucous membrane is greater than that of the entire skin (*Corpor. Hum. Fabrica*, t. vi., p. 295). Although not peculiar to the human species, they are much more developed in man than in the lower animals.

Besides the valvulæ conniventes, the mucous membrane of the small intestine presents some *irregular folds*, which are effaced by distension.

The Papillæ, or Villi.

Preparation.—1. Place the opened intestine in water, exposing it to a strong light, and agitate the fluid. A stream of water previously received upon the membrane will remove the mucus, which sometimes forms a tenacious sheath around each papilla.* 2. Roll up a portion of the detached mucous membrane, taking care to turn the adherent surface inward. 3. Evert a loop of intestine, so that the peritoneal coat may be on the inside: stretch it upon a cylinder, and then agitate it in a cylindrical vessel, so as to float out the valves.

The *papillæ*, or *villi*, are much more developed in the small intestine than in any other part of the alimentary canal, with the exception of the tongue. Fallopius has the honour of having discovered them. They were well described by Helvetius, Hewson, and Lieberkuhn, but still more accurately of late by Albert Meckel. When examined by the naked eye and under the microscope, the internal surface of the intestine appears to be roughened by an immense number of prominences or villi (*figs.* 157, 159), resembling very close, short grass, or a very hairy caterpillar. In some animals, as in the dog, and especially in the bear, the villi are so numerous and so long, that they in some degree resemble the filamentous roots of plants. They are found through the whole length of the small intestine, and cover the valvulæ conniventes, as well as the intervals between them. They vary in *length:* according to Lieberkuhn, they are one fifth of a line; their maximum length appears to be about four fifths of a line: and I have even found some in the duodenum, which, when extended, were a line in length; their *number* is very considerable, and attempts have been made to determine it. Lieberkuhn computed them at 500,000. Several Germans have taken up the subject; allowing 4000 to every square inch, by a calculation, the exactness of which I have not verified, there would be a million altogether. I have not observed any well-marked difference as regards the number of the villi, between the commencement and the termination of the small intestine. It

* A. Meckel recommends that the mucus should be removed by plunging the intestine first in an arsenical solution, and then in water impregnated with sulphuretted hydrogen; but the continued action of a stream of water is far preferable.

appears to me that the number and length of the villi are much greater in carnivora than in herbivora. The otter has been said to have the largest villi of any animal. Their form varies much. In the majority of animals which I have examined, as the dog, cat, calf, and bear, they are filiform. In the human subject they are all lamellar or foliaceous, but with many varieties. In the duodenum they are curved upon themselves, presenting the appearance of a calyx or corolla, and sometimes adhering to each other by their extremities. In the small intestine, properly so called (*figs.* 157, 159), they are rectilinear, floating, cylindrical, conical, clubbed at the end, constricted, and sometimes bent in the middle. In the neighbourhood of ulcerations, they are, as it were, cut off close or truncated, without presenting any alteration in their structure.

Structure.—Brunner calls them membranous tubes; Leeuwenhoek regarded them as muscular organs; Helvetius and Hewson considered them to be small valves, an idea which has been revived and carried out more lately by Albert Meckel. This anatomist, who has given representations of the villi in a great number of animals (*Journ. Complement*, t. vii., p. 209), regards them as formed of small lamellæ, sometimes twisted upon their axes, like the first leaf of a germinating grain of wheat, and sometimes folded into a semi-canal or groove; but he considers that all these varieties may be referred to that of a lamella, broad at the base and narrow at the apex; a fundamental form, which may always be demonstrated with the aid of a needle.*

Lieberkuhn states, that at the base of each villus there is an ampulla, which opens upon the summit of the villus by a single orifice; and he considers that both the ampulla and the orifice belong to the commencement of the lacteal vessels; arteries and veins ramify round the ampulla; and each villus has an afferent artery and an efferent vein. According to Mascagni, the villi are composed of an interlacement of bloodvessels and small lymphatics, and are covered by an extremely thin membrane, composed of lymphatics. The following are the results of my own observations: Having had occasion to examine a subject in which the lymphatic vessels were filled with tubercular matter, I was able to trace a lymphatic trunk into each villus (vide *Anat. Path.* avec planches, liv. 2), which traversed its entire length. This perfectly agrees with Lieberkuhn's account. In another subject I injected mercury into one of the mesenteric veins, and then above the mercury I forced in a coarse black injection. The mercury and a part of the black injection passed into the cavity of the intestine, and a globule of mercury appeared upon the summits of the villi, which were blackened from the injection. From this I have concluded that the villi are perforated at their summits. I shall return to this subject again.†

The Duodenal Glands and Follicles. Preparation.—Some intestines are not well adapted for the study of the follicles, which, indeed, seem to be entirely wanting in them. Others, again, are very favourable for that purpose. The follicles are rendered more apparent by plunging the intestine into acidulated water. They must be examined from the internal surface of the mucous membrane, and also from its external surface, by removing the serous, muscular, and fibrous coats by which they are covered. In the study of the duodenal glands, this last method of investigation is absolutely necessary.

The *follicles* are generally divided into two kinds, the *simple* or *solitary*, and the *agminated*; to these we shall add the *duodenal glands*.

The Duodenal Glands.—These, properly speaking, are the *glands of Brunner*. This anatomist, who had already made some curious experiments upon the pancreas, says that, having partially boiled the duodenum, he observed upon its internal membrane some granular bodies, which he has had figured, resembling the solitary follicles in the neighbouring portion of intestine. To this collection of granules he gave the name of the *second pancreas*. Farther observations have shown, that in the upper half, or upper two

* [Many of the villi are certainly cylindrical, and, therefore, not referrible to the fundamental form described by Albert Meckel. In the fœtus and young subject they are comparatively broader and flatter, and are connected at their bases so as to form folds having irregular margins. In this stage of their development they resemble the rugæ in the intestines of birds and reptiles.]

† [The villi contain all the elements of the intestinal mucous membrane; no nerves, however, have been actually demonstrated in them.

Fig. 156.

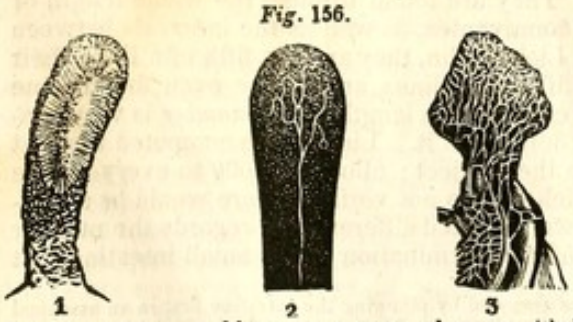

1 2 3

The bloodvessels are numerous, and form a very beautiful capillary network in each villus (3, *fig.* 156).

Great differences of opinion have existed, and still exist, as to the mode of origin of the lacteals in the intestinal villi: the best authorities, however, agree in stating that they do *not* commence by *open* orifices. Rudolphi and A. Meckel considered that they arose by a *closed* network. Dr. Henle found a single dilated but *closed* lacteal in each villosity; and more recently, Krause observed that in each villus the lacteal arose by several branches, some of which ended in free but *closed* extremities, while others anastomosed together (2, *fig.* 156). The villi, and, it may be observed here, every portion of the intestinal mucous membrane, are covered by a transparent, columnar epithelium, consisting of elongated prismatic nucleated corpuscules. The perpendicular arrangement of these upon the surface of a villus is shown in the diagram (1, *fig.* 156).]

thirds of the duodenum, there is a layer of flattened granular bodies, perfectly distinct from each other, however close they may be. This layer must not be confounded with the glanduliform arrangement of the duodenal villi; it can only be well seen after having removed the three outer coats. These granular bodies are nothing more than small (compound) glands, which, when examined with a powerful lens, present all the characters of the salivary glands. These glands do not cease abruptly, but become few and scattered towards the lower end of the duodenum; so that it is by no means inconsistent to admit that the solitary follicles of the rest of the intestinal canal may be of a similar nature.*

The *solitary follicles*, or *glandulæ solitariæ*, are generally known in the present day as the glands of Brunner (*Disput. de Gland Duoden.*, Heidelberg, 1687, 1715), although that anatomist only described the glands or follicles of the duodenum, which he said diminished in number below that portion of the intestine, and disappeared altogether in the jejunum. It is, therefore, by an extension of the author's meaning that we speak of the glands of Brunner as occupying the termination of the small intestine, the stomach, and even the large intestine.

The glandulæ solitariæ present the appearance of small rounded granulations, like millet seeds, projecting upon the internal surface of the mucous membrane, without any distinct orifice, and covered with villi (*fig.* 157); they are found upon the valvulæ conniventes, as well as in the spaces between them. Their number is very considerable; so that in certain diseases, where they become more prominent than usual, they might be mistaken for a confluent eruption. It is a mistake to say that they diminish in number from the upper towards the lower part of the small intestine, the contrary being nearer to the truth. When examined with the simple microscope, they have appeared to me to be hollow, and filled with mucus.†

The *agminated follicles*, or *glandular plexuses*, are more generally known as the *glands of Peyer*, although both the solitary and agminated glands were described by that anatomist. Pechlin noticed them under the name of *vesicularum agmina*. Willis, Glisson, Malpighi, Duverney, and Wepfer have given more or less complete descriptions of them; but Peyer (*De Glandulis Intestinorum*, J. C. Peyer, 1667, 1673), when still a young man, and without any knowledge of the work of Pechlin, described and figured them under the title of *glandulæ agminatæ* so accurately as to leave nothing to be desired.

These agminated glands are arranged in elliptical patches (*fig.* 158), the long diameter of which corresponds with the direction of the intestine: they are pierced with holes, or small depressions, so that they have a honeycombed appearance; and hence has arisen the name of *plaques gaufrées*, under which I believe I was the first to describe them: they are all situated on the border opposite to that by which the mesentery is attached to the intestine; that is, along the convex border of the intestine, and never along the concave border, nor even upon either side. They are chiefly found towards the end of the small intestine; they become more and more scattered as we approach the duodenum, in which, however, Peyer once met with a single patch. Their number varies considerably, twenty, thirty, and even more having been counted. Are they ever entirely wanting? The difficulty of detecting them in some subjects has led to their being rejected altogether, or considered as the results of a pathological condition; but this opinion is clearly at variance with observation. Again, these patches are not constant either in situation, form, or dimensions. Sometimes they assume the appearance of bands two or three inches in length (*fig.* 158), and sometimes they form circular or irregular clusters. The largest are found near the ileo-cæcal valve. It is not rare to find the termination of the small intestine surrounded by a circular patch; in other cases, the patches terminate some inches above the ileo-cæcal valve, and their place is supplied by simple follicles.

Fig. 158.

Fig. 157.

Magnified.

* [According to Dr. Boehm (*De Gland. Intestin. Struct. penitiori*), this is not the case, the compound glands of Brunner not existing below the commencement of the jejunum.]

† [*Fig.* 157 is a solitary gland magnified; it is represented, after Boehm, as a *closed* vesicle, filled with whitish matter, which contains granules smaller than those of mucus. Villi are seen upon the free surface of its capsule, and it is surrounded by the crypts of Lieberkuhn (the mouths of which are indicated by the darker spots), which have no communication with the vesicle itself (see also note, p. 370).]

These patches are generally contained in the substance of the mucous membrane, to which they give a much greater density, so that, in these situations, it will bear to be scraped. In some cases they appear to be imbedded in the fibrous coat. They should be examined both from the external and internal surfaces of the mucous membrane.* When they are filled with their secreted fluid, and are examined by transmitted light, they may be compared to the vesicles in the skin of an orange: this observation may be easily made in the day. They evidently consist of collections of glands, exactly resembling the solitary glands (*fig.* 159). Each depression appears to be the orifice of one of the follicles, which are quite independent of each other; so that we sometimes find two or three altered in the middle of a patch, which is otherwise perfectly healthy. Lastly, villi are found upon the patches of the glandulæ agminatæ: they occupy the intervals between the depressions.†

Fig. 159.

Magnified.

The Follicles or Corpuscules of Lieberkuhn.—Lieberkuhn speaks, also, of innumerable, rounded, whitish follicles, which are seen between the villi, and of corpuscules which are visible between these follicles. He calculates that there are eighty follicles for eighteen villi, and eight corpuscules for each follicle. I am disposed to think that these follicles and corpuscules, which have never been seen excepting by the microscope, should be referred to those globules which are revealed in all the tissues by the aid of a magnifying power.‡

The Vessels and Nerves.—All the *arteries* of the small intestine, properly so called, are branches of the superior mesenteric. They are very numerous. Those of the duodenum arise from the hepatic. The branches from the superior mesenteric are remarkable for the numerous anastomotic loops which they form before reaching the intestine, for their flexuous course within its coats, and for the series of vascular layers formed by them between the peritoneal and muscular, the muscular and fibrous, and the fibrous and mucous coats. The last layer forms a very complicated network, from which the vessels of the mucous membrane are derived. The *veins* are much larger than the arteries, and present a similar arrangement, except in regard to the flexuous course, which is peculiar to the arteries; they constitute the superior mesenteric vein, which is one of the principal branches that contribute to form the vena portæ.

The *lymphatic vessels* are of two kinds, viz., lacteals and lymphatics, properly so called; they both enter the numerous lymphatic glands, situated in the mesentery; those which belong to the duodenum enter the glands above the pancreas.

The *nerves* are derived from the solar plexus.

The *development* of the small intestine will be noticed in conjunction with that of the large intestine.

Uses.—Chylification, *i. e.*, the transformation of the chyme into chyle, is effected in the duodenal portion of the small intestine. The essential agents of this process are the bile and the pancreatic fluid. In the remainder of the small intestine (the jejunum and ileum), the absorption of the chyle takes place. The numerous convolutions, the valvulæ conniventes, and the villi, all tend to increase the extent of the absorbing surface. The products of exhalation and of follicular secretion serve to complete the digestive process. The contents of the bowels are forced along by the shortening of the longitudinal, and the contraction of the circular fibres, the latter producing the vermicular motion of the intestines.

The Large Intestine.

The *large intestine* is that part of the alimentary canal which extends from the end of the small intestine (*d*, *fig.* 139) to the anus (*i*). It commences in the right iliac region (*c*, *fig.* 161), and passes upward (*a*) as far as the right hypochondrium; then, having reached the liver, it makes a sharp flexure (the *right* or *hepatic flexure*), and proceeds

* [Their contents are sometimes transparent, and they are then very difficult of detection.]

† [In *fig.* 159, representing part of a patch of Peyer's glands magnified, are seen some of the elevated white bodies described by Boehm as resembling the solitary glands, except in not generally having any villi situated directly upon them. Each is surrounded by a zone of dark points, the elongated openings of the crypts of Lieberkuhn. Many of these crypts are also seen scattered irregularly between the numerous villi; none of them communicate with the interior of the whitish bodies, in which, whether solitary or agminated, Boehm could discover no opening, at least, not in a healthy human intestine. He considers them, therefore, to be *closed* vesicles, not follicles.

More recently, however, Krause has observed that, in the pig's intestine, they are occasionally open, independently of disease; and Dr. Allen Thomson has lately made a similar observation in reference both to the pig and to the human subject.]

‡ [The follicles or crypts of Lieberkuhn are tubes placed more or less perpendicularly to the surface of the mucous membrane, like those in the stomach, but situated more widely apart; their open mouths are seen scattered over the whole surface of the membrane, or collected around the solitary and agminated glands (*figs.* 157, 159). The *corpuscules* (*corpora albicantia*), described by the same observer as being situated in the bottom of the crypts, are probably collections of desquamated epithelium within them.]

transversely (*t*) from the right to the left side (*transverse arch of the colon*); in the left hypochondrium, below the spleen, it again makes a sharp bend and becomes vertical (*d*), (*left* or *splenic flexure*). In the left iliac region (*f*) it is twice bent upon itself, like the Roman letter S (*iliac* or *sigmoid flexure*), and it then dips into the pelvis (*r*), and terminates at the anus.

The large intestine, therefore, describes within the abdomen a nearly complete circle, which surrounds the mass of convolutions of the small intestine; and it occupies the right and left iliac regions, the right and left lumbar, the base of each hypochondriac, and the adjacent borders of the epigastric and umbilical regions. Although it is much more firmly fixed in its place than the small intestine, and is, therefore, less liable to displacement, yet it presents some varieties in length and curvature which have a considerable influence over its position. The large intestine is more deeply situated than the small in one part of its extent, but in another is at least quite as superficial.

From its long course, and from the different relations presented by its different parts, it has been divided into the *cæcum*, the *colon*, which is itself subdivided into several parts, and the *rectum*.

Dimensions.—The *length* of the large intestine is four or five feet, and, compared with the small intestine, is as one to four; but it varies considerably, rather, it would seem to me, from the effects of repeated distension, than from any original conformation; for it may be easily imagined that the bowel cannot be distended transversely without losing somewhat in length, and that, on returning to its former diameter, it must be elongated in proportion to the distension it had previously undergone. The large intestine has also generally appeared to me longer in persons advanced in age than in adults.

Its *caliber* or diameter usually exceeds that of the small intestine, but may become so reduced that the gut resembles a hard cord, about the size of the little finger. In other cases it is so large that it occupies the greatest part of the abdominal cavity: this is observed in tympanitic distension of the large intestine. It is not of uniform caliber throughout, as the following measurements will show. The circumference of the cæcum, moderately distended, and taken immediately below the ileo-cæcal valve, was found to be eleven inches and three lines in one subject, and nine inches and a half in another; the right colon in the loins and the right half of the arch were eight inches and nine lines in the first, and five inches some lines in the second subject. The circumference of the left half of the arch of the colon, and of the left lumbar colon, was six inches in the first and five inches and a half in the second. The circumference of the sigmoid flexure was five inches and a quarter; that of the rectum was three inches until near its termination, where it presented a dilatation four inches in circumference in one, and five inches in the other subject.

It follows, therefore, that the large intestine, like the small, has an infundibuliform shape; it resembles, indeed, two funnels, the base of the one corresponding to the cæcum, and its apex to the sigmoid flexure, while the base of the other is at the dilated portion of the rectum, and its apex is applied to that of the first. It is probable that this infundibuliform arrangement has some reference to the passage of the fæcal matters.

It also follows that there is no uniform relation between the diameters of the different portions of the large intestine: thus, a very large cæcum and ascending colon may coexist with a small descending colon In some cases we find in the large intestine considerable dilatations, separated from each other by such constrictions that the caliber of the corresponding part of the gut is obliterated. These strangulations from a contraction of the circular fibres are very different from those produced by organic diseases; they probably take place during life, and may account for the affection known as the windy colic. In some chronic diseases, accompanied with diarrhœa, the large intestine, contracted and containing no gases, is not as large as the small intestine.

The Cæcum.—The cæcum (*e*, *fig.* 139), so named because it resembles a cul-de-sac, is the first part of the large intestine The existence of a cæcum is one of the numerous indications of the line of separation between the large and the small intestine. Its upper boundary is altogether arbitrary; it is determined by a horizontal plane intersecting it immediately above the insertion of the small intestine. It is single in the human subject, but is double in some species of animals. It is *situated* (*c*, *fig.* 161) in the right iliac fossa, and occupies it almost entirely. It is one of the most fixed portions of the alimentary canal, for the peritoneum merely passes in front of it, and binds it down into the iliac fossa. It is not, however, so firmly fixed in all subjects; it is often enveloped by the peritoneum on all sides, and floats, as it were, in the region which it occupies, its capability of motion depending on the looseness of the right lumbar mesocolon. This arrangement of the peritoneum is not necessary, however, to explain the great amount of displacement which the cæcum undergoes in certain cases. It is not uncommon to find it in the cavity of the pelvis: it occasionally enters into the formation of herniæ and, what is somewhat remarkable, it has been at least as frequently found in herniæ upon the left as upon the right side.

Its *direction*, which is in general the same as that of the ascending colon, is not always vertical as may be seen by examining a moderately-distended intestine, but it passes

obliquely upward and to the right side, so that it forms with the colon an obtuse angle projecting on the right side; and I have even seen it form a right angle with the colon. This arrangement, connected with the obliquity of the plane of the iliac fossa, explains why, when its attachments are relaxed, it has less tendency to be displaced towards the right inguinal ring and femoral arch than to the same parts on the left side. In some subjects, the cæcum and its vermiform appendix are applied to the lower part of the small intestine, so that the cæcum and the neighbouring part of the colon describe a curve, the concavity of which embraces the lower end of the ileum.

In *size* it is generally larger than the portion of the intestine which succeeds it: this, perhaps, depends less upon its primitive conformation than upon the accumulation of fæcal matters resulting from the inclined position of this intestine, and from the direction in which its contents are moved. It may be said, as a general rule, that, next to the stomach, the cæcum is the largest part of the alimentary canal. There are many individual varieties in the length and capacity of this intestine, in which the fæcal matters are liable to be retained. These accumulations occasion great pain; they have been much studied lately, and have been often mistaken for inflammations. The cæcum is very slightly developed in carnivora, but, on the other hand, it is very large in herbivora.

Figure.—The cæcum is a sort of rounded ampulla, all the diameters of which are nearly equal; it is also sacculated like the rest of the large intestine. Upon it we observe the commencement of the three longitudinal bands, which I have already noticed: of these, the anterior is, in the cæcum, twice as broad as either of the two posterior; some folds of peritoneum, loaded with fat, which are called fatty appendages (*appendices epiploicæ*); and, lastly, some protuberances, separated by parallel depressions, an arrangement which exists in the colon also, and is produced by the longitudinal bands.

Relations.—In front, the cæcum is in relation with the abdominal parietes, through which it can be felt when it is distended with gases or fæcal matters. When the cæcum is collapsed, the small intestine is often interposed between it and the parietes of the abdomen.

Behind, it rests upon the iliacus muscle, from which it is separated by the lumbo-iliac fascia. The cellular tissue uniting it to this aponeurosis is extremely loose, and, therefore, offers no opposition to displacement of the intestine. When the peritoneum forms a complete covering for the cæcum, that intestine is, of course, in indirect relation with the iliacus. The vermiform appendix is often turned back behind the cæcum. On *the inside*, the cæcum receives the small intestine; the angle at which they unite (the ileo-cæcal angle) varies much. Sometimes the small intestine is inserted at a right angle; most commonly the angle of incidence is obtuse above and acute below (*fig.* 160). Sometimes the ileum, instead of passing upward, is directed downward, and then the angle of incidence is changed. A circular depression indicates the limit between the two intestines. *Below*, upon the free extremity or cul-de-sac of the cæcum, is seen the vermiform appendix (*v*), situated behind and on the left side, a few lines below the ileo-cæcal angle.

The arrangement of the *internal* or *mucous surface* of the cæcum is in accordance with that of its external surface: thus, three projecting ridges correspond with the three longitudinal bands; some cavities or pouches with the protuberances; and some transverse projecting folds, forming incomplete septa, which are easily seen in a dried specimen, correspond with the parallel depressions. Upon this surface, to the left and a little behind, we also find the ileo-cæcal valve (*a b, fig.* 160), and the orifice (*o*) of the vermiform appendix (*v*).

The Ileo-cæcal Valve.—This is also called the *valve of Bauhin*, from the name of the anatomist to whom its discovery is attributed, although it had been described before his time. To obtain a perfect knowledge of it, it should be examined upon a fresh specimen under water, and also upon an inflated and dried intestine.

In a fresh specimen, when viewed from the cæcum, it presents the appearance of a projecting cushion, oblong from before backward, and fissured in the same direction. It is a membranous and movable cushion, and was incorrectly compared by Riolanus to the pyloric ring. It has two lips and two commissures; the two lips are in contact, except during the passage of the contents of the bowels. Two folds, proceeding from the two commissures, one of which is anterior and the other posterior, are lost upon the corresponding surfaces of the intestine. The posterior fold is much longer than the anterior; Morgagni called them the *frœna* of the valve. When viewed from the ileum, it presents the appearance of a funnel-shaped cavity, directed upward and to the right side.

In a *dried intestine*, the ileo-cæcal valve is seen to consist of two prominent valvular segments, projecting into the cæcum, so as to form an angular ridge. The upper, or *ileo-colic* segment (*b, fig.* 160), is horizontal; the lower, or *ileo-cæcal* (*a*), forms an inclined plane of about 45°, and both are parabolic. The upper segment is fixed by its adherent convex border to the semicircular line, along which the upper part of the tube of the ileum is united with the colon; the adherent border of the lower segment, which is also convex, is continuous with the semicircular line of junction between the lower half of the ileum

Fig. 160.

and the cæcum. The free borders of the segments are directed towards the right side, and are semilunar; they are united at their extremities, but in the middle leave between them (between *a* and *b*) an opening like a buttonhole, which becomes narrower as the intestine is more distended. The diameter of this opening is in proportion to that of the small intestine. The free border of the lower segment is more concave than that of the upper. When examined from the ileum, the valve presents an angular excavation exactly corresponding to the projecting edge found in the cavity of the large intestine. The lower surface of the upper valvular segment is slightly concave; the corresponding surface of the lower segment is slightly convex.

This double ileo-cæcal valve differs widely from the ring of the pylorus; it offers no obstruction to the passage of the contents of the small into the large intestine; but in ordinary cases, it will not permit their regurgitation from the latter into the former. The lower or ileo-cæcal segment is elevated so as to prevent reflux from the cæcum, and the ileo-colic segment becomes depressed, and opposes any return of the contents of the colon. Still, from a great number of experiments which I have performed on this subject, I am satisfied that both water and air injected into the large intestine most frequently overcome the resistance offered by this valve, though with different degrees of facility in different subjects. This regurgitation, however, only takes place with gaseous or liquid matters; such as have a greater degree of consistence cannot pass back, and therefore the reflux of fæcal matter is impossible.*

Structure.—The structure of the ileo-cæcal valve was perfectly demonstrated by Albinus. If we follow his example, and remove the peritoneal coat from a distended intestine, at the point where the ileum enters the large bowel, we shall at once perceive most distinctly that the small intestine seems to sink in there; and if, by means of careful and gradual force, we attempt to disengage it from the large intestine, it may be drawn out, as it were, from the colon to the length of an inch or an inch and a half; and then, on inspecting the inside of the large intestine, we shall find that the valve has altogether disappeared, and that the ileum communicates with the cæcum and colon by a large aperture.

The precise *structure* of the valve is as follows: it is composed of the circular muscular fibres of the ileum, which are prolonged as far as its free edge;† of the fibrous coat, and of the mucous membrane. A similar fact has been observed regarding this mucous membrane to one we have already several times noticed in describing the alimentary canal, viz., a sudden change in its character opposite the free margin of the valve. That portion of the membrane which lines the surface turned towards the large intestine has all the characters of the mucous membrane of that bowel, while that lining the surface directed towards the ileum has those of the mucous membrane of the small intestine. The limit between them is generally observed in diseases.

The Appendix Vermiformis.—The appendix vermiformis (*v, figs.* 139, 160, 161), so named from its resemblance to an earth-worm, commences at the posterior lower and left portion of the cæcum, of which it may be considered an appendage (*the cæcal appendix*); it resembles a small, hollow, and very narrow cord (*duodecies nascente colo angustior*, says Haller). In *length* and in *direction*, it presents much variation: its length is from one to six inches. It is somewhat wider at its point of junction with the cæcum than in any other part, and is in general about the diameter of a goose-quill.

Its *direction* is sometimes vertically downward, sometimes upward, and often tortuous. I have found it spiral, and at other times contained in the substance of the mesentery, parallel to the ileum, and only free at its extremity. In some subjects it is funnel-shaped, widening out to become continuous with the cæcum, which, in such cases, is very narrow. Its *situation* and *relations* are equally variable. Thus, most commonly, it occupies the right iliac fossa, near the brim of the pelvis: it is attached to the cæcum and to the iliac fossa by a triangular or falciform fold of the peritoneum, which extends only to one half of its length, and allows it a greater or less capability of movement. It is still more movable when it is entirely surrounded by the peritoneum, and has no mesentery. From this it may be conceived that it may enter into the formation of herniæ, and may be twisted around a knuckle of the small intestine, so as to cause strangulation. It is

* Nevertheless, if we consider that the large intestine must always be very much distended in order to produce a reflux of gases and liquids, it may be questioned whether the passage of gaseous or liquid matters from the large to the small intestine can take place during life. I have been able to determine the mechanism of the resistance offered by the valve from the effects of distension. The two segments are turned back, the lower one upward, and the upper one downward; their corresponding surfaces become convex, and they are pressed together the more and more forcibly in proportion to the amount of distension. In some subjects distension may be carried so far as to rupture the longitudinal bands, and yet not overcome the obstacle. In most cases, the free edge of the lower segment glides from right to left under the upper one, which remains immovable; and the gas and liquids escape with more or less facility according to the degree of disturbance in the parts.

† [The longitudinal muscular fibres and the peritoneal coat pass directly from the small to the large intestine, without entering into the formation of the valve.]

often turned back behind the ascending colon between that intestine and the kidney: in one case of this kind, I found the free extremity of the appendix in contact with the lower surface of the liver. I have also once seen it turned up behind the lower end of the small intestine, and, at another time, embracing that bowel in front. None of these differences, however, depend on the situation of its point of attachment to the cæcum, which is always on the left side, below and behind the cul-de-sac, at a short distance from the ileo-cæcal valve.

When divided lengthwise, the cavity within it is seen to be so narrow that the walls are always in contact. A small quantity of mucus is found in it, and it often contains small scybala; cherry-stones and shot have also been found in it. The whole of its internal surface has a honeycomb appearance, like that at the lower end of the small intestine.* A valve of different size in different subjects, but never sufficiently large to cover the orifice entirely, is found at the point (*o*, *fig.* 160) where the appendix communicates with the cæcum. The cavity of the appendix, like the cæcum, terminates below in a cul-de-sac; and in this, which is extremely narrow, foreign bodies may be lodged, and may then sometimes become the cause of those spontaneous perforations which are occasionally seen. The uses of this appendix are altogether unknown; in the human subject, it is merely a vestige of an important part in many animals. Haller says that he has twice seen the vermiform appendix obliterated, *i. e.*, without any cavity. I presume that this was the effect of morbid adhesion. Lastly, I once found this appendix as large as the index finger, and two inches in length; its cavity contained some thick, transparent mucus. The orifice by which it should have communicated with the cæcum was obliterated.

The Colon.—The colon (κωλύω, *to impede*, *d f g h*, *fig.* 139) constitutes almost the whole of the large intestine. It extends from the cæcum to the rectum, and, as we have already seen, there is no line of demarcation between these different parts. In the first part of its course it ascends vertically, then becomes transverse, next descends vertically, and is then curved like the Roman letter S, and becomes continuous with the rectum. From this long course, and also from its direction and numerous relations, the colon has been divided into four portions, viz., the *ascending* or *right lumbar colon*, the *transverse colon*, or *arch of the colon*, the *descending* or *left lumbar colon*, and the *iliac colon*. or *sigmoid flexure*. Each of these parts requires a separate description, at least with regard to its relations. Let us first point out the general form of the colon.

The colon presents a sacculated appearance throughout, which gives it some resemblance to a chemical apparatus, consisting of a long series of aludels. The sacculi of the colon are arranged in three longitudinal rows, separated by three muscular bands. Each of these rows presents a succession of enlargements and constrictions, or deep grooves, placed across the length of the intestine. These enlargements and grooves are produced by the longitudinal bands, which, being much shorter than the intestine, cause it to be folded inward upon itself at intervals. It follows, therefore, that division of these bands by means of a bistoury, or, rather, their rupture, from great distension of the gut, should destroy this sacculated appearance, and such, indeed, is the result of the experiment; at the same time, the large intestine becomes twice or three times as long as it was before, and forms a regular cylinder, like the small intestine. An incontestable proof of the relation between the cells of the colon and the muscular bands, is the concurrent absence of both in a great number of animals. Lastly, the three rows of sacculi vary much in different subjects, and also in different parts of the great intestine. The descending colon and the sigmoid flexure have only two rows of sacculi, and, consequently, two intermediate bands. The sacculi almost entirely disappear in the sigmoid flexure.

Fig. 161.

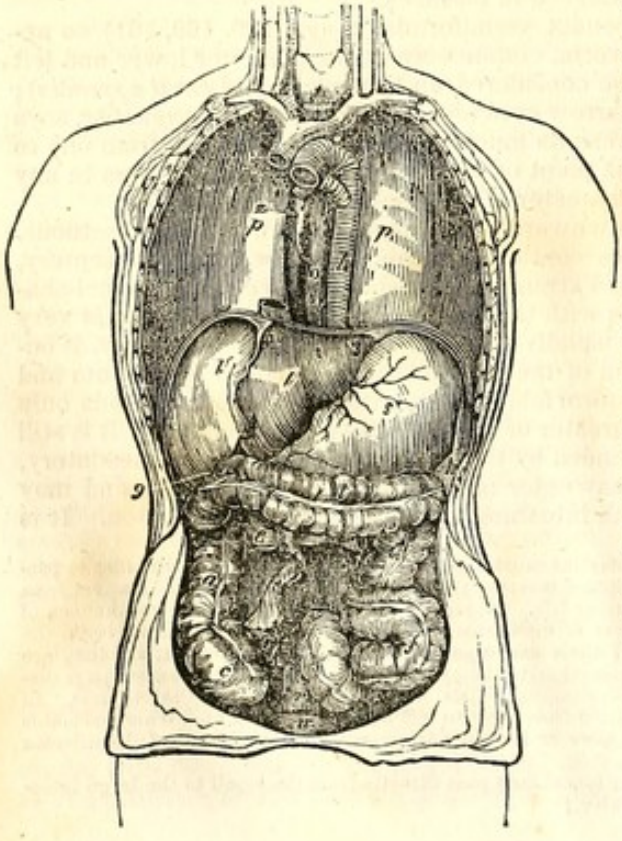

The Ascending or Right Lumbar Colon (*a*, *figs.* 155, 161).—This portion of the colon is bounded below by the cæcum,

* [Nevertheless, the structure of the mucous membrane in the two situations is very different (see notes, p. 370, 379).]

and above by the transverse arch, with which it forms a right angle, near the gall-bladder. It is more or less firmly held in its place by the peritoneum, which in some subjects merely passes in front of it, and in others forms a fold or lumbar mesocolon. The ascending and descending colon may be included among the most fixed portions of the alimentary canal. *In front* of it are the parietes of the abdomen, from which, excepting when greatly distended, it is separated by the convolutions of the small intestine. *Behind*, it is in immediate relation with the quadratus lumborum and the right kidney, no layer of peritoneum intervening. It is united to these parts externally by loose cellular tissue. This relation accounts for the bursting of abscesses of the kidney into the colon, and explains the possibility of reaching the colon in the lumbar region without wounding the peritoneum. On the left side, advantage has been taken of this fact in attempting to form an artificial anus.

On the inside and on the outside it is in relation with the convolutions of the small intestine; and on the inside also with the psoas muscle, and with the second portion of the duodenum.

The Transverse Colon, or Arch of the Colon.—This (*t*) is the longest portion of the large intestine; it extends from the ascending to the descending colon, from the right to the left hypochondrium, and generally occupies the adjacent borders of the epigastric and umbilical regions. It is not unfrequently found opposite the umbilicus, and even in the hypogastrium. Its right extremity corresponds to the gall-bladder (*g*), its left is below the spleen (*k*). It describes a curve having its convexity directed forward, and its concavity backward; hence the name, *arch of the colon*. In some subjects it is two or three times its ordinary length, and hence it presents various inflections. I have seen its middle portion descending as low as the umbilical or hypogastric region, and even reaching the brim of the pelvis; in other cases it descends parallel to, and on the inner side of, the ascending colon, and then passes upward again, or it describes curves of different extent. The arch of the colon is supported by a very remarkable fold of peritoneum, called the *transverse mesocolon*, which forms a horizontal septum between the small intestine below, and the stomach, the liver, and the spleen above. The extent of this fold, which is one of the largest of all those formed by the peritoneum, explains the great freedom of the movements of the transverse colon, which, next to the small intestine, is the part of the alimentary canal most frequently found in hernia.

Relations.—Above, it has relations with the liver (*l*), which generally presents a slight depression, corresponding to the angle formed by the ascending and transverse colon; with the gall-bladder (*g*), whence the discoloration of the right extremity of the arch from the bile; it is not rare to find the gall-bladder opening into the colon; with the stomach (*s*), which projects in front of it when distended, but is separated from it by a considerable interval when empty; and, lastly, with the lower extremity of the spleen (*k*). The two anterior layers of the great omentum, which proceed from the greater curvature of the stomach, pass over the arch of the colon without adhering to it. I have seen a large loop of the arch of the colon interposed between the liver and the diaphragm. *Below*, the arch of the colon corresponds to the convolutions of the small intestine (*fig.* 155). *In front*, it corresponds to the parietes of the abdomen, beneath which it may sometimes be felt when distended with gas. It is separated from them by the two anterior layers of the great omentum. The two posterior layers of the great omentum are given off from the middle of its anterior border. *Behind*, it gives attachment to the transverse mesocolon.

The Descending or Left Lumbar Colon.—The descending colon (*d*, *figs.* 155, 161) so closely resembles the ascending portion, both in situation and relations, that we can only refer to what has been already stated. We must observe, however, that it is more deeply situated above than the ascending colon, and that it is of less size. Advantage has been taken of its immediate relations behind, with the quadratus lumborum, in the operation for artificial anus in cases of imperforate rectum. It is preferred, for this purpose, to the ascending colon, simply from its proximity to the anus.

The Iliac Portion, or Sigmoid Flexure, of the Colon.—The sigmoid flexure of the colon (*f*, *figs.* 155, 161) is situated in the left iliac fossa, and is continuous below with the rectum. The line of demarcation between it and the descending colon is determined by the commencement of a fold of peritoneum, called the iliac mesocolon, or, rather, by the change in the direction of the large intestine, as it appears to detach itself from the parietes of the abdomen, opposite the crest of the ilium. It is continuous with the rectum at the point where it dips into the pelvis, opposite the left sacro-iliac symphysis. But, as it often happens that the lower portion, or even the whole of the sigmoid flexure, is contained in the cavity of the pelvis, it may be understood that such a definition is not precise.

It is retained in its place by a very loose fold of peritoneum, called the *iliac mesocolon*, and therefore, in some measure, partakes of the mobility of the small intestine. It has been found in almost all the regions of the abdomen, but especially in the sub-umbilical zone. It has been seen in the umbilical region, its first curvature reaching even to the liver. I have met with a case in which the sigmoid flexure extended upward, and the arch of the colon downward to the umbilicus, so that they came in contact with each oth-

er; the large intestine, therefore, corresponded with the whole anterior region of the abdomen, the sigmoid flexure alone occupying the umbilical, the hypogastric, and the left iliac region.

Should the following disposition, which I have met with several times, be regarded as accidental or congenital? Commencing from the descending colon, the sigmoid flexure passed transversely from the left to the right side, on a level with the brim of the pelvis as far as the right iliac fossa, below the cæcum, which it turned upward in one case, and pushed in front of itself in another; the sigmoid flexure then described its two curves either in the right iliac fossa or in the pelvis. These cases, in which the sigmoid flexure of the colon alone is transposed, must be carefully distinguished from general transposition of the viscera.

The most peculiar character of the sigmoid flexure is its *direction*. It passes at first upward, in an opposite direction to the descending colon, then descends vertically, and then, curving again, passes to the right or to the left, forward or backward, and becomes continuous with the rectum (*r*), (the *iliac flexure*). These several flexures, however, vary exceedingly: I have seen them very slight; but then the upper or free portion of the rectum was found decidedly flexuous; and, indeed, it is difficult to ascertain whether such flexures belong to the rectum or to the displaced sigmoid flexure. There can be no doubt that this double curve of the colon is connected with its uses as a receptacle for fæcal matters.

The *size* of the sigmoid flexure varies considerably. In a case of imperforate anus in an infant, which lived twenty days, it became enormously distended. Retention of the fæces in the adult seldom causes so proportionally great an accumulation in the sigmoid flexure: the rectum is almost entirely the seat of the accumulation.

Relations.—The sigmoid flexure corresponds to the abdominal parietes *in front*. When empty, its relations with the latter are indirect, in consequence of the interposition of some convolutions of the small intestine; when it is distended, they are immediate; and hence we are recommended to make an artificial anus in the sigmoid flexure of the colon, in cases where the rectum is imperforate. It is in contact *behind* with the iliac fossa, to which it is fixed by the mesocolon: hence it can be easily compressed and explored by the fingers, for the purpose of detecting hardened masses of fæces. In the rest of its circumference it is in relation with the convolutions of the small intestine.

The Internal Surface of the Colon.—On the internal surface of the colon are seen three longitudinal ridges, corresponding to the three muscular bands on its external surface; three intermediate rows of sacculi, the concavities of which agree exactly with the protuberances on the external surface; and, lastly, numerous ridges or incomplete septa, dividing the cells of each row from one another, and improperly called *valves;* they correspond to the grooves or depressions on the external surface. In order to comprehend the arrangement of the cells and the intervening septa, we must examine the large intestine when moderately distended and dried. If the muscular bands have been previously divided, the cells and septa disappear.

The internal sacculi, as well as the external protuberances, vary much in different individuals, and even in different parts of the same colon. Thus, there are generally only two rows in the descending colon and the sigmoid flexure, because there are only two muscular bands in those parts. Sometimes, indeed, there are no cells in the sigmoid flexure. Lastly, the internal surface of the large intestine presents some irregular folds, which are completely effaced by distension.

The Rectum.—The rectum (*h i, fig.* 139), so called from its direction, which is generally less flexuous than that of the rest of the intestinal canal, is the last portion of the large intestine, and, consequently, of the digestive tube. It commences at the base of the sacrum, and terminates at the anus. It is *situated*, in the true pelvis, in front of the sacrum and coccyx (*r, fig.* 161; *o o', fig.* 181).

We see, then, that the alimentary canal, after having abandoned the vertebral column in order to describe its numerous convolutions, is situated at its termination in front of the lower part of that column, just as, at its commencement, it is applied to the upper part of the same. It is firmly fixed, especially below, where it is surrounded on all sides by cellular tissue, and is also bound down by the superior pelvic fascia. This part of it cannot, therefore, suffer such displacements as occur in hernia; but, from its functions as an organ of expulsion, the whole effort of the abdominal muscles is concentrated upon it, and it is, therefore, liable to displacements of a different kind, viz., to invagination and eversion.

Its situation, which is in some degree constant, within a bony cavity, having unyielding walls, and its relations with the pelvic fascia, place it in conditions altogether peculiar to itself; for while the bladder and the uterus, which are also contained in the same cavity, ascend into the abdomen when they are distended, the rectum, in which the fæces are accumulated, dilates entirely within the pelvis, and undergoes no change of position.

From this fixed condition of the rectum along the middle of the pelvic cavity, it also follows that, in cases where the gut is denuded by destruction of the surrounding cellular tissue, it remains separate from the walls of the pelvis: such is the nature of fistu-

læ; and hence the necessity of cutting the rectum, in order to bring it in contact with the walls of the pelvis.

Direction.—Particular attention should be paid to the direction of this bowel, as an anatomical fact from which practical inductions of the greatest interest may be derived. It is not straight, but is curved both in the antero-posterior and lateral directions.

In the *antero-posterior direction* it follows the curve of the sacrum and coccyx, to which it is closely applied; it is, therefore, concave in front and convex behind (see *fig.* 181). Opposite the apex of the coccyx it bends slightly backward, so as to terminate about an inch in front of that bone. By this very remarkable inflection, it is separated from the vagina in the female, and from the urethra in the male.

The Lateral Inclination.—On the left side of the base of the sacrum, and opposite the sacro-iliac symphysis, the rectum passes downward, and to the right side, until it reaches the median line opposite the third piece of the sacrum. It then passes forward, still in the median line, and forms a slight curve with the preceding portion. It has been frequently said that the lower part of the rectum does not occupy exactly the median line, but deviates a little to the right: this is not unfrequently the case at the lower part of the sacrum, but it always regains its original position before its termination.

There are, however, some important varieties in the curvature described by the rectum. Thus, it is not uncommon to see the upper part of the gut twisted like an italic *S* before reaching the median line; and in this case, it is difficult to determine whether the twisted portion belongs to the rectum or to the sigmoid flexure of the colon. In several of the cases of unnatural position of the sigmoid flexure, which I have already mentioned, the rectum commenced on the right side of the base of the sacrum, and passed downward, and towards the left side. In one case, where the sigmoid flexure was in its natural position, the rectum passed almost transversely to the right side, as far as the right sacro-iliac symphysis, and then proceeded very obliquely to the left side. The situation of the upper part of the rectum on the left of the median line has been often quoted in explanation of the relative frequency of inclinations of the uterus to the right side, and also of the greater or less amount of difficulty in parturition, according as the occiput of the fœtus is turned towards the right or the left.

Form and Size.—The rectum is cylindrical, not sacculated, and has no bands like those observed in the other portions of the large intestine. Its external surface is covered with a uniform layer of well-marked, fasciculated, longitudinal fibres, which give it some resemblance to the œsophagus. At its commencement, its caliber is somewhat smaller than that of the sigmoid flexure, but it gradually increases towards the lower end. Immediately before its termination at the contracted orifice, called the anus, the rectum presents a considerable dilatation, or ampulla, capable of acquiring an enormous size; so that, in certain cases of retention of the fæces, it has been found occupying the entire cavity of the pelvis.

Relations.—*Behind*, the rectum corresponds with the left sacro-iliac symphysis and the curve of the sacrum and coccyx; it is attached to the sacrum above by means of a fold of peritoneum, called the *meso-rectum*, and is separated from the sacrum and the sacro-iliac symphysis by the pyriformis muscle, the sacral plexus of nerves, and the hypogastric vessels. Those portions of the rectum which project laterally beyond the coccyx are in relation with the levator ani muscles, which form a sort of floor for it.

In front, the rectum is free in its upper portion, but is adherent below; its relations vary in the two sexes, and are of the greatest importance in a surgical point of view.

In the male its upper or free portion (*o*, *fig.* 181) corresponds to the posterior surface of the bladder (*h*), from which it is separated, excepting in cases of retention of urine, or of considerable dilatation of the rectum by convolutions of the small intestines. Its lower or adherent portion is in immediate relation, in the middle line, with the inferior fundus (*bas-fond*) of the bladder, at the triangular space intercepted between the vesiculæ seminales (*s*); on each side, it is separated from the bladder by these vesicles. The extent to which it is in contact with this part of the bladder varies in different subjects, and according as the bladder and rectum are full or empty.

We shall see in another place that the peritoneum (*u u*) forms a cul-de-sac of variable depth between them. In some subjects the cul-de-sac extends as far as the prostate, so that the whole of the inferior fundus of the bladder is covered by it.

In front of the inferior fundus of the bladder the rectum is intimately united to the prostate (*i*). In some cases the prostate projects beyond the rectum, on one or both sides; in other cases the rectum projects beyond the prostate, on one or other, or both sides, and receives the gland, as it were, in a groove.

The rectum has also relations with the membranous portion of the urethra (*c*), but, on account of its inflection backward, it is separated from it by a triangular space, the base of which is directed downward and forward, and the apex upward and backward.

The practical inferences to be drawn from these relations are these: that the bladder projects into the rectum in cases of retention of urine; that the bladder can be explored from the rectum, and may be punctured and cut for the extraction of stone; that the finger passed into the rectum can assist in the introduction of the catheter, and in ex-

amination of the prostate; that the rectum must be emptied before performing the lateral operation for stone; and, lastly, that the membranous portion of the urethra may be opened without injuring this bowel.

In the female, the free portion of the rectum corresponds with the broad ligament, the left ovary and Fallopian tube, the uterus, and the vagina. The peritoneum forms a cul-de-sac between the vagina and the rectum, analogous to that already described between the bladder and the rectum in the male, and subject to the same varieties. When the uterus and the rectum are empty, a certain number of convolutions of the small intestine are always interposed between the rectum and the vagina; and, therefore, in lacerations of the posterior wall of the vagina, the small intestines escape through the wound.

The uterus and vagina are not unfrequently found deviating to the left side, while the rectum deviates to the right, and then the free portion of the latter corresponds to the right broad ligament and ovary. Lastly, in retroversion of the uterus, which is so common, the fundus of that organ rests upon the rectum.

The inferior or adherent portion of the rectum is intimately united to the vagina: hence vaginal cancer frequently extends into the rectum; below, on account of its inflection backward, it is separated from the vagina in the same way as from the urethra in the male, by a triangular space, the base of which is directed downward, and forms the perineum of the female.

On the sides, the free portion of the rectum corresponds to the convolutions of the intestines; the adherent portion is surrounded by adipose cellular tissue, which is nowhere more clearly intended to fill up intermediate spaces; the absorption or destruction of this tissue is an important circumstance in diseases of the anus.

The *internal surface of the rectum* is remarkable for some longitudinal folds, which are obliterated by distension, and somewhat resemble the longitudinal folds of the œsophagus. These folds, which have been inappropriately termed the *columnæ* of the rectum, are intersected by other semicircular folds, also effaced by distension. This internal surface presents, moreover, a dilatation corresponding to the enlargement seen from without, immediately above the anus.

Structure of the Large Intestine.—The same number of coats exist in the large as in the small intestine, but they present certain peculiarities in arrangement, of which some are common to the whole bowel, while others exist only in particular parts.

The Peritoneal Coat.—The peritoneum does not, in general, form so complete a covering for the large as for the small intestine. Moreover, it forms a great number of duplicatures on the surface of the bowel, which usually contain fat, and are called the fatty appendices (*appendices epiploicæ*). They are not constant, either in number, size, or length, but are sometimes arranged in regular series. Some of them are so long that they may form the contents of a hernial sac, or may even occasion strangulation, by forming a ring around the intestines; they are seldom entirely absent. They become lessened when the gut is distended, and are elongated by its contraction. They are sometimes loaded with an immense quantity of fat, of which they may be considered reservoirs. They are found along the whole of the large intestine, including the free portion of the rectum.

The peritoneum often envelops the whole of the cæcum; at other times it does not cover it behind. Most commonly it forms a fold, or mesentery, for the vermiform appendix. It only passes in front of the ascending and descending colon, which are always uncovered behind. It invests the whole of the transverse arch, excepting a triangular space behind corresponding to the transverse mesocolon, and in another triangular space in front corresponding to the great omentum. It completely surrounds the sigmoid flexure, excepting in a small space behind, corresponding to the iliac mesocolon. Lastly, at the upper part of the rectum, it is arranged in a similar manner, and then merely passes in front of that bowel, the lowest portion of which is entirely devoid of a peritoneal covering, and is surrounded by a large quantity of adipose tissue.

From the arrangement of the peritoneum upon the large intestine, it follows that the latter is more favourably circumstanced than the small intestine for assuming a large size; and, also, that it may be penetrated in many places without injuring the peritoneum.

The Muscular Coat.—As in the small intestine, this coat consists of a circular and a longitudinal set of fibres.

The *circular fibres* form the deep layer, and are arranged as in the small intestine; the *longitudinal fibres*, which constitute the superficial layer, are not disposed equally around the bowel, but are collected into three bands, which we have already noticed. These bands have the pearly appearance of ligaments when seen through the peritoneal covering;* they are continuous with the longitudinal fibres of the appendix vermiformis. The anterior is the largest; it becomes inferior along the arch of the colon, and again anterior upon the descending colon and sigmoid flexure, spreading out upon the latter. Of the posterior bands, which are narrower, one is external and the other internal; they become superior on the arch of the colon, and again posterior upon the descending colon and sigmoid flexure, upon the latter of which they are often blended into one. I have

* [They are involuntary muscular fibres; in the lower part of the rectum some transversely striated fibres are found.]

already said that these bands, being not more than one third, or, at most, one half the length of the large intestine, occasion its puckering, and arrangement into sacculi and intervening depressions.

The muscular coat is remarkably modified in the *rectum*. In the sigmoid flexure the longitudinal fibres become scattered, and at its termination surround the whole intestine; but this arrangement exists more particularly in the rectum, where they present the appearance of thick fasciculi, forming an uninterrupted covering (*r*, *fig.* 161). The deep or circular layer of the rectum is much thicker than that of any other part of the alimentary canal, excepting the œsophagus; it may be separated into distinct rings, the lowest of which is so distinct that it has been described as a particular muscle, under the name of the *sphincter internus*. It is arranged in precisely the same way as the corresponding coat of the œsophagus, but is not so thick: this difference depends upon the uses of the two canals, the œsophagus being intended to convey the food rapidly downward, while the rectum is assisted by the abdominal muscles. When the rectum is empty, it contracts upon itself like the œsophagus, and its walls are in contact.

The *fibrous coat* of the large intestine offers no peculiar characters.

The *mucous coat* of the large intestine has no valves: the semilunar crests, or ridges which separate the cells of the colon, are formed by all the coats. The irregular folds or wrinkles observed on this membrane are completely effaced by distension. The mucous membrane is not unfrequently protruded through the muscular fibres, so as to form small sacs having narrow necks, and containing masses of indurated fæces. At first sight such sacs resemble a varix. They are very common in the aged, and are probably the result of habitual constipation.

When examined with the microscope and under water, in the same manner as the mucous membrane of the small intestine, the inner surface of the large intestine is seen to have no villi, but we find exactly the same appearance as in the mucous membrane of the stomach, viz., an alveolar or honeycomb arrangement.* The openings or pores of this mucous membrane are innumerable; and, supposing that they assist both in exhalation and absorption, it may be conceived with what rapidity these processes must be carried on in the large intestine. It is also studded with a number of follicles (tanquam stellæ firmamenti, *Peyer*), which are depressed and perforated in the centre,* and in a great number of subjects, especially in the old, have a black colour. These follicles are never collected into patches, as in the small intestine, but are always solitary. They are often inflamed, though the rest of the membrane is healthy.

It is easy, then, to distinguish the large from the small intestine, simply from the characters of its mucous membrane. The limit between the two is at the free margin of the ileo-cæcal valve; all preceding this has the characters of the mucous lining of the small, all that comes after, of that of the large intestine.

We find dense patches of follicles in the vermiform appendix, the whole of which is sometimes lined with them.

The mucous membrane is more loosely united to the fibrous coat in the rectum than in any other part of the large intestine. This looseness is most marked at its lower part, and hence a protrusion of this membrane only may occur, as in the œsophagus; and this must be carefully distinguished from prolapsus of the entire rectum. I should also remark, that the capillary veins are much developed at the lower part of the rectum, and, when much larger than usual, constitute what are called hemorrhoidal tumours.

Vessels and Nerves.—The *arteries* of the cæcum, the vermiform appendix, the ascending colon, and the right half of the arch, are supplied by the superior mesenteric; the rest of the colon and the rectum receive blood from the inferior mesenteric. The rectum also receives a branch from the internal iliac, called the middle hemorrhoidal, and a branch from the internal pudic, called the inferior hemorrhoidal. Some small ramifications are also furnished to the great intestine by the gastro-epiploic, splenic, capsular, and spermatic arteries. The rectum exceeds all other parts of the large intestine in the number and size of its arteries, and, therefore, operations upon the lower part of that bowel are often followed by serious hemorrhage.

The *veins*, which bear the same name and follow the same course as the arteries, concur in the formation of the great and small mesenteric or mesaraic veins, which terminate in the vena portæ.

The *lymphatic vessels* are very numerous, and terminate in the

Fig. 162.

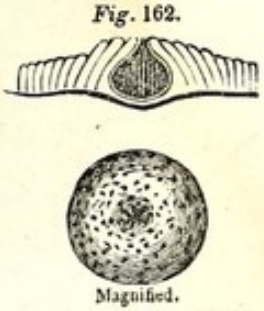

Magnified.

* [In the stomach this character is due to the presence of the alveoli, in the bottom of which the perpendicular tubuli open. In the large intestine, however, there are no pits; but the alveolar appearance is produced by the openings of numerous tubes, analogous in form and direction to the tubuli of the stomach, and to the crypts of Lieburkuhn in the small intestine.

The follicles of the large intestine differ from the solitary glands of the jejunum and ileum, in being always open. Each follicle is much dilated below, but has a narrow orifice. In *fig.* 162, the upper drawing represents a vertical section of a follicle (magnified), surrounded by the perpendicular tubes; the lower is a magnified superficial view, showing the depression and opening in the centre, and the orifices of the surrounding tubes.

The epithelium of this mucous membrane is cylindrical or columnar.]

glands situated along the attached border of the intestine; the large intestine is also possessed of lacteals, but they are less evident than in the small intestine.

The *nerves* are derived from the solar plexus, and form plexuses along the arteries; they all belong to the ganglionic system. The rectum alone receives additional nerves from the cerebro-spinal system, viz., from the hypogastric and sacral plexuses. The presence of these two sets of nerves has reference to the functions of the bowel, which are partly involuntary and partly subject to the influence of the will.

The Anus.—The word *anus*, borrowed from the Latin, signifies the lower orifice of the alimentary canal (the *anal orifice*); it is a narrow but dilatable opening, through which the fæces are expelled.

It is situated in the median line, about an inch in front of the point of the coccyx, at the back part of the perineum, between the tuberosities of the ischium, and at the bottom of the fissure between the buttocks. The skin around the borders of this orifice, which is constantly closed, contains a great number of sebaceous follicles, and is covered with hair in the male; it passes deeply into the orifice, to become continuous with the mucous membrane, and presents a great number of radiated folds, which are effaced during dilatation. The point at which it becomes continuous with the mucous membrane is deserving of notice: it is within the rectum, at the distance of some lines from the anus properly so called, and is marked by a waved line, which forms a series of arches or festoons, having their concavities directed upward. Sometimes there are small pouches in the situation of these arches, opening upward. From the angles at which the arches unite, some mucous folds proceed, and small foreign bodies, detached from the fæces, are often retained in the culs-de-sac, and become the causes of fistulæ.

Structure of the Anus.—The anus, intended as it is to prevent the revolting inconvenience of a constant and involuntary escape of the fæces, consists essentially of a *sphincter* muscle, which is antagonized, not only by the proper dilator, viz., the *levator ani*, with which I connect the *ischio-coccygeus*, but also by the diaphragm and the abdominal muscles. The absence of a sphincter is the great evil of every artificial anus. A fourth muscle, the *transversalis perinei*, must also be included among the muscles of the anus.

The *skin* and the *mucous membrane* which cover these muscles are remarkable for the great development of the erectile tissue, which forms the basis of all tegumentary membranes. The terminal branches of the hemorrhoidal arteries are extended upon this portion of the skin and mucous membrane. From this erectile, and, therefore, vascular tissue, arise a great number of winding, twisted, and plexiform veins, which form the lowest roots of the vena portæ. A considerable number of cerebro-spinal and ganglionic *nerves*, derived from the sacral plexus and the hypogastric nervous centre, are distributed around this orifice. Lastly, there are mucous crypts, or, rather, glands, a vestige of the highly-developed glandular organ found in some animals.

Muscles of the Anus.—We now proceed to the description of the muscles of the anus, which are six in number, viz., two single muscles, the *sphincter* and the *transversalis perinei*; and two pairs, the *levatores ani* and the *ischio-coccygei*, which, in fact, form but one muscle. The *sphincter internus* of authors is nothing more than the last ring of the circular fibres of the rectum.

The Sphincter Ani.

Dissection.—Remove carefully the corrugated skin which covers the anal region; prolong the dissection backward as far as the coccyx, and forward to the scrotum in the male, and the vulva in the female. It is not sufficient to expose the lower ring of the sphincter; the adipose tissue, which surrounds the lower part of the rectum, should be removed on each side. It is well to stuff the lower part of the rectum preparatory to this dissection, as well as that of the muscles of the perineum.

The *sphincter ani* (*a*, *fig.* 163) is an orbicular muscle, situated around the lower end of the rectum. It is not a simple ring, but a muscular zone of nearly an inch in width. Its form is an ellipse, much elongated from before backward, and terminating in a point in front and behind. The fibres which constitute the lowermost ring of the muscle *arise* from the sub-cutaneous cellular tissue in front of the coccyx, in the same manner as other cutaneous muscles; those which form the upper rings arise from a sort of fibrous tissue given off from the point of the coccyx. From these points the fleshy fibres proceed forward, and form a semi-ellipse on each side, composed of parallel and superimposed muscular rings, which terminate in front of the anus in the following manner: The lower rings

Fig. 163.

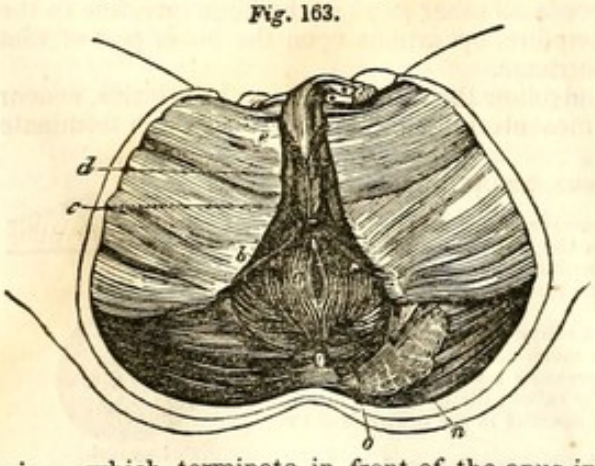

in the sub-cutaneous cellular tissue, the upper rings in the sort of fibrous raphé, which gives origin to the bulbo-cavernosus.

Relations.—The *internal surface* of the sphincter embraces the lower part of the rectum, the lowest circular fibres of which are seen within the sphincter, and are distinguished from it by their paleness. They constitute the internal sphincter. Its *external surface* is in relation with the adipose tissue of the pelvis. Its *upper border* is continuous with the antero-posterior fibres of the levaotr ani; so that it is very difficult to establish the limit between them.

Its *inferior border* projects a little below the lowest annular fibres of the rectum, and only adheres to the skin by loose cellular tissue, which is continuous with the dartos.

Action.—It is a constrictor of the anus. The contraction of the body of the muscle closes the lower part of the rectum; the constriction produced by the inferior ring occurs below that bowel.

The Transversus Perinei.

Dissection.—Remove with care the sub-cutaneous cellular tissue in front and upon the sides of the anus.

The *transversus perinei* (*b*) is situated almost transversely in front of the anus. It *arises* from the internal lip of the tuberosity of the ischium, immediately above the ischio-cavernosus (*erector penis*), by a broad and thin tendon, which is soon succeeded by fleshy fibres. These pass inward and a little forward, on to the anterior surface of the rectum, where they are usually described as becoming blended with those of the opposite side in a fibrous raphé, common both to the transversi, the sphincter, and the bulbo-cavernosi (*acceleratores urinæ*). This does not appear to me to be the exact termination. I have seen this muscle evidently continuous with that of the opposite side, after having traversed the anterior extremity of the sphincter. According to this, the two transversi would constitute a single muscle, forming a half ring, the concavity of which, being directed backward, would embrace the anterior part of the rectum, an arrangement well calculated to assist in expulsion of the fæces.

Relations.—This muscle is placed at the boundary between the anal and perineal regions. It forms the posterior side of a triangle, of which the outer side is formed by the ischio-cavernosus (*c*), and the inner by the bulbo-cavernosus (*d*). It is sub-cutaneous, excepting in the median line, and is in relation above with the levator ani.

Action.—It tends to compress and force the anterior against the posterior surface of the rectum, which we shall see is pushed forward by the levator ani. It therefore assists powerfully in defæcation.

The Ischio-coccygeus and Levator Ani.

Dissection.—These muscles must be studied both from the perineum and from the interior of the pelvis. In the perineum: remove the adipose tissue, which occupies the interval between the rectum and the obturator internus; in order to expose the whole of the ischio-coccygeus, cut the lower edge of the glutæus maximus, and carefully divide the great and small sacro-sciatic ligaments. In the pelvis: remove the peritoneum lining the sides of that cavity; remove the superior pelvic fascia which covers these muscles, and trace them very carefully backward and upon the sides of the rectum, the bladder, and the prostate gland.

The *ischio-coccygeus* and the *levator ani* constitute the floor of the pelvis. They form an uninterrupted muscular plane, from the lower border of the pyriformis muscle to the arch of the pubes. The ischio-coccygeus includes that portion which is inserted into the sides of the coccyx; the remainder is the levator ani.

The Ischio-coccygeus, or Coccygeus.

This is a flat, triangular, or, rather, a radiated muscle (*o*), situated at the lower part of the pelvis, in front of the sacro-sciatic ligaments. It arises from the sides and summit of the spine of the ischium, from the anterior surface of the lesser sacro-sciatic ligament, and often from the posterior part of the pelvic fascia; it passes in a radiated manner to the border of the coccyx and the lower part of the border of the sacrum. All these attachments are effected by aponeurotic fibres, to which the fleshy fibres succeed. In this respect its structure has considerable analogy with that of the intercostal muscles, the tendinous portion exceeding the muscular.

Relations.—Its *upper* surface (*o*, *fig.* 111) is slightly concave, and corresponds to the rectum; its *lower* surface (*fig.* 163) is slightly convex, and is in relation with the sacro-sciatic ligaments and the glutæus maximus; its posterior margin is applied to the lower border of the pyriformis; its anterior margin is continuous, without any line of demarcation, with the posterior margin of the levator ani (*n*), from which muscle it can be distinguished merely by its tendinous structure.

Action.—It assists in forming the floor of the pelvis. It tends to draw the coccyx to its own side: when the muscles of both sides act together, the coccyx is fixed, and cannot be thrown backward. It acts, therefore, in defæcation. The name *levator coccygis*, which was given to it by Morgagni, is altogether inapplicable.

The Levator Ani.

This muscle (*n*), so called from one of its chief uses, is situated in the cavity of the pelvis, and with its fellow forms a sort of muscular floor, which, in many respects, resembles that formed by the diaphragm. It is thin, curved, and quadrilateral, narrow in front, and broad behind.

It arises, by its *fixed* or *upper attachments*, *in front*, from the pubis, at the side of, and sometimes even from the symphysis; *behind*, from the anterior border of the spine of the ischium, and in the interval between these extreme points from the upper part of the obturator foramen, and from the brim of the pelvis.

Its *movable attachments* are to the side of the prostate, the bladder, and the rectum, to the point of the coccyx, and to the fibrous raphé extending from that point to the sphincter. The fibres arising from the symphysis pubis are concealed by the pubio-prostatic ligament;* they are few in number, short, and directed inward, backward, and downward, to form a bundle (the *prostatic*), which was described by Santorini as the *levator prostatæ*, and by Winslow as *le prostatique supérieur*. The fibres arising from the spine of the ischium are blended at their origin with those of the coccygeus, and pass transversely inward to the point of the coccyx. The origins from the upper part of the obturator foramen and from the brim of the pelvis take place by means of the pelvic aponeurosis, which divides and receives the muscle between its two layers (*i. e.*, the superior pelvic and the obturator fasciæ). These fibres, the hindermost of which are the longest, all pass inward, describe a curve having its concavity directed upward, and are divided into the *vesical*, *anal*, and *præ-coccygeal*. The *vesical* fibres pass upon the sides of the inferior fundus (*bas-fond*) of the bladder. I have never seen them terminate on the vesiculæ seminales. The *anal fibres* having reached the sides of the rectum, above the sphincter, pass backward, and meet behind the bowel. They constitute a half ring on each side, prolonging the sphincter upward, without any distinct line of demarcation. The *præ-coccygeal fibres* are directed backward, and form a thick fleshy layer, occupying the interval between the coccyx and the sphincter, and completing the lower wall or floor of the pelvis. In the female there are also vaginal fibres.

Relations.—Its upper or internal surface is covered by the superior pelvic fascia, which separates it from the peritoneum and the organs contained in the pelvis. The obturator fascia intervenes between its lower or external surface and the internal obturator muscle, from which it is separated below by a large triangular space, narrow above and broad below, and filled with adipose tissue. Its posterior part is in relation with the glutæus.

Action.—It serves as a muscular floor for the pelvis. It raises the prostate, the inferior fundus of the bladder and the anus, and counteracts the effect of the diaphragm and abdominal muscles during violent exertions. It assists powerfully in the expulsion of the urine, the seminal fluid, and the fæces.

As the largest portion of the muscle occupies the sides and the back of the rectum, its especial use is to expel the contents of that bowel: this is effected by the præ-coccygeal fibres of both muscles elevating the rectum, and by their anal fibres drawing it forward and upward, and compressing it on the sides.

Functions of the Large Intestine.—In the large intestine, the alimentary substances acquire the odour and all the other characters of the fæces; any remaining nutritious matter or chyle which they may contain is absorbed, and they become hardened and moulded in the cells of the colon. Absorption is sufficiently active in the large intestine to enable life to be supported for a considerable period by means of nutritive enemata, in persons who cannot receive food into the stomach. The large intestine acts also as a reservoir; its long course, its curvatures, and its easily yielding character, enable it to contain a great quantity of matter, and prevent the inconvenience of constant defæcation.

The appendix vermiformis has no use in man; it is merely the trace of a largely-developed intestine in herbivorous animals.

The rectum is the final reservoir, and one of the agents in the expulsion of the fæces, the presence of which gives rise to a sensation that informs us of the necessity for evacuating them. The sphincter, in general, opposes this evacuation, until it is determined upon by the will. The expulsion is effected by the action of the rectum, assisted by the diaphragm and the abdominal muscles.

Development of the Intestinal Canal.

The development of the intestinal canal offers two subjects for consideration, viz., the relations existing between it and that portion of the fœtal membranes called the *vesicula umbilicalis*; and the development of the canal itself, independently of that vesicle.

In reference to the first point, the anatomy of the human fœtus is still involved in much obscurity, authorities being divided in opinion on the subject. Without entering here into a discussion which belongs to a higher department of anatomy, I would observe, that

* [*I. e.*, by the anterior folds of the recto-vesical fascia, from which the fibres in question partly arise, and by which they are separated from the levator ani: the posterior layer of the triangular ligament is in relation with them in front.]

the principal arguments adduced by those who admit the communication between the intestinal canal and the vesicula umbilicalis are drawn from analogy, and especially from what occurs in oviparous animals, whose vitelline membrane is regarded as analogous to the umbilical vesicle, and in which the most evident communication exists at all stages of fœtal existence.

I would observe, also, that these same anatomists are not agreed respecting the point at which this communication occurs. According to Oken, it is at the junction of the small with the large intestine:* according to Meckel, it is at the lower part of the small intestine, and the diverticula so frequently observed in this place are vestiges of the canal of communication. The last-named anatomist, after having discussed all the arguments on either side of the question, concludes thus: "I think, then, that we must at present admit a continuity of substance between the umbilical vesicle and the intestinal canal, without pretending to decide whether the cavities of these two organs open into each other" (*Manual d'Anatomie*, tom. iii., p. 416, trad. par MM. Jourdan et Breschet). But the communication of the cavities is evidently the entire question.

The arguments of those who deny the existence of a communication in the human fœtus and mammalia are founded upon direct observation. I must say, with Emmert, Cuvier, and others, that I have never detected this communication; and though I am far from denying it altogether, yet I consider that facts are still wanting to prove its existence.†

The development of the intestinal canal itself presents, besides some questions yet undetermined, certain positive facts, concerning which there can be no dispute. One of the undetermined questions relates to the mode in which the intestine is formed. Is the digestive tube originally an oblong vesicle, which becomes elongated, at the same time, at both its cephalic and its coccygeal extremities, both being at first imperforate, but afterward opening so as to form the mouth and anus? Does it at first resemble a groove open in front, as Wolf has shown to be the case in birds; or is it developed from two lateral halves, subsequently united together, according to the opinion of M. Serres? Is the intestinal canal formed from one, or from several centres of development? Is it developed from several pieces, which afterward meet each other, so to speak? and are any grounds for this opinion afforded by the absence of different portions of the canal in acephalous monsters, or the occasional existence of septa in different parts of its extent? I think not.

Upon the whole, these microscopical investigations into the first traces of the development of organs are still involved in great obscurity; and I must say that, whenever I have been able to discern the intestinal canal, it has appeared to me to form a complete cylinder.‡ Another question, which yet remains undetermined, relates to the situation of the intestine in the early periods of intra-uterine existence. It is at first situated, as some authors believe, in front of the vertebral column; or, rather, as others imagine, in that portion of the cord which is next the umbilicus.

Embryologists agree in stating that, in the earliest periods of its development, the intestinal canal is not contained in the abdominal cavity, but only its two extremities; all the intermediate part, *i. e.*, almost the whole of the canal, is situated within the umbilical cord, which at that time is very considerably enlarged. The whole intestinal canal is not included in the cavity of the abdomen until towards the middle of the third month.

This fact is quoted in explanation of congenital umbilical hernia, which would be considered merely an arrest of development. I must here remark, that this situation of the intestines, in a cavity formed within the umbilical cord, does not seem to me to have been clearly established; that there are a great number of cases where no such arrangement exists; that in other cases there is only a loop of the intestine in the substance of the cord; and, lastly, that the cases in which such an arrangement has been observed, if not examples of actual disease, may at least be regarded as instances in which the development of the anterior wall of the abdomen had been retarded.§

Dimensions of the Intestinal Canal.—The earlier the period of development, the shorter and narrower is the intestinal canal. Its length at first appears to correspond to that of the vertebral column, a relation which is natural and permanent in a great number of the lower animals. The canal soon becomes flexuous, and its windings become more numerous in proportion as it increases in length. From the third to the fourth month, its curves are analogous to those which it subsequently describes: at the sixth month, the due proportion between the different parts of the canal is established. At the earlier periods, the small intestine has a much greater caliber in proportion to the large intestine than it afterward presents; and, on the other hand, the large intestine is relatively longer than at subsequent periods.

The division into the large and the small intestines does not exist at first. There is

* The vermiform appendix and the cæcum are the remains of this communication, according to Oken.

† [The communication has been distinctly seen and described by Dr. Allen Thomson.—(*Edin. Med. and Surg. Journ.*, cxl., p. 132.)]

‡ [In the ovum, No. II., described by Dr. A. Thomson (*loc. cit.*), the future alimentary canal has the form of a groove.]

§ [The presence of a portion of the intestinal canal within the umbilical cord, at some period of development, is constant not only in man, but in several quadrupeds, and cannot be merely accidental.]

no ileo-cæcal valve, no cæcum, and no appendix vermiformis; but these three means of distinction appear simultaneously from the second to the third month.* The cæcum and the vermiform appendix are not distinct from each other, but present the appearance of a sort of funnel. The appendix, though at first small, is gradually developed, and becomes proportionally greater than it is afterward; its caliber is nearly one half that of the small intestine. If it be not quite correct to say, with Haller, that the cæcum does not exist in the fœtus, yet it must be admitted that, at this period of existence, it is nothing more than the expanded base of the vermiform appendix; and the development which it acquires after birth may, to a certain degree, be regarded as the mechanical effect of the weight of the fæcal matters in dilating its cells. The anterior cells of the cæcum, on account of its vertical position, undergo a relatively greater amount of dilatation; and from this the vermiform appendix, which corresponded at first to the centre of the lower end of the cæcum, is turned backward, inward, and to the left side, towards the ileum. The cæcum and the appendix do not occupy the right iliac fossa until the fourth or fifth month; before that time they are situated in the neighbourhood of the umbilicus. For the first four or five months of intra-uterine life, the large intestine is not sacculated; so that its external surface is exactly similar to that of the small intestine, the only means of distinguishing one from the other being the situation of the vermiform appendix. About the fifth month, according to Morgagni, the three longitudinal depressions, and the transverse folds or depressions and intermediate protuberances, make their appearance simultaneously. These characters are first observed in the transverse arch of the colon.

The valvulæ conniventes of the small intestine do not appear until about the seventh month, and they are very slightly developed at birth. It is not uninteresting to remark, that the condition of the fœtus, in this respect, resembles that of animals, which never have valvulæ conniventes. The villi, however, can be observed as early as the third month. Meckel considers that they are developed from folds of the mucous membrane, the surfaces of which become notched. At the same period, according to that author, villi are very apparent in the large intestine; but, after the seventh month, they diminish in number and size, while those of the small intestine remain, even if they do not increase.

At first it is impossible to distinguish the several coats of the intestine; the serous and the mucous membrane can alone be recognised. The intestine is perfectly transparent.

The great omentum first appears during the third month, along the convex edge of the stomach, like a small and very thin border. Fat is never found within it before birth; nor are the appendices epiploicæ developed until after that event.

At birth, the intestinal canal presents the same characters as it afterward possesses. The small intestine is already provided with rudimentary valvulæ conniventes, with well-marked villi, and with very evident solitary and agminated glands. The large intestine, which is much developed, is distended with meconium; the cæcum is shorter than it afterward becomes, the vermiform appendix is larger, and the ileo-cæcal valve has the same appearance as in the adult. The mucous membrane of the large intestine is already characterized by its solitary follicles and alveolar appearance.

In the large intestine of the fœtus, we find, instead of fæcal matter, a thick, viscid inodorous, and dark-green substance, which fills the bowel more or less completely. This is the *meconium*, so called from the Greek word *μήκων*, a poppy, because it bears some resemblance in colour and consistence to the juice of that plant. Its quantity increases towards the period of birth. The time at which it first appears has not been ascertained: I have found it in fœtuses of four or four and a half months, but then it only occupied the rectum. From the seventh to the ninth month it is accumulated in the sigmoid flexure, and diminishes in quantity towards the ileo-cæcal valve. The vermiform appendix is not unfrequently found distended with this matter. The small intestine also contains a mucous substance; but it is less abundant and less viscid, sometimes colourless, and sometimes yellowish or greenish.

The changes which take place in the intestinal canal after birth, affecting its caliber, its situation, and its length, appear to me to depend upon its being more or less distended with gas and fæcal matters, and on its being displaced in consequence of adhesions, increase of size, or displacement of other organs. I have proved that in females who have had children, the intestines present more varieties in situation than in males. We may add, that these differences in position are much more frequently observed in the large than in the small intestine.

APPENDAGES OF THE ALIMENTARY CANAL.

The Liver and its Excretory Apparatus.—The Pancreas.—The Spleen.

The appendages of the sub-diaphragmatic portion of the alimentary canal are the *liver* and *pancreas*, two glandular organs which pour their secretions into the duodenum, and the *spleen*, which may be regarded as an appendage of the liver.

* Haller, who, in this and many other passages, seems to have foreseen the law of unity of organization, says, "Eadem primordialis hominis fere fabrica est quæ quadrupedum."—(Lib. xxiv., p. 116.)

The Liver.

The *liver* (*l l'*, *figs.* 155, 161) is a glandular organ, intended for the secretion of bile. Moreover, it is to this organ that the blood of the abdominal venous system is carried in the adult, and that of two systems of veins in the fœtus.

It is *situated* near the duodenum, *i. e.*, the portion of the intestinal canal into which the bile is poured; it occupies the whole of the right hypochondrium, advances into the epigastrium, and even slightly into the left hypochondrium. It is protected by the seven or eight lower ribs on the right side, which defend it from external violence; and it is separated from the thoracic organs by the diaphragm. It is supported by folds of the peritoneum connecting it with the diaphragm, and regarded as suspensory ligaments; by the stomach and intestines, which form a sort of elastic cushion for it; and by the vena cava, which is intimately adherent to it. These means of support and attachment allow of slight movements to and fro, and even of certain changes of position, not amounting to displacement. Thus, it is depressed during inspiration, and projects a little below the edges of the costal cartilages; it is raised during expiration; it sinks slightly downward during the erect posture, and backward, or in the direction in which its own weight would drag it, according to the way in which the body lies during the horizontal position; it is pushed upward by tumours in the abdomen, and downward by effusions in the chest. The disturbed sleep to which many individuals are subject when lying upon the left side, is attributed to the pressure of the liver upon the stomach; and to the dragging of the liver upon the diaphragm has been ascribed the sensation of hunger, as well as the relief of that feeling produced by tying something tight around the abdomen. These notions are, however, purely hypothetical; and generally, in solving such questions, the exact state of fulness of the abdomen, and of the mutual action and reaction of the abdominal parietes and viscera, has not been sufficiently taken into account. True displacements of the liver are very rare, and *hepatocele* (hernia of the liver) is the result of an imperfect development of the walls of the abdomen.

Size.—The liver is the largest and heaviest of all the organs of the body; and, indeed, in the human subject, it exceeds in weight and in size all the other glands together. It is not true, as the ancients declared, that the liver is larger in man than in any other animal. But the opinion maintained by many naturalists, that there is, in the animal series, an inverse ratio between the size of the liver and the development of the respiratory organs, so that this organ is much larger in reptiles and fishes, whose respiration is slight, than in birds and mammalia, which respire vigorously, is not altogether devoid of foundation.

The liver weighs from three to four pounds, thus forming one thirty-sixth of the whole weight of the body according to Bartholin, and one twenty-fifth according to others. Its longest diameter, the transverse, is from ten to twelve inches; its antero-posterior diameter is from six to seven inches; and its vertical diameter in the thickest part, from four to five. These dimensions are extremely variable, but are always inversely proportional to each other. In a great many livers the transverse diameter is the shorter, and the vertical the longer.

Few organs present a greater variation in size and form in different individuals than the liver. I am certain that the relative proportion between different livers may be as much as one to three, in the absence of all disease. It is pretty generally believed that a large liver occasions such modifications in the whole system as will give rise to a particular temperament. But it may be doubted whether there is any proof that the bilious and melancholic temperaments are specially accompanied by a large liver, or that hypochondriasis in particular is the result of a predominance of that organ.* Anatomical evidence affords but little support to such ideas, which are rather the result of preconceived notions respecting the functions of the liver and the influence of the bile, than the fruit of positive observations.

It varies much in size according to the state of its circulation; when its vessels, and especially the ramifications of the vena portæ, are empty, the tissue of the liver shrinks, and its surface becomes, as it were, wrinkled. When, on the other hand, the hepatic vessels are injected, the organ is in a state of turgescence. I have often been struck with the increase in the size of the liver produced by an injection pushed forcibly and continuously into the vena portæ.

The size of the liver, as influenced by age and disease, deserves particular attention. I shall point out the influence of age under the head of development. We shall then see that the liver is largest during intra-uterine life, and that it is proportionally larger at periods nearer to that of conception: hence it arises that the greatest relative size of the liver is coincident with the least amount of biliary secretion; and we may therefore conclude that this organ has some other use besides that of secreting bile.

When diseased, the liver has been found to weigh from thirty to forty pounds; but the enormous size in these cases is almost invariably owing to the development of acci-

* Hippocrates sometimes gave the name of *hypochondria* to the liver, and hence, no doubt, the term *hypochondriac*.

dental tissues. Some cases, however, have been recorded of simple hypertrophe of the liver without any organic disease, in which the size acquired was prodigious. In opposition to this, we must notice the state of atrophy* in which the liver is shrivelled, and not more than a third, fourth, or even a sixth of the natural size. In one subject, in which the umbilical vein remained pervious, and the sub-cutaneous abdominal veins were dilated and varicose, the liver weighed only about half a pound.

The specific gravity of the liver is, to that of water, as fifteen to ten

Figure.—The liver is a single and asymmetrical organ, of such an irregular form as to defy description. We shall compare it, with Glisson, to a segment of an ovoid, cut obliquely lengthwise, thick at its right extremity, and progressively diminishing towards the left, which terminates in a tongue. Its shape is represented by the sort of mould formed by the right half of the diaphragm, and bounded below by an oblique plane directed upward and to the left side (*fig.* 161).

No organ is more exactly moulded upon the surrounding parts, nor undergoes changes in form with greater impunity, either from external pressure or from that exercised upon it by other viscera; it may even be said to be, as it were, ductile or malleable under the influence of a slowly-exerted pressure. The injurious effects of very tight lacing are chiefly experienced by the liver. A circular constriction and a fibrous thickening of this organ opposite the base of the thorax sometimes afford evidence of this compression; its transverse and antero-posterior diameters become diminished, and its vertical diameter is increased; it projects more or less below the base of the thorax, descends as low down as the right iliac fossa, and may even touch the brim of the pelvis without any structural lesion. In these cases, its upper surface becomes anterior, and its lower surface posterior.

There are but few female subjects without some deformity of the liver, and, therefore, the type of the organ must be sought for in the male.† No practical conclusions, then, can be derived from the shape of the liver; and I am almost inclined to agree with Vesalius, in saying that it has no determinate form, but accommodates itself to the surrounding parts. In a few rare exceptions, we find the human liver divided into lobules by deep fissures, as it is in a great number of animals. The errors which have for a long time existed upon this subject, even since the time of Vesalius, arise from a blind respect for the assertions of older anatomists, who, having dissected few human subjects, were accustomed to confound, in their descriptions, the structure found in animals with that observed in man.

The liver presents for consideration a superior or convex surface, an inferior or plane surface, an anterior and a posterior border, a base, and a summit.

The *superior surface* (*pars gibba*) is convex and smooth, and in contact with the diaphragm, which is moulded exactly upon it: this convexity is not regular, but much greater on the right than on the left side, where the surface is almost flat (*fig.* 161). This surface is divided into two unequal parts (*l l'*) by a falciform fold of peritoneum (1 to 2), called the *falciform* or *suspensory ligament of the liver*, which seems to be principally intended to protect the umbilical vein, and which is never put upon the stretch during the natural state of fulness of the abdomen. One or more fissures are not unfrequently found running from before backward upon the upper surface of the liver; and I am sure that these fissures, in explanation of which Glisson and Fernel have advanced some very singular opinions, are due, at least in some cases, to the pressure of projecting folds of the diaphragm. The falciform ligament forms the line of separation between the *right* (*l'*) and the *left* (*l*) *lobes*, a purely nominal distinction, which results from the old habit of admitting several lobes in the liver, and is retained here only for the sake of conformity to custom. The portion of the liver situated to the left of the suspensory ligament is always smaller than that upon the right.

The convex surface of the liver is bounded behind by the reflection of the peritoneum upon it from the diaphragm. It is separated by the diaphragm from the heart, the ribs, and the base of the right lung. Its relations with the base of the right lung are very extensive: the base of the lung and the convexity of the liver are exactly fitted to each other; this may be shown by making a vertical section from before backward, upon the right side of the trunk, when the liver will be seen to be received, as it were, into a deep excavation in the base of the lung. This relation explains why abscesses and cysts of the liver may burst into the lung, and why abscesses of the lung point towards the liver; why the liver may increase in size in the direction of the thorax, and push up the lung as far as the third or even the second rib; and why effusions into the pleura may force the liver downward in the abdomen; and also why peritonitis, confined to the region of the liver, is sometimes mistaken for pleurisy at the base of the thorax. The relations of the liver with the seven or eight inferior ribs account for the impressions which are often seen upon its surface; and also explain the facts, that violent blows upon the ribs may bruise this viscus; that pointed instruments thrust into the intercos-

* We cannot admit the proposition of Sœmmering, "Quo sanior homo, eo minus ejus hepar est."

† Sœmmering, without giving any reason, says, "*In sexu masculo magis, minus in femineo costis istis tectum latet.*"—(*Corpor. Hum. Fabric.*, t. vi., p. 163.)

tal spaces on the right side may wound it; and that abscesses of the liver point and open between the ribs.

The relations of the convex surface of the liver with the abdominal parietes, which are so extensive in the new-born infant, and still more so in the fœtus, are generally confined in the adult to a variable extent of the epigastrium, and to a small space below the edges of the ribs on the right side (*fig.* 155). In certain conformations of the liver (almost always acquired), and in such diseases as are attended with an increased size of the organ, these relations become much more extended; and, even in the absence of any disease, the liver is not unfrequently found to extend into the neighbourhood of the umbilicus, or even into the right iliac region. In the erect posture, the liver has a tendency to project below the ribs; and, therefore, the sitting posture, with the upper part of the body inclining forward, and resting upon some object, is the most favourable one for exploring this organ.* It is by no means rare to meet with accidental adhesions between the liver and the diaphragm, consisting either of cellular filaments in the form of bands, or of cellular tissue of a greater or less density.

The *inferior* or *plane surface* (*pars sima*, *l l*, *fig.* 154 and *fig.* 164). This is much more complicated than the upper surface, and upon it the hepatic vessels enter and make their exit from the liver. Certain eminences and depressions, or fissures of variable depth, are met with here, which have led to the division of the liver into several lobes; but that kind of division, which in animals appears to enable the organ to adapt itself to the form of the viscera of the abdomen, and has probably some relation with the conformation of the heart, cannot be said to exist in man.† This lower surface is directed downward and backward, and sometimes directly backward: it presents for our consideration, in the first place, an *antero-posterior fissure*, or *fissure of the umbilical vein*, called also the *longitudinal* or *horizontal* fissure (*u h*, *fig.* 164), which extends from the anterior to the posterior border of the liver, and is divided by the transverse fissure (*d p*), meeting it at a right angle, into two halves, one anterior, the other posterior. The anterior half lodges the umbilical vein in the fœtus,‡ or the fibrous cord (*u*), to which it is reduced in the adult: the posterior half lodges the ductus venosus in the fœtus, or the fibrous band (*v*), by which it is replaced after birth. The anterior half of the longitudinal fissure is much deeper than the posterior, and is often converted into a complete canal by a sort of bridge formed by a prolongation of the substance of the liver: when incomplete, this bridge is always situated near the transverse fissure: it often consists of a band of fibrous tissue. Even when quite complete, it invariably presents a notch near the anterior border of the liver.◊ The posterior half of the longitudinal fissure inclines more or less obliquely to the left of the lobulus Spigelii (3), gives attachment, like the transverse fissure, to the gastro-hepatic omentum, and communicates with the fissure for the vena cava superior (*c*), behind the lobulus Spigelii.

Fig. 164.

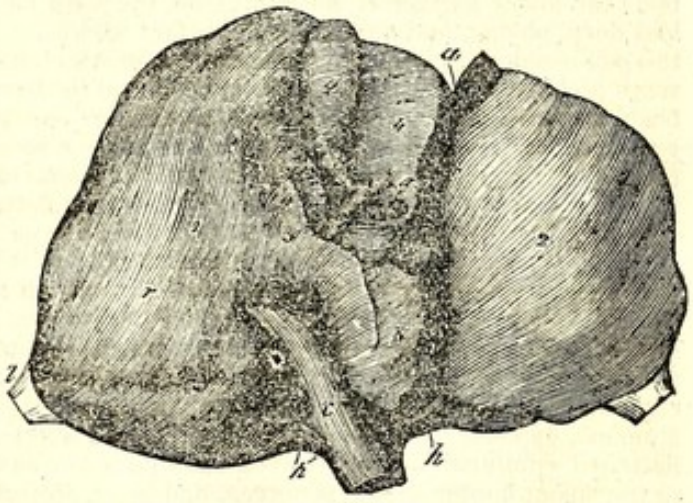

The existence of this fissure has been the chief cause of the division of the liver into the *right* or *great lobe* (1), and the *left lobe* (2), also termed the *middle-sized lobe* by those anatomists who admit as a third lobe the *small lobe*, the *lobule* or the *lobulus Spigelii* (3). This division of the liver into two lobes is also marked on the upper surface, as we have already seen, by the suspensory ligament. Of these lobes, the right is much larger than the left; the former occupies the right hypochondrium, the latter the epigastrium and left hypochondrium (*fig.* 161). The proportion between the right and the left lobe cannot be precisely determined. The left lobe is sometimes reduced to a thin tongue, while, at other times, it is almost half the size of the right lobe. Generally, the relative proportion between them is as six to one. This, however, is of but little consequence; for as the distinction between the two lobes is quite imaginary, the substance of the left

* In an old woman, whose liver was deformed but healthy, and projected below the ribs, I was able to diagnosticate, by mediate percussion, the existence of a knuckle of intestine between the liver and the parietes of the abdomen. Very lately I found a large loop of the transverse arch of the colon between the right lobe and the abdominal parietes, and a loop of the small intestine between the left lobe and those parietes.

† The ancients admitted four lobes in the liver, which they distinguished by the singular names of *mensa*, *porta*, *gladius*, and *unguis*

‡ [The term umbilical fissure is often restricted to this part of the longitudinal fissure; the posterior half is then called the fossa of the ductus venosus.]

◊ [This bridge was purposely divided in the liver from which *fig.* 164 was drawn.]

may, without any inconvenience, be included in the right, and *vice versâ*. The *transverse fissure*, or *fissure of the vena portæ* (*d p*), is the true *hilus* of the liver, for through it the hepatic vessels enter and pass out. It is a very broad, transverse fissure, from fifteen to eighteen lines in length, occupying almost the middle of the lower surface of the liver, a little nearer to the posterior than to the anterior border, and to the left than to the right extremity. It is bounded on the left by the longitudinal fissure, with which it communicates; to the right of the gall-bladder (*g*), it is prolonged obliquely forward by a deep and narrow cleft. In the transverse fissure we find the vena portæ, or the sinus (*p*) of the vena portæ, the hepatic artery (*a*), the roots of the hepatic duct (*d*), a great number of lymphatic vessels and nerves, and a considerable quantity of cellular tissue. The gastro-hepatic omentum is given off from this fissure. The transverse fissure is situated between two eminences, called by the ancients the pillars of the gate (*portal eminences*). All the peculiarities of the inferior surface of the liver may be referred to these two fissures.

Thus, *to the left of the longitudinal fissure* we observe the inferior surface of the left lobe, slightly concave behind, where it is applied to the lobulus Spigelii, from which it is separated by the gastro-hepatic omentum; concave in front, so as to be adapted to the convexity of the stomach, upon which it is prolonged to a greater or less extent. This relation of the liver with the stomach is of the utmost importance. Thus, when the stomach is distended, it pushes the liver upward and backward in such a manner that its lower surface is directed somewhat forward. In cases of chronic ulceration of the stomach, the tissue of the liver is not unfrequently found supplying the place of the destroyed coats of the stomach, and this to a considerable extent. The lower surface of the left lobe is often in relation with the spleen, which it occasionally covers like a helmet.

To the right of the longitudinal fissure, and in front of the transverse fissure, we find, upon the lower surface of the right lobe, the *fossa for the gall-bladder*, which is more or less deep, oblong, and directed from before backward, upward, and to the left side, like the gall-bladder (*g*) itself, for the reception of which it is intended. This fossa is not always prolonged as far as the anterior border of the liver. Between the fossa of the gall-bladder and the longitudinal fissure is a square surface, the *lobulus quadratus*, *anterior portal eminence*, or *anterior lobule* (4). This surface sometimes terminates behind in a distinct rounded prominence, which justifies the name of eminence applied to it; at other times, on the contrary, this portion of the liver is flattened.

Behind the transverse fissure we find the *posterior portal eminence*, or *small lobe* (*posterior lobule* or *lobule*), also called the *lobulus Spigelii* (3), from the name of the anatomist to whom its discovery has been attributed, although it was described, and even figured before his time by Vesalius, Sylvius, and Eustachius. It varies much, both in size and shape, and is situated between the transverse fissure and the posterior border of the liver, and between the fissure of the ductus venosus (*v*) on the left, and the fissure of the vena cava inferior (*c*) on the right. It is situated to the right of the œsophageal orifice of the stomach, opposite its lesser curvature, by which it is embraced; its form is that of a flattened semilunar tongue, convex upon its lower and free surface, which corresponds to the upper border of the pancreas, and has a projection in the centre, surrounded by an arterial circle, formed by the coronary artery of the stomach with the splenic and hepatic arteries. This projection (above 3) is called by Haller *major colliculus in magnæ papillæ similitudinem;* and by Winslow, *l'éminence triangulaire.* From its posterior extremity a prolongation is given off opposite the posterior border of the liver, which converts the fissure for the vena cava inferior into a canal that is sometimes complete.* A prolongation or ridge (5) (*the right prolongation of the lobule*) passes from its anterior extremity to the right of the transverse fissure, and, proceeding obliquely forward, separates the renal (*r*) from the colic (*o*) depression. This prolongation was minutely described by the older anatomists, and has been termed by Haller the *colliculus caudatus.*† At its junction with the lobule, this prolongation is marked in front by a groove (the *groove of the vena portæ*), sufficiently deep to lodge the vena portæ (*p*) and the hepatic artery (*a*); and it is still more deeply excavated behind for the vena cava inferior (*c*) (*the groove of the vena cava inferior*). Sometimes the right margin of the first-mentioned groove has a papilla similar to that of the lobulus Spigelii; and in this case it might be said that there are two lobes of Spigelius; opposite this groove, the vena portæ is separated from the vena cava only by a very thin lamina.

The lobulus Spigelii presents much variety in its size; but not such as to enable it to be felt through the abdominal parietes, unless the enlargement is the consequence of disease. Physicians who pretend to recognise by the touch obstruction or adhesion of the lobulus Spigelii,‡ are certainly not anatomists.

To the right of the longitudinal fissure, the lower surface of the liver presents, behind,

* [This prolongation did not exist in the liver represented in *fig.* 164.]

† [Now termed the lobulus caudatus.]

‡ Meckel and others consider that there is a right antero-posterior, or longitudinal fissure, formed by the fossa for the gall-bladder and the groove of the vena cava inferior; the latter groove being partly hollowed out of the lobulus Spigelii, and partly out of the contiguous portion of the right lobe, and then prolonged upon the lower surface of the liver.

an excavation of variable depth and extent in different subjects; this is the renal impression (*r*): it corresponds to the kidney, upon which it is exactly moulded, and with which it is loosely united, and also, though more loosely, with the supra-renal capsule. Sometimes the impression for the capsule is distinct from that for the kidney. It may be conceived that this impression must vary according as the liver corresponds to the upper third, to the upper half, or to the whole of the right kidney. This impression is always directed backward.

In front of the renal impression is a slight one, termed the colic depression (*o*), which corresponds with the angle formed by the ascending and transverse colon with part of the transverse colon itself, and sometimes, also, with the first portion of the duodenum.

Behind is the groove for the *vena cava inferior* (*c*), which advances slightly upon the lower surface of the liver, on the inner side of the renal and capsular impression.

The accidental fissures sometimes observed upon the lower surface of the liver are traces of the divisions which exist in a great number of mammalia.

To recapitulate the numerous objects seen upon the lower surface of the liver, we find as follows: the antero-posterior or longitudinal fissure, intersected at right angles by the transverse fissure; on the left of the antero-posterior fissure is the lower surface of the left lobe, presenting the depression for the lobulus Spigelii, the gastric impression, and sometimes the splenic; on the right and in front of the transverse fissure, are the fossa of the gall-bladder, and the anterior portal eminence, or lobulus quadratus; behind the transverse fissure is the posterior portal eminence, or lobulus Spigelii, with its right prolongation or lobulus caudatus, and the groove for the vena portæ; and still more to the right are the renal and colic impressions, and the groove for the inferior vena cava.

The Circumference of the Liver.—The *anterior* border of the liver presents a very thin, and, as it were, sharp edge, which is directed obliquely upward and to the left side, corresponding to the base of the thorax on the right side, and projecting below it, opposite the sub-sternal notch (*fig.* 155). Upon this edge there is invariably found a deep notch (below 2, *fig.* 161) for the umbilical vein; and more to the right another notch, which is often larger than the preceding, and corresponds to the base (*g*) of the gall-bladder. Sometimes there is merely a trace of this notch, and sometimes it is altogether wanting. In some subjects there is only one great notch, common to the gall-bladder and the umbilical vein, and the borders of it are sinuous, or cut into small notches. It is almost always possible, when the parietes of the abdomen are relaxed, to insinuate the fingers between the ribs and the liver.

The *posterior* border of the liver is very thick in all that part which corresponds to the right side, and becomes gradually thinner as it approaches the left extremity. This border, which is short, rounded, and curved, so as to fit the convexity of the vertebral column, adheres intimately to the diaphragm by rather dense cellular tissue. The peritoneum is reflected, both above and below this border, from the diaphragm to the liver, to form what is called the *coronary ligament*. The cellular interval between these two layers of peritoneum is of irregular form, and varies in size. This border is divided into two parts by a deep notch, which forms two thirds or three fourths of a canal for the reception of the inferior vena cava (*c*, *fig.* 164). This notch is converted into a complete canal, sometimes by a sort of fibrous bridge, and sometimes by a prolongation from the posterior extremity of the lobulus Spigelii. In order to comprehend the arrangement of the liver opposite this notch for the vena cava, that vein should be slit open, and we then see at the bottom of a deep notch a large cavity, into which all the hepatic veins (*h h*) open. We observe, also, that the antero-posterior fissure is continuous with the fissure of the vena cava, behind the lobulus Spigelii. This lobule, viewed from behind, appears like a tongue detached from the rest of the liver, by circumscribing fissures and grooves.

On the right side, the liver terminates in a thick, smooth extremity, forming the base of the pyramid, to which this organ has been compared. A triangular fold of peritoneum, called the *right triangular ligament* (*l*), is stretched from the middle of this thick extremity to the diaphragm.

On the left side, the liver terminates in an angular or obtuse tongue, more or less elongated, and sometimes reaching as far as the spleen, to which I have seen it adherent. This prolongation, which is attached to the diaphragm by a triangular fold of peritoneum, called the *left triangular ligament* (3, *fig.* 161; *l*, *fig.* 164), is slightly notched behind for the lower end of the œsophagus, which is bordered by it upon the left side. In one subject I saw this tongue completely separated from the rest of the liver, with the exception of a vascular pedicle about four lines in length. This peculiarity was probably owing to traction exercised by the spleen, to which the prolongation from the liver was intimately adherent.

Colour.—The liver is of a reddish-brown colour, the depth of which varies in different individuals. Its surface, and also sections of it, resemble in appearance a granite composed of two kinds of grains, the one deep brown, the other yellowish; and hence has arisen the distinction between the two substances of the liver. In no tissue in the body is there greater variety in colour than in that of the liver. Independently of the different shades, which it is impossible to describe, the liver is sometimes of a yellowish or

canary-yellow, or a chamois-yellow (hence the name *cirrhosis* given to a particular disease of the liver); or it may be of a more or less deep olive-green hue, or of a slate colour. These differences in colour, which have not, perhaps, been sufficiently investigated, are connected with more or less decided alterations of texture. The chamois-yellow colour almost always indicates the existence of fatty degeneration.

Fragility.—The fragility of the liver is one of the most important particulars in its description. It is *compact* and *fragile*, and cannot, therefore, be forcibly compressed without suffering laceration; hence the danger of contusions in the region of the liver, and the rules laid down by accoucheurs for avoiding all compression of the abdomen of the fœtus during the manipulations required in protracted labours. The fragility and the weight of the liver explain the occurrence of injuries of that organ by contre-coup, after falls from an elevated height. In fatty degeneration of this organ, the liver retains the impression of the finger, and its fragility is in a great measure lost. Olive-green and slate-coloured livers are dense, their molecules are much more closely united, and they are lacerated with difficulty.

Texture.—Before the admirable works of Glisson and Malpighi, anatomists were in the habit of saying, with Erasistratus, that the liver, like all other organs of a complicated structure, was a *parenchyma*; a vague term, intended to imply the effusion of a particular juice around a series of vessels. Malpighi showed, in opposition to the assertion of Warthen, that the liver is a conglomerate gland: he examined the glandular granules (the lobules of Kiernan), which Ruysch subsequently, by means of his beautiful injections, appeared to convert into vessels. Anatomists are still divided between the opinions of these two eminent observers concerning the intimate structure of the liver, as well as of all other glands, some believing it to be granular, others that it is vascular. We have to consider the coverings, and then the proper tissue of the liver.

The Coverings of the Liver.—These are two in number, viz., a peritoneal coat, and a proper fibrous membrane.

The *peritoneal coat* forms an almost complete covering for the liver; the posterior border, the transverse fissure, the groove for the vena cava, and the fossa for the gall-bladder, are the only parts that are destitute of this coat. The peritoneum, from being reflected upon the liver from the diaphragm, constitutes the several folds called the falciform, coronary, and triangular ligaments, of which we have already spoken. By means of this membrane, which is always moist, the liver is enabled to glide upon the adjacent parts without friction. We frequently find cellular adhesions between the liver and surrounding structures, which do not positively impair its functions. The peritoneal coat adheres intimately to the proper membrane.

The *proper* or *fibrous membrane* is very well seen over such portions of the liver as are not covered by the peritoneum, and from these points it can be easily traced over the whole of the remainder of the organ. It constitutes the immediate investment of the liver; its outer surface is adherent to the peritoneal coat, and its inner surface is connected with the tissue of the liver by means of *fibrous prolongations* interposed between the granules (lobules), affording to each a distinct covering.

It passes into and lines the transverse fissure, and is prolonged around the corresponding divisions of the vena portæ, the hepatic artery, and the biliary ducts, so as to form cylindrical sheaths for those groups of vessels, and for all their farther divisions and subdivisions. These sheaths constitute the *capsule of Glisson*, which we must therefore regard as a dependance of the proper fibrous coat. The internal surface of these sheaths is united to the vessels only by a very loose cellular tissue. Their external surface adheres intimately to the tissue of the liver by fibrous prolongations, which interlace in every direction, and form distinct coverings for the deep-seated granules, analogous to those which we have already stated are produced from the proper coat. The liver, therefore, is traversed in all directions by very delicate fibro-cellular prolongations, forming a vast network, in which the granules are contained. This proper coat, moreover, is fibrous,* not muscular, as Glisson believed.

It may be said, with truth, to constitute the skeleton or framework of the liver, for it affords a general covering for the organ; it is prolonged around the vena portæ, the hepatic artery, and the biliary ducts, and it furnishes a fibrous or cellular covering for each of the granules composing the proper tissue of the liver. The fibrous cells thus formed become very distinct in certain cases of hepatic disease. In fact, this fibrous tissue not unfrequently becomes so much hypertrophied, that some of the glandular granules are compressed and atrophied; and then larger or smaller portions of the liver appear to be converted into a reticulated fibrous tissue. The arrangement of the fibrous tissue is also very manifest in cases of softening of the granules, which may then be easily scraped out of their cells, and the surface of the section thus treated presents the appearance of the cells in a honeycomb.

The Proper Tissue of the Liver.—The first thing that strikes an observer in examining the structure of the liver, is the smoothness of its external surface, which does not present any of the lobulated appearance of most other glands. If we attentively examine

* [It is composed of dense cellular or fibro-cellular tissue: for its use, see note, p. 393.]

this surface, either before or after the removal of its coverings, we find that it is most distinctly composed of granules (lobules, *Kiernan*): the same is also rendered evident by making sections of the organ, or by tearing it: the granular arrangement has, it is true, been supposed to be the result of laceration.

From the mottled appearance of the liver (like granite), already noticed, anatomists have admitted the existence of two substances, or, rather, two kinds of granules in this organ, viz., *reddish brown* and *yellow* granules. This distinction was first made by Ferrein (*Hist. Acad. des Sciences*, 1735); it is now generally recognised, and has even served as the basis of several more or less ingenious explanations. This anatomist called the brown substance *medullary*, and the yellow *cortical*, names evidently derived from a rude analogy between them and the medullary and cortical substances of the brain. Others have reversed the meaning of these two words; but that is of little consequence.

"These two substances," says Meckel, "are not arranged as in the brain, one external and the other internal; but alternately throughout the whole liver, the yellow substance forming the mass of the organ, and the brown substance occupying the intervals."

This distinction into two substances does not appear to me to be well founded. The error has arisen from assuming as constant the existence of two colours, which, however, are far from being distinguishable in all subjects. The two colours, yellow and brown, when they do exist, do not belong to two distinct granules, but rather to the same granule, which is yellow in the centre, where the bile is found, and reddish brown at the circumference, where the blood is collected.*

The granules of the human liver are so small, that, excepting when they become considerably enlarged, it is not well adapted for examination. The liver of the pig, in which the granules are naturally very large, appears to me the best suited for this purpose. I have been accustomed to divide the liver in different directions, to slit up and remove the veins which have been cut across, and afterward to examine the granules in the semi-canals (*g g, fig.* 165; *c c, fig.* 166) which they then form. The granules (*l l l*) may thus be separated with the greatest facility; they are small, ovoid, elliptical, or, rather, polyhedral bodies, having five or six surfaces, and shaped so as to be moulded upon the surface of the adjacent granules, without leaving any interval. It is evident, therefore, that there is only one order of granules; that these granules are not arranged in lobules, as stated by Malpighi,† but are merely in juxtaposition; and that each has its proper capsule, formed by prolongations of the fibrous coat. And as these granules can be isolated, and detached from the capsules in which they are merely lodged, without adhering to them, except at the points by which they receive and emit their vessels, it follows that they are independent of each other, and that the most complete alteration of one or more of them may take place, without the adjacent or intermediate granules being in any way affected, or, at least, that such alteration would not be propagated by continuity of tissue.

The size of the granules varies much in different individuals, and is quite independent of the size of the liver itself. Physicians who have paid much attention to pathological anatomy have often mentioned their increased development, by the name of *hepar acinosum*. This disease is characterized by the simultaneous occurrence of atrophy of the entire organ, which is reduced to one half or one third its original size, and of hypertrophy of the granules themselves. In what is called *cirrhosis*, the greater number of the granules are atrophied.‡

The investigation of the structure of the liver is, then, reduced to the determination of the arrangement of the granules with respect to each other, of the mode in which the vessels are arranged, and of the structure of each granule.

1. The *arrangement of the granules*, with regard to each other, is revealed by the following fact: In the disease of the liver called *ramollisement* (*Dict. de Méd. et Chir. Pratiq.*, art. Maladies du Foie), in which that organ is reduced to a sort of pulp, as soon as the investing membranes are torn, the tissue of the liver escapes like a brownish-yellow pulp, which, as it is not fetid, cannot be supposed to be the result of gangrene. If this pulp be placed in water, myriads of small and very distinct yellow granules will be seen, resembling small raisin stones, and appended to the ramifications of the different kinds of vessels by vascular pedicles.

This fact, which I have several times observed, is confirmed by the observations of Harvey, who, in his work upon the generation of animals, says, that the tissue of the liver is formed along the umbilical vessels like a grape on its footstalk, a bud on the end of a twig, or an ear of corn springing from its stalk; and also by reference to compara-

* See note, p. 395.

† [This statement illustrates the confusion that has prevailed from the terms *lobule* and *acinus* having been employed by anatomical writers in different senses to those attached to them by Malpighi; the lobule of Malpighi is, in fact, equivalent to the granule of M. Cruveilhier, and was described by him as consisting of a collection of acini (see note, p. 395).]

‡ The ingenious explanation which has been given of cirrhosis is, then, destitute of foundation. In cirrhosis, as I have shown in another place, there is neither atrophy of the red substance, nor hypertrophy of the yellow, but rather *atrophy* of the greater number of granules, with *hypertrophy* and yellow discoloration of the remainder.

tive anatomy, for M. Blainville has informed me that, in certain species of animals, the liver is formed by rows of glandular granules attached along the vessels.*

2. *The Vessels of the Liver.*—The study of the vessels of the liver is one of the most important points in the history of that organ. Besides the arteries and veins corresponding to those of other parts of the body, the liver receives also a special system of veins, viz., *the system of the vena portæ*, which is distributed in its interior like an artery. It presents also, in the adult, the remains of a venous system peculiar to the fœtus, *the system of the umbilical vein;* and, lastly, it contains canals intended for the conveyance of the bile, named the *biliary ducts.*

The special venous system of the liver, or *the system of the vena portæ*, will be described more particularly in another place. I shall only now observe, that the branches of origin of this system commence in all the abdominal organs concerned in the function of digestion; that the ventral vena portæ, resulting from the union of these branches, reaches the transverse fissure of the liver, and divides there into a right and left branch, which constitute the hepatic vena portæ (*p*, *fig.* 164); and that these branches subdivide and spread into all parts of the liver, some forward and others backward, but all following a transverse direction. The capsule of Glisson, as we have seen, is developed around this vein; so that, in sections of the liver, the branches of the vena portæ can always be recognised by these two characters: a transverse direction, and the presence of the capsule.

Remains of the Umbilical Vein.—We can easily conceive the arrangement of these remains, if we consider that, in the fœtus, the umbilical vein (*u*, *fig.* 164†), proceeds from the placenta to the longitudinal fissure of the liver; and at the point where this is intersected by the transverse fissure, divides into two branches, one of which, under the name of the ductus venosus (*d*), passes directly to the vena cava (*c*), at the point where it traverses the posterior border of the liver; while the other is continuous with the hepatic vena portæ (*p*), which, as we have seen, occupies the transverse fissure. The portion common to the umbilical and portal veins remains pervious in the adult; but it then belongs exclusively to the vena portæ. The ductus venosus then becomes a mere fibrous cord (*v*, *fig.* 164†), as well as the trunk of the umbilical vein itself (*u*). It is not rare to find the trunk of the umbilical vein persistent in the adult, from an abnormal communication between it and the veins of the abdominal parietes. (See *Anat. Path.* avec planches, liv. xvii., pl. 6.) No example has been recorded of a persistent ductus venosus.

Fig. 164.†

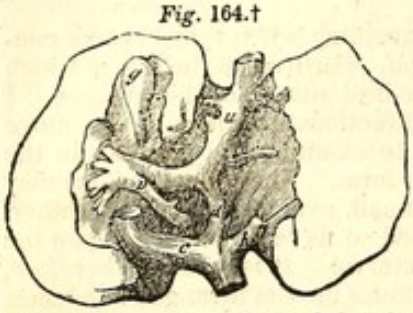

Arteries.—The hepatic artery is a branch of the cœliac axis (*t*, *fig.* 154), which also furnishes branches to the spleen and the stomach; and although a difference in the origin of an artery dose not occasion any difference in the blood within it, yet this community of origin is not the less remarkable, for it seems to denote a community, a coincidence, or a connexion of function. Moreover, as the nervous plexuses are supported upon the arteries, it follows that the nerves of the spleen, stomach, and liver, are derived from a common plexus, the cœliac. We frequently find a second hepatic artery arising from the superior mesenteric.

I must not omit to mention the smallness of the hepatic artery in comparison with the size and mass of the liver. In this respect few organs present so great a disproportion: compare, for example, the kidney and the renal artery, look at the muscles, and I may almost say at the bones. The small caliber of the hepatic artery enables us to determine *à priori*, that it cannot serve both for the nutrition of the organ and for the secretion of the bile. Lastly, it exactly follows the ramifications of the vena portæ and the biliary ducts, and the capsule of Glisson is common to it and to those two sets of vessels.

The Hepatic Veins.—The hepatic veins, the efferent vessels of the liver, are not pro portional to the size of the hepatic artery, but to that of the vena portæ. Proceeding from all points of the liver, and converging towards the fissure of the vena cava, the hepatic veins (*h h'*, *fig.* 164) empty themselves into that vein (*c*), especially near the posterior border of the liver. It follows, therefore, that the direction of the hepatic veins and of their divisions is from before backward, while that of the divisions of the vena portæ is transverse.† This direction, and the absence of the capsule of Glisson, on ac-

* *Arrangement of the Lobules.*—[According to M. Kiernan, from whose paper in the *Phil. Trans.* for 1833 this and the succeeding notes on the structure of the liver are derived, the lobules (granules, *Cruveilhier*) of the human liver are many sided bodies, flattened on one surface, called the base, and forming processes in every other direction; hence, in a longitudinal section they present a foliated, and in a transverse section a polyhedral form. The bases of all the lobules (*c c*, *fig.* 166) rest on certain branches of the hepatic vein, called *sub*-lobular veins (*h h*); while their other surfaces, surrounded by the capsular investments, are either in contact with those of the adjacent lobules, or appear on the outer surface of the liver, or in the portal canals (*g g*, *fig.* 165), which contain the vena portæ, hepatic artery, and hepatic duct, or in those for the larger trunks (*h*, *fig.* 166) of the hepatic vein. The intervals between the sides of the lobules are the inter-lobular *fissures*, and the points at which two or more of these meet are the inter-lobular *spaces*. The superficial lobules are imperfect, or more or less flattened on their exposed side.]

† At least in the principal trunks; for there are a great number of ramifications of the hepatic veins which pass transversely.

count of which the walls of these veins are directly adherent to the tissue of the liver, so that the veins themselves remain patent, while the sections of the vena portæ collapse, are the two characters by which the divisions of the hepatic veins may be distinguished from those of the vena portæ, on simply inspecting a section of the liver. Do these anatomical differences between the two kinds of veins produce any difference in the mechanism of the circulation through them? And is the want of immediate connexion of the divisions of the vena portæ to the tissue of the liver intended to permit them to contract so as to propel the blood? If we consider that the blood of the vena portæ proceeds from the trunk towards the branches, as in the arteries, we may conceive the advantages which must result from an anatomical arrangement that would allow these vessels to exert a direct pressure upon the blood.

Another point of difference between the branches of the hepatic vein and of the vena portæ is, that the walls of the former are perforated by a multitude of extremely small openings or pores, which are the orifices of very small veins.

The Lymphatic Vessels.—The lymphatics of the liver are so numerous that these vessels were first discovered in that organ; indeed, it was for a long time regarded as the origin of the lymphatic system, just as it had been originally considered the origin of the veins. The lymphatics of the liver form a *superficial* and a *deep* set. The superficial lymphatics are arranged in an extremely close network under the peritoneal coat. The deep set, which are very large and numerous, pass out of the transverse fissure of the liver, and terminate partly in lymphatic glands situated along the hepatic vessels, and partly in the lumbar glands. They communicate directly and freely with the thoracic duct, so that one of the best methods of injecting this duct consists in throwing the injection into the lymphatics of the liver.

The Nerves.—These are very small, considering the size of the liver. They are derived from two sources, the cerebro-spinal and the ganglionic systems. The former are branches of the pneumogastric nerves; the latter constitute the hepatic plexus, which is an offset from the solar plexus. They are interlaced around the hepatic artery: some of these nerves, however, by a special exception, accompany the vena portæ. It is generally admitted that a few filaments of the phrenic nerve are given to the liver.

The Biliary Ducts.—Whatever may be the origin of the biliary ducts, their radicles, however small they may be, are always found in the capsule of Glisson, together with the corresponding branches of the vena portæ and hepatic artery. These radicles are united like veins into smaller, and these into larger branches, which, at length, constitute the *hepatic duct* (*d*, *fig.* 164). They can be readily distinguished from the other vascular canals of the liver by their yellowish colour, by the fluid which they contain, and by the appearance of their parietes.*

Fig. 165.

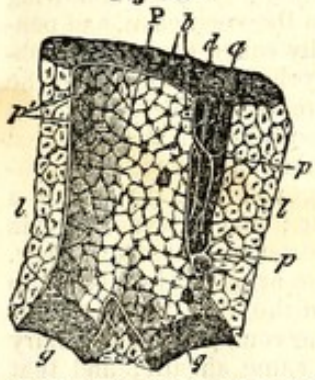

* *Vessels.*—[The first divisions of the vena portæ, hepatic artery, and hepatic duct, are situated in the portal canals, which are tubular passages formed in the tissue of the liver, commencing at the transverse fissure, and branching through the substance of the organ. The smallest divisions of the portal canals contain one principal branch of each of these vessels (P *a d*, *fig.* 165): from these proceed smaller branches, called vaginal, from their situation within the capsule of Glisson.

In the larger canals, the *vaginal veins* (*p'*) form a plexus in the substance of the capsule, and then give off the *inter*-lobular veins (*p p*), which pass between the lobules opposite the inter-lobular spaces, ramify in the inter-lobular fissures (*p p*, *fig.* 167), and, after freely anastomosing upon the capsular surfaces of the lobules, divide into branches, which penetrate the lobules themselves. In the smaller portal canals, the vaginal venous plexuses are less apparent, for many of the inter-lobular veins (*b*) arise at once from the principal branch of the vena portæ: where this occurs, the capsule of Glisson is very thin; and, indeed, the chief use of this structure, in other situations, appears to be to form a web, on which the vessels may ramify, so as to enter the liver at a great number of points, a use analogous to that of the pia mater and periosteum, in reference to the brain and bones.

Fig. 166.

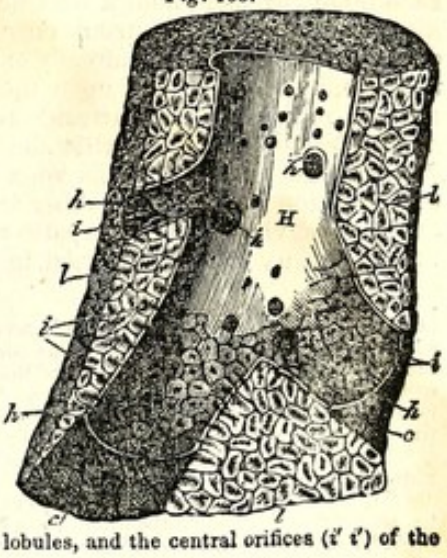

The hepatic artery also forms *vaginal* plexuses in the portal canals, which give off *inter-lobular* branches; from these vessels the proper capsule of the liver, the capsule of Glisson, the capsules of the lobules, and the coats of the different vessels, derive their nutrient arteries, which terminate in veins that enter the vena portæ. But few arterial branches enter the lobules themselves.

The hepatic duct, also, has its *vaginal* branches, but it is doubtful whether they anastomose; they are formed by the union of the inter-lobular branches (*d d*, *fig.* 168), which do appear to anastomose, and are derived from the biliary ducts, which pass out at the surface of the lobules.

The several divisions of the hepatic veins are termed the hepatic venous trunks, the *sub*-lobular veins, and the *intra*-lobular veins. The *intra*-lobular veins (*i*, *fig.* 166; *h*, *fig.* 167), of which but *one*, independent of the rest, emerges from the centre of the base of each lobule, open into the sub-lobular veins (*h h*), through the thin walls of which can be seen the polyhedral bases of the lobules, and the central orifices (*i' i'*) of the

3. What is the *structure* of the *granules?* In examining a section of the liver of a pig with the simple microscope, I have seen most distinctly that each granule has a porous and spongy appearance, like the pith of the rush or elder, so that the proper tissue of the liver resembles a sort of filter. This appearance was much more distinct in livers which I had injected with walnut oil, either pure or coloured blue. The colouring matter thrown into the vena portæ was, as it were, infiltrated into the spongy tissue of the liver.

If we endeavour to ascertain the structure of the liver by means of injections, we shall see what was observed by Sœmmering, that whichever vessel be injected, whether the hepatic artery, the duct, the vena portæ, or the hepatic vein (provided only the injection be thin, as, for example, coloured glue, size, or spirits of turpentine, or, better still, a strong aqueous solution of gamboge), there will not be a single granule into which the injection will not have penetrated; and, moreover, that the liquid thrown into one vessel will pass either into one, two, or all three of the others; and the facility with which this takes place proves that the different orders of vessels communicate with each other directly, and not through the medium of cells or small cavities.*

In a fœtus, or an infant that has died immediately after birth, an injection through the umbilical vein gives similar results. I have never been able to force the liquid into the lymphatic vessels, at least without rupturing the tissue of the liver. Air driven into the vessels penetrates more easily than liquids into the lymphatics, no doubt on account of its greater subtilty.

It follows, then, that in each granule there is an arterial radicle, a radicle of the vena portæ, one of the hepatic vein, and one of the duct, probably some lymphatic vessels, and a nervous filament. The aggregate has been represented by Sœmmering as having some resemblance to the arrangement of a Damask rose.† All the different vessels communicate freely with each other.‡

The manner in which these different vessels are arranged in each granule can only be discovered by injecting them simultaneously, or, rather, successively, for it is nearly impossible to inject all the vessels of the liver at the same time. I have accordingly injected the vessels in the following order: the vena cava, and, consequently, the hepatic veins, with wax coloured with Prussian blue—a certain quantity of walnut oil, also containing Prussian blue, had been previously thrown into the same vein; the vena portæ with a red injection; the hepatic artery with the same; and then the hepatic duct with a yellow injection. These injections were made in the liver of a pig, the liver being placed in warm water, and the injections pushed in with a gradually-increasing force. During the injection of the vena cava and vena portæ, the wrinkles of the liver disappeared, and the central depressions of the superficial granules became, on the contrary, slightly prominent. It was therefore evident that each granule was hollow, and that the space had been filled by the injected matter.

The liver thus injected and submitted to different chemical agents gave the following results: The blue injection, or that which had been thrown into the vena cava, had penetrated into the central part of each granule, which is generally called the yellow substance of the liver. In the middle of the central part was the yellow injection from the hepatic duct. Around the blue injection was found that coloured red, which had been forced into the vena portæ and the hepatic artery, and which occupied all the so-called red substance of the liver. It follows, therefore, that each granule had a vascular apparatus thus arranged: in the centre, a biliary duct; farther removed from the centre, a vascular circle formed by the ramifications of the hepatic vein; and external to this another vascular circle, formed by ramifications of the vena portæ and hepatic artery. As to the manner in which the vena portæ and hepatic artery are arranged in relation to each other, we shall find, if we trace them into the substance of the liver, that the ramifications of the hepatic artery correspond exactly to those of the vena portæ and biliary duct, which, as we have already said, are all contained in the same sheath; and that they ramify and are lost upon the parietes of the vein and duct, almost in the same manner as the bronchial arteries are distributed upon the divisions of the air tubes. I must, therefore, conclude that the hepatic artery furnishes for the liver the nutritious vessels (*vasa vasorum*) of the vena portæ and hepatic ducts; and this will explain the disproportion between its caliber and the size of the liver.

The subdivisions of the hepatic veins, which follow a separate course, present a similar peculiarity to that observed in the splenic vein, viz., a multitude of pores or holes,

inter-lobular veins. This appearance is peculiar to the sub-lobular veins, the canals for which alone are formed by the bases (*c c*) of the lobules. The portal canals (*g, fig.* 165) are formed by their capsular surfaces, and the openings (*b*), seen in the interior of the small divisions of the vena portæ, correspond to the inter-lobular spaces, not to the centres of the lobules. The sub-lobular veins anastomose with each other (this the divisions of the vena portæ never do), and unite to form the hepatic venous trunks (*H, fig.* 166), into which no intra-lobular veins open, nor do the bases of any lobules rest upon them.]

* [From this statement the ducts must be excepted; they do not communicate with the bloodvessels.—(See note, p. 395.)]

† "Quilibet acinus hepatis e glomeroso constat, vel e particulis arteriæ, venæ portarum, venæ hepaticæ, ductus biliferi et vasorum absorbentium, cujus formam rosæ sic dictæ Damascenæ imaginem pingere nobis licet."—(*Corp. Hum. Fab.*, t. vi., p. 180.)

‡ See note, p. 395.

by which very small veins open directly into them. Their ramifications are much less numerous than those of the vena portæ.

The result of the injections described above also explains the difference in colour between the centre and the circumference of each granule; it shows, moreover, that one part of the granule is impermeable to injections; and its spongy nature, resembling that of the pith of the rush or elder, is apparent even to the naked eye, in a section of a liver thus injected, when viewed by a strong light.

To resume, then, it may be said that the liver is composed of ovoid, elliptical, or, rather, polyhedral granules, moulded closely upon each other. Each granule has its proper fibrous capsule; and all the capsules are united together by prolongations, which also connect them with the general cellular investment of the liver, and with that extension of it called the capsule of Glisson. The granules are independent of each other. Each of them consists of a spongy tissue, impermeable to injections; of a biliary duct proceeding from its centre; of a venous network formed by the hepatic veins; of another venous network belonging to the vena portæ; and of a very delicate arterial network derived from the hepatic artery, which is ramified upon the parietes of the vena portæ and biliary ducts. Such is the structure of the liver.* It remains for me now to examine its excretory apparatus.

The Excretory Apparatus of the Liver.

The excretory apparatus of the liver consists of the hepatic duct, of the cystic duct, of the gall-bladder, and of the ductus communis choledochus.

The *hepato-cystic* canals,† admitted by some authors as constant or occasional in man, can be easily shown in the lower animals, but do not exist in the human species.

The Hepatic Duct.—The hepatic duct arises in the granules of the liver by *hepatic radicles*,‡ which, by uniting successively like veins, constitute small and then larger branches. These latter all converge towards the transverse fissure of the liver, where they terminate ultimately in two trunks of almost equal size, which join each other at a very obtuse angle, and form the hepatic duct (*d*, *fig.* 164). The condition of the branches of the hepatic duct in the transverse fissure is extremely variable: thus, sometimes the trunk of the right side is larger than that of the left, and sometimes the opposite is the case. Frequently several branches join the trunks late in the transverse fissure; but, whatever be the nature of these variations, the right trunk never corresponds exactly to the right lobe of the liver, nor the left to the left lobe.

All the divisions and subdivisions of the hepatic duct◊ are contained in the capsule of Glisson, together with the ramifications of the vena portæ and hepatic artery, to which

* *Structure of the Lobules.*—[It appears from the preceding note, that while several branches of the vena portæ and hepatic artery enter, and several of those of the hepatic duct pass out at the capsular surface of each lobule, only a single branch of the hepatic vein emerges from its base; within the lobules, the following is the arrangement of these vessels:

The branches from the inter-lobular (portal) veins (`p p p, *fig.* 167) form in the outer portion of each lobule a venous plexus (*l l*), consisting of branches radiating towards the centre, connected by others passing transversely; these veins become capillary, ramify upon the biliary ducts, and terminating in the branches of the intra-lobular (hepatic) vein (*h*), which correspond in number with the processes on the surface of the lobule, ultimately unite to form the central vein that passes out at its base.

Fig. 167.

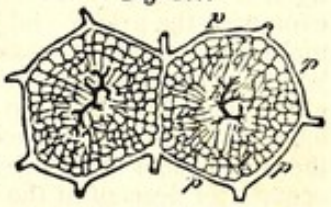

The lobular arteries are few in number, and, according to Kiernan, end in branches of the vena portæ, and not directly in those of the hepatic vein. Müller inclines to the more commonly received opinion, that the three kinds of bloodvessels communicate with each other. No communication, however, exists, as stated by M. Cruveilhier, between the bloodvessels and the biliary ducts, which, like the ducts of other glands, are an independent system of vessels. According to Mr. Kiernan, the ducts form a reticulated plexus, occupying principally the outer portion of each lobule (as shown at *b b*, *fig.* 168, which is a diagram copied from Mr. Kiernan's paper). Müller expresses doubts as to the anastomosis of the ducts, and thinks it probable, from analogical observation, that they terminate in tufts of tubes having blind extremities.

Fig. 168.

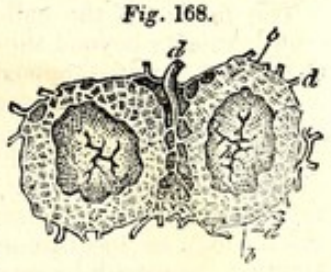

The islets formed between the radiating and transverse branches of the lobular (portal) veins (*l*, *fig.* 167) correspond to the acini of Malpighi, and contain the biliary ducts with their capillary bloodvessels, and also a peculiar tissue, which occupies all the intervals between the several kinds of vessels, and consists, according to Krause, of hexagonal, nucleated cells, having several bright points in them, like globules of oily matter.

The appearance of two substances in the liver can now be explained; it does not depend on the biliary ducts being situated in the centre, and the veins nearer to the circumference of each lobule (see p. 391, 394), but in a partial congestion of either the portal or hepatic system of veins.

In portal congestion, the margins of the lobules are dark, and their centres pale; it is very rare, and has been seen only in children.

Of hepatic venous congestion there are two stages: in the first, the centre of each lobule is dark, and the margin pale (*fig.* 166); it constitutes passive congestion, and is the common state of the liver after death: in the second, the congestion extends to the portal veins in the inter-lobular *fissures*, but not to those in the inter-lobular *spaces*, or points at which those fissures meet, which spaces are then seen to occupy the centre of each pale isolated spot: this is active congestion of the liver; it occurs in diseases of the heart, and in acute diseases of the lungs and pleura.]

† [*I. e.*, canals passing directly from the liver into the gall-bladder.]

‡ See note, *suprà*.

◊ [Excepting those within the lobules.]

they are connected by loose cellular tissue. The trunks of the hepatic duct lie at the bottom of the transverse fissure, and are hid by the trunk of the vena portæ and the branches of the hepatic artery. The hepatic duct (*t*, *fig.* 169), thus formed by the union of the two trunks which occupy the transverse fissure, passes downward and to the right side for about an inch and a half, and then unites at a very acute angle with the cystic duct (*s*), to form the ductus communis choledochus (*c*; and *x*, *fig.* 154). In this course the duct is contained in the gastro-hepatic omentum, together with the vena portæ, which is behind it, and the right branch of the hepatic artery, which is in front of it. A great quantity of loose cellular tissue unites the duct to these vessels.

The Gall-Bladder. Dissection.—A gall-bladder filled with bile may be studied without any preparation: if it is empty it must be distended, either with a fluid or with air. A beautiful preparation of the gall-bladder may be made for preservation by drying it after inflation, or by filling it with fat, which is afterward removed by oil of turpentine.

The gall-bladder (*cystis fellea*, *g*, *fig.* 164) is the reservoir of the bile. It is situated at the lower surface of the right lobe of the liver, occupying a particular fossa (the fossa of the gall-bladder) on the right of the longitudinal fissure, from which it is separated by the lobulus quadratus. It is held in this place by the peritoneum, which, in the majority of instances, merely passes below it, but, in others, almost entirely invests it, and thus attaches it to the liver by a sort of mesentery. In this latter case it is at some distance from the liver, as in certain animals.

Its *form* is that of a pear, or of a cone with a rounded base; it is directed obliquely, so that its great extremity (*g*, *figs.* 155, 161) looks forward, downward, and to the right; and its small extremity, backward, upward, and to the left side.

Size.—The small size of the gall-bladder corresponds with that of the rest of the excretory apparatus of the bile, and is strongly contrasted with the great bulk of the liver. This difference becomes still more striking if we compare, on the one hand, the kidney with the liver, and, on the other, the urinary bladder with the gall-bladder. It is true, however, that all the urine must pass through the former, while a part only of the bile is deposited in the latter.

The size of the gall-bladder, however, is subject to considerable variety; it sometimes acquires three, four, or even ten times its usual size from retention of the bile, in consequence of obstruction in the ductus choledochus.* Cases have been recorded in which it contained six, eight, or ten pounds of bile, but this I can scarcely credit. On the other hand, it is sometimes closely contracted round a small calculus, while the cystic duct is completely obliterated, and reduced to a fibrous cord. It must undoubtedly have been such cases as these that have been regarded as examples of congenital absence of the gall-bladder.

Relations.—In order to facilitate our description, we shall consider the gall-bladder as consisting of a *body*, a *fundus*, and a *neck*.

The *body* is conical, and has the following relations: *below*, where it is covered by the peritoneum, it is in relation with the first portion of the duodenum, and the right extremity of the arch of the colon. It is not unfrequently found in contact with the pylorus, or even with the pyloric end of the stomach. Sometimes it is united by accidental or normal adhesions to the duodenum and arch of the colon. These relations account for the yellow or green discoloration which always takes place after death in those parts of the alimentary canal that are in contact with the gall-bladder; and also for the passage of biliary calculi into the duodenum, the colon, and the stomach. It is not very rare to find the gall-bladder applied by its whole length to the right kidney: this relation can only occur after descent of the duodenum and transverse colon. *Above*, the body of the gall-bladder adheres to the cystic fossa by a more or less loose cellular tissue,† and by arteries and veins, but never in the human subject by biliary, *i. e.*, hepato-cystic, ducts.

The *fundus* of the gall-bladder (*g*, *fig.* 161), entirely covered by the peritoneum, generally projects beyond the anterior margin of the liver, and comes into relation with the abdominal parietes, opposite the outer border of the right rectus muscle, immediately below the costal cartilages near the anterior extremity of the tenth rib. When distended with bile or calculi, the fundus of the gall-bladder becomes prominent, so as to raise the abdominal parietes, through which it has been felt in emaciated individuals. It has even been stated that the noise made by the calculi may be heard on percussion. This relation explains the possibility of the occurrence of abdominal biliary fistulæ, and why calculi may escape through such openings: on it, also, is founded the scheme for extracting the calculi by an operation analogous to that performed for stone in the urinary bladder, and which I should not have mentioned had it not been proposed by J. L. Petit.

The relations, as well as the size of the fundus of the gall-bladder, present many vari-

* Another cause of enlargement of the gall-bladder is the obstruction of its neck by a calculus; but, instead of bile, it then contains a limpid serum, and, in fact, is converted into a serous cyst. The tumour thus formed may be compared to the lachrymal tumour in cases of obstruction of the lachrymal puncta or canals.

† This cellular tissue may become inflamed, and, if pus be formed, it may pass into the gall-bladder, while the bile escapes into the cellular tissue, and hence death may ensue. I have observed, in a very short space of time, three examples of this lesion, which, perhaps, has not been thoroughly examined: and several cases have been shown me under the name of gangrene of the gall-bladder.

eties. The fundus, or that part which projects beyond the liver, is sometimes as large as the body. I have seen this part of the gall-bladder turned back at a right angle upon its body, and reaching the umbilicus. It may be conceived, that the differences in the form and situation of the liver must greatly influence the situation of the fundus of the gall-bladder, which I have found in the hypogastrium and in the right iliac fossa, either with or without adhesion to the neighbouring parts.

The *neck* or apex of the gall-bladder is twice bent suddenly upon itself, like an italic *S*, having its three portions in contact. It would appear, in some cases, that these two curves resemble the thread of a screw. This double curvature may be easily effaced by removing the peritoneum with the subjacent cellular tissue. The limits between the neck and the body of the gall-bladder on the one hand, and between the neck and the cystic duct on the other, are marked externally by a constriction.

The *internal surface of the gall-bladder* is tinged either green or yellow, according to the colour of the bile; but this staining is the effect of transudation after death; its natural colour is a whitish gray. Moreover, the internal surface is irregular, like shagreen, and has some crests or prominences arranged upon it in polygons, and again subdivided by smaller crests, like the reticulum in the stomach of ruminantia; so that, when examined by a strong lens, it appears divided into a number of small and very distinct alveoli: some highly-developed papillæ or villi, of a very irregular shape, are also found upon it. As to the object of either the crests or the papillæ, or whether they favour absorption by multiplying the surface, we are altogether unable to decide.

Opposite each of the two curves of the *S*, described by the neck of the gall-bladder, we find a very large valve. The two valves, which are in opposite directions, as well as the curves, result from the alternate inflection of the neck itself, and are effaced by straightening that part. The portion of the neck between the two valves is not unfrequently dilated into an ampulla. A calculus is often formed in this intermediate portion, where it remains, as it were, encysted, and intercepts the course of the bile; and that the more easily, because the valves greatly contract the openings from the neck into the body of the bladder, and into the cystic duct. Moreover, these valves are opposed neither to the entrance of the bile into, nor to its exit from, the bladder.

Structure.—Proceeding from without inward, we find that the gall-bladder is composed of, 1. A *peritoneal* coat, which is reflected from the lower surface of the liver upon the bladder, completely invests its fundus, forms a more or less incomplete covering for its body and neck, and is continuous with the anterior layer of the gastro-hepatic omentum. 2. An areolar *fibrous coat*, which forms, as it were, the framework of the bladder, and prevents its sudden distension, though it will yield to a long-continued distending force; but I have not been able to see the muscular fibres admitted by some authors, and which can be so easily demonstrated in the larger animals, the ox in particular. 3. An *internal mucous membrane*, the principal characters of which I have noticed when speaking of the internal surface of the gall-bladder: it presents some folds, which may be easily distinguished from the borders of the alveoli, because they are readily effaced by distension. After the most attentive examination, I have been unable to recognise any crypts or follicles.

The gall-bladder receives one very considerable artery, the *cystic branch* of the hepatic. The *cystic vein* terminates in the vena portæ. The lymphatic vessels are very numerous, and easily demonstrated; they are sometimes tinged by the colouring matter of the bile. Its nerves are derived from the hepatic plexus.

The Cystic Duct.—The cystic duct (*s*, *fig.* 169), or excretory duct for the bile, is the smallest of all the biliary canals: it is not uncommon, however, to find it of an equal or even larger size than the others, in which case there has always been some obstacle to the flow of the bile through the ductus communis choledochus (*c*). It commences at the neck of the gall-bladder, passes downward and to the left side for about an inch, and unites at a very acute angle with the hepatic duct (*t*).

It is not straight, but inflected, and, as it were, sinuous.

Relations.—It is situated in the substance of the gastro-hepatic omentum, in front of the vena cava, the cystic artery being on its left side. Its *internal surface* is remarkable for its *valves*, which are indefinite in number; according to Sœmmering, there are from nine to twenty, but this appears to me to be an exaggeration: I have counted from five to twelve. These valves are concave at their free margins, irregular, alternate, oblique, transverse, sometimes even vertical, and united together by small oblique valves. In order to understand their structure, a cystic duct must be examined under water, or, rather, an inflated and dried specimen. This alternate arrangement of the valves sometimes gives a spiral appearance to the inner surface of the cystic duct.* These valves, which only exist in man, perhaps on account of the erect position peculiar to him, are not effaced, like the valves in the neck of the gall-bladder, by such dissection as will allow of straightening of the duct. Small calculi are occasionally met with in the intervals between the valves, giving to the cystic duct a nodulated appearance, and intercepting the flow of the bile. Moreover, the valves of the cystic duct are not more opposed to the descent than to the ascent of the bile. It is even probable that they facilitate the

* "Quæ possint aliquam spiralis fabricæ imaginem ferre."—(*Haller*, tom. vi., liv. xxiii., p. 530.)

ascent of the bile into the gall-bladder by supporting the column of liquid, like the valves of the veins. Perhaps they are also intended to retard the course of the bile from the gall-bladder towards the ductus choledochus. From their appearing sometimes to have a spiral arrangement, M. Amussat has advanced a very ingenious opinion: that the ascent of the bile is effected by a contrivance like an Archimedes' screw. But an Archimedes' screw only causes the ascent of a liquid when a rotatory movement is communicated to it, and how can such a movement be performed by the cystic duct?*

The Ductus Communis Choledochus.—The ductus communis choledochus (χολὴ, bile, δοχὸς, containing; *c*, *c*, *fig.* 169), the last excretory canal of the bile, seems to be formed by the union of the hepatic (*t*) and the cystic ducts (*s*). Another, and, perhaps, more simple manner of viewing the excretory canals of the liver, would be to consider the hepatic duct as giving off to the right, after a certain course, the cystic duct, which, after passing backward, dilates into an oval ampulla to form the gall-bladder; and the ductus choledochus as nothing more than the continuation of the hepatic duct.

Fig. 169.

The *direction* of the ductus choledochus is, in fact, the same as that of the hepatic duct, *i. e.*, obliquely downward, a little to the right, and backward: there is no line of demarcation between these two ducts: in the natural state there is no marked difference in their diameters: the ductus choledochus, when collapsed, is about as large as a moderately-sized goosequill. The same causes give rise to dilatation of the ductus choledochus and of the hepatic duct. I have seen the former as large as the duodenum. (*Anat. Pathol.* avec planches.) Its *length* is from two to two inches and a half.

Relations.—In the first part of its course, before it reaches the duodenum, the ductus choledechus is included in the gastro-hepatic omentum, in front of the vena portæ, and below the hepatic artery, having the right gastro-epiploic artery along its left side, and surrounded by loose cellular tissue, a great number of lymphatic vessels, and several lymphatic glands. Having reached the duodenum, opposite the first flexure of that intestine, it passes behind and to the inner side of its second portion, and is there received into a groove, or, more commonly, into a complete canal, formed for it by the pancreas.

Lastly, it penetrates very obliquely into the substance of the duodenum, about the middle of its second or vertical portion, perforates the muscular coat, passes between that and the fibrous coat, then between the fibrous coat and the mucous membrane, elevating the latter when distended with bile or by a probe, and after a course of about seven or eight lines between the coats, opens into the duodenum, about the lower part of the second portion, at the summit of a nipple-like eminence (above *e'*), which is more or less prominent in different subjects.

In this third portion of its course the ductus choledochus is in relation with the pancreatic duct (*u*), which is situated on its left. Opposite the base of the eminence abovementioned, the two ducts unite, or, rather, the pancreatic duct opens into the ductus choledochus; so that, at its termination, the latter may be regarded as a canal having a triple origin, viz., an hepatic, a cystic, and a pancreatic.†

Internal Surface of the Ductus Hepaticus and Ductus Choledochus.—The internal surface of both the hepatic duct and the ductus choledochus is characterized by the absence of valves, though traces of valves are occasionally met with in the ductus choledochus; by the absence of the alveolar structure observed in the gall-bladder; and by having a multitude of openings or well-marked pores, which are considered as belonging to muciparous follicles, and are apparently formed by an interlacement of fasciculi, having a fibrous character, and intersecting each other at very acute angles. The ductus choledochus and the hepatic duct are of uniform caliber throughout their whole length. The ductus choledochus is contracted a little in its third or duodenal portion; it dilates into an olive-shaped ampulla, opposite the base of the papilla in the duodenum, and opens by an extremely small orifice or mouth: hence the reason why biliary calculi are so frequently arrested in the ampulla of the ductus choledochus.

From the narrowness of the duodenal orifice of the ductus choledochus, from the mo-

* Another opinion, founded upon the existence of the valves, is that of Bachius, who, believing that he had shown that the valves prevent the ascent of the bile from the hepatic duct into the gall-bladder, has advanced very singular views concerning the formation and uses of the bile. The bile, according to him, is formed in the gall-bladder, and carried by the cystic duct into the hepatic duct and the ductus choledochus. By his theory, the bile which reaches the liver through the hepatic duct assists greatly in sanguification. This opinion, altogether erroneous as it is, has perhaps exercised a great influence in science, by contributing to eradicate the idea of the bile being an acrid, corrosive, and essentially injurious excrementitial fluid.

† Hence the definition of Sœmmering: "*Ductus choledochus, id est, ductus hepaticus, cysticus, et pancreaticus, in unum conflati.*"—(*Corpor. Hum. Fabric.*, tom. vi., p. 186.)

vable or yielding nature of the eminence upon which it opens, and from the oblique course of the duct through the substance of the walls of the duodenum, it follows that the bile and the pancreatic fluid may pass freely from the ductus choledochus into the duodenum, but cannot regurgitate from the duodenum into the duct. On this subject I have made several experiments. I have forcibly injected both water and air into the duodenum, included between two ligatures, but nothing entered into the biliary canals: on the other hand, I have injected the same fluids from the gall-bladder into the duodenum, which I was thus able to distend at pleasure. But then, on compressing the bowel thus distended with great force, I have never been able to cause the slightest reflux into the biliary canals.*

At the union of the cystic and hepatic ducts there is a very long spur-shaped process, formed by the lining membrane reflected upon itself. At the junction of the ductus choledochus and the pancreatic duct there is also a similar process, which I have seen extending down to the duodenal orifice. In neither situation do these processes prevent the fluid of one canal from passing into the other. Thus, the cystic bile might flow back into the hepatic duct, the pancreatic fluid might regurgitate into the ductus choledochus, and, on the other hand, the bile might enter the pancreatic duct, if these canals were not habitually full. Moreover, the spur-shaped process between the ductus choledochus and the pancreatic canal cannot arrest the flow, either of the bile or the pancreatic fluid, by being applied to the orifice of the one or other duct.

Structure of the Biliary Ducts.—All the biliary ducts have a similar structure: they have an internal *mucous* membrane, continuous on the one hand with the lining membrane of the gall-bladder, and on the other with that of the duodenum; it is thin, and provided with slightly-developed papillæ;† a *proper membrane*, composed of a dense areolar tissue, generally regarded as fibrous, but which appears to me analogous to the tissue of the dartos condensed; a cellular layer connecting these canals to the surrounding parts; and, lastly, the peritoneum, which forms a very incomplete accessory tunic for them.

Thus constituted, the biliary ducts have very thin walls, so that they collapse like veins, and are extremely dilatable. In certain cases of retention of the bile we find the ductus choledochus and the hepatic duct as large as the duodenum, the divisions of the hepatic duct dilated in proportion, and the tissue of the liver more or less atrophied by the compression to which it has been subjected.

Development of the Liver.—The development of the liver is one of the most important subjects in its history. Under this head we have several points to consider:

1. The *time of its appearance* is anterior to that of any other organ:‡ in the first days of intra-uterine life it may be distinguished by its colour in the midst of the cellular mass which represents the fœtus.

2. In *size* the liver is relatively larger as it is examined at an earlier period of development. Thus, according to Walter, in the embryo of three weeks it forms one half the weight of the whole body. This enormous proportion is maintained during the first half of intra-uterine life. After this period its growth is slower, while that of the other organs is proportionally increased, so that at birth the weight of the liver is one eighteenth that of the whole body.◊ After birth the liver undergoes an absolute diminution; some authors have even affirmed that a comparison of the weight of the liver in new-born infants and in children of nine or ten months old, gives a difference of one fourth in favour of the former. It is generally said that the difference in size affects the left rather than the right lobe; but this has not appeared evident to me. Towards the age of puberty the liver has the same relative bulk as at later periods. Attempts have been made to ascertain the proportion between the weight of this organ and that of the body, and it has been said that it forms one thirty-sixth part of the whole body. But what relation can be established between two terms, one of which, viz., the weight of the body, is subject to continual variations? In old age the liver is smaller than in the adult, a diminution apparently in unison with that which occurs in all the other organs.

3. The *differences in the situation* of the liver are connected with its variations in size: thus, in the first half of intra-uterine life, the liver occupies the greatest part of the abdomen, and is in relation with certain regions in which it is not found at more advanced stages. In the earliest periods it descends as low as the crest of the ilium, and when the abdomen is opened it presents the appearance of a red mass, beneath which are

* How can this fact be reconciled with another no less incontestable, viz., the passage of lumbrici into the biliary ducts? The reason is, that the lumbricus is a foreign body, which has a power of selection, and is able to overcome an obstacle, to seek for the orifice of the ductus choledochus, and to introduce itself within it.

† [Numerous follicles are found in the ductus communis and in the hepatic duct, and all its subdivisions; according to Mr. Kiernan, even in the smallest that can be examined. In the larger branches they are arranged irregularly; in the smaller ones, in two longitudinal rows, along opposite sides of the duct.]

‡ [In the embryo of the bird the liver is developed by a conical protrusion of the walls of the intestinal canal into a granular mass or blastema.—(See *Müller's Phys.* by Baly, p. 448.) The rudiments of the cerebro-spinal axis, of the heart, and of the intestinal canal, appear previously to the liver.]

◊ I have had occasion to notice, at the Maternité, the very great differences in the size of the liver in infants at birth, for which I have been unable to find any sufficient reason. There are some well-formed infants in whom the liver at birth is not relatively larger than that of adults

placed the other abdominal viscera. During the second half of intra-uterine life, and at birth, it occupies only a part of the abdomen ; but it still corresponds to a considerable extent of the abdominal parietes : hence the ease with which it is ruptured by pressure upon the abdomen of a new-born infant. One fact on record seemed to me to prove, that in a first labour, where the feet presented, the pressure of the genital organs of the mother was sufficient to produce this result.—(Vide *Procès-verbal de la Distribution des Prix de la Maternité*, 1832.)

In the earliest periods the falciform ligament of the liver corresponds to the median line of the body ; at birth it is a little to the right of that line, and is afterward removed still farther in the same direction.

4. The great size of the liver during intra-uterine life is connected with the existence of the *umbilical vein*, by which the fœtus receives the blood returned from the placenta, that is to say, all the blood necessary for its nutrition. The rapid diminution of the liver after birth is probably owing to the obliteration of this vein. It is a very remarkable fact, that the persistence of this vein in the adult is not accompanied by an unusually large liver. In one particular case of persistence of the umbilical vein the liver was of a very small size.—(*Anat. Path.* avec planches, liv. xvii.)

5. The tissue of the liver of the fœtus is of a pale red colour in the early periods, and of a deep brown near the full term of pregnancy ; its colour becomes lighter after birth. The liver contains a greater quantity of blood before than after birth. Its tissue is the less consistent the earlier the stage of development at which we examine it, and its softness is accompanied with great fragility.

6. The distinction between what are called the two substances of the liver is not appreciable during intra-uterine life. It only becomes apparent after birth.

Functions.—The liver is the secreting organ of the bile. The bile is secreted in the glandular granules by an unknown process. Doubts are still entertained as to whether the materials from which the secretion is formed are conveyed by the hepatic artery or the vena portæ.* The opinion advanced by some modern authors, that the yellow substance of the liver is the only part concerned in the secretion of the bile, and that the brown substance has other uses, is a purely gratuitous hypothesis.

The bile traverses the several ramifications of the hepatic duct, and, having arrived in the principal duct, it may either enter directly into the duodenum by the ductus choledochus, or it may pass into the gall-bladder by the cystic duct. This retrograde movement towards the gall-bladder has much occupied the attention of physiologists : perhaps it may be explained by the narrowness of the duodenal orifice of the ductus choledochus, by the elasticity of that canal, and especially by the pressure exercised on its duodenal portion by the circular fibres of the duodenum. The gall-bladder and the cystic duct are not indispensable to the elimination of the bile. Nothing is more common than to find the excretory apparatus of the liver in old subjects reduced to the hepatic duct and the ductus choledochus.

Has the liver any other function besides that of secreting bile ? The disproportion existing between the size of that organ and of its excretory apparatus, and also the enormous bulk of the liver during fœtal life, *i. e.*, at a time when the secretion of bile is at its minimum of activity, are both in favour of the opinion that the liver has some additional function ; and if, again, we consider that, in the adult, a very important system of veins is distributed to the liver, and that in the fœtus it receives the blood from the veins of the fœtal portion of the placenta, we shall be led to presume that the unknown functions of this organ are in some way connected with the process of sanguification.

The Pancreas.

Dissection.—The pancreas may be seen through the gastro-hepatic omentum, after drawing down the stomach, without any dissection. In order to expose it, turn the stomach upward (see *fig.* 154) after having divided the two layers of peritoneum which proceed from its greater curvature to form the great omentum. It may also be exposed by turning the arch of the colon upward, and dividing the inferior layer of the transverse mesocolon. The excretory duct is situated in the interior of the organ. In order to dissect it, the glandular substance which covers it must be very carefully removed towards the middle and the right extremity of the gland. It may be injected from the ductus choledochus, after the vertical portion of the duodenum has been included between two ligatures : when the duodenum is filled with the injection, the pancreatic duct becomes filled in its turn. It may also be injected from the ductus choledochus after having passed a ligature round the projection or ampulla which is common to the two ducts.

The *pancreas* (πᾶν-κρέας, all flesh) is a glandular organ annexed to the duodenum, with which it has immediate relations : it is situated transversely and deeply behind the stomach, and in front of the lumbar vertebræ.

* [From the researches of Mr. Kiernan (see note p. 395), it would appear that the blood of the vena portæ is *directly* concerned in the secretion of the bile, while that of the hepatic artery is only *indirectly* concerned, *i. e.*, after it has afforded nutrition to the tissue and vessels of the liver, and has entered the branches of the vena portæ, and thus become portal blood.]

Form and Size.—In form, the pancreas resembles no other gland; it is transversely oblong, flattened from before backward, large at its right extremity, where it presents a sort of angular expansion like a hammer, and gradually tapering towards its left extremity: hence the division of this organ into a *head*, *body*, and *tail*. Its long or transverse diameter is measured by the interval between the concavity of the duodenum (*e e*) and the spleen (*k*). The size and weight of the pancreas present many varieties. Its weight is generally from two to two and a half ounces, but may reach six ounces. The pancreas is sometimes found atrophied, and in one case of this kind it did not exceed an ounce in weight.

Relations.—Its *anterior surface*, convex and covered by the peritoneum, is in relation with the stomach, which moves freely upon it. In certain cases of disease, adhesion between the pancreas and the stomach takes place, so that in chronic ulceration of the latter we find the pancreas supplying the place of large portions of the walls of the stomach which had been destroyed. When the stomach is situated lower down than usual, the pancreas has relations either with the liver or with the anterior walls of the abdomen, from which it is separated only by the gastro-hepatic omentum, so that it may be felt with the greatest ease through the abdominal parietes.* In such cases, even experienced practitioners have not unfrequently been led to infer the presence of scirrhus of the pylorus. The pancreas is also in relation, in front, with the first portion of the duodenum, and with the angle formed by the ascending and transverse colon.

Its *posterior surface* is concave, and corresponds to the vertebral column, opposite the first lumbar vertebra: it is separated from the spine, however, by the splenic and the superior mesenteric veins, and by the commencement of the vena portæ. The two last-mentioned veins are lodged in a deep groove, or, rather, almost complete canal, formed in the pancreas, which also includes the superior mesenteric artery and its surrounding plexus of nerves. A great number of lymphatic vessels and glands, the pillars of the diaphragm (*d d*), the vena cava on the right side, and the aorta on the left, also separate the pancreas from the vertebral column. To the left of the spine it is in relation with the left supra-renal capsule and kidney, and the corresponding renal vessels. The relation of the pancreas to the aorta is important; it is through the pancreas that the pulsations of that vessel are felt in the epigastrium in emaciated individuals, and it is here that the vessel may be compressed.

Its *upper border* is thick, and is grooved for the reception of the splenic artery, which often runs in a sort of hollow canal formed in the substance of the gland through its entire length. It also has relations with the first portion of the duodenum (*e*), with the lobulus Spigelii, and with the cœliac axis (*t*). The thickness of this border has led some anatomists to say that the pancreas is prismatic and triangular.

Its *lower border* is much thinner than the upper, and is bounded by the third portion of the duodenum, from which it is separated on the left by the superior mesenteric vessels (*m*, the artery).

Its *right*, or *duodenal*, or *great extremity* is in contact with the duodenum and the ductus choledochus. This extremity presents a very remarkable arrangement; it is curved upon itself from above downward, like the duodenum, by the concavity of which it is circumscribed; then, having reached the third portion of the bowel, it passes transversely to the left, behind the superior mesenteric vessels, and forms the posterior wall of the canal in which they are situated. This reflected portion, arranged in the form of a whorl, is sometimes detached from the rest of the gland, on which account it has been called the *lesser pancreas*. By its great extremity the pancreas is, as it were, attached to the duodenum, beyond which it projects in front, but especially behind: it accompanies this intestine in all its displacements, so that when the duodenum is situated lower down than usual, which happens in displacements of the stomach downward, the head of the pancreas is always removed in the same direction.

Its *left*, or *splenic*, or *small extremity* is narrow, and touches the spleen, upon which it is flattened and blunted, and sometimes slightly enlarged. It is seen, then, that in its relations to other parts, the pancreas has a great analogy with the salivary glands. Thus, large vessels are situated near and penetrate this gland, which forms a sort of covered passage for them, and is moved by their pulsations. The diaphragm, the duodenum, and the stomach, also tend to disturb and press upon the pancreas.

Structure.—The analogies in structure between the pancreas and the salivary glands are no less numerous, and fully justify the name of *abdominal salivary gland* given to it by Siebold: it has the same whitish colour, the same density,† and the same arrangement into lobes, which are themselves divisible into lobules. The identity is such that it would be impossible to distinguish a portion of the pancreas from a part of a salivary

* This condition may be foretold: it occurs whenever the vertebral column can be felt immediately behind the parietes of the abdomen. I have never met with it excepting in emaciated individuals, where a great part of the small intestine occupied the cavity of the pelvis. It is probably the traction exercised by the small intestine contained in the pelvis that occasions the low position of the stomach.

† The pancreas sometimes assumes an extreme density, strongly resembling that of scirrhus. In such a case it is necessary to make sections of it, to be assured of the perfect soundness of the glandular tissue. This stony hardness generally occurs along with atrophy of the organ

gland. When boiled, they both have the same aspect and the same taste. There is no fibrous capsule, properly so called, but some fibrous lamellæ, which separate the lobes and lobules. Cellular tissue is tolerably abundant. Fat is not uncommonly met with, either on the surface or in the substance of the pancreas; I have even seen cases of atrophy of the gland, in which fat appeared to have been substituted for the glandular substance.

The determination of the structure of the pancreas, like that of all glands, involves two considerations, viz., the texture of each lobule, and the arrangement of the vessels and nerves in the substance of the gland. With regard to the first point, I shall merely refer to what has been already stated respecting the salivary glands.* The arrangement of the *vessels* is perfectly well known.

As in the salivary glands, the *arteries* enter the pancreas at a great number of points. They are very numerous and very large, considering the small size of the organ: they arise from the hepatic, the splenic, and the superior mesenteric. The principal artery is called the pancreatico-duodenalis.

The *veins* terminate in the superior mesenteric and the splenic. The *lymphatic vessels* are not well known; it is probable that they enter the numerous glands which are in the neighbourhood. The *nerves* of the pancreas are derived from the solar plexus.

The *excretory duct* (*u*, *fig.* 169) is called the *canal of Wirsung*, from the name of its discoverer, a young anatomist, who was too soon lost to science. By an arrangement, of which we have no other example in the body, this excretory duct is contained entirely in the substance, we might even say, in the centre of the gland; so that, in order to expose it, the superficial portion of the organ must be carefully divided. It is generally single, but sometimes double, and then there is a principal duct belonging to the body of the pancreas, and a small duct for the reflected portion, or lesser pancreas. The pancreatic duct measures the entire length of the gland; it is narrow at the splenic extremity, which may be regarded as its origin, and gradually increases in size as it approaches the duodenal extremity; there it bends downward, to reach the ductus choledochus, to the left of which it is placed; it runs along the side of that duct, then perforates it obliquely, and opens, as I have already described when speaking of the liver, in the olive-shaped ampulla immediately preceding the duodenal orifice of the ductus choledochus. It follows, therefore, that the pancreatic duct and the ductus choledochus open by a common orifice in the human subject. This arrangement is constant, and, when we find a pancreatic duct perforating the duodenum separately, we may be certain that there is another duct presenting the regular arrangement; at least, I have never observed to the contrary. As to the precise situation of the separate opening of the supernumerary pancreatic duct, it may be either in front of, behind, below, or above, the orifice of the ductus choledochus. Tiedemann, who has collected all the known cases of double pancreatic duct, and all the varieties of insertion found in the human subject, has arrived at the curious result, that these varieties have their analogies in the different species of animals.

The mode in which the divisions of the pancreatic duct are inserted into the principal trunk deserves to be noticed. The ultimate ducts of the pancreas do not, in fact, unite into larger and larger branches, like the veins, but the small branches coming from each lobule open directly, and in succession, into the general duct: an arrangement which gives to the excretory apparatus of the pancreas the appearance of those insects called *centipedes*.

As to the structure of the pancreatic duct, its walls are very thin; it is collapsed, and of a milk-white colour, very distinct from the grayish-white hue of the proper tissue of the gland. Its internal surface is extremely smooth, like a serous membrane;† its thinness renders the determination of its texture very difficult; it is very extensible.

Development.—The development of the pancreas presents no peculiarities excepting such as relate to its size, which is relatively greater in the fœtus and the new-born infant than in the adult. Examples have occurred of disease of the pancreas during intra-uterine life; and I have found a scirrhous pancreas in a fœtus at the full term.

Function.—The pancreas is the secreting organ of a particular fluid called the pancreatic fluid, the physical and chemical characters of which have not been well known until very lately. I have met with two cases of retention of the pancreatic fluid. The dilated canal resembled a transparent serous cyst; the contained liquid was extremely viscid and transparent, but of a whitish hue, like a solution of gum-arabic; it had a slightly saline taste; the collateral ducts were extremely dilated. There were some white patches, resembling plaster, in the centre of many of the lobules. This substance was more abundant in some of the lobules, and, when removed, presented the appearance of small lumps of plaster or chalk. The pancreatic fluid submitted to chemical analysis by M. Barruel proved to be an extremely pure mucus. M. Barruel even stated to me that it was the purest mucus he had ever examined. It possesses in the highest degree the

* [The only observable difference between the lobules of the pancreas and salivary glands is, that the closed termination of the ducts are cylindrical in the former, and slightly dilated in the latter (see note, p. 341).]

† [It is a mucous membrane, continuous with that of the duodenum, and covered with epithelium. In some subjects, Mr. Kiernan found mucous follicles in it, similar to those in the biliary ducts; in others, no traces of them could be discovered. None were seen in the salivary ducts.]

property of rendering water viscid, either by dissolving, or by being diffused in it. This mucus contains free soda, a trace of chloride of sodium, and a very slight trace of phosphate of lime. There is, therefore, an analogy between the pancreatic and salivary fluids, as the anatomical investigation of these glands had previously led us to suppose.*

The Spleen.

The *spleen* (σπλὴν, lien; *k, fig.* 154) is a spongy and vascular organ, the functions of which, though little known, appear to be connected with those of the abdominal venous system.

It is deeply situated (*k, figs.* 155, 161) in the left hypochondrium, behind and to the left of the great end of the stomach, to which it is united by a fold of peritoneum, called the *gastro-splenic omentum.* It is also retained in its place by the peritoneum, which is reflected upon it from the diaphragm,† and by the vessels which enter and pass out from it. Being suspended rather than fixed to certain movable parts, the spleen necessarily participates in their movements; and the contraction or relaxation of the diaphragm, as well as the alternate distension and collapse of the stomach, exert an undoubted influence upon it; but these slight and temporary changes of position do not constitute a true displacement.

It may even be said that displacements of the spleen, which are very rare, are almost always congenital. Thus, Haller has seen this organ situated at the left side of the bladder, in an infant one year old; Desault has found it in the right cavity of the thorax in a fœtus at the full time. I do not here allude to cases of complete transposition of the viscera, nor to cases where the change of situation depends on enlargement of the spleen, or on displacement of the stomach.‡ I have mentioned elsewhere that I have found the spleen in the umbilical region.

Accidental adhesions of the spleen are so frequent that they deserve to be mentioned. They are sometimes filamentous, and sometimes cellular, and they render painful the slightest changes of position in this organ, from violent contractions of the diaphragm, or from great distension of the stomach: these adhesions are almost always the sequelæ of intermittent fevers.

Number.—The spleen is single in the human subject. The *supernumerary spleens* occasionally met with near it are nothing more than small ovoid or spheroidal fragments of the spleen, which at first sight might be taken for lymphatic glands. I have never seen more than two supernumerary spleens in man. It is said that they are more frequent in the fœtus than in the adult: this opinion is erroneous.◊ It has been said that ten, twelve, and even twenty-three supernumerary spleens have been observed. Without denying the possibility of the fact, I am inclined to doubt its occurrence. As the spleen is always multiple in a great number of animals, supernumerary spleens in man may be regarded as the last trace of such an arrangement.

With regard to the examples of congenital or accidental absence of the spleen mentioned by some authors, it should be remarked, that they were accompanied with serious diseases of the abdomen, and that small adherent spleens, lost in some measure among the surrounding organs, may easily have escaped notice in a not very close examination.

Size and Weight.—There is no organ which varies more than the spleen in regard to size and weight. These differences may be referred to the following heads:

Individual Differences.—It is in vain to attempt to establish a relation between the size of the spleen and that of the liver, or between the size of the spleen and the stature, weight, constitution, and habits of the individual.‖

Differences from Physiological Conditions.—The spleen is often found small, wrinkled, shrunk, or, as it were, withered and collapsed; a state that certainly supposes the opposite condition of distension. In other cases the spleen is large, and looks as if it were stretched. Ought we, then, to admit, with Lieutaud,¶ that the pressure from the

* [According to the best analyses, the pancreatic fluid differs from saliva in containing a greater amount of solid matter, and also in the character of its constituents: saliva is usually alkaline, and, besides other substances, contains salivine, mucus, and sulpho-cyanate of potassa; the pancreatic fluid contains albumen, casein, but little salivine and mucus, and no sulpho-cyanate; in other respects the two fluids agree.]

† [This reflection is called the *ligamentum phrenico-lienale.* The spleen is also connected by the peritoneum to the arch of the colon.]

‡ The great end of the stomach is the most fixed part of that viscus, on account of its connexion with the œsophagus. Changes of position in this organ affect partly the portion between the pylorus and the cardia, and partly the pylorus itself.

◊ It is true that a greater number of cases of supernumerary spleens in the fœtus have been recorded than in adults; but the fact is easily explained, if we consider that in the fœtus supernumerary spleens cannot escape notice, while they are often difficult to be seen in the adult, on account of the fat with which the omenta are loaded.

‖ The spleen is proportionally larger in man than in the lower animals. It has been said, as if it were possible to establish a relation between two such variable terms as the weight of the spleen and the body, that the former is $\frac{1}{200}$th of the latter.

¶ Lieutaud asserts that he has constantly found the spleen larger when death has occurred while digestion was going on in the stomach than when it has happened after that process had been completed; but the spleen varies so much in size that we cannot compare the spleen of one subject with that of another. An ingenious experiment has been made, the result of which is opposed to Lieutaud's opinion: out of four newly-

distended state of the stomach during digestion diminishes the size of the spleen, which, on the other hand, becomes the seat of an afflux of blood in the intervals between the occurrence of that process. This idea is, perhaps, erroneous as far as regards the periods of collapse and turgescence; but it is correct as to the principal fact, viz., the alternation of those two opposite conditions.

Differences from Age.—The spleen is proportionally smaller in the fœtus than in the adult, and in the adult than in the aged.

Differences from Disease.—The morbid differences in the size of the spleen suggest most important considerations. In a great number of patients suffering with intermittent fevers, more especially when this organ is already enlarged from previous attacks, it is manifestly swollen during each access. Hypertrophy of the spleen may proceed to an extraordinary extent; so that this organ, which, in the natural condition, is withdrawn so deeply into the left hypochondrium as not to be seen on opening the abdomen, in certain cases fills almost the whole of the abdominal cavity; while its weight, which varies from two to eight ounces in the healthy condition, may be as much as ten, twenty, or thirty pounds; one case, indeed, has been recorded where the spleen weighed forty-three pounds.

Atrophy of the spleen is very rare. I have seen it reduced to the weight of two drachms.

The *specific gravity* of the spleen is, to that of water, as 1160 to 1000.

The spleen, both upon the surface and in the interior, most commonly resembles in colour the dark lees of wine. This colour, however, presents many varieties from a deep-brown red to a pale gray. When the surface has been some time exposed to the air, it becomes bright red, like the surface of venous blood soon after its abstraction. Age, the kind of death, and diseases, have much effect on the colour of this organ, the different parts of which are not always of a uniform tint. I have seen a spleen of a deep chestnut-brown hue.

Consistence.—One character of the tissue of the spleen is its extreme friability. In general it may be lacerated by the pressure of the finger, to which it communicates a feeling of crepitation, and emits a sound like the crackling produced by bending tin. The spleen may be regarded as the most friable of all organs excepting the brain. Thus, examples have been recorded of its laceration from blows, or falls upon the abdomen, and even from a general concussion, or from the contraction of the diaphragm and abdominal muscles during violent exertion, &c.

The consistence of the spleen also varies much in different individuals, and in diseases; indeed, the most important alterations of this organ may be referred to either increased or diminished consistence. In induration, which is generally accompanied with hypertrophy, the tissue of the spleen is compact, brittle, and dry, and breaks like a piece of compact resin. In softening, carried to its highest degree, the spleen is converted into an inorganic pulp, exactly resembling a healthy spleen broken down by the fingers, and containing a greater quantity of fluid than natural. This state is often observed after malignant fevers,* and when the membranes are torn, the substance of the spleen escapes spontaneously.

Figure.—The spleen has a crescentic form; its long diameter is vertical, its concavity directed to the right, and its convexity to the left side. It may be compared, as was done by Haller, to a segment of an ellipse cut longitudinally.

It presents for consideration an *external* and an *internal surface*, and a *circumference*.

The *external* or *costal surface* is convex, smooth, and in relation with the diaphragm, which separates it from the ninth, tenth, and eleventh ribs;† hence arises the influence of contractions of the diaphragm upon the spleen, and the possibility of its being ruptured during a violent effort. This relation also accounts for the pain felt in the region of the spleen after quick running, and the difficulty and pain attendant on a strong inspiration made while running by persons in whom the spleen is hypertrophied.

We frequently find a prolongation of the liver almost completely covering the external surface of the spleen.

The *internal* or *gastric surface* is concave in all directions, and presents, at the junction of the two anterior thirds with the posterior, a somewhat irregular series of openings, which are themselves irregular in form and number, are situated at greater or less intervals, and arranged longitudinally. This row of openings is called the *fissure*, or *hilus* (*h, fig.* 154) *of the spleen*. The *gastro-splenic omentum* is attached near this fissure. Some varieties are observed in the arrangement of the internal surface of the spleen. Thus, it sometimes presents a uniform concavity, and sometimes there is a sort of projecting ridge opposite the hilus, which divides it into two unequal parts, one anterior

born puppies, belonging to the same litter, two were kept without food, while to the other two milk was given; on killing them, their spleens were all found of the same size.

* Vide *Anat. Path. avec Planches*, liv. ii., art. MALADIES DE LA RATE. I have been able to collect the splenic fluid in a medicine vial, and to submit it to different experiments.

† It is said that the ribs produce marks upon the spleen from the pressure exercised by them upon it during life. I have never observed this appearance, and can only conceive it to exist in cases of hypertrophy of the spleen.

and larger, the other posterior and smaller: in the latter case, which is common, the spleen is of a prismatic and triangular form.

The following are the relations of the internal surface: the part situated in front of the hilus has relations with the great cul-de-sac of the stomach, and, on the right and behind this cul-de-sac, with the gastro-splenic omentum and the vasa brevia situated within it: the left extremity of the liver, which, as we have seen occasionally, covers the external surface of the spleen, is more frequently in relation with the internal surface of that organ. Behind the hilus the spleen corresponds with the left kidney, suprarenal capsule, and pillar of the diaphragm, which separate it from the spine, and with the small extremity of the pancreas.

The *circumferenc* is elliptical; its *posterior border* is thicker above than below, and is in relation with the kidney, which it sometimes covers through its entire length; its *anterior border* is thinner, and is applied to the stomach; its *upper extremity* is thick, often bent upon itself, and in contact with the diaphragm, from which, however, it is occasionally separated by the liver; its *inferior extremity* is pointed, and rests upon the angle formed by the transverse and descending colon, or upon the portion of transverse mesocolon which supports that angle. The circumference of the spleen is notched, and sometimes marked more or less deeply by fissures, which are prolonged upon both its surfaces, particularly upon the external surface, and which divide it into a greater or less number of distinct lobules. This lobular arrangement is the last indication of the multiple spleens, of which we have already spoken. The description of the relations just given applies when the stomach is empty; when that viscus is distended, they are somewhat different. The spleen, which before was separated from the stomach by the gastro-splenic omentum, is then applied directly to it, and is moulded upon it, so, as it were, to cover its walls. It has no longer any relations with the kidney and the vertebral column, but is situated below and behind the great cul-de-sac of the stomach, and not to the left of it; and it becomes horizontal instead of being vertical, as when the stomach is empty.

Structure.—Besides two investing membranes, one serous, the other fibrous,* the spleen consists of cells having fibrous parietes, and filled with a grumous fluid,† of the colour of port wine dregs, of certain corpuscules not very distinct in the human subject, of a very large artery and still larger vein, and of lymphatic vessels and nerves.

The *serous* or *peritoneal coat* invests the whole spleen, with the exception of the hilus, which corresponds to the gastro-splenic omentum. It gives a smooth appearance to the spleen, lubricates its surface, and, at the same time, fixes it to the neighbouring parts by the bands which it forms. Its internal surface adheres closely to the fibrous membrane.

The *proper coat* of the spleen forms a sort of fibrous shell, which is strong, notwithstanding its tenuity and transparency. This membrane is the seat of those cartilaginous plates which are so often found upon its surface, and which conceal its true colour. It is intimately united to the peritoneal membrane by its outer surface, and adheres still more closely by its inner surface to the tissue of the spleen by means of exceedingly numerous and dense fibrous prolongations, which penetrate it in all directions, and interlace in every way, so as to form areolæ or cells, the arrangement of which we shall hereafter examine. Farther, the proper coat is not perforated at the hilus for the passage of the vessels, but by an arrangement similar to that already noticed in the liver, it is reflected around the vessels opposite the hilus, like the capsule of Glisson, and is prolonged upon both the arteries and veins, forming sheaths which divide and subdivide like the vessels themselves, and receive the prolongations given off from the inner surface of the proper coat.

This arrangement has been very well described by Delasonne (*Mém. Acad. des Sciences*, 1754), and especially by Dupuytren (*Thèse de M. Assolant*). It follows, therefore, that the basis of the spleen is composed of a fibrous structure, consisting of an investing fibrous membrane, of fibrous sheaths which accompany the vessels in their divisions and subdivisions, even to their terminations, and of prolongations arising from the inner surface of the membrane, interlacing in all directions, and attached to the outer surface of the sheaths.‡

The internal framework of the spleen is therefore an areolar tissue, which may be very well displayed by washing away the pulpy matter of this viscus by means of a stream of water; there will then remain a whitish areolar and spongy tissue. This is also very clearly shown by injecting it either with mercury or some coloured liquid, or even by inflating it with air blown through a puncture. The coats are then raised in different places, and after desiccation, the areolar structure becomes evident. This experiment also shows that the spleen is divided into a number of compartments, for, without rupture, only a small portion of the organ can be injected in this way.

It appears, then, that the proper tissue of the spleen is composed of an areolar fibrous

* See note, *infrà*.

† See note, p. 406.

‡ [This basis or framework is more or less developed in the different species of animals: it is much stronger in the horse than in the ox. The proper coat of the spleen, together with the sheaths for the vessels, and the prolongations or trabeculæ given off from it, are highly elastic, and are generally stated to consist of yellow elastic tissue, not of ordinary fibrous tissue.]

network, and of a pultaceous matter, of the colour of port wine lees—the *splenic juice or matter*, regarded by the ancients as one of the fundamental humours of the body, called atra bilis, and which modern chemists have not yet sufficiently examined.

We have now to determine the arrangement of the cells, and the relation between these cells and the arteries, veins, and nerves.

The Splenic Artery.—No organ of so small a size receives so large an artery. The splenic artery is, in fact, the largest branch of the cœliac axis, and, on this account, ruptures or wounds of the spleen are almost always followed by fatal hemorrhage. It is also remarkable for its tortuous course; when reduced to half its original size, from having given off several branches, it enters the spleen by four or five branches at greater or less distances from each other. These branches divide in the usual manner in the substance of the organ, and preserve their tortuous character even to their terminations. One peculiarity well worthy of attention is, that the arteries constantly divide in a radiating manner, so that air, or water, or tallow, thrown into one arterial division, does not pass into the branches of the others. This mode of division is observed not only in the larger, but also in the smaller arteries,* so that the spleen may be considered as an aggregate of a considerable number of small spleens, united together by a common investment; and accordingly, if in a living animal one division of the splenic artery be tied, the portion of the spleen to which it is distributed becomes blighted, while the rest remains in the natural state. This arrangement of the arteries may be shown in a very striking manner by injecting their several divisions with differently-coloured substances. The injected matters will not mix, and the line of demarcation between the lobes will become evident.

This structure explains how multiple spleens may occur in man and the lower animals, and why there are so many varieties in this respect in the animal series.

Some branches from the splenic, lumbar, and spermatic arteries enter the spleen through the folds of the peritoneum.

The *splenic vein* is four or five times larger than the artery: it forms one of the principal roots of the vena portæ, and is almost equal to the other root formed by the superior mesenteric vein. The venous communication between the spleen and the liver has, in a great measure, given rise to the opinion that they are connected in function. The spleen is filled by the numberless and large divisions of this vein; it might even be said that the texture of the spleen is essentially venous, that it is composed of a venous plexus or an erectile tissue, and that it bears the same relation to the veins that the lymphatic glands do to the lymphatic vessels. All the splenic cells communicate with the veins, or, rather, they are nothing more than these veins themselves, supported by the fibrous columns and sheaths already described: this is shown by the following considerations and experiments:

1. If, according to the example of Delasonne,† we examine the spleen of the ox by laying open the splenic veins and their divisions by means of a grooved director, we shall find that these veins are almost immediately reduced to their lining membrane, and perforated with very distinctly formed foramina, through which the dark reddish-brown splenic matter is visible. These foramina soon become so numerous, that the veins are converted into cavities or cells, the walls of which are perforated with openings of various sizes, filled with the splenic pulp. This arrangement, which is most manifest under water, proves that the tissue of the spleen is composed of venous cells,‡ like the corpora cavernosa of the penis. In man, the horse, and the dog, the great veins are not perforated with foramina, but the cellular and areolar arrangement of the splenic veins, at a certain depth, is not less manifest.

2. If we inject the splenic artery, the spleen will become very slightly increased in bulk at first, *i. e.*, as long as the injected matter does not pass into the venous system; but as soon as this occurs, and it does so readily, the increase in size becomes rapid: it follows, therefore, that the communication between the artery and the splenic cells is indirect.◊ On the other hand, if we inject the vein, the cells are immediately dilated, and the spleen becomes prodigiously increased in bulk: it is easy to perceive that the communication is direct, and that the venous system, in some measure, forms the basis of this organ.

We can very seldom meet with a human spleen sufficiently healthy for the following experiment. It will succeed perfectly with the spleen of a horse, which is of a much denser structure. The spleen ought, in the first place, to be freed from the liquid which it contains; this must be accomplished by forcing water into the splenic artery. The

* [The minute arteries ramify in tufts or penicilli.]

† Delasonne has described the structure of the spleen in the ox as belonging to the human subject.

‡ [According to Mr. Kiernan, these venous cells are lateral dilatations, which communicate with the venous trunk by small branches. They contain only blood, however, for the red pulpy matter of the spleen is said by Müller to be *external* to, and not *within* them. This red substance consists principally of red granules, about the size of the blood-globules, but spherical, not flattened.]

◊ It has been erroneously asserted that the communication between the artery and vein is more direct in the spleen than in any other organ. The great anastamoses, visible to the naked eye, between the splenic artery and vein, admitted by Spigelius, Diemerbroeck, Bartholin, and others, are purely imaginary. The precise mode of communication is still unknown.

water will return by the veins, at first turbid, then merely tinged, and at last limpid and pure.* I have in vain attempted to force the injection from the veins into the arteries. After the water, air should be blown into the artery, so as to empty the spleen as much as possible of any liquid which it may contain.

If we examine a spleen thus freed of its contained matter, we observe that it is wrinkled, and, as it were, shrivelled on the surface, and remarkably diminished in bulk; and, on making a section of it, we find a white, spongy tissue, composed of laminæ or fibres, interlacing in every direction.

The following preparation† exhibits this structure most fully: The spleen of a horse, prepared in the way I have indicated above, and weighing one pound, could receive ten pounds of tallow. The injection was thrown in by the veins: at each stroke of the piston, the spleen swelled up readily, an evident proof that the splenic cells communicate directly with the veins; while, in order to obtain the same effect by injecting through the arteries, very considerable force was required. The injection of the spleen by the veins did not take place in a uniform manner, but successively; in one injection, the upper part was injected before the lower, and the anterior border before the posterior. The independence of different portions of the spleen on each other exists in regard to their veins as well as their arteries. I have been enabled to observe the resistance offered by the tissue of the spleen to the distending power; a resistance which caused the injection to flow back whenever the impelling force was discontinued. The cells are extensible to a certain degree, beyond which they resist very powerfully: it does not appear that they possess any elasticity.‡

After some days, when desiccation was complete, the spleen thus injected was divided into several portions, which were then immersed in spirits of turpentine moderately heated. The tallow, by which all the cells were distended, and which had taken the place of their contents, having been dissolved out, the sections presented a spongy, areolar structure, like that of erectile tissue, as found in the corpora cavernosa, or the substance of the placenta: and this cannot be considered, as Meckel would have it, as the artificial result of the insufflation and injection, which lacerate, as he believes, a part of the vessels and fibrous tissue.—(*Manuel d'Anatomie*, t. iii., p. 479.) This spongy cellular structure explains why the spleen, as well as the corpora cavernosa, is susceptible of such great variations in bulk; and why it is sometimes found collapsed and wrinkled, and sometimes distended, and, as it were, swollen. Are the splenic cells lined by the internal membrane of the veins? if so, the membrane is so thin as to be incapable of demonstration.

Corpuscles of the Spleen.—Malpighi described, as existing in the spleen, certain corpuscles, regarded by him as the principal elements in this organ, and believed by him to effect some important changes in the splenic blood. These corpuscles, which Ruysch considered to be essentially vascular, have been again brought into notice by Delasonne, who demonstrated them by maceration. Haller denied their glandular nature, because, as he said, there can be no glands where there is no secretion and no excretory ducts. The question is not, however, whether these corpuscles are glands or not, but rather whether they exist at all. It is certain that, in many animals, in the dog and the cat, for example, a great number of granules may be seen scattered through the spleen, and which, according to a calculation, the accuracy of which I do not guarantee, would seem to form two fifths of the weight of the organ. These corpuscles are soft, whitish or reddish, and vary in diameter from a fourth of a line to a line. They do not appear to me to exist in man.§

The *lymphatic vessels* of the spleen are divided into the superficial and deep. The superficial only are well known; a certain number pass from the spleen to the stomach; they all terminate in lymphatic glands situated opposite the hilus, within the layers of the gastro-splenic omentum.

* This injection, which requires considerable force, continued without interruption for a long time, occasions an exudation of a perfectly transparent fluid upon the surface of the spleen, even when water returned by the vein is still turbid. Here we have an imitation of an exhalant process. And, as this transudation takes place without rupture, it is evident that there are a set of vessels by which it is effected.* Instead of making an injection, which is always troublesome, we may attach the splenic artery to a tube, which is itself adapted to another tube, running from the bottom of a cistern; the column of water will overcome the resistance offered to its passage from the arteries into the veins, and in twenty-four hours it will pass through perfectly limpid.

† This mode of preparation was suggested to me by the plan adopted with the corpora cavernosa by Bogros, prosector to the Faculty, who died a victim to his zeal for science.

‡ [The lining membrane of these venous cells is not very extensible, but the trabeculæ, between which they lie, are highly extensible and elastic also.]

§ [The corpuscles here described are not those discovered by Malpighi, but large, soft, grayish bodies, rarely found in the human spleen, and the nature of which is not understood. The Malpighian corpuscles are much smaller; they are very evident in the ox, sheep, and pig; they lie in the red pulpy matter externally to the venous cells, and are attached by short pedicles, or without pedicles, to the minute arteries, which, however, have not otherwise any special relation to them; they contain grayish granules, similar in size and form to those of the red pulpy matter. In the human spleen they are very difficult to distinguish.

The extremities of the divided trabeculæ may be mistaken for white corpuscles.]

* [This transudation evidently depends on the porosity or permeability of animal tissues, and not on the existence of any special vessels.]

Nerves.—The nerves are derived from the solar plexus, and are termed the splenic plexus. It has been stated that some terminal divisions of the pneumogastric have been seen distributed upon the spleen. Several of the nerves are remarkable for their size, which enables us to examine in them the peculiar structure of the ganglionic nerves, and also to trace the splenic nerves themselves deeply into the substance of the organ.* We are completely ignorant of their mode of termination.

As to the *proper ducts* of the spleen, said to pass directly from that organ to the great cul-de-sac of the stomach, or even to the duodenum, and to pour into these parts a peculiar liquid, it may be confidently stated that they are purely imaginary. And again, the three kinds of vascular communication between the spleen and the stomach cannot in any way explain the afflux of liquids from the spleen to the stomach; in fact, the arterial vasa brevia of the stomach are given off from the splenic artery before it reaches the spleen; nor do the venous vasa brevia enter the splenic vein until after it has left the hilus of the spleen; the lymphatic vessels alone pass directly from the spleen to the stomach, but they are superficial, and have no connexion with the splenic cells.

There is no cellular tissue, properly so called, in the spleen, which, nevertheless, is liable to inflammation.

Development.—In opposition to the liver, the spleen is smaller in proportion as it is examined nearer the period of conception. It appears late; it begins to be distinguishable towards the end of the second month, and it then resembles a clot of blood. I have never seen it developed from separate lobules, which were afterward to be united by a common investment. At birth, its proportions are almost the same as at subsequent periods. The spleen is hard, and, as it were, tense, in most infants who die during birth: this is probably owing to impeded circulation.

The changes which the spleen undergoes during growth, both in density and in size, are partly physiological, which are not very remarkable, and partly pathological; these are very considerable, but they are foreign to my subject. In the aged, the spleen decreases, like all other organs; and atrophy of this organ, which may proceed so far that it only weighs a few drachms, is often accompanied by the development of a cartilaginous shell.

Functions.—The functions of the spleen appear to me to be referrible to its structure and its vascular connexions. The quantity of blood which passes through it, its entirely vascular structure, and the physical qualities of the splenic pulp prove, on the one hand, that the blood sent to the spleen serves other purposes besides that of nutrition; and, on the other, that it undergoes some important changes, of which we are completely ignorant, because the means of analysis are wanting; but, whatever they may be, they have undoubtedly some connexion with the functions of the liver,† for in all animals possessing a spleen, even though its arterial blood does not come to it from the same trunk as the hepatic artery, the veins of the spleen terminate in the venous system of the liver. It is, therefore, extremely probable that the spleen performs an important office in the abdominal venous system; but what this office is we do not know; and what tends to confound all our calculations is, that extirpation of this organ in animals does not seem to have any marked effect upon their health, that the most complete atrophy of the spleen is consistent with the most regular performance of all the functions, and that hypertrophy, even to such a degree that the organ occupies almost the whole of the abdomen, merely produces a discoloration of the skin, diminished nutrition, and, in young subjects, an arrest of growth.

The spongy and vascular texture of the spleen, and the absence of valves, which allows the venous blood to regurgitate into the spleen when there is any obstacle to the circulation, has led to the opinion that the spleen is nothing more than a diverticulum intended to restore the equilibrium of the abdominal venous system whenever it is deranged; and this opinion, which we owe to Haller, is pretty generally admitted.‡ A modification of this opinion is, that the spleen fulfils, with regard to the circulation in general, and especially to the abdominal circulation, the office of the safety-tube of Wolf in chemical apparatus. It is certain that compression of the splenic vein in a living animal causes tumefaction of the spleen, which gives place to a quick collapse, as if by elastic contraction, when the pressure on the vein is removed: it is certain that the whole structure of the spleen indicates that this organ may undergo alterations of expansion and turgescence, and of collapse and flaccidity; and it is known that, during intermittent fever, the spleen may be felt below the false ribs, &c. But all this leads to presumptions, and not to certainty.

From the preceding considerations, it would follow that the spleen is only an accessory organ.

* The sensibility of the spleen is very important. In a living animal it may be cut or torn without any apparent signs of pain. Dogs have been seen devouring their own spleens, which had been drawn out of the abdomen! What a difference, in this respect, between the spleen and the intestine! and yet they derive their nerves from the same source.

† We cannot state, with Malpighi, that the spleen is the preparatory organ of the bile, because we have seen that it is extremely probable that the liver is concerned in the process of sanguification.

‡ May we not quote, in support of this view, the pain felt in the region of the spleen after violent running, which can only be referred to extreme distension of this organ?

THE ORGANS OF RESPIRATION.

General Observations.—The Lungs and Pleura.—The Trachea and Bronchi.—Development of the Lungs.—The Larynx—its Structure, Development, and Functions.—The Thyroid Gland.

After describing the digestive apparatus, the object of which is to elaborate solid and liquid materials for the reparation of the waste that occurs in the body, and, at the same time, to present a vast surface for the absorption of those materials, we naturally turn to the consideration of the *apparatus of respiration*, the object of which is to renew the vital properties of the blood by the action of atmospheric air in the lungs.

This latter apparatus, which is much less complex than the former, is composed, 1. Of the *lungs*, the essential organs of respiration; 2. Of the thorax, a cavity forming a sort of bellows, and having walls capable of alternately expanding and contracting; 3. Of a tubular apparatus, by which the lungs communicate with the external air, and which consists of the *bronchi*, *trachea*, *larynx*, *pharynx*, and *nasal fossæ*; for it is only accidentally, so to speak, and in order to render respiration more certain, that air is allowed to pass through the mouth.

The thorax has been already described (see Osteology and Myology), and also the pharynx, which is common to both the respiratory and digestive passages.

The nasal fossæ, situated at the entrance of the respiratory passages, form the natural passages for the introduction of the air, and, at the same time, serve for the reception of the organ of smell, by which sense we may consider the qualities of the air are examined. Their bony framework has been already described under osteology. The pituitary membrane which covers the irregular surfaces of these fossæ will be described in the article devoted to the organs of the senses; we shall only consider, in this place, the lungs, the trachea, and the larynx.

The Lungs.

The *lungs* (*pulmones*; πνεύμων, from πνέω, to breathe, *p p*, *figs.* 155, 170, 171) are the essential organs of respiration. While the presence of an alimentary canal is the attribute of all animals, that of lungs is limited to those vertebrata which live in the air, different modes of respiration prevailing in the other classes.

Number.—The lungs are two in number; but, as the air which penetrates them is received from one tube, and the blood circulating through them is derived from one vascular trunk, they must be regarded as separated parts of a single organ; by this arrangement, respiration is rendered certain, and its unity maintained.

Situation.—The lungs are *situated* (*p p*, *fig.* 155) in the thoracic cavity, which is, in a great measure, occupied by them, and effectually protects them from the action of external agents; they are placed on each side of the heart (*h*, *figs.* 155, 170, 171), with which, physiologically, they are so directly connected; they are separated from each other by the mediastinum (*m*); hence the independence of the two cavities in which they are contained. Being separated by the diaphragm from the stomach, the liver, and all the other abdominal organs, they are so enclosed in all directions as not to be liable to displacements, or, rather, such displacements are only partial, and due to a loss of substance in the walls of the cavity in which they are placed.

Size.—The size of the lungs necessarily corresponds exactly with the capacity of the thorax, and therefore, like it, is subject to variations; and as, on the one hand, the size of the lung is generally a measure of the energy of respiration, and, on the other, the energy of respiration is a measure of the muscular strength, one cannot be astonished that a capacious chest, coinciding with broad shoulders, should be the characteristic of a sanguine temperament and athletic constitution.

In the natural state there is neither air nor watery fluid between the parietes of the thorax and the surface of the lung. The absence of air or other fluid may be shown after death as well as upon a living animal, by raising the inter-costal muscle from the costal pleura, so as to preserve the latter,* or by removing the muscular fibres of the diaphragm. It is then seen that the lung is always in contact with the parietes of the chest; in some subjects it even appears as if ready to escape; but scarcely is the thorax opened when the lungs instantaneously collapse, in consequence of the expulsion of the air from their interior. It is very common to find a small quantity of serum in the cavity of the pleura, but it is probable that this fluid did not exist during life. There is no space to be filled up here as in the cranium.

The differences in the size of the lungs depend, 1. On the state of inspiration or expiration. Attempts have been made to determine the difference from this cause by estimating the volume of air inspired or expired; it is about thirty cubic inches, and may be increased to forty in forced inspiration or expiration. 2. On age; thus, in the fœtus, the lungs are relatively much smaller than after birth. 3. On some morbid condition. The

* In order to demonstrate the absence of air, we may also repeat another experiment performed by Haller, which consists in opening the thorax of a dead body under water.

lungs diminish in size when the abdominal viscera encroach upon the thorax, either in ascites, in pregnancy, or in diseases of the liver, which organ has been found in some cases to become enlarged entirely by encroaching on the chest, and to extend as high up as the second rib. They diminish, also, when the heart is enlarged in aneurism, or when a large quantity of fluid is accumulated in the pericardium. In effusions into the thorax, the fluid takes the place of the lung; the latter gradually wastes, and is reduced to such a thin lamina, or to so small a mass, that it has sometimes been overlooked in a superficial examination; but if, in such cases, air be blown into the trachea, the organ appears of its full size, and gradually fills the remainder of the cavity. This extreme diminution of the lung, without any alteration of its substance, proves that the size of the organ is essentially dependant upon the air within it. Attempts have been made to calculate exactly the quantity of air contained in the cavity of the lungs, or, in other words, the capacity of these organs: according to one estimate, which can only be regarded as an approximation to the truth, it would seem to be about 110 cubic inches after expiration, and 140 inches after an ordinary inspiration.

When an effusion in the thorax has been very slowly absorbed, the lung of the affected side remains atrophied, and the thoracic cavity contracted, while the other lung acquires a very considerable size, so that the mediastinum is pushed to one side, and the healthy lung passes beyond the median line.* In certain cases of acute pneumonia, and in rickets affecting the thorax, we often see one of the lungs reduced to very small dimensions, while the other is very much enlarged.†

The size of the two lungs is not absolutely the same. In consequence of the heart projecting into the left cavity of the thorax, the transverse diameter of the left lung is not equal to that of the right; and on account of the projection of the liver into the right cavity, the vertical diameter of the right lung is less than that of the left. After allowing for these facts, the difference is in favour of the right lung. In determining the size of the lungs, we must bear in mind, that the lung as well as the thoracic cavity gains in one direction what it loses in another: elongated lungs, which are regarded as particularly liable to phthisis, have not seemed to me to be smaller than the lungs of a person of similar stature, but having a broad chest.

The *weight* of the lungs must be examined with reference to their specific gravity and to their absolute weight. The *specific gravity* of the lungs is less than that of any other organ, and even much less than that of water. Their lightness depends on the great quantity of air which penetrates them in every direction, so that the lungs rise to the surface of the fluid in which they are immersed. The specific gravity of the lungs presents some important differences depending on age. Thus, before birth, and in an infant that has died during birth, without having respired, the lungs sink in water; on the contrary, they swim when the infant has breathed; not because any change has taken place in the intrinsic nature of the organ, but because the air has insinuated itself into the cells. The estimation of the specific weight of the lungs constitutes what is called in legal medicine the *hydrostatic test*. In the adult, the lung always floats, notwithstanding any efforts which may be made to expel the air contained in the pulmonary cells; it seems as if the air enters in some way into the composition of the lung, and even in vacuo it cannot be completely extracted. The specific gravity of the lungs varies also from *disease*. Thus, lungs infiltrated with serum, or indurated by inflammation, being completely or partially deprived of air, on the presence of which their lightness depends, assume, in a greater or less degree, the appearance of compact organs, such as the liver or the spleen.

The *absolute weight* of the lung varies from similar causes. From *age:* thus, although the specific gravity of the fœtal lung is much greater than that of the adult, yet its absolute weight is considerably less. In infants that have not breathed, the weight of the body is to that of the lungs as 60 to 1, on an average, while in those that have breathed the proportion is as 30 to 1, so that the changes in the lungs resulting from respiration are such as to double their weight. We may easily conceive the great importance of this fact in legal medicine. This method of estimating the weight of the lungs is known by the name of the *static* test.

The absolute weight of the lungs varies much in *disease*. Healthy lungs are very light; diseased lungs may become eight or ten times heavier than natural, without increasing in size. The lungs almost always becoming engorged at their posterior border during the last moments of life, their weight must not be estimated from an ordinary corpse. It must undoubtedly have been from the examination of engorged lungs that authors have stated their average weight to be four pounds.

Colour.—The colour of the lungs varies according to age and disease. In the fœtus they are reddish-brown; after birth, rosy-white; in the adult and in the aged they are

* In a case of chronic induration of the left lung, the deviation of the mediastinum was so great, that the right lung was in relation with the left costal cartilages.

† The lungs become less increased in size from inflammation than most other organs; and this peculiarity is explained by the vesicular structure of the lung, the increase in size being effected at the expense of the cavity of the air-vesicles.

grayish-blue, and almost always marked by black spots, forming points, lines, or patches, and describing polygons more or less regular in figure. These black patches, which become much more numerous in advanced age, coexist with the black deposites in the bronchial glands, and probably depend upon the same cause; they lie below the serous covering of the lungs, and are very superficial, excepting in disease. The posterior part of the lung is usually of a reddish-brown colour, because it is distended with blood and serum. It has not been shown that this is altogether a post mortem condition, and the necessary consequence of the position of the corpse upon its back; many facts would, on the contrary, induce us to admit that it occurs antecedently to death.

Density, Crepitation, and Cohesion.—The lung, a spongy or aerial organ, so to speak, is the least dense of all the organs in the body; it yields to the pressure of the hand, and, if no cause prevents the escape of the air, it loses very much of its original size. I have remarked, when speaking of the spleen, that, under pressure, that organ emitted a peculiar noise, or, rather, gave rise to a sensation which might be compared to the crackling of tin, and that this sound was the result of rupture of the fibrous prolongations which traverse its tissue. Pressure of the lung causes a sensation and a sound somewhat analogous to the preceding; this sound is called *crepitation*. It may, in fact, be compared to the sound produced by the decrepitation of salt or the rattling of paper. This crepitation is only observed under a moderate pressure, and if the sensation communicated be strictly noted, we shall find that it is the feeling of a resistance overcome. On careful examination of the portion of the lung which has thus crepitated, bubbles of air are found under the pleura; in fact, emphysema is produced. Notwithstanding its slight density, the tissue of the lungs possesses tolerable strength; it resists laceration to a certain point; and all its parts are pretty firmly bound together.

Resistance to Distension.—The lung, though it yields to the finger without recovering itself at all, or only very imperfectly, is yet possessed of great elasticity, but such an elasticity as is in harmony with its functions. It also offers powerful resistance to any distending force. Thus, if a stopcock be adapted to the trachea of a dead body, and the lungs be inflated by means of bellows having double valves, the pulmonary tissue becomes extremely tense and hard; the effort necessary to rupture some of the air-cells, and produce emphysema, is surprising. In opposition to those authors who speak of the dangers of artificial insufflation of the lungs of asphyxiated persons, I have in vain endeavoured, with all the force I could employ in expiration, to produce a laceration of some of the pulmonary cells: and how, it may be asked, without great means of opposing every attempt to dilate them beyond measure, could the lungs resist the force to which they are subjected during violent exertions?

Elasticity.—The lungs are very elastic, *i. e.*, they have a constant tendency to collapse, and to free themselves of part of the air contained in their cells. It is this elasticity which maintains the vaulted form of the diaphragm after the abdomen has been opened, and occasions the lung to collapse suddenly, when an opening is made in the parietes of the thorax: before the chest is opened, the atmospheric pressure, operating through the trachea, prevents the elasticity of the lungs from being brought into action.* This elasticity is also shown by the quick collapse of inflated lungs. I have been accustomed to demonstrate, in my lectures, perfectly healthy lungs, preserved in alcohol. After having shown how far the inflation of the lungs may be carried, I open the stopcock used in the experiment, and the lungs instantly collapse, driving out the air with considerable force.

Shape and Relations.—The lungs are shaped like an irregular cone, deeply excavated on the inner side, with the base below and the apex above; they present for consideration an external and an internal surface, an anterior and a posterior border, a base, and an apex.

Outer or Costal Surface.—This surface is irregularly convex, corresponding to the concavity of the thoracic parietes, with which it is in contact, and on which it is exactly moulded; it is in relation with the costal pleura, which separates it from the ribs and the intercostal muscles. It presents a deep fissure, the *inter-lobular* fissure, which penetrates the entire thickness of the lung as far as the root. This fissure commences below the apex of the lung (*v'*, *fig.* 171), passes downward and forward (*v'*, *fig.* 170) as far as the anterior part of the base, upon which it encroaches a little at its termination. It is simple in the left lung (*v'*), but is bifurcated in front in the right; the lower division of this bifurcation continues in the original direction; the upper division (*w*) passes upward and forward. The left lung, therefore, is divided into two portions or *lobes*, distinguished as the *superior* (*s'*) and the *inferior* (*u'*); while the right is divided into three *lobes*, the *superior* (*s*), the *inferior* (*u*), and the *middle* (*t*). Of these lobes, the inferior, comprising the base of the lung, is larger than the superior, which forms the apex; the middle lobe is the smallest. The contiguous surfaces of these lobes are plane, and covered by the pleura: they are often adherent, and sometimes purulent matter collects be-

* [The lungs do not collapse until the chest is opened, because the atmospheric pressure is exerted *only* on the inner surface of the lungs, their outer surface being protected from it by the unyielding parietes of the thorax. When this protection is removed, the pressure on both surfaces is equal, and the elasticity of the pulmonary tissue is then enabled to act.]

Fig. 170.

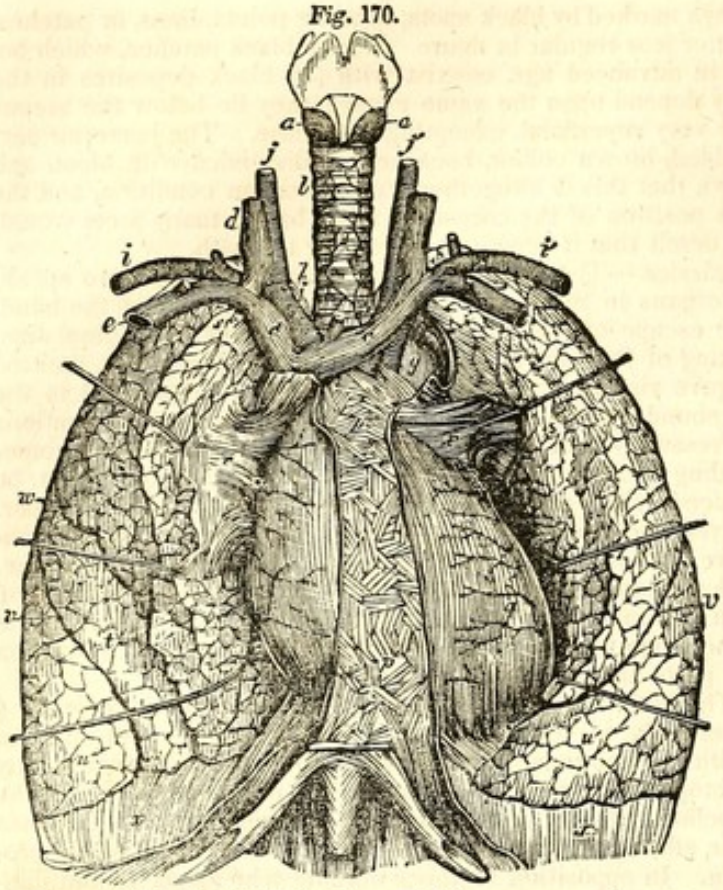

tween them, and, being surrounded on all sides by adhesions, it hollows out, as it were, a cavity for itself, at the expense of the corresponding surfaces of the lobes, and thus simulates an abscess of the lung.

There are many varieties in the arrangement of these lobes. Thus, sometimes, the fissures, and more especially those which bound the middle lobe, do not reach as far as the root of the lungs, but are only slightly indicated. Three lobes are not unfrequently found in the left lung, or four in the right; there were four lobes in the lung of a negro lately presented to the anatomical society.

Examples are on record of lungs with five, six, and even seven lobes, but in general this multiplicity of lobes is only rudimentary, and represents the normal condition in the majority of animals. The dog, the sheep, and the ox have seven lobes in their lungs

Inner or Mediastinal Surface.—This corresponds to the mediastinum (*p p*). On it we observe the *root* (*r*) of the lungs, that is, the part at which they communicate with the trachea, through the bronchi, and receive and emit their bloodvessels. This root occupies a very limited space upon the inner surface, one inch in height, and half an inch in breadth; it is situated at the junction of the posterior with the two anterior thirds of this surface, at an almost equal distance from the apex and the base.

That part of the inner surface of the lung which is behind the root corresponds to the vertebral column and the posterior mediastinum, in which are found, on the left side, the descending aorta and the upper part of the thoracic duct; and on the right side, the vena azygos, the œsophagus, and the lower part of the thoracic duct.

All that portion of the inner surface which is in front of the root corresponds with the anterior mediastinum, and is excavated to receive the heart (*l*); and as the heart projects more to the left than to the right side, it follows that the left lung, which corresponds to the left border and apex of the heart, and higher up to the arch of the aorta (*g*), is more deeply excavated than the right lung, which corresponds to the right auricle (*m*) and the vena cava superior (see *fig.* 170). We can obtain an accurate idea of the manner in which the lungs are excavated for the reception of the heart only by examining them when inflated; we are then struck with the propriety of the expression of Avicenna, who called the lung the *bed of the heart*. We can also understand how diseases accompanied with enlargement of the heart may directly influence the respiration, by reducing the size of the lungs. These organs, it may be remarked, are here in apposition with the heart through the medium of the pericardium and the pleura. I should not omit to mention their relation with the phrenic nerve, which is affixed closely to the pericardium by the pleura. In the fœtus, the lungs are in relation anteriorly with the thymus gland, which presses them backward.

The *anterior border* is thin and sinuous, presenting on the left side two notches, one inferior and very large, corresponding to the apex of the heart; the other superior and small, for the subclavian artery. On the right side there are also two notches, but smaller than those on the left; an inferior for the right auricle, and a superior for the vena cava superior.

The *posterior border* (*fig.* 171) is the thickest part of the lung. It fills the deep costo-vertebral groove situated at each side of the dorsal portion of the spine.

The *base* is concave, and exactly moulded upon the convexity of the diaphragm (*x*, *fig.* 170); it is, therefore, a little more excavated on the right than on the left side. Its circumference is very thin, and slightly sinuous. Like the diaphragm, the base of the lung forms an inclined plane from before backward and downward; and it occupies the deep angular groove formed behind, between the diaphragm and the parietes of the thorax. On account of this obliquity of its base, the vertical diameter of the lung is much

greater behind than in front; and as the posterior border is the largest part of the organ, it may be conceived that an examination of the lung should be directed chiefly to this part. It is of importance to form a correct idea of the manner in which the base of the right lung and the convexity of the liver are arranged with regard to each other. The liver is, as it were, received into the concavity of the base of the lung so completely, that the posterior part of this base is almost on a level with the lower surface of the liver. The relation of the liver with the base of the lung, which is only separated from it by the diaphragm, explains how abscesses and cysts of the liver may burst into the lung.

The *apex* is obtuse, and projects above the first rib, a very strongly-marked impression of which is found on its anterior surface. I have observed that the height of the portion which passes above the first rib varies in different subjects. In several I found it from an inch to an inch and a half. In an aged female, in whom the base of the thorax was extremely constricted, the apex of the lung (*i. e.*, the part bounded below by the depression corresponding to the first rib) was two inches in height. May not the mechanical pressure of the inner edge of the first rib upon the apex of the lung exercise some influence in the very frequent development of tubercles in that region? In order to form a correct idea of the apex of the lung, that organ must be previously inflated.

The whole surface of the lung is free, smooth, and moistened with serum; it is connected with the rest of the body only by its root, which attaches it to the bronchi and the heart, and by a fold of the pleura. It is very rare to meet with lungs free from adhesions upon their surface, so that the older anatomists regarded these adhesions, whether filamentous or otherwise, as natural formations.

Structure of the Lungs.

On examining the structure of the lungs, we find in each an investing membrane or serous sac, formed by the pleura, and a proper tissue. We shall commence with the pleura.

The Pleura.

Dissection.—In order to obtain a view of the costal pleura, saw through the six or seven upper ribs behind, near their angles; cut through the cartilages of the same ribs, at a distance of some lines from their sternal articulations; remove the intermediate portions of ribs and intercostal muscles with great care, so as to leave the costal pleura untouched. The cavity of the pleura may be inflated.

In order to see the mediastinal and pulmonary portions, the costal pleura must be opened, and its continuity traced.

The *pleura* (πλευρὰ, the side) is a serous membrane, and, therefore, a shut sac, which is extended partly over the parietes of the thorax, and partly over the lungs. There are two pleuræ, one for the right and the other for the left lung. The following is their general arrangement:

The pleura lines the parietes of the thorax, the ribs, and the diaphragm, forming the *pleura costalis* (*p p, fig.* 151) and *pleura diaphragmatica;* it invests the entire surface of the lung, constituting a sort of integument for it, and forming the *pleura pulmonalis;* lastly, it is applied to the pleura of the opposite side, so as to form a septum between the two lungs; this part is the *mediastinal pleura.*

In order to facilitate the description of the pleura, we shall suppose it to commence at a certain point; and then, following its course without interruption, shall trace it back to the point from which we started. If we thus commence at the sternum, we shall find that it lines the internal surface of the thorax, being applied to the ribs and the intercostal muscles, and covering the mammary vessels and lymphatic glands in front, the intercostal vessels and nerves behind, and the ganglia of the great sympathetic opposite the heads of the ribs: below, it is reflected upon the diaphragm, and covers the whole of its upper surface: above, it is reflected beneath the first rib, and terminates in a cul-de-sac, intended for the reception of the apex of the lung, and projecting more or less above that rib.

Having reached the sides of the vertebral column, the two pleuræ are reflected forward as far as the root of the corresponding lung, and form, by their approximation, a septum, which is called the *posterior mediastinum.* This septum contains within it the aorta, the œsophagus, the pneumogastric nerves, the thoracic duct, the vena azygos, a considerable quantity of cellular tissue, a great number of lymphatic glands, and the trachea. We see, then, that the two pleuræ are by no means in immediate contact.

Arrested, as it were, by the root of the lungs, the pleura is reflected outward behind that pedicle, passes over a small portion of the pericardium, covers all that part of the inner surface of the lungs which is behind its root, and also its posterior border and its outer surface, dips into the inter-lobular fissure, so as completely to invest the contiguous surfaces of the lobes, is reflected over their anterior margin upon their inner surface, reaches the root of the lung, and covers its anterior surface, is then reflected forward upon the side of the pericardium, in front of which it is applied to the pleura of the op-

posite side, and at length arrives at the border of the sternum, from which we had supposed it to commence.*

The antero-posterior septum formed by the two pluræ, between the sternum and the root of the lung, is called the *anterior mediastinum* (*m*, *fig.* 155).† This septum is not vertical nor median, like the posterior mediastinum, but is directed downward and to the left side, an arrangement that is connected with the oblique position of the heart, which encroaches more upon the left than the right cavity of the thorax. It follows, from this, that the upper part of the anterior mediastinum (*p p*, *fig.* 170) is behind the sternum, while its lower portion is behind the left costal cartilages, and hence the interior of this mediastinum may be reached without opening the cavity of the pleura, by introducing an instrument close to the left border of the sternum, opposite the fifth rib. The anterior mediastinum is narrow in the middle, and expanded above and below, like an hour-glass. The upper cone or expansion is very much developed in the fœtus, and is occupied by the thymus gland, which is afterward replaced by cellular tissue: the lower cone or expansion is much larger, and contains the heart and pericardium, the phrenic nerves, and in front of the heart a large quantity of cellular tissue.

This latter, which is so abundant in the anterior mediastinum, communicates freely above with the cellular tissue in front of the neck, and below with that of the abdominal parietes, through a triangular interval existing in the diaphragm behind the sternum.

This double communication explains how the pus of an abscess formed in the neck or in the mediastinum may reach the surface in the epigastric region.

The pleura has two surfaces, one an external, the other internal.

External or Adherent Surface.—This does not adhere with equal firmness to all the *parts* which it covers. The *pleura costalis* is but slightly adherent, and may be separated from the ribs and the intercostal muscles with the greatest ease. It is sometimes raised in the situation of these muscles by subjacent adipose tissue. It is strengthened by a layer of fibrous tissue, which, notwithstanding its tenuity, performs an important part in diseases of the chest; it explains why abscesses formed in the parietes of the thorax so seldom open into the cavity of the pleura, and why effusions into the pleura are so rarely discharged externally. The *diaphragmatic pleura* is more adherent than the costal. We sometimes find here, especially round the pericardium, some large fatty appendages, resembling the appendices epiploicæ of the great intestine. The pleura is extremely thin upon the lungs (*pleura pulmonalis*), where it is not strengthened by any fibrous tissue; and although it is more adherent here than the parietal pleura, still it can be easily demonstrated. The *mediastinal pleura* is united to the parts contained within the mediastinum by very loose cellular tissue, but it adheres more firmly to the sides of the pericardium, to which the phrenic nerves are closely applied.

The *internal* or *free surface* is smooth,‡ moistened with serum, and in contact with itself throughout its entire extent, as is the case in all serous membranes. The adhesions so commonly met with here are altogether accidental. The structure of the pleura is cellular.◊ It is doubtful whether it receives any arteries and veins. The vascular network, which is sometimes so highly developed after pleurisy, does not belong to it, but is situated upon its external surface. No nerves have been traced into this membrane.

Uses.—Each pleura forms an investment for the corresponding lung, separates it from the parietes of the thorax and from the other viscera, and, at the same time, facilitates its movements upon the walls of the thoracic cavity by means of the serosity, which is constantly exhaled and absorbed at its internal surface.

The Proper Tissue of the Lungs.

The pulmonary tissue appears like a spongy or vesicular texture, the cells of which are filled with air. This is rendered apparent by the most simple inspection of the surface of an inflated lung, either with the naked eye or with a lens. A microscopical examination of sections of a dried lung shows the existence of this cellular or vesicular texture in the most evident manner throughout the entire organ. The different shapes of the cells and their unequal size may also be distinguished.

But what are the relations of the cells with each other? Do they communicate throughout the whole extent of the lung, or only within a determinate space, or are they independent of each other? In order to resolve these questions, it is necessary to examine the lung of a large animal, of the ox, for example, the structure of which is similar to that of the human lung, on which the same observations may be subsequently re-

* [A fold of the pleura reaching from the lower edge of the root of the lung downward to the diaphragm, is called the *ligamentum latum pulmonis*. It is triangular; its base is attached to the diaphragm, one side to the lung, and the other to the mediastinum.]

† According to Meckel, the anterior mediastinum is the portion of the septum situated in front of the heart, just as the posterior mediastinum is the part situated behind that organ.

‡ [It is covered with a squamous epithelium, and cilia have been observed upon it in some of the mammalia.]

◊ [Beneath the pleura another cellular layer may be demonstrated; and in the lung of the seal and leopard an elastic coat is said to exist.]

peated. We then observe that the surface of the lung is traversed by lines, dividing it into lozenge-shaped compartments; and if the lung be previously inflated, it will be seen that the surface is slightly depressed opposite these lines, but that it bulges out between them. If, by means of a delicate tube, air be blown under the pleura, or if the lung be forcibly inflated through the trachea, so as to rupture some of the vesicles and produce emphysema, we then perceive that the lines bounding the lozenge-shaped intervals correspond to thin layers of very delicate, but tolerably loose cellular tissue, which divide the lung into a large number of groups or cells, which may be completely separated from each other by dissection, until at last we arrive at the pedicles by which they are united into a common mass.

These groups of cells are the *lobules of the lung;* the cellular tissue uniting them is the *interlobular cellular tissue*, which is extremely delicate, never loaded with fat, but often infiltrated with serosity, and is subject to emphysema. A great number of lymphatic vessels traverse this cellular tissue: they are often visible to the naked eye, and are always easily injected; they pass deeply into the substance of the lung.

The pulmonary lobules do not communicate with each other, but each is perfectly independent of the rest. This fact is shown by inflation; it is most distinctly proved by dissection; and an examination of the lungs of the fœtus will remove all doubts concerning it. The pleura and the interlobular cellular tissue having but little strength in the fœtus, the lobules become separated without dissection, resemble grapes attached to their footstalks, and hang from a common stem, formed by the divisions of the bronchi and the pulmonary vessels.

This independence of the lobules is also proved by pathological anatomy: thus, we continually find one lobule infiltrated with serum, with pus, or with tubercular matter, in the midst of perfectly healthy lobules.

Each lobule, then, is a small lung, and may act independently of those by which it is surrounded. I have satisfied myself, by a great number of experiments, that the lobules are not all equally permeable to the air, and that a moderate inflation of the lungs, made as much as possible within the limits of an ordinary inspiration, does not, perhaps, dilate one third of the pulmonary lobules. I have observed, and this fact appears to me of great importance, that the most permeable lobules are those of the apex of the lung; and this, perhaps, will explain the greater frequency of tubercles in that situation.* There are some lobules in the lung which are kept, as it were, in reserve, and only act in forced inspirations.†

The pulmonary lobules vary much in shape; all the superficial ones resemble a pyramid, the base of which is at the surface of the lung; the deep lobules lie along the bronchial tubes, have *numerous* facettes, and are exactly fitted to each other, like the fragments of mosaic work; but they are so irregular in form, that it would be equally difficult and useless to give a description of them.

The lung, then, is a collection of an immense number of lobules, placed along the bronchial tubes and pulmonary vessels, which serve as a support and framework for them, and to which they are appended by pedicles; they are united to each other by serous cellular tissue, and are all covered by one great cell formed by the pleura, which merely unites together this great number of parts.

The problem of the texture of the lungs reduces itself, therefore, to the determination of the structure of a single lobule; but the difficulty is rather postponed than got rid of, for each lobule is a little lung, receiving an air-tube and an artery, and giving out several veins and lymphatics.

Before describing the arrangement of the air-tube, and the vessels in each lobule, we shall say a few words upon the structure of the lobule itself.

Each lobule is an agglomeration of cells and of vesicles, all of which communicate with each other.‡ These cells are always full of air. Their size is not always the same. M. Magendie has already shown that the pulmonary cells are smaller in the infant than in the adult, and smaller in the adult than in the aged.◊ Nor is the size of the different cells in the same lobule constantly uniform. All the cells of the same lobule communicate, but they are not all equally permeable.‡ Thus, in a given degree of inspiration, some cells only are distended, while others require a greater degree of dilatation. The septa between the cells of a lobule are incomplete,‡ and consist of filaments or lamellæ; and the reticulated arrangement of the cells, which is so evident to the naked eye in the lung of the frog, seems to me to represent with tolerable accuracy the appearance of the human lung under the simple microscope.

* It is rather too much to say that pneumonia almost always attacks the base of the lungs; this disease has no special locality; it perhaps as often affects the apex as the base.

† In ordinary respiration, perhaps not more than one third of the lung is in action; exercise and yawning are probably required, from the necessity for bringing the whole lung into action. Thus, a great number of tubercles may exist in the lung without manifesting their presence by impeding ordinary respiration. It is in violent inspiration, in exercise, in efforts of the voice, and in all movements during which the whole of the lungs is called into play, that we detect the existence of a lesion in the central organ of respiration.

‡ See note, p. 419.

◊ Diseases have a remarkable influence upon their size; in chronic catarrh, and in some varieties of asthma, we find the pulmonary cells excessively dilated. Laennec has called this dilatation pulmonary emphysema.

With regard to the structure of the cells,* we cannot admit the existence of muscular fibres round them; the anatomist is unable to demonstrate them, and physiology rejects them. The most probable opinion is, that they are formed of dense cellular tissue, or of an elastic fibrous tissue, and that the bloodvessels are ramified upon their parietes.

The Air-tubes.

The air-tubes of the lungs consist of the *trachea*, the *bronchi*, and their *divisions*.

The Trachea.

The *trachea* (from τραχὺς, rough), or *asperia arteria* (*b*, *figs.* 170, 171), is the common trunk of the air-tubes of the lungs; it is situated between the larynx (*a*, *fig.* 171), of which it is a continuation, and the bronchi (*p p'*), which are nothing more than its bifurcation in front of the vertebral column, extending from the fifth cervical to the third dorsal vertebra.† In this situation, however, it is movable, and may easily be pushed to the right or left side. This mobility has occasioned serious accidents in tracheotomy, and has led to the invention of an instrument for fixing the trachea.‡ Its direction is vertical; it occupies the median line above, but appears to be slightly deflected to the right side below. I have often seen it somewhat flexuous, but these slight deviations only existed when the neck was bent upon the thorax; they disappeared during extension.

Dimensions.—The length of the trachea equals that of the space between the fifth cervical and the third dorsal vertebræ, and is, therefore, from four to five inches; but it varies according as the larynx is raised or depressed, and as the neck is flexed or extended. The difference produced in its length, by the utmost elongation and shortening, may be about half its entire length, *i. e.*, from two inches to two inches and a half; its shortening is limited by the contact of its cartilaginous rings.§

The *diameter* of the trachea is determined by that of the cricoid cartilage of the larynx; it is much wider in the male than in the female, and after than before puberty. Individuals who have been many years labouring under chronic catarrh have the air-passages remarkably large, especially the trachea. The mean diameter of the trachea is from ten to twelve lines in the male, and from nine to ten in the female. The trachea is not of equal diameter throughout; it is almost always dilated at its lower extremity, where it bifurcates. In some subjects it gradually increases in size from above downward, and resembles a sort of truncated cone, with the base below.

External Surface, Form, and Relations.—In front and on the sides the trachea is cylindrical (*fig.* 170), but is flattened behind (*fig.* 171), so that it resembles a cylinder, the posterior fourth or third of which has been removed. The external surface is rough, and, as it were, interrupted by circular ridges, which correspond to the cartilaginous rings. The relations of its external surface must be examined in the neck and in the thorax.

Relations of the Cervical Portion (*x*, *fig.* 140).—In *front* the trachea is in relation with the thyroid body, the isthmus of which being sometimes very narrow and sometimes very largely developed, covers a greater or less number of the rings of the trachea. In general, the first ring of the trachea is above the isthmus of the thyroid. Below the thyroid body the trachea is in relation with the sterno-thyroid muscles, the edges of which are separated only by the linea alba of the neck; also with the cervical fascia, the thyroid plexus of veins, a considerable quantity of cellular tissue, the thyroid artery of Neubauer, when it exists, and the brachio-cephalic artery, which always passes a little above the supra-sternal notch. All these relations are of the greatest importance in reference to the operation of tracheotomy. *On the sides* the trachea is embraced by the lateral portions of the thyroid body, and, therefore, in diseases of that organ, the corresponding part of the trachea is deformed, flattened on the sides, and elliptical, or even triangular. The compression of this canal may be carried so far as to produce suffocation. The common carotid artery and the pneumo-gastric nerve are in contact with it on either side; and hence the possibility of wounding that artery in the operation of tracheotomy. A great number of lymphatic glands are situated upon the sides of the trachea, and may become so large as to prevent the passage of the air. Lastly, all the relations of the trachea, excepting those with the thyroid body, take place through the medium of a very loose cellular tissue in which this canal is imbedded.

Behind, the trachea is flat and membranous, and is in relation with the œsophagus, which projects a little beyond it on the left side, and separates it from the vertebral col-

* See note, p. 419.

† The term trachea is derived from the roughness produced by the projection of the cartilages of the windpipe. The application of the term arteria, by the ancients, to the vessels which carry red blood, arose from a serious anatomical mistake. These vessels being habitually empty in the dead body, it was supposed that they contained air during life; and hence the name artery, which they still retain.

‡ By a surgeon of the name of Buchot. The mobility of the trachea is an obstacle to its puncture in the operation of tracheotomy.

§ The elongation and shortening of the trachea is much more limited in man than in birds, in which the rings of the trachea are moved by longitudinal muscles, and can be drawn within each other; in the greatest possible degree of shortening three rings overlap each other, so as to equal only one in height; and, therefore, the trachea of a bird may be diminished by two thirds These peculiarities of structure are connected with the different uses of the parts; the trachea in man and other mammalia merely conveying the air (*un porte-vent*), while the trachea of birds conveys the voice (*un porte-voix*).

umn. The left recurrent nerve is situated in the groove formed between the trachea and the œsophagus in this direction; the right recurrent nerve lies behind the trachea.

The immediate relation of the trachea with the œsophagus explains why foreign bodies arrested in the gullet may produce suffocation, and require the performance of tracheotomy.

The softness and flexibility of the trachea opposite the œsophagus have appeared to some physiologists to be intended merely to facilitate the dilatation of the latter during the passing of the food; but we shall see that the air-tubes continue to be membranous behind, even where they have no relation with the œsophagus, and comparative anatomy, which shows the trachea to be cylindrical in the bird, and angular behind in the ox, the sheep, &c., most completely refutes this opinion.

Relations of the Thoracic Portion of the Trachea.—In the thorax, the trachea occupies the posterior mediastinum. It corresponds in *front*, proceeding from above downward, with the sternum and the sterno-thyroid muscles; with the left brachio-cephalic vein (*c*, *fig.* 170); with the brachio-cephalic artery (*h*), an aneurism of which may open into the trachea; its left side is, as it were, embraced between the brachio-cephalic artery (*h*) and the left common carotid (*j*); with the back part of the arch of the aorta (*g*), which rests immediately upon it, and hence the dyspnœa which so generally accompanies aneurism of the aorta, and the frequency of its bursting into the windpipe; and, lastly, lower down, with the bifurcation of the pulmonary artery, which corresponds with that of the trachea.

The trachea is in relation *behind* with the œsophagus, which separates it from the spinal column; and *on the sides* with those portions of the pleuræ which form the mediastinum, with the pneumogastric nerves, and with the upper part of the recurrent nerves.

In all its thoracic portion the trachea is surrounded by numerous lymphatic vessels and glands, and by a loose and very abundant cullular tissue, which communicates with that of the cervical region. These lymphatic vessels and glands with the loose cellular tissue are the parts immediately adjoining the trachea; and it may readily be conceived that enlargement of the glands may be productive of serious consequences.

Internal Sarface.—The internal surface of the trachea is of a rosy colour, and presents the same circular ridges as the external surface, but they are more distinct. It is also remarkable in its membranous portion for the projection of certain vertical fasciculi, to which we shall again refer when speaking of the structure of these parts.

The Bronchi.

The *bronchi* (βρόγχος, *gutter*, *p p*, *fig.* 171) are the two branches formed by the bifurcation of the trachea, which spread out from each other at a right or a slightly obtuse angle; one (*p*) is intended for the right, the other for the left (*p'*) lung. A tolerably strong triangular ligament exists at the angle of the bifurcation, and seems intended to prevent too great separation of the bronchi.

Fig. 171.

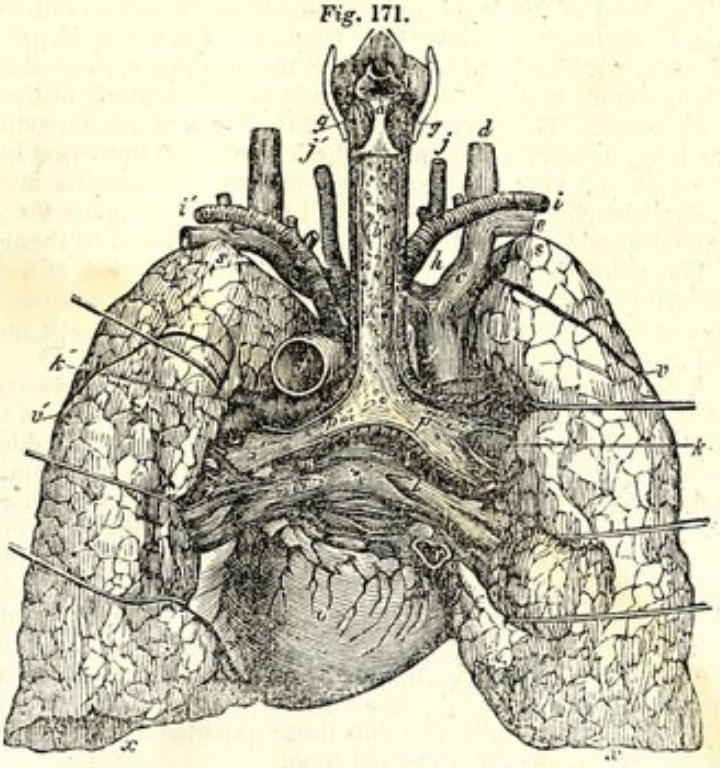

The bronchi differ *from* each other in many respects; first, in *width*. The right bronchus is much wider than the left, and its diameter is not much less than that of the trachea. In a female whose trachea was ten lines in diameter, the right bronchus was eight, and the left five. This difference in width corresponds with the difference in the size of the two lungs, and may afford a tolerably correct measure of that size; they differ also in *length*, the right bronchus being one inch in length, the left two; also in *direction*, the right bronchus passing less obliquely than the left, probably because it enters the corresponding lung sooner than the latter; and, lastly, in their *relations*. Thus, the right bronchus is embraced by the vena azygos, which forms a loop immediately above it, in order to terminate in the vena cava superior. The left bronchus is embraced above by the arch of the aorta (*g*), and has an important relation with the œsophagus behind, which it

crosses obliquely. Both are connected with the pulmonary plexus of nerves; both are surrounded with lymphatic glands, remarkable for their black colour, and for being frequently diseased, and which in some measure fill up the angle formed by the bifurcation of the trachea; and, lastly, both have the following relations with the pulmonary artery and veins. Each pulmonary artery (*k k'*) is situated in front of the corresponding bronchus, then passes above, and finally behind it. The two pulmonary veins on each side (*l l*, *m m*) are situated upon the same vertical plane as the corresponding artery; they pass upward in front of the artery and the bronchus, which is, therefore, behind the bloodvessels.*

The *shape* of the bronchi exactly resembles that of the trachea, *i. e*, they represent cylinders, the posterior fourth of which has been removed, and which are formed by parallel rings. The area of the two bronchi is greater than that of the trachea, in the same way as the area of the bronchial ramifications is greater than that of the bronchi themselves, so that the velocity of the expired air increases as it approaches the exterior.

At the root of the lungs the bronchi divide into two equal branches, but in a somewhat different manner. The upper branch of the bifurcation of the right bronchus is the smaller, and is intended for the upper lobe of the lung, in order to reach which it is bent slightly upward. The lower branch, which is larger, follows the original direction, and after passing about an inch, divides into two unequal branches, a small one for the middle lobe, and a larger one for the lower lobe. I have once seen a small bronchus proceeding from the lower part of the trachea directly to the apex of the right lung; the vena azygos passed between it and the regular bronchus.†

The secondary divisions are precisely the same in the two lungs; each branch of a bifurcation becomes bifurcated in its turn. All these ramifications pursue a diverging course, some ascending, others descending, and, after proceeding for a variable distance, they again bifurcate; so that, by separating a small portion of the pulmonary substance, we can see that several diverging series of tubes proceed in succession from a bronchial trunk, and pass outward into the tissue of the lung. The prevailing mode of division of the air-tubes in the lungs is that called *dichotomous*, viz., a division into two equal branches, which we shall afterward find to be the most favourable to the rapid transmission of the contents of any vessel. (See Arteries.) The two branches of a bifurcation separate at an acute angle, and a spur-shaped process, situated within the tube at the angle of division, cuts and divides the column of air. However, some small bronchial tubes are not unfrequently found arising directly from a principal division, to be distributed to the nearest pulmonary lobules. The number of subdivisions, which always corresponds with that of the pulmonary veins, is not so great as might at first be supposed; there are not many more than fifteen.

The form of the bronchial ramifications (*bronchia*) differs essentially from that of the *bronchi* themselves and of the trachea. They represent, indeed, a complete cylinder, which is not truncated behind; and the cartilages, instead of forming rings, have another arrangement, which I shall point out when speaking of their structure.

Relations.—The first divisions of the bronchi are surrounded, even in the substance of the lung, by very numerous and dark-coloured bronchial lymphatic glands, enlargement of which is a very frequent result of chronic bronchitis, and may cause suffocation.

The bronchial ramifications, as I have said, support the pulmonary lobules, which are applied to and moulded upon them, and are united to them by very loose cellular tissue.

The following are their relations with the branches of the pulmonary artery and veins: the artery always accompanies the bronchial ramification, and is situated behind it; the vein is often separated from it; the artery and vein are not unfrequently found interlaced around the corresponding bronchial tube.

Relations of the Bronchial Ramifications with the Pulmonary Lobules.—Each pulmonary lobule has its bronchial tube. This tube is cylindrical, of uniform diameter throughout, and entirely membranous; having entered the lobule, it dilates into a small ampulla, and disappears. There can be little doubt that these small ampullæ have deceived Malpighi, Reisseisen, and others, who have stated that the bronchial tubes terminate in culs-de-sac; so that, according to these authors, each pulmonary cell is the termination of a particular bronchial tube. But it is evident that such cannot be the case, for, on the one hand, the bronchial tubes are not sufficiently numerous, and, on the other, it can be shown that only a single bronchial tube enters into each group of cells or each lobule. If we inject with tallow a lung which has previously been deprived of air, either by an effusion in the chest during life, or by an artificial one after death, it will be seen that the injection is divided into small globules or rounded tubercles, which correspond to so many pulmonary cells, and that these globules are all connected with a common pedicle, corresponding to the bronchial tube.

Reisseisen, who has made this injection, thinks that the granular appearance of the injected matter represents the culs-de-sac, into which it had penetrated.‡

* [In consequence of the oblique direction of the left bronchus towards the root of the lung, the corresponding pulmonary artery is placed somewhat above it, and the pulmonary veins below it; on the right side, the pulmonary artery is in the middle, the bronchus above, and the veins below.]

† This appears to be the natural arrangement in the sheep and the ox.

‡ [According to Reisseisen, each small bronchial tube, on entering its corresponding lobule, divides and sub-

Structure of the Trachea, Bronchi, and Bronchial Ramifications.

Structure of the Trachea.—The trachea is composed of a series of imperfect cartilaginous rings, separated by an equal number of fibrous rings, and hence it has a knotted appearance; these cartilages keep the canal permanently open. Had the trachea been entirely membranous, it would have collapsed during inspiration, which tends to produce a vacuum in the thorax, and this collapse would have prevented the entrance of the air. The number of the cartilaginous rings varies from fifteen to twenty. They are more prominent on the internal than on the external surface of the trachea. In some subjects they form two thirds, in others three fourths or four fifths of a circle. Each ring has two surfaces, one anterior and convex, the other posterior and concave; an upper and a lower edge, both of which are thin, and give attachment to the fibrous rings; and two extremities, which terminate abruptly, without being inflected or thickened. In general, there is but little regularity in the arrangement of these rings; they are not exactly parallel, nor are they of equal depth, which varies from a line to a line and a half, two, or even two lines and a half; and the same ring is often of unequal depth at different points. Two rings are often united for a certain extent, and sometimes a ring is found bifurcated; indeed, it is probable that differences in the number of the rings depend upon their thus uniting or dividing. They are sufficiently thin to allow of being compressed, so that the opposite surfaces may touch without breaking. Their elasticity enables them to recover their original position immediately, and thus permit free access to the air. They can only be broken when ossified, which is frequently the case in the aged.

The first ring and the two lower rings present some peculiarities. The first is broader than any of the others, especially in the middle line, and it is often continuous with the cricoid cartilage.*

The last ring of the trachea, which forms the transition between it and the bronchi, has the following characters: the middle part is prolonged considerably downward, and curved backward, forming a very acute angle, and is developed into a spur-shaped projection within the trachea, which separates the two bronchi. The two half rings resulting from this arrangement constitute the two first rings of the bronchi. The last ring but one of the trachea presents an angular inflection in the middle, less marked, however, than that observed in the lowest ring.

The Fibrous Tissue of the Trachea.—This is arranged in the following manner: a fibrous cylinder commences at the lower edge of the cricoid cartilage; the cartilaginous rings are situated within the substance of this cylinder in such a manner, that the thicker layer of fibrous tissue lies on their exterior, so that, at first sight, their internal surfaces would appear to be in immediate contact with the mucous membrane. In the posterior part of the trachea, where the cartilaginous rings are wanting, the fibrous tissue alone forms its basis or framework.

The Muscular Fibres of the Trachea.—If we carefully remove the fibrous tissue from the back of the trachea, opposite its membranous portion, we arrive at certain transverse muscular fibres, extending from one end of each ring to the other, and also occupying the intervals between the rings. The existence of these muscular fibres, which I have seen forming a layer half a line thick in certain cases of chronic catarrh, cannot be doubted. It is evident that their contraction must draw the ends of the rings towards each other, and therefore narrow the trachea, the diminution in the width of which is limited by the contact of the ends of the rings.

The Longitudinal Yellow Fasciculi.—In the membranous portion of the trachea, be-

divides in a certain uniform order into numerous twigs (*t*, *fig.* 172), which, extending towards the surface of the lobule, gradually decrease in diameter, but increase in number, and at length terminate in clusters of short, free, closed and rounded extremities (*c c*); these are the pulmonary cells, which vary from $\frac{1}{70}$ to $\frac{1}{200}$ of an inch in diameter. Not only are the several lobules independent of each other, but the cells of each lobule have no communication with one another except indirectly through the twig or twigs from which they proceed.

This view of the minute structure of the lung, which is opposed to the opinion of M. Cruveilhier, receives support from what is known concerning the development of the lungs, and from the analogy between these organs and the compound glands.

In *fig.* 172, after Reisseisen, *a* shows the natural size of the portion represented, magnified about nine diameters in *b*. The bronchial twigs and pulmonary cells are seen distended with air; the knots or projections (*d*) on the sides of some of the twigs indicate the commencement of other twigs, into which no air has passed.]

Fig. 172.

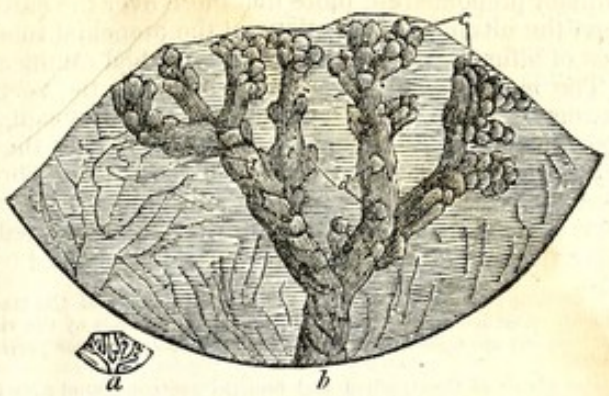

Minute structure of the lung.

* I have met with one case in which the thin upper rings of the trachea and the cricoid cartilage were joined together, but only on one side; the crico-thyroid muscle and the inferior constrictor of the pharynx evidently arose from the first ring of the trachea. This continuity of the cricoid cartilage with the trachea manifestly proves that the rings of the latter are cartilages, and not fibro-cartilages.

tween the muscular and the mucous layer, are situated a great number of parallel, longitudinal, yellow fasciculi, which, at first sight, resemble longitudinal folds, but are not at all effaced by distension; these fasciculi adhere to, and produce an elevation of, the mucous membrane, and opposite the bifurcation of the trachea they also divide, and are continued into the bronchi.

The nature of this tissue is not well known; it can only belong to the muscular or to the yellow elastic tissue, though I would rather incline to the latter opinion. According to either supposition, its use is to prevent too great an elongation of the trachea and the bronchi; actively in the one case, and by virtue of its elasticity in the other. Not unfrequently some longitudinal fasciculi are found behind the cartilaginous rings.

The Tracheal Glands.—If we carefully examine the posterior surface of the trachea, we find a certain number of ovoid flattened glands (see *fig.* 171), placed upon the outer surface of the fibrous membrane; and, by removing this membrane, we see a tolerably thick, but not continuous, layer of similar glands between the fibrous and the muscular coats; and, moreover, if either the inner or the outer layer of the fibrous tissue, situated between the cartilaginous rings, be removed, a series of much smaller glands will be found between these layers, occupying the intervals between the rings, and even extending behind them.

The Mucous Membrane.—This is a continuation of the mucous membrane of the larynx; it is remarkable for its tenuity, which permits the colour of the subjacent parts to be seen through it, and for its intimate adhesion to the structures covered by it. The longitudinal folds of which some authors speak do not exist; the yellow longitudinal fasciculi have been mistaken for them. Lastly, it presents a great number of openings, from which mucus can be expressed. These openings are nothing more than the orifices of the excretory ducts of the tracheal glands.*

The Vessels and Nerves.—The *arteries* of the trachea are derived from the superior and inferior thyroid. The *veins* are generally arranged thus: some venous trunks running along the inner surface of the trachea, beneath the mucous membrane, receive on each side, in the same manner as the vena azygos, small veins corresponding to the intervals between the cartilaginous rings, and then terminate in the neighbouring veins. The *lymphatic vessels* are very numerous; they enter the surrounding glands, which are of considerable size. The *nerves* are derived from the pneumogastrics.

Structure of the Bronchi.

The structure of the bronchi is exactly the same as that of the trachea. The left bronchus has ten or twelve cartilaginous rings; the right has five or six. They both possess transverse muscular fibres, longitudinal yellow fasciculi, glands, &c. Their *arteries* generally arise directly from the aorta, and are named *bronchial*. The *veins* of the right bronchus enter the vena azygos; those of the left terminate in the superior intercostal.

Structure of the Bronchial Ramifications (*Bronchia*).—The *fibrous* cylinder of the trachea and the bronchi is prolonged into the bronchial ramifications. The *cartilaginous* rings are remarkably modified beyond the first division of the bronchi; they become divided into segments, which together form a complete ring, so that there is no longer any membranous portion, properly so called, and the bronchial tubes become perfectly cylindrical. The segments above mentioned are oblong, curved, terminated by very elongated angles, and so arranged that they can overlap and be mutually received between each other. They are also united together by fibrous tissue. This arrangement of curved and angular segments exists as far as the last bifurcations of the bronchial tubes; but the size of the segments gradually diminishes, so that they soon form only narrow lines, and ultimately mere cartilaginous points. The fibrous and membranous constituents of the cylinder preponderate more and more over the cartilaginous laminæ, which disappear beyond the ultimate bifurcations of the bronchial tubes, being found last at the several angles of bifurcation: the ultimate bronchial ramifications are altogether membranous.

The *mucous* membrane is prolonged to the very last ramifications, where it becomes extremely thin. The longitudinal *elastic* fasciculi, which were limited to the membranous portion of the bronchi, are expanded over the entire surface of the bronchial tubes, beyond their first subdivision. The *muscular* fibres, which are confined to the membranous portion in the trachea and bronchi, become circular on the inner side of the bronchial ramifications, and form an uninterrupted but very thin layer, precisely resembling the circular fibres of the intestinal canal.† When we consider, on the one hand,

* *Structure of the Trachea.*—[The *muscular* fibres of the trachea are of the involuntary class (see p. 323), and are attached to the internal surface of the ends of the rings: the *longitudinal* fibres exist all round the trachea, but are collected into bundles on its membranous portion only; they are believed to consist of elastic tissue.

The *glands* of the trachea and bronchi are compound; its mucous membrane is covered with a columnar epithelium, and is provided with cilia, which urge the secretions upward towards the larynx.]

† *Structure of the Bronchi and their Branches.*—[According to Reisseisen, the *fibrous* cylinder gradually degenerates, in the smallest bronchial tubes, into cellular tissue; according to the same author, the *longitudinal* elastic and the *circular* fibres can be traced as far as the tubes can be opened. The contractility of the pulmonary tissue on the application of galvanism, recently observed by Dr. C. J. B. Williams, establishes the muscularity of the circular fibres of the bronchial tubes. The *mucous membrane*, as in the trachea, has a columnar and ciliated epithelium; it of course enters into and lines the pulmonary cells.]

the arrangement of the cartilaginous segments, which appear, as it were, shaped expressly for the purpose of fitting between each other at their extremities, and of constituting an apparatus capable of being moved, and, on the other, the existence of circular contractile fibres on the inner surface of these segments, we cannot doubt that they are moved upon each other, the extent of such motion being measured by the space they have to traverse in order to come into contact. When this is effected, the canals must be almost completely obliterated.*

The Pulmonary Vessels and Nerves.

Besides the trachea, the bronchi and the bronchial ramifications, which may be regarded as forming the framework of the lungs, these organs receive two sets of arteries, viz., the *pulmonary* and the *bronchial*, and give out two sets of veins, also called *pulmonary* and *bronchial*. A very great number of *lymphatics* arise from their interior, and from their surfaces, and they are penetrated by important *nerves*.

The size of the *pulmonary artery* is equal to, if not greater than that of the aorta; the *bronchial arteries* appear to be distributed upon the bronchi and their ramifications, which they exactly follow.

The *pulmonary veins* correspond with the pulmonary artery: they are two in number for each lung. The *bronchial veins* correspond with the bronchial arteries, and terminate in the vena azygos on the right side, and in the superior intercostal vein on the left.

Within the lung, as well as at its root, the pulmonary arteries and veins always accompany the bronchial tubes. The three vessels may be distinguished from each other upon sections of the organ by the following characters: the *artery* remains open, or rather so, and is of a white colour; the *bronchus* is also open, but of a more or less rosy colour, and contains a frothy mucus, which may be pressed out of it; the *vein* is collapsed, and much more difficult to be seen than the artery. The relations of these three kinds of vessels have not appeared to me to be constant. Notwithstanding the investigations of Haller, the arrangement of the bronchial with regard to the pulmonary arteries and veins is not well known.†

I ought to notice the easy communication between the arteries and the pulmonary veins and bronchial ramifications. The coarsest injection pushed with moderate force passes with the greatest facility from the arteries into the pulmonary veins and the bronchial tubes;‡ only inflamed portions of the lung have appeared to me to be impermeable.

The *lymphatic vessels*, both superficial and deep, are very numerous; they terminate in the bronchial and tracheal glands, the number and size of which sufficiently declare their importance. The black colour of these glands only begins to appear from the tenth to the twentieth year.

The *nerves* of the lungs are principally derived from the pneumogastrics, but they receive some branches from the ganglionic system. They form a large plexus behind the bronchi, with the divisions of which they penetrate into the substance of the lung. I should observe that there is only one great pulmonary plexus common to the two lungs; and on this circumstance the sympathy between the two is without doubt partially dependant.

Development.—According to Meckel, the lungs are among the latest organs to appear in the fœtus; they can only be distinctly recognised amid the other contents of the thorax, towards the end of the second month of intra-uterine existence.◊

* These anatomical facts explain, in a remarkable manner, all the phenomena of nervous asthma, nervous suffocation, &c.

† [The following are the results of Reisseisen's observations on this subject: the branches of the *pulmonary artery* accompany the bronchial tubes, and do not anastomose until their termination in a dense network of capillaries upon the walls of the air-cells. These capillaries have very thin coats; they are about one twentieth the diameter of a pulmonary cell, and the meshes which they form are scarcely so wide as the vessels themselves. From this network arise the branches of the *pulmonary veins*, which unite into larger and larger trunks, so as to correspond with the divisions of the pulmonary artery; these veins have no valves, and their caliber is not greater, perhaps less, than that of the artery.

Such is the chief mode of distribution of the pulmonary artery and veins; but both vessels, as indicated below, also communicate with the bronchial arteries.

The *bronchial* arteries are the nutrient vessels of the lung; some of their branches are distributed upon the air-tubes and to their lining membrane, even as far as the air-cells, upon all the pulmonary vessels and nerves, and to the bronchial lymphatic glands; while others, passing between the lobules, or upon the surface of the lung, anastomose with twigs from the pulmonary artery, and form, with the branches of the pulmonary vein, a vascular network in those situations, but more particularly beneath the pleura. The branches distributed to the larger bronchia and vessels, and to the lymphatic glands, and also some of the vessels composing the superficial network, terminate in the *bronchial veins*, which, however, cannot be traced very deeply into the substance of the lung. But by far the *greater number* of the bronchial arteries end in the pulmonary veins; for example, those distributed deeply to the smaller air-tubes and pulmonary vessels, and to the air-cells, and nearly all the vessels which enter into the formation of the interlobular and superficial network.]

‡ [This is due to *rupture* of the pulmonary vessels, which have exceedingly delicate coats, and are, perhaps, less supported by surrounding tissue than the vessels of other organs.]

◊ [The development of the lungs has been traced by various recent observers in frogs, birds, and mammalia, including man; according to Rathke and Müller, it closely resembles, in its early stages, that of the compound glands. In mammalia, the lungs appear at first as a protuberance upon the anterior part of the œsophagus, consisting of a soft mass, like the primitive blastema of a gland: within this substance a more opaque portion is formed, from which white lines extend, dividing and subdividing, and terminating in enlarged extremities;

The lung is smallest at the earliest period of its development. Its place appears then to be occupied by the thymus, which is the only organ that is seen when the thorax is opened, the lungs being situated behind it, upon each side of the vertebral column. The development of the lung takes place in an inverse ratio to that of the thymus, the lung increasing in proportion as the thymus diminishes. In the last two months of pregnancy the lung is completely developed, and fit for performing respiration.

The weight of the lung in the fœtus and in the adult presents some differences, which are well worthy of attention. During the whole period of intra-uterine life, the fœtal lung is specifically heavier than water; but as soon as the infant respires, it becomes much lighter, and floats in water.

Yet the absolute weight of the lung is sensibly increased, because it receives a much greater quantity of blood than it did previously. Before birth, the absolute weight of the lung to that of the whole body is as 1 to 60; after birth, it is as 1 to 30. It follows, therefore, that lungs which float in water, and which have acquired a much greater absolute weight than they would have had in the fœtus, must belong to an infant that has respired.

After birth, the lung participates in the development of the rest of the body. At the time of puberty it acquires the proportions which it subsequently presents. I have not observed that the lungs are smaller and lighter in the aged than in the adult.

The *colour* of the lungs varies considerably at different periods. In the earlier periods of development, the lung of the fœtus is of a delicate pink colour; subsequently it becomes of a deep red, like lees of wine, and remains so until the time of birth. After birth, it again becomes of a pink colour. Still later, from the tenth to the twentieth year, black spots become visible at different points along the lines which form the lozenge-shaped intervals on its surface. These spots subsequently unite into lines or patches, which give to the grayish surface of the organ a mottled appearance. The development of the black matter is so clearly the effect of age, that it is very rare not to find small masses of it in the apex or some other part of the lungs in the old subject. It is worthy of notice, that the black matter appears simultaneously on the surface of the lung, and in the lymphatic glands situated at its root and along the bronchi.

With regard to *structure*, it may be observed, that during the four or five earlier months of gestation, the pulmonary lobules are perfectly distinct from each other; they may be separated by very gentle traction, on account of the weakness of the pleura and cellular tissue which unites them, as compared with the pulmonary tissue itself. The cartilaginous rings begin to be visible after the third month.

Functions.—The lungs are the essential organs of respiration, that process by means of which the blood, though dark and unfit for supporting life before entering these organs, becomes red and vivifying. For the accomplishment of this function, the lungs receive, on the one hand, the atmospheric air, and, on the other, the venous blood, the whole of which, in the human subject, passes through the lungs. The air is not drawn in by any power resident in the pulmonary tissue itself, but by the muscular action of the parietes of the thorax; the blood is propelled into it by the right ventricle of the heart. While the blood undergoes the changes above mentioned, the atmospheric air loses a portion of its oxygen, which is replaced by carbonic acid gas. The manner in which these changes in the blood are effected is not yet well known.

The Larynx.*

It is necessary to have several specimens, from subjects of different ages and sexes, so as to be able to examine the general relations of the larynx in its natural situation; its cartilages separated from each other, its ligaments and muscles, its vessels and nerves, and its mucous membrane.

The *larynx* is a sort of box (*pixis cava*) or cartilaginous passage, consisting of several movable pieces, which form a complex apparatus intended for the organ of the voice. It is *situated* (*v, fig.* 140) in the median line, in the course of the air-passages, opening into the pharynx (3) above, and being continuous with the trachea (*x*) below: it occupies the anterior and upper part of the neck, below the os hyoides, the movements of which it follows, and in front of the vertebral column, being separated from it by the pharynx: it is covered by the muscles of the sub-hyoid region, which intervene between it and the skin, and it is, therefore, very liable to wounds, and may easily be reached by the surgeon. Its mobility allows of its being raised, depressed, and carried forward or backward, all of which movements are concerned both in deglutition and in the production of different tones of the voice. It may also be carried to the right or left side; but these lateral displacements are most commonly produced by external violence, or by the growth of tumours.

these are accompanied by bloodvessels, and are at first solid, but soon become hollowed out, into the trachea, bronchi, bronchial tubes, and air-cells.]

* The voice belongs essentially to the functions of relation, and, therefore, Bichat describes its organ after the apparatus of locomotion; but the anatomical connexions between the larynx and the respiratory organs are such that all animals provided with lungs have a larynx also, while the larynx disappears where the lungs cease to exist.

Dimensions.—The larynx appears like an expansion of the trachea, and has, therefore, been denominated its head, *caput asperæ arteriæ*. The exact determination of its dimensions, according to age and sex, or in different individuals, and their relations to the various qualities of the voice, would be extremely interesting in a physiological point of view. Its greater size in the male than in the female, and the development it undergoes in both sexes, but especially in the male, at the period of puberty, are among the most remarkable phenomena in the human economy.

Form.—It is cylindrical below, like the trachea, but is expanded above, and becomes prismatic and triangular. It may, therefore, be compared to a three-sided pyramid, the truncated apex of which is directed downward and the base upward ; it is perfectly symmetrical.

As the larynx is a very complicated organ, I shall describe, in succession, the numerous parts which enter into its composition. Being intended to admit of the continual passage of the air in the act of respiration, it must, therefore, present a constantly pervious cavity, having strong and elastic walls ; but as it is also the organ of the voice, it requires to be provided with a movable apparatus, subject to the will. We accordingly find in it a cartilaginous skeleton or framework, much stronger than that of the trachea ; certain articulations and ligaments, and a vocal apparatus, composed of four fibrous bands, or vocal cords ; muscles, which move the different pieces of the cartilaginous skeleton, and produce certain changes in the vocal apparatus indispensable for the production of sounds ; a mucous membrane, lining its inner surface ; glands, which pour out their fluid upon that surface ; and, lastly, certain vessels and nerves.

We cannot enter upon a general description of the organ until we have studied separately its constituent parts.

The Cartilages of the Larynx.—These are five in number, of which three are median, single, and symmetrical, viz., the *cricoid*, the *thyroid*, and the *epiglottis ;* and two are lateral, viz., the *arytenoid*, of which the *cornicula laryngis* are merely appendages. The cartilaginous nodules, described by some authors under the name of the *cuneiform cartilages*, and situated in the membranous fold extending from the arytenoid cartilages to the epiglottis, do not exist in the human subject.

The Cricoid Cartilage.—The cricoid or annular cartilage (*c c'*, *figs.* 173 to 177) forms the base of the larynx ; it is much thicker and stronger than any of the others. Its form is that of a ring, whence its name (κρίκος, a ring) ; it is narrow in front (*c*, *fig.* 173), where it resembles a ring of the trachea ; it is three or four times broader or deeper behind (*c'* and *c*, *fig.* 175), where it forms by itself alone the greater part of the larynx, being there about an inch in height. *In front*, its *external surface* is sub-cutaneous in the median line ; on each side it gives attachment to the crico-thyroid muscle, and presents a smooth process (*m*, *fig.* 177) for articulating with the thyroid cartilage. *Behind*, where it is covered by the mucous membrane of the pharynx, it presents in the median line a vertical projection, which gives attachment to some of the longitudinal fibres of the œsophagus, and on each side a depression for the posterior crico-arytenoid muscle.

Fig. 173.

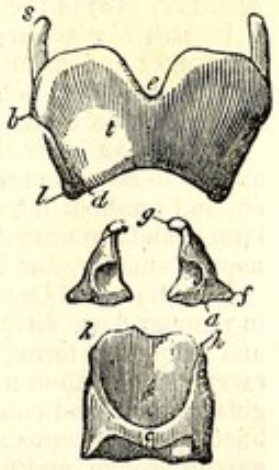

Its *internal surface* is covered by the laryngeal mucous membrane.

Its *lower border* is perfectly circular and slightly waved, and is connected by a membrane with the first ring of the trachea ; sometimes it is even united with it, and can only be distinguished by its greater thickness.

Its *upper border* is not exactly circular, but is oblong from before backward, as if the ring had been flattened laterally. It is cut very obliquely forward and downward, or, rather, it is deeply notched *in front*, where it is concave, and gives attachment to the crico-thyroid membrane in the median line, and laterally by its inner lip to a fibrous membrane, which is continuous with the inferior vocal cord, and in the rest of its thickness with the lateral crico-arytenoid muscle.

Behind, and on each side, is an oblong, articular facette, the *arytenoid facettes* (*h h*, *fig.* 173), which are directed outward and upward, and articulate with the arytenoid cartilages. Between these two facettes, the upper border of the cricoid is horizontal, and very slightly notched, and gives attachment to the arytenoid muscle. The upper border of the cricoid cartilage is, therefore, horizontal behind, oblique at the sides, and horizontal and slightly concave in front. The arytenoid facettes are situated upon the oblique portion.

The Thyroid Cartilage.—The *thyroid* or *scutiform* cartilage (*t*, *figs.* 173 to 177), so named because it has been compared to a shield (θυρεός, a shield),* occupies the upper and fore part of the larynx. It is formed by two quadrilateral plates (or *alæ*), united at an acute angle in the median line, and embracing the cricoid cartilage behind. Its *an-*

* The name may also have been derived from its use.

terior or *cutaneous surface* presents in *the median line* an angular projection (below *e*, *fig.* 173), more marked and deeply notched above, and completely effaced below; much less distinct in the female, in whom it forms only a rounded surface, than in the male, in whom it has received the special appellation of the *pomum Adami*. This angular projection does not appear until puberty; it presents certain individual varieties, but these do not appear to me to have any relation with the qualities of the voice.

On *each side* the surface (*t*, *figs.* 173, 174) is smooth and quadrilateral, and has two tubercles behind; one of which is superior (*b*), and the other inferior (*d*). The latter, or larger, is prolonged upon the inferior border of the cartilage. The two tubercles are united by an aponeurotic arch, but there is no oblique intermediate line, as has been generally affirmed. These tubercles, and the imaginary line between them, separate the anterior three fourths of the surface, which are covered by the thyro-hyoid muscle, from the posterior fourth, which is covered by the inferior constrictor of the pharynx and the sterno-thyroid muscle. The tubercles give attachment to these three muscles.

The *posterior surface* (*fig.* 175) presents, *in the median line*, a retreating angle, which gives attachment to the thyro-arytenoid ligaments, or vocal cords, and to the thyro-arytenoid muscles. This angle is sometimes so acute that the cartilage has the appearance of having been subjected to strong lateral pressure.

On *each side* (*t t*) the posterior surface projects beyond the cricoid cartilage, and forms part of the lateral groove of the larynx. It is lined by the pharyngeal mucous membrane, and corresponds in part to the thyro- and crico-arytenoid muscles.

Its *upper border* is horizontal and sinuous, and gives attachment to the hyo-thyroid membrane in its whole extent. It presents a notch (*e*, *fig.* 173) in the median line, which is shallower, but broader and more rounded in the female than in the male. On the sides there is a small prominence, which forms a continuation of the superior tubercle, and is often wanting. More posteriorly, we find on each side a slight notch, bounded by certain processes called the *great* or *superior cornua* (*s*, *figs.* 173, 174) of the thyroid cartilage.

The *lower border* is sinuous, and shorter than the upper, and hence the pyramidal shape of the larynx. It presents a slight median projection, to which the crico-thyroid ligament is attached; in the rest of its extent, it gives insertion to the crico-thyroid muscle, and presents a rough eminence, which forms a continuation of the inferior tubercle; and more posteriorly, on each side, a slight notch, bounded by the *lesser* or *inferior cornua* (*l*, *figs.* 173, 175) of the thyroid cartilage.

Its *posterior borders* (*s r*, *fig.* 174) are slightly sinuous, give attachment to the stylo-pharyngei and palato-pharyngei, and rest upon the vertebral column. As the thyroid cartilage projects behind the upper portion of the larynx, it may be regarded as protecting the larynx by its posterior borders resting upon the vertebral column.

The *cornua of the thyroid cartilage* are four in number, *two superior* and *two inferior*, and appear to be prolongations of the posterior borders of the cartilage. They are all rounded, and are bent inward and backward; the upper or *great cornua* (*s*) are generally the larger, and are united by ligaments to the os hyoides; the lower or *lesser cornua* (*l*) are usually smaller, and articulate with the cricoid cartilage.

The Arytenoid Cartilages.—The arytenoid cartilages (*a*, *figs.* 173, 175 to 177) are two in number,* are situated at the upper and back part of the larynx, and have a pyramidal and triangular form; they are directed vertically, and bent backward like the lip of an ewer, whence their name (ἀρυταίνα, a funnel). Their *posterior surface* (*fig.* 175) is triangular, broad, and concave, and receives the arytenoid muscle; their *internal surface* is lined by the mucous membrane of the larynx; their *anterior surface* (*fig.* 173) is convex, narrow, rough, and furrowed, and corresponds to the series of glands called the arytenoid glands, and to the superior vocal cord; their *base* is very deeply notched, articulates with the cricoid cartilage, and is terminated by two processes: one posterior and external (*f*), which gives attachment to the lateral and posterior crico-arytenoid muscles; the other is anterior (*a*), pyramidal, and more or less elongated, has the inferior vocal cord attached to its point, and it forms a fourth, or almost a third, of the antero-posterior diameter of the glottis; their *apex* is surmounted, or rather formed, by two very small and delicate cartilaginous nodules (*g*), which are bent inward and backward, and incurvated so that they almost touch; they are called the *cornicula*. They were very correctly described by Santorini, under the name of the sixth and seventh cartilages of the larynx. They are now generally known as the *tubercles of Santorini*, the *capitula* or *cornicula laryngis*. They appear to me constantly to exist, sometimes closely united with the arytenoid cartilages, and not moving at all upon them, and sometimes perfectly distinct and very movable.

The Epiglottis.—The epiglottis (ἐπὶ, upon, and γλωττὶς, the glottis, *i*, *figs.* 174 to 178), or lingula, forming a movable and highly elastic valve, is a fibro-cartilaginous lamina, situated (*i*, *fig.* 140) behind the base of the tongue, and in front of the superior opening of the larynx, not upon the glottis, as its name would seem to indicate.

* It was for a long time believed that there existed only one arytenoid cartilage, because the larynx was always examined when covered by its membranes; so that the word arytenoid, in the works of Galen, is always applied to the two united. Galen only admitted three cartilages in the larynx—the thyroid, the cricoid, and the arytenoid.

Its *direction* is vertical, excepting at the moment of deglutition, when it becomes horizontal, so as to protect the opening of the larynx like a lid (*laryngis operculum*). Its triangular *shape* has been well compared to that of a leaf of purslaine. It must be separated from the neighbouring parts to be properly studied.

It varies much *in size* in different subjects, but always appears to me to bear some relation to the dimensions of the upper orifice of the larynx, beyond which it almost always projects when depressed.

Its *anterior* or *lingual surface* presents a free and an adherent portion. The *free portion* surmounts the base of the tongue; it may be felt by the finger, and even seen by strongly depressing the tongue.* Three folds of mucous membrane, one in the middle and one on each side, pass from the epiglottis to the base of the tongue.

The *adherent portion* corresponds in front with the base of the tongue, the os hyoides, and the thyroid cartilage. In order to expose it, it is necessary to have recourse to dissection. We then find a *median glosso-epiglottid ligament*, which is very strong, and composed of yellow elastic tissue, and which, I believe, assists in drawing back the depressed epiglottis; its place is occupied by muscular fibres in the larger animals; also a *hyo-epiglottid ligament*, extending from the epiglottis to the posterior surface of the os hyoides; and, lastly, beneath this ligament, a yellow fatty tissue, improperly called the *epiglottid gland*, occupying the interval between the epiglottis and the concavity of the thryoid cartilage.

Moreover, the anterior surface of the epiglottis, examined in the vertical direction, is concave above, convex in the middle, and again concave below; it is convex in the transverse direction. The *posterior* or *laryngeal surface* (*figs.* 175, 178), the curvatures of which are the reverse of those on the anterior surface, is free in the whole of its extent, and covered by the laryngeal mucous membrane.

Circumference.—Its upper margin, or the base of the triangle which it represents, is free, bent forward, slightly notched, and continuous, by two rounded angles, with its lateral margins, from each of which proceed two folds, viz., the *aryteno-epiglottid* (*b*, *fig.* 178), extending from the epiglottis to the arytenoid cartilage, and enclosing a ligament (*b*, *fig.* 176), and the *pharyngeo-epiglottid*, situated anterior to the preceding, passing almost transversely outward, and lost upon the sides of the pharynx.

The epiglottis terminates below in a sort of pedicle, which is extremely slender, and is fixed (*fig.* 176) into the retreating angle of the thyroid cartilage, immediately above the attachment of the vocal cords. This attachment is effected by means of a ligament, called the *thyro-epiglottid*.

The epiglottis is remarkable for the great number of perforations found in it, which give it an appearance very much resembling that of the leaves of several of the *lauraceæ*. In these foramina we find small glands, which, for the most part, open on the laryngeal surface of the epiglottis. The so-called epiglottid gland has no relation with these orifices.

It is also remarkable for its flexibility and elasticity; on account of which it is classed by Bichat among the *fibro-cartilages*, a sort of tissue which we have stated does not exist. Its yellow colour gives it an appearance like the yellow elastic tissue. It is brittle, and may be crushed between the fingers; this depends partly upon the nature of its tissue, and partly upon the numerous foramina with which it is perforated, and which necessarily diminish its strength.

The Articulations and Ligaments of the Larynx.

The articulations of the larynx may be divided into the extrinsic and the intrinsic.

The Extrinsic Articulations.—The *thyro-hyoid articulation* consists of three ligaments, which unite the thyroid cartilage to the os hyoides. The *middle thyro-hyoid ligament* (*n*, *fig.* 174) is a loose yellowish membrane, extending from the upper border of the thyroid cartilage (*t*) to the os hyoides (*u*). Its vertical dimensions are much greater at the sides than in the middle; and, therefore, the cornua of the os hyoides can be raised higher than its body, and hence the sides of the tongue can be elevated so as to form a groove, along which the food glides. This membrane is thick in the middle, and thin, and, as it were, cellular on each side.

Fig. 174.

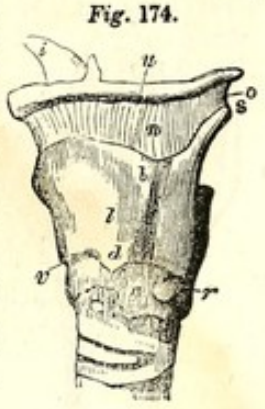

Relations.—It is sub-cutaneous in the middle, but is covered on each side by the thyro-hyoid muscle. It corresponds behind with the epiglottis, from which it is separated by some adipose tissue, and with the mucous membrane covering the posterior surface of the tongue. It is attached to the posterior lip of the upper edge of the os hyoides, not to the lower edge, as is frequently asserted. It therefore passes behind the os hyoides.

The *lateral thyro-hyoid ligaments* (*o*) may be considered as the margins of the thyro-hyoid membrane. They are small cords, extending from the great cornua of the thyroid

* I attach great importance to inspection of the epiglottis in diseases of the larynx.

cartilage to the tubercular extremities of the great cornua of the os hyoides. We often find a cartilaginous or bony nodule in these ligaments.

There is a very distinct *synovial capsule* between the posterior surface of the body of the os hyoides and the upper part of the thyroid cartilage. Its presence attests the frequent movements which take place between these parts, and during which the middle and upper part of the cartilage is placed behind the os hyoides.

The Tracheo-cricoid Articulation.—The first ring of the trachea is connected with the lower border of the cricoid cartilage by a fibrous membrane of the same nature as that between the rings of the trachea. A small vertical fibrous cord is added to it in the median line in front. This membrane permits some movements between the cricoid cartilage and the first ring of the trachea, and in these the sides of the ring are buried behind the cricoid cartilage.

The *intrinsic articulations* are the *crico-thyroid* and the *crico-arytenoid*. I need merely remind the reader of the articulation between the arytenoid cartilages and the cornicula laryngis.

The Crico-thyroid Articulations.—These are *arthrodial*. Each of the lesser cornua of the thyroid cartilage terminate in a plane surface, directed downward and inward, which rests upon a similar plane surface (*m*, *fig.* 177) on the cricoid cartilage, directed upward and outward. An orbicular or capsular ligament (*r*, *figs.* 174, 175), composed of shining, fasciculated, and parallel fibres, surrounds the articulation, which is provided with a synovial membrane. The posterior fasciculus is remarkable for its length and shape, and extends nearly to the crico-arytenoid articulation. In some subjects the orbicular ligament is very loose, in others the articulation is exceedingly close.

The *movements* are limited to simple gliding, combined with a forward and backward movement of the thyroid cartilage. The direction of the facettes upon the cricoid cartilage renders them fitted to support the thyroid.

The Crico-thyroid Membrane, or Middle Crico-thyroid Ligament.—Besides the preceding articulations, the lower border of the thyroid cartilage is connected with the upper border of the cricoid by a thick triangular membrane, the *pyramidal* or *conoid ligament* (*v*, *fig.* 174), which is attached in the median line to the lower border of the thyroid cartilage, and the base of which is fixed to the upper border of the cricoid cartilage. This membrane is fibrous, thick, very strong, perforated with foramina for vessels, and is yellow and elastic.

The Lateral Crico-thyroid Ligament.—This ligament (*d*, *fig.* 176) can be well seen only from the inner surface of the larynx. It consists of very strong fibres, which arise from the inner lip of the upper border of the cricoid cartilage, in front of the crico-arytenoid articulation, and pass horizontally inward to the retreating angle of the thyroid cartilage, below the insertion of the inferior vocal cord (*r*). This ligament, which is very strong, appears to be continuous above with the inferior vocal cord. It is covered on the inside by the mucous membrane of the larynx, and it corresponds on the outside (*d*, *fig.* 177) to the thyro- (*e*) and crico-arytenoid (*f*) muscles, which separate it from the thyroid cartilage.

The Crico-arytenoid Articulations.—These articulations are effected by mutual reception.

The *articular surface*, upon the cricoid cartilage, is an elliptical facette (*h*, *fig.* 173), directed obliquely downward and forward, and oblong and slightly concave in the same direction. The base of the arytenoid cartilage presents an oblong articular facette, deeply concave from without inward, *i. e.*, in an opposite direction to the former, which it accurately receives.

Means of Union.—Properly speaking, there is only one ligament, the *internal and posterior* (*e*, *fig.* 175). It arises from the cricoid cartilage, and is inserted in a radiated manner into the inner and back part of the base of the arytenoid cartilage, and to the inner side of its anterior process, behind the inferior vocal cord. This ligament is very strong, but yet sufficiently loose to allow of certain extensive movements. There is also a very loose *synovial capsule*, which can be easily demonstrated.

Fig. 175.

The *movements* of this articulation, like those of all similar joints, take place in every direction; but the movements inward and outward are much more extensive than those which are performed forward and backward. On account of the mode of insertion of its muscles, the arytenoid cartilage is not moved in a direct line, but undergoes a partial rotatory movement, the centre of which is in the articulation. In the movement, which is oblique, on account of the obliquity of the articular surfaces, the apex of the arytenoid cartilage is carried either outward and backward or inward and forward. These motions should be studied with the greater care, because they afford an explanation of the changes which take place in the glottis during the production of the voice.

The Aryteno-epiglottid Ligament.—This ligament (*b*, *figs.* 176, 177) is constituted by some radiated ligamentous fibres contained within the aryteno-epiglottid fold of mucous

membrane, and which pass from the anterior surface of the arytenoid cartilage to the corresponding margin of the epiglottis. In some animals, this ligament is replaced by muscular fibres.

The Thyro-arytenoid Ligaments, or Chordæ Vocales.—Although there is no immediate relation between the thyroid and the arytenoid cartilages, they are united by four very important ligaments, named the *chordæ vocales*, which require a special description.

The *chordæ vocales* are also called the *vocal bands*, the *ligaments of Ferrein*, or the *thyro-arytenoid* ligaments, because they have a ligamentous appearance, and extend from the retreating angle of the thyroid cartilage to the arytenoid cartilages.

There are two vocal cords on each side, a *superior* (*s*, *figs.* 176, 178) and an *inferior* (*r*); the space between them is called the *ventricle* of the larynx (*v*), and the interval between the cords of the right and left sides is called the *glottis* (*o*, *fig.* 178).* I shall speak of these parts again presently.

The *inferior vocal cord* (*r*, *fig.* 176) is much stronger than the superior, and has the form of a rounded fibrous cord, stretched horizontally from the retreating angle of the thyroid cartilage to the anterior process of the arytenoid cartilage. It is free in all directions, excepting on the outside, where it is in contact with the thyro-arytenoid muscle. Its free portion is covered by the mucous membrane of the larynx, which adheres intimately to it, and is so thin that the white colour of the cord can be seen through it. This vocal cord is thinner than it appears at first sight, the projection which it forms being, in a great measure, due to the thyro-arytenoid muscle. Its structure is entirely ligamentous, and consists of parallel fibres, running from before backward, and not at all elastic.†

Fig. 176.

It is continuous below with the lateral thyro-cricoid ligament (*d*).

The *superior vocal cord* (*s*) is smaller, and situated farther from the axis of the larynx than the inferior one (see *fig.* 178), and extends from the middle of the retreating angle of the thyroid cartilage to the middle of the anterior surface of the arytenoid cartilage: like the inferior cord, it has a fasciculated and fibrous appearance; but the fasciculi are few in number, and are intermixed with a series of glandular masses. The superior vocal cord can only be distinguished from the rest of the parietes of the larynx from the reflection of the mucous membrane below it, so as to form the ventricle. It is continuous with the aryteno-epiglottid ligament (*b*, *fig.* 176) above, without any line of demarcation.

Muscles of the Larynx.

These are divided into the *extrinsic* and the *intrinsic*: the former, which move the entire larynx, have been already described, viz., the sterno-hyoid, omo-hyoid, sterno-thyroid, and thyro-hyoid; to which we might add all the muscles of the supra-hyoid region, and those muscles of the pharynx which have attachments to the cricoid and thyroid cartilages.

The intrinsic muscles are nine in number, viz., four pairs and one single muscle. Those which exist in pairs are the crico-thyroidei, the crico-arytenoidei postici, the crico-arytenoidei laterales, and the thyro-arytenoidei. The single muscle is the arytenoideus.

The Crico-thyroideus.

Dissection.—This muscle is completely exposed by separating the larynx from the muscles by which it is covered. In order to gain a good view of the deep portion of the muscle, the lower part of the thyroid cartilage must be removed.

The crico-thyroideus (*a*, *figs.* 147, 170) is a short, thick, triangular muscle, situated on the anterior part of the larynx, on each side of the crico-thyroid membrane, and divided into two distinct bundles. It is attached below to the cricoid cartilage on each side of the median line, to the whole of the anterior surface, and even to part of the lower border of the cartilage. From these points the fleshy fibres radiate in different directions: the internal fibres pass somewhat obliquely upward and outward; the middle ones very obliquely, and the lower fibres horizontally outward, to the lower border of the thyroid cartilage (excepting to its middle portion), and to the lower margin of the corresponding lesser cornu. The greatest number of fibres are inserted into the posterior surface of the thyroid cartilage; some of them are continuous with the inferior constrictor of the pharynx (*w*, *fig.* 147).

It is covered by the sterno-thyroid muscle and the thyroid gland, and it covers the lateral crico-arytenoid and the thyro-arytenoid muscles. The inner borders of the crico-thyroid muscles are separated from each other by a triangular space, broad above and narrow below, in which the crico-thyroid membrane is visible.

* [In consequence of the voice being essentially produced opposite the *inferior* cords, they are termed the *true* vocal cords; the superior being called the false vocal cords.]

† [The inferior vocal cords are certainly composed of elastic tissue, so, also, are the thyro-hyoid and crico-thyroid ligaments; and, according to M. Lauth (*M m. de l'Acad. Roy. de Méd.*, 1835), the lateral crico-thyroid membranes, the superior vocal cords, and the aryteno-epiglottid ligaments are also composed of this tissue, which, he says, exists even in the thyro-epiglottid, hyo-epiglottid, and glosso-epiglottid ligaments.]

Their *action* is not yet well determined. By taking their fixed point upon the cricoid cartilage, it appears to me that they would move the thyroid cartilage in such a way as to increase the antero-posterior diameter of the glottis, and thus act as tensors of the vocal cords.

The Crico-arytenoideus Posticus.

Dissection.—This muscle is exposed by removing the mucous membrane from the posterior surface of the larynx.

It is a triangular muscle (*g*, *figs.* 171, 177), situated at the back of the cricoid cartilage. Its fibres arise from the lateral depression, which we have described on the posterior surface of the cartilage, and pass in different directions; the upper fibres are the shortest, and are almost horizontal; the middle are oblique, and the lower are nearly vertical; they all converge towards the posterior and external process on the base of the arytenoid cartilage, behind the crico-arytenoideus lateralis.

Relations.—It is covered by the mucous membrane of the pharynx, to which it is very loosely united, and it covers the cricoid cartilage.

Action.—It is a *dilator of the glottis.* It carries the base of the arytenoid cartilage backward, outward, and downward, and thus renders the inferior vocal cord tense

The Crico-arytenoideus Lateralis.

Fig. 177.

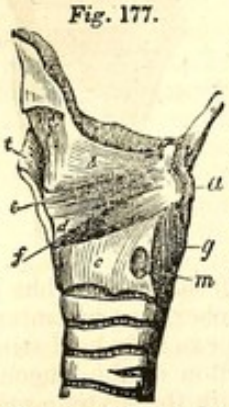

Dissection.—Remove with care one of the lateral halves of the thyroid cartilage (as in *fig.* 177). It is impossible to separate this muscle from the thyro-arytenoideus.

This is an oblong muscle (*f*), situated deeply under the thyroid cartilage. Its fibres arise from the side of the upper border of the cricoid cartilage, in front of the crico-arytenoid articulation; from this point they proceed obliquely upward and backward, to be inserted into the posterior and external process of the arytenoid cartilage, by a tendon common to them, and to the thyro-arytenoideus. It is covered by the thyroid cartilage and by the crico-thyroid muscle, and it covers the lateral crico-thyroid membrane (*d*).

The Thyro-arytenoideus.

Dissection.—The same as for the preceding. This muscle may be dissected from the interior of the larynx, by removing the vocal cords.

I describe the thyro-arytenoideus and the crico-arytenoideus lateralis separately, merely in accordance with custom, for in no instance, not even in large animals, such as the ox, have I ever been able to separate them completely. They have the same arytenoid insertion; their fibres are situated upon the same plane, without any line of demarcation, and they fulfil the same uses. We might, therefore, unite them under the name of the *thyro-crico-arytenoideus.*

The *thyro-arytenoideus* (*e*) is a broad muscle, very thin above and very thick below. It arises on each side from about the lower two thirds of the retreating angle of the thyroid cartilage. The greater number of its fibres arise from the lower part of the angle, and form a very thick fasciculus. From these points they pass horizontally backward and outward, and terminate in the following manner: The thick fasciculus above mentioned is inserted into the outer surface of the anterior process of the arytenoid cartilage, and into a depression on the outer side of the base of that cartilage, between the two processes. The upper fibres are attached to the outer border of the arytenoid cartilage. In the larger animals, the upper fibres of the muscle evidently proceed to the epiglottis, and form the *thyro-epiglottideus* of some authors.

Relations.—On the *outside* it corresponds with the thyroid cartilage, from which it is separated by loose and sometimes adipose cellular tissue; on the *inside* it is in contact with the vocal cords and the ventricle of the larynx. The thickest part of the muscle corresponds with the inferior vocal cord, and is almost the only cause of its projecting into the interior of the larynx. This fasciculus may even be considered as contained within the substance of the inferior vocal cord, and the two structures are so closely adherent that great care is required to separate them. Many anatomists, indeed, have thought that the fibres of the thyro-arytenoideus terminate in the vocal cord, which they therefore regarded as the tendon of the muscle; but the cord and muscle may always be completely separated.

Action.—It carries the arytenoid cartilage forward, and would thus seem to relax the inferior vocal cord, as Haller believed: "*Cartilagines guttales* (the arytenoid) *antrosum ducunt, glottidem dilatant, ligamentorum glottidis tensionem minuunt.*" (*Elementa Physiol.*, t. iii., liv. ix., p. 387.) But if we consider the mechanism of the crico-arytenoid articulations, and the mode of insertion of the thyro-arytenoid muscles into the outer side of the bases of the arytenoid cartilages, we shall perceive that, at the same time that these cartilages are carried forward, they undergo a partial rotatory movement, by which their anterior processes are turned inward. The ligaments of the glottis are, therefore, ren-

dered tense, and approximated towards each other. This movement may be carried to such an extent that the anterior processes may touch, and the antero-posterior diameter of the glottis be diminished accordingly.*

The thyro-arytenoideus is, then, both a tensor and a constrictor of the glottis. This, moreover, was the opinion of both Cowper and Albinus, but Haller attempted to refute it.†

The sudden action of the thyro-arytenoid muscle, pressing upon the ventricle of the larynx, may expel any mucus collected within it.

The Arytenoideus.

Dissection.—Remove the mucous membrane and glandular masses which cover it behind. Detach it along one of its borders, so as to be enabled to examine its thickness.

The *arytenoideus* (*a*, *fig.* 171) is a single, short, thick, trapezoid muscle, situated behind the arytenoid cartilages, and filling up the concavity on their posterior surfaces, as well as the interval between them. It arises from the whole length of the outer border of the right arytenoid cartilage, and is inserted into the corresponding part of the left. Some of the fibres arise from the upper border of the cricoid cartilage. The fibres have a triple direction, and form three layers, which have been regarded as so many distinct muscles.

The two more superficial layers are oblique, and cross each other, one passing from the base of the right arytenoid cartilage to the apex of the left, and the other following the opposite direction; they constitute the *arytenoideus obliquus* of Albinus: both of these layers are thin.

The third and deepest layer is very thick; it is composed of transverse fibres, and forms the *arytenoideus transversus* of Albinus.

None of the fibres reach the cornicula. Under the name of the aryteno-epiglottideus, muscular fibres have been described, extending from the arytenoid muscle to the margins of the epiglottis. Some fibres of the arytenoideus are also said to be continuous with the thyro-arytenoideus.

Relations.—*Behind*, with the mucous membrane and some glandular masses, which adhere to the muscle by means of loose cellular tissue; *in front* it is in relation with the posterior surface of the arytenoid cartilages, and in the interval between them with a thin fibrous membrane, extending from the upper border of the cricoid cartilage to the whole extent of the inner borders of the arytenoid cartilages.

Action.—It would appear, at first sight, that this muscle must forcibly approximate the two arytenoid cartilages, and therefore constrict the glottis;‡ but if we remember that it is attached to the outer borders of these cartilages, we shall understand that, besides drawing them together, it must produce in them such a movement as will carry their anterior processes outward, and stretch the vocal cords, but, at the same time, separate them from each other. And if we call to mind that the thyro-arytenoideus occasions an exactly opposite movement, it will be understood that the simultaneous action of the two muscles must produce tension of the cords, and, at the same time, fix the processes.

Having thus obtained a knowledge of the cartilages of the larynx, the articulations by which they are united, and the muscles which move them, we shall now proceed to give a general description of this organ.

The Larynx in general.

The larynx, the general position of which has been already described, presents certain differences in its *dimensions*, depending either upon the individual, upon sex, or upon age. These differences affect both the whole of the larynx and its constituent parts. Thus, the larynx of the female may always be distinguished from that of the male by being smaller, *i. e.*, about two thirds the size of the male larynx; and by the angles and processes of its cartilages being less prominent, and their depressions less marked. These differences are connected with the characters of the voice, and affect principally the dimensions of the glottis.

The individual differences in the size of the larynx have not been thoroughly examined. The differences depending on age will be noticed when speaking of its development.

The larynx presents for our consideration an *external* and an *internal* surface.

The External Surface of the Larynx—Anterior Region (*fig.* 170).—In the *median line* we observe a vertical ridge, formed by the angle of the thyroid cartilage; beneath this the crico-thyroid membrane, and still lower the convexity of the cricoid cartilage.

On the *sides* we find the oblique laminæ of the thyroid cartilage, a portion of the cricoid covered by the crico-thyroid muscle, and the thyro-cricoid articulation.

Sub-cutaneous in the median line, where it is only separated from the skin by the linea alba of the neck, the external surface of the larynx is covered on each side by the muscles of the sub-hyoid region, the inferior constrictor of the pharynx, and the thyroid gland.

* [The effect of this will be, as stated by Haller, to *relax* the vocal cords, which is considered by the latest observers to be the action of these muscles.]

† Loc. cit. "Cùm magni viri glottidem dixerint ab istis musculis arctari, experimento facto *diducere* didici. Neque potest ille ad latus cartilaginis arytænoidæ musculus terminari quin *eam rimam diducat*."

‡ [When acting together with the lateral crico-thyroid muscles, this is certainly their action.]

The superficial position of the surface enables us to examine its different parts through the integuments, and renders it liable to wounds. Its still greater proximity to the skin in the median line has suggested the operation of laryngotomy.

Posterior Region (*figs.* 141, 171).—In the *median line* we observe a prominence like a small barrel, on either side of which the thyroid cartilage projects. This prominence is formed by the back of the cricoid, and by the arytenoid cartilages, the expanded portion corresponding with the bases of the latter, which are covered by folds of a pale mucous membrane. Under this membrane we find, proceeding from above downward, the arytenoideus muscle, the vertical ridge of the cricoid cartilage, the crico-arytenoidei postici, and the crico-arytenoid articulations.

On *each side* of the barrel-shaped prominence is a deep angular groove, formed by the meeting of two flat surfaces, which are separated above, but approximated below; along these grooves it is supposed that liquids flow during deglutition. The external wall of each groove is formed by the posterior surface of the thyroid cartilage, the os hyoides, and the thyro-hyoid membrane. The internal wall is formed by the upper and lateral part of the barrel-shaped prominence. The grooves are lined by a closely-adherent mucous membrane; and it should be observed, that they exist only on a level with the arytenoid cartilages, and, consequently, in this region alone is the larynx protected by the thyroid cartilage, the posterior borders of which rest upon the vertebral column. The back of the cricoid cartilage is on a level with the posterior borders of the thyroid (*fig.* 174), and, like them, rests upon the vertebral column.

The Internal Surface of the Larynx.—The internal surface of the larynx does not correspond, either in shape or dimensions, with its outer surface; and this depends principally on the fact that the retreating angle of the thyroid is the only part of that cartilage which enters into the formation of the laryngeal cavity, the lateral laminæ being altogether unconcerned in it.

Cylindrical below, where it is formed by the cricoid cartilage, the cavity of the larynx is prismatic and triangular above, where it is constituted by the epiglottis in front, the arytenoid cartilages and the arytenoid muscle behind, and on the sides by the two mucous folds which extend from the margins of the epiglottis to the arytenoid cartilages. The dimensions of the lower of these two portions of the laryngeal cavity undergo no change, always remaining the same as those of the cricoid cartilage; while the upper, on the contrary, which is broadest in front, varies much in size, in consequence of the mobility of the epiglottis and the arytenoid cartilages. Between these two portions, and about the middle of the larynx, a fissure exists, which is narrower than the rest of the cavity, and oblong from before backward; this is the *glottis*, or *vocal apparatus*, properly so called. It can be seen without any dissection by looking down into the larynx (*fig.* 178), and requires a very particular description.

The Glottis, or Vocal Apparatus.—The glottis (γλωττὶς, from γλώσση, the tongue), frequently confounded with the superior orifice of the larynx,* is a triangular opening or fissure (*o*, *fig.* 178) (*rima*), elongated from before backward, and included between the vocal cords of the right and left sides. It represents two isosceles triangles, placed one above the other, and having perfectly equal borders, the base of each being directed backward, and its apex forward. The lower isosceles triangle is formed by the *inferior vocal cords* (*r*), and the upper one by the superior vocal cords (*s*). The inferior vocal cords are situated nearer to the axis of the larynx than the superior, so that a vertical plane let fall from the latter would leave the inferior vocal cords on its inner side. Many authors limit the term *glottis* to the lower triangle. This view is supported by the absence of the superior vocal cords in a great number of animals, the ox in particular.

Fig. 178.

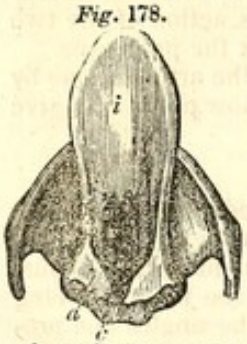

Dimensions of the Glottis.—The glottis is the narrowest part of the larynx, and hence the danger from the introduction of a foreign body into it, and from the formation of false membranes in this situation. The only action of the intrinsic muscles of the larynx is to dilate or contract the opening of the glottis. We have seen that, with the exception of the crico-thyroidei, they are all, in some measure, collected round the crico-arytenoid articulation, the movements of which determine the dimensions of the glottis.

The individual differences which constitute the tenour, baritone, or bass voices in singing, depend upon the size of the glottis; to which, also, must be attributed the difference between the male and female voice, and the change produced in its tone at the time of puberty. A deep voice coincides with a large glottis, and a shrill voice with a small one. In the adult male the antero-posterior diameter of the glottis is from ten to eleven lines, in the female it is only eight lines; in the male, the greatest transverse diameter is from three to four lines; in the female, from two to three lines.†

* This error is, perhaps, to be attributed to the use of the word *epiglottis*, so much do words influence our ideas. It was committed even in Haller's time, who says, "*Etiam hoc* (*laryngis*) *ostium non bene pro glottide sumitur.*"

† These measurements are taken at the level of the inferior vocal cords; the transverse diameter is rather longer opposite the superior vocal cords

From these dimensions, it may be understood how a *Louis d'or* might pass edgewise through the glottis, and thus fall into the trachea. In a case of this kind, most of those who were called in consultation rejected the idea of the presence of the coin in the windpipe, because, said they, the glottis cannot admit it. The patient died in about a year, and the *Louis d'or* was found in the trachea.

Ventricle of the Larynx.—Between the superior and inferior vocal cords of each side there is a cavity, called the *ventricle* or *sinus of the larynx* (*v*, *figs.* 176, 178); it is oblong from before backward, and of the same length as the cords; its depth is determined by the interval separating the cords from the thyroid cartilage, or, rather, from the thyro-arytenoid muscle, which forms the bottom of the corresponding ventricle. The opening of the ventricle is somewhat narrower than the bottom, is elliptical in its longest diameter, and has admitted the introduction of a foreign body. To each ventricle there is a supplementary cavity, which is accurately described and figured in the works of Morgagni.* This cavity resembles in shape a Phrygian cap; it has a broad base, opening into the ventricle, and a narrow apex; it is found at the anterior part of the ventricle, and is prolonged on the outer side of the superior vocal cord, between it and the thyroid cartilage, upon the side of the epiglottis. Its dimensions vary much. In one case its vertical diameter was six lines, and it was divided into two parts by a transverse band.

The Circumferences of the Larynx.—The superior circumference of the larynx (*fig.* 178) is much wider than the inferior, and presents the following objects: the superior angular border of the thyroid cartilage, and the great cornua, in which it terminates; behind the thyroid cartilage, the epiglottis (*i*); and between the cartilage and the epiglottis, a small triangular space, filled by a compact fatty mass, which has been incorrectly described as the *epiglottid gland.* I have already said that this fatty mass is bounded above by a fibrous membrane, extending from the epiglottis to the posterior surface of the os hyoides.

Behind the epiglottis, we find *the upper orifice of the larynx*, which must not be confounded with the glottis; it slopes obliquely from before backward and from above downward, having the form of a triangle, with its base directed forward and its apex backward, consequently in the opposite direction to the glottis. This orifice is formed in *front* by the free margin of the epiglottis, which is slightly notched; on each *side*, by the upper part of the lateral margin of the epiglottis, and by the free edge of the *aryteno-epiglottid fold* (*b*); and *behind*, by the cornicula laryngis, and by the summits of the arytenoid cartilages (*a*), and the deep notch between them.

The superior orifice is the widest part of the larynx, and admits foreign bodies which cannot pass through its lower portion. The epiglottis, when depressed, generally covers it completely, and may even overlap it at the sides.

The *inferior circumference of the larynx* is perfectly circular, is formed by the cricoid cartilage, and is continuous with the trachea.

The Mucous Membrane and Glands of the Larynx.—The mucous membrane of the larynx is a continuation of that of the mouth and pharynx. The larynx presents the only example in the body of an organ, part of whose external surface, namely, the posterior, is covered with mucous membrane; and this depends upon the circumstance of its forming part of the parietes of the pharynx.

The mucous membrane is disposed in the following manner: From the base of the tongue it is reflected upon the anterior surface of the epiglottis, forming the three glosso-epiglottid folds already described, one in the middle and one on each side; it adheres pretty closely to the epiglottis, is reflected over its free margin, covers its posterior surface, and penetrates into the larynx: on each side it passes from the epiglottis to the arytenoid cartilages, and becomes continuous with the pharyngeal mucous membrane, which covers the back of the larynx. At the superior orifice of the larynx, it is reflected upon itself, to form the aryteno-epiglottid folds, which constitute the sides of the supra-glottid region of the larynx; it then covers the superior vocal cord, and lines the ventricle, sending a prolongation into its supplementary cavity. In the ventricle it is remarkable for its slight adhesion to the subjacent parts. It is reflected from the ventricle upon the inferior vocal cord; there, as well as opposite the superior cord, it is so thin that it does not conceal the pearly appearance of the ligament beneath, to which it adheres so closely that it is difficult to separate them. Lastly, it covers the internal surface of the cricoid cartilage, and the middle and lateral crico-thyroid membranes.

The laryngeal mucous membrane is characterized by its tenuity, its adhesion to the parts beneath it, and by its pale pink colour.† It is perforated by the openings of a number of mucous glands. Its extreme sensibility, especially at the upper orifice and in the

* I first saw this cavity in a patient affected with laryngeal phthisis, in whom it was very much developed. I then examined the larynx in other individuals, and found it to be constant. I did not then know that Morgagni had pointed it out and figured it (*Advers.* i., *Epist Anat.*, viii.).

† [The epithelium of the laryngeal mucous membrane is, in the greater part of its extent, columnar and ciliated. The cilia urge the secretion upward; according to Dr. Henle, they extend higher up in front than on each side and behind; on the sides, for example, as high as the border of the superior vocal cords, or about two lines above them, and in front upon the posterior surface of the epiglottis, as high as its base or widest portion. Above these points the epithelium gradually assumes the laminated form, like that in the mouth and pharynx.]

supra-glottid portion of the larynx, is well known.* The aryteno-epiglottid folds, which include the ligaments of the same name, and some muscular fibres in the larger animals, are remarkable for the great quantity of very loose cellular tissue which they contain: this fact explains their liability to a serous infiltration, called œdema of the glottis, which proves rapidly fatal.

The Glands of the Larynx.—The glands of the larynx are the epiglottid and the arytenoid. The thyroid gland, or body, cannot be considered as belonging to the larynx; if it belongs to any organ, it must be to the trachea.

The Epiglottid Glands.—The name of epiglottid glands is generally given to the fatty mass already described as being situated between the thyroid cartilage and the epiglottis; and it has even been asserted that it opens by special ducts on the posterior surface of the epiglottis. But there is no other epiglottid gland besides those situated in the substance of the epiglottis, which is perforated with innumerable holes for their reception: these small glands are so numerous, that Morgagni (*Advers.*, i., 2; v., 68) regarded them as forming a single gland; they all open upon the laryngeal surface of the epiglottis by very distinct orifices, from which a considerable quantity of mucus can be pressed.

The Arytenoid Glands.—These were well described by Morgagni, who very properly considered them as forming a single glandular mass, situated in the substance of the aryteno-epiglottid fold. They are arranged in two lines, united at an angle, like the letter L;† the vertical line runs along the anterior surface of the arytenoid cartilage and its corniculum, and produces a slight prominence, perfectly distinct from that made by the cartilages; the horizontal line is less prominent, and is situated in the superior vocal cord. The arytenoid glands open separately upon the internal surface of the larynx.

Vessels and Nerves.—The *arteries* are derived from the superior thyroid, a branch of the external carotid, and from the inferior thyroid, a branch of the subclavian. The *veins* enter the corresponding venous trunks. The *lymphatic vessels*, which are little known, terminate principally in the glands of the supra-hyoid region, if we may judge from the frequency of their inflammation in cases of acute laryngitis, &c.

The *nerves* are branches of the pneumogastric, viz., the superior and the inferior, or *recurrent laryngeal*. The superior laryngeal nerves are not exclusively distributed to the muscles called constrictors of the glottis (the arytenoideus and the crico-thyroidei); nor do the inferior laryngeals belong exclusively to those called dilators (the crico-arytenoidei postici and laterales, and the thyro-arytenoidei), as a celebrated physiologist has affirmed. (See NEUROLOGY.) The peculiar rotatory movement of the arytenoid cartilages somewhat interferes with any classification of these muscles into dilators and constrictors.

Development.—The evolution of the larynx is remarkable in this respect, that, after having attained a certain size, it undergoes no appreciable change until the time of puberty. The ventricles are as yet so slightly developed that their existence has been denied. The prominence of the os hyoides in some measure conceals that of the larynx. M. Richerand (*Mém. de la Société Méd. d'Emulation*, tom. iii.) has proved that there is no very remarkable difference between the larynx of a child at three years of age and of one at twelve. Up to the age of puberty the larynx presents no trace of the sexual differences which afterward become so evident; and to these anatomical conditions are owing the shrillness and uniformity of the voice in the youth of both sexes.

At the period of puberty, at the same time as the genital organs, the larynx increases so rapidly as to attain its full development in the space of one year; the voice then loses its uniformity, and acquires its peculiar timbre and quality, and then also the sexual differences in the vocal apparatus become manifest.

Is it from an unequal development of the different parts of the larynx, or from want of a certain degree of education, that the voice at this period is so discordant, especially in singing, or *breaks*, as it is said?

The simultaneous development of the genital organs and the larynx has led to the opinion that they stand to each other in the relation of cause and effect; and observation has established that the vocal apparatus is in some measure under the influence of the generative organs; for in eunuchs the larynx remains as small as it is in the female. (M. Dupuytren, *Mém de la Soc. Phil.*, tom. ii.)

At the age of puberty the size of the glottis is increased by one third in the female, and is nearly doubled in the male. After puberty, any changes which the larynx may undergo are the result of exercise, not of development, properly so called.

Ossification of the cartilages of the larynx is not always the effect of age. I have seen it at the thirtieth year quite independently of disease. Chronic inflammation of the larynx induces a premature ossification of the cartilages. The thyroid has the greatest tendency to this change, then the cricoid, and, lastly, the arytenoid cartilages: I have never observed it in the epiglottis.

Functions.—The larynx is the organ of voice. Numerous experiments upon living animals, and many surgical facts, show that the vocal sound is produced exclusively in

* It has been observed, in experiments upon animals, and in introducing the canula after the operation of laryngotomy, that the sensibility of the mucous membrane beyond the glottis is much less acute.

† "Gnomonis, sed obtusanguli figuram utervis acervus habet."—(*Haller.*)

the larynx. The lungs, the bronchi, and the trachea perform, with regard to the voice, the office of an elastic conductor of air capable of contraction and dilatation, of shortening and elongation. The thorax acts like a pair of bellows, by which the air is driven into the larynx with any wished-for degree of force; and hence the quantity of air passing through the larynx, and the rapidity with which it moves, may vary to a very great extent.

What, then, is the mechanism of the voice? Is it the same as that of a horn (*Dodart*), of a stringed instrument (*Ferrein*), of a flute (*Cuvier*), of a reed instrument (*Biot* and *Magendie*), or of a bird-call* (*Savart*)? Is it produced by the vibration of the tense vocal cords, or merely by the vibration of the air while passing through a narrow opening, which is itself incapable of vibrating? We shall leave these questions to the decision of physiologists. It is sufficient for our purpose to know that the action of the muscles of the larynx and the arrangement of the vocal apparatus are perfectly fitted to produce either dilatation or contraction of the glottis; and such is the mechanism of this part, that, from the rotatory movement of the arytenoid cartilages, the vocal cords are always rendered tense, whatever may be the other actions of the muscles.

The voice as it issues from the larynx is simple, for the larynx is, with regard to the voice, what the mouth-piece is in the flute, or the reed in the bassoon; but during its passage through the vocal tube, composed of the epiglottis, the pharynx, the isthmus of the fauces, the mouth, and the nasal fossæ, the voice becomes modified.

According to a very ingenious theory of M. Magendie, the epiglottis resembles those soft and movable valves which M. Grénié places in the pipes of an organ to enable the sound to be increased without modifying the tone.

The isthmus of the fauces resembles the superior larynx of birds, which consists of a contractile orifice that can be diminished, and even closed at pleasure; and it is principally owing to this mechanism that the small glottis of birds can execute such an extensive range of notes. We know, in fact, that the tone of a wind instrument is reduced an octave lower by completely closing the lower orifice of the tube, and that, when it is only partially closed, the tone is depressed in proportion. Now the isthmus of the fauces acts exactly like the superior larynx of birds. On watching a person who wishes to utter a very low note, we see that he depresses and flexes the head slightly upon the neck, so as to approximate the chin to the thorax: by this means the vertical diameter of the isthmus of the fauces is diminished, the larynx being carried upward, while the velum palati is depressed; and from this we may judge of the important part performed by the velum in producing modulations of the voice.

If to this we add the changes which may be effected in the length and diameter of the pharynx (see *Pharynx*), and if we remember that, by diminishing by one half the length or diameter of the tube or body of a wind instrument, its tone is raised one octave, we shall be able to understand how the human voice can execute so extensive a scale of notes, although the glottis is so small. The voice is also modified while traversing the buccal and nasal cavities.

Do the *nasal fossæ* favour the resonance of the voice? or does the air, when passing through them, merely give rise to certain sounds denominated nasal? The latter opinion, which is supported by Mr. Gerdy, appears to me the most consistent with facts. MM. Biot and Magendie had already correctly observed that the voice becomes nasal only when it traverses these passages.

The voice becomes articulate in passing through the mouth, *i. e.*, the vocal sound is interrupted, and modified by the more or less rapid percussion of the lips and tongue against the teeth and the palate.

Articulate voice is very distinct from speech. Animals which differ much from man in the conformation of their vocal organs, the parrot, for example, may be made to articulate; but speech is the peculiar attribute of man, because he alone is possessed of intelligence.

The Thyroid Gland.

The *thyroid gland*, or thyroid body, is a glanduliform organ, the uses of which are unknown: it is situated like a crescent with its concavity directed upward, in front of the first rings of the trachea, and upon the sides of the larynx.

In describing this organ in connexion with the larynx, I follow the usual custom, which has arisen not from any direct relation between their functions, but from their contiguity to each other.

The thyroid body varies much in *size* in different individuals; there are few organs which present greater varieties in this respect.

The sexual differences in the size of this organ, like all those relating to the vocal apparatus, are very well marked, but in an inverse manner, that is to say, the thyroid body is larger in the female, in whom it forms a rounded projection, which assists in making the thyroid cartilage in that sex appear still less prominent.

* A bird-call is a cavity with elastic walls, perforated upon the two opposite sides. The cavity is represented by the ventricles, and the openings by the intervals between the vocal cords. If a tube capable of contracting and dilating be fitted to such an instrument, an infinite variety of sounds may be produced.

Climate, and more especially certain qualities in the water used as drink, have a remarkable influence upon its size, which, in many cases of goître, is enormous.

These differences in size affect either the whole of the gland equally, or only one lobe, or occasionally the middle portion alone.

The *weight* of the thyroid body, which is about an ounce, may be increased to a pound and a half, or even more.

Form.—The thyroid body is generally composed of two lateral *lobes* or *cornua*, united by a contracted portion, flattened from before backward, and called the *isthmus*. The varieties in shape principally affect the isthmus, which may be very narrow, long or short, regular or irregular, or entirely absent, or it may be as thick and as long from above downward as the lobes themselves. I have seen one case in which the thickest part of the thyroid gland was in the middle, and the lobes terminated above in a very narrow point.

The opinion of the ancients, and which is also met with in Vesalius, that the human subject has two thyroid glands, no doubt arose from the narrowness or absence of the isthmus, or, rather, from the separation and complete independence of the two lobes in a great number of animals. The surface of the thyroid body is smooth and well defined, and sometimes divided into lobules by superficial furrows.

We shall examine in succession the *relations* of the middle and lateral portions:

The *middle portion* or *isthmus* is convex in *front*, and is separated from the skin by all the muscles of the sub-hyoid region. *Behind*, where it is concave, it is in contact with the first rings of the trachea. Moreover, this middle portion descends to a greater or less distance in different subjects, and sometimes so low, that there is not room to perform tracheotomy between it and the sternum.

Each *lateral lobe* is convex in *front*, and corresponds with the muscles of the sub-hyoid region: in particular, I ought to mention the sterno-thyroid, by which it is directly covered, and the breadth of which seems to be proportioned to the size of the lobe: in many cases of goître I have seen this muscle twice or three times as broad as in the natural state. *On the inside*, each lateral lobe is concave, so as to be applied to the side of the trachea and cricoid cartilage, to the lower and latter part of the thyroid cartilage, to the lower part of the pharynx, and to the upper part of the œsophagus. The two lobes, together with the middle portion or isthmus, form a half or sometimes three fourths of a canal, which embraces all those parts; an extremely important relation, which explains how, in certain goîtres, the trachea is flattened on the sides, deglutition is impeded, and true asphyxia by strangulation is the final result. *Behind*, each lateral lobe corresponds with the vertebral column, from which it is separated, on the outside, by the common carotid artery, the internal jugular vein, and the pneumogastric and great sympathetic nerves, which, according to the size of the gland, are either covered by it, or are merely in relation with its outer surface.

The *upper extremity* of each lateral lobe terminates in a point, and hence the two-horned figure assigned to the thyroid body. It is situated on the inside of the carotid artery, in contact with the lateral and back part of the thyroid cartilage, and sometimes extends nearly to its upper border. Its *lower extremity* is thick and rounded, descends to a greater or less distance in different individuals, and corresponds to the fifth, sixth, or seventh rings of the trachea: it is situated between the trachea and the common carotid. The inferior thyroid artery enters the gland at its lower extremity.

Its *upper border* is concave and notched in the middle; the superior thyroid arteries run along it. A prolongation extends from this border, which has been correctly represented by Bidloo, and named the *pyramid* by Lalouette. It almost always exists; it passes perpendicularly upward, either on the right or left side of the median line, and presents numerous varieties in several respects. Thus it varies in its origin, sometimes arising from the isthmus, and sometimes from one of the lobes at one side of the isthmus; also in its termination, sometimes ending opposite the notch in the upper border of the thyroid cartilage, sometimes opposite the thyro-hyoid membrane, and at other times even on a level with the body of the os hyoides; but always firmly adherent either to the membrane or the bone. It also varies in its structure: sometimes it is a fibrous cord, and sometimes a reddish linear band, which has all the appearances of a muscular fasciculus, and has even been described as a muscle; it often consists of a series of granules arranged in a line; sometimes, again, we find, in the middle, or at one end of the cord, a glanduliform enlargement, exactly resembling the tissue of the thyroid gland; lastly, it may be double, or bifurcated, or even completely wanting; in which case, however, there exists a glanduliform mass of a certain height. This prolongation, in which I and many others have in vain attempted to find an excretory duct, is evidently of a compact nature. Is it the remains of a fœtal structure, or the trace of a normal disposition in some animals?

The *lower border* of the thyroid body is convex, more or less deeply notched in the centre, and is in contact with the inferior thyroid arteries.

Structure.—The proper tissue of the thyroid gland is of a variable *colour*, sometimes resembling the lees of Port wine, and sometimes of a yellowish hue. It is of tolerably

firm *consistence*, and feels granular. This organ presents all the anatomical characters of glands, and, like them, may be separated by dissection into glandular grains; but with this difference, that these grains communicate with each other, while, in ordinary glands, they are independent. The communication of the glandular grains may be shown in the following manner: if the tube of a mercurial injecting apparatus be inserted into the thyroid gland, the mercury will enter into and distend the cells, and after a certain time all the grains will be injected; it is easy to satisfy the mind that the mercury is not infiltrated into the cellular tissue, but is contained in the tissue of the gland itself, in the centre of the granulations. The right and left lobes do not communicate, but all the granulations of each lobe communicate with each other.

The thyroid gland has, therefore, a vesicular structure; and we have seen that the glandular grains of all glands are spongy and porous, and that the products of their secretion may be accumulated in these pores.

The glandular nature of the thyroid body is also shown by the viscid, limpid, yellowish fluid which pervades it in certain subjects, and which may be collected in sufficient quantity for chemical analysis; and also by the retention of this matter within a greater or less number of the vesicles when their orifices of communication with the neighbouring vesicles become obliterated.

But, in connexion with this view regarding its glandular nature, we seek in vain for an excretory duct. If we examine the trachea and the larynx, or lay open the œsophagus, and then press the thyroid gland, we shall see that no fluid escapes into those canals. It has been asserted, indeed, that the excretory duct of the thyroid gland terminated in the *foramen cæcum* of the tongue, in the ventricles of the larynx, or in the trachea opposite its first ring; but, after the example of Santorini, we are compelled to reject these fancied and too hastily announced discoveries.

I may here notice the intimate adhesion of the side of the thyroid gland to the first ring of the trachea. This can be very well shown by detaching the gland from behind forward; it is of a fibrous nature, and I have sometimes thought that I saw a duct in the centre of it, passing through the membrane which connects the trachea with the cricoid cartilage, though I have never been able satisfactorily to demonstrate it.

Still, I do not think that the absence of an excretory duct should remove the thyroid from among the glandular organs; for I believe that there exist in the body glands without excretory ducts, as the thymus, the supra-renal capsules, and the thyroid body. The secretion of the gland is entirely absorbed, and fulfils certain unknown uses.

Arteries.—The size and the number of the arteries distributed to the thyroid gland indicate that something more than a mere nutritive process must be carried on in it. The arteries are sometimes four, sometimes five in number; two superior arise from the external carotid; two inferior from the subclavian, and the fifth, or the thyroid artery of Neubauer, where it exists, arises from the arch of the aorta.

The *veins* are proportionally as large as the arteries, and form so considerable a plexus in front of the trachea, as, in certain cases, to have prevented the completion of the operation of tracheotomy.

The *lymphatic vessels* terminate in the cervical lymphatic glands.

The *nerves* are derived from the pneumogastrics, and the cervical ganglia of the sympathetic.

A thin cellular membrane envelops the gland, and sends very delicate prolongations into its substance, where we find a very firm cellular tissue, always destitute of fat.

Development.—The thyroid gland is developed in two lateral halves, which are afterward united by a median portion. It is not uninteresting to remark, that this disposition, which is transitory in the fœtus, represents the permanent condition of the gland in a great number of animals. During intra-uterine life and infancy it is relatively larger than at subsequent periods. Nevertheless, the changes which it afterward undergoes are not to be compared with those that occur in the thymus; and we cannot say, as of the latter structure, that the existence of the thyroid body has any peculiar relations with fœtal life.

Functions.—It is a secreting organ, but the uses of its fluid are not known.

THE GENITO-URINARY ORGANS.

I HAVE thought it proper to describe the *genital* and the *urinary organs* together, because, although their functions are very distinct, yet they have the most intimate anatomical, physiological, and pathological connexions.

THE URINARY ORGANS.

Division.—The Kidneys and Ureters.—The Bladder.—The Supra-renal Capsules

The urinary organs form a very complex secretory apparatus, consisting of two secreting organs, the *kidneys*; of two provisional reservoirs, the *calyces* and the *pelvis* of each kidney; of two excretory ducts, the *ureters*; of a second and final reservoir, the *bladder*;

and, lastly, of a second and final excretory canal, which, in the male, is common to both the genital and the urinary organs, viz., the *canal of the urethra*.

The Kidneys.

The *kidneys* (*νεφροὶ*) are glandular organs, intended to secrete the urine.

They are deeply *situated* (*k k, fig.* 199) in the lumbar region, hence called the *region of the kidneys*, on each side of the vertebral column, externally to the peritoneum, which merely passes in front of them; they are surrounded by a great quantity of fat, and, as it were, suspended by the vessels which pass into and emerge from them.

Fixed firmly in this situation, they are but little liable to displacement. Most of the changes in their position are congenital. The right kidney generally descends a little lower than the left, doubtless on account of the presence of the liver. One of the kidneys may not uncommonly be found in front of the vertebral column, or even in the cavity of the pelvis; and this unusual arrangement may, in certain cases, render diagnosis very obscure.* I have frequently found the right kidney in the corresponding iliac fossa in females who had been in the habit of wearing very tight stays. This displacement happens when the pressure of the stays upon the liver forces the kidney out of the depression in which it is lodged in the lower surface of that organ.

Number.—The kidneys are two in number. It is not very uncommon to find only one, which is almost always formed by the union of the two, by means of a transverse portion crossing in front of the vertebral column, and having its concave border directed upward.

Sometimes the two united kidneys are situated in the right or left lumbar region, or in the cavity of the true pelvis. Cases of union of the two kidneys should be distinguished from those in which one of them is atrophied.

Again, Blasius, Fallopius, Gavard, &c., relate examples of individuals having three kidneys; in some of these cases, two were situated upon the same side, in others the supernumary kidney was placed in front of the vertebral column.

Size.—The kidney is not subject to such great variations in size as most other organs. Its ordinary dimensions are from three and a half to four inches in length, two inches in breadth, and one inch in thickness. Its *weight* is from two to four ounces.† I have found them more than three times their ordinary size in a diabetic patient. When one kidney is atrophied, the other becomes proportionally enlarged, sometimes even to twice the usual dimensions. Atrophy of the kidney may be so extreme as to reduce it to a drachm and a half or two drachms in weight, and make it appear to be lost among the surrounding fat; but the presence of this fat distinguishes such a case from one of congenital absence of the kidney.‡

Density and Colour.—The tissue of the kidney is harder than that of other glands. Its *fragility* accounts for its laceration by direct violence, or by a concussion produced by a fall from a great height.

Its *colour* is that of the lees of red wine, somewhat analogous to that of the muscular tissue, but offers several different shades.

Figure.—The shape of the kidney may be well compared to a bean, with the hilus turned inward. This form enables us to consider its two surfaces and its circumference.

Relations.—The *anterior surface* of the kidney is directed slightly outward; it is convex,◊ and is covered by the lumbar colon, but sometimes only by the peritoneum, the gut lying to its inner side; on the left side it is also in relation with the spleen and the great tuberosity of the stomach, and on the right side with the liver and the second portion of the duodenum.

The relations of the right kidney with the liver are more or less extensive; sometimes it is entirely covered by the liver; in other instances it is inclined downward, and has no relation with that organ. The gall-bladder sometimes lies upon the anterior surface of the right kidney through the whole of its extent. Lastly, I have seen the kidney in immediate relation with the parietes of the abdomen, through which it could be easily felt.

As practical inferences from these relations, we would notice the difficulty of exploring the kidneys from the anterior surface of the abdomen, on account of their deep situation; also, the possibility of an abscess of the kidney opening into the colon.

The *posterior surface* is less convex than the anterior, and is turned inward; it corresponds with the quadratus lumborum, from which it is separated by the anterior layer of the fascia of the transversalis muscle; with the diaphragm, which separates it from the

* I lately had in my wards a female labouring under hectic fever, of which I could detect no cause, either in the thorax or the abdomen. Upon opening the body after death, I found the two kidneys united, situated in the true pelvis, behind the rectum, and projecting a little above the brim. They contained a large quantity of pus, which escaped by the rectum.

† [According to M. Rayer, the average weight of the kidney in the male is $4\frac{1}{3}$ ounces, in the female $3\frac{2}{3}$ ounces; he also states that the left kidney is almost always larger and heavier than the right.]

‡ I do not speak here of enlargement of the kidneys from disease. Many examples of extreme enlargement will be found in my work on *Pathological Anatomy*, liv. i., xviii.

◊ Not unfrequently the fissure of the kidney is found on the anterior surface of this organ. In one case of this kind, the right kidney occupied the right iliac fossa; it had two arteries, a superior, which proceeded directly to the fissure, and an inferior, arising from the angle of the bifurcation of the aorta, in front of the middle sacral artery, and terminating at the lower extremity of the kidney.

two or three lower ribs; and with the psoas, which intervenes between it and the vertebral column. These relations explain the possibility of exploring the kidney in the lumbar region through the quadratus lumborum, account for abscesses of the kidney opening in the lumbar region, and for the escape of renal calculi in the same direction, and form the grounds on which the operation of nephrotomy has been proposed. It is of importance to remark, that the relations of the kidneys with the ribs are variable in extent, and that sometimes they do not pass beyond the last rib.

The *circumference* of the kidney presents an external border, convex, semi-elliptical, and directed backward; an internal border, directed forward, and deeply notched in the middle, to form the *fissure of the kidney* (*hilus renalis*, *h*, *fig.* 179). This notch is more marked behind, where it corresponds with the pelvis of the kidney, than in front, where it corresponds with the renal vein; it is from fifteen to eighteen lines in depth.

If we separate the edges of this fissure, we expose a deep cavity containing fat, and called the sinus; in which are seen the pelvis of the kidney (*p*), the calices (*c c c'*), and the divisions of the renal artery and vein.

The upper end of the kidney is directed inward, and is more or less completely embraced by the supra-renal capsule; it is generally larger than the lower end, which is directed slightly outward, and projects beyond the last rib.

Structure.—Make a vertical section of the kidney from its convex to its concave border. Detach the proper capsule in the same direction. Inject the arteries, veins, and ureter, in different kidneys, and also in the same kidney. Inject also the uriniferous ducts.

The Proper Coat.—The kidney has no peritoneal covering. The remarkable fatty mass in which it is imbedded is called the *fatty capsule* of the kidney. Besides this, it is provided with a proper fibrous coat, the external surface of which adheres to the fatty tissue, by means of fibrous lamellæ passing through it; its internal surface is adherent to the tissue of the kidney, through the medium of a number of small prolongations, which are very easily lacerated.

The Tissue of the Kidney.—The kidney differs from other glands, all of which present a homogeneous and granular texture, in being composed of two substances: one of these is external, *cortical*, or *glandular* (*a a*); the other internal, *medullary*, or *tubular* (*b b b*). Some anatomists have described a third substance, the *mammillated*; but the papillæ (*d d*) of which it is composed belong to the tubular substance.

Fig. 179.

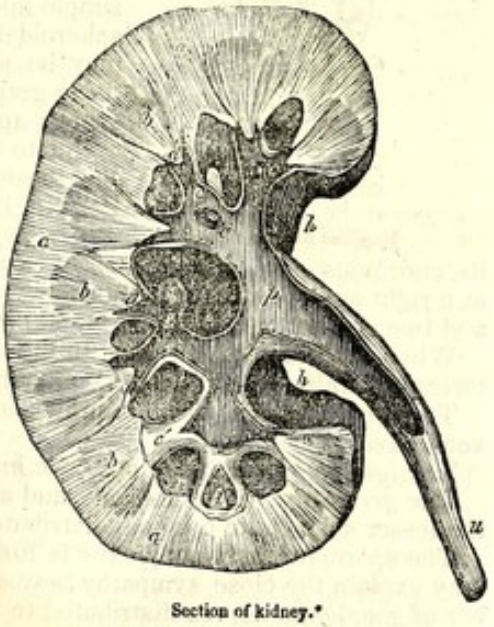

Section of kidney.*

The following is the respective arrangement of these two substances:

The *cortical substance* forms a soft, reddish, sometimes yellow layer, of a granular appearance, and about two lines in thickness, which occupies the surface of the kidney, and sends prolongations, in the form of pillars or septa, from one to three lines thick, between the cones of the tubular substance.

The *tubular* or *medullary substance* is redder, and presents the appearance of striated cones or pyramids (the *pyramids of Malpighi*), the bases of which adhere to the cortical substance, while their free apices are turned towards the sinus, where they appear like papillæ. Bellini, and, before him, Berenger di Carpi, considered the fibres or striæ of the medullary substance as so many uriniferous tubes (the *tubes of Bellini*), and hence the term tubular substance.

It follows, then, that the kidney is divided into a number of compartments, corresponding to the number of cones of tubular substance; there are from ten to twenty of these compartments, which represent the temporary lobules of the human fœtal kidney, and the permanent lobules in the kidneys of the greater number of animals.†

The kidney, therefore, is formed by the union of a greater or less number of small kidneys, applied together, and connected within a common investment. We shall see, presently, that, in reference to the circulation, these small kidneys are entirely independent of each other. Although the distinction between the two substances is well marked, it is easy to see that some of the fibres or striæ of the tubular structure penetrate the cortical substance in a flexuous course, and reach the surface of the organ. This fact was clearly shown by Ferrein, who considered the striæ to be the excretory ducts of the granules. These cortical and flexuous portions of the tubes, which become straight as soon as they reach the medullary substance, are termed the *cortical ducts*, or the *convoluted tubes of Ferrein.*

* This figure is a *plan*, not an actual representation of the structure of the kidney.
† In some animals the kidney resembles a bunch of grapes.

Ferrein having examined the tubes of Bellini under the microscope, believed that each of them formed a pyramid analogous to those of the tubular substance, and that each of these secondary pyramids consisted of about a hundred ducts; hence the tubes of the tubular substance have been named the pyramids of Ferrein,* in contradistinction to the pyramids of Malpighi.

We shall now examine the structure of the tubular and the cortical substance.

Structure of the Tubular Substance.—The tubular substance, which, at first sight, looks like muscular tissue, from its red colour and arrangement in lines, evidently consists of tubes or ducts.

In fact, an examination under the simple microscope of a section made perpendicularly to the axis of the tubes, demonstrates the existence of a number of small openings, each corresponding to a tube; and if, while the eye is fixed upon the section, the kidney be compressed, urine will be seen to exude from all points of the cut surface. Direct injection of the ducts, by means of a tube containing mercury, introduced at hazard into the tubular substance, will fill all the tubes, in whatever direction the instrument may be directed. The ingenious experiment performed by Galvani, who tied the ureters of birds, and by this means obtained an injection of the tubes with the white matter of their urine, leaves no doubt of the existence of these tubes. Lastly, the tubes themselves are collected together in the papillæ, and open either over their entire surface, or in a small depression which sometimes exists at their summits.

Fig. 180.

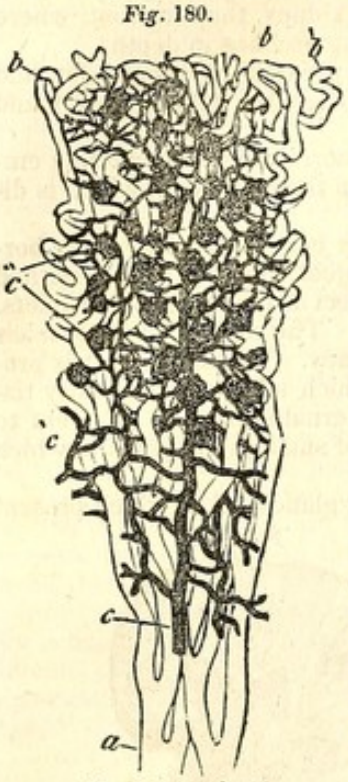

Magnified sixty times.‡

Structure of the Cortical Substance.—The cortical substance is tubular and granular. The granules are regularly disposed around the convoluted tubes of Ferrein.†

On examining a thin slice of uninjected kidney by the simple microscope, we perceive a great number of oval and spheroidal granules (*c''*, *fig.* 180), the *acini* of Malpighi, which may be separated from each other by maceration; and those granules which have been cut through present that spongy appearance, resembling the pith of the rush, which seems to belong to all glands. When the section is vertical, these corpuscles are seen appended to the tubes of Ferrein, like grapes upon their stalk.◊

Vessels and Nerves.—The *renal artery* is remarkable for its enormous size, in proportion to that of the kidney, for its origin from the aorta being at a right angle, and for its shortness. There are sometimes two or three renal arteries, and two are not unfrequently found twisted spirally around each other.

When the kidney is situated in the iliac fossa or in the pelvis, the renal artery or arteries generally arise from the common iliac.

The *renal vein* is as large in proportion as the artery, and passes in front of it into the vena cava.

The *lymphatic vessels* are but little known.

The *nerves* are very numerous, and are derived from the solar plexus; besides which, the lesser splanchnic nerve is distributed directly to the kidney.

The spermatic nervous plexus is formed by branches from the renal plexus, and this may explain the close sympathy between the testicle and the kidney. The great number of ganglionic nerves distributed to the kidney may account for the peculiar character of the pain experienced in this organ.

Injection of the Renal Vessels.—A very coarse injection thrown into the artery will return by the veins. One thrown into the vein will return by the ureter, and not by the

* See note, *infrà*.

† According to Ferrein, these convoluted tubes form, by their numerous anastomoses, a network, in the meshes of which the granules are contained.

‡ This is a plan, rather than an actual representation.

◊ [The uriniferous tubes, commencing at their orifices upon the surface of the papillæ, pass up into the tubular portion of the kidney, dividing and subdividing dichotomously several times (*a*, *fig.* 180), so as to constitute fasciculi of straight and radiating tubes: these are the pyramids of Ferrein, a considerable number of which are united to form one of the pyramids of Malpighi (*b*, *fig.* 179). At the base of the latter the fasciculi spread out, and the straight tubes become the convoluted tubes of the cortical substance (*fig.* 180).

In the human kidney, the tubuli uriniferi are said by Weber to be of a nearly uniform diameter throughout their entire course (averaging $\frac{1}{350}$ th of an inch); and all appeared to him to end in *loops* (*b b*), none in free and closed extremities (as at *b'*): according to Krause, they terminate in both ways. In either case, however, they form a closed system of tubes, independent of the bloodvessels, which merely ramify on their parietes. They are lined with a mucous membrane, continuous with that on the papillæ, and having a columnar epithelium.

The *acini* of Malpighi, or *granules* of M. Cruveilhier (*c''*), are not of a glandular nature; they consist entirely of minute convoluted arteries, which terminate in the veins, but have no direct communication, as was formerly supposed, with the uriniferous tubes; they are called the *glomeruli*.]

artery.* Having filled the artery with red injection, the vein with blue, and the ureter with yellow, I observed the following facts:

The renal artery divides into several branches within the sinus, where it is surrounded with fat; these branches pass between the calyces, and then between the cones of the tubular substance, proceeding as far as the commencement of the cortical substance without giving off any smaller branches: at that point, however, they divide and subdivide, so as to form a vascular network, the meshes of which are quadrilateral and of different sizes, inscribed within each other. The largest of these meshes embrace the entire base of each pyramid; the smaller pass in different directions through the substance of the bases.

In order to obtain a good view of this arrangement, it is necessary to divide an injected kidney along its convex border, and scrape away the tubular substance, which is so soft as to be easily removed. We shall then perceive that the arterial and venous network, corresponding to the base of each cone, is surrounded by a very thick fibrous sheath, apparently prolonged from the fibrous coat, which passes into the hilus. All the tubular substance being thus removed, the remaining cortical portion of the kidney presents the appearance of a series of perfectly distinct alveoli, each of which corresponds to a cone of the tubular substance. A very beautiful preparation may thus be made.

It remains for us to inquire how the arteries terminate. A number of vessels proceed from the convexity of the vascular network above described, traverse the cortical substance, become twisted like tendrils of the vine, and appear to terminate in small red masses, regularly arranged along the convoluted tubes of Ferrein. These small red masses are formed by the penetration of the injection into the cavity of each granule, as may be seen by examining a section of the kidney with a lens.† If both the artery and the vein be injected in the same kidney (and it is of importance that the vein should be injected before the artery, in order to prevent a mixture of the two injections), we shall see that the matter injected by the vein circumscribes that injected by the artery.

Almost all the vessels are destined for the cortical substance, the tubular substance scarcely receiving any branches:‡ the vessels of any one lobule do not communicate with those of the adjacent lobules.

Injection thrown into the ureter does not enter the uriniferous ducts, or, at least, very incompletely.

Development.—The surface of the kidney in the fœtus, as in the lower animals, is furrowed and lobulated. Each lobule is formed by the medullary substance, covered by a layer of the cortical substance. After birth the furrows are effaced, and the surface of the kidney becomes plane and smooth.

This change takes place during the first three years after birth; nevertheless, the lobular arrangement not unfrequently continues for nine or ten years, and even during the whole period of life. When the kidney is the seat of disease, and more particularly when it is distended from an accumulation of urine within the calyces and pelvis, the lobular arrangement reappears. Each lobule is then converted into a pouch, which is perfectly distinct from those in contact with it. The kidney is proportionally larger in the fœtus than in the adult.

Functions.—The kidneys are the secreting organs of the urine. The urine is secreted by the cortical substance, and, as it were, filtered by the tubular substance; for perfectly-formed urine is found in the former situation. The mechanism of this is not better known than that of other secretions; its rapidity is explained by the great quantity of blood received by the kidneys.

The Calyces, Pelvis, and Ureter.

Dissection.—Remove the fat from the sinus, and study the arrangement of the pelvis and calyces externally. Divide the kidney from the convex border towards the hilus.

The *calyces* (*c c c'*, *fig.* 179) are funnels (*infundibula*), or, rather, small membranous cylinders, embracing the bases of the papillæ by one of their extremities, almost in the same manner as the corolla of a flower embraces the stamina and pistil, and uniting at their other extremity with the adjacent calyces, to form the pelvis of the kidney. They vary in number like the papillæ, or even more so, for two or three papillæ frequently open into the same calyx. Whatever their number may be, they generally unite into three trunks, a superior, a middle, and an inferior, which correspond to the three groups of lobules, into which the kidney may be divided. These three trunks unite to form the pelvis. The external surface of the calyces is in relation with a great quantity of fat, and with the divisions of the renal artery and vein.

The *pelvis* (*p*) is a small membranous pouch, situated behind the renal artery and vein, opposite the deep notch in the posterior border of the hilus, so that, when seen from behind, it projects completely beyond that fissure. It is elongated from above downward,

* [This is the result of rupture.]

† See note, *suprà*.

‡ [The vessels (*c*, *fig.* 180) of the tubular portion run parallel with the tubuli from the cortical substance to the papillæ; they were mistaken by Ruysch for the tubuli themselves, which were, therefore, supposed by him to communicate with the arteries in the glomeruli.]

and flattened from before backward, and may become greatly dilated from retention of the urine, or from renal calculi : almost immediately after its commencement it becomes smaller, and takes the name of the *ureter*. In certain cases it would appear that there is no pelvis, and that the ureter succeeds immediately to the two or three trunks formed by the union of the calyces. The pelvis is, therefore, nothing more than the expanded or infundibuliform commencement of the ureter.

The *ureter* (*οὐρὸν*, urine, *u*, *figs.* 179, 181, 199) is the excretory duct of the kidney, and ex ends obliquely from the pelvis of that organ to the inferior fundus (*bas fond*) of the bladder. It is generally single on each side, but sometimes double, and that under two very different circumstances : for example, where the two kidneys are united into one, a double ureter is almost invariably found ; and, secondly, when, there being two kidneys, one of them is divided into two very distinct portions. In the latter case the two ureters are often united into one, after a course of a few inches. There is, then, no pelvis properly so called, and the two ureters may be regarded as the prolongation of the two trunks of the calyces, which remain separate longer than usual.

The ureter is a cylindrical tube, having whitish, thin, and extensible parietes, and varying in size from that of a crow's to that of a goose's quill. The most contracted portion of the canal is that situated in the substance of the parietes of the bladder. Occasionally it presents, at various parts of its extent, some circumscribed dilatations, which seem to indicate that the course of the urine had been for a time arrested. This canal is liable to extreme dilatation, when any obstacle occurs to the passage of the urine : I have seen it as large as the small intestine.

Each ureter is *directed* obliquely downward and inward, as far as the side of the base of the sacrum : from this point (*fig.* 181) it passes downward, forward, and then inward (*u*, *fig.* 186), to the lateral part of the inferior fundus (*a*) of the bladder, where it enters between the muscular and mucous coats, and passes obliquely for about ten lines within the substance of that organ, to one of the posterior angles of the trigone, at which point it opens by an orifice narrower than the canal itself, and having the form of a parabolic curve, with its concavity directed inward.

Relations.—In proceeding from the pelvis of the kidney to the base of the sacrum, the ureter passes along the anterior margin of the psoas, and is covered by the peritoneum and by the spermatic vessels, which cross it very obliquely. The *right* ureter is in relation with the vena cava inferior, being situated on its outer side. Opposite the base of the sacrum, each ureter crosses the common iliac, and then the external iliac artery and vein of its own side. In the pelvis, the ureter is applied to the parietes of that cavity, is covered by the peritoneum, and crosses in succession the umbilical artery, or the cord by which it is replaced, the obturator vessels, the vas deferens (*t*, *fig.* 181) in the male,* and the upper and lateral part of the vagina in the female. That portion of it which is contained within the substance of the walls of the bladder corresponds indirectly with the neck of the uterus ; and this important relation explains why carcinoma of the neck of the womb is so frequently accompanied with retention of urine. I have also observed that the ureters of all females who have died after delivery, or during the last months of pregnancy, are remarkably dilated.

Internal Surface.—The internal surface of the calyces, pelvis, and ureters is white, smooth, and has longitudinal folds, which are effaced by distension. There are no valves, either at the opening of the calyces into the pelvis, or of the pelvis into the ureter, or in any part of that canal.

Structure.—The calyces, the pelvis, and the ureter have all the same structure : they are formed by two membranes ; an *internal membrane*, continuous with the vesical mucous membrane, very thin, and even having the appearance of a serous membrane ; it is reflected from the calyces upon the papillæ, and is prolonged into the uriniferous tubes : an *external membrane*, which is very thick, and supposed to be a continuation of the external coat of the kidney, and therefore to be fibrous. Others regard it as muscular ;† I believe that it is formed of a tissue analogous to the dartos. Some arteries and veins, probably, also, some lymphatics and nerves, are distributed upon the calyces, the pelvis, and the ureters, but do not require any special description.

The Bladder.

The *bladder* (*h*, *fig.* 181) is a musculo-membranous sack, which serves as a reservoir for the urine.

It is *situated* in the cavity of the pelvis, upon the median line, behind the pubes (*b*), and is retained in that position by the peritoneum (*u*), which only partially covers it, and by the *urachus*, a sort of ligament connecting it with the umbilicus. These means of attachment are in accordance with the great enlargement of which the organ is capable ; but they cannot prevent certain partial displacements, known as *herniæ of the bladder*. When collapsed, it is completely protected from external injury ; but when

* Passing to its *outer* side.

† [In some quadrupeds the ureter distinctly contracts on applying a stimulus.]

filled, it passes above the osseous girdle in which it is contained, and enters the dilatable cavity of the abdomen, where it can be distended to the utmost without inconvenience.

Number.—The bladder is always single; the examples of *double* bladder which have been recorded are cases of protrusion of the mucous membrane through the separated muscular fibres. But, whatever may be the size of these accidental bladders (and I have seen them twice as large as the true bladder to which they were attached), they may always be distinguished by their having no muscular coat. The cases of deficiency of the bladder are generally examples of that species of malformation, in which the viscus is open anteriorly, and is everted, so as to resemble a fungous mass.

Fig. 181.

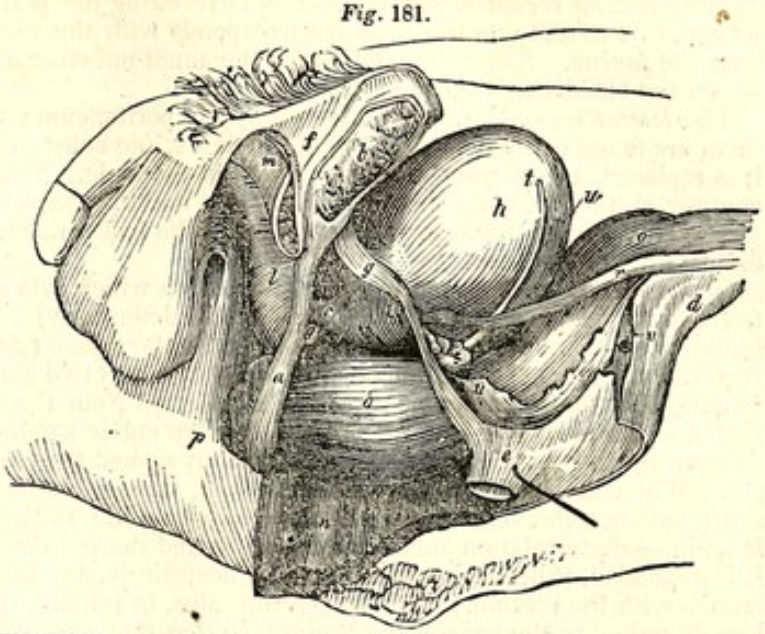

Dimensions.—The bladder is the largest of all the reservoirs of secretion; but its capacity varies, from a number of circumstances: from *habit*—in persons who are accustomed to retain their urine for a considerable period, the bladder is more capacious than in those who immediately attend to the desire to pass urine; from *sex*—thus, in the female the bladder is generally larger than in the male, because she is more influenced by the customs of society; from *age*—the bladder appears to be relatively larger before than after birth; from *disease*—in consequence of which it presents every variety between a morbid state of contraction, in which, from the contact of its parietes, it scarcely permits the accumulation of a spoonful of urine, and an extreme state of dilatation, in which it can hold several pints of that fluid.

Direction.—The direction of the bladder is determined by that of the anterior wall of the pelvis, so that its axis is oblique from above downward and backward. On account of this obliquity, a slight inclination of the trunk forward makes the neck of the bladder the most dependent part of the organ. The obliquity becomes still greater when the distended bladder has escaped from the pelvis and entered the cavity of the abdomen: its axis then exactly corresponds with that of the brim of the pelvis, *i. e.*, it is directed from the umbilicus to the lower part of the curvature of the sacrum. It has been said, since the time of Celsus, that the upper part of the bladder is a little inclined to the left side, but I have not observed this.

Shape.—The bladder is ovoid, the great end being directed downward and the smaller upward. Its shape differs according to age and sex, and in different individuals. The sexual differences are not congenital; they seem to result from the pressure to which the female bladder is subjected during pregnancy; but the transverse enlargement and the vertical shortening of the bladder in a female who has borne children are not so well marked as is generally said.

Relations.—In determining these, the bladder is divided into the *fundus*, which is the highest and the narrowest part; the *body*, or middle portion; and the *base*, which is the lowest and the broadest portion. It has, moreover, like all hollow organs, an external and an internal surface.

The *external surface* of the bladder is convex, and presents six regions for our consideration, the relations of which we shall now study, both in the collapsed and distended condition of the viscus. The *anterior region*, not covered by the peritoneum, is in relation with the symphysis and bodies of the ossa pubis, and with the internal obturator muscles, with which parts it is connected by a very loose serous cellular tissue, in stout persons more or less loaded with fat. Some fibrous bundles pass from the lower part of this region, and are attached to the sides of the symphysis; they are called the *anterior ligaments of the bladder*, and are traversed by numerous veins; they are a dependance of the superior pelvic aponeurosis (*q*, *fig.* 181). (Vide APONEUROLOGY.) In the female, on account of the absence of the prostate, the anterior region of the bladder passes below the symphysis, and advantage may be taken of this circumstance in the extraction of calculi. When the bladder is full, its anterior region corresponds immediately with the parietes of the abdomen, and sometimes rises as high as the umbilicus. The practical conclusions to be derived from these relations refer to the examination of the bladder in the hypogastrium, to puncture of this organ in the same situation, to

the high operation for stone, to the operation of dividing the symphysis, and, lastly, to ruptures of the bladder in consequence of fracture of the pubes.*

The *posterior region* of the bladder is covered by the peritoneum (*u*) throughout the whole of its extent; in the male it corresponds with the rectum (*o*), and in the female with the uterus. Some convolutions of the small intestine almost always intervene between the bladder and those parts.

The *lateral regions* are also covered by the peritoneum; and passing upon each of them are found the umbilical artery in the fœtus, and subsequently the ligament by which it is replaced, and also the vas deferens (*t*) in the male. When the bladder is perfectly contracted, there is some distance between it and that vessel and duct on either side.

The relations of the *lower region* or *base* of the bladder, which are all very important, differ in the two sexes.

In the *male* it corresponds to the rectum, from which it is separated on either side in front by the vesicula seminalis (*s*) and the vas deferens (*t*). The only part in direct relation with the rectum is, therefore, the triangular space (*fig.* 186) comprised between the vesiculæ (*s s'*) and the vasa deferentia (*l l'*) of the two sides. It is of importance to remark, that the peritoneum, where it is reflected from the rectum upon the posterior region of the bladder, forms a more or less deep cul-de-sac in the middle, and two small folds on the sides, which have been improperly named the *posterior ligaments of the bladder*. When the bladder is much contracted, the peritoneum covers the whole of the space between the vesiculæ and the vasa deferentia; so that, properly speaking, there is no immediate relation between that organ and the rectum. On the other hand, when it is distended, it becomes much enlarged posteriorly, and has much more extensive relations with the rectum.† It is important, also, to remark, that the peritoneum is very loosely united to the base of the bladder, so that they can be easily separated whenever it is desirable to reach the bladder from the rectum. On each side of the rectum the base of the bladder corresponds with the cellular tissue of the pelvis. The superior pelvic fascia and the levatores ani are attached to and embrace the sides of the base.

In the *female*, the base of the bladder corresponds not only with the vagina, but with the lower half of the neck of the uterus; it adheres very intimately to the former, but loosely to the latter.

As practical consequences of these relations, I would point out the following: In the *male*, the occurrence of recto-vesical fistulæ, the possibility of exploring the bladder by the rectum, and of operating upon it in the same situation. In the *female*, the capability of examining the bladder by the vagina, of puncturing it, and of performing lithotomy through the same part; the occurrence of vesico-vaginal fistulæ, and the frequency with which carcinoma of the bladder follows the same affection of the cervix uteri.

Summit, or Fundus.—This part of the bladder is directed forward and upward, and is covered by peritoneum. The *urachus* is a sort of cord, having a muscular appearance, and stretching from the summit of the bladder to the umbilicus, into which it appears to enter. This cord adheres tolerably firmly to the peritoneum,‡ which forms a falciform fold over it, and may be drawn down with it when it is displaced. In a case of hypertrophy of the bladder, I found the cord itself hypertrophied, and continuous with the longitudinal muscular fibres of the bladder, almost in the same way as the round ligament of the uterus with the fibres of that organ. The urachus is merely the vestige of a canal which exists in the fœtus of quadrupeds, and, according to several authors, in the human fœtus also.

There have been many discussions upon this subject, some stating that the cord is hollow, others that it is solid. I have always found it solid, both in the adult and in the fœtus. In one case I found a small concretion in it, which I regret not having submitted to chemical analysis. It is very common to find the urachus large at its origin, and becoming narrower after a course of two or three inches, and then blending with the cord, which takes the place of the left umbilical artery; at other times it expands into cellular tissue, and the filaments resulting from its division proceed, some to the umbilicus, and others to the cords which represent the obliterated umbilical arteries.

In the erect posture, the weight of the intestines presses on the summit of the bladder, which is thus pushed downward; and hence the necessity for placing the patient, during certain operations, especially that of lithotrity, in the horizontal position, or even on an inclined plane, so arranged that the pelvis is more elevated than the shoulders.

The *internal surface* of the bladder is covered by a mucous membrane, like all cavities which communicate with the exterior; and is remarkable for certain folds or wrinkles, which are effaced by distension, and for the reticular ridges formed by the fasciculi of its muscular coat; these are sometimes very highly developed, and, in certain cases,

* It has even been proposed to puncture the bladder through the symphysis, by means of a flattened trocar; but the difficulty of coming exactly upon the symphysis will probably prevent the execution of this plan.

† The varieties in the depth of the cul-de-sac formed by the reflected peritoneum, pointed out by modern surgeons, appear to me to be explicable by the difference in size of the bladders examined. The arrangement of the peritoneum seems to me to be exactly the same in all subjects.

‡ It would appear, from a fact which I have observed, that the bladder cannot be dragged into either internal abdominal ring, excepting after the urachus; this being itself drawn down by the peritoneum, with which it is closely united.

are so large, that they form pillars, which project into the interior of the bladder. The mucous membrane not unfrequently becomes insinuated between these columns, so as to form cells, or what is termed sacculated bladder. The base of the bladder presents three openings, viz., the orifices of the two ureters (*r r*, *fig.* 182), and the opening into the urethra. These three openings occupy the angles of an equilateral triangle ("colliculа ab ureteribus ad urethram producta," *Haller*), the surface of which is smooth and white, and is always devoid of wrinkles or columns. This is the *trigone* of the bladder, or *trigone of Lieutaud*, which has been supposed to possess a peculiar degree of sensibility. The posterior border (*r r*) of this trigone is more or less prominent in different individuals, and is formed by a line stretching between the orifices of the two ureters; this prominence is prolonged outward on each side by the portion of the ureter which lies in the parietes of the bladder. It has been stated incorrectly, that the trigone is formed by the projection of the prostate, for it exists in females as well as in males, though it is less prominent than in the former. All that part of the base of the bladder which is behind the trigone is generally called the *bas fond*, or *inferior fundus*.*

Fig. 182.

Most anatomists follow Lieutaud in describing, under the name of *uvula vesicæ*, a tubercle which arises from the lower part of the orifice of the urethra, and partially fills up that opening; but it exists only in cases of disease, being the result of hypertrophy of the middle portion of the prostate, described by Home as the middle lobe.

The orifices of the ureters are so constructed as to permit the easy passage of the urine into the bladder, but completely to oppose its reflux. Their long oblique course beneath the mucous membrane before opening into the bladder explains this arrangement. The raised and reflected portion of the membrane might be called the *valve of the ureter*.

The opening of the urethra, which is also called the *neck of the bladder*, is habitually closed, and, as it were, corrugated. Some force is required in order to overcome the resistance offered by it; the crescentic form which has been attributed to it is not very evident.

Structure.—The bladder has three coats: a peritoneal, which is incomplete, a muscular, and a mucous coat; these are connected by layers of cellular tissue: it has also vessels and nerves.

The *peritoneal coat* covers the posterior and lateral regions, and the inferior fundus of the bladder. The anterior region, and that part of the base which is in front of the inferior fundus, are not covered by it. It is united to the muscular coat by very loose cellular tissue.

The *muscular coat* is formed of interlacing fibres, the direction of which it is, at first sight, very difficult to determine.† This coat is very thin, and does not form a continuous layer in enlarged bladders; but in small and contracted bladders it is continuous, and consists of several layers, and may even acquire a thickness of eight or ten lines from hypertrophy. It is, then, very easy to determine the direction of the fleshy fibres, which seem to form a number of layers. The external layer consists of longitudinal fibres, all of which proceed from the neck of the bladder, and expand over the whole surface of the organ; the next layer is formed of circular fibres, some of which are irregularly interlaced, while the others are parallel. The regular circular fibres are most numerous opposite the inferior fundus of the bladder, and are continuous with the annular fibres of the neck.

The irregular circular fibres are most common in the posterior region of the organ. In the situation of the trigone, the muscular layer consists of transverse parallel fibres, placed near each other, and forming a perfectly regular plane. The transverse thick bundle stretching between the orifices of the ureters has been regarded by Sir C. Bell as the muscle of the ureters. Its contraction, by enlarging their orifices, will facilitate the entrance of the urine into the bladder.

The term *sphincter of the bladder* is applied to a muscular ring, which is continuous with the circular fibres of the body of the bladder, and is situated at the opening of the urethra. The vagueness and disagreement in the descriptions of this sphincter sufficiently prove that no very distinct structure of the kind exists at the neck of the bladder. Winslow describes some fibres arising from the ossa pubis, and embracing the

* It is not uncommon to find the bladder forming behind the trigone a deep cul-de-sac, which I have seen insinuated between that part and the rectum.

† [These fibres belong to the involuntary class, the microscopic characters of which are described in the note, p. 323.]

sides of the vesical orifice, as the sphincter muscle, but they evidently belong to the levator ani. It is certain, however, that, in the neck of the bladder, there is a thin external layer of longitudinal muscular fibres, and also a deep and very thick layer formed of circular fibres; both layers seem to be continued into the prostatic portion of the urethra.

The *mucous coat* is extremely thin,* of a whitish colour, and presents some small papillæ. It is so difficult to demonstrate its follicles, that their existence has been denied; but, with a little attention, they may always be found in the neighbourhood of the neck of the bladder, and upon the trigone. I have seen them in all parts of the bladder, under the form of vesicles, in certain cases of disease. The mucous membrane is moulded upon all the ridges of the muscular coat: it sometimes dips between the muscular bundles, and forms cells, in which calculi are often lodged. Bladders of this kind are called *sacculated*, and, moreover, are almost always *fasciculated*; *i. e.*, the muscular fibres are so highly developed as to raise up the mucous membrane into ridges. The cellular tissue uniting the muscular and the mucous coats is tolerably loose, serous, and extremely delicate.

Vessels and Nerves.—The *vesical arteries* arise either directly from the hypogastrics, or from their branches. They are variable in number. The *veins* form a very remarkable plexus around the neck of the bladder, which is prolonged upon the sides of the inferior fundus, and terminates in the hypogastric veins. The *lymphatic vessels* are, for the most part, situated between the muscular and the peritoneal coats, and terminate in the hypogastric lymphatic glands. The *nerves* are derived from the hypogastric plexus, which is composed both of ganglionic and spinal nerves; and hence the bladder is partly subject to, and partly beyond the influence of the will.

Development.—The bladder of the fœtus is remarkable for the predominance of its vertical over its transverse diameters, the latter being very short. This fact, added to the imperfect development of the pelvis, explains why the entire bladder projects above the brim of the pelvis at this period of life. The inferior fundus does not exist. The summit is gradually continued into the urachus, which is then much larger than at subsequent periods, and of which the bladder appears to be merely an expansion. According to some authors, the bladder is relatively larger, and, according to others, smaller before than after birth.

In the early periods of infancy, the bladder retains the characters which it had in the fœtus, and many important surgical inferences may, therefore, be drawn from its more extensive relations with the abdominal parietes. In proportion as the pelvis is developed, and also, perhaps, in proportion as the frequently-accumulated urine dilates the bladder in its transverse and antero-posterior diameters, this organ sinks into the pelvic cavity, and, when completely developed, presents the characters already assigned to it.

The *urachus*, which, we have seen, is converted into a muscular cord in the adult, and is sometimes lost before reaching the umbilicus, is much more developed in the fœtus: it may then be traced as far as the umbilicus, and even, according to some anatomists, through the whole extent of the umbilical cord. Analogy, and some observations upon the human subject, would seem to show that the urachus is hollow in the fœtus. In the lower animals the cavity of the urachus may be traced into a bag called the *allantois*, which is situated between the membranes of the ovum; and it is stated by several authors, that they have caused mercury injected into the bladder to pass some distance (half an inch, one inch, or one inch and a half) into the urachus, and even for a greater or less extent into the umbilical cord.

Moreover, in new-born infants, and even in adults, the urine has been seen to escape through the umbilicus; but, in these cases, the urethra is always obliterated. I have already said that I have met with a calculous concretion within the substance of the urachus, and I find that Haller and Harder have made a similar observation (*arenulæ in uracho visæ*). M. Boyer (*Traité d'Anatomie*, p. 477, SPLANCHNOLOGIE) says that he has dissected the bladder of a man twenty-six years of age, whose urachus formed a canal an inch and a half long, and contained twelve urinary calculi as large as millet-seeds; one of them was larger, and resembled a grain of barley. He convinced himself that the canal which contained these calculi was not formed by a prolongation of the internal membrane of the bladder through the other coats. On the other hand, a number of observers (myself among them) have found the urachus solid in the fœtus. New facts are, therefore, necessary to settle this anatomical question; although it is very probable that the urachus of the human subject is of the same nature as that of animals, but becomes obliterated at a much earlier period.

Functions.—The bladder is intended as a reservoir for the urine, and is also the principal agent in its expulsion. The urine constantly trickles, drop by drop, into the bladder, but cannot flow back by the ureters, on account of the mechanism already described. When the bladder is distended, it occasions a desire to evacuate its contents, and the urine is then expelled by the combined action of the bladder itself and the abdominal muscles. I have said that the bladder is the chief agent in this expulsion, for, in cases

* [This and all the other portions of the genito-urinary mucous membrane have an epithelium, which approaches to the columnar in character.]

of retention of urine from paralysis, or excessive distension of the bladder, the most powerful contractions of the abdominal muscles are not sufficient to expel it.

The Supra-renal Capsules.

The *supra-renal capsules* (*c c, fig.* 199) are organs whose use is unknown; they are situated near the upper end of the kidneys, and, like them, are outside of the peritoneum.

The proximity of the kidneys and supra-renal capsules has led to the supposition that there is some mutual relation between their functions; and hence they are generally described together, though not on perfectly just grounds.* The name *renes succenturiati* (*Casserius*) is sufficient evidence of the relation which has been supposed to exist between these organs. Nevertheless, this connexion of situation, which constitutes the most important and characteristic feature in the history of the supra-renal capsules, is not constant; and, in the numerous cases in which the kidneys occupy some unusual position, the supra-renal capsules do not accompany those organs in their displacement. Thus, when the kidneys are situated higher than usual, the capsules are placed on their inner side, and correspond with the renal fissure; when the kidneys occupy the pelvic region, the capsules undergo not the slightest change in their position, and no longer have any connexion with them.

Number.—There are two supra-renal capsules; it is said that two have been found on each side.

Size.—They vary much in size in different individuals: sometimes they are so small that they can scarcely be distinguished from the fat by which the kidney is surrounded; at other times they are very large. In a case where the two kidneys were very small, I found the supra-renal capsules much larger than usual. It has been said that they are larger in the negro than in the Caucasian race. I have examined two negroes, and did not find them unusually large. In the fœtus they are proportionally larger than in the adult. I have found them very large in several females far advanced in years.

The two capsules are not of the same size. Eustachius affirms that the right is larger than the left; but I have generally found the reverse. Their weight is about one drachm.

Form.—I shall follow the example of M. Boyer, in comparing these supra-renal capsules to a helmet, flattened on its anterior and posterior surfaces, and embracing the upper end of the kidney by a narrow and concave surface. The relations of its *anterior surface* are different on the right and the left side.

On the *right side* it is in relation with the liver, to which it adheres by a tolerably dense cellular tissue, so that the capsule is always removed in connexion with that organ. This relation between the liver and the capsule is much more constant and intimate than that between the capsule and the kidney. A small depression, already described as existing on the lower surface of the liver, to the right of the vena cava ascendens, is intended for the reception of the capsule.

On the *left side* the capsule is in immediate relation with the pancreas, and is indirectly connected with the spleen and the great end of the stomach.

The *posterior surface* is in contact with the highest part of the pillars of the diaphragm, opposite the tenth dorsal vertebra. The great splanchnic nerves and the semilunar ganglia are situated behind, and on the inner side of the capsules, to which they send off so many branches, that Duvernoy regarded these organs as the ganglia of the renal nerves.

Their convex, thin, and slightly sinuous border, is directed inward and upward. Their concave border is thick, and almost always deeply grooved. The surface of the capsules is invested by a thin layer of fat, which it is extremely difficult to remove, on account of the numerous fibrous and vascular prolongations that pass into it from the capsule; certain furrows, either containing vessels or not, and varying in depth and extent, traverse the surface of this organ, especially in front.

Cavity.—It is still doubtful whether the supra-renal capsules have a cavity in their interior, as their name would seen to indicate. It is certain that in the greater number of subjects, on dividing them in different directions, they are found to consist of two laminæ applied to each other, and united as by an adhesive substance, a sort of dark-coloured, false membrane; and that these laminæ are reflected inward opposite the concave border, so as to form a projection like a cock's comb in the interior of the capsule. The colour of the external surface is yellowish, or, rather, mottled with large yellow and brown spots. The internal surface, or, rather, of the parts which are in contact, is chestnut brown, or bistre colour of different shades, so that I am induced to compare its appearance with that of an apoplectic cyst. It seems as if in this, as in the other case, blood had been effused, and then absorbed.

The internal surface is also rough, and, as it were, lacerated; a sort of yellowish or chestnut-coloured pulp may be scraped off it. I have seen roundish, pulpy vegetations springing from several parts of this surface, sections of which presented a yellowish colour, mottled with brown.

The name of *atrabiliary capsules*, given to them by Bartholin, is undoubtedly derived

* Eustachius, who first described them, called them *glandulæ quæ renibus incumbunt.*

from the deep brown colour of their internal surface. That anatomist regarded them as small pouches or capsules, and thought that they were the reservoirs of the blackish fluid (sanguis niger, *Bartholin*; succus atrabiliaris, atramentum glandulosum, *Lecat.*) to which the ancients gave the name of atrabilis.

Structure.—The supra-renal capsules consist of two substances: one external or cortical, yellowish, and striated, which forms almost the whole thickness of the capsule; and an internal or central portion, presenting the appearance of a soft layer of a deep chestnut brown colour, and traversed by numerous vessels. The striated arrangement of the cortical layer, which is so easily seen in large animals, is frequently effaced in the human subject, where the capsule appears reduced to a thin yellowish lamella, folded back upon itself. The lobular character of the surface is only apparent, and depends upon the furrows formed in it for the vessels. The granular structure, admitted by most of the authors who have called these organs glands, has not been clearly demonstrated.

A fibrous *membrane*, analogous to the proper coat of the kidney, covers the supra-renal capsules.

The *capsular arteries* are very numerous and very large, in proportion to the size of the organ; they are divided into the *superior*, arising from the phrenic, the *middle*, proceeding directly from the aorta, and the *inferior*, furnished by the renal arteries. The *veins* are very large, and soon pass into the vena cava; the anterior furrow is chiefly intended for them. It has been supposed that they open directly into the cavity of the capsule, on account of the facility with which this latter may be distended by injecting air or any fluid into the veins. But it is probable that in such cases laceration has occurred. The veins of the right capsule enter the vena cava inferior directly; those of the left enter the renal vein of the same side. The *lymphatic vessels* are little known. The *veins* are very numerous; they are derived directly from the semilunar ganglia and solar plexus, and also from the renal plexus. It is in vain to search for the *excretory duct*, admitted by several anatomists; and described by some as entering the pelvis of the kidney, and by others as terminating in the testicle in the male, and in the ovary in the female.

Development.—The supra-renal capsules are relatively much larger in the fœtus than in the adult, and they are remarkable in this respect, that their size is inversely proportioned to that of the kidneys. They are distinct as early as the second month of intra-uterine life, and at that time exceed the kidney both in weight and size. This predominance continues during the whole of the third month; at the fourth, the kidneys and the supra-renal capsules are of equal size; at the sixth month, the capsules are not more than half as large as the kidneys; at birth, not more than one third. The existence of a cavity is not more evident in the fœtus than in the adult.

In the aged, the supra-renal capsules are sometimes very large, and their colour is always yellow at this period of life.

Uses.—The uses of the supra-renal capsules are unknown; we are even ignorant whether they should be classed among the glands. The great number of vessels with which they are supplied, and the numerous nerves distributed upon them, sufficiently prove that something more than mere nutritive changes must occur within these organs. Their pathological anatomy, which still remains to be investigated, may perhaps throw some light upon this obscure point of physiology.

THE GENERATIVE ORGANS.

The generative apparatus presents this remarkable peculiarity, that the organs of which it is composed are divided between two individuals of the same species; and from this division results the difference of sex.

The male sex is chiefly characterized by the faculty of producing a fecundating fluid, the *spermatic fluid*, or *semen*. The female sex is characterized by the faculty of producing certain *ovules*, which become fitted for the reproduction of an individual of the same species, as soon as they have been submitted to the fecundating influence of the fluid secreted by the male. The female sex is also characterized, in the human species, and in all mammalia, by the possession of a gland (the *mamma*), which is intended to provide nutriment for the newly-born creature.

The genital organs occupy the lower extremity of the trunk; they are situated in contact with the termination of the digestive canal on the one hand, and of the urinary organs on the other, with the latter of which they have the most intimate connexions, especially in the male.

THE GENERATIVE ORGANS OF THE MALE.

The Testicles and their Coverings.—The Epididymis, the Vasa Deferentia, and Vesiculæ Seminales.—The Penis.—The Urethra.—The Prostate and Cowper's Glands.

The *genital organs of the male* consist of a secreting and an excretory apparatus, composed of the following parts: two glands, called the *testicles*; two provisional excretory canals, the *vasa deferentia*; two reservoirs for the spermatic fluid during the longer or

shorter intervals between the periods of its expulsion, named the *vesiculæ seminales*; and certain ultimate excretory canals, the *ejaculatory ducts and the urethra*. To this latter canal is annexed an erectile structure, which enables it to assume the condition necessary for the ejection of the fecundating fluid; together, they form the *penis*. The *prostate gland* and *Cowper's glands* yield secretions, the use of which is connected with the generative functions: they may be regarded as appendages of the urethra.

The Testicles and their Coverings.

The Coverings of the Testicle.

The coverings of the testicle consist of several layers, which, reckoning from without inward, are the scrotum, the dartos, the tunica erythroides, the fibrous coat, and the tunica vaginalis. There is a sixth testicular covering, named the tunica albuginea; but, as it forms an integral part of the testis, we shall describe it with that organ.

The *scrotum*,* or cutaneous covering of the testicles, is a sort of pouch or bag common to both of those organs; the skin of which it is composed exhibits the following peculiarities:

It is of a browner colour than that of other parts of the body, so that, in some individuals, a layer of colouring matter, similar to that existing in the negro, may be demonstrated beneath it; like the skin of the penis and the eyelids, it is very thin, on account of the tenuity of its chorion; it is much larger than is needed for containing the testicle; it is provided with scattered and obliquely inserted hairs, the follicles of which are large, and project upon the surface; and, lastly, its external aspect presents many varieties: thus, it becomes flaccid and elongated under the influence of warmth, and in old and enfeebled persons, while, during youth, in the robust, and under the influence of cold, it becomes contracted, wrinkled, and closely applied to the testicle.

The scrotum is divided into two equal halves, by a sort of median line or ridge, called the raphé, from the Greek word ῥάπτω, to sew; because the two halves of the skin appear to be united at this part, as it were, by a seam.

The object of the great extent of the skin of the scrotum is, perhaps, to enable it to cover the penis when in a state of erection.

The *dartos* is a reddish filamentous tissue, traversed by a great number of vessels, which can be easily seen through the skin of the scrotum. This tissue envelops both testicles, and furnishes a prolongation interposed between them, and forming the *septum of the dartos*. Upon the sides, and opposite the spermatic cord, the dartos terminates abruptly, and is replaced by adipose cellular tissue. In front it is continued around the penis; behind, it is prolonged upon the median line, by an angular extremity, as far as the sphincter ani.

It follows, therefore, that there is only a single dartos, within which are contained both testicles, a septum alone intervening between them. This separation in the middle line has led some to follow Ruysch, in describing a distinct dartos for each testicle. The dartos is closely united to the skin of the scrotum by its external surface, and it is very loosely connected by extremely delicate cellular tissue, with the subjacent coverings, upon which it glides with the greatest freedom.

With regard to its structure, the dartos, at first sight, presents some analogy to cellular tissue, but it differs from it essentially in its aspect; for in no situation does cellular tissue exhibit distinct reddish nodulated filaments, like those of the dartos. It is true that these filaments are irregularly interlaced, but the majority of them pass in a vertical direction; and when a single fibre is examined, we are struck with its analogy to muscular tissue.† It also differs in its vital properties: thus, the dartos possesses the property of active contractility, as is seen in the contraction of the scrotum, and the vermicular motions observed in persons exposed to cold, or under the influence of great dread, or of the venereal orgasm, and also in the much more evident contraction of the scrotum after an irritating injection has been thrown into the cavity of the tunica vaginalis.

It is, therefore, intermediate between cellular and muscular tissue, and might be called the *dartoid tissue*. It was, for a long time, supposed to be confined to the scrotum, but it is met with in many other parts, viz., the vagina, the substance of the nipple, and the parietes of the veins, of which it seems to me to form the external coat.

Some anatomists regard the dartos as nothing more than the remains of the *gubernaculum testis*; but, in the first place, the dartos is found in the fœtus, before the descent of the testicle; and in an adult whose testicle had not escaped from the external abdominal ring, I satisfied myself that the gubernaculum and the dartos existed separately and independently of each other.‡

* From the Latin word *scrotum*, a sac, or purse of leather. The Greek term for the same part is ὄσχεον, and hence the word *oscheocele*, which serves to designate every tumour developed in the scrotum.

† [According to M. Jordan (*Müller's Archives*, 1834), the tissue of the dartos is composed of *uniform cylindrical* filaments, which resemble those of cellular tissue in diameter, but are larger than the varicose filaments of voluntary muscular fibre, and smaller than the involuntary muscular fibres, excepting those composing the iris. They resemble cellular tissue, and not muscle, in their chemical characters, and differ from the former only in presenting a reddish aspect, and in being arranged into longitudinal fasciculi, instead of interlacing in all directions.]

‡ The specimen from which this statement is taken has been presented to the anatomical society by M. Manec.

The dartos has also been incorrectly regarded as a continuation of the *superficial fascia* (see APONEUROLOGY).

The Tunica Erythroides.—This name (derived from the Greek word ἐρυθρὸς, red) is given to a thin membrane, formed by an expansion of the fibres of the cremaster. It is very well marked in the young and vigorous, but becomes partially atrophied in the aged.*

We have already seen (vide *Obliquus Internus Abdominis*, MYOLOGY) that the cremaster is essentially formed of fibres arising directly from the groove of the crural arch, on the outer side of the inguinal canal. The loops formed by the lower portions of the obliquus internus and transversalis are, where they exist, completely distinct from it. The cremaster and the tunica erythroides, which is an expansion of it, are the agents of the sudden upward movement of the testicle, which is very distinct from the slow vermicular motion resulting from the action of the dartos. In a patient whose urethra was extremely irritable, I found that the introduction of a bougie was followed by a sudden and long-continued elevation of the testicles, with a separation of their lower ends. This movement was entirely independent of the dartos and scrotum, which remained flaccid and pendent in front of the thighs.

When the cremaster reaches the testicles, it expands into a number of fasciculi, distributed over the surface of the fibrous coat, and inserted, in the lower animals, by well-marked tendinous fibres, which, however, I have never been able to discover in man. In hydrocele, these fibrous bundles resemble small cords, which, as Sir A. Cooper judiciously remarks, may be mistaken for veins.

The Common Fibrous Coat.—This membrane is very distinct from the tunica vaginalis, which lines its inner surface; it forms a common covering for the testicle and the spermatic cord; it is thin and transparent, narrow along the cord, and expanded below, so as to cover the testicle. At the inguinal ring it divides into two laminæ, one of which, almost always incomplete, is attached to the circumference of the ring, while the other seems to be prolonged within the canal, where it is, however, very difficult to follow it. Modern anatomists regard this fibrous tunic as a prolongation of the *fascia transversalis*, which would be dragged down with the testicle during its descent.

The Tunica Vaginalis, or Serous Coat.—The *tunica vaginalis* is a shut sac, and presents two portions: one, *parietal* (*p*, *fig.* 183), lining the fibrous coat; the other, *reflected* or *testicular* (*v*), which covers the testicle, without that organ being contained within the sac.

The intimate union of the serous and fibrous coats of the testicle affords an example of a fibro-serous membrane, analogous to the dura mater and the pericardium. As the reflection of the tunica vaginalis upon the testicle takes place at a variable height, it follows that a greater or less portion of the cord is covered by this coat.

The arrangement of the tunica vaginalis on one side of the epididymis differs from that on the other. On the *outer side* it immediately invests the epididymis, is then reflected from it, becoming applied to the part reflected from the opposite side of the epididymis, and forms a cul-de-sac, by which the middle of that body is completely separated from the upper border of the testicle. At the bottom of this cul-de-sac are some small openings, leading into a back cavity. It forms, therefore, a fold like the mesentery, at the middle of the epididymis, the two ends of which, however, are closely applied to the testicle. On the *inner side* it rises higher upon the cord than on the outer side, and is separated from the epididymis by the vas deferens and the spermatic vessels. It is easy to detach it from the fibrous coat, where it is reflected upon the testicle, but it adheres closely to the epididymis and to the tunica albuginea.

Its internal surface, free and smooth, exhales a serous fluid, the morbid accumulation of which constitutes the disease called *hydrocele*. In most animals the tunica vaginalis communicates with the peritoneum at all ages; but in man this communication exists normally only during intra-uterine life. After birth the two cavities are perfectly distinct. If, from any cause, this separation is not completed, the tunica vaginalis may form either a hernial sac, containing displaced intestines, or a cyst containing serous fluid effused from the abdomen. In the former case, the disease is called *congenital hernia*, in the latter *congenital hydrocele*.

The Testicles.

The *testicles* (*testes*) are two glandular organs, intended to secrete the spermatic fluid. They are situated in the scrotum, at the sides of and below the penis, and are, therefore, exposed to external violence. They are supported by their coverings, and by the cord formed by the spermatic vessels, and are at a greater or less distance from the inguinal ring, according as the dartos and cremaster are in a state of relaxation or contraction.

The testicles are not situated at exactly the same height, the left descending a little lower than the right. This arrangement, which has not escaped the observation of

* The cremaster is extremely well developed in the stallion; in which animal it is easy to establish the distinction between this muscle and the lower fibres of the internal oblique, the loops of which do not exist in all subjects.

painters and sculptors, assists in protecting them from injury by enabling them to glide one above the other when the thighs are closely approximated, and thus to avoid compression. Their situation is not the same at all periods of life. In the fœtus, they are contained within the abdominal cavity. Sometimes they remain permanently, or much longer than usual in that situation, which, in the natural state, is merely temporary.

Number.—The varieties in the number of the testicles are most of them only apparent. Thus, for example, in almost all *monorchides* (persons having but one testis: from μόνος, single, and ὄρχις, a testicle), that testicle which is absent from the scrotum is situated in the abdomen. Nevertheless, I have had occasion to dissect an individual who had only one testicle; there was an atrophied vesicula seminalis on the side where the testicle was wanting; the vas deferens commenced at this vesicle, and was lost upon the side of the bladder. I was not able to examine the spermatic vessels. The examples of three, four, or five testicles are not well attested.* An epiploic, or fatty tumour, or a cyst, may have been mistaken for a testicle.

Size.—The testicles vary in size in different individuals, and still more at different ages. At the period of puberty, the testicle, which up to that time had been, as it were, in a state of atrophy in comparison with the rest of the body, increases greatly in size. This atrophy, which is normal before puberty, may continue to a more advanced age. In a subject about twenty years of age, in which the penis and larynx were highly developed, I found the two testicles atrophied: they weighed less than a drachm; the epididymis, although it was atrophied, was larger than the body of the testicle.

The two testicles are not exactly of the same size: the left is generally larger than the right; but this difference is so slight and inconstant, that some anatomists have even thought that a slight predominance may be observed in the right.

The following are the average dimensions of the testicle: Length, two inches; breadth, one inch; thickness, eight lines.

Weight.—According to Meckel, the weight of the testicle is four drachms; according to Sir Astley Cooper, one ounce.

Consistence.—It is extremely important, especially in a practical point of view, to judge of the natural consistence of the testicle. The character of this consistence is determined less by the proper substance of the testicle than by the degree of tension of its immediate covering; and in this respect the consistence of the testicle very much resembles that of the eye. In the aged, the seminiferous ducts being empty, the testicle becomes soft, and, as it were, atrophied. It would be still less consistent, if it were not for the serous fluid with which the cellular tissue between these ducts becomes infiltrated.

Figure, Direction, and Relations.—The testicle is oval, but flattened at the sides. This form, added to the polished and slippery character of its surface, enables it easily to avoid compression. The long diameter or axis of the testicle is *directed* obliquely downward and backward; its *lateral surfaces* and its *lower border*† are convex, free, smooth, and constantly lubricated by the serosity of the tunica vaginalis. The *upper* border is straight; it is directed backward, is embraced by the epididymis, which surmounts it like the crest of a helmet, and is covered by the tunica vaginalis in a small portion only of its extent. The spermatic vessels enter at the inner part of this border, and behind the head of the epididymis. The *anterior extremity* of the oval is the larger, and is directed upward and forward; the *posterior extremity* is turned backward and downward. The white colour of the surface of the testicle is owing to its proper fibrous covering, which, on account of its whiteness, is called the *tunica albuginea.*

Structure.—The constituent parts of the testicle are a fibrous membrane, a proper tissue, and certain vessels and nerves.

The *fibrous membrane, tunica propria sive albuginea*, is white, strong, and inextensible; it is analogous to the sclerotic coat of the eye, and, like it, forms the most external coat or shell of the organ which it covers.

The tunica vaginalis invests the outer surface of the tunica albuginea, excepting opposite the epididymis, where the fibrous coat is destitute of the serous membrane for a considerable extent. The serous and fibrous layers adhere closely to each other.

Within the substance of the tunica albuginea, but nearer the internal than the external surface, are a great number of tortuous vessels, which may be seen through the semi-transparent fibrous layer by which they are covered. These vessels project on the internal surface of the tunica albuginea, so that at first it might be thought that they were simply in contact with the membrane, and not within its substance.‡

* I have been consulted concerning a child, who appeared to me to have two testicles upon one side, each of which was as large as that of the opposite side; but it is impossible to decide with certainty upon such a matter until dissection has shown the true nature of pretended supernumerary testicles. Nevertheless, the kind of pain felt upon pressing the body imagined to be a testicle may afford tolerably satisfactory indications during life.

† [M. Cruveilhier differs from most other anatomists in applying the terms *upper* and *lower* to the opposite *borders* of the testicle, instead of *posterior* and *anterior*; on the contrary, he describes the two *extremities* of this organ as *anterior* and *posterior*, instead of *upper* and *lower*, as is usually the case.]

‡ The existence of numerous vessels within the substance of the tunica albuginea has led Sir Astley Coop-

The internal surface of the tunica albuginea is in immediate relation with the proper substance of the testicle, and is connected with it by a great number of vascular filaments, which traverse it in all directions, and divide it into small masses or lobules, and also by the extension of the substance of the gland itself into oblique culs-de-sac, or cells formed by the tunica albuginea, several of which are a line and a half or two lines deep. When the tunica albuginea is carefully removed, filaments of the glandular substance are seen escaping from these small cells, which are most numerous at the upper borders of the testicle. The strength of the vascular filaments which traverse the testicle has led to the opinion that they are all enveloped by a fibrous sheath derived from the tunica albuginea, but I have never been satisfied of the existence of these sheaths.*

Fig. 183.

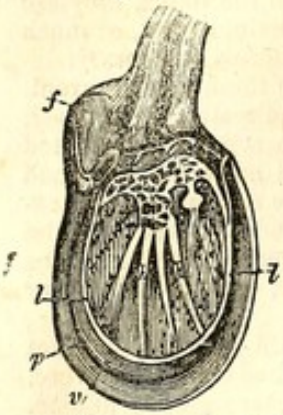

At the upper border of the testicle, the tunica albuginea becomes remarkably thickened, and forms the *corpus Highmori*, or mediastinum testis (*Cooper*). In order to obtain a correct notion of this structure, it is necessary to make a vertical section of the testicle at right angles with its long diameter: we then observe a nucleus (*i*, *fig.* 183), or fibrous thickening of a triangular shape, perforated by bloodvessels, but do not at first sight discover any canals in it; so that we might be inclined to agree with Winslow (who called it the nucleus of the testis) in denying that it contains any canals; or, rather, with Swammerdam, in regarding those canals that do exist in it as destined exclusively for the arteries and veins.

If, after dividing the testicle along its convex border, we reflect the tunica albuginea, we shall see that near the upper border the filaments (*a a*, *fig.* 184) which constitute the substance of the testicle enter (*b b*) numerous spaces existing in the tunica albuginea at this part, pass towards the thickening (*i*) of the upper border, traverse it (*c*) from its posterior to its anterior extremity, and then, uniting together into a greater or less number of tubes, perforate (*d*) the tunica albuginea opposite the head of the epididymis (*e*).

The corpus Highmorianum, moreover, exists only in the anterior half of the upper border of the testicle (see *i*, *fig.* 184). All the bloodvessels reach the testicle at this point, and, having entered it there, divide into two sets; one of these is situated in the substance of the fibrous coat, so as to form its sinuses (the tunica vasculosa), and furnishes a multitude of vessels, which are given off from it in succession, and are distributed to the substance of the gland.† Among these vessels, I would particularly notice one tortuous artery which passes from before backward along the upper border of the testicle. The other set of vessels perforate the corpus Highmorianum directly, and pass from the upper to the lower border of the testicle. The corpus Highmorianum, then, is a thickening of the tunica albuginea, which occupies the anterior half of the upper border of the testicle, and is perforated by the filaments composing the proper tissue of the testicle, and also by a great number of bloodvessels.

Proper Tissue.—The proper substance of the testicle resembles a soft yellowish pulp, grooved by a multitude of small tense and strong columns, which divide it into a great number of masses or *lobules* (*a a*, *fig.* 184). These small columns are nothing more than the vessels given off from the tunica albuginea.‡ Each lobule represents a pyramid, the apex of which is directed towards the upper border of the gland, and the base towards its lower border. The lobules consist of a collection of extremely delicate filaments, folded a very great number of times upon themselves, so as to resemble the granules of glands, and have, in fact, been described as such by some anatomists.◊ These filaments are the *seminiferous tubes*, which were injected by Haller and Mon-

Fig. 184.

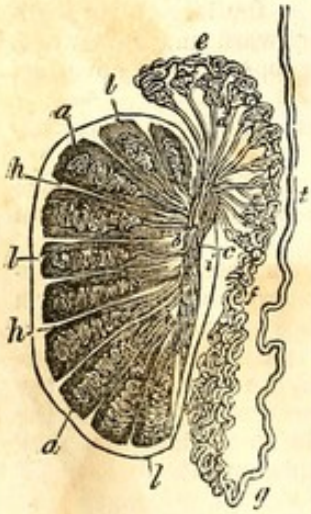

er to describe two layers in it; an external, which he compared to the dura mater, and an internal (the tunica vasculosa), which he likened to the pia mater. I cannot admit this analogy. The vessels contained in the tunica albuginea rather resemble the sinuses of the dura mater than the vascular network of the pia mater. * See note, p. 421.

† [According to Sir Astley Cooper, many of the arterial vessels pass along the septa, extending from the inner surface of the tunica albuginea to the mediastinum, and then turn back and are distributed upon the lobes. The principal veins arise upon the larger ends of the lobes, pass up to the mediastinum, and perforate it.]

‡ [Sir Astley Cooper has described fibrous columns which extend from the inner surface of the tunica albuginea, and unite with similar prolongations given off from the mediastinum testis, and forming the sides of the cells described by M. Cruveilhier (p. 449). From these columns lateral membranes proceed, so as to form septa between the larger masses of glandular structure, while other finer membranous extensions enclose the small lobes in separate pouches. The larger bloodvessels are supported by the columns, and the smaller ones ramify upon the membranous septa and pouches.]

◊ Riolanus described a fibrous thickening of the proper coat of the testicle. The description given by Highmore is very confused; he describes a body *obscurè aut omnid non cavum*, which appears to *perforate* the tunica albuginea, and to convey the semen to the epididymis; he has also represented as opening into this canal certain parallel vessels, which he considered to be an artery and a vein.

ro from the vas deferens. I have in vain attempted to perform the same experiment; the mercury never passed beyond the epididymis. It has been said that each lobule is formed by one or two tubuli, and the number of these tubes has been calculated at 300. Each tubulus is said to be 16 feet long, and $\frac{1}{200}$ of an inch in diameter. According to Monro's calculation, there would be 5000 feet of tubuli seminiferi in the small space occupied by one testicle.

If we take hold of the substance of the testicle with a pair of pincers, and then draw it out slowly, we shall raise a number of apparently knotted filaments from the common mass, some of which will break immediately, while others may be drawn out to a foot, a foot and a half, or two feet, without breaking. It is particularly easy to pull out the filaments when the tissue of the testicle is very moist. The little knots disappear during this process, and the tubuli then assume the character of straight and almost transparent filaments.*

The proper tissue of the testicle adheres to the tunica albuginea by the bloodvessels only, excepting near the upper border of the testicle. In this situation the tubuli are lodged in the cells or spaces, already described, in the substance of the tunica albuginea; they all pass towards the corpus Highmori, traverse it from behind forward, and form within its substance what Haller described as the *rete vasculosum testis* (*c*, *figs.* 184, 185), because he supposed that the seminiferous tubes in this situation communicated with each other.†

Lastly, the tubes composing the rete unite into an indeterminate number of efferent ducts (*d*), estimated at from ten to thirty, which perforate the tunica albuginea, opposite the head of the epididymis.

Vessels and Nerves.—The *testicular artery*, the principal division of the spermatic, divides, before entering the testis, into several branches, which pass into the tunica albuginea along the upper border of the gland, and are distributed as I have already pointed out when speaking of the corpus Highmori. The *veins* are very numerous, are arranged in an analogous manner, and form the spermatic veins. The *lymphatics* are very numerous, and are divided into the superficial and deep.

The *nerves* are derived both from the ganglionic and the cerebro-spinal system. They have not been traced into the interior of the testicle, and yet the sensibility of that organ is sufficient evidence of their existence there.

The *serous cellular tissue*, by which the seminiferous ducts are united, is so delicate, that it can only be shown bv the aid of a very favourable light.

The Epididymis.

The epididymis (*e f*, *figs.* 184, 185) is the vermiform appendage which lies along the superior border of the testicle, like the crest upon a helmet. Its name is derived from its position (ἐπὶ, upon, δίδυμος, the testicle).

It is so situated that it does not precisely occupy the superior border of the testicle, but encroaches a little upon its outer face (see *fig.* 182, a section of the right testis), so that when the tunica vaginalis is opened, and the inner side of the testicle examined, we cannot see the epididymis. It is closely connected with the testicle by its anterior extremity, which is remarkably enlarged, and is called the *head*, or *globus major* (*e*); its middle portion or body (*f*) is separated from the testis; and it again adheres by its posterior extremity, called the *tail*, or *globus minor* (*g*); which, after being prolonged as far as the posterior extremity of the testis, turns upward, by being reflected upon itself, and gives origin to the vas deferens (*t*). It is flattened from above downward, concave below, and slightly flexuous; its two extremities are covered by the tunica vaginalis only above and on the outside, but its body is completely enclosed by that membrane, which forms a fold for it like the mesentery. (See *Tunica Vaginalis.*)

Structure.—When the tunica vaginalis, which gives the epididymis a smooth appearance, is removed (as in *fig.* 185), the latter resembles a cord, so twisted upon itself that it would appear impossible at first sight to disentangle it. This cord is hollow, as may be shown by injecting mercury or a coloured liquid into it through the vas deferens. The canal or duct which forms the epididymis is not unfrequently found distended with semen; and then we may ascertain by simple inspection, as well as by injecting it, that it is of a determinate size, and that its parietes are thin and semi-transparent.

The epididymis is intimately connected with the body of the testicle by its *head* only; the other means of attachment between the two parts consisting exclusively of rather dense cellular tissue, and a fold of the tunica vaginalis. The head of the epididymis is united to the testicle by several ducts, the number of which varies from ten to thirty.

* [The seminiferous tubes are of the same diameter throughout. According to Lauth, they most commonly terminate in loops, and by numerous anastomoses; in one instance only did he observe a free closed extremity. In some animals, Müller found the seminal tubes ending in free extremities; and the same mode of termination was frequently seen by Krause in the human testis. Like the uriniferous tubes, the tubuli seminiferi terminate, therefore, in two ways.]

† [Immediately before the tubuli pass into the corpus Highmori to form the rete, they become rather larger and straight, and are hence called the *tubuli recti* (*d d*, *fig.* 184): the tubuli composing the rete are stated by Lauth to vary from seven to thirteen; they are tortuous, and, as supposed by Haller, anastomose.]

They form several groups, which emerge from the corpus Highmori, and immediately afterward become convoluted, so as to form the *head* or *globus major* of the epididymis. These vessels, which are called the *vasa efferentia*, or *coni vasculosi* (*d*), are perfectly distinct at their exit from the corpus Highmori; but, after a short course in the globus major, they unite into a single canal, the numerous convolutions of which constitute the vermiform body called the epididymis. It is possible, by careful and minute dissection, to unravel this duct, the folds of which, shaped like the figure 8, are united by very dense cellular tissue. Monro, who even counted the number of its inflections, has calculated its length to be about thirty-two feet.*

Fig. 185.

It is supplied with *arteries*, and some *veins* and numerous *lymphatics* issue from it. Its *nerves* are derived from the testicular, and accompany a small branch of the hypogastric artery, which has been named the *deferential artery* by Sir Astley Cooper.

Not unfrequently a dense cord, having the same structure as the vas deferens, is found proceeding from the epididymis; this cord is the vas aberrans.—(*Haller.*)

The supernumerary ducts of this nature, injected with mercury by Haller, extended for a few inches into the cellular tissue of the spermatic cord.

The Vas Deferens.

The vas deferens (*t*, *figs.* 181, 184, 186), the excretory duct of the testicle, extends from the epididymis to the ejaculatory duct (*fig.* 186), which may be regarded as a continuation of it. It commences at the point where the caudal extremity of the epididymis becomes separated from the testicle.

The following is a description of its very complicated course: in its first or *testicular* portion it passes from behind forward and upward along the upper border of the testicle, almost parallel with the epididymis, from the inner edge of which it is separated only by the spermatic arteries and veins. In this first portion of its course the vas deferens pretty closely resembles a braided cord, and is, moreover, folded a great number of times, like the canal of the epididymis.

The second, *funicular* or *ascending* portion of the vas deferens, forms part of the spermatic cord, and passes directly upward towards the inguinal ring. There it is in relation with the spermatic artery and veins, which are placed in front of it, and from which it is perfectly distinct, being surrounded by an independent sheath of filamentous cellular tissue. It is convoluted, at its lower part, for the space of an inch or an inch and a half, but is straight in the rest of its extent. The third or *inguinal* portion of the vas deferens passes through the inguinal canal to enter into the abdomen. Like that canal, it is directed obliquely upward, outward, and backward, and is from an inch and a half to two inches and a half in length. The lower margins of the obliquus internus and transversalis seem to curve over it; it crosses the epigastric artery at right angles, a little above the bend formed by that artery, where it changes its direction from horizontal to vertical; in this portion of its course, as well as in the preceding, the vas deferens forms part of the spermatic cord. The fourth or *vesical* portion.—Having arrived within the abdomen, the vas deferens leaves the vessels and nerves, proceeds vertically downward into the pelvis, passes along the side (*fig.* 181) and then the posterior surface (*fig.* 186) of the bladder, in which position it is retained by the peritoneum, crosses very obliquely the fibrous cord formed by the remains of the umbilical artery, and is then directed inward and downward to the inferior fundus of the bladder. Having arrived opposite and internally to the entrance of the ureter into the bladder, it is directed horizontally inward and a little forward like the vesicula seminalis (*s*, *figs.* 181, 186), internally to which it is situated, and gradually approaches nearer and nearer to its fellow of the opposite side, with which it seems to be joined. At the anterior extremity of the vesicula seminalis it unites at an acute angle with the efferent duct (*c*, *fig.* 186) of the latter, the union of the two forming the *ejaculatory duct* (*d*). In its vesical portion, for about two inches above the vesiculæ seminales, the vas deferens is considerably dilated, and, at the same time, its parietes become thinner.

On the inner side of the vesicula seminalis the canal still continues dilated, and is sometimes sacculated, and has a flexuous appearance. Each sacculus is formed by a small ampulla, which opens into the cavity of the canal.

The vas deferens forms, therefore, in this situation, a sort of provisional reservoir, resembling, in its internal aspect and structure, the vesiculæ seminales.

The *spermatic cord*, or cord of the spermatic vessels, is formed by the spermatic artery†

* [The average length of the vasa efferentia is stated by Lauth to be eight inches; they diminish in size as they approach the canal forming the epididymis, which they enter at intervals of about three and a quarter inches from each other. The length of that canal is, according to the same author, about twenty-one feet.]

† [Also the deferential artery, and the cremasteric branch of the epigastric artery.]

and veins, the lymphatic vessels, the spermatic plexus of nerves, a branch of the genito-crural nerve, and the vas deferens, all being surrounded by the cremaster muscle and the common fibrous coat.

Structure.—The following are the principal points concerning the structure of the vas deferens: It is harder than any other excretory duct, and it can be recognised by the touch among the other constituent parts of the cord, both in the healthy and in the diseased state, in which latter condition it may become considerably enlarged. It is perfectly cylindrical. Its bore is so small that it is almost capillary, and will scarcely admit Méjan's probe. Its parietes are thick, and contrast singularly with the fineness of its bore.

Several anatomists admit the existence of circular and longitudinal muscular fibres in this duct. Leuwenhoek demonstrated longitudinal fibres, with circular fibres beneath them. All that I have been able to discover in the human vas deferens, even by the aid of the glass, are circular. In their appearance, and kind of cohesion, they present much analogy to muscular fibres; but it is in the larger animals only, in the horse, for example, that their muscularity can be clearly ascertained, and that we find distinctly a very thin longitudinal and superficial layer of fibres, with very thick and strong circular fibres beneath. The internal surface of the vas deferens is white, rough, and alveolar; its roughness is due to small and very white fibrous fasciculi, some of which are directed longitudinally, while others are circular, and which are either regularly or irregularly arranged.

The mucous membrane lining the vas deferens is so thin that it is difficult to demonstrate it.

The Vesiculæ Seminales.

The vesiculæ seminales are two membranous pouches, which serve as reservoirs for the semen.*

They are *situated* (*s*, *fig.* 181) between the rectum and the bladder, on the outer side of, and parallel to, the vasa deferentia. As they are directed obliquely inward and forward (*s*, *fig.* 186), their anterior extremities are closely approximated, being separated from each other merely by the width of the vasa deferentia, while their posterior extremities are very far asunder; they thus form two sides of an isosceles triangle, within the area of which the bladder (*a*) is in immediate relation with the rectum. They are flattened and oblong, and are expanded at their posterior extremities, which sometimes project beyond the inferior fundus of the distended bladder, and always do so when that organ is contracted. Their anterior extremities are narrowed, and surrounded by the prostate, and their surface has a sacculated appearance. They vary in *size*, which is not always equal on the two sides; and they are much larger in the adult than in youth or old age. Their size also varies according to whether they are empty or full. They are from two inches to two inches and a half long, and about six lines broad, and two or three lines thick.

Fig. 186.

Their *relations* with the bladder and the rectum are not direct; for they are surrounded with a filamentous tissue, consisting of transverse fibres, which separates them from the neighbouring parts, and appears to me to be analogous to the tissue of the dartos.

When divided in various directions, the vesiculæ seminales exhibit a collection of cells, communicating with each other, and filled with a yellowish brown, thick, viscid fluid, very different in appearance from semen as ejaculated during life. The sacculi of the external surface, and the cells and septa of the interior of the vesiculæ, are formed by the extremely complicated convolution of a sort of intestinal tube, or narrow oblong sac, on which I have never been able to find any appendages, ramifications, or diverticula. When unravelled (as at *s*), its length varies from six to eight inches; its convolutions are attached to each other by fibrous tissue, but they may always be separated, either with or without maceration. I have seen an unfolded vesicle a foot in length; in other subjects I have seen two distinct pouches on each side, one of which was extremely small. Lastly, the internal surface of the seminal vesicles has the same rough and alveolar appearance as that of the vasa deferentia.

* [The semen, considered anatomically, consists, according to Wagner, of *liquor seminis*, *seminal granules*, and *seminal animalcules*; the latter were discovered by Ham, and described by Leuwenhoek. In the human subject, the seminal granules are round granulated bodies, about $\frac{1}{4800}$th to $\frac{1}{3600}$th of an inch in diameter; the seminal animalcules, or spermatozoa, have an elliptical body, about $\frac{1}{9000}$th to $\frac{1}{7200}$th of an inch in diameter, and a long caudal filament: their total length is from $\frac{1}{600}$th to $\frac{1}{480}$th of an inch: their organization is yet unknown; but in the spermatozoa of the bear, Valentin has lately observed evidences of a definite internal structure; they perform very rapid movements, which continue some hours after evacuation or removal from the body. They are not found before puberty, and then only in the vesiculæ seminales, vas deferens, and epididymis. The semen of the testis contains, besides the seminal granules, certain vesicles or cysts, in which, as shown by Wagner, the future spermatozoa are developed.]

The *structure* of the parietes of the vesicles is also precisely the same as that of the deferent vessels, excepting that the external coat is thinner; in the larger animals this coat is evidently muscular, and it appears to me to be so in the human subject also. I have in vain attempted to find the glands described by Winslow in the substance of the walls of the seminal vesicles.

Efferent Ducts of the Vesiculæ Seminales.—From the anterior extremity or neck of each vesicle, which we have said is situated in the substance of the prostate, arises a very delicate duct, the *efferent duct* (*c*) *of the vesicula seminalis:* this duct almost immediately unites with the vas deferens, the walls of which are thin and very dilatable in this situation. By the junction of the two, which occurs at a very acute angle, the *ejaculatory duct* (*d*) is formed; this passes through the prostate (which is shown divided in the figure), upward and forward, parallel to and in contact with its fellow of the opposite side, but without communicating with it. The ejaculatory ducts have very thin parietes, but they are tolerably wide, and very dilatable; closely applied to each other, they open separately on the enlarged extremity of the *verumontanum*, one on the right, the other on the left (*fig.* 182).

The Penis.

The *penis*, the organ of copulation, is situated in front of the symphysis pubis. When collapsed, it is flaccid, and forms a curve with the concavity looking downward; but during erection, it is large and hard, and forms a curve with its concavity turned upward.

It is cylindrical when collapsed, but has a triangular prismatic form, with blunt edges, when in the opposite condition. Two of these edges are lateral, and are formed by the projection of the corpus cavernosum; the other is anterior, and corresponds with the canal of the urethra. Its posterior extremity is attached to the pubis; its anterior extremity forms a conical enlargement, called the glans, on which is seen the orifice of the urethra.

Structure.—The penis consists essentially of the corpus cavernosum and the canal of the urethra, the expanded extremity of which forms the glans penis. Some proper muscles are attached to it; it receives large vessels and nerves, and it is covered by integument.

The Skin of the Penis and Prepuce.—The skin of the penis has several peculiarities: thus, it is very thin, although not so thin as that of the scrotum and the eyelids. In this respect it contrasts remarkably with the thick hairy skin which covers the cushion of adipose tissue situated over the symphysis; it is generally of a browner colour than that of the rest of the skin; it has no hair bulbs visible to the naked eye; it is extremely movable, being capable of gliding forward upon the corpus cavernosum, of forming a covering for tumours in the scrotum, and also of folding upon itself when the penis is reduced to its smallest dimensions. This great mobility of the skin is owing to the looseness of the sub-cutaneous cellular tissue, which is continuous with the dartos, and appears to me to be of the same nature; like that structure, it never contains fat, but may become infiltrated with serum.

The Prepuce.—The skin of the penis forms a non-adherent sheath for the glans, upon which it advances, and either projects beyond it or not, according as that part is flaccid or distended. At the free border of this sheath the skin does not terminate abruptly, but is reflected upon itself, assumes the characters of a mucous membrane, and passes backward as far as the base of the glans, so as to line the inner surface of the cutaneous layer. Opposite the constriction or neck surrounding the glans, the mucous membrane or reflected skin again becomes reflected over the glans, to which it forms a closely adherent covering, and at the margin of the orifice of the urethra becomes continuous with the mucous membrane lining that canal. The non-adherent sheath which covers the glans is called the *prepuce.**

Sometimes the orifice of this sheath is so narrow as to prevent its being easily drawn backward, especially during erection. This constitutes what is called *phymosis.*† Circumcision, an operation which consists in removing an annular portion of the prepuce, was, as we know, a general custom among the Jews, and is now recognised among the operations of surgery.

The length of the prepuce varies in different individuals; in some it is very short, and only covers one half of the posterior third of the glans.

The term *frænum præputii* is applied to a triangular fold of mucous membrane, which is reflected from the prepuce upon the furrow on the lower surface of the glans, below the urethral orifice. Sometimes the prolongation of the frænum as far as the orifice renders erection painful, and requires a slight operation, called section of the frænum.

The cellular tissue, between the cutaneous and mucous layers of the prepuce, partakes of the characters of the sub-cutaneous cellular tissue of the penis; its looseness

* [Beneath the mucous membrane covering the constriction behind the corona glandis are situated clusters of small sebaceous glands, named *glandulæ Tysoni*, or *odoriferæ*.]

† When this malformation exists, if the prepuce be drawn back over the base of the glans, it cannot be returned; this condition of the parts, and the sort of strangulation resulting from it, constitutes what is known by the name of *para-phymosis*.

enables the prepuce to be unfolded, and this takes place more or less completely during erection.

The Corpus Cavernosum.—The corpus cavernosum, so named on account of its structure, forms the greater portion of the penis; it commences behind by a bifurcated extremity, forming its *roots*, or *crura*. Each root arises immediately on the inside, and above the tuberosity of the ischium, by a very slender extremity, and gradually increasing in size, passes forward and inward along the ascending ramus of the ischium and the descending ramus of the pubes, to both of which it adheres intimately. At the symphysis the two roots unite. The triangular interval between them is occupied by the canal of the urethra.

The corpus cavernosum results, therefore, from the union of two distinct conical roots; and on this account the older anatomists distinguished two corpora cavernosa; but the communications existing between its two halves are opposed to any such distinction.

The corpus cavernosum is cylindrical, and presents a longitudinal groove above, in which are lodged the dorsal vessels and nerves of the penis, and a broad and deep groove below, in which the urethra is situated. The anterior extremity is obtuse, and is embraced by the base of the glans, with which it does not appear to have any vascular communication.

Structure.—The corpus cavernosum is composed of a very strong fibrous cylinder, filled with a spongy or erectile tissue.

The Fibrous Cylinder.—The external coat is of a fibrous nature, and is remarkable for its thickness, which is one or two lines; for its strength, which is such that the corpus cavernosum will bear the whole weight of the body without breaking, as may be proved experimentally upon the dead body; and for its *extensibility and elasticity*, properties which do not belong intrinsically to the tissue itself, but depend upon the areolar disposition of its fibres.*

Septum of the Corpus Cavernosum.—The interior of the cavernous body is divided into two lateral halves by an incomplete septum, formed of very strong vertical fibrous columns, which are much thicker and more numerous behind than in front. This median septum (*septum pectiniforme*, *b*, *fig.* 187), between the two halves of the corpus cavernosum, is not complete; it appears to be intended to prevent too great a distension of this part during erection.

The Spongy or Erectile Tissue.—An areolar tissue (*a a*), the meshes of which contain a greater or less quantity of blood, occupies the interior of the fibrous cylinder of the corpus cavernosum. This tissue, which is the chief agent in erection, consists of an interlacement of veins, supported by prolongations or *trabeculæ*, given off from the inner surface of the fibrous membrane.

If air or any fluid be injected into the crura of the corpus cavernosum, the penis will acquire the same size as it has during erection, and the injection will pass readily into the veins; we may therefore conclude that all the cells of the corpus cavernosum communicate with each other, and, farther, that they communicate freely with the veins. If the corpus cavernosum be distended with tallow, and then, after being allowed to dry, if the injection be dissolved out by hot oil of turpentine, we shall find that the cavernous body presents a spongy structure, analogous to that of the spleen. The several gradations from true veins to spongy tissue may be traced in the venous plexus, situated at the root of the penis. At first we find veins communicating with each other laterally, as it were, by perforations; then the communications become more and more numerous; and, lastly, in the corpus cavernosum all traces of distinct vessels are lost, and nothing can be detected but a mass of cells, apparently resulting from the anastomoses of veins. The structure of the spongy tissue of the corpus cavernosum is, therefore, essentially venous.

A transverse section of the corpus cavernosum (*fig.* 187), after it has been prepared in the manner above indicated, exhibits an appearance of cells, somewhat resembling that seen on a section of the body of a vertebra; these cells are bounded by laminæ, which appear to be chiefly derived from the lower wall of the corpus cavernosum, on the inner surface of which is found a convexity, corresponding with the groove for the urethra (*d*). These laminæ radiate, as from a centre, to the entire internal surface of the cylinder, represented by the corpus cavernosum.

Fig. 187.

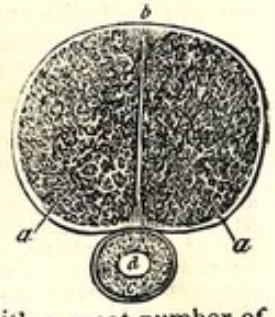

Vessels.—The *veins* of the corpus cavernosum are extremely large, and are divided into the *dorsal veins* of the penis and the proper veins of the cavernous body; they all pass beneath the symphysis, and are received into fibrous canals, through which they are transmitted into the pelvis. These veins are provided with a great number of valves, so that injections thrown into the trunks cannot pass into the branches.

* [The outer coat of the corpus cavernosum and the trabeculæ, in its interior, consist of tendinous fibres, mixed with some elastic tissue. In the penis of the horse there are pale red fibres, differing from cellular, tendinous, and elastic tissue, but which, according to Müller, do not possess muscular contractility.]

The *arteries* arise from the internal pudic, and enter the substance of the corpus cavernosum. Injection of these arteries does not produce erection until the fluid has passed from them into the veins.*

The *lymphatic vessels* are little known.

No *nerves* have been traced into the interior of the corpus cavernosum.†

The Triangular Suspensory Ligament of the Penis.—This ligament is composed of yellow elastic tissue, and extends in the median line from the symphysis pubis to the corpus cavernosum. Muscular fibres have been described as existing in it; but it is probable some fibres prolonged from the bulbo-cavernosus, and now known as the muscle of Houston, have been regarded as forming part of this ligament. I have seen the suspensory ligament reach along the linea alba, half way up to the umbilicus.

Muscles of the Penis.

These are eight in number, four on each side, viz., the *ischio-cavernosus*, the *bulbo-cavernosus*, the *pubio-urethralis*, and the *ischio-bulbosus*.

The Ischio-cavernosus, or the Erector Penis.

The ischio-cavernosus (*c*, *fig.* 163) is an elongated muscle, *situated* upon the corresponding root of the corpus cavernosum; it is curved upon itself, and is aponeurotic in part of its extent.

It *arises* from the inner lip of the tuberosity of the ischium, below the transversus perinæi, by tendinous and fleshy fibres, and also from the surface of the root of the corpus cavernosum. From these points its fibres pass inward, and are *inserted*, after a short course, into the edges of the upper surface of a very strong, shining, and fasciculated aponeurosis, having its fibres directed from behind forward, which covers the corresponding root of the cavernous body, upon which it is then prolonged. The fleshy fibres, terminating at the edges of the aponeurosis, form two bundles; one internal, and extending upon the inner side of the root, the other external, which passes on the outer side of the same, and is prolonged, much farther than the internal fasciculus, upon the cavernous body. In order to see the structure of this muscle, it is necessary to make a longitudinal incision into the aponeurosis, which entirely covers its lower surface; we then observe a muscular layer, which is tolerably thick behind, but thin in front, and is formed partly by the original fibres, and partly by others arising from the root of the corpus cavernosum itself.

Relations.—Below, with the cellular tissue and the dartos; above, with the root of the corpus cavernosum, upon which it is closely applied; on the inside, with the bulbo-cavernosus, being separated from it by a triangular space, the base of which is directed backward.

Uses.—It acts solely upon the corpus cavernosum, drawing the root of the penis downward and backward; instead of compressing the root of the corpus cavernosum by the contraction of its fibres, it tends, on the contrary, to dilate its cavity, by separating the wer from the upper wall, and, in this manner, facilitates erection.

The Bulbo-cavernosus, or Accelerator Urinæ.

This muscle (*d*, *fig.* 163) is much larger than the preceding; it is *situated* in front of the anus, extending along the lower surface of the bulb and the spongy portion of the urethra, upon which it seems to be moulded.

It *arises* in front of the sphincter ani by a median fibrous raphé, which is common to the two muscles of this name, and which appears to arise from the bulb, to which it adheres closely; while the external fibres arise from the posterior margin of the triangular ligament, or deep perineal fascia, and frequently from the rami of the ossa pubis, opposite that margin. From this double origin the fibres pass forward, and terminate in the following manner: the outermost fibres form a thin layer upon the lower surface of the triangular ligament, and are *inserted* by short, tendinous fibres to the inner side of the root of the corpus cavernosum; the middle fibres, which are larger, are directed obliquely inward, and are *inserted* by very distinct tendinous fibres immediately in front of the point of junction of the roots of the corpus cavernosum, in the sort of groove between that body and the urethra; the innermost fibres are the longest; they pass directly for-

* [Müller has described, besides the nutritious arteries of the corpus cavernosum, which terminate, as usual, in the veins, a peculiar set of vessels, called the *arteriæ helicinæ*. They are short, curled branches, much larger than capillaries, and ending abruptly in free rounded extremities; they project either singly, or in tufts arising from one stem, into the venous cells, by the lining membrane of which they are supported and invested. They are found principally in the posterior portions of the cavernous and spongy bodies, and are more marked in man than in animals. In the horse they are very indistinct; in the elephant they do not exist at all. Müller believes that the blood, during erection, is poured out directly from these vessels into the venous cells; but no openings through which the blood could escape have been detected, either in their sides or at their extremities, nor is analogy in favour of their existence.

According to Valentin, the so-called helicine arteries are the divided branches of common arteries curled up (after having been injected), in consequence of the retraction of the elastic trabeculæ on which they are supported; to this it is replied, by Müller, that these vessels may be seen in cells deeper than the surface of the section. Valentin farther maintains that the arteries terminate in the veins by wide, funnel-shaped orifices.]

† [Numerous nerves enter the corpus cavernosum; they are derived from the internal pudic and sympathetic nerves, and have been carefully traced by Müller.]

ward, and, at the point where the penis is bent in front of the pubis, are inflected outward (*e*, *fig.* 163), pass upon the sides of the penis, and terminate on its dorsal surface, becoming continuous with the suspensory ligament. The last-named termination appears to me to constitute the muscle described by Houston, which, according to that anatomist, is intended to compress the dorsal veins of the penis* in man and other animals; but it is evident, on the one hand, that it cannot compress the veins of the penis; and, on the other, as M. Lenoir has pointed out, that the dorsal veins of the penis are cutaneous veins, which do not communicate with those of the corpus cavernosum.†

Relations.—Below, the bulbo-cavernosus corresponds with the dartos, from which it is separated by the superficial perineal fascia by a very thin layer of fat, and by a proper fibrous sheath. Above, it is in relation with the bulb of the urethra, which it embraces, like a contractile sheath, resembling the sheath around the stems of grasses. The inner border is continuous with the muscle of the opposite side; so that, at first sight, it might be thought that there is but one bulbo-cavernosus.

Uses.—Its attachment to the inner side of the corpus cavernosum enables it to separate the lower wall of that body from the upper, and, consequently, to induce the entrance of the blood. It therefore contributes powerfully to erection. On the other hand, by compressing the urethra, it accelerates the expulsion of the urine and semen.

The Pubio-urethralis.

This muscle, known also as the *muscle of Wilson*, because it was described by that anatomist, may be regarded as the continuation of the levator ani. The two muscles arise from the middle of the sub-pubic arch, and descend first upon the sides and then on the lower surface of the membranous portion of the urethra, which they surround as in a ring. They are situated behind the triangular ligament, or *deep perineal fascia.*‡ When spasmodically contracted, it is said that they may arrest the point of a catheter.

The Ischio-bulbosus.

We may describe under this name a small muscle situated below the deep perineal fascia. It is stronger than the transversus perinæi; it arises from the ascending ramus of the ischium and the descending ramus of the pubis, and terminates on the sides of the bulb. This muscle, which is of a triangular shape, is separated from the one last described by the deep perineal fascia, so that it cannot be regarded as a dependance of the levator ani.§

The Urethra.

The *urethra* is the excretory passage for the urine, and in the male it serves the same purpose in regard to the semen.

Its *direction* has been particularly studied. Commencing at the neck of the bladder, it passes forward and downward; having arrived beneath the symphysis pubis, it describes a slight curve, with the concavity directed upward, embraces the symphysis, rises a little in front of it, and then enters the groove on the lower surface of the corpus cavernosum. Beyond this point its direction is determined by that of the penis; and it

* [The compressores venæ dorsalis penis, according to Houston (*Dublin Hosp. Reports*, vol. v.), arise from the rami of the pubes above the erectores penis and the crura of the corpus cavernosum, expand into a thin layer, pass upward, inward, and forward, and unite in a common tendinous band over the dorsal vein. They are separated by the crura from the erectores penis, of which muscles, he says, they might otherwise be regarded as portions: the anterior layer of the triangular ligament and the pudic artery are interposed between them and the muscles of Wilson.]

† Dissertation sur quelques Points d'Anatomie, de Physiologie, et de Pathologie, No. cccxv., 1833.

[The dorsal veins return the greater part of the blood from the glans penis and corpus spongiosum, as well as the skin, and are also joined by branches from the corpus cavernosum. (See M. Cruveilhier's own description of these veins, ANGEIOLOGY).]

‡ [In the description of the muscles given by Wilson himself (*Med. Chir. Trans.*, vol. i., p. 176, 177), it is stated, that "the line of tendon connecting the two bellies of these muscles is, in general, very distinctly seen running from the apex of the prostate gland, along the under surface of the membranous portion of the urethra, until it enters the corpus spongiosum penis." From this it would appear that the muscles discovered by him are placed *between* the two layers of the ligament, not behind its posterior layer.

On the same plane with Wilson's muscles, *i. e.*, between the layers of the ligament, are situated two small transverse muscles, which arise, one on each side, by broad thin tendons, from the rami of the ischia, near their junction with those of the ossa pubis, immediately above the crura penis and their erector muscles; from thence the fleshy fibres pass transversely inward and upward, and are inserted along the median line of the upper and under surface of the membranous portion of the urethra by means of two tendinous structures, which extend, one above the urethra, from the fascia covering the prostate to the union of the crura penis in front of the triangular ligament, and the other below that canal, from the fascia on the prostate to the central point of the perineum: to this tendinous structure the vertical muscles of Wilson are also attached. The pudic arteries run either above or below these transverse muscles, the lower fibres of which pass below Cowper's glands, *i. e.*, more superficially, when viewed from the perineum.

These transverse muscles are described and figured by Santorini (*Observ. Anat.*, c. x., § viii., t. 3, fig. 5; also, *Septemdecim Tabulæ*, t. 16, fig. 1), who states, however, that they are attached only to the lower surface of the urethra, behind the bulb; he named them elevatores urethræ, or ejaculatores. It has been recently shown by Mr. Guthrie (*Lond. Med. and Surg. Journ.*, 1833, p. 491, 492; also, *On the Anatomy and Diseases of the Neck of the Bladder and of the Urethra*, 1834, p. 34, &c.) that the transverse muscles of Santorini are inserted, as already described, both above and below the urethra; and that the vertical muscles of Wilson are blended with them at their insertions: he therefore proposes to regard them as one muscle, which has been termed the *compressor urethræ*.]

§ [The description of this muscle corresponds exactly with that of the *transversus perinæi alter* of Albinus.]

describes, with that organ, a second curve, much more marked than the preceding, having its concavity directed downward, but only in the state of relaxation, for the curve no longer exists when the penis becomes elongated, either from erection, or from direct traction.

It follows, therefore, that, except during erection, the urethra describes two curves, like the letter S;* but when the penis is elongated, it forms only a single curve, which is permanent.

Although the curvature of the urethra is not so rigid as to prevent the introduction of a straight instrument into the bladder, it would be wrong to conclude that the canal itself is straight. It must be remembered that organic membranous ducts are sufficiently pliable to accommodate themselves to the direction of instruments introduced into them; but the effacing, or the artificial removal of the curves, is very different from their non-existence. Moreover, the curvature of the urethra is demonstrated by the impossibility of drawing a straight line from the neck of the bladder, and passing a short distance below the symphysis to the point where the urethra joins the corpus cavernosum; also by the curve acquired by bougies after remaining for some time in the urethra; and, lastly, by the curvature presented by a mould obtained by injecting the bladder and urethra with any substance capable of becoming solid.

Dimensions.—The *length* of the urethra is from eight to nine inches; it is sometimes less than eight. The extreme dimensions noticed by Whately,† in measurements taken from forty-eight subjects, are nine inches six lines and seven inches six lines. It is difficult to estimate the *width* of the urethra. According to Home, it is four lines, except at the orifice, where it is only three. It is quite impossible to judge of its width externally, on account of the thickness of its walls, and especially on account of their being unequal. The extreme dilatability of the canal allows the introduction of instruments of considerable caliber, as in the operation of lithotrity.

The urethra is considered as divided into three portions, as different in their structure as in their relations; these are the *prostatic*, the *membranous*, and the *spongy portions*.

The Prostatic Portion.—This part of the urethra, which forms, as it were, a continuation of the bladder, and the commencement of the urethra, is called prostatic, because it appears to be hollowed out of the glandular body called the *prostate*, the description of which must be inserted here, on account of its intimate connexion with the urethra.

The *prostate* (*i*, *fig.* 181), a whitish glandular body, is *situated* in front of the neck of the bladder, and embraces it; it is behind the symphysis pubis, and in front of the rectum. It is shaped like a cone, with its base turned backward, and its truncated apex forward. Its *axis* or long diameter is horizontal, but slopes a little from behind downward and forward. It has often a bi-lobed appearance in man, but it is never truly double, as in a great number of animals.

The size of the prostate varies greatly in different subjects. The following dimensions have been taken from the measurements of the prostates of adults: Vertical diameter, twelve lines; transverse, eighteen; antero-posterior, or length, fifteen. Sometimes it acquires three or four times its nominal size; the increase may affect either the whole gland or one half, or the middle lobe only.

Relations.—We shall examine the relations of the prostate with the parts corresponding to its outer surface, and with those which are situated within it.

Relations of the Outer Surface of the Prostate.—The *lower surface* corresponds with the rectum, adhering to it by tolerably dense cellular tissue, in which there is never any fat or serum; and hence the rule of examining the prostate by the rectum. In consequence of alterations in the condition of the rectum, that intestine sometimes projects on each side beyond the prostate, as during distension; and sometimes, as when it is contracted, the prostate projects beyond it laterally. The lower surface of the gland is smooth, and is traversed in the median line by an antero-posterior furrow, which is well marked in some subjects, and divides it into two equal portions.

The *upper surface* is in relation with the recto-vesical fascia (*q*, *fig.* 181), or, rather, with some very strong ligamentous bundles, which extend from the pubes to the bladder, and are called the ligaments of the bladder. This surface has no immediate relations with the arch of the pubes, behind which it is placed; it is always some lines distant from it. Nevertheless, by means of a silver catheter or sound, introduced into the bladder, we may draw the prostate under the pubes, and make it project in the perineum.

The *sides* are embraced by the levator ani and the levator prostatæ. When the prostate is pushed downward by the catheter, its sides are embraced by the circumference of the arch of the pubes, and they then approach very near the trunk of the internal pudic artery.

The *base* of the prostate embraces the neck of the bladder, and is prolonged a little upon that organ, so as to surround the vas deferens and the neck of the vesiculæ seminales.

* It was this direction of the canal which suggested to J. L. Petit the idea of making silver bougies, shaped like the letter S, to remain in the passage.

† An Improved Method of treating Stricture of the Urethra, 1816.

The *apex* terminates behind the membranous portion of the urethra.

Relations of the Prostate with the Parts situated in its Interior.—The prostate is perforated by the urethra, by the ejaculatory ducts, and by its own excretory ducts.

The *relations of the urethra with the prostate* vary in different subjects: thus, sometimes its lower three fourths only are surrounded by the gland, which is accordingly wanting above, and is merely grooved, not perforated by a canal; sometimes the prostate forms a complete hollow cylinder around the urethra. The portion of the prostate situated above the urethra is scarcely ever thicker than the part beneath it. In some cases, however, the urethra has been found occupying the lower part of the prostate, and only separated from the rectum by a very thin layer of glandular substance. When such is the case, the rectum is very liable to be wounded in the different steps of the operation of lithotomy.*

In the natural state the prostate does not project into the urethra; but not unfrequently we find a prominence, of greater or less size, rising from the lower part of the urethra, opposite the base of the prostate, and obstructing more or less completely the commencement of that canal: this tubercle was named by Lieutaud *la luette vésicale* (*uvula vesicæ*); by Sir Everard Home, an enlargement of the middle lobe of the prostate. But, in the first place, this prominence only exists in disease; and, secondly, there is no middle lobe, unless that term be applied to the slightly-grooved, and, therefore, thinner portion by which the two lateral halves of the prostate are united.

Relations of the Ejaculatory Ducts with the Prostate.—The ejaculatory ducts (*d*, *fig.* 186), which lie close to each other, are received into a sort of conical canal, formed in the prostate. Some loose cellular tissue separates them from the substance of the gland, of which they are altogether independent; it was chiefly to the portion of the prostate which is situated above this canal that the name middle lobe was given by Home.

Density.—The density of the prostate is considerable, and yet the tissue of this gland is friable, and can be very easily torn after having been once divided. It is of the greatest importance to remember this friability in performing the operation of lithotomy. The prostate, in fact, is the only obstacle to the extraction of the calculus; and when this gland has been divided in its antero-posterior diameter, the bladder itself may be torn with the greatest facility.

Structure.—The structure of the prostate can only be properly studied in the adult. In certain cases of hypertrophy without alteration of tissue, its characters are, as it were, exaggerated. It consists of a collection of glandular *lobules*, which may be subdivided into *granules* pressed close to each other in the midst of a tissue that appears to me to be muscular, for it is continuous with the muscular coat of the bladder, and bears the most perfect resemblance to it in cases of hypertrophy. From these granules, which are generally of unequal size, small excretory ducts proceed, and unite into an irregular number of prostatic ducts that open, not upon the *verumontanum* itself, but upon its sides (see *fig.* 182), in the whole extent of the lower wall of the prostatic portion of the urethra, or prostatic sinus. I have assured myself of the existence of these ducts and their orifices in many cases where I have found them filled with innumerable small calculi, resembling grains of brownish sand. The orifices of the prostatic ducts may be easily detected by pressing the gland, when the fluid secreted by it will be observed to exude at several points.

The Membranous Portion.—The membranous portion of the urethra (*c*, *fig.* 181) extends from the prostatic portion to the bulb, and passes upward and forward.† It is in relation *above* and *laterally* with the arch of the pubes, from which it is separated by some considerable veins, or, rather, by a sort of erectile tissue; *below* it corresponds with the rectum, but is separated from it by a triangular space, having its base directed forward and downward, and its apex backward and upward. It is generally in this triangular space that the urethra is divided in the operation of lithotomy.

Its upper concave surface is about an inch long; its lower surface is from four to six lines. This difference in length is caused by the bulb projecting backward upon the lower surface of the membranous portion of the urethra.

This part of the canal is embraced *laterally* and *below* by the two muscular bundles which have been already described as the *muscles of Wilson;* and also by the transverse muscular fasciculi described by Santorini and Guthrie.

The Spongy Portion.—The spongy portion (*l*) constitutes the greatest part of the length of the urethra; it commences opposite the symphysis pubis by a very considerable expansion, called the *bulb* (below *l*), and terminates at the extremity of the penis by another and still larger expansion, which constitutes the *glans penis*.

* The varieties in the situation of the urethra, in relation to the prostate, were well pointed out by M. Senn, in an inaugural dissertation in 1825. According to his observations, the portion of the prostate situated below the canal is seven or eight lines thick in the middle, and ten or eleven lines when measured downward and outward.

† [The membranous portion perforates both layers of the triangular ligament, about an inch below the arch of the pubes (see *fig.* 138); but as the two layers are separated from each other below, the greater part of this portion of the urethra is included between them; a very small part is situated behind the posterior layer: both layers are prolonged over the urethra, one forward and the other backward.]

The *bulb* occupies the highest part of the pubic arch, and fills the interval between the crura of the corpus cavernosum. Its size varies in different individuals, and according to the state of the penis; it projects several lines below the level of the membranous portion, which is partially covered by it in this direction, and seems to open into its upper part.

As the bulb is directed very obliquely upward and forward, we might be inclined to consider the urethra to be much more curved than it actually is, if we judged of it only by the external appearance of the canal.

The bulb is embraced below and upon the sides by the bulbo-cavernosi muscles, which have numerous points of insertion upon it. Between these muscles and the bulb we find Cowper's glands. The bulb terminates insensibly in front, becoming continuous with the spongy portion: the angle of union of the crura of the corpus cavernosum may be assigned as its anterior boundary.

The Glands of Cowper.—These are two small, rounded bodies (*g g*, *figs.* 168, 181, 182) (so called after the anatomist who has given the best description of them), situated against the bulb, in contact with which they are retained by a tolerably dense layer of fibrous tissue.* From each of these glands, which are of variable dimensions, an excretory duct proceeds, and after a course of an inch and a half or two inches, opens into the canal of the urethra upon the sides of the spongy portion (*c*, *fig.* 182), passing obliquely through its parietes.†

In front of the bulb, the spongy portion of the urethra enters the groove on the lower surface of the corpus cavernosum, and is in relation below, in the first part of its course, with the bulbo-cavernosi muscles, which separate it from the cellular tissue of the scrotum, and more anteriorly with the skin of the penis.

The *glans*, so called from its shape, is the conical enlargement which forms the extremity of the penis. It is covered by the prepuce, which is united to it below by means of the frænum; its base projects considerably beyond the end of the corpus cavernosum, and forms what is called the *corona glandis*. This circular projection is grooved perpendicularly throughout its entire extent by some large nervous papillæ, which are visible to the naked eye. The base of the glans is cut very obliquely, so that its upper surface is twice as long as its lower. Below, and in the median line, the corona glandis presents a groove, in which the frænum is received.

At the extremity of the glans is situated the orifice of the urethra, *meatus urinarius*, a vertical fissure, three or four lines in extent, and placed in the same line as the frænum, from which it is separated by a very short interval. Sometimes this orifice is placed exactly opposite the frænum, and, like it, is directed downward: this malformation constitutes what is called *hypospadias*.

Internal Surface of the Urethra.—Upon this surface (see *fig.* 182) we find no trace of the distinction established between the different portions of the urethra, considered from without, except that the prostatic portion of the canal is of a white colour, while all the rest of it is of a more or less deep violet hue.

Dimensions.—Opposite the prostate the urethra becomes dilated, sometimes to a considerable extent (sinus prostaticus); at the commencement of the membranous portion it suddenly contracts, and then continues cylindrical as far as the glans, where it again dilates so as to form the *fossa navicularis* (*o*), and terminates by an orifice, which is the narrowest part of the entire canal.‡

In order to obtain more exact ideas of the comparative dimensions of the different portions of the urethra, M. Amussat inflated this canal, and then carefully removed all the structures superadded to its proper parietes, so as to reduce the latter to the mucous membrane only, and thus leave them of almost uniform thickness, instead of being very unequal. According to this mode of appreciation, which, however, is not free from objection, he has shown that the narrowest part of the canal is the bulbous, not the membranous portion; that the canal, after being contracted opposite the bulb, again expands at the spongy portion, and then gradually contracts as it proceeds forward. He denies the existence of a dilatation opposite the fossa navicularis; and attributes the dilated appearance of that part to the fact of the tissue of the glans being very dense, and closely adherent to the mucous membrane of the urethra, so as not to allow it to collapse, like that of the other parts of the canal.

However, the extreme dilatability of the walls of the urethra render an exact determination of its dimensions less important than might be imagined.

Besides the extensibility of the tissues, there is another anatomical condition which favours the extreme dilatability of the urethra, viz., the existence of longitudinal folds on the inner surface of the canal, which are effaced by distension. These folds must

* [They are placed between the two layers of the triangular ligament: the transverse muscles of Santorini cover them below, and the arteries of the bulb (*e e*, *fig.* 168) cross above them: they are compound glands.]

† I have never seen the gland called, by Litre, the anti-prostatic; nor have I seen the third gland of Cowper, which is said to be situated below the arch of the pubes.

‡ [Three dilatations in the urethra are usually described, viz., the prostatic sinus, the sinus of the bulb, and the fossa navicularis. The first and the third of these are described above; the second is at the commencement of the spongy portion, in the inferior wall of the urethra.]

not be confounded with certain small longitudinal fasciculi which lie beneath the mucous membrane throughout the whole extent of the canal, and appear to me to be of a muscular nature. The whole of the inner surface of the urethra presents a number of oblique orifices, which lead into culs-de-sac of variable depths. These sinuses, the orifices of which are always directed forward, are sometimes large enough to receive the extremities of bougies; they were very well described by Morgagni, and, therefore, they are generally called the *sinuses of Morgagni*. I have seen them more than an inch long. No glands open into them.*

The Verumontanum, or Crest of the Urethra.—The lower wall of the membranous portion of the urethra presents, in the median line, a crest, which has been named the *verumontanum, caput gallinaginis*, or *urethral crest* (*a* to *d*). This crest commences in front by a very delicate extremity; is directed backward along the median line, and terminates at the anterior part of the prostatic portion by an enlarged extremity (*a*), upon which the ejaculatory ducts open by two distinct orifices. From this posterior extremity several radiated folds proceed on either side, called the *frænа* of the verumontanum, which are lost in the opening of the neck of the bladder; they were carefully described by Langenbeck. The prostatic ducts open at the sides of the verumontanum.

Structure of the Urethra.—A very fine transparent mucous membrane, of an epidermic character, lines the inner surface of the urethra; and is continuous, on the one hand, with the mucous membrane of the bladder, and, on the other, with that covering the glans. It is also continued through the ejaculatory ducts, into the vasa deferentia and the vesiculæ seminales.†

The structure of the urethra, as regards the coats external to the mucous membrane, is not the same in the different portions of the canal.

In the prostatic portion, we find the same elements as in the bladder, which seems as if it were continued into the cavity of the prostate. The deepest layer of the muscular coat of the bladder is prolonged between the mucous membrane and the prostate, while the other layers form different planes which penetrate into the substance of the gland.

The membranous portion would be more correctly denominated the muscular part of the canal, for it is surrounded by a layer of muscular fibres. A plexus of veins surrounds these muscular fibres.

The spongy portion (*l f, fig.* 182; *c, fig.* 187) has a similar appearance to that of the cavernous body; it is an erectile structure, composed of a fibrous framework, formed by numerous prolongations interlaced in all directions, so as to resemble areolar tissue. It is probable that the internal coat of the veins lines all the cells, which contain more or less blood, according to the state of the penis.

In the tissue of the corpus spongiosum, as well as in that of the corpus cavernosum, are found longitudinal muscular fibres, very evident to the naked eye in the larger animals, and the existence of which appears to be shown by the microscope in the human subject. The structure of the glans (*f f*) is exactly the same as that of the bulb, only its tissue is more dense. The corpus spongiosum urethræ does not communicate with the corpus cavernosum, although at first sight it appears to be nothing more than a continuation of it. The blunt extremity of the corpus cavernosum is evidently embraced by the base of the glans, but no communication exists between the erectile tissue composing these two bodies, so that it is possible to inject them separately.

THE GENERATIVE ORGANS OF THE FEMALE.

The Ovaries.—The Fallopian Tubes.—The Uterus.—The Vagina.—The Urethra.—The Vulva.

The genital organs of the female consist of the *ovaries*, the *Fallopian tubes*, the *uterus*, the *vagina*, and the several parts forming the vulva. With these we may include the *mammæ*, as appendages to the generative apparatus.

The Ovaries.

The *ovaries* (*ovaria*), so called on account of the small vesicular ova which they contain, are the representatives of the testicles in the male; the product secreted by both the one and the other is absolutely indispensable for reproduction. From this analogy between the ovaries and testes the ancients called them *testes muliebres* (*Galen*).

The ovaries (*a a, fig.* 188) are two in number, and are *situated* one on each side of the uterus, in that portion of the broad ligament (*d d'*) termed the posterior ala (*b*), and behind the Fallopion tube. They are retained in this position by the broad ligament, and by a proper ligament called the *ligament of the ovary* (*c*).

* [One of these sinuses or lacunæ, larger than the rest, and situated on the upper surface of the fossa navicularis, is called the *lacuna magna*; they appear to be mucous crypts.]

† [It is prolonged into the ducts of Cowper's glands and the prostate, into the vesiculæ seminales, vasa deferentia, and tubuli seminiferi, and through the ureters into the uriniferous ducts; in the female it also lines the vagina, uterus, and Fallopian tubes; the whole forms the genito-urinary system of mucous membranes; it is covered throughout with an epithelium, which, in the male generative apparatus, approaches the columnar form.]

Their situation varies at different ages, and also according to the state of the uterus. In the fœtus, they are placed in the lumbar regions, like the testicles. During pregnancy they are carried up into the abdomen with the uterus, upon the sides of which they are applied. Immediately after delivery, they occupy the iliac fossæ, where they sometimes remain during the whole period of life, being retained there by accidental adhesions. It is extremely common to find them thrown backward,* and adhering to the posterior surface of the uterus.

The ovary has sometimes been found in inguinal or femoral herniæ: by descending into the labia majora, they have simulated the appearance of testicles.

The size of the ovaries varies according to age, and according as the uterus is gravid or unimpregnated, healthy or diseased. They are relatively larger in the fœtus than in the adult; they diminish in size after birth, again increase at the period of puberty, and become atrophied in old age. During the latter periods of pregnancy, they sometimes acquire double or triple their ordinary size.

The ovaries are of an oval shape, a little flattened from before backward; they are of a whitish colour; their surface is rough, and, as it were, cracked, and is often covered with very dark-coloured cicatrices, which have been incorrectly regarded as remains of ruptures in their external coat, to allow of the escape of the fecundated ovum.

The ovary is free in front, behind, and above, but is attached by its lower border to the broad ligament, by its outer end to the trumpet-shaped extremity of the Fallopian tube, and by its inner end to the corresponding side of the uterus, some lines below the upper angle of that organ, by means of a ligamentous cord, called the *ligament of the ovary* (*c*); which was for a long time regarded as a canal (*ductus ejaculans*), intended to convey an ovarian fluid into the uterus. The tissue of this ligament strongly resembles that of the uterus, and seems to be a prolongation from it.†

Structure.—The ovary is composed externally of a dense fibrous coat, covered by the peritoneum, which adheres so closely to it that it cannot be detached; and, internally, of a spongy and vascular tissue, the areolæ of which seem to be formed by very delicate prolongations from the external coat; in the midst of this tissue (the stroma, from στρωμα, a bed) the Graafian vesicles are deposited. These *vesicles* vary in number, from three or four to fifty. The structure of the ovary is most evident in the recently-delivered female. At that time its tissue, expanded, and, as it were, spongy, appears to me to resemble that of the dartos, and is traversed by a great number of vessels. I have also seen, in recently-delivered females, the ovaries from twelve to fifteen times larger than usual, and converted into a sac, having very thin parietes, which were easily torn; the ovary itself was of a spongy, vascular, and diffluent texture, in the midst of which the vesicles were seen unaltered.

The *vesicles* are nothing more than small cysts of variable size, with very thin transparent walls, adhering to the tissue of the ovary, and containing a limpid serosity, either colourless, or of a citron yellow. According to Von Baër, the most superficial vesicles which approach the expanded extremity of the Fallopian tube, contain a floating body, which was imperfectly seen by Malpighi, and constitutes the germ or ovum.‡

I have often met with ovaries destitute of vesicles; but then they had undergone some change, that of induration, for example. May the absence of these vesicles be regarded as a cause of sterility?

The *corpora lutea*, according to the observations of Haller, consist of the remains of vesicles that have been ruptured in consequence of the act of impregnation; they are brownish-yellow masses, of a tolerably firm consistence, and which I have found as large as a cherry-stone in females recently delivered. These bodies have been ascertained to exist in females who have never borne children, and this anomaly has been explained by supposing that they may be produced in consequence of masturbation. We would remark, however, that there is no constant relation between the existence of these bodies and the occurrence of fecundation. In some females who have had many children, no corpora lutea can be detected, and, on the other hand, a corpus luteum has been found in a girl of five years of age.

The *bloodvessels* and *veins* of the ovary correspond exactly with those of the testicles.

* The situation of the ovaries, behind the Fallopian tubes, prevents their displacement forward.

† It has even been stated that this so-called efferent duct of the ovary divides into two branches, one of which opens directly into the uterus, while the other runs along its border, and opens near the os uteri.

‡ [The vesicles of De Graaf vary from the size of a pea to that of a pin's head; they have two tunics, one external and vascular, the other called the *ovi-capsule*, which, according to Schwann, is lined internally with epithelium (membrana granulosa, *Baër*). In each vesicle there is usually but one *ovum*, which at first occupies its centre, but in the mature condition approaches the inner surface of its internal coat, and, surrounded by a granular covering (tunica granulosa, *Barry*), is held there by *retinacula* (*Barry*). The ovum is a perfectly spherical body, of uniform size (about $\frac{1}{120}$th of an inch in diameter); it consists of a thick but very transparent coat (zona pellucida, *Valentin*; chorion, *Wagner*), which surrounds the substance of the yolk; within the yolk is situated the *germinal vesicle* of Purkinjé (about $\frac{1}{120}$th of an inch in diameter), and within that the *germinal spot* of Wagner (about $\frac{1}{2500}$th or $\frac{1}{3500}$th of an inch). The changes incidental to impregnation, according to Dr. Barry, commence in the germinal spot and vesicle. For farther information, and for a list of works upon this subject, see *Müller's Physiology*, translated by Dr Baly, and *Wagner's Physiology*, translated by Dr. Willis.]

Uses.—Without precisely determining the part performed by the ovaries in reproduction, it may be said that they are indispensable to that function. Extirpation of these bodies is followed by sterility. And, again, ovarian fœtation proves that fecundation may occur within the ovary. The use of the Graafian vesicles in generation is not well known.*

The Fallopian Tubes.

The *tubæ uterinæ* (*f f, fig.* 188) are two ducts, situated in the substance of the upper margin of the broad ligament. They are also called the tubæ Fallopianæ,† the Fallopian tubes, after Fallopius, who first gave a good description of them; they extend from the upper angle of the uterus to the sides of the cavity of the true pelvis.

Fig. 188.

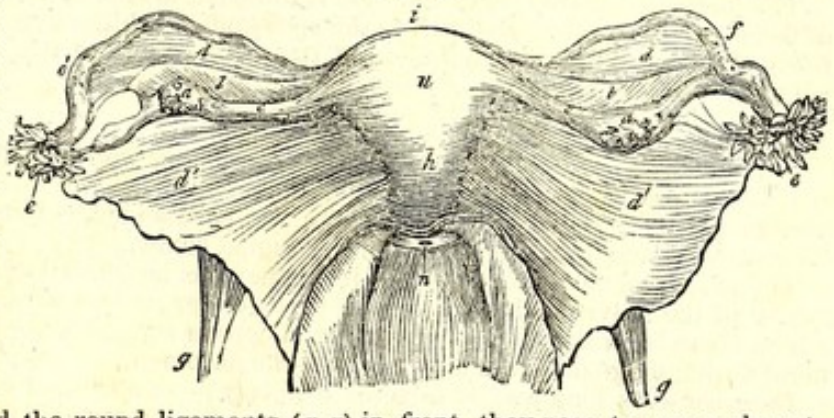

Situation and Direction.—Floating, as it were, in the cavity of the pelvis, between the ovaries behind, and the round ligaments (*g g*) in front, they pass transversely outward, and at the point where they terminate, bend backward and inward, in order to approach the outer end of the ovary, to which they are attached by a small ligament. Each Fallopian tube is straight in the inner half of its course, but describes certain windings in the remaining outer portion, which are so considerable in certain cases, and especially when the tube has been the seat of chronic inflammation or of dropsy, as to resemble in some degree the windings of the vas deferens. Moreover, accidental adhesions of the expanded extremity very frequently give it an entirely different direction from the one it usually takes. The tubes may be drawn down with the ovaries into a hernial sac, as I have several times observed.

The *length* of the Fallopian tube is four or five inches, but it sometimes varies on the two sides. The canal in their interior is very narrow along their inner half, but gradually enlarges as it proceeds outward to their termination, which is expanded and divided into irregular fringes, like the calyces of certain flowers; this expanded end constitutes the mouth of the trumpet, or the *fimbriated extremity* (*e*) of the Fallopian tube. In order to obtain a good view of this structure, it is necessary to place the tube in water, and then a number of fringes or small shreds of unequal length will be seen floating in the liquid, and consisting of folds divided unequally, and sometimes forming two or three concentric circles. It is generally said that one of these fringes, longer than the rest, is attached to the outer end of the ovary; but this connexion appears to me to be effected by means of a small ligament. All these folded fringes terminate around a circle somewhat narrower than the adjoining portion of the tube; this circle constitutes the *free orifice*, or *ostium abdominale* of the tube.

The outer portion of the tube will admit the end of a moderate-sized catheter, while the inner portion will scarcely admit a bristle. The diameter of that portion of the tube which traverses the uterine walls is capillary, and it is very difficult to detect with the naked eye its *uterine orifice*, or *ostium uterinum* (*o o, fig.* 189). As the canal of the tube opens into the uterine cavity on the one hand, and into the cavity of the peritoneum on the other, it forms a direct communication between the two; and hence certain cases of peritonitis have been supposed to depend upon the passage of a fluid from the uterus into the peritoneal sac. Not very unfrequently the fimbriated orifice of the tube is obliterated; in this case the tube becomes dilated like a cone, having its base directed outward, and it also becomes much more flexuous.

When opened longitudinally, and placed under water, the outer or wide portion of the tube presents longitudinal folds of unequal breadth, and touching by their free edges.

There is no valve, either in the course or at the orifices of the tube. Its narrow portion is hard to the touch, inextensible, and closely resembles in appearance the vas deferens; its wide portion is collapsed, and its walls are thin and extensible.

Structure.—The peritonium adheres closely to it, and forms its outer coat; it is lined by a mucous membrane, which can be easily shown in the whole extent of the broad and folded portion, and appears to form of itself the longitudinal folds already described. This lining membrane is continuous, on the one hand, with the uterine mucous membrane, and on the other, with the peritoneum, at the fimbriated extremity of the tube; it thus presents the only example in the human body of the direct continuity of a serous

* See note, p. 462. † [Literally, the Fallopian *trumpets*, from their expanded abdominal extremities.]

and mucous membrane. Between the peritoneal and the mucous coats is found a proper membrane, which appears to be a prolongation of the tissue of the uterus, and is probably muscular.*

Uses.—The Fallopian tubes, which represent in the female the vasa deferentia in the male, serve not only to transmit the fecundating principle of the male, but also to conduct the fecundated ovum into the uterus. These uses are proved by the sterility of females in whom the tubes have been tied; and by the occurrence of tubal fœtations, in which the fecundated ovum is arrested in the cavity of the tube, and there passes through the several stages of development.

The fimbriated extremity of the tube is intended to embrace the ovary during the act of fecundation, and to apply itself to the spot from which the ovum is to be detached; it follows, therefore, that any adhesion of the ovary or of the tube which prevents this, acts as a cause of sterility.

The Uterus.

The *uterus* (*uter*, a leather-bottle), *matrix* (*mater*), or womb, is the organ of gestation.

It is *situated* (*u*, *fig.* 190) in the cavity of the pelvis, in the median line, between the bladder and the rectum, and is retained in that position by the round and broad ligament on each side, and by the upper end of the vagina below.

The looseness and extensibility of its connexions enable it to float, as it were, in the cavity of the pelvis, and to be moved to a greater or less extent. The facility with which it can be drawn towards the vulva in certain surgical operations, and its displacement during pregnancy, when it rises into the abdomen, are proofs of its great mobility.

Direction.—Its long *axis* is directed obliquely downward and backward, *i. e.*, it coincides with the axis of the brim of the pelvis. Its direction is liable to frequent variations, the history of which belongs to midwifery; but one of them, viz., the obliquity downward, and from the right to the left side, is so frequent that it has been regarded as natural, and, according to some anatomists, appears to be connected with the position of the rectum on the left side of the pelvis. In pregnancy, this inclination is almost constant, and has some relation with the most usual position of the child, viz., that in which the occiput is turned towards the left acetabulum of the mother.

Number.—The uterus is single in the human species; it is double in most animals. The cases of double uterus observed in the human subject are nothing more than bifid uteri, or such as are divided by a septum: this state may exist either in the body of the uterus alone, or at the same time in the body and neck, and even in the vagina.

Size.—The size of the uterus varies according to age, and certain physiological conditions peculiar to this organ. It is very small until puberty, and then acquires the size which it subsequently presents. In females who have borne children it never returns to its original size. It becomes enormously enlarged during pregnancy, or from the development of certain tumours. In old age it becomes atrophied, and is sometimes as small as it is in newborn infants. The following are the measurements of the uterus after puberty: length, two and a half to three inches; breadth, at the fundus, sixteen to eighteen lines, at the neck six lines; antero-posterior diameter, or thickness, six lines.†

Weight.—The weight of the uterus is from six to ten drachms at puberty, an ounce and a half or two ounces in females who have had children. I have seen it from one to two drachms in aged females, in whom it had become atrophied. At the end of pregnancy the weight of the uterus is from a pound and a half to three pounds.

Form.—The uterus is shaped like a small gourd, or a pear flattened from before backward. It is divided into a *body* (*u*), and *cervix* or *neck* (*h*); the distinction between these two parts being established by a more or less marked constriction.

Relations.—These must be studied in front, behind, on the sides, at the upper border or fundus, and at the lower or vaginal extremity.

The *anterior surface* is covered by the peritoneum in its upper three fourths, and is indirectly in relation with the posterior surface of the bladder, from which it is often separated by some convolutions of the small intestine; in its lower fourth it is in immediate contact with the inferior fundus of the bladder, and is united to it by rather loose cellular tissue. The latter relation explains why cancerous affections of the uterus so often extend to the base of the bladder.

The *posterior surface* is entirely covered by the peritoneum, and is in relation with the anterior surface of the rectum, from which it is often separated by some convolutions of the small intestine. This surface is much more convex than the anterior; it may be examined from the rectum.

Its *sides* are slightly concave, and give attachment to the *broad ligaments* (*d d'*, *d d'*), which are two quadrilateral folds of peritoneum, extended transversely from the lateral

* [Muscular fibres have not yet been demonstrated in the human subject, though in some animals circular and longitudinal contractile fibres have been found. The epithelium of the mucous membrane is columnar and ciliated: by the action of the cilia the contents of the tubes are urged towards the uterus: Dr. Henlé has found cilia on both surfaces of the fimbriæ.]

† [The body of the uterus, at its thickest part, viz., immediately below the fundus, is from eight to twelve lines thick.]

borders of the uterus to the sides of the pelvis. Their upper margin is divided on each side into three folds or ridges, formed in the following manner: a posterior fold formed by the ovary (*a*) and its ligament (*c*), an anterior one by the round ligament (*g*), and a middle fold by the Fallopian tubes (*f*). Hence some anatomists have described three wings (*alæ vespertilionis*) in each of the broad ligaments.

The broad ligaments may be regarded as forming across the cavity of the pelvis a transverse septum, within which the uterus and its appendages are contained. This septum divides the cavity into two portions: one anterior, containing the bladder, the other posterior, in which are situated the rectum, and almost always some intestinal convolutions.

Besides the broad ligaments, there are also the ligaments of the ovary and the round ligaments, proceeding from the sides of the uterus.

The *round ligaments* (*g g*) have a fibrous appearance, but are evidently continuous with the tissue of the uterus. They arise from the side of the uterus, below and in front of the Fallopian tubes, pass upward and outward in the anterior fold of the broad ligament to the abdominal orifice of the inguinal canal, into which they enter, being accompanied by a prolongation of the peritoneum, which forms around them a cylindrical sheath called the *canal of Nuck*. In females far advanced in life, this sheath may be traced as far as the external orifice of the inguinal canal.

Besides the uterine fibres which enter into its composition, the round ligament also contains a great number of veins, which may become varicose, especially near the external orifice of the inguinal canal, where they sometimes simulate a hernia.

The *upper border* or *fundus* (*i*) of the uterus is convex, and is directed upward and forward; it is covered by convolutions of the small intestine; when not distended, it never reaches as high as the brim of the pelvis, and cannot, therefore, be felt by the fingers in the hypogastric region.

The *lower* or *vaginal extremity* of the uterus, called also the *os tincæ*, from its shape, is directed downward and backward; it is embraced by the vagina, into which it projects, and is divided by a transverse fissure into two lips, one anterior, the other posterior. The *os tincæ* is small, and perforated by an almost circular opening (*n*) in females who have not borne children; but in those who have been mothers it forms a more considerable projection, and its fissure is more marked and longer transversely.* In some females the os tincæ is of considerable length, and, as it were, hypertrophied, although the uterus is healthy.

The anterior lip is thicker than the posterior, which is a little longer than the other. It frequently happens that in old females every trace of the lips of the os tincæ disappears; the orifice alone remains, and in some cases even that is obliterated. In such a case the vagina terminates in a cul-de-sac, at the bottom of which a round and yielding point may be felt. This disappearance of the two lips is much more common than the elongation of the neck of the uterus, which was pointed out by my venerable colleague, M. Lallemand.

Cavity of the Uterus.—The cavity of the uterus is extremely small in comparison with the size of the organ; its figure is that of a curvilinear triangle; its walls are in contact, and are smooth, and covered with a layer of mucus. We shall examine it in the body and neck of the uterus.

The cavity of the body of the uterus (*u*, *fig.* 189) is of a triangular form, and has an opening at each angle. The inferior opening (*ostium internum*, *h*) establishes a free communication between the cavities of the body and neck; it is often obliterated in old women.† The other two orifices (*o o*) are those of the Fallopian tubes; they are scarcely visible to the naked eye, and are situated at the bottom of two funnel-shaped cavities formed at the superior angles of the uterus, and constituting the remains of the division of the body of the uterus into two halves or cornua. This division, which is normal in many animals, is sometimes met with in the human female.

Fig. 189.

Congenital deficiency of the cavity of the uterus is very rare. My colleague, Professor Rostan, kindly sent me a specimen, in which there was no trace of a cavity in the body of the uterus, although the cavity of the neck remained. The female to whom it belonged had never menstruated. It is unnecessary to say that she was barren.

The cavity of the neck (*h* to *n*) represents a cylinder flattened from before backward, and has upon its anterior and posterior walls certain ridges, which form upon each wall along the whole length of the neck a tolerably regular median column, from which proceed, at more or less acute angles, a certain number of smaller columns,‡ which project to a greater or less degree. The whole appearance resembles that of a fern-leaf,

* I have seen the os tincæ lacerated and fissured in different directions, in consequence of parturition.

† This obliteration, which causes retention of mucus and blood, and, consequently, distension and ramollissement of the body of the uterus, is so common that M. Mayer regards it as normal.

‡ These rugæ, which vary considerably in their arrangement, have been described in detail by Haller, Boyer, and others.

and has been called the *arbor vitæ*. It generally disappears after the first labour, at least only traces of it are left. Nevertheless, it is not unfrequently found perfect, even after several accouchements—a circumstance of some importance in legal medicine.

The internal surface of the body of the uterus is much more vascular than the neck. This difference is particularly observed in females who have died during a menstrual period, in whom the vessels of the body of the womb are much developed, and that organ itself is swollen and softened, while the cervix retains its accustomed whiteness and consistence.

Another character of the uterine cavity is the existence of a greater or less number of transparent vesicles, which were mistaken by Naboth for ova (*ova of Naboth*), but are only muciferous follicles. They exist both in the body and neck of the uterus, but are more numerous in the neck, near the vaginal orifice, and only become apparent when the mucus accumulates in them from obliteration of their orifices. They are sometimes much enlarged, and have then given rise to the opinion that some more serious disease has existed.

The orifices of the uterine sinuses, described by the older anatomists at the fundus of the uterus, cannot be detected. They are only to be seen after delivery in the situation where the placenta had been attached.

The parietes of the unimpregnated uterus are from four to six lines in thickness. The thinnest part is at the entrance of the Fallopian tubes, where they are not more than two lines thick. The parietes of the cervix are thinner than those of the body.

Structure of the Uterus.—The constituent parts of the uterus are, a proper tissue, an external peritoneal coat, an internal mucous membrane, and some vessels and nerves.

The proper tissue is of a grayish colour, very dense and strong, and creaks under the knife like cartilage. The body appears less consistent than the neck, but this depends upon the fact of its being more frequently the seat of sanguineous congestion. It is composed of fibres, *i. e.*, it has a linear arrangement. It may be asked, with regard to the nature of these fibres, Do they consist of fibrous tissue? are they muscular, or are they analogous to the yellow tissue of the arteries? The following considerations will determine this question:

The walls of the unimpregnated uterus appear to be composed of a fibrous tissue, traversed by a great number of vessels. During pregnancy, or in consequence of the development of tumours, or the accumulation of fluid in the cavity of the uterus, its proper tissue acquires all the properties of the muscular tissue, as it exists in the viscera of organic life, and, like it, is endowed with contractility. Can, therefore, the presence of a fœtus or a foreign body in the uterus cause a transformation in the tissue of that organ?* Assuredly not; but the great influx of blood into the uterus, and the consequent distension and development of its fibres, reveals a structure which before was concealed by the state of condensation and atrophy kept up by inactivity.

This view is fully confirmed by the microscopical observations of Rœderer, and the chemical experiments of Schwilgué; and also by the results furnished by comparative anatomy, which has shown circular and longitudinal muscular fibres in the uteri of some animals, even when not in a gravid condition.†

The nature of the fibres of the uterus being determined, we may now examine their direction. Some anatomists agree with Malpighi and Monro, that they have no regularity in their disposition, but are interlaced in an inextricable manner. It must be confessed that, in the unimpregnated uterus, such is the case; but during gestation, the arrangement of the greater number of fibres can be traced.‡

In the body the external thin layer is composed of two median vertical fasciculi, one on each surface of the uterus; of another fasciculus occupying the fundus, and of some oblique ascending and descending fibres, which converge towards the Fallopian tubes, the round ligaments, and the ligaments of the ovaries, which contain prolongations of these fibres.§ This first, or superficial layer, belongs exclusively to the body of the uterus. The deep layer of the body consists of two series of circular fibres; each series forming a cone, the apex of which corresponds to the Fallopian tube, while the base is directed towards the median line, and is there blended with that of the opposite side.

The neck is composed entirely of circular fibres, which intersect each other at very acute angles.

The facts furnished by comparative anatomy perfectly accord with the preceding description. Thus, in the uterus of a sow, which had littered, I found that the cervix was composed exclusively of circular fibres; and that the cornua (aduterum of *M. Geoffrey*

* I conceive that I have proved by facts, that only three tissues, viz., the muscular, the nervous, and the glandular, are never the products of organic transformations.—(Vide *Essai sur l'Anatomie Pathol.*, 1816.)

† [The muscular fibres of the gravid uterus have been described by Dr. Baly (translation of Müller's Physiology). Like other inorganic muscular fibres, they have no transverse striæ; they are much broader than those of the alimentary canal, and taper very much at their extremities, which are sometimes split into two or three points: the corpuscles upon them are comparatively small.]

‡ Hunter, *Anatomia uteri*. Rosemberger in Schlegel, *Syllog. Oper. Minor. ad Artem Obstetric.* Lipsiæ, tom. ii., p. 296. Mémoire présenté à l'Académie de Médecine, par Mme. Boivin. Oct., 1821.

§ *I. e.*, in the gravid state.

St. Hilaire), which represent the body of the uterus of the human female, were formed by two layers of fibres, one external and longitudinal, the other deep and circular. From this arrangement, we may therefore conclude that the human uterus results from the union of two cornua, which communicate directly with each other, instead of opening separately into the cavity of the cervix.

When examined in the state of pregnancy, the tissue of the uterus is found to be traversed by venous canals, or *uterine sinuses*, which are of very considerable size, especially opposite the attachment of the placenta. This great number of vessels gives to the tissue of the uterus the appearance of an erectile or cavernous structure, having muscular parietes.*

The External or Peritoneal Coat.—The peritoneum, after covering the posterior surface of the bladder, is reflected upon the anterior surface of the uterus, of which it covers only the upper three fourths, the lower fourth being in immediate contact with the bladder. At the fundus of the uterus, it passes to the posterior surface, which it covers entirely, is prolonged a short distance upon the vagina, and is then reflected upon the rectum. The broad ligaments are formed by a transverse duplicature of this coat. Two falciform folds, formed by this membrane between the bladder and the uterus, are called the *vesico-uterine ligaments*, and two others, between the uterus and the rectum, are named the *recto-uterine ligaments*.

The peritoneum adheres very loosely to the borders of the uterus, but much more closely as it approaches the median line. When enlarged during pregnancy, the uterus becomes covered with the peritoneum of the broad ligament, a species of mesentery, the folds of which become separated, and yield to the increasing size of the organ.

The Internal or Mucous Membrane.—The existence of a mucous membrane upon the internal surface of the uterus has been denied by those anatomists who have examined it after parturition, especially by Morgagni and Chaussier, and so, also, by those who do not admit the presence of a mucous membrane unless it can be demonstrated over a certain space. But the existence of a mucous membrane on the internal surface of the uterus appears to me incontestably proved by the following considerations:

First, every organized cavity which communicates with the exterior is lined by a mucous membrane; why, therefore, should the uterus form an exception to this rule? Secondly, by dissection it is shown that the mucous membrane of the vagina is continued into the neck of the uterus, and then into the body; but in this latter situation it is destitute of epithelium.† Notwithstanding the difficulty of dissecting this membrane, on account of its tenuity, and its close adhesion to the tissue of the uterus, its presence is demonstrated by the following observations: Under the microscope, the internal surface of the uterus presents a papillary appearance, but the papillæ are very small; it is provided with follicles or crypts, from which mucus may be expressed by a number of points, and which form small vesicles when distended with mucus, in consequence of obstruction or obliteration of their orifices. Thirdly, it is extremely vascular, and presents a capillary network of the same appearance as that of the other mucous membranes; and, lastly, it is constantly lubricated with mucus. Pathological observations also show that the internal surface of the uterus, like all mucous membranes, is liable to spontaneous hemorrhages from exhalation, without breach of continuity, to catarrhic secretions, and to those growths which are denominated mucous, vesicular, and fibrous polypi: and it is generally admitted that, where there is an identity of disease, there is also identity of structure.

During pregnancy, the elements of the mucous membrane are separated; the vessels become penicillate, and greatly increased in size; but in proportion as the uterus returns to its original dimensions, the mucous membrane regains its primitive form, and its dissociated elements approach each other. It seems as if this membrane was destroyed by a true exfoliation, and then entirely reproduced.

The *arteries* of the uterus are derived from two sources: the principal, called the uterine, arise from the hypogastric; the others proceed from the spermatic or ovarian arteries to the borders of the uterus, and are distributed upon it: both sets are very tortuous.

The *veins* are remarkable for their enormous size during pregnancy and after parturition. The term *uterine sinuses* has been given to the large veins which are then found in the substance of the organ; and this term is not altogether without foundation, for these venous canals are formed by the lining membrane of the veins which adheres to the proper tissue of the uterus, just as, in the sinuses of the dura mater, it adheres to the fibrous tissue of that membrane.

The *lymphatics*, which have been well examined only during pregnancy and after par-

* This combination of the erectile and muscular tissues is found in the penis of the horse, and perhaps, also, in that of man.

† [The mucous membrane of the uterus contains numerous tubular glands, or crypts, resembling, in form and direction, the tubuli of the stomach, and the crypts of Lieberkuehn, found in the intestinal canal. The epithelium of this mucous membrane is, according to Henlé, columnar, and also ciliated from the fundus to the middle of the cervix uteri; below that point it passes into the squamous form of epithelium found in the vagina and on the labia.]

turition, at which time I have often seen them full of pus, are, like the veins, extremely large (see *Anat. Path.*, avec planches, liv. xiv.); they form several layers in the substance of the uterus, the most superficial of which is the most developed. They terminate in the pelvic and lumbar lymphatic glands; some accompany the ovarian veins.

The *nerves*, as seen in the pregnant condition, have been well described and figured by Tiedemann. Some of them are derived from the renal plexus, and surround the ovarian arteries; others proceed from the hypogastric plexus, and are formed by some of the anterior branches of the sacral nerves, and by branches from the lumbar ganglia of the sympathetic.

Development.—It is generally agreed that the body of the uterus is always bifid, or two-horned, in the embryo, up to the end of the third month; and that, towards the end of the fourth month, the two halves are united to form a single cavity. I have not observed this in the earliest periods of intra-uterine life.

During fœtal life, the uterus, instead of presenting the same form as it subsequently possesses, is decidedly larger at the neck than in the body: at this period the broadest part of the uterus is its vaginal extremity.

After birth, and up to the time of puberty, the development of the uterus is almost stationary; so that, according to the observations of Rœderer, which are confirmed by Professor Duges, it is from twelve to fourteen lines long in the new-born infant, and only an inch and a half at ten years of age.

At puberty, the uterus rapidly acquires its full dimensions, and at the same time becomes the seat of a periodic and sanguineous exhalation, the occurrence of which constitutes menstruation.

In old age, the uterus becomes atrophied, and altered in shape; the cervix and body are separated by a much more decided constriction. These two parts of the uterus seem to become more independent of each other. The lips of the os tincæ are generally effaced in old women. The tissue of the body preserves its softness, while that of the neck acquires an extreme density.

The situation of the uterus is very different at different ages. In the fœtus it projects beyond the brim of the pelvis, and is in the abdominal cavity; after birth, and in consequence of the development of the pelvis, it seems gradually to sink into that cavity. At the age of ten years, the fundus of the uterus is on a level with the brim; afterward it is lower down. In old women it is generally inclined to one side, or reversed upon the rectum.

Functions.—The uterus is the organ of gestation; the fecundated ovum is deposited in its cavity, and there meets with the most favourable conditions for its development. The uterus is also the principal agent in the expulsion of the fœtus.

The Vagina.

The vagina is a membranous canal, extending from the vulva to the uterus; it is the female organ of copulation, and also forms the passage for the menstrual blood, and the product of conception.

It is *situated* in the cavity of the pelvis between the bladder and the rectum, and is held in that situation by tolerably close adhesions to the neighbouring parts, but still is so loose that it can be everted like the finger of a glove.

Direction.—It is directed obliquely forward and downward, *i. e.*, it coincides with the axis of the outlet of the pelvis; and as the direction of the uterus corresponds with the axis of the brim, these two parts form an angle or curvature with each other, having its concavity directed forward.

Shape and Dimensions.—The vagina is shaped like a cylinder, flattened from before backward, and having its walls in contact, as may be seen upon applying the speculum. It is from four to five inches long;* sometimes it is much shorter: I have seen it as short as an inch and a half. This congenital shortness must be distinguished from the apparent shortness produced by prolapsus uteri.

The vagina is not of the same diameter throughout. Its lower orifice is the narrowest part, while its upper extremity is the widest. In females who have borne children, the bottom of the vagina forms a large ampulla, in which the speculum may be moved about extensively, and in which, also, a considerable quantity of blood may accumulate during hemorrhage. It is, moreover, a dilatable canal, as is proved during parturition; and is, at the same time, elastic, and contracts after delivery, so as almost to return to its original dimensions. It would appear, also, to be capable of a vermicular contraction.

Relations.—In front, where it is slightly concave, it corresponds to the inferior fundus of the bladder, to which it is united by very dense filamentous cellular tissue, resembling the dartos; it cannot be separated from the urethra, which appears to be hollowed out of the substance of its walls. The close adhesion of the vagina to the bladder and urethra accounts for these latter organs always following the uterus in its displacements. Behind, the vagina corresponds with the rectum, through the medium of the peritoneum in its upper fourth, and immediately in its lower three fourths. It adheres to the rec-

* [From the nature of the curve formed by the vagina, its anterior wall is shorter than the posterior.]

tum by cellular tissue resembling the dartos, and analogous to that existing between it and the bladder, but much looser, so that the rectum does not follow the vagina in its displacement. The sides of the vagina give attachment to the broad ligaments above, and to the superior pelvic fascia and the levatores ani below, and they are in relation with the cellular tissue of the pelvis and with some venous plexuses.

Internal Surface.—The internal surface of the vagina is covered with an epithelium, which can be very easily demonstrated, and which is prolonged as far as the os uteri, where it terminates by a sort of indented margin, in the same manner as the epithelium of the œsophagus ceases at the stomach.* This surface presents on both walls, but especially in front and near the orifice of the vulva, some transverse rugæ, or, rather, prominences, which very nearly resemble the irregular ridges upon the palate; they all pass from a median prominent line, which is often prolonged like a median raphé along the whole anterior wall of the vagina; the raphé on the posterior wall is not so well marked. These two median raphés are called the columns of the vagina. They are the remains of the median septum, which generally coexists with a bifid uterus, but exists sometimes independently of it.

The transverse rugæ of the vagina are very numerous in the new-born infant and in virgins; they are partially effaced after the first labour, at the upper part of the vagina, but always remain at the lower part. These rugæ are not folds, and do not appear to assist in the enlargement of the vagina.

The *upper extremity* of the vagina embraces the neck of the uterus, upon which it is prolonged without any line of demarcation, and forms a circular trench around the os tincæ, which is deeper behind than in front.

The *lower extremity*, or opening into the vulva, presents a corrugated transverse projection in front, which is exposed by separating the labia and nymphæ; it narrows, and seems even to close the entrance of the vagina.

In virgins, the orifice of the vulva is provided with a membrane, concerning the form and existence of which there have been numerous disputes; it is called the *hymen*, and is a sort of diaphragm interposed between the internal genitals on the one hand, and the external genitals and urinary passages on the other. This membrane is of a crescentic shape, having its concavity directed forward, and closing up the posterior and lateral parts of the vagina: it sometimes forms a complete circle, perforated in the centre. Its free margin is fringed; it varies in breadth in different individuals, and thus regulates the dimensions of the vaginal orifice. The hymen sometimes forms a complete membrane, constituting what is called imperforate vagina.

The hymen is composed of a duplicature of mucous membrane, varying in strength, and containing within it some cellular tissue and vessels. The débris remaining after its laceration constitute the *caruncuIæ myrtiformes*, which vary in number from two to five.

Structure.—The walls of the vagina consist of an erectile spongy tissue interposed between two very strong fibrous layers, of which the external is the thicker. Around this erectile tissue we find a tolerably thick layer resembling the tissue of the dartos condensed. I cannot agree with some anatomists in admitting an identity of structure in the walls of the vagina and uterus, for in no case does the vagina assume a muscular character like the latter organ. From the presence of the dartoid tissue an obscure vermicular movement may take place, and assist the elasticity of the walls of the vagina.

The posterior wall and the upper part of the anterior wall are thin; the vagina is very much thicker opposite the urethra, which seems to be hollowed out of its substance, and terminates by a rugous enlargement, which forms, at the entrance of the vagina, the projection already mentioned, and which is only a very dense spongy tissue.

The mucous membrane of the vagina is remarkable for the thickness of its epithelium,† for its close adhesion to the proper membrane, and for its highly developed papillæ, especially at the entrance of the passage, where the rugæ are nothing more than papillæ in an exaggerated form. The mucous follicles can be easily demonstrated.

The Bulb of the Vagina.—Besides the spongy expansion at the orifice of the vagina, there is in front and on each side of this orifice an enlargement or cavernous body, occupying the interval between the entrance of the vagina and the roots of the clitoris. It is not very thick in the middle, where it is placed between the meatus urinarius and the union of the roots of the clitoris, but gradually enlarges from this point, and terminates below, upon each side of the vagina, by an enlarged extremity. The posterior wall of the vagina is the only part in which it does not exist. In position, as well as shape, it resembles the bulb of the urethra in the male.‡

The Constrictor Vaginæ.—This consists of two muscles, one on each side of the orifice of the vagina, the arrangement of which very nearly resembles that of the bulbo-

* [In both of these situations the epithelium does not cease, but is merely changed in its character (see note, p. 467).]

† [The epithelium in the vagina, and also in the vulva, is squamous.]

‡ In one subject, on the outer side of this vaginal bulb, I found a smooth sero-fibrous pouch, containing a transparent mucous fluid. A narrow canal, proceeding from this pouch, passed directly towards the entrance of the vagina. I could not find the orifice of this canal, which was probably obliterated. The same disposition existed on both sides.

cavernosus in the male. Each muscle commences in front of the rectum, by an interlacement of fibres common to it, to its fellow of the opposite side, and to the sphincter ani, passes forward under the form of a flattened band, and terminates upon the sides of the clitoris, a portion being continued above it, and blended with the suspensory ligament of that body.

Relations.—It is covered on the outside by the skin and the fatty cellular tissue of the labia majora; it corresponds on the inside with the bulb of the vagina, which it must strongly compress.

The proper vaginal *arteries* arise from the hypogastric. The uterine arteries also send numerous branches to the vagina.

The *veins* are very numerous, form plexuses, and terminate in the hypogastric veins.

The *nerves* are derived from the hypogastric plexus.

Development.—The rugæ of the vagina are not visible until about the end of the fifth month of intra-uterine life; from the sixth to the eighth they become much more developed than they are subsequently. The transverse rugæ are visible in the whole length of the vagina, and are placed closely to each other. The hymen does not make its appearance until about the middle of fœtal life; it is directed forward, and is rough and jagged. It is always present.

The Urethra in the Female.

This canal, which is, as it were, hollowed out of the anterior wall of the vagina, differs considerably from the male urethra, of which it represents the membranous portion only. It is about one inch in length.

It is very difficult to determine its diameter, on account of its dilatability; but it is about three or four lines when quite undilated. Its lower end is somewhat contracted.

It is directed obliquely downward and forward, and is slightly concave in front.

Relations.—*Anteriorly*, while behind the symphysis, it is in contact with the cellular tissue of the pelvis; opposite the symphysis, it is in relation with the angle of union of the two crura of the clitoris. The pelvic fascia, or, rather, the anterior ligaments of the bladder, form a half sheath for it above, but are separated from it by numerous venous plexuses. *Posteriorly*, the canal is so closely united to the vagina, that it is impossible to separate them.

The vesical orifice of the female urethra is similar to that of the male, only there is no prostate gland.

The *internal surface* is of a deep colour, and is remarkable for certain longitudinal folds or parallel ridges, the majority of which are not effaced by distension; one of these folds is in the median line of the lower wall of the canal. We also find the orifices of mucous crypts or lacunæ, and some parallel longitudinal veins.

Structure.—It is muscular and erectile, like the membranous portion of the male urethra. It is surrounded by a thick layer of circular muscular fibres, which seem to be continuous with the fibres of the bladder, some of the longitudinal fibres of that organ being prolonged upon the outside of these.* A thin layer of spongy or erectile tissue lies subjacent to the mucous membrane, which is very thin.

The Vulva.

Under the term *vulva* we include all the external genitals of the female, viz., the mons Veneris, the labia majora and minora, the clitoris, and the meatus urinarius, to which we may add the orifice of the vagina already described.

The *mons Veneris* is a rounded eminence, more or less prominent in different individuals, situated in front of the pubes, and surmounting the vulva; the prominence of this part is owing partly to the bones, and partly to a collection of fatty tissue beneath the skin; it is covered with hair at the time of puberty.

The *labia majora* are two prominent cutaneous folds, which form the limits of an antero-posterior opening, by most anatomists named the vulva. They are flattened transversely, and are thicker in front than behind; their external surfaces are covered with hairs; their internal surfaces are moist and smooth, and in contact with each other; their free borders are convex, and provided with hair; their anterior extremities are continuous with the mons Veneris; their posterior extremities unite to form a commissure called the *fourchette*, which is almost always lacerated in the first labour. The interval between the fourchette and the anus constitutes the *perineum*, which is generally from

* [The female urethra perforates the triangular ligament precisely in the same way as the membranous portion of the urethra in the male; and, moreover, between the two layers of the ligament it is surrounded by muscular fibres corresponding exactly with the *compressor urethræ* in the male sex. The vertical fibres, or Wilson's muscles, were noticed by him (*loc. cit.*), descending from the symphysis, separating on the urethra, and passing around it: the transverse fasciculi, which are often very large, form together the *depressor urethræ* of Santorini, and were described and figured by that author (*Obs. Anat.*) as arising by a broad tendon from the lower part of the rami of the pubes, above the erectores clitoridis, passing obliquely upward and inward, and uniting with each other *above* the urethra. Mr. Guthrie has shown (*loc. cit.*) that the relations of the vertical and transverse fasciculi to each other, to the urethra, and to the layers of the triangular ligament, are precisely the same as in the male.]

eight to ten lines long. The interval between the fourchette and the entrance of the vagina is called the *fossa navicularis*.

The constituent parts of the labia majora are, a cutaneous layer, a mucous layer, both provided with numerous sebaceous follicles.* In fat persons, a great quantity of adipose tissue, a layer of dartoid tissue next the mucous membrane, and some arteries, veins, lymphatics, and nerves. They are therefore very analogous to the scrotum in the male, and, like it, are liable to serous infiltration in anasarca.

The *labia minora*, or *nymphæ*, are seen after separating the labia majora, under the form of two layers of mucous membrane; they are narrow behind, where they commence upon the inner surface of the labia majora, and they enlarge gradually as they converge towards each other in front. At the clitoris they become slightly contracted, and bifurcate before their termination. The lower division of the bifurcation is attached to and continuous with the glans of the clitoris; the upper division unites with that of the opposite side, and forms a hood-like fold above that body, called the *preputium clitoridis*.

The nymphæ are provided with very large crypts, which are visible to the naked eye, and secrete an abundance of sebaceous matter. They vary much in size, according to age: thus, in new-born infants, they project beyond the labia majora, principally on account of the imperfect development of the latter. They also vary in different individuals: in some females being extremely small, and in others always projecting beyond the labia majora; and, lastly, in different countries; for in certain African nations, among the Hottentots, for example, they are of a disproportionate length, and constitute what is called in females of that race the *apron*.

The *clitoris* is an erectile apparatus, forming a miniature representation of the corpus cavernosum of the penis. Its free extremity is seen in the anterior part of the vulva, about six lines behind the anterior commissure of the labia majora, and resembles a tubercle situated in the median line, covered, as by a hood, with the upper divisions of the bifurcated nymphæ, and continuous with the lower divisions of the same. This tubercle, which, though imperforate, has been compared to the glans penis (*glans clitoridis*), is generally very small. Sometimes, however, it is very long, so as to have excited a suspicion of the existence of hermaphrodism. In one instance that came under my observation, the free part of the clitoris was two inches long, and extremely slender.

Like the corpus cavernosum in the male, the clitoris arises from the ascending rami of the ischia by two roots, which expand and converge until they arrive opposite the symphysis, where they unite and form a single corpus cavernosum, flattened on each side; this, after passing for some lines in front of the symphysis, separates from it, and forming a curve with the convexity directed forward and upward, and the concavity downward and backward, gradually becomes smaller towards its free extremity.

It has a suspensory ligament precisely resembling that of the penis, and ischio-cavernosi muscles, similar to, but smaller than those of the male. We have already said that the constrictor vaginæ, which represents the bulbo-cavernosi of the penis, has a similar arrangement to those muscles, *i. e.*, it passes upon the sides of the clitoris, and then becomes continued on to its suspensory ligament.

The last circumstance which completes the analogy between the clitoris and the corpus cavernosum of the penis, is the reception of the canal of the urethra into the V-shaped interval formed by the union of the two crura of the clitoris.

The corpus cavernosum of the clitoris forms a longitudinal ridge between the labia majora, extending from the anterior commissure to the glans of the clitoris.

The Meatus Urinarius.—About an inch below and behind the clitoris, we find in the median line, immediately above the projecting margin of the opening of the vagina, the *meatus urinarius*, or the orifice of the urethra, which constantly appears closed.

The Mucous Membrane of the Vulva.—The mucous membrane lining the vulva is continuous, on the one hand, with the skin at the internal surface of the labia majora, and with the mucous membrane of the vagina on the other; upon the labia majora and nymphæ it has a great number of *sebaceous follicles* visible to the naked eye, and yielding a cheesy, odorous secretion; and also *mucous follicles*, which are most numerous near the meatus urinarius, and open into culs-de-sac, the orifices of which are visible to the naked eye, and are often large enough to admit the blunt extremity of a probe.

Development.—In the fœtus the labia majora are small, and separated from each other by the nymphæ, which are much larger in proportion, and also by the clitoris, which projects beyond them to a greater extent in the earlier periods of development. This predominance of the clitoris is still so decided at birth, that it has occasioned mistakes concerning the sex of the infant.

THE MAMMÆ.

Number.—Situation.—Size.—Form.—Structure.—Development.

THE *mammæ* or *breasts* (μαστὸς, from μάω, to seek eagerly, because the infant seeks

* It is not rare to see small and very short hairs growing from the sebaceous follicles on the inner surface of the labia majora; they are analogous to those of the caruncule lachrymales.

them for the milk) are glandular appendages of the generative system, which secrete the milk, and even after birth establish intimate relations between the mother and the infant.

The important office performed by the mammæ has led zoologists to arrange in the same class, under the term *mammalia*, all animals having an apparatus for lactation. We may mention here another character peculiar to this class of animals, because it is intimately connected with the existence of mammæ, viz., that all mammalia are viviparous, that is to say, give birth to their young freed from all their fœtal envelopes.

The mammæ exist in both sexes, but are rudimentary and atrophied in the male, and belong essentially to the female.

Number.—They are two in number in the human species, which is uniparous; in the lower animals they are generally double the number of the young. Examples of three or four mammæ in the human subject are very rare, and the supernumerary mammæ are generally nothing more than simple nipples, or, rather, masses of fat.

Situation.—They are situated on the anterior and upper part of the chest, the transverse enlargement of which in the human subject is so favourable to their development. In the lower animals they occupy the abdominal region.

They are situated on each side of the median line, over the interval between the third and the seventh ribs. They are therefore placed at the same height as the arms, and occupy this region, says Plutarch, in order that the mother may be able to embrace and support her infant while she is suckling it.

Size.—In the male they are rudimentary during the whole of life; in the female until the period of puberty only, when they become much enlarged as the generative apparatus is developed more completely. They again increase in size during pregnancy, and especially after delivery; they become atrophied in old age. In some females who are still young, the size of the mammæ by no means corresponds to their stature, strength, and soundness of constitution; while, on the other hand, it is not uncommon to see thin, phthisical individuals with very large breasts. In judging of the size of the mammæ, we must not confound that depending upon the gland itself with that due to fat. The largest breasts are not always those which furnish the most milk, because their extreme size often depends on an accumulation of fat, the gland itself being small. The left mamma is almost always a little larger than the right.

Form.—The mammæ represent a semi-sphere surmounted by a large papilla called the *nipple*.

The skin covering the mamma is remarkably delicate. Surrounding the nipple is an *areola* or *aureola* of a pinkish hue in young girls, but of a brownish colour in most females who have borne children; it has also a rough appearance, owing to a number of sebaceous glands, which yield a kind of waxy secretion that prevents the irritating action of the saliva of the infant. Morgagni, Winslow, and Meckel state that they have observed milk to escape from them; but if there was no error in their observations, it must be admitted that, by some unusual anomaly, a lactiferous duct opened at the side of one of these little glands.

The *mammilla* or *nipple* is of a pinkish or brown colour, rough, and, as it were, cracked at the summit, and capable of undergoing a sort of erection; it varies in form and size in different subjects; it is either cylindrical or conical, and sometimes so short that the lips of the infant cannot lay hold of it; in certain cases it is even depressed. In the centre of the nipple we observe one or more depressions, in which the lactiferous ducts open by a variable number of orifices.

The papilla is provided also with a great number of sebaceous glands having the appearance of tubercles, and secreting a substance which prevents the nipple from being chapped by the act of sucking and the saliva of the infant.*

Structure.—The breasts consist of the mammary glandular tissue and of fat.

The Mammary Gland.—When freed from the fat by which it is surrounded, the mammary gland appears like a mass flattened from before backward, and thicker in the centre than at its circumference, which is irregular, but less so on the inside than on the outside. Its base, which is plane, and even slightly concave, rests upon the pectoralis major, and sometimes beyond it upon the serratus magnus; a continuation of the fascia superficialis separates it from these muscles, to which it adheres by very loose serous cellular tissue only, and hence it is very movable.

The cutaneous surface of the mammary gland is very unequal, and forms alveoli filled by fat, by which means the inequalities are concealed.

The proper tissue of the gland is considerably denser than that of most glandular organs. It should be examined both during lactation, and when that function is not being performed.

In the absence of lactation, the gland has the appearance of a very compact, whitish,

* [Sir A. Cooper has described numerous cutaneous papillæ upon the nipple and areola; they are highly vascular and nervous. He has also shown that the glands found in the areola and at the base of the nipple have branched ducts, ending in blind extremities: in the female, from one to five open on each tubercle.—(*Anatomy of the Breast*, 1840.)]

fibrous tissue, divided into unequal lobes, which cannot be compared to anything better than to certain fibrous tumours of the uterus. The granular structure proper to the tissue of glands is not visible during this state.

During lactation, the granular structure becomes very evident. The following are the results of my observations respecting it at this period: The glandular granules or lobules are united into small clusters, forming flattened lobes, placed one upon another. From each little lobe proceeds an excretory duct, which may be recognised by its white colour, is easily injected, and is formed by the union of a number of smaller ducts corresponding to the number of lobules. Having had an opportunity of dissecting the mamma of a female recently delivered, in which the cellular tissue between the lobules was infiltrated with serum, the lobules themselves, as it were, dissected, and the lactiferous ducts injected with yellowish coagulated milk, I found that some of the lobules were isolated, and, as it were, pediculated, while others were collected into regular or irregular clusters. In one of these clusters the lobules had a circular arrangement, small ducts proceeded from each lobule, and, passing from the circumference towards the centre of the circle like radii, opened into a common efferent duct, which issued from the central point. Another cluster was elongated and swollen at intervals, and in the centre was a duct which received the smaller ducts from the several lobules. Each lobule had a central cavity, from which a worm-shaped mass of coagulated caseous matter could be expressed. When examined by the simple microscope, the parietes of these cavities had a spongy aspect like the pith of the rush, a character which I have already noticed as belonging to all glandular organs.*

The Fibrous Tissue of the Mamma.—Besides the lobules, a large quantity of fibrous tissue also enters into the structure of the gland, forms a complete investment for it, and then sends more or less loose prolongations into its substance, and unites the lobes together. It is to the great quantity of fibrous tissue that the hardness of the mammary gland is to be ascribed. Sometimes the enlargement of the mamma at the time of puberty is confined entirely to the fibrous tissue; in such a case, the organ may acquire an enormous size, the glandular tissue disappears, and the mamma is transformed into a many-lobed fibrous mass, which has been sometimes mistaken for a degenerated lipoma.

The Adipose Tissue.—The alveoli on the outer surface of the mamma are filled with masses of fatty tissue, which are separated by fibrous laminæ extending from the gland to the skin. The cells in which these masses are contained do not communicate with each other, and hence the frequency of circumscribed abscesses in the mamma. The relative quantities of fat and glandular tissue have an inverse ratio to each other. The great size of the mammæ in some men is owing to development of the fatty tissue. Haller says that it is an essential element in the structure of the gland, and that he has several times seen lactiferous ducts arise from it.

The Lactiferous Ducts.—If the mamma of a female who has died during lactation be divided, the milk will be seen to exude from a number of points, as from the pores of a sponge; these points correspond to sections of the thin, whitish, semi-transparent excretory ducts of the mammary glands, which are called *lactiferous*, or *galactophorous ducts*. They arise from the lobules, and perhaps, also, from the fatty tissue, as was thought by Haller;† they unite successively like the veins, converge from the circumference to the centre, traverse the substance of the gland, and at length form a variable number of ducts, which reach the centre of the gland, opposite the areola. In that situation they acquire their utmost size, and form considerable ampullæ or dilatations, between which scarcely any intervals are left. According to some anatomists, the number of these ampullæ is not less than twenty; I have never counted more than ten. They are of unequal size. At the base of the nipple they become contracted, straight, and parallel, and open upon its summit by orifices, which are much narrower than the ducts themselves. Thus, then, although there is no reservoir properly so called in the mammary gland, the ampullæ above described may be regarded as such; with this difference only, that instead of one reservoir there are several.

The lactiferous ducts, moreover, are surrounded, both in the mammilla and opposite the areola, with a dartoid tissue, the existence of which explains the state of orgasm and erection of the nipple, as well as the expulsion of the milk in a jet when the gland is excited. There is no trace of the cavernous structure described by some anatomists as existing in the nipple. The lactiferous ducts do not communicate with each other in any part of their course; neither in their terminating canals, nor in their ampullæ, nor in their smaller ducts; this may be proved by mercurial injections, or by filling each duct with a differently-coloured injection. The mammary gland, like most others, is therefore divided into a certain number of distinct compartments, which may perform their functions independently of each other.

Injections also show that the lactiferous ducts have no valves. Their structure is little

* [The ultimate structure of the mammary gland consists of the terminations of the lactiferous ducts in clusters of microscopic cells within each lobule; these cells are round, and have a diameter twenty times as great as that of the capillaries which ramify upon them.

† [Our present knowledge of the minute structure of glands has proved the inaccuracy of this supposition of Haller.]

known. It is generally admitted that they consist of an internal membrane continuous with the skin, and which must be analogous to the mucous membranes, and of an external fibrous coat, which I am inclined to regard as analogous to the tissue of the dartos.

The *arteries* of the mamma arise from the thoracic, especially that which is called the external mammary, also from the intercostals and the internal mammary.

The *veins* are very large, and of two kinds, sub-cutaneous and deep; the latter accompany the arteries, the former are visible through the skin.

The *lymphatics* are very numerous, and enter the axillary glands. The older anatomists admitted a direct communication between the thoracic duct and the glandular tissue of the breast; but this opinion, suggested by the resemblance in colour between the chyle and milk, is altogether erroneous.

The *nerves* are derived from the intercostals and the thoracic branches of the brachial plexus.

Development.—The mammæ become visible after the third month of intra-uterine life. At birth they are more developed than at a subsequent period, and contain a certain quantity of milky viscid fluid. Until puberty the mammæ of the two sexes differ only in the nipple being larger, and the gland somewhat larger in the female than in the male.

In the female, at puberty, they gradually acquire the size which they subsequently retain, their development coinciding with that of the genital organs. Most commonly the change precedes, but sometimes it follows, the appearance of the menses.

The mammæ of the male also participate in the development of the generative apparatus at the time of puberty, and in some subjects even a milky secretion is formed.*

The mammæ become atrophied in old age, and are sometimes replaced by fibrous tissue; in several old women I have found the lactiferous ducts distended with a dark, inspissated mucus, of a gelatinous consistence which has enabled me to trace the ducts even to their most delicate radicles.

THE PERITONEUM.

The Sub-umbilical Portion.—The Supra-umbilical Portion.—General Description and Structure.

The *peritoneum* (*περὶ*, around, and *τείνω*, to extend) is a serous membrane, which, on the one hand, lines the abdominal parietes, and, on the other, invests nearly all the viscera contained in the cavity of the abdomen.

As it enters into the formation of almost all the abdominal viscera, it has been already partially examined while describing them. It remains for us to demonstrate these parts as a whole, and for this purpose, we shall suppose the membrane to commence at one particular point, and shall trace it without interruption in a circular course until we again arrive at the point from which we started.

Fig. 190.

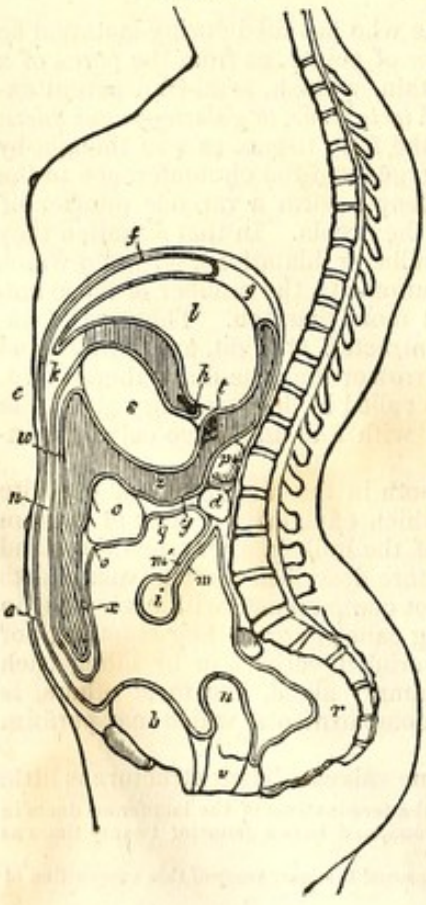

The peritoneum is the largest and most complicated of the serous membranes; it forms, like all of them, a shut sac, the external surface of which adheres to the parts over which it is reflected, while its internal surface is free and smooth.

Taking the umbilical region as a point of departure, we shall divide the peritoneum into two portions, a superior, epigastric or supra-umbilical, and an inferior or sub-umbilical portion.

The Inferior or Sub-umbilical Portion of the Peritoneum.—The inferior or sub-umbilical portion, supposed to commence at the umbilicus, lines the whole of the parietes of the abdomen (*a*, *fig.* 190) below that point. In so doing, it is raised up by the urachus and the two umbilical arteries, or, rather, by the ligaments replacing those arteries, so as to form *three falciform folds*, one median and two lateral, which converge towards their termination at the umbilicus, but diverge in the direction of the bladder; the peritoneum then dips into the pelvis, and covers the fundus, the sides, and the posterior surface of the bladder (*b*), but to a variable extent, according as that organ is distended or empty. When the bladder is contracted, the peritoneum descends behind the symphysis; when, on the

* [It has been shown by Sir A. Cooper, that the mammary gland of the male has a system of ducts and cells like those of the female gland, but very much smaller.]

other hand, it is distended and rises into the abdomen, the peritoneum retires before it, and the bladder then comes into direct contact with the anterior wall of the abdomen, so that it can be reached by the surgeon without wounding the peritoneum.

From the posterior surface of the bladder the peritoneum is reflected upon the other pelvic organs, being arranged differently in the two sexes. In the male it is reflected from the bladder upon the rectum, forming two lateral semilunar folds, called the *posterior ligaments of the bladder*, and a cul-de-sac between them of variable depth, which sometimes reaches as low as the prostate.* In the female it is reflected from the posterior surface of the bladder upon the neck of the uterus (*u*), forming a cul-de-sac between the two, so that the inferior fundus of the bladder is entirely uncovered by it. It then covers the two surfaces and the superior border of the uterus, and forms two lateral, broad, transverse folds (the *ligamenta lata*), each of which is subdivided superiorly into three smaller folds, the *alæ vespertilionis* or *alæ* of the broad ligament, the *anterior* fold corresponding with the round ligament, the *middle* one to the Fallopian tube, and the *posterior* fold to the ovary.

The peritoneum has no relation with the front of the vagina (*v*), but it covers the upper third of that canal behind; from thence it is reflected upon the rectum (*r*), and has then the same arrangement in both sexes. Inferiorly it is limited to the anterior surface of the gut, but superiorly it entirely surrounds it, excepting behind, where it forms a duplicature known as the *mesorectum*.

After leaving the cavity of the pelvis, the peritoneum continues to ascend, so as to cover the posterior wall of the abdomen; in this situation we shall examine it in the middle and at the sides.

In the middle it passes in front of the sacro-vertebral angle, then in front of the lumbar vertebræ, and having arrived opposite an oblique line, extending from the left side of the second lumbar vertebra to the right iliac fossa, it is reflected forward to constitute the left layer (*m*) of the *mesentery* (*μέσος*, middle, *ἔντερον*, an intestine); it immediately expands, so as to correspond to the whole length of the small intestine (*i*), lines the left lateral half, the convex borders, and the right lateral half of that intestine, and then passing from before backward (*m'*), is applied to the back of the layer just described, and in this manner forms the mesentery (*m m'*), the largest of all the duplicatures of the peritoneum, and remarkable for its resemblance to a plaited ruffle.

On the left side, the peritoneum, after having formed the *mesorectum*, then forms the *iliac mesocolon*, a considerable fold, which allows great mobility to the sigmoid flexure of the colon. From the sigmoid flexure it is prolonged upon the left lumbar colon, covering the anterior five sixths of that part of the intestine, and applying it against the kidney, but without forming any duplicature for it; so that the kidney and the colon are in immediate relation. Still, the left lumbar colon is not unfrequently entirely surrounded by the peritoneum, so as to have a duplicature behind it, called the *left lumbar mesocolon*.

Along the whole course of the great intestine, the peritoneum usually forms a number of small folds containing fat, and named the *appendices epiploicæ*.

On the right side the peritoneum arrives at the cæcum, and may be arranged in one of two modes: it either entirely invests that portion of intestine, which is then very movable; or else, and this is the most common arrangement, it passes immediately in front of the cæcum, which is thus applied against the right iliac fossa, and is attached there by rather loose cellular tissue. The peritoneum sometimes forms a small mesentery for the vermiform appendix, sometimes fixes it against the posterior surface of the cæcum, or against the ileum, or, lastly, against the lower portion of the mesentery. Above the cæcum the peritoneum covers the right lumbar colon, and has the same arrangements as on the left side.

Such is the course of the sub-umbilical portion of the peritoneum.

The Superior or Supra-umblical Portion of the Peritoneum.—We shall trace the superior or supra-umbilical portion from the umbilicus to the posterior wall of the abdomen, opposite to the mesentery and the lumbar mesocolon, to which points we have already traced the lower portion.

Commencing at the umbilicus and proceeding upward, the peritoneum (*e*) lines the anterior abdominal parietes; on the right side it meets with the umbilical vein, or the fibrous cord to which that vein is reduced in the adult, covers it, and forms a falciform duplicature, named the *suspensory ligament of the liver*, or *falx of the umbilical vein*; this fold is of a triangular shape, its apex corresponds with the umbilicus, and its base with the upper surface of the liver, which is divided by it into two lateral portions or lobes.† From the umbilicus, then, as from a centre, proceed four peritoneal folds: one superior or ascending, for the umbilical vein; and three descending, one for the urachus and two for the umbilical arteries.

From the anterior wall of the abdomen, the peritoneum is continued upon the lower

* The peritoneum, forming the cul-de-sac between the bladder and the rectum, sometimes has a fissured appearance, like that seen upon the parietes of the abdomen in women who have had many children.

† [Its lower free margin encloses the umbilical vein, and its upper or interior border is attached to the abdominal parietes.]

surface of the diaphragm (*f*), and is arranged differently on the right and left sides and in the middle.

The Right or Splenic Portion.—The peritoneum, after having lined the lower surface of the diaphragm as far as the vertebral column, is reflected upon the posterior surface of the vascular pedicle of the spleen, covers the posterior half of the internal surface of that organ, its posterior border, the whole of its external surface, the anterior half of its internal surface, and the anterior surface of its vascular pedicle, from which it is prolonged upon the great end of the stomach, and becomes continuous with the anterior layer of the great omentum. The two layers which are applied to each other, one in front of and the other behind the vessels of the spleen, constitute the *gastro-splenic omentum*. Below the spleen, the peritoneum forms a horizontal fold, or septum, by which that organ is separated from the viscera below it.

The Middle or Gastro-epiploic Portion.—In the middle the peritoneum lines the lower surface of the diaphragm, as far back as the cardiac extremity of the œsophagus, is reflected over the anterior surface of the stomach (*s*), and descends into the abdomen in front of the arch of the colon and the convolutions of the small intestine, to form the *anterior layer* (*n*) *of the great omentum.*

After descending towards the lower part of the abdomen for a distance, which varies in different individuals and at different ages, it is folded backward upon itself, and passes upward to form the *posterior layer* (*o*) *of the great omentum.* Having arrived at the convex border of the arch of the colon (*c*), it covers the lower surface of that intestine, and passes horizontally backward (*q*) to the anterior surface of the vertebral column, in front of which it is again reflected, and becomes continuous with the right layer (*m'*) of the mesentery. The horizontal portion, which extends from the arch of the colon to the vertebral column, forms the *inferior layer* (*q*) *of the transverse mesocolon.*

It follows, then, that the portion of the peritoneum which is continuous with that upon the anterior surface of the stomach, forms below that organ a kind of bag, which has a direct or descending layer, and a reflected or ascending layer, in the interval between which are placed the stomach (*s*), the pancreas (*p*), the duodenum (*d*), and the arch of the colon (*e*). We shall afterward find that each of these layers is lined internally by another layer of peritoneum, so that the great omentum consists of four layers of serous membrane.

The Right or Hepatic Portion.—On the right side the peritoneum is reflected from the diaphragm upon the convex surface of the liver (*l*), and forms the *coronary ligament of the liver* (at *g*), being continuous with the suspensory ligament, the direction of which is at right angles to its own.

From the convex surface of the liver, the peritoneum is reflected over its anterior margin, and then upon its concave surface, investing the gall-bladder, sometimes almost entirely, but generally on its lower surface only. At the transverse fissure it is reflected downward in front of the vessels of the liver, and to the left of those vessels reaches the lesser curvature of the stomach, and is continued upon the anterior surface of that organ. That portion of the peritoneum which extends from the transverse fissure to the lesser curvature of the stomach, constitutes the *anterior layer* (*h*) *of the gastro-hepatic* or *lesser omentum.* To the right of the vessels of the liver and to the right of the gall-bladder, the peritoneum covers the lower surface of this viscus, and becomes directly continuous with the portion which covers the right lumbar colon.

As the peritoneum is reflected from the diaphragm upon the right and left extremities of the liver, it forms two folds, one on each side, called the *triangular ligaments of the liver.*

The Foramen of Winslow and Sac of the Omentum.—Behind the vessels of the liver, and under the anterior root of the lobulus Spigelii, is an opening which leads into a cavity situated behind the stomach and the gastro-hepatic omentum. This opening is the *orifice of the omental sac*, or the *foramen of Winslow* (in which a probe is placed in the figure); the cavity is called the *posterior* cavity of the peritoneum, or the *sac of the omentum* (*i*). The foramen of Winslow is semicircular, sometimes triangular in shape, and about one inch in its longest diameter. It is bounded in front by the vessels of the liver, behind by the vena cava inferior, below by the duodenum, and above by the neck of the gall-bladder, or, rather, by the lobulus caudatus, or anterior root of the lobulus Spigelii, these several parts being covered with peritoneum. Through this opening the peritoneum enters the sort of pouch formed between the two layers of the great omentum.

In tracing the course of the reflected portion of the peritoneum, we shall commence at this opening, and shall return without interruption to the same point. The peritoneum is first applied to the posterior surface of the anterior layer of the gastro-hepatic omentum already described, and forms the *posterior layer* (*t*) *of that omentum;* it then covers the posterior surface of the stomach; below that organ it is applied (*w*) to the descending or anterior layer of the great omentum, behind and parallel to which it passes down; having arrived at the point where the anterior layer of the great omentum is reflected, the layer we are now describing is itself reflected (*x*) in the same manner, and becomes applied to the anterior surface of the posterior layer of that omentum; con-

tinuing to ascend, it gains the convex border of the transverse colon, covers the upper surface of that intestine, and, farther back, is applied to that layer of the great omentum which is continued over the lower surface of the colon; it thus forms the upper (*y*) of the two layers of which the *transverse mesocolon* is composed. Having reached the front of the vertebral column, it leaves the inferior layer of the transverse mesocolon, covers the anterior surface of the third portion of the duodenum (*d*), the anterior surface of the pancreas (*p*), the lobulus Spigelii and the anterior part of the vena cava, and arrives at the transverse fissure of the liver, opposite the foramen from which we began to trace it.

It follows, therefore, that the great omentum, notwithstanding its thinness and transparency, consists of four perfectly distinct layers, two of which, united together in front, and two behind, constitute the parietes of a cavity called the posterior cavity of the peritoneum, or the sac of the omentum.

We may, however, describe the omentum in a different mode, as follows: Two layers of peritoneum applied to each other pass off from the transverse fissure of the liver, separate along the lesser curvature of the stomach, in order to enclose that organ, again unite along its greater curvature, then pass downward, and, opposite the brim of the pelvis, are reflected backward upon themselves, and proceed upward. Having reached the convex border of the colon, they separate to receive that intestine between them, become reunited at its concave border to form the transverse mesocolon, and then separate finally. The inferior layer is reflected downward, to become continuous with the right layer of the mesentery; the superior is reflected upward, to cover the third portion of the duodenum, the pancreas, and the lobulus Spigelii, and then becomes continuous with the rest of the peritoneum at the foramen of Winslow.*

General Description of the Peritoneum.—From the preceding description, it follows that the peritoneum forms a continuous membrane, so that, if it were possible to unfold all its duplicatures, and to detach it entire from the surface of all the organs covered by it, it would form a large membranous sac without an opening. Nevertheless, in the female there is a remarkable interruption at the point corresponding to the free extremity of the Fallopian tube, in which situation we find the only example in the body of a serous and mucous membrane being continuous with each other.

The peritoneum has two surfaces, an *external* and an *internal*. The internal surface is free, smooth, and moist, and is the seat of an exhalant and absorbent process, which, in the natural condition, exactly counterbalance one another.

The *external* or *adherent surface* lines the parietes of the abdominal cavity, covers most of the abdominal viscera, of which it forms the external or common coat, and is in contact with itself in the different folds formed by the peritoneum. The attachment of this surface is effected by means of cellular tissue, the character of which varies in different situations.

We shall examine the external surface of the portion of the peritoneum applied to the abdominal parietes, or the *parietal peritoneum;* of that upon the viscera, or the *visceral peritoneum;* and also of that forming the different folds.

The Parietal Portion of the Peritoneum.—Upon the *diaphragm* it is attached by a very dense cellular tissue; nevertheless, it may be torn off in dissecting that part. Upon the anterior wall of the abdomen it adheres most strongly opposite the linea alba and the sheath of the rectus muscle, and more loosely opposite the crural arches than in any other part. Still, it is not very difficult to separate the whole of the membrane corresponding to the parietes of the abdomen. In the *lumbar region* the adhesion is extremely loose, and also in the iliac fossæ on the front of the vertebral column: the same is the case in the cavity of the pelvis.

The cellular tissue on the outside of the peritoneum, which most anatomists have regarded as forming the external tissue of that membrane, sends prolongations through the numerous openings with which the walls of the abdomen are perforated. These prolongations connect the sub-peritoneal cellular tissue with that of the lower extremities on the one hand, and with the cellular tissue external to the pleura on the other. The peritoneum is supported throughout by a *fibrous layer*, and this accounts for the difficulty with which abscesses of the abdominal parietes open into the cavity of the peritoneum.

The Visceral Portion of the Peritoneum.—Among the viscera of the abdomen some receive a complete investment from the peritoneum, always excepting the point at which their vessels reach them; to this class belong the spleen, the stomach, and the small intestines. Others have a less complete covering, so that a portion of their surface is in immediate relation with surrounding parts: of this number are the ascending and descending colon and the cæcum. Lastly, others have only very slight relations with the peritoneum, which merely pass over them, and do not appear to enter into their forma-

* In many subjects the existence of the sac of the omentum may be demonstrated by introducing a large catheter into the foramen of Winslow, and by blowing carefully through it; the air will enter between the two anterior and the two posterior layers of the great omentum, and form a large and more or less regular bladder. For this experiment to succeed, the omentum must be perfectly uninjured, and free from adhesions.

tion: to this class belong the bladder, the lower part of the rectum, the pancreas, the two lower portions of the duodenum, and the kidneys. To the last-named organs the peritoneum is connected only by very loose cellular tissue.

The visceral portion of the peritoneum is not strengthened by the fibrous layer met with in its parietal portion, and, therefore, perforation of the serous coat of the viscera is much more common than perforation of the parietal portion of the serous membrane.

The Folds of the Peritoneum.—Among the folds of the peritoneum, most of which have been already described, and which need be only recapitulated here, some bear the name of *ligaments*, viz., the triangular, coronary, and falciform ligaments of the liver, the posterior ligaments of the bladder, and the broad ligaments of the uterus.

Others are called *mesenteries*, viz., the mesentery, properly so called, or the mesentery of the small intestine, the transverse mesocolon, the right and left lumbar mesocolon when they exist, the iliac mesocolon, and the mesorectum. With these we should include the duplicature extending from the transverse fissure of the liver to the lower curvature of the stomach, and known as the lesser omentum; it really constitutes the *mesogastrium*.

Lastly, there are certain folds, named *omenta* or *epiploa* (ἐπὶ, upon, πλέω, to float), viz., the great, or gastro-colic, small, or gastro-hepatic, gastro-splenic, and colic omenta.* With this class we may connect the appendices epiploicæ. It may be well to make a few observations upon the great and lesser omenta.

The Great Omentum.—The great or gastro-colic omentum, so called because it is attached, on the one hand, to the stomach, and on the other to the colon, scarcely exists in the new-born infant; it is gradually developed as age advances, and about the period of the termination of growth it reaches to the brim of the pelvis. It has been remarked that it descends a little lower on the left than on the right side.

When the stomach and the colon are distended, this omentum is reduced to a more or less narrow border extending along the arch of the colon.

It presents also a number of individual varieties: sometimes it is very regularly suspended in front of the intestinal convolutions; sometimes it is folded upon itself, and carried to one side or the other; occasionally it adheres at some point, becomes stretched like a cord, and may then give rise to strangulation; and, lastly, it is not very rare to find it turned upward and backward between the diaphragm above and the stomach and liver below.

It is so transparent and thin that it is difficult to conceive it to be formed of four layers. In some individuals it is even perforated with holes like a piece of lace. The great omentum is found, in very fat persons, to be loaded with an immense quantity of adipose tissue, deposited chiefly along the vessels; so that it may acquire a very considerable size, and a weight of several pounds.

The great omentum has an *anterior* and *posterior surface*, both of which are free, an *upper* adherent border, a *lower* border, free, convex, and more or less sinuous, which corresponds with the crural arches, and the internal openings of the inguinal canals; it is, therefore, very often found in hernial sacs.

The lower border is more liable to adhesions than any other part of the omentum. The *lateral borders* have nothing remarkable; they proceed parallel to the ascending and descending portions of the colon, which are sometimes covered by them.

The *arteries* of the great omentum are furnished by the right and left gastro-epiploic arteries; they descend vertically between its two anterior layers, scarcely diminishing in caliber. At its lower border they turn upward, and ascend between the two posterior layers as far as the arch of the colon, where they communicate with the arteries of that intestine.

The *veins* follow the same course as the arteries, and assist in forming the vena portæ.

Some *lymphatic glands* are found in the great omentum along the curvatures of the stomach and the arch of the colon.

Nerves.—Some nervous filaments from the solar plexus can be traced upon the arteries of the omentum; it is doubtless from them that the epiploon derives its peculiar sensibility, and on them that the phenomena of strangulation depend when it is constricted in a hernia.

The *uses* of the omentum are not known.

The Lesser Omentum.—The lesser omentum, a true mesentery, the *mesogastrium*, presents a lower concave border, attached to the lesser curvature of the stomach, and an upper border, attached to the transverse fissure of the liver, to that part of the antero-posterior fissure which is behind the transverse fissure, and also to the œsophagus and the diaphragm; its right border contains the ducts and vessels of the liver, and behind the border thus formed is seen the foramen of Winslow; on the left it is bounded by the œsophagus.†

* [The colic omentum consists of two layers of peritoneum, with intermediate vessels and fat, which descend, behind the great omentum, from the upper part of the ascending colon.]

† [The cellular tissue surrounding the vessels, ducts, and nerves, contained between the layers of this small omentum, has been described as giving origin to Glisson's capsule.]

Structure of the Peritoneum.—The peritoneum, like all other serous membranes, has neither arteries, veins, nor nerves. Those which are contained within the omenta and the mesentery do not properly belong to this membrane. The finest capillary injections, either natural or artificial, form an extremely delicate network below the peritoneum, but never penetrate it.*

ANGEIOLOGY.

Definition and Objects of Angeiology.

Angeiology (ἀγγεῖον, a vessel) is that division of anatomy which treats of the organs of the circulation.

The circulating system consists of a central organ, the *heart*, the agent for propelling the blood; of the *arteries*, vessels through which the blood is conveyed from the heart to all parts of the body; of the *veins*, through which the blood is returned from all parts of the body to the heart again; and, lastly, of the *lymphatic vessels*, appendages of the venous system, into which their contents are ultimately poured.

THE HEART.

General Description.—External and Internal Conformation.—Structure.—Development.—Functions.—The Pericardium.

Dissection.—In order to study the external conformation of the heart, inject the cavities of the right side of that organ by the pulmonary artery, or by one of the venæ cavæ, taking care to tie the other; the cavities of the left side may be filled from the aorta, or one of the pulmonary veins.

Tallow, wax, and glue-size are the most suitable materials for this purpose.

The *heart* (καρδία), the central part of the circulating apparatus, is a hollow muscular organ, divided into several compartments, and intended for propelling through the arteries into all parts of the body the blood which is poured into it from the veins.

The heart is one of the most important organs in the body. In a zoological point of view, the presence or absence of a heart, and the complexity or simplicity of its structure, deserve particular attention, because such variations in regard to the central organ of the circulation are accompanied by very great modifications in the entire organism.†

Congenital absence of the heart is extremely rare, and is always accompanied with other malformations, more especially with absence of the brain. These deficiencies are incompatible with life.

Number.—Man and vertebrated animals have only one heart; in mollusca it is double, or even triple. This plurality of hearts, instead of being an index of perfection, should be regarded as a subdivision, and less perfect condition of the organ. We shall see that man, as well as mammalia and birds, has, in reality, two hearts united into one.

Situation.—The heart is situated at the junction of the upper third with the lower two thirds of the body; hence the upper parts of the system are more immediately under the influence of this important organ.‡

The heart (*l*, *fig.* 170; *o*, *fig.* 171) occupies the middle of the thoracic cavity; it is situated in the mediastinum, in front of the vertebral column, behind the sternum, which forms a kind of shield for it, and beyond which it projects on the left side; it is placed between the lungs, and above the diaphragm, by which it is separated from the abdominal viscera.

It is retained in this situation by the pericardium (*p p*, *fig.* 170), a fibro-serous covering, which is itself closely adherent to the diaphragm (*x*); by the pleuræ (*q q*), which are reflected on each side of it, to form the parietes of the mediastinum; and, lastly, by the great vessels which pass out or enter at its base.

* [The basis of the peritoneum is cellular tissue; its smooth surface is covered with a squamous epithelium.]

† Vertebrata and mollusca are the only animals which are provided with a heart. Mammalia and birds alone possess a double heart, *i. e.*, a heart with two auricles and two ventricles. Fishes and reptiles have a simple heart, *i. e.*, a heart with only one auricle and one ventricle, this ventricle being pulmonary in fishes, and both systemic and pulmonary in reptiles.*

‡ The distance from the heart to the brain varies in different individuals, according to the length of the thorax and the neck. This difference may amount to two inches, and may exercise some influence upon the cerebral circulation. In consequence of this observation, extreme shortness of the neck has been regarded as a predisposing cause of apoplexy.

---

* [A central pulsating vessel is found in some of the higher radiata, and in the articulata; in some of the latter it constitutes a strong muscular ventricle, but the addition of a systemic auricle to this ventricle is first observed in the mollusca; in the invertebrata, generally, the ventricle is entirely systemic: in the higher cephalopods there are two branchial hearts. In fishes the heart consists of a systemic auricle and a pulmonary ventricle, and is preceded by a sinus venosus, and followed by a bulbus arteriosus. In the early condition of the batrachia the same conformation exists; but in their adult state, and also in all reptilia, there are *two* auricles and one ventricle, the additional auricle being pulmonary, *i. e.*, receiving the blood from the lungs. In the higher reptilia, the single ventricle, which is both systemic and pulmonary, is divided by an imperfect septum ascending from the apex of the heart. In the crocodilus lucius, as well as in birds and mammalia, this interventricular septum is complete, so that in them the heart is divided into two auricles and two ventricles, the cavities of one side being systemic, and of the other pulmonary.]

These means of attachment are not such as to prevent the heart from undergoing remarkable changes of position, depending upon peculiar attitudes, upon shocks acting on the body, or upon diseases of the surrounding organs. Thus, in a case of hydrothorax on the left side, the apex of the heart struck against the right side, and gave rise to the suspicion that the viscera were transposed.

Size and Weight.—Neither the size nor the weight of the heart can be estimated with exactness, on account of the numerous individual varieties in both. It is very difficult to determine the limits, in either the one or the other, between a healthy and a morbid condition; and a heart which would be considered normal in one individual would be regarded as hypertrophied in another.

The defects of the method proposed by Laennec for obtaining an approximative estimate of the size of the heart, by comparing it with that of the closed hand of the same subject, afford sufficient evidence of the difficulty of arriving at an accurate result in this matter.*

No organ in the body is more subject to enlargement than the heart; when caused by dilatation of the cavities, it constitutes *aneurism* of the heart (*dilatation*); when due to thickening of the parietes, it is termed *hypertrophy*. When enlargement occurs from both these causes, the heart acquires an enormous size, and has been called *bullock's heart* (*hypertrophy with dilatation*).

The size of the heart may be estimated directly by ascertaining the quantity of water displaced by it, and by admeasurement; it may also be determined, in an approximate manner, by its weight, which bears a certain relation to the size.

In making these estimates, it is necessary to distinguish the size and weight dependant upon thickness of the parietes of the heart, from the increase occasioned by blood contained in its cavities. In order to obtain comparative results upon this point, the heart must be weighed and measured both in its empty and its distended state. The average weight of the empty heart is from seven to eight ounces. Some atrophied hearts do not weigh more than two ounces: dilated and hypertrophied hearts, when empty, may weigh twenty-two ounces. The ordinary weight of the heart distended with tallow is twenty-four ounces. I have seen dilated hearts, also, filled with tallow, which weighed three pounds.

As to the admeasurement, we shall apply it in succession to the ventricles and to the auricles.

Form, Direction, and Divisions.—The heart has the form of a flattened cone, the axis of which is directed obliquely from above downward, from the right to the left side, and from behind forward. This direction, which is peculiar to the human species (for in the lower animals the heart is vertical), appears to have some relation to the erect position. The heart is not symmetrical in reference to the median line of the body, nor yet in regard to its own axis.

The general relations of the heart will be indicated when we describe the pericardium. I shall here simply state that the heart is in relation with the left lobe of the lungs, which is deeply notched to receive it; that that portion of the heart which is uncovered in front between the lungs, after the sternum and the ribs have been removed, is extremely variable in different subjects; that independently of the volume of the heart, the adhesions of the lungs exercise a very great influence upon the extent of these direct relations of the heart with the anterior part of the sternum. In an old woman, whose lungs were closely adhering to the walls of the thorax, the anterior face of the heart was almost entirely bare behind the sternum and the cartilages of the ribs on the left side.† That the posterior face of the heart deserves the name of vertebral surface just as well as that of diaphragmatic surface; that this surface occasions a marked impression upon the liver; that the relations of the posterior surface of the heart with the œsophagus are such as will cause the distended œsophagus to raise the corresponding portion of the pericardium, and that the posterior surface of the heart is not only separated from the vertebral column by the œsophagus, but also by the aorta, which is situated between the œsophagus and the bodies of the dorsal vertebræ.

The heart is divided into *ventricles* and *auricles*. The ventricles (*l o, figs.* 191, 192) constitute the chief part, in some measure the body of the organ, the conical form of which is determined by them; the auricles (*m n*) are a kind of appendices, which can be well seen only when the heart is raised; they occupy the base of the organ; the limit between the auricles and the ventricles is indicated by a circular furrow.

External Conformation of the Heart.

The External Surface of the Ventricles.

The external surface of the *ventricles*, or the *ventricular portion of the heart*, called also

* The large hand of a workman does not imply the existence of a larger heart than the small hand of a female, or of a man exempt from manual labour.

† The heart descends as far as the middle portion of the xiphoid appendix. The upper half of this appendix is, therefore, in direct relation with the heart, and the inferior half in direct relation with the liver. Should not this circumstance be of some weight in explaining the acute pains by which a pressure upon this appendix is accompanied?

by the ancients the *arterial portion*, because the arteries arise from it, presents for our consideration an anterior and an inferior surface, a right and a left border, a base and an apex.

The *anterior* or *sternal surface* (*fig.* 191) is convex, and is divided into two unequal parts, a larger on the right, and a smaller on the left side, by the *anterior furrow of the heart* (*e b*), which passes vertically from the base towards the apex, is occupied by the anterior coronary artery, and is often obscured by fat. All that part of the organ which is to the right of the furrow belongs to the right ventricle (*l*), all on the left belongs to the left ventricle (*o*). The furrow itself corresponds to the septum between the ventricles.

Fig. 191.

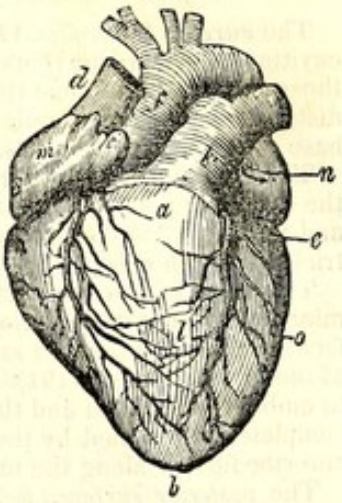

This surface, or, rather, the pericardium which covers it, is in relation with the sternum, more especially in that part which lies to the right of the furrow; also with the fourth, fifth, and sixth costal cartilages of the left side, and with the lungs, which cover it more or less completely. It should be remarked that, in large hearts, this surface, or its pericardium, corresponds immediately to the sternum, while in the natural state it is situated at some distance from that bone. The relations of the heart with the anterior wall of the thorax enable us to examine its condition by means of percussion and auscultation.

The *inferior* or *diaphragmatic surface* (*fig.* 192) is plane and horizontal; it rests upon the diaphragm, which forms a sort of floor for it, and separates it from the liver and the stomach. Like the anterior surface, it is marked by a longitudinal furrow, the *posterior furrow of the heart* (*e b*), which is traversed by vessels and concealed by fat. It differs from the anterior furrow in running parallel to the axis of the heart, and dividing its diaphragmatic surface into two nearly equal parts, excepting near the apex. In consequence of the relations of this surface, pulsations are observed in the epigastrium, which are sometimes much more distinct than those felt upon the anterior wall of the thorax. Another result of these relations is, that the same meaning is attached to the terms *scrobiculus cordis* and *pit of the stomach*, and also to the expressions *pain at the heart*, *pain at the stomach*, *&c.*

The *right* or *lower border* is thin and horizontal, and rests upon the diaphragm; it is straight near the apex, but becomes convex towards the base. The *left border* (*o b*, *fig.* 191) is very thick, convex, and almost vertical; it resembles a surface rather than a border, and corresponds to the left lung, which is deeply notched to receive it.

The *base* of the ventricular portion of the heart is turned upward, backward, and to the right side. From it arises, upon an anterior plane, an artery, which immediately passes from the right to the left; this is the pulmonary artery (*k*); the portion of the ventricle from which it proceeds forms a prominence on the right side of the anterior furrow of the heart, and is prolonged towards the left, becoming narrower at the same time, so as to form a funnel-shaped projection (*infundibulum*, *conus arteriosus*) (*a*), extending a little beyond the base of the ventricles. Upon a second plane we find the aorta (*f*), the origin of which, from the left ventricle, is concealed by the funnel-shaped prolongation of which we have just spoken. On a third plane we find a circular furrow (*o u*, *fig.* 195), separating the auricles from the ventricles. Its posterior half is occupied by the coronary arteries and veins, and the anterior and posterior furrows of the heart terminate in it at right angles.

This circular furrow at first sight appears to be superficial, but is very deep in its posterior half. If we dissect carefully down to the bottom of this furrow, it is found that the base of each ventricle is, as it were, turned inward, so as to be in contact by a broad surface with the base of the auricle. We find, also, that the base of the ventricles is cut obliquely, and hence the anterior surface of the heart is longer than the posterior surface. The difference in length between these two surfaces is about fifteen lines upon the right, and from nine to ten lines upon the left ventricle. Thus, in a heart of the ordinary size, the length of the ventricles in front was three inches three lines, and behind two inches three lines. In a very large heart the length in front was four inches, and behind only three. The circumference of the base of an injected heart, of the average size, measured ten inches; that of a large heart was thirteen inches six lines.

The *apex* (*b*) or *point* of the heart is slightly curved backward in the majority of subjects, and is notched opposite the junction of the two longitudinal furrows. This notch, which is partially concealed by vessels and adipose tissue, divides the apex of the heart into two unequal portions; a right and a smaller, belonging to the right ventricle, and a left and larger portion, belonging to the left ventricle. The relative size of the two portions of the apex of the heart is not constant. In some cases of hypertrophy of the left ventricle, the apex of the heart is entirely formed by it; in other cases, on the contrary, the apex of the heart is nearly equally subdivided.

The apex of the heart is directed forward, downward, and to the left, and corresponds to the cartilages of the fifth and sixth ribs of the left side, and therefore to the region of the corresponding mamma; the left lung is notched opposite the apex of the heart, so that the latter strikes directly against the parietes of the thorax.

The External Surface of the Auricles.

The *auricles* (*m n, figs.* 191, 192), forming the *auricular portion of the heart*, are saccular cavities in which the veins terminate; they may, in fact, be regarded as dilatations of those vessels, and hence this portion of the heart is called the *venous portion*, in contradistinction to the ventricles. They are situated upon the hindermost portion of the base of the heart (*fig.* 192).

Their *size* varies in different individuals; in an injected heart, the average height of the auricular portion is two inches; its antero-posterior diameter is nearly the same; and when the auricles are distended, its transverse diameter extends beyond the ventricles on each side.

The *shape* of the auricular portion of the heart, which can only be accurately determined by means of injection, is irregularly cuboid. It therefore presents several surfaces; its *anterior surface* is situated on a plane much farther back than that of the front of the ventricles (*fig.* 191). It is concave, and describes three fourths of a circle, so as to embrace the aorta and the pulmonary artery, being moulded upon those vessels, and completely concealed by them. The anterior surface of the auricular portion has no anterior furrow along the middle line.

The *posterior surface* (*fig.* 192) is convex, and is continuous with the inferior surface of the ventricles; it presents a vertical furrow, which is prolonged upward from the posterior furrow of the ventricles, then deviates to the left side, and forms a curve, the concavity of which is directed towards the right; it corresponds to the septum of the auricles. Immediately to the right of this furrow we find the termination of the vena cava inferior (*r*), and lower down, that of the great coronary vein. The posterior surface of the auricles is turned towards the vertebral column, from which it is separated by the œsophagus and the aorta.

Fig. 192.

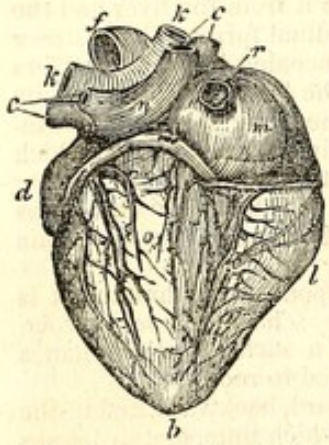

The *superior surface* of the auricular portion forms the highest part of the heart, and is directed backward and towards the right side. It is divided by a furrow, which is convex on the right side, is continuous with the furrow upon the posterior surface, and, like it, corresponds to the interauricular septum. Upon this surface we find the terminations of five different veins; one only of these is to the right of the furrow, viz., that of the vena cava superior (*d, fig.* 191); the other four are on the left of the furrow, and are those of the four pulmonary veins, which are arranged in pairs (*c c, fig.* 192), two at the extreme left of the auricles belonging to the left pulmonary veins, and two immediately in the neighbourhood of the posterior furrow belonging to the right pulmonary veins. This surface corresponds to the bifurcation of the trachea, which, as it were, rides upon it.

The *extremities* of the auricles, or the *auriculæ*, are free, and somewhat resemble the pendulous portion of a dog's ear; hence the term *auricles*. They are indented like a cock's comb; the right auricula is anterior, the left posterior.

The right auricula (*c, fig.* 191) is broader and shorter than the left; it is triangular and concave, so as to embrace the aorta, in front of which it projects; the left auricula (*i*) is narrower and longer, it is sinuous, and curved twice upon itself like an italic *S*; it embraces the pulmonary artery, and terminates opposite the highest part of the anterior furrow of the ventricles.

The right auricula is continuous with the rest of the corresponding auricle, without any well-marked line of separation; but the left auricula is very distinct from its auricle; and upon this latter side, the distinction pointed out by Boerhaave, between the sinuses and the auricles properly so called, may be particularly observed: according to him, the sinus constitutes the body of the auricle, and may be regarded as a dilatation of the veins, while the auricular appendix forms the proper auricle.

The Internal Conformation of the Heart.

The heart is divided internally into four cavities, which are separated from each other by complete or incomplete septa; two of these cavities belong to the auricles, and two to the ventricles. There are a right ventricle and auricle, and a left ventricle and auricle. The auricle and ventricle of the same side are separated by incomplete septa or valves, and communicate with each other. The cavities of the opposite sides are separated by complete septa, and do not communicate. The heart is therefore, in this latter respect, truly double. The right ventricle and auricle constitute the right heart, also

named the *cœur à sang noir*, from the colour of the blood which it contains; and the *pulmonary heart*, because it propels the blood into the lungs. The left ventricle and auricle constitute the left heart, called also the *cœur à sang rouge*, or the *aortic heart*, because it throws the blood into the aorta.

The Internal Conformation of the Ventricles.

Dissection.—In order to obtain a general idea of the internal conformation of the heart, make a series of sections at right angles to its length, or else make an incision along its borders parallel to its long axis.

To obtain a more exact notion of the ventricles, make a V-shaped incision in the right ventricle, letting one branch of the incision extend along the anterior furrow, and the other along the right border, while the angle at which they meet should correspond to the apex of the ventricle.

The best method of opening the left ventricle consists in making a vertical section through the septum; but in doing this, the right ventricle must be sacrificed.

In order to obtain a general view of the appearance of these cavities, they may be prepared in the dried state. For this purpose, the heart is to be injected with tallow, and then, after being dried sufficiently, to be opened in the manner above described, and immersed in warm turpentine, which will dissolve the tallow, and leave the ventricles dilated.

Interior of the Right Ventricle.

The *right ventricle* occupies the right anterior and inferior portion of the heart, and has, therefore, been called the anterior or the inferior *ventricle*. Its cavity (*fig.* 193) has a three-sided pyramidal form. Its inner wall (*b*) is convex, and is formed by the septum of the ventricles; in its lower half it has a well-marked reticulated appearance, which is almost entirely absent in the upper half (*a*). The anterior and inferior walls (partly removed in *fig.* 193) are both concave, and are remarkable for their thinness, so that they are always collapsed when the ventricle is empty. The base of this ventricle presents two openings, which are separated from each other by a projecting part, and which may be compared to the wide circular end, and the narrow mouthpiece of a huntsman's horn. The opening into the auricle (in which a bristle is placed) corresponds to the wide end of the horn, and the infundibulum (*a*) to the narrower end. The transverse diameter of the *base* of this ventricle is nearly equal to its height. The summit (*l*) is turned towards the apex of the heart.

Fig. 193.

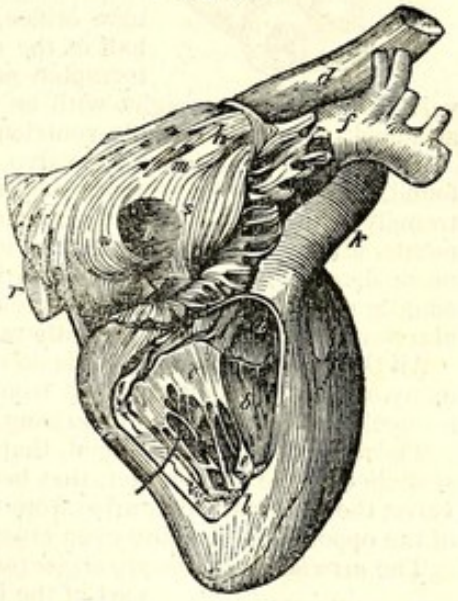

The walls of the right ventricle are very remarkable for their reticulated or areolar character; this areolar portion might be termed the *corpus cavernosum of the heart*, for it presents the spongy structure of the erectile tissues. The fleshy columns which form the areolæ are observed not only upon each of the walls of the ventricle, but they also pass across the cavity of the ventricle near its summit, extending from one wall to the other; in consequence of which the capacity of the ventricle is singularly diminished.

The cylindrical fleshy columns (*columnæ carneæ*, *teretes lacerti*), which separate the meshes or areolæ, are of three kinds. Some (*c*) are attached to the parietes of the heart by one of their extremities, and are free in the rest of their extent; they terminate by a kind of simple or double mammillated projection, from which proceed small *tendinous cords* (*chordæ tendineæ*), that are inserted into the auriculo-ventricular valves (*c*). They are very few in number, and have been named the *muscles of the heart* (*musculi papillares*). The fleshy columns of the second kind are free throughout the whole of their extent, excepting at their extremities, which are attached to the walls of the ventricle. These columns, which are the most numerous, are divided and subdivided to form the areolæ. The third kind of columnæ carneæ adhere to the walls of the ventricle by one of their sides; they are therefore sculptured like pilasters upon the walls of the ventricle.

Most of the columnæ carneæ pass from the apex towards the base of the heart. In all their free portion, the columns of the two first kinds are attached to each other or to the walls of the ventricle, by means of small *tendinous cords*, which are much more delicate than those proceeding to the valves. The areolar muscular structure just described is the essential constituent of the walls of the ventricle; but in addition to it there is a rather thin, compact, and non-reticulated layer of superficial fibres, on which depends the smooth appearance of the external surface of the ventricle.

The Orifices of the Right Ventricle.—At the base of the right ventricle there are two orifices, one *auricular*, which establishes a communication between the ventricle and the

auricle; the other *arterial*, which leads into the pulmonary artery. They are both furnished with valves.

The *right auricular* or *auriculo-ventricular orifice* (through which the bristle is inserted, *fig.* 193) is placed at the posterior and right part of the base of the ventricle; it is elliptical, and is provided with a membranous structure, called the *tricuspid* or *triglochin valve* (*c*), which projects into the interior of the ventricle. This valve is of an annular form (*annulus valvulosus*). Its *ventricular surface* (*t t t*, *fig.* 194) is directed towards the parietes of the ventricle, and receives a great number of small tendinous cords, which, being attached to it at different points, give it an irregular aspect. Its *auricular surface* (*t t t*, *fig.* 195), which is turned towards the axis of the ventricle, is smooth. The *adherent border* is fixed to the margin of the auricular orifice. The free border or margin forms a ring, the diameter of which is equal to that of the adherent border: this margin is irregularly divided, so that, instead of the three segments (*t t t*) generally described, and from which the name of the valve has been derived (τρεῖς, *tres*, three, and γλωχὶς, *cuspis*, a point), some authors admit four, or even six segments.

Fig. 194.

Fig. 195.

The construction of the tricuspid valve can be understood only by regarding it as composed of two parts, an anterior, corresponding to the anterior half of the elliptical auriculo-ventricular orifice, and a posterior, corresponding to the posterior half of the same. The tricuspid valve is not unfrequently interrupted on the left side opposite the junction of these two valves. This valve might, with as much propriety, be termed *mitral*, as that which is attached to the left auriculo-ventricular opening.

To the free margin of the valve, upon which some small nodules are occasionally found, are attached a number of tendinous cords of a nacreous aspect, which are extremely strong considering their tenuity. These small cords, or, rather, tendinous filaments, always arise in greater or less number from the summits of the columnæ carneæ; diverging from thence, often bifurcating during their course, and sometimes becoming united together, they terminate, some at the free margin, others at the ventricular surface of the valve, and others, again, at its adherent border.

All the smalll tendinous cords do not arise from the columnæ carneæ of the first kind; many of them proceed directly from the parietes of the heart. We constantly find a fasciculus of diverging cords arising from the septum.

These cords are so arranged, that, by drawing upon them, the valve is depressed and stretched. We find, in fact, that both in the anterior and posterior part of the tricuspid valve, those cords which arise from the free margin on one side converge towards those of the opposite side, some even crossing each other in the form of the letter X.

The *arterial* or *pulmonary orifice* (*ostium arteriosum*, *d*, *fig.* 194) is placed at the anterior part of the left side of the base of the right ventricle. It is separated from the auricular orifice by a tolerably prominent muscular band, which is concave on its lower surface, and divides the right ventricle into two portions, an auricular and a pulmonary portion or infundibulum. This orifice is circular, and is provided with three very distinct valves, which are named *sigmoid* or *semilunar* (*f*, *fig.* 195; *a a a*, *fig.* 196).* Although thin and semi-transparent, they are very strong. They are directed vertically as the blood is passing from the ventricle into the artery, and become horizontal when it tends to flow back from the artery into the ventricle. Of their two surfaces, the ventricular corresponds to the cavity of the ventricle; the other, or arterial surface, includes between it and the walls of the artery a small cul-de-sac, which has been compared to a pigeon's nest. The adherent border of each valve is convex, and directed towards the ventricle; its free margin presents in the middle a small nodule, by which it is divided into two semilunar halves.

Fig. 196.

When depressed, the valves completely close the vessel, the three nodules filling up the triangular interval left between the approximated free margins. These valves must, therefore, oppose the reflux of the blood into the ventricle; but the resistance offered by them is easily overcome by an injection thrown into the pulmonary artery.

Interior of the Left Ventricle.

The left ventricle occupies the left upper and back part of the heart; it is evidently

* It is extremely rare to find any anomaly in the number of these valves, either by an increase or a diminution of them.

constructed upon the same fundamental type as the right ventricle, but differs from it in many respects, as we shall now proceed to show.

Difference in Situation.—The different positions of the two ventricles are sufficiently known from what has already been stated; but it is important to remark, that the left ventricle projects beyond the other at the apex of the heart (*fig.* 197), while the right is more prominent at the base, in consequence of the existence of the infundibulum.

Difference in Shape.—The right ventricle is pyramidal, and becomes collapsed when not distended; the left is conical and convex, not only on its free surface (*b*), but even at the septum (*a*, *fig.* 194), where it seems to project into the interior of the right ventricle.

Difference in Size.—It is generally stated, in accordance with Senac, Winslow, and Haller, that the right ventricle is more capacious than the left: this statement is founded upon direct observation, which proves that the right ventricle gains more at the base than the left does at the apex; also upon deductions made by comparing the right auricle and the pulmonary artery with the left auricle and the aorta; and, lastly, upon the results obtained by injecting the cavities of the heart. No two observers agree as to the exact numbers which would represent the capacities of the two ventricles, as the following different estimates will show. The capacity of the left ventricle to that of the right has been stated as 31 to 33, as 10 to 11, as 5 to 6, as 2 to 3, and as 1 to 2.—(*Haller*, t. i., l. iv., sect. 3, p. 327)

Now the discrepancies in these estimates prove either the deficiency of the methods of observation, or the existence of real differences resulting from a greater or less amount of accidental obstruction to the pulmonary circulation occurring shortly before death. In the great majority of subjects, the right ventricle is proved to be more capacious than the left, and this, according to the judicious remark of Sabatier, depends upon the state of the circulation through the heart during the last moments of life, at which time the blood flows back from the lungs into the right ventricle, while the left ventricle, not experiencing a similar obstruction, and, moreover, acting with greater vigour, empties itself, more or less completely, of the blood contained within it. After death by decapitation, the right ventricle is as much contracted as the left; also, in individuals that have died without any agony or exhaustion, the cavity of the left ventricle has been completely contracted.*

The condition of the heart, then, in the dead body, in which that organ is found as it was at the moment of death, affords us no means of judging of the relative capacity of its cavities during life. If, by tying the aorta in a living animal, we cause stagnation of the blood in the left ventricle, while the exit of that fluid from the right cavities through the pulmonary artery remains unimpeded, the relative capacity of the two ventricles will be found to be exactly the reverse of what is generally indicated.

The gradual injection of the heart with wax or tallow, so as to distend the ventricles without producing laceration, enables us to determine the size and the weight of the mass of injection contained within each cavity of the heart, and also to measure these cavities under similar conditions, that is to say, in a state of distension. From observations which I have made in this way, it appeared that the left ventricle was rather more capacious than the right.

Difference in the Appearance of the Cavity and in the Structure of its Parietes.—In the left ventricle we find the three kinds of columnæ carneæ. Of the columns of the first kind there are only two (*i i*, *fig.* 197), which are remarkable for their great size. Their summits are almost always bifurcated, and sometimes they are divided into three parts; not unfrequently each of these columnæ results from the apposition of two or three others, which are united by small fibrous cords or filaments.

Fig. 197.

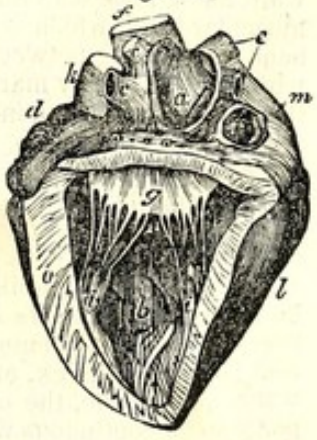

The fleshy columns of the second kind are smaller in the left than in the right ventricle. The areolar arrangement is less strongly marked, and is observed only in the innermost layer, excepting always at the apex, the whole thickness of which, with the exception of the most superficial layer, presents the cavernous arrangement. Moreover, the areolæ are remarkable for their small size, and for the slenderness and number of the columnæ by which they are surrounded. These muscular areolæ are often completed by fibrous cords.

Difference in Thickness.—The walls of the left ventricle are much thicker than those of the right (*figs.* 193, 194, 197). The proportion of one to two, arrived at by Laennec, is too slight; it is one to four, or even one to five. It is generally said that the muscular tissue of the heart is more compact on the left than on the right side.

* The concentric hypertrophy mentioned by authors appears to apply to ordinary hearts, or to hearts in a state of hypertrophy, with their cavities closed, in consequence of the contraction continuing to the last moment. I, therefore, am opposed to admitting concentric hypertrophy as a pathological state.

Difference in the Orifices.—The left auriculo-ventricular orifice (through which a bristle is inserted, *fig.* 197) exactly resembles the right one, and, like it, is provided with a valve (*g*) analogous to the tricuspid, and named by Vesalius the *mitral valve*, from its being regularly divided into two opposite segments (*m m*, *figs.* 194, 195). The mitral valve is stronger than the tricuspid, it is thicker and longer, and receives stronger and more numerous chordæ tendineæ. These differences are more particularly observed in the right segment of the mitral valve, which projects, like an incomplete septum, into the cavity of the ventricle, and appears to divide it into an aortic and an auricular portion; the left segment of the valve (*g*, *fig.* 196), on the contrary, is applied against the walls of the ventricle.

The aortic orifice (*e*, *fig.* 194) exactly resembles the pulmonary orifice of the right ventricle; like that opening, it is also provided with three sigmoid valves (*e*, *fig.* 195), which differ from those of the pulmonary artery merely in being stronger, and in having larger nodules or globules upon their free borders; and, as Arantius admitted their existence only in these valves, they are therefore called *globuli*, *noduli* or *corpora Arantii*.*

The right auriculo-ventricular and arterial orifices are placed at a distance from each other, but the corresponding orifices of the left side are contiguous, so that the adherent border of the right half of the mitral valve is continuous with the adherent border of the corresponding sigmoid valve; and hence it follows, that when these valves are removed, the base of the ventricle presents only one orifice.

Interior of the Auricles.

Dissection of the Right Auricle.—Make a horizontal incision from the auricula to the inferior vena cava, and then a vertical one from the vena cava superior perpendicularly to the first.

Of the Left Auricle.—Make a vertical incision from before backward, between the right and left pulmonary veins, including the entire posterior wall of the auricle. In order to have an accurate idea of the shape of the interior of the auricles, inject a heart with tallow or wax, and then examine the cast thus taken of their cavities.

Interior of the Right Auricle.

The shape of the right auricle, when distended, may be compared to the segment of an irregular oval, the long diameter of which is directed from before backward. It has three walls: an *anterior*, which is convex; an *internal*, which is slightly concave, and corresponds to the septum; and a *posterior*, also concave, which forms the greatest part of the auricle, and is remarkable for the existence upon it of fleshy columns. The right auricle has four orifices in the adult, and five in the fœtus, viz., the auriculo-ventricular orifice, the opening of the vena cava superior, that of the vena cava inferior, that of the coronary vein, and, in the fœtus, the foramen ovale (*trou de Botal*), the situation of which is occupied in the adult by the fossa ovalis.

The *auriculo-ventricular orifice* (see *fig.* 195), the largest of all, is of an elliptical form, from sixteen to eighteen lines in its longest diameter, which is from before backward, and about twelve lines in its shortest diameter. It is surrounded by a whitish zone (*a q*), to which is attached the adherent border of the tricuspid valve (*t t t*). The cavity of the auricle presents a sort of constriction opposite the auriculo-ventricular orifice.

The *orifice* (*h*, *fig.* 193) *of the vena cava superior* (*d*) is circular, and is directed downward and a little backward; it has no valves; it is bounded on the left by a projecting muscular band, which separates it from the auricle, and on the right by a less prominent band intervening between it and the vena cava inferior. The former of these two bands, which are distinctly marked upon the cast of wax, separates the fasciculated portion of the auricle from the non-fasciculated portion, which seems to be formed by an expansion of the venæ cavæ.

The *orifice* (*i*) *of the vena cava inferior* (*r*) opens into the auricle, near the septum, not perpendicularly upward, but horizontally, and at right angles to the original direction of the vein, which is vertical. The orifice is circular, and larger than that of the superior cava; the inferior cava sometimes forms an ampulla or dilatation before it enters the auricle; its orifice, unlike that of the superior cava, is provided with a remarkable semilunar valve, the *valvula Eustachii* (*n*), which surrounds the anterior half, and sometimes two thirds of this opening. Its free margin is concave, and directed upward; its adherent border is convex, and directed downward: one of its surfaces is turned forward towards the auricle, the other backward towards the vessel; one of its extremities appears to be continuous with the margin of the fossa ovalis (*s*), and the other is lost upon the margin of the opening of the inferior cava.

The valve of Eustachius closes the orifice of that vein very imperfectly. In its upper two thirds it is extremely thin, and resembles the valves of the veins; its lower third contains a muscular fasciculus.

* The three sigmoid valves of the aorta are generally very similar in form; in one case, however, which I examined, one of these valves had twice the size of the others. I have lately observed, in a man of sixty, who died of a disease of the heart, the rare sight of an aorta provided with only two sigmoid valves; these two valves were very large, and in relation with the diameter of the aortic orifice, which they covered completely

The *orifice of the coronary vein* is placed immediately in front of the preceding, from which it is separated by the Eustachian valve. It is sometimes situated at the bottom of a small cavity or vestibule. It is provided with a very thin semilunar valve (*valvula Thebesii*, below and behind the bristle), which exactly resembles the valves of the veins, and completely covers the mouth of the vessel. The upper extremity of this valve is continuous with the lower end of the Eustachian valve.

The Inter-auricular Orifice.—In the fœtus, the inter-auricular septum is perforated behind and below by an opening improperly called the *foramen of Botal*, for it was known to Galen, who described a free communication between the auricles. After birth, we find in the situation of the foramen ovale a fossa (*fossa ovalis*, *vestigium foraminis ovalis*), or, rather, a plane surface, which is generally smooth, but occasionally uneven, and, as it were, reticulated; it is bounded in front and above by a semicircular ridge or border (*s*), which is improperly called the *isthmus* or *annulus Vieussenii*, and may be regarded as a more or less perfect sphincter. Behind, the fossa ovalis is continuous with the vena cava inferior; the semicircular ridge or border of the fossa ovalis is formed by a curved muscular fasciculus, sometimes very thick, the concavity of which is directed backward; the inferior extremity of the fasciculus is continuous with the Eustachian valve.

The fossa ovalis is frequently found to be prolonged beneath the semicircular border or annulus, so as to form a sort of cul-de-sac, the bottom of which is often perforated, and the handle of a scalpel may not unfrequently be introduced through this opening into the left auricle, although no morbid phenomenon may have been observed during life.

The Fasciculated and Reticulated Portion of the Auricle.—Upon the internal surface of the auricle, to the right of the vena cava, are observed certain muscular fasciculi or fleshy columns (*musculi pectinati auriculæ*), which are directed vertically from the auricula towards the auriculo-ventricular orifice. These fasciculi adhere to the auricle on one side only; they are intersected by other oblique and smaller bundles, which give a reticulated aspect to the inner surface of the auricle.

Cavity of the Auricula.—The auricula, or that portion of the auricle which extends from the vena cava superior to the bottom of the appendix, consists of an areolar or cavernous structure, exactly resembling that which has been described in the ventricles. The same cavernous structure is found in other parts of the auricle, and in particular near the orifice of the coronary vein.

I agree with Haller* and Boyer, in denying the existence of the *tubercle of Lower*, described by that anatomist as situated (at *m*) between the openings of the venæ cavæ.

It is generally admitted that a certain number of small veins open into the right auricle by minute orifices without valves. We find, in fact, some openings resembling vascular orifices, and known under the name of the *foramina Thebesii*; they are constantly found below the orifice of the vena cava superior, but most of them only lead into small groups of areolæ, and injections do not demonstrate the existence of any corresponding vessels. The only true vascular orifices are those for the anterior coronary veins.

Interior of the Left Auricle.

The cavity of the left auricle (*fig.* 197) differs from that of the right in the following circumstances: in being less capacious than the right auricle, the proportion between them being four to five; in its form, which is irregularly cuboid; in the number of its orifices, of which there are five after birth, and six in the fœtus; in the character of those orifices: thus the left auriculo-ventricular orifice (see *fig.* 195) is smaller than the right; its long diameter, which is transverse, is from thirteen to fourteen lines, its short diameter is from nine to ten lines; the four other openings belong to the pulmonary veins, two (*c*) on the right, and two (*c c*) on the left side, and all are without valves;† in the structure of its auricula, which is perfectly distinct from the rest of the auricle, and contains a central conical cavity, leading into the auricle by a well-defined circular opening; in the left auricle, nothing is seen on the septum corresponding to the fossa ovalis,‡ at least we perceive neither band nor ring by which it is circumscribed. When the two auricles communicate by an oblique passage, we find a very thin fibrous band, beneath which the scalpel may be introduced into the right auricle.

Structure of the Heart.

The heart is essentially a muscular organ, and has a framework consisting of certain fibrous rings or zones; it is covered by a layer of serous membrane; the left cavities are lined by a membrane continuous with the internal coat of the arteries, and the right

* "Id tuberculum cupide receptum est, ut fere fit, ab iis scriptoribus quibus occasio ad propria experimenta nulla est, deinde etiam ab iis qui tandem omninò in corporibus humanis dissecandis se exercuerunt."—(Haller *Elem. Phys.*, t. i., lib. iv., sect. 2, p. 314.)

† It is not uncommon to meet with five openings, three on the right and two on the left side; in other cases, the two left pulmonary veins open by a common orifice.

‡ [The situation of the fœtal opening (*a*, *fig.* 197) is very commonly indicated by a recess of variable depth opening between the left surface of the septum and the (still free) crescentic border of the valve of the foramen ovale.]

cavities by one continuous with the lining membrane of the veins.* Some nerves, proper vessels, and cellular tissue, also enter into its structure.

The Framework of the Heart.

This term may be applied to four *fibrous zones* (the tendinous circles of Lower), which may be regarded as affording both origin and insertion to all the muscular fibres of the heart. These zones are situated at the four orifices of the ventricles, viz., the two auriculo-ventricular and the two arterial orifices.

Dissection.—Remove with care the adipose tissue, and the vessels which occupy the furrows of the heart. Examine the fibrous zones from the internal surface of the heart. In order to study the relations of the orifices with each other, remove the auricles, the aorta, and the pulmonary artery, a little above those orifices.

The Auriculo-ventricular Zones.—Each *auriculo-ventricular* zone is a tolerably regular fibrous circle, which surrounds the opening between the auricle and ventricle, and determines its form and dimensions. These fibrous circles give off expansions of a similar nature, which enter into the formation of the tricuspid and mitral valves, and thus add to their strength. The chordæ tendineæ of the heart also terminate in these zones, either directly or through the medium of the valves.

The left auriculo-ventricular zone is stronger than the right.

The Arterial Zones.—These are two circular rings, the diameter of each of which is somewhat less than that of its corresponding artery, so that there are some very distinct folds or wrinkles produced. These two zones are exactly alike in form, but differ somewhat in strength, the aortic being stronger than the pulmonary. From these zones are given off three very thin but very strong prolongations, which occupy the angular intervals formed by the indented border by which the aorta and pulmonary artery commence; and three other prolongations extend into the substance of the sigmoid valves. These prolongations form very distinct fibrous bundles in the sigmoid valve of the aorta.†

Relative Position of the Orifices of the Ventricles (see *fig.* 195).—The two auriculo-ventricular orifices are situated upon the same plane, posterior to the other orifices, and approach each other at their middle.

The long diameters of these two orifices are at right angles to each other: thus, the long diameter of the right auriculo-ventricular orifice is directed from before backward, while that of the left orifice is directed transversely.

In the angular interval left between these two orifices in front, the aortic opening (*e*) is closely united to them both; so that the posterior half of the circumference of the aortic zone is blended with both auriculo-ventricular zones. At the point of junction between them, we find a cartilaginous, and in the larger animals a bony, arch, which was described by the ancients under the name of the *bone of the heart:* in this situation, also, we frequently find the ossiform concretions of the orifices.

Lastly, upon a plane in front and on the left of the aortic opening, and about five or six lines above it, is situated the orifice (*f*) of the pulmonary artery.

The orifice of the aorta is directed towards the right side, that of the pulmonary artery towards the left, so that these two vessels cross each other, so as to represent the letter X. It follows, therefore, that the pulmonary orifice is separated from the right auriculo-ventricular opening by the orifice of the aor a.

In examining these openings, we observe that the plane of the auriculo-ventricular orifices is directed obliquely backward and downward: this explains the difference in the heights of the ventricles before and behind. We also notice the reflection or turning inward of the base of each ventricle (*q a, p b*) upon itself, so as to form a circular groove or trench on the inner surface of its cavity, running entirely round the margin of the corresponding auriculo-ventricular orifice.

The Muscular Fibres of the Heart.

The Muscular Fibres of the Ventricles.

Dissection.—The muscular fibres of the heart may sometimes be traced without any preparation; but, generally speaking, either commencing putrefaction, maceration in vinegar, or, still better, hardening and separation of the fibres by means of alcohol, and especially by boiling, are necessary for this purpose. This being done, remove first the

* [The muscular fibres of the heart, though involuntary, very closely resemble in structure those of the voluntary muscles (see note, p. 194), but the transverse striæ upon them are less distinct.

The lining membranes of the two sides of the heart are covered by epithelium, and form what is termed the *endocardium.*]

† I for a long time believed that the sigmoid valves, both the aortic and the pulmonary, were formed by two prolongations of the internal membrane of the heart reflected upon itself; but I have from pathological facts lately the positive demonstration that each sigmoid valve was formed, 1st, by a prolongation of the internal membrane of the aorta; 2d, by a prolongation of the internal membrane of the ventricle; 3d, by an intermediate lamella occupying only the half of the height of the valve on the side of its adhering border; this lamella is fibrous, and comes from the arterial zone. The half of the valve which is near the free border is not furnished with this intermediate lamella. Now the arterial lamella may be affected independently of the ventricular, and both the arterial and ventricular lamellæ may be injured independently of the intermediate fibrous lamella which constitutes the foundation of these valves, since it gives them chiefly their power of resistance.

outer membrane, and then the different muscular layers one by one, taking care to follow the fibres from their origin to their termination.

The most general formula which can be given respecting the structure of the ventricles is, that *this portion of the heart is composed of two muscular sacs, contained within a third, which is common to both ventricles.* We should add, that, when the superficial or common fibres arrive at the apex of the heart, they turn up so as to pass into the interior of the ventricles at that point, and form the deep fibres of these two cavities, so that the proper fibres of each ventricle are situated between the direct and the reflected portion of the common fibres.

We shall now enter into some details regarding these fibres.

All the muscular fibres arise from the fibrous zones, and they all terminate upon them, as was clearly pointed out by Lower.* They do not consist of short fibres placed end to end, but are of considerable length, descending in one part of their course, and ascending in the other. The muscular fibres are ranged in successive layers, which pass, as it were, into each other. The muscular fasciculi of each layer are not distinct from one another, but they mutually send off fibres, by which they are bound together like the pillars of the diaphragm; or it may be said that they intersect each other at very acute angles; it is, therefore, impossible to calculate the number of layers, which, according to Wolff, are about three in the right ventricle and six in the left. All that we are able to determine is, the different sets of fibres which enter into the formation of the heart, and of these we find that there are two sets, one *common*, the other *proper* fibres.

The Superficial Common Fibres.—All the superficial fibres are common to the two ventricles, and all are oblique and curved; they commence at the base of the heart, and pass obliquely, in a spiral manner, towards the apex. All the superficial fibres of the anterior region of the heart pass from the right to the left side; all those of the posterior region from the left to the right side. There are neither vertical nor horizontal fibres in the heart, as some authors have stated. The arrangement of the fibres at the apex of the heart forms, as it were, a key to the structure of the entire organ. The anterior and the posterior superficial common fibres both converge towards that point. Each of these sets of fibres forms a very distinct fasciculus or band, and the two bands mutually turn round each other in a semi-spiral direction, so that the anterior band is embraced on the left side by the posterior, which is, in its turn, embraced by the anterior band on the right side; from the apex of the heart the fibres change their course, and instead of descending, they ascend; and instead of being superficial, they become deep-seated. Having entered the heart at its apex, they continue to be reflected upward, and present an arrangement which I shall describe after having explained the course of the proper fibres.

The Proper Fibres.—These are situated between the superficial or descending, and the deep or ascending portion of the common fibres. They form in each ventricle a sort of small barrel or truncated cone, which is applied to that of the opposite ventricle; the superior openings of these cones correspond to the auriculo-ventricular orifices; while the inferior, which are smaller, leave opposite the apex of the heart two considerable intervals, which are filled up by the common fibres. Do these proper fibres turn round and round without end, like an uninterrupted spiral, as Senac was inclined to believe? It appears to me that their extremities are attached to the auriculo-ventricular zones, and that they describe more or less complete circles, which intersect each other at very acute angles.

The Reflected or Deep Common Fibres.—The superficial common fibres are reflected at the apex of the heart, and penetrate into its interior through the lower orifices of the small barrels or cones, formed by the proper fibres. In this situation the anterior and posterior bands, by being reflected upward, and mutually turned round each other, form, at the apex of the heart, a sort of *star with curved rays.*

Nothing can be more evident than the reflection or turning up of the fibres; it was pointed out, though vaguely, by Vesalius, but has been most explicitly described by Steno, who stated expressly that the external fibres enter the heart at the apex, and, assuming an opposite direction to their former one, become the innermost layers, and who compared the apex of the heart to a star. It was also described by Lower, who has accurately figured a radiated structure at the summit of each ventricle; by Winslow, who says that the superficial fibres enter the heart at its apex; and by Wolff and Gerdy, who state that the fibres of the heart are twisted into a whorl or vortex.

From the turning back and the lateral twisting of the anterior and posterior bands, it follows that, by removing the serous membrane which covers the apex of the heart, we may, without injuring the fibres, penetrate into its interior at two points, one to the right, and the other to the left of the anterior band.

The deep reflected fibres having thus reached the interior of the ventricles, pass on the inner side of the proper fibres, and are arranged in three perfectly different modes: thus, some form simple loops with the superficial portion; others are arranged like the thread of a screw, or the figure 8, and others constitute the columnæ carneæ.

* The same arrangement occurs in regard to the fibres of the auricles; it follows, therefore, that the muscular fibres of the ventricles are not directly continuous with those of the auricles.

The *looped fibres*, noticed by Winslow under the name of the bent or arched fibres, and so well described by Gerdy, form, by their superficial and their deep portions, the opposite walls of the ventricle: thus, the anterior superficial fibres constitute by their reflection the deep layer of the posterior wall, while the posterior superficial fibres, after being reflected, form the deep layer of the anterior wall.

The fibres, arranged like the thread of a screw, or like the figure 8, with its lower ring extremely narrow, have been accurately described and even figured by Lower, and were improperly rejected by Winslow, Senac, and others. The superficial portion of these fibres exactly resembles that of the looped fibres, and are always twisted after their reflection, so that their deep portion belongs to the same wall as their superficial. Thus, those fibres whose superficial portion belongs to the anterior wall of the ventricle, assist in forming the same wall by their deep portion.

The *columnæ carneæ* of the heart are formed by a certain number of fibres reflected in loops, or like the figure 8.

Such is the arrangement of the muscular fibres of the ventricles.*

The Muscular Fibres of the Auricles.

The auricles, like the ventricles, *have common and proper muscular fibres*. There is only one fasciculus of common fibres; it occupies the anterior surface of both auricles, and extends transversely from the right to the left auricula. The proper fibres constitute a very thin muscular layer for each auricle; they all commence and terminate at the corresponding ventricular zone.

The Proper Fibres of the Left Auricle.—The muscular layer in this auricle is continuous and uniform, and not areolar. It consists of circular fibres, which occupy the neighbourhood of the auriculo-ventricular orifice, and all the anterior region of the auricle; and of oblique fibres, also arising from the auriculo-ventricular orifice, and divided into several very distinct loops. One circular loop passes between the auricula and the left pulmonary veins; a second forms a vertical zone, interposed between the right and left pulmonary veins; it is very broad, and occupies the entire interval between the veins of the right and left side; a third and a fourth, very small, are interposed between the two pulmonary veins of each side. These fasciculi, by changes in their direction, become adapted to the circular form of the orifices, and constitute true sphincters. It would appear that, besides these bundles, there are some proper circular fibres around each orifice.

The Proper Fibres of the Right Auricle.—In the right auricle the fleshy fibres do not form a continuous layer. This auricle may be regarded as consisting, in the first place, of a non-muscular portion, which may be called the *confluence of the venæ cavæ* (*sinus venosus*); in it there is only one small muscular bundle, situated immediately to the right of the orifice of the vena cava superior; and, secondly, of a muscular portion, which resembles a sort of grating, and is comprised between two fasciculi, one a circular bundle, surrounding the auriculo-ventricular orifice; the other a very prominent semilunar bundle, interposed between the vena cava inferior and the auricula, and forming a vertical, or, rather, an oblique arch, which terminates to the right of the inferior cava.

Muscular Fibres of the Auriculæ.—The walls of the left auricula present a cavernous or areolar structure, in the middle of which we see a central canal, which opens into the anterior of the auricle by a distinct orifice. There is not, in general, any central canal in the right auricula, but only an areolar or cavernous structure.

The muscular fibres of the inter-auricular septum form a muscular ring for the border of the fossa ovalis (so incorrectly termed the *isthmus* or *annulus of Vieussens*), which must be regarded as a true sphincter, consisting of two thirds, three fourths, or even an entire circle. The fibres of which it is formed arise from the auriculo-ventricular orifice, near the septum. Some muscular fibres are often found in the substance of the floor of the fossa ovalis. The other muscular fibres of the septum are continuous with the circular fibres of the auricles.

Separation of the Two Hearts.

Dissection.—Divide the anterior fibres of the ventricles carefully, layer by layer, parallel to the anterior furrow. Then separate the two ventricles, by means of the finger or the handle of the scalpel. In order to separate the auricles, carry the scalpel along the posterior inter-auricular furrow, being particularly careful upon arriving at the fossa ovalis. It is often possible to separate the auricles completely without opening either of them.

The division of the heart into the *right* and the *left heart* is not merely imaginary or theoretical, but is capable of actual demonstration. After making the beautiful preparation described above, we find that the left convex ventricle is received into a corresponding concavity in the right ventricle; the two are therefore adapted to each other, and

* The arrangement described above is common to both ventricles. In the right ventricle almost all the reflected fibres enter into the columnæ carneæ. There is no interlacing, or indigitation of the fleshy fibres along the anterior and posterior furrows, as has been stated; still less do we find a raphé in the situation of these furrows. The splitting and separation of the muscular fibres, caused by the entrance of the bloodvessels opposite the furrows, and the condensation of the fibres between the openings for the vessels, have occasioned these erroneous views.

their mutual reception is rendered complete by means of the infundibuliform prolongation of the right ventricle.

On the other hand, the right auricle is convex, and is received into a corresponding concavity in the left auricle.

By placing the two halves of the heart together, we see clearly the position of the aortic opening behind and to the right side of the pulmonary, the crossing of the aorta and the pulmonary artery in the form of the letter X; the relation of the aorta with the base of the right ventricle, and its situation between the right auriculo-ventricular orifice, which is behind, and the infundibuliform prolongation of the right ventricle, which is in front of it. This last relation explains how a communication may take place between the aorta and the right ventricle.

The separation of the two sides of the heart also enables us to judge accurately of the shape and the relative size of the two ventricles, the regular conical form of the left ventricle, and the prismatic and triangular form of the right ventricle, the left wall of which is, as it were, pushed inward by the corresponding projection of the left ventricle. We can also ascertain the shape and relative size of the two auricles.

Vessels, Nerves, and Cellular Tissue.

Arteries.—The heart receives certain proper arteries, called *cardiac* or *coronary*, from their being arranged in the form of a circle or crown. They are two in number, and are the first branches given off by the aorta. They form two arterial circles placed at right angles to each other; that is to say, one circle follows the auriculo-ventricular furrow, and the other occupies the inter-ventricular furrow.

Veins.—Corresponding to these two arteries there is one vein, named the *great cardiac* or *coronary vein*, and a few small ones, called the *anterior coronary veins*. I do not think that the existence of those accessory veins described by Thebesius as terminating directly in the right auricle and the other cavities of the heart has been clearly demonstrated. I have already said that the common openings of several groups of areolæ have been often mistaken for the orifices of veins. There is always an opening resembling the orifice of a vein below the vena cava superior, but injection does not show any vessel there.

Lymphatics.—These terminate in the numerous lymphatic glands which surround the bronchi and the lower part of the trachea.

Nerves.—The *cardiac nerves* are small when compared with the nerves received by other muscular organs, with those of the tongue, for example, and especially with those of the muscles of the orbit. Some are derived from the cervical ganglia of the sympathetic nerves, the others from the cerebro-spinal system, viz., the cardiac branches of the pneumogastric.

These nerves, which are placed near the arteries, follow them at first, but soon separate from them, and are lost in the muscular substance. We cannot, therefore, admit the opinion of Behrends, who attempted to prove that the nerves are intended only for the vessels of the heart, and not for its proper tissue.

Cellular Tissue.—The serous cellular tissue which unites the muscular fasciculi of the heart is so delicate, that it is extremely difficult to demonstrate it. In certain cases of disease it may become loaded with fat.

We always find a greater or less amount of fat upon the surface of the heart beneath the serous membrane; it abounds in the circular furrow between the auricles and ventricles, in the furrow of the ventricles, at the apex and right border of the heart, in the furrow between the pulmonary artery and the aorta, and between the small digital appendages upon the top of the left auricle.

Development.

In Size.—The heart is larger in proportion to the rest of the body in the earlier stages of its development.

In the fœtus, at the full term and after birth, the weight of the heart is to that of the body as 1 to 120; before the end of the third month of intra-uterine life it is as 1 to 50. It should be remembered that, at the fourth or fifth week, the heart of the fœtus occupies the entire cavity of the thorax. In old age, the heart does not undergo atrophy like most of the other organs; and, in many subjects far advanced in years, it is even hypertrophied.

In Direction.—During the first three months the heart of the fœtus is directed vertically, as in other mammalia; it does not begin to deviate to the left side and forward, as in the adult, until the fourth month.

*In Shape.**—The heart, at an early period, forms a rounded and symmetrical mass, of which the auricles constitute the greatest part; the ventricles appear at this time to be only appendages of the heart, and the right auricle alone is equal in size to all the rest of the organ. The ventricles are gradually enlarged, while the auricles diminish, and towards the fifth month the due proportion between the auricles and ventricles is estab-

* See note, p. 492.

lished; the left ventricle is, at this period, more capacious than the right. The walls of the heart are thicker than they are afterward, and the heart is firmer, and does not collapse when empty. The thickness of the parietes of both ventricles is almost the same.

In Internal Conformation.—It is in reference to its internal structure that the principal changes occur during the development of the heart. The right and left sides of the heart communicate freely during the whole period of intra-uterine existence. The inter-auricular septum does not exist, or, at least, only in a rudimentary state, during the earlier months of fœtal life.

Is there any period of fœtal existence during which the inter-ventricular septum is entirely wanting? and does the development of the human heart, which would then resemble the heart of reptiles, coincide with the general law by which the organs of man, before acquiring their perfect form, pass successively through the several conditions represented by the corresponding organs in the lower animals? The observations of Meckel, which extend as far back as the fourth week, prove that the inter-ventricular septum always exists at that period, but that it is imperfect at the upper part, where it is perforated or notched.*

Cases of malformation, in which the septum of the ventricles is absent, cannot be quoted in support of the opinion that the septum is wanting in the early periods of life; for it would be necessary to prove that such a malformation is an arrest of development.

The opening between the two auricles becomes contracted, and forms the foramen ovale (or *foramen of Botal*), which is found at the posterior and inferior part of the septum.

The valve of Eustachius is sufficiently broad to separate the orifice of the vena cava inferior from the cavity of the right auricle, so that the blood of that vein is carried directly into the left auricle.

Towards the end of the third month, the valve of the foramen ovale, which afterward forms the bottom of the fossa ovalis, begins to appear; it arises from the posterior half of the opening of the vena cava inferior. About the same period the Eustachian valve decreases in size, and from this time the development of these two valves proceeds inversely, that is to say, the Eustachian valve diminishes, while that of the foramen ovale becomes larger. In consequence of this change, the vena cava inferior no longer opens into the left auricle, but into the right.

At the fifth month the foramen ovale is almost entirely closed by the valve which grows from below upward, and from behind forward; at a later period it projects into the left auricle, beyond the margin of the foramen ovale, so that there is an oblique passage from one auricle to the other. After birth, adhesion takes place between these parts; but even when this does not occur, the obliquity of the passage is such, that the want of adhesion does not necessarily allow of any admixture of the blood of the two auricles.

Function.

The heart is the agent by which the blood is impelled through the vessels. The venous blood is poured into the auricles, which then contract; part of the blood flows back into the veins, but the greater portion passes into the ventricles, which contract in their turn. The auriculo-ventricular valves meet, and prevent the reflux of the blood into the auricles, and it is, therefore, propelled into the arteries. The sigmoid valves at first lie in contact with the walls of the arteries, so as to permit the blood to pass from the ventricles; they then fall down at the moment when the distended arteries react upon their contents, and thus prevent the reflux of the blood into the ventricles. The contraction and dilatation of the heart have been termed its *systole* and its *diastole*.

The two auricles contract simultaneously; so also do the two ventricles. The dilatation of the auricles occurs during the contraction of the ventricles, and *vice versâ*. Dilatation is not an active phenomenon, for the fibres of the heart are so arranged that they can produce shortening and contraction of this organ, but can neither elongate nor dilate it.

The spiral direction of the fibres of the heart induced the ancients to conjecture that the contractions of the ventricles took place in a spiral fashion; and, in the first edition of this work, looking only at the anatomical arrangement, I said that this view of the subject was not so devoid of foundation as at first sight it might be imagined. But,

* [The researches of modern embryologists have shown that the heart, in its simplest condition, consists of a straight tube, which is placed vertically in the body, receives the veins at its inferior extremity, and gives off the arteries from its superior extremity. The lower or venous end soon turns upward, so that the tube becomes bent into a loop, which for a time projects through a cleft on the anterior aspect of the body. The tube then becomes divided into an auricular and a ventricular portion, and into a bulbus arteriosus, all enclosed in a pericardium; and in this state the heart of the human fœtus corresponds with the permanent condition of this organ in fishes. Each of these three portions becomes again subdivided: the auricular portion by a descending septum into the two auricles, the ventricular by an ascending septum into the two ventricles, and the bulbus arteriosus into the aorta and pulmonary artery. For a certain period, the right and left auricles and the right and left ventricles communicate with each other. When the septum between the ventricles is yet imperfect (a condition which is permanent in reptiles generally), the common ventricular cavity gives origin to both the aorta and the pulmonary artery. Before the middle of fœtal life this septum is completed, and then the two vessels arise each separately from its proper ventricle. The septum between the auricles remains imperfect until after birth, when the foramen ovale at length becomes closed.]

from the opportunities I have lately had of observing the movements of the heart in a new-born child, full of life and vigour, whose heart, deprived of the pericardium, had passed entirely outside of the chest, through a circular perforation in the upper part of the sternum, I have been enabled to establish the following facts in reference to this interesting subject (see *Gazette de Paris*, August 7th, 1841):

First, the contraction of the right ventricle and the contraction of the left ventricle are simultaneous, or synchronous; this is also the case with the contraction of the auricles.

Second, the contraction of the ventricles coincides with the dilatation of the auricles and the projection of the blood into the arteries. The dilatation of the ventricles coincides with the contraction of the auricles and that of the arteries.

Third, there are but two conditions in the movements of the heart: those of its contractions and those of its dilatations; the state of rest which is spoken of by authors is completely wanting. Dilatation is immediately followed by contraction, and contraction by dilatation.

Fourth, in observing the heart in the case referred to, the question about the order of succession in the movements of the heart, viz., whether the contraction of the auricles precedes that of the ventricles, as most observers assert, or whether the contraction of the ventricles precedes that of the auricles, is found to have no foundation to rest on: it seems that the contraction and the dilatation of the ventricles and that of the auricles result from two opposite forces, continually active, which alternately, and, as it were, necessarily conquer each other in an invariable order, in the fashion of the two alternate movements of a pendulum, or a perfectly-balanced balance-pole.

Fifth, the duration of the contraction of the ventricles continues twice as long as that of their dilatation. On dividing into three equal periods the whole duration of the systole and diastole of the ventricles, we will have two for the contraction and one for the dilatation. The period of repose mentioned by authors has been taken from the first period of the contraction. In regard to the auricles, on dividing into three equal parts the whole duration of their contraction and dilatation, we will have two for dilatation and one for contraction.

Sixth, during the time of their contraction or systole, the ventricles grow pale, their surface becomes rugged, strongly folded, and, as it were, shrivelled. The superficial veins swell; the columnæ carneæ of the ventricles are marked off; the twisted fibres of the summit of the left ventricle, which of itself constitutes the apex of the heart, become more manifest.

Seventh, during their contraction the ventricles contract in all their diameters; and if the phenomenon of their shortening is the most sensible, this is attributable to the greater dimension of the vertical diameter. During the systole of the ventricles, the summit of the left ventricle, or, what is the same, the summit of the heart, describes a spiral movement from right to left and from behind forward.

Eighth, it is this spiral contraction, which is slow, gradual, and successive, as it were, which produces the movement forward of the summit of the heart, and, consequently, the striking of the apex against the walls of the thorax. The systole of the ventricles is not accompanied, as I had before believed, with a movement of projection of the heart forward: it is the spiral contraction which determines exclusively the approximation to, and even the striking of the apex of the heart against the walls of the thorax.

Ninth, the dilatation or diastole of the ventricles takes place in a sudden, instantaneous manner: at first sight one would say that it constituted the active movement of the heart, it is so rapid and energetic. No one can have any idea, without having experienced it, of the force with which the dilatation overcomes pressure made upon this organ. The hand which firmly grasps the heart is forcibly opened by its diastole.

Tenth, the dilatation or diastole of the ventricles is accompanied with a movement of projection of the heart downward. This movement of projection was carried to its maximum when the child was placed in the vertical position; it was so marked, that at first I was induced to believe that it was during the diastole of the ventricles that the percussion of the heart against the walls of the thorax took place. This idea I still entertained, from an experiment which I had made at a former period upon the hearts of frogs; but a more accurate examination of the phenomenon has shown me that it was, indeed, during the systole of the ventricles, and towards the end of this systole, that the percussion of the apex of the heart against the walls of the thorax took place.

Eleventh, the dilatation of the auricles takes place as suddenly as the dilatation of the ventricles, but it lasts as long as the systole of the ventricles: the contraction of the auricles, on the contrary, lasts no longer than the diastole of the ventricles.

Twelfth, during its dilatation, the right auricle seems on the point of bursting, so great is its distension and so thin are its walls. The left auricle, which is narrower, more elongated, and thicker, does not exhibit the same phenomenon, at least not in the same degree. I have not been able to judge of what takes place in the auricular processes except from the movements of the auricles.

In regard to the sounds of the heart, it results, from the experiments which I have made upon the heart of this child (*Medical Gazette*, loco citato), that the two sounds of the heart have their seat at the origin of the pulmonary and aortic arteries, and that they originate in the clashing of the sigmoid valves; that the first sound, which coincides with the systole of the ventricles and the dilatation of the arteries, results from the rising of the sigmoid valves, which were previously lowered; that the second sound, which coincides with the diastole of the ventricles and with the contraction of the arteries, results from the lowering of the sigmoid valves pressed down again by the gush of the returning blood. The simplicity of this theory, the easy and natural explanation which it affords of all the facts that have come to my knowledge, may, perhaps, be considered as a proof of its truth.

THE PERICARDIUM.

The *pericardium* (*p p, fig.* 170) is a fibro-serous sac, which surrounds and protects the heart.

Congenital absence of the pericardium is extremely rare; complete adhesion of the pericardium to the heart, or cellular transformation of this membrane, have been most commonly mistaken for such malformation. Nevertheless, I have seen the heart of an adult to which there was no pericardium: this anomaly has been figured by M. Breschet. The heart was free from any adhesion, and occupied the cavity of the left pleura.

The older anatomists, and particularly Senac, attempted to determine exactly how much larger the cavity of the pericardium is than the heart. Having injected water into the pericardium in different subjects, this observer found that the quantity of liquid contained between the heart and its covering varied from six to twenty-four ounces. I have satisfied myself that in the healthy state, the capacity of the pericardium exactly corresponds to the size of the heart when that organ is dilated to the utmost. In certain cases of hydrops pericardii, this sac becomes enormously enlarged; on the other hand, its inextensibility explains the syncope which immediately follows rupture of the heart,* and which is produced by the accumulation of a small quantity of blood in the pericardium. The syncope which accompanies the effusion from acute pericarditis probably depends upon a similar cause.

Form.—The pericardium is shaped like a cone, with its base downward and its apex upward. It has an external and an internal surface.

External Surface.—The pericardium is situated in the mediastinum, and has the following relations:

In *front* it corresponds to the sternum and the cartilages of the fifth, sixth, and seventh ribs on the left side, from which it is separated by the pleura and the lungs; in the middle it is separated from the sternum by some cellular tissue only. The pericardium is in more or less immediate relation with the sternum, according to the size of the heart, or the quantity of fluid in the pericardium. *Behind*, it corresponds to the vertebral column, from which it is separated by the posterior mediastinum and the organs contained in it, viz., the œsophagus, the aorta, the thoracic duct, &c. *On the sides*, it is in immediate relation with the pleuræ, and indirectly with the lungs. The phrenic nerves and the superior phrenic arteries are applied along the sides of the pericardium. The *base* corresponds to the cordiform tendon of the diaphragm and to the muscular fibres on the left side of it. It adheres closely to the diaphragm only in the anterior half of its circumference; in every other part the base of the pericardium may be easily detached. The *apex* is prolonged upon the great vessels which enter and pass out at the base of the heart.

The pericardium is covered by the pleuræ in the greatest part of its extent, and is united to them by cellular tissue, which is tolerably dense at the sides, and very abundant in front and behind. The cellular tissue of the anterior mediastinum is often loaded with fat, as well as that which surrounds the base of the pericardium, where it sometimes forms prolongations resembling the appendices epiploicæ upon the large intestine.

The *internal surface* of the pericardium is free and lubricated by serosity, like the inner surface of all serous cavities.†

Structure.—The pericardium is a fibro-serous membrane analogous to the dura mater, and, like it, is composed of two very distinct layers, one external and fibrous, the other internal and serous.

The *fibrous layer* consists of fasciculi interlacing in all directions. It is extremely thin, and from its adhesions to the cordiform tendon of the diaphragm, it has been regarded as a prolongation of that structure, but it adheres closely to the diaphragm only

* Death from rupture of the heart is not produced by hemorrhage, for often we do not find more than seven or eight ounces of blood escaped; but it is caused by compression of the heart, in consequence of the inextensibility of the pericardium.

† On opening the thorax of dead bodies, the internal surface of the pericardium is, as it were, dried up; this drying up is owing to the air contained in the lungs.

in front, and much less intimately in the fœtus and the new-born infant. In consequence of this adhesion, the pericardium follows all the motions of the diaphragm.

The fibrous layer is prolonged upon the surface of the great vessels which open into the cavities of the heart, and furnishes for each of them an indistinct sheath, which is soon lost upon them.

The *serous layer* of the pericardium, like the serous membranes generally, forms a shut sac, adherent by its outer surface, but free and smooth internally.* After having lined the fibrous layer, it is reflected upon the great vessels at the base of the heart, and then covers the heart itself, of which it forms the external membrane. We shall consider it as consisting of a parietal, and a visceral or reflected portion.

The Parietal Portion.—The fibrous and the serous layer of the pericardium are so closely adherent, that it is very difficult to separate them. We shall find the same to be the case with the dura mater.

The Reflected or Visceral Portion.—The existence of this portion of the serous membrane can be shown most readily at the points where it is reflected from the fibrous membrane upon the great vessels. It forms one complete sheath, which is common to the aorta and pulmonary artery; some fat is often found in the furrow between these two vessels; it also forms two semi-sheaths for the venæ cavæ and the four pulmonary veins, which are thereby rendered smooth only in the anterior half of their circumference. The heart is entirely covered by the serous membrane, which is here extremely thin. In fat hearts it is raised from the muscular fibres by some flakes of adipose tissue, like the appendices epiploicæ of the great intestine.

Vessels and Nerves.—The *arteries* of the pericardium are very small; they are derived from the surrounding arterial branches, viz., the superior phrenic, the anterior mediastinal, and the bronchial. The *veins* accompany the arteries, and open into the brachio-cephalic veins. Several of them are also said to terminate in the coronary veins. The *lymphatic vessels* enter the lymphatic glands, which surround the vena cava superior.

No *nerves* have yet been demonstrated in the pericardium, though possibly they may exist.

THE ARTERIES.

Definition.—Nomenclature.—Origin.—Varieties.—Course.—Anastomoses.—Form and Relation.—Termination.—Structure.—Preparation.

The term *arteries*† is applied to the vessels which arise from the ventricles of the heart, and to their several divisions.

There are two systems of arteries, one of which commences at the right ventricle, while the other commences at the left. The primitive trunk of the first is the *pulmonary artery*, that of the second is the *aorta*.

These two arterial systems are perfectly distinct in the adult, but communicate freely, and form only one system in the fœtus.

The following general remarks apply more particularly to the aorta and its divisions:

The *arteries* form an uninterrupted succession of decreasing canals, all arising from a common trunk. In this respect we may compare the entire arterial system to a tree, the trunk of which is the aorta, while the larger and smaller branches and the twigs are represented by the divisions which arise in succession from that vessel, as from their common origin.

Again, since the total area or capacity of all the arterial divisions greatly exceeds that of the aorta, we may also regard the arterial system as a cone, the base of which is situated in the entire body, and the apex at the aorta.‡

The study of the arteries includes that of their nomenclature, origin, course, direction, relations, anastomoses, termination, and structure.

Nomenclature.

The nomenclature of the arteries leaves little to be desired in regard to precision; the names of these vessels are derived either from those of the parts to which they are distributed, as the thyroid, lingual, and pharyngeal arteries, &c.; or from their situation, as the femoral and radial arteries; or from their direction, as the circumflex and coronary arteries.

The limits by which one artery is distinguished from another immediately succeeding to it, may be either natural or artificial.

We may regard as *natural limits* the point of origin on the one hand, the point of division on the other, as in the common iliac and common carotid arteries.

* Its inner surface is covered with epithelium.

† From ἀήρ, air, and τηρεῖν, to keep. The etymology of this term affords us evidence of the error of the ancients, who, because they always found these vessels empty and patent after death, imagined that they contained air during life.

‡ Haller has collected all the comparative estimates that have been made between the area of the principal trunks and that of their respective divisions collectively.—(*Elem. Phys.*, t. i., p. 151–163.)

The object of *artificial limits* is to enable us to establish certain divisions of the same arterial trunk, by which means we can describe its relations with greater accuracy. Thus we shall find successive portions of the artery of the upper extremity named the subclavian, the axillary, and the brachial artery.

Origin of the Arteries.

The common origin* of the arterial system is the aorta, which arises from the left ventricle of the heart in the manner already indicated (see THE HEART);† but the origins of the other arteries take place according to certain very general laws: thus, two arteries of equal size may arise from the extremity of a larger artery, and appear to result from the bifurcation of that vessel; arteries arising in this manner might be called *terminal arteries*. Other arteries arise from some point in the circumference of a larger vessel; these may be termed *collateral* arteries.

The terminal arteries almost always arise so as to form a bifurcation at an acute angle; the dichotomous division or bifurcation is the most common mode of division. The acute angle is evidently favourable to the passage of the blood, which, in the first place, maintains nearly the primitive direction in which it was impelled, and, secondly, is easily divided into two columns by the projecting crest at the angle of division.

The collateral arteries very often arise at an acute angle, but sometimes at a right, or even at an obtuse angle. The two latter modes, especially the last, are unfavourable to the flow of the blood. It must, however, be remarked, that many of the arteries which follow a retrograde course in reference to the trunk from which they are derived, nevertheless arise at an acute angle. The caliber of the terminal arteries is very nearly proportional to that of the artery from which they are given off, but the collateral arteries bear no proportion to the caliber of their trunks. We shall see a remarkable example of this in the spermatic arteries, as compared with the aorta from which they arise.

It should also be observed, that the caliber of a principal trunk does not diminish in proportion to the branches which it supplies: in proof of this, observe the aorta as it enters the abdomen, and just before its division into the common iliac.

Anatomical Varieties of the Arteries.

No system of organs is more subject to anatomical varieties than the arteries. These varieties sometimes affect their origin only, sometimes their course, but hardly ever their termination.‡ The study of these varieties is of great importance in surgery, both in reference to the ligature of arteries, and also to operations performed in their vicinity.§

Course of the Arteries.

The principal arteries generally follow the *direction* of the axis of the limbs. The secondary, tertiary, and farther divisions pursue the most varied courses, subject to no particular rule.

The principal arteries are usually straight; but they present slight curves, which render the artery longer than the corresponding limb, and hence tend to prevent laceration during the movement of extension, when the curves merely become obliterated and the vessel undergoes no injurious stretching. The use of these curves in the arteries may be proved by comparing the opposite conditions of the vessels during extension and flexion of the upper and lower extremities.

A great number of the arteries pursue a very distinctly tortuous course, which, as Haller remarks, is preserved by the surrounding cellular tissue, and which is connected with certain particular conditions of the organs to which they are distributed. Thus, we meet with very tortuous arteries in parts which are alternately subject to considerable dilatation and contraction; as, for example, the coronary arteries of the heart and of the lips.

Again, the serpentine course of an artery, by increasing its length in a given space, adds to the extent of surface from which collateral branches may arise. The curvatures of the internal maxillary and of the ophthalmic arteries evidently have this advantage; and it is highly probable that the arch of the aorta may serve a similar purpose.

The arteries are tortuous in certain parts also, in which this arrangement would seem to diminish the force and rapidity of the current of blood; it cannot fail to be perceived

* The word origin must not be taken here in its exactly literal sense, for it has by no means been shown that the arteries are developed from the heart towards the extremities. A very ingenious theory tends, on the contrary, to prove that development proceeds from the extremities towards the heart.

† I should add that the proper tissue of the aorta only touches the fibrous arterial zone opposite the angle, or at the summit of the three festoons which the origin of the aorta exhibits. The arterial zone may be considered as the tangent of the three festoons.

‡ While the origin of the nerves exercises a great influence on their functions, the place from whence the arteries originate appears to be of but little consequence, and is, at all events, very secondary. We cannot agree in the opinion of Walther, that the origin of the arteries of an organ are intimately connected with the mode of its existence, and with the functions which it performs.

§ [For special information on the varieties in the distribution of the arteries, the reader is referred to Haller, *Icones Anatomicæ*, 1756; Murray, *Descriptio Arteriarum*, &c., 1783–98; Barclay, *Description of the Arteries*, &c., 1818; Tiedemann, *Tabulæ Arteriarum*, &c., 1822; and to R. Quain's *Anatomy of the Arteries*, &c., with drawings by J. Maclise, 1840, 1841.]

that such is the intention of the curvatures described by the internal carotid and the vertebral arteries. Bichat, it is true, has objected to this, that, in a system of communicating and permanently distended canals, the curvature can have no influence upon the rapidity of the fluid circulating through them. But I would answer, that this principle, though true in reference to a system of inextensible tubes, is not so when applied to a system of dilatable canals like the arteries. In the latter case, in fact, part of the momentum acts against the curvature itself, and straightens it in a certain degree, and in this way there is a loss of some portion of the original momentum.

In some arteries this tortuous condition is acquired, in others it results from the progress of age. It proceeds from elongation of the arteries, which is itself produced in the following manner: At each ventricular systole, the arteries tend to become elongated as well as dilated. In the aged, and especially in those whose heart is very powerful, this tendency to become elongated produces an actual and permanent elongation, as may be seen in the abdominal aorta and in the common iliac, the humeral, and the radial arteries, which, in almost all old subjects, present alternate curvatures, that are never met with in the infant and the adult. It has been incorrectly stated, that at each systole of the heart the curves were diminished, or manifested a tendency to be diminished: on the contrary, the curves increase. This increase of curve is evidently perceived in observing the temporal artery during the systole of the ventricles. If an artery is injected, its branches, at each stroke of the piston, become more flexuous. If the arteries were straightened, the dilatations and the calcareous deposites would not be constantly observed on the side of the convexity of the curves.

Let us remark, that the dilatation of the arteries is, just as much as their elongation, a cause of the increase of their flexuosity.

The flexuosities of the arteries are of a twofold order, *zigzag* and *spiral*. The former are more frequent; the latter are especially noticed in the ovarian or testicular, uterine, and sometimes facial arteries.

We may also consider as acquired the tortuous condition assumed by collateral arterial branches, after the obliteration of the main trunk.*

Anastomoses of the Arteries.

During their course, the arteries communicate with each other by certain branches, which sometimes unite two different trunks, and sometimes form a connexion between two parts of the same trunk. This mode of communication is called *anastomosis* (ἀνὰ, by, and στόμα, a mouth). There are several kinds of anastomoses.

Anastomosis by inosculation, or by loops, in which two vessels running in opposite directions open into each other by their extremities and form a loop.

Anastomosis by transverse communication, as when two parallel trunks are united by means of a branch at right angles to their own direction: for example, the anterior communicating artery of the brain.

Anastomosis by convergence, in which two arterial branches unite at an acute angle to form a larger artery, as in the union of the vertebral arteries to form the basilar trunk.

By means of the anastomosis by inosculation or by loops, which is the most common method of communication, uninterrupted collateral channels are established along the great arterial trunks, the place of which they may even supply. The existence of these anastomoses, and the power possessed by arteries of becoming enlarged to an almost indefinite extent, originated the bold idea of attempting to tie even the largest arterial trunks.

Anastomoses by inosculation are sometimes useful in regulating the distribution of blood,† and spreading out the origins of arteries over a more extended space. Thus, by means of several series of arches, the superior mesenteric artery gives off branches which proceed at right angles to the small intestine throughout its whole length.

Forms and Relations.

The arteries represent regular cylinders when they give off no branch, and cones, or, rather, a series of decreasing cylinders, when they gradually diminish by giving off a certain number of branches. Their cylindrical form, together with the looseness of the surrounding cellular tissue, preserves them from a number of accidents. Thus, the humeral and the femoral arteries glide over the head of the humerus and femur in dislocations of these bones; and so the carotid arteries, contrary to all apparent probability, sometimes escape uninjured in incised wounds of the neck.

The arteries have relations with many other parts. *With the bones*, being supported by them, and more or less closely approximated to them. Thus, the aorta is applied to the vertebral column, and the arteries of the limbs, after escaping from the trunk, become

* There are flexuosities originating in malformation, by deviation or by fracture. In a case of fracture of the neck of the femur, the femoral artery described very marked inflections at the hip. This was also the case in a luxation of the femur with considerable shortening. The aorta becomes very flexuous in cases of hunchbacks.

† [The retia mirabilia of arterial vessels, found in some animals, are examples of the repeated subdivision and anastomosis of arteries.]

applied to the corresponding bones, their course along which is marked by a depression, and against which they may easily be compressed (see OSTEOLOGY).

From the relations of the arteries with the articulations, some important practical inferences are derived. The arteries always occupy the aspect of flexion; and as flexion is performed in the larger articulations of a limb alternately in opposite directions, the arteries are observed to alter their relative position, as it were, to regain the aspect of flexion. This is seen in the femoral artery as it becomes popliteal, and also in the brachial, which at first lies in the cavity of the axilla, and then turns forward at the bend of the elbow. In consequence of this arrangement, the arteries are protected by the habitual, and, as it were, instinctive, position of the limbs.

On the other hand, the proximity of certain arteries to articulations, and the absence of any curvatures in such situations, may explain the occurrence of rupture of these vessels in dislocation, and often, also, in immoderate attempts at reduction.

With the Muscles.—The muscles are the essential protectors of the arteries, which they separate from the skin. There are large cellular spaces in the centre of the limbs for the reception of the principal arteries, which are thus removed from the influence of external violence.

Most arteries have a special muscle, which may be termed their *satellite* muscle. Thus, the sartorius is the satellite muscle of the femoral artery; the sterno-cleido-mastoideus of the common carotid; the biceps of the brachial artery, &c.

With the Skin.—Some arteries are sub-cutaneous, or, rather, sub-aponeurotic, in a certain part of their extent; and in large arteries, this is almost always at the point where they emerge from the trunk, as in the femoral artery. The arteries of the cranium are situated between the skin and the epicranial aponeurosis in the whole of their extent. The importance of these relations in reference to compression of the vessels may be easily conceived.

With the Veins.—The arteries are always in relation with certain veins, which are applied to them. When there are two satellite veins (*venæ comites*) for one artery, the latter vessel is constantly placed between the two veins.

With the Nerves.—The arteries support the plexuses of nerves distributed to the organs of nutritive life. We may even regard their plexuses as forming an accessory coat to this set of vessels. Other nerves, though not so immediately in contact with the arteries, have a constant relation with them. This it is of importance to know, so that the nerves may be avoided, or that they may direct the operator in applying a ligature to the vessels themselves. For each artery it may be said there is one satellite nerve.

With the Aponeurotic Sheaths.—The principal artery of a limb is provided with a fibrous sheath, which belongs to it in common with its veins, and often with its accompanying nerve. When an artery perforates a muscle, it is protected in its passage by a sheath or aponeurotic arch, which prevents, or at least moderates, the compression during the contraction of the muscle.

Lastly, the arteries are surrounded by a loose cellular sheath, which allows of their dilatation and their alterations in position. The looseness of this cellular tisssue favours the displacement of arteries during the infliction of wounds, and enables us to isolate these vessels by blunt instruments, which cannot injure them.* As the nutritious vessels reach the coat of the arteries through this sheath, we can easily understand the impropriety of separating the vessel from it too extensively in tying the arteries.†

Termination of the Arteries.

The divisions of the arteries are not so numerous as would at first sight appear. The number of successive divisions, commencing at the aorta, is not more than twenty.

The arteries terminate in the substance of organs. The number of arteries distributed to each organ is in proportion to the activity of its functions; secreting organs are much more plentifully supplied with vessels than those in which the function of nutrition only is performed. Sœmmering, Prochaska, and others, have observed that the actual termination of the arteries is different in different organs. Referring for farther details upon this subject to textural anatomy, I shall content myself with stating here, 1st, that the arteries terminate in the capillary system, through the medium of which they become continuous with the veins, as is demonstrated even by the coarsest injections; 2d, that the arteries enter only in a very slight degree into the composition of the capillary system, which is essentially venous; this may be ascertained by injecting the arteries of an organ, the venous capillary system of the same having been previously injected by the veins; it will then be perceived that the arteries enter but very little into the formation of the capillary system, and that they cease to exist as soon as they have communicated with it. If it were objected that, through this preparation, the injected liquid might have passed over from the venous capillary system into

* [Another important result of this is, that a divided artery is enabled to retract within its sheath. In the abdomen and head this sheath scarcely exists.]

† I have seen a ligature of the primitive carotid which had been laid bare to too great an extent followed by a consecutive hemorrhage and death.

the arterial, I would remark, that the impossibility of this reflux is one of the most clearly demonstrated facts in anatomy.

Structure of Arteries.

The walls of an artery are composed of three coats : an external, a middle, and an internal.*

The External Coat.—This is generally called the *cellular coat*, because it is in some measure continuous with the surrounding cellular tissue. Scarpa erroneously regarded it as not forming an integrant part of the arteries. It consists of a filamentous, areolar, and, as it were, felted tissue, which is never charged with fat or infiltrated with serum, and which appears to me to present all the characters of the dartoid tissue. I believe that the contractility which has been attributed to the middle coat is altogether dependant upon this.† It is the only coat which remains undivided after the application of a ligature.

The Proper or Middle Coat.—The characteristic properties of arteries are chiefly dependant upon this coat. It is composed of circular fibres, which interlace at very acute angles, but which do not present the spiral arrangement admitted by some authors. From its yellow colour and its elasticity, it has been called the *yellow* or *elastic coat*. It is extensible longitudinally and transversely. It is very fragile, is easily torn by longitudinal extension, and is cut by a ligature. It is proportionally thinner in the great than in the small arteries. This coat is of the same nature as the yellow elastic ligaments, and is therefore not muscular. Moreover, chemical analysis shows that it contains no fibrine ; direct irritation develops no contractility in it ; and the supposed phenomena of irritability pointed out by Haller may be entirely attributed to elasticity. It should be remarked that the middle coat may be separated in several distinct layers, which are, however, not independent of each other ; while the most external layers present a strongly-marked fibrous linear disposition, the most internal exhibit an equally marked lamellar one ; indeed, to such extent, that authors have considered as a dependance of the internal coat the layer of yellow tissue which is in contact with the internal membrane, properly so called.

The Internal Coat.—It is a transparent pellicle of extreme tenuity ; it must be carefully distinguished from the subjacent layer, which is almost always dissected off with it. It is of a pale pink colour, and is lubricated with serosity. It appears to be of the nature of serous membranes, of which it presents the chief characteristics, viz., tenuity and non-vascularity.‡ It may even be said that, like the serous membranes, it is exclusively formed by a lymphatic net. I do not think that this internal coat of the arteries, which may have been considered as a sort of inorganic glue, is extensible or elastic ; on the contrary, in arteries in a non-distended state, this coat exhibits the appearance of folds which disappear by distension.

Vessels and Nerves.—The arteries and veins distributed to the coats of the arteries are called *vasa vasorum*. In regard to the question whether the arteries receive any nerves, or whether the nervous plexuses which accompany them are only intended for the organ to which the vessels are distributed, I would observe, that it has appeared to me that several filaments of the great sympathetic nerve were lost in the thickness of the aorta, and it is probable that the same disposition exists in regard to the less considerable arteries. As to the vasa vasorum, some believe they arise from the neighbouring vessels, while others are of opinion that they are derived from the vessels themselves to which they belong. I adopt the latter opinion, and believe that they mostly arise from the arteries to which they are attached. The venous vasa vasorum of the arterial coats join the nearest veins.

Preparation.

The preparation of an artery consists in separating it from the neighbouring parts, at the same time preserving its relations. Most of the arteries may be studied without any other preparation than a careful dissection ; but injections are necessary in order to follow the smaller branches. The most convenient injection with which I am acquainted is the following :◊ Tallow, nine parts ; Venice turpentine, one part ; ivory black, mixed with spirits of turpentine or varnish, two parts.

* All the vessels, and all the tubes of the body, are formed of different layers.

† All experimenters have observed that, in an animal which dies of hemorrhage, the arteries, during the last moments of its life, lose a considerable part of their caliber, which is restored to them immediately after death. This phenomenon, which appears at first sight to be in opposition to the absence of the contractility, properly so called, of the middle coat, may be easily accounted for by the tonic contractility of the dartoid tissue. The presence of this tissue may also account for the smallness or the contraction of the pulse, in opposition with its fulness, a double character which is sometimes met in the same individual, and in the same diseases, at short intervals.

‡ [It consists of longitudinal fibres, which are slightly interlaced, and are covered with a squamous epithelium. The longitudinal wrinkles observed in arteries contracted after death are produced in this coat.]

◊ [The paint or cold injection is one of the most useful ; it consists of either red or white lead, mixed as a paint, with a small quantity of boiled linseed oil, with spirits of turpentine, and also with some driers, viz., sugar of lead and litharge.]

The best injection for preparations intended to be preserved is wax, one part; tallow, three parts; vermilion, indigo, or Prussian blue, first mixed with spirits of turpentine.

It is advantageous, before making the general injection, to throw in some turpentine or spirit varnish, coloured with the substances mentioned above.

For a very fine injection it is necessary to use glue-size, coloured either with lamp-black or vermilion; but this mode of injection is not suitable where the preparation is to be preserved.

In order to place a tube in the aorta, saw through the sternum longitudinally; keep the two halves apart by means of a small piece of wood; open the pericardium; be careful not to mistake the pulmonary artery for the aorta; raise up the aorta by a ligature; make an incision in it anteriorly, and introduce the pipe. Injections of the whole body may also be made by introducing the tube into a large artery, such as the primitive carotid; this mode of injection permits of injecting the heart and the cardiac arteries, and of avoiding the mutilation of the arch of the aorta. The partial injections in a whole subject are preferable to the general injections, especially when such substances as tallow are used, which are easily solidified. Of course, an indispensable condition for the success of these partial injections is the previous isolation of the arterial system that you wish to prepare. This isolation is effected by ligatures which are put upon the large arteries communicating with the small arteries that are to be injected.

In injecting the coronary arteries, the pipe must be introduced into one of the carotids.

DESCRIPTION OF THE ARTERIES.

THE PULMONARY ARTERY.

Preparation.—Description.—Relations.—Size.—Development.

Preparation.—In order to inject the pulmonary artery, the injecting pipe must be introduced into one of the venæ cavæ.

The *pulmonary artery*, called *vena arteriosa* by the older writers, because having all the external characters of an artery; it nevertheless contains black blood, extends from the right ventricle to the two lungs. It arises (*k*, *fig.* 191) from the infundibuliform prolongation of the right ventricle, and then passes upward and to the left side, crossing in front of the aorta, which is embraced by its concavity; having reached the left side of this artery, after a course of about fourteen or fifteen lines, it divides into two trunks (*k k*, *fig.* 192), which proceed transversely, one to the right, the other to the left lung (*k k*, *fig.* 171), where they terminate by dividing into branches. From the point of division into the right and left branches* a fibrous cord, the remains of the ductus arteriosus, proceeds in the original direction of the artery, and is attached to the concavity of the arch of the aorta opposite the left subclavian artery.

At its origin the pulmonary artery is covered externally by the highest fibres of the infundibulum; internally it is provided with three sigmoid movable valves (*a a a*, *fig.* 196), which, when depressed, completely close the mouth of the vessel. By careful dissection, it is found that the pulmonary artery is cut at its origin into three festoons, corresponding to the sigmoid valves, and that it is connected to the tissue of the heart by its internal coat, which is contiguous with the lining membrane of the right cavities of the heart; and also by prolongations given off from the fibrous zone, and attached to the convex borders of the three festoons, and to the angular intervals between them.

Relations.—In front and on the left side the pulmonary artery is convex, and covered by the serous layer of the pericardium, which is often separated from it by some fat; behind and on the right side it is concave, and is in relation with the aorta, which it embraces. The right and left auricles are in contact with its corresponding sides.

Size.—The left branch of the pulmonary artery is about one inch in length; it is in relation behind with the left bronchus, one of the bronchial arteries often passing between them; it is in direct relation with the aorta. In front, it is covered by the serous layer of the pericardium, excepting near the lungs, where the pulmonary veins are placed in front of the arterial branches.

The right division of the pulmonary artery is from sixteen to eighteen lines in length; it is in relation in front with the vena cava superior, and with the ascending portion of the aorta, but not immediately, for the serous layer of the pericardium covers both the aorta and the corresponding part of the pulmonary artery. Behind, it is in relation with the right bronchus, and passes above the right auricle.

Development.—In the fœtus, instead of the fibrous cord, which we have described as proceeding from the point at which the pulmonary artery divides into its two branches,† there is a canal called the *ductus arteriosus*, almost equal in diameter to the pulmonary

* See note, *infrà*.

† [It was noticed by Haller and Senac, that the ductus arteriosus in the fœtus, and the cord to which it is reduced after birth, arise, not from the angle of division into the right and left pulmonary arteries, but from the left pulmonary artery itself: this is an interesting and important fact in reference to the development of the great vessels issuing from the heart.]

artery itself, the course of which vessel it pursues; at this time the right and left branches of the pulmonary artery are very small. At birth the whole of the venous blood proceeds to the lungs, none of it passing through the ductus arteriosus, which then becomes obliterated.

THE AORTA.

Preparation.—Definition.—Situation.—Direction.—Size.—Division into the Arch of the Aorta, the Thoracic Aorta, and the Abdominal Aorta.

Preparation.—The aorta may be studied without having been injected.* In order to study it in an injected subject, the median incision made for the purpose of introducing the injection must be prolonged down to the pubes. Then disarticulate the clavicles, separate the two sides of the thorax, even so far as to break some of the ribs, and keep them separate by introducing a piece of wood; cut through the abdominal parietes, and turn the left lung over to the right side.

The *aorto* (*ἀορτὴ, arteria magna, arteriarum omnium mater, a b c d, fig.* 198), the common origin of all the arteries of the human body, commences at the left ventricle, and terminates by bifurcating (at *d*) opposite the fourth lumbar vertebra.

Situation.—It is situated deeply in the thoracic and abdominal cavities, along the vertebral column, which affords it both support and protection. In those animals in which the aorta is prolonged beyond the trunk, the vertebral column accompanies the vessel, and forms a bony canal or sheath for it, distinct from the canal for the spinal cord.

Direction.—Immediately after its origin, the aorta advances towards the right side (*a, fig.* 198), and almost directly afterward proceeds upward, describing a slight curve, the convexity of which is turned forward and to the right, and the concavity backward and to the left.

Fig. 198.

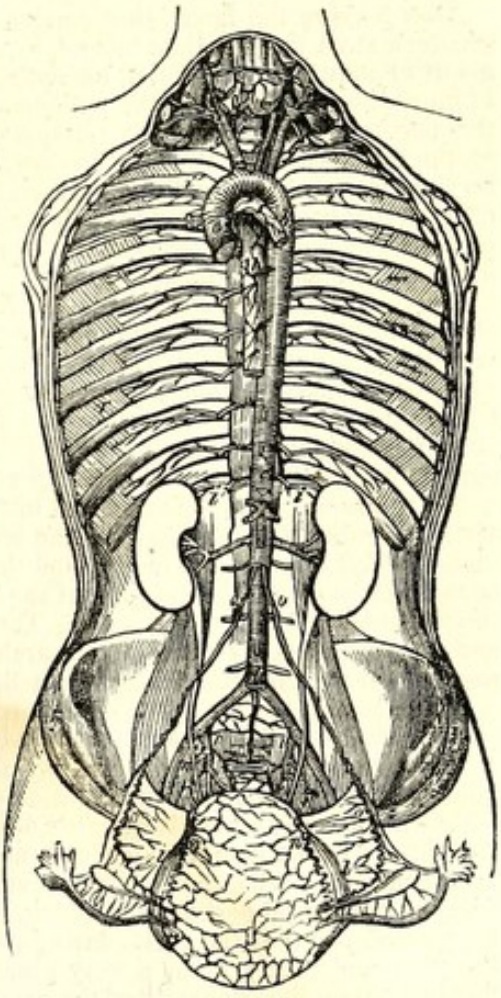

After leaving the pericardium, it changes its direction, becomes suddenly curved, and passes almost horizontally from the right to the left, and from before backward, to reach the left side of the vertebral column, on a level with the third dorsal vertebra, at which point (*b*) it makes a third curve, and becomes vertical and descending. Having reached the diaphragm (at *c*), it inclines a little to the right side, in order to gain the median line, and to pass through the ring, or, rather, the canal, formed for it by the pillars of the diaphragm. From this point to its termination, it rests upon the middle of the anterior surface of the vertebral column.

Varieties in its Direction.—It is not a very rare occurrence to find the aorta curving over to the right instead of the left side—a disposition which may either be accompanied with a complete transposition of the thoracic and abdominal viscera, or may be independent of it.

Size.—The several portions of the aorta have not a uniform caliber;† but its gradual decrease, in this respect, bears no direct proportion to the number and size of the branches given off from it.

At its origin it always presents three ampullæ, which correspond to the sigmoid valves; they are called the *sinuses of the aorta*, or *sinuses of Valsalva*. They exist originally, and must, therefore, be distinguished from a dilatation found on the convex side of the arch of the aorta in old subjects, and called the *great sinus of the aorta*. This dilatation results entirely from the impulse of the current of the blood.

The caliber of the aorta, moreover, differs exceedingly in different subjects, even when there is no appreciable organic lesion:‡ it should be remarked, however, that the thickness of its coats is not at all in proportion with its caliber.

* It will be advantageous to study the aorta in the same subject in which the viscera have already been examined.

† Thus, the caliber of the commencement of the aorta, compared with that of its termination, is generally as five to three; hence the diminution is not by any means proportionate to the number of branches arising from it, for the united calibers of its collateral branches would much exceed that of the main vessels.

‡ Thus, I have seen a case in which the aorta was 4 inches 8 lines in circumference opposite the arch, and 2 inches 6 lines at its lower end: the latter is the usual size of the vessel.

The aorta is generally divided into three portions, viz., the *arch* of the aorta, the *thoracic aorta*, and the *abdominal aorta*. The two latter portions form together the *aorta descendens*.

The Arch of the Aorta.

I shall give this name to all that part of the aorta (*a b*, *fig.* 198) which is comprised between its origin from the left ventricle and the point where it is crossed by the left bronchus.*

The direction of the arch of the aorta is neither transverse nor antero-posterior, but oblique from the right to the left side, and from before backward; so that it is anterior, median, and substernal in its first portion, and posterior at its termination, and in relation with the left side of the vertebral column. In consequence of these relations, aneurisms of the anterior part of the arch of the aorta frequently affect the sternum, while aneurisms of the posterior portion affect the vertebral column.

Relations.—We shall examine the relations of the arch of the aorta, first in its pericardiac or ascending portion, and then in its horizontal and descending portions taken together.

The Pericardiac Portion (*f*, *fig.* 191).—Concealed, as it were, in the substance of the heart at its origin, it is in relation in front with the infundibulum of the right ventricle, and behind with the concavity of the auricles, which are moulded upon it. On the right, it rests upon the groove between the infundibulum and the right auriculo-ventricular orifice; on the left, it is in relation with the pulmonary artery. It is important to note the practical consequences of these relations. I have recently seen a communication between the aorta and the infundibulum. Again, aneurisms of the origin of the aorta may burst into the auricles.

After leaving the heart, this portion of the aorta is surrounded on all sides, but to a greater extent in front than behind, by the serous layer of the pericardium, which forms a sort of additional coat for it, excepting in front, below, and on the left side, where it is in immediate contact with the pulmonary artery, as that vessel turns round it. Behind, this portion of the aorta is in relation with the right division of the pulmonary artery; on the right, with the vena cava superior. It follows, therefore, that the pulmonary artery on the one hand, and the aorta on the other, form two half-rings, like the branches of the letter *x*, which embrace each other by their concavities. The pericardiac portion of the aorta is situated beneath the sternum, from which it is separated by the pericardium and the anterior mediastinum

The Second Portion, comprising the Horizontal and Descending Portions of the Arch.—On the outside of the pericardium, the aorta is in relation, *in front and on the left side*, with the left pleura, and is separated by it from the corresponding lung, which is excavated at that point. The phrenic and pneumogastric nerves are also in immediate contact with it. *Behind, and on the right side* (*f*, *fig.* 171), it is in direct relation with the trachea, the commencement of the left bronchus, the œsophagus, the thoracic duct, the recurrent nerve, the vertebral column,† and a great number of lymphatic glands.

By its convexity, which is directed upward, it gives origin to three large arterial trunks, viz., proceeding from the right to the left side, the *brachio-cephalic* (*e*, *fig.* 198) or *innominate*, the *left common carotid* (*f*), and the *left subclavian* (*g*) arteries. The highest point of the arch is opposite the origin of the brachio-cephalic artery in the infant, and that of the left subclavian in old subjects. The distance between the fourchette of the sternum and the highest point of the aortic arch varies in different ages and individuals: it is generally from ten to twelve lines in the adult; it is much less in the aged and in the newborn infant, but for very different reasons; in the infant it is owing to the undeveloped condition of the sternum, but in advanced age it depends upon dilatation of the arch of the aorta; in some adults, also, we find the distance very inconsiderable, and this is important in reference to the operation of tracheotomy.

By its *concavity*, which is directed downward, the arch of the aorta is in relation with the left recurrent nerve, which embraces it, as it were, in a loop, having its concavity turned upward; with the left bronchus (*p*, *fig.* 171; also, *fig.* 198), which is placed behind the horizontal portion of the arch, and then becomes situated in front of its descending portions, so that the aorta, during its curvature, has two different relations with this air-tube; and, lastly, with a very great number of lymphatic glands, which in some measure fill up the concavity of the aortic arch.

Anomalies of the Arch of the Aorta.—A very remarkable anomaly of the arch of the aorta has been observed, in which the vessel, being simple at its origin, divides into two trunks, which pass, one in front and the other behind the trachea, and then reunite to form the descending aorta. The aorta sometimes presents traces of a subdivision into

* The limits of the arch of the aorta are not well defined; most authors exclude the first curve of the artery. The lower boundary is marked by the origin of the left subclavian, according to some; by the left bronchus, according to others; and, lastly, according to a great many, by the articulation of the fourth with the fifth dorsal vertebra.

† I have, I believe, satisfactorily demonstrated, in another part of this work, that the left lateral concavity of the vertebral column was owing to the presence of the arch of the aorta

two from its origin; such a case appears to indicate a fusion of two aortæ into one, for we then find five sigmoid valves.

The Thoracic Aorta.

The *thoracic aorta* (*b c, fig.* 198) is situated in the posterior mediastinum, along the left side of the vertebral column, and it projects into, and encroaches upon, the left cavity of the chest.

Relations.—It corresponds, on the *left side*, with the lung, from which it is separated by the left wall of the posterior mediastinum; *on the right*, it is in relation with the œsophagus, the vena azygos, and the thoracic duct; *in front*, with the left pulmonary arteries and veins above; with the œsophagus (*h*) below, which canal becomes anterior to it before passing through the œsophageal opening in the diaphragm, and with the pericardium in the middle, by which it is separated from the posterior surface of the heart; *behind*, it is in relation with the vertebral column, the thoracic duct passing between them above.

The thoracic aorta is surrounded by an abundance of cellular tissue, and by a number of lymphatic glands.

Diaphragmatic Portion of the Thoracic Aorta.—The diaphragm does not form a simple orifice or an aponeurotic arch for the aorta, but its crura (*s s, fig.* 199) are arranged into a muscular semi-canal, from fifteen to eighteen lines in length, and terminating below by a tendinous arch. The aorta is accompanied, while passing through this canal, by the thoracic duct* and the vena azygos, and it inclines a little to the right side, in order to become anterior to the vertebral column.

The Abdominal Aorta.

The *abdominal aorta* (*c d, fig.* 198) occupies the middle part of the anterior surface of the vertebral column, and is in relation on the *right side* with the vena cava inferior, and *in front* with the pancreas and the third portion of the duodenum, which rests immediately upon it; in the rest of its extent it corresponds with the adherent borders of the mesentery, and with the peritoneum covering the lumbar region of the vertebral column. The stomach and the convolutions of the small intestine separate the aorta from the anterior parietes of the abdomen. When the small intestine falls down into the pelvis, the abdominal aorta may be felt immediately behind the wall of the abdomen, and may be easily compressed there, so as completely to intercept the passage of the blood.†

BRANCHES FURNISHED BY THE AORTA IN ITS COURSE.

Enumeration and Classification.—Arteries arising from the Aorta at its Origin, viz., the Coronary or Cardiac. — Arteries arising from the Thoracic Aorta, viz., the Bronchial, the Œsophageal, the Intercostal.—Arteries arising from the Abdominal Aorta, viz., the Lumbar, the Inferior Phrenic, the Cœliac Axis, including the Coronary of the Stomach, the Hepatic and the Splenic, the Superior Mesenteric, the Inferior Mesenteric, the Spermatic, the Renal, and the Supra-renal or Capsular.

The aorta is the common trunk of all the branches and twigs given off by the arterial tree. It alone furnishes, therefore, all the arteries of the human body. The branches which come from it I shall divide into terminal and collateral branches.

The terminal branches of the aorta consist of the middle sacral and the two common iliac arteries. The *collateral* branches are very numerous: they may be divided into those arising from the pericardiac portion of the aorta, viz., the coronary or cardiac arteries; those arising from the aortic arch, viz., the brachio-cephalic, the left common carotid, and the left subclavian: these we may consider as terminal arteries, which, taken together, have been termed the ascending aorta in opposition to the descending aorta; those arising from the thoracic aorta, which may be subdivided into the parietal branches, viz., the intercostals and the visceral, viz., the bronchial, œsophageal, and mediastinal arteries; and, lastly, those arising from the abdominal aorta, which may also be distinguished as the parietal, viz., the lumbar and inferior phrenic arteries, and the visceral, viz., the cœliac axis, the superior and inferior mesenteric, the supra-renal, the renal, and the spermatic arteries.

Arteries arising from the Aorta at its Origin.

The Coronary or Cardiac Arteries.

Dissection.—Take off the serous membrane from the heart, and also the fat which oc-

* It is a mistake to say that the right azygos vein passes through the same opening as the thoracic duct. The azygos vein traverses the opening which is destined to the passage of the great splanchnic branch of the sympathetic nerve.

† This compression is very easily applied in women immediately after parturition, both in consequence of the relaxed state of the abdominal parietes allowing them to be readily depressed, and also from the facility with which the small intestines are moved aside.

cupies the furrows; in order to see distinctly the origin of these arteries, remove the pulmonary artery and the infundibulum of the right ventricle.

The *cardiac* or *coronary arteries* (see *figs.* 191, 192), the nutritious vessels of the heart, or, as it were, its *vasa vasorum*, are two in number, and are named *right* and *left* on account of their origin, and also anterior and posterior from their distribution. Their number is not constant. Thus the two coronary arteries sometimes arise by a common trunk, to the left of the pulmonary artery.* Sometimes there are three coronary arteries; Meckel has seen four; but these varieties in number do not affect their distribution, for the supernumerary arteries merely represent branches, which, instead of arising from the coronary arteries themselves, proceed directly from the aorta. I have recently seen the right coronary artery arise from the aorta by three branches in juxtaposition, one of which was of considerable size: the others were small.

Origin.—They arise from the anterior part of the circumference of the aorta, immediately above the free margin of the sigmoid valves, at the highest points of the two corresponding sinuses. The origins of these vessels are so situated, that their orifices are not covered by the valves when these latter are applied to the walls of the aorta, so that the heart receives its arterial blood at the same time as all the other organs. The angle at which the coronary arteries arise is extremely obtuse, so that the course of the blood in them is completely retrograde.

The coronary arteries differ from each other in caliber, the right being larger than the left, and also in their course, so that a special description is requisite for each.

The *left* or *anterior coronary artery* is destined principally for the anterior furrow of the heart; it is concealed, at its origin, by the infundibulum, from between which and the left auricula it then escapes, and entering (*e*, *fig.* 191) the anterior furrow of the heart, traverses it in a very tortuous manner, and anastomoses, at the apex, with the right or posterior coronary artery. Not unfrequently this artery divides into two branches, one of which runs along the anterior furrow, while the other passes upon the anterior surface of the left ventricle. In this course, opposite the base of the ventricles, the artery gives off an auriculo-ventricular branch, which, arising at a right angle, enters the left auriculo-ventricular furrow, and, passing along it, turns round the base of the left ventricle, as far as the posterior inter-ventricular furrow (*e*, *fig.* 192), where it anastomoses with the right coronary artery.

The *right* or *posterior coronary artery* is larger than the left; it arises to the right of the infundibulum, between that part and the right auricle. Immediately after its origin it is surrounded with a large quantity of fat, and turns directly, so as to gain the right auriculo-ventricular furrow. At the upper end of the posterior inter-ventricular furrow (*e*, *fig.* 192) it bends at a right angle, and entering the furrow, runs along it to the apex of the heart, where it anastomoses with the left coronary artery. At the point where it changes its direction, the right coronary artery gives off a branch, which anastomoses with the auriculo-ventricular branch of the left artery.

From this description, it follows that the cardiac arteries and their principal divisions occupy the furrows of the heart; that they form two vascular circles, which are placed at right angles to each other like the furrows themselves; that the auriculo-ventricular circle is formed on the right by the trunk of the right cardiac, and on the left by a branch of the left cardiac artery; that the vessels forming these two circles are tortuous, but especially those on the ventricles, because that part of the heart is subject to greater variations in its dimensions than the part with which the auriculo-ventricular circle is in relation; and, lastly, that both coronary arteries anastomose by inosculation, and therefore can easily supply each other.

All the arteries of the heart proceed from these two circles. The *auriculo-ventricular circle* gives off some ascending or *auricular* branches, an aortico-pulmonary branch to the origins of the aorta and pulmonary artery, and an adipose branch, all of which were pointed out by Vieussens; also some descending or ventricular branches, the two principal of which run somewhat obliquely along the right and left borders of the heart.

The *ventricular circle* gives off branches which penetrate the fleshy fibres at right angles. A large artery, which has been described as the *artery of the septum*, appears to be one of the terminal branches of the left coronary artery; it dips into and is lost in the substance of the septum.

Lastly, the coronary arteries communicate with the bronchial. They are very liable to calcareous deposites.†

Arteries arising from the Thoracic Aorta.

These may be divided into visceral branches, all of which arise from the front of the

* The coronary arteries were denominated by the older anatomists, and especially by Bartholin, *coronariæ modo simplex, modo gemina*. Meckel, Harrison, and others have described cases in which there was but one coronary artery. According to the descriptions of writers on comparative anatomy, that disposition is natural with the elephant.

† It is not uncommon from such deposites to find cardiac arteries which are extremely narrowed, and even obliterated. Several pathologists have considered this ossification of the cardiac arteries as the cause of those phenomena which are designated by the name of *angina vectoris*; but this opinion is a mere hypothesis.

aorta, viz., the *bronchial* and the *œsophageal*, and parietal branches, which arise from the back of the aorta, viz., the *aortic intercostals*.

The Bronchial Arteries.

Dissection.—Carefully take away the heart and pericardium, dissect the bronchi, and trace these arteries both to their origin and towards their termination.

Number and Origin.—The bronchial arteries (see *fig.* 198) vary much both in number and origin. There are generally two on each side; but sometimes there are three, or even four, arising either at different heights or by a common trunk. Occasionally, one of them arises from the subclavian, or from the internal mammary, or, rather, from the first intercostal, or, lastly, from the second, or even the third intercostal artery.

I have seen the inferior thyroid artery give off a bronchial artery, which, after running along the trachea, passed in front of the right bronchus, and anastomosed freely with the right bronchial furnished by the aorta. The right bronchial artery is always larger than the left.

Whatever be their origin, the bronchial arteries pursue a tortuous course to the corresponding bronchus, and are usually situated on its posterior surface. When the right bronchial artery arises from the aorta, it crosses obliquely over the lower part of the trachea. The bronchial arteries always give some branches to the œsophagus; a very great number to the bronchial glands; also several to the left auricle: they anastomose with the coronary arteries on the one hand, and with the inferior thyroid and the superior intercostal arteries on the other.

Haller believes that the terminations of the bronchial arteries anastomose with the divisions of the pulmonary artery, and says that he has seen free and evident communications between them.*

The Œsophageal Arteries.

The *œsophageal arteries* (*h*, *fig.* 198) vary in number from three to seven, and are remarkable for their slenderness and length. They arise in succession from the front of the aorta, which they leave at right angles, and immediately curve downward to reach the front of the œsophagus, where they divide into extremely slender ascending, and into very long descending branches, from which are given off a numerous series of twigs. The superior œsophageal artery almost always anastomoses with the bronchial arteries, and the œsophageal branches of the inferior thyroid. The inferior œsophageal artery anastomoses with the œsophageal branches derived from the left inferior phrenic, and from the coronary artery of the stomach.

The branches from the œsophageal arteries perforate the muscular coat of the œsophagus, ramify in the sub-mucous cellular tissue, and terminate in a network in the substance of the mucous membrane.

The Aortic Intercostal Arteries.

Dissection.—In order to see the posterior branches, dissect the posterior spinal muscles, and open the vertebral canal. To see the anterior branches or the intercostals, properly so called, expose these vessels on the inside of the parietes of the chest in the first half of their course, and then on the outside of the chest to their termination.

The *aortic* or *inferior intercostals* (*i i' i'*, *fig.* 198), so named to distinguish them from the superior intercostal, a branch of the subclavian, and from the anterior intercostals, derived from the internal mammary, are generally eight or nine in number, the upper two or three intercostal spaces being supplied by the superior intercostal branch of the subclavian.

The varieties in their number depend upon the number of intercostal spaces which are supplied with branches from the subclavian, and also upon the number of intercostal arteries which arise by a common trunk.

Origin.—They arise at various angles from the back of the aorta; the superior generally at an obtuse angle to gain the spaces situated above them; the succeeding ones at different angles, which are less and less obtuse, and sometimes right angles, or even acute angles. In the latter case, the vessel immediately ascends to reach the intercostal space for which it is intended. The right and left intercostals are of equal size, and there is little difference in this respect between the superior and the inferior intercostals.

In consequence of the aorta being situated towards the left side, the right intercostals (*i' i'*) are longer than the left. They turn over the body of each dorsal vertebra, passing behind the œsophagus, the thoracic duct, and the vena azygos, and reach the corresponding intercostal space. The left intercostals enter their proper spaces at once. Both are in relation with the costal pleura and the thoracic ganglia of the great sympathetic nerve, behind which they are situated. The lower intercostals on the left side are covered by the vena azygos minor. The two lower intercostals on both sides are covered by the pillars of the diaphragm. In their course over the bodies of the vertebræ, the intercostals give off numerous nutritious branches, which enter the foramina on the anterior surface of these bones.

See note, p. 421.

On reaching the intercostal space, each artery immediately divides into an anterior and a posterior branch.

The *anterior* or *intercostal branches* are larger than the posterior, and may be regarded as the continuation of the arteries themselves in their original course. They are at first situated in the middle of the intercostal spaces, between the pleura and external intercostal muscles; they then pass between the external and the internal intercostals, reach the lower border of the rib above them, and are lodged in the grooves found in that situation; having reached the anterior third of the intercostal spaces, where they have become extremely small, they quit the grooves, and again become placed in the middle of the spaces; the superior intercostals then terminate by anastomosing with the intercostal branches of the internal mammary, and the inferior intercostals with the epigastric, the phrenic, the lumbar, and the circumflex iliac arteries

During its whole course, each intercostal branch is in relation with the corresponding intercostal vein and nerve. The inferior intercostal arteries, commencing at the fifth, after leaving the intercostal spaces, are lost in the external and internal oblique muscles of the abdomen, which, as we have seen, form, as it were, continuations of the intercostal muscles (see MYOLOGY).

The intercostal branch furnishes numerous ramusculi to the intercostal muscles, the ribs, the sub-pleural cellular tissue, the muscles which cover the thorax, and even to the integuments. A very small, but tolerably constant branch, is given off at an acute angle from the artery, at the moment where it dips between the two sets of intercostals, gains the upper border of the rib below, and is lost in the periosteum and the muscles, after running a variable distance.

The *posterior* or *dorsi-spinal branches* pass directly backward between the transverse processes of the vertebræ, on the inner side of the superior costo-transverse ligaments, and each of them immediately divides into two branches: one, the *spinal*, which enters the inter-vertebral foramen, and again divides into a *vertebral* branch for the bodies of the vertebræ, and a *medullary* branch for the coverings of the spinal cord, and for the cord itself, to the distribution of which we shall hereafter return. The second, or *dorsal* branch, is larger than the spinal, and forms a continuation of the dorso-spinal ttunk; it escapes behind between the transverso-spinalis and longissimus dorsi, sends some ramifications between the longissimus dorsi and sacro-lumbalis, and terminates in the muscles and the skin.

ARTERIES ARISING FROM THE ABDOMINAL AORTA.

The branches furnished by the abdominal aorta are parietal, viz., the *lumbar* and the *inferior phrenic* arteries; and the visceral branches, viz., the *cœliac axis*, the *superior* and *inferior mesenteric*, the *spermatic*, the *renal*, and the *middle supra-renal* arteries. In reference to their place of origin, these arteries may be divided into those which arise from the anterior aspect of the aorta, viz., the cœliac axis, the superior and inferior mesenteric. and the spermatic arteries; and those which arise from its sides, viz., the renal, the middle supra-renal, and the lumbar arteries. The lumbar arteries might be regarded as arising from the back of the aorta.

The Lumbar Arteries.

Fig. 199.

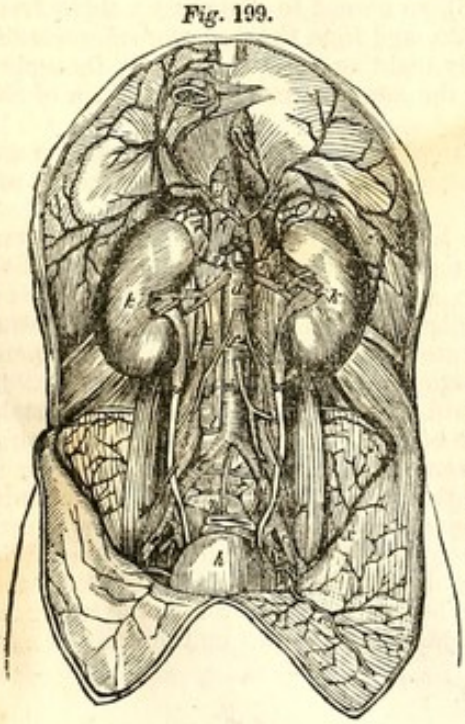

Dissection.—Remove the pillars of the diaphragm and the psoas muscles. In order to expose the dorsi-spinal branches, dissect the posterior spinal muscles, and open the vertebral canal. To expose the anterior branches, dissect the abdominal muscles carefully.

The *lumbar arteries* (*l l*, *fig.* 199) continue the series of intercostals, with which they present numerous analogies in reference to their origin, course, and termination. They vary in number from three to five, but there are usually four. These varieties depend either upon the greater or less size of the ilio-lumbar artery, which bears the same relation to the lumbar arteries as the superior intercostal does to the aortic intercostals, and which sometimes takes the place of the last, sometimes of the last two lumbar arteries; or the varieties may depend on several lumbar arteries arising from a common trunk.

Origin.—The lumbar arteries are given off at right angles from the back of the aorta. Very rarely the right lumbar arteries arise by a common trunk with the left.

Course. — They proceed transversely in the grooves on the bodies of the vertebræ, and pass

under the tendinous arches of the psoas, by which muscle they are covered. They send a great number of branches to the bodies of the vertebræ; and having reached the base of the transverse processes, each of them divides into two branches, a *posterior* or *dorsi-spinal*, and an *anterior* or *abdominal* branch.

The *posterior branch*, which is analogous to the dorsi-spinal of an intercostal artery, divides into two branches: one, the *spinal*, which enters the spinal canal through the inter-vertebral foramen, and subdivides into a *vertebral* branch for the body of the vertebra, and a *medullary* branch for the cord and its coverings; the other branch is the dorsal, which terminates in the muscles and integuments of the lumbar region.

The *anterior branch* is smaller, and analogous to the anterior branch of an intercostal artery: it is situated between the quadratus lumborum and the middle layer of the aponeurosis of the transversalis, and ramifies in the substance of the abdominal muscles. The anterior branch of the first lumbar artery runs along the lower border of the twelfth rib, passes obliquely downward and forward, and divides into two ramusculi, one of which continues in the same course, while the other turns downward to the crest of the ilium. The anterior branches of the second and third pair of lumbar arteries are generally small: not unfrequently the third artery is wanting. The anterior branch of the fourth lumbar artery runs along the crest of the ilium, and sends branches to the muscles of the abdomen and to the iliacus and glutæi muscles.

The Inferior Phrenic Arteries.

Dissection.—Carefully detach the peritoneum from the lower surface of the diaphragm.

The *inferior phrenic* or *diaphragmatic*, or the *sub-diaphragmatic arteries* (*d d*, *fig.* 199), so named in contradistinction to the superior phrenic, which are branches of the internal mammary, are so frequently derived from the cœliac axis, that some anatomists, Meckel among others, describe them as branches of that trunk. They are two in number, a *right* and a *left*. They arise from the aorta, immediately below the cordiform tendon of the diaphragm, either side by side, or by a common trunk. Sometimes they arise from the cœliac axis itself, or, rather, from the coronary artery of the stomach, from the renal, or from the first lumbar artery; in some subjects we find as many as three or four.

Each artery passes upward and outward in front of the corresponding pillar of the diaphragm, gives some twigs to this pillar, and one to the supra-renal capsule, and then divides into two branches, an *internal* and an *external*. The *internal* branch passes directly forward, ramifies and anastomoses by loops with the vessel of the opposite side around the œsophageal opening, behind the cordiform tendon of the diaphragm. The *external* branch is larger and more tortuous than the preceding; it proceeds obliquely outward, between the peritoneum and the diaphragm, and divides into a great number of branches, which extend as far as the attachments of this muscle, where they anastomose with the intercostal and the internal mammary arteries.

The right inferior phrenic artery, moreover, sends some branches into the coronary ligament of the liver; the left artery gives off a branch to the œsophagus, which enters through the œsophageal opening in the diaphragm, and joins the œsophageal branches derived from the coronary artery of the stomach and from the aorta.

The Cœliac Axis.

Dissection.—Elevate the liver by means of hooks, or by a ligature fixed to the right side of the chest; depress the stomach; divide the fold of peritoneum by which these two viscera are united; and search for the cœliac axis between the pillars of the diaphragm, by removing the solar plexus of nerves, which forms a thick layer in front of it.

The *cœliac axis* or *artery* (from κοιλία, the belly or stomach, *y*, *fig.* 199), le tronc opisthogastrique, *Chauss.* (ὄπισθεν, behind, γαστὴρ, the stomach), supplies the stomach, the liver, the spleen, the pancreas, and the great omentum. It is remarkable for its size, being larger than any of the other branches of the abdominal aorta, not excepting the superior mesenteric; for arising at a right angle from the front of the aorta, immediately below the phrenic arteries; for its horizontal course, which is rarely more than five or six lines in extent, and for its very early division into three branches, *ad modum tridentis*. These three branches are of unequal size: they are the *coronary artery of the stomach* (*b*, *fig.* 200), the *hepatic* (*c*), and the *splenic* (*d*), which, together, are called the *cœliac tripos*, or the *tripos of Haller*.

In its short course the cœliac axis is in relation with the lesser curvature of the stomach, or, rather, with the gastro-hepatic omentum, behind which it is situated; on the left side, it is in relation with the cardia; below, with the upper border of the pancreas, upon which it rests; above, with the left side of the lobulus Spigelii. It is surrounded by so large a plexus of nerves, that it cannot be exposed until the plexus is removed.

The Coronary Artery of the Stomach.

The *coronary artery of the stomach*, or the *superior gastric* (*b*, *figs.* 200, 201), is the smallest branch of the cœliac axis. It is directed upward and to the left side, to reach the œsophageal orifice of the stomach; it then turns suddenly to the right side, pursues a

Fig. 200.

semicircular course along the lesser curvature (*arteria coronaria ventriculi*), and terminates by inosculating with the pyloric artery (*e*), a branch from the hepatic.

In this course it gives off from its convex border *ascending œsophageal branches*, which pass through the œsophageal opening of the diaphragm, ascend upon the œsophagus, and are there distributed like the aortic œsophageal branches, with which they anastomose; also *cardiac branches*, which form a vascular network around the œsophageal opening of the stomach, and pass transversely upon its great tuberosity; and a series of *gastric branches*, which arise along the lesser curvature, and are divided into two sets, an anterior set for the front, and a posterior set for the back of the stomach. No branch arises from the concavity of the curve formed by this artery.

Not unfrequently the coronary artery of the stomach gives off an hepatic branch, and hence the first branch of the cœliac axis has been called the *gastro-hepatic* by some anatomists. In such cases, as may be conceived, this artery is very large. It is also not uncommon to find the left inferior phrenic arising from it.

The Hepatic Artery.

The *hepatic artery* (*c*, *figs.* 200, 201) is larger than the preceding. It passes transversely from the left to the right side, describing a curve, having its concavity directed upward, and moulded, as it were, upon the lobulus Spigelii. Near the pylorus it changes its direction, and passes upward to the transverse fissure of the liver, where it divides into two branches. In the latter part of its course it is contained within the gastro-hepatic omentum, in front of the foramen of Winslow, and is in relation with the ductus choledochus and the vena portæ, the vein being placed behind both the artery and duct.

It is not uncommon to find two hepatic arteries, one derived from the coronary of the stomach, and the other from the superior mesenteric. Sometimes there are even three hepatic arteries, one from the coronary of the stomach, a second from the superior mesenteric, and a third from the cœliac axis.

Collateral Branches.—The hepatic artery gives off three collateral branches, the *pyloric*, the *right gastro-epiploic*, and the *cystic*.

The *pyloric* artery, also named the small right gastric artery, to distinguish it from the coronary artery of the stomach, which was called the left gastric (*e*), is a small vessel which arises from the hepatic, near the pylorus: it runs from right to left along the pylorus and the lesser curvature of the stomach, and inosculates with the coronary artery (*b*) of that viscus. Two sets of branches, an anterior and a posterior, arise from its convex border, and are distributed to the stomach and the first part of the duodenum, in the same manner as those from the coronaria ventriculi itself. Not unfrequently the pyloric artery terminates near the pylorus, without anastomosing with the coronary.

The *right gastro-epiploic* artery (*f*, *figs.* 200, 201) is remarkable for its size and for its length. It passes vertically downward, behind the first portion of the duodenum, near the pylorus. Having reached below the duodenum, it changes its direction, passes from right to left (*l*) along the great curvature of the stomach, where it inosculates with the left gastro-epiploic (*h*, *fig.* 201). In one case, where the hepatic artery was given off by the superior mesenteric, the right gastro-epiploic arose directly from the cœliac axis.

The first portion of this vessel, usually called the *gastro-duodenal* artery, furnishes several branches to the pylorus, which may be called the *inferior pyloric*; it then gives a branch to the duodenum and the head of the pancreas, named the *pancreatico-duodenalis* (*k*), and remarkable for its anastomosing with the superior mesenteric; an arrangement that leads, as it were, to the cases in which the hepatic itself is derived from the last-mentioned artery; it is also remarkable for its size, which is sometimes such that the continuation of the vessel, the right gastro-epiploic artery proper, is only half the size of the trunk from which it is given off (the gastro-duodenal).

In its horizontal portion along the great curvature of the stomach, the right gastro-epiploic sends both ascending and descending branches: the former, or *gastric* branches, divide into two sets; one for the anterior, and one for the posterior surface of the stomach. The latter, or *epiploic* branches (*g g*, *fig.* 200), are extremely long and slender;

they pass downward parallel to each other, without any windings, in the substance of the two anterior layers of the great omentum, are reflected upward at its lower border, just as the two layers are themselves, and accompany them as far as the transverse colon, to which they are distributed.

The *cystic* artery (*i*, *fig.* 200) is a small vessel which almost always arises from the right of the terminal divisions of the hepatic artery, reaches the neck of the gall-bladder, and divides into two branches; one superior, running between the liver and the vesicula, the other inferior, which pursues a tortuous course between the peritoneum and the proper coat of the gall-bladder, divides and subdivides, and is finally distributed to the mucous membrane.

Terminal Branches.—Of the two terminal branches of the hepatic artery, one dips into the right extremity of the transverse fissure of the liver, and the other into the left extremity of the same fissure: in these situations they become applied to the corresponding branches of the vena portæ and hepatic duct, are enclosed with them in the capsule of Glisson, and closely accompany the corresponding ramifications of those vessels through all their divisions and subdivisions.

The Splenic Artery.

The *splenic artery* (*d*, *figs.* 200, 201) is larger than either of the other divisions of the cœliac axis. Immediately after its origin it is received into a slight groove formed along the whole of the upper border of the pancreas (*i*). It passes from the right to the left side, and is exceedingly tortuous in its course:* having reached the hilus of the spleen, it divides into a great number of terminal branches (*n*, *fig.* 201), which enter that organ separately. It is not rare to find one of these branches detached from the others, to be distributed either to the upper or the lower end of the spleen.

Fig. 201.

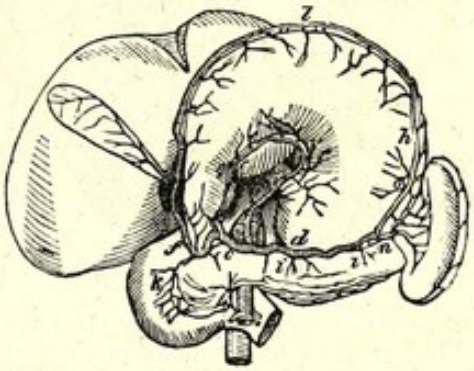

Near the spleen, the splenic artery and its divisions are enclosed within the gastro-splenic omentum.

The relations of the splenic artery to the posterior surface of the stomach explains how, in certain cases of ulceration of the stomach opposite the pancreas, this artery may become the source of hæmatemesis.

The splenic artery gives off several collateral branches:

The *pancreatic* arteries (*i i*), which are variable in number, and are very large, considering the size of the organ to which they are distributed.

The *left gastro-epiploic artery* (*h*), which often arises from one of the divisions of the splenic, passes vertically downward, behind the great end of the stomach, gains the great curvature, along which it runs from left to right, and anastomoses with a branch of the hepatic, viz., the right gastro-epiploic (*l*); like which artery, it sends off *ascending* or *gastric*, and *descending* or *epiploic* branches. The size of the gastro-epiploica sinistra varies much, and has an inverse proportion to that of the gastro-epiploica dextra.

The *vasa brevia* (*o o*), which are remarkable for their number and shortness, generally arise from one or several of the terminal branches of the splenic artery, just as these are entering the spleen; they pass directly, by a retrograde course, from that organ to the great cul-de-sac of the stomach, as far as the cardia, where they anastomose with the cardiac branches of the coronary artery of the stomach.

From the preceding description of the branches of the cœliac axis, we perceive that the stomach is surrounded by an uninterrupted arterial circle, formed by the right and left gastro-epiploic, by the pyloric, and by the coronary arteries; and that, secondly, the branches derived from this circle constitute an anastomotic network upon the anterior and posterior surfaces of the stomach.

The Superior Mesenteric Artery.

Dissection.—Look for the origin of the artery between the pancreas and the third portion of the duodenum; turn the whole of the small intestines to the left side; remove with care the right layer of the mesentery, the left layer of the right lumbar mesocolon, the inferior layer of the transverse mesocolon, and the numerous lymphatic glands which conceal the artery and its divisions.

The *superior mesenteric artery* (below *y*, *fig.* 199) is the artery of the small intestine, and of the right half of the large intestine. It arises from the front of the aorta, imme-

* I have seen some splenic arteries not at all tortuous; and at other times I have found the curvatures so decided that the lower part only of the curves came in contact with the pancreas. Why do these curvatures exist? It cannot be to accommodate the variations in the size of the spleen; but is it to retard the flow of the blood? There is no proof of it; indeed, the law which governs the existence of a tortuous condition of certain arteries is yet to be discovered. The caliber of the splenic artery is strictly proportioned to the size of the spleen. Where it is strophied the artery is small: where hypertrophied, it becomes enormously enlarged.

diately below the cœliac axis, and very rarely from a common trunk with it. It is at first situated behind the pancreas, and then passes vertically downward, between that gland and the third portion of the duodenum, which is crossed at right angles by it, and of which it forms the lower boundary (*vide* DUODENUM); it at length reaches the mesentery, opposite the point (*a*, *fig.* 202) where that fold meets the transverse mesocolon. Continuing its course within the substance of the mesentery, and following its adherent border, it describes a slight curve, with the convexity directed to the left and the concavity to the right side: gradually diminishing in size as it advances, it proceeds to opposite the ileo-cæcal valve (*b*), and then becomes so small that it can no longer be distinguished from the branches given off from it. It follows, therefore, that the trunk (*a b*) of the superior mesenteric artery corresponds with the adherent border of the mesentery, with the length of which it, as it were, agrees.

Fig. 202.

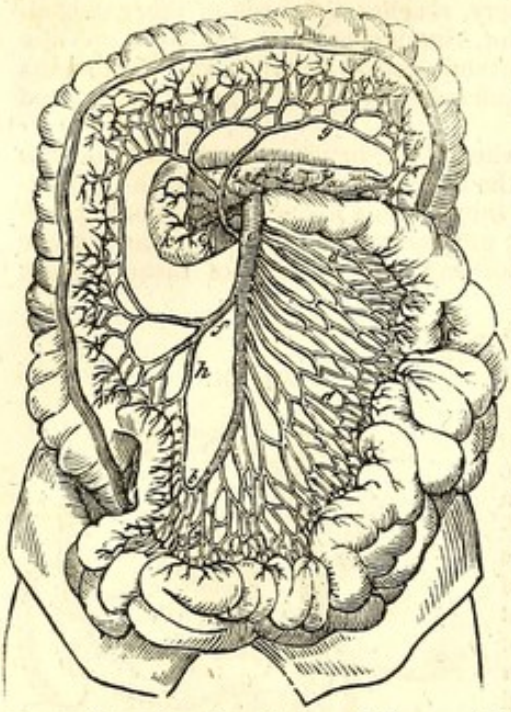

Collateral Branches.—While behind the pancreas, the superior mesenteric sends off *pancreatic branches* (*k*), which anastomose with those derived from the hepatic and the splenic arteries; it rather frequently gives off the hepatic, and it is then larger than the cœliac axis.

In the mesentery, the superior mesenteric gives off two sets of branches: one set arising from its convexity, and forming the *arteries of the small intestine;* the other set from its concavity, viz., *the arteries of the great intestine*, called the right *colic* arteries.

The arteries of the small intestine have received no particular name; they are large branches, directed obliquely downward and forward, all of which proceed parallel to each other in the substance of the mesentery, towards the concave border of the small intestine. Their number is irregular, and their size unequal: seven or eight of them are at least equal in size to the radial artery, others are smaller; the superior branches are generally the largest. Their number is calculated at from fifteen to twenty.

After a course of about two or three inches, each of them bifurcates; the branches of the bifurcation separate from each other, and, curving into arches, inosculate with the neighbouring branches. From the convexity of this series of arches, which is turned towards the intestine, a multitude of branches arise, which soon bifurcate, and form anastomotic arches (*d d d*), which, as they are nearer the small intestine, describe a curve of much greater extent in the mesentery than the first series. From the convexity of this second series of arches a great many more branches arise than were given off from the first series. Lastly, from the division of these branches a third series of anastomotic arches is formed, which is still nearer the concave border of the intestine than the second.

There are only three series of arches at the commencement and the termination of the small intestine; but in the middle there is a fourth, sometimes even a fifth.

From the convexity of the arches nearest to the small intestine arise two sets of vessels, intended for the two halves of the cylindrical gut. Each of these sets of vessels divides into *superficial branches*, which, ramifying beneath the peritoneum, form a superficial network, and anastomose upon the convex border of the intestine; and into *deep branches*, which perforate in succession the muscular and cellular coats, and terminate in an inextricable network in the mucous membrane.

The series of anastomotic arches formed by the divisions of the superior mesenteric artery, not only regulate the current of the blood, but also enable a small number of branches, occupying a very limited space at the root of the mesentery, to supply branches to so great an extent of surface as the entire length of the small intestine, which is from fifteen to twenty-one feet. This spreading out of the vessels over a large surface will be still better seen in the arrangement of the arteries of the great intestine.

The arteries for the great intestine, or the *right colic arteries*, are two or three in number, and are distinguished into the superior (*e*), middle (*f*), and inferior (*h*). They arise from the concavity of the curve formed by the superior mesenteric artery, and pass from the mesentery, in which they are enclosed at their origin, into the right lumbar mesocolon. The superior is ascending, the middle horizontal, and the inferior descending; near the great intestine they bifurcate. The branches of the bifurcation anastomose, and form very large arches, with their convexities turned towards the great intestine. From these arches the intestinal branches take their origin directly, and divide into two

sets of parallel ramifications, an anterior and a posterior, which, like those of the small intestine, subdivide into the *sub-peritoneal* and the *deep branches*, and terminate in the different coats of the intestine. Where the primary anastomotic arches are situated at a certain distance from the intestine, for example, opposite the angles of bifurcation of the arteries, or opposite the angles formed by the ileum with the cæcum, and by the ascending with the transverse colon, we find one, or even two, small arches filling up the angular interval.

The upper branch (*g*) of the right superior colic artery (*e*, *figs.* 202, 203), which supplies the right half of the arch of the colon, anastomoses with the upper branch of the left colic artery (*f*, *fig.* 203), which is derived from the inferior mesenteric (*c*). This remarkable anastomosis between the superior and inferior mesenteric arteries has been pointed out by anatomists as the most important anastomosis in the body.

The lowest branch of the right inferior colic artery (*h*, *fig.* 202) anastomoses with the termination (*b*) of the superior mesenteric, which becomes exceedingly slender. This right inferior colic, or *ileo-colic* artery (*h*), supplies the cæcum, the ileo-cæcal angle, and the appendix vermiformis.

The Omphalo-mesenteric Artery.—In the early periods of intra-uterine life, the superior mesenteric artery gives off a branch, called the *omphalo-mesenteric*, which reaches the umbilicus, passes out of the abdomen, traverses the entire length of the cord, and is distributed upon the umbilical vesicle. I have found this artery perfectly distinct in an anencephalous fœtus at the full term; it is generally obliterated towards the end of the second month of intra-uterine life.

The Inferior Mesenteric Artery.

Dissection.—Turn the small intestines to the right side; spread out the arch of the colon, the right lumbar colon, and the sigmoid flexure; remove the peritoneum, which forms the inferior layer of the transverse mesocolon, and the right layer belonging to the descending colon and sigmoid flexure.

The *inferior mesenteric artery* (*m*, *fig.* 199; *c*, *fig.* 203) is much smaller than the superior. It arises from the front of the aorta, about two inches above the bifurcation of that vessel. It descends vertically in front of, and in contact with the aorta, and then in front of the left common iliac artery. It is at first enclosed in the iliac mesocolon, but afterward enters the meso-rectum, where it divides into two branches, which are named the *superior hemorrhoidal* (*h*, *fig.* 203). In this course, the inferior mesenteric gives off no branch on the right side; on the left it gives two, more frequently three branches, called the *left colic* arteries (*f*), which are distributed in precisely the same manner as the right colic arteries. I have already said that the upper division of the left superior colic artery (*f*) inosculates with the upper division (*g*) of the right superior colic (*e*). Near the sigmoid flexure we find two, and sometimes three series of arches from the *sigmoid* branch, so arranged that the last may reach the intestine.

Fig. 203.

The superior hemorrhoidal arteries are distributed to the rectum, in the same manner as the other intestinal arteries; near the sphincter, they anastomose with the middle hemorrhoidals, which are derived from the internal iliac arteries.

The Spermatic Arteries—the Arteries of the Testicles in Man, and the Utero-ovarien in Woman.

Dissection.—Remove carefully the mesentery and the peritoneum. Follow these arteries, in man, through the inguinal passages imbedded in the substance of the spermatic cord, down to the testicle and the epididymis; and in woman, follow them into the substance of the broad ligament as far as the ovaries on one side, and on the other, as far as the bottom and the body of the uterus. To inject perfectly these arteries to their termination, recourse must be had to very penetrating liquids, or, what is better, to partial injections.

The *spermatic arteries* (*o o*, *fig.* 198; *f f*, *fig.* 199) are distributed to the testicles in the male, and to the ovaries in the female.

They are two in number, and are as variable in their origin as they are regular in their course and distribution.

Their *origin* is remarkably distant from their termination; an unsatisfactory attempt

has been made to explain this circumstance by referring to the situation of the testicle in the fœtus.

Varieties of Origin.—These arteries generally arise from the front, sometimes from the side of the aorta, below the corresponding renal artery, rarely above it, and still more rarely from the renal itself. It is rather rare for the right and left spermatics to come off at the same heights. I have seen the right spermatic artery arise below the renal, and the left by the side of the inferior mesenteric.*

Whatever may be their origin, these arteries pass directly downward. Sometimes they come off at a right angle, and then curve downward, so as to descend almost vertically upon the sides of the spine, behind the peritoneum, in front of the corresponding psoas muscle and ureter, and on the inner side of the spermatic veins. The right spermatic artery is in relation with the vena cava inferior, and almost always passes in front, but sometimes behind it; the artery of the left side is situated behind the sigmoid flexure of the colon. On both sides, having reached the side of the pelvis, the artery is situated on the inner side of the psoas, in front of the external iliac artery, and is then differently distributed in the two sexes.

In the male (*f, fig.* 199), it enters the abdominal orifice of the inguinal canal, along which it proceeds, and, together with the vas deferens and the spermatic veins, forms the spermatic cord; it escapes from the canal, and, at a greater or less distance from the ring, divides into two branches, one of which enters the head of the epididymis, while the other, the *testicular*, penetrates the testicle at its upper border, and is then distributed as already described (see TESTICLES).

In the female, the ovarian arteries (*o o, fig.* 198), which are much shorter than the spermatics of the male, dip into the pelvis, reach the upper border of the ovaries, supply them, and also the Fallopian tubes, with a great number of branches, and terminate upon the sides of the uterus, by anastomosing freely with the uterine arteries (*n n'*).†

The ovarian arteries are distributed more to the uterus than to the ovary, as may be proved by the post mortem examination of the body of a pregnant or puerperal female; for it is then seen that the ovarian arteries also become largely developed as well as the uterine, and that the branches sent to the uterus are enormous in comparison with those given off to the ovaries.

The ovarian arteries are very tortuous, especially opposite the brim of the pelvis; they are quite as much convoluted as the uterine arteries.

The Renal or Emulgent Arteries.

Dissection.—The renal arteries are prepared after the intestines, the peritoneum, the renal adipose tissue, and the numerous nervous filaments by which the arteries are surrounded, have been removed.

The *renal* or *emulgent arteries* (*e e, fig.* 199) arise at right angles from the side of the aorta, above the inferior mesenteric: the left renal artery often arises a little higher than the right, doubtless on account of the size of the liver. These arteries are very large in comparison to the kidney, for they are nearly equal in size to the cœliac axis, or the superior mesenteric; they are remarkable for their transverse, and, generally, straight direction; for their shortness; and, lastly, for their numerous varieties. These we shall now mention.

Varieties as to Number.—There is generally one for each kidney, but frequently there are two, three, or four. *Varieties as to Origin.*—Not uncommonly the renal arteries arise from the aorta lower down than usual, or even from the common iliac or the internal iliac. The two latter modes of origin are scarcely observed, excepting when the kidney is displaced, and occupies either the iliac fossa or the cavity of the pelvis. In a case which I recently examined, the kidney occupied the cavity of the pelvis, and there were two renal arteries, one of which arose from the aorta at its bifurcation, and the other near the inferior mesenteric. Lastly, I should add that Meckel has seen the two renal arteries arise by a common trunk from the front of the aorta. *Varieties in Direction.*—When two renal arteries arise from the same side, or when one divides into two branches, I have found them, in several cases, twisted spirally round each other, like the umbilical arteries. *Varieties as to Division.*—The renal artery sometimes divides immediately after its origin; and then one of the branches, separating itself from the others, proceeds to one or other extremity of the kidney. Such a mode of division leads to those cases in which there is more than one artery.

Relations.—The renal arteries are covered by the peritoneum and the corresponding renal veins; they are surrounded by a quantity of adipose cellular tissue, and they rest behind upon the bodies of the vertebræ. The right renal artery is also covered by the inferior vena cava. In one case, where there were two renal arteries on the right side, one of these was in front, and the other behind the vena cava.

* It is not uncommon to meet with two spermatic arteries on one side

† We know that the development of the uterus, during the first five months of pregnancy, takes place almost exclusively at the expense of the body, and that the neck of the uterus begins to be developed from the fifth to the sixth month. I have seen some diseases of the uterus in which a sort of independence might have been traced between the neck and the body of the womb.

Collateral Branches.—The renal arteries give off some small twigs to the supra-renal capsules, which are called the *inferior capsular* or supra-renal, and also some small branches to the adipose tissue which covers the kidney, and to its proper cellular coat.

Terminal Branches.—At the hilus of the kidney, the renal artery divides into three or four branches, all of which enter the hilus, between the pelvis of the ureter, which is behind, and the branches of the renal vein, which are in front. The arteries subdivide in the kidney so as to form a network at the limits between the tubular and cortical substances. (See KIDNEY.) A very few of the branches from this network proceed to the tubular substance, almost all of them being distributed to the cortical substance. Most anatomists have remarked the facility with which even coarse injections pass from the renal arteries into the veins and ureters.

The Middle Supra-renal, or Capsular Arteries.

The *middle supra-renal arteries* (*s s, fig.* 199), so named in contradistinction to the superior vessels of the same name, derived from the diaphragmatic and the inferior, proceeding from the renal, are of large size in comparison with the organ to which they are distributed. They arise from the sides of the aorta, above the renal, supply twigs to the surrounding fat, and to the pillar of the diaphragm, run along the concave border of the corresponding supra-renal capsule, give off anterior and posterior branches, which enter the furrows on the surface of that organ, and penetrate and ramify in its interior.

ARTERIES ARISING FROM THE ARCH OF THE AORTA.

Enumeration and Varieties.—The Common Carotids.—The External Carotid—the Superior Thyroid—the Facial—the Lingual—the Occipital—the Posterior Auricular—the Parotid—the Ascending Pharyngeal—the Temporal—the Internal Maxillary.—The Internal Carotid—the Ophthalmic—the Cerebral Branches of the Internal Carotid.—Summary of the Distribution of the Common Carotids.—Artery of the Upper Extremity.—The Brachio-Cephalic.—The Right and Left Subclavians—the Vertebral and its Cerebral Branches, with Remarks on the Arteries of the Brain, Cerebellum, and Medulla—the Inferior Thyroid—the Supra-scapular—the Posterior Scapular—the Internal Mammary—the Deep Cervical—the Superior Intercostal.—The Axillary—the Acromio-thoracic—the Long Thoracic—the Sub-scapular—the Posterior Circumflex—the Anterior Circumflex.—The Brachial and its Collateral Branches.—The Radial, its Collateral Branches, and the Deep Palmar Arch.—The Ulnar, its Collateral Branches, and the Superficial Palmar Arch.—General Remarks on the Arteries of the Upper Extremity.

THREE arterial trunks, intended to supply the head and the upper extremities, take their origin from the arch of the aorta. Proceeding in the order in which they arise, *i. e.*, from right to left, they are the *innominate* or *brachio-cephalic* (*e, fig.* 198), which soon subdivides into the *right common carotid* (*f*) and *right subclavian* (*g*), the *left common carotid* (*f'*) and the *left subclavian* (*g*).

The direction of that portion of the arch of the aorta which gives origin to these arteries is such, that they are arranged one after the other upon a plane which slopes downward, backward, and to the left; so that the trunk of the innominate artery lies almost immediately behind the sternum, while the left subclavian is near the vertebral column.

Varieties.—These three arteries present numerous varieties in their origin, all of which appear to me to be referrible to the three following heads: varieties by approximation or fusion, varieties by multiplication, and varieties by transposition of their origins. In many cases, several of these kinds of varieties may coexist.*

Varieties by Approximation or Fusion of Origins.—Sometimes the left common carotid becomes closely approximated to the brachio-cephalic trunk; and this condition leads us to the not very uncommon variety in which these two vessels arise by a common trunk.† Again, two brachio-cephalic trunks may be given off from the arch of the aorta, one on the right, the other on the left side.‡ Of these two trunks which arise from the aorta, the first, which is the most voluminous, gives origin to the two carotid arteries, and to the right subclavian; the second, which is the smallest, gives origin to the left subclavian. The greatest amount of variety of this kind is observed in the case where the three branches which usually arise from the arch are united into one common trunk, which forms an ascending aorta. In this case, there is no arch of the aorta; the aorta,

* [A variety, affecting merely the *situation* of the three primary vessels upon the arch, is noticed by Professor R. Quain (*Opera cit.*). It consists in those vessels arising to the right of their usual position, *i. e.*, nearer to the origin of the aorta.]

† I have often seen these three branches, viz., the brachio-cephalic trunk, the left primitive carotid, and the left subclavian, arising by the side of each other, so that their three orifices were only separated, as it were, by a spur.

‡ This variety, which, together with the preceding, constitutes the normal state of some animals, seems, moreover, the reproduction of the normal disposition of the venous system, in which there are two cephalic venous trunks, one right, the other left, which unite for the purpose of forming the superior vena cava. Meckel, I believe, was the first to remark that certain anomalies of the arterial system might be attributed to the normal disposition of the venous system.—(See the excellent article of Dr. Rendu, *Memoir on the History of Arterial Anomalies, Gazette Medicale*, 1842, vol. x., p. 129.)

immediately after its origin, is divided into ascending and descending. This arrangement is normal in the ox, the horse, the sheep, the goat, and some other animals.*

Varieties by Multiplication of Origin.—Sometimes the two common carotids arise separately in the interval between a right and a left subclavian, a condition that leads us to the case in which the two carotids arise by a common trunk between the separated subclavians. Again, the left vertebral artery may arise directly from the aorta, between the left carotid and subclavian; this is very common: or the two vertebrals, the two carotids, and the two subclavians may all arise separately; or the inferior thyroid, or the thyroid of Neubauer, from the name of the anatomist who first described this variety, may arise directly from the curvature of the aorta; lastly, the right internal mammary and the left vertebral may arise directly from the arch of the aorta.

Varieties by Transposition or Inversion of Origin.—The brachio-cephalic trunk is sometimes found on the left side instead of the right; still more frequently the right subclavian arises separately below the left subclavian, and then passes upward and to the right side, most commonly behind the trachea and œsophagus, but sometimes between these two canals. Again, the trunks arising from the arch of the aorta have been seen to be given off in the following order: a single trunk for both common carotids; then the left subclavian; and, lastly, the right subclavian, which arose from behind the arch of the aorta, and passed as in the preceding case. A fifth variety consists in a combination of the variety by transposition either with the variety by fusion or with the variety by multiplication.

The Common Carotid Arteries.

Dissection.—Dissect the anterior cervical region, preserving all the parts in relation to the vessels. In order to see the thoracic portion of these arteries, remove the upper part of the sternum.

The *primitive* or *common carotid arteries* (*ff*, *fig.* 198; *a*, *fig.* 204) are the arteries of the head. Their limit above is marked by the upper border of the thyroid cartilage, opposite which they divide into the *external* and *internal* carotids.†

They are two in number, distinguished as the right and left: they differ as to their origin, their length, and their directions; thus, on the left side, the common carotid arises directly from the aorta; on the right, it arises from a trunk common to it and to the subclavian, viz., the *innominate*, or *brachio-cephalic* artery (*e*, *fig.* 198). As the brachio-cephalic and the left common carotid are given off from the aorta nearly at the same level, it follows that the left common carotid is longer than the right by the entire length of the brachio-cephalic.

It follows, also, from the obliquity of the arch of the aorta, that the left common carotid is placed much deeper than the right at its origin; but, in the cervical region, the two carotids are upon the same plane.

They pass somewhat obliquely upward and outward immediately after their origin, but they are directed vertically and parallel to each other in the cervical region.‡ The interval between them is occupied by the trachea and the œsophagus below, and by the larynx and pharynx above. Their course is straight, and without any winding. Their diameter is uniform throughout, a circumstance which is connected with the absence of any collateral branches. The caliber of these arteries is relatively larger in man than in other animals; and this has reference to the greater size of his brain. I have not observed any difference in diameter between the right and left common carotids.

As about one inch in length of the left common carotid lies in the thorax, its relations must be separately studied in that situation.

Relations of the Thoracic Portion.—*In front*, with the left subclavian vein, and the sterno-hyoid and sterno-thyroid muscles, which separate it from the sternum; *behind*, with the trachea and œsophagus, and with the left subclavian and left vertebral arteries; *on the outside*, with the pleura or the left wall of the mediastinum; *on the inside*, with the brachio-cephalic trunk, from which it is separated by a triangular interval, in which the trachea is visible.

Relations of the Cervical Portion.—These are the same for both arteries. *In front*, each common carotid is covered below by the sterno-mastoid, and more immediately by the sterno-hyoid, sterno-thyroid, and omo-hyoid muscles, the latter of which crosses the artery obliquely.◊ In its upper half it corresponds to the platysma myoides, which separates it from the skin. The cervical fascia, the superior thyroid vein, and the descendens noni, a branch of the hypoglossal nerve, are in more immediate relation with

* Some anomalies of the arterial system of man may be in some measure explained from the normal state of the arterial system of certain animals; but the number of such cases is extremely limited. I do not know whether any one has ever thought of applying to these anomalies the rule of the arrest of development, which some have lately made to play such an exaggerated part in the theory of the vices of conformation.

† [The common carotid has been seen to divide above the os hyoides, also opposite the thyroid cartilage, and even low down in the neck.]

‡ [In consequence of the larynx being wider than the trachea, the common carotids are not quite parallel in the neck, but are somewhat farther apart above than below.]

◊ In order to omit nothing, I should say that the common carotid is crossed obliquely by a branch which is given off from the superior thyroid artery to the sterno-mastoid muscle.

it. The most important of these relations is that with the sterno-mastoid, which, in a surgical point of view, may be regarded as its satellite muscle. *Behind*, the common carotid is the vertebral column, from which it is separated by the pre-vertebral muscles, the great sympathetic nerve, and below by the recurrent nerve and inferior thyroid artery.* *On the inside*, it is in relation with the trachea, œsophagus, larynx, and thyroid gland, which passes in front of the artery when larger than usual; *on the outside* of the artery is the internal jugular vein. The pneumogastric nerve lies at the back, between the artery and vein. The common carotids are also surrounded by much loose cellular tissue, and by some lymphatic glands.

The left common carotid is in more direct relation with the œsophagus than the artery of the right side.

The common carotids give off no branch during their course: nevertheless, it is not very rare for this artery to give off the inferior thyroid artery, or a supernumerary branch known as the *middle thyroid*.† Neabauer has seen the common carotid give off a thyroid artery, and the internal mammary of the right side.

Terminal Branches.—Having reached the upper border of the thyroid cartilage, at a variable height, according to the subject, the common carotid divides into two branches, called the *external* and *internal carotids*, which, by no means a common arrangement, do not leave each other at an acute angle, but remain in contact, and even frequently become crossed before they separate. The point of division is also remarkable for a sort of ampulla or dilatation, which the primitive carotid exhibits. Sometimes the primitive carotid bifurcates much sooner than usually. Morgagni relates a case in which the bifurcation took place at the distance of an inch and a half from the origin of the artery. Sometimes the primitive carotid does not terminate in a bifurcation. In such a case, all the branches given off by the external carotid arise successively from the primitive carotid, which penetrates the cranium and terminates as the internal carotid.

The External Carotid Artery.

Dissection.—Prolong the incision made for exposing the common carotid as far as the neck of the condyle of the lower jaw. Dissect carefully the styloid muscles and the digastricus, and cautiously separate the artery from the surrounding tissue of the parotid gland.

The external or *superficial carotid artery* (*b*, *fig.* 204) is, in a great measure, intended for the face, and has, therefore, been called the *facial carotid* by Chaussier. It arises from the common carotid, forming one of its two divisions, and extends as far as the neck of the condyle of the lower jaw, where it terminates by dividing into the *temporal* and *internal maxillary* arteries.

Fig. 204.

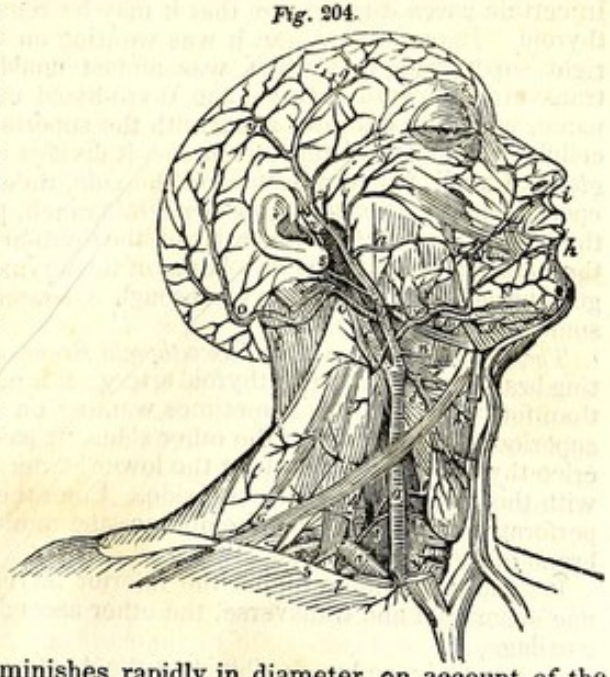

The origin of this artery is remarkable for being situated on the inner side of the internal carotid. It ascends vertically as high as the digastricus, and passes under that muscle; it is then directed a little backward and outward, leaves the vertebral column, reaches the angle of the lower jaw, and again becomes vertical as it proceeds upward to the neck of the condyle, opposite to which it terminates. It is very slightly tortuous in the adult, and in the infant is almost straight. In the adult it is nearly equal in size to the internal carotid, but it is much smaller in young subjects. It diminishes rapidly in diameter, on account of the number of branches given off from it, so that at its termination it is scarcely one third its original size. Sometimes it divides immediately into a sort of bunch of arterial vessels; in other cases its branches arise in succession from the common carotid, which is then directly continuous with the internal carotid.‡

* A variety of relations which it is important to know in a surgical point of view is the relation which often exists behind, between the right primitive carotid and the trachea. Where this anomaly exists, the brachio-cephalic trunk arises a little more to the left side than usually.

† This supernumerary artery arises at different elevations. In a case which has been communicated to me by Professor Dubreuil, the middle or supernumerary thyroid artery was given off by the right primitive carotid at the distance of a centimeter from the innominata. It passed up in a straight line into the gland, where it was lost, and anastomosed freely with the superior and inferior thyroidian arteries on each side. The right inferior thyroidian artery was not half as voluminous as usual. Mr. Dubreuil, who teaches anatomy with so much talent at Montpelier, has communicated to me several arterial anomalies, which are to be inserted in a professional work that he is preparing on that subject in a surgical point of view.

‡ It is doubtless on account of the numerous branches given off by the external carotid that several ancient

Relations.—It is superficial at its origin, like the upper part of the common carotid, and, like it, is merely separated from the skin by the platysma myoides; but it then dips into the supra-hyoid region, below the digastricus, the stylo-hyoideus, and the hypoglossal nerve.* Higher up it is situated deeply in the parotid excavation, surrounded on all sides by the tissue of the parotid gland, which, on this account, cannot be entirely extirpated without wounding the vessel.

Collateral Branches.—These are six in number, and are arranged into three sets, viz., an *anterior* set, consisting of the *superior thyroid*, the *facial*, and the *lingual*; a *posterior*, including the *occipital* and the *auricular*; and an *internal* set, formed by one vessel, the *inferior*, or *ascending pharyngeal.*

The *terminal branches* are two in number, the *superficial temporal* and the *internal max-*

The Superior Thyroid Artery.

The *superior thyroid artery* (*d*, *fig.* 204) belongs both to the larynx and the thyroid gland. It is the first branch given off from the external carotid; it rather frequently arises opposite the bifurcation of the common carotid, which in this case would seem to divide into three branches. In some cases it arises directly from the common carotid; at other times it has been seen to come off by a common trunk with the lingual. It is always of considerable size, but varies in this respect, maintaining either a direct relation to the size of the thyroid body, or an inverse proportion to that of the other thyroid arteries.

Direction.—It is at first directed horizontally forward and inward; but it almost immediately bends, and proceeds vertically to the upper end of the corresponding lobe of the thyroid gland, in which it terminates.

Relations.—It is superficial at its origin, where it is covered only by the skin and the platysma; it then dips under the omo-hyoid, sterno-hyoid, and sterno-thyroid muscles, and it is also covered by the cervical fascia and the superior thyroid veins. This artery furnishes several collateral branches, viz., the *superior laryngeal*, the *inferior laryngeal* or *crico-thyroid*, and the *sterno-mastoid* branch.†

The Superior Laryngeal Branch.—This (*e*) comes off from the thyroid, at the point where the latter changes its direction; sometimes it arises from the external carotid. In certain cases it is so large that it may be regarded as formed by a bifurcation of the thyroid. In one case where it was wanting on the left side, I found it replaced by the right superior thyroid, which was almost double its usual size. This artery passes transversely inward between the thyro-hyoid muscle and the membrane of the same name, which it perforates along with the superior laryngeal nerve; having reached the cellular tissue behind this membrane, it divides into two branches, an ascending, or *epiglottid* branch, which passes upon the side, then in front of the epiglottis, and ramifies upon it; and a descending, or *laryngeal* branch, properly so called, which passes behind the thyroid cartilage, between it and the thyro-arytenoid muscle, and is distributed upon the muscles and mucous membrane of the larynx. Not unfrequently the superior laryngeal branch enters the larynx through a foramen existing in the thyroid cartilage in some subjects.

The Inferior Laryngeal or Crico-thyroid Branch.—This arises from the internal terminating branch of the superior thyroid artery; it is more remarkable for its constant presence than for its size. It is sometimes wanting on one side, but it is then replaced by the superior thyroid artery of the other side. It passes transversely inward, in front of the crico-thyroid membrane, along the lower border of the thyroid cartilage, and inosculates with the branch of the opposite side. From the arch thus formed twigs proceed, which perforate the crico-thyroid membrane, and ramify in the muscles and the mucous membrane of the larynx.

It is not uncommon to find the inferior laryngeal artery dividing into two branches: one superficial and transverse, the other ascending, which passes up behind the thyroid cartilage.

M. Chassaignac has exhibited, at the Anatomical Society, a preparation, in which the trunk of the superior thyroid artery, instead of giving off the inferior laryngeal branch, passed itself transversely over the crico-thyroid ligament.

The Sterno-mastoid Branch.—This is constant, but of variable size. It comes off from the superior thyroid, a little below the superior laryngeal, and passes downward to reach the deep surface of the sterno-mastoid muscle, to which it is distributed.

Terminal Branches.—Having reached the gland, the thyroid artery divides into three branches, viz., one which passes between the gland and the trachea; another, which

authors have not described this vessel as a particular artery, but have contented themselves with describing the branches which it gives off.

* [It crosses over the styloid process, the stylo-glossus and pharyngeus muscles, and the glosso-pharyngeal nerve, which lie between it and the internal carotid.]

† [The first branch is usually a small one, named the hyoid, which arises opposite the great cornu of the os hyoides, passes inward on the thyro-hyoid membrane, and anastomoses with the vessel of the opposite side.]

proceeds along the outer border of the corresponding lobe; and a third, which runs along the inner border, and anastomoses in the median line with the corresponding branch of the opposite side. It is this vessel which sometimes gives off the inferior laryngeal.*

The Facial, the Labial, or External Maxillary Artery.

Dissection.—Let the head fall backward by means of a billet placed under the neck, and incline it towards the side opposite to that on which the artery is to be laid bare; dissect carefully the digastricus and stylo-hyoid muscles, which must be cut superiorly at their origin from the styloid process; dissect the sub-maxillary gland, then the muscles of the face, avoid injuring the numerous branches which may come under the scalpel.

The *facial artery* (*f, figs.* 204, 206), so called from its distribution, is given off from the front of the external carotid, a little above the os hyoides: it is so large in some subjects that it seems to be formed by a bifurcation of the external carotid. It proceeds in a tortuous course from below upward, and then from behind forward, along a groove formed in the sub-maxillary gland. After leaving this groove, it passes vertically upward, crosses the body of the lower jaw at right angles in front of the masseter muscle, becomes oblique, arrives near the commissure of the lips, reaches the furrow between the ala nasi and the cheek, and terminates near the inner angle of the eye, by anastomosing with one of the branches of the ophthalmic, and with the infra-orbital artery. The termination of the facial artery is subject to numerous individual varieties. The vessel is also remarkable for being extremely tortuous, a condition which is connected with the mobility of the parts supplied by this artery, which runs in succession over the supra-hyoid, the inferior maxillary, the buccal, and the nasal regions

Relations.—In the supra-hyoid region the facial artery is covered by the digastric and stylo-hyoid muscles; then, along the base of the jaw, it is in relation with the outer surface of the sub-maxillary gland, and is separated from the skin by the platysma and a great number of lymphatic glands. In the facial region, the artery is covered below by the platysma, higher up by the triangularis oris and the zygomaticus major, and in all the rest of its extent by a greater or less quantity of fat, which separates it from the skin; it lies upon the inferior maxilla, against which it may be compressed in front of the masseter, also upon the buccinator, the orbicularis oris, the levator communis, and the levator proprius.

Collateral Branches.—The following branches are given off by the facial artery in the *supra-hyoid* region. The *inferior palatine*, a small branch which is sometimes derived from the external carotid, or from the ascending pharyngeal artery, passes up behind [or between] the stylo-glossus and stylo-pharyngeus muscles, to which it furnishes some branches, gains the side of the pharynx, and is distributed to the tonsil, which it covers with its ramifications, and also to the velum palati and the pillars of the fauces, opposite which it anastomoses with several branches of the ascending pharyngeal artery. I have seen the palatine branch of the facial extremely large, and taking the place of the tonsillar and palatine branches of the ascending pharyngeal artery.

The *sub-mental branch* (*g, fig.* 204) runs along the inner side of the lower border of the ramus of the jaw, between the digastricus and mylo-hyoideus, passes upward in front of the bone, on the outer side of the anterior attachment of the digastricus, and ramifies in the skin and muscles of the chin, anastomosing with the ramifications of the inferior dental artery. Sometimes the sub-mental divides into two or three branches, all of which terminate in the same manner, after perforating the digastric muscle.

Branches for the Sub-maxillary Gland.—These are three *or* four in number, and are large in proportion to the organ which they supply.

The Pterygoid Branch.—This is a small branch which passes into the internal pterygoid muscle.

The collateral branches of the *facial* region are divided into *external* and *internal*. The *external branches* ramify in all the muscles and integuments of the cheek, and anastomose freely with the transversalis faciei, a branch of the superficial temporal: the most remarkable of these branches are the two given to the masseter and buccinator muscles.

Among the *internal branches*, besides a number of small twigs which have received no names, we remark the following.

The *inferior coronary* or *labial* artery (*h*), which is given off from the facial, a little below the commissure of the lips; it pursues a serpentine course in the substance of the lower lip, between the muscular and glandular layers, at a greater or less distance from the free border of the lip, and anastomoses, in the median line, with the corresponding vessel of the opposite side. I have seen this artery occupy the lower or adherent border of the lower lip until it reached the median line, when it ascended vertically to the free border, where it divided into two equal branches, which passed, horizontally, one to the

* I have seen the branch which runs along the inner border of the thyroid gland pass transversely to the left side, above and at a certain distance from this border; having reached the median line, it proceeded vertically downward, in front of the crico-thyroid ligament, to the middle of the thyroid gland, where it gave off the right and left inferior laryngeal branches. The left thyroid was very small, and only furnished the external branch for the thyroid gland.

right and the other to the left, in order to form a second coronary artery, smaller than the first.

The *superior coronary*, or *labial*, arises opposite the commissure, passes in the upper lip between the muscular and glandular layers, and inosculates, in the median line, with the vessel on the opposite side. Branches are given off from this arch to the mucous membrane, the gums, the muscles, and the skin. One branch only of this artery requires a special description; it is known by the name of the *artery of the septum nasi* (*i*). It comes off, in the median line, by one, two, and sometimes three branches, which pass vertically upward, and then horizontally beneath the skin, covering the under surface of the septum as far as the tip of the nose, where they anastomose with the artery of the ala.

The *artery of the ala nasi*, or lateral artery of the nose (*l*), which is very often the termination of the facial, divides into two branches: a small one, that runs along the lower border of the cartilage of the ala, and anastomoses with the artery of the septum; and a larger one, that runs along the upper convex border of that cartilage. A small branch penetrates into the interior of the nares, between the cartilage and the opening of the nostril.

Termination of the Facial Artery.—The facial artery having become extremely slender, sometimes terminates, under the name of the angular branch (*m*), upon the side of the nose, by anastomosing with the nasal branch of the ophthalmic, and with the infra-orbital. At other times its termination is formed by the artery of the ala of the nose, or by the superior coronary of the lip, or even by the inferior coronary. I have seen it terminate in the artery of the septum. We seldom find the facial arteries of both sides alike. Sometimes there is merely a trace of one, while the other is very much developed, and supplies by itself alone all the nasal and labial branches. No artery varies more than the facial, both in size and extent of distribution.

Its anastomoses with the inferior dental and infra-orbital arteries, branches of the internal maxillary, as well as those with the ophthalmic, a branch of the internal carotid, should be particularly noticed.

The Lingual Artery.

Dissection.—Cut the hyoidian insertions of the mylo-hyoid muscle, which is to be turned up from below upward; saw the inferior maxillary bone, either at the symphysis or on each side of it. Hook the tongue and draw it out of the mouth, and maintain it in that position while you follow the artery as situated at its inferior surface.

The *lingual artery* (*n*, *figs.* 204, 205), which is very large considering the size of the organ to which it is distributed, comes off from the front of the external carotid, between the facial and the superior thyroid, and often by a common trunk with the facial; it passes at first obliquely upward, and then transversely inward and forward, along the upper margin of the corresponding great cornu of the os hyoides: opposite the lesser cornu of that bone it changes its direction, and runs in a serpentine course from behind forward, in the substance of the tongue as far as the apex, where it terminates by anastomosing with the artery of the opposite side; in the latter part of its course it is named, we know not why, the *ranine artery* (*g*, *fig.* 205; *rana*, a frog). Its remarkably tortuous course is connected with the liability of the tongue to undergo great changes in its relative dimensions.

Fig. 205.

Relations.—It is deeply seated, at its origin, under the digastric and stylo-hyoid muscles and the hypo-glossal nerve; opposite the os hyoides (at *n*, *fig.* 205) it is situated between the hyo-glossus (the nerve passing over that muscle) and the middle constrictor of the pharynx: in the substance of the tongue it is placed between the genio-hyo-glossus and the lingualis, and is accompanied by the lingual branch of the fifth nerve; consequently, it occupies the inferior surface of the tongue.

Collateral Branches.—A small transverse branch, the *hyoid* (*e*), forms an anastomotic arch with the vessel of the opposite side, upon the body of the os hyoides, between the genio-hyo-glossus and the genio-hyoideus.

The dorsal artery of the tongue (*f*), generally small and difficult to demonstrate; it arises opposite the great cornu of the os hyoides, ascends upon the lateral border of the tongue, near the anterior pillar of the fauces, to which it gives branches, then passes forward and inward, and giving several epiglottid branches, which anastomose with those of the opposite side, is finally distributed to the caliciform papillæ. In the whole of its course, this artery lies immediately beneath the mucous membrane.

The *sub-lingual artery* (*i*) is large enough to be regarded by some as resulting from the bifurcation of the lingual, which, according to them, takes the name of raninal only after it has furnished the sub-lingual branch. It arises as often from the facial, by a common trunk with the sub-mental, as from the lingual itself. It passes horizontally forward between the mylo-hyoideus, which separates it from the sub-mental, and the genio-hyo-glossus, and, in company with the Warthonian duct, runs along the lower border of the

sub-lingual gland, to which it furnishes numerous twigs, and then divides into two branches: the larger, or the *artery of the frænum*, anastomoses, in an arch, with the vessel of the opposite side above the frænum; while the smaller, or ascending branch, passes upon the sides of the symphysis menti, and sends twigs into the several incisor foramina, situated behind the teeth of the same name. It is this artery of the frænum, not the ranine artery, which is liable to be wounded in division of the frænum. Not unfrequently the sub-lingual artery gives off a superficial branch, which passes through the anterior belly of the digastricus, and ramifies upon the region of the chin, like the analogous branches of the sub-mental.

Lastly, in the substance of the tongue, the lingual artery gives off superior, internal, and external branches, which supply the muscles and the papillary membrane of that organ.

The Occipital Artery.

Dissection.—Detach the sterno-mastoideus and the splenius at their superior insertions. To uncover more completely this artery, which is deeply situated between the mastoid process and the transverse process of the atlas, cut with a chisel or saw the mastoid process at its base, turning it from above downward with the muscles which are inserted into it; cut the styloid process at its base, and turn the styloid muscles down. Remove carefully the skin of the occipital region, so as to enable you to follow the subcutaneous branches.

The *occipital artery* (*o o*, *fig.* 204), which is distributed to the posterior region of the head, is smaller than the three branches of the external carotid already described. It arises from the back of the external carotid, on a level with the lingual or the facial, sometimes immediately below the parotid gland: it passes obliquely upward and backward, as high as the apex of the mastoid process; it then passes horizontally backward, and on the inner side of the splenius muscle, divides into two ascending branches: one external, which immediately bends upward; the other internal, which is continued horizontally, and is then reflected vertically upward on the side of the occipital protuberance. These two branches, which are very tortuous, cover the occipital region with their numerous ramifications, and reach as high as the vertex, anastomosing with each other, and with the superficial temporal arteries.

It is situated deeply at its origin, and is covered by the digastric muscle and the hypoglossal nerve; it is still more deeply situated as it passes between the mastoid process and the atlas, where it is covered by the digastric and the sterno-mastoid; its horizontal portion is situated between the obliquus capitis superior and the splenius muscle, then between the complexus and the splenius, running along the occipital insertion of the latter muscle, on the inner side of which it becomes sub-cutaneous. The two branches into which this artery divides, and all its succeeding ramifications, are situated between the skin on the one hand, and the occipital muscle and the occipito-frontal aponeurosis on the other.

Collateral Branches.—Among a great number of small and unnamed ramusculi, we shall distinguish the following branches: a *superior sterno-mastoid artery*, which constantly exists, but is sometimes given off from the external carotid itself: it forms a curve, with its concavity directed downward, under which the hypo-glossal nerve turns; it then penetrates the deep surface of the upper portion of the sterno-mastoid: a *stylo-mastoid branch*, which is often derived from the posterior auricular artery: a *meningeal artery*, or *posterior mastoid*, which enters the cranium, either by the foramen mastoideum, the foramen lacerum posterius, or even the foramen magnum, and is distributed to the dura mater: a *cervical artery* (*princeps cervicis*), which descends between the splenius and complexus muscles, and may be followed down to the lower part of the neck; this branch is sometimes of considerable size; lastly, very often, a terminal branch, the *parietal*, which enters the cranium by the parietal foramen, and ramifies in that portion of the dura mater which forms the superior longitudinal sinus.

The Posterior Auricular Artery.

Dissection.—Avoid cutting this artery at its origin in preparing the trunk of the external carotid; turn the pinna of the ear forward; seek for the trunk of the artery between the meatus auditorius externus and the mastoid process; follow up the dissection on one side towards the origin, on the other towards the termination of this artery, being guided by the description.

The *posterior auricular artery* (*s*, *fig.* 204) is intended for the pinna, the internal ear, and the neighbouring parts of the cranium: it is usually smaller than the occipital, but is sometimes as large; it arises from the back of the external carotid, a little above the occipital, and rather often by a common trunk with that artery. It passes vertically upward, being deeply seated under the digastricus; it is then covered by the parotid gland, which it perforates to gain the posterior border of the mastoid process, upon which it divides into two branches, a *mastoid* and an *auricular*.

In this course it gives off several *parotid* and *muscular* branches, and the stylo-mastoid artery, which is sometimes derived from the occipital. The *stylo-mastoid artery*, so re-

markable for the length of its course, dips into the stylo-mastoid foramen, runs the whole length of the aqueduct of Fallopius, giving off, as it proceeds, some twigs to the internal ear, and terminates by anastomosing with a branch of the middle meningeal artery, which enters by the aqueduct of Fallopius.

The *terminal mastoid branch* of the posterior auricular passes upward and backward between the mastoid process and the skin, and subdivides into two sub-cutaneous ramusculi: one horizontal, which passes inward along the occipital attachment of the sterno-mastoid and splenius; the other ascending, which continues in the original course of the vessel, and is lost in the skin upon the outer margin of the occipitalis muscle.

The *terminal auricular branch* almost always divides into two: a *superior* and an *inferior*. The *superior* branch runs along the anterior border of the mastoid process, ramifies upon the upper half of the internal surface of the pinna, and turns round its free margin, so as to reach the external surface. The *inferior* branch passes behind the auditory meatus, supplies the lobule of the ear, insinuates itself into the fissure in the cartilage, between the helix and concha, and thus gains the external surface of the pinna, upon which it passes upward in the furrow between the helix and antihelix. It terminates by anastomosing with the superior branch.

I have seen the auricular artery of great size, to supply the place of the posterior branch of the superficial temporal.

The Parotid Arteries.

While passing through the parotid gland, the external carotid gives off four or five large branches to that organ, which deserve special description. They arise from the carotid at right angles, cross the ramus of the lower jaw also at right angles, and divide into a great number of ramifications, most of which are lost in the substance of the gland; the remainder are distributed to the skin and muscles. One or more of these branches pass between the parotid gland and the masseter muscle, parallel to the transversalis faciei artery, and reach as far as the zygomaticus major; others gain the angle of the jaw, and are lost in the supra-hyoid region.

The Inferior or Ascending Pharyngeal, or Pharyngo-meningeal Artery.

Dissection.—Make the section necessary for examining the pharynx, as described in a former part of this work when on the Anatomy of the Pharynx. The steps required for this purpose render it advisable that the study of this artery should be postponed until after that of the internal maxillary.

The *ascending pharyngeal* is the smallest branch of the external carotid: it arises from the inner side of that artery opposite the lingual. I have seen it arise from the occipital. Not unfrequently it is given off either from the angle of bifurcation of the common carotid, or from the internal carotid; and in this last case, there is almost always a very small pharyngeal branch arising from the external carotid, and passing transversely inward to the pharynx.

It varies in size to a certain degree, and, as it appears to me, in an inverse ratio to that of the palatine branch of the facial. I have seen it almost as large as the occipital.

Immediately after its commencement the ascending pharyngeal passes vertically upward, at first between the external and internal carotid, and then behind the internal carotid, with which latter vessel it is found in the triangular interval between the pharynx and the internal pterygoid muscle; it then almost immediately divides into two branches, a *meningeal* and a *pharyngeal*.

Before dividing, it gives off an *inferior pharyngeal branch*, which passes transversely inward, and subdivides into ascending and descending branches, the latter of which anastomose on the pharynx with some twigs of the superior thyroid.

The *meningeal branch*, which is situated behind the internal carotid, passes vertically upward, gives off twigs to the superior cervical ganglion of the sympathetic nerve, to the pneumogastric, glosso-pharyngeal, and hypo-glossal nerves, and to the accessory nerve of Willis, enters the cranium through the foramen lacerum posterius, and ramifies upon that portion of the dura mater which lines the inferior occipital fossa. I have seen this vessel divide into a great number of branches, one of which entered the cranium by the carotid canal, and another by the foramen lacerum anterius.

The meningeal branch, and sometimes even the trunk of the pharyngeal, gives off a *prævertebral branch*, which passes upward in front of the longus colli and the recti antici major et minor, supplying these muscles, and anastomosing with the cervicalis ascendens. I have traced a branch into the cranium through the first intervertebral foramen (*i. e.*, along the superior notch of the atlas), and another which entered the vertebral canal between the atlas and axis. I regard this prævertebral branch as supplementary to the cervicalis ascendens (a branch of the inferior thyroid), for it has a similar distribution.

The *pharyngeal branch* passes in front of the internal carotid, and having reached the base of the cranium, divides into numerous branches, which ramify in the very dense fibrous tissue found at the occipital attachment of the pharynx: they are all reflected downward, and are distributed upon the Eustachian tube and the muscles of the pharynx.

In a case in which the palatine branch of the facial artery was absent, this pharyngeal branch was very large and supplied the tonsil, and, finally, ramified in the velum palati.

The Temporal Artery.

Dissection.—Turn back the parotid gland; seek for the artery under the skin of the temporal region; follow its different collateral and terminal branches upon the cranium as far as the vertex, on the face, and on the ear.

The *temporal* or *superficial temporal artery* (*p*, *fig.* 204) appears, by its direction, to form the continuation of the external carotid. It commences opposite the neck of the condyle of the lower jaw, between it and the external auditory meatus, which is behind; it passes vertically upward, immediately behind the zygomatic arch, reaches the temporal region, where it describes some curves, still continuing its vertical course, and terminates by bifurcating at the middle, or sometimes the upper part of that region.

Relations.—It is covered at its origin by the parotid gland; it becomes subcutaneous as soon as it passes beyond the zygomatic arch, and then rests upon the temporal fascia at first, and upon the epicranial aponeurosis afterward. Its superficial position, added to its proximity to a bony surface, render it easily compressible, and explain why this artery, and especially its anterior or frontal branch, is generally chosen for arteriotomy.

Collateral Branches.—These are divided into anterior, posterior, and internal.

The Anterior Branches.—The most remarkable of these is the *transversalis faciei* (*u*), which arises from the temporal immediately after its origin, opposite the neck of the condyle of the lower jaw, and, consequently, in the substance of the parotid gland: it very often comes directly from the external carotid. It varies much in its size, which is generally in an inverse proportion to that of the facial artery. It proceeds horizontally forward, across the direction of the neck of the condyle and the masseter muscle, about six lines below the zygoma, above the Stenonian duct, which runs parallel to it. The transversalis faciei gives an articular branch to the temporo-maxillary articulation, and *several deep masseteric branches*, of which one of considerable size penetrates the back part of the muscle, and anastomoses with the masseteric branch of the internal maxillary. It also gives a small twig, which runs along the Stenonian duct. At the anterior margin of the masseter the transverse facial artery subdivides into a great number of *cutaneous*, *muscular*, and *anastomotic branches*. Among the first we should notice a *malar cutaneous branch*; and among the muscular branches, those which are distributed to the great zygomatic muscle. The muscular branches of the transversalis faciei may be traced in one direction as far as the orbicularis palpebrarum, and in another into the levator proprius labii superioris. The anastomotic branches establish an intimate communication between the temporal artery and the buccal, infra-orbital, and facial arteries.

A second anterior branch of the temporal artery also requires special notice, viz., the *orbital*, which is given off above the zygomatic arch, passes from behind forward, between the superficial and deep layers of the temporal fascia, then behind the orbicularis muscle, which it supplies, as well as the corresponding skin, and anastomoses with the superior palpebral branch of the ophthalmic. This artery is very variable in regard to size. I have seen it very large and reflected upward, between the frontalis muscle and the skin, parallel to the supra-orbital branch of the ophthalmic, and capable of being followed as far as the parietal region. From the bend which it forms by turning upward, it gives off a palpebral branch, which completes the superior palpebral arch, and also a branch which anastomoses with the supra-orbital. This orbital branch of the temporal does not exist in all subjects; the branches which it furnishes are then given off directly from the temporal.

The *posterior branches* consist of the *anterior auriculars* (*v*), which are irregular as to number: the lower branches are distributed to the lobule, the middle ones to the external auditory meatus, and the upper branches to the highest part of the pinna.

The *internal branch* is the *middle deep* or sub-aponeurotic *temporal* artery; it arises from the temporal above, sometimes on a level with the zygoma, perforates the fascia, and is distributed to the temporal muscle, anastomosing with the anterior and posterior deep temporal branches derived from the internal maxillary.

Terminal Branches.—Of the two branches into which the temporal artery divides, the *anterior* or *frontal* (*q*) passes forward and upward towards the frontal region, upon which it ramifies, anastomosing with the branches of the frontal and supra-orbital arteries, and with the temporal of the opposite side. This branch is divided in the operation of arteriotomy. The *posterior* or *parietal branch* (*y*) is larger than the anterior: it passes upward and ramifies upon the parietal bone, anastomosing with the auricular and occipital arteries, with the frontal branch of the temporal, and with the temporal of the opposite side. It is sometimes derived from the auricular artery.

The Internal Maxillary Artery.

Dissection.—Saw through the zygomatic arch in two places, and turn it downward together with the masseter muscle, taking care not to tear the masseteric artery.

Dissect the temporal muscle, and saw through the coronoid process of the inferior

maxilla. Saw through the cranium circularly, and remove the brain, which may be put into diluted nitric acid or alcohol, to be hardened for the subsequent dissection of the cerebral arteries. The artery may then be exposed in two ways, either from the outer or else from the upper wall of the zygomatic fossa.

It may be reached from the outer wall of the zygomatic fossa by sawing through the lower jaw in front of the masseter, by disarticulating the condyle, or, rather, by sawing it across its neck, and by carefully dissecting the pterygoid muscles

The artery can be reached from the upper wall by making two sections in this part of the bone, which will meet at an acute angle in the foramen spinosum of the sphenoid bone.

The branches of this artery, especially those which are enclosed in bony canals, such as the dental, the pterygo-palatine, the vidian, &c., must be dissected by carving out their courses in the bone.

A vertical section, made from before backward through the middle of the face, facilitates the examination of this artery, and enables us to see the terminations of its nasal, palatine, and pharyngeal branches.

The *internal maxillary artery* (*e, fig.* 206), little known to the older anatomists, but accurately described by Haller, is the continuation of the external carotid, at least as far as size is concerned.

Fig. 206.

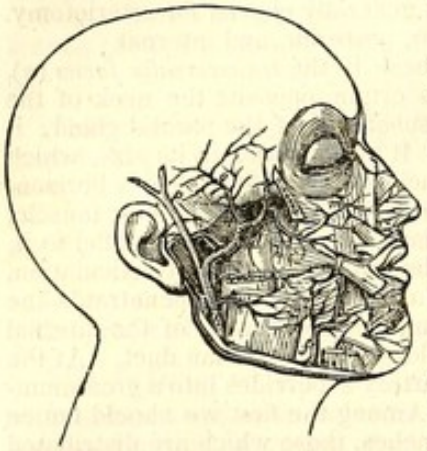

Immediately after its origin, it forms a curve, and passes deeply to the inner side of the neck of the condyle of the lower jaw.

Tortuous and horizontal in the first part of its course, it traverses the zygomato-maxillary fossa diagonally, passes forward, inward, and a little upward, to reach the highest part of the tuberosity of the superior maxillary bone, upon which tuberosity it describes a very considerable curve with the convexity turned forward, and then dips into the bottom of the zygomatic fossa, *i. e.*, the spheno-maxillary fossa, where it terminates by one or several branches, called the spheno-palatine. The tortuous course of the internal maxillary is connected with the great number of branches given off from it.

Relations.—Opposite the neck of the condyle, it is situated between the condyle, to which it is applied, and the styloid process—an important relation in a surgical point of view. Its relations in the zygomato-maxillary fossa are not very definite. Some anatomists, with Bichat and Meckel, state that it is situated between the internal and external pterygoid muscles; others, with Haller, that it is placed in front of the external pterygoid, *i. e.*, between that muscle and the temporal. Both modes of distribution are equally common, and I have even seen one existing on the right, and the other on the left side in the same subject. If the internal maxillary is situated between the pterygoids, it passes directly forward, on the outside of the dental and lingual nerves; when it has to get between the external pterygoid and the temporal, it bends downward and then upward, so as to embrace the lower half of the circumference of the external pterygoid: in this manner it gains the outer surface of that muscle, appears opposite the sigmoid notch of the lower jaw, and passes from behind forward, between the external pterygoid and temporal muscles; in both cases it passes between the two origins of the external pterygoid, in order to reach the pterygo-maxillary fissure.

Collateral Branches.—These are thirteen in number, and are divided into those arising on the inner side, and near the neck of the condyle, viz., the *tympanic*, the *middle meningeal*, and *inferior dental*, the *posterior deep temporal*, the *masseteric*, the *pterygoids*, and the small *meningeal* arteries; those arising near the maxillary tuberosity, viz., the *buccal*, the *anterior deep temporal*, the *alveolar*, and the *infra-orbital* arteries; and those arising within the spheno-maxillary fossa, viz., the *vidian* or *pterygoid*, the *pterygo-palatine*, and the *superior palatine* arteries.

Branches arising near the Neck of the Condyle.

The *tympanic* artery is a very small branch, which sometimes arises from the temporal, and sometimes from the inferior dental; it is distributed to the external auditory meatus and the temporo-maxillary articulation, and penetrates through the Glasserian fissure into the cavity of the tympanum, to the muscles and walls of which it sends its ramifications.

The *middle* or *great meningeal artery*, or spheno-spinous artery, is destined for the dura mater and the bones of the cranium; it almost always arises from the internal maxillary before the dental, but sometimes in the same situation; it passes vertically upward, behind the neck of the condyle, and gains the foramen spinosum in the sphenoid bone, through which it enters into the interior of the cranium; it is then reflected upon the anterior margin of this foramen, becomes horizontal, and divides into two branches, an *anterior* and a *posterior*. The *anterior* branch is the larger; it runs upon the outer ex-

tremity of the lesser wing of the sphenoid, and reaches the anterior angle of the parietal bone, where it is received into an imperfect, and sometimes even into a complete bony canal, and then divides and subdivides in the ramified grooves upon the internal surface of the parietal bone. Its branches may be traced even into the walls of the longitudinal sinus.

The *posterior branch* is smaller, and passes backward and upward upon the squamous portion of the temporal bone, and upon the internal surface of the parietal bone, enters into the ramified grooves upon that surface, and terminates in the dura mater and the bones of the cranium. The ultimate twigs of the middle meningeal artery anastomose with those of the opposite side, and with the branches of the anterior and posterior meningeal arteries.

Relations.—In the first part of its course, it is very deeply situated, and is in relation in front with the condyloid attachments of the external pterygoid muscle; in the cranium it is situated on the outer surface of the dura mater, between that membrane and the bones, into the substance of which it sends a number of extremely fine ramusculi. The relation of the two divisions of this artery with the two inferior angles of the parietal bone deserves notice in a surgical point of view. In consequence of its sending branches into the bones, separation of the dura mater is always followed by effusion of blood.

The middle meningeal artery also gives off some *collateral* branches. On the outside of the cranium it furnishes some unnamed twigs. Within the cranium it gives a small branch, named the *vidian*, which enters the aqueduct of Fallopius through the *hiatus Fallopii*, and supplies the facial nerve, ramifying in its neurilemma, and anastomosing with the stylo-mastoid branch of the occipital artery; some small branches, which supply the fifth or trigeminal nerve, and evidently anastomose with the meningeal branches of the internal carotid; a small twig, which enters the canal for the internal muscle of the malleus, and is distributed upon that muscle; opposite the sphenoidal fissure, several *orbital* branches, which enter the orbit at the narrowest part of that fissure, or even by proper canals in its neighbourhood; and, lastly, some rather large *temporal* branches, which pass into the great alæ of the sphenoid at their orbital surface, and anastomose in the temporal fossa with the deep temporal arteries: not unfrequently the lachrymal artery, or a small supplementary lachrymal artery, is furnished by the middle meningeal.

The *inferior dental artery* (*d*) is the artery of the lower jaw: it generally arises on a level with the middle meningeal, but sometimes before and sometimes after that vessel; it passes downward, along the inner surface of the ramus of the jaw, between the bone and the internal pterygoid, sending off branches to that muscle, but being separated from it by the fibrous band called the spheno-maxillary ligament; it thus reaches the superior orifice of the dental canal, before entering which it gives off a small branch that passes downward and forward in a groove on the inner surface of the jaw, and terminates in the mylo-hyoid muscle.

The inferior dental artery traverses the entire length of the dental canal, accompanied by the nerve of the same name. Opposite the bicuspid teeth it divides into two branches: a *mental* branch, the larger, which escapes through the mental foramen, and anastomoses with the submental artery and the inferior coronary artery of the lip; and an *incisor* branch, which continues in the original course of the artery, passes beneath the canine and incisor teeth, and is lost in the diploë opposite the symphysis.

During its course, the dental artery, as well as its incisor branch, gives off a great number of twigs, which are lost in the diploë of the bone; and a series of *dental branches*, which correspond in number with the roots of the teeth, penetrate into the alveoli, and from thence into the teeth through the foramen observed at the apex of each fang.

The *posterior deep temporal artery* (*g*) arises opposite the sigmoid notch, passes vertically upward between the external pterygoid and the temporal muscles, gains the posterior border of the latter muscle, gets between that border and the temporal fossa, remains in contact with the periosteum, and then divides and subdivides so as to terminate partly in the temporal muscle and partly upon the periosteum, anastomosing with the middle and anterior deep temporal arteries. It often gives off the masseteric, and sometimes the buccal artery.

The *masseteric artery* is a small branch, the size of which is inversely proportioned to that of the masseteric branch of the transversalis faciei. It often arises by a common trunk with the posterior deep temporal, passes outward in front of the condyle, and, therefore, in the notch between the condyle and the coronoid process, and enters the internal surface of the masseter, in which muscle it anastomoses with the masseteric branches given off by the transversalis faciei and facial arteries.

The *pterygoid arteries* are irregular in number; some of them arise directly from the internal maxillary, others from the posterior deep temporal and the middle meningeal.

The *small meningeal artery* is not constant, but I have seen it in one case as large as the middle meningeal; it arises at the same height as the inferior dental, passes between the pterygoid muscles, and divides into two branches, one of which turns round the origin of the internal pterygoid, and terminates in the velum palati and the nasal fossæ; and another, which passes vertically upward, between the external pterygoid and the

upper wall of the zygomatic fossa, enters the cranium by the foramen ovale, and supplies the trigeminal nerve and the dura mater, anastomosing with small branches given off from the internal carotid.

Branches arising near the Tuberosity of the Superior Maxillary Bone.

The *buccal artery* (*h*) is a small branch of variable size, and sometimes exists only in a rudimentary state. It rather frequently arises by a common trunk with the superior dental artery, passes in a tortuous course from behind forward, between the ramus of the lower jaw and the internal pterygoid muscle, emerges in front of the ramus, and is lost in the buccinator muscle, anastomosing with the buccal branches of the facial and transversalis faciei.

The *anterior deep temporal artery* (*i*) is of considerable size: it passes vertically upward, along the anterior border of the temporal muscle, with which it is in contact, is lost in that muscle, anastomosing with the posterior deep temporal and the middle temporal. It gives off some extremely delicate orbital branches, which traverse the canals in the malar bone, and are lost in the adipose tissue of the orbit.

The *alveolar* or *superior dental* (*l*) often arises by a common trunk with the infra-orbital, passes in a very tortuous manner forward and downward upon the tuberosity of the superior maxilla, and divides into several branches; some of these, having reached the alveolar border, are reflected upon the margins of the alveoli, pass into their cavities, and ramify in the alveolo-dental periosteum; other branches enter the small posterior dental canals, penetrate into the alveoli of the molars and bicuspids, and divide into as many ramusculi as there are roots to each of those teeth. Several of these branches penetrate into the maxillary sinus. I have seen one which ran along this sinus from behind forward near its lower wall, was reflected upward on the anterior wall of the same cavity, and entered the base of the ascending process of the superior maxilla, at which point I could no longer follow it. This branch was situated between the lining membrane of the sinus and the bones. All the divisions of the alveolar artery furnish branches to the superior maxillary bone, and, at the same time, supply them to the corresponding teeth. Lastly, some very delicate twigs of the superior dental artery enter the buccinator muscle.

The *infra-orbital artery* arises from the internal maxillary opposite the spheno-maxillary fissure, sometimes alone, sometimes by a common trunk with the superior dental, immediately enters and then traverses the infra-orbital canal, emerges at the infra-orbital foramen, and divides into a great number of branches (*m*), which are distributed to the skin and mucous membrane of the cheek, anastomosing with the facial artery, the transversalis faciei, and the alveolar and buccal branches just described. Several branches enter the alveoli of the canine and incisor teeth at their borders: others penetrate into the nasal fossæ at the nostril.

During its course, the infra-orbital artery furnishes a very remarkable branch, which enters the cavity of the orbits, where it divides into two branches, one of which passes directly forward, and is lost in the lower eyelid, while the other, which is larger, turns inward, and inosculates with the inferior palpebral branch of the ophthalmic artery; another branch of the infra-orbital artery enters the anterior dental canal, to supply the canine and incisor teeth, penetrating into the foramina at the points of their fangs, in the same way as in the other teeth.

Branches arising in the Pterygo-maxillary Fossa.

The *vidian* or *pterygoid artery* is a very small vessel, which, immediately after its commencement, enters the vidian canal, traverses its whole length, and then ramifies in the pharynx and around the Eustachian tube.

The *pterygo-palatine artery* is as small as the preceding, below and to the inner side of which it is situated: it traverses the pterygo-palatine canal, and terminates in the pharynx and on the Eustachian tube. It sometimes arises from the spheno-palatine artery.

The *superior palatine artery* is larger than the preceding branches, and pursues a downward course: it arises opposite the pterygo-maxillary fissure, passes vertically downward, enters the posterior palatine canal, and, having emerged from its inferior orifice, is reflected from behind forward, advances in a tortuous manner (*r*, *fig.* 205) between the hard palate and the mucous membrane, in the groove which runs along the alveolar border, and forms an anastomotic arch in the median line, with the palatine artery of the opposite side. Before entering the posterior palatine canal, it gives off some branches, which run through the accessory palatine canals, and ramify upon the velum palati. While upon the hard palate, it sends off branches, which are distributed to the glands of the mucous membrane; others, which are distributed to the gums, and enter at the margins of the alveoli, and supply the alveolo-dental periosteum; and, lastly, a small *nasal branch* (*t*, *fig.* 205), which enters the anterior palatine canal, bifurcates above like that canal itself, so as to penetrate into each of the nasal fossæ, and anastomoses with the spheno-palatine artery of both sides.*

* There are, in the interior of the bones of the face, as in all spongy bones, true arterial canals, the study of which is not less important than that of the venous canals found in similar situations.

Terminal Branch of the Internal Maxillary Artery.

This is named the *spheno-palatine;* it is a large vessel, often multiple, and is intended exclusively for the pituitary membrane; it passes from below upward, in a tortuous manner, to penetrate the corresponding nasal fossa, by the spheno-palatine foramen, that is, at the back part of the superior meatus, where it immediately divides into two branches: one internal (*s*, *fig.* 205), which passes obliquely downward and forward, covers the septum with a complicated network, and anastomoses in front with the nasal branch of the superior palatine; the other external, which divides into three ramusculi for the three meatuses, and ramifies in them and upon the turbinated bones. Some of the twigs enter the sphenoidal and maxillary sinuses, the posterior and the anterior ethmoidal cells, the frontal sinus, and the lachrymal canal

All these arteries form areolæ of different sizes in the pituitary membrane, and give it, in successful injections, a reticulated aspect; they are situated between the periosteum and the pituitary membrane, properly so called. The arteries of the turbinated bones are lodged in the areolar cells on the surface of those bones, and in the arterial canals which are hollowed out of them

Summary of the Distribution of the Internal Maxillary Artery

The internal maxillary sends branches to the organs of mastication and deglutition, to the nasal fossæ, to the bones and fibrous membranes of the cranium, to the face, and to the organ of hearing. Its different branches are distributed in the following manner:

To the passive instruments of mastication, viz., the jaws and teeth, the *inferior dental*, the *superior dental*, and the *infra-orbital arteries;* to the active organs concerned in that process, the *masseteric*, the *anterior* and *posterior deep temporal*, and the *pterygoid arteries.*

To the organs of deglutition, viz., the hard and soft palate and the pharynx, the *superior palatine*, the *small meningeal*, the *vidian*, and the *pterygo-palatine arteries.*

To the nasal fossæ, some branches of the *infra-orbital*, and the whole of the *spheno-palatine artery;* the latter vessel, and, consequently, the internal maxillary artery also, are very large in those animals which have a highly-developed olfactory apparatus.

To the organ of hearing, the *tympanic artery*, *those branches of the middle meningeal* which enter the hiatus Fallopii, and also those which enter the canal of the internal muscle of the malleus.

To the face, viz., to the muscles and integuments, the *buccal*, the *infra-orbital*, and the *mental arteries.* The region of the eye is the only part not supplied by the internal maxillary.

To the bones of the cranium, and to the dura mater, the *middle and the small meningeal arteries.*

THE INTERNAL CAROTID.

Dissection.—The simplest method of exposing this vessel is to make the section for examining the pharynx. The carotid canal must be opened with a chisel, and the outer wall of the cavernous sinus removed.

The *internal carotid* is distributed to the anterior part of the brain, and to the eye and its appendages.

It is one of the two branches into which the common carotid divides: situated, at its origin, on the outside of the external carotid, it passes sometimes vertically upward, parallel to, and in contact with, that artery, and sometimes behind it, by crossing it at an acute angle opposite the digastric muscle; it then leaves the external carotid to pass deeply into the triangular space between the pharynx and the ramus of the lower jaw, and reaches the base of the cranium, into which it penetrates by the carotid canal. After emerging from this canal, it is situated in the cavernous sinus, upon the sides of the sella turcica, is reflected upward on the inner side of the anterior clinoid process, and terminates by dividing into three branches.

The size of this artery, which is always exactly proportioned to that of the brain, is, in the adult, equal to that of the external carotid; in the infant it is much larger (ramus grandior carotidis, *Vesal.*). In man, as in the whole series of animals, the relative size of the internal and external carotids is determined by the relative development of the brain and the face. The internal carotid is remarkable for retaining the same diameter from its commencement to its termination.

Its *direction* is generally straight until it reaches the base of the cranium, but sometimes it describes a single curve immediately after its commencement, sometimes several curves having opposite directions. At the base of the cranium, before entering the carotid canal, it becomes horizontal, and then vertical and ascending.

In traversing the carotid canal, it follows the angular course of that passage; in the cavernous sinus, it passes directly forward and upward, like the carotid groove; at other times it describes two distinct curves; lastly, on the inside of the anterior clinoid process, it is reflected directly upward and a little backward. The double curvature which it describes in traversing the carotid canal and the cavernous sinus has been well compared to the Roman letter S. The numerous inflections of the internal carotid form

one of the most decided arguments in favour of the opinion that the use of these windings is to retard the passage of the blood.

Relations: from its Origin to the Base of the Cranium.—At its *origin*, the internal carotid is situated as superficially as the termination of the common carotid, and is crossed by the hypoglossal nerve and the occipital artery; it soon passes behind the external carotid, and becomes deeper and deeper Protected by its position in the triangular space, which is bounded on the inside by the pharynx, and on the outside by the ramus of the lower jaw, it rests behind upon the vertebral column, from which it is separated by the prævertebral muscles and aponeurosis: it is in relation in front and to the outer side with the stylo-glossus and stylo-pharyngeus muscles, which pass between it and the external carotid; on the inside, with the pharynx; and on the outside and behind, with the internal jugular vein The ascending pharyngeal artery is, moreover, in relation with it behind, and the great sympathetic nerve on the inside: the pneumogastric, glosso-pharyngeal, and hypoglossal nerves are situated behind the internal carotid at their exit from the cranium, but soon get to its outer side, between it and the internal jugular vein.

The relation of the artery with the external surface of the pharynx explains how this vessel may be wounded from the interior of that cavity. Sometimes one of its curves approaches the region of the tonsil; and this may, perhaps, have been the case when the artery has been wounded by an instrument directed transversely outward and carried into the tonsil, either to open an abscess or to excise the gland.

In the *carotid canal*, the artery is in relation with the nervous filaments ascending from the superior cervical ganglion. A very thin fibrous lamina, a prolongation of the dura mater, separates the vessel from the bony walls of the canal. Its proximity to the internal ear while traversing the petrous portion of the temporal bone, is probably the cause of the arterial pulsations which are heard in certain cases.

In the *cavernous sinus*, the artery is applied against the inner wall of that cavity, and is, therefore, placed on the inner side of the nerves which pass through the sinus, and more particularly of the sixth pair; it is said that the artery is not bathed in the blood contained in the sinus, but is protected from it by a very thin layer of membrane, continuous with the internal coat of the veins. However careful I may have been, I have never succeeded in separating this membrane.

On the inner side of the anterior clinoid process, the artery is upon the outer side of the optic nerve; and at the point where it emerges from the dura mater, above the anterior clinoid process, it is received in a sheath formed by the arachnoid.

Branches of the Internal Carotid.—On the outside of the cranium it gives off no branch, excepting in a few cases where it furnishes the ascending pharyngeal, or, rather, only a supplementary pharyngeal branch; and, lastly, when it gives off the occipital. In the carotid canal, it sends a twig into the cavity of the tympanum by a special opening. In the cavernous sinus, it furnishes several small branches (*arteriæ receptaculi*), some of which are reticulated, and distributed to that portion of the dura mater which lines the basilar surface of the occipital bone, and to the walls of the inferior petrosal sinus; while others ramify upon the pituitary body, the fifth pair of nerves, and the adjacent portion of the dura mater: a larger branch anastomoses with the middle meningeal artery.

Lastly, on the inner side of the anterior clinoid process, just as it passes above that process, the internal carotid gives off in front a remarkable artery, named the *ophthalmic*.

The Ophthalmic Artery.

Dissection.—Make a partial injection, either from the common or internal carotid. Remove the roof of the orbit, after having carefully detached the integuments and periosteum of the frontal region: leave a small bridge of bone on the inner part of the margin of the orbit for the supra-orbital artery, or, rather, open the supra-orbital foramen and disengage the artery from it. Dissect the muscles of the eye with great care, preserving all the vessels which present themselves. The study of the branches of the ophthalmic artery, which are distributed to the ball of the eye, requires a perfect knowledge of that organ.

This artery is principally destined for the eye and its appendages, and is less remarkable for its size, which is inconsiderable, than for the number of its branches. Immediately after its origin, it enters the optic foramen (*b*, *fig.* 207), on the outer side of and below the optic nerve.* The artery is at first contained in the same sheath as the nerve, but, soon escaping from it, penetrates into the orbit between the abducens oculi nerve and the external rectus muscle of the eye, turns inward and crosses the optic

* A very remarkable variety in the origin of the ophthalmic artery is that in which this artery arises by a common trunk with the middle meningeal or arteria media dura matris, which is a branch of the internal maxillary. In a case of this kind, which has been communicated to me by M. Dubreuil, the ophthalmic artery arose from the anterior branch of the meningeal; when this branch reached the canal at the anterior inferior angle of the parietal bone, it entered the orbit by the external extremity of the foramen lacerum orbitale, and successively gave off the branches furnished by the ophthalmic artery.

nerve, sometimes at right angles and sometimes obliquely, and is then placed above the nerve. Having reached the inner wall of the orbit, it again changes its direction, passes horizontally and in a slightly tortuous manner along the lower border of the superior oblique muscle of the eye, and terminates by bifurcating at the margin of the orbit. Not unfrequently, the ophthalmic artery, immediately after its origin, is placed on the inner side of and below the optic nerve, and then passes directly forward along the inner side of that nerve; so that, in these cases, the nerve and artery do not cross each other.

Fig. 207.

The ophthalmic artery gives off a great number of branches, which, according to their origin,* may be divided into those arising on the outside of the optic nerve, viz., *the lachrymal artery and the central artery of the retina*; those arising above the nerve, viz., *the supra-orbital, the short ciliary, the middle or anterior ciliary, the superior and the inferior muscular arteries*; those arising on the inner side of the optic nerve, viz., *the posterior and anterior ethmoidal and the inferior and superior palpebral arteries*; in all, eleven branches, to which may be added the terminal branches, viz., *the nasal and the frontal arteries*. It is well to remark, that the origins of most of the above-named branches are subject to extreme variety.

Branches arising on the Outer Side of the Optic Nerve.—The *lachrymal artery* (*c*, *fig.* 207), one of the largest branches of the ophthalmic, arises immediately before the entrance of the latter into the orbit. Not unfrequently it is given off from the middle meningeal artery.

The lachrymal artery passes from behind forward along the outer wall of the orbit, between the periosteum and the external rectus muscle, and enters the lachrymal gland (*l*), supplying it with a great number of branches. Emerging from the gland very much reduced in size, it terminates partly in the conjunctiva, and partly in the structures composing the upper eyelid.

In its course it sometimes gives off a small meningeal branch, which passes backward through the sphenoidal fissure, and enters the dura mater, in which it anastomoses with the middle meningeal artery. This branch may be considered, in some subjects, as one origin of the lachrymal artery; a condition that leads to those cases in which the lachrymal artery arises from the middle meningeal. It often gives off a long ciliary artery, and always some twigs to the neurilemma of the optic nerve, and muscular branches to the levator palpebræ superioris and the superior rectus; lastly, it furnishes a muscular branch, the *malar*, which perforates the malar bone, and anastomoses in the temporal fossa with the anterior deep temporal artery, and upon the malar bone itself with the transversalis faciei.

The *central artery of the retina* (*arteria centralis retinæ*, *i*), quite distinct from the twigs supplied to the neurilemma of the optic nerve, is an extremely delicate vessel: it arises either from the ophthalmic, or from one of the ciliary arteries, penetrates obliquely into the substance of the nerve, runs along its centre from behind forward, enters into the globe of the eye, and expands in diverging ramifications, which are applied to the internal surface of the retina, and accompany it as far as the ciliary processes. A branch very distinct from those just mentioned traverses the vitreous body from behind forward, in the axis of the eye, and reaches the capsule of the crystalline lens, after having furnished some extremely fine twigs to the hyaloid membrane.

Branches arising above the Optic Nerve.—The *supra-orbital* or *superciliary* artery (*d*) arises from the ophthalmic as that vessel is crossing the optic nerve; it is sometimes given off from the lachrymal. It is very variable in size, and appears in certain cases to be partially replaced by the orbital branch of the temporal, or by the frontal branch of the ophthalmic. It passes horizontally between the periosteum of the roof of the orbit and the levator palpebræ superioris, accompanied by the frontal nerve; it escapes from the orbit at the superciliary notch, is reflected over it as over a pulley, ascends vertically, and divides into two branches, one of which passes upward between the skin and the orbicularis and occipito-frontalis muscles, and the other is situated between the muscles and the periosteum, and ramifies in that membrane. The sub-cutaneous branch often divides into an internal and an external twig. It is also said constantly to furnish a branch to the diploë of the frontal bone, as it is passing through the superciliary notch. It appears to me that this branch is often wanting.

The *ciliary arteries* may be divided into the *posterior* or *short*, the *middle* or *long*, and the *anterior*.

The *posterior ciliary* arteries (*r*) distributed to the choroid coat and the ciliary processes (artères uvéales, *Chauss.*) are irregular in number which is stated to be thirty, or even

* The branches given off by the ophthalmic artery might be more philosophically divided as follows: 1st. Those which are destined to the globe of the eye, viz., the arteries of the retina, the short ciliary or choroidian, the middle or long ciliary, and the anterior ciliary; 2d. Those which are distributed to the parts contained in the orbital cavity, lachrymal and muscular arteries; 3d. Those which are on the outside of the orbital cavity, the palpebral, sub-orbital, ethmoidal, frontal, and nasal arteries.

forty; they arise from two trunks: one inferior, which is given off from the ophthalmic artery on the outer side of the optic nerve; the other is superior, and arises above that nerve. Not unfrequently the lachrymal artery gives off the inferior long ciliary trunk. They run in a very tortuous course along the optic nerve, and, having reached the ball of the eye, twist spirally and immediately expand into a tuft of tortuous ramusculi, which surround the optic nerve, perforate the sclerotic coat around the entrance of the nerve, and then ramify, as will be elsewhere stated, in the choroid coat and ciliary processes.

The *middle* or *long ciliary* arteries (artères iriennes, *Chauss.*), which are distributed to the iris, are two in number, an internal and an external; they perforate the sclerotic at some distance from the optic nerve, and pass between the sclerotic and the choroid membrane on the sides of the eyeball. Having reached the ciliary ring, each of them divides into two branches, which anastomose together, and form the great vascular circle of the iris. Numerous radiating branches proceed from all points of the inner border of this circle towards the free margin of the iris, where they subdivide and anastomose to form the lesser vascular circle of that membrane.

The *anterior ciliary arteries* are irregular in number, and are derived from the muscular branches, and sometimes from the lachrymal and infra-orbital; they give some branches to the conjunctiva, penetrate the sclerotic at a short distance from the cornea, and terminate in the great circle of the iris.

The *muscular arteries* are two, viz., the superior and the inferior. The *superior* is the smaller: it is often wanting, and is then replaced by branches from the lachrymal, infra-orbital, or ciliary arteries. It is distributed to the levator palpebræ superioris, the superior rectus, and the obliquus superior. The *inferior*, which always exists, passes from behind forward between the optic nerve and the inferior rectus, gives off most of the anterior ciliary arteries, and is distributed to the external and inferior recti, and to the obliquus inferior. Sometimes the inferior muscular is not entirely distributed to the muscles, but forms an anastomotic arch with the infra-orbital branch of the internal maxillary.

Branches arising on the inner Side of the Optic Nerve.—The *ethmoidal arteries* are two, viz., the anterior and the posterior. The posterior ethmoidal (*e*) is given off the first from the ophthalmic, and is sometimes as large as the continuation of that artery: at other times merely a trace of it exists. It runs from without inward, passes through the posterior internal orbital canal to reach the ethmoidal groove within the cranium, and then divides into a *meningeal* and a *nasal* branch. The meningeal ramifies in the dura mater, particularly in the falx cerebri; the nasal branch enters the nasal fossa, through the foramina of the cribriform plate, and anastomoses with the ultimate divisions of the spheno-palatine artery.

The *anterior ethmoidal* (*f*) is inversely proportioned, as regards size, to the posterior artery, which is sometimes replaced by it; it enters the cranium through the anterior internal orbital canal, and divides into a *meningeal branch*, distributed upon the falx cerebri, and a *nasal branch*, which penetrates the olfactory cavities by the foramina of the cribiform plate. The branches to the falx are remarkably tortuous.

The *palpebral arteries* are divided into the *superior* and the *inferior*. Both arise from the ophthalmic, opposite the cartilaginous pulley of the superior oblique. Sometimes they arise by a common trunk. Most commonly the inferior palpebral is given off a little before the superior. Sometimes the superior is so large that it appears to result from a division of the ophthalmic itself into two equal branches.

The *inferior palpebral* passes vertically downward, behind the tendon of the orbicularis muscle, proceeds outward to reach the lower eyelid, along the whole length of which it runs in the form of an arch without any winding, and is gradually lost at the external canthus or angle of the eyelids.

The vascular arch thus formed, the *inferior palpebral*, is situated between the muscular fibres of the eyelid and the tarsal cartilage, immediately below the free border of that cartilage.

At the point where it enters the eyelid, it gives off a very remarkable branch, which anastomoses with the orbital branch of the infra-orbital artery. From the arch of anastomosis a branch arises, which enters the nasal duct (*branch of the nasal duct*), and ramifies in the mucous membrane of that passage, as far as the inferior meatus.

The *superior palpebral* passes downward behind the orbicularis palpebrarum, and, having reached the superior punctum lachrymale, is reflected outward, between the muscular fibres and the tarsal cartilage, immediately above its free border, along which it forms an arch, and terminates by anastomosing with a palpebral branch derived from the superficial temporal.

Terminal Branches of the Ophthalmic.—At the anterior extremity of the angle formed by the upper and internal walls of the orbit, the ophthalmic artery terminates by dividing into a *nasal* and a *frontal* branch.

The *nasal branch* varies in size, and is often larger than the ophthalmic artery itself, so that some anatomists have regarded it as a branch of the facial, with which it always anastomoses. It emerges from the orbit above the tendon of the orbicularis, and hav-

ing given off a small branch, which afterward enters the groove in the os unguis, to be distributed to the mucous membrane of the lachrymal sac, it divides into two branches: one, named the *angular artery*, runs in the groove formed by the nose and cheek, between the pyramidalis nasi and the levator labii superioris alæque nasi; it is accompanied by the vein, which lies to its outer side, and it is continuous with the facial artery, without any line of demarcation, the two vessels inosculating so completely, that it is impossible to define their respective limits: the other branch, the *dorsal* artery of the nose, runs along the dorsum of the nose, and terminates opposite each ala by anastomosing with its corresponding artery. These two divisions of the nasal branch of the ophthalmic are sub-cutaneous, and give off numerous ramifications, which cover the whole surface of the nose.

The *frontal branch* is smaller than the nasal, and generally smaller than the supra-orbital or superciliary; it passes upward upon the forehead, parallel to the supra-orbital, with which it communicates above by a transverse branch; it divides into sub-cutaneous twigs, situated between the skin and the muscles, and into muscular and periosteal twigs.

Summary of the Distribution of the Ophthalmic Artery.—The ophthalmic sends branches to the ball of the eye, to its appendages, viz., the muscles, eyelids, and lachrymal apparatus, to the frontal region, and to the nose and nasal fossæ.

To the ball of the eye it gives the arteria centralis retinæ, which supplies the retina, the hyaloid membrane, and the capsule of the crystalline lens; the posterior, middle, and anterior ciliary arteries, which are distributed to the choroid membrane, the ciliary processes, and the iris.

It supplies proper muscular branches, and also twigs from its other branches, to the muscles of the eye.

To the eyelids it gives off the palpebral arteries. To the lachrymal apparatus it supplies the lachrymal artery for the gland, and the two branches for the lachrymal sac and the nasal duct.

The frontal region receives its frontal and supra-orbital branches; the nose, the nasal branch, and the nasal fossæ, the anterior and posterior ethmoidal arteries.

The Cerebral Branches of the Internal Carotid Artery.

When the internal carotid has given off the ophthalmic artery, it enters (*c*, *fig.* 208) a deep fossa seen on the base of the brain at the inner end of the fissure of Sylvius, and immediately divides into three branches, which spread out from each other.

Fig. 208.

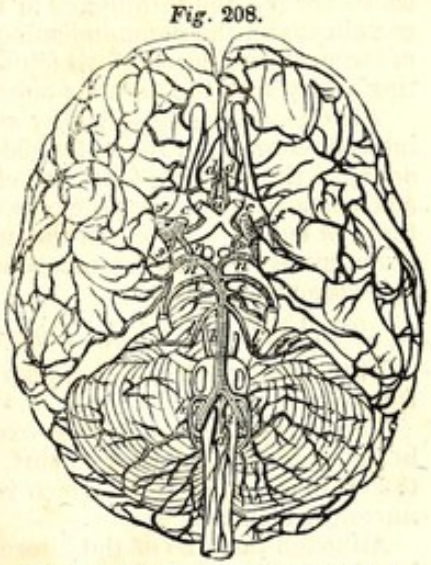

Of these three branches, the anterior is called the *anterior cerebral*, or *artery of the corpus callosum*; the external is named the *middle cerebral*, or *artery of the fissure of Sylvius*; and the third, or posterior, is the *posterior communicating artery*.

Not unfrequently the carotid gives origin to the posterior cerebral artery, from which, in that case, the posterior communicating artery is then given off, and immediately joins the anterior extremity of the basilar artery.

The Anterior Cerebral Artery. Dissection.—The study of these arteries requires no preparation; it is sufficient to overturn the brain in a manner which will bring its base into view. Each artery will be recognised by the following description: This vessel (*d d*, *fig.* 208), also called the *artery of the corpus callosum*, passes, immediately after its origin, forward and inward, towards the median line, and thus reaches the longitudinal fissure between the right and left anterior lobes of the brain. There it approaches its fellow of the opposite side, and communicates with it by a transverse branch, which passes at right angles between them. This anastomotic branch (*a*), so remarkable for its size, shortness, and direction, is called the *anterior communicating artery*; instead of one, there are sometimes two smaller branches; sometimes it is so short that the two anterior cerebral arteries may be said to be applied to each other, and blended together at this point: most commonly it is from one to two lines in length, and it then gives off some small twigs, which penetrate into the third ventricle.

After communicating in this manner, the anterior cerebral arteries become parallel, run from behind forward, turn upward in front of the anterior extremity of the corpus callosum, and then run backward upon its upper surface, as far as its posterior extremity, describing a curve, which exactly corresponds with that of the corpus callosum itself.

Before turning over the anterior border of the corpus callosum, the anterior cerebral arteries give off some ramusculi to the optic and olfactory nerves, to the third ventricle, and the adjacent part of the anterior lobe of the brain, and also a series of large branches, which are distributed to the inferior surface of the same lobe. At the point

where the arteries are reflected, and also along the upper surface of the corpus callosum, large branches arise from the convexity of the curve described by these vessels, and ramify upon the inner surface of the two hemispheres : the anterior branches run from behind forward, and the others from before backward, and from below upward ; most of them reach the convex surface of the brain. Some capillary twigs proceed from the concavity of the curve, and penetrate the substance of the corpus callosum.

We may regard as the termination of each anterior cerebral artery a very small branch which continues in the same course, reaches the posterior extremity of the corpus callosum, is there reflected downward, and terminates in the adjacent convolutions of the brain.

The Middle Cerebral Artery.—This is larger than the preceding vessel ; it passes (*f*, *fig.* 208) outward and backward to enter the fissure of Sylvius, having previously given off a great number of rather large branches, which run perpendicularly upward into the very thin layer of cerebral substance situated at the junction of the longitudinal fissure of the brain with the fissure of Sylvius.*

As soon as the middle cerebral artery has entered the fissure of Sylvius, it divides into three branches : an anterior, which is applied to the anterior lobe ; a posterior, which lies upon the middle lobe ; and a median branch, which corresponds to the small lobe that is concealed within the fissure : they all follow the direction of this fissure, and are concealed within it, but soon emerge so as to ramify upon the convolutions and anfractuosities of the brain, anastomosing with each other, and with the branches of the anterior and posterior cerebral arteries.

It is of importance to remark, and this observation applies to all the cerebral arteries, that the arterial ramifications destined for the surface of the brain are extremely tortuous, that they dip into the anfractuosities, and cover the free borders and the two surfaces of the convolutions, between which they are situated ; that they ramify very freely, and run a very extensive course ; and that they do not divide gradually into smaller and smaller branches, but that bundles of very fine capillary vessels arise from every part of the circumference of vessels of a certain size, and immediately penetrate the cerebral substance.

The Posterior Communicating Artery, or Communicating Artery of Willis.—This artery varies exceedingly in size, being generally small, but sometimes forming the largest division of the internal carotid. It arises from the back of the carotid, runs from before backward (*r*), and terminates in the posterior cerebral branch of the basilar artery. In certain cases, the communicating artery of Willis may be regarded as the chief origin of the posterior cerebral, which then seems to result from the union of this communicating artery with the anterior bifurcation of the basilar.

The Choroid Artery.—A very small but constant branch (*s*) arises from the back of the internal carotid, on the outer side of the communicating artery of Willis. This is the *artery* of the *choroid plexus*, which passes backward and outward, along the optic tract, and, consequently, along the crus cerebri, to both of which it sends branches, and then enters the lateral ventricle at the anterior extremity of the great transverse fissure of the brain, gives twigs to the hippocampus major and corpus fimbriatum, and terminates in the choroid plexus.†

Summary of the Distribution of the Common Carotid Arteries.

The common carotids are distributed to the head, and to the organs which occupy the front of the neck.

The *internal carotid* belongs exclusively to the brain, and to the organs of vision ; and hence, doubtless, at least in part, arises that intimate relation between the condition of the brain and of the eye, which is expressed by the common saying, that the eye is the mirror of the soul.

Although the size of the internal carotid is almost always in proportion to that of the brain, yet this artery is not the only one by which that organ is supplied with blood. The vertebral artery, a large branch of the subclavian, completes the arterial system of the brain ; and the fact of an artery, principally destined for the upper extremity, also sending a branch to the brain, proves that there is nothing peculiar in the quality of the blood transmitted to the encephalon.

We have already seen that the ophthalmic artery communicates by its nasal branch with the facial artery, and by its inferior palpebral branch with the infra-orbital branch of the internal maxillary. But the internal carotid has no direct communication with the external, unless when it gives origin to the ascending pharyngeal and the occipital arteries. I may remark, however, that some meningeal branches are given off by the internal carotid within the cavernous sinus.

The *external carotid* differs from the internal, in giving origin to a very great number of branches, which are distributed to the face, to the parietes of the cranium, to the organs of respiration, and, lastly, to the organs of digestion.

The *facial* branches may be divided into the superficial and the deep-seated.

* We shall see hereafter that this region of the brain belongs to the corpus striatum.

† See vertebral artery (p. 533), for the completion of the arterial system of the encephalon.

The *superficial* arteries of the face are derived from many sources. The principal one is furnished by the facial or external maxillary; the others are the transverse artery, or transverse arteries of the face, coming from the temporal; the nasal, a descending branch of the ophthalmic; the buccal, masseteric, infra-orbital, and mental—all derived from the internal maxillary. The arteries of the right side communicate very freely and fully with those of the left; and on each side, branches from the different sources communicate as freely with each other; so that, in hemorrhage from any of them, the injured vessel must be tied on both sides of the wound. I may call attention to the abundance of arterial vessels in the face, and to the number and size of the muscular and cutaneous branches; this is evidently connected with the extreme susceptibility of the skin of this region, the existence of the *hair-bulbs*, and the action of the muscles in giving expression to the features.

The *deep* arteries of the face are principally derived from the internal maxillary. Thus, the spheno-palatine supplies the nasal fossæ: some branches of the infra-orbital enter the orbit. We shall afterward allude to the branches which are furnished to the buccal cavity and the zygomatic and spheno-maxillary fossæ. Lastly, the superficial and deep arteries of the face are united by numerous anastomoses.

The *first set of cranial branches*, derived from the external carotid, are the *arteries of the hairy scalp*, viz., the occipital, temporal, posterior auricular, supra-orbital, and frontal. With regard to these arteries, it is important to notice their large size, which is connected with the great vitality of the skin of the head, and with the existence of the bulbs of the hair; also, that they are extremely tortuous, which appears to me to be in correspondence with the great number of branches which they give off; and, lastly, that they are situated in the dense cellular tissue which connects the skin with the muscles and the epicranial aponeurosis.

Besides these, small branches are found upon the pericranium, under the muscles and epicranial aponeurosis: they are seen on the forehead, where they arise from the frontal and infra-orbital arteries, and also in the temporal region, where they are called the deep temporals; these branches are both periosteal and muscular.

The *second set* of branches to the cranial parietes are *arteries of the interior of the cranium*, viz., the meningeal, the chief of which is the middle meningeal, a branch of the internal maxillary: the others, or small meningeals, enter through most of the foramina at the base of the cranium. Among these latter we would mention the meningeal branches of the ascending pharyngeal artery, and meningeal branches from the ethmoidal arteries, to which may be added some small twigs given off from the internal carotid, while enclosed in the cavernous sinus.

We may also refer the arteries of the organ of hearing to those of the cranial parietes. They are the posterior auricular and the anterior auricular, which are distributed to the pinna and to the external meatus; the tympanic, which passes through the fissure of Glasserus, and a small branch of the middle meningeal, which enters through the hiatus Fallopii.

The branches of the external carotid distributed to the organs of digestion belong to the following parts:

To the organs of mastication, viz., the alveolar, the infra-orbital, and the inferior dental arteries, which go to the teeth and the jaws; the superior palatine, which supplies the roof of the palate; and, lastly, the deep temporal, the masseteric, and the pterygoid, which are distributed to the muscles of mastication. To the salivary organs: thus, the parotid receives its branches from the external carotid and the temporal; the sub-maxillary gland from the facial; and the sub-lingual gland from the sub-lingual branch of the lingual artery. To the velum palati and the tonsils we find the ascending or inferior palatine branch of the facial artery, the superior palatine branch of the internal maxillary, and the ascending pharyngeal. To the pharynx, the pharyngeal twigs from the superior thyroid, the ascending pharyngeal, the pterygo-palatine or superior pharyngeal, and the vidian from the internal maxillary, and the inferior palatine branch of the facial. To the œsophagus there are the descending œsophageal branches of the superior thyroid.

The branches given by the external carotid to the air-passages are the superior and inferior laryngeal, from the superior thyroid artery, which is essentially distributed to the thyroid gland.

Artery of the Upper Extremity.

A single arterial trunk, called the *brachial trunk* (*Chaussier*), is destined for the upper extremity. On the left side it arises directly from the arch of the aorta, and on the right side from the innominate artery; it emerges from the thorax, between the first rib and the clavicle, traverses the axilla, runs along the inner side of the arm, passes in front of the elbow-joint, and divides into two branches, which supply the forearm and the hand.

As the brachial trunk has some highly important relations during its course, and, moreover, furnishes a very great number of branches, it has been artificially divided, in order to facilitate its study: each of the divisions has received a particular name, according to the region through which it passes: thus, the artery of the upper extremity

is called successively the *sub-clavian*, the *axillary*, and the *humeral* artery; and its terminal divisions are named the *radial* and *ulnar arteries*.

The Brachio-cephalic Artery.

The *brachio-cephalic* or *innominate artery* (*arteria anonyma* of many authors, *e*, *fig.* 198) is the common trunk of the right sub-clavian and right common carotid arteries, and has in turns been regarded as a portion of the carotid, and as a part of the sub-clavian. It arises from the aorta, at the point where that vessel changes its direction from vertical to horizontal. It is situated in front and to the right of the other arteries given off from the arch of the aorta. It is from one inch to fifteen lines in *length*. It is *directed* obliquely upward and outward.

Relations.—*In front* of the innominate artery is the sternum, beyond the upper end of which the artery almost always projects, and from which it is separated by the left brachio-cephalic vein, by the remains of the thymus, and by the sternal attachments of the sterno-hyoid and sterno-thyroid muscles. *Behind*, it is in relation with the trachea, which it crosses obliquely; on the *outer* side, with the pleura and mediastinum, which separate it from the lungs; on its *inner* side is the left common carotid, from which it is separated by a triangular interval, in which the trachea is seen.

From a knowledge of these relations, modern surgeons have succeeded in applying a ligature to the innominate artery. Its relations, however, vary in different individuals. In some cases almost the whole length of the vessel projects beyond the sternum; and it is then extremely accessible, either to accidental wounds, or to the surgeon in the application of a ligature. It has been thought that the presence of the innominate artery explains the predominance of the right over the left upper extremity; but this opinion is entirely unfounded.

The arteria innominata gives off no collateral branch, except in those cases in which it affords origin to the thyroid artery of Neubauer, so named from the anatomist who called attention to this anatomical variety.* The same anatomist has seen the right internal mammary artery arise from the brachio-cephalic trunk.

The Right and Left Sub-clavian Arteries.

The *right* sub-clavian artery (*g*, *fig.* 198; *f*, *fig.* 204) arises from the innominate (*e*); the *left* sub-clavian (*g'*), from the arch of the aorta.

Varieties of Origin.—One very common variety is that in which the right sub-clavian arises below the left, from the posterior and inferior part of the arch of the aorta, from which it passes upward and to the right side, generally behind the trachea and œsophagus, sometimes between the two, and rarely in front of the trachea.†

The precise termination of this artery is not well defined. By some authors it is said to end, and the vessel to take the name of *axillary* artery as it passes between the scaleni.‡ It appears to me more convenient to take the clavicle as indicating the respective limits of the two vessels. All above the clavicle, then, belongs to the sub-clavian, and all below it to the axillary artery.§

From the difference, as to origin, between the right and left sub-clavians, they differ from each other remarkably in length, direction, and relations.

Differences in Length.—The right sub-clavian is shorter than the left by the length of the innominate artery; and we should, moreover, bear in mind the slight difference in the height between the origin of the innominate and the left sub-clavian. The *difference in the size* of the two sub-clavian arteries requires no special notice.

Differences in Direction.—The right sub-clavian passes at first obliquely outward and a little upward, and then bends over the apex of the lung, describing a curve with the concavity looking downward. The left sub-clavian passes vertically upward before curving over the apex of the lung, opposite which it changes its direction abruptly, and becomes horizontal.

Differences in Relations.—In describing these, we shall divide the sub-clavian artery into three portions: the *first*, extending from the origin of the artery to the scaleni muscles; the *second*, situated between the scaleni; and the *third*, extending from the scaleni to the clavicle. The relations of the right and left sub-clavians differ from each other only in the first of these portions.

The *first portion* (1, *fig.* 204) *of the right* sub-clavian is in relation in front with the inner end of the clavicle, the sterno-clavicular articulation, the platysma, and the clavicular attachment of the sterno-mastoid muscle, with the sterno-hyoid and sterno-thyroid muscles, with the termination of the internal jugular and vertebral veins in the sub-clavian

* This inferior thyroidean artery arises, perhaps, more frequently from the arch of the aorta, between the brachio-cephalic trunk and the left primitive carotid.

† [It rarely passes between the trachea and œsophagus; and it appears there is no record of its having been actually seen in front of the trachea (see *Quain on the Arteries*).]

‡ According to some authors, the artery changes its name as it emerges from between the scaleni; according to others, while it is yet between those muscles.

§ We are in the habit of dividing this artery into three portions: a cardiac, a middle, and an axillary portion. The first, that part between its origin and the scaleni; the second, the portion embraced between the scaleni; and the third, the remaining part of the artery.—Ed.

vein, and with the right pneumogastric and phrenic nerves; behind, with the recurrent laryngeal nerve and the transverse process of the seventh cervical vertebra; on the outer side, with the mediastinal pleura, which separates it from the lung. On the inner side, it is separated from the common carotid by a triangular interval.* It is surrounded by loose cellular tissue, a great number of lymphatic glands, and nervous loops formed by the great sympathetic.

The *first portion of the left* sub-clavian is in relation with the same parts, though to a somewhat different extent: thus, its relations with the left mediastinal pleura and lung are much more extensive. The sub-clavian vein crosses it at right angles, instead of being parallel to it; but the left pneumogastric and phrenic nerves run parallel to, instead of crossing it. It is parallel to the left common carotid, instead of forming an angle with it; and, instead of being near the clavicle, the left sub-clavian is close to the vertebral column, and rests on the longus colli, the inferior cervical ganglion of the sympathetic nerve, and the thoracic duct, which is there to its inner side.

The *second portion of both the right and left* sub-clavian arteries, situated between the scaleni, is in close relation below with the middle of the upper surface of the first rib, on which there is a corresponding depression behind the tubercle for the attachment of the anterior scalenus; above, with the two scaleni, which are in contact with each other above the vessel; behind, with the brachial plexus; in front, with the scalenus anticus, which separates the sub-clavian artery from the sub-clavian vein. This separation of the artery from the vein is one of the most important points in its history.†

The *third portion* of the sub-clavian, or that extending from the scaleni to the clavicle, corresponds to a triangular space, bounded in front by the sterno-mastoid and anterior scalenus, above by the omo-hyoid, and below by the clavicle: this space is named the lower or clavicular portion of the posterior triangle of the neck, which is bounded in front by the sterno-mastoid, behind by the trapezius, below by the clavicle. In front of, but somewhat lower than the artery, is the clavicle, that bone being separated from the vessel by the sub-clavian vein, which is here below and in contact with the artery, and by the sub-clavius muscle; behind and to the outside of the artery is the brachial plexus of nerves, which surrounds the vessel in the axilla; it is covered by the deep cervical fascia, the platysma, the superficial fascia, and the skin, and is crossed by the descending cutaneous branches of the cervical plexus, and obliquely by the supra-scapular artery and vein; below, it rests upon the first rib.

In consequence of these relations, the sub-clavian artery may be compressed, and the circulation of the upper extremity stopped by forcible depression of the clavicle; the sub-clavian may be easily felt, compressed, and tied above the clavicle; and, lastly, it follows that the sharp fragments of a broken clavicle can wound the coats of the artery only after having transfixed the sub-clavius muscle and the sub-clavian vein.

This artery, moreover, presents individual varieties both in regard to its direction and relations; it usually rises slightly above the clavicle, but in persons with short necks and high shoulders it is situated deeply under the clavicle, while in those who have long necks and low shoulders it may even slightly raise up the platysma and the skin. But the most important variety is that in which the relations of the sub-clavian with the scaleni muscles are changed. It is not uncommon‡ to see the sub-clavian artery situated in front of the scalenus anticus, forming immediate relations with the sub-clavian vein.§

Collateral Branches.—The sub-clavian artery gives off certain collateral branches, which may be divided into the *superior*, *inferior*, and *external*. The superior are the *vertebral* and the *inferior thyroid*; the inferior are the *internal mammary* and the *superior intercostal*; the external are the *supra-scapular*, the *posterior scapular* or *transversalis colli*, and the *deep cervical*.

Besides these, the sub-clavian arteries sometimes give off, near their origin, pericardiac, thymic, and œsophageal branches; not unfrequently the left sub-clavian gives origin to the bronchial artery of that side.

The Vertebral Artery.

The *vertebral artery*, destined for the cerebro-spinal nervous centre, supplies more particularly the spinal cord, the pons Varolii, the cerebellum, and the posterior portion of the cerebrum. It is the first and largest branch of the sub-clavian, and in some subjects is about equal in size to the continuation of that vessel. A very great inequality in the size of the two vertebrals is rather frequently met with. Morgagni states

* [It has been observed by Professor R. Quain (*loc. cit.*) that the origin of the right sub-clavian is sometimes partially or completely covered by the right carotid, a process of the cervical fascia separating the two vessels.]

† [Professor Quain has seen, in a few cases, the artery perforating the anterior scalenus; and it has even been found, by himself and others, anterior to that muscle, and therefore in contact with the vein.]

‡ According to our observation, this is a most rare variety.—Ed.

§ In a case of this kind, which has been communicated to me by M. Demeaux, adjunct of anatomy to the Faculty, there was no brachio-cephalic trunk, but a bi-carotid trunk; the right sub-clavian arose from the descending aorta, and went behind the trachea and the œsophagus. (This preparation has been deposited in the museum of the Faculty.)

that he has seen the right vertebral four times as large as the left; I have seen the left vertebral represented by a very small twig.

The vertebral artery arises (2, *fig.* 204) from the upper and back part of the sub-clavian, at the point where it curves over the apex of the lung; the left vertebral often arises directly from the arch of the aorta, between the common carotid and sub-clavian of the same side. The right vertebral has been found arising from the point at which the innominate divides into the right common carotid and right sub-clavian. It has also been seen arising by two trunks, both of which sometimes come from the sub-clavian; and at others, one proceeds from that artery, and the other from the arch of the aorta.*

Immediately after leaving the sub-clavian, the vertebral artery passes vertically upward and a little backward, enters between the transverse processes of the sixth and seventh cervical vertebræ, in order to reach the foramen in the base of the transverse process of the sixth, ascends through the foramina in the transverse processes of the succeeding cervical vertebræ, describing some slight curves in passing from one to another. In order to gain the foramen in the axis, it forms a considerable vertical curve between the atlas and that bone; it then forms a second horizontal curve between the atlas and the occipital bone,† perforates the posterior occipito-atloid ligament and dura mater, and enters the cranium by the foramen magnum. The right and left vertebral arteries turn round the sides of the medulla oblongata, between the hypoglossal and sub-occipital nerves, converge (*i i*, *fig.* 208) in front of the medulla, and near the furrow which separates it from the pons Varolii, unite at an acute angle to form the *basilar artery* (*b*). The two remarkable curves described by the vertebral artery before it enters the cranium are in accordance with those formed by the internal carotid within the carotid canal and cavernous sinus. I have seen the vertebral very tortuous at the lower part of the neck, before it entered the covered way formed for it by the cervical transverse processes.

Not unfrequently the vertebral artery enters the canal of the transverse processes at the fifth cervical vertebra; it has occasionally been seen to enter at the fourth, third, and even at the second. It very rarely enters the foramen of the seventh cervical vertebra.

Relations.—Before entering the foramen of the sixth cervical vertebra, the vertebral artery is situated deeply upon the spine, between the longus colli and the anterior scalenus, and behind the inferior thyroid artery. The thoracic duct is at first on the inner side, and then in front of the left vertebral artery. From the sixth cervical vertebra to the atlas, it is protected by the canal formed by the series of foramina in the transverse processes, and in the intervals between them by the inter-transversales muscles; it lies in front of the cervical nerves, but the sub-occipital nerve lies between it and the groove in the atlas. In the intervals between the axis and atlas, and between the atlas and occipital bone, it is in relation with the complexus and trachelo-mastoideus, and with the rectus capitis posticus major and obliquus superior. In those cases where the vertebral artery does not enter the vertebral foramina until it has passed up to the third or second cervical vertebra, it goes upward along the side of the internal carotid artery. In the cranium, it is situated between the basilar surface of the occipital bone and the anterior surface of the medulla oblongata.

Collateral Branches.—In its course along the canal of the transverse processes, the vertebral artery gives off spinal branches, which enter the vertebral canal through the inter-vertebral foramina, and are distributed in the same manner as the spinal branches of the intercostal and lumbar arteries. Several of these branches, however, are derived from the ascending cervical artery, and from the prævertebral branches of the ascending pharyngeal. From the two curves formed by the vertebral artery arise a great number of small muscular branches, which are distributed to the deep muscles of the cervical region, and anastomose with branches of the occipital and deep cervical arteries. Among these there is one, sometimes two, which enters the cranium through the foramen magnum, and is distributed to the dura mater lining the inferior occipital fossæ, and to the falx cerebelli: it is the *posterior meningeal artery* (rami meninges posteriores, *Haller*). Sœmmering has pointed out a small meningeal branch, which enters the cranium with the first cervical or sub-occipital nerve, and which appears to me to be constant.

In the cranium, before uniting to form the basilar, the vertebral arteries give off the *posterior* and *anterior spinal arteries*, and the *inferior cerebellar*.

Spinal Arteries.—These are small branches, remarkable for being extremely slender, and for arising at an obtuse angle, so that they descend in a precisely opposite direction

* One of the most remarkable varieties of origin of the vertebral artery is the following, which has been communicated to me by Professor Dubreuil:

In a woman of forty-five years, the left vertebral arteries arose neither on the right nor on the left side from the corresponding sub-clavian arteries. The left vertebral took its origin directly from the arch of the aorta, between the left sub-clavian and the left primitive carotid. The right vertebral arose from the right primitive carotid, at the distance of four millimeters from its origin. Both arteries passed upward, in parallel lines, along the vertebral column, as far as the third cervical vertebra, when they entered the vertebral foramina of the transverse processes of this vertebra, having previously given off several small supplementary branches of the ascending cervical arteries. The sub-clavian artery gave here origin only to five collateral branches.

† Have the curvatures of the vertebral artery any relation to the motions of the head upon the vertebral column?

to the vertebral arteries, which ascend vertically; they are distinguished into the *anterior* and the *posterior* spinal artery. It is incorrect to regard them as continued down to the lower part of the spinal cord: they are so slender, that they can only supply a very small portion of the cord; in reality, they are nothing more than the commencement of the spinal arteries, which are continued through the whole extent of the cord by means of branches given off from the cervical, dorsal, and lumbar arteries.

The *posterior spinal* artery arises from the vertebral while that vessel lies upon the side of the medulla oblongata, and sometimes from the inferior cerebellar artery; it passes in a tortuous manner inward, and divides into an ascending branch, which terminates upon the sides of the fourth ventricle, and a descending tortuous branch, which winds along the sides of the posterior surface of the cord, and divides into two twigs, a small one situated before, and a larger one placed behind the posterior roots of the spinal nerves; around each of these roots they form a network, and, by means of transverse branches, which are twisted on themselves and much interlaced, they communicate with the corresponding branches of the opposite side. Chaussier was therefore incorrect in giving the name of the *posterior median artery of the spine* to the two posterior spinal arteries. These small branches of the vertebral are soon exhausted; they are continued on each side by branches of the cervical, dorsal, and lumbar spinal arteries, which run upward along the posterior roots of the nerves, and having reached the sides of the cord, divide into ascending and descending branches, which anastomose with the neighbouring vessels, form a network around each pair of nerves, and communicate by tortuous transverse branches with the arteries of the opposite side.

The *anterior spinal* artery (*u*, *fig.* 208), which is somewhat larger than the posterior, arises from the vertebral near the basilar, sometimes even from the basilar itself, or from the inferior cerebellar, passes almost vertically inward and downward, in front of the medulla oblongata, and anastomoses in the same manner as the vertebral with its fellow of the opposite side, so as to constitute a median trunk, which is correctly named the *anterior median artery* of the spine; it is situated beneath the pearly fibrous band found along the anterior median furrow, and is continued by branches from the cervical, dorsal, and lumbar arteries.

The anterior, or median spinal artery, therefore, results from the anastomoses of the two anterior spinal branches of the vertebral. In one case there was no artery on the left side, but the right was twice as large as usual. The vessel is of considerable size, until it has passed below the cervical enlargement of the cord, from which point down nearly to the dorsal enlargement it becomes exceedingly delicate; a little above the last-named enlargement it suddenly increases in size, again gradually diminishes as it approaches the lower end of the spinal cord, and becoming capillary, is prolonged down to the sacrum, together with the fibrous string in which the spinal cord terminates.

During its course, this artery receives lateral branches from the ascending cervical and the vertebral in the neck, and from the spinal branches of the intercostal and lumbar arteries in the back and loins. These branches penetrate the fibrous canal formed by the dura mater around each of the spinal nerves; become applied to the nervous ganglia, to which they supply branches; get intermixed with, and follow the course of, the corresponding nerves; send small twigs backward to the posterior spinal arteries, and terminate in the anterior spinal trunk, at variable angles, similar to those at which the nerves are attached to the spinal cord.

The re-enforcing spinal branches are not nearly so numerous as the nerves. If the condition which I have observed in three subjects be constant, there are three in the cervical region, one or two in the contracted portion of the cord, and one only at the inferior enlargement. This last, which in one case was as large as the ophthalmic artery, reached the cord at a very acute angle; opposite the median line, it divided into two branches, one ascending and very small, the other descending, of considerable size, and forming the true continuation of the trunk.

From the anterior spinal arteries there proceed a great number of twigs, which pass backward into the anterior median furrow, and from thence into the substance of each half of the corresponding portion of the cord; also some lateral branches, which ramify on the sides of the cord in the pia mater.

The Inferior and Posterior Cerebellar Arteries.—These (*h h*) arise from the outer side of the vertebral, and sometimes from the basilar; they are of considerable size, and often differ in this respect on the two sides. Each of them soon turns round the medulla oblongata, pursuing a tortuous course, passes between the filaments of origin of the hypoglossal nerve, runs in front of the roots of the pneumogastric and glosso-pharyngeal nerves, crosses the restiform body, and reaches the back of the medulla oblongata on one side of the opening of the fourth ventricle; it then passes backward, between the inferior vermiform process and lateral lobe of the cerebellum, and divides into two branches: one *internal*, which continues along the furrow between the vermiform process and lateral lobe, supplies the former, and turns upward into the notch in the posterior margin of the cerebellum; the other branch is *external*, and passes outward upon the lower surface of the cerebellum, and divides into a great number of twigs, which may be traced as far as

the circumference of the cerebellum, and which anastomose with those of the superior cerebellar artery.

The Basilar Trunk.—The basilar trunk (*b*) results from the junction or confluence of the two vertebral arteries. It is larger than either of them singly, but its area is not equal to the sum of their areas; so that, by this arrangement, the passage of the blood is accelerated. It commences opposite the furrow between the medulla oblongata and the pons Varolii, and terminates by bifurcating in front of the anterior border of the pons; its length, therefore, corresponds to the antero-posterior diameter of the pons, on the median furrow of which it is situated. When the vertebral arteries are displaced towards the right side (a very common condition), the basilar trunk passes horizontally or obliquely to the left, so as to reach the median furrow.

It gives off no branch from its lower surface, which rests upon the basilar groove of the occipital bone. A great number of capillary twigs are detached from its upper surface, and enter the pons Varolii. From its sides proceed the *anterior inferior cerebellar* and the *superior cerebellar*.

The anterior and inferior cerebellar arteries (*l l*) vary much in size in different subjects, and are rarely equal in this respect on the right and left sides: each of them arises from about the middle of the basilar, and occasionally from the vertebral itself, passes outward and backward, sometimes behind, and sometimes in front of the sixth nerve, runs along the crus crebelli, passes in front of the facial and auditory nerves, and terminates upon the anterior portion of the hemisphere of the cerebellum.

The *superior cerebellar arteries* (*t t*) arise one from each side of the basilar, immediately before it divides into its two terminal branches; they might, therefore, also be regarded as terminal branches of that artery, which would thus end by dividing into four branches. Having arisen at a right angle behind the third, or motor oculi nerve, each superior cerebellar artery, accompanied by the fourth or trochlear nerve, turns round the crus cerebri in the groove between it and the pons Varolii, and, having reached the upper surface of the corresponding crus cerebelli, divides into two branches: one *external*, which passes outward on the upper surface of the cerebellum, along the anterior half of its circumference; the other *internal*, which is directed inward upon the sides of the superior vermiform process, or median lobule of the cerebellum, and then subdivides into an *antero-posterior* branch, which passes from before backward upon the sides of the vermiform process, as far as the circumference of the cerebellum, upon which it ramifies; and a *transverse* branch, which continues the original course of the vessel towards the median line, running between the superior vermiform process and the valve of Vieussens, and being distributed to both.

The terminal branches of the basilar trunk are *the posterior cerebral arteries* (*n n*); they arise at variable angles, are directed forward and outward, and then curve backward, so as to turn round the crus cerebri, parallel to the superior cerebellar arteries, from which they are separated by the third or motor oculi nerve. They follow the concave border of the great transverse fissure of the brain, and, having reached the posterior extremity of the corpus callosum, leave this fissure to pass backward upon the lower surface of the posterior lobe of the cerebrum, where they may be traced as far as the occipital region. Each of the posterior cerebral arteries gives off, immediately after its origin, an immense number of small parallel twigs, which enter the substance of the brain between the anterior crura, whence the name of perforated spot given to that portion of the brain. Just as each posterior cerebral artery curves backward, it receives the communicating artery of Willis (*r*), which is sometimes very large, and at other times very small. When large, it evidently assists in the formation of the posterior cerebral, which, after its junction with the communicating artery, sometimes becomes doubled or trebled in size. The part performed by the internal carotid in the formation of the posterior cerebral is, therefore, subject to variety. In certain cases, as I have already stated, the posterior cerebral is exclusively derived from it.

The *posterior choroid* artery arises from the back part of the posterior cerebral, immediately after the junction of that vessel with the communicating artery; it turns round the crus cerebri, passes above and supplies the tubercula quadrigemina, and terminates in the velum interpositum and choroid plexus.

As the posterior cerebral artery quits the crus cerebri, it gives off a branch which passes outward and backward, crosses obliquely the long convolution which forms the lateral boundary of the great fissure of the brain, and ramifies upon the lower surface of the cerebrum. Lastly, the posterior cerebral gives off a small constant branch, which may be called the artery of the *fascia dentata*, to which it is distributed.

Remarks on the Arteries of the Brain, Cerebellum, and Medulla Oblongata.

The arteries of the encephalon, *i. e.*, of the brain, cerebellum, and medulla, are derived from four principal trunks, two anterior, viz., the internal carotids, which arise from the common carotids, and two posterior, viz., the vertebrals, which are branches of the sub-clavian arteries. There are several circumstances to be remarked concerning these vessels, viz., their great size, which is dependant on that of the brain; their depth from

the surface before they enter the cranium ; the numerous curves formed by them as they are entering the cranial cavity, the use of which is evidently to retard the course of the blood ; the absence of any large collateral branches, the only exception being the ophthalmic branch of the internal carotid, by the existence of which the circulation in the eye is connected with that in the brain. Another remarkable point concerning these vessels is their anastomoses at the base of the cranium, viz., the anastomosis, or, rather, the confluence of the right and left vertebral so as to form the basilar artery ; the anastomosis of the right and left internal carotids by means of the anterior communicating artery, which unites the anterior cerebrals, and the anastomosis of the internal carotids with the vertebrals by the communicating arteries of Willis. By these anastomoses an arterial hexagon (the circle of Willis) is formed, the anterior margins of which correspond with the anterior cerebral arteries, the posterior with the posterior cerebrals, and the lateral with the communicating arteries of Willis.*

From this hexagon, as from a centre, proceed all the arteries of the brain, viz., from the anterior angle, the anterior cerebral arteries ; from the posterior angle, the basilar artery ; from the anterior lateral angle on each side, the middle cerebral ; and from the posterior lateral angle on each side, the posterior cerebral artery

Owing to the existence of these large anastomotic communications, any one of the four arterial trunks would be sufficient to carry on the circulation in the brain, if the other three were wanting or obliterated The situation of this arterial hexagon between the bones of the cranium and the brain is remarkable, because it explains the alternate movements of elevation and depression seen in the brain when that organ is exposed during life

It should also be observed, that the arteries of the cerebellum, pons Varolii, and medulla oblongata, are derived from the same sources as those of the brain.

Lastly, as to the mode of distribution of these vessels, it may be remarked, that the arteries of the brain pass over the free surface of one or more convolutions, dip into the sulci between the convolutions, are reflected from one side of them to the other, give off a great number of very small branches, emerge from a given sulcus to regain the surface of the adjacent convolutions, and so on until they are exhausted. The principal arteries of the cerebellum run upon its surface without passing into the sulci, between the laminæ, into which they send only very small branches. With some exceptions, the arteries are reduced to capillary dimensions before they enter the nervous substance.

The Inferior Thyroid Artery.

Dissection.—Dissect the muscles of the sub-hyoid region ; follow the branches of the thyroid ; trace the divisions of the ascending cervical artery into the grooves upon the transverse processes of the cervical vertebræ, and into the vertebral canal.

The *inferior thyroid* artery (3, *fig.* 204) arises from the front of the sub-clavian on a plane anterior to the vertebral, which often comes off exactly opposite to it. It varies remarkably in size and origin, as well as in the branches which it furnishes. It frequently arises from the common carotid ; sometimes from the arch of the aorta, between the brachio-cephalic and the left common carotid ; at other times from the brachio-cephalic itself. Lastly, it is occasionally replaced by the thyroid of Neubauer.

It often commences by a common trunk with the supra-scapular, less frequently with the posterior scapular, and rarely with the internal mammary.

Its size bears an inverse proportion to that of the superior thyroid of the same side and depends, also, on the presence or absence of a third thyroid. It is larger in infancy than at any other period. In certain cases of goitre it becomes prodigiously developed. Sometimes there is merely a trace of its existence, or it is even altogether wanting.

Immediately after its origin it passes vertically upward, then descends so as to describe a curve with its concavity directed downward, and again forms another curve with its concavity turned upward, to reach the lower end of the lateral lobe of the thyroid gland, in the interior of which it ramifies.

Relations.—Behind, it is in relation with the trachea, the œsophagus, and the vertebral column, being separated from the latter by the prævertebral muscles and the vertebral artery. Its relation with the œsophagus is more marked on the left than on the right side, and it is important to bear this fact in mind in performing the operation of œsophogotomy. *In front*, its first curve embraces the common carotid, the internal jugular vein, the pneumogastric, and the great sympathetic nerves. The middle cervical ganglion, when it exists, rests upon it. The second curve embraces the recurrent laryngeal nerve, and is also in relation with the muscles of the sub-hyoid region. It may be remarked, that there is one point in the neck where three arteries come into contact, viz., the common carotid, the inferior thyroid, and the vertebral.

Collateral Branches.—The inferior thyroid gives off, downward, an *œsophageal branch*,

* In a person who died of apoplexy, Morgagni found a want of communication between the vertebrals and carotids ; and he attributed the apoplexy partly to this circumstance, and partly to the fact that the left vertebral arose directly from the arch of the aorta.

some *tracheal* branches, and a small *bronchial* twig. I have seen the right bronchial artery derived from it. It also gives off several muscular branches to the scalenus anticus and the prævertebral muscles. The most remarkable of all these is the *ascending cervical* artery (4), which is of variable size, and is sometimes so large that it may be regarded as resulting from the bifurcation of the inferior thyroid. It passes vertically upward, in front of the scalenus anticus, then in the groove between it and the rectus capitis anticus major, to both of which, as well as to the attachments of the levator anguli scapulæ, it gives some small branches. The most remarkable of its branches, called the *cervico-spinal*, enter the grooves by which the cervical nerves emerge, run in front of these nerves, and anastomose with the branches of the vertebral artery. I have seen these branches divide into two ramusculi: the one anterior, very small, which passed in front of the vertebral artery, and emerged upon the sides of the body of the vertebra; the other posterior, which passed between the corresponding nerve and the artery, entered the spinal canal through the intervertebral foramen, and was distributed to the vertebræ, and to the spinal cord and its membranes, in the same manner as the dorsal and lumbar spinal arteries. The prævertebral branch of the ascending pharyngeal artery sometimes supplies the cervico-spinal branch of the first two intervertebral spaces in the cervical region.

Terminal Branches.—Opposite the lower extremity of the lateral lobe of the thyroid gland, the inferior thyroid artery divides into three branches: of these, one follows the lower border of the gland, another passes to the posterior surface of its lateral lobe, while the third dips between the gland and the trachea, runs along the lower border of the cricoid cartilage, sometimes becomes superficial opposite the isthmus of the thyroid body, and forms an anastomotic arch with its fellow of the opposite side, along the upper margin of that isthmus.

The Supra-scapular Artery.

The *superior* or *supra-scapular artery* (*transversus humeri*, 5, *fig.* 204), destined for the supra- and infra-spinous fossæ, and which might also be denominated the *cleido-supra-scapular* from its course, arises from the front of the sub-clavian below the inferior thyroid, and often by a common trunk, either with the posterior scapular, or with the inferior thyroid and posterior scapular united, forming what is then called the thyroid axis. It is at first directed vertically downward, then bends horizontally outward, to run along behind the clavicle and gain the upper border of the scapula, where it passes over, very rarely under, the ligament, which converts the coracoid or supra-scapular notch into a foramen, and, being reflected over that ligament, dips into the supra-spinous fossa, and crossing the concave border of the spine of the scapula, enters the infra-spinous fossa, in which situation it terminates (5′, *fig.* 209).

Relations.—It is concealed at its origin by the sterno-mastoid muscle, and is then situated along the base of the supra-clavicular triangle; it is in relation *in front* with the clavicle, following the direction of that bone; *behind*, with the sub-clavian artery and the brachial plexus of nerves, which it crosses at right angles; *above*, with the deep fascia and the platysma myoides, which separate it from the skin; and *below*, with the sub-clavian vein: more externally, it dips under the trapezius, and comes in contact with the supra-scapular nerve, is separated from it at the coracoid notch, and again becomes applied to it in the supra- and infra-spinous fossæ, where it is situated between the muscles of the bone.

Collateral Branches.—Among a great number of unnamed muscular and cutaneous branches, I would particularly notice, 1. A small thoracic branch, which passes vertically downward behind the clavicle, perforates the sub-clavius, and anastomoses with the thoracic arteries. 2. A branch for the trapezius, which is so large that it appears to result from the bifurcation of the artery. It generally arises at the point where the vessel dips into the supra-spinous fossa; at other times it comes off very near the origin of the artery, passes from before backward, turns round the scaleni muscles parallel with the posterior scapular artery, with which one might confound it, and ramifies in the trapezius and the supra-spinatus muscles, entering the former at its under, and the latter at its upper surface: some of the branches are distributed to the periosteum of the acromion and to the corresponding integuments.

Again, in the supra- and infra-spinous fossæ it gives off a great number of periosteal, osseous, muscular, and articular branches. In the infra-spinous fossa (5, *fig.* 209), it forms a free arched anastomosis with the sub-scapular artery, and gives off a branch which runs along the axillary border of the scapula, and anastomoses with the posterior scapular artery at the lower angle of that bone.

The Posterior Scapular Artery.

The *posterior scapular* (*transversus cervicis*, *transversalis colli*, 6, *fig.* 204, 209) is larger than the preceding, and extends from the sub-clavian to the vertebral border of the scapula; it arises from the front of the sub-clavian, sometimes to the inner side of the sca-

leni, sometimes between them, but most commonly on the outer side of those muscles:* in the first case it often comes off by a common trunk with the inferior thyroid, and in the two other cases by a common trunk with the supra-scapular. It passes transversely and in a slightly tortuous manner outward, through the nerves of the brachial plexus, and sometimes through the scalenus posticus, and curves backward towards the posterior superior angle of the scapula. Then, opposite the levator anguli scapulæ, it divides into an *ascending* and a *descending* branch. The *ascending* or *cervical* branch, the *superficial cervical* artery of authors, passes beneath the trapezius, and divides into a great number of twigs, which ramify in that muscle, in the levator anguli scapulæ, and in the splenius. The *descending* branch forms the posterior *scapular* artery, properly so called (*a*, *fig.* 209), and may be regarded as the continuation of the vessel; it turns round the posterior superior angle of the scapula, beneath the levator anguli, passes vertically downward along the vertebral border of that bone, and terminates at the inferior angle by anastomosing with the sub-scapular artery, a branch of the axillary, and with the supra-scapular, already described.

Fig. 209.

Relations.—It is superficial in the first part of its course, during which it traverses the supra-clavicular triangle horizontally, being merely covered by the cervical fascia, the platysma myoides, and the omo-hyoid; and hence, doubtless, the name *superficial cervical*, which has been given to it by some authors.† It is but rarely that the posterior scapular turns round the posterior scalenus and the brachial plexus, without passing between the nerves of the plexus, which it traverses at variable heights. As it proceeds backward, it is protected by the trapezius; and, lastly, along the vertebral border of the scapula, it lies between the rhomboideus and the serratus magnus

Its *collateral branches* are destined for the following muscles: the trapezius, scalenus posticus, levator anguli scapulæ, splenius, supra- and infra-spinati, sub-scapularis, rhomboideus, and serratus magnus.

The Internal Mammary Artery.

The *internal mammary*, or internal thoracic artery, not so remarkable for its size, which is less than that of the vertebral, as for its length and the number of its branches, arises (7, *fig.* 204) from the sub-clavian opposite the inferior thyroid, and behind the supra-scapular. Few arteries are less variable in their origin. The only varieties which have been observed are those in which it arises from the brachio-cephalic, from the arch of the aorta, or from a common trunk with the inferior thyroid. Immediately after its origin, it passes vertically downward behind the inner end of the clavicle, enters the thorax, crosses obliquely behind the cartilage of the first rib, and bends a little inward to run along the first portion of the sternum, below which it resumes its vertical direction, parallel to the border of that bone, as low down as the sixth rib, where it divides into an internal and an external branch.

Relations.—It is situated in front of the scalenus anticus, and is covered at its origin by the phrenic nerve, which crosses it very obliquely, in order to reach its inner side; it corresponds to the inner end of the clavicle, from which it is separated by the brachio-cephalic vein; it is then placed behind the costal cartilages and the intercostal muscles, in front of the pleura, from which it is separated by the triangularis sterni. It is situated about two lines to the outer side of the margin of the sternum, so that a cutting instrument may be carried into the thorax along that bone without injuring the internal mammary; the name sub-sternal is, therefore, not at all applicable to this artery, which would be better named *sub-chondro-costal*.

Collateral Branches.—These are very numerous; they may be divided into the *posterior*, *anterior*, and *external*. The *posterior branches* are, the *thymic* or *anterior mediastinals*, and, lower down, the *superior phrenic*, an extremely small artery, which runs along the phrenic nerve, is situated, like it, between the pericardium and the corresponding layer of the mediastinum, and reaches and is ramified in the diaphragm. Bichat has seen the superior phrenic artery as large as the internal mammary itself.

The *external branches* are the *anterior intercostals*. Their number corresponds with that of the intercostal spaces: they are small in the first two, and gradually increase or diminish according to the length of the corresponding spaces. I have seen the common trunk for the third intercostal space so large, that it appeared like a bifurcation of the mammary. There are generally two branches for each intercostal space: one, which runs along the lower margin of the rib above, and the other along the upper margin of the rib below. These two branches sometimes arise separately from the mammary,

* In the last case, those authors who describe the sub-clavian as terminating between the scaleni, say that the posterior scapular arises from the axillary artery.

† [It is the ascending or cervical branch only that is named *superficial* cervical.]

sometimes by a common trunk; as they arise above the level of the space for which they are intended, it follows that they pass obliquely behind the costal cartilages. The anterior intercostals inosculate with the aortic or posterior intercostals, so that it is sometimes impossible to determine the limits between these two sets of vessels. In some subjects they form a communicating arch of uniform caliber, extending between the internal mammary and the thoracic aorta.

The *anterior branches* are superficial, and correspond in number to the intercostal spaces; they arise from the internal mammary, pass directly from behind forward, through the corresponding intercostal space, and divide into *cutaneous* and *muscular branches*, both of which sets curve outward, the muscular branches beneath the pectoralis major, in which they ramify, and the cutaneous branches beneath the skin. The anterior branches of the first three spaces are distributed to the *mammary gland*. In females recently delivered, and in nurses, these branches become extremely large, especially the second, which I have seen as large as the radial artery, and very tortuous. Before perforating the intercostal muscles, the anterior branches send some periosteal twigs behind the sternum, some of which penetrate the bone directly, while others ramify on the periosteum.

Terminal Branches.—Of the two terminal branches, the *internal*, and smaller, continues the original course of the artery, passes behind the rectus abdominis muscle, enters its sheath, and then divides into a great number of branches; some of these are lost in this muscle by anastomosing with the capillary divisions of the epigastric, while the others emerge from the sheath of the rectus by special openings, and are distributed to the broad muscles of the abdomen, and to the integuments. Before leaving the cartilage of the seventh rib, it gives off a small twig, which passes inward upon the side of the ensiform cartilage, and forms an anastomotic arch with its fellow of the opposite side, in front of that cartilage. The anastomosis of this artery with the epigastric, which has been known from the very earliest periods, and afforded the ancients an explanation of the intimate physiological connexions between the genital organs and mammary glands, is accomplished in the usual manner of capillary communication.

The *external terminal branch*, as far as distribution is concerned, is the continuation of the internal mammary. It is directed downward and outward, behind the cartilages of the seventh, eighth, ninth, tenth, and eleventh ribs, which it crosses obliquely, and terminates opposite the last intercostal space. During its course, it gives off the *anterior intercostals* of the corresponding spaces, two for each space, sometimes only one, which immediately subdivides. These intercostals diminish gradually in size as the spaces decrease in length, and are distributed precisely as the anterior intercostal branches of the internal mammary itself. The external terminal branch, and also the internal, while passing through the diaphragm near its costal attachments, give off a great number of branches to that muscle, and hence the name *musculo-phrenic*, given by Haller to the external division, which, indeed, furnishes many more branches to the diaphragm than the internal.

The Deep Cervical Artery.

Dissection.—Seek at first for the artery behind the scalenus anticus, between the transverse process of the seventh cervical vertebra and the first rib; trace it, both to its termination, between the complexus and semi-spinalis colli, and towards its origin, within the scaleni.

The *posterior*, or *deep cervical*, comes off deeply from the upper and back part of the sub-clavian, on the same plane as the vertebral, to the outside of which it is situated. Very often it arises by a common trunk with the first intercostal. It passes at first upward and backward, then bends outward behind the scalenus anticus to dip between the transverse process of the seventh cervical vertebra and the first rib. I have never seen it pass between the transverse processes of the sixth and seventh cervical vertebræ, though for this purpose I have examined forty subjects.*

After leaving the inter-transverse space, the deep cervical artery divides into two branches: one *descending*, which I have been able to trace as far as the middle of the dorsal region, between the long muscles of the back; the other *ascending*, which passes up between the complexus and the semi-spinalis colli, in which it terminates, and anastomoses with the occipital and vertebral arteries.

The Superior Intercostal Arteries.

Dissection.—This artery can only be dissected from the internal surface of the thorax. For this purpose it is necessary to saw through the thorax vertically. The artery must be exposed by removing the pleura from the two upper ribs and intercostal muscles.

* This relation is so constant, that, even in cases where there is a supernumerary cervical rib, the deep cervical artery passes between this supernumerary rib and the first dorsal rib. Some students having called me to examine a subject in which this artery was wanting, I sought in vain for it between the first rib and the transverse process of the last cervical vertebra, and then perceived that there was a cervical rib, between which and the first dorsal rib the artery was found.

[In 264 observations, Professor Quain met with this variety in the course of the artery four times, and also other peculiarities.]

The *superior intercostal* artery, intended for the two or three superior intercostal spaces, sometimes only for the first, varies in size according to the extent of its distribution. It comes off from the lower and back part of the sub-clavian, near the deep cervical, and sometimes by a common trunk with it. It descends, in a tortuous manner, in front of the neck of the first, and then of the second rib, on the outside of the first dorsal ganglion of the sympathetic nerve, and terminates in the second intercostal space, like an aortic intercostal artery; sometimes it anastomoses freely with the first of the aortic intercostals. It gives off in each space a *dorso-spinal branch*, and an *intercostal branch*, properly so called. It is not rare to find the intercostal branch wanting in the first space: in all cases it is extremely small.

The Axillary Artery.

Dissection.—In order to prepare the axillary, as well as all the other arteries of the upper extremity, it is sufficient to dissect the muscles carefully, at the same time preserving all the branches which are met with, and tracing them to their origin.

Fig. 210.

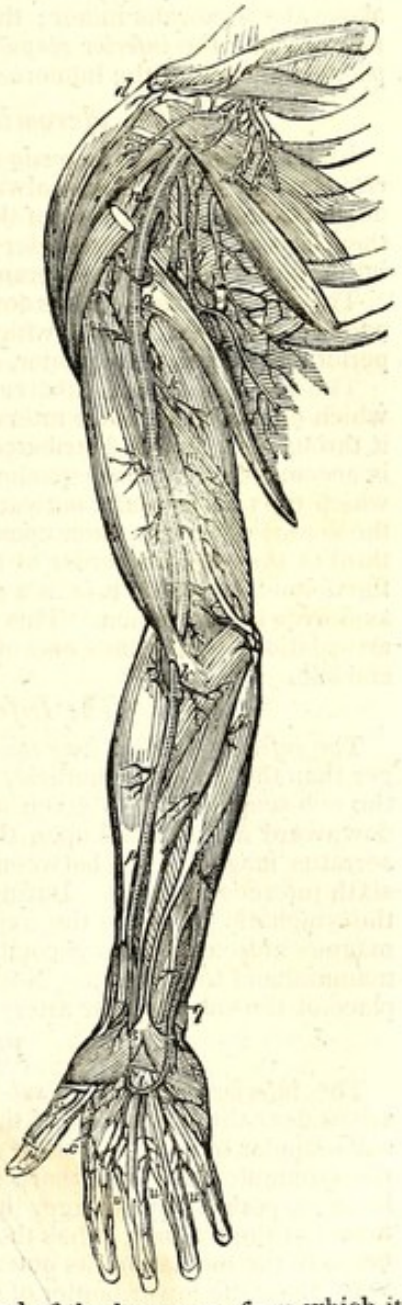

The *axillary artery* (*a a'*, *fig.* 210) is that part of the artery of the upper extremity which intervenes between the sub-clavian and the brachial. Its limits, which are entirely artificial, are the clavicle,* on the one hand, and the lower border of the pectoralis major on the other. It traverses the axilla diagonally, and bends opposite the neck of the humerus, so as to become continuous with the brachial artery. Its upper part rests upon the thorax, and its lower upon the humerus; it is not very tortuous, so that in forcible abduction of the arm it may be stretched even to laceration. Its direction corresponds pretty nearly with the cellular interval so generally existing between the sternal and the clavicular portions of the pectoralis major, or, rather, with an imaginary line, extending from the junction of the outer with the two inner thirds of the clavicle to the inner side of the neck of the humerus.

Relations.—From the importance necessarily attached to an accurate knowledge of the relations of this artery, we shall consider them in the four aspects of the vessel.

In front, the axillary artery is in relation from above downward with the sub-clavius muscle, a process of the deep cervical fascia intervening between them; then with the costo-coracoid ligament and the pectoralis major; next with the pectoralis minor; below this muscle, with the pectoralis major again; and, lastly, with the coraco-brachialis. In a subject where the pectoralis major had no clavicular insertions, that portion of the axillary artery which is intermediate between the clavicle and the superior border of the pectoralis minor, was separated from the skin only by the platysma myoides. *Behind*, it is in relation with the cellular interval between the sub-scapularis and serratus magnus; lower down, with the teres major and latissimus dorsi. *On the inside*, it rests at first upon the first rib and the first intercostal space; it next leaves the thorax, from which it is separated by the hollow of the armpit, and its inner side is then in relation with the skin which forms the outer wall of the armpit, and with the subjacent fascia. *On the outside*, it is at first embraced by the concave surface of the coracoid process, and it is then placed opposite the head of the humerus, from which it is separated by the sub-scapularis muscle

Relations with the Axillary Vein and Nerves.—Immediately below the clavicle, the axillary vein is situated on the inner side of, and at some distance from, the artery; lower down, the vein lies upon the artery. The cephalic and acromial veins pass in front of the artery.

Immediately below the clavicle, the entire brachial plexus is situated on the outer side

* Those authors who consider the sub-clavian as terminating between the scaleni, describe the axillary as commencing at the same point.

[The axillary artery is commonly said, in this country, to commence at the lower border of the first rib (*a*), and to terminate at the lower border of the conjoined tendons (*a'*) of the latissimus dorsi and teres major muscles.]

of the artery, only one thoracic nerve crossing in front of it. Under the pectoralis minor the artery is surrounded by the plexus; it is at first embraced by the external and internal roots of the median nerve, which meet in the form of a V opening upward; lower down, it is placed between the external cutaneous nerve on the outer side, the median in front, the internal cutaneous and the ulnar on its inner side, and the radial, or musculo-spiral, and the circumflex behind. In order to expose the artery in the axilla, the vessel may be sought for between the median and ulnar nerves.

In consequence of these relations, wounds of the axilla may be very serious; compression may be applied to the axillary artery, either by forcibly depressing the clavicle against the first intercostal space and second rib, or by placing the finger upon the vessel in the axilla, and pressing it against the head of the humerus; a ligature may be applied to this artery, either under the clavicle above the pectoralis minor, or in the axilla; lastly, the artery may be torn from extreme violence in attempting to reduce a dislocation.*

Collateral Branches.—The axillary gives off five branches, viz., the *acromio-thoracic*, above the pectoralis minor; the *inferior thoracic*, or *external mammary*, below the pectoralis minor; the *inferior scapular*, and the anterior and posterior circumflex arteries, opposite the neck of the humerus.

The Acromial and Superior Thoracic Arteries.

Under the name of *acromio-thoracic* I include two arteries, the *acromial* and the *superior thoracic*, which almost always arise by a common trunk, which is detached at right angles from the inner side of the axillary artery immediately above the pectoralis minor, then crosses the upper border of that muscle at right angles, and immediately divides into the two above-named branches.

The *thoracic branch* passes downward and inward, and subdivides (*b b*) between the two pectoral muscles, both of which it supplies, but especially the lesser. Some branches perforate the pectoralis major, and are distributed to the skin and the mamma.

The *acromial branch* subdivides into two others: a *descending* or *deltoid* branch (*c*), which enters the cellular interval between the pectoralis major and the deltoid, traverses it throughout, and is distributed to these two muscles, but especially to the deltoid; it is accompanied by the cephalic vein: the second is a *transverse* or *acromial* branch (*d*), which runs horizontally outward, passes over the apex, and sometimes over the base of the coracoid process, then upon the coraco-acromial ligament, and runs along the outer third of the anterior border of the clavicle. It is covered in the whole of its course by the deltoid, to which it is in a great measure distributed. Some twigs terminate in the skin over the acromion. This acromial branch terminates near the acromio-clavicular articulation: sometimes one of its divisions closely follows the anterior border of the clavicle.

The Inferior or Long Thoracic Artery.

The *inferior thoracic*, *long thoracic*, or *external mammary* artery (*e*, *fig.* 210), is much larger than the acromial thoracic, and sometimes arises by a common trunk with it or with the sub-scapular; it is given off from the axillary below the pectoralis minor, passes downward and forward upon the side of the thorax, between the pectoralis major and serratus magnus, then between the serratus and the skin, and terminates at about the sixth intercostal space. During this course it gives off a great number of branches† to the lymphatic glands in the axilla, to the sub-scapularis, pectoralis major, and serratus magnus muscles, to the second, third, fourth, fifth, and sixth intercostal spaces, to the mamma, and to the skin. Not unfrequently the inferior thoracic partially supplies the place of the sub-scapular artery, in which case it is as large as that vessel.

The Sub-scapular Artery.

The *inferior*, *common*, or *sub-scapular* artery (*f*), the largest branch of the axillary, arises near the lower part of the head of the humerus opposite the lower border of the sub-scapular muscle, sometimes by itself, sometimes by a common trunk with the posterior circumflex, the long thoracic, or the deep humeral artery; in the last case it is as large as, perhaps even larger than, the brachial. At its origin, which is from the outer aspect of the axillary, it has the musculo-spiral nerve to its inner side, and the principal origin of the median on its outer side; it passes in a tortuous manner downward and outward along the lower border of the sub-scapularis muscle, parallel with the teres major, and beneath the head of the humerus,‡ furnishes large branches to all these muscles, and having arrived below the insertion of the sub-scapularis, divides into two branches, a *descending* or *thoracic*, and a *scapular*, properly so called.

* I have seen two cases of rupture of the axillary artery from attempts to reduce old dislocations.

† [These branches represent the *alar thoracic* artery, and sometimes arise directly from the axillary, behind the pectoralis minor, or from the sub-scapular.]

‡ The relation of the sub-scapular artery to the head of the humerus appears to me to be important. In abduction this artery is much stretched, and I am surprised that it has not been torn in same cases of luxation; on the contrary, the circumflex artery, and, therefore, the circumflex nerve, appear to me to be much less liable to be stretched during abduction. Nevertheless, it is certain that the circumflex nerve has been lacerated in some dislocations of the humerus, because they have been followed by paralysis of the deltoid muscle.

The *descending* or *thoracic branch* (*g*), which is often given off by the inferior or long thoracic, passes downward and forward near the axillary border of the scapula, parallel with and behind the long thoracic, and divides into a great number of large branches, some of which enter the latissimus dorsi, several penetrate the serratus magnus even as far as the lowest portion of that muscle, while others turn round the lower angle of the scapula, and anastomose with the following or scapular branch, and with the posterior scapular derived from the sub-clavian.

The *scapular branch* (*i*), properly so called, proceeds along the lower border of the sub-scapularis muscle, in front of the long head of the triceps, and having reached below the scapular attachment of the triceps, divides into three branches: an *anterior* or *sub-scapular branch*, which dips into the sub-scapular fossa below the muscle, and expands into a great number of branches, the highest of which are distributed to the capsule of the shoulder-joint; an *infra-spinous branch* (*b*, *fig.* 209), which turns round the axillary border of the scapula, runs between the muscle and the infra-spinous fossa, and anastomoses, by a considerable branch, with the termination of the supra-scapular artery; a *median branch* (*c*, *fig.* 209), which continues in the original course of the vessel, runs along the axillary border of the scapula, between the teres major and minor, then becomes posterior, and terminates by anastomosing again upon the lower angle of the scapula with the thoracic branch of this artery, and with the infra-spinous branches of the supra-scapular.

The Posterior Circumflex Artery.

The *posterior circumflex* artery (*l*, *fig.* 210) arises from the back of the axillary opposite the sub-scapular, which it sometimes equals in size. It passes horizontally backward, between the sub-scapularis above and the teres major below, turns inward round the surgical neck of the humerus, passing first between the internal head of the triceps and the teres minor, then between the long head of the triceps and the bone, and finally (*l*, *fig.* 209) under the deltoid, to the deep surface of which it is applied; it always turns round so as to describe three fourths of a circle, and thus reaches the anterior and outer aspect of the humerus, and is lost in the deltoid by anastomosing with the deltoid branches of the acromio-thoracic artery. In the whole of its course it is accompanied by the circumflex vein and the circumflex nerve. As it turns round the bone, the posterior circumflex gives off some articular and periosteal branches, which pass to the capsular ligament of the shoulder-joint, and to the periosteum of the humerus.

The Anterior Circumflex Artery.

The *anterior circumflex*, a small artery (*n*, *fig.* 210), sometimes represented by several branches, arises from the axillary in front of the posterior circumflex, and often by a common trunk with it. It passes horizontally outward above the conjoined tendons of the latissimus dorsi and teres major, covered by the coraco-brachialis and the short head of the biceps, runs beneath the tendon of the long head of the biceps, turns round the neck of the humerus, crosses the bicipital groove at right angles, being held down by the synovial membrane, and divides into an *ascending* and a *descending* branch. The latter presents nothing remarkable; but the ascending branch, having reached the upper part of the groove, anastomoses with the osseous branch of the acromial artery, and is lost in the head of the humerus, which it penetrates at one or more points. The anterior circumflex is, therefore, intended for the humerus, its periosteum, and the synovial membrane of the groove. Sometimes there are several anterior circumflex arteries, which enter the substance of the deltoid muscle.

The Brachial Artery.

The *brachial* or *humeral artery* (*a' h*, *fig.* 210) is that portion of the artery of the upper extremity which extends from the lower border of the axilla to the point of its bifurcation at the upper part of the forearm. It passes downward, and a little forward and outward, so that it is situated on the inner side of the humerus above, and in front of it below. The absence of any bendings in this artery explains the possibility of its being torn from extreme extension of the forearm in dislocations of the elbow, &c.*

The relations of the brachial artery require to be examined separately along the arm, and in front of the elbow-joint.

Along the arm, the artery is in relation, *in front*, with the coraco-brachialis and the inner margin of the biceps, which may be regarded as the satellite muscle of the artery: in emaciated subjects the biceps does not cover the artery, which is then situated immediately under the fascia; *behind*, it is in relation with the triceps, and then with the brachialis anticus; *on the inner side*, with the fascia of the arm, which separates it from the skin; *on the outer side*, with the coraco-brachialis, then with the inner side of the humerus, from which it is separated by the tendon of the coraco-brachialis, and in the rest of its extent with the cellular interval between the biceps and the brachialis anticus. The brachial artery is enclosed in a fibrous sheath, which is common to it and the me-

* In old subjects, the humeral artery is almost always tortuous, and sometimes these windings are so remarkable that the artery is sub-aponeurotic during a portion of its course.

dian nerve. The following are its relations with the veins and nerves: the principal brachial vein is situated on its inner side; another smaller vein is on its outer side: both are in contact with the artery, which they separate from the nerves, and they are connected by several transverse branches, which embrace the artery.

The median nerve is situated in front of the artery, excepting above, where it is on its outer side, and below, near the elbow, where it passes to its inner side; the median nerve sometimes crosses behind the artery.* The ulnar nerve is placed on the inner side of the artery above, then passes behind it, and is lodged in a separate sheath. The musculo-spiral nerve is situated, together with the deep humeral artery, at first behind the brachial, but soon leaves it to turn round the humerus; lastly, the internal cutaneous follows the same course as the vessel, crossing it slightly from before backward.

From these relations, it follows that the vessel may be most efficaciously compressed from within outward, against the inner surface of the humerus, and also that it may be tied in any part of its course.

At the bend of the elbow, the brachial artery occupies the middle of the articulation; it is superficial *in front*, where it is only separated from the skin by the fascia and tendinous expansion of the biceps, and by the median basilic vein, which crosses it at a very acute angle; *behind*, it rests upon the brachialis anticus, by which it is separated from the elbow-joint; *on its inner side* is the median nerve and pronator teres muscle, and, *on its outside*, the tendon of the biceps, over which it soon crosses, and, farther outward, the supinator longus.

In consequence of the superficial position of the brachial artery at the bend of the elbow, and from its relations with the median basilic vein and the elbow-joint, it follows that this artery may be easily compressed, may be wounded in the operation of venesection, and may be lacerated in dislocations of the joint.†

Collateral Branches.—These may be divided into the *external* and *anterior*, and the *internal* and *posterior*.

The *external* and *anterior* are very numerous, and are intended for the coraco-brachialis and biceps, which they penetrate at different heights, and also for the brachialis anticus. A very remarkable branch, which appears to me to be constant, viz., the *deltoid*, passes transversely in front of the humerus, beneath the coraco-brachialis and the biceps, and terminates partly in the deltoid at its humeral insertion, and partly in the brachialis anticus. The *internal and posterior branches* are small, excepting those which enter the brachialis anticus directly: I have seen them all arise from the axillary by a large branch given off from a common trunk with the sub-scapular and the posterior circumflex arteries.

Whatever may be their mode of origin, four of these collateral branches are remarkable for their regular distribution, viz., the *deep humeral*, the *internal collateral*, the *superficial branch for the internal portion of the triceps*, and the *superficial branch for the brachialis anticus*. The two former only have received particular names.

The *deep humeral* artery (*profunda superior*, *k*, *fig.* 210), called also the *external collateral*, from its terminating on the outer side of the articulation of the elbow, arises from the brachial, opposite the lower border of the teres major. It occasionally comes off by a common trunk with the posterior circumflex, which, in that case, arises from the brachial instead of the axillary artery. It passes downward and backward, gains the groove for the musculo-spiral nerve, and traverses the whole extent of that groove together with the nerve. In this part of its course it is situated between the triceps muscle and the humerus, as it turns round the posterior surface of that bone; below the insertion of the deltoid it emerges from the groove, between the brachialis anticus and the triceps, and divides into a *deep* branch, which continues with the nerve, and a *superficial* branch. The former is distributed essentially to the triceps muscle, and sometimes comes off directly from the brachial; it passes vertically downward in the substance of the triceps, supplies its internal and external portions, and terminates in them by anastomosing freely with the collateral branches situated around the elbow-joint. The *superficial* branch perforates the external head of the triceps, and the external inter-muscular septum, along which it descends vertically to the back of the epicondyle, or external condyle of the humerus, where it anastomoses with the interosseous recurrent artery.

The *internal* or *ulnar collateral* artery (*profunda inferior*, *m*, *figs.* 210, 211) is much smaller than the external collateral, from which it is sometimes derived; it is often double. It usually arises at a variable height from the lower part of the brachial, sometimes passes transversely inward, and sometimes proceeds in a tortuous manner downward before becoming transverse, and then divides into two branches: one *anterior*, which is distributed to the brachialis anticus, the muscles attached to the epitrochlea or internal condyle of the humerus, and the periosteum upon that process; the other *posterior*, which perforates the internal intermuscular septum, and divides into muscular branches for the

* Dubreuil has seen that arrangement in three cases; and M. Chassignac has met with it twice last winter.

† I have seen this artery lacerated in a case of luxation forward of the humerus on the forearm, in consequence of a fall from a horse upon the wrist. The lower extremity of the humerus had torn the brachialis anticus, the artery and the skin through which it had passed. A hemorrhage, followed by syncope, took place at the moment of the accident. The patient having been carried to her residence in this swoon, the reduction was accomplished, the hemorrhage did not return, and the cure was as perfect as possible.

triceps; into periosteal and osseous branches, which pass transversely in front of the triceps, and anastomose with the interosseous recurrent; and into a descending branch, which accompanies the ulnar nerve, and anastomoses with the posterior ulnar recurrent.

The *superficial branch for the internal portion of the triceps* is remarkable for its size and length; it arises from the brachial, immediately below the profunda superior, from which also it is rather frequently derived, and passes vertically downward applied to the ulnar nerve. It is at first situated in front of the internal intermuscular septum, then perforates it, accompanied by the ulnar nerve, and, passing backward between the epitrochlea and the olecranon, anastomoses with the posterior ulnar recurrent.

The *superficial branch for the brachialis anticus* arises from the brachial artery at the same height as the preceding, runs along the inner side of the brachialis anticus, gradually diminishing in size down to the lower part of the arm, where it anastomoses with the internal collateral artery.*

The *terminal branches* of the brachial are the *radial* (*p*, *figs.* 210, 211) and *ulnar* (*g*) arteries. The bifurcation of the brachial artery into the radial and ulnar usually takes place below the bend of the elbow, sometimes on a level with it, but rather frequently above the articular line; in the latter case, the bifurcation has been observed to occur sometimes at the lower third or at the middle of the arm, sometimes at the junction of the upper with the two lower thirds, and sometimes in the axilla itself, the radial and ulnar arteries immediately succeeding to the axillary. In these cases, one division of the artery, generally the radial, is sub-cutaneous, while the ulnar assumes the ordinary relations of the brachial; but the reverse of this may take place; and, lastly, the radial and the ulnar have both been found sub-cutaneous. Not unfrequently, the radial artery, at its origin, is the inner branch of the bifurcation, and then crosses the ulnar at a very acute angle, in order to reach the radius. Besides these anomalies resulting from varieties in the point of bifurcation, there is yet another, in which a premature division takes place into two branches, one of which forms the interosseous artery, and the other the brachial, which has its usual arrangements; at other times, instead of a bifurcation, only a very slender branch is given off, and terminates in the ulnar, which in that case arises by two roots.

The frequency of high divisions of the humeral artery require that the practical considerations to which these give rise should be taught. If, therefore, a hemorrhage by the arteries of the forearm should not yield to a ligature of the humeral artery, we should, with M. Danyau, suspect the high division of the humeral artery, and search for the other branch.

Here follows the minute description of three rare varieties which I have exhibited at the Anatomical Society. From the inferior part of the axillary artery arose a slender artery, which first coursed all along the humeral artery, on the inside of which it was situated; it then crossed this vessel by passing before it at the union of the two superior with the inferior third of the arm, and finally joined the radial artery opposite the bicipital tuberosity of the radius.

At the bend of the elbow, this artery, which might be considered as a slender branch of origin of the radial artery, occupied the same relations as the humeral artery, and was situated below the aponeurotic expansion of the biceps, while the trunk of the humeral artery was not placed under this expansion, but below the tendon of the biceps. It was behind this tendon, a little above its insertion into the radius, that the humeral artery was divided into radial and ulnar; the radial, instead of coursing directly downward, described a curve with the concavity inward; and it was with the lower part of this curve that the long and feeble branch coming from the axillary artery united.

I have met, again, a similar anomaly, with this difference, that the long and slender arterial branch, instead of going to the radial, anastomosed with the ulnar. This variety may be considered as a mode of anastomosis between the upper and the lower part of an arterial trunk, *a mode of anastomosis by a collateral canal*, unusual in the arterial, but very frequent in the venous system.

In a case where one of the branches of the high division was the interosseous artery, and the other the common trunk of the radial and ulnar arteries, the respective relations of these vessels were as follows:

The humeral dichotomic division took place below the hollow of the axilla. One of the branches was the common trunk of the interosseous arteries, which first followed the usual course of the humeral artery, then crossed, at a very acute angle, the other branch by passing behind it, coursed obliquely downward and outward, and finally reached the external border of the tendon of the biceps. Having been sub-aponeurotic so far, it now dipped under the pronator teres, gave off the radial and ulnar recurrent branches, and terminated as the interosseous arteries terminate.

The other branch constituted the common trunk of the radial and cubital arteries;

* [These two superficial branches are frequently represented in their distribution by a single branch, called the *anastomotic artery* (*o*, *figs.* 210, 211), which arises from the brachial, about two inches above the elbow.

The *nutritious* artery of the humerus is small, but constant: it arises from the outer side of the brachial, or one of its collateral branches, passes downward, perforates the insertion of the coraco-brachialis muscle, and enters the oblique foramen in the inner side of the humerus, to ramify in the medullary canal of that bone.]

sub-aponeurotic, like the preceding, it reached the anterior side of the epitrochlea, and divided into two secondary branches: one internal, which was the ulnar, a little tortuous, coursed downward as far as the annular carpal ligament; the other external, which was the radial, passed obliquely downward and outward as far as the radial insertion of the pronator teres, when it became vertical. During their whole course, the radial and ulnar arteries were sub-aponeurotic.

I have been on the point of opening the radial artery at the bend of the arm, in a case where it lay over the superficial tendon of the biceps.*

A knowledge of these anomalies, both in reference to the point of bifurcation and to the new relations of the parts, is extremely important to the surgeon.

The Radial Artery and its Branches.

Dissection.—The radial artery in the forearm is completely exposed by dissecting the supinator longus; the carpal portion of the artery by dissecting the tendons of the thumb opposite the wrist; the palmar portion by dividing all the flexor tendons in the palm. It is, therefore, advisable to postpone the examination of the palmar portion of the artery until the ulnar has been studied.

The *radial artery* (*p, figs.* 210, 211), the outer of the two branches into which the brachial divides, is more superficial and smaller than the ulnar; it extends from the point of bifurcation of the brachial down to the palm of the hand. Sometimes the radial turns backward, after having reached the lower third of the forearm, and remains sub-cutaneous until it dips between the first and second metacarpal bones; its place in front of the lower part of the radius is then supplied by the radio-palmar artery or superficialis volæ, which is extremely small. It is very common to find the radial artery of one arm larger than that of the other; in one case I found both radials wanting in front of the lower part of the radius.

The radial artery is at first directed downward, and somewhat obliquely outward, like the brachial, with the direction of which it corresponds; it then descends vertically as far as the lower end of the radius, turns round the anterior surface and apex of the styloid process, to gain the outer side of the carpus, and passes obliquely downward and backward, to reach the upper part of the first interosseous space; there it turns abruptly forward, between the upper extremities of the first and second metacarpal bones, passing between the two origins of the first dorsal interosseous muscle, enters the palm of the hand, and runs almost transversely inward, to form the *deep palmar arch* (*b, fig.* 211). The radial artery is frequently tortuous at the lower part of the forearm. From the long course and the direction of the radial, it may be divided into three portions, corresponding to the *forearm*, the *wrist*, and the *palm* of the hand.

The *first portion* of the radial artery, viz., that situated in the *forearm*, has the following relations: *In front*, with the inner border of the supinator longus, which overlaps it, especially above; in the rest of its extent it lies beneath the fascia. In emaciated subjects the supinator longus is narrow, and this part of the artery is sub-aponeurotic in its whole extent.

Behind, it corresponds to the anterior surface of the radius, from which it is separated above by the supinator brevis; lower down by the pronator teres, and by the radial origins of the flexor sublimis and flexor longus pollicis; still lower by the pronator quadratus, below which it rests directly upon the inferior portion of the radius. The superficial position of the radial artery, and the support afforded it by the bone, are the reasons why it is chosen for examining the pulse.

On the *inner side*, it is in relation with the pronator teres, then with the tendon of the flexor carpi radialis, along which it runs, and which is on a plane anterior to it; so that the contraction of this muscle, by causing its tendon to project, renders the pulsations of the vessel more difficult to be felt.

On the *outer side*, it is in relation with the supinator longus, and in the middle part of its course with the radial nerve (the continuation of the musculo-spiral), which is situated at some distance from it, both above and below, and has a separate fibrous sheath.

Of the *collateral branches* of the radial artery in the *forearm*, only three require a special description, viz., the *anterior radial recurrent*, the *anterior carpal branch*, and the *radio-palmar* artery.

The *anterior radial recurrent* artery (*r, figs.* 210, 211) is given off from the back part, and immediately below the origin of the radial. It is very large in some subjects, indeed as large as the radial itself: it descends a little, and then turning upward, so as to describe a curve with its convexity directed downward, it ascends between the supinator longus and the brachialis anticus, in order to anastomose with that part of the pro-

* The editor, engaged as he has been, for thirty years, in teaching anatomy, has had very extensive opportunities of observing varieties in the origins of the radial and ulnar arteries; and as the result of these, he would state as a general rule, liable to very few exceptions, 1st. When the radial arises prematurely, it passes, like the humeral, under the aponeurotic expansion of the biceps muscle.

2d. When the ulnar arises above the elbow, it passes superficially above this aponeurosis, being placed subcutaneous in connexion with the veins.

The editor believes, that in the majority of cases where an artery is wounded in performing the operation of bloodletting at the bend of the arm, the vessel injured is the ulnar, which has arisen prematurely. In several cases where he has been called on to operate for aneurism produced by this accident, he has found this to be the case.

funda superior which forms the external collateral branch of the elbow. I have seen this recurrent artery arise from the ulnar.

From the convexity of the arch described by the radial recurrent, a great number of branches proceed obliquely downward and outward, and are distributed to all the muscles on the external aspect of the forearm, viz., the long and short supinators, and the two radial extensors. One of these branches passes transversely between the long supinator and the long radial extensor, to anastomose on the outer condyle with the profunda artery; others pass between the radius and the muscles attached to it, ramifying in the extensor muscles of the forearm, and anastomose with the posterior interosseous artery derived from the ulnar.

The *anterior carpal branch of the radial artery* is a small branch (*a*, *fig.* 211) which passes transversely inward at the lower margin of the pronator quadratus muscle, and anastomoses with a similar branch from the ulnar artery.

The *radio-palmar* or *superficial palmar artery* (*superficialis volæ*, *s*, *fig.* 210) arises at an acute angle from the inner side of the radial, at the point where that vessel turns outward to pass over the carpus. Sometimes its origin is situated at the junction of the lower with the two upper thirds of the forearm. It varies much in its size and distribution; most commonly it passes vertically downward, on a level with the anterior ligament of the carpus, perforates the origin of the short abductor of the thumb, and anastomoses with the extremity of the superficial palmar arch (*t*) of the ulnar (*g*). Several branches arise from its convexity, and are distributed to the muscles and integuments of the ball of the thumb. The radio-palmar branch is frequently very small, is entirely lost in those muscles, and does not assist in the formation of the superficial palmar arch. On the contrary, it is often so large that it may be regarded as formed by the bifurcation of the radial, and then assists as much as the ulnar in forming the superficial palmar arch. In some cases in which the superficial palmar arch did not exist, I have seen the radio-palmar give origin to the internal collateral artery of the thumb, both collateral arteries of the index, and the external collateral of the middle finger, the ulnar artery furnishing the collaterals of the other fingers. In one case, a transverse branch, resembling the anterior communicating artery of the brain, formed the anastomosis between the radio-palmar and the ulnar arteries.

The *second* or *carpal* portion of the radial artery extends from the styloid process of the radius to the upper part of the first interosseous space. Closely applied to the ligaments and bones of the carpus, it passes at first obliquely downward and inward, and then becomes vertical as it dips into the interosseous space, to pass between the two heads of the first dorsal interosseous muscle. It is well protected on the outer side of the carpus by the projecting tendons of the two extensors and the long abductor of the thumb, all of which cross it obliquely, and separate it from the skin; but between the tendons of the long abductor of the thumb and the long radial extensor it becomes sub-aponeurotic, and therefore very superficial. In this short course it gives off several branches.

The *dorsal carpal branch* of the radial artery, more remarkable for its constancy and the mode of its distribution than for its size, which is inconsiderable, arises opposite the articulation of the two rows of carpal bones, passes transversely inward, and terminates either by being lost in the adjacent parts, or by anastomosing with the corresponding branch of the ulnar artery. From the arch thus formed proceed certain *ascending branches*, which anastomose with twigs from the anterior interosseous artery, sometimes appearing to form the termination of that vessel, which, as we shall presently describe, becomes posterior at the lower part of the forearm; and also some *descending branches*, of very variable size, which, having reached the upper part of the third and fourth interosseous spaces in particular, anastomose with the perforating branches of the deep palmar arch, and form one of the origins of the small twigs, which are named the *dorsal interosseous* arteries of those spaces.

The *dorsal interosseous branch for the second space*, known also as the *dorsal metacarpal* branch of the radial artery, is sometimes so large that it seems to be a continuation of the radial, and at other times very small, and, as it were, a mere vestige. It often arises by a common trunk with the dorsal carpal branch just described; it runs along the dorsal surface of the second interosseous space, and, having reached the lower part of it, gives *superficial dorsal* arteries to the index and middle fingers, and then bends forward between the heads of the second and third metacarpal bones, to anastomose with that digital branch of the superficial palmar arch which gives off the internal collateral artery of the index, and the external collateral artery of the middle finger.*

The *interosseous artery of the first space* is so large that it is described as formed by the bifurcation of the radial: it arises from that artery between the first and second metacarpal bones, and sometimes runs along the dorsal aspect of the first interosseous space, and at others between the first dorsal interosseous muscle and the adductor pollicis; in

* [Three small branches, two of which usually arise by a common trunk, are given off from the radial artery near the *dorsal* aspect of the head of the first metacarpal bone; two of them form the *superficial dorsal arteries* of the two sides of the thumb (*dorsales pollicis*), while the other is the *dorsal artery* of the radial side of the *index* finger (*dorsalis indicis*).]

either case, when it reaches the lower part of the space, it divides into two branches, which may arise separately from the carpal portion of the radial artery, as in *fig.* 211, and which constitute the *internal collateral artery of the thumb* and the *external collateral artery of the index finger* (*x*). The *external collateral artery of the thumb*, sometimes derived from the preceding, or even from the extremity of the superficial palmar arch, crosses the muscles of the ball of the thumb obliquely, to reach the outer side of its metacarpo-phalangal articulation (*v*, *fig.* 210), and runs along the outer border of the thumb.*

The Deep Palmar Arch.

The *third* or *palmar* portion of the radial artery constitutes the *deep palmar arch* (*b*, *fig.* 211), which is completed by inosculating with a branch of the ulnar, in the same manner as we have seen the superficial palmar arch of the ulnar artery completed by a branch of the radial. This arch is situated deeply across the front of the metacarpal bones, immediately below their upper extremities; it rests immediately upon them and the interosseous muscles, and is therefore subjacent to all the nerves, tendons, and muscles (except the interosseous) in the palm of the hand. The deep palmar arch describes a slight curve, the convexity of which is directed downward. I have seen the palmar arch formed by the dorsal artery of the second interosseous space, which then dipped between the *upper* ends of the second and third metacarpal bones.

The deep palmar arch gives off very short *superior* or *ascending branches* (*recurrentes*), which are lost in front of the carpus, anastomosing with the anterior carpal branches of the radial and ulnar arteries; also some *descending* or *palmar interosseous arteries* (*d d*, interosseæ volares, *Haller*), three or four in number, which descend vertically along the interosseous spaces, and anastomose with the descending digital branches (cut across in *fig.* 211) of the superficial palmar arch, either opposite or above their bifurcation into the collateral arteries of the fingers. The size of the palmar interosseous arteries is extremely variable, as well as that of the deep palmar arch itself; it bears an inverse proportion to that of the superficial palmar arch and its branches. The relative size of the different palmar interosseous arteries, also, varies much; most generally the first is the largest, at other times the second, and occasionally the third.

The *deep palmar* arch also gives off the *posterior* or *perforating branches* (*c c*). These are three in number, and form for the second, third, and fourth interosseous spaces what the radial itself is for the first, with this difference, that the radial perforates the first space from behind forward, while these perforating branches traverse the corresponding spaces from before backward. They arise from behind the deep palmar arch, and immediately perforate the upper part of the interosseous spaces in a straight line, and having reached the dorsal aspect of the hand, generally anastomose with the corresponding dorsal interosseous arteries, which, in a great number of cases, are formed entirely by these perforating branches. In some subjects, the dorsal interosseous arteries result from the anastomoses of the perforating arteries with the interosseous arteries derived from the dorsal carpal arch formed by the dorsal carpal branches of the radial and ulnar arteries; they pass vertically downward on the dorsal surface of the interosseous spaces, and having reached their lower parts, anastomose with the descending digital branches of the superficial palmar arch, and thus assist in the formation of the collateral arteries of the fingers.

The Ulnar Artery and its Branches.

The *ulnar artery* (*g*, *figs.* 210, 211), which is larger than the radial, leaves that vessel at a very acute angle, passes at first downward, inward, and backward, in front of the ulna, describing a slight curve, the convexity of which is directed upward and inward, and then descends vertically. Having arrived at the wrist, it is placed on the outer or radial side of the pisiform bone, in front of the annular ligament of the carpus, and then enters the palm of the hand, where it describes beneath the palmar fascia an arch, which has its convexity turned downward, and is named the *superficial palmar arch* (*t*, *fig.* 210; removed in *fig.* 211).

The *relations* of the ulnar artery must be separately examined in the forearm and in the hand.

In the *forearm*, it is at first covered by the thick bundle of muscles which are attached to the inner condyle of the humerus, and also by the median nerve, from which it is separated by that part of the pronator teres which arises from the coronoid process; it is then covered by the flexor sublimis, and finally by the fascia and skin; the tendon of the flexor carpi ulnaris is upon its inner side, and that of the flexor sublimis on its outer: these two tendons, by their projection, occasion an interval between the artery and the skin. It is in relation behind with the brachialis anticus, the flexor profundus digitorum, and the pronator quadratus. The ulnar nerve is applied to the inner side of the artery

* [The two collateral arteries of the thumb, and the external collateral of the index finger, frequently arise in a different manner from that described above: thus, the two arteries for the thumb may take origin from a common trunk, which is then named the *great* or *principal artery of the thumb* (*magna vel princeps pollicis*); while the artery for the index finger arises separately, and is named the *radial collateral artery of the index finger* (*radialis indicis*).]

Fig. 211.

at the point where the vessel becomes vertical, and accompanies it as far as the hand. The median nerve is situated on its inner side at the bend of the elbow, but afterward becomes anterior, and then external to it. In some cases of high division of the humeral artery, the ulnar has been found immediately under the fascia in its whole length.

In the hand, it is at first situated on the outer or radial side of the pisiform bone, and then in front of the hook-like process of the unciform bone; finally, where it forms the superficial palmar arch, it is entirely sub-aponeurotic.

In the forearm, the ulnar artery gives off a great number of unnamed collateral branches, which are divided into internal, external, anterior, and posterior, and are distributed to the muscles and integuments. Four branches, however, require special notice, viz., in the forearm, the *common trunk of the ulnar recurrents*, the *interosseous* artery, the *branch for the median nerve*, and the anterior *artery of the carpus;* in the palm of the hand, the ulnar artery gives off the *collateral arteries of the fingers*.

The *anterior and posterior ulnar recurrent* arteries generally arise by a common trunk, which is given off from the back of the highest portion of the ulnar artery, passes transversely inward, and divides into two branches—an anterior and a posterior. The former, or *anterior ulnar recurrent* artery (*e, fig.* 211), passes between the brachialis anticus and pronator teres, gives branches to all the muscles attached to the inner condyle, and anastomoses with the internal collateral branch from the brachial. The other branch, the *posterior ulnar recurrent*, is larger than the anterior, runs behind the muscles arising from the inner condyle, is then situated between that condyle and the olecranon, passes between the two origins of the flexor carpi ulnaris in front of the ulnar nerve, anastomoses freely with the internal collateral branch of the brachial artery and with the interosseous recurrent, and contributes to form an arterial network upon the back of the elbow-joint. The branch given off by the posterior ulnar recurrent to the ulnar nerve deserves to be pointed out; it may be traced from below upward, along that nerve, and anastomoses with the other branches given off to the same nerve from the brachial artery.

The *interosseous artery* is so large that it appears to be the result of a bifurcation of the ulnar, and is described as such by many anatomists; it comes off from the back of the ulnar, immediately below the trunk of the recurrents, on a level with the bicipital tuberosity of the radius; it not unfrequently arises from the radial. Lastly, in several cases of high division, either of the brachial or of the axillary artery, the interosseous has been found to constitute one of the branches of the bifurcation, the other branch being the common trunk of the radial and ulnar arteries.

Immediately after its origin, the interosseous passes directly backward, and divides into two branches of almost equal size, which are named, from their distribution, the *anterior* and *posterior interosseous*.

The *anterior interosseous* (*f, fig.* 211) descends vertically in front of the interosseous ligament, and is held down to it by a layer of fibrous tissue;* it is placed behind the flexor profundus digitorum and the flexor longus pollicis, in the cellular interval between these muscles. Having reached the upper borders of the pronator quadratus, it passes between that muscle and the interosseous ligament, rests upon the latter, and perforates it towards its lower part; having thus reached the back of the forearm, the anterior interosseous descends upon the dorsal surface of the carpus, and terminates by anastomosing with the dorsal carpal branches of the radial and ulnar. While perforating the interosseous ligament behind the pronator quadratus, the artery almost always gives off a small twig, which descends perpendicularly to join the arch formed by the anterior arteries of the carpus.

In one case where the radial artery was exceedingly small, indeed in a rudimentary state, its place was supplied by the anterior interosseous; which, after having passed behind the pronator quadratus, escaped forward under the lower border of that muscle, and passed transversely outward, to anastomose with the rudimentary radial artery, which, thus re-enforced, immediately assumed its usual size.

During its course, the interosseous artery only gives off some small branches to the front of the forearm, among which the *artery of the median nerve* deserves special notice; but several large branches are detached in succession from its posterior aspect, and immediately perforate the interosseous ligament: they are called the *perforating arteries of the forearm*, and are distributed to the deep layer of muscles on the back of the forearm. I have seen one of these run along the posterior surface of the interosseous ligament, in the same manner as the anterior interosseous artery.

* After amputation of the forearm, the interosseous artery becomes retracted between this fibrous layer and the interosseous ligament; and it is hence so difficult in some cases to place a ligature upon it, that it has been recommended to divide the interosseous ligament for a short distance.

The *artery of the median nerve* is remarkable for its constancy and its length; it comes off from the front of the anterior interosseous artery, reaches the posterior surface of the median nerve, penetrates it, and then runs downward along its inner side. I have seen the artery of the median nerve very large, and anastomosing with the superficial palmar arch. It has also been found continuous with the brachial artery, and supplying the place of both the radial and ulnar, which were in a rudimentary state.

The *posterior interosseous* artery is generally smaller than the anterior; it perforates the interosseous ligament opposite the lower border of the supinator brevis, and immediately gives off an ascending branch, the *interosseous recurrent;* it then descends between the deep and superficial layer of muscles on the back of the forearm, and divides into a number of branches, which are distributed to those muscles, but especially to the superficial layer.*

The *interosseous recurrent* is a branch of the posterior interosseous, of such size that it may be regarded as resulting from the bifurcation of that artery: it passes vertically upward, having the anconeous and the extensor carpi ulnaris behind it, and the supinator brevis in front of it; it runs behind the inner condyle, and anastomoses on the outer side of the elbow-joint with the cutaneous, muscular, and periosteal divisions of the superior profunda artery, the external collateral branch of the brachial

The *anterior carpal branch* of the ulnar artery is a small twig, which arises opposite the lower borders of the pronator quadratus, passes between the tendon of the flexor carpi ulnaris and the ulna, and anastomoses with a similar branch from the radial, to form the anterior carpal arch, from which several branches descend to reach the interosseous muscles, and those of the ball of the thumb †

The Superficial Palmar Arch.

Opposite the articulation between the two rows of carpal bones, and before it forms the superficial palmar arch, the ulnar artery gives off a deep branch backward, called the *radio-cubital*, or communicating artery (*y*, *fig.* 210), which dips between the short abductor and short flexor of the little finger, then passes outward between the short flexor and opponens, to anastomose with and complete the deep palmar arch. This artery is sometimes so large that it may be regarded as formed by the bifurcation of the ulnar

The *superficial palmar arch* (*t*, *fig.* 210), which constitutes the termination of the ulnar, gives off no important branch from its upper or concave side. Four or five diverging *digital branches* pass from its lower or convex side, and constitute the collateral arteries of the fingers.

The *digital branches* (*u u u*) are distinguished as the first, second, third, and fourth, proceeding from within outward. The first reaches the inner or ulnar border of the little finger, and constitutes its *internal collateral* artery; the second runs along the fourth interosseous space, and divides into the *external collateral artery of the little finger*, and the *internal collateral artery of the ring finger;* the third runs along the third interosseous space, and supplies the *external collateral artery of the ring finger* and the *internal collateral artery of the middle finger;* the fourth runs in the second interosseous space, and gives the *external collateral artery of the middle finger* and the *internal collateral artery of the index finger*. It is very rare to find the external collateral artery of the index finger (*x*), and the internal collateral of the thumb derived from the superficial palmar arch; and still more rare to see the external collateral artery of the thumb (*v*) given off by that arch.

Whatever varieties there may be in the arteries of the palm of the hand,‡ in reference to the share which the radial and ulnar respectively take in the formation of the collateral arteries of the fingers, the following general facts are apparent in their distribution: The size of the superficial and deep palmar arches respectively are always inversely proportioned to each other; the communication between the two arches takes place not only directly between the arches themselves, but also indirectly in a great number of points by their branches; all the descending branches of the deep palmar arch anastomose with the angle of bifurcation of the descending branches of the superficial palmar arch; those from the deep arch are sometimes smaller, sometimes larger than those

* Some branches may be traced as far as the carpus.

† [There are usually two other branches given from the ulnar in the wrist: the first is a *dorsal metacarpal* branch, which arises above the anterior carpal, runs under the tendon of the flexor ulnaris, turns round the ulna to reach the back of the carpus, anastomoses with the dorsal metacarpal branch of the radial, and sends a twig along the fifth metacarpal bone, to form the *superficial dorsal* artery of the little finger. The second branch of the ulnar in this situation may arise with the one just described; it is a *posterior* or *dorsal carpal* branch, which passes backward, and anastomoses beneath the extensor tendons with the dorsal carpal branch of the radial artery.]

‡ In one case the superficial palmar arch was formed in the most regular manner by the radial and the ulnar arteries, which concurred in its formation by two perfectly equal trunks, and gave off the collateral branches to all the fingers except the external collateral of the thumb, the internal collateral of the index, and the external collateral of the middle finger.

The deep palmar arch, very small in comparison with the superficial palmar arch, which was very considerable, was formed as usual. It gave off the external collateral of the thumb and the common trunk of the internal collateral of the index, and the external collateral of the middle finger. This common trunk was the continuation of the non-flexed portion of the radial artery. The radial artery in this case was much larger than the ulnar.

from the superficial arch; they are rarely of the same size, but always bear an inverse ratio to them; the bifurcation of each digital branch of the superficial palmar arch takes place two or three lines below the metacarpo-phalangal articulation, opposite the junction of the body with the upper end of the first phalanx; the collateral arteries of the fingers are situated upon the anterior aspect of the phalanges, on each side of the sheath of the flexor tendons; they give off dorsal and palmar branches, and anastomose with each other in front of the body of the phalanges by small transverse branches; having reached the middle of the last phalanx, they anastomose in an arch, from the convexity of which a great number of anterior branches pass to the skin, over the last phalanx, and some dorsal branches to the matrix of the nail; one of these branches runs along the curved adherent border of the nail.

The *termination of the superficial palmar arch* is subject to variety: thus, it terminates either by anastomosing with the radio-palmar or superficialis volæ, of the same size as itself, or by receiving a very small radio-palmar branch, and being prolonged so as to constitute the common trunk of the internal collateral artery of the thumb, and the external collateral artery of the index finger; or else it terminates in the external collateral of that finger; or, lastly, after having given off the internal collateral of the thumb and the external collateral of the fore-finger, it ends in the external collateral of the thumb. At other times, again, there is no superficial palmar arch properly so called, and the ulnar artery terminates by furnishing the collaterals of the little and ring fingers, and the internal collateral of the middle finger, the other collaterals being derived from the radio-palmar, which is then very large. In certain cases, a very small transverse branch forms the communication between the radial and the ulnar arteries.

General Remarks on the Arteries of the Upper Extremity.

A single trunk, which may be called the brachial trunk, supplies the whole of the upper extremity; it forms, in succession, the sub-clavian, the axillary, and the brachial artery, which latter bifurcates near the bend of the elbow into the radial and ulnar arteries: these form the palmar arteries, from which the arteries of the fingers take their origin.

The difference in the origin of the right and left brachial trunks has been considered to account for the difference in strength between the two arms; and the different size of the two vessels has also been supposed to be connected with the same fact, which, however, in reality, depends upon the more frequent exercise of the right than of the left arm.

The brachial trunk is not exclusively distributed to the upper extremity, but supplies the most dissimilar parts; a fact which shows that the conditions of origin, which have so great an influence in regard to nerves, are altogether without importance in reference to the arteries. Thus, the brachial trunk sends branches to the following parts: the vertebral artery to the brain, the cerebellum, the pons varolii, the medulla oblongata, and the spinal cord; the inferior thyroid artery, to the thyroid gland, the larynx, the trachea, the œsophagus, and sometimes the bronchi; the internal mammary and thoracic arteries, to the corresponding mamma; and the same arteries, together with the superior intercostal, to the parietes of the thorax and abdomen; the ascending cervical, to the prævertebral muscles and the spine; and, lastly, the deep cervical, sub-scapular, and posterior scapular arteries, to the superficial and deep muscles of the back of the neck.

Setting aside those branches which do not belong to the upper extremity properly so called, we find that, during its course along the limb, the artery always occupies the aspect of flexion, which is at the same time the position where it can be best protected; and that, for this purpose, it is directed from the axilla to the bend of the elbow: we find, also, that it gives off a great number of anastomotic branches around the articulations, and thus establishes a collateral circulation, through which the blood can pass when the principal artery is obliterated. This anastomosis, and, consequently, the collateral circulation, is effected by the cutaneous, muscular, and periosteal branches, and even by those distributed to the nerves. Thus, along the clavicle, we find the acromio-thoracic in front, and the supra-scapular or transversus humeri behind; around the scapula there are the supra-scapular on the upper border, the posterior scapular on the vertebral border, and the sub-scapular on the axillary border; so that that bone is completely surrounded by an anastomotic triangle.

Around the elbow-joint are the external and internal collateral branches of the brachial artery, and the radial, ulnar, and interosseous recurrents.

Around the wrist we find the anterior and posterior carpal arteries, and also anastomotic arches around the metacarpo-phalangal and phalangal articulations.

On comparing the size and number of the arteries of the arm and forearm with the size and number of the arteries of the hand, it will be seen that the latter has greatly the advantage: indeed, in this part of the body, there is an unusual distribution of the arterial system into a deep and a superficial set of vessels, precisely as is the case with the veins. Why is this? Is it not extremely probable that, as the deep veins are intended to supply the place of the superficial, when the circulation in the latter is for a time impeded, so in the hand the arteries are arranged in a similar manner, because the

superficial circulation is liable to be interrupted by pressure from grasping hard bodies firmly in the hand for a longer or shorter period? and is it not for the same reason that the superficial system derived from the ulnar artery has so many communications with the deep system given off from the radial?

It is worthy of remark that the radial, which is the superficial artery of the forearm, becomes deep-seated in the hand; and that the ulnar, which is deep-seated in the forearm, becomes superficial in the hand.

The great quantity of blood circulated through the hand is connected with the active use of that part, in the almost constant exercise of the sense of touch, and in prehension.

ARTERIES ARISING FROM THE TERMINATION OF THE AORTA.

Enumeration.—The Middle Sacral.—The Common Iliacs.—The Internal Iliac, or Hypogastric—the Umbilical—the Vesical—the Middle Hemorrhoidal—the Uterine—the Vaginal—the Obturator—the Ilio-lumbar—the Lateral Sacral—the Glutæal—the Sciatic—the Internal Pudic.—Summary of the Distribution of the Internal Iliac.—Artery of the Lower Extremity.—The External Iliac—the Epigastric—the Circumflex Iliac.—The Femoral—the Superficial Epigastric—the External Pudic—the Muscular—the Deep Femoral, its Circumflex and Perforating Branches.—The Popliteal and its Collateral Branches.—The Anterior Tibial and the Dorsal Artery of the Foot.—The Tibio-peroneal—Peroneal—Posterior Tibial, and the Internal and External Plantar.—Comparison between the Arteries of the Upper and Lower Extremities.

The arteries arising from the termination of the aorta are the middle sacral and the two common iliac arteries.

The Middle Sacral Artery.

The *middle* or *anterior sacral artery* (*n, fig.* 199), the small median artery of the sacrum, arises from the lower and back part of the aorta, a little above its termination. Like the aorta, it is a single vessel, and seems to be the continuation of it, as far as direction is concerned; which, indeed, is really the case in such animals as are provided with a tail. Sometimes, but rarely, it arises from the left common iliac, or the last lumbar artery. I have seen it arise by a common trunk with the two lower lumbar arteries.* It passes vertically downward in front of the fifth lumbar vertebra, the sacrum and the coccyx being closely applied to them all. It is situated in the median line at its origin, but sometimes deviates to one side or the other. In size it is scarcely equal to one of the lumbar arteries, and it gradually diminishes from its origin to the first bone of the coccyx, towards the apex of which it terminates in a very variable manner.

The size of the middle sacral is generally inversely proportioned to that of the lowest lumbar arteries. When the aorta divides higher than ordinarily, and the last lumbar is given off from the middle sacral, the last-named artery is of course unusually large.

During its course, the middle sacral gives off, opposite the fifth lumbar and each of the sacral vertebræ, a right and left lateral branch, which correspond with the series of intercostal and lumbar arteries. The two *lumbar branches* are generally small, but are very large when the fifth lumbar arteries are neither furnished by the aorta, nor by the fourth lumbar, nor by the ilio-lumbar. The lateral branches given off upon the sacrum pass transversely outward, supply twigs to the periosteum and bone, and anastomose with the lateral sacral, the place of which they sometimes supply within the interior of the sacral canal.

The middle sacral having become very slender near the base of the coccyx, bifurcates in order to form an anastomotic arch with the right and left lateral sacral arteries. I have seen its lower end divided into three branches, of which the median was prolonged as far as the tip of the coccyx, while the lateral branches anastomosed with the lateral sacral arteries.

The Common Iliac Arteries.

The *primitive* or *common iliac arteries* (*i i, figs.* 199, 212), the two branches into which the aorta subdivides, commence opposite the lower margin of the fourth lumbar vertebra, and terminate by bifurcating opposite the base of the sacrum; they separate from each other at an acute angle, pass obliquely downward and outward, and form the two sides of an isosceles triangle, the base of which corresponds with the transverse diameter of the fifth lumbar vertebra. These arteries are generally straight, but not unfrequently they are tortuous in aged persons. In the adult they are about two inches long, the right being rather longer than the left, from the position of the aorta; but they are often much shorter, on account of their bifurcating higher than usual. Meckel has remarked that this premature bifurcation is more common on the left than on the right side. In a specimen deposited in the museum of the Ecole de Médecine, the right common iliac

* I have seen the middle sacral artery arise from the renal artery. In this case, the renal artery came from the angle of bifurcation of the aorta.

is entirely wanting; the aorta dividing into three branches, two on the right, viz., the internal and external iliacs, and one on the left, viz., the common iliac, which is distributed in the usual manner. In this case the descending aorta resembled, to a certain extent, the ascending aorta, and, like it, gave off three trunks

Relations.—They are covered by, and loosely connected with, the peritoneum; they are crossed by the ureters and the spermatic vessels, besides which, the left common iliac is crossed by the inferior mesenteric artery; they are surrounded by a great number of lymphatic glands, and rest above upon the vertebral column, and on the outside and below upon the inner side of the psoas muscle.

It is of great importance to comprehend their relations with the common iliac veins. The veins are situated behind the arteries; but as the right and left vein unite on the right side of the vertebral column, the left common iliac vein comes into relation with both common iliac arteries.

The *common iliac artery* gives off no collateral branch; it merely supplies some twigs to the cellular tissue, the lymphatic glands, and the coats of the common iliac veins. It occasionally gives off one of the renal arteries; and it has been seen to supply the spermatic and the ilio-lumbar arteries.

Terminal Branches.—The common iliac artery terminates by dividing into two branches, which remain in contact with each other for a short distance: the internal branch dips into the pelvis, and is called the *internal iliac* or *hypogastric* artery; the external branch continues in the original course of the common iliac, and is termed the *external iliac* artery.

The Internal Iliac or Hypogastric Artery.

The *internal iliac* or *hypogastric* artery (*t*, *figs.* 199, 212) is distributed to all the organs contained in the cavity of the pelvis; to the muscles which line it within and cover it without; to the external and internal organs of generation, and to the integuments.

Fig. 212.

It passes at first obliquely downward and forward, and, as it were, in contact with the external iliac; it then dips vertically into the pelvis in front of the sacro-iliac synchondrosis, describing a short curve; and, after a course of about one inch or one inch and a half in length, divides opposite the upper part of the sacro-sciatic notch into a greater or less number of branches, which do not always arise in the same way from the principal trunk, but whose ultimate distribution is constant. It is covered by peritoneum, and is crossed by the ureter; it rests behind on the lumbo-sacral nerve and pyriformis muscle; and the internal iliac vein is behind and to its outer side.

Its branches, all of which sometimes arise from two principal trunks, one anterior and the other posterior, may be divided into an *anterior* set, consisting of the *umbilical*, *vesical*, *obturator*, *middle hemorrhoidal*, *uterine*, *vaginal*, *sciatic*, and *internal pudic* arteries; and a *posterior* set, including the *ilio-lumbar*, *lateral*, *sacral*, and *gluteal* arteries. Altogether, there are nine in the male and eleven in the female.

The Umbilical Artery.

The *umbilical artery*, which is so large in the fœtus, is converted into an impermeable cord (*u*, *fig.* 212) in the adult, excepting near its origin (*a*), where it gives off some vesical branches: the examination of the umbilical arteries belongs, therefore, more especially to the anatomy of the fœtus. They are intended to convey the blood of the fœtus to the placenta, and are then the continuations of the common iliac arteries. The external and internal iliacs, being very small at that period, in correspondence with the small size of the abdominal extremities, appear to be nothing more than divisions of the umbilical.

The umbilical arteries pass downward, forward, and outward, and, having arrived at the sides of the bladder, run along them, in order to reach the umbilical ring, through which they emerge from the abdomen, and, having traversed the whole length of the umbilical cord in a spiral and tortuous manner, are at length distributed to the placenta.*

The vesical, middle hemorrhoidal, uterine, vaginal, and obturator arteries are given off in succession from the apparently ligamentous cord formed by the umbilical artery near its origin.

The Vesical Arteries.

These are variable in number: the principal of them on each side are given off from

* It is curious to study the variable manner in which the umbilical arteries are converted, after birth, into a fibrous tissue. Sometimes these arteries are converted into two regular cords, which converge towards the umbilicus. At other times each of these cords is subdivided into irregular bundles which it is difficult to trace to their true origin.

the umbilical artery (*a*), which seems to be converted into a ligamentous cord (*u*) at the place where the vesical arteries arise, but which is in reality pervious. This ligamentous appearance of the umbilical arteries depends upon the narrowness of their canal, as compared with the thickness of their coats. Other vesical branches arise from the middle hemorrhoidal and obturator arteries, and in the female from the uterine and vaginal. We shall divide the vesical arteries into the *posterior*, the *anterior*, and the *inferior*.

The *posterier vesical artery* (*b*, *fig.* 212) frequently arises, in the female, by a common trunk with the uterine. It reaches the base of the bladder, on the outer side of the ureter, passes inward and upward upon the posterior surface, as far even as the summit of that viscus. I have seen the right posterior vesical artery, of large size, running along the posterior surface of the bladder in the median line, and prolonged upon the urachus; the left posterior vesical was very small, and, in fact, rudimentary.

The *anterior vesical* (*c*) arises from the umbilical, from the obturator, and sometimes from the internal pudic artery. When it arises from the umbilical, it is given off from that artery opposite the sides of the bladder, and passes downward and inward along its anterior surface. I have seen it given off near the summit of that organ. When it arises from the obturator or the internal pudic, it traverses the anterior ligament of the bladder, and passes upward upon the front of that organ.

I have seen a very large vesical artery given off from the obturator, which, in that case, arose from the epigastric, and farther the vesical artery arose by a common trunk with the artery of the corpus cavernosum.

The *inferior vesical* (*d*), which often arises direct from the internal iliac, reaches the inferior fundus of the bladder, and ramifies abundantly upon it and the commencement of the urethra: in the male it also supplies the corresponding vesicula seminalis and vas deferens, the branch to which is called the deferential artery, and the prostatic portion of the urethra. I have seen the dorsal artery of the penis arise from the inferior vesical.

The Middle Hemorrhoidal Artery.

This is a small artery (*e*), which is sometimes wanting, its place being then supplied by branches from different sources, but especially from the sciatic or the internal pudic; it passes upon the sides of the anterior surface of the rectum, where it terminates by anastomosing with the superior and inferior hemorrhoidal arteries.

The Uterine Artery.

The *uterine artery* (*n n*, *fig.* 198) arises from the umbilica., near the posterior vesical, and frequently by a common trunk with it; passes transversely inward to the corresponding lateral border of the uterus, a little above the os tincæ; is reflected upward along the uterus, and terminates by expanding into several ascending branches, of which the anterior reach the front, the posterior the back, and the middle the upper border of the viscus, and inosculate either with their fellows of the opposite side, or with the uterine branches of the ovarian artery. The uterine arteries are remarkable for the great size which they acquire during pregnancy, and also for their tortuous and spiral course, even to their smallest branches: a disposition which no other artery presents in the same degree. These tortuosities, instead of diminishing, appear to increase during pregnancy: a fact which seems opposed to the view generally adopted regarding the use of arterial flexuosities in organs liable to variations in their size.

Collateral Branches.—At the point of its reflection, each uterine artery gives off one or more descending branches between the vagina and the bladder to supply both parts; in their course along the borders of the uterus, they furnish a series of anterior and posterior ascending branches, which are distributed in the same way as the terminal ascending branches; they all anastomose in the median line with their fellows of the opposite side.

Relations.—The trunks of the uterine arteries are beneath the peritoneum; the principal branches are situated under a thin layer of the substance of the uterus, and the ultimate divisions and subdivisions enter its tissue.

The Vaginal Artery.

The *vaginal artery* arises from the umbilical, sometimes before, sometimes after the origin of the uterine, which is sometimes given off from a common trunk with it. It is as large as the uterine in young subjects, but is smaller than it after puberty. It descends directly upon the sides of the vagina, to which it gives off a numerous series of branches, supplies a considerable branch to the neck of the bladder and the urethra, gives an equally large one to the bulb of the vagina, and then passes backward between the orifice of the vagina and the rectum, and anastomoses with its fellow of the opposite side.

The Obturator Artery.

The *obturator artery* (*f*, *fig.* 212) is remarkable for the varieties of its origin, and for the important consequences which result from those varieties, in reference to the operation for femoral hernia.

It generally arises from the internal iliac by the side of the umbilical, but sometimes above the gluteal; it is almost as frequently given off from the external iliac, either directly,* which is rare, or by a common trunk with the epigastric. Lastly, and much more rarely, it arises from the femoral artery.

The course of the obturator artery is modified by these differences of origin, which, notwithstanding the assertion of some anatomists, are as common in the male as the female, and which may occur on one side only, or on both sides of the same subject. Thus, when the obturator comes from the femoral, it passes upward on the inner side of the femoral vein, enters the pelvis through the crural ring, is reflected upon the upper surface of the body of the os pubis, then passes behind it and gains the internal opening of the sub-pubic canal. When it arises by a common trunk with the epigastric, it dips vertically behind the os pubis to the same opening. In its ordinary mode of origin, it passes horizontally forward upon the sides of the brim of the pelvis, being bound down by the peritoneum, runs parallel with the obturator nerve (*n*), which is placed above it, gains with it the internal orifice of the sub-pubic canal, and, having traversed this passage, divides into an *internal* and an *external* terminal branch.

Collateral Branches.—Near its origin, the obturator artery gives off a tolerably large branch, the *iliac*, which perforates the iliac fascia, dips between the iliacus muscle and the iliac fossa, and anastomoses with a branch of the circumflex iliac artery.†

As it enters the sub-pubic canal it gives off a small branch, which passes transversely behind the body of the pubis, and ramifies upon the side of the symphysis, anastomosing with its fellow of the opposite side; also a small ascending branch (*s*), which anastomoses with the epigastric artery, and which may be regarded, according to Meckel, as one of the origins of the obturator; so that the variety in which the obturator arises from the epigastric is often nothing more than an unusual development of this communicating branch. In support of this view, we may quote the very rare case, in which the obturator arises by two roots of almost equal size, one coming from the epigastric, and the other from the internal iliac.

Terminal Branches.—The *internal branch* passes between the obturator externus muscle and the conjoined rami of the pubes and ischium, so as to describe a semicircle around the inner half of the obturator foramen, gives branches to the periosteum of the os pubis, muscular branches to the two obturator and to the adductor muscles, some genital branches to the coverings of the testis in the male and to the labia majora in the female, and, lastly, some very important anastomotic branches, which join those of the internal circumflex.

The *external branch* runs along the outer half of the obturator foramen; it is placed, like the preceding, between the two obturator muscles, and terminates between the neck of the femur and the quadratus femoris muscle by anastomosing with the sciatic artery. This anastomosis is very remarkable. During its course, the external branch supplies the obturator muscles and the hip-joint; the articular branch enters by the notch of the cotyloid cavity, and is lost in the reddish, fatty tissue situated at the bottom of it. The distribution of the obturator artery is much more limited than that of the obturator nerve.

The Ilio-lumbar Artery.

The *ilio-lumbar* artery (*h*) arises from the back of the internal iliac, and, tolerably frequently, from the gluteal. There are often two ilio-lumbar arteries. This vessel bears the same relation to the lumbar arteries that the superior intercostal does to the aortic intercostals; its size and distribution vary according to the presence or absence of the fifth lumbar artery.

It has a retrograde course, running upward and backward in front of the lumbo-sacral nerve, and behind the psoas muscle, and soon divides into two branches: an *ascending* or *lumbar*, and a *transverse* or *iliac*. The *ascending* or *lumbar branch* passes vertically upward along the bodies of the lumbar vertebræ, hidden by the psoas, and subdivides into a *muscular* branch, which corresponds to the abdominal branches of the lumbar arteries, and is distributed to the psoas and to the quadratus lumborum; and a *spinal* branch, which enters the vertebral canal by the foramen between the fifth lumbar vertebra and the sacrum, and is distributed in the same manner as the other spinal arteries.

* The cases where the obturator artery arises separately from the external iliac are not unfrequent. The following description may serve as an example. In one case, the obturator artery arose separately from the external iliac artery, at the distance of one inch above the femoral arch, and above the origin of the epigastric artery; it went downward and inward to reach the lateral wall of the pelvis, crossed the obturator nerve, and entered the sub-pubic canal. In this subject, the obturator vein joined also the external iliac vein. The same disposition existed on both sides.

† The obturator artery sometimes gives off the artery to the bulb of the urethra. In a preparation which was exhibited by M. Denonvilliers, now *chef des travaux anatomiques*, at the concours for the office of prosector, I have seen a voluminous branch which had arisen from the obturator artery, extending all along the internal part of the obturator foramen, cross perpendicularly the posterior surface of the descending branch of the pubis, reach the bulb transversely by crossing the internal pudic artery, above which it was placed. This was on the left side. On the right side the arrangement was normal. This arrangement is not as rare as might be believed; it is evident that the ligature of the internal pudic artery would be useless in a case of this kind, in arresting a hemorrhage consequent upon an operation for the stone.

The *transverse* or *iliac branch* passes horizontally outward, opposite the brim of the pelvis, and divides into a superficial branch, which passes under the iliac fascia, ramifies upon the iliacus muscle, and anastomoses with the circumflex iliac artery; and into a deep and much larger branch, which passes between the iliacus muscle and the iliac fossa, and divides into muscular and periosteal twigs. The principal nutritious artery of the ilium is derived from this branch.

When there are two ilio-lumbar arteries, the superior represents the lumbar branch, and the inferior the iliac branch: in such a case the latter branch always arises from the gluteal artery.

The Lateral Sacral Arteries.

Most commonly there are two lateral sacral arteries on each side; they belong rather to the interior of the sacral canal than to the cavity of the pelvis, and form a continuation of the spinal branches of the lumbar arteries; they almost as frequently arise from the gluteal as from the internal iliac; sometimes they are derived from the sciatic or the ilio-lumbar arteries.

The *superior lateral sacral* is generally of considerable size. It passes almost horizontally inward, and after having given off some small transverse branches, which anastomose with the middle sacral, enters the first anterior sacral foramen, and divides into two branches: one intended for the nerves and their coverings, and another which emerges from the sacral canal by the corresponding posterior sacral foramen, and is distributed to the spinal muscles and to the skin.

The *inferior lateral sacral* (*l*, *fig.* 212) is situated at first under the digitations of the pyriformis muscle, afterward passes in front of that muscle, and is directed inward and downward on the inner side of the sacral foramina, and along the borders of the coccyx, where it anastomoses with the middle sacral. In this course it gives off a series of very small internal branches, which correspond to the several sacral vertebræ, and anastomose with the middle sacral; also some posterior or spinal branches, each of which enters the sacral canal through the corresponding sacral foramen, and subdivides into two small branches: one intended for the nerves and their coverings, while the other emerges from the sacral canal by the corresponding posterior sacral foramen, and is distributed to the muscles and the skin. When the superior lateral sacral is small, the posterior or spinal branch of the inferior lateral sacral is very large. The inferior lateral sacral artery often terminates by a spinal branch, which enters at the lowest anterior sacral foramen.

The Gluteal Artery.

The *gluteal artery* (*m*, *fig.* 212), called also the posterior iliac, is the largest branch of the internal iliac, of which it might be considered the continuation. It might be called *superior gluteal*, in contradistinction to the sciatic, which is, in reality, an inferior gluteal. It passes downward and backward between the *lumbo-sacral nerve* and the first sacral nerve, escapes from the pelvis at the upper part of the great sacro-sciatic notch, above the pyriformis muscle (*m*, *fig.* 45), is reflected upon the border of that notch, and divides into a *superficial* and a *deep* branch. The *superficial branch* (*a*) passes horizontally forward, between the glutæus maximus and medius, and is almost entirely distributed to the upper part of the first-named muscle and to the adjacent part of the skin; the *deep branch* (*b*) passes between the glutæus medius and minimus, and subdivides into two branches; the lower of these runs horizontally, and may be traced as far as the anterior border of the glutæus medius, while the other very nearly follows the curve described by the origin of the glutæus minimus. This branch gives off some muscular arteries, several nutritious arteries to the bone, and several articular branches.

One circumstance regarding the gluteal artery worthy of remark is the fact that, in common with all arteries of a certain size, it is liable to aneurism, and that for the cure of this aneurism (which has always been the result of external violence), the common iliac artery has in two cases been tied in America, and the gluteal artery itself recently by an English surgeon.

The Sciatic Artery.

The *sciatic artery* (*o*, *fig.* 212), from its distribution, might be called the *inferior gluteal*. It often arises by a common trunk, either with the gluteal or with the internal pudic, behind and internal to which it is situated; it descends in front of the sacral plexus and the pyriformis muscle, traverses the sacral plexus, emerges from the pelvis (*o*, *fig.* 215) between the pyriformis and the lesser sacro-sciatic ligament, accompanied on its inner side by the great sciatic nerve, and behind by the internal pudic artery (*p*). Outside the pelvis, the sciatic artery gives off *internal* or *transverse* branches, some of which pass transversely inward between the glutæus maximus and the great sacro-sciatic ligament, while others (*c*) perforate that ligament, and ramify in the internal attachments of the glutæus maximus. Several of these branches ramify upon the skin of the coccygeal region; its other branches are *descending*, the largest of which (*d*) gains the deep surface of the glutæus maximus, and enters that muscle by numerous branches, which become cuta-

neous at their termination; one and often two or three branches (*e*) of the sciatic artery attach themselves to the deep surface of the great sciatic nerve, and accompany it to the lower part of the thigh. A great number of twigs are given off from the several branches of the sciatic artery, which are distributed to the small rotator muscles, or to the origins of the muscles attached to the tuberosity of the ischium, while others anastomose with the circumflex (*f*) and perforating arteries (*s*) derived from the femoral. Among these anastomoses, I would point out one very considerable anastomotic loop, formed behind the neck of the femur by the sciatic and internal circumflex arteries, and constituting one of the principal communications between the internal iliac and femoral arteries.

The Internal Pudic Artery.

The *internal pudic* (*p*, *fig.* 212), the terminal branch of the internal iliac, is, practically speaking, the most important of all the pelvic arteries. It is smaller than the sciatic, from which it is sometimes given off, either shortly after the origin of that vessel, or as it is passing out from the pelvis. The internal pudic runs in a tortuous manner downward, in front of the sacral plexus and the pyriformis muscle, parallel to the sciatic artery (*o*), which is behind it; escapes from the pelvis, together with that vessel (*p*, *o*, *fig.* 215), between the pyriformis muscle and the spine of the ischium; is reflected upon that process, turning round it from behind forward, so as to embrace in succession its posterior, its external, and its anterior surfaces, and then enters the pelvis again between the two sacro-sciatic ligaments. The artery, after descending a short distance, then becomes ascending, and is situated in the ischio-rectal fossa (*a*, *fig.* 213), and is applied to the internal surface of the tuberosity of the ischium, or, rather, of the obturator internus muscle, with which it is kept in contact by a layer of fascia: it is separated from the levator ani by a considerable quantity of fat, and having reached the posterior border of the transversus perinei muscle, it divides into an *inferior*, *superficial*, or *perineal* branch (*c*), and a *superior* or *deep* branch (*e*), which is distributed to the *penis* in the male and to the *clitoris* in the female. An important variety in the course of this artery has been pointed out by Burns, who, in a male subject, saw the trunk of the internal pudic, instead of passing out of the pelvis, run upon the sides of the inferior fundus of the bladder, perforate the upper part of the prostate, and then terminate in the usual manner.

Fig. 213.

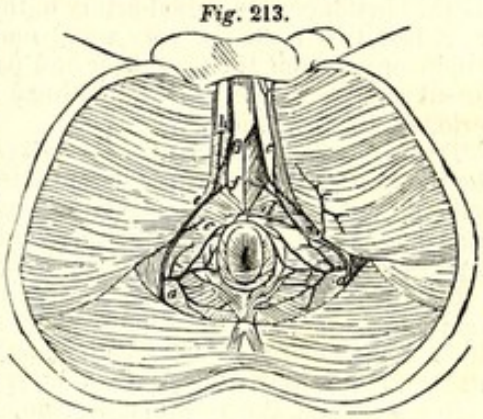

Collateral Branches.—During its course within the pelvis, the internal pudic supplies branches to the bladder, rectum, vesiculæ seminales, and prostate in the male, and to the vagina in the female; it also rather frequently gives off the middle hemorrhoidal. As it turns round the spine of the ischium, it gives some branches to the rotator muscles of the thigh. Opposite the internal surface of the tuberosity of the ischium, it gives origin to one or more branches, named the *external* or *inferior hemorrhoidal* (*b*, *fig.* 213), which run inward to be distributed to the lower end of the rectum, to the sphincter, the levator ani, and the skin; also some branches which proceed outward, some to supply the periosteum of the tuberosity, while others ramify in the muscles attached to that process; lastly, a very important communicating branch passes between the tuberosity of the ischium and the great trochanter, and anastomoses with the sciatic and internal circumflex arteries.

Terminal branches.—These differ in the two sexes. We shall first describe them in the male:

The *inferior branch*, the *superficial artery of the perineum*, or the *perineal artery* (*c*), is smaller than the superior branch: it passes forward and inward, in the cellular interval between the ischio-cavernosus and the bulbo-cavernosus; above, *i. e.*, deeper than the superficial fascia of the perineum, which separates it from the skin; and below, *i. e.*, superficial to the transversus perinei muscle, it thus reaches the dartos at the side of the median line, where it is named the *artery of the septum*, and is distributed to the scrotum and the skin of the penis.

During its course the superficial perineal artery gives internal and external branches. Some of the internal branches run along the posterior border of the transversus perinei muscle, and are sometimes so large as to bleed very profusely when they are divided in the operation of lithotomy; from its situation, one of them is named the transverse artery of the perineum (*d*).

The *deep superior* or *deep branch* (*e*), or the *artery of the penis* (in the male), is the continuation of the trunk of the internal pudic, both in regard to size and direction: it runs along the ascending ramus of the ischium, between the layers of the triangular ligament; above, *i. e.*, deeper than the transverse muscle, which it sometimes perforates, also above the ischio-cavernosus and the corresponding crus of the corpus cavernosum; and oppo-

site the point at which the two crura unite, it subdivides into two branches, viz., the *dorsal artery of the penis* (*g*) and the *artery of the corpus cavernosum* (*h*).

During its course, the artery of the penis gives off a very important collateral branch, named *the artery of the bulb* (*f*), which is as large as the superficial perineal artery, is sometimes double, and generally arises near the bulb, passes transversely inward, above the middle perineal fascia or triangular ligament, or, rather, in the substance of that ligament, and is distributed to the bulb of the urethra and to the spongy portion of this canal.*

The *dorsal artery of the penis* (*g*) is sometimes the only terminal branch of the internal pudic, and then a very delicate twig supplies the place of the artery of the corpus cavernosum, which, in this case, is supplied from another source. This artery reaches the dorsal surface of the penis by passing between the symphysis pubis and the crura of the corpus cavernosum, and perforating the suspensory ligament of the penis, and then runs in a very tortuous manner along, beneath the skin, upon the dorsal aspect of that organ, on one side of the median line, being retained in its position by a layer of fibrous membrane : it terminates by ramifying in the prepuce and in the glans, around the base of which it forms a *corona*. I have seen the dorsal artery of the penis given off by one of the external pubic arteries, from which it arose immediately above the entrance of the saphenous vein into the femoral ; it then formed a curve in the groin, with its concavity directed downward, and passed upon the sides of the dorsal surface of the penis ; in another instance, the dorsal artery of the penis was derived from the obturator, or, rather, it had two roots : a very small one, which had the usual origin, and a large one, which arose from the obturator and passed under the symphysis. The right and left dorsal arteries of the penis sometimes anastomose by a transverse branch, like the anterior cerebral arteries.

The *artery of the corpus cavernosum* (*h*) is also sometimes the only terminal branch of the internal pudic artery, the dorsal artery of the penis, in such cases, being derived from some other source. I have seen the cavernous artery arise from the obturator. In all cases it enters the corpus cavernosum by the corresponding crus, runs along its median septum, and ramifies in its areolar structure.

I have seen the dorsal arteries of the penis and the cavernous artery arise by a common trunk from the hypogastric ; this trunk passed directly from behind forward to be divided immediately. The same disposition existed on both sides. The internal pudic artery gave off a small cavernous artery.

In the female, the terminal branches of the internal pudic are arranged as follows : the *inferior* or *superficial perineal branch* is larger than the superior, and might be named the *artery of the labia majora*, to which it is distributed ; the *superior* or *deep branch*, or the *artery of the clitoris*, runs along in contact with the tuberosity of the ischium, and then with its ascending ramus, and having given off a branch, which runs inward to the bulb of the vagina, terminates in the *dorsal artery* and *cavernous artery of the clitoris*, these vessels being very small in consequence of the diminutive size of that organ.

Summary of the Distribution of the Internal Iliac Artery.

The internal iliac artery, which is so deeply situated as to be inaccessible to the surgeon, sends branches to all the organs contained in the cavity of the pelvis ; to the bony parietes of the pelvis and the sacral canal ; to the muscles which line the pelvis within and cover it without ; and to the skin and the external genital organs.

Its several branches may be divided into *parietal* and *visceral*. The *visceral branches* are the vesical, middle hemorrhoidal, vaginal, and uterine arteries, and the deep branch of the internal pudic. The sympathy existing between all the organs to which the above-named vessels are distributed, depends less upon those vessels having a common source than upon the community of origin of the several nerves which those vessels serve to support.

The *parietal branches* are the ilio-lumbar and lateral sacral arteries, which, with the middle sacral, continue the series of intercostal and lumbar arteries into the sacral region, and supply the sacrum, the spinal nerves and their coverings, and also the muscles of the vertebral grooves and the skin of the sacral region ; the glutæal and the sciatic arteries intended for the muscles of the glutæal region ; the superficial branch of the internal pudic artery, which supplies the perineum ; and, lastly, the obturator artery, which forms an arterial circle around the obturator foramen, and supplies the obturator muscles.

Several branches of the internal iliac artery establish anastomoses between that vessel and the femoral artery ; these are more especially the sciatic, the internal pudic, the gluteal, and the obturator arteries.

Artery of the Lower Extremity, or Crural Trunk.

The arterial trunk of the lower extremity, or the *crural* trunk (*Chaussier*), corresponds

* The artery of the bulb, after having traversed the bulb, is directed from behind forward in the substance of the spongy portion of the urethra, and may be followed up to about its middle part. When the artery of the bulb comes from the obturator artery, the inferior pudic sends a rudimentary branch to the bulb. It is the pudic artery which supplies Cowper's glands.

with the brachial trunk of the upper extremity. This vessel, which is the direct continuation of the common iliac artery, passes downward and outward, emerges from the pelvis beneath the crural arch, and thus reaches the anterior region of the thigh. Opposite the junction of the two upper thirds with the lower third of the femur, it traverses the fibrous canal formed for it by the tendon of the great adductor muscle, and thus gains the popliteal space, at the lower part of which it terminates by dividing into two branches. The numerous and important relations of this vessel, and the great number of branches arising from it, have led to its division by anatomists into three portions, which are named the *external iliac artery*, the *femoral* or *crural artery*, and the *popliteal artery*. The two terminal branches are the *anterior tibial*, which, in the foot, is termed the dorsal artery of the foot, and the *tibio-peroneal trunk*, which divides into the *peroneal* and *posterior tibial* arteries, the latter of which terminates in the sole of the foot by subdividing into the *internal* and *external plantar arteries*.

The External Iliac Artery.

The *external iliac artery* (*r*, *figs.* 199, 212), the outer of the two branches into which the common iliac divides, is analogous to the subclavian artery in the upper extremity. It extends from the highest part of the sacro-iliac symphysis to the lower border of the femoral arch or Poupart's ligament, below which it takes the name of *femoral artery*. It is directed obliquely downward and outward, in a line extending from the sacro-iliac symphysis to the crural ring, and is almost always straight, but sometimes tortuous. It has the following relations: *in front* and *on the inner side*, it is covered by the peritoneum, which is very loosely attached to it: an important fact, which enables the surgeon to separate that membrane from it in applying a ligature to the vessel; *on the outer side*, it rests against the psoas muscle, from which it is separated by the iliac fascia; *behind*, the artery of the right side is in relation with the corresponding external iliac vein, which is placed to its inner side below; on the left side the vein is below, and on the inner side of the artery; lastly, the genito-crural nerve, just as it is about to enter the inguinal canal, crosses in front of this artery, and so also do the spermatic vessels; the circumflex iliac vein crosses it at right angles behind the femoral arch, in order to terminate in the external iliac vein; besides this, it is covered immediately behind the arch by several lymphatic glands; higher up, the ureter crosses obliquely in front of it, and the artery of the right side is covered by the termination of the ileum, and that of the left side by the sigmoid flexure of the colon.

Collateral Branches.—The external iliac artery furnishes no branches, excepting at its lower part, near the femoral arch, where it gives off the *epigastric* and *circumflex iliac* arteries.

The Epigastric Artery.

The *epigastric artery* is, practically speaking, one of the most important to be well understood, on account of its relations with the crural ring and inguinal canal, that is to say, with the parts through which the viscera generally descend in herniæ.

This artery (*v*, *figs.* 199, 212) arises from the inner side of the external iliac, two or three lines above the femoral arch. Its origin, however, is subject to some varieties: sometimes it takes place half an inch, one, or even two inches above the crural arch: an important fact in reference to the application of a ligature to the external iliac. Hesselbach and several others state that they have seen the epigastric arise from the obturator artery; but their descriptions appear to me to prove nothing more than that the epigastric and obturator arteries may arise by a common trunk. It is worthy of remark that the obturator is often observed to arise from the epigastric, while there is, perhaps, no example of the epigastric being derived from the obturator. The obturator so frequently arises by a common trunk with the epigastric,* that many anatomists have thought that the obturator is derived from the epigastric more frequently than from the internal iliac artery. In 250 subjects examined for this purpose by M. Jules Cloquet, the obturator arose 150 times from the epigastric on both sides, 28 times on one side only, and 6 times from the femoral artery. Although it is a very common occurrence to have the obturator artery arising from the epigastric, it is very rare to find the epigastric taking its origin from the obturator. This anatomical variety has only been reported as having occurred in two cases. One can easily understand how dangerous it would be to operate for the relief of a strangulated hernia in such a case.

The epigastric artery, whether it gives off the obturator or not, passes transversely or obliquely inward, and, having arrived below the spermatic cord in the male, and the round ligament in the female, is reflected upward, so as to describe a curve having its concavity directed upward, and corresponding to the loop formed by the spermatic cord or round ligament, the concavity of which is directed downward. When the obturator arises by a common trunk with the epigastric, it is given off at the point where the latter is reflected upward, and from the convexity of the curve. After being reflected, the

* It would be very difficult to explain why the epigastric and the obturator arteries are so intimately connected at their origins.

epigastric artery ascends obliquely inward, soon reaches the outer border, and next the posterior surface of the rectus abdominis muscle, and then passes vertically upward. Having reached the umbilicus, it penetrates into the substance of the rectus, and terminates by anastomosing with the internal mammary artery.

Relations.—The relations of the transverse, oblique, and vertical portions of the epigastric artery should be examined separately. The *transverse portion* varies in length in different subjects; sometimes it is almost entirely wanting, the artery running immediately upward; at other times it is an inch and a half in length. This difference in length, which is of no consequence when the obturator artery arises from the internal iliac, becomes highly important when that vessel is given off from the epigastric.*

This transverse portion of the artery is directed obliquely downward, when the epigastric arises at a certain distance above the ring.

The *oblique portion* of the epigastric artery forms the outer side of a triangle, the inner side of which is formed by the outer border of the rectus abdominis muscle, and the base by the crural arch: the epigastric constitutes the true boundary between the internal inguinal fossa, which comprises all the triangular space situated on the inner side of the vessel, and the external inguinal fossa, which comprises the space upon its outer side. The abdominal orifice of the inguinal canal is situated in the external inguinal fossa, and, consequently, to the outer side of the epigastric artery. Those inguinal herniæ which pass through the internal fossa are called internal or direct inguinal herniæ; those which take place on the outer side of the artery are called external or oblique inguinal.

In its horizontal and oblique portions, the epigastric artery is placed between the peritoneum and the fascia transversalis. I should observe that the spermatic cord in the male, and the round ligament in the female, do not cross the epigastric artery precisely in the situation of the loop which this vessel describes, but a little above it. The axis of the inguinal canal being directed obliquely downward and inward, intersects at right angles the oblique portion of the artery, which slopes in the opposite direction.

In its *vertical portion*, the epigastric artery is situated between the rectus and the posterior wall of the sheath of that muscle until near the umbilicus, where it dips into the fleshy fibres.

Collateral Branches.—Near its origin, or, rather, opposite the bend which it takes, the epigastric artery sometimes gives off the internal circumflex, which, as we shall hereafter see, generally arises from the deep femoral. It always gives off the following branches: a *cremasteric* branch (*l*, *fig.* 214), which enters the inguinal canal, runs along the fibrous sheath of the cord in the male, and the round ligament in the female, and passes in the one to the coverings of the testicles, and in the other to the labia majora; a second branch, which runs along the inner portion of the femoral arch, and anastomoses with its fellow of the opposite side behind the symphysis; and, lastly, a branch which crosses the horizontal ramus of the pubes at right angles, and anastomoses with the obturator. I have already stated that this small branch may be regarded as forming the trunk of the obturator when that artery arises from the epigastric. In its oblique and vertical portions, the epigastric gives off a number of *internal* and *external ascending* branches, which pass very obliquely through the rectus abdominis, partially supply that muscle, and then pierce the anterior wall of its sheath, the internal branches near the linea alba, and the external branches near the outer border of the sheath, to ramify upon the skin. These branches anastomose with the internal mammary and with the lumbar arteries.

The anastomosis of the epigastric with the internal mammary takes place only in the substance of the rectus, and by very small vessels.

The Circumflex Iliac Artery.

The *circumflex* or *posterior iliac* artery (*x*, *figs.* 199, 212), smaller than the epigastric, arises from the outer part of the external iliac, either opposite the epigastric or a little below it. It sometimes arises from the upper part of the femoral artery: it is generally single, but occasionally double, which may be regarded as resulting from a premature division of the vessel.

It passes obliquely upward and outward, behind the crural arch, with which it is held in contact by a fibrous layer interposed between it and the peritoneum. Opposite the anterior superior spinous process of the ilium it divides into two branches: one is an *ascending* or *abdominal branch*, which passes upward, in the substance of the abdominal parietes, between the transversalis and obliquus internus muscles, parallel with the epigastric artery, and terminates by anastomosing with the inferior intercostal and the lumbar arteries; the other is the *circumflex* iliac artery properly so called, which is the

* [If the obturator arises high up from the epigastric, it describes, before it enters the pelvis, a semicircle extending along the upper, and then the inner border of the crural ring; and, consequently, has such relations with the neck of the sac in femoral hernia, that render it almost impossible to avoid wounding the artery in dividing the stricture upward and inward. But if, as is much more frequently the case, it arises from near the commencement of the epigastric, or by a common trunk with it, it then descends at once into the pelvis obliquely along the outer border of the crural ring, and will have the same relation with a femoral hernia.]

continuation of the vessel in direction and sometimes in size; it runs along the crest of the ilium, is at first sub-aponeurotic, or, rather, is contained between two layers of fascia in the cellular interval separating the transversalis from the obliquus internus, and terminates by anastomosing with the fourth lumbar artery upon the crest of the ilium.

During its course, the circumflex iliac artery gives off ascending branches, which ramify in the muscles and integuments of the abdominal parietes; and descending branches, which ramify in the iliac fossa, and anastomose with the iliac branches of the obturator artery.

The Femoral Artery.

The *femoral* or *crural artery* (*a a'*, *fig.* 214) is that portion of the artery of the lower extremity which intervenes between the external iliac and popliteal arteries; it is bounded above by the crural arch, and below by the junction of the two upper thirds with the lower third of the thigh, or, rather, by the place where the artery passes through the tendinous ring formed by the adductor magnus.

Fig. 214.

It has been proposed to take as the lower boundary of the femoral artery the origin of the deep femoral or profunda artery, which has been correctly regarded as a terminal branch resulting from the bifurcation of the femoral artery, rather than as a collateral branch. According to this view, which has not been generally adopted, the femoral would not be more than from an inch and a half to two inches in length, and would divide into a superficial and deep femoral.

The femoral artery is directed vertically, and somewhat obliquely backward, so that it forms a slight angle with the external iliac, on account of the oblique inclination forward of that vessel; and, farther, although it is in front of the femur above, it is placed on the inner side of it below, preparatory to becoming posterior to it in the popliteal space. A line drawn from the middle of the space between the anterior superior spinous process of the ilium and the symphysis pubis, down to the inner side of the femur, below the middle of that bone, would exactly represent its direction. The direction of the femoral artery, in respect to the femur, is such, that immediately below the femoral arch it is situated over the point of junction of the inner with the two outer thirds of the head of that bone, while lower down it is in relation with the inner aspect of the bone; the artery, therefore, forms an acute angle, opening upward, with the shaft of the femur, and there is an interval of an inch to eighteen lines between the vessel and the upper part of the bone, into which instruments may be passed without wounding the artery. Advantage is taken of this fact in disarticulating the head of the femur in amputation at the hip-joint.

The femoral artery, which is slightly tortuous when the thigh is flexed upon the pelvis, becomes straight when the limb is extended, and it is much stretched during forcible extension.

Relations.—In front, the femoral artery lies beneath the fascia in the triangular space which is bounded on the inside by the inner border of the adductor longus; on the outside, by the sartorius; and above, by the femoral arch. Lower down, the sartorius is placed between the fascia and the artery, which is in relation, first, with the inner border, then with the posterior surface, lastly, with the outer border of that muscle: besides the fascia, a number of lymphatic glands lie between the upper part of the artery and the skin. Enlargement of one or more of these glands has been mistaken for an aneurism, and an aneurism for an enlarged gland. From these relations of the front of the femoral artery, it follows that its anterior aspect may be exposed in the whole of its extent, but that it is more superficial in the neighbourhood of the crural arch.

Behind, the femoral artery rests, first, upon the body of the pubes, or the ilio-pectineal eminence, with which it is in immediate contact in emaciated subjects, but from which it is generally separated by the contiguous borders of the psoas-iliac and the pectineus muscles. The iliac fascia separates it from the psoas-iliac muscle, so that, in cases of simple psoas abscess, or congestive abscess from caries of the lumbar vertebræ, the femoral artery is situated in front of the sac of the abscess. The femoral artery is also in relation, behind, with the head of the femur; lower down, with the pectineus, and then with the adductor longus. It follows, therefore, that the femoral artery may be very effectually compressed at its upper part, since it is superficially situated, and rests upon hard parts.

On the outer side, it is in relation, first, with the psoas-iliac, then with the inner border

of the sartorius, and, lastly, with the vastus internus, which separates it from the inner surface of the femur.

In consequence of this relation to the bone, and also of the slight thickness of the sartorius, which separates it from the skin, the femoral artery may be compressed against the femur from within outward in the middle third of the thigh.

On its inner side, it is in relation with the pectineus, the adductor longus, and afterward with the outer border of the sartorius.

Relations of the Artery with the Vein and Nerves.—The femoral vein is situated on the inner side of the artery above, but it soon passes behind it, and, still lower down, is on its outer side. The crural nerve lies on the outer side of the artery, from which it is separated by a fibrous layer belonging to the sheath of the psoas and iliacus. The artery and nerve, therefore, have no immediate relation with each other; but the internal or long saphenous nerve soon runs upon the sheath of the femoral vessels, and is situated on the outside of the artery; but as the vessel is passing through the tendon of the adductor magnus, the nerve leaves it, and, lower down, escapes from under the tendon of the sartorius. The short saphenous nerve, or nerve of the internal vastus, is in relation with the outer side of the artery for a short distance, and the vessel is also crossed by another small nerve.

The Sheath of the Femoral Vessels.—The femoral artery and vein are enclosed in a proper fibrous sheath, which is constructed, as it were, in the midst of the muscles of the thigh (see APONEUROLOGY). It is, therefore, necessary to open this sheath, and not that of any of the surrounding muscles, in order to expose the artery.

Anatomical Varieties.—Independently of the very frequent and remarkable anatomical varieties in the origin of the deep femoral artery, which is often given off opposite, and sometimes above the femoral arch—varieties to which I shall immediately refer in speaking of the deep femoral artery—the common femoral artery itself offers some varieties which are not less interesting. The most important is the following, found in a preparation deposited by M. Manec in the museum of Clamard: In this preparation, the femoral artery presents behind the Fallopian ligament a caliber which is not larger than that of the radial artery, and is lost in the anterior muscles of the thigh. The ischiatic artery, which is a branch of the hypogastric, presents, on the contrary, the caliber of the femoral artery, descends backward along the great sciatic nerve, and is continuous with the popliteal artery. During its course along the thigh, the ischiatic artery gives off the muscular branches which generally come from the deep femoral artery.

Collateral Branches.—The collateral branches of the femoral are, the superficial epigastric artery, the two *external pudic* arteries, a great number of *muscular branches*, and the *deep femoral* artery.

The Superficial Epigastric Artery.

The superficial epigastric or sub-cutaneous abdominal artery (cut across at *b*, *fig.* 214) is a very small, but remarkably constant branch, which arises from the front of the femoral, and sometimes from the external pudic, immediately below the crural arch, passes vertically upward, between the integuments and the superficial fascia, gives some branches to the inguinal lymphatic glands, and terminates in the skin, near the umbilicus (arteria ad cutem abdominis, *Haller*)

The External Pudic Arteries.

The *external pudic* or *genital arteries*, also named *scrotal* in the male, and *vulvar* in the female, arise from the inner side of the femoral: they are two in number (*c c*, *fig.* 214), and are named the *superior* or sub-cutaneous, and the *inferior* or sub-aponeurotic.

The *superior* or *sub-cutaneous* arises immediately below the crural arch, passes transversely inward in the sub-cutaneous cellular tissue, and divides into two branches: a superior, which passes to the pubic eminence, and an inferior, which is distributed to the skin of the penis and scrotum in the male, and to the corresponding external labium in the female. I have seen the dorsal artery of the penis arise from this vessel.

The *inferior* or *sub-aponeurotic branch* arises a little below the preceding, and sometimes even from the deep femoral; it passes transversely inward, crosses the femoral vein at right angles immediately below the point where it is joined by the saphenous vein, so that this artery is generally received in the loop described by the upper end of the saphenous vein: it soon perforates the fascia and becomes sub-cutaneous, and then ramifies in the scrotum in the male, and in the external labium in the female. The anastomoses of the superior and inferior external pudics, both with each other and with those of the opposite side, are so free and large, that when one of them is cut across, it becomes necessary to tie both of the cut ends of the vessel. These arteries are remarkable on account of their relations with hernial tumours.

The Muscular Arteries.

The femoral gives off a great number of muscular and cutaneous branches, which have received no particular names. One, however, is usually described as the *superficial* or

great muscular artery, which frequently arises from the deep femoral; it passes transversely between the sartorius and the rectus femoris, and immediately divides into *ascending branches*, which proceed to the iliacus, sartorius, and tensor vaginæ femoris, and into very large *descending branches*, some of which are distributed to the rectus femoris, passing in at its posterior surface, while others penetrate the vastus internus and vastus externus. The last-mentioned branches can be traced as far as the lower part of the triceps muscle; and, indeed, the great muscular artery might be named the muscular artery of the triceps extensor femoris, which (*g*, *fig.* 214) may arise from the deep femoral artery.

The Deep Femoral Artery.

The *deep femoral artery* (*profunda femoris*; *d d'*, *fig.* 214.) is intended to supply the muscles and integuments of the internal and posterior regions of the thigh.*

It arises from the back of the femoral, generally about one and a half or two inches below the crural arch, about half way between the pubes and the lesser trochanter, very rarely below this point, but more commonly above it. Thus the femoral often divides, either about six lines below the crural arch, or immediately beneath and on a level with it, into two equal and parallel branches, of which the *external* is the deep femoral, and the *internal* the femoral properly so called. I have seen this subdivision, which bears a rather close analogy to the bifurcation of the humeral artery into the radial and ulnar in the axilla, take place above the crural arch, that is to say, in the external iliac artery. Immediately after its origin, the deep femoral passes backward and outward, and then vertically downward, gradually approaching the femur; it is situated deeply behind the femoral artery, but is separated from it by the femoral and deep femoral veins; it runs parallel to the femoral artery, in front of the pectineus, and on the outer side of the vastus internus; having reached the upper border of the long adductor, it passes behind that muscle to arrive between it and the short and great adductors, perforates the latter muscle a little below the tendinous opening for the proper femoral artery, and terminates by ramifying in the biceps and semi-membranosus. Sometimes the deep femoral perforates the adductor magnus almost immediately, and at once becomes posterior to it.

Varieties of Origin.—In the history of the deep femoral artery, the varieties in its origin are most important, considered in a surgical point of view.

The common femoral artery is very often divided prematurely into two equal and parallel branches, the external of which is the deep femoral, and the internal the true or superficial femoral artery.† This premature division may take place at a distance of six lines below the crural arch, opposite this arch, or even beneath it. I have seen this division, which bears a resemblance to the high division of the humeral artery into the radial and ulnar arteries in the hollow of the axilla, to take place above the femoral arch, consequently at the expense of the external iliac artery. Burns has seen this division taking place in the pelvis three times; Tiedemann, who has observed it on both sides, thinks that it is only met with in small-sized individuals. In a case which Professor Dubreuil has communicated to me, where the right femoral artery was divided higher than usual, the epigastric artery, instead of being given off by the external iliac, came from the deep femoral, and the anterior circumflex iliac artery came from the superficial femoral artery.

In another case which has been furnished to me by the same observer, the external iliac or femoral artery, in its passage below the crural arch, was divided into three branches: the external branch was the superficial muscular, the internal branch was the deep muscular, which, immediately after its origin, dipped between the muscles; the middle branch, which was of a larger size than the two others, was the true femoral artery. The only anomalies in this case were in the origin of the branches; in their distribution they were as usual.

During its course, the deep femoral gives off a great number of collateral branches, which are soon expended in the adjacent muscles, and most of which are unnamed. Those that are named are the *internal* and *external circumflex*, and the several *perforating* arteries.

The *internal circumflex artery* (*e*) is larger than the external, and is the first branch given off from the deep femoral; not unfrequently it arises from the femoral. I have observed, however, that this only takes place when the deep femoral artery arose a little lower down than usual. In a case of this kind, the origin of the deep artery took place

* It is the proper artery of the thigh, while the femoral itself may be regarded as the artery of the leg and foot.

† This relation is the one which always exists when the deep femoral artery arises opposite or above the femoral arch; the deep femoral passes down close by the external side of the superficial femoral; this latter covers the vein: if, in a case of this kind, the femoral artery were to be tied, and the ligature were applied only to one vessel, it would be to the deep artery, which holds the relations that generally belong to the trunk of the femoral artery itself.

In a case exhibited at the Anatomical Society by M. Mercier, the deep femoral, which arose from the anterior side of the common femoral six lines below the arch, descended downward before the femoral vein, which it crossed opposite the opening for the scaphena vein, turned round this vessel to become the deep artery, and coursed along as usual. In this case, the deep femoral gave off the external pudic arteries.

more than two inches below the femoral arch. Sometimes the internal circumflex comes from the external iliac artery. Whatever may be its origin, it almost immediately dips backward, between the pectineus and the neck of the femur, round which it turns in the same manner as the posterior humeral circumflex artery, so that it may be ruptured in luxation of the femur inward: it escapes backward beneath the quadratus femoris, and terminates by dividing into ascending branches, and into internal and external descending branches.

Opposite the pectineus, it gives off the following collateral branches: one very remarkable *articular branch* ascends along the capsular ligament, enters the hip-joint, passes under the ligament which converts the cotyloid notch into a canal, and is distributed to the synovial membrane, the adipose tissue, and the fibrous capsule of the joint: one or more anastomotic branches communicate freely with the ramifications of the obturator artery; lastly, a great number of muscular branches, some of which are very small, and pass in front of, while others, which are larger, run behind, the pectineus, and are distributed to the obturator externus, the pectineus, and the adductors: the largest is intended for the adductor magnus.

The *terminal branches* are as follows: *Ascending muscular branches*, some of which are external, and ramify in the glutæus maximus, while others are internal, and are distributed to the ischiatic attachments of the biceps, semi-tendinosus, and semi-membranosus muscles; *descending muscular branches*, which ramify upon the anterior surface of the biceps, semi-tendinosus, and semi-membranosus, upon the great sciatic nerve, and also in the small muscles situated between the pelvis and the trochanter major; *periosteal branches*, of which some ramify upon the periosteum of the trochanter, others upon the posterior surface of the neck of the femur; and, lastly, *anastomotic branches*, which pass upon the obturator, gemelli, and pyriformis muscles, and anastomose freely with the sciatic, glutæal, internal pudic, and obturator arteries, but especially with the sciatic and the obturator.

It follows, then, that the internal circumflex is an important means of communication between the internal iliac, and, consequently, the common iliac and the femoral; for, independently of the direct anastomoses above mentioned, there are a great number of indirect communications in the substance of the muscles and upon the periosteum.

The *external* or *anterior circumflex* (*f*), smaller than the internal, sometimes arises directly from the femoral; it is often given off from the profunda by a common trunk with the great muscular artery of the triceps, and it may then be regarded as formed by the bifurcation of the profunda: it passes horizontally behind the rectus femoris, crossing in front of the psoas and iliacus, to which it gives a rather large vessel, and then divides into two branches: an *ascending muscular*, which is distributed to the glutæus minimus and to the tensor vaginæ femoris; and a *circumflex* branch, properly so called, which turns round the base of the great trochanter (*f*, *fig.* 215), dips into the substance of the triceps, and expands into a great number of ascending branches, which anastomose with the internal circumflex upon the outer surface of the great trochanter. Not unfrequently, an anastomosis is formed in front by a transverse branch between the internal and external circumflex arteries, by which the arterial circle of the hip-joint is completed.

The *perforating arteries* (*r r*, *fig.* 214) are both muscular and cutaneous, and are intended for the posterior region of the thigh: they vary in number from one to four, and are all distributed in a similar manner. They perforate the tendinous attachments of the adductor muscles to the femur, and, having reached the back of the thigh, they turn horizontally round the bone, and divide into *ascending* and *descending branches*, which form a series of loops or anastomotic arches in the substance of the muscles; these loops acquire a great size in cases where the femoral has been tied after Hunter's method, *i. e.*, in the middle third of the thigh.

The first perforating artery (*r*, *fig.* 215), which is the largest, and sometimes represents two, or even the whole of the perforating arteries, passes through the great adductor about one inch below the lesser trochanter, between the horizontal and oblique fibres of the muscle; its *ascending branch* (*s*) turns round the great trochanter, and anastomoses with the internal circumflex and sciatic in the substance of the glutæus maximus; its *descending branch* (*l*) is distributed to the vastus externus, the semi-tendinosus, semi-membranosus, biceps, and adductor magnus muscles. Some branches ramify upon the great sciatic nerve.*

I have seen an inferior perforating artery arise from the femoral, just where it passed through the tendon of the adductor magnus.

The terminal branch (*d'*, *fig.* 214) of the deep femoral constitutes the last perforating artery, which is distributed in the same manner as the other arteries of that name.

The Popliteal Artery.

When the femoral artery has perforated the tendinous portion of the adductor magnus, it takes the name of the *popliteal* artery, which extends down to its division into the anterior tibial and tibio-peroneal arteries.

* The principal nutritious artery of the femur arises from the first or second perforating artery.

The popliteal artery (*o*, *figs.* 215, 217) is the artery of the ham or popliteal space: it is bounded *above* (*p*, *fig.* 215) by the tendinous ring formed in the adductor magnus, and *below* (*p*, *fig.* 217) by the lower border of the popliteus muscle, at which place it is situated opposite the lower end of the upper fourth of the leg.* Its length in an adult subject is about seven inches.

Fig. 215.

It passes vertically, or somewhat obliquely outward and downward, the direction of the artery being represented by a line extending from the inner surface of the femur to the space between its two condyles. It is tortuous when the leg is flexed upon the thigh, but it becomes straight when the leg is extended, and may be ruptured by very forcible extension. It has been proved by experiment, that extension may be carried as far as to cause laceration of the ligaments of the joint, without rupturing the artery.†

Relations.—It is situated deeply in the whole of its course, and it is in relation, *behind*, with the semi-membranosus above; lower down, with the popliteal fascia, from which it is separated by a layer of fat of greater or less thickness, according to the prominence of the hamstring muscles; below this, with the gastrocnemius and plantaris muscles; and still lower, with the soleus. The popliteal vein lies behind and slightly to the outer side of the artery, and then behind it, adhering rather firmly to it. The internal popliteal nerve also lies upon it behind, but is separated from it by a very thick layer of fat. The veins and nerves both cross the artery beneath the gastrocnemius, so as to get to the inner side of the lower portion of the vessel.

From these relations, it follows that the popliteal artery may be exposed from behind in the whole of its extent, but that it is deeper seated below than above.

In front, it is in relation, from above downward, with the adductor magnus; with the internal surface of the femur, which appears to be expanded and become posterior, so as to support the vessel; with the knee-joint, with which it is in direct contact; and, lastly, with the popliteus muscle. The direct relation of the popliteal artery with the joint explains the facility with which it may be lacerated when its tissue has been rendered fragile from organic change, and accounts for the frequency of aneurism in this region.

On the inner side, this artery is in relation with the semi-membranosus, the inner condyle of the femur, and the inner head of the gastrocnemius.

On its outer side, it has the biceps, the outer condyle, the outer head of the gastrocnemius, and also the plantaris and soleus muscles.

Collateral Branches.—The popliteal artery gives off from its posterior aspect several small branches, which pass into the muscles of the ham; most of them are not named; but there are some which are distinguished as the *sural* arteries: in front it gives several arteries, named *articular*, because they surround the knee, like the collateral arteries of the elbow-joint. The articular arteries are divided into *superior*, *middle*, and *inferior*; the superior and inferior would have been better named the *collateral arteries of the knee*.

The *sural arteries* (*g g*, *figs.* 215, 217) are two in number: one *internal*, for the inner head of the gastrocnemius, and the other *external*, for the outer head of the same muscle. Arising from the back of the popliteal artery, they pass downward and backward, are separated from each other by the internal popliteal nerve, enter the anterior and internal surface of each head of the gastrocnemius a little before the two heads meet, and may be traced down to the lower part of the fleshy belly of that muscle. Generally one of their branches accompanies the external saphenous nerve from the popliteal space to the upper part of the tendo Achillis.

The *superior articular* or *collateral* arteries of the knee are divided into internal and external.

The *internal* superior articular arteries are sometimes three, but most commonly two in number, one of which arises higher than the other; their origin is subject to variety,

* The division of the popliteal artery takes place sometimes higher, sometimes lower than usual. In a case where its bifurcation was premature, the anterior tibial has been seen passing between the popliteus muscle and the posterior face of the tibia.

† I have had an opportunity of observing a case of luxation of the knee, with complete laceration of the crucial ligaments, where the popliteal artery was left entire.

but they are constant in their distribution. We shall distinguish them as the first and second.

The *first internal superior articular* artery, usually called the *great anastomotic artery* of the knee, is the largest of the whole: it arises opposite the point where the femoral becomes the popliteal artery, and sometimes even from the lower part of the femoral itself; it perforates the adductor magnus from behind forward, and immediately divides into four descending branches: the first is a *muscular branch* (*i*, *fig.* 214), which enters the substance of the vastus internus, passes inward and downward to reach the inner border of the tendon of the triceps, and, opposite the base or upper border of the patella, perforates the fibres of the muscle, becomes superficial, and runs transversely outward along the base of the patella, and forms an anastomotic arch with the external superior articular artery. The second and third branches are *periosteal;* one of them passes between the triceps and the femur, with which it is in contact, and terminates above the trochlea of that bone by anastomosing (at *s*) with the external superior and the second internal superior articular arteries; while the other runs along the adductor magnus, being held down against it by a layer of fibrous tissue, and anastomoses with the second internal superior articular artery, supplying its place when that vessel is only in a rudimentary state. The fourth branch (*h*) accompanies and supplies branches to the internal saphenous nerve: it appears to be constant; it is placed under the sartorius, along which it runs, together with the internal saphenous nerve, continuing with it below that muscle.

The *second internal superior articular* artery (*h*, *figs.* 215, 217) arises immediately above the inner condyle of the femur, turns round it horizontally, and divides into condyloid branches, which cover the condyles with their ramifications, and communicate partly with the first internal superior articular artery, and partly with the external superior articular artery coming from the opposite side. It also gives off a patellar branch, which runs upon the borders of that bone, supplies the skin and the synovial membrane of the knee-joint, and anastomoses with the internal inferior articular artery.

The *external superior articular* artery (*i*, *figs.* 215, 217) arises opposite the second internal superior, turns horizontally round the outer condyle of the femur, gives off some ascending *muscular* branches, which ramify in the vastus externus, and then terminates in three *periosteal branches.* One, which is superior and transverse, turns round the lower end of the femur, and anastomoses with the corresponding branch of the second internal superior articular; another and inferior branch ramifies upon the inner condyle, and anastomoses freely by a great number of branches with the external inferior articular; the third is a more superficial branch for the patella, on the side of which bone it runs, and near its upper border gives off a transverse twig, which anastomoses on the upper border of the patella with a similar one from the internal superior articular arteries, and a descending twig, which runs along the outer border of the bone, and anastomoses with the external inferior articular artery.

The *inferior articular* or *collateral* arteries of the knee are also divided into the *internal* and the *external.* They both arise from the front of the popliteal artery, opposite the middle of the knee-joint.

The *internal inferior articular* artery (*c*, *fig.* 217) runs downward and inward, and, having reached the internal tuberosity of the tibia, turns horizontally forward, passes beneath the tendons of the semi-tendinosus, semi-membranosus, and gracilis muscles, and also beneath the internal lateral ligament of the knee, turns upward upon the inner side of the anterior tuberosity of the tibia and ligamentum patellæ, describing a curve with its concavity directed upward, and anastomoses either with the superior articular arteries or with the anterior tibial recurrent. During its course it gives off ascending and descending periosteal and osseous branches.*

The *external inferior articular* artery (*b*, *fig.* 217) arises opposite the internal vessel, turns horizontally forward, not upon the external tuberosity of the tibia (for this is prevented by the tibio-fibular articulation), but upon the convex borders of the external semilunar cartilage, passes beneath the tendon of the biceps and the external lateral ligament of the knee-joint, and terminates by dividing into an ascending branch, which runs upward along the outer border of the patella, a descending branch, which anastomoses with the anterior tibial recurrent, and a transverse branch, which passes behind the ligamentum patellæ below the patella, and anastomoses with a similar branch from the internal inferior articular. The inferior articular arteries complete the arterial circle which surrounds the patella, and from which numerous branches are given off, some covering the patella by their anastomoses, and others entering the bone directly through the numerous foramina which exist upon its surface.

The *middle articular* arteries (*s*, *fig.* 215) consist of several small branches, which arise directly from the front of the popliteal artery, or from the external inferior articular, run from behind forward into the interior of the knee-joint, and are distributed in the intercondyloid notch to the crucial ligaments, the adipose tissue, the synovial membrane, and

* By osseous branches I mean those which enter the bone directly through the foramina, on the internal and external tuberosities of the tibia.

especially to the lower extremity of the femur, which they penetrate through the large foramina on the adjacent surface of each condyle. The middle articular artery or arteries belong, therefore, to the knee-joint exclusively, and do not assist in the restoration of an impeded circulation: in this respect they differ entirely from the other articular arteries, which acquire a very considerable size when the principal trunk has been tied.

The Anterior Tibial Artery.

Opposite the lower border of the popliteus muscle, the popliteal artery divides into two branches: an anterior, named the *anterior tibial* (*a*, *fig.* 217); and a posterior, which forms the continuation of the popliteal, and may be denominated the *tibio-peroneal trunk* (*f*). This trunk soon subdivides into the *posterior tibial* (*t*) and the *peroneal* (*k*) *arteries*.

The *anterior tibial artery* (*a*, *figs.* 216, 217), the anterior branch of the bifurcation of the popliteal, terminates opposite the dorsal annular ligament of the tarsus (*b*, *fig.* 216), below which the vessel is named the *dorsal artery of the foot* (*f*). Immediately after its origin, it passes horizontally forward, perforates the upper part of the interosseous ligament, is reflected over it, and descends vertically in front of it; having reached the lower fourth of the leg, it is directed somewhat obliquely inward, following the direction of the external surface of the tibia, and then passes under the annular ligament, at the lower border of which, as stated, it terminates.

Fig. 216.

A line stretched from that process of the tibia, which has been described as the tubercle of the tibialis anticus (Osteology, p. 278), to the middle of the tibio-tarsal articulation, will indicate its direction and course.

Relations.—The anterior tibial artery is situated very deeply, and yet it can be exposed at any point; it is in relation, *behind*, with the interosseous ligament in its three upper fourths, and with the tibia in its lower fourth; it lies in contact with the interosseous ligament, and is retained in its place by a layer of fibrous tissue, so that, after amputation of the leg, it retracts between these two fibrous layers, and is sometimes seized and tied with difficulty.

In front, it is covered successively by the tibialis anticus, the extensor longus digitorum, and the extensor proprius pollicis, the tendon of which crosses over it; it is placed exactly along the cellular interval between the tibialis anticus and the extensor muscles; and the incision should, therefore, be made along the line corresponding to that interval, in order to expose the artery when it is to be tied; lower down it is only separated from the skin by the fascia of the leg and the projecting tendon of the extensor proprius pollicis, and hence it may be compressed in this situation.

On the inner side, it is in relation with the tibialis anticus, then with the tibia, and, lastly, with the tendon of the extensor pollicis, being lodged in the same sheath.

On its outer side, it has the extensor longus digitorum, then the extensor pollicis, both of which afterward cross over it; and, lastly, it has only the fascia of the leg: the anterior tibial nerve runs along the outer side of the artery in its whole extent.

Its *collateral branches* are very small and numerous, and are distributed to the muscles and the skin. Among them, the *anterior tibial recurrent*, and the *external* and *internal malleolar*, require special notice.

The *anterior tibial recurrent* artery (*c*, *fig.* 216) is sometimes of considerable size; it arises from the tibial, after that vessel is disengaged from the interosseous ligament, passes obliquely upward and inward between the tibialis anticus and the external tuberosity of the tibia, with which it is in contact, and expands into diverging, periosteal, and articular branches, some of which ascend and anastomose with the external inferior articular of the knee, while others pass transversely, and anastomose with the internal inferior articular. I have seen the anterior tibial recurrent, of large size, run transversely below the patella, and terminate upon the internal tuberosity of the tibia.

The *malleolar*, which would be more correctly named *articular* arteries, are divided into the *internal* and *external*.

The *internal malleolar* or *articular* artery (*d*) arises opposite the dorsal annular ligament of the tarsus, passes transversely inward under the tendon of the tibialis anticus, and divides into two branches: a *deep*, or articular, which dips perpendicularly into the ankle-joint, and is distributed to that articulation; and a *superficial*, or malleolar, properly so called, which passes above the malleolus, and is distributed upon it, on the inner side of the tarsus, as far as the internal plantar region, where it anastomoses with the branches of the internal plantar artery.

The *external malleolar* or *articular artery* (*l*), larger than the preceding, varies much in

its origin. Thus, it sometimes arises under the dorsal ligament of the tarsus, opposite the internal malleolar; it often arises from the tibial, about two or three inches above the annular ligament. Sometimes it is derived from the posterior peroneal artery, and perforates the lower part of the interosseous ligament. Lastly, and most commonly, it arises by two roots; one of which is small, but variable in size, and is derived from the peroneal, while the other is larger, and is given off from the anterior tibial.

These differences of origin affect the course of the artery. When it arises under the ligament of the tarsus, it passes transversely outward, and then turns in front of the external malleolus to run forward, resting upon the tarsus. It receives the branch from the posterior peroneal at the point where it changes its direction. In those cases where it arises higher, it passes obliquely downward, in front of the external malleolus, and then upon the outer side of the astragalus. In all cases, the external malleolar artery runs forward on the outer side of the cuboid bone, and forms an anastomotic arch with the dorsal artery of the tarsus. It is in contact with the bones throughout its course, and is crossed by the tendon of the extensor longus digitorum: it gives off *malleolar* branches, which ramify upon the outer surface of the external malleolus; very large *articular branches*, which dip into the tibio-tarsal articulation; and one, which I would especially notice, that enters the deep fossa between the astragalus and os calcis; and, lastly, *external calcaneal branches*, which pass under the tendons of the peroneus longus and peroneus brevis, and ramify upon the outer side of the os calcis, where they terminate by anastomosing with the peroneal artery, and with some branches of the external plantar. Several of these branches are reflected upon the upper surface of the os calcis in front of the tendo Achillis, and anastomose with branches from the posterior tibial artery.

The Dorsal Artery of the Foot.

The dorsal artery of the foot (*dorsalis pedis*, *f*, *fig.* 216) is the continuation of the anterior tibial, which takes this name after emerging from below the dorsal annular ligament of the tarsus; it terminates in the sole of the foot, by becoming continuous with the plantar arch. Not unfrequently this artery arises by two roots, one of them being formed by the anterior tibial, which is much smaller than usual, and is, as it were, exhausted near the ankle, and the other by the peroneal, which is then very large, and perforates the lower part of the interosseous ligament. In a few rare cases, the anterior tibial is entirely wanting, and is represented by some small perforating branches from the posterior tibial or the peroneal; the dorsal artery of the foot is then wholly derived from the peroneal.

The size of the dorsal artery of the foot is also subject to variety; it generally bears a direct proportion to that of the anterior tibial, which I have seen as large as the posterior tibial and peroneal arteries together, while it has an inverse ratio to that of the two last-mentioned vessels combined.

The dorsal artery runs horizontally and directly forward upon the dorsum of the foot, as far as the posterior extremity of the first interosseous space, at which point it bends downward at a right angle, perforates that space like a perforating artery, and terminates by becoming continuous with the plantar arch.

The direction of the dorsal portion of this artery is marked by a line extending from the middle of the tibio-tarsal articulation to the posterior extremity of the first interosseous space.

Relations.—It lies in contact with the bones of the tarsus, in which position it is retained by a layer of fibrous tissue. It is separated from the skin by the fascia of the foot, and also anteriorly by the inner portion of the extensor brevis digitorum. It runs along the outer side of the tendon of the extensor proprius pollicis, which projects so as to raise the integuments from the vessel; it may be exposed in its entire length by cutting along the outer border of that tendon. It is not uninteresting to remark that, under the dorsal ligament of the tarsus, this artery is situated in the same sheath as the tendon of the extensor proprius pollicis.

Its *collateral branches* are *internal* and *external*.

The *internal* branches are numerous, but are not named; they ramify upon the inner side of the tarsus, and anastomose upon the inner border of the foot, either with each other, with the internal malleolar arteries, or with the internal plantar artery. One of them may be described under the name of the *internal tarsal artery*, a branch which has a remarkable course: it passes obliquely forward and inward as far as the posterior extremity of the first metatarsal bone, and is sometimes continued along the inner side of that bone to form the internal collateral artery of the great toe; at other times it is reflected under the first metatarsal bone, and anostomoses directly with the internal plantar artery, after having given off a great number of branches to the inner side of the metatarso-phalangal articulation of the great toe.

Among the *external branches* there are two which require particular description, viz., the *dorsal artery of the tarsus*, or the *external tarsal*, and the *dorsal artery of the metatarsus*, or the *metatarsal artery*.

The *external tarsal artery* (*g*) varies in its size, which almost always bears an inverse

proportion to that of the external malleolar and metatarsal arteries. I have seen it as large as the dorsal artery of the foot, by the bifurcation of which vessel it appeared to be formed.

It passes transversely outward under the extensor brevis digitorum, anastomoses freely with the external malleolar artery, and gives off the following branches: some which ramify upon the outer side of the os calcis, and anastomose with the peroneal; a branch which runs upon the cuboid bone, sometimes being so large as to be regarded the continuation of the artery, and then passes under the sole of the foot to anastomose with the external plantar; and, lastly, some branches in front, which anastomose with the metatarsal artery, the place of which vessel it sometimes partially supplies, by giving off the dorsal interosseous arteries. In one case, where the external tarsus artery was very large, it passed transversely outward as far as the outer surface of the cuboid bone, was reflected backward on the outer surface of the calcaneum, and there anastomosed very freely with the external malleolar and the peroneal arteries. In another case, the external tarsal artery divided into two branches, one of which ran transversely outward and reached below the sole of the foot, while the other formed the dorsal interosseous artery of the fourth interosseous space.

The *metatarsal artery* (*h*) generally arises from the front of the dorsal artery of the foot, opposite the posterior extremity of the first interosseous space, sometimes by a common trunk with the external tarsal just described. According to the most regular distribution, it passes transversely outward, opposite the posterior extremities of the several metatarsal bones, and constitutes the *dorsal arch of the metatarsus* (*i*).

Three branches given off from the convexity of this arch, which is directed forward, are named the *dorsal interosseoas arteries* (*l l*). They run along the dorsal surface of the second, third, and fourth interosseous spaces, and having arrived opposite the metatarsophalangal articulations, divide into two collateral branches for the corresponding toes. During its course along its own interosseous space, each dorsal interosseous artery receives two perforating branches, viz., a *posterior perforating artery*, opposite the posterior extremity of the interosseous space, and an *anterior perforating*, opposite the anterior extremity of the same space. This explains the otherwise singular fact, that the dorsal interosseous arteries are increased in size opposite the posterior and anterior extremities of their respective spaces. In some subjects, the dorsal interosseous arteries are derived exclusively from the perforating arteries.

It is not very rare to find the metatarsal and the dorsal interosseous arteries wanting; their places are then supplied by the plantar interosseous arteries.

The *dorsal interosseous artery of the first interosseous space* (*n*) is given off directly from the dorsal artery of the foot, at the point where that artery dips into the first interosseous space; it is larger than the other dorsal interosseous arteries, but is distributed in a similar manner.

The dorsal interosseous artery of the second space is also rather frequently derived directly from the dorsalis pedis.

Fig. 217.

The Tibio-peroneal Artery.

The *tibio-peroneal artery* or trunk (*f*, *fig.* 217), the posterior branch of the bifurcation of the popliteal artery, is bounded above by the origin of the anterior tibial, and below by its subdivision into two branches, viz., the *posterior* tibial (*l*) and the *peroneal* (*k*). It is from one inch to eighteen lines in length, sometimes it is not more than six lines. and it may be two or even three inches; I have seen it extend as low as the inner part of the os calcis, where it divided into the internal and external plantar arteries.*

It forms the continuation of the popliteal in regard to direction, and is in relation with the soleus behind and the muscles of the deep layer in front; the posterior tibial nerve crosses behind to get to its outer side below.

The *collateral branches* of the tibio-peroneal artery are, first, an *internal recurrent branch*, which perforates the soleus from behind forward, turns round upon the inner border of the tibia, is reflected upward, and anastomoses with the internal inferior articular artery upon the internal tuberosity of that bone; secondly, the *nutritious artery of the tibia* (*s*); and, lastly, a single large branch, or several branches, to the *soleus* muscle, which

* M. Dubreuil has communicated to me a case in which the tibio-peroneal trunk continued undivided all along the posterior face of the peroneus, and gave off the posterior tibial artery only at the lower part of the leg.

they enter near its peroneal attachments, and then anastomose with the anterior tibial and the external inferior articular. When the tibio-peroneal artery is short, the branch to the soleus is derived from the peroneal artery.

The Peroneal Artery.

The *peroneal artery* (*k*) extends from the bifurcation of the tibio-peroneal trunk to the os calcis. It is generally smaller than the posterior tibial, and even than the anterior tibial, and bears an inverse proportion to the size of the two, more particularly to that of the anterior tibial, the place of which it often partially supplies. In some cases it is itself replaced by some small branches derived from the posterior tibial.*

It descends vertically along the posterior surface of the fibula, from which it is separated by the flexor longus pollicis; it is covered by the soleus, and dips below between the flexor longus pollicis and the tibialis posticus, to reach the interosseous ligament, at the lower part of which it divides into a *posterior* and an *anterior* branch.

Its *collateral branches* are, first, posterior ones, which are very numerous, and supply the soleus; the highest of these are of considerable size, and often arise from the tibio-peroneal artery. Secondly, there are internal and external branches, which pass to the deep-seated muscles of the leg: among the external branches is the nutritious artery of the fibula; and among the internal branches a transverse or oblique anastomotic twig may be specially noted, which extends from the peroneal to the posterior tibial. Sometimes this anastomotic branch is very large, and, in that case, the posterior tibial is more slender than usual up to that point, but increases in size after receiving this addition, and afterward gives off the plantar arteries.

Terminal Branches.—The anterior terminal branch, named the *peroneal perforating*, or the *anterior peroneal* artery (*g*, *fig.* 216), perforates the lower part of the interosseous ligament, descends upon the lower end of the tibia, and anastomoses with the external malleolar artery, which is sometimes formed by it. This peroneal perforating branch, which is generally very small, is sometimes as large, or even larger, than the posterior branch, and then supplies the place of the lower part of the anterior tibial, and forms the dorsal artery of the foot; the anterior tibial is then very small. There almost always exists a trace of this distribution in the presence of a small branch, which anastomoses with the anterior tibial.

The *posterior terminal branch* (*l*, *fig.* 217) of the peroneal artery, which might be called the *external calcaneal*, forms the continuation of that vessel, and gains the posterior aspect of the external malleolus, to which it is applied, after running along the outer border of the tendo Achillis, being separated from the skin by the fascia of the leg and another layer of fibrous tissue. It gives off to its inner side, opposite the posterior border of the lower end of the tibia, a transverse branch, which anastomoses with the posterior tibial artery. It then ramifies upon the outer surface of the os calcis, supplies the calcaneal attachments of the muscles of the sole of the foot, and also the skin of the heel, and anastomoses with the external malleolar, and also with the external plantar artery. Some small ascending branches pass above the os calcis, and anastomose in front of the tendo Achillis with corresponding branches of the posterior tibial. I have seen the external calcaneal artery derived from the posterior tibial.

The Posterior Tibial Artery.

The *posterior tibial artery* (*t*, *fig.* 217) is the internal branch of the bifurcation of the tibio-peroneal artery or trunk, and having entered a groove on the os calcis, beneath the internal annular ligament of the tarsus (*t*, *fig.* 218), terminates by dividing into the *internal* (*a*) and the *external* (*b*) *plantar arteries*. It is larger than the other arteries of the leg, and is generally inversely proportioned to the anterior tibial and the peroneal. Thus, in a subject in which the anterior tibial and the dorsal artery of the foot were very large, the posterior tibial and the internal plantar were scarcely one third of their ordinary size.

The posterior tibial artery is at first directed obliquely inward, and then vertically downward; and it is in relation, *in front*, with the tibialis posticus; lower down, with the flexor communis digitorum, which separates it from the tibia; below that, with the posterior border of the internal malleolus, from which it is separatad by the tendons of the tibialis posticus and flexor longus digitorum; still lower, with the ankle-joint; and, lastly, while under the arch of the os calcis, with the groove for the tibialis posticus. *Behind*, it is at first covered by the gastrocnemius and soleus; and in the lower third of the leg, where these muscles are wanting, it is in relation with the inner border of the tendo Achillis, and is separated from the skin by two fibrous layers. The internal popliteal nerve runs along the outer side of this artery.

It follows, then, that the posterior tibial artery may be compressed and exposed in the whole of the lower third of the leg.

* In a case where the anterior tibial, being very small, disappeared at the union of the two superior with the inferior third of the leg, the peroneal artery, which was twice as large as the posterior tibial, arose on the inside of this latter artery, which it crossed at a very acute angle, to become external. When it had reached the lower third of the leg, it passed down close to the posterior surface of the interosseous ligament, which it traversed at its inferior portion, and then formed the artery of the foot.

The *collateral branches* of the posterior tibial artery are very small, and do not require any particular description: some of them are posterior, and pass to the soleus and gastrocnemius; others are anterior, and supply the deep-seated muscles, and the periosteum of the tibia. The principal nutritious artery of the tibia, which we have stated to arise from the tibio-peroneal trunk, is often given off by the posterior tibial. Most of the lower internal branches perforate the flexor longus digitorum, turn round over the internal border of the tibia, and ramify in the periosteum and integuments. Lastly, opposite the posterior border of the lower end of the tibia, we find a small transverse branch, which anastomoses with a corresponding branch, already mentioned as arising from the peroneal artery.

Beneath the concavity on the under surface of the os calcis, the posterior tibial gives off before its subdivision several calcaneal branches, some of which ramify upon the internal surface of the os calcis, while others mount up above that bone, and anastomose with twigs from the peroneal; also, some articular branches for the tibio-tarsal and astragalo-calcaneal articulations; and, lastly, some branches which pass up upon the inner border of the tarsus, to anastomose with the internal malleolar artery.

The Internal and External Plantar Arteries.

The internal and external plantar arteries, the terminal branches of the posterior tibial, commence in the concavity beneath the os calcis, under the internal annular ligament of the tarsus.

The *internal plantar artery* (*a*, *fig.* 218) is generally much smaller than the external; it passes horizontally forward, along the inner side of the sole of the foot, between the abductor pollicis and the tendons of the flexor longus digitorum; more anteriorly, it is subjacent to, *i. e.*, farther from the skin, than the flexor brevis digitorum; it supplies the muscles in question, gives off several ascending and oblique branches to the numerous articulations of the tarsus, anastomoses freely by some internal branches with the internal malleolar and internal tarsal arteries, and ends in different ways. The following is its most common mode of termination: having reached the posterior extremity of the first metatarsal bone, it divides into two branches; one of which is *internal*, and runs along the outer side of the abductor pollicis, and deviates a little, so as to form the *internal collateral artery* (*i*) of the great toe: the other is *external*, varies much in size, and anastomoses (at *g*) with the common trunk of the collateral arteries of the first and second toe. We may regard as its terminating branch a *cutaneous artery*, which perforates the plantar fascia, and is distributed to the skin and sub-cutaneous cellular tissue on the inner side of the foot. I have seen the internal plantar artery very small, and terminating in the flexor brevis pollicis.

Fig. 218.

The *external plantar artery* (*b*) forms the continuation of the posterior tibial in reference to its size; but in certain cases, however, it is not larger than the internal plantar artery. It passes obliquely downward, outward, and forward, accompanied by the external plantar nerve, under the os calcis, between the flexor brevis digitorum, which is below or superficial to it, and the flexor accessorius, which is above or deeper: as soon as it gains the outer border of the flexor brevis digitorum, upon the aponeurotic septum between this muscle and the abductor of the little toe, it turns directly forward, and having reached the under surface of the posterior extremity of the fifth metatarsal bone, it changes its direction, leaves the nerve, and curves inward and forward, towards the posterior extremity of the first interosseous space (at *g*), where it inosculates with the dorsal artery of the foot: this curved portion of the artery, extending from the fourth to the first interosseous space, constitutes the *plantar arch*, which is formed by the junction of the dorsal artery of the foot with the external plantar artery; it runs obliquely below the posterior extremities, or sometimes the middle of the metatarsal bones, between them and the adductor of the great toe, by which, and all the other muscles of the middle plantar region, it is covered in below; and it establishes a free and uninterrupted communication between the anterior and posterior tibial arteries. I have seen the plantar arch formed exclusively by the dorsal artery of the foot, the external plantar being very small, and losing itself in the abductor and flexor brevis minimi digiti; at other times, the external plantar artery only communicates with the plantar arch by means of some small branches.

Before it constitutes the plantar arch, the external plantar artery gives off an *inferior calcaneal* branch (*c*), which passes transversely outward, in front of the tubercles on the lower surface of the os calcis, above the flexor brevis digitorum, and terminates in the muscles of the external plantar region; also, some *muscular* branches to the muscles of the external plantar region, the flexor brevis digitorum, and the flexor accessorius; and, lastly, some *periosteal*, *osseous*, and *articular* branches, to the bones and to the corresponding articulations of the tarsus.

The plantar arch itself gives off superior and anterior branches. The *superior* branches, or the *posterior perforating arteries*, pass perpendicularly upward, through the posterior extremities of the interosseous spaces, and anastomose with the dorsal interosseous arteries. There are only three posterior perforating arteries, which belong to the second, third, and fourth (*d*) interosseous spaces: the dorsal artery of the foot represents the perforating artery of the first interosseous space.

The *anterior* branches are five in number; of these, four are *plantar interosseous* or *digital arteries*, and are distinguished by the numerical names of first, second, and third, proceeding from within outward; the fifth anterior branch is the external collateral artery of the little toe.

All the plantar interosseous or digital arteries (*e*) run forward in the corresponding interosseous spaces, and then between two of the metatarso-phalangal articulations; opposite the anterior extremity of the metatarsal bone, each digital artery gives off a small *anterior perforating branch* (as at *s*), which anastomoses with the corresponding dorsal interosseous artery; having reached beyond the posterior extremity of the first phalanges of the toes on either side, each digital artery divides into two branches, which constitute the *internal* and *external collateral arteries* (*f*) of the corresponding toes, and are distributed in precisely the same manner as the collateral arteries of the fingers; that is to say, the internal and external collaterals of each toe anastomose by a small transverse branch opposite the second phalanx, anastomose again opposite the middle of the last phalanx, and are almost entirely distributed to the skin.

The *first plantar interosseous* or *digital artery* (arteria magna pollicis pedis) requires a special description. It is very large, and arises precisely at the point (*g*) where the dorsal artery of the foot terminates in the plantar arch, so that it appears to result from the bifurcation of the dorsal artery of the foot; it passes under the first metatarsal bone, and, having arrived behind the anterior extremity of that bone, it gives off a branch from its inner side, which sometimes forms the internal collateral artery of the great toe; it then passes outward to reach the space between the metatarso-phalangal articulations of the first and second toes, and divides into the *external collateral artery of the great toe* (*h*) and the *internal collateral artery of the second toe* (*f*). Opposite the middle of the first phalanx of the great toe, its external collateral artery gives off a branch inward, which anastomoses with the internal collateral artery, and sometimes even constitutes that artery.

The *external collateral artery of the little toe* (*l*), which may almost be regarded indifferently as arising from the external plantar artery, or from the plantar arch, passes forward under the flexor brevis of the little toe, and terminates along the outer border of that toe, by anastomosing with the tarsal and metatarsal arteries derived from the dorsal artery of the foot. I have seen this branch give origin to both the external and internal collateral arteries of the little toe.

Comparison between the Arteries of the Upper and Lower Extremities.

All the arteries of the lower extremities are derived from two primitive trunks, viz., the right and left common iliac arteries, each of which soon subdivides into an internal and external iliac. The arteries for the upper extremities and head arise from three primitive trunks, the first being the brachio-cephalic, or innominate artery, which soon subdivides into the right common carotid and right sub-clavian; the second is the left common carotid, and the third the left sub-clavian, which may justly be regarded as forming together a single primitive trunk. There are, then, ultimately, four trunks for the upper as well as the lower parts of the body.

The common carotid arteries, distributed as they are to the head, cannot be compared to the internal iliacs, which are given to the pelvis and the organs contained in the pelvic cavity; but as the pelvis corresponds to the shoulder, we may find some analogy, if not in origin, at least in distribution, between the arteries of the one and of the other.

The external iliac corresponds to the sub-clavian; the more numerous collateral branches of the latter are in part represented by the branches of the internal iliac to the walls of the pelvis. Thus, the os coxæ, as well as the scapula, is, as it were, girdled by an arterial circle. The posterior scapular artery, which runs along the vertebral border of the scapula, represents the circumflex iliac, which turns round the crest of the ilium, and is distributed to the muscles of the abdominal parietes in the same manner as the posterior scapula is distributed to the serratus magnus and the rhomboideus. I will not carry the analogy farther, by comparing the supra-scapular, sub-scapular, and internal mammary arteries with the sciatic, gluteal, obturator, and internal pudic.

The axillary and brachial arteries correspond to the femoral and popliteal.

The deep humeral artery represents the deep femoral; the circumflex branches of the femoral correspond to the circumflex and sub-scapular branches of the axillary: the anastomoses of the femoral circumflex arteries with the obturator, gluteal, and sciatic, correspond to the anastomoses of the circumflex and sub-scapular branches of the axillary with the supra-scapular and posterior scapular branches of the sub-clavian.

The popliteal portion of the femoral represents that part of the brachial which is sit-

uated opposite the bend of the elbow; the internal and external collateral arteries derived from the brachial, together with the radial, ulnar, and interosseous recurrents, form anastomotic circles around the elbow, which are exactly analogous to those formed by the superior articular arteries given off from the popliteal with the inferior articular arteries and the anterior tibial recurrent artery.

The bifurcation of the popliteal into the anterior tibial and the tibio-peroneal trunk represents the bifurcation of the brachial into the radial and ulnar: the anterior tibial corresponds to the portion of the radial situated in the forearm; the dorsal artery of the foot to the carpal portion of the radial; and the plantar arch, which is continuous with the dorsal artery of the foot, represents the deep palmar arch, which is the continuation of the radial in the hand.

The tibio-peroneal trunk corresponds to the commencement of the ulnar artery, the posterior tibial artery to the trunk of the ulnar, and the peroneal artery to the interosseous artery of the forearm. Just as the peroneal often gives origin to the dorsal artery of the foot, so does the interosseous sometimes give off the carpal portion of the radial.

The plantar arch is represented by the deep palmar arch; the plantar interosseous and the collateral arteries of the toes, by the palmar interosseous and the collateral arteries of the fingers.

If it be asked why there is no superficial plantar arch corresponding to the superficial palmar arch, it may be said, first, that the arteries of the dorsum of the foot are much larger than those on the back of the hand; and, secondly, that the hollow, vaulted form of the sole of the foot preserves the plantar arch from the compression to which the palmar arch is liable in consequence of the flattened form of the hand.*

THE VEINS.

Definition.—The Venous System.—Origin of the Veins.—Course.—Anastomoses and Plexuses.—Varieties.—Termination.—Valves.—Structure.—Preparation.—Method of Description.

The *veins* (φλὲψ) are those vessels which convey the blood back from the extremities to the heart. They are also called *les vaisseaux à sang noir*, in opposition to the arteries, which are then named *les vaisseaux à sang rouge*; but these terms are incorrectly applied, for the pulmonary veins convey red, and the pulmonary artery black blood.

There are two venous systems, corresponding to the two arterial systems, viz., the *pulmonary venous system*, through which the blood returns from the lungs to the left auricle, and the *general venous system*, which conveys the blood from all parts of the body to the right auricle. There is also a third venous system, the *system of the vena portæ*, which is an appendage of the general venous system, and, as we shall see, forms by itself a perfect circulatory apparatus. In the fœtus there is a fourth venous system named the umbilical.

General View of the Venous System.

Both the general venous system and the pulmonary venous system, regarded as a whole, resemble the roots of a tree, the trunk of which, in the former case, would correspond to the right auricle, and, in the latter, to the left auricle. While a single arterial trunk, the aorta, gives origin to the general arterial system, the corresponding veins terminate in three venous trunks, viz., the superior and inferior venæ cavæ and the coronary vein; and so in the pulmonary venous system there is a single arterial trunk, the pulmonary artery, to four veins, two for each lung.

Each artery has generally two accompanying veins, which are called its *satellite* veins (*venæ comites*), and bear the same name as the artery; besides these, there exist in some parts certain *superficial* or *sub-cutaneous veins*, which form a system totally apart from the arteries, and may be regarded as supplementary veins.

The *number* of the veins is, therefore, much greater than that of the arteries. This rule, however, has some exceptions; in fact, there is only one accompanying vein for the great arterial trunks, and even for some arteries of moderate size; lastly, in some few instances, there is but one vein to two arteries. Thus, there is only one superior and one inferior mesenteric, one renal, and one external iliac vein, each of which corresponds to the artery of the same name; but there is but one umbilical vein to two umbilical arteries, and there are several supra-renal arteries, but only one supra-renal vein.

It is impossible to estimate the size of the veins with accuracy, in consequence of the variations to which they are liable from their extreme dilatability. Hence the very different results obtained by authors in this respect. According to Haller, the capacity of

* [For farther information concerning varieties in the distribution of arteries, the reader is referred to the "Anatomy of the Arteries, with its Applications to Pathology and Operative Surgery," by Professor R. Quain, with drawings by J. Maclise, 1841, 1842.]

the veins is to that of the arteries as two to one; according to Borelli, as four to one according to Sauvages, as nine to four.

The entire venous system represents a truncated cone, the apex of which corresponds to the heart, and the base to the origins of the veins. From this disproportion between the total area of the smaller veins, and the area of the trunks in which they terminate, it follows that, in the course of the circulation, the blood passes from a wider to a narrower space; an arrangement which tends to accelerate the progress of the fluid.

The study of the veins includes the consideration of their origin, course, anastomoses, relations, termination, and structure.

Origin of the Veins.

The veins are continuous with the arteries; a fact that is proved by the facility with which even very coarse injections will pass from the arteries to the veins, and is also most satisfactorily shown by examining the circulation in the mesentery of the frog. In some parts, instead of the communication between the arteries and veins being direct, it is established by means of an intermediate vascular network or spongy tissue, which is entirely venous: of this we have an example in the corpus cavernosum penis. Lastly, the facility with which injections forced into the veins from the trunks towards the extremities escape upon the surface of the mucous membranes, would seem to establish the fact of these vessels arising by open mouths at the surface of those membranes. Haller admitted the existence of absorbent veins arising from all the free surfaces.*

Course.

Immediately after their origin, the veins form networks, from which small branches are given off to anastomose together and form larger and larger networks: from these, again, proceed larger branches, which become successively united, just as the arteries are successively divided; that is to say, the smaller branches unite to form larger ones, and these still larger branches, which are at length united into the venous trunks. In the limbs, the veins are divided into the *superficial* and the *deep*. The *deep veins*, which accompany the arteries, have similar relations with the bones, muscles, nerves, fasciæ, and skin, as those vessels. The deep veins are always in contact with the arteries, and are contained in the same fibrous sheaths. All attempts to ascertain any law by which the relations of the veins with the arteries are regulated have been unsuccessful. Indeed, the relative position of the two kinds of vessels, although constant, does not seem to follow any general rule. The close relations between the arteries and veins, interesting as they are to the surgeon, who is required to separate the veins carefully from an artery before tying the latter, are no less so to the physiologist. The shock communicated to the blood in the venæ comites by the pulsations of their corresponding artery, must assist the circulation of that fluid. In some cases of hypertrophy of the heart, I have seen the blood issue in jets from a vein as if it were from an artery.

When, as it in some places happens, the deep veins do not accompany the arteries, there is always some special roason which observation may determine. For example, the cerebral sinuses, which are really veins, do not accompany the arteries; nor are the hepatic veins, the ophthalmic vein, and the vena azygos, satellites of their corresponding arteries.

The *superficial veins* exist only in parts where the circulation in the deep veins is liable to be obstructed during the exercise of those parts. In fact, as the venous blood does not circulate like the arterial, under the influence of an impelling agent directly connected with them, it is retarded by the slightest cause, and hence, therefore, the necessity for additional means of circulation.

The superficial veins, therefore, constitute, in reference to the deep veins, a collateral route for the venous blood, especially during the contraction of the muscles of the upper and lower extremities, as we find in persons who exercise their limbs much. I have shown that the tongue, as well as the extremities, is provided with a superficial and a deep set of veins. The superficial veins are situated between the investing aponeuroses of the muscles and the skin, from which they are separated by a very thin layer of fascia: they are accompanied by the sub-cutaneous nerves and lymphatics.

From this description it follows, that such of the deep veins as accompany the arteries do not require any special description, because they have the same distribution and the general relations as the arteries: the description of the venous system will therefore be confined to an examination of such veins as pursue a course independent of that of the arteries.

Anastomoses and Plexuses.

The *anastomoses* of the veins are more numerous than those of the arteries, and they take place by means of much larger vessels; an arrangement which compensates for the want of an impelling organ directly connected with them. Thus, anastomoses by

* [The escape of injections upon mucous membranes is due to rupture or transudation; the existence of veins having open mouths upon these or other free surfaces is now denied by the best authorities.]

direct inosculation, by lateral, transverse, or oblique communications, and anastomoses by convergence, are found in every situation, and with all conceivable varieties. The branches of the veins form lozenge-shaped meshes; and both the trunks and the branches communicate freely with each other; that is to say, the superficial with the deep set, the veins of the superficial set and those of the deep set among each other, and the vena cava superior with the vena cava inferior; so that we may say that the whole venous system forms one vascular network, and it is by these free communications that such obstacles as impede, or even completely intercept the course of the blood in a given part, are rendered incapable of stopping it altogether. In order to intercept the course of the venous blood completely, it would, in fact, be necessary to obliterate, not only the principal trunk, but also all the collateral channels. One remarkable mode of anastomosis is the following: a collateral vein arises from some point of a particular vein, and terminates at a greater or less distance in the same vein, like a canal intended to unite two distant points of the same stream; this collateral channel is intended to receive a number of veins, which would otherwise have terminated in the principal vessel. The following is a variety of this kind of anastomosis: one vein divides into two of equal size, which diverge from each other at a very acute angle, or, rather, run parallel, and reunite at a greater or less distance. The saphenous vein often presents this arrangement.

A *venous plexus*, which consists of a complicated network of vessels, is nothing more than the highest development of an anastomosis: venus plexuses are found in parts where the circulation is liable to be retarded, or in organs whose functions require a large afflux of blood; *example*, the vesical, uterine, and spermatic plexuses.

The veins are rarely tortuous, like the arteries, but are generally straight; a circumstance which also helps to lessen the effects of the deficiency of a direct impelling organ; for tortuosities, by multiplying the points of friction, would evidently retard the flow of blood in the veins. The great veins are not at all tortuous, but the smallest veins, and those forming the plexuses, are distinctly so. The tortuosities of veins are generally regarded as the result of their too great development. Thus, hypertrophied veins, whether varicose or not, always pursue a distinctly zigzag course.

Varieties.

The varieties in the size, the anastomoses, and the terminations of the veins are so numerous, that it is impossible to include them in any general description; it would seem that, for the due performance of its function, it matters not whether a vein terminates in one or another part of the venous system. It may be readily conceived that as the anastomoses of the veins are very numerous, and take place by very large branches, it can be of little consequence which of those anastomotic branches predominates.

Termination.

The veins of all the supra-diaphragmatic portion of the body terminate in the vena cava superior; the veins of the sub-diaphragmatic portion terminate in the vena cava inferior; the veins of the heart terminate separately in the auricle; the two venæ cavæ communicate with each other through the vena azygos, and especially through the veins of the spinal canal, so that when either of them is obliterated the other supplies its place.

Valves.

The existence of membranous folds, or *valves* (*a a*, *fig.* 218*), in the interior of the veins is one of the most characteristic features in their structure. The existence of these valves is shown externally in injected veins by a more or less distinct knotted appearance.

Fig. 218.*

If we open, under water, a vein provided with valves, we perceive attached to its interior surface certain membranous folds, or membranous processes, as they were named by Charles Etienne, who appears to have discovered them; there are generally two, placed one opposite the other; they are rarely solitary even in the smallest vessels, and still less commonly are three found together, as Haller and Morgagni say they have observed. They all have a semilunar form, like the sigmoid valves of the aorta and pulmonary artery; their adherent border is convex, and directed towards the extremities; their free border is straight, and is directed towards the heart.

Both surfaces are free; the inferior is turned towards the centre of the vessel, while the superior corresponds to its sides, which always present a dilatation or sinus (*b*) opposite the valves, that gives a knotted appearance to the vein when distended; the constricted part of the vein corresponds to the adherent border of the valve, and the dilated portion to the valve itself.

As a necessary consequence of their direction, the valves permit the blood to flow from the extremities towards the heart, but prevent its course in the opposite direction; it was this anatomical fact which led Harvey to the discovery of the course of the venous

blood. The valves are so long, that when two opposite ones are depressed, they almost completely close the channel of the vessel.

Notwithstanding their tenuity, the valves are extremely strong: a fact of which we may be easily convinced by endeavouring to inject the veins in the opposite direction to that in which the blood flows through them. The perforations and notches sometimes observed in the valves of veins appear to me to be accidental.

The office of the valves is to prevent that retrograde movement in the course of the blood which would otherwise occur from so many causes.

All veins are not provided with valves, and those which have them are very unequally so. It may be said that their presence and their number, their proximity, and their distance from each other, are directly influenced by the degree of opposition to the onward progress of the blood in any set of veins: thus, the valves are more numerous in the veins of the limbs where the blood flows against its own gravity than in those parts where it follows the direction of gravitation. There are no valves in the system of the vena portæ. They are generally more numerous in the deep than in the superficial veins.

We always find a pair of valves at the termination of a vein in a larger trunk. Very small veins have no valves. I shall take care to describe the number and arrangement of the valves in the principal veins.

The number of the valves is subject to many varieties. Some valves completely, and others but imperfectly intercept the course of the blood.

Structure.

In structure, a vein appears to me to resemble an artery, without its middle coat.* In fact, even by the most careful examination, we can only distinguish two coats in a vein; an *external*, called the *cellular* coat, but which I believe to be of the same nature as the *dartos*, and an *internal* coat, very thin, which is analogous to the lining membrane of the arteries, and, therefore, resembles the serous membranes. The internal membrane is the essential constituent of a vein; for the external coat may be wanting, or its place may be supplied by some other tissue: thus, in the sinuses of the dura mater, in the cells of the corpora cavernosa penis, in the substance of the walls of the uterus, and in the venous canals of bones, the place of the external membrane is supplied by the dura mater, by the fibrous parietes of the cells of the corpora cavernosa, by the tissue of the uterus itself, and by the proper substance of the bones.

The valves are formed by a fold of the internal membrane, containing some fibrous filaments, which are found especially along their adherent border.

The existence of a middle coat in the veins is admitted by authors, some of whom say it is composed of longitudinal fibres, while others think it consists of circular fibres; but such fibres do not, in reality, exist. Vesalius relates that, wishing to show them at one of his lectures, he was obliged to confess that he had never seen them, and could not find them.†

The walls of the veins are themselves supplied with small *arteries* and *veins* (*vasa vasorum*). No *nerves* have been demonstrated in them, nor do either mechanical or chemical stimuli applied to the inner membrane of the veins occasion pain.

It is rather a remarkable fact, in reference to the relations of the veins with the nerves, that nervous plexuses are never supported by veins, but, on the contrary, seem always to be separated from them. The trunk of the vena portæ is the only exception.

Preparation.

Most of the veins above a certain size may be examined without being previously injected; but injections are necessary for their minute investigation. The arrangement of the valves, which, in general, oppose the transmission of liquids from the heart towards the extremities, renders it necessary to inject a great number of veins from their extremities towards the heart. In general, in order to obtain as perfect an injection as possible, it is necessary to throw in the fluid simultaneously at several points and in several directions. Thus, a pipe may be placed in the vena cava superior, into which the injection should be pushed from the heart towards the extremities; another in the upper part of the cephalic or basilic vein of the right side; a third in the dorsal vein of the left thumb; a fourth in the right femoral vein; and, lastly, one in the left internal saphenous vein. In all these vessels, excepting in the vena cava, the injection should be thrown from the extremities towards the heart.

The injection of the veins from the arteries, which was proposed by Jankius, is doubly

* [The walls of a vein are thinner than those of an artery; and hence the former, when cut across, does not remain patent, like the latter kind of vessel. The coats of the superficial veins are thicker than those of the deep-seated ones, especially in the lower limbs.]

† [Nevertheless, the veins have an intermediate set of fibres, constituting a thin middle coat. The external coat is thinner than that of the arteries, and consists of interlaced cellular filaments. The middle coat, differing from that of an artery, is composed of pale red filaments, like those of cellular tissue, mixed with others resembling elastic tissue; the bundles into which these filaments are collected pursue a very irregular course around the vein. The internal coat is more distinct, less brittle, and more readily detached than the corresponding arterial tissue: it consists of fine longitudinal interlacing filaments, covered with an epithelium; it is continuous with the lining membrane of the auricles.]

inconvenient ; first, because both veins and arteries would be coloured alike, which would make it difficult to distinguish between them ; and, secondly, because we must use a very thin liquid, which would not become firm.

The most convenient injection mass is a coloured glue-size, because it sets slowly. If tallow be used, the subject must be placed in warm water.

The dissection of the veins, as well as that of the arteries, consists in separating them from surrounding parts, and preserving their relations as much as possible.

Method of Description.

In describing the veins, we may either follow the course of the blood, and trace the veins from the extremities to the heart, or we may pursue an opposite direction, and trace them from the heart to the extremities. I shall adopt a combination of the two methods ; that is to say, I shall commence with the trunks, and pass in succession to the larger and then to the smaller branches ; but in the particular description of each vein, I shall consider it as originating at the point most remote from, and terminating at the point nearest to, the heart.

DESCRIPTION OF THE VEINS.

THE PULMONARY VEINS.

Preparation.—Description.—Relations.—Size.—Peculiarities.

Preparation.—These veins may be traced from the heart towards their terminations. The facility with which injections pass from the pulmonary arteries into the pulmonary veins should be borne in mind.

There are four pulmonary veins (*l l*, *m m*, *fig.* 171), two for each lung, which open separately into the left auricle. Not unfrequently, however, there are five ; three for the right, and two for the left lung. Sometimes the two left pulmonary veins seem to unite immediately before opening into this auricle.

The trunks of these veins, each of which corresponds to a lobe of the lung, pass out of that organ in front of the corresponding pulmonary artery. The two upper veins of the right lung generally unite into a single trunk, which descends towards the root of the lung, while the inferior trunk runs horizontally. In the interior of each lobule, the pulmonary veins commence from the ultimate ramifications of the pulmonary artery, and unite into a single branch, which emerges from the lobule in contact with the corresponding artery. These venous branches successively unite, so as to form a single trunk for each lobe of the lung. There are, therefore, three trunks for the right lung and two for the left ; but the trunk from the middle lobe of the right lung soon unites to that from the upper lobe. The pulmonary trunk belonging to the upper lobe lies in front of that belonging to the lower lobe ; it also passes obliquely downward and outward, while that which belongs to the lower lobe runs horizontally. These four trunks open into the four angles of the left auricle (*n*), after having perforated the pericardium, within the cavity of which their course is exceedingly short.

Relations.—In the substance of the lungs the branches of the veins are behind, those of the arteries are in front, and the bronchia are in the middle. The larger branches of these three kinds of vessels cross each other at acute angles, but their extreme ramifications are parallel. At the root of the lung, the veins are in front, the artery is in the middle, and the bronchus behind.

In the pericardium, the anterior surface of the veins is invested by the serous layer of the pericardium. The right pulmonary veins are in relation, in front, with the vena cava superior, which crosses them at right angles : the left pulmonary veins are in relation with the left pulmonary artery.

It is generally said that the pulmonary artery is larger than the pulmonary veins ; but it has appeared to me that the pulmonary veins are no exception to the general rule that the veins are larger than their corresponding arteries.

Moreover, although there are two pulmonary venous trunks for each lung, by a remarkable exception only a single vein accompanies each branch of the artery.

The pulmonary veins have no valves, even at their openings into the auricle ; they carry red blood like the arteries, and hence the name *arteriæ venosæ*, by which they were designated by the ancients. Distinctly circular muscular fibres can be traced upon the portion of the pulmonary veins situated within the pericardium. The serous layer only partially invests these veins, and it is doubtful whether the fibrous layer is prolonged upon them at all.

THE VEINS OF THE HEART.

The Great Coronary or Cardiac Vein.—The Small Cardiac Veins.

The *cardiac* veins are divided into the great coronary vein and the small coronary veins of the heart.

The *great coronary vein* commences near the apex of the heart, at the lower part of the anterior inter-ventricular furrow, up which it runs (*e*, *fig.* 191), gradually increasing in size; having arrived at the base of the ventricle, it turns to the left, so as to leave the anterior coronary artery, and, changing its direction, it runs along the left auriculo-ventricular furrow, becoming larger as it proceeds, and at length opens (*e*, *fig.* 192) into the posterior and inferior part of the right auricle, near the inter-auricular septum.

The very great size of that portion of the vein which embraces the left auriculo-ventricular furrow has obtained for it the name of the *coronary venous sinus*. It almost always presents a very remarkable dilatation, or *ampulla*, before it enters the auricle. During its course it receives a great number of branches.

Thus, its vertical or ascending portion receives both superficial and deep veins, which emerge from the adjacent parts of the ventricles and their intervening septum.

Its circular portion receives some small *descending* or *auricular branches* from the left auricle, and also larger *ascending* or *ventricular branches*, which enter it at right angles; among the latter, we find the *vein of the left border of the heart*, which commences near the apex of the left ventricle, runs backward, crossing obliquely over the corresponding artery, and opens, almost at a right angle, into the great coronary vein, behind the left border of the heart; secondly, two or three branches from the posterior surface of the left ventricle; and, lastly, a *posterior inter-ventricular branch*, which traverses the posterior inter-ventricular furrow, and terminates in the ampulla, at the opening of the coronary vein into the right auricle. I have seen this branch terminate at once in the auricle by a distinct opening, covered or protected by the valve of the coronary vein. A small vein which runs along the posterior half of the right auriculo-ventricular furrow opens directly into the right auricle, near the ampulla of the great coronary vein: I do not know whether this small vein is constant. The great coronary vein has no valves, excepting at its entrance into the right auricle, where the valve, however, cannot completely oppose the reflux of the blood, for the great coronary vein is always filled when an injection is thrown into the vena cava superior.

The *small* or anterior coronary veins of the heart, or small *cardiac veins* (*venæ innominatæ* of Vieussens), consist of three or four small veins, which run upon the anterior surface of the right ventricle, and open at the lower part of the right auricle. Among them we may point out one which runs along the right border of the heart, and has been called the *vein of Galen;* and also another very small one, which commences upon the infundibuliform prolongation of the right ventricle, enters the right auriculo-ventricular furrow, and opens directly into the right auricle.

It follows, then, that the small cardiac veins belong to the front of the right ventricle and auricle, or, we might even say, to the greater part of the right side of the heart; while the great coronary vein belongs to the left side of the heart, and to the remaining part of the right side.

I have already said that the *veins of Thebesius*, or *venæ minimæ*, which are described by Vieussens, Thebesius, and Lancisi, and which are said to pour their contents into all the cavities of the heart, do not exist at all, and that their supposed orifices are nothing more than culs-de-sac, formed by intervals between the muscular fasciculi of the heart, and at the bottom of which an areolar structure is seen. I agree with Sénac in admitting the existence of venous openings in the right auricle only (of course excepting those of the pulmonary veins)

THE SUPERIOR, OR DESCENDING VENA CAVA AND ITS BRANCHES.

The Superior Vena Cava.—The Brachio-cephalic Veins—the Inferior Thyroid—the Internal Mammary—the Superior Phrenic, the Thymic, Pericardiac, and Mediastinal—the Vertebral.—The Jugular Veins, viz., the External—the Anterior—and the Internal.—The Encephalic Veins, and the Sinuses of the Dura Mater, viz., the Lateral—the Superior Longitudinal—the Straight—the Superior and Inferior Petiosal—the Cavernous—the Coronary—and the Anterior and Posterior Occipital Sinuses—the Conflux of the Sinuses.—The Branches of Origin of the Jugular Veins—the Facial—the Temporo-maxillary—the Posterior Auricular—the Occipital—the Lingual—the Pharyngeal—the Superior and Middle Thyroid—the Veins of the Diploë.—Summary of the Distribution of the Veins of the Head.—The Deep Veins of the Upper Extremity—the Palmar, Radial, Ulnar, Brachial, and Axillary—the Sub-clavian.—The Superficial Veins of the Upper Extremity—in the Hand—in the Forearm—at the Elbow—and in the Arm.—General Remarks on these Superficial Veins.

The *vena cava superior, descendens*, is the common trunk of all the veins of the upper half of the body, and very nearly corresponds to the ascending aorta in the parts to which it is distributed. It is situated to the right of the sternum, within the thorax, and hence has been named the *thoracic vena cava;* it commences immediately below the cartilage of the first rib on the right side, where it is formed by the junction of the two brachio-cephalic veins (*c c'*, *fig.* 170), which return the blood from the whole supra-dia-

phragmatic portion of the body: from the point above mentioned it descends vertically, describing a slight curve, the concavity of which is turned to the left, and the convexity to the right side; it enters the pericardium, and (*d*, *figs.* 191, 193) opens into the upper part of the right auricle (*m h*, *fig.* 193) behind the auricula; its posterior half appears to be continuous with the corresponding part of the vena cava inferior: hence, doubtless, arose the opinion of Vesalius, that there is but one vena cava.

Its *relations*, while without and within the pericardium, require to be separately examined. Externally to the *pericardium*, the vena cava superior is in relation with the right lung, being separated from it, however, by the right wall of the mediastinum, and by the phrenic nerve, which is at first on the outer side, and then passes in front of the vein; on the left side, it is in relation with the arch of the aorta; in front, with the remains of the thymus gland and the cellular tissue of the mediastinum, by which it is separated from the sternum; behind, with the trachea, a great number of lymphatic glands intervening between them.

Within the pericardium the vena cava is covered by the serous layer of that membrane in its anterior three fourths: it is in immediate contact behind with the right pulmonary artery and right superior pulmonary vein; on the left side, it is merely in contact with the aorta.

The superior vena cava has no valves, either in its course or at its opening: it follows, therefore, that each contraction of the auricle is accompanied by a regurgitation of blood into the vena cava and into the branches immediately opening into it. Upon this regurgitation depends the phenomenon of venous pulsation.

The vena cava presents certain conditions in its *structure* which require special notice. It has been said that the muscular fibres of the auricle are prolonged upon it; I can state that such is not the case. The serous layer of the pericardium covers the pericardial portion of this vein, and the fibrous layer is prolonged upon that part of the vessel which is external to the pericardium.

Lastly, the relative length of the intra- and extra-pericardial portions of the vena cava is subject to much variety: sometimes the vein enters the pericardium at about the middle of its course; sometimes only a few lines from its termination in the auricle.

The *caliber* of the vena cava superior is less than that of both the brachio-cephalic trunks taken together, and also less than that of the vena cava inferior. Its length varies from two and a half to three inches.

Sometimes this vein is double: I once found in an adult two superior cavæ, opening into the right auricle, a variety which evidently depended upon the two brachio-cephalic veins not having united. This condition is normal in several animals.

Collateral Veins.—The vena cava superior receives no branch while within the pericardium, immediately before entering which it receives the *vena azygos*. The *right inferior thyroid* and *internal mammary veins*, and the small veins called *thymic*, *pericardiac*, *mediastinal*, and *right superior phrenic*, generally enter opposite the junction of the two brachio-cephalic trunks, and not into the vena cava itself.

As the vena azygos forms part of the system of spinal veins, it will be described with them.

As the other veins have a similar distribution on both sides, the description of those on the left side will apply to those of the right also.

The Brachio-cephalic Veins.

The *brachio-cephalic veins*, or *venæ innominatæ* of Meckel (*c c'*, *fig.* 170), which are generally included in the description of the sub-clavian vein, correspond exactly to the brachio-cephalic or innominate artery, being formed by the union of the internal jugular vein (*d*) and the sub-clavian vein (*e*), properly so called, which correspond to the common carotid and the sub-clavian arteries.

There are two brachio-cephalic veins, one for the right (*c'*) and one for the left side (*c*); so that the arrangement of the veins of the upper half of the body is more symmetrical than that of the arteries.

The right and left venous trunks differ from each other in *length*; for as they both commence at the junction of the corresponding internal jugular and sub-clavian veins, opposite the sternal end of the clavicle of their own side, and terminate on the right of the median line, to form the commencement of the vena cava superior, it follows, therefore, that the right brachio-cephalic vein must be much the shorter; it is, in fact, only from twelve to fourteen lines in length, while that of the left side is twice as long.

They differ also in caliber, the left brachio-cephalic trunk being much larger than the right, in consequence of receiving the internal mammary and inferior thyroid veins of its own side.

Also in *direction*, the right being almost vertical, and sloping only slightly to the left side as it descends, like the superior vena cava, which follows the very same direction; the left vein, on the contrary, is almost horizontal, and describes a curve with its concavity directed backward; the two brachio-cephalic veins, therefore, unite at a right angle to form the vena cava.

Lastly, they have different *relations*. The concavity of the *left vein* embraces the front of the highest part of the aortic arch, and the three great arteries arising from it. It corresponds anteriorly with the sternal extremity of the left clavicle and the sterno-clavicular articulation, and runs along the upper border of the sternum. The *right vein* is situated in the right cavity of the thorax; it is parallel with, and on the outer side of, the brachio-cephalic artery, and it is in contact behind and on the right side with the right wall of the mediastinum and with the pneumogastric nerve, which are interposed between it and the apex of the lung.

The relations of the left brachio-cephalic vein with the arch of the aorta account for its obliteration in aneurism of that vessel, and its relation to the upper part of the sternum explains the venous pulse, seen so distinctly opposite the fourchette of the sternum in severe attacks of dyspnœa.

There are no valves in the interior of these veins, and hence considerable regurgitation may occur.

Collateral Branches.—The right brachio-cephalic vein, in some cases, receives only the vertebral brain; but most commonly the right inferior thyroid and right internal mammary veins terminate in it. The left brachio-cephalic vein always receives the above-mentioned veins of its own side, and also the *superior phrenic*, the *thymic*, and *pericardiac veins*, and often the *superior intercostal vein*. As this last forms part of the system of the vena azygos, it will be described in another place.

The Inferior Thyroid Veins.

There are two o tnese, viz., a *right* and a *left* inferior thyroid vein: not unfrequently there are three, and even four.

The course of the inferior thyroid veins corresponds exactly with that of the inferior thyroid artery of Neubauer, when it exists. They arise from the thyroid venous plexuses, and sometimes directly from the superior thyroid vein by an anastomotic arch; they descend vertically between the trachea and the muscles of the sub-hyoid region, and terminate differently on the right and left sides, the right inferior thyroid vein terminating at the junction of the two brachio-cephalic veins, and sometimes even in the upper and anterior part of the superior vena cava, while the vein of the left side enters the corresponding brachio-cephalic vein.

In one case in which there were three inferior thyroid veins, the middle one ended in the superior cava, and the two lateral veins in the corresponding brachio-cephalic trunks.

These veins, moreover, present innumerable varieties in their number, course, anastomoses, and termination. One of the most curious and frequent of these varieties is that in which the right and left veins form an arch, which receives four or five parallel branches that issue from the thyroid gland.

The inferior thyroid veins are joined by the tracheal and inferior laryngeal veins, so that Winslow named them guttural or tracheal. They form, in front of the trachea, a large plexus, which it is impossible to avoid in performing tracheotomy.

The Internal Mammary Veins.

The internal mammary veins follow the same course as the arteries of that name, and receive a series of branches corresponding to those given off by the arteries, excepting in one instance, viz., the superior phrenic veins, neither of which, in general, terminates in the corresponding internal mammary.

Usually, there are two veins of unequal size for each internal mammary artery, which is placed between them. The two almost always unite into a single trunk, which terminates on the right side at the junction of the two brachio-cephalic veins, or in the upper and front part of the superior cava, and on the left in the corresponding brachio-cephalic vein.

Among the veins which open into the internal mammary, I should mention the proper veins of the sternum, which form a very remarkable venous network in front of and behind each piece of that bone beneath the periosteum.

The Superior Phrenic, and the Thymic, Pericardiac, and Mediastinal Veins.

These are small veins which unite into two groups, one for the *right* side, terminating at the junction of the two brachio-cephalic veins, or at the upper and anterior part of the superior vena cava; the other for the *left*, and terminating in the left brachio-cephalic vein. The *pericardiac* and *mediastinal* veins commence upon the pericardium and the anterior mediastinum.

The *thymic* veins, which are very large in the fœtus, may still be seen in the adult and the aged, for the thymus gland is never completely absorbed.

The *superior phrenic* veins are remarkable for their length as well as for their small size; they accompany the phrenic nerve and the superior phrenic artery: the left superior phrenic vein often enters the corresponding superior intercostal vein, and frequently the internal mammary vein.

The Vertebral Veins.

The *vertebral vein* corresponds to the cervical portion of the artery of the same name, and, like it, is contained in the canal formed by the series of foramina at the base of the transverse processes of the cervical vertebræ; it opens into the brachio-cephalic vein immediately behind the internal jugular; and it is said to open occasionally into the last-mentioned vein. Not unfrequently, as Eustachius remarks, this vein divides into two branches near its termination, one of which emerges with the artery, between the fifth and sixth vertebræ, while the other, either alone or accompanied by a small arterial twig, escapes by the foramen of the seventh cervical vertebra. I have seen these two branches emerge, one at the foramen of the fifth, the other at that of the sixth cervical vertebra.

This vein commences in the deep muscles at the back of the neck, communicates by a large branch with the occipital vein, and sometimes receives a small branch, which passes out at the posterior condyloid foramen; it enters the canal of the transverse processes, between the occipital bone and the atlas; and while within this canal, it receives anterior muscular branches from the prævertebral region, posterior branches from the external spinal veins, and vertebro-spinal branches from the interior of the spinal canal. At the point where it opens into the brachio-cephalic vein, it receives a large branch, which corresponds in its course to the ascending cervical artery; it also receives the deep cervical vein, which has the same distribution as the artery of that name.

The Jugular Veins.

The *jugular veins* (from *jugulum*, the throat) are three in number on each side, viz., the *internal* or *deep jugular* (*n*, *fig.* 219), the *external jugular* (*h*), and the *anterior jugular* (*m*). The two latter veins form part of the superficial or sub-cutaneous venous system; but the internal jugular is the satellite vein of the common carotid artery and its branches. I shall describe these three veins in succession, but shall not notice the veins with which they are directly continuous, nor yet their branches of origin, until I have described all three of them, because those branches terminate almost indifferently in either of them.

The External Jugular Vein.

The *external jugular* (*h*), one of the supplementary veins of the internal jugular, is a sub-cutaneous vein of the neck, on the lateral and anterior aspect of which it is situated. It is bounded above by the angle of the lower jaw according to some authors, by the neck of the condyle of that bone according to others: the former mode of limitation seems to me to be preferable. It is bounded below by the clavicle, behind which it ends in the sub-clavian vein (*o*), immediately to the outer side of the internal jugular, and sometimes even opposite that vein, but upon a plane anterior to it.

Fig. 219.

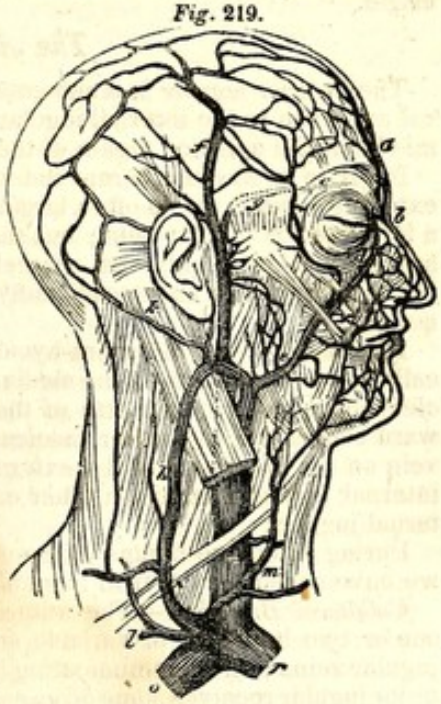

The external jugular is generally *single*, but is sometimes *double*; and this depends either upon some of its branches of origin not joining it until they reach the lower part of the neck, or else upon the existence of a small collateral branch, which arises from the upper part of the *external* jugular, runs along its outer side, and opens into it below, immediately before its termination; at other times the external jugular bifurcates before it ends in the sub-clavian.

The external jugular varies extremely in *size*, which frequently differs on the two sides, and is not uniform throughout its whole length. Thus, it almost always presents an ampulla, or ovoid dilatation of variable dimensions, near its termination. In size it is inversely as that of the other jugular veins of the same and the opposite side, and its differences are either congenital or acquired; the former depending upon the fact of its receiving more or fewer branches, while acquired alterations in size are occasioned either by some occupation requiring violent respiratory efforts, or by the venous circulation being impeded by disease.

Direction.—The external jugular vein passes obliquely downward and backward in the opposite direction to the sterno-cleido-mastoideus, which it crosses at a very acute angle, and then runs parallel to the posterior border of that muscle. A line drawn from the angle of the jaw to the middle of the clavicle will exactly indicate its direction. Opposite the clavicle, the external jugular vein turns forward and opens into the sub-clavian, either directly, or after running horizontally for some lines.

Relations.—The external jugular vein runs first across the sterno-mastoid, and then the supra-clavicular region of the neck. In the whole of its extent it is covered and

separated from the skin by the platysma; hence the rule to open this vein across the fibres of the platysma, when it is desirable that the orifice should be free, and favourably disposed for the flow of blood. By its *deep surface* it is in relation with the sterno-mastoid, which it crosses obliquely, so that it rests above upon the anterior border of that muscle, and below upon its external surface, and parallel with its outer border. In the supra-clavicular region it is in relation behind with the omo-hyoid and scalenus anticus muscles and with the brachial plexus. It is always separated from these different parts by the cervical fascia, which is perforated by it as it curves forward to enter the sub-clavian vein.

The external jugular vein is surrounded by the superficial nerves of the cervical plexus, some of which pass in front, and others behind it. The auricular nerve runs behind its upper portion.

This vein has generally two valves, one in the middle, the other near its termination; sometimes only the latter exists. These valves do not appear, in general, to oppose any great obstacle to an injection thrown from the heart towards the extremity of the vein.

Collateral Branches.—The external jugular vein receives, *in front*, branches of variable size and number, which communicate with the anterior jugular vein, and others which pass directly out of the sterno-mastoid muscle; *behind*, it receives the *superficial occipital veins* (*k*), and several superficial branches from the posterior and lateral regions of the neck; lower down, it also receives the *supra-scapular* and *posterior scapular veins* (*l*), which exactly correspond to the arteries of the same names. A constant branch passes beneath the clavicle, and establishes a communication between the external jugular vein and the upper part of the veins of the arm.

Branches of Origin.—These are extremely variable; most commonly the external jugular is formed by the junction of the *temporal* (*f*) and the *internal maxillary veins*. Sometimes it is formed by a branch resulting from the bifurcation of a trunk common to those two veins; at other times, by the successive juction of the *temporal*, *internal maxillary*, *facial*, *lingual*, and *superior laryngeal* veins.

In all cases the external communicates either directly or indirectly with the internal jugular vein in the substance of the parotid gland by means of a *communicating branch*, which may be regarded as a branch of origin, and which sometimes is the only branch of origin.

The Anterior Jugular Vein.

The *anterior jugular* is a sub-cutaneous vein (*m*, *fig.* 219), supplementary to the external and even to the internal jugular, and collects the blood from the parts situated in the middle of the anterior region of the neck.

It varies in *size* in different individuals, is almost always inversely proportioned to the external jugular, and is often larger than that vein. We frequently find both a right and a left anterior jugular vein; but then they are rarely of equal size. Rather frequently, however, there is only one, scarcely a trace of the other existing. Lastly, instead of these veins, there are occasionally only some small branches, which scarcely deserve notice.

Direction.—From the supra-hyoid region, where it commences, this vein passes vertically downward, between the median line and the inner border of the sterno-mastoid muscle; opposite the fourchette of the sternum it bends abruptly, passes horizontally outward behind the two lower fasciculi of the sterno-mastoid, and enters the sub-clavian vein on the inner side of the external jugular, sometimes opposite to, but in front of the internal jugular; lastly, in other cases, it terminates by a common orifice with the external jugular.

During its course it runs in the substance of that median layer of fibrous tissue which we have called the cervical linea alba, and it receives several collateral branches.

Collateral Branches.—The anterior jugular veins communicate with the external by one or two branches of variable size; they also communicate freely with the internal jugular veins; the communicating branches often form the origins of this vein. The anterior jugular receives some *laryngeal branches*, and sometimes an *inferior thyroid vein*. At the point where it bends at the lower part of the neck it receives a sub-cutaneous vein, which comes from the upper part of the thorax, and passes above the fourchette of the sternum. At the same point, also, the right and left anterior jugular veins communicate with each other by a transverse branch (*r*, *fig.* 223), into which branches derived from the inferior thyroid vein, or even some branches communicating directly with the left brachio-cephalic vein, pour their contents.

Branches of Origin.—The anterior jugular vein often commences by sub-cutaneous and muscular branches, derived from the supra-hyoid region, and corresponding in their several courses to the branches of the sub-mental artery. I have seen it arise from one end of a loop, the other end of which was continuous with the external jugular vein; at other times it commences by a common trunk with the facial and lingual veins. Lastly, I have seen the anterior jugular form the continuation of the facial vein.

The Internal Jugular Vein.

The *internal jugular vein* (*n*, *fig.* 219), the principal vein of the head, collects the blood from the interior of the cranium and from the greater part of the face and neck; it commences at the posterior lacerated foramen, and terminates in the brachio-cephalic vein (*r*), which is formed by the junction of the internal jugular with the sub-clavian vein (*o*). Its *direction* is vertical, without any deviation or bending.

It is of considerable *size*, but varies in different individuals; it is seldom of equal size on both sides, and is inversely proportioned to the external and anterior jugular veins; it becomes extremely large in such chronic diseases as impede the entrance of blood into the cavities of the heart. I have sometimes seen the internal jugular vein of the left side very small, its place being then supplied, as in the lower animals, by a very large external jugular.

Moreover, the internal jugular is not of uniform size throughout its whole length. It commences at the posterior lacerated foramen by a dilatation, which is called the *gulf of the internal jugular vein*; it continues of the same size until opposite the larynx, where it becomes greatly enlarged in consequence of receiving several branches; it terminates below in an oblong dilatation, and is again slightly contracted as it opens into the brachio-cephalic vein. This oblong dilatation in some asthmatic persons is very large, and might be called the *sinus of the internal jugular vein.*

That part of the internal jugular vein which extends from the os hyoides to the brachio-cephalic vein represents the common carotid artery; the part included between the os hyoides and the posterior lacerated foramen represents the internal carotid; and the series of branches which terminate in it represent the external carotid and the ramifications of that artery. These branches of the internal jugular, however, do not unite into a common trunk corresponding to the trunk of the external carotid artery, so that the distribution of this vein represents very nearly that variety in the distribution of the arteries of the neck, in which there is no external carotid artery; the branches usually given from it arising from the common carotid artery, which then terminates in the internal carotid.

Relations.—In that portion of its course which corresponds to the internal carotid artery, the internal jugular vein has almost the same relations as that vessel: thus, it is situated in the triangular interval between the pharynx and the ramus of the lower jaw; the artery, together with the pneumogastric, hypo-glossal, glosso-pharyngeal, and spinal accessory nerves, lie to the inner side and in front of it; the styloid and vaginal processes, and the styloid muscles, are also anterior to the internal jugular vein. That portion of the vein which represents the common carotid artery lies on the outer side of that vessel and in contact with it, excepting below, where the carotid is directed somewhat inward to reach the arch of the aorta, while the vein continues to be vertical, and is therefore separated from the artery. During its course it has the same relations as the artery, only on account of being situated to the outer side of that vessel, it follows that it is not covered by the platysma myoides to so great an extent as the artery, and, therefore, that it is covered for a greater length by the sterno-mastoid; and, indeed, its lower end is inclined to project beyond the outer border of that muscle, so that in asthmatic persons the skin covering the anterior part of the supra-clavicular triangle becomes elevated when the enlarged part of the vein is dilated. The pneumogastric nerve is situated behind, between the artery and the vein. A very important relation of the internal jugular vein is that which it has with the sub-clavian artery, which is situated between it and the vertebral vein, the internal jugular being in front, and the vertebral vein behind the artery.

The internal jugular vein returns all the blood from the interior of the cranium, receiving it from the lateral sinus, which may be regarded as the origin of this vein, and as the common trunk of all the veins within the cranium. Its *collateral branches*, several of which belong sometimes to the internal, and at others to the external jugular, are the *facial* (*e*), *lingual*, *inferior pharyngeal*, *superior thyroid* (all which open by a common trunk), and *middle thyroid* veins, sometimes also the *temporal* (*f*), *internal maxillary*, and *deep occipital* veins. We shall describe in succession the branches of origin, and then the collateral branches of the internal jugular vein.

The Encephalic Veins and the Sinuses of the Dura Mater.

The commencing twigs and the branches of the cerebral veins are like all other veins, but their trunks are essentially different, for they consist of fibrous canals, formed, as it were, in the substance of the dura mater; the lining membrane of these canals is the only part in which they correspond in structure with the rest of the venous system, the dura mater forming their outer coat. These canals are called the *sinuses of the dura mater.* They receive the blood from the brain, cerebellum, and medulla, from the eye, and from the bones of the cranium.

All the *sinuses of the dura mater* have a similar situation; they all occupy grooves formed for them upon the internal surface of the bones of the cranium, and which we have already described. They are, for the most part, situated opposite the intervals between

the great divisions of the encephalon : thus, the superior longitudinal sinus occupies the fissure between the two hemispheres of the brain ; the lateral sinuses are situated opposite the great fissure which separates the cerebrum from the cerebellum. All the sinuses communicate with each other, and form an uninterrupted series of canals ; they all open into the lateral sinuses, which are to the other sinuses what venous trunks are to their branches.

There are *twelve* sinuses in all, not including the inferior longitudinal sinus, which may be regarded as a vein. Eight of the sinuses exist in pairs, the remaining four are single, and occupy the median line. The single sinuses are the *superior longitudinal sinus*, the *straight sinus*, the *coronary sinus*, and the *transverse occipital sinuses*. The eight sinuses which exist in pairs are placed four on each side of the cranium ; they are the two *superior* and two *inferior petrosal*, the two *occipital*, and the two *lateral sinuses*.

As the lateral sinuses form, as it were, the common trunks of all the others, I shall describe them first.

The Lateral Sinuses.

The *lateral* or *transverse sinuses* (*a a, fig.* 221) are situated in the lateral grooves (*vide* OSTEOLOGY, p. 80) ; each of them commences, like those grooves, at the internal occipital protuberance, and passes horizontally outward as far as the base of the petrous portion of the corresponding temporal bone, at which point it dips obliquely downward and inward into the inferior occipital fossa, turns round the base of the pars petrosa, and again ascends to reach the posterior lacerated foramen of its own side (*s s, fig.* 221), where it terminates in the internal jugular vein. Like the corresponding grooves, the right and left lateral sinuses are of unequal size, the right being almost always the larger. Both of them gradually increase in size from their posterior extremity, which may be regarded as their origin, to their anterior extremity.

A section of the horizontal portion of each lateral sinus, which is situated in the outer margin of the tentorium cerebelli, is triangular, while that of its vertical or curved portion is semi-cylindrical. In the first part of its course it projects beyond the corresponding groove in the occipital bone, so as to occupy the fissure between the cerebrum and cerebellum. In the remainder of its course it does not project into the interior of the cranium, or pass beyond the groove, which is exactly suited to its dimensions.

The internal surface of each lateral sinus is smooth, and it is not traversed by bands like those found in the other sinuses. However, I once found in the horizontal portion of this sinus some of the white bodies called glandulæ Pacchioni.

One of the lateral sinuses has been found divided, in front, into two equal parts, a superior and inferior, by a perfect horizontal septum ; it is very common to find a fibrous lamina indicating a trace of this subdivision.

The anterior extremity of each lateral sinus is continuous with the gulf of the corresponding internal jugular vein, and the inferior petrosal sinus of its own side opens into it at the same point. During its course it receives some *inferior cerebral veins*, some *cerebellar veins*, and the *superior petrosal sinus* (*f*), which enters it at the point where it changes its direction from horizontal to oblique, *i. e.*, opposite the base of the petrous portion of the temporal bone.

The *lateral and inferior cerebral veins* commence partly on the lateral and inferior parts of the convex surface of the cerebrum, and partly on the base of the brain ; they unite so as to form a group of three, four, or five veins, which open into the horizontal portion of the lateral sinus. They enter from before backward, that is to say, in an opposite direction to the course of the blood in the sinus. One of these veins is sometimes observed to run along the tentorium cerebelli, with which it is maintained in contact by the parietal layer of the arachnoid for about an inch before it opens into the lateral sinus.

The *lateral and inferior cerebellar veins* are very large ; they commence upon the lower surface of the cerebellum, and terminate in two or three trunks, which are found upon the circumference of the cerebellum, and open into the horizontal portion of the lateral sinus by perforating its lower wall.

A *large mastoid vein*, which may be regarded as one of the principal origins of the occipital, also opens into the lateral sinus, and thus establishes a free and direct communication between the venous system within and that outside the cranium.

The Superior Longitudinal Sinus.

The *superior longitudinal sinus* (*b b, fig.* 220) is a single and median sinus, which occupies the longitudinal groove, and accordingly extends from the crista galli to the internal occipital protuberance ; it is formed within the substance of the convex border of the falx cerebri, and is three-sided ; a section of it represents an isosceles triangle (*b, fig.* 221), with its base turned upward and its apex downward. It is small at its anterior extremity, but gradually increases in size as it approaches the confluence of the sinuses (*n, fig.* 221), in which it terminates. It not unfrequently bifurcates near its posterior extremity ; sometimes it is directly continuous with the right lateral sinus.

The internal surface of this sinus is remarkable for the transverse bands found in it.

especially along its inferior angle. These bands consist of fibrous tissue covered by the lining membrane of the sinus, and they conceal the orifices of the veins which open into it; in some points they are so numerous as to form an areolar tissue. Lastly, we almost always find on the internal surface of the sinus some small white projecting bodies, the *glandulæ Pacchioni.*

Fig. 220.

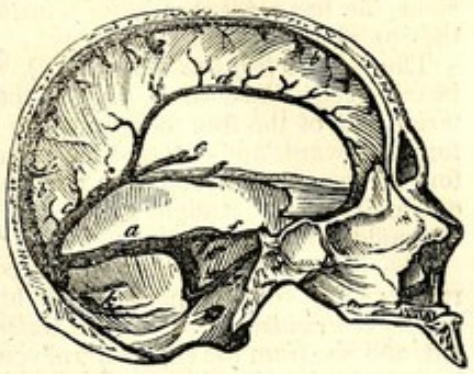

The following veins open into the superior longitudinal sinus: some from the internal or flat surface of each cerebral hemisphere, called the *internal cerebral veins;* others from the upper half of the convex surface of the brain, or the *external cerebral;* and, lastly, several veins from the dura mater and the bones of the cranium.

The *internal cerebral veins*, three or four in number on each side, return the blood from all the convolutions of the flat surface of the corresponding hemisphere of the brain, and enter the superior cerebral veins at the point where these are applied to the surface of the falx.

The *superior cerebral veins* vary in number, but are generally seven or eight on each side. The anterior of these veins are very small; the posterior are much larger. There is almost always one of greater size than the rest, which may be named the *great superior cerebral vein:* it appears to commence in and run along the fissure of Sylvius, is then prolonged obliquely backward, and turning forward upon the convex surface of the brain, so as to describe a curve having its concavity directed forward, it becomes applied to the falx cerebri, and opens into the longitudinal sinus, after having run for about one inch in the substance of its walls. During its course this vein receives a great number of branches, some anterior and others posterior, which, although corresponding to the arteries in their origin and in a part of their course, are completely separated from those vessels at their termination. The common trunks pass inward towards the great median fissure of the brain; near the sinus they become attached to the dura mater, being held down by the arachnoid membrane, which is reflected from the brain upon the dura mater; they then change their direction, turn forward in the substance of the falx cerebri, beneath a very thin layer of the dura mater, and after a course of from six to ten lines in length, terminate in the longitudinal sinus by one or more openings. The manner in which the cerebral veins open into the sinus varies: for some there are lateral openings, as if made by a punch; others open by means of an areola fibrous tissue, which, as I have already stated, is found in certain parts of the walls of the sinuses. All the venous orifices are concealed by fibrous areolæ, none of the veins opening directly into the sinus. Most of them run for a certain distance from behind forward, *i. e.*, in an opposite direction to the course of the blood, before they open into the sinus; the most anterior veins, which run from before backward, are the only exceptions to this rule. Moreover, the fold or bands which are formed in this and other sinuses do not perform the functions of valves, for they permit fluids to pass from the sinus into the veins. The inferences drawn by physiologists from the direction in which the cerebral veins open into the sinuses appear to me to be erroneous, for that direction facilitates instead of opposing the reflux of the blood. I have satisfied myself that the cerebral veins have no valves in any part of their extent.

The superior longitudinal sinus also receives *proper veins from the dura mater*, some *venous* or *diploic* veins, and several veins which commence in the pericranium, and establish a communication between the external and internal veins of the cranium. Among the communicating veins are those which traverse the parietal foramina, and are called the *veins of Santorini.* A very great number of veins penetrate through the longitudinal suture, to open into the corresponding sinus in young subjects; the communication of the diploic veins with those of the dura mater, and with the sinuses and cerebral veins, may be shown by perforating with a pin, in a young subject, the very thin and brittle external bony table which covers one of the numerous veins of the diploë, and then inserting into the orifice the fine point of a mercurial injecting apparatus: the mercury will fill the diploic veins, and will pass into the sinuses, the veins of the dura mater, and the cerebral veins.

The Straight Sinus.

The *straight sinus* (*c*, *fig.* 220) occupies the base of the falx cerebri, corresponding with the line of junction of the falx with the tentorium cerebelli.

The straight sinus is therefore single, and situated in the median line; it is directed somewhat obliquely backward and downward, and it opens into the confluence of the sinuses or torcular Herophili (*n*), by one or sometimes two orifices, according to the presence or absence of a vertical band across its termination. It is three-sided, and a section of it represents an isosceles triangle (*c*, *fig.* 221), having its base turned downward. This sinus increases in size as it proceeds backward.

The straight sinus receives by its anterior extremity the *inferior longitudinal vein* or *sinus*, the *two great ventricular veins* or *venæ Galeni*, the *inferior median cerebral veins*, and the *superior median cerebellar vein*.

The *inferior longitudinal vein* (*d*), which is generally but incorrectly described as the *inferior longitudinal sinus*, may be regarded as an ordinary vein enclosed within the posterior half of the free margin of the falx cerebri. This vein increases in size from before backward, and enters directly into the straight sinus. It sometimes bifurcates before its termination, and then the lower branch of the bifurcation opens into the anterior extremity of the straight sinus, and the upper describes a decided curve, and enters at the middle of that sinus.

The inferior longitudinal vein receives the *proper veins of the falx cerebri*. It seldom receives any vein belonging to the brain itself.

The *ventricular veins*, or *venæ Galeni* (*e*), are two in number, one proceeding from the left, and one from the right lateral ventricle. Each of them is formed by the union of two branches, viz., the *choroid vein*, and the *vein of the corpus striatum*.

The *choroid vein* runs along the whole length of the outer border of the choroid plexus, in a direction from behind forward. During this course it receives the vein from the hippocampus major, one from the fornix, and one from the corpus callosum, and having reached the anterior extremity of the choroid plexus, it turns back again within the substance of the plexus, and unites with the vein of the corpus striatum.

The *vein of the corpus striatum* is much smaller than the preceding; it commences behind in the furrow between the corpus striatum and the thalamus opticus, traverses the whole length of that furrow, covered by the tænia semicircularis, receives, during its course, a great number of small veins from the corpus striatum and thalamus opticus, and having arrived behind the anterior pillow of the fornix, unites with the choroid vein to form one of the venæ Galeni.

The two *venæ Galeni* proceed parallel with each other, and horizontally backward beneath the velum interpositum, pass out from the brain beneath the corpus callosum, and immediately enter the straight sinus below the opening of the inferior longitudinal vein without crossing each other, as is stated by some anatomists.

Not unfrequently we find an anterior and superior cerebellar vein opening into the venæ Galeni, as the latter enter the straight sinus.

The *inferior median cerebral veins* are very large. One is anterior, and commences upon the fore part of the lower surface of the cerebrum, and turns round its corresponding crus; while the other, which is posterior, arises upon the posterior convolutions; they both enter the anterior extremity of the straight sinus, behind the venæ Galeni.

The *superior median cerebellar vein* passes upward between the valve of Vieussens and the superior vermiform process, and opens into the anterior extremity of the straight sinus.

The Superior Petrosal Sinuses.

The *superior petrosal sinuses* (*f f*, *fig.* 221) are situated along the upper border of the petrous portion of the temporal bones, and are partly lodged in the small corresponding grooves; they are continuous as regards their direction with the horizontal portion of each lateral sinus, and occupy the anterior half of the lateral or adherent borders of the tentorium, the lateral sinuses occupying the posterior half. They are very small, and, like the part of the lateral sinus with which they are continuous, they are three-sided. The anterior extremity of each superior petrosal sinus communicates with the corresponding cavernous sinus (*h h*); and its posterior extremity opens into the corresponding lateral sinus at the point where the latter leaves the tentorium cerebelli to turn round the base of the petrous portion of the temporal bone.

Fig. 221.

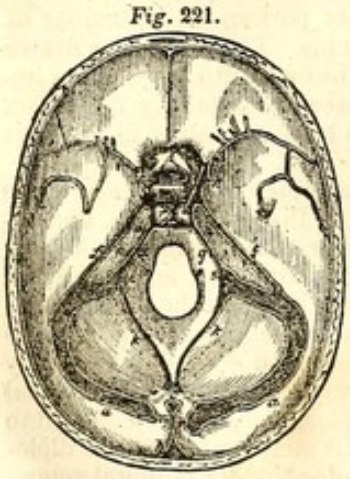

The superior petrosal sinuses, therefore, establish a direct communication between the cavernous and the lateral sinuses; they sometimes receive an *inferior lateral cerebral vein*, but always an *anterior lateral cerebellar vein*, which passes upward under the free margin of the tentorium cerebelli, behind the fifth pair of nerves. The veins which come from the sides of the pons Varolii also enter the anterior extremity of this sinus.

The Inferior Petrosal Sinuses.

The *inferior petrosal sinuses* (*g g*) are situated, one on each side, upon the petro-occipital sutures, and lie in corresponding grooves; each of them extends from the anterior to the posterior lacerated foramen of its own side. They are larger than the superior petrosal sinuses, and are semi-cylindrical, like the anterior part of the lateral sinuses, with which they are continuous. The anterior extremity of each opens into the anterior

occipital sinus (*r*) and into the cavernous sinus of its own side; while its posterior extremity opens into the anterior end of the corresponding lateral sinus, opposite the commencement of the internal jugular vein (*s*). These sinuses establish a free anastomosis between the anterior and posterior sinuses found at the base of the cranium.

Excepting one vein which comes from the base of the cranium through the foramen lacerum anticus, the inferior petrosal sinus receives no vein of importance.

The Cavernous Sinuses.

The *cavernous sinuses* (*h h*), so named from their reticulated, and, as it were, spongy structure, occupy the sides of the sella turcica and the grooves on the body of the sphenoid bone. Each cavernous sinus is bounded in front by the inner part of the sphenoidal fissure, and behind by the apex of the petrous portion of the temporal bone: its cavity (shown on the right side in the figure) is larger than it at first sight appears to be, but is encroached upon by the internal carotid artery, which curves twice upon itself during its passage through the sinus, and also by the abducens oculi, or sixth cranial nerve. The motor oculi or third nerve, the trochlearis or fourth, and the ophthalmic branch of the fifth cranial nerve, are situated in the substance of the outer wall of the sinus. It is traversed by reddish reticulated filaments, the nature of which is unknown. The older anatomists said that the internal carotid artery and the sixth nerve were bathed in the blood of the sinus; but it is now generally believed, in accordance with the opinion of Bichat, that they are protected by the lining membrane of the veins; it is difficult to prove the accuracy of this opinion, although analogy is in its favour. Bichat also thought that the reticulated filaments mentioned above were folds of the lining membrane of the vein. The anterior extremity of each cavernous sinus has been named the *ophthalmic sinus*, doubtless on account of its being prolonged outward. Its posterior extremity opens into the corresponding superior and inferior petrosal sinuses, and into the transverse occipital sinus. On the inner side it receives the coronary sinus, which establishes a direct communication between the right and left cavernous sinuses. Lastly, each cavernous sinus receives below several branches, which connect the veins within with those outside the base of the cranium, more particularly with the pterygoid venous plexuses.

The cavernous sinuses receive in front the *inferior* and *anterior cerebral veins*, which commence upon the lower surface of the anterior lobe of the cerebrum. The largest of these veins on each side reaches the sphenoidal fissure, turns backward over the lateral and middle fossa of the base of the cranium, and enters the middle meningeal vein. Several anatomists state that they have seen the middle meningeal veins open into the cavernous sinuses.

Lastly, the anterior extremity of each of these sinuses receives the ophthalmic vein.

The *ophthalmic vein* is a very large vessel, which commences on the inner side of the orbit as a continuation of the *frontal vein*, and terminates by opening into the anterior extremity of the corresponding cavernous sinus; and it thus establishes a very free communication between the veins of the interior and exterior of the cranium. It pursues the same course as the ophthalmic artery, but without any windings, and receives venous branches corresponding to the ramifications of that artery. Among them, I shall mention particularly the *ciliary veins*, which commence in the choroid membrane of the eye, where they are called *vasa vorticosa*, on account of being arranged in whirls.

The Coronary Sinus.

The *coronary sinus*, or *circular sinus of Ridley* (*i*), runs round the margin of the pituitary fossa, and completely surrounds the pituitary body. Its posterior is much larger than its anterior half. In old subjects it is not rare to find the quadrilateral plate of the sphenoid bone behind the pituitary fossa worn away, as if corroded by the blood of the sinus, so that it may easily be broken. At this period of life, the coronary sinus is larger than in young subjects, and extends under the pituitary body itself.

The coronary sinus only receives osseous veins from the sphenoid, some veins from the dura mater, and those from the pituitary body. It opens freely on each side into the cavernous sinuses, which thus communicate with each other.

The Anterior Occipital, or the Basilar Sinus.

The *anterior* or *transverse occipital sinus* (*r*) is median and single; it extends transversely across the basilar groove from the foramen lacerum posticus of one side to that of the other; it is of an irregular form, much larger in the aged than in adult and young subjects, and connects the superior and inferior petrosal sinuses and the cavernous sinus of one side with the corresponding sinuses of the opposite side. In old subjects, the basilar surface not unfrequently appears as if corroded opposite this sinus, the cavity of which often presents a cellular or spongy structure.

The Posterior Occipital Sinuses.

These (*k k*) are the smallest of all the sinuses of the dura mater; they commence one at each foramen lacerum posticus, pass from thence upon each side of the foramen

magnum, converge towards the falx cerebelli, enter its substance, and open separately into the confluence of the sinuses: they receive some small veins from the bones of the cranium and from the dura mater: the posterior occipital sinuses may be said to represent the chord of the arc formed by the lateral sinuses.*

The Confluences of the Sinuses.

From what has been stated above, it appears that there are three central points in which all the sinuses meet: one situated behind and in the middle line, and one on each side of the middle line in front. The term *confluence of the sinuses* might be applied to all three points, but it has hitherto been confined to the posterior and median central point, or occipital confluence. All the sinuses open directly into one of these three points, the inferior longitudinal, if it be considered a sinus, forming the only exception.

The Posterior or Occipital Confluence, or Torcular Herophili.—If that portion of the dura mater which corresponds to the occipital protuberance be opened from behind, six orifices will be exposed to view, viz., a superior, which belongs to the superior longitudinal sinus; an anterior, sometimes divided into two by a vertical band, which belongs to the straight sinus; two lateral orifices, which belong to the two lateral sinuses; and two inferior, which belong to the posterior occipital sinuses. The point at which these sinuses meet is named the *torcular Herophili* (*n n, figs.* 220, 221), because it is supposed that the columns of blood flowing from the different sinuses must, in some degree, press against each other.

The Anterior or Petro-sphenoidal Confluence.—Between the apex of the petrous portion of the temporal bone and the sphenoid bone, there is on each side another confluence, at which a great number of sinuses meet, viz., in front, the cavernous sinus and the coronary sinus; on the inside, the transverse occipital sinus; and behind, the superior and inferior petrosal sinuses.

The Branches of Origin of the Jugular Veins.

The Facial Vein.

The *facial*, or *external maxillary vein* (*e, fig.* 219), represents the artery of the same name; also the terminal divisions of the ophthalmic artery; and, lastly, some of the branches of the internal maxillary artery.

It commences in the frontal region, where it is called the *frontal vein;* at the inner angle of the eye it is named the *angular vein;* and afterward the *facial vein* until its termination.

The *frontal vein* (la vein préparate, *a, fig.* 219) is a sub-cutaneous vein, which was selected by the ancients for phlebotomy: it is sometimes single, and is then placed in the median line; but there are generally two frontal veins united by a transverse anastomosis. Among the numerous varieties which this vein presents, I shall point out one in which the two frontal veins are united into a single trunk, which bifurcates above the root of the nose. These veins do not exactly follow the course of the frontal arteries; they descend from the vertex, where, by their numerous anastomoses, either with each other or with the temporal veins, they form a venous plexus large enough to cover the whole frontal region. They open into a transverse venous arch, having its concavity directed downward; it is sometimes tortuous: it is situated at the root of the nose, and is named the *nasal arch* (*b*). This arch is also joined by the *supra-orbital vein*, a deep-seated vessel (indicated by the dotted lines *c*), which runs transversely along the upper part of the orbit, receives the superior internal palpebral vein, and opens into the extremity of the arch, on the outer side of the frontal vein: the *ophthalmic vein* also terminates in the nasal arch of the vein, between which and the cavernous sinus it establishes a free communication. Thus the upper parts of the face, more particularly the eye and its appendages, are intimately connected with the brain through the medium of the veins as well as of the arteries. Moreover, the *dorsal veins of the nose*, which run on each side of the ridge of that organ, open into the concavity of the nasal arch.

The *angular veins* are given off from the right and left extremities of the nasal arch, and may be regarded as the continuations of the frontal veins; like the corresponding arteries, each of them (*d*) is situated in the furrow between the nose and the cheek. The *inferior palpebral vein* and the *vein of the lachrymal sac* and *nasal duct* enter the outer side of each angular vein, which is joined on its inner side by the veins of the corresponding ala of the nose.

The *veins of the ala nasi* form a very dense network between the cartilage and the skin, and also between the cartilage and the mucous membrane; from these networks two branches are given off: a superior, which runs along the convex border; and an inferior, which runs along the lower border of the inferior lateral cartilage, or the cartilage of the ala. These two branches unite into a very large common trunk, which passes upward, often very obliquely, into the angular vein.

The *facial vein* (*e*) commences in the angular vein, at the point where the latter is

* [They sometimes join the lateral sinuses in front, as shown in the figure.]

joined by the veins of the nose; it proceeds very obliquely downward and outward, passes under the great zygomatic muscle, reaches and then runs along the anterior border of the masseter, crosses at right angles over the base of the jaw, is received into a groove in the sub-maxillary gland, and terminates in several different modes.

Most commonly, it unites with the lingual to form a common trunk, which enters the internal jugular; it is into this common trunk of the facial and lingual veins that the superior thyroid and the pharyngeal vein, and the common trunk of the temporal and internal maxillary veins, sometimes open. In other cases the facial vein passes obliquely across the outer surface of the sterno-mastoideus, and enters at some point of the external jugular vein. I have seen it directly continuous with the anterior jugular, also with the external jugular of the same or of the opposite side, or it may enter the convexity of an arch of communication between the external and anterior jugular veins.

Collateral Branches.—During its course the facial vein in joined on its *outer side* by the *alveolar venous trunk*, which is very large, and may be regarded as the deep branch of origin of the facial vein, which, in fact, becomes much larger, sometimes even twice as large, after its reception. This alveolar trunk commences in a very remarkable venous plexus, named the *alveolar plexus*, in which the *alveolar veins properly so called*, together with the *infra-orbital*, *superior palatine*, *vidian*, and *spheno-palatine veins* terminate, and which communicates with the pterygoid plexus. All these veins accompany the branches of the internal maxillary artery having the same names. From the alveolar plexus the alveolar trunk runs forward and downward below the malar bone, and unites obliquely with the facial vein. The facial is also joined on its *inner* side by the *superior* and *inferior coronary* veins of the lip, which are distributed like the arteries, but are not tortuous; by the *buccal* vein or veins; and by the *anterior masseteric veins*.

Below the base of the jaw, the facial vein is joined by the *sub-mental* vein; by the *inferior palatine*, which is remarkable for the *plexus* around the tonsils, which is formed almost entirely by it; also by the vein or veins from the *sub-maxillary gland*, and sometimes by the *ranine vein*.

During its course the facial vein is, in general, more superficial than the facial artery, and does not accompany it on the face, but is situated more to the outside, and is not tortuous.

The Temporo-maxillary Vein.

The *temporo-maxillary vein*, or venous *trunk*, represents the temporal artery, a part of the internal maxillary, and the upper part of the external carotid: many authors follow Walther in naming it the *posterior facial vein*, in contradistinction to the facial vein properly so called, which they name the *anterior facial*. The temporo-maxillary is formed by the junction of the temporal and internal maxillary veins: it most frequently terminates in the *external jugular* vein.

The Temporal Vein.—This vein commences above by superficial, middle, and deep branches.

The *superficial temporal veins* (*f*, *fig.* 219) commence upon the crown of the head by *anterior* or *frontal branches*, which communicate freely with the origin of the frontal vein, by *middle* or *parietal* branches, which communicate with the corresponding branches of the opposite side, and by *posterior* or *occipital* branches, which communicate with the branches of the occipital vein. These form a very open network over the greater part of the cranium. From this network anterior and posterior branches arise, and unite with each other above or opposite to the zygomatic arch. During this course the veins do not exactly follow the direction of the corresponding arteries. It might be said that the veins of the scalp partake of the characters both of the venæ comites and the subcutaneous veins. These venous networks are, moreover, situated in the substance of the hairy scalp, and, like the arteries, are placed between the skin and the occipito-frontalis muscle.

The *middle temporal vein* is a very large vessel, often much larger than the common trunk of the superficial veins. It is situated (as indicated by the dotted lines, *g*, *fig.* 219) beneath the temporal fascia, between it and the temporal muscle. It is sometimes formed principally by the junction of the *palpebral* with the *external orbital veins*, which, corresponding in their distribution to the arteries of the same name, unite into a common trunk that runs backward at first between the two layers of the temporal fascia, then between the muscle and the fascia, is directed backward and downward, again perforates the fascia from within outward above the antero-posterior root of the zygomatic process, and unites with the superficial temporal vein in front of the external auditory meatus.

The trunk resulting from the junction of the superficial temporal and middle temporal veins passes vertically downward, between the external auditory meatus and the temporo-maxillary articulation, dips into the substance of the parotid gland, and, having arrived behind the neck of the condyle, receives the internal maxillary vein, which constitutes the deep origin of the temporo-maxillary trunk.

The Internal Maxillary Vein.—This vein, the deep origin of the temporo-maxillary trunk, is called by Meckel the *internal* and *posterior maxillary*, in opposition to the *alveolar* branch

of the facial vein, which he calls the *internal* and *anterior maxillary:* it corresponds to all the branches given off from the internal maxillary artery behind the neck of the condyle, in the zygomato-maxillary fossa; while the alveolar vein, the deep branch of the facial, corresponds to all the branches given off by the internal maxillary artery upon the tuberosity of the superior maxilla and in the pterygo-maxillary fossa.

Thus it is joined by the *middle meningeal veins.* The venæ comites of the middle meningeal artery, the existence of which has been erroneously denied, are two in number, and are situated, one in front, the other behind the artery. These veins often receive some inferior and anterior cerebral veins, which enter them near the foramen spinosum of the sphenoid; they always receive veins from the bones of the cranium and from the dura mater, and communicate with the superior longitudinal sinus; they are sometimes so large, especially the anterior branch, that they have deep grooves formed for them upon the sphenoidal fossa, reaching from the foramen spinosum to the point of the great ala of the sphenoid bone. Lastly, the distribution of the middle meningeal veins is similar to that of the corresponding artery.

The internal maxillary vein is also joined by the *inferior dental*, by the *deep temporal*, by the *pterygoid*, and by the *posterior masseteric veins.* All of these veins communicate with a very large and important venous plexus, the *pterygoid* plexus, situated between the temporal and external pterygoid muscles, and between the two pterygoid muscles. In this plexus, which communicates freely with the alveolar plexus, so freely, indeed, that they may be regarded as forming but a single plexus, the internal maxillary vein commences and joins the temporal vein, behind the neck of the condyle of the lower jaw.

The temporo-maxillary trunk, thus formed by the junction of the temporal with the internal maxillary vein, is much larger than the former vein, and continues its course through the substance of the parotid gland; it is joined directly by some *parotid veins*, by the *posterior* and *anterior auricular veins*, and, lastly, by the *transverse veins of the face.* The last-named veins form, between the parotid gland and the masseter muscle (*i*, *fig.* 219), between that muscle and the ramus of the lower jaw, and around the temporo-maxillary articulation, a very large plexus, named the *masseteric plexus*, which communicates freely with the pterygoid plexus through the sigmoid notch.

Termination of the Temporo-maxillary Trunk.—Most commonly the temporo-maxillary vein or trunk terminates directly in the *external jugular vein* (*h*); at other times it enters the internal jugular, and then there is merely a trace of the external jugular, which is formed principally by the superficial branches of the occipital vein, and by some communicating branches from the anterior jugular. In some cases, the temporo-maxillary vein is almost equally divided between the internal and external jugulars; lastly, it is sometimes united to the lingual and the facial vein: when it ends in the external jugular, it sends to the internal jugular a large communicating branch which passes above the digastric muscle.

The Posterior Auricular Vein.

The *posterior auricular vein* follows the distribution of the artery of that name; it receives the *stylo-mastoid vein*, and enters the external jugular, or, rather, the temporo-maxillary vein, which does not take the name of external jugular until after it is joined by this vein.

The Occipital Vein.

The *occipital vein* is distributed in the same manner as the occipital artery; it commences at the back of the cranium, passes beneath the splenius muscle, and is joined opposite the mastoid process by one or more large *mastoid veins*, which come from the corresponding lateral sinus, establishing a direct and free communication between the venous circulation in the interior and exterior of the cranium. It was this that led Morgagni to prefer the occipital veins for the purpose of bloodletting in apoplexy. The occipital vein ends in the internal, and sometimes in the external jugular.

The Lingual Veins.

The *lingual veins*, being intended for a contractile organ, the circulation in which is on that account liable to be much interfered with, are divided, like the veins of the limbs, into the *superficial* or *sub-mucous*, and the *deep veins.*

The *superficial veins of the dorsum of the tongue*, which are generally named the *lingual* veins, occupy the dorsal region of the tongue, ramifying in a remarkable manner between the mucous membrane and the muscular fibres of that organ: all these veins open into a *dorsal* or *superior lingual plexus*, which is situated at the base of the tongue, and is joined by a great number of veins from the tonsils and epiglottis.

The *satellite vein of the lingual nerve* emanates from this plexus, accompanies the lingual nerve, receives some branches from the sub-lingual glands and the tissue of the tongue, and enters the facial or the pharyngeal vein, or terminates directly in the external jugular, communicating freely with the ranine veins.

The *ranine veins* are the superficial veins of the lower surface of the tongue. They

are seen one upon each side of the frænum, where they form a ridge beneath the mucous membrane. Each of them accompanies the corresponding hypoglossal nerve, between the genio-hyoglossus and hyoglossus muscles, and terminates either in the common trunk of the lingual and facial veins, or directly in the facial vein.

The ranine veins communicate upon the sides of the tongue with a very large plexus, the vessels composing which are sometimes provided with valves, so that it is impossible to inject it in a direction from the heart towards the extremities of the veins, which, in other cases, may be done with the greatest facility.

Lastly, the *lingual veins*, properly so called, are extremely small; they are two in number, and accompany the lingual artery throughout the whole of its course. Not unfrequently the veins of the tongue terminate directly in the internal jugular: I have seen them open into the anterior jugular.

The Pharyngeal Vein and Pharyngeal Plexus.

The Pharyngeal Plexus.—In making the section already described for examining the pharynx, we observe round the back of that organ a considerable venous plexus, which forms loops or rings for embracing the pharynx; several *meningeal branches*, and some derived from the *vidian* and *spheno-palatine veins*, open into this plexus; from which a variable number of *pharyngeal branches* arise, and terminate by a common trunk, or by several distinct branches, in the lingual vein, sometimes in the facial or the inferior thyroid, and frequently in the internal jugular.

Besides this plexus, which may be called the *superficial* pharyngeal plexus, an extremely dense network is found beneath the mucous membrane, from which branches proceed to join with those that arise from the superficial plexus just described

The Superior and the Middle Thyroid Veins.

The *superior thyroid*, or *thyro-laryngeal vein*, commences upon the thyroid gland by branches corresponding to the thyroid arteries, and upon the larynx by branches corresponding to the ramifications of the superior laryngeal artery. The thyroid and laryngeal branches unite and end in the internal jugular vein, opposite the upper part of the larynx; they perhaps end more frequently in the common trunk of the facial and lingual veins. It is not uncommon to find the superior laryngeal branch terminating directly either in one or the other of these veins, or in the anterior jugular.

The *middle thyroid vein* arises from the lower part of the lateral lobe of the thyroid gland, and is joined by some branches from the larynx and the trachea. By their union they form a trunk, which ends in the lower part of the internal jugular vein. The constant existence of this vein explains in some degree a rather frequent variety in the arteries of the thyroid gland, viz., the existence of a middle thyroid artery given off by the common carotid. Not unfrequently there are two middle thyroid veins on each side. These, as well as all the other thyroid veins, are much enlarged in goître

The Veins of the Diploë.

To complete the description of the vessels of the head, it only remains for me to notice the *diploic veins*, or the proper veins of the bones of the cranium. They were first described by M. Dupuytren, in his inaugural thesis, under the name of *venous canals of the bones:* they were afterward figured by M. Chaussier (*Traité de l'Encéphale*), and, together with their principal varieties, they have lately been represented with uncommon accuracy by M. Breschet, in his admirable work upon the veins.

In the substance of the cranial bones there are found ramified venous canals, which are occupied by veins, having only their internal membrane, the bony canals themselves serving for an external coat. These venous canals are not exclusively confined to the bones of the cranium: they exist in all spongy bones, and even in compact bones; but, while the canals are found in the entire substance of spongy bones, in the compact part of the long bones they are situated near the medullary canal.

The venous canals of the bones of the cranium vary much in their size, and in the extent to which they are distributed: they are independent of each other as long as the cranial bones remain distinct and separable; but they almost always communicate when, in the progress of age, those bones become united together. They get larger and larger as life advances, and their size is indirectly proportioned to the number of their ramifications: they sometimes present ampullæ or dilatations, and at other times are suddenly interrupted, and terminate in culs-de-sac, reappearing again farther on, or ceasing altogether: these peculiarities depend upon the venous canal opening at different points into the middle meningeal veins. Moreover, these venous canals communicate by a number of orifices of different sizes, either in the interior of the cranium with the meningeal veins, and with the sinuses of the dura mater, or on the exterior with the veins which lie in contact with the bones of the scull.

In some heads of old subjects, these canals are found blended with the furrows for the branches of the meningeal arteries; those furrows themselves present some large foramina, which open into the cranium in various places.

In new-born infants there are no venous canals, properly so called; but the whole substance of the bones is traversed by a venous network, which may be seen when its constituent veins are naturally injected with blood, or when they have been filled with mercury, by which as delicate a network of vessels can be shown in the diploë as in injections of the soft parts. At this period all the cells of the bones are filled with venous blood.

On the roof of the cranium the canals of the diploë are divided into the *frontal*, *temporal*, *parietal*, and *occipital*.

The *frontal diploic canals* are two in number, one on the right, the other on the left side: they commence by numerous ramifications upon the upper part of the frontal bones, increase in size as they approach the lower part of the roof of the scull, communicate with each other by transverse branches, and also with the periosteal or the meningeal veins, open externally by vascular foramina, and then enter the supra-orbital and frontal veins.

The *temporo-parietal diploic canals* are divided into anterior and posterior: they correspond to the furrows which contain the ramifications of the meningeal artery, and open into those furrows by a great number of foramina, which become very distinct in advanced life: they also communicate with the deep temporal veins on the exterior of the scull.

The *occipital diploic canals*, two in number, a right and a left, communicate with each other by a great number of branches, and open below into the occipital veins.

Summary of the Distribution of the Veins of the Head.

Circulation in the Brain.—Corresponding to two of the arterial trunks, the common carotids, which convey blood to the head and neck, there are six veins, to return it back to the heart from the same parts, viz., the two internal, the two external, and the two anterior jugulars. This arrangement tends to prevent interruption of the venous circulation in the head, which, from so many causes, is liable to be disturbed. The external and anterior jugular veins belong to the sub-cutaneous venous system, and may be regarded as supplementary veins which have no corresponding arteries, and which would be sufficient of themselves to carry on the venous circulation; and as the veins of the right and left sides communicate very freely with each other, it follows that one of them would suffice to return the blood from the head. It will be seen hereafter, when describing the veins of the spine, that the obliteration of all the six jugular veins would not of necessity be followed by interruption of the venous circulation in the cranium. Lastly, it is important to observe, that the external and anterior jugulars open into the sub-clavian vein, while the internal jugular joins the inner end of the sub-clavian, to form the brachio-cephalic vein.

We have seen that the lower part of the internal jugular vein represents the common carotid, and the upper part of it the internal carotid; and that the external carotid is represented by all the veins of the face and neck, which open into the internal jugular either by a common trunk, or by several distinct branches.

The cerebral venous system is remarkable for the extreme thinness of the parietes of the veins upon the brain, and for the existence of the sinuses, which take the place of the venous trunks, and differ so much in their distribution from the arteries. The cerebral veins are divided into the *ventricular veins*, which go to form the venæ Galeni, and the *superficial veins of the brain*. All of them run towards the sinuses, in which they terminate in succession like the barbs of a feather upon the common shaft, but do not acquire a great size. From the absence of valves at their orifices into the sinuses, the blood may regurgitate into them. The presence of the spongy areolar tissue at the orifices of these veins, together with their oblique course through the walls of the sinus, must diminish this regurgitation: the communication of the cerebral veins with each other, and the continuity of the several sinuses, explain the varied means contrived for carrying on the cerebral circulation, which can only be interrupted by obliteration of the lateral sinuses.

Lastly, the position of the principal sinuses opposite the fissures between the great divisions of the encephalon, and the resisting nature of the walls of the sinuses themselves, prevent the fatal effects which might otherwise ensue from compression produced by obstruction of the venous circulation.

Circulation in the Parietes of the Cranium.—In the parietes of the cranium we find the veins of the dura mater, the veins of the diploë, the periosteal veins, and the veins of the hairy scalp. The numerous communications existing between these four systems of veins, and the direct communications established between the sinuses of the dura mater and the veins on the exterior of the scull, are worthy of particular attention. I would observe that the principal veins of the scalp, like the arteries of the same part, are situated between the skin and the epicranial aponeurosis. I have ascertained the existence of free and frequent anastomoses among these veins. As at the back of the cranium there is a very free communication between the occipital vein and the lateral sinus by means of a large vein, so, also, along the superior longitudinal groove, and opposite the sutures upon the base of the scull (through most of the foramina found in that

situation), an uninterrupted communication is established between the veins within and those outside the cranium.

Venous Circulation of the Face.—All the veins of the face and of the parietes of the cranium end in two principal trunks, the facial and the temporal. The facial vein corresponds to a part of the internal maxillary artery, to a part of the ophthalmic artery, and to the facial artery properly so called. One of the most remarkable circumstances connected with the distribution of the facial vein is the communication between it and the cavernous sinus, established at the inner angle of the orbit by means of the ophthalmic vein, so that the veins on the inside and on the outside of the cranium are most intimately connected.*

The temporal vein represents the temporal artery, a part of the internal maxillary artery, and the upper part of the external carotid, and returns the blood from the entire side of the head.

With regard to the veins of the tongue, we should remark the existence of two submucous veins, corresponding to the sub-cutaneous veins in the limbs, and intended to return the blood, instead of the deep veins of the tongue, during the contractions of that organ.

The size of the superior middle thyroid veins, their number, which exceeds that of the arteries, and their free anastomoses with the inferior thyroid veins, render them an important medium of circulation when the passage of the blood from the head is obstructed, and, at the same time, a *diverticulum* in great impediments to the circulation.

The irregularity which exists in the relative size of the internal, external, and anterior jugular veins, and also in the distribution of the veins of the head between these three trunks, proves that, in the venous as well as in the arterial system, the origin or termination of the vessels is of little importance, and that, after the venous system of any part is once formed, it matters but little with which of the great vascular trunks it is connected.

Lastly, the free communications which exist between all the preceding veins afford sufficient evidence that but little interest need be attached to their termination in one or another of the principal venous trunks.

The Deep Veins of the Upper Extremity.

The *veins of the upper extremity* are divided into the deep and the superficial or subcutaneous.

The Palmar, Radial, Ulnar, Brachial, and Axillary Veins.

The *deep veins of the upper extremity* exactly follow the course of the arteries, form their venæ comites, and take the same names: there are almost always two to each artery. The large venous trunks alone form exceptions to this rule. Thus, there are two *superficial* and two *deep palmar* veins; two *deep radial* and two *deep ulnar* veins; we also find two *brachial* veins; but there is only one *axillary* and one *sub-clavian* vein. All these venæ comites receive branches formed by the union of still smaller ones, which are themselves the venæ comites of the ramifications of the arteries, there being two veins with each small artery. The sub-clavian vein, however, is an exception to this, for it does not receive all the veins which correspond to the branches of the sub-clavian artery; while, on the other hand, it receives other veins that are totally unconnected with the distribution of that artery. I ought to allude, in this place, to a mode of termination of the collateral veins, which is frequently observed, especially in the brachial vein. The circumflex veins, for example, instead of entering the brachial vein directly, terminate in a collateral branch, which runs parallel to the brachial vein, like a canal running alongside a river, and communicates with that vein above and below. Several large veins have these collateral canals, which establish a communication between different points of their length. Thus, I have seen a venous trunk proceed from the external jugular, descend through the brachial plexus of nerves, and enter the lower part of the axillary vein.

The deep veins, moreover, communicate freely and frequently with the superficial veins. They are also provided with valves, like the superficial veins, and, it appears, even with a greater number: an injection thrown from the heart towards the extremities will not enter more readily into one than into the other set. We always find two valves at the mouth of a small vein where it opens into the larger trunk; and it is a remarkable fact that, while the valves situated in the course of the veins are sometimes passed by the injection, those which are placed at the mouths of the small veins are scarcely ever overcome.

The Sub-clavian Vein.

The term *sub-clavian* is generally given to all that portion of the brachial venous trunk

* The study of these anastomoses ought to lead us again to have recourse to those local venesections which have fallen into disuse since the discovery of the circulation; and it will enable us to determine, on anatomical grounds, the proper places at which they should be performed. Thus, it appears to me that we might advantageously introduce into practice bleeding from the angular vein in diseases of the eye; from over the mastoid region, and the point which corresponds to the junction of the longitudinal with the lambdoidal suture, in cerebral affections; and bleeding from the ranine vein in diseases of the pharynx.

which extends from the vena cava superior to the scaleni muscles; but this vein may be described more naturally, as being limited internally by the brachio-cephalic vein, or, rather, by the junction of the internal jugular vein with the venous trunk of the upper extremity, and externally by the clavicle, or, rather, by the costo-coracoid, or sub-clavian aponeurosis. If the sub-clavian veins be thus defined, they will be of equal length on both sides; and the left vein, and even the right vein also, will be shorter than the corresponding artery.

The *direction* of the sub-clavian veins differs much from that of the arteries: we have seen that the sub-clavian arteries describe a curve over the apex of the lung, with its concavity turned downward; the sub-clavian veins, on the contrary, proceed directly outward as far as the first rib, over which they bend, so that they resemble the cord of the arc described by the sub-clavian artery. We have seen, also, that the inferior thyroid vein, the internal mammary, the vertebral, the supra-scapular, the posterior scapular, the deep cervical, and the left superior intercostal veins, enter not into the sub-clavian, but either into the superior vena cava, or into the brachio-cephalic vein. The right superior intercostal vein, when it exists, that is to say, when the branches which should form it do not terminate separately in the vena azygos, is the only one of the veins corresponding to the branches of the sub-clavian artery which opens into the sub-clavian vein.

The external jugular, the anterior jugular, and a small branch from the cephalic vein of the arm, also terminate in the sub-clavian vein. It would therefore, in some respects, be proper to describe the external and anterior jugulars in connexion with the sub-clavian vein, instead of with the internal jugular. I would remark, that the external and anterior jugulars frequently terminate, not in the sub-clavian vein, but at the point where it ends in the brachio-cephalic vein, in front of the internal jugular.

Relations.—In front of the sub-clavian vein is situated the clavicle, which is separated from the vein only by the sub-clavian muscle, so that this vessel may be wounded in fractures of the clavicle: a very dense fibrous sheath binds it down to the sub-clavius muscle; and it perforates the costo-coracoid or sub-clavian aponeurosis, which adheres to it, and keeps it open when cut across; *behind* the vein is the sub-clavian artery, from which it is separated, towards the inner part, by the scalenus anticus; *below*, it is in relation with the pleura and with the first rib, on which there is a corresponding but slight depression; *above*, it is covered by the cervical fascia, which separates it from the skin: a considerable swelling is often seen in this region when the venous circulation is obstructed.

The Superficial or Sub-cutaneous Veins of the Upper Extremity.

The *sub-cutaneous veins of the upper extremity* belong essentially to the skin and to the subjacent adipose tissue, since all the branches from the muscles enter the deep veins. The superficial are larger than the deep veins, with which they communicate freely at a great number of points; and it may be remarked, that the size of the one set of vessels is always inversely proportioned to that of the other set. We proceed to describe them in succession in the hand, the forearm, and the arm.

The Superficial Veins of the Hand.

All the largest veins of the hand are situated upon its dorsal aspect; and it is worthy of notice, that the largest arteries, on the contrary, occupy the palm of the hand. If the superficial veins had existed on the palmar aspect, the venous circulation would have been impeded whenever the hand was used in prehension. Entering into the large sub-cutaneous network of veins situated upon the back of the hand are several branches, which constitute the *superficial, external, and internal collateral* veins of each finger; they occupy the outer and inner borders of the dorsal surface of the fingers, and communicate frequently on the dorsal surface of each phalanx and around the phalangeal articulations, but not upon the articulations themselves.

Opposite the lower part of each interosseous space, these collateral veins unite at an acute angle, just as the digital arteries bifurcate at the same point. All the superficial digital veins ascend vertically between the metacarpo-phalangeal articulations, which they seem to avoid, and then enter into the convexity of a very irregular venous arch, which is formed by a series of loops, at each of the junctions of which one of the digital veins is seen to terminate.

From the concavity of this irregular arch, which is turned upward, are given off a greater or less number of ascending branches, which are sometimes formed directly by the junction of the digital veins, without the intervention of an arch. Among these branches, we should especially notice the external branch, which is situated nearest to the first metacarpal bone, and is called the *cephalic vein of the thumb;* also the innermost branch, which corresponds to the fifth metacarpal bone, and, for some reason not very well known, has been named the *vena salvatella.*

The Superficial Veins of the Forearm.

The superficial veins are much more numerous on the anterior than on the posterior

aspect of the forearm. We find there the radial vein or veins, the ulnar vein, and the median vein.

The *superficial radial vein* (*r*, in the representation of the superficial nerves of the arm) is the continuation of the cephalic vein of the thumb; it is situated along the outer side of the carpus and of the radius, and it soon unites with some branches from the vena salvatella, or with the salvatella itself. The superficial radial vein often divides into several branches, which are joined by others from the venous arch at the back of the hand. There are sometimes two superficial radial veins. The vein or veins having reached the middle of the forearm, turn forward upon the outer border of the radius, and then continue to ascend vertically along the outer side of the anterior surface of the forearm, up to the bend of the elbow.

The *ulnar vein* (*u*) commences partly from the vena salvatella, and another vein on the dorsal region of the forearm, and partly from some branches which arise from the lower part of the back of the forearm, and even from some small veins proceeding from the thenar and hypothenar eminences.

The branches which arise from the vena salvatella and the back of the wrist pass forward; the other branches run backward; the common trunk or trunks resulting from their union are directed at first vertically upward, parallel with the superficial radial vein, then somewhat obliquely forward, to anastomose with the median basilic vein, above the bend of the elbow. When there is a second or *posterior ulnar vein*, it ends in the basilic higher up, or else it anastomoses with the anterior ulnar vein.

Between the anterior radial and ulnar veins we find the *common median* or *median vein* (*m*), formed by the anterior veins of the carpus and forearm. There may be more than one median vein, and it is not unfrequently wanting, in which case its place is supplied by a venous network, the branches from which enter separately into the radial and ulnar veins. In some cases its place is supplied by an additional radial vein, and at other times by the deep veins.

The Superficial Veins at the Elbow.

At the elbow all the veins are on the anterior aspect. The most common arrangement is the following: on the outer side we find the upper portion of the radial vein or veins; on the inner side, the upper portion of the ulnar vein or veins, which pass in front of the internal condyle of the humerus; between the radial and ulnar veins is the median, which divides into two branches: one external (*a*), which unites with the radial to form the cephalic vein (*c*), and is called the *median cephalic*; the other internal (*e*), generally smaller, but more superficial than the preceding, which unites with the ulnar to form the basilic vein (*b*), and is called the *median basilic*.

Several varieties are observed in the arrangement of the veins of the elbow; sometimes the common median vein is wanting; but then its cephalic and basilic branches are given off by the radial, and the cephalic vein is almost always very small. In other cases we only find two veins at the bend of the elbow, viz., the radial and the ulnar, which are directly continuous with the cephalic and basilic. I once saw the common median vein replaced by the anterior radial, and by a branch from one of the deep ulnar veins.

The Superficial Veins in the Arm.

In the arm there are only two superficial veins, an external, named the *cephalic* vein, and an internal or *basilic*.

The *cephalic vein* (*c*) is formed by the junction of the radial with the median cephalic vein, which junction may occur at very different heights. It ascends vertically along the outer border of the biceps; then, running a little inward, it gains the furrow between the deltoid and pectoralis major, passes over the summit of the coracoid process, above or in front of which it curves backward, so as to enter the axillary vein immediately below the clavicle. From this curve the cephalic vein gives off a branch, which passes in front of the clavicle, crosses at right angles over the middle of that bone, and enters the sub-clavian vein. Not unfrequently the cephalic vein is replaced by a very small branch.

The internal vein of the arm, which is called the *basilic vein* (*b*), is generally larger than the cephalic. It is formed by the junction of the ulnar with the median basilic vein, passes at first obliquely backward, and then vertically upward, in front of the internal intermuscular septum, and enters either the brachial or the axillary vein.

General Remarks upon the Superficial Veins of the Upper Extremity.

From the preceding description, it follows that the cephalic vein forms the continuation of the radial, which is itself the continuation of the cephalic vein of the thumb, and that the basilic is a prolongation of the ulnar, which is a continuation of the vena salvatella. The median vein, placed as it is between the radial and ulnar veins, bifurcates so as to terminate equally in the two latter veins, and establishes a free anastomosis between them.

The anastomoses of the several sub-cutaneous veins together are very numerous, and enable them mutually to supply the place of each other. The anastomoses between the sub-cutaneous and deep veins are not less numerous.

Thus, the superficial collateral veins of the fingers communicate with the deep collateral veins: communications exist between the superficial and deep veins of the carpus; very large communications exist between the two sets of vessels at the bend of the elbow, so that, in fact, they are continuous with each other; thus, the superficial radial vein is sometimes continuous with one of the deep radials, and the median, as it divides into the median basilic and median cephalic, occasionally sends a very large branch to the brachial. In one case, where the median vein was wanting, I found that the ulnar, the deep interosseous, and the deep radial veins, formed a plexus, which gave off two branches, an external to the cephalic, and an internal, which formed the deep brachial vein. The superficial ulnar veins often communicate freely with the deep ulnar, beneath the muscles attached to the internal condyle.

Along the arm, the basilic vein communicates with one of the brachial veins by several transverse branches. Not unfrequently the basilic vein communicates with the brachial by a very delicate branch, which forms a lateral canal.

Valves.—The valves are more numerous in the deep than in the superficial veins; they increase in number as we approach the upper part of the arm, and are much more numerous in the basilic than in the cephalic vein. There are three in that part of the cephalic which corresponds to the furrow between the deltoid and the pectoralis major. There is one at the opening of the cephalic into the axillary; another at the opening of the basilic into the brachial; all the small veins which enter the cephalic and basilic, as well as those which terminate in the deep veins, are also provided at their openings with valves, which prevent the regurgitation of the blood during life, and the passage of an injection from the heart towards the extremities.

General Relations.—The sub-cutaneous veins are separated from the skin by the *superficial fascia*, and by the layer of fat above it. The median basilic is the only exception, for it is in contact with the skin, at least in the majority of subjects.

The *sub-cutaneous veins* must be carefully distinguished from the *cutaneous veins*, properly so called, which are in contact with the true skin, or even ramify in its substance, and which are sometimes of considerable size, especially in the neighbourhood of certain tumours.

From the relation of the median basilic vein with the brachial artery, over which it crosses at a very acute angle, and from which it is separated only by the fibrous expansion from the tendon of the biceps, it follows, that in emaciated persons the vein is almost in contact with the artery; so that, in bleeding from the median basilic, if the vein be perforated quite through, the artery may be wounded. The practical rules to be derived from this anatomical fact are, in the first place, to avoid bleeding in the median basilic as much as possible, and whenever it must be chosen, to open it either below or above the point where it crosses over the artery.

In the description of the lymphatics and nerves of the arm, I shall point out their relations with the superficial veins. I may now state, however, that the musculo-cutaneous nerve passes behind the median cephalic vein, and that the internal cutaneous divides into several branches, some of which pass in front, and others behind the median basilic vein.

THE INFERIOR OR ASCENDING VENA CAVA AND ITS BRANCHES.

The Inferior Vena Cava — the Lumbar or Vertebro-lumbar Veins — the Renal — the Middle Supra-renal—the Spermatic and Ovarian—the Inferior Phrenic.—The Portal System of Veins—the Branches of Origin of the Vena Portæ—the Vena Portæ—the Hepatic Veins. —The Common Iliacs — the Internal Iliac — the Hemorrhoidal Veins and Plexuses — the Pelvic Veins and Plexuses in the Male and in the Female.—The Deep Veins of the Lower Extremity — the Plantar, Posterior, Tibial, Peroneal, Dorsal, Anterior Tibial, and Popliteal—the Femoral — the External Iliac. — The Superficial Veins of the Lower Extremity —the Internal Saphenous—the External Saphenous.

The *vena cava inferior* or *ascendens*, or the *abdominal vena cava* (*l*, *fig.* 222), is the large venous trunk which returns the blood from all the parts below the diaphragm to the heart.

It is formed below by the junction of the two common iliac veins (*n n*), opposite the intervertebral substance between the fourth and fifth lumbar vertebræ; it passes vertically upward, and, having reached the lower surface of the liver, inclines a little towards the right side, to gain the groove formed for it in the posterior border of that organ. At the upper end of that groove the vena cava inferior perforates the tendinous opening in the diaphragm, and also the fibrous layer of the pericardium, which is, as it were, blended with the cordiform tendon at this point; the vein then curves suddenly to the left, and opens (*r*, *fig.* 192) horizontally into the posterior inferior part of the right auricle.

It is larger than the vena cava superior, but is not of uniform caliber throughout; for example, it increases in size in a marked degree immediately above the renal veins. The vena cava inferior presents also a second still larger dilatation opposite the liver, where it is joined by the hepatic veins; in comparison with its diameter at that point, the vena cava inferior appears to be slightly contracted as it passes through the diaphragm.

Relations.—The inferior cava is in contact with the anterior surface of the vertebral column, and runs throughout the whole of its extent along the right side of the aorta; it inclines somewhat obliquely to the right as it is about to pass into the groove on the liver. In front it is covered by the peritoneum, the third portion of the duodenum, the pancreas, the vena portæ, which crosses it at a very acute angle, and at its upper part by the liver, which forms a semi-canal, or a complete canal for it.

It adheres closely to the margins of the tendinous opening in the diaphragm, and to the fibrous layer of the pericardium, as if its outer coat were blended with those structures.

The serous layer of the pericardium covers the vein, but the fibrous layer does not form a sheath for it. The relations of the inferior cava with the liver account for the erroneous notion of some old anatomists, that this organ was the centre from which all the veins of the body proceeded.

There is no valve in the inferior cava; but at its termination we find the Eustachian valve, which has been already described with the heart.

Branches of Origin.—We have stated that the junction of the common iliac veins constitutes the origin of the inferior cava. It is very rare to find these veins uniting above the intervertebral disc between the fourth and fifth lumbar vertebræ; but in some few cases the junction has been observed to take place opposite the renal veins.

Collateral Branches.—The vena cava inferior receives all the veins corresponding to the branches of the abdominal aorta, excepting the veins from the alimentary canal and its appendages, of which it only receives those from the liver, viz., the hepatic veins. All the abdominal veins which do not open directly into the inferior cava unite to form a large venous trunk, called the *vena portæ*. Thus, the vena cava inferior receives the renal, the spermatic or ovarian, the lumbar, the supra-renal, and the inferior phrenic veins; while the superior and inferior mesenteric, the splenic, the pancreatic, and the gastric veins open into the vena portæ. It may still be said, however, that the vena cava inferior receives all the abdominal veins; for, in fact, the veins of the portal system terminate in the vena cava through the medium of the hepatic veins. The portal system is, therefore, an appendage to the inferior cava. For this reason, and also for the sake of economizing subjects, I shall not describe the vena portæ and its branches until I have noticed the collateral veins of the vena cava inferior.

The Lumbar or Vertebro-lumbar Veins.

The *vertebro-lumbar veins* are three or four on each side, and correspond to the arteries of the same name; they have two branches of origin: an *external* or *abdominal* branch, which represents the intercostal veins, and a *posterior* or *dorso-spinal* branch, which is itself formed by the union of two other branches; one *muscular* or *cutaneous*, which commences in the muscles and integuments, and the other a proper spinal branch, which forms part of the rachidian venous system, to be hereafter described.

By the junction of these two branches a lumbar vein is formed, which runs forward and inward in the groove on the body of the corresponding lumbar vertebra, and enters the vena cava at a right angle. The left lumbar veins are longer than the right, in consequence of the vena cava being situated towards the right side of the vertebral column: they pass under the aorta.

The Renal Veins.

The renal veins are remarkable for their size, and occasion a great increase in the diameter of the inferior cava, above the point where they open into it; they are of unequal size on the two sides, and are unequal in length, on account of the vena cava being placed towards the right side of the vertebral column, and, therefore, nearer the right than the left kidney: they also run more obliquely on the right side, on account of the right kidney being generally situated lower down than the left.

These veins commence in the substance of the kidney by a number of minute divisions, which unite into small, and then into larger branches, gain the surface of the organ, and are collected into a single trunk, either in the hilus or at some distance from it. The trunk of each renal vein is always placed in front of the corresponding artery. The left renal vein passes in front of the aorta. We sometimes find one division of the left renal vein in front of the aorta, and another behind it.

Plurality of the renal vein appears to me less common than an excess in the number of the arteries.

The renal veins receive the *inferior supra-renal* and several veins from the surrounding

adipose tissue. The left renal vein is almost always joined by the *spermatic* or *ovarian vein* of that side.

In some cases we find several communicating branches between the left renal vein and the superior mesenteric, which is one of the branches of the portal system.

The Middle Supra-renal Veins.

The *middle supra-renal* or *capsular veins*, which are often numerous and very large, are found on the surface of the supra-renal capsules, while the arteries enter into their substance from every point. The venous trunks run in the grooves seen upon the surface of the organ. The left middle supra-renal vein almost always enters the renal vein of the same side; the right vein generally opens into the vena cava inferior.

The Spermatic or Ovarian Veins.

The *spermatic veins* commence in the interior of the testicle, where they form a great number of those filaments which traverse the proper substance of the gland: they all terminate in branches, which are applied to the inner surface of the tunica albuginea, and are bound down to it by a thin layer of fibrous tissue, a disposition somewhat resembling that of the sinuses of the dura mater. The spermatic veins perforate the tunica albuginea on the inner side of the epididymis, not opposite that body. They are soon joined by the veins of the *epididymis*, so as to form a plexus, which communicates with the dorsal veins of the penis, and with the external and internal pudic veins. The spermatic veins soon unite into five or six trunks, which pass upward in front of the vas deferens, and, together with that canal and the spermatic artery, enter into the formation of the spermatic cord. These veins are tortuous; they divide, and anastomose so as to form the *spermatic venous plexus*, which is often the seat of varicose dilatations. The veins ascend through the inguinal ring and canal, and having reached the interior of the pelvis, they leave the vas deferens, accompany the corresponding spermatic artery along the psoas muscle, and terminate either in the renal vein, or in the inferior vena cava of their own side.

In some cases the right spermatic vein opens both into the renal vein and the inferior cava. When there are two veins on one side, they communicate with each other by a great number of transverse branches, and, before terminating, unite into a single trunk.

The name *plexus pampiniformis* is given to a plexus generally formed by the spermatic veins before their termination: this plexus is more frequently found on the left than on the right side, according to the observations of Meckel.

The spermatic veins sometimes communicate with some branches of the portal system.

The left spermatic vein passes under the sigmoid flexure of the colon, which may perhaps account for the greater frequency of varicocele on the left side.

The *ovarian veins* accompany the arteries of the same name: they commence by several sets of branches, viz., *uterine* branches, which communicate very freely with the uterine sinuses; *ovarian* branches, properly so called; branches from the *round ligaments*; and, lastly, some from the *Fallopian tubes*. All these unite within the substance of the broad ligaments, and pass vertically upward, without being at all tortuous: in some cases they form a *plexus pampiniformis*.

The ovarian veins, like the uterine veins, become much enlarged during pregnancy.

The Inferior Phrenic Veins.

These exactly follow the course of the inferior phrenic arteries, to each of which there are two veins.

The *hepatic veins* do not in any way correspond to the artery of that name; they form a separate system, or, rather, they are connected with the portal venous system, of which they may be regarded as an appendage.

The Portal System of Veins.

The system of the *vena portæ* (*vena portarum*), or the portal system, constitutes a special venous apparatus, appended to the general venous system, and representing by itself a complete circulatory tree, having its roots, trunk, and branches. The first, or venous portion of this system of veins, is arranged like the veins of the other parts of the body, and has its roots of origin in the spleen and pancreas, and in the sub-diaphragmatic portion of the alimentary canal; while the second, or arterial portion, sends its branches, like those of an artery, into the interior of the liver.

The hepatic veins, which perform the functions of ordinary veins in reference to the second or arterial portion of the vena portæ, connect the system of the vena portæ with the general venous system.

The Branches of Origin of the Vena Portæ.

The branches of origin of the vena portæ (*i*, *fig.* 222) consist of all the veins which return the blood from the sub-diaphragmatic portion of the alimentary canal, and also from the spleen and pancreas. They correspond to the branches of the cœliac axis,

with the exception of the hepatic artery; they unite into three trunks, the *great mesenteric* (*a*), *small mesenteric* (*b*), and *splenic* (*c*) *veins*.

These veins are arranged like venæ comites to the corresponding arteries.

Fig. 222.

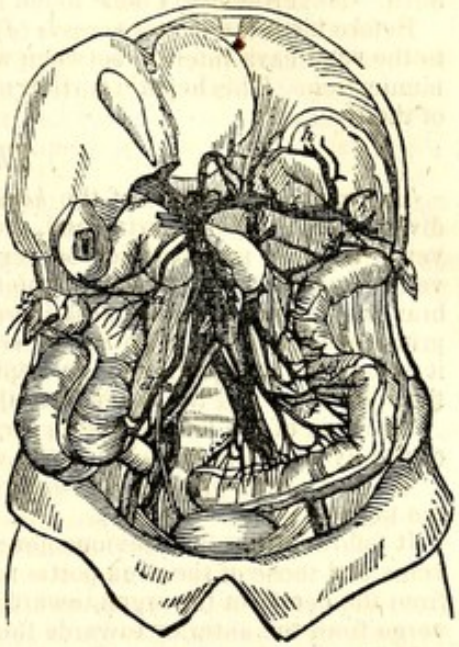

The Great and Small Mesenteric Veins.—The *intestinal* or *mesenteric veins* commence just as the arteries terminate, by two layers of vessels, viz., a sub-serous layer, the vessels of which ramify beneath the peritoneum, and a deep layer, formed by the vessels of the coats of the intestinal canal. These small vessels unite into anastomotic meshes, which always lie subjacent to the arterial network, and which terminate in larger branches, and thus constitute a series of veins corresponding to the arteries of the intestine. The right *colic veins* (*d d*) and the *veins of the small intestine* (shown cut short at *e*) terminate, the one in the right and the other in the left side of the *superior mesenteric* or *great mesaraic vein* (*a*): this vein, in the early periods of intra-uterine life, receives the *omphalo-mesenteric vein*, a branch which corresponds to the omphalo-mesenteric artery, and commences upon the vesicula umbilicalis; the artery and the vein disappear about the third month of utero-gestation, but the vesicle remains for a longer period. On the other hand, the *left colic veins* (*f*) enter the *inferior mesenteric* or *small mesaraic vein* (*b*): this vessel forms the continuation of the *superior hemorrhoidal veins* (*g*), which communicate very freely with the middle and inferior hemorrhoidal branches of the internal iliac vein.

The *splenic vein* (*c*), which is proportionally larger than the artery, arises in the cells of the spleen by a great number of roots, which gradually unite in the hilus of that organ, and form the same number of branches as there are arteries, each coming from a distinct compartment of the organ. All these branches soon unite into a single trunk, which passes across to the right side behind the pancreas, and, therefore, behind the splenic artery, which it accompanies without being tortuous: it is one of the branches immediately concerned in forming the trunk of the vena portæ. During its course, the splenic vein receives the venous *vasa brevia* (*h h*) from the stomach.

The inferior mesenteric vein opens into the splenic; so that there are only two venous trunks, the union of which constitutes the vena portæ, viz., the splenic and the great or superior mesenteric.

The Vena Portæ.

The trunk of the *vena portæ* (*i*) is formed by the union of the splenic and superior mesenteric veins at an acute angle, behind the right extremity of the pancreas, in front of the vertebral column, and to the left of the vena cava inferior. The vena portæ is larger than either of its two branches of origin, but is smaller than the two taken together. It passes obliquely upward and to the right side; and, after running for about four inches, reaches the left extremity of the transverse fissure of the liver, where it terminates by bifurcating. The following are its relations during its course: anteriorly it is covered by the head of the pancreas, the second portion of the duodenum, the hepatic artery, the biliary ducts, and the lymphatics of the liver, and also by some branches from the hepatic plexus of nerves; posteriorly it is covered by that portion of peritoneum which dips behind the vessels of the liver into the foramen of Winslow, to line the sac of the great omentum. By this foramen it is separated from the inferior vena cava, the direction of which it crosses at a very acute angle.

The two branches into which the vena portæ divides in the transverse fissure of the liver separate so widely from each other, that they seem to form a trunk, at right angles to which the vena portæ itself is attached. Some anatomists apply the term *sinus of the vena portæ* to that portion of the vein which is situated in the transverse fissure; that part of the vein which adheres to the liver is more commonly called the *hepatic* portion of the vena portæ, to distinguish it from the free and floating part, which is named the abdominal portion.

The two divisions of the vena portæ pass horizontally each towards the corresponding lobe of the liver; they soon divide and subdivide into diverging branches, which supply all the granules or lobules of the liver. The branches of the vena portæ are accompanied by the ramifications of the hepatic artery and biliary ducts. The capsule of Glisson, or the fibrous coat of the liver, is reflected upon them, and forms a common sheath for them. (See LIVER.)

Before birth, the hepatic portion (*p*, *fig.* 164) of the vena portæ receives, besides the

abdominal portion of the same vein, the *umbilical vein* (*u*), which is obliterated soon after birth. Nevertheless, I once found it perfectly permeable in an adult.*

Before birth the *ductus venosus* (*d*) extends from the hepatic portion of the portal vein to the vena cava inferior, between which and the vena portæ it establishes a direct communication. This hepatic portion might, therefore, be named the confluence of the veins of the liver.

The Hepatic Veins.

The capillary radicles of the *hepatic* or *supra-hepatic veins* commence in the capillary divisions of the vena portæ, and, gradually uniting into larger and larger branches, converge towards the posterior border of the liver, or, rather, towards the fissure for the vena cava inferior, at which point they terminate by an indefinite number of small branches, named the *small hepatic veins*, which open all along the fissure; and also by two principal trunks, the *great hepatic veins*, which end in the vena cava immediately before it passes into the opening in the diaphragm. One of these great hepatic veins comes from the right lobe, and the other from the left lobe of the liver.

The vein of the left side often receives a great number of branches from the right lobe of the liver, and is larger than the vein of the right side.

The vena cava inferior is always dilated into a large ampulla opposite the openings of the hepatic veins.

It follows, from the previous description, that, in the liver, the branches of the hepatic veins and those of the vena portæ run directly across each other, since the latter diverge from the centre of the organ towards its right and left extremities, while the former converge from the anterior towards the posterior border.

Moreover, the branches of the hepatic veins are unaccompanied by other vessels, and are in direct contact with the tissue of the liver; while those of the vena portæ are separated from it by the capsule of Glisson, and are accompanied by the ramifications of the artery, the nerves, and the hepatic ducts.

I shall farther remark, that although the hepatic veins gradually unite, like other veins, into branches, which decrease in number, but increase in size, they most of them receive besides, during their course, a multitude of capillary vessels, the inter-lobular hepatic veins, from the neighbouring lobules; so that their internal surface is perforated with innumerable foramina.

The cribriform structure of their internal surface is therefore a peculiar characteristic of all the hepatic veins [except the very large ones], and enables us always to distinguish them from the branches of the vena portæ.

Lastly, the capillary communication between the extremities of the vena portæ and hepatic veins is extremely free, as may be shown even by very coarse injections.

All the veins of the portal system are without valves,† and they can therefore be injected with the greatest ease from the trunks towards the extremities. An injection thrown in towards the intestine penetrates very readily into the interior of the alimentary canal, so that the minute branches of the vena portæ appear to open at the apex of each villus. This can be made evident by throwing mercury into the vena portæ, and then forcing it on by an ordinary injection; drops of the mercury will then be seen in the open mouth of each villus.‡

The system of the vena portæ is not so completely isolated from the general venous system as is commonly stated. It always communicates with branches of the internal iliac veins by means of the middle hemorrhoidal veins, and communicating branches with the renal veins have also been noticed; and hence injections of the vena cava inferior always enter in a greater or less degree into the veins of the portal system.

The Common Iliac Veins.

The *common iliac veins* (*n n, fig.* 222) correspond exactly to the arteries of the same name; they commence opposite the sacro-vertebral articulation by the junction of the internal and external iliac veins, and terminate by uniting at an acute angle to form the vena cava inferior or ascendens, the point of union being opposite the articulation of the fourth and fifth lumbar vertebræ, to the right side of, and a little below, the bifurcation of the aorta.

The common iliac veins have the same relation to the lower extremities that the brachio-cephalic veins bear to the upper; and as the right brachio-cephalic vein is shorter and more vertical than the left, so also is the right common iliac vein shorter and more vertical than the left.

The relations of the common iliac veins with the corresponding arteries are remarkable, inasmuch as they are placed between these vessels and the vertebral column. The *right* common iliac vein is situated to the outer side of and behind the corresponding ar-

* Anat. Pathol., livraison 17.

† M. Bauer says that he has seen valves in the venous vasa brevia of the stomach; I have never been able to discover them.

‡ [The escape of the mercury is due to rupture of the bloodvessels. In the villi, the minute branches of the vena portæ commence in the capillary network described and figured at page 369.]

tery, and is parallel to it; while the *left* common iliac is situated on the inner side, and behind the corresponding artery, and is covered by its lower part. At the point where the left common iliac vein joins the vena cava inferior, it is also crossed obliquely by the right common iliac artery. It follows, therefore, that the left common illiac vein is covered, and may be compressed by both common iliac arteries, while the right common iliac vein cannot be compressed by either of them, and probably this is partly the reason why anasarca of the left lower extremity is more common than in the right extremity in atonic diseases.

The right common iliac vein receives no collateral branch; the left common iliac (*n*, *fig.* 223) is joined by the middle sacral vein (*h*).

The *middle sacral vein* is situated in the median line, and its size depends upon that of the artery of the same name; it belongs to the rachidian veins, with which it will be described

The Internal Iliac Vein.

The *internal iliac* or *hypogastric vein* exactly represents the internal iliac artery, on the inner side of which it is situated, separated from it, however, by a very thin fibrous layer, which holds it down against the walls of the pelvis.

The internal iliac vein receives the venæ comites of the branches of the internal iliac artery, the umbilical arteries in the fœtus alone being excepted; for their satellite vein, the umbilical vein, which is also peculiar to the fœtus, terminates in the hepatic portion of the vena portæ, as we have already seen.

The internal iliac vein, therefore, receives the blood returned from the parietes of the pelvis, from the organs contained within the cavity of the pelvis, and from the external genitals. There are always two veins for each artery; but the two unite into a single vein at their point of termination in the principal trunk.

The veins belonging to the parietes of the pelvis, viz., the *gluteal*, *obturator*, and *sciatic* veins, are arranged precisely like the corresponding arteries. The *ilio-lumbar* and *lateral sacral veins* (*i*, *fig.* 223) form part of the rachidian system, which will be specially described.

The veins belonging to the genito-urinary organs present a plexiform arrangement both in their trunks and in their roots, which deserves particular attention.

Some of the venous plexuses of the pelvis are found both in the male and female, as the *hemorrhoidal*, while some are peculiar to one or the other sex, as the vesico-prostatic and the plexuses of the penis to the male, and the vaginal and uterine plexuses to the female.

The Hemorrhoidal Veins and Plexuses.

The *hemorrhoidal veins and plexus* form a venous network, surrounding the lower end of the rectum. They are formed by the *superior hemorrhoidal veins*, which form the commencement of the inferior mesenteric, and by the *middle and inferior hemorrhoidal veins*, which are branches of the internal iliac. We ought to notice in particular the sub-mucous venous network near the anus. The plexus formed by it is analogous to that found in all other mucous membranes; its vessels are liable to become varicose, a condition which constitutes the greater number of hemorrhoidal tumours.

The Pelvic Veins and Plexuses in the Male.

Preparation.—Introduce one injection-pipe into the corpus cavernosum, and another into the glans penis, and then push an injection simultaneously into both of them, and also into the crural vein.

The *superficial scrotal veins* terminate partly in the superficial veins of the perinæum, and partly in the external pudic branches of the femoral vein; they communicate with the superficial veins of the under surface of the penis.

The Vesical Veins, or Vesico-prostatic Plexus.—The prostate gland and the neck of the bladder are covered by a very complicated plexus of veins, which become exceedingly developed in chronic inflammation of the bladder; it receives the superficial veins of the penis, and gives off the vesical veins.

This plexus, which communicates with the hemorrhoidal plexus behind, is supported by a very thick fibrous layer, which is continuous with the pelvic fascia, and which limits the degree of dilatation of the veins of the plexus in the same way as the dura mater limits the dilatation of the sinuses contained between its layers.

The Veins and Plexuses of the Penis.—The *veins of the penis* are divided into a *superficial* and *deep* set, the former representing the sub-cutaneous veins of the limbs. They commence in the skin of the prepuce, and run backward along the upper and lower surfaces of that organ. The superior are called the *dorsal veins of the penis;* they communicate freely with each other by large branches; most of them run beneath the arch of the pubes, between it and the corpus cavernosum, passing through some openings or fibrous canals in the sub-pudic ligament, which have the effect of keeping the veins always open; they end by assisting in the formation of the prostatic plexus. These veins communicate freely with the deep veins, especially opposite the junction of the two crura

of the corpus cavernosum: this communication is proved by the fact that the superficial vessels are always filled when the injection is thrown into the deep veins.

The areolar tissue of the corpus cavernosum and that of the corpus spongiosum may be regarded as composed of a venous network or plexus at its maximum of development. Branches proceed from this plexus, which correspond to the divisions of the internal pudic artery, and follow the same course.

These veins, and the vesico-prostatic plexuses, are liable to become varicose; hard earthy concretions, called phlebolites, are also frequently found in them.

The Pelvic Veins and Plexuses in the Female.

The *vesical*, or *vesico-urethral plexus* of the female, is less developed than that of the male, on account of the absence of veins corresponding to the superficial veins of the penis, which are represented by a few branches from the labia majora. This plexus communicates with the veins of the clitoris, and also very freely with the vaginal plexus behind.

The *vaginal plexus* is a vascular network, extremely well developed, especially opposite the orifice of the vulva, which is entirely surrounded by it with several series of circular anastomosing veins: it communicates with the vesical plexus in front, and with the hemorrhoidal plexus behind; so that all the plexuses in the pelvis are involved in the state of turgescence, which accompanies the phenomenon of erection in the female. The radicles of this vaginal plexus commence in the mucous membrane of the vagina, and especially in the erectile tissue surrounding the orifice of that canal; some large veins arise, in particular, from the bulb of the vagina, forming a true erectile apparatus, which we have already described. (See SPLANCHNOLOGY, p. 320.)

The Uterine Plexus.—The veins contained in the substance of the walls of the uterus do not present any trace of the tortuous arrangement of the corresponding arteries. In order to obtain a satisfactory idea of them, they should be studied in a gravid uterus. The uterine veins, like the uterine arteries, are then found along the sides and upper angles of the organ; opening into these veins are found larger venous canals, which run from side to side through the substance of the uterus, and anastomose frequently with each other. These venous canals are called the uterine sinuses, on account of their great size during gestation, and from the dilatations presented by them at the confluence of several secondary veins: they are also entitled to be so named from their structure, which has some analogy with that of the sinuses of the dura mater, inasmuch as only the lining membrane of the veins is prolonged into them; their outer coat is formed by the proper tissue of the uterus, and hence the walls of these veins are contractile. I have stated elsewhere that, in reference to its veins, we may consider the uterus as consisting of an erectile tissue with muscular walls; it is scarcely necessary to add, that these sinuses are unequally developed in different parts of the uterus, and that the point to which the placenta has been attached may be recognised by the greater size of the adjacent uterine sinuses.

The veins contained within the substance of the walls of the uterus do not open into the uterine veins alone; several of them terminate in the ovarian veins, which communicate freely with the uterine, and may, if necessary, supply their place.

The great size acquired by the uterine veins, both in the substance and on the surface of the uterus, proves that the venous apparatus plays an important part in the interstitial development of this organ.

Moreover, the size of the veins and venous plexuses belonging to all the genito-urinary organs, and the essentially venous structure of such organs as are capable of being erected, prove that the venous system performs an essential part in the truly active phenomena of erection. It is partly upon these anatomical and physiological arguments that I have endeavoured to show the active part performed by the veins in all the great phenomena of the economy, such as nutrition, secretion, inflammation, &c.

The pelvic veins are provided with a great number of valves, which prevent injections from passing from the heart towards their extremities; it ought to be remembered, that the venous plexuses of the pelvis establish a very important and very free communication between the veins of the right and left sides of the body.

THE DEEP VEINS OF THE LOWER EXTREMITY.

The veins of the lower extremities, like those of the upper, are divided into the deep veins or venæ comites of the arteries, and the superficial veins.

The Plantar, Posterior Tibial, Peroneal, Dorsal, Anterior Tibial, and Popliteal Veins.

The *external* and *internal plantar* veins unite to form the *posterior tibial*, which accompanies the artery of that name, and soon joins the *peroneal* vein, to constitute the *tibio-peroneal* vein: again, the *anterior tibial vein*, which commences by the *vena dorsalis pedis*, perforates the upper part of the interosseous ligament, joins the tibio-peroneal vein, and in this way forms the *popliteal* vein. Up to this point there are two venæ comites for each artery, one of the veins being placed on each side of the artery, across which they

very frequently send communicating branches. The peroneal veins are generally larger than the posterior tibial, and receive all the muscular veins from the posterior and outer regions of the leg.

Commencing with the popliteal, there is only one vein for the main artery of the limb; but the arteries of the second and third order always have two veins.

The *popliteal vein* is situated in the popliteal space, behind and in contact with the artery. Its coats are remarkably thick, so that when cut across it remains open, and in the dead body has been sometimes mistaken for the artery. Below, and opposite the articulation of the knee, the vein is situated immediately behind the artery; above the joint it is behind, and a little to the outer side.

The popliteal vein receives the large bundles of veins, the sural veins, from the *gastrocnemius* muscle: they are remarkable for the number of their valves; also the *articular* veins, and generally the external saphenous vein. I have seen a small vein having very numerous valves, and being analogous to the collateral venous canals of which I have already spoken, extend from the upper part of the anterior tibial to the middle of the popliteal vein.

The Femoral Vein.

The femoral vein, like the artery of that name, is bounded below by the ring in the tendon of the adductor magnus, and above by the crural arch; it has different relations with the femoral artery in various parts of its course: thus, below, it is on the outer side of the artery; higher up, it is situated behind that vessel; lastly, from the entrance of the vena saphena interna to the crural arch, it is placed to the inner side of the artery, and is in close contact with the posterior part of the opening for the femoral vessels; so that femoral herniæ descend in front of the vein, but not of the artery. The femoral vein is single, like the artery; nevertheless, there are one or two collateral venous canals, which run parallel with the lower half, or lower two thirds of that vein; some communicating branches from the internal saphenous vein, and some mnscular branches, open into these venous canals, which are always abundantly supplied with valves.

The femoral vein receives all the branches corresponding to the divisions of the femoral artery, excepting the external pudic veins and the cutaneous veins of the abdomen, which terminate in the internal saphenous vein.

The great deep vein (*profunda*) opens into the femoral about ten or twelve lines below the crural arch.

The External Iliac Vein.

The *external iliac vein* is bounded below by the femoral arch, and terminates at the upper part of the sacro-iliac symphysis by uniting with the internal iliac vein; it has the same relations as the artery, and is placed behind and to the inner side of that vessel, excepting over the os pubis, where it is exactly to the inner side of the artery. In one case I found the left common iliac receiving the right internal iliac, so that the right external iliac was prolonged into the vena cava.

The external iliac receives the epigastric and the circumflex iliac veins. These two veins are double, but each pair unites into a single trunk, as it is on the point of opening into the external iliac vein.

All the deep veins of the lower extremity, excepting the external iliac, are provided with valves. There are four in the deep femoral, the same number in the popliteal, and many more in the tibial and peroneal veins; the mouths of all the small veins which open into them are provided with a pair of valves.

The Superficial Veins of the Lower Extremity.

The superficial veins of the lower extremity are much less numerous than those of the upper, and all terminate in two trunks, viz., the *internal saphenous vein* and the *external saphenous vein.*

As in the hand, they are all situated upon the dorsal region of the foot. All the collateral veins of the toes enter the convexity of a venous arch, which is more regular and constant than that in the hand, and which is placed on the fore part of the metatarsus. From the inner end of this arch is given off a large branch, named the *internal dorsal vein of the foot*, which is the origin of the internal saphenous vein; the outer extremity also gives off a somewhat smaller branch, called the *external dorsal vein of the foot*, which forms the commencement of the external saphenous vein.

The Internal Saphenous Vein.

The internal or great saphenous vein (*saphena interna*, *s*, in the representation of the superficial nerves of the leg) is a collateral vein of the femoral venous trunk, and is continuous with the *internal* dorsal vein of the *foot*. The last-mentioned vein commences at the inner extremity of the dorsal venous arch of the foot, into which the collateral veins of the great toe open; it runs along the dorsal surface of the first metatarsal bone and the corresponding part of the tarsus, and receives, during its course, a deep branch from the internal plantar vein and all the superficial veins of the internal plantar region,

and particularly the *internal calcaneal vein*, which is sometimes large, and which, in certain cases, does not terminate in the saphenous vein until it has reached above the internal malleolus, around the posterior border of which it turns. The internal saphenous vein succeeds to the one just described; it is reflected upward in front of the internal malleolus, and continues to ascend upon the inner surface, then along the posterior border of the tibia, and upon the back of the internal tuberosity of that bone and the internal condyle of the femur. In this place it is situated on the inner side of the tendons of the semi-tendinosus, gracilis, and sartorius; it then inclines forward, describing a slight curve, with its concavity directed forward; ascends along the anterior border of the sartorius, and crosses obliquely over the adductor longus; having arrived at the saphenous opening in the fascia lata, about eight or ten inches below Poupart's ligament, it immediately curves backward, passes through that opening, and enters into the femoral vein, just as the vena azygos enters into the superior vena cava, that is to say, it describes a loop having its convexity directed downward. Several lymphatic glands are found near this curve.

Relations.—The internal saphenous vein is separated from the skin by a very thin fibrous layer, the superficial fascia, and is in relation with the internal malleolus, the tibia, the tibial origin of the soleus, the tendons of the semi-tendinosus, gracilis, and sartorius, with the last-named muscle itself, and with the adductor longus. It is accompanied by the internal saphenous nerve, from the knee down to the internal malleolus.

During its course it receives all the sub-cutaneous veins of the thigh, most of the sub-cutaneous veins of the leg, the sub-cutaneous veins of the abdomen, the external pudic veins, and several communicating branches from the deep veins.

The *sub-cutaneous femoral veins* of the back of the thigh sometimes unite into one rather large trunk, which appears like a *second internal saphenous vein*; it runs parallel with the regular vein, and enters it at a greater or less distance from its termination. I have met with an anterior superficial vein which commenced around the patella, ascended vertically along the anterior region of the thigh, and might be regarded as a third saphenous vein. In one case of this kind, these three saphenous veins, viz., the anterior, posterior, and internal, entered separately into the femoral vein, or, rather, into a dilatation in which the internal saphenous vein terminated.

The internal saphenous vein often presents the following arrangement: opposite the lower part of the leg, or at the lower end of the thigh, it divides into two equal branches which pass upward, communicate with each other by transverse branches, and unite after running a variable distance; in these cases the two branches represent a very elongated ellipse. I have even seen this arrangement in both the thigh and leg of the same subject, that is to say, the saphenous vein divided into two branches in the leg, which united opposite the internal tuberosity of the tibia, and again divided in the thigh.

It is not uncommon to find a venous network supplying the place of the internal saphenous vein in the thigh.

The *sub-cutaneous abdominal veins* should be arranged among the superficial and supplementary veins, although there is a small artery, the superficial epigastric, which corresponds to them. There are three or four of these veins, which are joined by one from the gluteal region; they open sometimes by a common trunk, sometimes by three or four distinct trunks, into the internal saphenous, just as that vein is passing through the fascia lata. In a case of obliteration of the vena cava I found these veins very large, and prolonged over the thorax into the axilla, where they anastomosed with the cutaneous branches of the intercostal and thoracic veins. In a case in which the umbilical vein was persistent, the right and left internal saphenous veins were tortuous, and as large as the little finger.*

The internal saphenous also receives the *external pudic veins;* and I have seen it joined by the obturator vein, which commenced by a common trunk with the epigastric.

The *communicating branches of the internal saphenous with the deep veins* are very numerous, and should be studied in the foot, the leg, and the thigh. The origin of the internal saphenous vein gives off a branch, which communicates with the internal plantar vein.

Along the leg several other branches exist, which establish a communication between the internal saphenous and the posterior tibial veins; these branches perforate the tibial origins of the soleus muscle.

There is a very remarkable communication between the anterior tibial and internal saphenous veins in the middle third of the leg, by means of a branch which proceeds from the anterior tibial vein in front of the fibula, becomes sub-cutaneous, is reflected inward and upward between the fascia of the leg and the skin, and terminates in the internal saphenous.

Again, an inferior, internal, articular vein enters the internal saphenous.

Lastly, the anastomoses in the thigh, between the deep and the superficial veins, are less numerous than those in the leg; at most we only find two such describing loops, with the concavity directed upward.

* Anat. Path., liv. xviii.

Valves.—The number of the valves appears to me variable: I have counted six along the internal saphenous, but at other times I have not found more than two or four. There is a greater number of valves in this vein in the thigh than in the leg.

The External or Posterior Saphenous Vein.

The *external saphenous* vein (la péronéo-malleolaire, *Chauss.*; see figure of nerves of leg), smaller and much shorter than the internal saphenous, is a branch of the popliteal vein; it forms a continuation of the *external dorsal vein of the foot*, which commences from the outer extremity of the dorsal venous arch; it passes behind the peroneo-tibial articulation, crossing it from before backward; it receives, as it runs outward, a great number of branches, the chief of which come from the external plantar region; also an external calcaneal vein, which is sometimes of considerable size, and comes from the outer side of the os calcis; the vein then runs along the outer border of the tendo Achillis, and crosses it at a very acute angle, to reach the middle line of the posterior aspect of the leg: commencing at this point, it passes directly upward, crosses the internal popliteal nerve, and terminates in the popliteal vein between the internal and external popliteal nerves, between the two heads of the gastrocnemius, and by the side of the internal inferior articular vein.

In some subjects the external saphenous, at the moment when it bends to dip into the popliteal space, gives off an ascending vein, which runs along the posterior border of the semi-membranosus muscle, as high as the upper third of the thigh, where it then turns forward to open into the internal saphenous, or one of the branches of that vein, immediately below its opening into the femoral.

Relations.—The external saphenous vein is covered by the superficial fascia, which separates it from the skin, and it covers the external saphenous nerve, from which it is separated by a layer of fascia; it crosses this nerve twice, being at first situated to the inner side, then to the outer side, and again on the inner side of the nerve.

The external saphenous vein communicates with the deep veins only, behind the external malleolus, and upon the dorsum of the foot.

This vein has only two valves, one of which is situated immediately before its opening into the popliteal vein.

Such are the veins of the lower extremity. The analogy which exists between the internal dorsal branch of the foot and the cephalic vein of the thumb; between the external dorsal branch and the vena salvatella; between the external saphenous and the radial and cephalic veins; between the internal saphenous and the ulnar and basilic veins, cannot be doubted. There is no branch in the lower extremity analogous to the median vein.

THE VEINS OF THE SPINE.

General Remarks.—The Superficial Veins of the Spine.—The Anterior Superficial Spinal Veins, viz., the Greater Azygos—the Lesser Azygos—the Left Superior Vertebro-costals—the Right Vertebro-costals—the Vertebro-lumbar—the Ilio-lumbar, and Middle and Lateral Sacral—the Anterior Superficial Spinal Veins in the Neck.—The Posterior Superficial Spinal Veins.—The Deep Spinal or Intra-spinal Veins—the Anterior Longitudinal, and the Transverse Veins or Plexuses, and the Veins of the Vertebræ—the Posterior and the Posterior and Lateral Transverse Veins or Plexuses—the Medullary Veins.—General Remarks on the Veins of the Spine.

The spinal or *rachidian veins* constitute a very important part of the venous system, which has only recently been specially studied.

These veins differ, in many respects, from the spinal arteries, so that the description of the one does not afford much assistance in the study of the other; nevertheless, I shall frequently have occasion to point out some remarkable analogies between these two sets of vessels.

The spinal veins are arranged most distinctly as venæ comites and supplementary veins.

We shall divide them into the veins *exterior* to the spine or the *superficial* veins, and the *veins in the interior* of the spinal canal, or the *deep veins*.

The Superficial Veins of the Spine.

The superficial veins of the spine may be subdivided into the *anterior* and *posterior*.

The Anterior Superficial Rachidian Veins.

The anterior *superficial rachidian* or *spinal veins* (see *fig.* 223) comprise the vena azygos major, the vena azygos minor, the common trunk of the right superior intercostals, that of the left superior intercostals, the vertebro-lumbar and ilio-lumbar veins, and the lateral and middle sacral veins; in the neck, the ascending cervical and the vertebral veins.

The Greater Azygos Vein.

The vena azygos major (*a a'*, *fig.* 223) is a large single vein (*ἄζυγος, without a fellow*),

situated along the vertebral column; it commences (*a'*) in the lumbar region, and terminates at the upper part of the thorax by opening into the vena cava superior.

Its *origin* is subject to much variety. It very rarely arises from the trunk of the inferior vena cava itself, with which, however, it almost always communicates by small branches. It generally forms the continuation of a series of anastomoses, which surround the bases of the right transverse processes of the lumbar vertebræ, and which may be called after some authors the *ascending lumbar vein* (*b*, on the right side); sometimes it arises from the trunk of the last vertebro-costal, or the first vertebro-lumbar vein: we rarely find a branch of origin from the renal or supra-renal veins. It often has two origins, one from the ascending lumbar, and the other from the first vertebro-lumbar, or last vertebro-costal vein. The vena azygos, almost immediately after its origin, passes from the abdominal into the thoracic cavity, through the aortic opening in the diaphragm, ascends upon the right side of the bodies of the thoracic vertebræ, as high as the third intercostal space, *i. e.*, between the third and fourth ribs, where it curves forward, forming, like the aorta, an arch, which passes over and embraces the right bronchus, and opens into the back of the vena cava superior, as that vein is entering the pericardium.

Fig. 223.

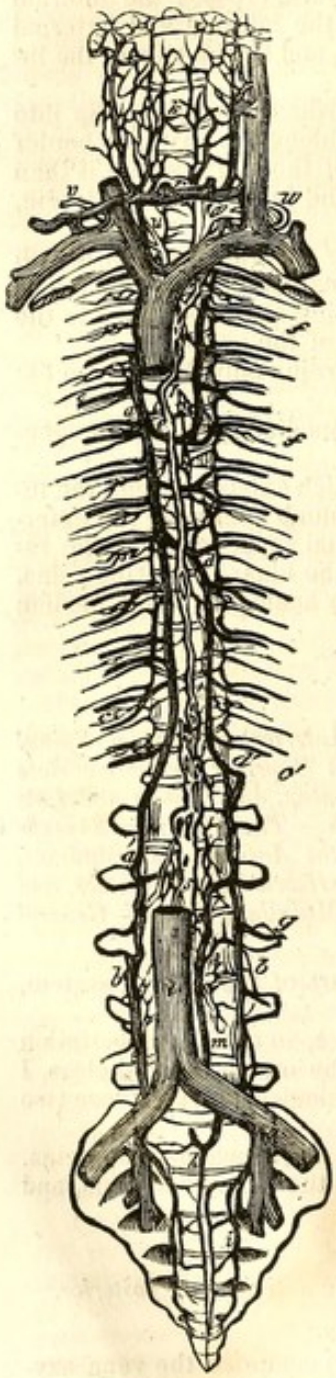

During its course the vena azygos is in contact with the vertebral column, and is situated in the posterior mediastinum, on the right side of the aorta and of the thoracic duct (*t t*), which runs parallel to it; it lies in front of the right intercostal arteries, and crosses them at right angles. It varies in size, according to the number of branches which it receives, but gradually increases from below upward.

The question of the existence of valves in the vena azygos has given rise to much discussion. It appears to me to be settled in the negative.

The vena azygos is joined in front by the *right bronchial vein* and some *œsophageal* and *mediastinal veins*; on the right side by the eight inferior *vertebro-costal veins* (*c c*) of that side; and on the left by the *lesser azygos* (*d*) and the common trunk (*e*) of the *left superior intercostal veins*.

Before opening into the superior vena cava, opposite the third intercostal space, the azygos vein receives at its curve, either by a common trunk, or by two or three separate branches, the three superior right vertebro-costal veins, which sometimes enter the right brachio-cephalic vein, and sometimes the vena cava superior, above where it is joined by the vena azygos. In the last case they pass vertically upward; in the second they are directed almost vertically downward.

The Semi-azygos, or Lesser Azygos Vein.

The *lesser azygos vein* (*d d,'* azygos minor, semi-azygos) may be regarded as the common trunk of the three, four, or five inferior vertebro-costal veins (*c' c'*) of the left side: it opens into the great azygos vein.

It commences below (*d'*) in as many different ways as the great azygos vein, but it communicates with the renal vein much more frequently. It runs upward upon the left of the vertebral column, approaches the median line, and opens into the great azygos at a different height in different subjects. It joins the great azygos either at right angles or obliquely, passing behind the thoracic duct. The lesser azygos vein may be regarded as the left branch of origin of the greater azygos: sometimes it is extremely large; in that case the greater azygos is directly continuous with it, and the right branch is very small.

The lesser azygos vein is joined by the four or five inferior vertebro-costal veins (*c' c'*) of the left side. It also frequently receives the common trunk of the superior vertebro-costal veins, which might be said to form a superior lesser azygos vein.

The Left Superior Vertebro-costal Veins

The common trunk (*e*) of the left superior intercostal veins (*f f*) might be called the *left superior lesser azygos*, for it has the same relation to these veins that the lesser azygos has to the inferior intercostals of the same side. It runs downward upon the left of the vertebral column, increasing in size as it approaches its termination, which is

either near the end of the lesser azygos, or in the greater azygos. Not unfrequently the common trunk of the left superior intercostals bifurcates and opens both into the lesser azygos and into the left brachio-cephalic vein. In some cases it terminates entirely in the left brachio-cephalic vein: I have myself met with this disposition. I have seen the left superior phrenic and the mediastinal veins enter the trunk of the lesser vena azygos immediately before its termination.

The number of the left vertebro-costal veins which unite to form the lesser azygos vein varies from three to seven; when only three or four of the highest of these vertebro-costal veins end in it, the two or three lower ones enter directly into the greater azygos vein.

General Remarks on the Vena Azygos Major.—This vein returns the blood of the right and left vertebro-costal veins to the heart; its presence is rendered necessary, first, in consequence of the inferior vena cava not being able to receive any veins from the point where it enters the groove in the liver to its termination in the right auricle; and, secondly, because the superior vena cava is also unable to receive any veins while it is within the pericardium. The greater azygos is, therefore, a supplementary vein, a true collateral canal which supplies the place of the venæ cavæ, and receives all the veins corresponding to the branches given off by the aorta during this long course. These observations are, for the most part, applicable to all the azygos veins.

Anatomical Varieties of the Azygos Veins.—It would be both useless and tedious to notice here all the varieties that have been observed in the distribution of the azygos veins. M. Breschet has described six, but there are many more. The following is a very curious variety: the greater azygos occupies the median line of the dorsal portion of the vertebral column, and is divided below into two equal branches, a right and a left, each of which receives the three inferior vertebro-costal veins of its own sides; all the other vertebro-costal veins end directly in the greater azygos.

Another not less curious variety is the following: there are two equal and parallel azygos veins, a right, which receives all the right intercostal veins, and a left, which receives all the left intercostals: the two main trunks communicate with each other opposite the seventh or eighth dorsal vertebra by a very large transverse branch.

The Intercostal or Vertebro-costal Veins.

The *intercostal* or *vertebro-costal veins* of both sides (*c c*, *c′ c′*, *f f*) correspond to the intercostal or vertebro-costal arteries, the distribution of which it is important to call to mind. We have seen that each of these arteries divides into two branches: an *intercostal* branch, properly so called, intended for the intercostal spaces; and a *spinal* branch, the dorsal division of which terminates in the spinal muscles and the skin, while its vertebral, or intra-spinal division, is distributed to the vertebræ, to the spinal cord, and to its coverings. In like manner, the *vertebro-costal veins* are formed by the junction of the spinal branch, to which we shall presently return, and the intercostal branch. These two sets of branches unite into a common trunk, the vertebro-costal vein, which passes transversely along the groove on the body of each vertebra, receives some veins from the bone in that situation, and enters at a right angle into the corresponding axygos vein.

The Lumbar or Vertebro-lumbar Veins.

In the lumbar region there are no azygos veins, and each vertebro-lumbar vein enters separately, or by a common trunk, with its fellow of the opposite side, into the back of the vena cava inferior. Not unfrequently two of the vertebro-lumbar veins of the same side open by a common trunk; and it is not rare to find the left superior vertebro-lumbar vein enter the renal vein.

The vertebro-lumbar veins (*g*) are distributed very differently from the corresponding arteries. Opposite the bases of the transverse processes there are a series of anastomotic arches, which together constitute, on each side, an ascending branch, called the *ascending lumbar vein* (*b b*), which communicates above with the corresponding azygos vein, and below with the ilio-lumbar veins, and which might be regarded as a *lumbar azygos vein*. The trunks of the vertebro-lumbar veins proceed from this series of arches to the vena cava; and all the intra-spinal and dorsi-spinal veins terminate in it.

The Ilio-lumbar, Middle Sacral, and Lateral Sacral Veins.

The *ilio-lumbar vein*, which opens into the common iliac, is distributed like the artery of that name; it sometimes receives the last vertebro-lumbar vein: it is joined by the great veins which emerge from the lower inter-vertebral foramina of the lumbar vertebræ; by the branch which is continuous in front of the fifth lumbar vertebra, with the series of arches forming what may be called the *lumbar azygos*; and, lastly, by a communicating branch from the lateral sacral veins.

The *middle sacral* and *lateral sacral veins* represent the azygos veins in the sacral region; they are joined by all the dorsi-spinal branches passing out from the inter-vertebral foramina, and end in the common iliac veins.

The *middle sacral vein* (*h*) often commences below by three branches, a median in

front of the coccyx, and two lateral and anterior branches. One of these joins the vesical plexus, while the other communicates with the hemorrhoidal veins, and establishes a remarkable communication between the general venous system and the system of the vena portæ.

The middle sacral vein passes vertically upward, somewhere near the middle line, and opens into the left common iliac vein (*n*) at a greater or less distance from its junction with the right common iliac. I have seen it bifurcate above to enter both common iliacs.

During its course it is joined opposite each vertebra by some transverse, plexiform branches, which establish a free communication between it and the lateral sacral veins, and which receive some large branches from the bodies of the sacral vertebræ. These transverse branches represent the vertebro-costal and vertebro-lumbar veins, which also receive the veins which issue from the bodies of the vertebræ, through the foramina, upon the inner surface of those bones.

The *lateral sacral veins* (*i*), of which there are always more than one on each side, are continuous with the dorsi-spinal veins, which emerge from the anterior sacral foramina; there are generally two, a superior, which enters the common iliac vein, and an inferior, which forms a very remarkable plexus, opposite the great sciatic notch, and ends in the internal iliac vein, or in its gluteal and sciatic branches.

The Anterior Superficial Spinal Veins in the Neck.

In the anterior cervical region we find transverse plexiform branches (*k*) opposite each vertebra, more particularly opposite the first and second; these plexuses open partly into the ascending cervical vein, which corresponds to the ascending cervical artery, but principally into the vertebral vein, which is contained within the canal formed by the series of foramina at the base of the transverse processes of the cervical vertebræ. These plexiform branches, which cover the sides of the bodies of all the vertebræ, are joined by the veins from the prævertebral muscles, by the articular veins, and by the anterior osseous veins from the bodies of the corresponding vertebræ.

The vertebral veins and the ascending cervical veins may therefore be said to represent the azygos veins in the cervical region.

The Posterior Superficial Spinal Veins.

The posterior superficial spinal veins commence in the skin, and in the muscles of the vertebral grooves: some of them closely accompany the arteries; for example, those that pass between the muscles of the vertebral grooves; the others have a peculiar distribution, and require a special description.

These veins, which are called *dorsi-spinales* by MM. Dupuytren and Breschet, form an exceedingly complicated network, the meshes of which surround the spinous processes and laminæ, and the transverse and articular processes of all the vertebræ: these meshes are more numerous in proportion as the injection is more perfect.

After a successful injection, we sometimes find along the summits of the spinous processes, especially in the dorsal and cervical regions, certain *median longitudinal veins*, from which the interosseous branches proceed. These latter run forward, on each side of, and in contact with, the inter-spinous ligaments. Having reached the base of the corresponding spinous process, they pass outward, opposite the intervals between the laminæ of the vertebræ, as far as the bases of the transverse processes, and then divide into two branches: one of these ascends, and anastomoses with the descending branch from the vein above; while the other branch descends, and anastomoses with the ascending branch of the vein below. It follows, therefore, that around the transverse processes and the laminæ of the vertebræ there is a series of venous circles, which communicate, opposite each inter-vertebral foramen, with the veins contained in the interior of the spine.

The posterior superficial spinal veins in the neck have a much more complicated arrangement, and, indeed, form a plexus. Moreover, we generally find, between the complexus and the semi-spinalis colli, two longitudinal veins, which appear to me to deserve a particular description, under the name of the *posterior jugular veins*.

The *posterior jugular veins* commence between the occipital bone and the atlas, pass tortuously out from the interval between these bones, run downward and inward, and, opposite the spinous process of the axis, the veins of the two sides anastomose by a transverse branch. They then change their direction, pass downward and outward, and having reached the lower part of the neck, turn forward, between the seventh cervical vertebra and the first rib, and open into the back of the brachio-cephalic vein behind the vertebral vein. The two posterior jugular veins are therefore arranged in the form of the letter X.

The posterior jugular vein, which does not always exist, for its branches of origin sometimes remain separate, seems to be inversely proportioned to the vertebral vein, with which it communicates opposite each inter-transverse space. It has appeared to me to communicate above with the deep occipital and the mastoid veins, with the veins situated in the spinal canal, and with the internal jugular vein. Throughout the whole

of its course, it communicates freely, opposite each inter-vertebral foramen, with the veins contained in the interior of the spinal canal, and with the vertebral vein.

The Deep Spinal or Intra-spinal Veins.

The *veins in the interior of the spine* comprise the proper veins of the spinal cord, and the veins situated between the bones and the dura mater, which are subdivided into the *anterior* and the *posterior longitudinal veins* or *plexuses*, and the *transverse veins* or *plexuses*; the latter establishing a free communication between all four of the longitudinal veins or plexuses, opposite each vertebra.

Before describing the veins situated between the bones and the dura mater, I must state, in a few words, what is the arrangement of the proper arteries of the vertebræ.

The spinal branches which are given off on each side of the body by the vertebral artery in the neck, by the intercostal arteries in the back, by the lumbar arteries in the loins, and by the lateral sacral arteries in the pelvis, enter the spinal canal through the several inter-vertebral foramina, and then each of them divides into an ascending and a descending branch; the ascending branch runs upward upon the lateral part of the body of the vertebra above, and anastomoses with the descending branch of the spinal artery above it, while the descending branch anastomoses with the ascending branch of the artery below. Each of the anastomotic arches thus formed has its concavity directed outward; so that there is a series of arterial arches, united at their extremities, situated upon each side of the posterior surface of the bodies of all the vertebra. From the convexity of each arch two transverse branches are given off, one running above and the other below the small foramina upon the posterior surface of the body of the corresponding vertebra. The cribriform portion of the bone is thus surrounded by the arterial arches with their transverse branches; and from all points of the polygon which they form small arteries are given off, which penetrate into the substance of each vertebra, and anastomose with the arterial twigs that enter the anterior surface of the body of the vertebra

The arrangement of these arteries gives a perfect idea of that of the veins known as the *anterior longitudinal veins* or *plexuses*, and of the *transverse plexuses*, which pass from one to the other.

The Anterior Longitudinal Intra-spinal Veins or Plexuses, the Transverse Plexuses, and the Proper Veins of the Bodies of the Vertebræ.

Dissection.—Remove the arches of the vertebræ, and the spinal cord and its coverings. The plexus may also be viewed from the front, by carefully sawing through the pedicles and then removing the bodies of the vertebræ.

The *anterior longitudinal plexuses*, described by Chaussier, but still more correctly by Breschet, form two venous trunks, named the *great anterior longitudinal veins*, extending from the foramen magnum to the base of the coccyx, one on each side of the posterior common vertebral ligament, and therefore upon the sides of the posterior surface of the bodies of the vertebræ, and on the inner side of their pedicles. These veins, improperly called *vertebral sinuses*, communicate together opposite each vertebra by a *transverse* plexus, situated between the body of the vertebra and the posterior common ligament. These longitudinal plexuses are less developed in the cervical and sacral regions. It is probable that in the neck their place is supplied by the vertebral veins.

It would be in vain to consider these plexuses as having a distinct origin, course, and termination; the description given above of the distribution of the arteries is applicable to the veins in every respect: thus, the venous plexuses are formed by a series of plexiform arches, which embrace the pedicles of each vertebra, have their concavity directed outward and their convexity inward, and the extremities of which anastomose together opposite the inter-vertebral foramina, where they communicate with the branches on the outside of the spine, and assist in the formation of the vertebro-lumbar and vertebro-costal veins, and, consequently, of the azygos veins. From the convexity of each arch proceeds a transverse plexus, which goes to join with its fellow of the opposite side; and, just as we have seen that the transverse arteries extending from one arterial arch to another give off branches to the bodies of the vertebræ, so, in like manner, the transverse venous plexuses receive the veins which emerge from the body of each vertebra.

The arrangement of the veins or plexuses just described explains the alternate enlargements and contractions observed in different parts of the anterior longitudinal plexuses. The rare interruptions described by M. Breschet, I believe to depend upon imperfect injections, which succeed so differently in different subjects.

The anterior longitudinal veins or plexuses cannot be regarded as *sinuses*, for they are not contained in a fibrous sheath, like the veins of the dura mater, nor are they reduced merely to the lining membrane of the veins. Notwithstanding their extreme tenuity, we can recognise an external coat, and the posterior common ligament does not cover them behind. Nor is the term sinus more applicable to the transverse plexuses, although they are situated between the bodies of the vertebræ and the posterior common ligament, for the ligament merely covers them without forming a sheath for them.

The Proper Veins of the Bodies of the Vertebræ.—The foramina upon the posterior surface of the body of each vertebra, which are generally proportioned to the size of the vertebra, are principally intended for the proper veins of the bodies of their bones: the arteries are much smaller, and though they enter by the same openings, they occupy but a small part of their areas. These veins belong to that system of venous canals found in the substance of bones, which we have already noticed as existing in the bones of the cranium. Their chief varieties have been correctly described and delineated by M. Breschet. These venous canals, which are more developed in the old than in young subjects, occupy the centre of the body of the vertebra, and always run parallel to the upper and lower surfaces of the bone: they arise from all parts of the circumference of the vertebra, communicating with the veins which enter by the foramina on its anterior surface, and converge towards the principal foramen, or foramina, upon its posterior aspect. They frequently enter a semicircular canal, which has its convexity directed forward, and gives off from its concavity a venous canal, which opens directly into the transverse plexus: the lateral veins of the body of the vertebra open into the extremities of this semicircular canal; while within the venous canals of the vertebræ, the veins are reduced to their lining membrane, like the veins in the canals of the cranial bones.

The transverse plexuses, therefore, collect the blood from the bodies of the vertebræ, and transmit it to the anterior longitudinal plexuses.

The Posterior Intra-spinal Veins or Plexuses, and the Posterior and Lateral Transverse Plexuses.

The *posterior intra-spinal plexuses*, much smaller than the anterior, are situated one on each side between the vertebral laminæ and ligamenta subflava behind, and the dura mater in front. These veins are rarely injected along the whole length of the spine, and hence they sometimes appear to exist only in the dorsal region. They communicate opposite each vertebra, by means of *posterior transverse plexuses*, or by transverse veins. They communicate with the anterior longitudinal plexuses by small *lateral transverse plexuses*, which pass from behind forward. It follows, therefore, that the veins within the spine, but external to the coverings of the cord, consist of four longitudinal plexuses, all of which are connected by a transverse circular plexus opposite each vertebra. A strict analogy may be said to exist between the sinuses of the cranium and the intra-spinal plexuses; an analogy which did not escape the notice of the ancients, as the common application of the term sinus by them to the veins of the cranium and to those of the spine would seem to indicate. Thus, in the cranium we find certain *longitudinal sinuses*, that is, those which run from before backward, viz., the superior longitudinal sinus, the straight sinus, and the posterior occipital sinuses; also, the superior and inferior petrosal sinuses, the cavernous sinuses, and the right and left lateral sinuses. The former set represent the posterior intra-spinal plexuses; the latter correspond to the anterior intra-spinal plexuses.

In the cranium we also find certain *transverse sinuses*, viz., the basilar or transverse occipital sinuses and canals, and the coronary sinus, which exactly correspond to the transverse plexuses, extending from one anterior intra-spinal plexus to the other. We sometimes find two or three transverse venous plexuses in the basilar groove of the occipital bone.

Lastly, may we not compare the veins on the outer surfaces of the spine to the occipital, frontal, and temporal veins; and do not the veins passing through the posterior lacerated foramen and the sphenoidal fissure, which we have regarded as representing the inter-vertebral foramina (see OSTEOLOGY), establish a communication between the veins on the inside and those on the outside of the cranium, just as the veins which escape through the inter-vertebral foramina connect together the superficial and the intra-spinal veins?

The anterior and posterior deep spinal veins communicate with the superficial veins of the spine at the inter-vertebral foramina so freely, that the circulation would not be interfered with even if a considerable amount of obstruction existed. I have already stated (see VERTEBRÆ) that the diameter of the inter-vertebral foramina is in relation, not with the size of the nervous ganglia, but rather with that of the veins, which establish a communication between the superficial and intra-spinal venous systems.

The Proper Veins of the Spinal Cord, or the Medullary Veins.

If we examine the pia mater of the spinal cord, even without having injected it, in the body of a person who has died suddenly, as in that of a new-born infant after death from asphyxia or apoplexy, the surface of the pia mater will be found covered by very tortuous veins, which emerge from the posterior median furrow of the spinal cord. This venous network, which is spread over the whole surface of the cord, gives off opposite the roots of each nerve a small vein, which runs directly between those roots, enters the corresponding inter-vertebral foramen, is enclosed with the nerve in the sheath formed by the dura mater, and having emerged from that sheath, opens into the large vein situated in the inter-vertebral foramen.

There is, therefore, this difference between the proper veins and arteries of the spinal

cord, that the number of veins is equal to that of the nerves; while the arteries are less numerous, and enter the fibrous sheaths of the nerves only at intervals, and in proportion as the preceding arteries are exhausted. Moreover, the anterior and posterior spinal veins, like their corresponding arteries, may be regarded as belonging only to the upper part of the cord, and not as being intended to traverse its whole length.

General Remarks on the Veins of the Spine.

The veins of the spine may be regarded, in reference to the general circulation, as establishing an unbroken communication between the veins of all parts of the trunk; so that we can suppose one of the venæ cavæ to be obliterated, without the venous circulation being interrupted. The greater azygos itself, which is generally regarded as the principal means of communication between the two venæ cavæ, is not, however, necessary, when we consider the arrangement of the anterior and posterior spinal plexuses. Thus, I have sometimes seen the inferior, and sometimes the superior vena cava obliterated without any apparent increase in the diameter of the vena azygos, and, what will perhaps be thought surprising, without œdema, either of the upper or lower extremities.

Supposing the vena cava ascendens to be obstructed from the entrance of the hepatic veins down to the renal veins, the blood would then flow back by the vertebro-lumbar veins into the plexuses contained within the spinal canal; through these plexuses, it would ascend to the vertebro-costal veins, from thence to the azygos veins, and through them into the superior vena cava.

If all the jugular veins were obliterated, the venous circulation in the head would still continue, and would be carried on through the spinal veins. I have tied the two external jugular veins in a dog. The animal showed no sign of cerebral congestion: after opening the body, I did not find any increase of size in the small veins which accompany the carotid arteries, and which in those animals are naturally very small. In this case, the circulation was evidently carried on by means of the spinal veins.

THE LYMPHATIC SYSTEM.

Definition, History, and general View of the Lymphatic System.—Origin.—Course.—Termination and Structure of the Lymphatic Vessels.—The Lymphatic Glands.—Preparation of the Lymphatic Vessels and Glands.

The term *lymphatic vessels* is applied to certain transparent tubes provided with valves, and conveying either lymph or chyle, which pass through small, rounded, glanduliform bodies called *lymphatic glands*, and in all cases empty themselves into the venous system, to which, indeed, they may be said to form an appendage.

From their tenuity and transparence, these vessels for a long time escaped the notice of anatomists. The thoracic duct was discovered by Eustachius in 1565. The lacteals were discovered in 1622 by Gaspard Asellius, who, by a lucky chance, while seeking quite another object, discovered certain vessels filled with chyle. In 1641, Pecquet discovered the receptaculum chyli, and showed that the lacteals entered the thoracic duct, and not the liver, as Asellius and all his contemporaries believed.

Rudbeck, Thomas Bartholin, and Jolyff dispute the honour of having discovered the lymphatic vessels, properly so called, in contradistinction to the lacteals or chyliferous vessels.

Mascagni devoted a great part of his life to the study of the lymphatic system; and his work, ornamented by magnificent plates, is a monument of science, which should be taken for a model by all who are engaged in anatomical inquiries. Lastly, within the last few years, MM. Fohmann, Lauth, Lippi, Panizza, and Rossi have thrown light upon some most important points in the anatomy of this system.

In describing this system of vessels, the lacteals, or the lymphatics containing chyle, have commonly been separated from the lymphatics, properly so called, or the vessels containing lymph. This distinction, however, is not warranted by anatomy, for the two sets of vessels are perfectly identical in structure.

The lymphatic system offers many analogies with the venous system; but there are also no less remarkable differences between the two.

Like the venous system, it consists, as a whole, of afferent or converging vessels, which arise from all parts of the body, and run from the periphery towards the centre.

Like the veins, the lymphatics are divided into two sets: a *sub-cutaneous* set, which, in general, accompanies the superficial veins of the limbs; and a *deep* set, which follows the course of the deep arteries and veins; and, lastly, the lymphatics resemble the veins in being provided with valves.

The lymphatics differ from the veins in passing through certain bodies improperly called glands, which, at intervals, intercept their course. They differ from the veins, also, in their arrangement; for they do not successively unite into larger and larger branches, and these into trunks, but they scarcely increase in size from their origin to their termination; and, though they communicate with each other by numerous anasto-

moses, each of them follows, as it were, an independent course : lastly, the blood which circulates in the veins is still, though indirectly, under the influence of the heart's action, while the onward movement of the lymph is exclusively dependant upon the parietes of the vessels.

Before proceeding to the special description of the lymphatics, we shall make some general remarks upon the origin, course, and termination of these vessels.

Origin of the Lymphatics.

The origin of the lymphatics, like every point connected with the minute structure of the tissues, is yet a new subject for inquiry.*

It has been said that the lymphatics are continuous with the arteries, so that, according to this hypothesis, the arteries are continuous with two kinds of vessels, viz., with the lymphatics, which carry off the serum, and with the veins, which transmit the coloured part of the blood. The continuity of the arteries with the lymphatics has been admitted, in consequence of its having been observed that injections thrown into the arteries passed into the lymphatics. I have frequently seen this in injecting the spleen and the liver ; but it was only when the injection was pushed in with great and continued force : so that it is possible, as thought by Hunter, Monro, and Meckel, that, in these cases, some of the vessels had been ruptured, and the injection extravasated ; or, what is still more probable, there may have been transudation through the pores of the tissues. Microscopical observations show most distinctly that the arteries are continuous with the veins ; but there is no fact to demonstrate the continuity of the arteries with the lymphatics.

The origin of the lymphatics can be actually shown only upon free surfaces, such as the mucous membranes, the skin, the serous and synovial membranes, and the lining membranes of arteries and veins ; so that, in the actual state of our knowledge, it might be maintained that the lymphatic vessels arise exclusively from all the free surfaces.

All the lymphatics arise by a network of such tenuity that, when injected with mercury, the whole surface appears changed into a metallic layer.

About eight years since, having introduced at random a tube filled with mercury for injecting the lymphatics into the pituitary membrane in a calf, I was astonished to find the surface covered by a metallic pellicle : I repeated the experiment frequently, and constantly found that the pellicle was not caused by extravasation, for the mercury ran in determinate lines, forming plexuses of different kinds ; also that, to succeed in this experiment, it was necessary to puncture the membrane very superficially, or the mercury would run into the subjacent plexus of veins ; and, lastly, that there was no communication between that plexus of veins and the more superficial network, which I suspected to consist of lymphatic vessels, for it exactly resembled the network of those vessels in the peritoneum covering the liver. I ascertained that the same structure existed in the skin ; in the lingual, buccal, and vaginal mucous membranes ; in the conjunctiva ; and, lastly, in the uterine mucous membrane of a sow which had lately littered. I showed this lymphatic network of the pituitary membrane in several of my lectures ; and lately, having again examined the subject for the purposes of the present work, I have ascertained that this network exists upon all the free surfaces, that it communicates with the lymphatics, and that it is possible to inject those vessels and the lymphatic glands by introducing the pipe very superficially into the surfaces of these membranes.† I may be permitted to observe, that it is only a few months since I became acquainted with the splendid work of M. Panizza, of Pavia, upon the lymphatic vessels of the testicles (*Osservazioni Antropo-zootomico Fisiologiche*, 1830) ; and with M. Fohmann's last very important memoir (*Mémoire sur les Vaisseaux Lymphatiques de la Peau, des Membranes Muqueuses, Séreuses, du Tissu Nerveux, et des Muscles*, 1833).

Origin of the Lymphatics from the Mucous Membranes.—The villi found upon the mucous membrane of the small intestines contain, in their centre, a cavity, named the *ampulla of Lieberkuhn*, which I have seen in one instance filled with tuberculous matter. (*Anat. Pathol.*, liv. ii.) Still, I have never been able to discover any open orifice on the summit of that villus.‡ Independently of these cavities within the villi, which are proper to the system of lacteal vessels, the thin pellicle of the mucous membranes which cannot be injected from the arteries or veins (*vide* p. 370), when carefully and very superficially punctured by the pipe of a mercurial injecting apparatus, is covered by a metallic pellicle. Panizza and Fohmann have proved that the membrane which covers the glans penis has two sets of lymphatics : a superficial and a deep. M. Fohmann has figured, in some very beautiful plates, the lymphatic network of the mucous membranes of the glans penis, bladder, urethra, trachea, bronchi, œsophagus, stomach, ileum, and colon. This network is so superficial, that the mercury appears almost uncovered ; it does not com-

* Do lymphatics commence in all parts of the body ? It is true that absorption is carried on in every part, for absorption is one element of the process of nutrition ; but, as it can be effected by other vessels besides the lymphatics, its occurrence in any part does not necessarily involve the presence of this peculiar class of vessels.

† These preparations were made by M. Bonami, my prosector, under my direction, with extreme skill, and a zeal above all praise.

‡ [For what is known concerning the structure of the villi, see note, p. 369.]

municate either with the arteries or the veins, but communicates freely with the lymphatic vessels. It was correctly delineated by Mascagni: according to that anatomist, it covers all the intestinal villi, as with a sheath, and does not appear to have any openings on the exterior.

Origin of the Lymphatics from the Skin.—Are the openings or pores so evident upon the skin when viewed through a lens, and from which drops of sweat may be seen to exude, intended to serve the purpose both of exudation and absorption? or are there rather two distinct kinds of orifices for these two functions? or, lastly, are these orifices altogether unconnected with the absorbent vessels?*

If we puncture the skin very superficially, so that the injecting pipe may enter immediately below the epidermis, the mercury will be seen to run with great rapidity into some very small vessels, and to form a metallic network, precisely like that already described as existing in the mucous membranes; from this layer proceed sub-cutaneous lymphatics, which may be traced filled with mercury as far as the adjacent lymphatic glands, or even beyond them. In order that this experiment may succeed, it is necessary that the skin to be injected should be plunged into hot water.

I made the following experiment in order to detect, if possible, in the lymphatics of the skin, the mercury absorbed during mercurial frictions. I caused two dogs to be rubbed with mercurial ointment night and morning; and, that the absorption might be more complete, I enveloped their bodies in a frock made of skin. These animals died in about eight days with gangrene of the gums; but I could not find in any part the slightest trace of mercury, although the frictions were continued up to the period of their death.

Origin of the Lymphatics from the Serous and Synovial Membranes.—The same results as those above stated are obtained by injecting the serous and synovial membranes. The portion of peritoneum covering the liver is generally chosen for injecting the lymphatic network of serous membranes, because the tension and adhesion of the peritoneum over the liver renders it more easy to inject. The same results may be obtained by injecting the costal or pulmonary pleura, the tunica vaginalis, or the parietal and visceral portions of the arachnoid.

The *synovial* membranes may be injected with the greatest facility, either near the cartilages, where they are more tense than in other parts, or upon the ligaments, to which they adhere.

Origin of the Lymphatics from the Lining Membrane of the Veins and Arteries.—The lymphatic plexuses upon the lining membrane of veins and arteries have hitherto been only partially displayed, but the analogy between these and serous membranes is so close, that I have no doubt of their identity in this respect. I have, moreover, found the lymphatic vessels of the aorta filled with blood in several cases of degeneration of the coats of that vessel.

Origin of the Lymphatics in the Free Cellular Tissue.—In order to exhibit the origin of the lymphatics in this situation, I injected coloured liquids, such as ink, into the sub-cutaneous and inter-muscular cellular tissue in several animals, and I found the lymphatic vessels and the corresponding lymphatic glands of a jet-black colour. I made a great number of experiments to induce absorption of mercury, by injecting it either into the cellular tissue, or into a serous cavity; but the metallic mercury always acted like a foreign body, the mechanical effect of which produced more or less inflammation, but it was never absorbed.

I have found pus in both the superficial and deep lymphatics, and in the lymphatic glands of the groin, after phlegmonous erysipelas and acute abscesses of the leg; but it is not proved that the presence of this pus was the result of absorption. It is more probable that it had been produced by inflammation of the lymphatics themselves.

Although it is impossible to demonstrate, anatomically, the presence of lymphatics in the free cellular tissue, it is most probable that that tissue, as well as the serous membranes, with which it has so many analogies, is formed by this kind of vessels. Mascagni stated that all the white tissues consist of lymphatic vessels, and that the lymphatic system forms the basis of the whole body.

From the preceding observations, it may be stated that, with the exception of the lacteals which open upon the summits of the villi,† all the lymphatic vessels of free surfaces arise by an exceedingly delicate network; M. Fohmann believes that all the lymphatics commence by a network of closed vessels.‡

I have never been able to discover the lymphatic networks, either in the nervous substance, in muscles, glands, or in the fibrous, cartilaginous, and osseous tissues.

* [These pores are the orifices of the ducts of the sudoriferous glands, which are imbedded in the true skin, or the sub-cutaneous cellular membrane, and have no direct connexion with the lymphatics.]

† [Whether the lacteals commence in each villus by a *network*, or by free closed extremities, is not yet determined; but they form no exception to the rule that the absorbent vessels arise by *closed* extremities, and not by *open* mouths. See p. 370.]

‡ [These networks are arranged in layers, the most superficial of which is formed by the finest vessels, and has the smallest meshes.]

Course of the Lymphatics.

From the networks above described, the *lymphatics* themselves arise, and, in all the organs, are divided into a *deep* and a *superficial* set. The former set accompany the deep vessels of the organ, while the others follow the superficial veins in such parts of the body as are provided with them. In those organs which are covered with a serous coat, they appear to be contained within the substance of that membrane. The lymphatics run parallel with each other, and communicate pretty frequently by bifurcating, and then joining the neighbouring vessels; but they do not converge towards each other, nor do they, like the veins, unite successively into a smaller and smaller number of larger and larger branches; thus, their increase in size is not progressive; and it might even be said that, throughout their whole course, they undergo no decided increase nor diminution.

Their *direction* is slightly tortuous. (In *fig.* 224 are shown short portions of lymphatics of different sizes.)

Anastomoses.—We do not find in the lymphatics those numerous and important anastomoses which form such characteristic points in the history of the arteries and veins. These vessels present only one kind of anastomosis, which is accomplished in the following manner: A lymphatic, after a certain course, divides into two equal branches, which diverge at a very acute angle; these two branches anastomose with two other lymphatics, each of which communicates either by bifurcation or directly with the neighbouring lymphatic vessel. This explains how, by injecting a single lymphatic, a certain group of these vessels may be filled. Not unfrequently, a lymphatic divides into two branches, which, after a certain distance, again unite.

During their course, the lymphatic vessels meet certain small *glanduliform bodies*, the *conglobate glands* of the ancients, but which are also called *lymphatic ganglia*, on account of the analogy pointed out by Sœmmerring between them and the ganglia of nerves; the lymphatic glands form centres, to which a number of lymphatic vessels proceed, and are lost in them for a time, but from which they afterward emerge.

The name of *afferent lymphatics* (vasa afferentia, *a a a*, *fig.* 225) is applied to those which enter a gland, and those which emerge from it are called *efferent lymphatics* (vasa efferentia, *b b*).

Do all the lymphatics necessarily traverse one or more of these glands? Mascagni has successfully maintained the affirmative in opposition to Hewson and others, who assert that they have seen lymphatics entering directly into the thoracic duct. Mascagni states that he invariably found that these vessels passed through one or more glands. As to the argument derived from the absence of dropsy in cases of obstruction in the lymphatic glands, Mascagni explains this by the frequent anastomoses of the lymphatic vessels, the result of which is, that they communicate with several series of glands, some of which are situated at very great distances.

The most numerous anastomoses of the lymphatics take place within the lymphatic glands; thus, if we inject the afferent vessels of a lymphatic gland, the mercury escapes by its efferent vessels. In injecting a gland, it frequently happens that the mercury passes not only into the efferent, but also into some of the afferent vessels.

Size of the Lymphatics.—The lymphatics are generally so small as to escape the notice of the observer; but they may become enlarged to a remarkable degree. Thus, I have seen the lymphatics of the groin and of the uterus as large as the thumb.

An attempt has been made to draw some comparison between the total capacities of the lymphatic, venous, and arterial systems; but all that has been said respecting this is founded upon no positive data. I would, moreover, observe, that in all probability we are acquainted with but a portion of the lymphatic system.

Termination of the Lymphatics.

According to the most generally received opinion, all the lymphatics terminate in two trunks, the *thoracic duct* and the great *right lymphatic duct*; the latter vessel receives the lymph from the right upper extremity, and from the right half of the head, neck, and thorax; the lymphatic vessels of all the other parts of the body end in the thoracic duct; the lymphatic vessels enter successively into these two trunks, as the plumes of a feather are attached to its shaft. The two trunks themselves end as follows: the thoracic duct enters the left sub-clavian vein, at the junction of that vein with the internal jugular; the great right lymphatic duct terminates in the right sub-clavian vein; hence it is that the lymphatic system may be regarded as an appendage of the venous system.

Are the thoracic and the great right lymphatic ducts, notwithstanding their small size, the only terminations of the lymphatic system? With this question may be connected another: Are the lymphatics the exclusive agents of absorption, or do they share this function with the veins?

Mascagni appeared to have established, beyond dispute, that absorption was performed by the lymphatics to the exclusion of the veins; when Magendie* and Delille in France,

* It is established, says M. Magendie, that the lacteals absorb the chyle, and that the intestinal veins ab-

Tiedemann and Gmelin in Germany, and Flandrin and Emmert in England, relying upon some ingenious experiments, again attributed a power of absorption to the veins, and hence led other anatomists to undertake still farther researches.

The inquiry was soon entered upon by M. Fohmann in 1820 and 1821, by M. Lauth in 1824, and by M. Lippi in 1825, all of whom again referred the phenomena of absorption exclusively to the lymphatics, and supported that opinion both by arguments and facts.

MM. Fohmann and Lauth admit two other modes of termination of the lymphatic system in the veins besides the one already indicated: first, a direct termination of the lymphatic radicles in the radicles of the veins, which is supposed to occur in the substance of organs; and, secondly, a communication between the lymphatics and veins within the lymphatic glands. This opinion, which seems reconcilable with the fact that the area of the thoracic and right lymphatic ducts is very small as compared with that of all the lymphatic vessels, appears, *à priori*, to be exceedingly probable.

But an anatomical fact must be shown anatomically before it can be admitted. Now there is no proof of the communication of the lymphatic and venous radicles. M. Fohmann relies upon certain more or less ingenious inductions, but not upon direct anatomical facts. I am, therefore, still compelled to doubt the existence of these communications, and to class them with the vasa serosa, or serous veins of Haller.

Again, a communication between the lymphatics and the veins in the substance of the lymphatic glands had been conjectured by many anatomists; the elder Meckel had seen mercury, when thrown into the lumbar lymphatics, pass into the abdominal veins; but this fact was attributed to rupture in the interior of the glands.—(*Hewson, Cruickshank.*) This apparent communication had also frequently been observed by Mascagni, and was attributed by him to rupture.

M. Fohmann urges in reply, that this communication takes place under too slight a pressure to be referred to rupture, that actual extravasations may be easily recognised, and that the mercury is then infiltrated into the cellular tissue with much greater facility than it can enter the veins. "Why," he asks, "supposing the existence of rupture, does the mercury never pass from the lymphatics into the arteries?" He also adduces in support of his opinion a considerable number of facts, which show that injections thrown into the lymphatic glands sometimes escape by the lymphatics alone, sometimes by the veins alone, and sometimes by both the lymphatics and the veins. He states that, having emptied the veins passing out from a mesenteric gland in a horse which had been killed while digestion was going on, and having replaced the intestines in the abdomen, he found some streaks of chyle in the veins. Lastly, he has seen, in birds, the renal lymphatic vessels, which represent the lymphatic glands in those animals, opening directly into the renal and sacral veins. M. Lauth has repeated these experiments, and obtained the same results. But, however imposing the authority of the authors just cited may be, I must confess that I am far from being convinced, and that the facts stated by them do not appear to me to be conclusive. I have made a great number of injections of lymphatics, and in by far the greater number of cases the mercury passed from the afferent into the efferent lymphatic vessels, and not at all into the veins. In some cases, it passed from the glands into the veins; but it appeared to me that the glands had then undergone a change in their texture, more particularly a red softening.

It does not seem to me, then, to be shown that there is any direct communication between the lymphatics and the veins within the substance of the lymphatic glands.

Lippi (of Florence) denies the communication of the lymphatics with the veins within the lymphatic glands; but believes that, besides the terminations of the lymphatics in the venous system through the thoracic duct and the great right lymphatic trunk, there are a great number of direct communications between the lymphatics and the vena portæ, the internal pudic and the renal veins, and the vena cava ascendens and vena azygos.

Several anatomists, indeed, had already met with lymphatic vessels opening directly into the venous system; among whom were Walœus, Wepfer, Abraham Kaw, Hebenstreit, the elder Meckel, Caldani, and Vrolyk; but the isolated facts recorded by them were regarded by Haller, Mascagni, and Sœmmering as anomalies, or as the results of rupture.

The memoir published by Lippi excited new investigations on all sides. I was the more inclined to subscribe to the opinions of that observer, because, in 1825, I had most distinctly seen a large lymphatic trunk opening directly into the external iliac vein; because it appeared to me rational to admit that the communications between the lymphatic and venous systems would not be restricted to the internal jugular and sub-clavian veins; because the communications supposed to exist by Fohmann and Lauth had not been demonstrated; because ligature of the thoracic duct does not prove fatal to all animals subjected to that experiment, even when the duct is single; and, lastly, because the thoracic duct has been found obliterated in many individuals. There seemed, besides, a difficulty in admitting that the thoracic and right lymphatic ducts formed the termination

sorb other substances. It is shown that the veins are the absorbing agents in other parts of the body, but it is not shown that the lymphatics absorb. Some authors have stated that the veins absorb only when the lymphatic system is diseased.

of the whole of the lymphatic vessels. It appeared, moreover, at variance with the general laws of the animal economy to suppose that two sets of organs should be devoted to the same functions; for, if the veins absorb, the lymphatic system would seem to have no special use.

Nevertheless, truth compels me to state that, after the most minute and frequent researches which I have been able to make, I have not obtained a single result confirmatory of the statements of M. Lippi; and that, with his plates before me, I have searched for the communications in all the points which he has indicated, and have never found any. I am, therefore, obliged to conclude, with MM. Rossi, Fohmann, and others, that the vessels which M. Lippi has described as lymphatics opening into different parts of the venous system are nothing more than veins.

Structure of the Lymphatics.

The lymphatics, as well as the veins, have two coats. This structure can be readily shown in the thoracic duct of the human subject, and still better in that of the horse: the existence of these two coats may also be shown by a method suggested by Cruickshank, which consists in turning the thoracic duct inside out, and forcibly introducing a tube into it; the lining membrane, which is then on the outside, being less extensible than the external coat, becomes lacerated.

The *external coat* is considered to be fibrous by some, and muscular by others. Sheldon says that he has distinctly seen muscular fibres arranged circularly around the thoracic duct of the horse. It appears to me that this external coat resembles the dartoid tissue, like the outer coat of the veins. It is not uninteresting to remark, that the outer surface of the lymphatics is often covered by a thin layer of fat, which has deceived several anatomists.

The *internal coat* of the lymphatic vessels appears to be of a serous nature, like that of the veins. Some arterial and venous twigs ramify in their parietes; but no nerves have yet been traced into them. Minute lymphatics probably arise from the coats of the larger ones. Mascagni believes that their lining membrane is entirely lymphatic.

Notwithstanding their excessive tenuity, the lymphatics are tolerably strong; less so, however, than is generally stated, for they are often lacerated by the weight of a small column of mercury. They do not appear to me to be stronger than the veins. They are much less extensible. When the thoracic duct, or any other lymphatic vessel, is punctured, it immediately collapses, and forces out its fluid contents sometimes in a jet. Some admit the existence of muscular contractility in them. The vermicular motion caused by contraction of their external coat is sufficient to explain the above-named fact.*

The lymphatics are much more abundantly supplied with valves than the veins. The valves (*a a*, *fig.* 224) are parabolic, and are arranged in pairs; they have an adherent border turned towards the commencement, and a free border towards the termination of the vessel; they are generally situated at very short intervals apart, as is shown by the knotted appearance of the vessels (see *fig.* 224), and occasionally they present a circular or annular arrangement, from which they have been regarded as true sphincters.

Fig. 224.

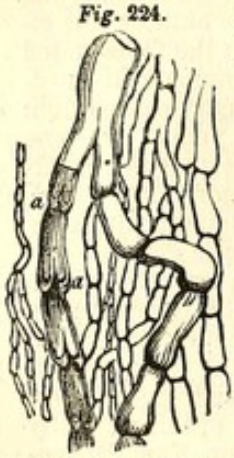

In general, these valves are strong enough to prevent the retrograde course of the lymph, and, consequently, of injections also. Nevertheless, Hunter inflated all the lacteals from the thoracic duct; Haller filled all the lymphatics of the lung from the upper part of the same canal, and Marchettis says that he has injected the whole of the lymphatics from the reservoir of Pecquet. The valves are extremely numerous in the lymphatics; they have sometimes appeared to me to be wanting in the thoracic duct. Like those of the veins, the valves of the lymphatic vessels appear to be formed by a fold of the internal membrane.

The Lymphatic Glands.

Sylvius was the first to distinguish the lymphatic glands under the term *conglobate glands*, from the glands properly so called, which he named *conglomerate*. Chaussier called these little bodies *lymphatic ganglia*, following Sœmmering, who first pointed out the analogy between them and the venous ganglia.

The lymphatic glands are situated along the course of the lymphatic vessels, in reference to which they may be regarded as centres in which a certain number of the vessels open; those of the extremities are chiefly found at the upper part of the limbs on the aspect of flexion; those of the thorax, the abdomen, the head, and the neck are placed along the vertebral column and the great vessels; they are found also in the substance of the mesentery, in the mediastina, at the roots of the lungs, &c.

* [The lacteal vessels have been seen to undergo a *slow* contractility on exposure to air, or to the action of any other stimulus; but there is no evidence of the muscularity of any part of the lymphatic system of mammalia. In certain reptilia and amphibia there are pulsating muscular sacs connected with the lymphatic system, which are called *lymphatic hearts*.]

Their *size* varies from that of a millet seed to that of a large filbert. The smallest are situated in the epiploon, the largest at the roots of the lungs. They are often greatly enlarged by disease. They are generally of a reddish-gray *colour*, excepting at the root of the lungs, when they are black. Their form is irregularly spheroidal; and they have been distinctly shown by Malpighi to have a cellular structure.* If we examine with a lens a lymphatic gland distended with fluid, we observe that it contains cells; the same fact is clearly demonstrated by injecting it with mercury, which shows, moreover, that the cells communicate freely with each other. It is, nevertheless, doubtful whether all the cells communicate. The researches which I have made upon this subject appear to show that each lymphatic vessel is connected with a distinct portion of the lymphatic gland; and diseases of the glands establish the same fact, by attacking one part only of a gland, the rest continuing unaffected.

Several lymphatic vessels enter each gland, and several emerge from it. Each afferent vessel (*a a a*, *fig.* 225), as it reaches the circumference of the gland, divides into a considerable number of branches, which diverge and run for a short distance upon the surface of the gland, and then dip into its substance.† The efferent lymphatics (*b b*) commence in precisely the same manner as the afferent vessels terminate.

Fig. 225.

The study of these vessels in the larger animals appears calculated to clear up all doubts as to the structure of the lymphatic glands. Abernethy having injected the mesenteric arteries and veins of a whale, saw the fluid run into pouches about the size of an orange; he then injected mercury into the lacteals, and found that it flowed into the same cavities; he therefore concluded that the arteries, veins, and lacteals all opened into the same cavities. This fact appears to confirm the observations quoted by MM. Fohmann and Lauth, relative to the communications of the lymphatics with the veins within the substance of the glands; but the objections already urged against those observations will apply to this one also.

The lymphatic glands are enclosed in a fibrous membrane; I have in vain attempted to find the fleshy coat described by Malpighi, and which he imagined sent prolongations into the substance of these glands.

The lymphatic glands are supplied with very large arteries for their size, and they give off still larger veins: a proper tissue (*d*) appears to enter into their composition.

The lymphatic glands may be said to consist essentially of an inextricable interlacement of lymphatic vessels, their structure having some analogy to that of the corpus cavernosum penis, and to that of the spleen. This opinion is confirmed by reference to the anatomy of birds, in which lymphatic glands exist only in the neck, their place being supplied by plexuses in all other parts.

Preparation of the Lymphatic Vessels and Glands.

I have already said, that in order to inject the network of lymphatics, the pipe should be very superficially introduced into the free cutaneous, serous, or mucous surfaces. When the injection is successful, the mercury passes from this network into the vessels which emerge from it, reaches as far as the lymphatic glands, and even penetrates through several series of them.

The great number and peculiar arrangement of the valves prevents the injection of the lymphatics from the centre towards the extremities; I have attempted to do this several times, without success, by introducing the tube into the thoracic duct.

From the small caliber of the lymphatics, it is necessary to use a capillary tube for these injections. Mercury, notwithstanding the inconvenience of its fluidity, and incapability of being made solid, is the most convenient material for the purpose; the weight of a column of mercury about fifteen or eighteen inches in height affords sufficient power for the injection. Anel's syringe is well adapted for injecting the thoracic duct, which may be filled with a solution of isinglass, or, still better, with milk, which becomes coagulated by the alcohol. The best apparatus for injecting the lymphatics is a glass cylinder, to the lower end of which is adapted a flexible tube, which is terminated by a metal pipe, provided with a stopcock, and supporting a capillary tube of glass, which is better than one made of steel or platinum, like those generally used in Germany. A ring is attached to the upper end of the glass tube, by means of which the apparatus may be suspended: this greatly facilitates the employment of the apparatus.

In order to inject the lymphatics, one of these vessels should be exposed at a greater or less distance from the centre; for example, in the lower extremity, upon either the internal or external malleolus, or, what is still better, over the metatarso-phalangal articulations, in the way practised by Mascagni; the vessel must then be punctured, and the tube introduced into its interior; the stopcock is then opened, and the mercury runs

* See note, *infrà*.

† [Within the gland the lymphatics form a dense network (*c*); when the vessels of which this network is composed are distended, they give the cellular appearance to a section of the gland noticed by Malpighi, Cruickshank, &c.]

as far as the gland into which the vessels opens, and at the same time enters all the vessels which anastomose either directly or indirectly with the one into which the tube is introduced. The vasa efferentia are also soon injected, and if the experiment be continued long enough, the mercury will, in all probability, reach the thoracic duct if no rupture should occur. The internal jugular, sub-clavian, and brachio-cephalic veins of both sides of the body may be previously injected, in order to prevent the mercury entering these vessels by the thoracic duct and its supplemental canals.

We may also have recourse to the following method, on account of its greater facility. Puncture a lymphatic gland with a capillary tube; all the efferent vessels which communicate with the cells thus punctured, and all the other portions of the lymphatic system which communicate with those vessels, will thus be injected. But this method is manifestly defective.

With regard to the choice of subjects, it may be remarked that the lymphatics are much more easily seen when the cellular tissue is moderately infiltrated than when there is extreme emaciation. Fat subjects are the worst of all: adults are preferable to children and old subjects.

In describing the lymphatics, I shall follow the same arrangement as Mascagni, with some slight modifications. Thus, after having described the thoracic duct and the great right lymphatic trunk, I shall notice in succession all the lymphatic vessels which enter it, beginning with those of the lower extremities. I shall not describe the vessels and glands separately, but I shall group the vessels around the glands, as around central points towards which they all converge.

DESCRIPTION OF THE LYMPHATIC SYSTEM.

The Thoracic Duct—the Right Thoracic Duct.—The Lymphatic System of the Lower Extremity—of the Pelvic and Lumbar Regions—of the Liver—of the Stomach, Spleen, and Pancreas—of the Intestines—of the Thorax—of the Head—of the Cervical Regions—of the Upper Extremity and Upper Part of the Trunk.

The Thoracic Duct.

Dissection.—The thoracic duct may be examined, when distended with chyle, in an animal killed during the process of digestion. If it is to be injected in the human subject, turn the intestines to the left and the liver to the right; seek for the reservoir of Pecquet (*receptaculum chyli*) between the aorta and the right crus of the diaphragm; follow one of the lymphatic trunks leading from this reservoir to the lumbar glands, and puncture it with the injecting tube. Care must be taken to tie the left sub-clavian vein both on the inside and on the outside of the termination of the internal jugular vein; or, still better, first fill the sub-clavian and internal jugular veins with a solid injection. If we wish to make a preparation to be preserved, it is much better to inject the thoracic duct with isinglass size by an Anel's syringe than to use mercury.

The *thoracic duct* (*s t t u*, *fig.* 223), so called from its situation, is the common trunk of all the lymphatics of the human body, excepting those of the right side of the head, neck, and thorax, and of the right upper extremity.

It commences opposite the second lumbar vertebra, by the junction of a variable number of branches: Meckel says there are three, but I have generally found five or six. These vessels, which are usually of large size, pass out from the abdominal lymphatic glands; they all converge towards a dilatation or ampulla of a triangular shape, which is called the *reservoir* or *cistern of Pecquet* (cisterna, receptaculum chyli, *s*, *fig.* 223), after the anatomist who showed that the lacteals did not pass to the liver, as was generally believed, in accordance with the opinion of Aselli, but that they entered the thoracic duct.

This ampulla, which is often nothing more than the point at which the lymphatic vessels meet, and presents no dilatation, is situated to the right of and behind the aorta, immediately below the aortic opening in the diaphragm, and by the side of the right crus of that muscle.

Having commenced thus, the thoracic duct passes vertically upward, enters the thorax through the aortic opening in the diaphragm, and becomes situated in the posterior mediastinum (*t t*), in front of the vertebral column, a little to the right of the median line, and has the vena azygos (*a a'*) on its right side, and the aorta on its left. Having reached the front of the fourth dorsal vertebra, it inclines towards the left, still continuing to ascend, passes behind the aorta, gains the left side of the œsophagus, runs along behind and on the inner side of the left sub-clavian artery, and escapes through the superior opening of the thorax; having arrived behind the left internal jugular vein, and in front of the seventh cervical vertebra, it immediately bends forward, so as to form an arch (*u*) like that of the aorta, and finally opens into the angle formed by the junction of the left internal jugular and sub-clavian veins, or sometimes into the sub-clavian vein externally to that angle. The direction of the thoracic duct is not straight, but flexuous: its windings are sometimes very numerous.

From the relations of the thoracic duct while within the posterior mediastinum, it fol-

lows that, in order to expose its lower portion, it must be sought for on the right side of that cavity, and that we must look for its upper portion on the left side, and must divide the left layer of the mediastinum in order to expose it.

The thoracic duct terminates in many different ways: thus, it not unfrequently opens by several trunks into the left internal jugular and sub-clavian veins. A still more frequent method of termination, and one which it is extremely important to know, is that in which the duct, at its upper part, is divided into two branches, the left one of which (*u*) is distributed in the usual manner, while the right (indicated by a smaller letter *u*) opens into the right sub-clavian vein in connexion with the great lymphatic duct of the right side.

The *caliber* of the thoracic duct is not at all proportioned to the number and size of the lymphatics which terminate in it. Sometimes, in fact, lymphatics are found which, when distended, are as large as a goose-quill. Still less is it proportioned to all the lymphatics of the body, of which it is regarded as the common trunk. Its caliber is even smaller than that acquired by some lymphatics under many circumstances; for example, by those of the uterus during pregnancy: this is a powerful argument in favour of those who regard the thoracic duct as by no means corresponding to all the lymphatics of the human body.

The thoracic duct is not of uniform caliber in its entire length. It commences by a dilatation of two or three lines in diameter; in the middle of the thorax it becomes contracted to less than two lines in diameter, and it is again dilated a little at the arch which it forms before its termination.

The thoracic duct not unfrequently divides, during its course, into several branches, which form a sort of network; it often subdivides into two branches of unequal size, which unite again after a variable distance.

The thoracic duct receives, while in the thorax, a very large trunk, which is derived from the liver, and perforates the diaphragm through a special opening. I have seen this trunk cross and continue in front of the thoracic duct, being equal to it in size, and at last enter it opposite the fifth dorsal vertebra.

The thoracic duct has been observed to end on the right side, and then the lymphatics of the left side of the head, left upper extremity, left lung, and left side of the heart, entered separately into the sub-clavian vein of the corresponding side. Meckel has correctly observed, that such a disposition is a first trace of the lateral transposition of the viscera.

Valves.—Of all parts of the lymphatic system, the thoracic duct has the fewest and the smallest valves. The most remarkable are those situated at its termination in the sub-clavian vein; their free borders are turned towards the vein, so that they oppose any influx of the venous blood into the thoracic duct. The free borders of the other valves, when they exist, are turned upward, their convex borders being directed downward: the course of the fluid within the duct is, therefore, from below upward.

The Right Thoracic Duct.

The great right lymphatic duct, or *right thoracic duct*, is a large vessel, the common trunk of all the lymphatics derived from the right half of the head and neck, the right upper extremity, the right lung, the right side of the heart, and often, also, of those from the right half of the diaphragm and of the liver. This trunk (*v*, *fig.* 223), which is not more than an inch long, resembles the curved portion of the thoracic duct; it opens at the angle formed by the junction of the right internal jugular and sub-clavian veins.

Sometimes this common trunk does not exist, and then the lymphatics, by the junction of which it is usually formed, enter the veins separately. Anastomoses always exist, moreover, between the left and right thoracic ducts.

The Lymphatic System of the Lower Extremity.

The Lymphatic Glands of the Lower Extremity.

The lymphatic glands of the lower extremity are the *anterior tibial gland*, the *popliteal gland*, and the *inguinal glands*.

The *anterior tibial gland* is situated at a variable height in front of the interosseous ligament, generally at its upper part. Hewson has seen it below the middle: Meckel has found two glands here; but the existence even of one gland is not constant.

The *popliteal glands* are four in number; one of them is situated immediately beneath the fascia; the other three are placed deeply at variable heights along the vessels of the popliteal space: they are rather small.

The *inguinal glands* are the most numerous and important; they are situated in the fold of the groin, below Poupart's ligament, and are generally grouped around the entrance of the internal saphenous into the femoral vein, in a sort of depression formed between the adductor longus and pectineus on the inside, and the psoas and iliacus on the outside. They are not unfrequently continued along the internal saphenous vein as low down as the middle of the thigh. They are divided into *superficial* and *deep*. The latter are very variable in size and number, and are often wanting: they are sometimes

continuous with the superficial, through the saphenous opening in the fascia lata. The number of the superficial glands also varies much: it is nearly always inversely proportioned to the size of the glands, which is also subject to great variety in different individuals and at different ages. There can be no doubt that these differences in number and in size depend, *cæteris paribus*, no less upon actual differences than upon the subdivision of one gland into several, or, rather, upon the union of a certain number of glands into one. Sometimes we find a large circular gland situated around the termination of the saphenous vein. The inguinal glands, moreover, are placed at different depths in the substance of the fibrous layers which constitute the *superficial fascia*. Several of these glands are frequently united to each other, not only by lymphatic vessels, but also by prolongations of their proper substance.

The Lymphatic Vessels which enter the Lymphatic Glands of the Lower Extremity.

Preparation.—Introduce the pipe into some of the lymphatic vessels between the toes, over the metatarso-phalangal articulations. Mascagni employed this method, which is as easy as introducing the pipe into the vessels which run between the internal malleolus and the skin. A still better method of injection, when it proves successful, is to fill the lymphatic network in the skin by introducing the pipe into the dermis at any point beneath the cuticle. But the limb requires to be warmed for this injection to succeed. I have made a very beautiful preparation by injecting the cutaneous network of lymphatics upon the sole of the foot in a new-born infant. The mercury ran as far as the glands situated along the iliac vessels.

If the pipe be inserted into the skin upon the scrotum, or into the mucous membrane covering the glans penis in the male, or into the skin of the labia majora in the female, the mercury will reach the lymphatic glands of the groin.

The lymphatics which ramify in the gluteal region, and those situated in the sub-cutaneous cellular tissue of the abdominal parietes, may be injected in the same manner.

The deep lymphatics of the leg open into the anterior tibial gland and popliteal glands. All the superficial lymphatics of the lower extremity, and also those of the gluteal region, perineum, external genital organs, and sub-umbilical portion of the parietes of the abdomen, terminate in the inguinal glands.

Lymphatics of the Lower Extremities.—The lymphatics of the lower extremities, like the veins, are divided into superficial and deep.

The *deep-seated lymphatics* are fewer in number and less accurately known than the superficial; they accompany the deep-seated bloodvessels. It is probable that every arterial and venous branch has its corresponding lymphatics; but those only which accompany the great vessels have been as yet discovered. They are divided into the peroneal, the anterior and posterior tibial, and the femoral.

Of the *anterior tibial lymphatics*, two only have been demonstrated, although their number must certainly be greater. One of these accompanies the plantar arch, the dorsal artery and vein of the foot, and the anterior tibial vessels; it communicates with the posterior tibial and the peroneal lymphatics, opposite the upper part of the interosseous ligament, and enters the anterior tibial gland, or more frequently perforates the interosseous ligament, and enters the popliteal glands.

The other anterior tibial lymphatic arises deeply from the outer side of the foot, and joins the preceding.

The *posterior tibial lymphatics*, two or three in number, and likewise the *peroneal* lymphatics, sometimes unite into a single trunk, and enter the popliteal glands.

The branches which emerge from the popliteal glands, five or six in number, traverse the opening in the adductor muscle, ascend along the femoral vein, and open into the deep inguinal glands.

The *superficial lymphatics*, which can be very easily shown to arise from a network in the skin, run upward and inward, to reach the inner side of the leg, and then pass behind the internal condyle of the femur: those which arise from the outer side of the foot and leg, after ascending vertically in front of the muscles of the anterior region of the leg, cross over the upper part of the tibia obliquely from without inward, so that all the superficial lymphatics at last gain the inner and back part of the internal condyle of the femur: from this point they incline forward like the sartorius, upon which they are placed, and then pass vertically upward, and are distributed to the different lymphatic glands of the groin.

A certain number of lymphatic vessels which commence upon the outer border of the foot (there are not more than two or three) pass over the external malleolus to reach the external saphenous vein, become sub-aponeurotic like that vein, and enter the most superficial of the popliteal glands. These lymphatics, which accompany the external saphenous vein, are regarded by some authors as forming part of the deep set of vessels.

Superficial Lymphatics of the External Genital Organs, Gluteal Region, Perineum, and

Lower Part of the Abdomen.—The superficial lymphatic vessels from these parts also enter the inguinal glands.

The *superficial lymphatics* of the *external genital organs of the male* are divided into those of the scrotum and those of the penis. If the skin of the scrotum be injected, several sub-cutaneous branches will be seen to pass from the network beneath the epidermis upward along the sides of the penis, and then, after describing a curve with the concavity directed downward, to open into the inguinal glands, generally into those which are nearest the middle line, but I have seen them pass to the glands surrounding the saphenous opening. If we inject the skin of the penis, and more especially the membrane covering the glans, the mercury penetrates into the dorsal lymphatics of the penis, and reaches the innermost and highest of the inguinal glands. The injection from the skin of the penis enters the superficial lymphatics; the injection from the membrane covering the glans enters only those superficial lymphatics which accompany the dorsal blood-vessels of the penis.

In the female, injections of the skin of the labia majora, and of the mucous membrane of the labia majora, labia minora, and clitoris, yield similar results as the injection of the scrotum and penis in the male. We know that diseases of the labia, nymphæ, and clitoris, like those of the prepuce, penis, and scrotum, occasion enlargement of the inguinal lymphatic glands.

The *lymphatics of the perineum* unite with the preceding, and with the lymphatics of the lower extremities.

The *superficial lymphatics of the gluteal region* turn horizontally round the glutæus maximus and medius, and enter the external and middle lymphatic glands of the groin. This is the reason why furunculi or other diseases of the skin upon the nates may give rise to enlargement of the inguinal glands.

The *superficial lumbar lymphatics*, as well as those of the *sub-umbilical portion* of the abdominal parietes, have a descending course: those of the loins run forward and downward, those of the abdomen vertically downward; they both terminate in the outermost and highest of the inguinal glands; and hence diseases of the skin covering the lumbar and sub-umbilical regions may occasion swelling of the inguinal glands.

The lymphatic vessels which accompany the epigastric and circumflex iliac veins also enter the glands of the groin.

The Lymphatic System of the Pelvic and Lumbar Regions.

The Pelvic and Lumbar Lymphatic Glands.

The lymphatic glands of the pelvis are divided into the *external iliac*, the *internal iliac*, and the *sacral*.

The *external iliac lymphatic glands*, irregular in number, are situated along the artery of that name. Three of them require to be particularly noticed; they are situated immediately behind the femoral arch, one of them on the outer side, another in front, and the third on the inner side of the external iliac vessels. It is important, in reference to the ligature of the external iliac artery, to know that these lymphatic glands are subject to enlargement.

The *internal iliac lymphatic glands* occupy the space between the external and internal iliac vessels. The bladder has proper lymphatic glands situated upon its posterior surface, and near its summit. In the female, some of the pelvic lymphatic glands may be regarded as belonging to the vagina and uterus. One tolerably large gland, which may be said to be constant, occupies the internal orifice of the obturator canal, and I have often found it inflamed or indurated in diseases of the uterus.

The *sacral lymphatic glands* occupy the sides of the anterior surface of the sacrum: several of them are situated within the folds of the meso-rectum, and belong to the rectum itself.

The *lumbar* or *aortic lymphatic glands* are very numerous, and form a continuous chain with the pelvic glands; they occupy the angular interval between the common iliac arteries, being placed along those arteries themselves, and also surround the aorta and the ascending vena cava, but more particularly the aorta. It is important to note the relation of these lymphatic glands with the aorta, for that vessel is sometimes found much compressed and narrowed from enlargements of these glands by tubercular or cancerous deposite.

There is also a lymphatic gland in each inter-transverse space on both sides of the lumbar region; so that the lumbar lymphatic glands may be divided into the *median* and the *lateral*.

The Lymphatic Vessels which enter the Pelvic and Lumbar Lymphatic Glands.

The different lymphatic vessels which proceed from the inguinal glands enter the pelvis behind the femoral arch, and near the femoral vein. The foramina through which they pass are so numerous, that the fascia which is perforated by them is named the *cribriform fascia*. Having arrived beneath the peritoneum, they are divided into two

sets, one of which descends into the cavity of the pelvis, and terminates in the several internal iliac lymphatic glands; while the other enters the external iliac glands, and more particularly those situated behind the femoral arch. These external iliac glands, moreover, are joined by the *epigastric lymphatics*, some of which enter the inguinal glands, and by the *ilio-lumbar lymphatics*.

The lymphatic glands of the pelvis also receive the deep lymphatics of the nates, which accompany the gluteal and sciatic arteries; the lymphatics corresponding with the obturator vessels; the lymphatics of the bladder and lower end of the rectum, those of the prostate and vesiculæ seminales, and the deep lymphatics of the penis in the male, and those of the vagina, clitoris, and neck of the uterus, in the female. The lymphatics of the bladder, before entering the pelvic glands, traverse the glands proper to itself: the greater number of the lymphatics of the bladder run beneath the peritoneum upon its posterior surface. I have seen the vesical lymphatics filled with pus. Some other lymphatics emerging from the internal iliac glands accompany the external and internal iliac arteries and veins, ascend in front of the sacrum, pass through other lymphatic glands, and arrive at the brim of the pelvis. At this point, the lymphatics of the right and left sides unite together. These vessels pass through one or several series of lumbar lymphatic glands, and at last open into the thoracic duct. This collection of lymphatic vessels and glands forms the internal and external iliac lymphatic plexuses. The internal iliac lymphatic plexus is placed in the cavity of the pelvis, and surrounds the internal iliac vessels: the external iliac lymphatic plexus is situated along the vessels of that name.

All the lymphatics of the lower extremities, after having passed through a greater or less number of glands, open at last into these lumbar glands, so that the vessels and glands together may be said to form an uninterrupted chain. Thus, passing from plexus to plexus, and from gland to gland, the lymphatics of even the most distant parts arrive, at length, at the thoracic duct.

The *lateral lumbar lymphatic glands*, viz., those which occupy the spaces between the transverse processes of the lumbar vertebræ, receive the lumbar lymphatics, properly so called, which correspond to the bloodvessels of that name. From these glands, communicating vessels pass to the aortic lumbar glands. The collection of lymphatic vessels and glands occupying the lumbar region is called the lumbar lymphatic plexus. The following lymphatic vessels also enter directly into the lumbar glands: the lymphatics of the testicles in the male; the lymphatics of the ovaries and Fallopion tubes, and also of the body and upper part of the neck of the uterus, in the female; and the lymphatics of the kidneys in both sexes.

The Lymphatics of the Testicle.—It has been already stated that the lymphatics of the covering of the testicle enter the superficial inguinal glands; those which belong to the gland itself are divided into the *superficial* and *deep*. The superficial lymphatics may be injected with the greatest facility by puncturing the serous membrane covering the tunica albuginea; the tunica vaginalis will then appear as if covered with a coat of silver. (See the beautiful plates of Panizza.) These superficial vessels have numerous communications with the deep-seated lymphatics, so that both sets are injected at the same time. All the lymphatics from the epididymus and the body of the testicle, which are very numerous and large, ascend with and assist in forming the spermatic cord, pass through the inguinal canal, follow the course of the spermatic vessels, and enter the lumbar lymphatic glands.

The Lymphatics of the Uterus.—Having, in diseases of the uterus incidental to the puerperal state, frequently detected pus in the lymphatics of the uterus (vide *Anat. Path.*, liv. xiii., pl. 1, 2, 3), I have been able to trace the exact distribution of these vessels, and would divide them into *superficial* and *deep*. The superficial lymphatics are situated immediately under the peritoneum; the deep lymphatics form several successive layers, which occupy different planes within the substance of the uterus. The lymphatics near the neck of this organ enter the pelvic and sacral lymphatic glands. A certain number of the uterine lymphatics enter a lymphatic gland situated at the internal orifice of the obturator canal.

All the uterine lymphatics, excepting those near the neck of that organ, pass towards the sides and upper border of the uterus; some run within the substance of the broad ligaments, and they all reach the upper or tubal angles of the viscus. They are joined by the lymphatics of the *ovaries*, *broad ligaments*, and *Fallopian tubes*, and then ascend in front of the corresponding ovarian artery and veins. Having arrived in front of the lower part of the kidneys, they incline towards the middle line, and enter the glands which are situated in front of the vena cava and aorta. Without having witnessed it, it is impossible to form any idea of the enormous size which the uterine lymphatics may acquire during pregnancy: several of these vessels, when filled with pus, become so dilated that one would at first sight believe that an abscess had been formed.

The Lymphatics of the Kidneys and Supra-renal Capsules.—These are divided into *superficial* and *deep*. The superficial lymphatics have never been injected directly; but if a fine injection be thrown into the renal arteries and veins, the injection, freed from col-

ouring matter, passes into the lymphatics. This was the only way in which Mascagni could inject the superficial lymphatics of the kidney, which he has represented in his beautiful plates.

The deep lymphatics, which are very numerous, pass out of the fissure of the kidney, and enter the glands in front of and behind the aorta and vena cava.

The lymphatics of the *supra-renal capsules* are remarkable for their size and number; they unite with those of the kidneys, and terminate in the same manner.

The Lymphatic System of the Liver.

Preparation.—Of all the lymphatic vessels, those of the liver are the most easily demonstrated. Before they are injected, they may be rendered more apparent, and even be filled, by throwing water either into the hepatic arteries, the vena portæ, the hepatic veins, or the hepatic ducts. In order to inject them, it is sufficient to make a superficial puncture in any part of the peritoneum covering the liver; but it is most convenient to operate upon one of the lymphatic trunks which run upon the surface of that organ. It is of importance that the tube should be introduced between the peritoneal covering and the fibrous coat, without perforating the latter. It is sufficient to inject from a single vessel in order to fill all the others. The mercury generally runs as far as the nearest lymphatic gland, the resistance in which causes the fluid to flow back into the surrounding branches, even as far as their most delicate ramifications, so that, in successful injections, the whole surface of the liver has a silvery aspect; the possibility of injecting the lymphatics of the liver, from the trunks towards the branches, must lead us to suppose that there are fewer valves in them than in the lymphatics of other parts of the body.

The Lymphatic Glands of the Liver.

These are situated along the hepatic vessels, behind the pylorus, and are continuous with the cœliac lymphatic glands. I have seen them of a jet-black colour; a liquid may be expressed from them, resembling that contained in the bronchial lymphatic glands.

The Lymphatic Vessels of the Liver.

The lymphatics of the liver may be divided into the *superficial* and the *deep*.

The Superficial Lymphatics.—These are subdivided into those of the convex and those of the concave surface.

The *lymphatics of the convex surface* of the liver consist of a certain number of trunks, some of which belong to the right and the others to the left lobe. Some of them run from behind forward, others from before backward, towards the posterior border of the organ.

The first set, or those which run from behind forward, reach the suspensory ligament of the liver, and unite into several trunks, some of which perforate the diaphragm, enter the anterior mediastinum, behind the xiphoid cartilage, and terminate in the mediastinal lymphatic glands; while others are reflected over the anterior margin of the liver, to gain the longitudinal fissure, along which they run as far as the gastro-hepatic omentum, by which they are conducted to the lymphatic glands placed round the pylorus, to those around the cardiac orifice of the stomach, and to those which lie along the lesser curvature of that organ, and near the lobulus Spigelii.

The second set of the lymphatics of the convex surface of the liver, or those which run from before backward, having reached the posterior border of the liver, divide into three distinct groups of vessels: those on the left enter the substance of the left triangular ligament of the liver; those on the *right* pass into the right triangular ligament; while the remainder, which occupy the middle, enter the substance of the coronary ligament.

Those lymphatics of the second set that do not perforate the diaphragm enter the lymphatic glands along the vena cava, and from thence reach the thoracic duct. Some of them run along the lower border of the twelfth rib, and open into the glands situated near its posterior extremity, and into another gland which rests upon the twelfth dorsal vertebra.

Those lymphatics of the second set which do perforate the diaphragm pass through its crura, and proceed, some to the intercostal lymphatic glands, or into those which lie along the vena azygos and the aorta, and thence into the thoracic duct; while others enter that duct directly. I have seen a very large lymphatic trunk open directly into the thoracic duct, opposite the fifth dorsal vertebra. Mascagni pointed out some lymphatic vessels which, after having perforated the fleshy fibres of the diaphragm, ran between the pleura and that muscle, re-entered the abdomen through the aortic opening in the diaphragm, and then passed into the glands surrounding the aorta and vena cava, or entered the thoracic duct at no great distance from the reservoir of Pecquet, without passing through any lymphatic glands.

The *lymphatics of the concave surface of the liver* consist of several trunks, which are all directed from before backward, and are divided into three sets: those which are situated to the right side of the gall-bladder; those which surround it; and those which are situated to its left side.

Those situated on the right of the gall-bladder partly enter the lumbar glands, and partly terminate in the glands around the vena cava and aorta.

Those which surround the gall-bladder form a remarkable plexus, which accompanies the hepatic vessels, and terminates in the lymphatic glands which lie along those vessels, and in the glands situated in the substance of the gastro-hepatic omentum. Among this set of lymphatics I would point out one considerable trunk, which runs in the cellular tissue connecting the gall-bladder to the liver.

The lymphatic trunks on the left of the gall-bladder end in the œsophageal lymphatic glands, and in those which occupy the lesser curvature of the stomach.

The Deep-seated Lymphatics of the Liver.—These vessels accompany the hepatic ducts and the vena portæ, and are contained with them in the capsule of Glisson; they emerge from the transverse fissure of the liver, penetrate the substance of the gastro-hepatic omentum, and enter the lymphatic glands situated along the lesser curvature of the stomach and behind the pancreas.

Those lymphatics of the liver which accompany the hepatic artery and duct and the vena portæ are extremely large, and are often filled with yellow lymph: they are sometimes found distended with gas in cases of commencing putrefaction. They were known long before the lacteals; indeed, they were the first lymphatic vessels that were discovered.

The Lymphatic System of the Stomach, Spleen, and Pancreas.

The Lymphatic Glands of the Stomach, Spleen, and Pancreas.

Those of the stomach accompany the coronary vessels along the great and lesser curvatures of the stomach; some of them are situated within the gastro-splenic omentum, and a great number surround the pyloric and cardiac orifices.

The lymphatic glands of the spleen occupy the hilus of that organ.

The *pancreatic lymphatic glands* are ranged along the splenic artery, and, consequently, along the upper border of the pancreas; several of them are grouped around the cœliac axis. They receive a very great number of lymphatic vessels.

The Lymphatic Vessels of the Stomach, Spleen, and Pancreas.

The lymphatic vessels of the *stomach* are divided into the *superficial* and *deep*.

The *superficial* lymphatics form a network beneath the peritoneum; the deep lymphatics arise from an equally complex network situated in the mucous membrane. They follow different directions: a great number of them pass to the great curvature, and enter the glands situated there; others proceed to the lesser curvature, and pass through the glands in that situation. Several run towards the spleen, and enter the splenic lymphatic glands; and, lastly, others go to the lymphatic glands around the pylorus.

It has been stated that the lymphatics of the stomach have been seen filled with chyle: this is at least doubtful.

The Lymphatics of the Spleen.—The superficial lymphatics of this organ cannot be seen unless the splenic bloodvessels have been previously injected with size injection: the size freed from the colouring matter will pass into them. I have seen tallow, thrown into either the arteries or veins of the spleen, pass into the superficial lymphatics. It is true that the injection was made forcibly, and kept up for some time. The deep lymphatics of the spleen are not known.

The proper lymphatics of the *pancreas* are little known.

The Lymphatic System of the Intestines.

The Lymphatic Glands of the Intestines.

The *lymphatic glands of the small intestine*, or the *mesenteric glands*, are extremely numerous. Several anatomists, who have had the patience to count them, have arrived at very different results, partly on account of individual varieties, and partly because several, having chosen tuberculated subjects for the purpose, have mistaken the tubercles for lymphatic glands.

The mesenteric glands are situated between the folds of the mesentery, in the meshes of the network formed by the arteries and veins. Those which are nearest to the intestine are found in the intervals observed between the vessels of the mesentery close to the intestine. Those which are most distant from the intestine are situated near the adherent border of the mesentery, along the trunk of the superior mesenteric artery. The largest of these glands are found near the origin and termination of that artery. Thus we find, below, a group of large lymphatic glands, the *ileo-colic*, opposite the termination of the ileum in the colon. Another cluster, named the *duodenal*, is situated above, in front of the duodenum: they are extremely large. We generally find one larger than the rest: it is represented in the oldest works on anatomy, and has been sometimes mistaken for the pancreas.

The group of *ileo-colic lymphatic glands* is remarkable for frequently becoming inflamed in follicular enteritis.

The *lymphatic glands of the great intestine*, or *meso-colic glands*, much less numerous than those of the mesentery, generally lie along the vascular arches formed by the colic arteries and veins: several of them are situated near the posterior border of the intes-

tine; and some are even found upon the intestine, accompanying those bloodvessels which run for a short distance beneath the peritoneal coat, and then penetrate the muscular coat. The meso-colic lymphatic glands are not nearly so numerous along the transverse colon as along either the ascending or descending colon. Those situated in the transverse meso-colon form an uninterrupted chain with the mesenteric glands.

The Lymphatic Vessels of the Intestines.

The Lymphatics of the Small Intestine.—These vessels are divided into two sets, the *lymphatics*, properly so called, and the *lacteals*.

The *lymphatics*, properly so called, like those of the stomach and great intestine, arise from two sets of networks; one in the serous, the other in the mucous coats. The vessels which pass out from these networks have a remarkable character, which was well described by Mascagni; instead of passing directly into the mesentery, they first proceed for a short distance along the intestine, and then curve and enter the mesenteric glands.

The *lacteals*, or *lacteal vessels of the small intestine*, can be easily seen in an animal that has been killed while the absorption of chyle is going on in the intestine; and they have occasionally been observed in the human subject, in cases of accidental death. They then appear as white, nodulated, and slightly flexuous lines, which communicate occasionally with each other, pass from one mesenteric gland to another, enter the lymphatic glands situated in front of the aorta and vena cava, and terminate in the thoracic duct by a variable number of trunks: the lymphatic plexuses of the left side pass behind the aorta.

The lacteals commence, according to Lieberkühn, upon the summit of each of the villi of the small intestines, run down to its base, and then enter at right angles into the submucous lacteal vessels, which invariably perforate the other coats of the intestine, on its concave border. This arrangement was very evident in a case in which the lacteals were filled with tuberculous matter.—(*Anath. Pathol.*, liv. ii., pl. 2.)*

The Lymphatics of the Great Intestine.—We may, with Mascagni, divide these lymphatics into two sets, according to the glands in which they terminate, viz., those of the cœcum and of the ascending and transverse colon, which pass through the meso-colic lymphatic glands, and then terminate in the mesenteric glands; and those of the descending colon and rectum, which enter the lumbar lymphatic glands together with the lymphatics of the genital organs, and of the lower extremities.

The Lymphatic System of the Thorax.

The Lymphatic Glands of the Thorax.

The thoracic lymphatic glands are divided into those of the parietes of the thorax, those of the mediastinum, and the bronchial or pulmonary glands.

The *lymphatic glands of the parietes of the thorax* are very small, and are thus arranged: the *intercostal glands* are situated on each side of the spine near the costo-vertebral articulations; some are placed between the two layers of the intercostal muscles: they are very small, and irregular in number. The *sub-sternal* or *mammary glands* are found at the anterior extremity of the intercostal spaces near the internal mammary vessels, and applied along the borders of the sternum; there is one for each intercostal space.

The *mediastinal lymphatic glands* are divided into *those of the posterior mediastinum*, which are arranged along the œsophagus and aorta, and form a continuation of the intercostal glands: they have been known to become enlarged and press upon the œsophagus, so as to cause dysphagia; and into those *of the anterior mediastinum*, the principal of which lie upon the diaphragm in front of the pericardium, and around the great vessels connected with the base of the heart.

The *bronchial* or *pulmonary glands* were noticed by the oldest anatomists, and especially by Vesalius, whence the name of *glandulæ Vesalianæ*, by which they are still known: they are remarkable for their situation, number, size, and colour. They are situated along the bronchi and their first divisions. The largest are generally placed opposite the bifurcation of the trachea. The smallest lie within the substance of the lungs, around the first divisions of the bronchi; some of them are seen in the inter-lobular fissures.

Their number is very considerable.

In disease, they may acquire such a size as to compress and narrow the bronchi, and thus prevent the passage of the air through those tubes.

In infancy they do not differ in colour from the other lymphatic glands, but they are black in the adult, and especially in the aged. They are also liable to become the seat of depositions of phosphate of lime.

Senac considers them to be secreting glands quite distinct from the lymphatic glands. Portal divided them into true glands and lymphatic glands; but no one has been able to demonstrate the excretory ducts, which, according to Portal, proceed from the lymphatic glands upon the trachea. The communications between these and the trachea, observed in some cases of disease, are altogether accidental.

* See also note, p. 369.

The Lymphatic Vessels of the Thorax.

The lymphatic vessels of the thorax are divided into those of the parietes and those of the organs contained in the thoracic cavity.

The Lymphatics of the Thoracic Parietes.—We shall here merely notice the deep-seated lymphatics. They are divided into the intercostal, the sub-sternal or internal mammary, and the diaphragmatic.

The *intercostal lymphatics* accompany the arteries and veins of that name; they receive the lymphatic vessels of the intercostal muscles and costal pleura, run along the grooves of the ribs, pass through the intercostal lymphatic glands, reach the sides of the vertebræ, unite with other lymphatics from the back of the thorax and from the spinal canal, enter the lymphatic glands on the sides of the vertebral column, and are for the most part directed downward to terminate in the thoracic duct.

The *sub-sternal* or *internal mammary lymphatics* arise from the supra-umbilical portion of the anterior walls of the abdomen: they pass into the thorax, behind the ensiform cartilage, and form two bundles, which run upon the sides of the sternum, unite with the anterior intercostal and external mammary lymphatics, and enter the internal mammary lymphatic glands. From the lowest of these glands other lymphatics proceed, and ascend in succession from one gland to another up to the inferior cervical lymphatic glands; on the left side they enter the thoracic duct, and on the right, the great lymphatic trunk. Sometimes, but rarely, the mammary lymphatics open directly into the internal jugular and sub-clavian veins.

The *lymphatics of the diaphragm* for the most part unite with the intercostal and hepatic lymphatics; the others run forward between the pleura and the fleshy fibres of the diaphragm; some of them enter the inferior mediastinal glands, and the others, the internal mammary lymphatic glands.

The Lymphatics of the Thoracic Viscera.—The *lymphatics of the lungs* are divided into superficial and deep: the *superficial* lymphatics may be injected in the same manner as those of the liver; they form an extremely close network beneath the pleura pulmonalis, and frequently present a number of, as it were, varicose enlargements: these were noticed and figured by Mascagni; and the frequency of their occurrence led him to inquire whether such was not the natural structure of lymphatics. Some of the vessels which proceed from this network run in the inter-lobular fissures, and enter the lymphatic glands situated at the bottom of these fissures; while the others reach the internal surface of the lung, and terminate in the bronchial glands.

These superficial lymphatics also communicate with the deep lymphatics in the cellular intervals between the lobules of the lung.

The *deep lymphatics of the lung* are very numerous: the manner in which they commence in the lobules is not well known: they run in the inter-lobular cellular tissue, and all proceed towards the root of the lung, in order to terminate in the glands situated around the bronchi, and in several which lie along the œsophagus. It is doubtful whether a single pulmonary lymphatic vessel enters directly into another lymphatic gland without first going through a bronchial gland.

Other lymphatics proceed from these bronchial glands; some of which pass in front of the trachea to enter the tracheal lymphatic glands, while the others proceed to the lymphatic glands upon the œsophagus. On the left side both sets enter the thoracic duct, at a short distance before its termination; these are more numerous than those on the right side, which enter the right lymphatic duct. Some of them terminate in the thoracic duct, before it emerges from the thorax; several of these vessels are also seen to enter the internal jugular and sub-clavian veins.

I should observe that, in consequence of the above-mentioned anatomical fact, the cervical lymphatic glands sometimes become enlarged in diseases of the lungs.

The Lymphatics of the Heart, Pericardium, and Thymus.—The *lymphatics of the heart* are divided into superficial and deep; the *superficial* vessels commence by a sub-serous network, and, for the most part, run along the right border of that organ; the *deep* lymphatics arise from the internal membrane of the heart, in which I have never been able to inject a perfect network: they all accompany the coronary vessels, and all pass out of the pericardium; some of them unite with the lymphatics of the lung; the others enter the glands in front of the arch of the aorta and pulmonary artery, and from thence pass to the thoracic duct.

The *lymphatics of the pericardium and thymus* enter the internal mammary, anterior mediastinal, and bronchial lymphatic glands.

The Lymphatic System of the Head.

The Lymphatic Glands of the Head.

There are more lymphatic glands in the *face* than in the *cranium*.

All the *lymphatic glands of the cranium* are found upon its posterior region: some of them are situated behind the ear, along the attachments of the occipito-frontalis; several are placed beneath the upper end of the sterno-mastoid; they are very small, and often

escape notice in a hasty dissection: they become very distinct in diseases of the scalp.

Are there *any deep lymphatics of the cranium?* The pituitary body, the pineal gland, and the white bodies known as the glandulæ Pacchioni, have been regarded as belonging to the lymphatic system. Some authors have even considered the tubercles, so frequently found in the brains of infants, and which are evidently accidental formations, to be of the same nature. Certain bodies found in the carotid canal, and which are evidently enlargements of the ganglionic nerves, have also been described as lymphatic glands; but this opinion is now completely rejected.

Of the *lymphatic glands of the face*, the largest occupy the base of the lower jaw, and are called the *sub-maxillary* lymphatic glands: several of them are situated upon the outer surface of the maxillary bone, along the facial vessels, in front of the masseter muscle.

We find, also, in the face, the *parotid lymphatic* glands, some of which are superficial and others deep, the latter being situated in the substance of the gland: we find some, also, between this gland and the masseter: lastly, there are the *zygomatic* glands, situated under the zygoma, and the *buccinator* lymphatic glands.

The Lymphatic Vessels of the Head.

These belong either to the *cranium* or to the *face*.

The Lymphatics of the Cranium.—The *superficial* or *sub-cutaneous cranial* lymphatics are divided into two sets: the *temporal lymphatics*, which run along the superficial temporal artery, and pass through the parotid lymphatic glands, from which vessels proceed to the glands in the anterior region of the neck; and the *occipital lymphatics*, which follow the occipital artery, and terminate in the mastoid and the occipital lymphatic glands.

The *deep lymphatics of the cranium*, the *lymphatics of the dura mater*, or the *meningeal lymphatics*, accompany the meningeal vessels, escape through the foramen spinale of the sphenoid bone, and enter the jugular lymphatic glands.

Ruysch appears to have been the first who noticed lymphatics in the brain; he has named them *vasa pseudo-lymphatica*. Mascagni could only show the presence of the superficial lymphatics of the brain by injecting coloured size into the carotid arteries. The size freed from the colouring material passed into the lymphatics.

The lymphatics of the brain are but little known. M. Fohmann has described and figured a lymphatic plexus situated between the arachnoid and pia mater, and precisely resembling those found in other parts of the body. This network dips into the sulci, and appears to be continued into the substance of the brain, where it is no longer possible to follow it. From this network some small lymphatic trunks proceed, and accompany the arteries and veins as far as the foramina, in the base of the cranium, beyond which M. Fohmann was never able to trace them; so that he inquires whether these vessels do not form an exception to the general rule from their want of connexion with the absorbent system generally, and whether they do not enter directly with the veins upon which they are placed. On the other hand, Mascagni has figured some lymphatics around the internal carotid, within the carotid canal, and also around the vertebral arteries and internal jugular vein. The existence of these trunks leads us to suppose that there must be cerebral lymphatics.

M. Fohmann has also found lymphatics in the choroid plexuses of the lateral ventricles of the brain: these vessels were remarkably dilated, so as to present ampullæ.

The Lymphatic Vessels of the Face.—These are divided into the superficial and deep.

The *superficial lymphatics* are much more numerous than those of the cranium. They commence upon all parts of the face; those from the frontal region accompany the frontal vessels: the others accompany the adjacent bloodvessels; several of them pass through the buccinator glands, and they all finally enter the sub-maxillary lymphatic glands. The lymphatics of the face are to be injected by introducing the pipe into the plexus contained in the skin.

The *deep lymphatics of the face* accompany the bloodvessels. They are divided into those of the temporal fossæ, those of the zygomatic and pterygo-maxillary fossæ, and those of the nasal fossæ. The lymphatics of the pharynx, velum palati, mouth, tongue, and larynx, enter the deep parotid and the cervical lymphatic glands. The lymphatic plexuses of the pituitary membrane, and of the lingual, buccal, and pharyngeal mucous membranes, may be perfectly injected. Indeed, it is only in that way that we can demonstrate the lymphatic vessels which emerge from these different parts.

The Lymphatic System of the Cervical Regions

The Cervical Lymphatic Glands.

The lymphatic glands of the neck are concentrated in the anterior region of the neck. They are divided into the *superficial* and *deep*.

The *superficial lymphatic glands* of the neck are found principally along the external jugular vein; they are therefore situated between the platysma and the sterno-mastoid; and in the supra-clavicular triangle, that is to say, in the triangular interval between the

clavicle, the sterno-mastoid, and the trapezius. We also find several very small superficial glands between the os hyoides and the thyroid cartilage, and upon the sides of the larynx.

The *deep lymphatic glands* of the neck are very numerous, and form an uninterrupted chain around the internal jugular vein and the carotid artery, from the mastoid process to the superior opening of the thorax, in front of the vertebral column, and upon the sides of the pharynx and œsophagus.

The *tracheal lymphatic glands* are also continuous with the deep cervical glands.

The cervical glands form a continued series with the facial and sub-maxillary lymphatic glands on the one hand, and with the lymphatic glands of the thorax and axilla on the other.

The Cervical Lymphatic Vessels.

The *cervical lymphatics* consist of those which have passed through the sub-maxillary and facial lymphatic glands, and which afterward traverse the chain of glands along the jugular veins. They are joined by those of the pharynx, œsophagus, larynx, trachea, and thyroid gland. They then proceed from one lymphatic gland to another, and from one plexus to another, down to the lower part of the neck, where they are joined by some lymphatics from the lung, which also pass through some of the cervical glands: they terminate on the left side in the thoracic duct, and on the right side in the right lymphatic duct.

The Lymphatic System of the Upper Extremity.

The Lymphatic Glands of the Upper Extremity and of the Upper Part of the Trunk.

There are generally no lymphatic glands in the hand or forearm, but Meckel found several very small ones along the ulnar and radial bloodvessels. There are two or three which are sub-cutaneous in the front of the bend of the elbow, and one or two above the internal condyle of the humerus, behind the basilic vein; in the arm we also find a series of small lymphatic glands, which are never numerous, along the inner side of the humeral artery.

The *axillary lymphatic glands* are situated deeply in the axilla, and are very numerous; some lie along the great vessels, others are scattered through the axilla: they are often of a very large size.

The following may be regarded as appendages of the axillary glands: a small sub-clavicular gland, situated deeply beneath the costo-coracoid membrane, opposite the triangular interval between the pectoralis major and the deltoid, and two or three small glands situated along the attachments of the pectoralis major, as far as the mammary gland.

Mascagni has figured a small lymphatic gland near the umbilicus.

The Lymphatic Vessels of the Upper Extremity and of the Upper Half of the Trunk.

The Lymphatics of the Upper Extremity.—The *superficial* set of these vessels arise from the skin of the hand, and run parallel to the fingers: they are, for the most part, situated upon the back of the hand; they cross obliquely over the metacarpal bones, pass over the carpus, and thus reach the forearm.

In the *forearm* they are distributed almost equally upon its anterior and posterior aspects.

The anterior lymphatics are collected upon the inner and outer sides of the forearm; having reached the elbow, some pass in front of the epitrochlea and its muscles; others in front of the epicondyle. In this place they are re-enforced by the lymphatics from the posterior aspect of the forearm, which are also collected into an outer and inner group. Not unfrequently a certain number of the posterior lymphatics, which arise from the outer side of the hand and forearm, after ascending almost vertically for some distance, pass obliquely, or cross transversely inward, above and below the olecranon, and unite with the inner group.

In the *arm* some of the inner group of lymphatics pass to the lymphatic glands above the epitrochlea; the others run along the inner border of the biceps muscle and basilic vein, and then pass backward and upward to reach the axillary glands.

The external lymphatics cross very obliquely over the anterior aspect of the arm, to terminate, like the preceding, in the axillary glands. One of them has a remarkable course; it runs along the cephalic vein, gains the cellular interval between the pectoralis major and the deltoid, dips down over the upper edge of the pectoralis minor and below the costo-coracoid membrane, and describes a curve so as to enter the sub-clavicular lymphatic ganglion.

The *deep lymphatics* of the upper extremity exactly follow the course of the bloodvessels; they often communicate with the superficial lymphatics, and terminate in the axillary glands. I have seen some of the deep lymphatics of the forearm communicate at the bend of the elbow with the superficial lymphatics on the outer part of the back of the arm, and enter the glands above the epitrochlea.

The Lymphatic Vessels of the Upper Half of the Trunk.—We have seen that all the lymphatics of the sub-umbilical portion of the trunk enter the inguinal glands; and so all the lymphatic vessels of the supra-umbilical portion terminate in the axilla.

The *anterior and lateral lymphatics* pass upward upon the pectoralis major and the serratus magnus, to gain the axilla.

The *posterior lymphatics* are divided into those of the neck and those of the back; the *posterior cervical lymphatics* descend upon the trapezius and the deltoid, and are reflected over the posterior border of the last-named muscle, in order to reach the cavity of the axilla; the *posterior dorsal lymphatics* run in different directions; some horizontally, the others from below upward, to be reflected into the axilla below the tendons of the latissimus dorsi and teres major.

NEUROLOGY.

Neurology is that part of anatomy which treats of the apparatus of sensation and innervation: this apparatus consists of the *organs of the senses*, of the *cerebro-spinal axis*, or central portion of the nervous system, and of the *nerves*, or peripheral portion of that system.

THE ORGANS OF THE SENSES.

The Skin—its External Characters, Structure, and Appendages.—The Tongue considered as the Organ of Taste.—The Organ of Smell—the Nose—the Pituitary Membrane.—The Organ of Sight—the Eyebrows—the Eyelids—the Muscles of the Orbit—the Lachrymal Apparatus—the Globe of the Eye, its Membranes and Humours—the Vessels and Nerves of the Eye.—The Organ of Hearing—the External Ear—the Middle Ear or Tympanum—the Internal Ear or Labyrinth—the Nerves and Vessels of the Ear.

The *organs of the senses* are certain parts of our bodies which are intended, by means of the sensibility they possess, to establish relations between us and external objects. The organs of the senses, to use a strong figurative expression, are, as it were, the bridges which connect the individual with the world around him.—(*Meckel's Anatomy*, by Jourdan, p. 471.)

The organs of the senses, being placed between the brain and surrounding objects, have the following characters in common: they occupy the surface of the body; they communicate with the brain by means of nerves of greater or less size; and, lastly, each of them has a peculiar structure in harmony with that particular quality of matter, the perception of which it is intended to convey to us.

Anatomists generally admit five organs of sense, which we shall name, and then describe in the following order: the *skin*, or the organ of tact and touch, the *organ of taste*, the *organ of smell*, the *organ of sight*, and the *organ of hearing*.

The Skin.

General Remarks on the Skin.

The *skin*, the proper organ of tact and of touch, is a membrane which serves as a covering or integument to the body, and is so accurately moulded upon it as to preserve the form, and yet conceal the inequalities, of its entire surface. It may be regarded as forming an external surface or limit, endowed at the same time with *sensibility* and a *power of resistance*; enabling us by the one to perceive such qualities of bodies as are distinguishable by the touch, and by the other preserving us, to a certain extent from their action. It forms, moreover, an exhalant surface, or sudorific organ, by which the system is freed from noxious substances, and also an inhalant surface, by which fluids may be absorbed.*

External Characters.

Examined in reference to its external characters, the skin presents an *external* or *free* surface, and an *internal* or *adherent* surface.

The Free Surface.—Upon the *free surface* of the skin the following objects require attention: its folds, or wrinkles, and its furrows; a peculiar colour, which is subject to

* Some ancient authors, Marcus Aurelius Severinus among others, adhering closely to the order of superimposition, which is sometimes called the anatomical order, commenced the description of the human body with the skin; and the same part, though for a very different reason, is described first by M. de Blainville, in his *Anatomie Comparée:* that celebrated naturalist, carrying out analogical induction to its utmost limits, makes the skin the fundamental organ of the body, connecting with it all the organs of the senses, which he regards as analogous to hairs, and names *phanerœ* (a word constructed by M. Blainville in opposition to the term *cryptœ*, hidden, and derived from φανερος, evident, manifest, apparent). He considers that the apparatus of locomotion is a development of the elastic element of the skin, which becomes endowed with contractility; the digestive and respiratory organs he regards as modifications of the absorbent apparatus of the skin; and the organs of secretion and generation as developments of its exhalant structure. The circulatory apparatus alone is not derived by him immediately from the external integuments; yet he almost believes that it is an extension or prolongation of the meshes of the cutaneous cellular tissue.

variety in different races of men, and in different individuals; certain horny growths, as the nails and hairs, which are appendages of the skin; and, lastly, numerous orifices for the escape of the cutaneous secretions, some of them being the orifices of the sebaceous follicles, others of the sudorific glands, while others, again, are the foramina, or depressions through which the hairs protrude. The horny growths of the skin will be noticed presently; and its colour and orifices, or pores, will be examined under the head of its structure.

We shall here make a few remarks upon the different folds or wrinkles found in the surface of the skin: they are of several kinds.

Some of them may be termed *folds of locomotion;* they are permanent, and are inherent, as it were, in the skin itself, and have distinct relations to the various movements of the body. They are of two kinds: the *larger folds* are observed around the joints, both on the aspect of flexion, and that of extension; for example, over the knuckles and in the palms of the hands; the *small folds* are found over the whole surface of the skin, which is divided by them into irregular lozenge-shaped intervals; it is to these folds that the skin owes its extensibility.

Other folds, called wrinkles, are produced by the contraction of sub-cutaneous muscles; such as the transverse wrinkles produced by the action of the occipito-frontalis, the vertical wrinkles by that of the corrugatores supercilii, and the radiated folds caused by the contractions of the orbicularis palpebrarum, the orbicularis oris, and the sphincter ani. These wrinkles, like the contraction of the muscles by which they are produced, are only transitory; but they become permanent when their causes are frequently repeated. In the same class as these we must include the corrugations of the skin of the scrotum, from contraction of the dartos.

The folds or wrinkles resulting from *age* and from *emaciation* depend upon the skin becoming, after more or less distension, too much stretched, and, therefore, too loose to fit closely to the parts beneath. Hence, emaciation in young subjects does not produce the same effects as in the aged; for in the latter, the wrinkles are caused by the want of elasticity in the skin, and they are more distinct in proportion as that property is lost. In cases of extreme distension, when the skin has been altered in its texture, the wrinkles are more marked, and are permanent; as, for example, those observed on the abdomen of females after pregnancy, and of either sex after dropsy.

Furrows between the Papillæ.—It is necessary carefully to distinguish from the folds or wrinkles of the skin those more or less regular but slight furrows which exist between the linear ridges or eminences formed by the cutaneous papillæ in the palm of the hand and the sole of the foot, and which are also found, though in a less marked degree, in all other parts of the body.

Adherent Surface of the Skin.—In mammiferous animals the skin is lined throughout the greater part of its extent by a layer of muscular fibres, which are intended to act upon it, and constitute the cutaneous muscle or *panniculus carnosus;* but in man the only traces of this structure are the platysma myoides and the palmaris brevis.

The sub-cutaneous muscles of the human subject are concentrated in the face. It follows, therefore, that, although in animals the passions can be expressed by movements of the entire surface of the body, in man their expression is limited to the face. It has been erroneously supposed that the phenomenon termed *cutis anserina*, or *goose-skin*, a corrugated condition of the skin, in which the bulbs of the hairs are rendered prominent by being forced outward, depends upon the contraction of a layer of muscular fibres situated beneath the integument. But the most careful examination has demonstrated no muscular fibres there; we do not even find a dartoid tissue, such as is observed wherever there exists a certain kind of active contractility independent of the will.

Beneath the skin of the human subject we find a layer of adipose tissue, *panniculus adiposus;* it varies in thickness, and is contained in the meshes formed by the fibrous lamellæ, which extend from the internal surface of the skin, and are then either attached to the investing aponeuroses where the skin is said to be adherent, or become expanded into a very thin aponeurotic membrane, called the *fascia superficialis*, in which case the skin is movable. The quantity of sub-cutaneous adipose tissue, and the fixed or movable condition of the skin, have a constant and necessary relation with the functions of each particular region. Thus, while adipose tissue is very abundant in the palm of the hand and sole of the foot, where we always find a *cushion* of fat, it is never present in the skin of the eyelids and penis.

When the skin over any bony eminence is required to be very movable, and at the same time is exposed to continual friction, we find beneath it a sort of synovial capsule, or *bursa*, as it is called; some of these bursæ exist at birth, and belong to the original organization; while others are accidental, and result from friction.

We must regard the sub-cutaneous adipose tissue as a dependance, or even as a constituent part, of the integument, for it is impossible to separate one completely from the other. The adipose tissue, in fact, penetrates into, and entirely fills the areolar spaces in the skin.

The cutaneous vessels enter or pass out, and the cutaneous nerves penetrate at the

adherent surface of the skin, and more particularly opposite the areolæ observed on that surface; so that whenever the skin is stripped off for a certain extent, it either sloughs off, or its vitality is so greatly impaired as to be incapable of completing the process of cicatrization. An accurate idea is, perhaps, not generally entertained of the enormous quantity of nervous filaments and of the immense number of arteries which enter the skin, or of the number of veins which issue from it. Its importance, both in a healthy and in a diseased condition, is sufficiently explained by these anatomical facts regarding it.

Structure of the Skin.

The skin consists essentially of the *cutis*, *dermis*, or true skin (*a*, *fig.* 226); of the *papillæ*, which project upon its external surface; of the *pigmentum*, or colouring matter (*b'*); of the *lymphatic network*; and of the *epidermis*, or cuticle (*b*); as accessory parts, it also contains the *sebaceous follicles*, as well as *arteries*, *veins*, *lymphatics*, *and nerves*; and has connected to it the hairs and the nails.

The Cutis or Chorion.—The *dermis*, *chorion*, or *cutis vera* (*a*, *fig.* 226; *e*, *fig.* 227), is the fundamental part or the basis of the skin; and to it the skin owes its strength, extensibility, and elasticity. If the skin be regarded as formed of several distinct layers, the dermis constitutes the deepest of these.

Fig. 226.

Skin of Negro.

The *thickness* of the dermis varies in different parts, but is always in proportion to the amount of resistance which it is required to offer. Thus, in the cranium, it is very thick and dense; on the face, generally, it is thinner than on the cranium, but not in every part of the face. Compare, for example, its density and thickness in the skin upon the lips with its tenuity and delicacy in that of the eyelids. On the trunk it is almost twice as thick behind as in front; and upon the penis, scrotum, and mamma it is much thinner and finer than upon any other part of the anterior aspect of the body. In the limbs the dermis is much thinner on the surfaces which are turned towards the median line and on the aspect of flexion, than it is on the outer side of the limbs and on the aspect of extension, which are more exposed to the action of external objects. On the palms of the hands and soles of the feet, which are almost incessantly in contact with external objects, the dermis is very thick.

The thickness of the dermis varies in different individuals, and also according to sex and age. In old persons it participates in the general atrophy of the tissues, and becomes so thin as to be somewhat translucent, and enables us in certain regions to distinguish beneath it the pearly aspect of the tendons, and the reddish colour of the muscles.

The dermis has a *deep surface*, and an *epidermic* or *papillary surface*.

The deep surface presents a number of conical depressions, the base of each of which corresponds to the sub-cutaneous layer of adipose tissue, while its summit is directed towards the outer surface of the skin, and is pierced with very fine openings. These depressions or alveoli, which are most strongly developed in the soles of the feet and palms of the hands, are filled with conical prolongations or masses of fat, which, when inflamed, give rise to boils, and in a state of gangrene, constitute the slough from such sores.

When examined in reference to its structure, the dermis is found to be composed of bundles of cellulo-fibrous tissue, interlaced with each other, and becoming closer and closer towards its external surface: this fibrous tissue is scarcely extensible or elastic, so that the extensibility and elasticity of the skin are due, not to the nature of the dermoid tissue, but to the arrangement of its component bundles.* The elasticity of a tissue may depend, like that of caoutchouc, upon the nature of its material, or, like that of a spiral piece of brass wire, may result from the arrangement of that material. The elasticity of the skin appears to be of the latter kind.

The Papillæ.—Upon the external or epidermic surface of the cutis are found a multitude of small eminences, which are either arranged side by side, in rows or ridges (*d*, *fig.* 227), as in the palms of the hands and soles of the feet, or are irregularly scattered over the surface. These eminences are called the *cutaneous papillæ*; together, they constitute the *papillary body* (*corpus papillare*). To understand them properly, we must examine a section of a portion of skin from the palm of the hand or the sole of the foot, which section should be made transversely to the direction of the papillary ridges (see *fig.* 227): numerous small eminences are then seen projecting from the dermis into the substance of the epidermis, which may be distinguished from these projections by its transparency and its horny appearance. The papillæ are still more distinctly seen by removing the epidermis from a piece of skin, and then examining the latter under a thin layer of fluid.

The papillæ consist of a spongy erectile tissue,† containing nervous filaments, arteries, and veins.

* The dermoid, like other cellular and fibrous tissues, is resolved into gelatine by boiling. It acquires great density and strength in the process of tanning, by which it is converted into leather.

† It is impossible to doubt the analogy of the papillæ of the skin to those of the tongue, and even to the in-

The nerves of the papillæ are very numerous. In reference to this point, it is observed that the number of nervous filaments distributed to the skin is always in a direct ratio with the number and size of the cutaneous papillæ; and hence the nerves of the skin covering the palm of the hand are exceedingly numerous.

Several anatomists state that they have seen the nerves spreading out like pencils in the papillæ themselves.*

The papillæ receive both arteries and veins; in successful injections with mercury, or with glue-size, spirit-varnish, or turpentine, coloured with vermilion, all the papillæ are penetrated by the injection, and exhibit, both in their interior and on their surface, a vascular network, which might be called an erectile tissue.†

Lymphatics of the Skin.—If we introduce the pipe of the mercurial injecting apparatus very obliquely beneath the epidermis, the mercury, if the process is successful, will run into a *sub-epidermic network* of vessels, and will soon cover the skin with a metallic layer. These vessels are most evidently lymphatics, for the mercury soon passes from them into the sub-cutaneous lymphatic vessels, and from them into the adjacent lymphatic glands: in no case does it enter the bloodvessels.

Mascagni, who has given so many representations of the vessels of the skin in his beautiful plates, has delineated in several of them this lymphatic network, lying superficially to the layer of bloodvessels.

The universal prejudice against microscopical observations had very improperly thrown some discredit upon the positive results obtained by this great anatomist, when an accidentally successful injection enabled Haase to trace and delineate the cutaneous lymphatics of the groin from the skin to the inguinal glands.‡ M. Lauth, also, by accident, injected the lymphatic network of the same region. Panizza, in 1830, clearly demonstrated the arrangement of the superficial lymphatic network upon the glans penis and the prepuce, in his beautiful injections of that organ in the human subject and in animals. Lastly, M. Fohmann (*Essai sur les Vaisseaux Lymphatiques de divers Ordres*, 1833) has made some special researches upon this subject, viz., upon the lymphatic network in the skin and in other parts. Two beautiful plates, one representing the skin of the mamma, and the other that of the scrotum, glans penis, and prepuce, give a perfect idea of the arrangement of this network, which, when filled with mercury, forms a silvery layer beneath the epidermis. From this network branches are given off which perforate the dermis in all directions, and enter the sub-cutaneous lymphatic vessels proceeding from its internal surface. We have succeeded perfectly in injecting the sub-cutaneous lymphatic vessels in the entire lower extremity of a new-born infant, merely by introducing the pipe into the sole of the foot.

This lymphatic network is remarkable for being situated superficially to the bloodvessels, as Mascagni had correctly observed, and for being completely independent of any other system of vessels; also, for its vessels being dilated into ampullæ at various places, for being destitute of valves, and for not opening anywhere upon the surface of the skin; so that, excepting from laceration, the mercury does not escape through the pores of the epidermis. Lastly, the network generally consists of two very distinct layers, situated between the epidermis and the dermis; one extremely delicate and superficial, the other lying immediately upon the dermis, and belonging to deeper vessels.◊

The Pigmentum.—All the different shades of colour observed in the skin of the several races of mankind belong to either the white, the black, or the copper-coloured variety: they depend upon the presence of a colouring matter called the *pigmentum*, which exists in the European as well as in the negro, though in a less marked degree, and which is deposited beneath the epidermis.

This colouring matter, or *pigmentum* (*b'*, *fig.* 226; *c*, *fig.* 227), may be demonstrated in the skin of the negro (represented in *fig.* 226) with the greatest facility by means of maceration. It is then found not to be contained in special vessels, as Bichat supposed, but to be deposited beneath the epidermis, where it constitutes a uniform layer, that either comes off with the epidermis or remains attached to the dermis, but is independent of either.‖ The epidermis, the papillæ, and the chorion are of precisely the same colour in the negro as in the white races. The pigmentum of the skin is identical in

testinal villi. Although we are unacquainted with their precise structure, it is enough to know that they are composed of an erectile spongy tissue, in which both nerves and vessels terminate. The nervous filaments can be traced by dissection as far as the bottom of the alveolar depressions in the dermis.

* Analysis of a former Memoir upon the Structure and Functions of the Skin, by MM. Breschet and Rousel de Vauzême. These authors state that they have ascertained that the nerves of the skin terminate in loops or arches, as had been pointed out by MM. Prevost and Dumas, in regard to the nerves of the muscles. We shall elsewhere see what is to be thought concerning the existence of these terminal loops of the nerves in muscles, and the theory of muscular contraction founded upon it.

† [The papillæ are prolongations of the vascular and nervous chorion.]

‡ De Vasis Cutis et Intestinorum Absorbentibus, Lipsiæ, 1789. In the plate given in this work, the lymphatic plexus is very badly represented.

◊ According to M. Fohmann, the skin is composed of the following parts proceeding from within outward: 1. The panniculus adiposus. 2. The internal layer of the dermis, characterized by its fibrous meshes. 3. A vascular layer composed of lymphatics, and the terminations of the bloodvessels and veins, united by a small quantity of animal matter. 4. A vascular network, formed exclusively by the ultimate ramifications of the lymphatics. 5. The rete mucosum of Malpighi. 6. The epidermis.

‖ See note, p. 635.

every respect with the choroid pigment in the eye, and is formed of black molecules insoluble in water. Blumenbach conjectured that this black matter was nothing more than carbon: several experiments appeared to confirm this opinion, but it is now generally believed to be formed by the colouring matter of the blood.* In the European it escapes observation, because it does not differ much in colour from the epidermis and dermis.

The colour of the skin, which is a matter of such interest in the natural history of mankind, and which forms one of the principal characters of the several human races, has a tolerably constant relation to the colour of the hair: thus, individuals with light hair have generally fairer skins than such as have dark hair; and thus, also, red hair is accompanied with a somewhat analogous colour of the skin. In albinoes the colouring matter is deficient in the skin, as it is in the hair, and in the interior of the eye. Moreover, the transition, in regard to the colour of the skin, from the white to the black races of mankind, occurs through a succession of intermediate shades: thus, I have found a colouring matter precisely similar to that of the negro's skin beneath the epidermis of several Europeans, particularly upon the scrotum, and upon the tanned faces of those who have lived exposed to a strong solar heat. In the disease called black or green jaundice, the skin of white persons becomes black or olive-coloured. A superficial chronic irritation produced by blisters, or certain skin diseases, or by an adjacent wound, will also sometimes cause a black discoloration of the skin.

As to the source of the pigment of the skin, it is thought by M. Gauthier that it is yielded by the bulbs of the hairs. M. Breschet describes a series of glandular organs for secreting this pigment, which, according to him, are situated in deep furrows in the outer portion of the dermis, and are surmounted by a great number of excretory tubes, from which the globules of pigment are poured out beneath the epidermis. I have never been fortunate enough to ascertain the existence of these glandular organs and their excretory tubes. It is generally supposed that the vessels of the cutaneous papillæ are the source whence the pigment is derived; the mechanism of its formation must be the same as that of the formation of the choroid pigment in the eye, and it is quite as little understood.*

The Epidermis.—The epidermis, or cuticle (*b*, *fig.* 226; *a b*, *fig.* 227), is the outermost of the several layers of the skin; it is a semi-transparent, horny layer, which is moulded upon the surface of the dermis and its papillæ like a coat of varnish, and protects them from the action of external agents. Its internal surface is, in fact, marked by a multitude of little pits, into each of which a papilla is received; so that this surface of the epidermis may be said to form a mould of the papillary surface of the skin. In the skin of the negro, the colouring matter occupies the little pits in the epidermis, and is found in greater abundance between the papillæ than upon them.

In order to obtain a good view of the structure of the internal surface of the epidermis, various sections may be made of the skin upon the palms of the hands and soles of the feet. It will then be seen that the papillæ dip, as it were, into the epidermis, which furnishes a kind of sheath for each of them. This arrangement is exceedingly distinct in the skin upon the lower surface of the bear's foot. I have alluded to this structure in my *Anatomie Pathologique* ("Diseases of the Lymphatics," liv. ii.). M. Breschet has recently observed it in the skin of the whale, in which animal the epidermis forms a complete tube for each of the papillæ. These sheaths, or tubes, are united by a glutinous matter, and may be separated, at least in the bear, with the greatest facility.

The internal surface of the epidermis is intimately adherent to the external surface of the dermis; but this adhesion may be destroyed in the living subject by the application of a blister, and after death by maceration. If in a piece of macerated skin the epidermis be carefully separated from the true skin, it will be seen that the adhesion of one to the other is in part effected by a number of very delicate transparent filaments, which may be stretched to the extent of several lines without breaking. On examining the internal surface of the epidermis under water, these filaments are seen floated out.

What, then, is their nature? Are we to regard them, with Cruickshank, as prolongations of the epidermis which dip into the areolæ of the true skin? or, with Béclard, as strings of mucus formed by the stretching out of the viscid mucous matter situated between the dermis and the epidermis? or, on the other hand, are they canals? and if so, are they to be regarded as exhalant vessels, as Kaaw, Boerhaave, and W. Hunter believed? are they exhalant and absorbent vessels too, as Chaussier and Bichat imagined? or are they not, rather, special vessels, the *vasa sudoris* of Bidloo, and the *vasa sudatoria* of Eichhorn, the latter of whom attributed to them both an exhalant and an absorbent function? These questions are not yet satisfactorily solved. The very great activity, both of exhalation and absorption of the skin, necessarily supposes the existence of some special apparatus for these processes.

Steno, Malpighi, and others admitted the existence of certain *sudoriferous glands*, situated in the adipose cellular tissue, and consisting of tubes which opened on the exte-

* See note, p. 635.

rior by means of an orifice provided with a valve. (Vide *Haller*, t. v., lib. xii., p. 42.)

Fig. 227.

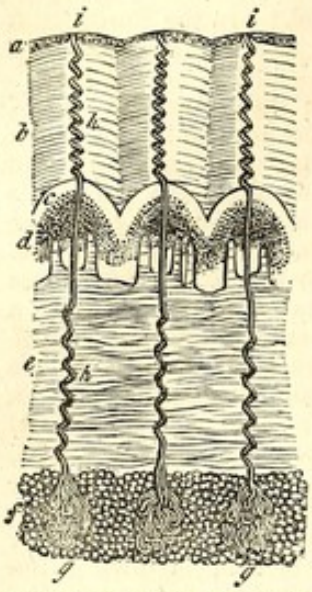

Section of the skin of the finger, magnified 14 times.

This description, when somewhat modified, agrees with the statements recently made by M. Breschet, who has described sudoriferous glands (*g g*, *figs.* 227, 228) having a saccular form, and situated in the substance of the dermis. A spiral canal* (*h*, *fig.* 227), proceeding from each of these sacs, traverses the dermis and epidermis, and, after having made several turns, opens upon the external surface of the skin (at *i*).†

Besides these filaments, the deep surface of the epidermis presents certain irregularities, which may be felt by the finger, and which, under the microscope, appear pointed like thorns; they seem to be prolongations of the epidermis, but I have not been able to determine their precise nature.

The *external surface* of the epidermis presents corresponding folds and furrows to those already described upon the free surface of the skin. It also has numerous orifices or pores, visible to the naked eye on the palms of the hands and soles of the feet, and very distinctly seen by the aid of a lens. Along each of the ridges formed by the rows of papillæ are found a series of orifices, arranged in a regular manner, and resembling in appearance the puncta lachrymalia in the eyelids. If the skin be examined with a lens during life, while the person is perspiring, drops of the excreted fluid are seen to exude, and form into a small globule, which is soon lost by evaporation, and, after a few seconds, another globule makes its appearance. It is impossible to conceive how several celebrated anatomists could have denied the existence of pores in the skin.‡

Della Torre, Fontana, and Mascagni believed that the epidermis was organized, and that it consisted of a network of lymphatic vessels. But as Panizza has clearly proved (*Osservazioni Antropo-zootomico Fisiologiche*, 1830, p. 83), the lymphatic network always lies beneath the epidermis, which may, by maceration, be raised up from it. After the example of Panizza, I have endeavoured to inject the epidermis upon the soles of the feet, and upon other parts of the body, but without being able to find a single vessel. As for the opinion that the epidermis contains arterial and venous capillaries, it is so at variance with the results of observation that it does not require refutation. The epidermis, then, is unorganized [non-vascular].

It is a product of secretion, a layer of concrete, transparent, and very hygrometric mucus; a sort of horny matter, of variable thickness, capable of reproduction after having been destroyed, and the morbid alterations of which result, not from any proper vital action in itself, but from a diseased condition of those living parts of the skin by which it seems to be produced.

As to the structure of the epidermis, it has been repeatedly stated to consist of imbricated scales; but the most careful examination discloses nothing more than a layer of uniform structure, into which the papillæ enter; so that it may be decomposed, hypothetically and even actually, by the aid of the scalpel, in some animals, into a number of agglutinated tubes or sheaths, each of which belongs to a single papilla. The different forms of the fragments of epidermis, detached either spontaneously or in consequence of disease, depend upon accidental circumstances, and show the continuity of this membrane in the human subject.◊ I shall presently describe the relations of the epidermis to the hair, the nails, and the sebaceous follicles.

* Fontana had previously spoken of serpentine vessels, which he had seen beneath the epidermis by means of the microscope.

† [The sudoriferous glands, discovered by Breschet, Purkinjé, and Wendt, may be seen best by examining under the microscope a thin perpendicular section of a piece of skin taken from the palm of the hand (as in *fig.* 227), and hardened in a solution of carbonate of potash. They are situated in the sub-cutaneous adipose cellular tissue (*f*); they consist of a long convoluted tube (or of two tubes which unite together), ending in an efferent duct (*h*), which opens (*i*) upon the free surface of the epidermis, and is lined by flattened epidermic corpuscules. Where the epidermis is thin, these ducts are nearly straight, as in the scalp (see *fig.* 228), and their orifices are scattered irregularly over the surface; where it is thick, they have a spiral course, as in the palm and sole (*fig.* 227), where their orifices are arranged in single rows on the papillary ridges. These spiral ducts are turned in opposite directions on the right and left extremities; the average number of their orifices is fifty in the square line; the filaments described in the text as connecting the epidermis to the dermis are the epidermic linings drawn out of these ducts, and out of the sebaceous and piliferous follicles.]

‡ See note, p. *supra*.

[◊ The epidermic portion of the skin has been so long supposed to consist of several distinct structures, that it is still convenient to describe separately an epidermis, a pigmentum, and a rete mucosum; but modern research has shown that these are merely different layers of the same structure, in different stages of development. The most superficial and hardest of these layers, which is separated from the skin in vesication during life, and by maceration after death, is the epidermis described in the text, and by authors generally; the deeper, more recently formed, and softer portions, which may be displayed and subdivided into several layers by maceration and dissection, constitute the pigmentum and the rete mucosum: together, these insensible, extra-vascular, but not inorganic layers, form what is now called the *epidermis*.

Thus defined, the epidermis exactly resembles the epithelium of mucous membranes, in consisting of a number of adherent nucleated corpuscules, each of which undergoes an independent development. Immedi-

According to M. Breschet, certain minute reddish glands are situated among the subcutaneous adipose vesicles, and constitute the secreting apparatus of the epidermis. Excretory ducts are said by him to proceed from the summits of these small glands, to traverse the dermis, and to open at the bottom of the furrows found upon its external surface. According to the same observer, these ducts generally resemble rows of regularly-arranged columns, and the glands are sometimes situated at unequal depths from the surface, and communicate with each other by intermediate ducts. I have never succeeded in verifying these observations; and I have equally failed in attempting to decompose the epidermis into a series of layers, becoming less and less compact in proportion to their distance from the surface.

The Corpus Mucosum, or Corpus Reticulaire of Malpighi.—Malpighi applied the term *reticulum*, and others, following that great anatomist, have given the names *corpus reticulaire*, *corpus mucosum*, and *rete mucosum*, to a gelatiniform layer (*d*, *fig.* 227) of what is regarded as a concrete mucus, situated beneath the epidermis and perforated by the papillæ, which thus give it a reticulated appearance. This inorganic [non-vascular] layer, which Malpighi first demonstrated beneath the thick epithelium of the tongue of the ox, after it had been boiled, and which he then supposed to exist also in the skin, cannot be demonstrated anatomically; so that the expressions *corpus mucosum*, *corpus reticulaire*, have lost their original signification, and have been interpreted in a different sense. Haller, and several anatomists quoted by him, regarded the corpus mucosum as a deep layer of the epidermis, some of them confounding it with the pigmentum, and others distinguishing it from that body. Bichat considered the corpus mucosum to be an extremely delicate network of vessels, or system of capillaries, which formed, with the papillæ, an intermediate layer between the chorion and epidermis, and was partly intended to convey the blood, and partly the colouring matter of the skin.

M. Gauthier, in examining the skin of the heel in the negro, recognised four distinct layers in the corpus mucosum, arranged in the following manner, from within outward: 1. Vascular processes containing red blood (*bourgeons sanguins*), which are situated upon and adhere to the papillæ; 2. A deep white layer, composed of serous vessels, and moulded upon the vascular processes and papillæ; 3. A layer of gemmules, forming a kind of coloured membrane, excavated upon its deep surface, and separated from the vascular processes and papillæ by the deep white layer; 4. A superficial white layer, which he regards as formed of serous vessels, as well as the deep white layer. Externally to this is the epidermis. M. Dutrochet, founding his opinion upon the examination of the skins of quadrupeds, admits the different layers of M. Gauthier, excepting the vascular processes, which he very properly regards as forming parts of the papillæ: he calls the deep white layer of M. Gauthier the *epidermic membrane*, the gemmules he terms the *coloured layer*, and the superficial white layer he names the *horny layer*.

Lastly, Gall regarded the corpus mucosum as a layer of gray nervous matter, precisely similar to that of the gray substance of the brain and of the nervous ganglia.

I agree with Chaussier that we ought altogether to reject the corpus mucosum, in whatever sense that term may be understood; and I believe there are good grounds for supposing that the different layers described as forming this body belong, in reality, some to the papillæ, and others to the epidermis.*

Appendages of the Skin.

Under this title may be included the sebaceous follicles and the horny growths, viz., the nails and hairs.

The Sebaceous Follicles.—The skin contains within its substance certain *sebaceous follicles* (*i i*, *fig.* 228); these consist of small pouches, or bags, about the size of a millet seed, which form projections beyond the epidermis, but are lodged in the substance of the dermis, and open externally by very small orifices, which are visible under a lens, and, in some persons, even to the naked eye. From these orifices an unctuous matter is constantly poured out upon the surface of the skin, and assists in preserving its pliability; in some individuals this unctuous matter may be expressed from the follicles upon the

ately upon the surface of the true skin, these corpuscules are soft, roundish vesicles, containing a distinct nucleus and peculiar pigment granules, and adhering together by a viscid matter, the cytoblastema, in which they are first developed. In approaching the surface of the cuticle, they become larger and more compressed, their walls become thicker and denser, their nuclei less distinct, and their pigment paler, until, at length, they form the thin, flattened, horny, nucleated, colourless discs, which, adhering to each other firmly in an imbricated manner, constitute the upper and horny portion of the epidermis, from the free surface of which they are constantly being thrown off as minute scales, to be continually replaced by others having a similar origin, and undergoing the same changes: these imbricated scales were described by Leuwenhoek and Baker.

The epidermis is insoluble, even in boiling water; but it swells and becomes softened and transparent, in these respects resembling mucus and epithelium; it consists of a substance called *keratin*.

The pigment granules contained in the deeper epidermic corpuscules are the cause of the colour in the skin; they are black in the negro, &c., of lighter hues in other dark races, and fawn-coloured in the European; in all cases they are darkest in the deeper and newly-formed corpuscules, and fade as these approach the surface: in albinoes they are either absent or colourless. The pigment contains iron and carbon, both in a combined state, phosphate of lime, and animal matter; but as it is bleached by chlorine, it contains no free carbon, as supposed by some.]

* See note, p. 634.

Fig. 228.

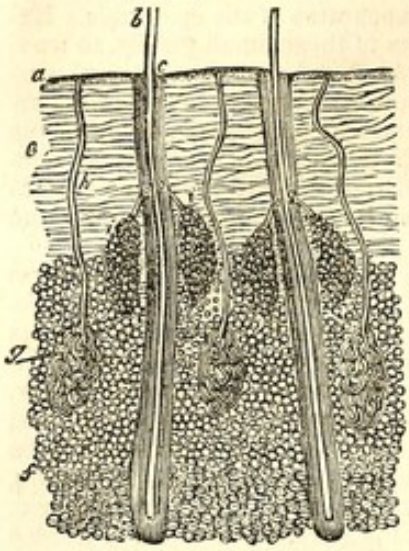

Section of skin from the head, magnified 14 times.

alæ of the nose, in masses which look like small worms. These sebaceous follicles are somewhat analogous to the follicles of the mucous membranes; they are not found in the palms of the hands and soles of the feet; but, in all probability, they exist in every part of the body: they are especially observed in the axilla, on the hairy scalp, and around the margins of the anus and vulva, and the openings of the nose and mouth: they are very much developed in the new-born infant. The sebaceous follicles appear to me to have a glandular structure; and this is particularly evident in those of the axilla, the organization of which seems to me to be more complex than that of those found in other parts. The supposition that these follicles are formed by the reflection of the thin portion of the skin is altogether fanciful.*

The Nails and the Hair.—In man the horny growths of the skin are less developed than in any animal exposed to similar atmospheric conditions; and in man, also, we find the highest development of the sense of touch.

The *nails* of the human subject are hard, yet flexible and elastic, semi-transparent scales, and present the appearance of laminæ of horn: they are situated upon the dorsal surface of the last phalanges, which are therefore called the ungual phalanges; and they appear rather to be intended for the support and protection of the pulpy extremities of the fingers. than as weapons of attack, or instruments of defence and prehension. In a state of civilization it is customary, therefore, to cut off that part of the nail which projects beyond the end of the finger. The ingenuity of man enables him to provide himself with offensive weapons amply sufficient to compensate for the weakness of those provided by nature, which, indeed, are quite rudimentary in him, and if more fully developed, would greatly interfere with the delicacy of his sense of touch.

The peculiarity of the human nail consists in its only covering the dorsal surface of the last phalanx, and in its being of considerable breadth, corresponding, in this respect, with the horseshoe-like enlargement at the end of the phalanx. It follows from this, that the whole of the pulp of the finger is concerned in the exercise of the sense of touch.†

The nail is divided into the *root*, the *body*, and the *free portion*: the *root* is that part of the nail which is covered on both surfaces; the *body* is that part which has one surface free; while the third, or entirely *free* portion, projects beyond the end of the finger, and has a tendency to become incurvated when left to grow naturally.

In order to obtain a correct idea of the anatomy of the nails, we should, by a longitudinal incision, make a vertical section of the ungual portion of one of the fingers (see *fig.* 229). We shall then perceive that the root is about one fourth of the length of the body of the nail (*b*); that it is also the thinnest part of the nail; that it diminishes in thickness towards its posterior edge, which is slightly indented, and that it increases towards the body of the nail; that it is flexible, and is received into a duplicature of the skin (*c c*), to which it is attached by both surfaces; that the posterior edge and lower surface of the root adhere so slightly to the skin, that they may be said to be merely applied to it; that the upper surface of the root, though it adheres more closely to the skin than the lower surface, is yet much less firmly attached to it than the under surface of the body of the nail, which cannot be torn off without great violence; that the nail is separated from the phalanx by a very thick dermis (*c'*); that this skin is of a white colour at the root of the nail, and for some distance in front of it, where it occasions a semilunar white mark, visible through the transparent nail, and called the *lunule* (*lunula*); and, lastly, that the dermis, which corresponds to the body of the nail, is extremely vascular, and hence the nail has a rosy hue, because its semi-transparency enables us to perceive the colour of the subjacent tissue.

One of the most important points in the anatomy of the nail is the nature of its connexion with the dermis. The fold of the skin, which is called the matrix of the nail, is formed in the following manner: the skin (*c*, *fig.* 229, being the dermis) is prolonged

* [The sebaceous glands (*i i*, *fig.* 228) are multilocular follicles; their ducts are lined by epidermic corpuscules, and open upon the surface of the skin in parts without hairs; where hairs exist, they open into the hair follicles (*c*), to each of which two sebaceous glands (*i i*) are generally attached. On the face, very minute hairs have been found around the orifices of the ducts of these glands: their secretion is albuminous as well as fatty.]

† The *hoof*, of which a very perfect example is met in the horse, is nothing more than a nail which encloses the united phalanges on all sides, like the wooden shoes sometimes worn; the *claw* of carnivorous animals is a nail which covers two thirds of the slender ungual phalanx, is compressed at the sides, and terminates in a pointed hook. The nail, properly so called, is found only in man and in quadrumana, and in the latter it approaches in character to the claw. The division of mammalia into ungulated and unguiculated is exceedingly natural, and is, in some measure, represented by certain correlative and constant differences in all other parts of the system.—(See *Anatomie Comparée de M. de Blainville.*)

Fig. 229.

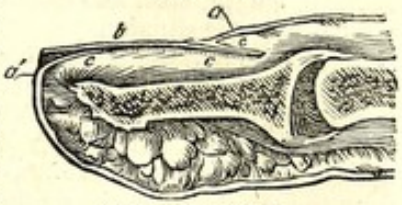

Section of skin of hand.

from the finger on to the dorsal surface of the nail, as far as the curved line that marks the posterior boundary of the *body* of the nail; from thence it is reflected backward, folded upon itself, as far as the posterior border of the root of the nail. At this point it is again reflected forward upon itself by passing behind that border, and then (c' c') between the under surface of the nail and the dorsal aspect of the phalanx: in consequence of this twofold reflection, it follows that it is always the epidermic surface of the true skin that is in contact with the nail: at the anterior extremity of the nail the skin again meets, as it were, the epidermis (a'), and becomes continuous with the integument upon the tip of the finger. But what is the arrangement of the epidermis at the point where the skin is first reflected backward? It is prolonged forward (a), slightly beyond the curved line formed by the reflection of the dermis, and forms a semicircular zone or band, which terminates by a smooth border, and adheres intimately to the nail. As to its arrangement beyond this point authors are not agreed. Some are of opinion that it would be prolonged upon the free surface of the nail, if it were not destroyed by friction; but they overlook an objection to this view to be derived from the accustomed regularity of the epidermic border: others, again, believe that the epidermis is reflected backward like the dermis, but differ among themselves as to its ultimate disposition; some, for example, conceiving, with Bichat, that the epidermis is continuous with the posterior border of the nail, and some supposing that it is again reflected forward beneath the nail, together with the dermis (see dotted line), which, according to this hypothesis, it never quits.*

A very simple experiment most clearly demonstrates the nature of the connexion between the epidermis and the nail: it consists in submitting a finger to the process of maceration, by means of which the nail and epidermis come off together in the form of a partly epidermic and partly horny sheath. In this the epidermis (a) is found to be reflected backward upon the dorsal surface of the root of the nail, and to become blended with it (see *fig.* 229) without ever passing beyond its posterior border; while in front, at the limits between the body and the free portion of the nail, the epidermis (a') is manifestly continuous with the deepest layer of the horny lamina; so that it cannot be doubted that there is an identity of nature between the nail and epidermis.

Structure and Growth of the Nail.—On examining the two surfaces of the nail, and especially its deep surface and posterior border, it is found that they are marked by very distinct longitudinal lines or striæ, which appear to indicate a corresponding linear texture. It would seem, accordingly, that the nail was formed by the agglutination into laminæ of a number of longitudinal fibres; but, if we examine the free surface of the nail attentively, we find that it is marked by curved striæ, which intersect the longitudinal ones. These curved striæ are particularly distinct in the not uncommon cases in which the nail of the great toe is much hypertrophied, and becomes incurvated upon the plantar surface of the toe: the enlarged nail is found to consist of imbricated laminæ, received one into the other like the several laminæ in the hoof of an animal. We may even separate these different layers by aid of maceration, and find that they are fitted one into the other, the deepest being that which was last secreted. The nails, therefore, are developed by a method very analogous to that by which we have already stated the teeth are formed. (See p. 179.)

The nails, then, like the hoofs of animals, and like the epidermis, are products of secretion: they receive neither vessels nor nerves: alterations in their texture are not dependant upon diseases inherent in themselves, but result from some morbid condition of their formative organ. The fold of the dermis, which is called the matrix of the nail, is not the only part by which the substance of the nail is secreted, but the whole papillary surface of the dermis, to which the nail adheres, is concerned in its formation. The papillæ are arranged in longitudinal rows, and hence the substance of the nail is deposited in longitudinal striæ.†

The nail grows continually in length; it does not increase sensibly in thickness, excepting during disease. The layers that have been deposited the longest time are the most superficial, and occupy the free extremity of the nail, in precisely the same manner as the oldest-formed ivory in the tooth is nearest to the enamel.‡

* See note ‡, below.

† The arrangement of the papillary dermoid layer which covers the dorsal surface of the ungual phalanx is worthy of notice: it adheres intimately to the periosteum, and forms an extremely dense, grayish stratum, penetrated by vessels and nerves; so that, if the mode of termination of the nerves in the papillæ can ever be ascertained, it is, without doubt, beneath the nail, where these papillæ present their highest state of development.

‡ [The nails are found by Schwann to consist of nucleated corpuscles, which, like those of the epidermis, are formed upon the surface of the dermis, where they are soft and vesicular, and afterward become hard, flattened, and firmly agglutinated together, as in the substance of the nail. These corpuscles are developed, not only opposite the matrix of the nail, but beneath the whole of its attached surface; the nail is thus elongated, and, at the same time, its thickness is maintained, notwithstanding the flattening of the corpuscles formed at the root as they approach the surface. The thin layer of epidermis, described by Weber, Lauth, and Gurlt, as continued under the whole attached surface of the nail, is nothing more than the soft stratum of growing corpuscles, which pass insensibly into those of the true epidermis.

Like the epidermis, the nails consist of keratin.]

The Hairs.—The *hairs* are filiform productions of the epidermis, generally flexible, variable in length, size, and colour, and bearing different names, according to the region on which they are situated.*

The surface of the human body, with the exception of the palms of the hands and the soles of the feet, is covered by very fine and short hairs, which form a light *down*, as it is named ; but the hairs, properly so called, are collected upon particular parts of the surface of the body, where they serve some special purpose. Thus, they exist in great abundance upon the cranium, where they are called *the hair ;* on the face, where they form the *whiskers* and *beard ;* the hairs upon the margins of the eyelids are called the *eyelashes ;* the arched row over each orbit is called the *eyebrow ;* the hairs upon the lips constitute the *mustache.*

On the trunk the hairs are collected, in more or less abundance, around the genital organs : they exist, also, in the axillæ of both sexes ; and on the chest, between the breasts, in the male. The hairs present well-marked differences, according to sex, age, and the peculiar race to which the individual belongs. The pilous system is most developed in the Caucasian race, and least so in the negro.

The hair, eyelashes, and eyebrows exist before birth : before birth, also, the whole body is clothed with a very thick down, which is shed during the first few months afterward. At the period of puberty, hairs are developed upon the pubic region, and in the axillæ of both sexes, upon the labia majora of the female, and upon the scrotum and around the anal orifice in the male : the beard also appears in the male, and the anterior aspect of the trunk, and the limbs are covered with hairs of variable length in different persons. I should observe, that the development of the hairs is not always in proportion to the personal strength, as is asserted by certain authors, who regard an abundance of hair as an attribute of strength and virility. But, although some men with hairy skins have robust constitutions, a great number are delicate, and are even affected with tubercular phthisis.

In mammalia, the hairs upon the posterior or *dorsal* region of the trunk are more developed than those upon the anterior or abdominal aspect, a proof that they are destined to the quadruped attitude : in some animals, which turn upon their backs to protect themselves, the hairs upon the abdominal surface are most highly developed.

The hair of the head may grow to a very considerable length : it has been seen to reach as low down as the middle of the leg, and, when thrown around the trunk, sufficiently abundant to cover it like a garment. The length and the direction of the hair upon the head evidently prove that man is destined for the erect posture ; for, if he assumed the attitude of a quadruped, it would trail upon the ground, and fall over the face.

The hair also presents peculiarities, or differences, in many respects ; for example, in *direction*, some hair being long and smooth, some crisped and woolly ; this latter kind is peculiar to the negro race, and it never grows to a very great length : also in *diameter*, some hair being excessively fine, and some large and coarse.† It differs, again, as to quantity, for, in general, the hair of the head is more abundant in the female than in the male, as if the activity of the pilous system was principally confined to the hairy scalp in the former sex ; and, lastly, in its colour, from which certain very important distinctions among men are established.

Every different shade in the colour of the hair may be referred to three principal varieties, the *black*, the *flaxen*, and the *red*. The *flaxen* hair belongs particularly to the inhabitants of the north, and to persons of lymphatic and sanguineous temperaments ; the *black* is characteristic of the inhabitants of the south, and of those of a bilious and sanguineous temperament ; the *red* belongs to no particular temperament ; and in our ideas of beauty, this coloured hair, which is usually accompanied with a disagreeable odour of the perspiration, is regarded as a natural misfortune.

The *beard* and whiskers are peculiar to the male sex ; they occupy the lower part of the face, and, consequently, leave uncovered all those parts which are principally concerned in giving expression to the physiognomy, viz., the ocular, nasal, and frontal regions. We cannot insist too strongly on the connexion existing between the development of the genital organs and that of the beard. The eunuch is almost destitute of that appendage.

The great attention rendered necessary by wearing a long beard and long hair has led to the custom of cutting the hair and shaving. It is remarkable that the most effeminate nations, the Orientals, for example, are those among whom long beards are in highest estimation. The influence of these different customs upon the health are deservedly subjects of examination for those who study Hygiene.

Structure and Growth of Hairs.—The only method of obtaining an accurate knowledge of the structure of hairs is to study their growth. The extremity of the hair which is inserted into the skin is contained in a sort of *follicle*, very analogous to the dental folli-

* The *spines* of the hedgehog, the *bristles* of the boar, the *hair* of horses, the *wool* of sheep, and the *fur* of most mammalia, are different kinds of hair.

† [The hair of the head also varies in its *form ;* a section being a more or less flattened oval, or even reniform, from the hair being excavated along one side. On the face, the hairs are still more flattened.]

cles. This *hair-follicle* (*e*, *fig.* 230), which is the formative organ of the hair, is imbedded in the sub-cutaneous cellular tissue (*g*), and is prolonged to the surface of the skin by a sort of membranous canal, which was well described by Bichat. The *hair-follicles* consist essentially of a *pouch* or *sac*, and a *papilla*.

Fig. 230.

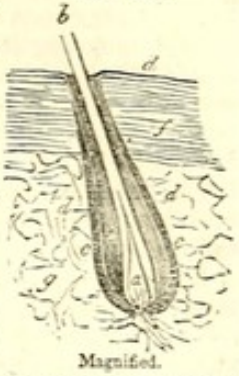

The membranous *pouch* or sac (*c c*), called the bursal membrane by Heusinger, forms a sort of cul-de-sac, having a narrow neck, and opening externally by a contracted orifice, through which the hair (*b*) passes without adhering to it at all. Its walls are sufficiently transparent to allow the hair contained in its cavity to be seen. If this cavity or sac, which, according to M. Dutrochet, is formed merely by the inversion of a portion of the skin, be laid open, its internal surface (*c*) is found to be smooth, not adherent to the hair, but separated from it by a reddish liquid, first pointed out by Heusinger.

From the bottom of this sac, *i. e.*, from the part farthest from the orifice through which the hair protrudes, a *papilla* (*a*), called the pulp of the hair, arises: this papilla is of a conical form, its base being adherent, while its apex is free; it reaches nearly to the orifice of the sac, and even projects beyond it in the disease called plica polonica. Bloodvessels and nerves pass to the bottom of the hair-follicle, and are probably distributed upon the papilla.

It is upon the papilla that the hair is formed. At its commencement it resembles a *conical horny sheath*, which is exactly moulded upon the apex of the papilla. On the inner side of this horny cone another is formed, which raises up the preceding one, and so on in succession, the entire hair constantly maintaining a conical form. According to the experiments of Heusinger, who plucked out at intervals the hairs from the whiskers of a dog, and afterward killed the animal, so as to observe the successive changes which took place in the hair-follicles during the development of the new hairs, a rather long period elapses before the hair projects beyond the epidermis; but, when once it has overcome that obstruction, its growth proceeds rapidly.

What is the arrangement of the epidermis at the point where the hair emerges beyond its surface? According to some, it is prolonged upon the hair, and forms its outer coat; according to others, it dips into the cavity of the hair-follicle, and is reflected upon the base of the hair, so as to form upon it an epidermic tube, which falls off in scales as the hair is prolonged outward; according to others, again, the epidermis has no connexion with the hair; and I am the more inclined to subscribe to such an opinion, because the hair is of the same size both before and after it has left the follicle.*

The hair is the product of a secretion, and, therefore, destitute of vitality, being formed by a series of small horny cones fitted one into the other. It is generally admitted that it is composed of a horny, colourless, transparent, epidermoid sheath, containing a sort of coloured pith in its interior. Bichat presumed that this central substance was formed of certain bloodvessels which contained the colouring matter; but the mode in which the hair is developed proves that it is not tubular, and also that the colouring matter itself is produced by the papilla at the same time as the epidermoid sheath. The white hairs of old people are merely deprived of colouring matter.†

The Organ of Taste.

The structure of the *tongue*, the organ of taste, which has already been described (see p. 332), presents a greater analogy to that of the skin than any other of the organs of the senses.

The sense of taste resides essentially in the papillary membrane which covers the upper surface of the tongue.‡ It has already been stated that the perforated eminences found at the base of the tongue are not papillæ, but glands; and the true papillæ have been divided into the large or caliciform papillæ, which are arranged in the shape of the letter V at the base of the tongue, and the small papillæ; which may be again subdivided into the conical, the filiform, and the lenticular or fungiform, according to their respective shapes.

Every special sense, by which term is understood all such as receive sensations different from that of touch, properly so called, presents for our consideration a *special ap-*

* [The root of some hairs is larger than the shaft, and is named the *bulb*; this, however, does not depend on the hair being covered by the epidermis, a thin layer of which (*d d*, *fig.* 230) lines the follicles, and is believed to terminate at the root of the hair. Into each hair-follicle one or more sebaceous glands (*i i*, *fig.* 227) pour their secretion.]

† [Hairs, like the nails, consist, according to recent researches, of nucleated corpuscles, which differ in form, density, and arrangement, in different parts of the hair. At the root, upon the surface of the papilla, where they are first developed, they are soft and vesicular; in the central medullary part of the shaft they are harder, compressed, and polyhedral; in the cortical part they form an immense number of very long and fine fibres, and, on the outside of these, a layer of short, hard scales.

The hairs consist principally of keratin and an oily matter; besides which, they yield sulphur, phosphorus, iron, salts of lime, and traces of manganese, silica, and magnesia.]

‡ [The mucous membrane on the under surface of the tongue, and that covering the buccal surface of the soft palate and the immediately adjacent parts of the fauces, also possess the sense of taste.]

paratus, on which the impressions act, and a *special nerve* or nerves, adapted to receive those impressions and transmit them to the brain.

The muscular structure of the tongue, which at first sight appears to be useful only in mastication, deglutition, and the articulation of sounds, is intimately connected with the sense of taste, which would have been exceedingly imperfect, had not the gustatory membrane been capable of being moved over the bodies to be tasted. The gustatory apparatus of the tongue consists, then, of a *papillary membrane* stretched over a muscular surface, and united so closely to it that it is impossible to separate one from the other. Moreover, this membrane is constantly kept in a state of humidity, and occupies the first cavity presented by the digestive apparatus.

The Gustatory Papillary Membrane.—All the elements of the skin are found in the gustatory membrane.

The *chorion* is as dense as the densest part of the chorion of the skin: a very great number of muscular fibres are inserted into it, so that the gustatory membrane can be moved not only as a whole, but each part of it has its own separate movements.

The *papillæ*, by which the surface of the tongue is rendered so rough, may be said to represent the papillary body of the skin in a very highly-developed state.*

The lingual papillæ are supplied with nerves, which can be more easily shown than those in the cutaneous papillæ. Haller has traced them into the papillæ; and I have succeeded in doing the same, but without being able to ascertain their mode of termination.

The papillæ also receive *bloodvessels*, which are so abundant that, in successful injections, the papillary body appears to be altogether vascular.

The Lymphatic Network.—By making a superficial puncture into any part of the membrane which covers the dorsum or the borders of the tongue, we may inject a lymphatic network upon it, precisely similar to that found in the skin.

The mucous body, or *rete mucosum*, does not exist as a distinct membrane upon the tongue any more than in the skin. I have already stated that it was while examining the boiled tongue of the ox that Malpighi discovered a glutinous stratum situated between the epidermis and the papillæ, and perforated by a number of openings, corresponding to that of the papillæ themselves; hence the name of *reticulum* which he gave it;† but it is as impossible to demonstrate it upon the tongue as in the skin.

The Pigmentum.—There is never any black colouring matter in the tongue of the human subject; but it is distinct upon the tongue of some animals, as the ox, and can be easily demonstrated between the papillæ and the epithelium.‡

The Epithelium.—Each papilla is covered with a sort of epidermic sheath, which, according to Haller, was discovered by Mery and Cowper, and which has been perfectly described by Albinus under the name of the *periglottis*. This epidermis, or epithelium, so easy of demonstration in the lower animals, in which it has the consistence of horn, may be also readily shown in the human subject, although, in accordance with the greater perfection of the sense of taste in man, the epithelium is comparatively thin. If the upper surface of the tongue be examined with a lens, especially after maceration, the lingual epithelium will be seen to be arranged in precisely the same manner as the epidermis of the skin, and to form a protecting sheath for each papilla. In persons who have sunk after long abstinence, the epithelial covering forms several imbricated layers, which can be rubbed off; the fur which adheres to the tongue is in a great measure formed by this débris of the epithelium somewhat dried. The epithelium of the tongue can be removed by friction; and, in certain inflammatory diseases, the tongue is denuded of it. When one of the lingual papillæ is thus exposed, it becomes excessively painful.

The Nerves of the Tongue.—No other organ, perhaps, of equal size, receives so many nerves as the tongue: one pair, the *ninth* or *hypoglossal*, is exclusively appropriated to it; and it also receives, on each side, the *glosso-pharyngeal* branch of the eighth, and the *lingual* branch of the fifth of the cerebral nerves. Which of these nerves must be regarded as the nerve of taste in the tongue? Evidently the one that is distributed to the papillæ. On this account, since the time of Galen, the lingual branch of the fifth pair, or the lingual nerve, as it is called, has been regarded as the gustatory nerve; though it would seem more natural to admit, with Boërhaave, that the hypoglossal nerve, which is distributed exclusively to the tongue, should, as it were, preside over the special sense situated in this organ. But the lingual nerve is found to enter the tongue at its corresponding border, and to spread out into branches which pass vertically upward, and are exclusively distributed to the papillary membrane of the anterior, or free portion of the tongue.

The *ninth* or *hypoglossal nerve* of each side runs from behind forward, between the genio-glossus and stylo-glossus muscles, and communicates with the lingual nerve, so as to form the *lingual plexus*. It is not certain that some of the filaments of the hypoglos-

* If the epidermic tubes, which are so remarkably distinct on the foot of the bear, be removed from the papillæ, the latter, when exposed, exactly resemble those of the tongue.]

† "Hanc fabricam a Malpighio inventam, et a Bellino libenter acceptam, scriptores anatomicorum, et physiologicorum operum iconibus etiam pictis expresserunt."—(*Haller*, t. v., lib. xiii., p. 107.)

‡ [The pigment in these cases, and the lingual rete mucosum also, are the lowermost layers of the extravascular squamous epithelium.]

sal nerve do not reach the papillæ; but there is no doubt but that almost all of them are lost in the intrinsic muscles of the tongue.

The *right* and *left glosso-pharyngeal nerves* supply the base of the tongue, and are exclusively distributed to the mucous membrane covering that part. No filament of the glosso-pharyngeal nerve is intended for the muscular fibres; and it is a remarkable fact, that in one case in which the facial nerve sent a branch to the tongue supplementary to the glosso-pharyngeal, that branch was distributed precisely in the same manner as the glosso-pharyngeal itself; that is, it was exclusively distributed to the mucous membrane at the base of the tongue. From what is stated above, then, it is anatomically shown that the lingual branch of the fifth nerve and the glosso-pharyngeal nerve are the special nerves of the tongue.*

The following case is no less demonstrative of the same fact: An individual had complete paralysis of the right half of the tongue. That side of the tongue became atrophied, and had scarcely one third of its natural thickness. Both its tactile and gustative sensibility were equally acute on the two sides of the organ. After the death of the person thus afflicted, an acephalo-cyst was found in the right posterior condyloid foramen, which had caused a complete atrophy of the right hypoglossal nerve. The corresponding half of the tongue had undergone the fatty degeneration.

The Organ of Smell.

The *organ of smell* is situated in a cavity formed within the bones of the face, as, indeed, are most of the other senses; it is placed at the entrance of the respiratory passages, and above the organ of taste, with which it has many points of relation. Although situated in the median line, it is a double organ. It consists of an external apparatus, which serves to protect the organ, to keep it in the necessary state of moisture for the proper exercise of its functions, and to direct the air towards that part of it which is endowed with the greatest olfactory sensibility: this is the *nose*, properly so called.

And, secondly, of two complicated and winding cavities, the *nasal fossæ*, lined by a mucous membrane, called the *pituitary membrane*, which is the essential seat of the sense of smell.

The Nose.

The *nose* resembles in form a three-sided pyramid, directed vertically, and projecting from the middle of the face, so that the olfactory organ is the most anterior of all the organs of the special senses.

Its numerous varieties in shape and size fall under the consideration of painters rather than anatomists; for these varieties have greater effect upon the physiognomy than upon the exercise of its functions.

On each side of the nose, at its lower part, is observed a semicircular furrow, having its concavity directed downward, and forming the upper border of the alæ nasi; from this furrow, on either side, the naso-labial furrow of the semeiologists commences. The lateral surfaces of the nose form, by their union, the *dorsum*, which is either straight, convex, or concave, according to the subject; differences which, in a great measure, determine the national or individual forms of this part of the face. The term lobe of the nose is applied to the rounded eminence in which the dorsum nasi terminates below.

The summit, or *root of the nose*, is separated from the nasal protuberance by a transverse furrow. The *base of the nose* presents two elliptical or semilunar orifices, called the *nostrils* (*nares*): the long diameters of these two orifices are directed horizontally backward and outward, and they are separated from each other by an antero-posterior septum; they are provided with stiff hairs, or *vibrissæ*, which serve to arrest any small particles floating in the air.†

The *direction* of the nostrils is a proof that the erect position is natural to man; for, if he were to assume the attitude of a quadruped, only the dorsum of the nose would be directed towards odoriferous bodies. The situation of the nostrils above the orifice of the mouth explains how no alimentary substance can be introduced into that cavity without having been previously examined by the sense of smell.

The nose consists of a skeleton or basis, and of certain muscles; it is covered by the skin externally, and by a mucous membrane internally; and it receives both vessels and nerves.

The Structure of the Nose.

The *basis* or *framework* of the nose is composed of *bone*, *cartilage*, and *fibrous tissue*.

* [The result of the vast number of experiments and observations made upon this subject, by persons of opposite opinions, would appear to be, that the lingual nerve (a branch of the fifth), and the lingual portion of the glosso-pharyngeal nerves, are both of them gustatory nerves, and also nerves of ordinary sensibility to the tongue. The portion of the palate and fauces endowed with the sense of taste derives its power from the palatine nerves, which are given off from a ganglion (Meckel's) connected with the second division of the fifth nerve.]

† This use of the vibrissæ becomes very evident in serious diseases; when, in consequence of the hurried respiration, dry particles floating in the air become attached like a fine powder to these hairs. The collection of particles of dust around the nostrils often warns the practitioner of the serious nature of a disease

The *osseous portion* occupies the upper part of the organ, and consists of the proper nasal bones, and of the ascending processes of the superior maxillary bones.

The *cartilaginous part* consists of the two *lateral cartilages of the nose*, to which we may add the *cartilage of the septum*, although it rather forms part of the nasal fossæ than of the nose properly so called; and, secondly, of the two *alar cartilages*, or *cartilages of the nostrils*, making five in all. To this we must add certain cartilaginous nodules, situated between the lower part of the cartilages of the alæ and that of the septum. Santorini described eleven cartilages in the nose, doubtless because he reckoned certain cartilaginous nodules, which are sometimes accidentally developed in the substance of the fibrous tissue.*

The *fibrous portion of the nose* consists of a fibrous layer, which occupies the interval between the lateral cartilages of the nose and the cartilages of the alæ.

From this structure, it follows that the nose is inflexible above, flexible in the middle, and extremely movable below. This arrangement has the threefold advantage of providing against fractures of the most prominent part of the nose, of permitting the dilatation of the nostrils, and, lastly, in consequence of the solidity of the highest and narrowest part of the nasal fossæ, of ensuring a free passage to the air.

The lateral cartilages of the nose (*a a*, *fig.* 231) are of a triangular form; and they are united together along their anterior margins, which are thick above, so as to form a sharp ridge, which constitutes the dorsum of the nose. Along the line of union there is a sort of furrow or groove, which can be felt even through the skin. By their *upper* and *posterior* margins, they are articulated with the nasal bones; I say articulated, because there is no continuity of substance, but the parts are connected by fibrous tissue, which allows a considerable degree of motion. Their *lower margins* are convex, and correspond in front to the cartilages of the alæ of the nose, and behind to the fibrous tissue which occupies the intervals between the cartilages. The lateral cartilages are intimately united with the cartilage of the septum, along the dorsum of the nose; so that we might regard these three pieces as forming a single cartilage.

Fig. 231.

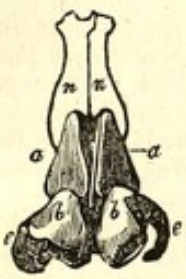

The thickest part of each lateral cartilage is above and in front.

The *cartilages of the nostrils* are generally called, after Bichat, the *fibro-cartilages of the alæ of the nose;* but we have already seen that some of the fibro-cartilages of Bichat are thin layers of ordinary cartilage, while others consist merely of condensed fibrous tissue. The so-called fibro-cartilages of the nostrils belong to the former kind. There is but a single cartilage on each side (*b b*, *fig.* 231) for the ala nasi, the lobe, and the inferior portion of the septum; it consists of an irregular lamina folded upon itself into a semi-ellipse or parabola, opening behind. We shall examine its external and internal portions.

The *external portion* (*b*) is extremely thin, and corresponds to the ala of the nose; it is not situated in the substance of the ala, but is placed above it, so that its lower margin corresponds to the curved furrow which forms the upper boundary of the ala.†

The *internal portion* (*b*, *fig.* 232) is thicker than the external, and is situated upon a lower plane than it: it corresponds, on the inside, to the internal portion of the cartilage of the opposite side, from which it is separated above by the cartilage of the septum. The internal portions of the two alar cartilages are separated from each other by some rather loose cellular tissue, which allows them to move upon each other, and also permits the cartilage of the septum to extend between them, without interfering with them at all. The internal portions of the cartilages of the alæ do not reach the anterior nasal spine, but terminate abruptly at a certain distance from it, by forming a projection, which is very distinct, especially in some individuals, and which sensibly elevates the mucous membrane at the entrance of the nostrils. At the point of union between the internal and external portions of each alar cartilage, that is to say, at the summit of the parabola, the cartilage itself becomes wider and excavated behind, and assists in forming the lobe of the nose. The margins of these cartilages are irregularly notched or scolloped. The upper margins are united to the other cartilages by means of a fibrous tissue, which allows them to move freely, both upon the cartilage of the septum and upon the lateral cartilages of the nose.

A small *cartilaginous nodule* is found on either side, between the lobe of the nose and the cartilage of the septum; the only use of these nodules is to facilitate the movements of the lobe upon the septum.

The *cartilage of the septum nasi* (*c*, *fig.* 232) occupies the triangular interval between the perpendicular plate of the ethmoid bone and the vomer. It consists of two parts: one, wide and free, which is that generally described; the other, which is narrow, and may be called the *caudal prolongation of the cartilage*, is received into the bony portion of the septum, between the two lamellæ of the vomer

* See note, *infrà*.

† [Two or three cartilaginous nodules (*c c*, *fig.* 231) are generally found appended in a curved line to the posterior extremity of this portion of the cartilage of the ala.]

Fig. 232.

The *free portion of the cartilage* is thick and triangular; it has the same direction as the bony septum, and presents *two lateral surfaces*, covered by the pituitary membrane; an *anterior margin*, of which the upper half (*c*, *fig.* 231) is blended with the lateral cartilages along the dorsum of the nose, while its lower half is free, convex, directed downward, and received between the two cartilages of the nostrils; a *superior and posterir margin*, which is extremely thick and rough, and is intimately united to the corresponding margin of the perpendicular plate of the ethmoid bone (*e*, *fig.* 232): the mode in which this union is effected is not by articulation, but by a continuity of tissue, like that between the costal cartilages and the ribs; lastly, an *inferior margin*, which is received between the two plates of the vomer (*v*). The groove into which it is received is very deep; and as the two plates of the vomer become more and more separated in extending forward, so does the corresponding margin of the cartilage increase in thickness; hence the lower extremity of the septum frequently projects considerably into one or other of the nostrils.

The *caudal prolongation of the cartilage* of the septum may be seen by carefully examining the retreating angle formed by the perpendicular plate of the ethmoid and the vomer; in which situation the cartilage of the septum gives off a considerable prolongation, in the form of a band, which occupies the interval between the two plates of the vomer, and is attached to the rostrum of the sphenoid bone. This cartilaginous band is contained entirely within the substance of the middle portion of the bony septum: its *upper margin* is thin, and, as it were, toothed; the *lower margin* is thick and rounded. The two naso-palatine nerves are situated in the same canal as the cartilage, and are placed one on each side of it.

The *muscles of the nose* are the pyramidalis nasi, the levator labii superioris alæque nasi, and the transversalis nasi, or compressor narium, which we have described as a dependance of the depressor alæ nasi, or myrtiformis: an accurate description of these muscles is still to be desired.

The *skin* covering the nasal bones and the lateral cartilages of the nose has no particular character: it is thin and movable. That which covers the alæ and the lobe of the nose is very thick and extremely dense; it crepitates under the knife, to such a degree, that cartilages have been supposed to exist in the substance of the alæ. We have seen, however, that the cartilages of the nostrils are not prolonged into the alæ, which are composed essentially of the dense integument just described, and which is reflected inward upon itself around the margins of the nostrils.

I should remark, that the antero-posterior diameter of the opening of each nostril is much less than that of the corresponding cartilage; this depends upon the fact that the skin is prolonged anteriorly, and is reflected for some lines below and behind the lower margin of the cartilage.

The skin of the nose is remarkable for the great development of its sebaceous follicles. The orifices of these follicles are shown in many individuals by certain black points, which are nothing more than the sebaceous matter discoloured. When forced out of the follicles by lateral pressure, the masses of sebaceous matter resemble in form small worms.

The skin, which is reflected upon itself around the margins of the nostrils, preserves the character of integument as far as where it is provided with hairs, and then suddenly assumes the characters of *mucous* membranes.

The Pituitary Membrane.

The *pituitary* or *Schneiderian* membrane*, the immediate seat of smell, is a fibro-mucous membrane, which lines the whole extent of the nasal fossæ, and is prolonged, with some modifications of texture, into the different cells and sinuses which open into those fossæ.

When covered with this membrane, the nasal fossæ present a configuration differing in many respects from that which they have in the skeleton. Many of the foramina and canals are closed, and several are contracted in their dimensions. The irregularities of the surface of the turbinated bones are, in some measure, concealed. Besides this, the mucous membrane, where it is reflected upon itself, forms a number of folds, some of which prolong the turns of the turbinated bones; while others, more or less, contract the orifices of communication between the various cells and sinuses and the nasal fossæ.

The pituitary membrane, originating, then, on the one hand, from the skin, which is reflected at the margins of the nares, and provided with hairs (*h*, *fig.* 233), is, on the other hand, continuous, without any line of demarcation, with the mucous membranes of the pharynx and velum palati (at *t s*), of the Eustachian tubes (at *m*), and of the nasal ducts (at *r*). In the *roof of each nasal fossa* (*u v*) it closes the foramina of the cribriform plate

* Conrad Victor Schneider (*de Catarrho*) gave his name to this membrane, because he was the first to refute successfully the erroneous notion of the ancients, that the secretion of the nasal fossæ descended from the ventricles of the brain; the common term *cold in the head* still remains as a vestige of this error.

of the ethmoid bone, and those of the nasal bones, so that all the vessels and nerves which pass through these foramina enter the mucous membrane by its external surface; before it enters into the sphenoidal sinus, it forms a fold around the orifice of that sinus, by which the opening is narrowed, so as to have the form of a vertical fissure (see the bristle marked *d*).

Upon the *external wall of each nasal fossa* (see *fig.* 233)* it covers a great number of parts, counting from below upward, viz., the *inferior meatus*, at the upper and anterior part of which it meets with the lower orifice of the nasal duct (*r*, *figs.* 233, 234); around this opening it forms a semilunar valvular fold, the free margin of which is directed downward, and which prolongs the canal of the ducts to a greater or less distance in different subjects; in passing a probe into the nasal duct from the inferior meatus, this valve must, almost of necessity, be torn.

Fig. 233.

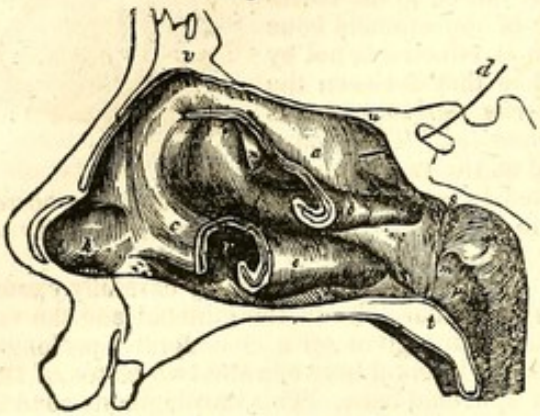

From the inferior meatus the pituitary membrane is reflected upon the *inferior turbinated bone* (*c c*, *figs.* 233, 234), which appears longer in the recent state, in consequence of a fold of the mucous membrane being continued in front, and another still more marked behind the bone: this is the thickest part of the nasal mucous membrane.

In the *middle meatus* (*i*) the pituitary membrane covers the *infundibulum*, at the lower extremity of which is an ampulla or dilatation, where the *orifice of the maxillary sinus* is generally found. This orifice (see bristle *a*, *fig.* 234) has a very different appearance from that which it presents in the dried scull: it is extremely narrow, scarcely admitting the blunt end of a common probe. It sometimes appears as if it were wanting; but it will then be found opposite the middle of the infundibulum; in this case, the maxillary sinus might be said to communicate directly with the frontal sinus. Not unfrequently the maxillary sinus opens both into the middle meatus and the infundibulum. The pituitary membrane is prolonged from the infundibulum into the anterior ethmoidal cells (*e e*, *fig.* 234), and into the frontal and maxillary (*m m*) sinuses. If we remove the middle turbinated bone, we find a considerable projection, which bounds the infundibulum above (*n*, *fig.* 233), and corresponds to a large ethmoidal cell. Upon the back part of this projection, on which the middle turbinated bone is moulded, an opening (see bristle) is often found leading into this great cell, and on its fore part (at *e*), one or more orifices leading into the anterior and superior ethmoidal cells.

From the middle turbinated bone (*b*, *figs.* 233, 234), which is continued backward by a fold of the membrane, the pituitary membrane passes into the superior meatus, where I have frequently met with four or five openings leading into as many of the posterior ethmoidal cells, which, in this case, did not communicate with each other: I have even seen the orifice of an ethmoidal cell upon the superior turbinated bone (*a*).

Fig. 234.

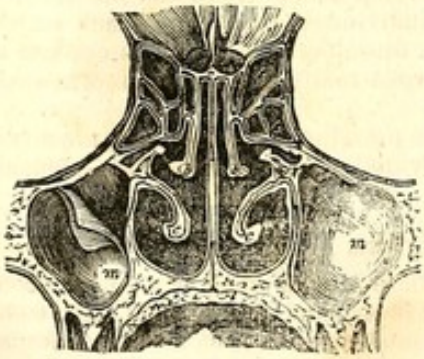

The pituitary membrane dips into all the ethmoidal cells, and into the frontal sinuses, either directly or indirectly, but it does not enter the spheno-palatine foramen, which, on the contrary, is completely closed by it.

Upon the septum the pituitary membrane is remarkable for its thickness, being exceeded in this respect only by the membrane covering the inferior turbinated bone. We do not find in man that prolongation or cul-de-sac, which is so very distinct in some animals, in front of the lower border of the septum; but at this point the pituitary membrane closes the two superior orifices of the anterior palatine canal.

Structure.—The pituitary membrane is a mucous membrane, and its peculiarity consists in its being extended over osseous and cartilaginous surfaces. Its free surface is smooth, red, and scattered over with foramina, from which a great quantity of mucus may be expressed.† Its adherent surface is intimately united to the periosteum and perichondrium of the bones and cartilages of the nasal fossæ, so that it is classed among the fibro-mucous membranes.

* [In this figure, portions of the middle and inferior conchæ are represented as cut away, to show the parts in the middle and inferior meatuses.]

† [In the nasal fossæ the epithelium of the pituitary membrane is columnar and ciliated; in the sinuses it approaches the squamous in character, but yet it is provided with cilia, the movements of which have been observed in the lower animals to produce currents towards the openings of the respective sinuses.]

The pituitary membrane is generally thicker than the other mucous membranes, so that it is very easy to determine the highly vascular and truly erectile structure of this membrane. If it be punctured, and the tube of a mercurial injecting apparatus introduced, the mercury will immediately enter the cells of the erectile tissue, and from thence pass into the veins arising from those cells. If a more superficial puncture be made, a lymphatic network will be injected, situated so superficially, that the mercury exhibits all its metallic lustre. This lymphatic network has no communication with the venous cells just mentioned.*

This lymphatic network, which is common to all the mucous membranes, gives to the non-vascular layer by which they are covered the appearance of a serous membrane.

The pituitary membrane receives a great number of *arteries*, which penetrate it by several points, and which are almost all derived from the same source, viz., the internal maxillary artery; as, for example, the spheno-palatine, the infra-orbital, the superior alveolar, the palatine, and the pterygo-palatine. Some arise from the ophthalmic artery, viz., the supra-orbital and the ethmoidal; and others from the facial artery, viz., the dorsalis nasi, the artery of the alæ, and the artery of the septum.

The capillary veins are so numerous, that they in a great measure form the basis of the pituitary membrane; the larger veins which proceed from them follow the course of the arteries, and enter, by very large trunks, into the internal maxillary, the facial, and the ophthalmic veins. There are numerous communications between these last-named veins and those of the ethmoidal region of the base of the cranium.

The spongy character of the internal surface of the nasal fossæ, and more particularly of the surface of the turbinated bones, is due to certain grooves and foramina intended for the reception and transmission of bloodvessels.

I am only acquainted with the superficial *lymphatic* network already noticed. In order to inject it, it is necessary to scratch the membrane with the injecting pipe.

Are there any *glands* or *follicles* in the pituitary membrane? Steno has described certain glands which I have not been able to find. The follicles in this membrane are rather difficult to be shown.

Like all the organs of the special senses, the pituitary membrane is provided with a special nerve, called the *olfactory*, the nerves of the two sides constituting the *first pair* of cerebral nerves. Comparative anatomy shows that the development of the olfactory nerves is in relation with the development of the sense of smell, and thus establishes, in a most positive manner, the generally-received opinion regarding the function of this pair of nerves. Without entering here into the description of the olfactory nerves, which will be given hereafter, I would observe, that they pass through the foramina and canals of the cribriform plate of the ethmoid bone, at the same time becoming enveloped in fibrous sheaths; that they enter the pituitary membrane by its external surface; and that they expand into a plexus in its substance. The branches of these nerves cannot be traced lower than the middle turbinated bones on the one hand, and the middle of the septum on the other. Thus, while the upper and extremely narrow part of each nasal fossa (*s*, *fig.* 234) is the essential seat of the sense of smell, the lower and much wider part only gives passage to the air during the act of respiration.

Besides the special nerve of smell, the pituitary membrane receives other nervous filaments, all of which are derived from branches of the fifth nerve, viz., from the internal nasal and the frontal branches of the ophthalmic division of that nerve, and from the spheno-palatine, the great palatine, the vidian, and the anterior dental branches of its second or superior maxillary division. The experiments of modern physiologists have shown that the integrity of these different branches of the fifth pair is necessary for the perfect possession of the olfactory sense. This, however, is very different from saying that the seat of that sense is in the branches of the fifth pair.

The membrane which lines the several sinuses, although it is continuous with the pituitary membrane, does not resemble it in character; it is exceedingly thin and transparent, and appears like a serous rather than a mucous membrane; that it is a mucous membrane, is satisfactorily established only by certain pathological facts. The mucous membrane of the sinuses has a very close resemblance to the conjunctiva.†

The Organs of Sight.

The *eyes*, or the organs of sight, are situated at the highest part of the face, so that they are enabled to explore objects at a distance.

They are two in number; but they co-operate in their function so as to act like a single organ. The result of this is, that vision is rendered more certain, and its field of operation more extensive, at the same time that, from the unity of action of both eyes, it is *single*.

The eyes are protected by the orbital cavities in which they are contained; they are covered by the *eyelids*, and these are surmounted by the *eyebrows*. They are surrounded by *six muscles*, by which they can be moved in all directions; they are divided into

* It was in the pituitary membrane of the calf that, about eight years ago, I first accidentally injected the superficial lymphatic network.

† See note, p. 648.

the *straight* and the *oblique* muscles. There is also a secreting apparatus, the *apparatus of the lachrymal passages*, the secretion from which lubricates the anterior surface of the ball of the eye, and facilitates the exercise of its functions.

The study of the organ of sight, therefore, is not limited to that of the eyes alone, but includes that of the means of protection, viz., the orbital cavities (see OSTEOLOGY), the eyelids, and the eyebrows; that of the muscles, or moving organs; and that of the lachrymal passages, or lubricating apparatus. These accessory parts, or appendages of the organ of vision, have been collectively named by Haller the *tutamina oculi*. We shall commence our description with them.

The Eyebrows.

The *eyebrows* are two arched ridges, which are covered with short stiff hairs, that are directed from within outward, and overlap each other; the eyebrows are situated at the lower part of the forehead, and form the boundary of the upper eyelid. Their direction corresponds precisely with that of the orbital arch. The hairs upon them are more numerous, and longer at the inner extremity, which is called the head, than at the outer, which is denominated the tail of the eyebrow. The heads of the two eyebrows are separated from each other by an interval which corresponds to the root of the nose; sometimes, however, they are blended together.

Structure.—The skin in which the hairs of the eyebrow are implanted is thick, and very closely united beneath to a muscular layer formed by the frontalis, the orbicularis palpebrarum, and the corrugator supercilii, the last-named muscle being situated beneath the other two. The orbital and superciliary arches serve as a basis to support the eyebrows; the nerves of these parts are very numerous, and are derived from the facial and the fifth nerves; their vessels arise from the ophthalmic and temporal arteries.

Uses.—The eyebrows, which give a peculiar character to the human countenance, protect the eye, and, when depressed in front of it, intercept a great number of the rays of light; they assist in a remarkable degree in giving expression to the face.

The Eyelids.

The *eyelids* are two movable and protecting curtains, placed in front of the ball of each eye, which they conceal or leave uncovered, according as they are in a state of approximation or separation.

The eyelids are two in number—a *superior* and an *inferior*. In a great number of animals there is a third eyelid, of which merely a trace exists in man. The eyelids are large enough to close the base of the orbit completely, and to intercept entirely the passage of light.

Each of the eyelids presents for our consideration a *cutaneous surface*, which is convex, and marked with concentric semilunar folds that become effaced when the lids are closed; an *ocular surface* (*fig.* 235), which is concave, is accurately moulded upon the ball of the eye, and presents a series of yellowish vertical lines, formed, as we shall see, by the Meibomian glands; an *adherent border*, which is indicated by the orbital arch in the upper eyelid, but is less clearly defined in the lower lid, in which it is continuous with the cheek; lastly, a *free border*, or margin, which, in both eyelids, is straight when the lids are closed, and curved when they are open: in the latter position they enclose an elliptical space (*rima palpebrarum*), the dimensions of which vary in different persons, and hence give rise to the expressions *large eyes* and *small eyes*, which have no reference to the actual size of the globe of the eye, but merely to the size of that part which is exposed to view. The free margins of the eyelids are not cut obliquely from before backward, so as to intercept, when they are closed, a three-sided interval or channel, which is completed behind by the globe of the eye, and which is supposed to become larger from without inward, in order to conduct the tears towards the larchrymal puncta. On the contrary, these margins are cut horizontally from before backward (see section, *fig.* 240); and when approximated, they leave a narrow fissure between them, which may serve as a channel for the tears during sleep, quite as well as the three-sided canal which is generally supposed to exist.

The margins of the eyelids, moreover, are tolerably thick, and are furnished at their anterior lip with three or four rows of hard, stiff, and curved hairs, which are more numerous and longer on the upper than on the lower eyelid, and at the middle than at either end of each: these are the *eyelashes*. Their direction is worthy of notice: in the upper eyelid they are at first directed downward, and are then curved upward, so as to describe an arc having its concavity turned upward; the eyelashes of the lower lid have just the opposite arrangement. From this it follows, that the convexities of the eyelashes of the two lids are turned towards each other; and thus, when the eye is shut, they touch each other without being able to interlace. Serious inconvenience is produced when the eyelashes deviate from their proper course, and are turned inward; when the eyelashes are wanting, the free margins of the lids are attacked with chronic inflammation. Along the posterior lip of the free margin of each eyelid, or, rather, along the angular ridge formed by the union of that margin with the posterior surface of the

lid, are placed a very regular series of foramina (*figs.* 235, 236), from which the sebaceous matter secreted by the Meibomian glands may be expressed in masses having the form of small worms.

At the junction of the external five sixths with the internal sixth of the free margins of the two eyelids are found two very remarkable tubercles, the *lachrymal papillæ* or *tubercles* (*a*, *fig.* 239; also seen in *figs.* 235, 236), each of which is perforated by an opening, visible to the naked eye; these openings are the *puncta lachrymalia*, the orifices of the corresponding lachrymal canals. That part of the free margin of each eyelid which is on the inner side of the corresponding lachrymal papilla is straight, rounded, and destitute of hairs or follicular orifices: in the space enclosed between this part of the eyelids, and called *lacus lachrymalis*, is situated the *caruncula lachrymalis* (*, *fig.* 239).

The upper eyelid, moreover, is twice as deep as the lower; so that, when depressed, it descends below the transverse diameter, or equator of the eye, to use an expression invented by Haller.

The terms *angles of the eye*, or *commissures of the eyelids*, are applied to the angles formed by the junction of the extremities of the free margins of the eyelids. The external angle, *external* or *temporal commissure* (*b*, *fig.* 239), is also named the *little angle* (*canthus minor*).*

The internal angle, *internal* or *nasal commissure* (*c*), improperly called the *great angle of the eye* (*canthus major*), corresponds to the posterior border of the ascending process of the superior maxillary bone.

Structure of the Eyelids.—The constituent parts of the eyelids are, the tarsal cartilages, a fibrous membrane, a muscular layer, two integumentary layers, one mucous and the other cutaneous, and certain follicles, with vessels, nerves, and cellular tissue.

The *tarsal cartilages*, which resemble in their use the cylinders of wood attached to the bottom of a map or diagram, to prevent it from hanging in folds, are two in number, one for each eyelid; they are cartilaginous plates, situated within the free margin and the contiguous portion of the lids. The tarsal cartilage of the upper eyelid (*a*, *figs.* 235, 236) is semilunar; that of the lower eyelid (*b*) has the form of a small, narrow band; neither of them occupies the entire length of the corresponding lid. Their anterior surface is convex, and is covered by the fibres of the orbicularis palpebrarum muscle. Their posterior surface (*fig.* 235) corresponds to the conjunctiva, and is closely adherent to it. The Meibomian glands are situated between the conjunctiva and the cartilage, or, rather, in the substance of the cartilage.

The adherent border of each tarsal cartilage is thin, and affords attachment to the fibrous membrane of the lids; the adherent border of the cartilage of the upper eyelid, which is convex, also gives attachment to the levator palpebræ superioris muscle. The free margins of these cartilages are their thickest parts, and occasion the thickness of the free margins of the eyelids.†

The *cutaneous layer* is remarkable for its excessive tenuity and semi-transparency: the *eyelashes* are appendages of this part of the integument.

The *cellular layer* is no less remarkable for the absence of fat than for its extreme delicacy: it is the type, indeed, of serous cellular tissue, and is frequently the seat of serous infiltrations.

The *muscular layer* is formed by the palpebral portion of the orbicularis muscle, the pale colour of which, as I have already noticed, contrasts with the dark-red hue of the orbital portion of the same muscle. Besides this, the upper eyelid has an extrinsic muscle, the *levator palpebræ superioris* (*a*, *fig.* 237), the tendon of which, however, is alone concerned in the formation of that eyelid, by being attached to the upper border of the corresponding tarsal cartilage.

The *fibrous layer* consists of a fibrous membrane, which arises from the margin of the orbit, and is attached to the corresponding borders of the tarsal cartilages. This membrane is very strong and unyielding in the outer half of the base of the orbit, but diminishes in thickness towards the inner half of that base, especially on the inner portion of the upper eyelid, where it degenerates into cellular tissue.

The term *ligament of the external canthus* might be applied to a fibrous raphé, which extends horizontally from that angle to the base of the orbit. This raphé bifurcates opposite the outer canthus, so as to become attached to the outer end of each tarsal cartilage, and it exactly corresponds to the tendon of the orbicularis palpebrarum, which is situated at the inner canthus, and which is also bifurcated, to join the inner ends of the same cartilages.

On cutting through this raphé, some very strong fibrous bundles are exposed, which arise from the external wall of the orbit, and spread out into the substance of the upper eyelid.

* The external commissure does not correspond to the outer extremity of the transverse diameter of the base of the orbit, but is situated about three lines nearer to the nose; hence the necessity of dividing this commissure in extirpation of the eye.

† [The substance of the tarsal cartilages differs from that of ordinary cartilage in being more opaque, and also in having a few microscopic filaments scattered through it; in this respect approaching in character to fibro-cartilage.]

The expanded tendon of the levator palpebræ superioris, which is subjacent to the fibrous layer, completes the fibrous structure of the upper eyelid. The tarsal cartilages and the fibrous layer are situated upon the same plane.

The *mucous layer*, or *palpebral conjunctiva*, consists of a membrane which lines the posterior surface (*fig.* 235) of the eyelids, and is, moreover, extended over the globe of the eye. This membrane is called the *conjunctiva*, or *tunica adnata*, because it connects the eyelids with the ball of the eye. In order to facilitate our description, we shall suppose it to commence at the free margin of the upper eyelid (*a'*, *fig.* 240), where it is continuous with the skin: having covered the whole thickness of this margin, it then lines the posterior surface of the tarsal cartilage (*c'*), to which it is intimately adherent, and continues in the same direction as far as beneath the orbital arch. At this point it is reflected upon the anterior surface of the globe of the eye, so as to form a cul-de-sac between that organ and the eyelid: upon the eyeball, where it is called the ocular conjunctiva, it adheres to the sclerotic coat by means of cellular tissue, which is at first loose, but gradually becomes closer and closer as it approaches the transparent cornea. Upon the cornea (*d'*) its adhesion is so intimate that some anatomists have denied its existence in that situation. In fact, it can only be anatomically demonstrated in the healthy state upon the margin of the cornea, but its existence over the whole of that part of the eye is shown in some diseases. After having covered the anterior and inferior part of the sclerotic (*c''*), the conjunctiva is reflected upon the posterior surface of the lower eyelid (*b'*), lines its tarsal cartilage, covers its free margin, and then becomes continuous with the skin. On the inner side of the ball of the eye the conjunctiva forms a small semilunar fold, the *plica semilunaris* (*e*, *figs.* 235, 239), which has its concavity turned outward, and which may be regarded as the vestige of the third eyelid found in animals: it is misnamed the *membrana nictitans* (la membrane clignotante). On the outer side, the conjunctiva dips between the eyelids and the ball of the eye, and forms a deep cul-de-sac. Opposite the lachrymal papillæ the conjunctiva passes into the puncta, and lines the lachrymal passages.

Fig. 235.

From what has been stated above, it will be seen that the conjunctiva would form a shut sac, like the serous membranes, if the eyelids were supposed to be united. Like the serous membranes, it covers two surfaces that rub one upon the other. Its tenuity, its transparency, and the filamentous adhesions which are sometimes observed between its contiguous surfaces, have induced some anatomists to place this membrane among the serous rather than the mucous membranes; but its continuity with the skin, its extreme vascularity, and its uses, which require it to be in contact with the air, prove that it should be retained among the latter class of membranes.*

The *glands found in the eyelids* consist of an appendage of the lachrymal gland, which will be described with it, of the Meibomian glands, and of the caruncula lachrymalis.

The *Meibomian glands* (*m m*, *fig.* 236) are situated upon the posterior surface of both eyelids, opposite the tarsal cartilages; they resemble yellowish vertical and parallel lines, sometimes straight and sometimes curved; their length is proportioned to the depth of the cartilages, and they never project upon the inner surface of the eyelids. Each of these lines, of which there are from thirty to forty in each eyelid, consists of a tortuous canal, folded upon itself a great number of times, and having a considerable number of small follicles opening into it on each side. All these canals open very regularly upon the posterior lip of the free margin of the lid by a row of orifices arranged in a single line. I have never seen two rows of openings, as Zinn states he has observed. If the eyelids be compressed over the tarsal cartilages by a pair of pincers, masses of a waxy substance exude from these orifices, having the form of small worms twisted frequently upon themselves. Sometimes these small linear canals communicate with each other opposite the adherent border of the tarsal cartilage; at other times they bifurcate. It is the waxy sercetion from the Meibomian glands which prevents the tears from trickling in front of the eyelids. These glands are lodged in the deep grooves in the tarsal cartilages; they are, therefore, as visible upon the external as the internal surface of the cartilages.

Fig. 236.

The Meibomian glands belong to the class of sebaceous follicles, and form a transition, as it were, from follicles to glands.

The *caruncula lachrymalis* (*c*, *fig.* 235,* *fig.* 239) consists of a small, oblong group of follicles, situated at the inner angle of the eyelids, and on the inner side of that semilunar fold of the conjunctiva, which we have spoken of as the trace of a third eyelid. It is about the size of a grain of wheat. It is interposed between the free margins of

* The absence of villi has been stated as characteristic of the conjunctiva; but villi or papillæ are found upon that portion which lines the superior tarsal cartilage.

[The epithelium of the conjunctiva is squamous, and consists of several layers: according to Henlé, it is ciliated upon the inner surface of the eyelid; but cilia have not been observed upon the eyeball.]

the eyelids, in that part of those margins which extends between the lachrymal tubercles and the internal commissure; but it is upon a plane posterior to these margins, so that it does not prevent their mutual contact. It is covered by a fold of the conjunctiva, which gives it a reddish aspect; it presents a great number of openings, through which a waxy secretion exudes, and projecting from it are several small hairs, which may become so long as to produce ophthalmia. The caruncula lachrymalis is composed of sebaceous follicular glands, of the same nature as the Meibomian glands. It was for a long time considered to be a second lachrymal gland. In order to obtain a good view of the orifices, and of the light-coloured and sometimes very numerous hairs of the caruncula lachrymalis, that body should be covered with ink or a solution of carmine, and then examined with a lens.

Vessels and Nerves of the Eyelids.—The arteries are the internal and external palpebral branches of the ophthalmic, and the palpebral branches of the temporal, infra-orbital, and facial arteries. I have already said that the palpebral arteries form two arches, one for each eyelid.

The *veins* have the same name, follow the same direction, and open into the corresponding venous trunks.

The *nerves* are derived from two sources, viz., the facial and the fifth nerve.

Uses.—The eyelids protect the eye from the action of light and air, and of any particles floating in the latter; by a sweeping movement, they clean the surface of the organ, over which they also spread the lachrymal fluid, which serves as a protection to the eyeball against the action of the air. The eyelids, from their capability of being interposed between the eye and external objects, place the exercise of vision under the control of the will.

The Muscles of the Eye, and the Levator Palpebræ Superioris.

The muscles of the eye are six in number, and are distinguished into the *straight* and the *oblique*. There are four straight and two oblique muscles. With these we shall also describe the levator palpebræ superioris.

Dissection.—Remove the roof of the orbit by two cuts with the saw, meeting each other at an acute angle opposite the optic foramen; be careful that the inner cut does not injure the cartilaginous pulley of the superior oblique muscle. Dissect the origins of these several muscles from the deepest part of the orbit with the greatest care. They are arranged completely round the optic nerve (*o*, *figs.* 237, 238) and the motor oculi nerves. Those which arise above the optic nerve are attached to the dura mater and periosteum, but not to the bone; but those which arise below the nerve adhere more closely to the bone. The inferior or small oblique muscle is the only one which does not arise from the bottom of the orbital cavity.

The Levator Palpebræ Superioris.

The *levator palpebræ superioris* (*a*, *figs.* 237, 238), much thinner and narrower than the rectus superior, which is subjacent to it, *arises* from the bottom of the orbit, at the upper part of the margin of the optic foramen, or, rather, from the fibrous sheath given off from the dura mater around the optic nerve. It arises by short and radiated tendinous fibres, to which the fleshy fibres succeed, in the form of a thin, flat muscle, that passes outward in a line parallel with the axis of the orbit, is reflected upon the globe of the eye, and ends in an aponeurotic expansion, which is *inserted* in the upper border of the tarsal cartilage of the upper eyelid.

Fig. 237.

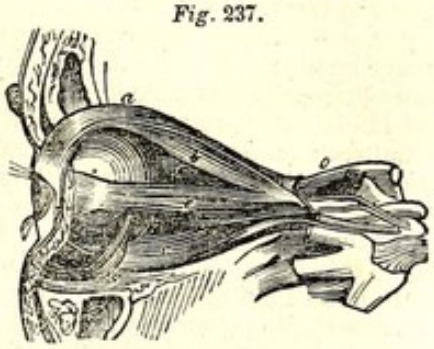

Relations.—It is covered by the periosteum of the roof of the orbit, it is covered obliquely at its origin by the ophthalmic nerve, and it covers the superior rectus muscle.

Action.—This muscle raises the upper eyelid, and draws it backward, so that the upper border of the eyelid is concealed under the orbital arch.

The Rectus Superior, or Levator Oculi.

The *superior rectus* (*b*) has two very distinct *origins*. The first resembles that of the levator palpebræ superioris in being from the upper part of the fibrous sheath of the optic nerve, but it is on a lower plane than that muscle; the second is from the inner margin of the sphenoidal fissure, *i. e.*, between that fissure and the optic foramen. The latter origin, which is continuous with those of the external rectus, appears to take place from the sheath furnished by the dura mater to the third cranial or motor oculi nerve.

The fleshy fibres arising from this radiated tendon form a flat bundle, which passes forward and outward in the direction of the axis of the orbit, and is reflected upon the eyeball, where it becomes converted into a broad and thin aponeurosis, and is *inserted* into the sclerotic coat, at a short distance from the cornea.

This muscle, like all the other recti, is in relation with the periosteum of the orbit,

from which it is separated towards the inner side by the levator palpebræ superioris; it covers the optic nerve and the eyeball.

The Rectus Inferior, or Depressor Oculi.

The *inferior rectus* (*c*) *arises*, together with the internal and external recti, by a common tendon, called the *tendon* or *ligament of Zinn*, which is attached to the lower half of the optic foramen, and more particularly to a depression which is seen to the inner side of the sphenoidal fissure. Almost immediately after its commencement this tendon divides into three branches, from the middle one of which the inferior rectus muscle arises, and then passing horizontally forward and outward, is reflected upon the globe of the eye, and terminates in a similar manner to the preceding muscle.

The Rectus Internus, or Adductor Oculi.

The *internal rectus* (*d*) has two very distinct *origins:* one from the tendon of Zinn, the other from the inner side of the fibrous sheath of the optic nerve; the latter origin is continuous with those of the superior rectus. From these points it passes forward along the internal wall of the orbit, is reflected upon the globe of the eye, and terminates like the preceding muscles.

The Rectus Externus, or Abductor Oculi.

The *external rectus* (*e*) also has a double *origin:* one inferior, derived from the ligament of Zinn; the other superior, from the fibrous sheath of the sixth cranial or abducens oculi nerve, and continuous with the external origin of the superior rectus. A fibrous arch, under which certain veins pass, unites these two origins, and also serves as a point of attachment to the muscular fibres. From these points the muscle passes obliquely forward and outward along the external wall of the orbit, is reflected upon the eyeball, and terminates like the other recti muscles.

General Description and Action of the Recti Muscles.

The four straight muscles of the eye arise from the bottom of the orbit, and terminate upon the eyeball, a few lines from the cornea.

They all have the same form, viz., that of a long isosceles triangle, having its base turned forward and its apex backward. Their relations are also similar: thus, they correspond, on the one hand, to the periosteum of the orbit, and on the other to the optic nerve and the globe of the eye, from which they are separated by some fat and vessels.

In consequence of their being inserted in front of the transverse diameter of the eye, they are all reflected upon the eyeball; this fact is rendered much more evident when the eye is drawn in an opposite direction to that in which the particular muscle under examination would act. Their tendons are surrounded with a whitish, and, as it were, elastic cellular tissue, by which the movements of these muscles are facilitated.*

The recti differ from each other, both in length and thickness. Thus, the internal rectus is the shortest and thickest, the external rectus is the longest, and the superior rectus is the smallest.

Action.—If these muscles were not reflected upon the globe of the eye, their action would be simply to draw it forcibly backward towards the bottom of the orbit; but, in consequence of this reflection, they can give it a rotatory motion. Thus, the superior and inferior recti rotate the eyeball upon its transverse axis, while the internal and external recti rotate it upon its vertical axis. After either of these effects is produced, the eye is then drawn backward. The direct movement backward is produced by the simultaneous contraction of the four muscles.

When any two *adjacent* recti act together, the eye is moved in the diagonal of the two forces exerted by those muscles; and hence the eye, and therefore the pupil, can pass over all the radii of the circle represented by the base of the orbit; this arrangement is not only highly favourable to the exploratory power of the eye, but also assists in placing the function of vision under the control of the will, since it enables us to turn away the eyes from any offensive object. The straight muscles of the eye, as well as the oblique muscles, also aid in expressing the passions; and hence the following names have been given to them by the ancients. The superior rectus is called *superbus* (mirator, *Haller*); the inferior rectus, *humilis;* the external rectus, *indignatorius;* the internal rectus, *amatorius* seu *bibitorius*.

Lastly, it has been supposed that the muscles of the eye, by compressing that organ, can alter the distance between the retina and the crystalline lens; and a theory to explain the power we possess of adapting the eye for distinct vision at different distances has even been constructed on the supposed possibility of this compression.

The necessarily simultaneous and co-ordinate action sometimes of the same muscle, and sometimes of different muscles in the two eyes, is a remarkable physiological fact. Thus, the contraction of the superior rectus of the right eye is of necessity accompanied by contraction of the corresponding muscle of the left eye; while the contraction of the external rectus of one eye is accompanied by contraction of the internal rectus of the

* [Small synovial bursæ have been described as existing between these tendons and the globe of the eye.]

other eye, and *vice versa*: the will can neither prevent nor disarrange these co-ordinate contractions. However, even without much practice, it is possible to overcome them, so far as to squint by endeavouring to look at the nose.

It is not uninteresting to remark, that the sixth cranial nerve, or the abducens oculi, is destined exclusively for the external rectus muscle; and that the third cranial nerve, or motor oculi, supplies the three other recti, the levator palpebræ superioris, and the obliquus minor. No other muscles in the body receive such large nerves in proportion to their size as those of the eye.

The Oblique Muscles of the Eye.

These are two in number, the *superior* or *great oblique*, and the *inferior* or *lesser oblique*.

The Obliquus Superior.

The superior or *great oblique muscle* of the eye (*f*, *fig.* 238) is a long filiform muscle, which is reflected over a pulley or trochlea, and hence has been termed the *trochlearis* muscle; it *arises* from the fibrous sheath of the optic nerve, between the superior and internal recti, in the same manner and upon the same plane as those muscles; from this point it passes forward along the angle formed by the junction of the roof with the inner wall of the orbit, and forms a rounded muscular fasciculus, which ends in a rounded tendon near the cartilaginous pulley intended for its reception; the tendon passes through this pulley, is reflected upon itself at an acute angle, so as to be directed downward, outward, and somewhat backward; gets beneath the superior rectus, where it spreads out, and is then *inserted* into the sclerotic coat *on a level* with the longest transverse diameter of the eyeball, and, consequently, farther back than the insertion of the recti. The superior oblique is the longest muscle of the eye.

Fig. 238.

The *trochlea*, or *pulley* of the superior oblique, is a small cartilage, which forms five sixths of a short cylinder or ring; the edges of this imperfect cylinder are attached to the slight bony ridges which bound a depression upon the superior wall of the orbit. Its attachment is effected by means of loose ligamentous fibres, so that the pulley itself has a certain degree of mobility. The gliding of the parts is facilitated by a *synovial membrane*, which is reflected from the tendon upon the pulley, and is prolonged in front of and behind the latter. Beyond the pulley, a whitish filamentous tissue takes the place of the synovial membrane.

The *relations* of the superior oblique are similar to those of the superior rectus.

Action.—Like all reflected muscles, the superior oblique must act from the point of its reflection. It follows, therefore, that this muscle rotates the eye upon itself from without inward, that is, around its antero-posterior axis. From the oblique direction of its tendon from before backward, after it is reflected, it can draw the eye forward, and tends to bring it out beyond the orbit. This muscle is believed to assist in the expression of the tender passions (*musculus patheticus*). The fourth cranial nerve, also called the trochlear or pathetic nerve, is destined exclusively for this muscle.

The Obliquus Inferior.

The *inferior* or *lesser oblique* (*g*, *fig.* 237, 238) is the shortest muscle of the eye, and the only one which does not arise from the bottom of the orbit; it *arises* from the inner and anterior part of the floor of that cavity, and, therefore, from the orbital surface of the superior maxillary bone, immediately behind the margin of the orbit, and often even from the lachrymal sac. From this origin it passes backward, in the form of a flat bundle, which turns round the lower surface of the globe of the eye, situated at first between the eyeball and the inferior rectus, then between it and the external rectus, and at length ends in an aponeurotic expansion, which is blended with the sclerotic, near the outer border of the superior rectus.

Its insertion into the sclerotic is farther back than that of the superior oblique, and, therefore, much farther back than those of the recti.

Action.—It rotates the eye in the opposite direction to the superior oblique. Its turning round the lower surface of the eyeball renders its action extremely effective. From its oblique course from before backward, it can draw the eye slightly forward.

The Lachrymal Passages.

The term *lachrymal passages* includes both the apparatus for secreting and that for conveying away the tears, consisting of a secreting organ, named the *lachrymal gland*; of *excretory ducts*, which pour out the tears upon the conjunctiva; and of a second set of ducts, intended to absorb the tears and convey them into the nasal fossæ, comprising the *puncta lachrymalia*, the *lachrymal canals*, the *lachrymal sac*, and the *nasal ducts*. Such is the order in which we shall describe this apparatus.

The Lachrymal Gland.

The *lachrymal gland* (*glandula innominata* of the ancients) consists of two very distinct parts: an *orbital portion*, situated in the fossa on the roof of the orbit; and a *palpebral portion*, which is enclosed in the substance of the upper eyelid.

The first or *orbital portion* (*l*, *fig.* 207), the only part generally described, is of an irregular semi-ovoid form, having its long diameter placed transversely. It varies in size in different subjects, but is generally about as large as a filbert.* Its upper surface is convex, and corresponds to the fossa in the frontal bone, to which it adheres, especially in front, by very distinct fibrous bands: its interior surface is concave, and is in relation with the external rectus, and with a small part of the superior rectus. Its anterior border corresponds to the orbital arch, or, rather, to the fibrous membrane of the eyelid, immediately behind which it is situated; hence it may be exposed by an incision along this arch. By its posterior edge it receives its vessels and nerves.

The second or *palpebral portion*, though continuous with the first, is separated from it by several fibrous bands. It forms a thin granular layer, which is covered and concealed by a very dense lamina of fibrous tissue that appears to be prolonged into its interior. This palpebral portion occupies the outer portion of the upper eyelid, and extends almost as far as the upper border of the tarsal cartilage.

The Excretory Ducts of the Lachrymal Gland.—Before the discovery of these excretory ducts, it was only by inference that the so-called *glandula innominata* was regarded as the secreting organ of the tears. In 1661 Steno discovered these ducts in the sheep, in which animal they are large enough to admit bristles. He described thirteen or fourteen ducts. The difficulty of detecting these ducts in the human subject is sufficiently proved by the fact that neither Morgagni, Zinn, nor Haller could ever find them; the second Monro, however, succeeded in filling them with mercury, and described them accurately. They are from ten to twelve in number; they run parallel to each other beneath the palpebral conjunctiva, and open upon the inner surface of the eyelid by a corresponding number of orifices (*d*, *fig.* 235), placed very regularly about a line from the tarsal cartilage, along its outer half. MM. Chaussier and Ribes have succeeded in filling them with mercury, by injecting them from the gland towards the eyelids. Having sought in vain, both with the naked eye and with a lens, for the orifices of the excretory ducts of the lachrymal gland in the human subject, I thought of dipping the eye and eyelids in a solution of carmine or slightly-diluted ink; and I then saw distinctly a dozen openings arranged in a line along the point of reflection of the palpebral conjunctiva upon the eyeball, and occupying the outer half of the eyelid.†

The Lachrymal Puncta and Canals.

The *puncta lachrymalia* (*a*, *fig.* 239), two in number, one for each eyelid, are those small orifices or *foramina* which are visible to the naked eye in the centre of the lachrymal papillæ: they are perfectly circular, are always open, and are directed backward, the upper one being turned downward, and the lower one upward. These openings, which are kept apart from each other by the caruncula lachrymalis, are the capillary orifices of two small canals, called the *lachrymal canals*.

Fig. 239.

The *lachrymal canals* (*l l*) are small tubes, extending from the puncta lachrymalia to the lachrymal sac. They are two in number, a superior and an inferior, each being somewhat larger than the corresponding lachrymal punctum. Their angular course is very remarkable. They pass at first vertically, the superior duct upward, and the inferior duct downward, and after a short course they bend abruptly at right angles, run inward, and open by separate orifices, never together, into the anterior and external part of the lachrymal sac. The direction of the second portion of each of the lachrymal canals varies according as the eyelids are closed or open: the duct of the lower eyelid is directed somewhat obliquely upward, that of the upper eyelid downward, even when the lids are completely closed; but they are both very oblique when the eyelids are separated; and as this separation is principally due to the elevation of the upper eyelid, it follows that the obliquity of the upper lachrymal canal must be very well marked.

The coats of the lachrymal canals are dense and elastic, so that they do not collapse when empty, and must, therefore, act as capillary tubes. We do not find any sphincter, either at their palpebral or their nasal orifice; they appear to be formed in the substance of the free margin of each eyelid; they are lined by a prolongation of the conjunctiva, and are covered by the fibres of the orbicularis palpebrarum muscle. Behind them are found some muscular fibres, forming a dependance of a small fasciculus, called the *muscle of Horner*, or the *lachrymal muscle*, which was believed by that anatomist to serve in drawing the lachrymal ducts inward.

* [It has all the anatomical characters of a compound gland.]

† I find in Haller that it was in a human eye which had been macerated for some time in water tinged with blood, that Monro (Secundus) discovered these orifices. After they have been discovered, it is easy to introduce the end of the mercurial injecting pipe into them.

The Muscle of Horner.

Dissection.—Turn the eyelids inward, and carefully remove a fibrous layer which covers this muscle upon the lachrymal sac.

This small muscle *arises* from the vertical ridge of the os unguis, which forms the posterior border of the lachrymal groove; from this point it passes transversely outward along the posterior tendon of the orbicularis palpebrarum, and divides into two tongues, a superior and an inferior, which correspond to the lachrymal canals, and terminate at the respective lachrymal puncta.

I regard these fibres as a dependance of the orbicularis palpebrarum.

The Lachrymal Sac and Nasal Duct, or Lachrymo-nasal Canal.

The *lachrymal sac* and *nasal duct* constitute a single canal, which extends from the upper part of the lachrymal groove to the inferior meatus of the corresponding nasal fossa.

The *lachrymal sac* (*m*), that portion of the lachrymo-nasal canal which occupies the lachrymal groove, represents the half of a cylinder terminating above in a cul-de-sac. It is buried, so to speak, in the substance of the inner wall of the orbit, immediately behind the margin of that cavity, and is in relation with the inner angle of the eyelids, the caruncula lachrymalis, the adipose tissue of the orbit, and the tendon of the orbicularis muscle. The last-named relation is one of the most important points in the anatomy of the lachrymal sac. If a circular incision be made through the eyelids from their outer angle along their adherent borders, and the lids be then turned inward, by then carefully dissecting the tendon of the orbicularis, it will be found that that tendon divides into three branches; that the anterior branch, called the *straight tendon*, is inserted in front of the ascending process of the superior maxillary bone; that the posterior branch, which is of equal size with the anterior, is inserted into the ridge upon the os unguis, behind the lachrymal groove; that the middle branch ascends to be attached to the upper part of the lachrymal groove; and, lastly, that the lower part of the tendon gives off a fibrous expansion, which forms the outer side of the lachrymal sac, and which may be regarded as a fourth tendinous expansion. The muscle of Horner lies upon the posterior of these tendons, and must be regarded as a portion of the orbicularis itself.

The tendon of the orbicularis palpebrarum corresponds to the upper part of the lachrymal sac, only its cul-de-sac projecting above the tendon. The greatest part of the sac is, therefore, situated below it.

The internal surface of the lachrymal sac presents the ordinary appearance of all canals lined by mucous membrane: a considerable quantity of mucus is often found in it. At the anterior part of its external wall, and at about an equal distance from the top and bottom, are the two orifices of the lachrymal canals; above, is the narrow cul-de-sac, in which it terminates in that direction; and below, it becomes continuous with the nasal duct: in this place there is rather frequently found a semilunar, sometimes even a circular valve; this is the kind of diaphragm spoken of by Zinn, but the existence of which was denied by Morgagni. Haller says that he only met with it once.

The lachrymal sac consists of a partly bony and partly fibrous canal, lined by a mucous membrane. The *bony portion* of this canal is formed by the groove upon the ascending process of the superior maxillary bone, and upon the os unguis; the last-mentioned bone, which is thin and pierced with foramina, may be easily perforated; and hence the facility of making an artificial passage for the tears. The lachrymal sac is opposite to the middle meatus of the corresponding nasal fossa.

The *fibrous portion* forms the external flattened wall of this canal; it is very strong and unyielding, unless to long-continued extension.

The slight *muscular layer*, described as the *muscle of Horner*, may be regarded as belonging to the lachrymal sac: this muscle is itself covered by a layer of fibrous tissue.

The lining *mucous membrane* of the lachrymal sac is reddish, and, as it were, pulpy, and closely resembles the pituitary membrane;* from its close attachment to the periosteum of the walls of the canal, it might be called a *fibro-mucous membrane*.

The *nasal duct* (*n*), which may be said to be formed in the outer wall of the corresponding nasal fossa, extends from the lachrymal sac to the anterior part of the inferior meatus of the nose. It is of a cylindrical shape, slightly flattened on the sides, and rather narrower at the middle than at its extremities. It is directed vertically, but forms a slight curve, having its concavity turned forward and outward. It may be also readily conceived that the relative breadth of the root of the nose must affect the direction of this canal.

It corresponds, *on the inner side*, to the middle meatus of the nose, and the inferior turbinated bone; *on the outer side*, to the maxillary sinus, from which it is separated by a very thin lamina of bone. This latter relation has doubtless led one anatomist to state that the nasal canal opens both into the maxillary sinus and the nasal fossa.

The nasal canal consists of a bony canal lined by a fibro-mucous membrane; the bony canal is complete, and is formed by the superior maxillary bone, the os unguis, and the inferior turbinated bone. It is very strong in the part formed by the superior maxillary

* See note, p. 654.

bone, excepting opposite to the sinus in that bone, but it is very thin and fragile where it is formed by the os unguis and inferior turbinated bone. Its lining membrane is of a fibro-mucous structure; it adheres very slightly to the walls of the canal, and is continuous, on the one hand, with the mucous membrane of the lachrymal sac, and, on the other, with the pituitary membrane.* This lining membrane is often prolonged for several lines beyond the nasal duct, so as to form a valvular fold (*o*). Where this fold exists, the inferior orifice of the nasal duct (see *r*, *fig.* 233) is always closed, and, therefore, difficult to be detected, even when the inferior turbinated bone has been taken away or displaced, so that, in order to discover it, it becomes necessary to introduce a probe through the lachrymal passages from above. In catheterism of the nasal duct from below upward, according to the method practised by Laforest, this fold of mucous membrane must of necessity be torn.

It has been stated by some authors, that the lower orifice of the nasal duct is preceded by an ampulla, or infundibuliform dilatation. I have met with this disposition, but regarded it as morbid. I am convinced that a great many lachrymal tumours depend upon contraction or obliteration of the lower orifice of this canal.

The Globe of the Eye.

The *globe of the eye* (*v*, *fig.* 240) is *situated* in the fore part of the orbital cavity; it is retained in this situation by the optic nerve (*o*), the straight and oblique muscles (*b e g*), the vessels, the conjunctiva (*d*), and the eyelids; these parts, however, do not confine it in a fixed position, but allow it great mobility. In fact, the eye can be rotated around all its axes, and can even be drawn forward and backward (see *Muscles of the Eye*). The eyes are small in comparison to the orbital cavities; and they present some slight differences as to size in different persons, which have not yet been properly estimated. The common terms *large* and *small* eyes apply less to the eyeball than to the opening between the eyelids. The eye is proportionally larger in the fœtus and new-born infant than in the adult and aged.

Fig. 240.

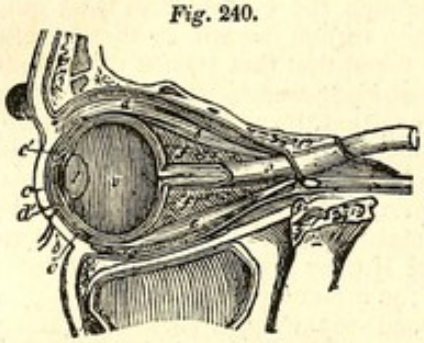

In *form*, the globe of the eye resembles a regular spheroid, to the front of which is attached a segment of a smaller sphere (see *fig.* 241): by this arrangement, the antero-posterior diameter of the organ is increased to the length of eleven lines, while its other diameters are only ten lines. It is said that the form of the eyeball can be altered by the contraction of its muscles, but, in consequence of the great tension of this organ, the alteration produced is so slight that it scarcely deserves to be mentioned.

The *general relations* of the eyeball are the following: *in front*, it is covered by the conjunctiva and the eyelids, which defend it from light and from dust, rather than from external violence. It results, also, from the obliquity of the margin of the orbit, that, on the outer side, the eye projects considerably beyond the bones. In every other part of its surface the eye rests upon an elastic cushion of fat (*f f*), which separates it from the muscles and nerves, fills up all intervals, and facilitates the movements of the organ. The absorption of this fat in emaciated individuals causes the depression of the eye into the orbital cavity. A membranous cellular tissue, or, rather, a rudimentary synovial membrane, exists between the eye and this fat.

Structure.—Like all the other organs of the senses, the eye consists essentially of a membrane provided with a special nerve, and of a particular apparatus, placed in relation with the external agent by which the organ is to be acted upon. In the organ of vision, the sentient membrane is the retina, which is the immediate seat of the sense of sight; the other parts of the eyeball form nothing more than a very complicated dioptric instrument, a dark chamber, in which the rays of light are refracted, and concentrated so as to form a vivid image, and which is, moreover, provided with a movable diaphragm to regulate the number of rays to be admitted.

In an anatomical point of view, the eye is said to consist of certain membranes and humours. The membranes, counting from without inward, are the *sclerotic coat* and *cornea*, the *choroid coat* and *iris*, and the *retina*. The humours are, the *vitreous body* and its *hyaloid membrane*, the *crystalline lens* and its *capsule*, and the *aqueous humour*.

The Sclerotic.

Dissection.—Clean the globe of the eye, leaving the attachments of the muscles to the sclerotic coat; with a pair of strong scissors divide this coat circularly into an anterior and posterior portion, taking care to avoid the choroid coat; turn the one portion forward and the other backward. It is easier to make this section, without injuring the choroid, upon a slightly flaccid eye than upon one which is perfectly fresh.

The *sclerotic* (σκληρὸς, hard), or the *opaque cornea* (*b*, *fig.* 241), is the outermost of the

* [The epithelium of the mucous membrane of all the lachrymal passages is columnar, and, according to Henlé, is provided with cilia, although Perkinjé and Valentin failed to discover them in these situations.]

coats of the eye, and forms, as it were, the shell of that organ; it is of a pearly-white colour, and very strong: it is perforated behind to give passage to the optic nerve (*o*), and presents a circular opening in front (from *a* to *a*), into which the cornea is fitted.

Its *external surface* forms the outer surface of the eyeball, and therefore has the same relations. Thus, it is covered in front by the conjunctiva, which adheres to it by means of very loose cellular tissue, that is liable to infiltration. The straight and oblique muscles of the eye are implanted into it. An imperfect or rudimentary synovial capsule separates it from the cushion of fat, and gives it a smooth aspect.

Its *internal surface* has a dull, rough appearance, very different from that of its external surface: it is, moreover, of a deep-brown colour, from the choroid pigment; it corresponds to the choroid coat (*c*), and is united to it by a very delicate cellular tissue, and by the ciliary vessels.* The ciliary nerves run from behind forward between the sclerotic and the choroid, occupying slight grooves upon the internal surface of the former. Both the ciliary vessels and nerves perforate the sclerotic coat very obliquely.

Structure.—The sclerotic is one of the thickest and strongest fibrous membranes in the body: it is not of uniform thickness throughout; it is thickest behind, at the entrance of the optic nerve, and thinnest in front, near the cornea. Like all the fibrous membranes, it is unyielding; and on this depends the firmness and tense condition of the globe of the eye: it is also the cause of the intense pain produced by inflammation of the interior of the eye and by certain cases of hydrophthalmia.

The older anatomists considered the sclerotic to be composed of two layers, the inner of which was, according to Zinn, a prolongation of the pia mater, and, according to Meckel, of the arachnoid. But, independently of the fact that the division of the sclerotic into two layers is purely artificial, it may be stated that neither the pia mater nor the arachnoid is prolonged upon the optic nerve. Lastly, the sclerotic has been regarded as a continuation of the dura mater, through the medium of the neurilemma of the optic nerve; and this view is supported by dissection, which shows clearly that the sheath furnished by the dura mater to the optic nerve is prolonged upon the sclerotic. It has, moreover, been stated, but incorrectly, that the anterior part of the sclerotic has an additional layer, formed by the union of the tendons of the recti muscles.

The sclerotic is composed of fibrous bundles which interlace in all directions.

Its *use* is especially to protect the globe of the eye, of which it forms the covering and determines the shape.

The Cornea.

The *transparent cornea* (*a a*, *fig.* 241) completes the external shell of the eye in front: in reference to the sclerotic coat, it represents a segment of a smaller sphere superadded to a larger sphere; its circumference is circular, or, rather, slightly elliptical, for its transverse diameter is half a line longer than its vertical diameter.

Its *anterior surface* is convex, and projects forward beyond the sclerotic; it is covered by the conjunctiva, which adheres to it so closely, that the existence of that membrane upon it has been denied by some anatomists.†

Too great a convexity of the cornea, by increasing the refracting power of the eye, occasions myopia, or short-sightedness.

Its *posterior surface* is concave, and forms the anterior wall of the anterior chamber of the eye. A thin membrane (*m*) covers this surface, and is called the *membrane of the aqueous humour*.

The *circumference* of the cornea, which is fitted into the opening in the front of the sclerotic, is cut obliquely, so that its external surface is smaller than its internal surface; the oblique edge of the sclerotic, to which it corresponds, is sloped in the opposite direction.

The cornea and sclerotic adhere so closely that they were for a long time regarded as forming but one coat; but, independently of their difference in appearance and texture, they may be separated by boiling or by long-continued maceration.

Structure.—The cornea is thicker than the sclerotic: it may be separated into a great number of lamellæ, united by very thin layers of cellular tissue; but this separation is purely artificial, so that the number of lamellæ is indefinite. The thinnest layer of fluid interposed between the lamellæ is sufficient to impair the transparency of the cornea; maceration, accordingly, gives it a milky appearance. The opacity of the cornea, which occurs in some cases of ophthalmia, depends upon the infiltration between the lamellæ of a certain quantity of fluid, after the absorption of which the cornea recovers its original transparency.

No vessels can be shown in the cornea, even by the aid of the finest injections of the arteries and veins of the eye: its superficial layer, which is continuous with the conjunctiva, contains a network of lymphatics communicating with those of the conjunctiva, and capable of being demonstrated by puncturing any part of the superficial layer of

* See note, p. 656.

† A careful dissection, especially after prolonged maceration, shows the continuity of the most superficial layer of the cornea with the conjunctiva. A malformation sometimes occurs in which one part of the cornea is covered by a prolongation of the conjunctiva.

the cornea. It is useless to introduce the tube deeper, for the lymphatic network is entirely superficial.

Uses.—The transparent cornea is the first medium through which the rays of light have to pass; in consequence of its density and its convexity, it refracts the rays of light, and causes them to converge. The density of the cornea is the same in different persons; but its convexity is subject to variations, upon which depend, in a great measure, the states of myopia (short sight), presbyopia (long sight), and natural vision.

The Choroid Coat, and the Ciliary Circle and Processes.

The *choroid* (indicated by the thick black line, *c*, *fig.* 241), so called from its extreme vascularity,* is the second membrane of the eye, proceeding from without inward; it is a vascular membrane, covered with a thick layer of pigment: it exactly lines the sclerotic, and terminates, like it, at the circumference of the cornea.

Its *external surface* (*c*, *figs.* 242, 244) adheres to the schlerotic by means of the ciliary vessels and nerves, and by a thin and very delicate cellular tissue, which is easily lacerated, and when raised appears like a spider's web.† This surface, when magnified, has a flocculent appearance.

Its *internal surface* is in relation with, but does not adhere to, the retina (*r*, *fig.* 241), by which it is lined nearly throughout its whole extent.

Both surfaces of the choroid are covered with a pigment, which resembles the pigment of the skin of negroes; this pigment is much more abundant on the internal than on the external surface, and less so behind than in front, where it forms a thick layer, in the form of a zone surrounding the corona ciliaris.

Upon both surfaces are found innumerable longitudinal and contorted lines, which correspond to the vessels of the choroid.

In a great number of animals, in the ox, for example, the pigment on the internal surface of the choroid at the back of the eye is replaced by a brilliant metallic-looking substance called the tapetum. When deprived of its pigment, the internal surface of the choroid presents a smooth aspect, and is not flocculent like the external surface. It is of a grayish-white colour, and anteriorly, where it is covered by a thick layer of pigment, it becomes white and shining when the pigment is removed.

Behind, the choroid is pierced by a circular opening for the passage of the optic nerve; *in front*, it terminates in the *ciliary circle* and *ciliary processes*, which must be regarded as appendages to it.

The Ciliary Circle.—The *ciliary circle*, *ring*, or *ligament* (*n*, *fig*, 241; *b*, *figs.* 242, 244), is a circular zone, from a line to a line and a half in breadth, of a grayish colour, and soft consistence, which bounds the choroid coat (*c c*) in front. It is of considerable thickness. Its external surface corresponds to the sclerotic, to which it is slightly adherent. Its internal surface corresponds to the ciliary processes (*e*, *fig.* 241); by its outer or larger border, which is distinguished from the choroid by a slight ridge, it receives the ciliary nerves (*a a*, *fig.* 242), which bifurcate, and appear to anastomose with each other before they enter the substance of the ciliary circle: by its lesser or inner border, which corresponds to the iris (*i*), it adheres intimately to the circumference of the cornea, exactly where that membrane is continuous with the sclerotic (at *a a*, *fig.* 241). The older anatomists called this structure the *ciliary ligament*. From the great number of the nerves which enter the ciliary circle, from its grayish colour, and its pulpy aspect, modern anatomists have regarded it as a nervous ganglion (annulus gangliformis, or annular ganglion, *Sœmmering*).

Fig. 241.

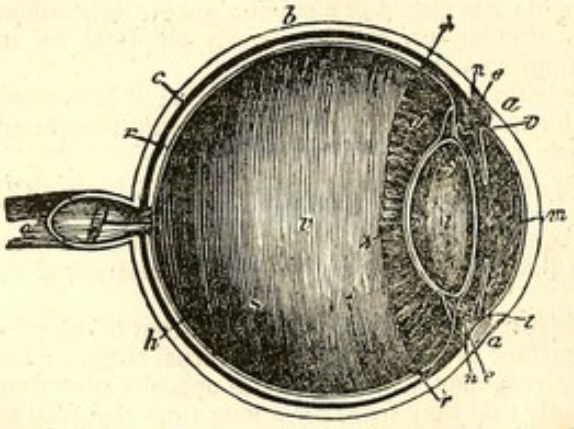

Fig. 242.

Anterior view.

Some anatomists describe, under the name of the *ciliary canal*, or the *canal of Fontana*, a very small and extremely narrow circular space (*v v*, *fig.* 241), which is formed between the ciliary circle, the cornea, and the sclerotic. This space can be filled with injection, and it is not certain that it is not the cavity of a bloodvessel.

The Ciliary Processes and the Ciliary Body.—If the back part of the sclerotic, choroid, and retina be cut away, or even if the globe of the eye be merely divided into an anterior and posterior

* Choroid is synonymous with vascular.

† [A serous cavity is said by some to exist between the sclerotic and choroid; the lining membrane of this supposed cavity is named the arachnoid membrane of the eye.]

half by a circular incision, on looking into the anterior half a perfectly regular radiated disc (*d*, *fig.* 241 ; *a b*, *fig.* 243) will be seen around the crystalline lens. This disc, which has been very correctly compared to a radiated flower, is called the *ciliary body*, or *corona ciliaris ;* each of the rays is called a *ciliary process* or *ray* (rayon sous-irien, *Chaussier*). If, after a correct idea of the arrangement of this radiated disc has been obtained, the choroid coat be separated from the humours of the eye, it will be found that there are two perfectly distinct discs : one of these remains attached to the choroid coat, and constitutes the *ciliary disc* or *ciliary body of the choroid* (*a b*, *fig.* 243) ; the other remains attached to the vitreous body and to the crystalline lens, and is the *ciliary zone of Zinn*, which may be termed, after M. Ribes, the *ciliary processes of the vitreous body* (*a b*, *fig.* 248). We shall now describe the ciliary processes of the choroid coat only, leaving the ciliary processes of the vitreous body to be described together with that part of the eye.

Fig. 243.

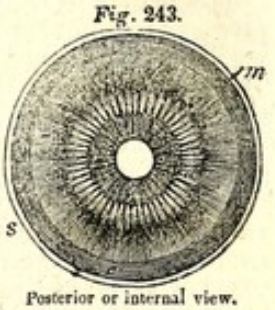

Posterior or internal view.

The ciliary processes of the choroid coat, so well described by Zinn, who enumerates sixty of them, are regarded as so many folds of the internal layer of the choroid. They may be divided into *great* and *small*, the latter occupying the intervals between the former. They all increase in size (from *b* to *a*, *fig.* 243) as they approach the outer border of the iris, behind which they are prolonged without adhering to it, and are then bent forward upon themselves, to be attached to that border. These ciliary processes, the sides of which are turned towards each other, have, therefore, a posterior *adherent* or *choroid portion* (*b*), and an anterior *free* or *iridian portion* (*a*). The free portion (*e e*, *fig.* 241 ; *a*, *fig.* 244) floats among the humours of the eye like a fringe ; the slightest agitation of the vessel or of the liquid in which the ciliary processes are contained is immediately communicated to this free portion of the corona ciliaris.

Fig. 244.

Anterior view—iris removed

The *ciliary body* or *disc*, which is formed by the union of all the ciliary processes or rays, is in relation behind with the vitreous body (*v* in the centre, *fig.* 241), and advances (*e*, *fig.* 241 ; *a*, *fig.* 244, in which the iris is removed) over the circumference of the crystalline lens. It is not simply in contact with the vitreous body, but is rather firmly adherent to it ; and we shall afterward see that they are dovetailed together, that is, the ciliary processes of the vitreous body are fitted into the intervals between the ciliary processes of the choroid, and *vice versâ*.

If the thick layer of pigment with which they are covered be removed, the ciliary processes of the choroid, when examined through a lens under water, have a white colour. In their substance are seen irregular cells which are filled with the brown pigment, and which give them a spongy, and, as it were, jagged appearance. They are evidently continuous with the choroid, which immediately around them presents a zone of a whiter colour than the rest of the inner surface of that membrane.

Structure of the Choroid Coat and its Ciliary Processes.—The structure of these parts is essentially vascular. Fine injections thrown into the carotid artery and internal jugular vein, in young subjects, fill a beautiful network of vessels in this membrane. The *vorticose* arrangement (*v*, *fig.* 244) of some of these vessels is then clearly displayed ; and, indeed, this is very well indicated, without the aid of an injection, by the striæ already described as visible upon the surfaces of the choroid. The short ciliary arteries belong exclusively to the choroid coat. From a great number of experiments made by M. Ribes, it would appear that injections pushed into the arteries do not enter the villi and fringes of the ciliary body, but that their vessels may be filled from the veins ; so that, according to this, the structure of the free and fringed portion of the ciliary processes is altogether venous, like the cavernous or erectile tissues.*

From the different appearance of the external and internal surfaces of the choroid, anatomists have regarded this coat as being composed of two layers, of which the internal is called the *membrana Ruyschiana*, after Ruysch, who has given the best description of it. According to one view, which is not altogether unsupported, the internal layer alone concurs in the formation of the ciliary processes, while the external layer corresponds to the ciliary ring.

The Iris.

The *iris* (*i*, *figs.* 242, 243), so called on account of the varied colours which it presents, is a membranous vertical septum, perforated in the centre, like the diaphragm of an optical instrument. By means of this septum (*i*, *fig.* 241), the space (*p*) between the cornea (*m*) and the crystalline lens (*l*) is divided into two parts or *chambers*, an *anterior* and a *posterior*. The iris is circular, and perforated in its centre by an opening which constitutes the *pupil* (*p*, *fig.* 242), vulgarly, the apple of the eye, and which is surrounded by the *lesser* or *inner border of the iris ;* the pupil is circular in the human subject, and oblong,

* [In successful injections, arterial as well as venous ramifications are demonstrated in the ciliary processes.]

either transversely or vertically, in the lower animals ; the number of luminous rays suffered to impinge upon the retina are regulated by variations in the size of this opening. We constantly find in several kinds of animals, and occasionally in the human subject, small fringes attached to the lesser border of the iris, which float in the aqueous humour.

The *outer* or *greater border of the iris* is, as it were, fitted in between the ciliary ligament, which projects beyond it slightly in front, and the ciliary processes, which encroach upon it behind (*see fig.* 241). The manner in which it adheres to these parts is not well understood. There is a true continuity of tissue, and yet they may be separated by a slight degree of force ; on this is founded the operation for *artificial pupil* by detaching the iris. The outer border of the iris is not continuous with the circumference of the cornea.

The *anterior surface of the iris* (*i, fig.* 242), with its different shades of colour, is the part which is seen through the transparent cornea ; it is plane, not convex. The interval between it and the cornea constitutes the anterior chamber of the eye (*fig.* 241). The form and size of this interval can be correctly estimated in a frozen eye ; it is filled with the aqueous humour ; its longest diameter from before backward is about one line.

When examined with a lens, the anterior surface of the iris has a *flocculent* appearance, more distinct than, but similar to, that of the external surface of the choroid. It appears as if it were fissured here and there, and in the human subject presents some very well-marked radiated bands. When the pupil is contracted these radiated bands are straight, but during its dilatation they become flexuous. They appear to interlace, and thus to become blended with each other near the pupil. It is generally admitted that the membrane of the aqueous humour covers the anterior surface of the iris ; but it cannot be demonstrated in that situation. The colour of this surface differs in different individuals, and it has generally some relation to that of the hair ; upon these differences depend the colour of the eyes, whether blue, black, gray, &c. Whatever may be the colour of the iris, two shades of different intensity may be distinguished in it, and occasion the appearance of two concentric coloured zones in this membrane ; the smaller and deeper-coloured zone is situated near the pupil ; the larger and lighter-coloured one includes the two outer thirds of the membrane. It is not always easy to distinguish these two zones.

The *posterior surface* (*i, fig.* 243) of the iris corresponds to the crystalline lens, from which it is separated by an interval filled with the aqueous humour, and called the *posterior chamber of the eye* (*fig.* 241).

The two chambers of the eye, therefore, communicate at the pupil (*p*).

The posterior surface of the iris is covered by a thick layer of pigment, which is continuous with the pigment of the choroid ; near its outer border it is also overlaid by the free or iridian portion (*e e*) of the ciliary processes of the choroid, which can be easily turned back so as to expose the entire posterior surface. It presents extremely well-marked radiated bands, which can be well seen, even before the choroid pigment is removed.

The aspect of the posterior surface of the iris differs essentially from that of the anterior surface ; it is white and smooth, and resembles in many respects the internal surface of the choroid. Some anatomists are of opinion that the posterior surface of the iris is covered by the membrane of the aqueous humour. If such be the case, it is difficult to comprehend how that membrane is arranged with reference to the pigment.

Structure.—The iris is three or four times as thick as the choroid ; it diminishes in thickness from its outer to its inner border. Its real structure is but little understood. The old opinion of its muscularity, which was refuted by Weitbrecht and Demours, has been revived by M. Maunoir, who admits two sets of muscular fibres, viz., radiated fibres, which correspond to the external coloured ring, and circular fibres, which correspond to the internal coloured ring, and form a sort of sphincter around the pupil ; but no circular fibres can be distinguished around the pupil. An appearance as if such were the case, is occasioned by a peculiar arrangement of the radiated fibres, which seem to bifurcate opposite the internal coloured ring, to interlace with each other, and then terminate abruptly around the pupil ; so that the inner border of the iris, or the pupil, appears to be formed by the blunt extremities of these radiated fibres.

In the ox and the sheep, the iris has two very distinct sets of fibres : an anterior and circular layer, which occupies the whole of the anterior surface ; and a posterior and radiated set of fibres, which converge from the outer to the inner border. The anterior set of fibres does not exist in the human subject.

Another and much more plausible opinion regarding the structure of the iris is, that it consists of a *vascular* or *erectile* texture.*

If we examine an oblique section of the iris under a lens, we find, indeed, that it has an areolar spongy structure ; and the extreme vascularity of this part also supports the same view.

* A case is related of a young man who could produce contraction of the pupils by holding his breath.

[The muscularity of the fibres of the iris is now established beyond a doubt ; the fibres of the iris of the pig are described by Schwann as being very minute, cylindrical, and not beaded ; they therefore resemble the muscular fibres of organic life.]

Arteries of the Iris.—The *arteries* of the iris are principally derived from the two long ciliary arteries, which bifurcate and anastomose after they have reached the ciliary ligament, and form a vascular circle, which gives off radiated vessels that converge from the outer border of the iris towards the pupil. There are also some anastomotic arches near the pupil.

Veins of the Iris.—The *veins* of the iris are much more numerous than the arteries; they terminate in the venæ comites of the long ciliary arteries, and in the *vasa vorticosa*.

Nerves.—The nerves of the iris, or *ciliary nerves* (*a a*, *fig.* 242), are very large; as we have stated, they gain the ciliary circle, and then pass through it in great numbers, to enter the iris, and be distributed in its substance. Most of these nerves are given off from the ophthalmic ganglion: some of them are derived directly from the nasal nerve, which is a branch of the fifth cranial nerve.

The older anatomists distinguished two layers in the iris: one *anterior*, which they called the *membrane of the iris*; the other *posterior*, covered with pigment, which they called *membrana uvea*. By examining an oblique section of the iris with a lens, two layers may, in fact, be seen, separated by the spongy tissue of which I have spoken

The Membrana Pupillaris.

Dissection.—By opening the eye of the fœtus from behind, this vascular membrane may be easily seen through the vitreous body and the crystalline lens.

In the fœtus, the opening of the pupil is closed by a membane, called the *membrana pupillaris*, which was discovered and very well described by Wachendorf, but more perfectly so by Haller and Sœmmering, and recently by M. Jules Cloquet. It may be seen about the third month of intra-uterine life, and generally disappears towards the seventh month. When persistent, it may occasion congenital blindness. Wachendorf and Sœmmering have demonstrated the vessels of this membrane, which are continuous with those of the iris. During the existence of the membrana pupillaris, the membrane of the aqueous humour forms a shut sac. From the researches of M. Jules Cloquet concerning the pupillary membrane, it appears that it consists of two thin layers, between which the bloodvessels are arranged in loops; that the convexities of these loops are turned towards each other, but that the loops which approach each other from opposite sides do not anastomose together; that between these loops, and towards the centre of the pupil, there is a small irregular portion of the membrane which is destitute of vessels, and is, therefore, weaker than any other part; that the formation of the pupil is effected by the rupture of this membrane, and that this rupture is occasioned by the retraction of the vascular loops, which ultimately occupy the lesser border of the iris.

Uses of the Iris.—The iris regulates the quantity of light that is admitted into the interior of the eye. The contraction of the pupil is an active movement, and its dilatation is passive; facts which are opposed to the doctrine of its muscularity, but support the idea of its being a vascular and erectile structure.

It has been stated that the movements of the iris are intended to enable us to judge of the distance and size of objects, or, rather, to enable us to see objects at different distances: this is erroneous, for the pupil remains of the same size, under the action of a similar quantity of light, whether the object looked at be near or distant.* The effect of narcotics, and especially of belladonna, either applied topically, or taken internally, in producing dilatation of the pupil, is one of the most curious facts concerning the iris. The direct action of the rays of light upon the iris has no influence upon the size of the pupil, the dimensions of which are altered either by the action of light upon the retina, or in consequence of a peculiar condition of the optic nerve of the brain

The Pigment of the Eye.

It has been stated that the external surface of the choroid and the internal surface of the sclerotic are coloured by a very thin layer of pigment; and also that the internal surface of the choroid is covered with a thicker layer, which is itself thickest on the fore part of that surface, near the ciliary body, between the greater ciliary processes, and behind the iris. By means of this pigment the interior of the eye is converted into a true dark chamber. Still, it may be asked why the pigment is less abundant behind than in front.

The choroid pigment is not black, but of a very dark-brown colour, like bistre; in this respect resembling the pigment of the skin of the negro; it consists of molecules or globules insoluble in water.

The pigment of the choroid of the iris is wanting in albinoes, as well as the cutaneous pigment. Both have the same chemical composition.†

* [The pupil certainly dilates in looking at distant objects, and contracts under the opposite circumstances; but it is by no means certain that the adjustment of the eye to objects at different distances depends on these alterations in the condition of the iris.]

† [The pigment of the eye consists of nucleated cells containing the pigment granules; on the inner surface of the choroid these cells are flattened and hexagonal, and their sides fit accurately together, so as to present an appearance like mosaic work; on the back of the iris the cells are irregularly rounded. In albinoes the cells contain no coloured granules.]

In some animals the pigment of the eye has a metallic lustre, and an iridescent aspect in a great part of its extent.

The Retina.

The *retina* (*r*, *figs.* 241, 245), counting from without inward, is the third membrane of the eye; it is the immediate seat of vision, and is an essentially nervous membrane, situated within the choroid and the sclerotic. Its *external surface* (*r*, *fig.* 245) corresponds to the choroid, from which it is separated by the pigment, which, in eyes that have undergone slight decomposition, forms an irregular layer upon it, like a web. Dr. Jacob (*Philosoph. Trans.*, 1819) has described a serous membrane between the retina and the choroid, in the cavity of which a dropsical effusion may occur, and constitute what is called *posterior staphyloma of the eye.* M. Weber believes that this membrane is prolonged forward to the circumference of the crystalline lens, and is then reflected over the posterior surface of the iris, where it becomes continuous with the membrane of the aqueous humour. I have not succeeded in demonstrating the membrane of Jacob.*

The *internal surface* (*r*, *fig.* 246) of the retina is applied to the vitreous body, but does not adhere in the slightest degree to it.

The point at which the retina terminates in front is still regarded by most anatomists as undetermined. Several, with the older authors, describe it as extending to the circumference of the crystalline lens. Some entertain a modification of this opinion, believing that an extremely thin membrane is given off from the rim (*r' r'*, *fig.* 241) in which the retina seems to terminate, and that this membrane advances upon the inner surface of the ciliary body to the front of the capsule of the crystalline lens, to which it is attached. M. Dugès, in an excellent work upon the comparative anatomy of the organ of vision, expresses a somewhat different opinion: according to his view, the retina having reached the ciliary processes, divides into numerous tongues, each of which passes between two of the ciliary processes, and terminates by expanding upon the circumference of the crystalline lens. A careful examination has proved to me distinctly that the retina terminates by a defined edge (margo dentatus, *r' r'*, *fig.* 241; *m*, *fig.* 245) at the posterior extremities of the ciliary processes of the vitreous body (*a*), to which processes it adheres rather firmly, though it can be sometimes separated from them without laceration.

Fig. 245.

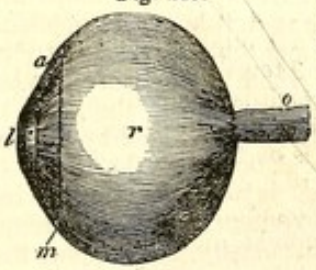

Is the retina an expansion of the medullary part of the optic nerve, or is it a special organ continuous with that nerve? Although the former of these opinions appears more probable than the latter, still it is liable to objections. The optic nerve is constructed in a particular manner as it passes through the sclerotic, and the corresponding nervous substance is so arranged that pressure upon the nerve does not force the nervous substance into the interior of the eye, though pressure upon every other part of the nerve causes a white pulpy matter to exude from its divided surface.

The retina is semi-transparent, like a thin layer of opal: it scarcely holds together, and can be torn with the greatest facility. It does not appear to me to be thicker behind than in front.

The radiated lines stated by several of the older anatomists, and also by M. Dugès, to exist in the retina, can only be distinguished behind at the entrance of the optic nerve. This radiated character was evident in the eye of an ox which I recently examined. The optic nerve divided into three thick diverging bundles, which expanded into a layer; but this filamentous arrangement was soon succeeded by what appeared, at least, to be a pulpy structure.

Two layers are described in the retina: an *external*, which is pulpy and nervous; and an *internal*, which is vascular, and is formed by the ramifications of the arteria centralis retinæ; but this subdivision of the retina is purely fictitious. Sœmmering has given a good representation of the vascular network, which seems in some manner to support the nervous substance.

The Foramen Centrale, the Fold, and the Limbus Luteus of the Retina.—Sœmmering was the first to describe in the retina a foramen (*foramen centrale*), which had escaped the researches of Ruysch, Zinn, and Haller, doubtless because it is concealed by the folds formed by the retina at this point.

It is doubtful whether these *folds* of the retina result from the collapsed condition of the eyeball, which necessarily follows the dissection required for the examination of its interior; or whether they are really part of its structure, and should be regarded as the vestige of the singular folds existing in different kinds of animals, and especially in birds, the visual powers of which are thereby greatly increased. However this may be, the foramen, which is always situated to the outer side of the entrance (*b*, *fig.* 246) of the

* [If the posterior part of the sclerotic and choroid be carefully removed from a fresh eye (leaving the optic nerve untouched), and the eye be then macerated a few hours in water, portions of Jacob's membrane will either separate, or they can easily be separated from the outer surface of the retina.]

optic nerve, is surrounded with a zone of a canary-yellow colour: this is the *limbus luteus foraminis centralis* (*Sœmmering*), or the *yellow spot of Sœmmering* (*a*).

Fig. 246.

Interior of left eye.

The *foramen centrale* and the *limbus luteus* exist in man and the quadrumana only; that is to say, in those cases only in which the visual axes of the two eyes are parallel to each other, as in man.

I have not found that the yellow spot corresponds to the thickest part of the retina

It should, moreover, be observed, that the foramen centrale, not the entrance of the optic nerve, corresponds to the antero-posterior axis of the globe of the eye, and is the true centre of the retina.

The uses of the central foramen and the yellow spot are not known.

The yellow spot does not exist in the fœtus.*

The Humours of the Eye.

The media through which the light passes in the eye, besides the transparent cornea already described, are the *vitreous body*, the *crystalline lens*, and the *aqueous humour*.

The Vitreous or Hyaloid Body.

The *vitreous* or *hyaloid body* (*v*, *figs.* 247, 248) (from ὕαλος, glass), so called from its resemblance to glass, is an imperfectly spheroidal, and quite transparent mass, which occupies the posterior three fourths (*v*, *fig.* 241) of the globe of the eye; it is covered immediately by the retina (*v*, *fig.* 245), which is simply in contact with it, and indirectly by the other coats of the back part of the eye, which are accurately moulded upon it. It presents a slight depression in front, for the reception of the posterior surface of the crystalline lens (*l*). The vitreous body and the crystalline lens together very nearly resemble in form the entire globe of the eye, the projection of the crystalline lens representing the prominence of the cornea (compare *figs.* 241 and 245).

The vitreous body is composed of a liquid, named the *vitreous humour*,† and of the *hyaloid membrane*.

The *hyaloid membrane* (*h*, *fig.* 241), which was first discovered by Fallopius, can be easily demonstrated by puncturing the vitreous body, and allowing the vitreous humour to escape. If it be then dipped in diluted nitric acid, the membrane will become opaque, and easily distinguishable. This membrane not only forms a general investment or capsule for the vitreous body, but gives off lamellar prolongations from its internal surface, which separate the vitreous humour into an irregular number of *compartments*, or *cells*. The existence of these cells can be easily proved by moving the vitreous body between the fingers; and if this body be frozen, their shape is shown by that of the masses of ice which may be taken from them.

It is generally admitted that all these cells communicate with each other; because, when one of them only is punctured, all the vitreous humour will gradually escape. Still, I have several times observed that the eye did not collapse when a part of the vitreous body had escaped in the operation for extracting a cataract; this, however, might have depended upon any farther escape being opposed by the approximation of the lips of the incision.

The manner in which the hyaloid membrane is arranged with reference to the crystalline lens is still a disputed point. It is generally admitted that, about a line from the margin of the crystalline lens, the hyaloid membrane divides into two layers, one of which passes behind (*h*, *fig.* 241) and the other in front of the lens. The three-sided interval (*s s*) which exists all round the crystalline lens, and which has been described by François Petit, under the name of *canal godronné*, is formed between these two layers and the lens. This circular canal, or *canal of Petit*, can be very easily shown by blowing air into it (as in *p*, *fig.* 247); it is then seen to be constricted at intervals, as if by small folds or bands, so that it presents a knotted or plaited appearance. Other anatomists, on the contrary, state that the hyaloid membrane does not split into two layers, but passes altogether behind the crystalline lens, in order to cover the front of the vitreous body. It is certain that

Fig. 247.

* [From recent researches, especially those of Valentin and Hanover, the following appears to be the minute structure of the retina: 1. The membrane of Jacob consists of minute cylindrical or prismatic bodies, placed closely together, and perpendicularly to the surface of the membrane; among these are somewhat larger bodies, "coni gemini," which might be compared in shape to two cylinders applied to each other lengthwise. Both kinds of bodies are attached by one extremity to the inner surface of the choroid, being received into exceedingly minute sheaths, which rise from the surface of the pigment cells. 2. The filaments of the optic nerve spread out on the inner surface of this structure, and, according to Valentin, have a plexiform arrangement, but their mode of termination seems doubtful. This nervous expansion is covered on its outer and also on its inner surface by a layer of ganglionic globules.]

† [The vitreous humour, according to Berzelius, contains 98·4 per cent. of water; its solid matter consists of albumen, extractive matter, and chloride of sodium.]

a circular layer, having the form of a radiated crown, is given off from the anterior part of the hyaloid membrane; this circular radiated disk was described by Petit and Camper, but it is called the *corona ciliaris*, or the *zonula Zinni:* it corresponds accurately to the ciliary processes and ciliary body of the choroid coat.

The *ciliary zone of Zinn* (*a*, *fig.* 245, *b*, *figs.* 247, 248), or *the ciliary processes of the vitreous body*, can be seen through that transparent body (*d*, *fig.* 241) when the several coats are removed from the back part of the globe of the eye: it is completely exposed to view when the choroid coat and the iris are separated from the vitreous body (*fig.* 248). It is this structure which constitutes the beautiful radiated crown situated in front of the vitreous body around the crystalline lens, and which extends considerably beyond the ciliary body of the choroid; it consists of alternate black and transparent rays, and is generally regarded as a reverse impression of the ciliary processes of the choroid. The ciliary processes of the vitreous body correspond to the black lines, and the intervals between the processes to the transparent rays.

Fig. 248.

The ciliary processes of the vitreous body are not so thick as those of the choroid; but the folds of which they consist commence farther back than the ciliary processes of the choroid, so that the radiated disc formed by them is larger than that formed by the processes of the choroid. These folds of the vitreous body have the same spongy and jagged appearance as those of the choroid: they have no free portion, or, rather, that part of the zone of Zinn (*a*, *fig.* 248) which corresponds to the free portion of the ciliary processes of the choroid is applied to the crystalline lens.

The ciliary processes of the choroid and those of the vitreous body are so arranged that those of the one are received in the intervals between those of the other. It appears to me difficult to determine whether they are simply applied to each other, or whether their structure is continuous. However, on examining these parts through a lens while they are being separated, it has appeared to me that a sort of cellular structure was lacerated, and that the black pigment, which had been hitherto confined, escaped together with a little fluid. M. Ribes believes that, during this separation, some shreds of the hyaloid membrane are drawn away with the ciliary processes of the choroid.

The inner border (*a*) of the ciliary zone of Zinn is in contact with the margin of the crystalline lens (*l*), and adheres rather firmly to it. Around the outer border, which extends beyond the ciliary body of the choroid, are found the origins of certain radiated folds (*b*), which form, as it were, the commencement of the ciliary processes. This border adheres to the anterior margin of the retina (*m*, *fig.* 245), which appears to me to be thickened and slightly uneven in this situation, and not to be continuous with the hyaloid membrane.

From what has been stated, it follows that the canal of Petit is formed between the hyaloid membrane and the zone of Zinn, and that the crystalline lens is fixed by this zone to the anterior margin of the vitreous body; that the anterior surface of the crystalline lens is not covered by a prolongation of the hyaloid membrane, besides its own capsule; and that the retina does not reach as far as the margin of the crystalline lens.

M. Jules Cloquet has described, under the name of the *hyaloid canal*, a cylindrical passage, which is formed by the reflection of the hyaloid membrane into the interior of the vitreous body around the nutritious artery of the lens, and which, like that artery, traverses the vitreous body from behind forward. I have never been able to see this canal.

No vessels have been demonstrated in the hyaloid membrane; it does not receive any from the retina, and yet we cannot doubt that it is provided with them. Although the structure of the ciliary processes of the vitreous body is little known, yet, as it is probable that it is similar to that of the ciliary processes of the choroid, and, therefore, essentially vascular, it may be, as stated by M. Ribes, that the materials for the formation and nutrition of the lens and of the ciliary processes of the vitreous body are conveyed to both of these parts through the vascular ciliary processes of the choroid.

The Crystalline Lens and its Capsule.

The *crystalline lens* (*l*, *figs.* 241, 244, 245, 248) is a transparent body, having the form of a lens, as its name implies; it is situated at the junction of the posterior three fourths with the anterior fourth of the globe of the eye, and is placed between the vitreous body, which is behind, and the aqueous humour, which is in front (see *fig.* 241).

Its axis corresponds to the centre of the pupil.

It is shaped like a double convex lens, the posterior surface of which is more convex than the anterior. From some very exact and minute investigations which have been made upon this point by François Petit and others, it appears that both the relative and the absolute convexity of the two surfaces of the crystalline lens are subject to great varieties in different individuals; that, in general, the posterior convexity forms part of a circle from four to five lines in diameter, while the anterior forms part of one from six to nine lines in diameter. In some subjects the degree of curvature of the two surfaces

of the crystalline lens is almost equal. In the fœtus the crystalline lens approaches the spheroidal form, which is that which it has in fishes.

The *anterior surface* of the crystalline lens corresponds to the iris, from which it is separated by the aqueous humour. It has been incorrectly stated by Winslow that the crystalline lens pushes the iris forward: there is a space between the crystalline lens and the iris which constitutes the posterior chamber of the eye. The anterior surface of the lens may be seen through the pupil, so that slight shades of difference in the colour of the lens may be detected. When the pupil is very much dilated, the anterior surface of the lens is entirely exposed.

Its *posterior surface* is in relation with the vitreous body, which is depressed so as to receive it. This surface does not adhere to the hyaloid membrane. When dissecting a subject of twenty-seven years of age who had suffered with hydrophthalmia in both eyes, M. Ribes found about six grains of a limpid fluid between the hyaloid membrane and the crystalline lens; so that the space occupied by this fluid might have been taken for a third chamber.

The margin of the lens (*l*, *fig.* 248) is set (like the stone of a brooch) in the ciliary processes (*a*) of the vitreous body, which cover and adhere to the fore part of that margin, so that the lens is kept firmly in its place. Its margin is surrounded by the canal of Petit (*fig.* 247).

The crystalline lens presents different shades of colour at different periods of life. It is reddish in the fœtus, but is perfectly transparent after birth; in the adult, it becomes slightly opaline at the centre; in the aged, it acquires a yellowish opacity, which approaches somewhat to the colour of amber or topaz. Morbid opacity of the lens constitutes lenticular cataract.

The crystalline lens consists of a *capsule*, and of a *proper substance* enclosed within it.

The Substance of the Crystalline Lens.—When stripped of its capsule, the crystalline lens is found to have three degrees of consistence, at different parts: thus, at its surface, it is almost of a liquid softness; below this, it is soft and gelatinous, and may be crushed by the finger—this is the *cortical layer*; and, lastly, it is hard in the centre, which is called the *nucleus*, and closely resembles a mass of gum-arabic. The most superficial and fluid layers constitute the *liquor Morgagni*.

The substance of the crystalline lens consists of concentric layers (*b c*, *fig.* 249), which can be very easily demonstrated, even without any previous preparation, but are rendered most distinct by boiling, or immersion in a diluted acid. The crystalline lens then separates into superimposed laminæ or scales, like the bulb of the onion.

Fig. 249.

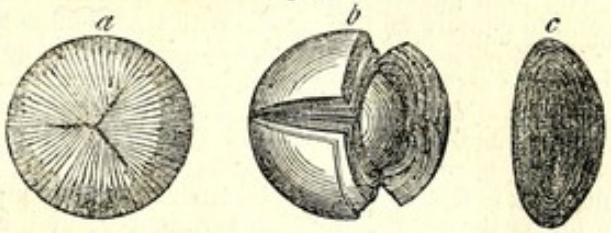

The different degrees of consistence observed in the substance of the lens do not depend upon differences in nature, but upon mere modifications. When hardened by an acid, the structure of the lens is exactly the same throughout: even the liquor Morgagni appears to become laminated.

Each of these concentric laminæ is itself composed of radiated fibres (*a*, *fig.* 249), which can be readily seen without dissection, by placing one of them upon a black surface, and examining it through a lens, or even by a strong light.

Lastly, the crystalline lens, when boiled, or submitted to the action of an acid, splits into three, four, or even a greater number of triangular segments (*a b*), all of which unite by their summits at the centre of the lens, so that its anterior and posterior surfaces have a stellate appearance.* Pathologists have successfully applied this anatomical fact to the explanation of the stellate forms of cataract, in which the opacity branches out in three or more directions.

What is the nature of the crystalline lens? Is it the product of a secretion? or is it an organized structure? M. Dugès has recently supported by his authority and by additional facts the opinion of Dr. Young, who believed that the crystalline lens is not only an active organized structure, supplied with vessels and veins, but that it is even muscular and possessed of contractility, so as to be able of itself to increase or diminish its curvatures and its density, thus endowing the eye with the power of adjusting itself to the different distances of the objects to be seen. The substance of the laminæ of the crystalline lens has, indeed, a linear structure; but it does not at all resemble muscular tissue, either in its consistence or in its regularly stratified character. I conceive, therefore, that I am warranted in regarding the superimposed layers of the crystalline lens as the solidified product of a secretion formed by its capsule.†

* See note, *infrà*.

† [The lines indicating the divisions between the triangular segments of the lens (*a*, *fig.* 249) are called *septa*; the septa of the anterior surface are placed opposite the intervals between the septa of the posterior surface. The fibres of which the laminæ are composed have a linear arrangement, and, as discovered by Sir D. Brewster, are fitted into each other by indented margins (*fig.* 250). Schwann has shown that these fibres are developed from rounded, nucleated cells, which become elongated into fibres, the margins of which sub-

The *capsule of the crystalline lens* (*t*, *fig.* 241) is accurately fitted to the lens itself; in the healthy state it is transparent, but may become opaque, and thus constitute a membranous or capsular cataract.

Its external surface is free in front, where it is bathed by the aqueous humour: it is merely in contact with the hyaloid membrane behind, but its circumference adheres intimately to that membrane, or, rather, to the ciliary zone of Zinn.

Its internal surface does not appear in the slightest degree adherent to the lens. If an incision be made into this capsule in the living subject, the lens is forced out merely by the tonicity of the coats of the eye. The anterior segment of the capsule is twice as thick as the posterior: it might be compared to a layer of the cornea.*

It receives bloodvessels derived from the arteria centralis retinæ.† These vessels, according to Meckel, are distributed only upon the posterior half of the capsule; those which belong to the anterior half arise from the vessels of the ciliary processes.

Some anatomists believe that these vessels send ramifications between the different concentric laminæ of the crystalline lens for its nutrition; but I am not aware that they have ever been demonstrated.

No nerves have been discovered in the crystalline lens. M. Dugès believes that the retina gives off some nervous filaments which reach as far as the lens, and spread out upon its capsule; but, after the most careful examination, I am convinced that such is not the case.

The Aqueous Humour and its Membrane.

The term *aqueous humour* is applied to a perfectly limpid and transparent fluid, which occupies the two chambers of the eye. These two chambers, which have been correctly understood only since the discovery of the true seat of cataract in the crystalline lens, correspond to that small portion of the cavity of the eye which is situated between the cornea and the lens (see *fig.* 241). The space between these two parts is divided unequally by the iris (*i*) into two chambers: an anterior and larger, which is called the *anterior chamber*; and a posterior and smaller, named the *posterior chamber*. These two chambers communicate through the pupil (*p*). The existence of the posterior chamber was long disputed, but it may easily be proved by freezing the eye; and by the same experiment we may obtain an approximation to the relative capacity of the two chambers, which will be found as 3 to 1, the anterior being decidedly the larger.

The total quantity of the aqueous humour is about five grains; 100 parts of it are found to contain 98·1 of water, with traces of albumen and chloride of sodium.

The Membrane of the Aqueous Humour.—It is now generally admitted that the aqueous humour is secreted by a special membrane, called the *membrane of the aqueous humour*, or *membrane of Demours*, although it had been previously described by Zinn and Descemet. This membrane, according to Demours, lines the posterior surface of the cornea (*m*, *fig.* 241), and is reflected upon the front of the iris. At this point, according to most anatomists, it is lost, and cannot be traced to the pupil; but, according to others, it proceeds as far as the pupil, and there terminates; and, lastly, some believe that it is reflected through the pupil, in order to cover the posterior surface of the iris, where it retains the pigment in its situation.

It is easy to detach a tolerably thick and strong layer, of a cartilaginous aspect, from the posterior surface of the cornea, either after long-continued maceration, or after slight boiling; but it is not shown that this is anything more than the posterior layer of the cornea, which it resembles in appearance.

It is only from analogy that the existence of the membrane of the aqueous humour can be admitted.

We cannot demonstrate anatomically its reflection upon the outer border of the iris; and, moreover, it is certain that it does not exist upon either surface of that membrane.

According to M. Ribes, the aqueous humour is supplied by the vitreous body, and is poured into the posterior chamber by the canals said by him to exist in the substance of the ciliary processes of the vitreous body. This opinion is founded, 1. Upon an experiment which consists in carefully removing the cornea, and suspending the eye by the optic nerve, when the vitreous humour will exude from the wound of the cornea, so that, in less than twenty-four hours, two thirds of that body will have escaped; and, 2. Upon the observation of cases of imperfect iris, in which, according to M. Ribes, the aqueous

Fig. 250.

sequently become dentated; the lens, therefore, resembles some other non-vascular parts (as the horny tissues) in its mode of growth. It consists, according to Berzelius, of 58·0 per cent. of water, 3·7 of extractive and salts, 2·4 of membrane, and 35·9 of a peculiar substance, which, except in its colour, resembles the colouring matter of the blood.

* According to M. Ribes, whom I always have pleasure in quoting, because his researches are worthy of every confidence, "by examining the internal surface of the crystalline capsule in a good light, and with a good lens, a series of transverse fissures are observed around its entire circumference, where the anterior and posterior segments of the capsule unite. I could never satisfy myself whether these fissures corresponded to the ciliary processes of the vitreous body, or to the villous fringes of the ciliary processes of the choroid."

† Vide fig. v., pl. 6, of Sœmmering's *Icones Oculi Humani*.

humour is contained entirely in the posterior chamber. He believes that the free portion of the vitreous ciliary body has the power of absorbing this liquid.

M. Dugès adopts the following modification of this opinion: the canal of Petit, according to him, is divided into as many compartments as there are ciliary processes. It resembles, therefore, a collection of short canals directed from before backward, rather than a single circular canal; these short canals communicate behind with the vitreous body, and open in front by certain slits or perforations existing in the zone of Zinn, which enable the aqueous humour secreted by the vitreous body to escape in front of the crystalline lens.

Haller has stated all the opinions which have been entertained regarding the production of the aqueous humour, which has been said to be secreted by the vitreous body, as believed by MM. Ribes and Dugès, by the ciliary processes, by the choroid, by the iris, and, lastly, by certain special ducts proceeding from without the eye, and perforating the sclerotic at its junction with the cornea.

The Vessels and Nerves of the Eye.

The *arteries* of the eye are the following: a considerable number of *short posterior ciliary arteries*, which surround the optic nerve, perforate the sclerotic near it, and ramify in the choroid, in the ciliary processes, and in the iris; the *anterior short ciliary*, which perforate the anterior part of the sclerotic, and are distributed to the iris; the *long ciliary arteries*, two in number, which run between the sclerotic and the choroid, as far as the outer border of the iris, and then, bifurcating and curving inward, anastomose with each other around that border. From the vascular circle thus formed most of the vessels of the iris are given off. The *central artery of the retina* (*arteria centralis retinæ*) enters the globe of the eye through the centre of the optic nerve (at the porus opticus, *b*, *fig.* 246), and, sending off a branch to the crystalline lens, which traverses the vitreous body from behind forward, covers the internal surface of the retina with its other ramifications.

The *veins* correspond to the arteries, but are much more numerous. The posterior, or short ciliary veins, form vortices or whorls in the choroid, and are hence called *vasa vorticosa* (*v*, *fig.* 244). All the veins of the globe of the eye open into the ophthalmic and angular veins.

The *nerves* of the eye consist of a special nerve called the *optic nerve*, the origin, course, and structure of which will be described hereafter (see Cranial Nerves); and, secondly, of the *ciliary nerves*, which are derived from the fifth nerve, either directly from its nasal branch, or indirectly from the ophthalmic ganglion. These nerves (*a a*, *fig.* 242) are distributed to the ciliary ligament, and to the iris.

The Organ of Hearing

Hearing is that sense by which we perceive the vibrations of the air, which produce *sound*.

The organ of hearing is not situated in the face, like those of the other senses, but is contained in the substance of the base of the cranium, in the petrous portion of the temporal bone, its deep situation preserving it from external violence: it is composed essentially of a membranous and nervous apparatus contained in an extremely complicated osseous cavity, named the *labyrinth* or *internal ear*.

The labyrinth (*f*, *fig.* 251) communicates with the exterior by means of an acoustic trumpet formed by the *auricle*, or *pinna* (*a*), and external *auditory meatus* (*b*), and named the *external ear*, which may be regarded as an apparatus for collecting sonorous undulations.

Fig. 251.

The term *middle ear*, or *tympanum*, is applied to a cavity (*d*) which is placed between the labyrinth and the external ear, and may be considered as an apparatus for modifying sounds, the intensity of which is increased or diminished by it, according as they happen to be weak or loud.* It follows, therefore, that the ear is formed by a succession of cavities, which, proceeding from without inward, are, the external ear, consisting of the auricle and external auditory meatus, of the middle ear, or tympanum, and of the internal ear, or labyrinth. I shall describe the ear in this order, and shall thus proceed from the less to the more complicated parts of this organ.

The External Ear.

The *external ear* resembles a funnel or ear-trumpet, the expanded part of which represents the *auricle*, while the contracted portion corresponds to the external auditory meatus.†

* M. Richerand (*Elemens de Physiologie*, first edit.) has drawn an excellent comparison between the uses of the tympanum in hearing, and those of the iris in vision.

† The external ear, properly speaking, only exists in mammalia; and even among mammalia, those which do not live constantly in the air are not provided with it.

The Auricle.

The *auricle* of the ear (*auricula*, *pinna*), commonly called *the ear*, is placed at the side of the head, behind the articulation of the lower jaw, and in front of the mastoid process; it is an oval elastic lamina, folded in various ways upon itself, and having an undulated surface.

The auricle or pinna is free above, behind, and below, but is so firmly attached in front and on the inner side, that the two ears can support the weight of the entire body.

The individual varieties in the shape, direction, prominence, and size of the auricle are generally known. Of these varieties, some are congenital, and others acquired. Among the latter should be noticed the effects produced by the habit of confining the entire ear more or less closely by the head-dress. The direction or prominence of the auricle is not without some influence upon hearing, the perfection of which sense, according to Mr. Buchanan, depends on the kind of angle formed by the auricle with the side of the face, and which should be from 25° to 30°.

The *internal* or *mastoid surface* of the auricle presents certain eminences and depressions, which correspond inversely with those on its external surface.

The *external surface* is remarkable for the alternate ridges and depressions observed upon it: at its centre, but somewhat nearer to the lower than the upper part, we find the *concha* (*a*, *fig.* 252), a funnel-shaped excavation, the form and expansion of which are familiar to all, and at the fore part of the bottom of which is found the orifice of the external auditory meatus.

Fig. 252.

The concha is bounded in front by the *tragus* (*b*), a triangular process, the adherent base of which is turned forward and inward, while its free apex is directed backward and outward: it advances like a lid over the orifice of the external auditory meatus, which is completely closed by its depression. The posterior surface of the tragus, which forms part of the concha, is covered with stiff hairs, especially in old subjects; whence its name of *tragus*, from τράγος, a goat. The use of these hairs is to arrest any small particles that are floating in the air.

Behind and below, that is, opposite the tragus, the concha is bounded by the *anti-tragus* (*c*), a triangular tongue, which is smaller than the tragus, and is separated from it by a wide, deep, and rounded notch, named the *notch of the concha* (*incisura tragica*).

Behind and above, the concha is bounded by the *anti-helix* (*e*), a curved fold, which commences above the anti-tragus, being separated from that part by a slight depression, passes upward and forward, bifurcates, and then ends in the groove of the helix. The superior branch of the bifurcation of the anti-helix is broad and smooth, while the inferior is sharp; between them is situated a slight depression, called the *scaphoid*, or *navicular fossa*, but which would be more correctly named the *fossa of the anti-helix* (*f*).

The term *helix* (ἕλιξ, a roll, from ἑλίσσω, to roll around) is applied to a curved fold (*g g*), which forms the external border of the auricle: it commences in the cavity of the concha, which it divides into two unequal parts, one superior and narrow, the other inferior and broader; gradually increasing in size, it then passes upward and forward above the external meatus, then above the tragus, from which it is separated by a very distinct furrow: it next runs directly upward, curves backward, descends to form the posterior margin of the auricle, and terminates by becoming continuous with the anti-helix in front, and with the *lobule* (*l*) behind.

The groove or *furrow of the helix* is the groove (*i*) which surrounds the helix, and separates it from the anti-helix.

The *lobule* occupies the lower or small extremity of the auricle, from the rest of which it is distinguished by its softness; it is surmounted by the tragus in front, by the anti-tragus behind, and by the notch of the concha in the middle. The lobule of the ear varies exceedingly in size in different individuals, and is the part to which ear-rings are generally appended.

The Structure of the Auricle.—The *cartilage* of the ear (*figs.* 253, 253*) constitutes the framework of the auricle, in a great measure determines its shape, and is the cause of its pliability and elasticity.

Fig. 253.

Fig. 253.*

When the skin is removed from it, this cartilage, therefore, presents certain eminences and depressions, corresponding, with some exceptions, to those already described as existing upon the surface of the auricle. The cartilage of the ear has no part corresponding with the lobule: again, the cartilaginous fold which constitutes the helix terminates at the middle of the concha, from whence it is continued by a fold of skin, which, moreover, covers it throughout, and increases its prominence. Upon the cartilage of the auricle we also observe the following parts: 1. A mammillated eminence (*a*, *fig.* 253),

called the *process of the helix:* it is of considerable size, is very dense, and arises from the anterior margin of the helix, above the tragus. This process gives attachment to a ligament.

2. A tail-shaped tongue of cartilage (*b*), separated from that of the anti-tragus and concha by a very long fissure, which is occupied by ligamentous fibres. This tongue is formed by the united ends of the helix and anti-helix, and is very thick and dense; it may be called the *caudal extremity of the helix and anti-helix;* it supports the base of the lobule.

3. A well-marked thickening, situated opposite the concha, and characterized by a dead white colour. This thickening occupies a vertically elongated portion of the mastoid surface of the concha, and terminates at the lower part of the auricular cartilage: it seems to be intended to preserve the form of the concha, which cannot be flattened unless this thickened portion of the cartilage is first divided. Several fissures or notches are also found in the cartilage of the ear, which is thus imperfectly divided into several pieces that are movable upon each other, and united together by ligaments. The principal fissure, independently of that already described as existing between the anti-tragus and the caudal extremity of the helix and anti-helix, are, a small vertical fissure upon the anterior margin of the helix; another vertical fissure upon the tragus; several irregular notches in the helix; and, lastly, a much more important fissure, to which I shall have to allude in describing the external auditory meatus. It is situated between the helix and the tragus, and is prolonged upon the outer half of the orifice of that meatus.

The *skin* of the auricle is remarkable for its thinness and transparency: hence the sub-cutaneous vascular network can be seen through it without dissection; it is no less remarkable for its tension, and its close adhesion to the cartilage, upon which it is moulded, so as accurately to reveal its form. The portion of skin which covers the concha is especially remarkable for its great tenuity and intimate adhesion to the cartilage.

The skin upon the free border of the auricle adheres but slightly to, and projects beyond the helix; the same fold of skin, when doubled upon itself and prolonged below the helix, constitutes the lobule, which, together with the adjacent part of the free border of the auricle, is nothing more than a duplicature of the skin, containing some soft fat. A small quantity of fat is formed around the entire circumference of the auricle, but none exists in other situations.

The skin of the ear is provided with sebaceous follicles, which can be easily shown by maceration, after the method employed by Sœmmering, and which are most numerous in the concha and the scaphoid fossa.

The *ligaments* of the auricle are divided into the intrinsic and the extrinsic ligaments.

The *extrinsic ligaments* are, the *posterior ligament*, which is a thick, tendinous layer, extending from the concha to the mastoid process; the *anterior ligament*, which is a triangular, very broad, and very strong ligament, arising from the process of the helix and the adjacent part of the border of the helix, and terminating at the zygomatic arch, where it is blended with the superficial temporal fascia; and, lastly, the *ligament of the tragus*, which is very strong, and extends from the tragus to the adjacent part of the zygomatic arch.

The *intrinsic ligaments*, the object of which is to keep the cartilage of the auricle folded upon itself, are, the ligament which keeps the caudal extremity of the helix applied to the concha; the very strong ligament which extends from the tragus to the helix, and unites the outer half of the auditory meatus to the cartilage of the auricle; some very strong bundles, which are situated upon the mastoid surface of the auricle, and are intended to preserve its convolutions, for when they are divided the auricle may be unfolded; lastly, those most remarkable ligamentous bundles, which occupy the fold presented by the inferior branch of the bifurcation of the anti-helix.

The three *extrinsic muscles* of the ear, which exist in a rudimentary condition in the human subject, but are so highly developed in timid animals, are intended to move the auricle as a whole (see MYOLOGY).

The *intrinsic muscles* move the different parts of the auricular cartilage upon each other. Like the extrinsic, they are quite rudimentary. There is no difference in their size in savage and civilized races. They are five in number, four of them being situated on the concave, and one only on the convex, or mastoid surface of the auricle.

The *great muscle of the helix* (helicis major, *c*, *fig.* 253) is situated vertically upon the anterior part of the helix, near the tragus; it is a narrow, oblong tongue, fleshy in the middle, and tendinous at its extremities; its fibres are vertical.

The *small muscle of the helix* (helicis minor, *d*), the smallest of the intrinsic muscles of the ear, lies upon that portion of the helix which divides the concha into two parts.

The *muscle of the tragus* (tragicus, *e*) is a broad band, lying upon the external surface of the tragus; its fibres are directed vertically.

The *muscle of the anti-tragus* (anti-tragicus, *f*) is a tongue-like bundle, which covers the external surface of the anti-tragus, and is inserted by a tendon to the upper part of the caudal extremity of the helix. Its use may be to move this caudal extremity upon the anti-tragus.

The fifth is the *transverse muscle* (transversus auriculæ, *a*, *fig.* 253*), which is situated

on the mastoid surface of the auricle. According to Sœmmering, it consists of a transverse layer of fibres of unequal length, which spread out in a semicircular form from the convexity of the concha to the ridge, corresponding to the groove of the helix. I doubt the muscularity of these fibres, which I am inclined to regard as constituting an intrinsic ligament intended to preserve the fold of that portion of the anti-helix by which the concha is bounded behind and above.

The *arteries* of the auricle are the posterior auricular, a remarkable branch of which passes through the cartilage, between the caudal extremity of the helix and the concha, so as to ramify in the cavity of the concha. All the branches of the posterior auricular arteries turn over the free border of the helix, so as to reach the concave surface of the auricle. The anterior auricular arteries arise from the external carotid and the temporal, and divide into inferior branches or arteries of the lobule and ascending branches. The *veins* have the same names and follow the same course as the arteries.

The *nerves of the auricle* are derived from the auricular branch of the cervical plexus; three or four of them ramify upon the internal surface of the auricle. A remarkable branch perforates the cartilage between the anti-tragus and the caudal extremity of the helix, and is distributed to the skin which lines the concha.*

The External Auditory Meatus.

The *external auditory meatus* (*b, fig.* 251) is a partly cartilaginous and partly osseous canal, extending from the concha (*a*) to the membrane of the tympanum (*c*). It forms the narrow portion of the ear-trumpet represented by the external ear.

It is about an inch in *length*. Its section represents an ellipse, of which the longest diameter is vertical. Its direction is transverse, and it describes a very slight curve, having its convexity turned upward. Moreover, near its external orifice it is bent at an angle which projects upward, and hence it is necessary to draw the auricle upward and backward, if we wish to examine the bottom of the external auditory meatus.

The external meatus is in relation with the temporo-maxillary articulation in front, with the mastoid process behind, and with the parotid gland below.

Its *external orifice*, which is vertically oblong, more or less widened out in different individuals, and covered with hairs in old age, occupies the anterior and inferior part of the concha behind the tragus, which serves as a lid for it. It is bounded behind by a sort of *semilunar ridge*, which projects more or less forward in different individuals, so as to contract its orifice to a greater or less extent. In front of the auditory meatus there is an excavation or fossa concealed by the tragus, and named the *tragic fossa of the concha*; it forms, as it were, the vestibule of the meatus.

The *internal orifice* of the auditory meatus is circular: it is directed very obliquely downward and inward, and is closed by the membrana tympani.

Structure.—The auditory meatus consists of an osseous portion, and of a *cartilaginous and fibrous part.*

The *osseous portion* has been already described with the temporal bone, as the *external auditory meatus.* It is wanting in the fœtus, and in the new-born infant, in which its place is supplied by the *tympanic ring* or *circle.* We have stated that, in the adult, this ring forms an osseous lamina distinct from the rest of the temporal bone, that it rests behind upon the mastoid and styloid processes, for the latter of which it forms the vaginal process, and that it is separated in front from the auricular portion of the glenoid cavity by the fissure of Glasserius; this lamina forms both the anterior and inferior walls of the auditory meatus and cavity of the tympanum.

The *cartilaginous and fibrous portion* forms the outer half of the external auditory meatus, and may be separated from the cartilage of the auricle by a careful dissection. If an incision be made over the similunar ridge which constitutes the outer border of the orifice of the auditory meatus, it will be seen that this ridge is formed by the juxtaposition of two cartilaginous borders, one of which belongs to the concha, and the other to the auricle, and which are united by fibrous tissue. If the dissection be continued between the tragus and the corresponding part of the helix, the auricle may be separated from the auditory meatus, exceping below, where their continuity is established by means of a tongue or isthmus of cartilage.

The tragus belongs essentially to the auditory meatus, the cartilage of that canal being merely a prolongation of the tragus folded upon itself (see *b, fig.* 253*), so as to form the lower two thirds or three fourths of a cylinder. The inner end of this imperfect cylinder is attached to the rough external rim of the osseous portion of the meatus by means of a fibrous tissue, which extends farther above and behind than below and in front, and which gives the cartilage a great degree of mobility; there is a thick prolongation or process at the lower and anterior part of the inner end of the cartilage of the meatus.

The *fibrous portion* of the auditory meatus forms the upper third or fourth of that canal, and also fills up the large notch in the inner end of the cartilaginous portion.

* [The auricle also receives twigs from the *posterior auricular* branch of the facial nerve, from the auriculo-temporal branch of the inferior maxillary division of the fifth nerve, and from a small branch of the pneumogastric nerve. See description of those nerves.]

Near the tragus there are two or three fissures or divisions in this cartilage, named the *fissures of Santorini*, which give it some resemblance to the rings of the trachea: these fissures are at right angles to the length of the canal, and are filled up with a fibrous tissue, which some anatomists have conceived to be mixed with muscular fibres, or to consist entirely of muscular fibres intended to move the small and partially separated portions of the cartilage. It is evident that the mode in which the partly cartilaginous and partly fibrous portion is united with the osseous portion of the canal, and also the existence of the fissures just described, have reference to the mobility of the entire canal.

The internal surface of the auditory meatus is lined by a prolongation of the *skin*, which is remarkable for its extreme thinness. It becomes thinner and thinner in advancing from the orifice to the bottom of the meatus; and the fineness and extreme delicacy of that portion of the skin which corresponds to the osseous part of the meatus deserves special attention. The skin of the meatus is also characterized by being covered in all parts with fine downy hairs; a fact which proves that it is of a cutaneous structure, and not a mucous membrane. In old subjects, there are some tolerably long hairs at the commencement of the auditory meatus, as well as upon the internal surface of the tragus; they prevent the entrance of dust and insects, which, moreover, get involved in the ceruminous secretion.

The skin of the meatus is farther characterized by the presence of a number of sebaceous follicles, or glands, called the *ceruminous glands*,* the orifices of which are visible to the naked eye, and give the skin an areolar appearance. These small glands occupy the entire inner surface of the cartilaginous and fibrous portions of the auditory meatus: from their yellowish-brown colour, they can be readily seen in oblique sections of the skin. They secrete a rather thick unctuous substance, resembling wax, whence it is called *cerumen* (*cera*, wax). It is very bitter, and is partially soluble in water, with which it forms an emulsion which leaves a greasy stain upon paper; it sometimes becomes exceedingly hard from remaining long in the passage, and then acts as a mechanical cause of deafness. By analysis, this substance, according to Berzelius, yields a fatty oil, an albuminous substance, and a colouring matter, and, according to Rudolphi, a bitter principle like that of the bile. Nature intended, says Sœmmering, that there should be a sufficient quantity of cerumen, not only to keep out insects, but also to diminish the intensity of sonorous vibrations. It is, therefore, a bad habit to remove it artificially, unless there be an abnormal accumulation of this substance.

The Middle Ear, or Tympanum.

Dissection.—The cavity of the tympanum may be laid open, either from its external wall, by removing the membrana tympani, or from its upper wall, by cutting away the anterior part of the base of the petrous portion of the temporal bone with a strong scalpel; the situation in which this may be done is indicated by a fissure, or, rather, a suture, which exists between the petrous and squamous portions; lastly, the tympanum may be opened from its lower wall, by breaking down the osseous plate of the auditory meatus.

In order to show all the parts contained in the cavity of the tympanum, several specimens should be prepared in different ways. It is of importance, moreover, to study the ear in the temporal bones of the adult subject and the fœtus, as well in macerated specimens as in such as have been dried without previous maceration.

The *tympanum*, *tympanic cavity*, or *drum* of the ear (*tympanum*, a drum, *d*, *fig.* 251), is a cavity situated between the external auditory meatus (*b*) and the labyrinth or internal ear (*f*); it communicates with the pharynx, and, consequently, with the air-passages, by means of the Eustachian tube (*e*, *fig.* 255); it is prolonged into the mastoid process, by means of the mastoid cells (*c*), and it is traversed by a chain of small bones (1, 2, 3), named the *ossicula auditûs*.

The tympanum is placed in the anterior part of the base of the petrous portion of the temporal bone, above the osseous lamina of the external meatus, and in front of the mastoid process; it is directly continuous with the osseous portion of the Eustachian tube, of which it seems only to be a dilatation.

From its *form*, which is otherwise irregular, or, rather, from the two dry membranes formed upon its opposite walls, it has been compared to a military drum; it is flattened from without inward, so that its transverse diameter is the *shortest*. It presents for our consideration an *internal* and an *external wall*, and a circumference.

The External Wall of the Tympanum.—This wall is formed by the *membrana tympani*, and by that portion of the temporal bone in which the membrane is fitted. This portion of the temporal bone is a compact lamina, which is flat in the human subject, but extremely prominent in some animals.

The *membrana tympani* (*c*, *fig.* 251) is a nearly circular, semi-transparent membranous septum, dry-looking like parchment, and vibratile; it is situated between the external

* [The ceruminous glands consist of a long convoluted tube, closed at one end, and opening by the other upon the internal surface of the meatus.]

auditory meatus, at the bottom of which it may be seen in the living subject, and the cavity of the tympanum. It is *directed* very obliquely downward and inward; so that, instead of passing perpendicularly across the auditory meatus, it is continuous, at a very slight angle, with the upper wall of that canal. In consequence of this obliquity, the membrana tympani unites with the lower wall of the meatus at an angle of about 45°, and the meatus itself terminates in such a manner that its lower wall is much longer than the upper.

The *external surface* of the membrana tympani is free, and is directed downward and outward; the *internal surface* is turned upward and inward, and adheres very firmly to the handle of the bone of the ear, called the malleus, by which it is drawn inward, so that its centre presents a funnel-shaped depression, which is concave externally and convex within. The circumference of the membrane is fitted, like a watch-glass, into a circular furrow formed at the inner end of the external meatus in the adult, and into the tympanic ring in the fœtus. Above and behind, near its insertion into its bony frame, the membrana tympani is elevated by a small process (the short process) of the malleus.

Immediately on the inner side of the insertion of the membrana tympani, opposite the posterior extremity of a line drawn across its middle, is situated a small foramen, the orifice of a canal which transmits the *chorda tympani nerve*.

Is the membrana tympani perforated? Some anatomists have asserted that there is an aperture between the membrane and the bone, at one point of its circumference; and others have believed that an oblique slit traverses the membrane. But these perforations do not exist in the natural state; so that the membrana tympani forms a complete septum between the tympanum and the external auditory meatus.

Notwithstanding its tenuity and transparency, the membrana tympani consists of three very distinct layers. The *external* or *epidermic layer* is a prolongation of the epidermic portion only of the skin which lines the external meatus.

The *internal* or *mucous layer* is a prolongation of the extremely thin mucous membrane which lines the tympanum. The handle of the malleus is situated between this and the middle layer.

The *middle* or *proper layer*, on which the strength of the membrane depends, appears to be of a fibrous nature. According to Sir Everard Home, it is muscular; he states that he distinctly saw muscular fibres radiating from the centre to the circumference, first in the elephant, and afterward in the ox, and in the human subject.*

By fine injections some very delicate vessels are demonstrated in the membrane. The network represented by Sœmmering, who only injected the arteries, is not nearly so dense as that which may be displayed by filling the veins. If a blue injection be thrown into the jugular vein of the fœtus, the whole membrane will become of that colour, and will present an exceedingly fine vascular network under a lens. In a new-born infant, which had died with inflammation of the tympanum, the membrane was found quite red. The bloodvessels appear to be situated entirely in the internal layer; they run from the circumference towards the centre of the membrane; and this arrangement has probably led to the supposition of the existence of radiated muscular fibres.

The *use* of the membrana tympani is to transmit the sonorous vibrations received through the external auditory meatus to the air contained within the tympanum, and to the ossicula of the ear. Its obliquity, besides increasing the dimensions of this vibratile membrane, has certainly some use in the reflection of sonorous vibrations. As it adheres to one of the chains of small bones of the ear, it is influenced by their movements; and in this way it may be either stretched or relaxed.

The Internal Wall of the Tympanum.—The *internal wall* of the tympanum (*figs.* 254, 255), which is perfectly exposed when that cavity is opened from its external wall, presents a great number of objects for our consideration. At its upper part is situated the *fenestra ovalis* (*f*, *fig.* 254), the long diameter of which is directed transversely, but rather obliquely downward and forward; the upper border of this fenestra (*f*, *fig.* 258) is semi-elliptical, while the lower border is straight, or, rather, it projects somewhat into the opening. The fenestra ovalis, called also the *vestibular orifice of the tympanum*, would establish a free communication between the tympanum and the vestibule if it were not closed by the base of the stapes (3, *fig.* 255; *n*, *fig.* 257), which is accurately fitted to it.

The fenestra ovalis is placed at the bottom of a depression, which is named the fossette of the fenestra, and the depth of which depends upon the de-

Fig. 254.

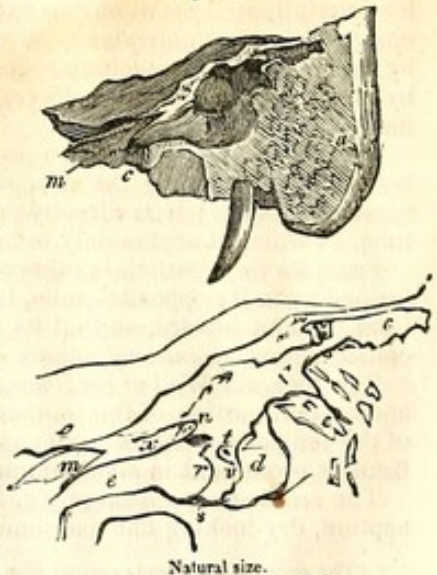

Natural size.
(Section of the tympanum.)

* Philosophical Transactions, p. 23, 1823. To his paper are annexed three plates, representing the membrana tympani in the elephant, the ox, and man.

gree of projection of the aqueduct of Fallopius, which bounds it in front, by that of the promontory, which is below, and by an osseous tongue which passes up to the pyramid behind.

Below the fenestra ovalis is the *promontory* (*r*, *figs.* 254, 255), an eminence which corresponds to the first turn of the cochlea, and has three grooves upon its surface, that diverge above and converge below, where they terminate in a common canal, which opens upon the lower surface of the petrous portion of the temporal bone, between the carotid canal and the groove for the internal jugular vein. This canal (canalis tympanicus, *Arnold*) may be called the *canal of Jacobson*, because it contains Jacobson's nerve, a branch given off from the glosso-pharyngeal, which establishes a very remarkable anastomosis between the glosso-pharyngeal and the nervi molles derived from the vidian and great sympathetic nerves.* The furrows upon the promontory are intended to lodge this anastomosis. They are often formed into complete canals.

Behind the fenestra ovalis, and opposite its transverse diameter, is a small projection of variable size, called the *pyramid* (*t*, *figs.* 254, 255). There is an opening upon it which is distinctly visible to the naked eye, and makes the pyramid appear tubular. From this opening emerges a small cord (*o*, *fig.* 255), the nature of which is not known, but which is called the *stapedius muscle*. A bristle passed into this opening enters the *canal of the pyramid*, which canal is generally described as ending in a cul-de-sac, but this is not the case. M. Huguier, prosector of the faculty, has clearly demonstrated, in a series of preparations, that the canal of the pyramid is a long passage, which passes backward and downward below the aqueduct of Fallopius, becomes vertical like the aqueduct, is separated from it only by a thin lamina of bone, communicates with it by a small opening, and at length abandons it below, to open upon the inferior surface of the petrous bone, on the inner side of the stylo-mastoid foramen, at a variable distance from it. Sometimes this canal bifurcates below; so that two bristles introduced into the small openings near the stylo-mastoid foramen will both enter the canal of the pyramid. A small, very short, and horizontal passage, which terminates in the diploë of the temporal bone, may be regarded as a diverticulum of this canal.

I have already stated that a fibrous-looking cord, named the stapedius muscle, emerges from the canal of the pyramid. It is not yet known what structures are transmitted through the divisions of this canal.

Below the fenestra ovalis, and behind the promontory, is situated the *fenestra rotunda* (*s*, *figs.* 254, 255); it is placed at the bottom of a funnel-shaped depression, which was well described by M. Ribes as the *fossa of the fenestra rotunda*, at the bottom of which is found a partly membranous and partly osseous lamina, which is the commencement of the spiral septum of the cochlea. In a dry bone, which has been previously macerated, the membranous part being destroyed, the fossa of the fenestra rotunda communicates with the vestibule. Below this compound lamina, *i. e.*, at the lower part of the fossa just described, is found the fenestra rotunda (*s*, *fig.* 257) properly so called, which leads into the tympanic scala of the cochlea (*l*); whence the term *cochlear orifice of the tympanum* is applied to the fenestra rotunda, in contradistinction to the term *vestibular orifice*, which is given to the fenestra ovalis.

The fenestra rotunda is closed, in the fresh state, by a membrane called the *secondary membrana tympani*, which is said to be composed of three layers—a middle layer, an external or tympanic, and an internal or cochlear layer. The two last named are mucous membranes.†

Under the pyramid, and behind the fenestra rotunda, is seen a deep fossa, *the sub-pyramidal fossa* (*v*, *fig.* 254), remarkable for its constancy, and pierced by several foramina at the bottom.

Upon the internal wall of the tympanum, in front of the fenestra ovalis, somewhat above the transverse diameter of that opening, and under the prominence of the aqueduct of Fallopius, is the internal *orifice* (*n*, *figs.* 254, 255) *of the canal* (*m*) *for the internal muscle of the malleus*, or tensor tympani muscle. This orifice is wide and cup-shaped, and is supported by a hollow eminence (*x*, *fig.* 254), which is itself sustained by several ridges; so that there is the greatest analogy between it and the hollow projection constituting the pyramid. Both of them transmit a tendon. One is situated in front, and the other behind the fenestra ovalis. M. Huguier, who has paid much attention to this subject, has shown that the *cochleari-*

Fig. 255.

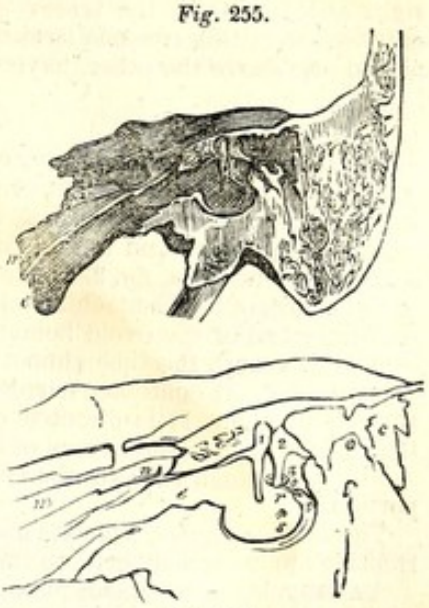

Natural size.
(Section of the tympanum.)

* This can be clearly seen in some preparations in the museum of the Faculty at Paris.

† [The internal or cochlear layer is merely a part of the common lining membrane of the labyrinth, and is, most probably, a *fibro-serous* membrane, see p. 681.]

form process of anatomists (*n*, *fig.* 255) is nothing more than the remnant of the hollow projection (*x*, *fig.* 254) just described, one half of which is very thin and fragile, and is sometimes destroyed by long-continued maceration. The so-called cochleariform process, therefore, is merely the reflected canal for the internal muscle of the malleus.

The Circumference of the Tympanum.—We shall examine this circumference above, below, in front, and behind.

Above, the tympanum corresponds to the projection formed on the anterior part of the base of the petrous portion of the temporal bone. In it there is formed a recess, which may be named the *recess of the tympanum*, and which is intended for the reception of the head of the malleus (1, *fig.* 255), and the body and posterior ramus of the incus (2). It is thin and spongy, and is separated from the squamous portion of the temporal bone by a suture, which persists even to the most advanced age. This suture is traversed by a great number of canals, through which communicating vessels pass from those of the dura mater to those of the tympanum.

Below, the tympanum is very narrow, and has the form of a trench, in which there is nothing particular to notice. The wall of the tympanum is here formed by the osseous lamina of the external meatus.

At the *upper* and *back* part of the circumference of the tympanum is situated a large opening which leads into the *mastoid cells* (*c c*, *figs.* 254, 255).

These cells are extremely numerous, and of very unequal size ; they occupy the whole of the mastoid portion, and the adjacent parts of the petrous portion of the temporal bone, and are prolonged even above the external meatus. We may therefore regard the mastoid portion of the temporal bone as an appendage to the tympanum. The mastoid cells have a very regular arrangement in the ox and horse, in which animals they are disposed in a series radiating from the surface of the mastoid process towards the tympanum ; their arrangement is much more irregular in the human subject. Two large cells are almost always found, one near the apex, and the other at the posterior border of the mastoid process. In one case I found the whole mastoid process forming a single large cell, having extremely thin parietes.

The mastoid cells are lined with a very delicate fibro-mucous membrane, which is continuous with the mucous membrane of the tympanum. They contain air, and it is only in some cases of disease that any quantity of mucus is found in them.

The mastoid cells represent, in the auditory apparatus, the cells and sinuses which are connected with the organ of smell. It may be easily conceived that the intensity of sounds may be increased by being reverberated from so considerable a surface.

In the fœtus there are no mastoid cells ; but there exists instead, in the base of the petrous portion of the temporal bone, a cavity prolonged from the recess already described in the upper wall of the tympanum, for the ossicula of the ear.

In front, the tympanum is contracted like a funnel, to become continuous with the *Eustachian tube* (*e*, *fig.* 255) ; it might even be said that the tympanum and the Eustachian tube form together a single funnel-shaped cavity, the expanded portion of which is constituted by the tympanum, and the contracted portion by the tube of Eustachius.

The canal for the internal muscle of the malleus is formed in the upper wall of the Eustachian tube ; it is a narrow tubular canal (*m*), which, having reached the anterior part of the tympanum, becomes applied to the internal wall of that cavity ; it passes horizontally backward, forming a projection upon this wall, and is then reflected outward, at a right angle, to form the hollow eminence already described. This canal is separated only by a very thin osseous lamina from the Eustachian tube ; so that the two passages, placed one above the other, have some resemblance to a double-barrelled gun.

The Eustachian Tube.

The *Eustachian tube* (more correctly called the Eustachian *trumpet*, from *tuba*, a trumpet, *e*, *fig.* 255), or the guttural meatus of the ear, is a straight, funnel-shaped canal, flattened upon its outer side, and about two inches in length ; it extends from the tympanum to the upper and lateral part of the pharynx, where it terminates by a free, expanded extremity (*m*, *fig.* 234), directed inward and downward, named the *guttural orifice*, or the mouth of the Eustachian tube. This orifice is wide and dilatable, of an oval shape, the larger end of the ovoid being turned upward, and being exceedingly dilatable ; but beyond its mouth the tube almost immediately contracts, and will scarcely admit an ordinary probe. It continues narrow as far as its tympanic orifice, where it again becomes sensibly dilated. It is directed obliquely inward, forward, and downward ; hence the facility with which the mucus of the tympanum flows into the back of the throat.

The Eustachian tube consists of an osseous portion and of a cartilaginous and fibrous portion.

The *osseous portion*, which is about seven or eight lines in length, is situated at the retreating angle formed between the squamous and petrous portions of the temporal bone

A triangular *cartilaginous* plate, formed into a groove, constitutes the inner half of the tube ; a *fibrous* layer, which is at first applied against the *circumflexus palati* muscle, and is then lodged in the groove between the petrous portion of the temporal bone and the

posterior border of the sphenoid, forms the external wall of the canal, which is habitually collapsed. The base of the triangular cartilage, which forms the guttural orifice of the tube, is notched in the middle, and terminates in two thickened elongated angles; of these, the posterior one, which is more distinct, is movable, and may be pushed upward and backward. The anterior angle is firmly fixed to the posterior margin of the pterygoid process. As catheterism and injection of the Eustachian tube have become common operations in treating diseases of the ear, it is of importance to define the exact position of its guttural orifice; it is situated (*m*, *fig.* 234) upon the side of the pharynx, immediately behind, and a little above the inferior turbinated bone.

The *mucous membrane* which lines the Eustachian tube is thin, but at the mouth of the tube it assumes the characters of the mucous membrane of the pharynx and of the pituitary membrane, with both of which it is continuous; it is also continuous with the mucous membrane of the tympanum; hence the close sympathy which exists between the lining membrane of these several parts.*

The use of the Eustachian tube is to renew the air contained within the tympanum; but it also gives exit to the mucous secretion of that cavity.†

Besides the orifice of the Eustachian tube, and that of the canal for the internal muscle of the malleus, the anterior funnel-shaped part of the circumference of the tympanum presents two orifices placed one above the other: the uppermost of these is the internal orifice of the canal for the chorda tympani nerve; the lower one is an oblique fissure, which transmits a fibrous cord called the *anterior muscle of the malleus*. M. Huguier has shown me a number of preparations in which the chorda tympani nerve does not escape through the fissure of Glasserius, but runs in a very narrow special canal, about five or six lines in length, which is situated on the inner side of the Glasserian fissure, and opens at the base of the scull in the retreating angle formed between the squamous and petrous portions of the temporal bone, upon the outer side of the Eustachian tube, behind the spinous process of the sphenoid, and sometimes upon that bone itself.

The fissure of Glasserius, then, merely transmits a fibrous bundle, named the anterior muscle of the malleus, and some small arteries and veins.

We may now describe the course of the chorda tympani nerve.

In its course this nerve passes through *two canals*, entering the tympanum by one, and escaping from it by the other. The canal by which it enters commences at the vertical portion of the aqueduct of Fallopius, in which the facial nerve is situated, passes upward and forward, and opens immediately on the inner side of the posterior margin of the membrana tympani, on a level with the horizontal diameter of that membrane, and almost in the groove into which it is inserted. Having entered the tympanum through this canal, the chorda tympani describes a curve, having its concavity directed downward, passes between the handle of the malleus and the long ramus of the incus, enters its proper canal upon the inner side of the fissure of Glasserius, and emerges at the point already mentioned.

The Ossicula of the Ear.

The tympanum is traversed from without inward by an osseous chain, which describes several angles, and consists of four bones articulated with each other, and extended from the membrana tympani to the fenestra ovalis. These little bones, forming the links of the chain, are named, from their respective shapes, the *malleus*, or hammer (1, *fig.* 256); the *incus*, or anvil (2); the *os orbiculare*, or round bone (4); and the *stapes*, or stirrup bone (3): the os orbiculare, however, appears to be merely a tubercle belonging to the incus.

Fig. 256.

The Malleus.—The malleus (1, *fig.* 256) is the most anterior of the bones of the ear; it is divided into a *head*, a *neck*, and a *handle*, and it has also two *processes*.

The *head* of the malleus (*a*, *fig.* 257) is situated in the recess of the tympanum, in front of the incus, and above the membrana tympani. It is ovoid, and smooth, excepting behind and below, where it is concave, in order to be articulated with the incus. Sœmmering has figured a small fibrous cord, which he calls the *proper ligament of the malleus*, extending from the head of this bone to the upper part of the recess of the tympanum.

Fig. 257.

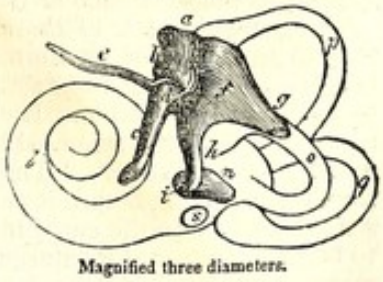

Magnified three diameters.

The head is supported by a constricted *neck* (*b*), which is slightly twisted and flattened, and serves also as a support for the two processes.

The *handle* (manubrium, *c*) is directed vertically, and,

* [According to Dr. Henlé, the mucous membrane of the Eustachian tube, like that of the upper part of the pharynx, is covered with a columnar ciliated epithelium; but in the tympanum and mastoid cells the epithelium is squamous, and not ciliated.]

† [The Eustachian tube, by establishing a communication between the tympanum and the external air, ensures an equal atmospheric pressure on the two surfaces of the membrana tympani, so that the necessary condition of that membrane, and of the ossicula auditûs, as conductors of vibrations, is not interfered with.]

with the head and neck, forms a very obtuse angle, which retreats on the inner side; it is in contact with, and adheres firmly to the internal surface of the membrana tympani, opposite the centre of which its rounded extremity is placed; it therefore forms a radius to the circle represented by the membrana tympani. The lower part of the handle of the malleus is distinctly curved, having its concave side turned outward; this explains the funnel-shaped depression upon the external surface of the centre of the membrana tympani.

The *processes* of the malleus are two in number: the external, or *short* process (*d*), is directed slightly outward, and rests against the upper part of the margin of the membrana tympani, so as to make it project outward; the other, or *long* process, is very slender (*processus gracilis of Raw*, *e*), and is shaped like a thorn (*processus spinosus*): it arises from the *anterior* part of the neck, enters the Glasserian fissure, and affords attachment to a muscular or fibrous cord. I have several times found a simple ligamentous cord instead of this process.

The Incus.—This bone (2, *fig.* 256) has been well compared to a bicuspid tooth, the body of which would be represented by the *body* of the incus, and the *fangs* by its two *processes*.

The *body* (*f*, *fig.* 257) is contained in the recess of the tympanum, behind the malleus, with which it is articulated by a very concave surface, directed forward and somewhat upward; so that the articulation between the head of the malleus and the body of the incus is effected by mutual reception.

Of its two rami, the *superior* or *short* one (*g*) is thick, conoid, and directed horizontally backward: it is situated upon the same plane as the body, and, like it, is contained in the recess of the tympanum, in which it terminates; its extremity does not appear to me to be free.

The *inferior*, or *long* ramus (*h*), is longer and thinner than the superior one; it passes vertically downward, parallel to the handle of the malleus, on a plane internal and somewhat posterior to it. Its lower portion is bent into a hook, the concavity of which is turned inward; and at its point is formed a sort of *lenticular* and distinctly defined *tubercle* (4, *fig.* 256; *i*, *fig.* 257), which has been regarded as a separate bone, and named the *os orbiculare*, or *os lenticulare*; it appears to me to be merely a dependance of the incus, with which I have always found it united, even in the fœtus.

The Stapes.—The *stapes* (3, *fig.* 356), which is shaped like a stirrup, extends horizontally from the extremity of the long process of the incus to the *fenestra ovalis* (see *fig.* 257), and is situated upon a lower plane than the rest of the small bones of the ear. Its *head* presents a small articular cavity, for the reception of the orbicular tubercle of the incus. Its *base* (*n*) is directed inward, and consists of a thin plate exactly corresponding to the fenestra ovalis, which is rather accurately filled up by it, and to draw it away from which a slight force is necessary, so that it has a greater tendency to fall into the vestibule than into the cavity of the tympanum. The slight obliquity of the long diameter of the fenestra ovalis causes an inclination of the stapes in the same direction. Of its two crura, or *branches* (*fig.* 256), the anterior is the shorter and straighter. Upon those surfaces of the crura which are turned towards each other there is found a groove, which appears to indicate the existence of a membrane stretched between the crura. I have found the stapes very small, and, as it were, atrophied. In one case, the two crura of the stapes were united together.

Muscles belonging to the Ossicula of the Ear.

Most modern anatomists agree with Sœmmering in admitting four muscles for the ossicula of the ear, viz., three belonging to the malleus, and one to the stapes. The incus has no proper muscle, because it is merely an intermediate bone between the malleus and the stapes. It is certain, however, that only one of these muscles has been actually demonstrated, viz., the *internal muscle of the malleus*; but it is so easy to fall into error when examining such minute objects, that I feel bound to suspend my judgment as to the existence or non-existence of the other muscles.

The *internal muscle of the malleus*, or *tensor membranæ tympani* of Sœmmering (*e*, *fig.* 251), is an elongated, fusiform muscle, contained within the bony canal formed in the retreating angle of the temporal bone, above the Eustachian tube, with which it exactly corresponds in direction. It *arises* from the cartilaginous portion of the tube, from the adjacent part of the sphenoid bone, behind the spinous foramen, and from the bony canal which forms its sheath. The fleshy fibres converge around a tendon, which appears from among them, before it passes out from the bony canal. This tendon is reflected at a right angle, like the canal in which it is contained, and then passes directly outward, to be inserted into the anterior and superior part of the handle of the malleus, below the processus gracilis of Raw.

The muscularity of the band or cord named the *anterior muscle* or *ligament of the malleus*, or the great external muscle of Meckel, is doubted by a great number both of present and former anatomists.* I have never seen anything more than a fibrous cord, which

* "Fuêre autem et dudum et nuper clari viri qui de veris hujus musculi fibris carneis dubitarunt, cum

commenced at the tip of the processus gracilis of the malleus, traversed the glenoid fissure, was re-enforced by other fibres arising from that fissure, and became continuous with a fibrous layer arising from the spinous process of the sphenoid bone, and generally regarded as the internal lateral ligament of the temporo-maxillary articulation.

The same remarks will also apply to the *small external muscle of the malleus*, or small muscle of the malleus of Casserius. This muscle is figured by Sœmmering, who says that he found it exceedingly developed in one subject. All that I have clearly seen is a cylindrical cord, extending from the upper part of the frame of the membrana tympani to the short process of the malleus, or, rather, below it, according to the observations of Sœmmering (*ad manubrium mallei, infra brevem ejus processum*). This small muscle would relax the membrana tympani; hence it has been named by Sœmmering the *laxater membranæ tympani*.

The *muscle of the stapes*, or *stapedius* muscle (*o*, *fig.* 255), which is the smallest in the body, has, since the time of Varolius, by whom it was discovered, been regarded as a ligament by some anatomists; nevertheless, it is more generally admitted to be muscular than that last described. It arises from some part of the interior of the pyramid, and, escaping from that process, passes forward, and terminates at the back of the neck, or constricted part of the head of the stapes, behind its articulation with the incus. Sœmmering has not only represented its fleshy belly and its tendon, but also (see fig. 20, tab. 11) a filament of the facial nerve terminating in it. It is difficult to conceive that such a serious mistake should have been committed by this great anatomist. I have examined this cord under a lens, and have never been able to discover any muscular fibres in it. We do not conceive how a muscle should exist in so delicate a cord. Supposing, however, that it does exist, it must move the stapes in such a way that the posterior extremity of the base of that bone would be pushed into the fenestra ovalis, while the anterior extremity would be carried outward.

Movements of the Ossicula.—The chain of small bones in the ear is so arranged, that any movement of one of its extremities is communicated to the entire chain. Their motion is precisely similar to that of a bell-crank. M. Huguier is inclined to believe that the processus gracilis of Raw serves as a fulcrum, around which the malleus performs a rotatory movement, the effects of which are transmitted to the stapes through the incus. The contraction of the internal muscle of the malleus, or tensor membranæ tympani, must draw the handle of the malleus inward and its head outward; the incus, from its firm connexion with the head of the malleus, follows that bone, and as it swings upon its short horizontal process, its vertical process is carried inward, and therefore presses the stapes into the fenestra ovalis.

The Lining Membrane of the Tympanum.

The tympanum is lined by a very thin membrane, which not only covers the walls of this cavity, but also forms a very evident investment for the ossicula, and is, moreover, prolonged into the mastoid cells, lining them throughout, and forming small duplicatures around the vessels by which some of the cells are traversed. This membrane is continuous with the mucous membrane of the Eustachian tube, and therefore indirectly with that of the pharynx.*

It serves at once as an internal lining for the tympanum, and a periosteum for the osseous walls of that cavity, and should therefore be regarded as a fibro-mucous membrane. It secretes a mucus, which in the natural state simply moistens its surface, but in some cases of disease occupies the whole cavity. The catarrhal character of the products of suppuration in the tympanum, the continuity of this lining membrane with the mucous membrane of the pharynx, and its extreme vascularity, leave no doubt of its being a mucous membrane.

The Internal Ear, or Labyrinth.

The *internal ear*, or *labyrinth* (*f*, *fig.* 251), the deep-rooted and essential portion of the organ of hearing, is situated on the inner side of the tympanum, in the substance of the petrous portion of the temporal bone. It consists of the *osseous labyrinth*, which forms a receptacle for the *membranous labyrinth*, which is the immediate seat of the sense of hearing. No part of the body has a more complex and delicate structure. The labyrinth is composed of three very distinct compartments, which have been named the *vestibule*, the *semicircular canals*, and the *cochlea*.

The Osseous Labyrinth.

Preparation.—This is justly regarded as one of the most difficult dissections, even when the parts are previously known. The dissection should be made upon temporal bones from subjects of different ages, upon bones that have been macerated, upon others that have been dried without maceration, and also upon bones in the fresh state.

multam quidem membranam a periosteo propagatam, sulcum maxillæ repleri viderent, et processui longissimo circumnasci, cæterum in eo carneam naturam non deprehenderent. Neque mea experimenta rem expediunt. Musculum quoties volui, ostendi, num veras fibras viderem, plerumque dubius hæsi."—(*Haller*, tom. v, lib. xv., p. 218.)

* See note, p. 673.

Commence with a fœtal temporal bone, in which the labyrinth can very easily be isolated, in consequence of its being surrounded only by a spongy texture, readily yielding to the knife. In the adult, the labyrinth is, in proportion, much less developed than in the fœtus, and is surrounded with so compact a tissue, that, in order to cut it, it is necessary to use a chisel, a file, or a very strong scalpel. It is important to have a great number of temporal bones, so as to be able to make several different sections.

Preparation of the Vestibule.—Open the vestibule through its upper wall, which corresponds to the upper surface of the petrous portion of the temporal bone, opposite the fenestra ovalis, between the superior vertical semicircular canal and the internal auditory meatus.

Preparation of the Semicircular Canals.—In the fœtus, one of the semicircular canals projects upon the base of the petrous portion of the temporal bone; it is easy to isolate it, as well as the other canals, by removing, with a strong scalpel, the spongy tissue in which they are imbedded. It is useful to have two preparations of the semicircular canals; one in which the canals remain entire, and another in which they have been opened.

Preparation of the Cochlea.—Remove layer by layer that part of the petrous portion of the temporal bone which corresponds to the bottom of the internal auditory meatus. A layer of very thin spongy tissue shows, in the fœtus, that we have arrived at the cochlea; remove this spongy tissue with care, and expose the cochlea, both on its upper and lower surfaces. In one preparation, the cochlea should be merely isolated; in another, it should be carefully opened, and for this purpose it is sufficient to make a simple cut into each of its turns: it is of importance not to remove the summit of the cochlea.

The Vestibule.

If a probe be passed from the tympanum through the fenestra ovalis (*f*, *fig.* 258), it enters an ovoid cavity (*a b t*, *fig.* 259) called the *vestibule*.

Fig. 258.

The vestible is the centre of the internal ear, and forms an intermediate cavity or passage (forum fodinæ metallicæ, *Vesalius*) between the semicircular canals (*o p q*, *fig.* 258), which are on its outer side, and the cochlea (*l*), which is to its inner side. It is situated in a line with the axis of the internal auditory meatus. It is remarkable for having a great number of both large and small openings into it.

The *large openings* are seven in number: the first is the *fenestra ovalis* (*f*, *figs.* 258, 261), which would establish a free communication between the vestibule of the tympanum if it were not for the base of the stapes, which closes it hermetically, as we may be convinced by examining it from the vestibule, when the stapes remains in its place.* There are *five* openings (*o' p' q'*, *fig.* 259; *o' a'*, *fig.* 261) for the three semicircular canals; and the seventh is the orifice (*t*) of the vestibular scala of the cochlea. In macerated bones we find, besides, an eighth opening, situated below the fenestra ovalis, having an oblong shape, and leading into the highest part of the fenestra rotunda.

Fig. 259.

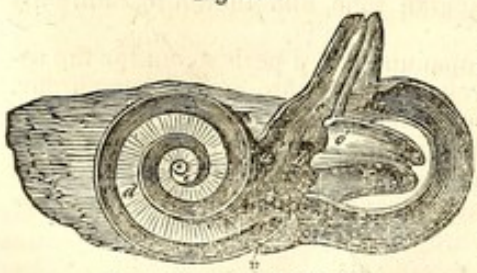

Osseous labyrinth of the left side. Magnified two diameters.

Of the *small openings*, the first is the *orifice* (*r*, *fig.* 259) *of the aqueduct of the vestibule*, which opens upon the posterior wall of this cavity to the inner side of the common opening for the two vertical semicircular canals (*i. e.*, in the recessus sulciformis). The aqueduct of the vestibule turns a short distance around that common opening, and then, bending at a right angle, terminates upon the posterior surface of the petrous portion of the temporal bone by an orifice already described (see Osteology). The other small openings in the vestibule are foramina for the passage of vessels and nerves; they form the *macula cribrosa*, which corresponds with the bottom of the internal auditory meatus.

The character of the vestibule is irregularly ovoid, and is divided by a *crista* into two fossæ: one inferior and hemispherical, named the *fovea hemispherica* (*a*, *fig.* 259); the other, superior and semi-elliptical, called the *fovea semi-elliptica* (*b*). Morgagni has described a third groove-like fossa (*recessus sulciformis*), situated at the mouth of the common orifice of the two superior semicircular canals.

The Semicircular Canals.

The *semicircular canals*, three in number, represent three cylinders or tubes (tubæformes canales, *Sœmmering*), of equal diameters, and curved very regularly, so as to describe

* [The base of the stapes is retained in its situation, and the complete closure of the fenestra ovalis is effected, by the reflection of the lining membrane of the tympanum on the one hand, and by that of the lining membrane of the labyrinth on the other.]

portions of circles; they are situated within the substance of the base of the petrous portion of the temporal bone, behind the vestibule, into which they open by the five orifices already described.

They have been named the *great*, the *middle*, and the *small* semicircular canals; terms which have caused much confusion, because the differences between them, in regard to length, are not alone sufficient to distinguish them from each other.

Their *direction* forms a much better ground of distinction between them. Two are *vertical*, and one is *horizontal:* there is an *anterior* and *superior* vertical, and a *posterior* and *inferior* vertical canal; the horizontal canal is *external*, and is situated between the two others.

The *superior vertical canal* (*p*, *figs.* 258, 260), which describes two thirds of a circle, is placed at the highest part of the labyrinth, immediately to the outer side of the vestibule. A plane passing through the two branches of this canal would cut the base of the petrous portion almost at a right angle.

The convexity of this canal is turned upward, and its concavity downward. In the fœtus, its concavity is free, so that it can be seen without any dissection; but in the adult it is filled up with osseous tissue.

The anterior and outer extremity (*p'*, *figs.* 258, 259) of this canal is dilated into an *ampulla*, and opens separately at the upper and outer part of the vestibule. The posterior and inner extremity unites with the corresponding extremity of the inferior vertical canal to form a common canal (*a*, *fig.* 260), which opens without any dilatation into the upper and inner part of the vestibule (*a'*, *fig.* 261).

Fig. 260

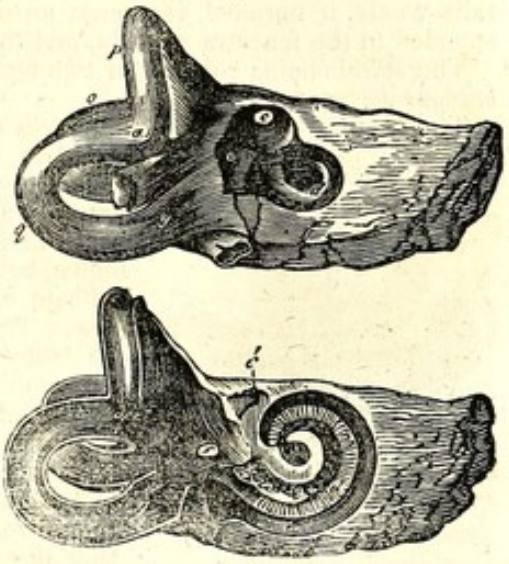

The *inferior vertical canal* (*q*, *figs.* 258, 260) is placed at right angles to the preceding, and parallel with the posterior surface of the petrous portion. It commences at the inner and upper part of the vestibule, by the common canal (*a*, *fig.* 260) already described, passes almost directly outward, curves at first downward, and then forward, and becomes dilated into an *ampulla* (*q'*, *fig.* 258) near the vestibule, into which cavity it opens (*q'*, *fig.* 259), about the distance of a line from the point at which it commences. This canal, therefore, describes nearly a complete circle; and hence the term *canalis major et longior*, still given to it by Sœmmering, in contradistinction to the superior vertical semicircular canal, which he calls *minor et brevior*.

The *horizontal canal* (*o*, *figs.* 258, 260), *canalis minimus, brevissimus, sive exterior* of Sœmmering, commences in the vestibule (*o'*, *figs.* 258, 259) between the fenestra ovalis, which is below, and the ampullar opening of the superior vertical canal, which is above; it becomes dilated into an *ampulla*, describes a horizontal curve having its convexity turned outward, and opens (*o'*, *fig.* 261) upon the inner wall of the vestibule, between the common opening (*a'*) of the two vertical canals and the proper opening (*q'*) of the inferior vertical canal.

It appears, then, that each of the three semicircular canals has one of its extremities dilated into an ampulla, and the other not dilated; that the two vertical canals unite by their non-dilated extremities; that of the five openings belonging to the semicircular canals, two occupy the outer, and three the inner wall of the vestibule, and that the three last consist of the common canal formed by the two vertical canals, by the ampullar extremity of the posterior vertical canal, and by the non-ampullar extremity of the horizontal canal.

The Cochlea.

The *cochlea* (*l*, *fig.* 258), or *snail*, so called from its resemblance to the shell of that molluscous animal, may be said to consist of a conoid tube, which is subdivided into two cavities, called *scalæ*, by a septum extending from its base to its apex, and is coiled upon itself into a spiral containing two turns and a half.

The cochlea is the most anterior part of the internal ear; it is situated on the inner side, and in front of the tympanum; its base (*d*, *fig.* 260) rests upon the bottom of the internal auditory meatus.*

Its external surface is blended, in the adult, with the substance of the petrous portion of the temporal bone, so that it requires much skill to carve it out without breaking into its cavity: in the fœtus, on the contrary, such a dissection is extremely easy, on account of the thin layer of spongy osseous tissue by which it is separated from the rest of the bone.

* [The summit of the cochlea is directed forward, downward, and outward. The gyri of the cochlea are coiled in a direction from below upward, and from without inward.]

The following parts of the cochlea are separately described: the *tube of the cochlea* or *lamina gyrorum*, the *lamina spiralis*, the *axis* or *columella*, the two *scalæ*, and the *aqueduct*.

The Tube of the Cochlea.—The tube of the cochlea (*canalis spiralis cochlæ*, or *lamina gyrorum*) is the compact lamina (*l*, *figs.* 258, 262) which forms the external walls of the cochlea. If we imagine a hollow osseous cone, coiled spirally, *cicut circa fulcrum convolvulus* (*Haller*), or like a winding staircase; and farther, that the lowest turn of the spire embraces the turn above it, and that the walls of the different turns are blended with each other, we shall have a correct idea of the tube of the cochlea: as before stated, the spire thus formed describes two turns and a half.

The Spiral Lamina of the Cochlea.—The spiral canal, or tube of the cochlea, is subdivided lengthwise into two secondary cavities (*c c*, *c c*, *figs.* 263, 264), called *scalæ* (*scala*, a staircase), by a septum (*a*), which is named the spiral lamina of the cochlea (*lamina spiralis cochleæ*).

Commencing at the base of the cochlea (*t*, *fig.* 259; also *fig.* 263), and at the fenestra rotunda, where it can be very easily seen, the spiral lamina winds edgewise around the axis or columella (*b b*, *fig.* 262), and is continued without any interruption to the summit or cupola (*f*) of the cochlea, the several turns of which it exactly follows. Its *internal border* is applied against the axis of the cochlea, and adheres intimately to it, excepting above, where it is free for a short distance, and leaves a communication (*n*, *fig.* 263) between the two scalæ. *Margo liber laminæ spiralis quo fit ut utriusque scalæ sit communicatio* (*Sœmmering*). Its *external border* adheres to the inner surface of the lamina gyrorum, or tube of the cochlea. In consequence of the conical form of this tube, the lamina spiralis would, if unrolled, represent an isosceles triangle, the base of which had corresponded to the fenestra rotunda, and the apex to the summit of the cochlea.

The *spiral lamina* consists of two portions—an internal *osseous* and an external *membranous portion.**

The osseous portion (*lamina spiralis ossea*, *d*, *figs.* 259, 261, 262, 264) predominates in the first turn, diminishes gradually in the second, and ceases at the commencement of the third, where it terminates in a kind of *hook* or *beak* (*hamulus vel rostrum*, *e*, *fig.* 262). This bony portion is thick, and consists of two lamellæ, between which are found a great number of very delicate canals, through which the nerves of the cochlea pass. These two lamellæ form two distinct furrows upon the columella.

Fig. 262.

Cochlea (dry) magnified four times.

The membranous portion (*lamina spiralis membranacea*, *a a*, *figs.* 263 to 265) completes the septum, forming its outer part. It is narrow in the first turn of the cochlea, becomes broader in the second, and constitutes the entire septum in the third.

Fig. 263.

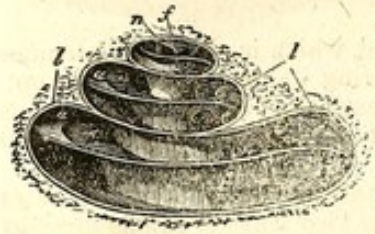

Cochlea (recent).

The bony and membranous portions of the spiral lamina, therefore, represent two isosceles triangles, so arranged that the base of the one corresponds to the apex of the other, and *vice versâ*.

Moreover, as Comparetti remarks, three zones can be distinguished in the membranous portion of the spiral lamina, the consistence of which diminishes progressively from the margin of the osseous lamina towards the internal surface of the tube of the cochlea.

The Axis or Columella of the Cochlea.—From the bottom, or, rather, from the posterior part (*d*, *fig.* 260) of the bottom of the internal auditory meatus, arises a bony process, which is directed almost horizontally outward; it occupies the centre or axis of the cochlea, and around it both the tube and spiral lamina describe their several turns. This bony process is called the *axis of the cochlea*, *columella*, *modiolus*, or *nucleus* (*b*, *figs.* 262, 264). It extends from the base to the summit of the cochlea, but undergoes certain changes during its course. Opposite the first turn it is extremely thick, but becomes much thinner in the first half of the second turn. In the second half of the second turn, and in the last half turn, it is replaced by a cup-shaped lamella, called the *infundibulum* (scyphus, *Vieussens*, *c*, *fig.* 262), the expanded portion of which is turned towards the cupola (*f*) of the cochlea. The modiolus or axis of the cochlea, then, has three perfectly distinct parts.

The *base* of the modiolus, which is seen at the bottom of the auditory meatus, is marked by a very distinct spiral tract (*d*, *fig.* 260), perforated with foramina, through which the filaments of the auditory nerve are transmitted. It is the *tractus spiralis foraminulentus* of Cotugno.

The *apex* of the modiolus, when examined in a cochlea which has been opened from the under surface of the petrous portion of the temporal bone, presents a decidedly infundibuliform figure. But in a cochlea which has been opened from its upper surface

* [In the dried cochlea (*fig.* 262), the two scalæ communicate along their whole course.]

(*fig.* 264), on the contrary, it has the appearance of a very slender stalk, continuous with the rest of the modiolus, and proceeding directly to the cupola of the cochlea. This two-fold structure depends upon the fact that the terminal lamella of the modiolus forms only half a funnel, which half is turned towards the lower half of the cochlea. This *terminal lamella of the modiolus*, which has been very well described by Huguier, is of a triangular form, extends through half a turn of a spiral, and adheres to the inner surface of the tube of the cochlea by its external convex border. Its internal border or margin is straight and free, and is the only part of this lamella which is seen when the cochlea is opened from above, while its convex border and its surfaces are distinctly seen when the cochlea is opened from below. The hamulus (*e*, *fig.* 262) of the osseous portion of the lamina spiralis terminates opposite the middle of this free border or margin.

The surface of the modiolus is marked like a screw by two furrows corresponding to the two lamellæ of the osseous part of the spiral lamina; this surface is pierced with foramina for the branches of the auditory nerve.

If the modiolus be divided longitudinally (*fig.* 264), it will be seen that its centre is traversed by a number of canals, for the passage of the branches of the auditory nerve. These canals open by the foramina on its surface. In the centre of the half funnel formed by the terminal lamella of the modiolus is an opening, through which the terminal filament of the cochlear branch of the auditory nerve passes out; it is the orifice of the *tubulus centralis modioli*.

Fig. 264.

Cochlea magnified.

The Scalæ of the Cochlea.—The spiral lamina (*d d*, *fig.* 264) divides the cavity of the tube of the cochlea into two secondary cavities (*c e*, *c e*), called the *scalæ* of the cochlea. They are distinguished as the *external*, *superior*, or *vestibular scala* (scala vestibuli, *c c*, *figs.* 263, 264), and the *internal*, *inferior*, or *tympanic scala* (scala tympani, *e e*). The first (*c c*, *fig.* 265) communicates directly with the vestibule (between *t* and *s*); the second, which commences at the fenestra rotunda (*s*, *fig.* 258), would communicate with the tympanum if that fenestra were not closed by a membrane; hence the term *scala clausa*. The tympanic scala is decidedly larger than the vestibular. The *section* of either of the scalæ, at right angles to its axis, is semicircular.

The two scalæ communicate near the summit of the cochlea (at *n*, *figs.* 263, 265). Both the situation and nature of this communication can be easily ascertained, and have been well described by Sœmmering, and more recently by MM. Breschet and Huguier.

The lamina spiralis, which, we have seen, adheres closely to the modiolus, continues to wind spirally around the half-funnel-shaped termination of the modiolus, but when it arrives opposite the concavity of this half funnel, it ceases to be attached to that concavity, its internal border becomes free, and is then continued on to the inner surface of the summit of the cochlea. It follows, therefore, that the free concave border of the lamina spiralis is opposite to the concavity of the infundibulum; and hence there is an interruption in the septum, in the form of a *circular opening*, the *canalis scalarum communis* of Cassebohm, the *helicotrema* of Breschet (*n*, *figs.* 263, 265), which establishes a communication between the two scalæ: moreover, this opening is not situated precisely at the summit of the scalæ, but a little below that point; nor is the opening of communication (between *t* and *s*, *fig.* 265) between the vestibular scala and the vestibule situated at the lowest part of that scala.

The Aqueduct of the Cochlea.—The *aqueduct of the cochlea* opens at one end (*n*, *fig.* 259) into the tympanic scala of the cochlea, near the fenestra rotunda; and at the other, by an expanded extremity, upon the lower border of the petrous portion of the temporal bone, near the jugular fossa. It does not appear to have any such use as was attributed to it by Cotugno. Like the aqueduct of the vestibule, it is merely a canal for a vessel, and as such was denominated by Wildberg *canalis venosus cochleæ*. The liquor Cotunnii could not pass through this canal, for it is closed by the dura mater. Ilg has taken a very ingenious view of the structure of the modiolus and cochlea. According to that author, the modiolus is not an osseous centre independent of the lamina gyrorum, but rather the internal wall of the spiral tube of the cochlea, which, in describing its first turn, intercepts a considerable cylindrical space of about two lines and a half in diameter, and then a smaller, but still cylindrical space, of about half a line in diameter, in its second turn; while in the third turn there is no space, and therefore the axis or modiolus is wanting, but it is replaced by the internal wall of the spiral tube of the cochlea itself. The terminal lamella of the modiolus would therefore be formed by the internal wall of the spiral tube.

This view is supported by the structure of the bottom of the internal auditory meatus, on which is found a turn and a half of a spiral groove, precisely corresponding to the spire of the cochlea, and by sections of the cochlea made after Sœmmering's plan, from the apex to the base. (*Vide figs.* 11, 12, 13, 14, 15, of Sœmmering's fourth plate.)

The Membranous Labyrinth.

The *membranous labyrinth*, discovered by Comparetti and Scarpa, has been correctly

described and figured by Sœmmering. M. Breschet has recently enriched our knowledge of this intricate anatomical subject with many most interesting facts. (*Etudes anatomiques et physiologiques sur l'organe de l'ouie et sur l'audition dans l'homme et les animaux vertebres*, 1833.)

It is useless to attempt the examination of the membranous labyrinth in the human subject without some previous preparation. If the labyrinth be opened, it is found to contain a fluid; the eye can detect nothing else. By previously macerating it in diluted nitric acid, the twofold advantage is gained of softening the bones, so that they can be cut with a scalpel, and of hardening and rendering opaque the nervous tissues. Before studying the membranous labyrinth in the human subject, it should first be examined in the large cartilaginous fishes, such as the ray and the turbot, in which it is most highly developed. It is then seen that the semicircular canals and the vestibule contain, besides a fluid, certain *semi-transparent membranous tubes* and *sacs*, the aspect of which closely resembles that of the retina.

The membranous labyrinth (*fig.* 265) is not so extensive as the osseous labyrinth; thus, it does not enter the cochlea, and its diameter is much less than that of the bony labyrinth. It scarcely occupies one half the cavity of the latter.

Fig. 265.

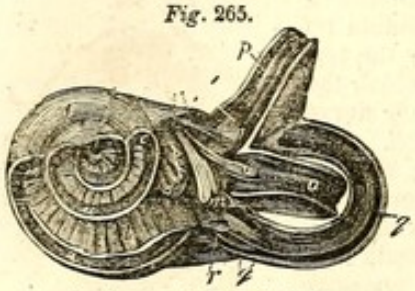

Membranous labyrinth (left side).

The space between the bony and membranous labyrinths is filled with a limpid fluid, named, after Cotugno, the *liquor Cotunnii*, although it had been noticed by several anatomists before that author. (*De aquæ ductibus auris humanæ internæ.* Cotugno, 1760.) It is the *perilymph* of M. Breschet.

There is no air in the labyrinth, and it is somewhat singular that so accurate an anatomist as M. Ribes should have recently defended a contrary opinion, although it has been repeatedly refuted.

The membranous labyrinth is itself filled with a fluid which was correctly described by Scarpa, and which might be named the *fluid of Scarpa*. M. de Blainville has compared it to the vitreous humour of the eye, and has named it *la vitrine auditive:* it is the *endo-lymph* of M. Breschet.

The membranous labyrinth consists of membranous semicircular canals, and of a vestibular portion.

The Membranous Semicircular Canals.

The *membranous semicircular canals* (*o p q*, *fig.* 265) were regarded as nervous cords by Scarpa, who first described them; they have precisely the same form as the osseous semicircular canals, although they do not completely fill them. Sœmmering improperly calls them *tubuli membrano-cartilaginosi*. Each membranous canal, like the corresponding osseous one, has its *ampulla*, or *ovoid* muscle (*o' p' q'*).

The two vertical membranous canals unite at one end into a common canal, and, therefore, the three membranous semicircular canals, like their osseous investments, open into the membranous vestibule by five distinct orifices.

The *membranous vestibule* consists of two very distinct parts, the *common sinus* and the *saccule*.

The sinus communis vestibuli, or *vestibular utricle* (*u*),* as was first shown by Scarpa, forms the confluence of the membranous semicircular canals which open into it by five orifices. The utricle is situated in the fovea semi-elliptica of the vestibule, and floats, as it were, in the liquid of Cotugno; it is distended by the liquid of Scarpa, so as to resemble an oblong bulla. The liquid of Cotugno separates it from the base of the stapes, as Scarpa very well pointed out.

The *sacculus vestibuli*, or vestibular saccule (sacculus proprius sphæricus, *Sœmmering*, *s*), is much smaller than the utricle. Its connexions with the utricle have been compared by Fischer to those of the crystalline lens with the vitreous body: it occupies the fovea hemispherica of the vestibule, and is therefore situated below the utricle. According to Sœmmering, it does not adhere to the utricle; that author has even represented a small space between these two parts.† According to others, there is a communication between them, and the saccule is merely a supplementary cavity to the utricle. I have not yet been able to satisfy myself concerning this point.

The membranous labyrinth, then, is quite distinct from the membrane which lines the labyrinthic cavities. This periosteal membrane, which analogy would lead us to regard as a fibro-serous membrane, is the only membrane which is prolonged into the cochlea. We might, however, regard that portion of the lamina spiralis which is next to the inner surface of the lamina gyrorum as a portion of the membranous labyrinth.

* *Alveus utriculosus* of Scarpa, *utriculus communis* of Sœmmering, *sinus médian* of M. Breschet.

† Sacculus teres cum utriculo communi nullibi cohæret, et ubi cultri apice aperitur, sphæricam ormam retinet. (Explanation of fig. 2, pl. 3.) According to M. Breschet, the sacculus and utriculus adhere intimately, and he is inclined to believe that their cavities even communicate; but, from the extreme delicacy of these structures, he has been unable to confirm this supposition.

The Calcareous Matter of the Vestibule.—The examination of the ear of fishes, which has proved of such assistance in investigating the structure of the human membranous labyrinth, has also led to the inquiry, whether there existed anything in the human ear analogous to the solid calcareous concretions found in the labyrinth of the ear of fishes. From the researches of M. Breschet, it appears that the labyrinthic stones, or *otolithes*, of fishes, are represented in all the mammalia, and, consequently, in man, by a cretaceous powder, which he has named *otoconia* (οὖς, ὠτὸς, the ear, and κόνις, dust); and that this powder exists both in the utricle and the saccule, collected together into two white shining masses, which were seen and described by both Comparetti and Scarpa, but were mistaken by them for the dried acoustic nerve. Does it fulfil the same uses as the otolithes in fishes? or should it be regarded as a rudimentary condition of an important structure in other animals?

The Auditory Nerve and the Vessels of the Ear.

The *auditory nerve*, or special nerve of the organ of hearing, is remarkable for its softness, and hence it has been named the *portio mollis* of the seventh cranial nerve. The auditory nerve arises, at least in part, from the anterior wall of the fourth ventricle; having reached the bottom of the internal auditory meatus, it divides into two branches: an *anterior* and larger, distributed to the cochlea, and a *posterior*, intended for the vestibule and semicircular canals. The anterior or *cochlear branch* (*t*, *fig.* 264) has a spiral arrangement, like that portion of the bottom of the auditory meatus (*d*, *fig.* 260) to which it proceeds, and it enters through the foramina in the tractus spiralis of the lamina cribrosa. One set of nervous filaments enters the small canals in the centre of the modiolus (*b*, *fig.* 264); the others are applied to the surface of the modiolus (*t*, *fig.* 263); the latter filaments spread out upon the first turn of the lamina spiralis (*t*, *fig.* 265), radiating in the most regular manner, and having arrived near the outer border of the spiral lamina, they each divide into two or three ramuscules, which anastomose together, so as to form a nervous expansion.* These radiating filaments are more distinct upon the lower than upon the upper surface of the spiral lamina.

Those filaments of the nerve which are not spread out upon the first turn of the lamina spiralis pass through the foramina in the centre of the modiolus, and spread out upon the second turn, in the same manner as those already described. Lastly, the highest filaments emerge from the opening at the apex of the modiolus, and terminate in a similar manner. It follows, therefore, that the nerves of the cochlea successively diminish in length, as the spiral lamina does in width; and thus the radiating nervous filaments resemble the strings of a harp, in becoming successively shorter and shorter. It is probable that this arrangement is not without its influence upon the function of hearing. In a temporal bone softened by the action of nitric acid, the auditory nerve, the modiolus, the spiral lamina, and the periosteal membrane which lines the cochlea, may be dissected with the greatest facility.

The posterior or *vestibular* division of the auditory nerve is subdivided into three branches, the largest of which (*v*, *fig.* 265) is distributed to the utricle (*u*) and to the ampullæ (*o' p'*) of the superior vertical and horizontal membranous semicircular canals; the middle-sized branch is distributed to the sacculus (*s*), and the smallest ends in the ampulla (*q'*) of the inferior vertical membranous semicircular canal.†

Bloodvessels may be traced into the membranous labyrinth; most of them enter by the internal auditory meatus; those which belong to the cochlea pass through the foramina in the modiolus, and are distributed in a radiating manner like the nerves.

THE CEREBRO-SPINAL AXIS.

General Observations.

The *cerebro-spinal axis* constitutes the *central* portion, while the *nerves* form the *peripheral* portion of the nervous system.

The *apparatus of innervation* formed by the cerebro-spinal axis and the nerves together, and named the *nervous system*, is the most important part in the animal machine; it is the source not only of sensation and motion, but of the universal sympathy existing between the several parts of the animal economy; and that part of it called the brain performs the highest function allotted to organized beings, by becoming the immediate instrument of the soul in the exercise of the intellectual faculties.

* [According to observations made by Treviranus, Gottsche, and others, the filaments of the cochlear nerve in animals do not anastomose, but terminate in isolated extremities, which are in some cases papillary (*Treviranus*), and in others club-shaped (*Gottsche*).]

† [The nervous filaments proceeding to the utricle and saccule form a fan-like expansion upon those sacs, penetrate into their interior, and spread out as a nervous layer on their internal surface. Each of the nerves which are distributed to the membranous ampullæ appears to bifurcate, so as partially to embrace its corresponding ampulla in a transverse direction; the nervous filaments then penetrate into the ampulla, and spread out upon a transverse septum, formed in its interior by the folding inward of the walls of the cavity, and also upon the adjacent parts of those walls. (See *Steifensand*, *Müller's Arch.*, 1835.)]

The cerebro-spinal axis consists of that soft, pulpy, elongated, and symmetrical mass of nervous substance, which, becoming enlarged at its upper part, occupies the vertebral canal and the cavity of the cranium, and forms the centre from which the nerves of all parts of the body take their origin, or in which they all terminate.

The structure of no other organ in the body excites so much curiosity, and, unfortunately, there is none whose structure is involved in greater obscurity. Notwithstanding the real advances that have recently been made in our knowledge of the anatomy of the brain, we must still acknowledge, with Stenò, that the human mind, which has carried its investigations even into the heavens, has not yet been able to comprehend the nature of the instrument by which its own operations are performed, and that its powers seem to abandon it as soon as it turns its attention to the organ in which it resides. Until the end of the last century, the study of the central portion of the nervous system consisted in a simple enumeration of its parts, or, rather, in a more or less imperfect description of its external surface, and of the different objects displayed by various sections. The nomenclature of the different parts of the encephalon* is alone enough to show with what limited views the researches of those anatomists must have been made, who did not suspect that this pulpy-looking mass—a sufficient definition of which they believed to be, that it held an intermediate place between the solids and the fluids of the body—was as wonderful in the delicacy and intricacy of its structure, as in the importance and elevated character of its functions. In the present day, anatomists include in the study of the encephalon not only the topographical study of its various constituent parts, but also the determination of the mode in which those parts are connected together. To ascertain this latter point, apart from all questions as to origin, formation, generation, and re-enforcement, with which the subject has lately been embarrassed, should constitute the special aim of every inquiry into the anatomy of this part of the nervous system.

The central portion of the nervous system consists, 1. Of the *spinal cord;* 2. Of the *tuber annulare*, the *peduncles of the cerebrum and cerebellum*, and the *tubercula quadrigemina;* these together constitute a very constricted portion, which forms the bond of union between the other parts of the encephalon, and which I shalll accordingly name *le nœud de l'encephale;*† 3. Of the *cerebellum*; 4. Of the *cerebrum*.

The cerebro-spinal axis is surrounded by three membranes or cóverings, called the *meninges* (from *μήνιγξ*, a membrane), which perform some important functions in regard to it, and which must in the very first place occupy our attention.

THE MEMBRANES OF THE CEREBRO-SPINAL AXIS.

General Remarks.—The Dura Mater—the Cranial Portion, its Structure and Uses—the Spinal Portion.—The Arachnoid—its Cranial Portion—its Spinal Portion—the Subarachnoid Fluids—their Uses.—The Pia Mater—its External Cerebral Portion.

But few parts of the body are so effectually protected as the cerebro-spinal axis; this protection is afforded in part by the vertebral column,‡ and by the cranium, the mechanism of which we have already described as being so eminently calculated to defend the parts situated within them.

Besides the osseous case formed by the vertebro-cranial column, we find, surrounding the cerebro-spinal axis, a fibrous sheath, named the *dura mater;* a serous membrane, called the *arachnoid;* and a proper membrane, named the *pia mater*, in which the vessels of the nervous centre ramify.

The Dura Mater.◊

Dissection of the Dura Mater of the Scull.—Make either a crucial incision, or one extending from before backward, or from ear to ear, through the integuments of the head; turn back the flaps, taking care to remove the periosteum with the hairy scalp.

The bones of the cranium being thus exposed, the scull-cap may be removed, either with a sort of hatchet (*marteau-hachette*) or a saw.

This hatchet is the most expeditious and the best instrument. There is no fear of shaking or lacerating the brain, if the instrument be properly used; but it is almost impossible to avoid cutting the brain with the saw, the only advantage of which over the other is, that it makes an even section.

The section should be carried quite round the cranium, about a finger's breadth above

* From *ἐν*, in, and *κεφαλὴ*, the head; a convenient term, used to signify that part of the cerebro-spinal axis which is situated within the cranium.

† [It is necessary to bear in mind that the equivalent term, *nodus encephali*, has been assigned by Sœmmering to the pons Varolii.]

‡ A vertebrated animal may also be defined to be an animal provided with an encephalon; an inter-vertebrated animal is one having no encephalon.

◊ The application of the term *mater* to the meninges of the brain is derived from the Arabians, who regarded these membranes as the origin, or mothers of all the other parts of the body; or, perhaps, as Haller has observed, this use of the term depends upon an Arabic idiom, by which the covering of any body whatsoever is called its mother.

the orbital arches, the scull-cap being raised and removed by means of the narrow end of the hatchet, or by means of a hook attached to the extremity of its handle.

If the brain is not to be preserved, a somewhat different method of proceeding is adopted. Two parallel cuts must be made with the saw, one on each side of the superior longitudinal sinus, along its whole extent. Each of these cuts should then be met by another, carried horizontally through the corresponding side of the scull. When the two portions of bone included between these sections are removed, there remains an intermediate portion of bone, about an inch wide, extending from the nasal eminence to the occipital protuberance. The dura mater should then be divided along the borders of this intermediate portion of bone, and the brain and cerebellum removed.

If, however, it be intended to preserve the brain and cerebellum, after the entire scull-cap has been removed in the ordinary manner, the dura mater must be divided circularly, along the cut edge of the cranium, the anterior extremity of the falx cerebri must be divided with the scissors, and the whole fibrous cap turned backward.

Another mode, and one which I prefer, is, to make an incision through the dura mater along each side of the superior longitudinal sinus, and then to divide the anterior extremity of the falx, and reflect that part backward.

Dissection of the Dura Mater in the Vertebral Canal.—This part of the dura mater may be exposed, either by removing the arches of the vertebræ, or by taking away the bodies of these bones. The latter method is but seldom adopted.

The arches of the vertebræ may be removed by means of a chisel and mallet, or, still better, by the *rachitome*.

An instrument has lately been invented, consisting of two parallel saws, slightly convex on their toothed edges, firmly connected together, but capable of being separated or approximated as may be desired. Preference is justly given to the rachitome over this complicated instrument. The important object in opening the spine is, to make the section opposite the junction of the laminæ with the transverse and articular processes.

In order to display the continuity of the cranial and spinal portions of the dura mater, it is necessary to connect the sections already made in the head and spine, by removing with the saw the intervening portion of the occipital bone.

A beautiful preparation of the dura mater may be made by removing the roof and sides of the scull, and the arches of all the vertebræ; by then taking out the encephalon and spinal cord through incisions in the dura mater, which may be readily concealed; and by filling the cavity thus left with tallow, which is afterward to be dissolved out by spirits of turpentine, or, what is easier to do, the cavity of the dura mater may be filled with fine sand.

The *dura mater* (meninx crassa, *Galen;* le méninge, *Chauss.*) is a fibrous membrane which covers and protects the cerebro-spinal axis, and the roots of all the nerves which arise from or terminate in that portion of the nervous system.

It is the most external of the membranes of the brain and spinal cord (meninx exterior, *Sœmmering*); it consist of a *cranial* and a *spinal* portion.

The Cranial Portion of the Dura Mater.

The *cranial portion of the dura mater* forms a fibrous sac, which lines the internal surface of the bones of the cranium, forming their internal periosteum, and at the same time serves as a covering for the encephalon, and separates its different parts by means of prolongations or incomplete septa.

The dura mater in the scull presents for our consideration an *external* and an *internal surface.*

External Surface of the Dura Mater.

Its *external surface* is accurately moulded upon the internal surface of the bones of the cranium, to which it adheres by a multitude of small fibrous and vascular prolongations, which can be readily displayed by putting the membrane under water. These prolongations give the external surface of the dura mater a rough appearance, which contrasts strongly with the smooth aspect of its internal surface. The ramifications of the middle meningeal arteries and veins are seen on the external surface of the membrane, and project from it, as if they were only laid upon it.

The dura mater adheres to the parieties of the cranium with different degrees of firmness in different situations.

Thus, it is generally less firmly adherent to the roof of the scull than to its base, where it is impossible to separate it from the bone. The upper border of the petrous portion of the temporal bone, the posterior border of the lesser wings of the sphenoid, and the margin of the foramen magnum, are points to which it is very firmly attached; but the dura mater adheres more strongly opposite the sutures than in any other situation. Upon the orbital plates, on the occipital fossæ, and upon the squamous portion of each temporal bone, it adheres so slightly, that it has been conceived to be altogether unattached in those regions.*

* An erroneous opinion for a long time prevailed that the adhesions between the dura mater and the bones

The firmness of the adhesion between the dura mater and the bones varies at different periods of life, and also the manner in which it is effected. Thus, in old subjects, the parts are so closely united, that it is almost impossible to take off the roof of the scull without, at the same time, removing portions of the dura mater. When this happens, there is ossification of the outermost layers of this membrane. In the new-born infant, the adhesion is firmer than in the adult, especially opposite the sutures.

As to the mode in which this adhesion is effected, it may be stated, that in the infant it appears to be exclusively by means of vessels; in old age, almost entirely by fibrous tissue; and in the adult, by partly vascular and partly fibrous prolongations.

The dura mater is, moreover, attached to the bones of the cranium by means of the fibrous canals formed by this membrane for the nerves and vessels which pass through the foramina in the base of the scull.

The most remarkable prolongations of the cranial portion of the dura mater, excepting that for the spinal cord, are those given off opposite the right and left sphenoidal fissures. Each of these prolongations separates into two layers, one of which forms the sheath of the corresponding optic nerve, while the other blends with the periosteum lining the cavity of the orbits.

The Internal Surface of the Dura Mater.

The *internal surface* of the cranial portion of the dura mater appears smoothly polished, and is constantly lubricated with serosity; its polished appearance is owing to a layer of arachnoid with which it is covered; this layer is so thin that one might be disposed to deny its existence, and it is so firmly united to the dura mater that its demonstration is extremely difficult. Excepting at the points where the cerebral veins enter the different sinuses, the internal surface of the dura mater lined by the arachnoid is free, and is in contact with the cerebral arachnoid, and indirectly with the outer surface of the encephalon.

From this surface certain prolongations or imperfect septa are given off, by which the cavity of the cranium is divided into several compartments. These septa are three in number, viz., the *falx cerebri*, the *tentorium cerebelli*, and the *falx cerebelli*.

The Falx Cerebri.—This is a fibrous lamina (*d*, *fig.* 220), which is placed vertically along the median line, is shaped like a sickle, and extends from the foramen cæcum to the tentorium cerebelli. Its point, which is in front, dips into the foramen cæcum, and envelops the crista galli; its *base* is behind, and rests perpendicularly upon the middle of the tentorium cerebelli. The venous canal, called the *straight sinus*, is situated along the line in which the falx and the tentorium meet. The *upper border* of the falx is convex, and extends from the foramen cæcum to the internal occipital protuberance. In this border is placed the superior longitudinal sinus.

The *lower border* is concave, thin, sharp, and free, and corresponds to the corpus callosum, touching that body, however, only at the back part, and, according to some anatomists, making a rather deep furrow upon it. This free border, which is thicker behind than in front, contains within it a small vein, which has been named the *inferior longitudinal sinus*. The two *surfaces* of the falx correspond to the internal surfaces of the two hemispheres of the brain. Not unfrequently the falx cerebri is found as if torn through in some points, and I once observed the two hemispheres continuous with each other through an opening in this septum.

The use of the falx is evidently to obviate the effects of lateral concussion of the brain, and to prevent one hemisphere from pressing upon the other, while the person is lying upon his side.

The Tentorium Cerebelli.—This is an imperfect horizontal septum (le septum transverse, *Chauss.*), which is, as it were, notched in front, and which separates the cerebrum from the cerebellum. It is constantly in a state of tension; a condition which depends upon the permanently tense state of the falx cerebri. These two parts, indeed, mutually preserve each other's tension, and when either of them is cut, the other necessarily becomes relaxed. It is, therefore, only when the tentorium is examined *in situ*, and the falx is left uninjured, that the anatomy of the former can be properly understood. It is then seen that it represents two planes, inclined upward, and united in the middle line at an obtuse angle, so as to form a sort of arch, upon the top of which the base of the falx cerebri rests. The concavity of this arch corresponds to and is accurately fitted upon the convex upper surface of the cerebellum below; the convexity corresponds to the slightly concave under surface of the posterior lobes of the cerebrum.

Its *outer* or *convex border* is directed horizontally; it corresponds behind to the posterior portion of the lateral grooves, and in front to the upper border of the pars petrosa. The lateral sinus occupies the whole occipital portion of this border.

Its *inner* or *concave border* is parabolic; between it and the basilar groove, in front, a small space is intercepted, which is occupied by the *nodus encephali*, being accurately

were the results of disease; and it has even been believed that a space existed between the dura mater and the bones of the cranium. These errors resulted from a physiological hypothesis, which attributed the movements of the brain to contraction of the dura mater.

adapted to that part of the brain. The *extremities* of the external and internal borders cross each other on each side like the letter X ; the extremities of the outer border are attached to the posterior clinoid processes, and form on each side a sort of bridge, near the apex of the pars petrosa, beneath which the fifth cranial nerve passes ; the extremities of the inner border are prolonged above those of the outer border, and are attached to the anterior clinoid processes. They form the sides of the pituitary fossa, and contain in their substance the cavernous sinuses.

The Falx Cerebelli.—This is a small falciform fold, situated vertically in the median line (le septum médian du ceverlet, *Chauss.*); Winslow remarks that it is sometimes double. It extends from the internal occipital protuberance to the foramen magnum, and separates the two hemispheres of the cerebellum. Its *base*, directed upward, corresponds with and is attached to the tentorium cerebelli; its *apex* bifurcates upon the sides of the foramen magnum. Its *posterior border* corresponds with the internal crest of the occipital bone, and its *anterior border* with the bottom of the median fissure of the cerebellum.

Structure.

The dura mater is perhaps the thickest and strongest of all the membranous investments of the viscera. It may be regarded as consisting of two very distinct fibrous layers : of an *external* or *periosteal layer*, which forms the internal periosteum of the bones of the cranium ; and of an *internal* or *proper cerebral layer*, which, though blended with the preceding throughout the greatest part of its extent, is separated from it at certain points, in order to form both the fibrous canals, which are called the *sinuses*, and also the several folds just described as projecting from the internal surface of the dura mater. Thus, the periosteal layer of the dura mater enters into and lines the longitudinal groove, but the central layer passes off from it on either side ; and the two laminæ thus formed by the right and left portions of the cerebral layer approach each other, so as to include between themselves and the periosteal layer lining the groove a long three-sided interval, which forms the *superior longitudinal sinus*.

The internal layer of the dura mater, which is essentially fibrous, must not be confounded with the arachnoid membrane by which its internal surface is lined, and which will be presently described.

The dura mater is evidently composed of fibrous, not of muscular tissue, as was for a long time believed.*

It consists of fibres which interlace in various directions

Anatomists generally describe, in connexion with the dura mater, those white granular bodies which are chiefly collected into clusters along the superior longitudinal sinus, and which are improperly called *glands* (the *glands of Pacchioni*, from the name of the author who first gave a good description of them).

These bodies are not found in infants, but exist almost constantly in the adult, and are very numerous in old subjects. They are sometimes single and sometimes collected into groups ; they are, at first, formed upon the internal surface of the dura mater, but after a time they displace the fibres of the internal layer, and separate them into small, parallel, or reticulated fasciculi, and, in this way, insinuate themselves between the two layers of the membrane. In this situation they form tumours, which project upon the external surface of the dura mater, and occupy corresponding depressions formed in the bones of the cranium. The rough and irregular depressions so frequently found in the parietal bones of old subjects, and ascribed by the older anatomists to caries of the bone, are occasioned by the clusters of these granular bodies.

These bodies often insinuate themselves along the obliquely running veins into the substance of the walls of the sinuses, and project into the interior of the veins and sinuses, so as apparently to be in direct contact with the blood ; but they are, in reality, separated from that fluid by the lining membrane of the vessels and sinuses.

Although these bodies are principally collected along the superior longitudinal sinus, they are also found, as Haller remarks, opposite the anterior extremity of the straight sinus. I have seen a small pedunculated mass of them, which projected into the interior of the horizontal portion of one of the lateral sinuses, and might have impeded the circulation.

I consider that the bodies in question are seated in the sub-arachnoid cellular tissue ; in fact, they are often found beneath the arachnoid, at some distance from the longitudinal sinus, along the superior cerebral veins. They always project at first upon the internal surface of the dura mater, and then insinuate themselves into the substance of that membrane.

What is the nature of these bodies ? Ruysch noticed them, and considered them to be of a fatty nature. Some authors have likened them to the granulations so frequently

* Pacchioni, who wrote a treatise of some length upon this membrane, even went so far as to admit the existence of three fleshy bellies, viz., one for each hemisphere, and a third for the cerebellum. The same author gives a very minute description of the direction of the different layers of fibres in the dura mater. I do not believe that there exists in the history of our science a more striking example of the misapplication of textural anatomy.

found in the choroid plexuses; but there is not the slightest resemblance between the two. Pacchioni regarded them as glands which secreted a peculiar lymph. He has even described certain, so called, excretory ducts, which have been said by others to enter the superior longitudinal sinus. Those clusters which project into the sinuses have been supposed to act as valves. It has been said that these bodies are lymphatic glands; this, also, is erroneous; and, indeed, it is better to confess our ignorance of their nature. They occur so frequently that they cannot be regarded as morbid productions. Their absence in the infant, and their much greater abundance in the old subject than in the adult, are the principal features in their history.

Vessels.—In respect of the number and size of its vessels, the cranial dura mater seems to form an exception to fibrous membranes in general, which are remarkable for their slight vascularity. It receives, in fact, the following *arteries:* the middle meningeal, which is a branch of the internal maxillary artery; the anterior meningeal, from the ethmoidal artery; and the posterior meningeal, from the ascending pharyngeal, or pharyngo-meningeal. Nevertheless, if we consider that these vessels are situated between the dura mater and the bones, and that they are almost entirely distributed to the bones, we shall be able to account for the apparent anomaly in the number and size of these vessels.

The *veins* of the dura mater are two venæ comites for each meningeal artery, and the small veins which enter the sinuses; the venous sinuses themselves are situated between the two layers of this membrane.

The *lymphatics* form a network upon the internal surface of the dura mater, but do not appear to belong to the proper fibrous tissue.

Nerves of the Dura Mater.—On consulting the various writers upon this subject, it is found to be involved in the strangest perplexity: some authors admit, while others deny in the most positive manner, the existence of nerves in this membrane; and those who do admit their existence, differ altogether in regard to their origin.

Modern anatomists, with Haller, Wrisberg, and Lobstein, state that there are no nerves in the dura mater; on the other hand, Vieussens, Winslow, Lieutaud, Lecat, Valsalva, and others, declare that they have observed them. Valsalva says that they are derived from the seventh pair; all the other authors state that they arise from the fifth; but they do not agree as to the exact point of origin, which, according to some, is the Gasserian ganglion; and according to others, either the ophthalmic, or the superior or inferior maxillary divisions of that nerve. Chaussier admits their existence, and says that they are derived from the ganglionic system; but it is evident that he has been led to this conclusion from theory, and not from actual observation.

Accident has enabled me most distinctly to demonstrate nerves in the dura mater. In a head which had been macerated in diluted nitric acid, and afterward in water, the dura mater having become transparent and jelly-like, I was surprised to see within its substance certain white lines exactly resembling nervous filaments. I cut down to these white lines, ascertained that they were nerves, and dissected them throughout their whole course. I recognised on each side of the middle line two nervous filaments which came from the fifth nerves, and reached nearly to the superior longitudinal sinus. There was a third nervous filament in the substance of the tentorium cerebelli, but I could not ascertain its origin.*

Uses of the Cranial Dura Mater.—The dura mater serves as an internal periosteum for the bones of the cranium, with which it has numerous vascular connexions; and it also covers and defends the encephalon. Its prolongations separate from each other the different parts of the encephalon, and in some measure prevent the effects of concussion. It also contains within its substance certain venous canals, in which all the blood is returned from the encephalon.

The Spinal Portion of the Dura Mater.

The *spinal portion of the dura mater* forms a long fibrous tube, which is prolonged from the cranial dura mater, and extends from the occipital foramen to the termination of the sacral canal.

In order to ascertain the capacity of this fibrous sheath, it must be first distended with an injection: it is then seen to form a funnel-shaped tube, which is of considerable size in the cervical region, becomes contracted in the dorsal region, is again expanded in the lumbar region, and terminates in the sacral region by subdividing into a number of sheaths for the sacral nerves. When distended, the spinal portion of the dura mater almost entirely fills the bony canal formed by the vertebral column. Why the cavity of the dura mater (*d, fig.* 266, A B) should be larger than the spinal cord (*s*), a question the solution of which had exercised the ingenuity of almost all anatomists, has been well answered by Cotugno—it is for the purpose of containing a serous fluid.†

* [The tentorium receives a branch from the fourth cranial nerve (see description of that nerve).]

† "Quidquid autem spatii est inter vaginam duræ matris et medullam spinalem, id omne plenum etiam semper est; non medullâ quidem ipsâ in viventibus turgidiori, non nube vaporosâ, quod in re adhuc obscurâ suspicantur summi viri; sed aquâ ei quidem simili, quam circa cor continet pericardium, quæ caveas cerebri ventriculorum adimplet, quæ auris labyrinthum, quæ reliquas tandem complet corporis caveas, libero aeri, nequaquam adeundas."—(*De Ischiade Nervosa*, p. 11.)

The *external surface* of the spinal portion of the dura mater, unlike, in this respect, to the cranial portion, scarcely adheres to the bony parietes of the spinal canal. Covered by a plexus of veins *behind*, it has no attachment at all to the arches of the vertebræ, nor to the yellow ligaments; the intervals between those parts and the membrane is occupied by a soft, reddish, adipose tissue intermixed with veins, which, in the fœtus, and during infancy, is infiltrated with serosity. This fat, which is most abundant in the sacral region, may be most aptly compared to the marrow of the long bones, with which it has so much analogy in respect of its use. In one class of vertebrated animals, *viz.*, fishes, a precisely similar kind of fat is accumulated in large quantities in the cranium, always filling up the spaces left by the contained organs.

In *front*, the external surface of the dura mater adheres to the posterior common vertebral ligament by fibrous bands prolonged from it at intervals.

On each *side*, the spinal portion of the dura mater gives off fibrous sheaths (*l*, *fig.* 266; *b'*, *fig.* 267) for the roots of the spinal nerves (*n*), which sheaths accompany the nerves beyond the inter-vertebral foramina, and are lost in the cellular tissue.

The *internal surface* of this part of the dura mater is smooth and moist, in consequence of being covered by a serous layer, viz., the arachnoid (*a*). Down each side of this surface are seen the double orifices of the several fibrous canals, which transmit the anterior and posterior roots of the spinal nerves. It is very rarely found entirely free from adhesions to the arachnoid; and it is necessary to be careful not to confound these adhesions, which are always met with at isolated points, with such as are the result of morbid action.

The *inferior extremity* of the spinal portion of the dura mater is situated opposite the bottom of the lumbar region, and it therefore extends much lower than the spinal cord; this extremity is formed into a large ampulla around the cauda equina, which enlargement seems to be of use only as a reservoir for the cephalo-rachidian fluid.

Its *superior extremity* is firmly attached to the margin of the foramen magnum, and is continuous with the cranial portion of this membrane. In consequence of the firm adhesion of this membrane to the margin of the foramen magnum, and of its attachment to the sacrum by means of the sheaths for the sacral nerves, and to the sides of the vertebral column by those for the cervical, dorsal, and lumbar nerves, it is constantly maintained in a state of tension highly favourable to its use as a protecting covering of the spinal cord.

Vessels.—The vessels of the spinal dura mater are much less numerous than those of the cranial portion; for these belong exclusively to it, and not to the surrounding bones.

Its *arteries* arise from the spinal branches of the arteries of the cervical, dorsal lumbar, and sacral regions. Its *veins* terminate in the intra-spinal veins.

The *lymphatic vessels* observed appear rather to belong to the arachnoid.

The *nerves* of this membrane have not yet been demonstrated; but experiments upon living animals, especially upon dogs, have convinced me that the cranial, and probably, also, the spinal portion of the dura mater, although insensible to the knife, are extremely sensible to laceration.

The Arachnoid.

The cerebro-spinal axis is surrounded by a serous membrane named the *arachnoid*, which, like all membranes of this kind, forms a shut sac, adherent by its external surface, but free and smooth on its internal surface. We shall first describe the *cranial*, and then the *spinal portion* of the arachnoid.

The Cranial Portion of the Arachnoid.

Dissection.—The arachnoid may be shown upon the convex surface of the brain without any preparation, if the sub-arachnoid cellular tissue be infiltrated. It can also be very easily demonstrated by blowing air under it.

The *arachnoid* membrane, which, from its extreme tenuity, was for a long time confounded with the pia mater, was demonstrated by Ruysch upon the convex surface of the brain by injecting air beneath it; it was shown by Varolius upon the base of that organ, and its arrangement in that situation was figured by Casserius. It was described first by the Anatomical Society of Amsterdam as a special membrane covering the brain, under the name of the *arachnoid*; and Bichat, reasoning from analogy, demonstrated that it not only forms a covering for the brain, but is also reflected upon the dura mater, and lines it through its whole extent. He also believed that it was continuous with the lining membrane of the ventricles, an error which has been successfully refuted by M. Magendie.

Like all serous membranes, the arachnoid presents a *visceral* and a *parietal layer*

The Visceral Layer of the Arachnoid.

The *visceral layer of the cranial portion of the arachnoid* requires to be examined upon the convex surface and the base of the brain.

Upon the base of the brain, the arachnoid is separated from this organ in a great num-

ber of points, and more particularly as it is passing from one lobe to another. We shall examine in detail the arrangement of this part of the membrane.

In the median line, in *front*, it dips between the anterior lobes of the brain, but only at the fore part; behind, it connects these lobes by passing directly from one to the other; it covers the lower surface of the optic nerves and optic commissure, then the tuber cinereum and the infundibulum, for the latter of which it forms a sheath, and is then reflected above the pituitary body; from the tuber cinereum it passes across to the pons Varolii, leaving a hollow space between it and the brain, which is traversed by a few dense fibrous filaments.

I shall call this space the *anterior sub-arachnoid space*; it may be regarded as the principal reservoir of the serous fluid of the cranium.

In the median line, *behind*, the arachnoid lines the furrow between the posterior lobes of the brain, and is reflected from the corpus callosum upon the superior vermiform process of the cerebellum: at this point it meets with the venæ Galeni, and generally forms a circular fold around them, which was compared by Bichat to the foramen of Winslow in the peritoneum, and which he supposed to be the orifice of an *arachnoid canal*, which opened into the third ventricle beneath the velum interpositum.

The arachnoid covers the whole upper surface of the cerebellum; and, having reached the great circumference of that organ, it passes like a bridge from one hemisphere to the other, and from the cerebellum itself to the posterior surface of the spinal cord. In thus passing from one hemisphere of the cerebellum to the other, and from the cerebellum to the spinal cord, the arachnoid leaves a considerable space or reservoir for serosity, which may be called the *posterior sub-arachnoid space*.

Laterally, the arachnoid covers the inferior surface of the anterior lobes of the cerebrum and the olfactory nerves, which are thus held in contact with the anterior lobes; it then passes from the anterior to the posterior lobe, without entering the fissure of Sylvius, and from the posterior lobe to the tuber annulare and the cerebellum. It follows, therefore, that there are certain small sub-arachnoid spaces which communicate with the great anterior sub-arachnoid space of the brain; so that in the dead body there exists, between the arachnoid and the pia mater, at the base of the brain, a large space, the centre of which corresponds to the median excavation of the base of the cerebrum, and which is prolonged forward between the anterior lobes of the brain, laterally along each of the fissures of Sylvius, and backward, around the peduncles of the cerebellum. By this last-named prolongation a communication is established between the anterior and posterior sub-arachnoid spaces. All these spaces contain serum in the natural state, and coagulable lymph in some cases of inflammation of the sub-arachnoid cellular tissue.

The arachnoid is arranged in a uniform manner in reference to all the nerves situated at the base of the brain; it passes over their lower surface, and therefore holds them firmly against the under surface of the brain; but where these nerves are separated from the brain it furnishes a tubular prolongation around each, and again leaves them as they are about to enter the foramina in the base of the scull, and is reflected upon the dura mater.

Upon the upper surface of the brain, the arachnoid dips into the median fissure, and is reflected from one hemisphere to the other immediately below the free margin of the falx cerebri; and as this margin is nearer to the corpus callosum behind than in front, it follows that the anterior portions of the two hemispheres are in contact with each other for a certain distance, or, rather, they are merely separated by the pia mater.

The cerebral arachnoid adheres intimately to the arachnoid of the dura mater, along the sides of the superior longitudinal sinus, by means of the tubular prolongations which it forms around the cerebral veins that enter that sinus. This adhesion is also strengthened by the granular bodies called the glands of Pacchioni, which, as we have already stated, lie in the substance of the dura mater.

Moreover, on the convex surface, as well as upon the base of the brain, the arachnoid, in covering this organ, passes, like a bridge, from one convolution to another, never dipping into the intermediate sulci.

The cellular tissue, which unites the arachnoid to the pia mater, is of a serous nature and extremely delicate, so that the two membranes can be easily separated, excepting in cases of inflammation. When air is blown beneath the arachnoid, the extreme tenuity of this cellular tissue becomes evident: it is very frequently infiltrated with a serous fluid.

The sub-arachnoid cellular tissue never contains any fat. The fat which Ruysch, Haller, and other anatomists say they have observed, must have been that yellowish, gelatiniform lymph so commonly met with in cases of inflammation.*

In some parts the arachnoid is lined by a fibrous tissue, which gives it great strength. This fibrous tissue, which may be regarded as a prolongation of the neurilemma of the spinal cord, is especially distinct in the great furrows of the brain. Thus we find it

* I once found in an old woman an adipose cyst, about the size of a small grape, arising by a very thin pedicle from the upper surface of the pituitary body.

around the great anterior sub-arachnoid space, where it constitutes, as it were, a very strong fibrous band, which surrounds the arterial circle of Willis, situated at the base of the brain; it also retains the different parts of the brain in their relative positions, even when that organ is removed from the cranium, and is laid with its base uppermost.

The Parietal Layer of the Arachnoid.

The internal surface of the dura mater is lined with a very delicate and closely-adherent serous membrane, which, owing to these two qualities, for a long time escaped the notice of anatomists. It was only by reasoning analogically from the structure of all other serous membranes, that Bichat was led to enter upon the inquiry which ended in the discovery of the parietal portion of the arachnoid. This portion is quite distinct from the internal layer of the dura mater, the existence of which we have admitted with several anatomists. Upon a mere inspection, we should say that it does not exist, because, from its transparency, the fibrous bundles of the dura mater can be seen as distinctly as if they were not covered. But if a very superficial incision be made upon the inner surface of the dura mater, some extremely thin shreds may be detached by the aid of the forceps. Lastly, ecchymosis not unfrequently occurs between the dura mater and the arachnoid.* Ossific deposites in the dura mater, especially those found in the falx cerebri, being found beneath the arachnoid, sometimes enable us to detach this latter membrane in the most distinct manner.

It still remains, however, to describe the mode in which the parietal and cerebral portions of the arachnoid become continuous with each other. It has been stated that the arachnoid membrane forms tubular prolongations around each of the nerves which are given off from the base of the brain, and around each of the veins which enter the different sinuses; these prolongations just enter the fibrous canals formed by the dura mater for these nerves and veins, and almost immediately terminate by being reflected upon the dura mater itself; so that the arachnoid forms a sort of cul-de-sac around the cranial orifice of each fibrous sheath of the dura mater. In order to see the funnel-shaped prolongations of the arachnoid, it is convenient to examine them when the brain is being lifted up from before backward, in order to expose and divide the nerves which are attached to the base of the scull. The tubular prolongations being then dragged upon, they become very distinct. Not unfrequently, the development of adventitious false membrane on the base of the brain also extends along these prolongations.

The arachnoid does not enter into the interior of the ventricles, below the posterior border of the corpus callosum. The arachnoid canal, called the canal of Bichat, does not exist, but it is formed by the very experiment made to demonstrate it. The following is the statement of Bichat regarding this alleged canal:

"The brain being exposed from behind and allowed to remain in its natural position, the back part of each posterior lobe is to be raised, and drawn gently outward; the venæ Galeni are then seen emerging from the canal by which they are embraced, and the oval orifice of which is now very apparent. Sometimes, however, the margin of this orifice embraces the veins so closely, that it can only be recognised by a small fissure on each side, and the parts, at first sight, would appear to be continuous. If a probe be then glided from behind forward along these vessels, and when it has penetrated a short distance, *if it be turned all round the veins it will destroy the adhesions, and the opening will become very evident.*

"In order to be convinced that this opening leads into the middle ventricle of the brain, a grooved director must be introduced below the venæ Galeni and pushed gently forward: it will enter the ventricle without difficulty. The corpus callosum and the fornix are then to be removed, and the velum interpositum left untouched. Next, dividing the velum on the director, the membrane will be found to be smooth and polished in the whole of its course, and nowhere lacerated by the introduction of the director. *Occasionally some resistance is experienced to the entrance of the director, which may even be completely arrested: this depends upon the fact that the veins which enter the venæ Galeni interlace in all directions within the canal, so as to form a network, which arrests the instrument.* If this be the case, it should be withdrawn, and, in order to demonstrate the communication, some mercury should be poured into the external opening, and, by inclining the position of the head, this fluid will flow into the middle ventricle. Air blown into the canal will also enter that ventricle, and will pass from it into the lateral ventricles through the openings behind the anterior pillars of the fornix. If the fornix be removed, and the velum be exposed, the latter will be seen to be elevated each time that the air is blown in.

"The internal orifice of this communicating canal is at the lower part of the velum interpositum; in order to see it, this membrane must be reflected backward, either with the fornix, the under surface of which it covers, or after it has been separated from that part of the brain. The pineal gland which adheres to the velum is also to be turned

* As to the collections of blood which are said to have been met with between the arachnoid and the dura mater, M. Baillarget has clearly shown, in several preparations which he presented to the Anatomical Society, that the supposed laver of arachnoid is a newly-formed membrane, having all the appearances of a serous membrane.

back; below and in front of this gland is then seen a row of cerebral granulations, arranged in the form of a triangle, having its point turned forward. The internal orifice of the canal of the arachnoid is at the base of this triangle."

Now, if we make the dissection described by Bichat, it is easy to see that there exists at the back part of the brain, below the corpus callosum, a circular or oval opening, leading into a sort of cul-de-sac, which is of variable depth, and is formed by the reflection of the arachnoid around the venæ Galeni: it is seen, also, that the bottom of this cul-de-sac may be easily lacerated by a blunt probe, which may then be passed beneath the velum interpositum, as Bichat has pointed out; but it is through an artificial canal. Moreover, if a coloured liquid be injected into the ventricles, it can never be made to escape through this imagined canal of Bichat; and so, on the other hand, if a liquid be thrown into the orifice of this canal, it never enters the third ventricle: mercury enters only by lacerating the parts; and the same is the case with air. Analogy, which has so often conducted Bichat to beautiful and grand discoveries, has, therefore, misled him in this particular.

Since, then, the arachnoid canal of Bichat does not exist, it will be necessary to determine how the ventricles communicate with the external arachnoid cavity. This question we shall discuss presently.*

The Spinal Portion of the Arachnoid.

The spinal cord, besides its own proper investment, is covered by a transparent membrane of extreme tenuity, and only to be demonstrated properly by raising it with the forceps, or by subjecting it to the mode of preparation above described: this is the *visceral layer of the spinal portion of the arachnoid.*

The *visceral layer* (*b*, *fig.* 266, A B) forms a membranous sheath, which is much larger than the spinal cord (*s*); hence it is named the *loose arachnoid.* It is prolonged around the bundle of nerves called the *cauda equina*, and forms around each nerve a funnel-shaped sheath, which terminates in a cul-de-sac at the corresponding inter-vertebral foramen, by being reflected upon the inner surface of the fibrous sheath formed for the nerve by the dura mater (see *fig.* 266, B).

Fig. 266.

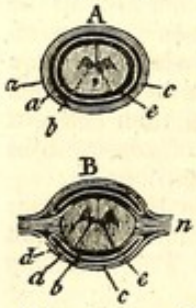

There exists, then, between the spinal cord and the visceral portion of the arachnoid a considerable space (*e*, *fig.* 266, A B), which can be best displayed by inflating it, or injecting it with some liquid. This space, as we shall immediately show, contains a serous fluid.

We have seen that, opposite the median excavation at the base of the brain, the arachnoid adheres to the cerebral pia mater only by means of long fibrous filaments. The spinal arachnoid also adheres to the proper covering of the cord by means of fibrous filaments; but in no part does there exist any delicate sub-arachnoid cellular tissue, like that found beneath the cerebral arachnoid.†

Another peculiarity in the visceral layer of the spinal portion of the arachnoid is this, that it adheres to the parietal layer in a number of points.

The *parietal layer* (*a*) of the spinal portion of the arachnoid is arranged precisely in the same manner as the parietal layer of arachnoid in the scull. It becomes continuous with the visceral layer opposite the sheaths which are formed by the latter around the spinal nerves.

The Sub-arachnoid Fluid.

There exists around the spinal cord a serous fluid, in quantity sufficient to occupy the interval left between the cord and the dura mater: this fluid is seated in the sub-arachnoid space (*e*). A similar fluid exists in the ventricles of the brain and in the sub-arachnoid cellular tissue, and fills the free spaces of the cranial cavity.†

The existence of the sub-arachnoid fluid was pointed out by Haller (*Elementa Physiologiæ*, t. iv., 87), and most explicitly and completely demonstrated by Cotugno (*De ischiade nervosâ commentarium*), but the fact was neglected by anatomists, and the fluid regarded by some as the result of cadaveric exudation, and by others as that of a morbid action. The existence of this fluid has been again confirmed by M. Magendie, who, moreover, has clearly proved that it is seated in the sub-arachnoid tissue.

In order to prove the existence of the sub-arachnoid fluid, or cephalo-rachidian fluid

* [The existence of the canal of Bichat is admitted by Arnold, a recent authority. Perhaps the opposite statements of anatomists concerning this canal may depend on the fact that the canal itself, though originally present, is sometimes closed subsequently, and at other times remains open.]

† [The spinal sub-arachnoid space is divided behind by a thin, and, in some parts, cribriform longitudinal septum, which extends from the loose arachnoid to the posterior median fissure of the cord. This space is probably lined throughout by a serous membrane, which contains the rachidian fluid, and which might be named the *internal arachnoid.* The septum just mentioned may be supposed to consist of two layers of this membrane reflected from the loose arachnoid to the cord, and having the same relation to it as the mesentery has to the intestine; and the membrane itself may be conceived to be prolonged through the foramen described by Magendie at the bottom of the fourth ventricle (see p. 718), so as to form the lining membrane of the fourth, third, and lateral ventricles; and, farther, in case of the existence of the foramen of Bichat, to become continuous with the external or true arachnoid through that foramen.]

of Magendie, it is necessary to open the lumbar region of the spinal canal in a certain number of subjects. If an incision be very carefully made through the dura mater, it will be seen that the serous fluid raises the visceral layer of the arachnoid, so as to make it protrude like a hernia through the incision: if this layer of arachnoid be then divided, the liquid will escape. Cotunni, who performed this experiment upon twenty subjects, collected from four to five ounces of fluid in each case.

To the objection that this fluid is found after death, but does not necessarily exist in the living subject, we may answer thus: There is a space between the spinal cord and the dura mater, and the brain itself does not exactly fill the cranial cavity. Now in no part of the animal body does there exist any vacuum; the spaces between the solids are always filled either with liquids or gaseous fluids. But if it be said that in this situation the space is filled by a serous vapour, the elasticity of which might establish an equilibrium with the external air, it may be replied, that this vapour would not be sufficient to produce so large a quantity of fluid as is found in the spinal canal.

Moreover, all these objections, and also the supposition that the brain and spinal cord may be smaller after death than during life, are overthrown by the following experiment. If the posterior cervical muscles be divided in a living dog, at their occipital attachments, the posterior occipito-atlantoid ligament will be exposed. The parts being well cleansed from blood, the ligament must be cut away, layer by layer, with a scalpel held flat against it. The ligaments will scarcely be cut through before a small hernial protrusion, containing a fluid, will be seen; this consists of the visceral arachnoid raised by the rush of fluid. If a crucial incision be then made in the occipito-atlantoid ligament, by the aid of a director,* a fluid as limpid as distilled water will be seen beneath the visceral layer of the arachnoid, which fluid is agitated by two kinds of motion, one of which is isochronous with the pulse, and the other with the respiratory movements. If the arachnoid be next punctured, the fluid will immediately escape in jets, and its quantity may be ascertained.

The difficulty of not wounding the visceral layer of the arachnoid explains why, until recently, it was thought that the spinal fluid was contained within the arachnoid cavity (*c*, *fig.* 266), *i. e.*, between the two layers of the arachnoid membrane, although most observers had noticed that the serous fluid in the cranium occupied the sub-arachnoid cellular tissue. It follows, therefore, that besides the fluid which is exhaled from the free surface, *i. e.*, into the cavity of the arachnoid, a certain quantity of a similar fluid fills up the areolar tissue of the sub-arachnoid space: in this respect the arachnoid differs essentially from other serous membranes, all of which pour their secretions into their cavities, and not into the subjacent cellular tissue.

This peculiarity depends simply upon the non-adhesion of the arachnoid to the spinal cord; it may be stated as a law, that serous membranes exhale almost indifferently from either their internal or their external surface, when the latter surface is not adherent. The arachnoid exhales a fluid from both surfaces; a certain quantity of fluid is rather frequently found between its two layers; and although, in acute inflammations, the deposite of purulent matter or of false membranes most generally takes place in the sub-arachnoid cellular tissue, yet these morbid products are not unfrequently found in the cavity of the spinal arachnoid itself.

The sub-arachnoid fluid exists not only in the vertebral canal, but also within the cranium, in which it fills up all the spaces between the brain and the dura mater.

Now these spaces are subject to much variety in size in different individuals, or from age or from disease: thus, in atrophy of the brain and spinal cord, from old age or disease, the interval between the dura mater and the cerebro-spinal axis is augmented, and the quantity of fluid increases in the same proportion.

The quantity of the sub-arachnoid fluid is in a direct ratio with the progress of age; in aged lunatics, in whom the convolutions of the brain are much atrophied, the quantity of this fluid contained within the cavity of the cranium is very great.†

The sub-arachnoid fluid in the cranium is not distributed equally around the brain, but is chiefly seated at its base. In order to show this fluid, it is merely necessary to raise up the brain carefully from before backward, when it will be seen distending all the funnel-shaped prolongations formed by the arachnoid around the nerves, and it will escape as soon as the membrane is divided.

As regards quantity, the sub-arachnoid fluid at the base of the brain and the fluid of the ventricles are always directly proportioned to each other, but are inversely proportioned to the sub-arachnoid fluid upon the convex surface of the brain. Upon opening the head of infants who have died from acute ventricular hydrocephalus, we sometimes

* It is highly important to make the transverse incision very short, in order to avoid injuring the very large vertebral veins; for if these vessels be cut, the hemorrhage will be so abundant as to prevent the continuation of the experiment.

† None of these facts escaped the notice of Cotugno:

"Nec tantum hæc aqua complens ab occipite ad usque imum os sacrum, tubum duræ matris . . . sed et in ipso redundat calcariæ cavo omniaque complet intervalla quæ inter cerebrum et duræ matris ambitum inveniuntur . . . . quantum autem magnitudinis cerebrum in his perdit, tantum a contactu subtrahitur duræ matris, et quidquid loci decrescendo reliquit, aquosus vapor collectus lotum adimplet."—(*Op. cit.*, p. 11, 12.)

find the convex surface of the brain dry, and, as it were, adhesive. It is of importance to determine whether the cavities containing the cephalic and the spinal fluids communicate with each other. There can be no doubt that the sub-arachnoid spaces of the brain communicate with the sub-arachnoid space around the spinal cord; but do the cavities of the ventricles communicate with the sub-arachnoid space?

Haller admitted that the fluid could flow from the ventricles into the spinal canal, and he believed that this was effected by a communication between the ventricles and the cavity of the arachnoid itself.* Cotugno expresses the same opinion still more distinctly. Both Haller and Cotugno† thought that this communication occurred at the bottom of the fourth ventricle, but they neither indicated the exact situation, nor the mode in which it is effected. M. Magendie has pointed out that it occurs at this very spot, near the point of the *calamus scriptorius*. Bichat stated that the communication between the ventricles and the arachnoid cavity was at the so-called canal of Bichat. The mode in which the fourth ventricle communicates with the sub-arachnoid space will be much better understood if stated in our description of that ventricle.‡

Uses of the Arachnoid and of the Sub-arachnoid Fluid.

Uses of the Arachnoid.—Like all serous membranes, the essential use of the arachnoid is to lubricate the surface of the brain and spinal cord, and thus facilitate their movements. No other membrane more completely fulfils such a use, for the arachnoid is moistened in both its external and internal surfaces. It would, in fact, be an error to suppose that the serous secretion is poured out solely by that surface of the arachnoid which is turned towards the pia mater: the fluid is exhaled upon its internal surface also, as in all other serous membranes, so that we sometimes find serum, pus, and false membranes in the cavity of the arachnoid itself.

Uses of the Sub-arachnoid Fluid.—The sub-arachnoid fluid forms a sort of bath around the spinal cord, which effectually protects it during the various motions of the vertebral column. It might be said that the spinal cord, being, in reference to its delicacy, in conditions somewhat analogous to those of the fœtus in utero, requires a similar method of protection; and in this point of view the sub-arachnoid fluid exactly represents the liquor of the amnios.

As to the other uses which have been attributed to it, they are all more or less hypothetical.

If we open the spinal canal of a dog, between the atlas and the occipital bone, some fluid will immediately gush out; air is drawn in, which is forced out in bubbles during expiration, and again enters during inspiration. If the animal be then left to himself, he will stagger like a drunken man; he will crouch into a corner, and remain in a drowsy state for some hours. On the next day he will walk about again perfectly well. I have repeated this operation several times upon the same dog, until at last he became accustomed to it, at least as far as regards the physiological effects resulting from the removal of the fluid, by which means the slight pressure usually exercised upon the spinal cord was removed.

The Pia Mater.

The *pia mater* is the innermost of the three membranes of the encephalon and spinal cord. It consists of an extremely delicate membrane, or, rather, of a vascular network, which immediately invests the nervous axis, and which may be regarded as the nutritious membrane of the parts that are covered by it. In fact, the arterial vessels divide into an infinite number of branches within this membrane before they enter the nervous substance, and so, also, the veins which pass out from the brain and spinal cord unite into small, and then into larger vessels, which form part of this same network. These vessels are supported by a very delicate serous cellular tissue: to this is added, in some regions, a certain amount of fibrous tissue, which converts the membrane into a very strong fibrous structure, having all the characters of the neurilemma, or proper investment of the nerves.

The characters of the spinal portion of the pia mater are so distinct from those of the cranial portion, that it will be better to postpone the description of the former until we are treating of the spinal cord, of which it constitutes the proper covering.

The Cranial Portion of the Pia Mater.

This portion, or the *cerebral pia mater*, does not merely enclose the brain like the arachnoid, but dips into the sulci or anfractuosities on its external surface, and penetrates into the interior of the ventricles. That portion of the pia mater which invests the brain is

* "Qua prodit de ventriculo aqua, facili in medullæ spinalis circumjectum spatium etiam parat; eam aquam enim difficulter omnino in tertium ventriculum et ad infundibulum redderet, quoad perpendiculum oportet ascendere (*Haller*, tom. iv., sect. 3, p. 77) . . . Non dubito quin collecta ex ventriculis cerebri aqua eo descendere possit."—(*Ibid.*, sect. 3, p. 87.)

† "His spinæ aquis eas etiam subinde commisceri, quas, sive a majoribus cerebri ventriculis per lacunar et Sylvii aqueductum, sive a propriis exhalantibus arteriis, cerebelli ventriculus accipiat; cujus positio perpendiculata et via ad spinæ cavum satis patens defluxum humoris in spinam manifesti persuadent."—(*Cotugno*, p. 18, 19.)

‡ See note, p. 960.

called the *external pia mater*, and that which is continued into the ventricles is denominated the *internal pia mater*.

The internal pia mater cannot be satisfactorily studied until the internal conformation of the brain is understood, and it will therefore be described together with the ventricles.

The External Cerebral Pia Mater.

Dissection.—At the base of the brain, the pia mater is naturally separated from the arachnoid by a considerable space, which is occupied by the sub-arachnoid fluid; but it is easy to separate these two membranes everywhere by introducing air or water between them. The arachnoid may be easily distinguished from the pia mater in cases of serous or purulent infiltration into the sub-arachnoid cellular tissue.

The *external pia mater* is subjacent to the arachnoid, and is connected with it by a very delicate serous cellular tissue; it not only covers the free surface of each convolution, but also dips into the adjacent sulci; it passes down on one side of a sulcus, and then, being reflected upon the other, is continued over the free surface of the next convolution, and so on. It follows, therefore, that this part of the pia mater is in contact with itself to a great extent; and also that its superficies is much larger than that of the arachnoid, so that if the brain could be unfolded, as Gall supposed, its surface would be entirely covered by the pia mater. These remarks apply equally to the pia mater of the cerebellum, for every one of the numerous laminæ of that organ is covered on each side by a fold of the pia mater.

The internal surface of the pia mater is in contact with the brain, and is united to it by innumerable vessels, which penetrate into the substance of that organ. This adhesion, however, is such, that the pia mater can generally be detached without injuring the surface of the brain.

I do not think, however, with some pathologists, that the adhesion of this membrane to such a degree that it cannot be removed without injuring the substance of the brain is any evidence of disease.*

For displaying the vessels which pass into the substance of the brain from the pia mater, an asphyxiated subject is very well adapted. But an injected condition of these vessels may be produced by allowing the head of the subject to hang down for some hours. The pia mater will then be not only black from its congested state, but it will be infiltrated with serum; and if it be detached slowly, an immense number of vascular filaments, looking like hairs, will be seen emerging from the substance of the brain, remarkable for their extreme tenuity and length, and for having no anastomoses. Some drops of blood will indicate the points upon the surface of the brain from which the vessels escape, and which, when examined through a lens, prove to be foramina.

The *use* of the pia mater is connected solely with the circulation of blood through the brain. This membrane affords to the vessels a very large surface, on which the arteries divide into their capillary branches, and the veins unite into their larger and larger trunks. According to my observations, five sixths of the vessels of the pia mater belong to the venous system.

The pia mater is the nutritious membrane of the brain, and may thus be regarded as its neurilemma.

It will afterward be seen that the internal pia mater is connected with the arteries and veins of the walls of the ventricles, just as the external pia mater is with the external vessels.

THE SPINAL CORD AND THE MEDULLA OBLONGATA.

General View of the Cord—its Limits and Situation—the Ligamentum Denticulatum.—Size of the Spinal Cord—Form, Directions, and Relations—the Cord in its proper Membrane—the proper Membrane, or Neurilemma of the Cord—the Cord deprived of its proper Membrane.—Internal Structure of the Cord—Sections—Examination by Means of Water—and when hardened in Alcohol—the Cavities or Ventricles of the Cord.—The Medulla Oblongata—Situation—External Conformation—Anterior Surface, the Anterior Pyramids, and the Olivary Bodies—the Posterior Surface—the Lateral Surfaces—the Internal Structure—Sections—Examination by Dissection, and under Water.—Development of the Spinal Cord.—Development of the Medulla Oblongata.—Comparative Anatomy of the Spinal Cord.—Comparative Anatomy of the Medulla Oblongata.

The *spinal cord* (*μυελὸς ῥάχιτης, medulla spinalis, a b c, fig.* 268) is that white, roundish, symmetrical, nervous trunk, which occupies the spinal canal; it is continuous with the encephalon, of which it has been alternately considered the origin and the termination. It is called the *medulla*, in consequence of a rude analogy between it and the marrow of the long bones, in regard to its situation and consistence. Chaussier has sub-

* In some cases the membranes are so dry that the pia mater cannot be removed without tearing the substance of the brain, even when that organ is perfectly healthy.

stituted for this term the title of *rachidian prolongation*, but the generally received name of spinal marrow, which can give rise to no error, might be retained.*

The Extent and Situation of the Spinal Cord.

Authors are not agreed as to the superior limit of the spinal cord. The natural limit is evidently at the groove, between the medulla oblongata (*a*, *fig.* 268) and the pons Varolii (*e*), which groove, on account of the great size of the pons in man, is much more distinctly marked in him than in those vertebrated animals in which the pons is also found.

The spinal cord is *situated* in the median line, at the back part of the trunk; it is behind the organs of digestion, circulation, and respiration.†

The vertebral column, the dura mater, the arachnoid, and the pia mater form a fourfold sheath for the spinal cord; the first being osseous; the second, fibrous; the third, serous; and the fourth, or proper sheath, both fibrous and vascular: this last-named membrane is accurately adapted to the cord, so as to support it, and gently compress it on all sides.

The spinal cord is not suspended freely in the vertebral canal, but is attached on each side by a ligament called the *ligamentum denticulatum*.

The Ligamentum Denticulatum.

The *ligamentum denticulatum* (*c c*, *fig.* 267), so called from the toothlike prolongations which proceed from its outer border, is an extremely slender, fibrous band, which runs along the side of the spinal cord, and adheres to the proper sheath of the cord by its inner border, which is very thin. The outer edge is free, thicker than the inner portion, and gives off certain toothlike prolongations, which are attached to the dura mater in the intervals between the canals formed by that membrane for the spinal nerves: the first denticulation of this ligament, which may be regarded as its origin, is very long, and is found opposite the margin of the foramen magnum, between the vertebral artery and the hypoglossal nerve; the last, which is the twentieth or twenty-first, forms the termination of the ligament, and corresponds very nearly to the lower extremity of the spinal cord. The form, thinness, and length of these toothlike processes are subject to much variety.

Fig. 267.

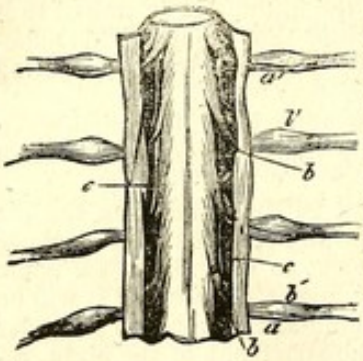

The ligamentum denticulatum is evidently fibrous, and cannot be regarded, as Bonn imagined, as a prolongation of the arachnoid.‡

The ligamentum denticulatum appears to answer the twofold use of assisting in fixing the spinal cord, and of separating the anterior (*a*) from the posterior (*b*) roots of the spinal nerves.

The Dimensions of the Spinal Cord.

The length of the spinal cord in the adult is from fifteen to eighteen inches. Its circumference is twelve lines at the thinnest part and eighteen at the thickest. But it is of much less importance to determine the actual dimensions of the spinal cord than to estimate its relative size as compared with that of the brain, or in reference to the capacity of the vertebral canal, or than to examine the differences in size which it presents at different parts of its extent.

If the size of the spinal cord be compared with that of the whole body, throughout the series of vertebrated animals, we shall perceive that it always bears a direct ratio to the vital activity of the animal. Thus considered, the spinal cord is small in fishes and reptiles, and large in birds and the mammalia.

Size and Weight of the Spinal Cord compared with the Size and Weight of the Brain.—It was while studying the spinal cord and the brain in serpents and fishes that Praxagoras, as quoted by Galen, originated the idea that the brain was a production of the spinal cord. All the old anatomists, on the other hand, who studied the brain and cord in man, in mammalia, and in birds, regarded the medulla spinalis as a prolongation or appendix of the brain (tanquam cerebri effusionem, *Rufus*); indeed, it was for a long time consid-

* The first description of the spinal cord which is worthy of notice was given by Huber (*J. Huber, De Medullâ Spinali*, Goettingæ, 1741); it served as the basis for the works of Haller (*Elem. Physiol.*, tom. iv., sect. 1); of Mayer, who published a beautiful plate of it in 1779; and perhaps of Alexander Monro, Secundus (*Observations on the Structure and Functions of the Nervous System*, 1783). Sœmmering, Reil, and Gall, who so successfully studied the other parts of the nervous system, have noticed the spinal cord in a superficial manner. Chaussier (*De l'Encephale en général et en particulier*); Keuffel, in his inaugural dissertation (*De Medullâ Spinali*, 1810, dedicated to Reil, his preceptor); and Rolando (*Richerche Anatomiche sulla Struttura del Midollo Spinale*, Torino, 1824), have supplied many of the deficiencies in our knowledge of this part. There is a good description of the medulla in M. Ollivier's work upon the diseases to which it is subject.

† The position of the nervous axis *behind* the alimentary canal constitutes one of the great differences which exist between the nervous system of the vertebrated and the invertebrated animals; in the latter, the nervous system lies below, *i. e.*, in *front* of the alimentary canal.

‡ It is idle to inquire whether it should be considered a prolongation of the dura mater, or an extension of the neurilemma, or a proper ligament.

ered that the medulla was the principal nerve in the body, *summus in corpore humano nervus*. In the present day, anatomists have returned to the opinion of Praxagoras, and the spinal marrow is generally regarded (Reil, Gall, Tiedemann) as the fundamental part of the nervous system, and that the brain is merely a production, an appendage, or an expansion of the cord. I shall not here enter into these purely speculative questions of production or emanation, origin, and relative importance, for the spinal cord no more produces the brain than the brain produces it.

Sœmmering has shown that, in man, the spinal cord is smaller in proportion to the size of the encephalon than in the lower animals; and of this there can be no doubt; but it does not follow that the lower animals have a larger spinal cord than man in proportion to the size of their bodies: on the contrary, from actual observation, I should say that, if we except birds, man has a relatively larger spinal cord than any other animal. Compare, indeed, the medulla of the horse, or of the ox, with that of man, and it will at once be found that the last is the largest and heaviest in proportion to the rest of the body.

According to Chaussier, the weight of the spinal cord in the adult is from the nineteenth to the twenty-fifth part of that of the brain, and in the newborn infant about the fortieth part. According to Meckel, this last is also the proportion in the adult. It must be remembered, however, that Meckel examined the cord when deprived of its proper membrane, and, therefore, after the roots of the nerves were detached from it.

Size of the Spinal Cord compared with the Capacity of the Spinal Canal.—The spinal cord does not, by a great deal, fill up the vertebral canal, and a considerable interval occupied by fluids exists between it and the sides of the canal. What is the object of this disproportion? and why is there any interval? We have already stated (see OSTEOLOGY) that the dimensions of the canal are in relation, not only with the size of the cord, but also with the extent of motion of the vertebral column. The opinion of Vieussens, that this space is intended to allow of certain movements of elevation and depression in the spinal cord analogous to those which have been observed in the brain, is sufficiently refuted by the fact that, although the latter organ is affected by movements synchronous with the respiration and with the pulse, it still fills the cavity of the cranium.*

The *length* of the spinal cord does not correspond with that of the vertebral canal, for the cord terminates near the first lumbar vertebra (between 20 and 21, *fig.* 268), while the canal is prolonged into the sacrum.

The position of the *lower end* of the spinal cord has not been determined with the precision which so important a question demands. According to Winslow, it terminates opposite the first lumbar vertebra; Morgagni has seen it reach down to the second; Keuffel has observed it to descend as low as the third lumbar vertebra in one subject, and to terminate opposite the eleventh dorsal vertebra in another. The discrepancy between various authors upon this subject depends upon individual varieties in the point of termination of the cord, and upon the different acceptation of the term lower extremity of the spinal cord; some regarding the thick swollen part as the end of the cord, while others include in it the tapering portion also. From some experiments which I made upon this subject by thrusting a scalpel horizontally from before backward through the inter-vertebral substance between the first and second lumbar vertebræ, I ascertained that there are varieties in different subjects in regard to the point of termination of the spinal cord, and that it was influenced by the position of the body, and by the state of flexion or extension of the head and spine, but that, in general, the widest part or base of the cone in which the cord ends corresponds to the first lumbar vertebra, and the apex of the cone to the second.

During the early periods of fœtal life, the cord descends as low as the sacrum; but in fœtuses at the full time, I have never found so marked a difference as has been described by some modern anatomists.†

Differences in the Size of the Spinal Cord at different Points of its Extent.—The spinal cord is not of uniform dimensions throughout its whole extent: it is much enlarged at

* From several experiments which I have made upon this subject, it appeared that the spinal fluid seen (confined in its membranes) in the cervical region, between the occipital bone and the axis, was agitated by movements synchronous with the pulse and the respiration; but that, when this fluid had been evacuated, the spinal cord did not move at all. I have examined with the greatest care the tumours existing in the lumbar region in infants afflicted with spina bifida; I could never detect in them any movement corresponding with the pulse, but the movement of respiration exerted a manifest influence upon them; thus, when the sac was emptied by compression, the cries of the infant, excited by pain, were almost instantly followed by extreme tension of the sac. As the spinal cord is not affected by the great arteries at the base of the brain, it cannot participate in the slightest degree in those movements which are observed in the spinal fluid at every pulse of the heart, and which are communicated to that fluid by the cerebral arteries.

† The spinal cord is capable of elongation and retraction; it is elongated during flexion, and returns to its original condition during extension of the vertebral column; the difference between the two states appears to me to be from an inch to fifteen lines.

In the body of an infant at the full time, which was affected with spina bifida in the sacral region, and died a short time after birth, the spinal marrow descended as low as the sacrum, and there was no cauda equina. Malacarne had already observed a similar fact; this peculiarity depends not upon an arrest of development in the cord, but upon adhesions contracted by it at an early period of fœtal life.—(See *Anat. Pathol.*, liv. xvii., art. SPINA BIFIDA.)

its upper part, opposite the basilar groove, where it constitutes the *superior* or *occipital rachidian bulb*, or the *medulla oblongata* (*a*); it becomes narrowed immediately after having emerged from the foramen magnum. This constriction, which is named the *neck of the rachidian bulb*, is regarded by many anatomists as the commencement of the spinal cord.

Another oblong enlargement, extending over a much greater length than the preceding, and named the *middle, cervical*, or *brachial rachidian bulb*, or *cervical enlargement* (*b*), commences opposite the third cervical, and terminates opposite the third dorsal vertebra.

The spinal cord again becomes considerably contracted from the first to the eleventh dorsal vertebra, and then presents a third enlargement of less extent than either of the other two, constituting the *inferior lumbar* or *crural rachidian bulb*, or *lumbar enlargement* (*c*); it then immediately tapers like a spindle, and terminates in an exceedingly slender semi-transparent cord, which has a fibrous, filiform aspect, is concealed among the nerves of the cauda equina (*d*), and is always accompanied by a vein. This cord may be distinguished from the surrounding nerves by its being situated in the median line, and by its thinness, its fibrous character, and its termination. It may be traced as far as the base of the sacrum, when it terminates in the dura mater.

In some cases the narrow portion of the inferior rachidian bulb is bifurcated, but the two branches of the bifurcation terminate in a single fibrous cord. Huber, Haller, and Sœmmering describe the spinal cord as terminating below by two small globular enlargements, of which the superior is oval, and the inferior conical. They have evidently mistaken an exception for the rule.

These three enlargements of the spinal cord constitute a totally different structure from that admitted by Gall, who, comparing with Haller the spinal cord of man, and the vertebrata generally, to the double series of ganglia in annelida and insects, maintained that there are as many enlargements of the cord as there are pairs of nerves. A strict examination into facts is completely at variance with this opinion, for even in the fœtus, the temporary conditions of which so frequently resemble the permanent state of the lower animals, we find no trace of this series of enlargements. An erroneous inference, together with the aspect of the cord when surrounded by its nerves, have misled this celebrated physiologist, who should have sought for the representatives of the ganglia of insects, not in the spinal cord itself, but in the series of ganglia on the spinal nerves.*

The existence of the three enlargements of the spinal cord above described is in accordance with two general laws relating to the nervous system, viz., 1. That the size of the spinal cord is in proportion to the size and number of the nerves which arise from and terminate in it, and to the functional activity of the organs to which those nerves are distributed; and, 2. That the exercise of sensibility is connected with larger nerves than that of muscular contractility.

Now the most numerous and the most important nervous communications take place opposite those three enlargements. The nerves of the lower extremities correspond with the inferior or lumbar enlargements; those of the upper extremities, with the middle one; and the nerves of respiration, the nerves of the tongue, and a part, or perhaps the whole of the nerves of the face, with the superior enlargement.

The cervical enlargement, which corresponds to the upper extremities, is certainly larger than the lumbar one, but this is because the upper extremities possess a greater degree of muscular activity than the lower, and also because they are the organs of touch.

This explanation is completely justified by comparative anatomy, and is applicable also to the differences in the length of the spinal cord: thus, it is found that in the different species of animals, the length of the spinal cord depends, not upon that of the vertebral canal, nor upon the presence or absence of a tail, but is proportionate to the muscular energy, and to the degree of sensibility. Desmoulins, a young anatomist, too soon lost to science, has established this fact by incontrovertible evidence.†

The Form, Direction, and Relations of the Spinal Cord.

The spinal cord has the form of a cylinder flattened in front and behind (D, *fig.* 269).

* These supposed enlargements are not to be found even in the spinal cord of the calf, which Gall took as offering the type of this structure. The committee of the institute likewise failed to discover them in the dog, the pig, the deer, the roe-buck, the ox, and the horse, in which Gall asserted that he had found them. The beautiful researches of Tiedemann into the development of the spinal cord have completely overthrown Gall's opinion, which rested merely upon unsubstantiated analogies.

[It may be remarked, that though Gall's anatomical statement is not correct, his view as to the analogy is more in accordance with received doctrines than that of the author.]

† The spinal cord of birds furnishes a striking proof of the law which presides over the development of this part of the nervous system. There are no movements performed by animals which require greater force and agility than those observed in the act of flying. It is therefore not astonishing to find that the spinal cord is enlarged opposite the nerves which go to the muscles of the wings. It would be supposed that the portion of the cord which corresponds to the lower extremities should be much smaller than that corresponding to the upper, but yet the inferior enlargement is equal to the one for the wings, because, according to a more ingenious than probable idea, the lower extremities are the organs of touch in birds.

The spinal cord of the tortoise most clearly confirms the law which we have adopted from Desmoulins. The sort of calcareous and horny case in which the trunk of that animal is enclosed is destitute of all power of motion or sensation; and it is found, the enlarged part of the spinal cord which corresponds to the upper extremities is united to that which corresponds to the lower by an extremely slender portion.

It exactly corresponds in *direction* with the vertebral column, every deviation of which it closely follows; and it is an interesting fact, that it escapes compression, even in angular curvatures of the spine.

The right and left halves of the spinal cord are perfectly symmetrical. There is less symmetry between the anterior and posterior halves, and still less between the upper and lower halves of the cord.

The spinal cord is divided by anatomists into a *body* and *extremities*. The body of the cord requires to be examined, both when covered by its proper sheath, and after the removal of that membrane.

The Body of the Spinal Cord enveloped in its Proper Membrane.

The surface of the cord everywhere presents certain transverse folds, united by others running obliquely, so as to form zigzag folds, which were compared by Huber to the rings of a silkworm, and regarded by Monro as so many small articulations; these folds are situated in the sheath of the cord, and are precisely analogous to those which have been noticed in the tendons during relaxation of the muscles, and those which we shall hereafter have to describe as appearing in relaxed nerves; they are effaced by extension of the spinal cord, and are reproduced when it resumes its original length.

The existence of these folds prevents that stretching of the cord which would otherwise occur in the different movements of the vertebral column. They endow the cord with a certain degree of elasticity.

The spinal marrow presents for consideration an anterior, posterior, and two lateral surfaces.

The *anterior surface* presents in the median line a *fibrous band*, which runs along the entire length of the medulla, and conceals the anterior median groove.

The *posterior surface*, at first sight, presents no trace of a median groove. Many anatomists, therefore, and especially Huber, have denied its existence; but with a little care we may detect a very delicate line which indicates the situation of the posterior median groove, to which we shall presently advert. On each side of the median line, both on the anterior and posterior surfaces of the cord, are seen the roots of the spinal nerves (1 to 31, *fig.* 268), which are arranged in four regular lines down the cord, and are divided on either side into the *anterior* (*a*, *fig.* 267) and the *posterior* (*b*) roots. The differences which we shall hereafter describe as existing between these two sets of roots, both in their number, size, and mode of attachment, enable us, at first sight, to distinguish between the anterior and posterior surfaces of the cord.

If these roots be detached, it will be seen that their place of insertion is marked by a series of depressed points, which together constitute two furrows both upon the front and back of the cord, accurately described by Chaussier under the name of the *collateral furrows* of the spinal cord. We cannot deny the existence of the posterior collateral furrows, but I do not think that the anterior collateral furrows should be admitted.

The *sides* of the spinal cord are rounded, and narrower than either the anterior or the posterior surface: there is no furrow upon these sides, as described by some authors. The two ligamenta denticulata are attached to them.

We must next examine the proper membrane of the cord, or the *rachidian pia mater*, which we shall name the *neurilemma* of the cord, from its analogy to the neurilemma of the nerves; we shall then describe the cord itself.

Neurilemma of the Spinal Cord, or Rachidian Pia Mater.

Dissection.—It is difficult to separate the rachidian pia mater from the cord, in the greater number of subjects, on account of the softness of the cord itself, and of the rapid changes which it undergoes after death. In order to succeed in doing so, it is advisable to select the body of a person who has died from an acute disease or from an accident. The spinal cord of new-born infants is more fitted for this purpose than that of adults, not only from its relatively greater density at that period of life, but also from its adhesion to the neurilemma being less firm.

In the bodies of infants, after making a circular incision through the neurilemma opposite the medulla oblongata, the sheath may be drawn downward, in the same manner as an eel is skinned, or a stocking drawn off by turning it inside out. When the sheath is more adherent to the cord, it must be very carefully divided along each side of the median furrows, and then detached by breaking down, with the handle of a scalpel, the cellular and vascular prolongations which connect it with the cord.

Although the proper covering of the brain, or *cerebral pia mater*, consists essentially of an interlacement of vessels, the proper sheath of the spinal cord, or *rachidian pia mater*, is a fibrous, and, therefore, a strong membrane, which supports and protects that part of the cerebro-spinal axis, as the neurilemma does the nerves.

The external surface of this membrane is surrounded with a network of remarkably tortuous bloodvessels; and vessels are also found in its substance. The spinal cord is visible through this semi-transparent membrane, which is naturally of a pearly-white

colour, but is sometimes dull, yellowish, blackish, or even covered with black spots, especially in the cervical region.*

This surface of the rachidian neurilemma is also rough, being covered with small cellular and fibrous filaments which float under water, and are the remains of small fibrous cords, which extended from the neurilemma to the arachnoid.

The *internal surface* of the neurilemma adheres to the spinal cord by a great number of cellular and vascular prolongations, which form areolæ or meshes in its interior, and which have been well described and figured by Keuffel.

Along the anterior median furrow, the neurilemma sends off a prolongation, which, entering that furrow, lines one of its walls, and is then reflected at its bottom, so as to line the other wall; within the substance of the duplicature thus formed, the bloodvessels penetrate. A simple prolongation of the neurilemma, of extreme tensity, also enters into the posterior median furrows, and forms a line of separation between the two posterior halves of the spinal cord.

The neurilemma is prolonged below the lower extremity of the spinal cord as a fibrous filament, very well described by Huber, which is inserted into the base of the coccyx.

This filament the older anatomists regarded as a nerve, and named it the *nervus impar;* it is very strong considering its thinness; it is always tense, and appears to be intended to fix the lower end of the spinal cord; in this respect serving a similar purpose with the ligamentum denticulatum. Its upper part is hollow, and is filled with a gray and extremely soft substance.

The ligamentum denticulatum, which has been considered as a prolongation of the proper membrane of the cord, is attached to the external surface of this membrane; and the proper neurilemma of each nervous filament is also given off from this surface.

Monro has stated that a soft layer of gray substance covers the white substance of the spinal cord, and separates it from its neurilemma, but such a layer does not exist.†

While the other membranes of the spinal cord are much larger than the part which they have to invest, the neurilemma of the cord is exactly moulded upon it, and even exerts a certain degree of pressure upon it, as is evident from the manner in which the substance of the cord protrudes when this covering is punctured; this compression occasions the apparent consistence of the cord when it is enveloped in its sheath; a condition which contrasts so strongly with its softness when that sheath has been removed.

This compression, as well as the absolute inextensibility of the neurilemma, accounts for the rarity of effusions in the cord, and also for the fatal effects of even the slightest effusions within its substance when they do occur.

Structure.—The proper membrane of the cord is essentially fibrous; nor has it any claim to be termed a vascular membrane (*tunica vasculosa*, Sœmmering). Its component fibres interlace in every direction, but the majority of them are longitudinal. It is quite evident that the vessels which ramify upon its surface, and afterward penetrate it, do not belong to the membrane itself.

Uses.—The neurilemma is essentially a protecting structure; it constitutes the framework of the spinal cord, and serves, at the same time, as a support for the nutritious vessels of that organ; in this latter respect it has been compared to the pia mater of the brain. The transition from the spinal into the cerebral portion of the pia mater takes place gradually. The fibrous character of this tunic diminishes upon the medulla oblongata and tuber annulare, and is entirely lost opposite the peduncles of the brain; while its vascular character, on the contrary, becomes gradually more and more marked as it passes from the cord towards the brain.

It has been stated that the neurilemma is the secreting organ of the spinal cord; one might as well say that the testicle is secreted by the tunica albuginea, and the heart by the pericardium.

The Body of the Spinal Cord deprived of its Neurilemma.

When the neurilemma of the cord is removed, the spinal nerves are also taken away. We shall hereafter have to inquire whether this fact should lead us to conclude that the nerves do not enter into the substance of the cord, but merely come into contact with it.

We would observe, however, in this place, that the posterior roots of the spinal nerves arise in a perfectly regular line, while the anterior roots come off irregularly from different points of the corresponding medullary column.‡

The Anterior Median Groove and the Commissure.—The *anterior median groove*, or fissure

* These different shades of colour are much more common in certain animals, in the sheep, for example, than in man; they result from the deposition of a colouring matter, and are in no way connected with any recent or previous morbid action.

† In several subjects, I have most distinctly seen a very thin yellowish layer over the medulla oblongata, which dipped between the pyramidal bodies, and filled up the shallow groove which separates the olivary from the pyramidal bodies.

‡ This mode of origin of the anterior roots is perfectly distinct in the spinal cord of the fœtus or new-born infant; up to this period, the tract from which the anterior roots arise is still formed of gray substance. The roots, which are white, emerge from this gray tract, and when the neurilemma is removed, their small, white, ruptured ends which remain may be traced into the substance of the cord.

(*fig.* 268; *f*, *fig.* 269, D), penetrates to about one third of the thickness of the cord. At the bottom of the groove, which is occupied by a prolongation of the neurilemma and a great number of vessels, is seen an extremely thin white layer, perforated with foramina, which is named the *anterior commissure* (commissure longitudinale, *Chaussier*). The foramina in this structure are intended for the transmission of tufts of vessels, which enter the substance of the cord. The alternate arrangement of these foramina greatly increases the difficulty of drawing out the vessels, and gives to the commissure the appearance of being formed by interlacing fibres; and, in fact, several anatomists have not only admitted such an interlacement, but have expressly stated that it was produced by the spinal nerves themselves.*

Fig. 268.

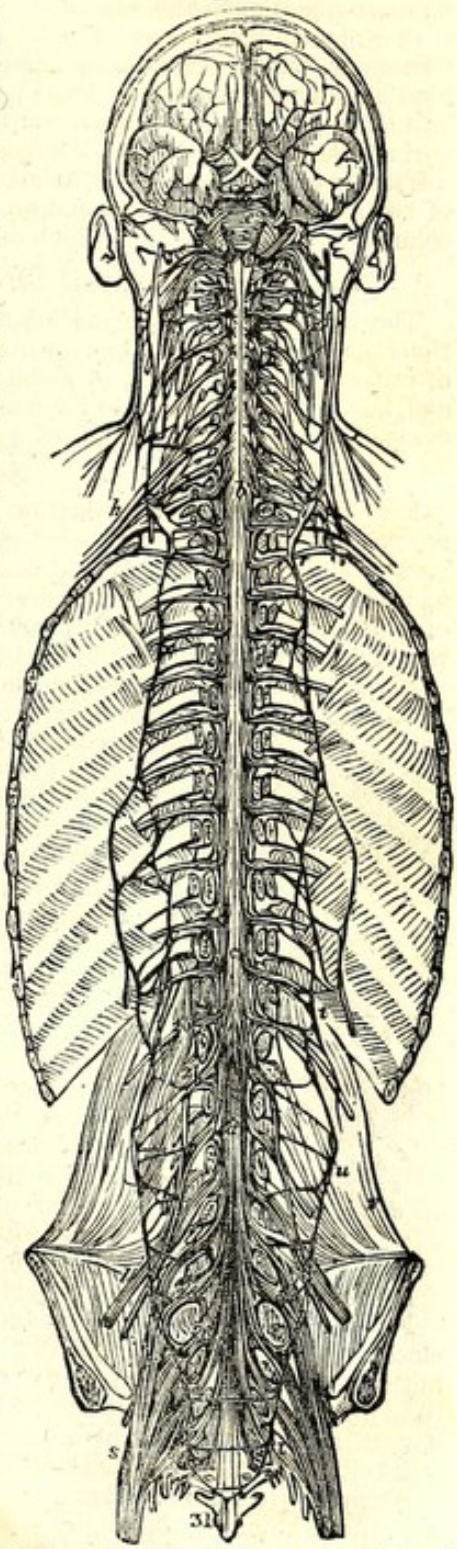

According to Gall and Spurzheim, the bundles of which this commissure consists are directed transversely, and are fitted into each other like the molar teeth; but I repeat, that the most careful examination demonstrates nothing in the commissure, besides a white lamella, perforated for the transmission of bloodvessels.

The Posterior Median Groove.—The posterior median groove or fissure (*a*) not only exists, but is much deeper than the anterior one. Its narrowness, and the tenuity of the membranous prolongation which enters it, have alone concealed it from the observation of anatomists; there is no white band analogous to that of the anterior median fissure at the bottom of this fissure, but the gray substance of the commissure is all that is seen.

As there are two median furrows, it follows that there are really two distinct spinal cords, connected together by an extremely thin band or commissure.

The Furrows opposite the Posterior Roots of the Nerves, or the Posterior Lateral Furrows.—Immediately to the outer side of the line of origin of the posterior roots of the spinal nerves, there is a grayish line or furrow (*i*), which extends the whole length of the cord. If a stream of water be allowed to fall upon this line, the continuity of the cord is soon destroyed, and the water penetrates to the centre of the organ.

But there are no true fissures in these situations analogous to the anterior and posterior median furrows. The separation is effected by the destruction of the gray substance, a prolongation of which reaches to the surface of the cord opposite these points. We shall, nevertheless, suppose these furrows to exist in accordance with the views of Sœmmering and Rolando, who divided each half of the spinal cord into two columns: a *posterior column*, consisting of that portion (*e*) which is comprised between the posterior median furrow (*a*) and the posterior roots (*i*); and an *antero-lateral* column, including all that portion (*d*) which is situated between the anterior median furrow (*f*) and the supposed posterior lateral furrow (*i*). We must also admit, with Haller, Chaussier, Gall, and Rolando, a third column on each side; these may be called the *posterior median* columns, and are continuous with the projecting bundles which form the borders of the calamus scriptorius, and which are each limited externally by a slight groove. These small and exceedingly narrow columns, the existence of which is admitted by most anatomists in the cervical region only, are prolonged through the whole extent of the spinal cord.

Is there an *anterior lateral furrow?* If the line on the outer side of the attachment of the anterior roots of the spinal nerves be closely examined, the appearance of a furrow is seen along the whole of the cord. But if water be allowed to fall upon that line, it is

* There is no physiological or pathological fact which demonstrates the crossing effect of lesions of the spinal cord.

found that there is no fissure or furrow properly so called, and that the jet of water has no more effect upon this line than on the adjoining parts; we are therefore led to reject, with Rolando, both these anterior lateral furrows and the *lateral* tracts described by Chaussier, which would be bounded in front by the furrow of the anterior roots, and behind by that of the posterior roots; these *lateral* tracts have, nevertheless, become celebrated, since so much importance has been attached to them by Sir C. Bell and Bellingeri as the *lateral columns* of the spinal cord.

From what has been stated above, it follows that each half of the cord is composed of two columns, a posterior and an antero-lateral, and as an appendage to the posterior column, of a small column, which forms the border of the posterior median furrows.

Internal Structure of the Spinal Cord.

The following results regarding the structure of the cord have been obtained by various modes of investigation: by making sections of it; by acting upon it with a stream of water; by hardening it in alcohol and dissecting it; by studying its development; and, lastly, by a reference to its comparative anatomy, which appears to be necessary to complete the knowledge acquired by the other means of investigation.

Sections of the Cord.

It appears, from an examination of the external structure of the spinal cord, that it consists of two white, juxtaposed cylinders; that the surfaces by which these cylinders correspond are flat, closely in contact, and united together by a median commissure; and that each of them may be divided into two columns, the one *posterior* and smaller, of which the posterior median column is only an appendage; the other, *antero-lateral*, which forms two thirds of the circumference of the cylinder.

Horizontal Sections.—If various horizontal sections be made through different parts of the spinal cord, we see that each half consists of a cylinder of white substance, containing gray substance in its interior (see *fig.* 269, D); that the median commissure is composed of a white layer (*white commissure*) and a gray layer (*gray commissure*); and that in each section the gray matter has a tolerably close resemblance in form to the letter *x*, the two halves or curves of which are joined in the middle by a horizontal line, while the extremities of the curves are directed towards the origins of the anterior and posterior roots of the nerves. The posterior extremities reach much nearer to the surface than the anterior. We perceive, also, in these different sections, that the circumference of the cord is not perfectly regular, but is somewhat sinuous, as we shall presently mention.

Fig. 269.

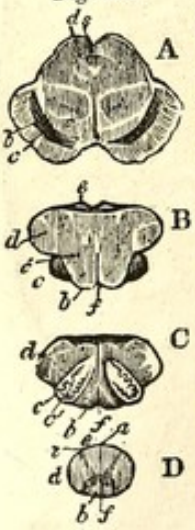

The size of the central gray mass in each half of the spinal cord, the length and thickness of the prolongations or points, which it sends off towards the anterior and posterior roots, and, lastly, the thickness of the gray commissure, present many varieties, according to the place of section;* and hence there is a discrepancy between different authors as to the appearances of this section. Thus, Huber compared the section of the gray matter to an os hyoides; Monro, to a cross; Keuffel, to four rays converging towards a central point.

Rolando has given figures of sections of the cord at every part of its length.

From sections of the cord the general fact is established, that the white substance encloses the gray matter. The thin layer of gray matter on the surface of the cord admitted by Monro has been justly rejected by all anatomists. The relative situation of the two substances in the cord, which is the reverse of what is observed in the brain, has attracted the attention of anatomists, and various explanations, of greater or less ingenuity, but all hypothetical, have been given of this fact.

According to Rolando, there are two kinds of gray matter in the cord, one occupying the anterior, and the other the posterior half of the cylinder; and these two halves are fitted into each other by a series of indentations, like the bones of the cranium.

I have never been able to convince myself of the existence of these two kinds of gray matter, but I have distinctly observed the denticulated appearance of the circumference of the gray matter, which indicates that the gray and white matter mutually penetrate into each other.

The colour of the gray substance varies considerably. In some subjects it is whitish, and can only be distinguished from the white matter by its softness, its vascularity, and its not having a fibrous structure. The younger the individual, the more marked is the difference in colour between the two substances.

The two substances appear also to differ in their relative proportions in different individuals. Keuffel has ascertained that the gray matter is more abundant in man than

* I would recommend five sections of the cord, which appear to me to give a very accurate notion of its internal structure: the first should be immediately below the decussation of the pyramids; the second through the middle of the brachial enlargement; the third through the dorsal constricted part; the fourth through the middle of the lumbar enlargement; and the fifth near the apex of the cone formed by the lumbar enlargement.

in the lower animals; and this fact would account for the pre-eminent sensibility of the human subject, in accordance with the view of Bellingeri, who considers that the gray matter is the seat of sensation.

These horizontal sections enable us not only to determine the relative position and proportions of the white and gray substances, but also to distinguish the superficial furrows from those which really enter into the cord; the existence of these columns in the spinal cord, which have already been described, is in this way fully established.

Vertical Sections.—The most important of these is one made from before backward in the median line, so as to separate the two halves of the cord. Each of these halves may then be unfolded like a riband, on the inner surface of which the gray matter forms a thin layer.

A transverse vertical section, through the centre of the cord, displays the mode of origin of the anterior and posterior roots of the nerves.

Examination of the Spinal Cord under a Stream of Water.

The different sections above mentioned expose the general internal arrangements of the cord rather than its actual structure.

Until lately, authors had regarded the spinal cord as consisting of a semi-fluid pulp, which oozed out when the neurilemma was divided. Several had said, incidentally, and without distinguishing between the white and the gray substance, that the cord had a fibrous structure, and that its fibres were directed longitudinally. Gall supposed the cord to consist of a series of ganglia, arranged one upon the other; but it is now generally admitted that the white matter is fibrous, and that its fibres have a linear arrangement; and this is clearly shown by examining this organ by means of a stream of water, the force and size of which may be varied at will.

When directed upon the surface of a vertical section, made from before backward down the middle line, the stream of water penetrates the substance of the cord through the gray commissure, breaks down the central gray matter, and spreads the cord out like a riband, from which it is very difficult to wash off all the gray matter. When treated in this way, each half of the cord is almost immediately subdivided into two columns, and if the stream of water be now directed upon the internal surface of the columns themselves, they may be separated into a great number of wedge-shaped vertical lamellæ, directed from the circumference to the centre, the thick external backs of which are turned towards the surface, and the thin internal edges towards the centre of the cord. Now, as all these lamellæ are not of equal depth from back to edge, their internal edges reach to different distances from the centre; hence the denticulated appearance of the circumference of the gray matter in a section; and hence, also, the mistake of Rolando, in describing the white matter as formed by a medullary layer, folded a very great many times upon itself.*

According to my observations, each lamella is completely independent of the adjacent ones; and pathological anatomy fully confirms this observation, by showing that one only may be altered or atrophied, while the others remain unaffected.

If the action of the stream of water be continued, these medullary lamellæ are decomposed into very delicate juxtaposed filaments, which extend along the entire length of the cord; they are all independent of each other, and are merely connected by cellular tissue and some vessels.

The structure of the spinal cord is therefore filamentous or fasciculated; its filaments are almost perfectly identical with those which constitute the proper substance of the nerves. Each filament in the cord traverses its entire length, as each nervous filament extends along the whole nerve.

The very important inference to be drawn from these facts is the independence, not only of each lamella, but, I may venture to say, of each filament.†

* Rolando has even counted these folds: he numbers fifty in the spinal cord of the ox, opposite the origin of the sixth pair of sacral nerves, and about thirty opposite the third pair of sacral nerves; both of these observations refer to the anterior columns only, for in the two figures which he gives of them the posterior columns appear to have no folds. Rolando made his observations upon spinal cords which had been macerated either in pure water or in salt and water.

† [The microscopic structure of the white and gray substances of the brain and spinal cord has been investigated by Fontana, Ehrenberg, Weber, Remak, Valentin, and others. The fibres of the white matter consist of coherent threads of a soft, semi-transparent, tenacious substance, enclosed in an extremely delicate homogeneous or structureless sheath, which is very difficult of detection: these fibres are smaller than those of the nerves; they differ much in size, but each of them is of uniform diameter throughout; when submitted to the slightest pressure during examination, they have a remarkable tendency to become varicose or beaded, a property which is peculiar to them and to the fibres of the olfactory, optic, and auditory nerves, which also resemble the fibres of the brain in other respects.

The gray matter of the brain and spinal cord consists of large reddish gray globules, containing a nucleus and one or more nucleoli, and having spots of pigment upon them, in situations where the gray matter is darker than usual. Surrounding and attached to these globules there are minute jointed fibres, which are marked at intervals with granules (nuclei); by Ehrenberg these jointed fibres were considered to be of the same nature as the fibres of the white matter, differing from them only in size; by Müller and Schwann they are regarded as organic nervous fibres, resembling those found in such abundance in the sympathetic nerves and ganglia; while by Valentin and others they are supposed, not only in the brain, but also in the ganglia and nerves, to be the filaments of a delicate cellular tissue.

The mode in which the white fibres of the brain and spinal cord end in the gray substance is not well made

Examination of the Spinal Cord hardened in Alcohol.

When deprived of its humidity by alcohol, the spinal marrow becomes very firm, extensible, and elastic. Its filamentous texture becomes very apparent, and the filaments themselves, which, from the contraction of the cord, are flexuous, may be separated from each other, either by the handle of the scalpel, or by slight traction. I have not seen that interlacement of the fibres of the cord which is figured in the beautiful plates of Herbert Mayo, and which, in my opinion, is only apparent, and is produced by drawing the parts under examination in different directions.

The Cavities or Ventricles of the Spinal Cord.

Several anatomists are of opinion that there is a canal in each half of the spinal cord.*

Morgagni has slightly alluded to its existence, which he had not leisure to trace for a greater extent than about five fingers' breadth.†

Gall relates that, in examining the body of an infant affected with spina bifida, he cut transversely through the cord, and found that it contained two canals, which he traced into the substance of the medulla oblongata and tuber annulare, beneath the tubercula quadrigemina, and as far as the optic thalami, where they terminated in a pouch as large as an almond.‡

It is certain that, up to the fourth month of fœtal life, each half of the spinal cord contains a canal precisely similar to that which exists in fishes; but after this time the gray matter takes the place of the gelatiniform fluid which had occupied the canal. However, in one case I found the canal persisting after birth.

The Medulla Oblongata.

Situation.—The *medulla oblongata*, the *rachidian* bulb, or *cranial enlargement*, is that conoid enlargement (*a*, *fig.* 268) which forms the upper part of the spinal cord, crowning it like the capital of a column: it is situated upon the basilar groove of the occipital bone, and connects the spinal cord with the cerebrum and cerebellum. It was named *medulla oblongata* by Haller; but it has also been called the *cauda* or *tail* of the medulla oblongata, this term being derived from a comparison of the pons Varolii, the four peduncles, and the medulla oblongata to an animal, the body of which was represented by the tuber, the arms by the anterior peduncles, the legs by the posterior peduncles, and the tail by the rachidian bulb.

External Conformation of the Medulla Oblongata.

The medulla oblongata is received into the deep groove on the fore part of the circumference of the cerebellum (see *fig.* 276), so that its anterior part only is exposed.

In man and the mammalia the medulla oblongata is *bounded* above and in front by the tuber annulare or pons Varolii (*a*, *fig.* 270); but above and behind its limits are quite artificial, for it is prolonged upward beyond the pons, as we shall presently see. Its limits below are altogether arbitrary: the medulla oblongata, in fact, does not contract abruptly, as the term *neck of the bulb*, applied to its lower extremity, would seem to imply, but it is very gradually narrowed, so as to become continuous with the spinal cord.

A plane, which is a tangent of the lower surface of the condyles of the occipital bone, would correspond with the lower boundary of the medulla oblongata.◊ I think, however, that it is more rational to fix this boundary according to the precise point where the medulla undergoes some decided modifications; and this point is immediately below the decussation of the pyramids.

The medulla oblongata is from fourteen to fifteen lines in length, nine lines in

out; according to Valentin, they separate to admit the gray globules between them, and then unite with one another so as to form loops.

The substance of the brain and spinal cord, according to Vauquelin, contains 80 per cent. of water; its solid constituents consist of albumen, stearine and elaine, phosphorus (1·5 per cent.), osmazome, some acids and salts, and sulphur.]

* It is unnecessary to say, that the existence of the single central canal admitted by some authors, is quite irreconcilable with the real structure of the cord.

† *Adversaria Anat.*, vol. i., p. 17. Morgagni relates that, having separated the medulla oblongata from the rest of the spinal cord by a horizontal section, he saw in the substance of the cord, and for the space of about five fingers' breadth (*et fortasse etiam longius si quis tunc otium habuisset ulteriorum medullam e vertebris eximendi*), a cavity which admitted the end of the finger; everything appeared to be in a natural state, excepting this cavity. He adds, that he had never met with so large a cavity; which seems to imply that he had seen cavities of this kind before.—*Neque enim alias tantam aut quæ huic accederet vidi.*

‡ Spina bifida and hydrocephalus have no direct relation with the persistence of the canals of the spinal cord; and on this point, I can remove all the doubts expressed by Keuffel (*De Medullâ Spinali*, 62) concerning Morgagni's observation. "Forsan nos quoque," says Keuffel, "eam (scilicet medullæ spinalis cavcam) invenissemus, si medullam spinalem ex homine hydrocephalico aut spinâ bifidâ laborante, inquirere potuissemus. Utinam hujusmodi opportunitas, si occurreret, a nemine negligatur, ut tandem de hâc re certiores fiamus." In five infants affected with spina bifida, and two who died of chronic hydrocephalus, which I examined for this purpose, the spinal marrow was perfectly normal. Tiedemann regards the canals described by Gall as produced by insufflation.

◊ I have made experiments upon several subjects, which show that the relations of the medulla oblongata to the foramen magnum vary according as the head is directly vertical, flexed, or extended; an instrument thrust horizontally between the atlas and occipital bone divides the medulla oblongata at different parts in these various positions of the head.

breadth, and six in thickness; it is therefore much broader and thicker than the spinal cord.

The medulla oblongata is directed obliquely, like the inclined plane of the basilar groove, so that it forms with the spinal cord a very obtuse angle, which projects backward.

In shape it resembles a cone flattened in front and behind, and having its base turned upward and its apex downward; it has, therefore, four surfaces, viz., an anterior, a posterior, and two lateral.

Anterior Surface of the Medulla Oblongata.

This surface (*fig.* 270) is directed downward, and is therefore named inferior by some anatomists; it is convex, and is lodged in the basilar groove of the occipital bone; it can be properly examined only after its neurilemma has been dissected off, which is easily done, because its substance is denser than the spinal cord.

Fig. 270.

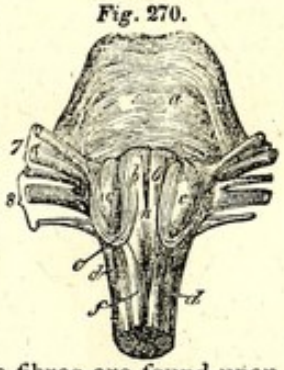

On this surface we observe a *median furrow* (*f*), into which numerous vessels enter: this furrow, which is not nearly so deep as the anterior median furrow of the spinal cord, with which it is continuous, is interrupted by a decussation of fibres about ten lines below the pons Varolii (below *n*), and terminates above in a tolerably deep fossa (*le trou borgne*, or *foramen cæcum*, of Vicq d'Azyr), at the point where the furrow meets the pons. Not unfrequently some transverse fibres occupy the place of this median furrow, in which case the anterior surface of the medulla oblongata resembles the pons Varolii; sometimes these transverse fibres are found upon only a part of the medulla oblongata.

On each side of this median furrow are seen two eminences, which seem as if moulded in relief upon the part, and which form two planes, succeeding one another like steps from within outward. The two internal eminences are called the *anterior pyramids*; the two external are named, from their shape, the *olivary bodies*.

The Anterior Pyramids.

The *anterior pyramids* (*Vieussens*, *b b*), situated on each side of the median line, and to the inner side of the olivary bodies, are two white pyramidal bundles (bandes médullaires, *Malacarne*), which extend through the entire length of the medulla oblongata; they project in relief upon the body of the medulla, and seem to emerge or originate near its narrow portion or neck, where they separate from each other the anterior columns of the spinal cord, from which columns they are quite distinct: at their point of emergence they are closely approximated and narrow, being about a line and a half in width; they pass somewhat obliquely upward and outward, become more prominent, and about three lines wide; having reached the pons Varolii, they become rounded and cylindrical, and are constricted before they enter the substance of the pons, in which we shall afterward trace them.

When the two pyramids are gently held apart, it is said that some transverse fibres are seen passing from one to the other, along the bottom of the median furrow; and it is even stated that there is a decussation of their fibres: this, however, is only apparent, and I cannot here too particularly caution the student against those illusive appearances, which depend either upon the existence of foramina for the passage of vessels, or may be produced by pulling about the scattered fibres in drawing the parts asunder. It will soon be shown that there are no transverse fibres here, and that there is no decussation of fibres at an acute angle along the whole length of the anterior pyramids, as was admitted by Petit, Winslow, Santorini, and others.

The two halves of the medulla oblongata are, in fact, merely applied to each other, and agglutinated together. There is no decussation excepting at the point where the pyramids emerge.

The Olivary Bodies.

Upon the anterior surface of the medulla oblongata, to the outer side of the anterior pyramids, and upon a plane somewhat posterior to them, are found two white ovoid bodies (corpora ovata), sometimes projecting in relief; these are peculiar to the human subject, and are more prominent in the fœtus and new-born infant than in the adult. They were first described by Eustachius, and afterward more accurately by Vieussens, who, on account of their shape, gave them the name of *olivary bodies* (*corpora olivaria*, *c c*); they are much shorter than the anterior pyramids, being not more than six lines in length; they are directed obliquely downward and inward. The upper extremity of the olivary body does not reach the pons Varolii, but is separated from it by a deep furrow; the lower extremity, which is less prominent than the upper, is bound down by a bundle of arched fibres, the concave borders of which are directed upward (*processus arciformes*, *e*). The outer border of the anterior pyramids and the series of nervous filaments which unite to form the hypoglossal nerve (9, *fig.* 276) constitute the internal boundary of each

olivary body; and a deep furrow, directed vertically, separates them on the outer side from the inferior peduncles of the cerebellum or the restiform bodies.*

It is of importance to observe, that that portion of the olivary body which projects on the outer side of the pyramid is only the external half of the olivary body, its internal half being imbedded in the substance of the medulla oblongata, so as to reach behind the anterior pyramid.†

The Posterior Surface of the Medulla Oblongata.

This surface is partly concealed by the cerebellum, being received into a groove on its under surface, and cannot be completely exposed unless the medulla oblongata be forcibly bent forward, or the middle part of the cerebellum be divided vertically. It is then seen that the cord appears to open out (*t*, *fig.* 271) opposite the upper part of this surface, and to be turned inside out, so that the gray substance is exposed. In consequence of this separation of the posterior columns of the cord, there is left between them a shallow, triangular, or V-shaped depression (*p*), the bottom of which is smooth, and forms the anterior wall of the fourth ventricle; Herophilus named this depression, from its appearance, the *calamus scriptorius*.

Fig. 271.

A vertical median groove corresponds to the shaft of the quill; while its barbs are represented by certain white medullary lines, which vary exceedingly in number, and are not symmetrical; some of these lines are lost upon the walls of the ventricle, and others turn round the lateral surface of the medulla oblongata, and constitute, in part, the origin of the auditory nerves. The point of the pen is represented by the very acute inferior angle formed by the sides of the depression, which terminates below in a cul-de-sac, the *fossette of the fourth ventricle*, also called the *ventricle of Arantius*. According to some authors, at the point of the calamus is situated the upper orifice of a canal, which runs through the whole length of the spinal cord; such a canal, however, does not exist, but is, in fact, produced by the means employed to demonstrate it, for example, by insufflation, by the introduction of a probe, or by the weight of a column of mercury. A slight V-shaped deposite of corneous matter is constantly found inserted within the correspondingly-shaped bifurcation of the columns of the cord: between the branches of the V is found the prolongation of gray substance, which is continuous with the gray matter of the cord.

The medullary columns which immediately bound the calamus on each side, and which result from the separation of the elements of the cord, are formed by the posterior median columns (*e*, *fig.* 269, B C, and *fig.* 271), already described, which become slightly enlarged where they separate from each other, so as to form a mammillary projection, and then terminate insensibly upon the back of the restiform bodies: we shall call the upper part of these columns the *mammillary enlargements of the posterior median columns*, and not "*posterior pyramids.*"‡

On the outer side of these mammillary enlargements are found the *restiform bodies* (*d*, *fig.* 269, C; *fig.* 271), which, as we shall afterward describe, pass to the cerebellum, and may be said to form its root; they are also called the *inferior peduncles of the cerebellum*, or *processus à cerebello ad medullam oblongatam*. Ridley named them the *restiform bodies*, or cord-like processes; and others, again, call them the *posterior pyramids*.

The Lateral Surface of the Medulla Oblongata.

Fig. 272.

These present (*fig.* 272), in front, the olivary bodies (*c*), which we have already seen upon the anterior surface. Behind them are the restiform bodies (*d*); and, lastly, about three lines below the lower extremity of each olivary body, is found an oblong projection, the colour of which is intermediate between that of the white and that of the gray substance: this projection is continuous with the gray matter of the furrow, from which the posterior roots of the spinal nerves arise; and Rolando, who first directed attention to it, has named it the *ash-coloured tubercle* (tuberculo cinereo).

The arched fibres, or *processus arciformes* (*e*, *fig.* 270), pointed out by Santorini, and still better described by Rolando, are principally found upon the lateral surfaces of the medulla oblongata; they consist of filaments of medullary substance, which vary exceedingly in

* I do not say, with some authors, that the filaments of origin of the glosso-pharyngeal and pneumogastric nerves (8, *fig.* 270) bound the olivary bodies behind, for these filaments arise from the inferior peduncles of the cerebellum, or the restiform bodies, not from the furrow between those peduncles and the olivary bodies.

† In the body of a female who died at the Maternité, the left pyramidal and olivary bodies were not more than half their usual width. It might have been supposed that they were atrophied; but the patient had exhibited no symptom indicative of so serious and uncommon a lesion. With a little attention, I could easily see that the pyramid was divided into two portions, the anterior of which occupied the usual position, while the posterior covered the posterior half of the olivary body.

‡ [The term posterior pyramids is, nevertheless, applied to these bodies by many modern anatomists.]

number and arrangement; they appear to arise from the anterior median furrow of the medulla oblongata, to turn like a girdle around the pyramidal and olivary bodies, and, having reached the restiform bodies, to pass obliquely upward and outward to terminate upon the sides of the restiform bodies. These arched fibres sometimes seem to be entirely wanting; at other times they are collected on each side into two bundles: one superior, which turns round the anterior pyramid, as that body is about to enter the pons; the other inferior, which covers and circumscribes the lower extremity of the olivary body. Lastly, the pyramidal and olivary bodies are not unfrequently found to be completely and regularly covered by a thin layer of circular fibres: it will be presently shown that these fibres dip into the anterior median furrow of the medulla oblongata, and reach as far as the posterior median furrow.*

Internal Structure of the Medulla Oblongata.

The internal structure of the medulla oblongata should be examined by means of sections, by the ordinary method of dissection, by separating its elements by means of a jet of water, and by dissecting it after it has been hardened in alcohol or boiled in oil.

Sections.

Horizontal Sections.—Following the example of Rolando, we shall examine four sections of the medulla oblongata.

The first should be made immediately below the decussation of the pyramids; the second, opposite the middle of the decussation; the third, through the middle of the olivary bodies; and the fourth, immediately below the pons.

The *first section* presents exactly the same appearances as a section of the spinal cord.

The *second* presents a very different arrangement: the decussating bundles of the pyramids are of very considerable size, and occupy the anterior two thirds of the substance of the medulla: their section represents a triangle having its base turned forward, and its truncated apex backward. The gray matter is not circumscribed, as in the first section, but appears to penetrate irregularly into the white substance of which the remaining part of the medulla consists. The white substance itself has not the pure whiteness of medullary substance; nor does the gray matter resemble that of the rest of the spinal cord, but it is of a *yellowish-gray* colour, and is much denser.

The *third section* through the middle of the olivary bodies (*fig.* 269, C) presents, besides the triangular section of the pyramidal bodies (*b*), the serrated section of the *corpus dentatum* (*c'*) of the olivary bodies (*c*); it enables us to form an accurate idea of the shape and size of these bodies, which extend to each side of the median line; it shows that they are directed obliquely inward and backward, and that they consist of successive layers, viz., of an external white layer, of an interrupted yellowish layer, and of a second white layer, which lines the inner surface of the yellowish one. It is seen that the corpora dentata of the olivary bodies are interrupted, or, rather, open on the inner side towards the median line, so as to admit the white fibres with which their interior is filled. The waving gray line seen on these sections depends upon the yellow layer being frequently folded inward and outward upon itself; and from this appearance the terms *corpus dentatum*, or *corps festonné*, have been applied to the gray substance of the olivary bodies. The remaining part (*d*) of the medulla oblongata consists of a substance which is of the colour of coffee mixed with milk, and which offers more resistance to the knife than other parts of the medulla, and consists neither wholly of white matter nor wholly of gray, but of a mixture of both.

The *fourth section*, made immediately below the pons (*fig.* 269, B), presents a triangular surface, on which we remark, at each of the posterior angles, a thick white bundle, almost as large as the posterior pyramidal body, and which will be hereafter shown to constitute one of the roots of the fifth nerve: these bundles are also seen upon the third section made through the olivary bodies, but they are much smaller than in this section. The section of the two anterior pyramids (*b*) is circular at this point. The centre of this section of the medulla consists entirely of a grayish-white or coffee-coloured substance (*d c'*), covered by a white layer. The grayish-white substance belongs specially to the medulla oblongata; the surrounding white layer is the continuation of the columns of the spinal cord.†

The oblique sections display appearances corresponding with those of the horizontal section.

Vertical Section.—A very interesting section of the medulla oblongata is a vertical one, extending from before backward through the median line. I prefer the plan of forcibly separating the two halves of the medulla to that of dividing it with a scalpel. By this means it may be shown that there are in the median line of the medulla some an-

* Ought we to regard as a part of this system of arched fibres a small, slender cord which surrounds the upper part of the anterior pyramids, and which in other respects has a similar arrangement to the arched fibres generally?

† The medulla oblongata of a child seven or eight years old is much better adapted for the examination of these sections than that of an adult or old subject, because the two substances are blended in the latter; a stream of water directed upon the sections will greatly assist the examination, by making the colours more distinct.

tero-posterior fibres, which appear to me to vary in number in different subjects: these fibres (*o*, *fig.* 274) run from behind forward through the whole antero-posterior diameter of the medulla; having reached the anterior median furrow, they pass horizontally outward to cover the pyramids and olivary bodies, and form the arched fibres already described. These antero-posterior fibres are limited below by the decussating fibres of the pyramids.

Examination of the Medulla Oblongata by Dissection under a Jet of Water, and when hardened in Alcohol.

The *anterior pyramids* may be separated by ordinary dissection, and a tolerably accurate view obtained of their decussations; and, moreover, the medulla oblongata may be divided into two lateral halves, and its principal parts may then be isolated. The examination of the medulla when hardened in alcohol, or boiled in oil, or in a solution of salt, leads to important results, by enabling us to dissect it fibre by fibre, and to trace these fibres above and below their points of decussation. Together with these different modes of investigation I have employed another, viz., that of acting upon the medulla and its parts by a jet of water, the force and size of which is to be varied at pleasure, and the drops of which insinuate themselves between the fibres and separate them from each other.*

If a stream of water be directed upon the anterior pyramids, the fasciculated arrangement of their component fibres, all of which are parallel, will be clearly demonstrated; and it will also be seen that these two bodies are not mere medullary bands, but are two three-sided bundles occupying an angular groove between and in front of the two olivary bodies (*fig.* 269, C).

The *decussation of the anterior pyramids* demands attention, as one of the most important points in the anatomy of the cerebro-spinal axis.

On examining the anterior median groove of the medulla oblongata (see *figs.* 270, 276), it will be found that, at a distance from the pons Varolii of about ten lines (Gall says an inch and some lines), the anterior pyramids divide into three or four bundles, which alternately interlace in a regular manner (below *n*), so as to form a plaited structure of from two to four lines in length. Is this decussation only apparent? and if so, does the appearance result, as has been said, from the traction of parallel fibres in opposite directions? or do the pyramids commence by alternate bundles arising from each side of the middle line, and does this alternate arrangement occasion the appearance of a decussation? or, lastly, do the right and left pyramids actually cross like the limbs of the letter X?

On consulting the various authorities on this subject, it is found that the decussation of the pyramids, first pointed out by Aretæus, renoticed by Fabricius Hildanus, and demonstrated by Mistichelli† and Pourfour Dupetit,‡ has been admitted by Santorini, Winslow, Lieutaud, Duverney, Scarpa, and Sœmmering; and that the opposite opinion has been maintained by Morgagni, Haller, Vic d'Azyr, Sabatier, Boyer, Cuvier, Chaussier, and Rolando.◊ As to Gall and Spurzheim, they do not seem to have had a decided opinion upon this point; for, after having appeared to admit the decussation in some passages of their work, they say elsewhere that the small cords of the pyramids do not form a true decussation, but merely intersect and pass over each other obliquely.

In order to settle the question of decussation, I submitted the medulla oblongata to the action of a jet of water upon both its anterior and posterior surfaces; and by then examining it from behind forward, I was able to ascertain that the right and left pyramidal bundles do most evidently decussate (*a*, *fig.* 273); that this decussation is effected, not only from side to side, but also from before backward (*b*, *fig.* 274); that the left pyramidal bundle (*b*) passes downward to the right side and backward (*w*), traverses the gray matter of the cord, and becomes continuous with the right lateral column of the cord, and *vice versâ*; and, lastly, that the anterior pyramids are not in the slightest degree continuous with the anterior columns of the spinal cord.

The Olivary Bodies.—When the anterior pyramids are removed, it is seen that the olivary bodies (*d*, *figs.* 273, 274) do not consist merely of the prominent masses which project beyond and on the outer side of the anterior pyramids, but that they extend inward to the median line behind the pyramids, which are received in a slight concavity formed by the anterior surfaces of the olivary bodies (*fig.* 269, C). This arrangement is very evident, without any preparation, in anencephalous infants, or in such as are born

* If we employ a stream of water in the examination of a fresh medulla oblongata, it may easily be conceived that the results will be much more conclusive than if we had thus examined one which had already been subjected to different modes of preparation that may have altered its structure.

† Trattato dell' Apoplessia, 1709. ‡ Letters d'un Médécin des Hôpitaux, 1710.

◊ Of all who have denied the reality of the decussation, Rolando appears to me to have opposed the doctrine with the greatest force. He examined the subject with the greatest attention; he made horizontal sections of the medulla oblongata, but he could never see anything more than the alternate origin of the fasciculi which constitute the anterior pyramids; he could never find that the bundles of the right side passed over to the left, and *vice versâ*. In reply to the objection, that without admitting the decussation it is impossible to account for the cross effects of injuries or diseases of the brain, he states that these are explained by the intimate union between the optic thalami and tubercula quadrigemina of the two sides, and between the two halves of the pons Varolii and medulla oblongata. The error of Rolando evidently arose from his attaching such exclusive importance to sections, as a means of determining the structure of the medulla oblongata.

with very imperfectly-developed brains; the situation of the atrophied pyramids is then occupied by two tracts of gray matter, and the olivary bodies, more developed than usual, reach as far as the median line.

When a jet of water is directed against the median line between the olivary bodies, it encounters a white and very dense tissue, upon which it produces little effect.*

As soon as this tissue has been removed with the knife, the water insinuates itself into the substance of the olivary bodies, which, as we have seen, are open towards the inner side; each olivary body is then spread out, its anterior half is turned outward, and assumes the appearance of a dense yellowish layer folded upon itself, like a leaf while within its bud; after some white lamellæ are removed by the action of the water, the posterior half is exposed, and displays a similar appearance to that of the anterior half. Rolando compares the arrangement of this yellow folded layer, or corpus dentatum of the olivary body, to a flattened purse (*borsa appiattita*), the neck of which is open, somewhat constricted, and directed backward and towards the median line.

Gall and Spurzheim regarded the olivary bodies as ganglia, but these anatomists appear to me to have singularly misapplied the term ganglion, which they have given to such dissimilar parts as the olivary bodies, the corpora striata, and the tuber annulare.

Lastly, by directing the stream of water against the median line, and by assisting its action by gently drawing the parts asunder, the medulla oblongata becomes divided into two perfectly similar halves, excepting opposite the decussation. A beautiful preparation may thus be made, exhibiting the separation of the two halves of the medualla oblongata and spinal cord, and leaving the decussation of the anterior pyramids.

It appears, then, on the one hand, that the anterior pyramids are not formed by the anterior columns of the spinal cord; and, on the other hand, that the posterior columns of the cord become separated from each other behind when they have reached the medulla oblongata. What, then, becomes of the white bundles of the cord in the medulla oblongata?

Having arrived opposite the neck of the bulb, the white matter of the cord is divided into two bundles: one *anterior*, which forms the *anterior pyramid* (*b. fig.* 273), and may be called the cerebral bundle, because it passes up (*b'*) to the brain; the other *posterior*, or the *restiform body* (*c e*), which may be called the *peduncle* of the cerebellum, because it is exclusively intended (*n*) for that organ; the former is composed of white bundles, which emerge from the interior of the spinal cord, and the latter of the anterior columns, and of the remaining white bundles of the cord. The olivary bodies (*d*) are situated between these two sets of white fibres.

When, by means of the stream of water, the anterior pyramids and the restiform bodies have been removed, it is seen that each half of the medulla oblongata is formed principally of a very dense nucleus, consisting of a mixture of gray and white substances. This *nucleus*, or *fasciculus of re-enforcement of the medulla oblongata*, which we shall call the *unnamed fasciculus* (*faisceau innominé*) of the medulla, commences opposite the decussation of the pyramids by a narrow extremity, increases in size as it proceeds upward, passes above (*l, fig.* 274), *i. e.*, deeper than the pons, and becomes continuous, as we shall afterward see, with the corresponding optic thalamus. Each half of the medulla oblongata has its fasciculus of re-enforcement, of which the *internal surface*, viz., that turned towards the middle line, corresponds to the fasciculus of the opposite side, but is separated from it by the white fibres (*o, fig.* 274) already described (p. 706) as passing horizontally from before backward, in the median line of the medulla. The *posterior surface* of these fasciculi (*p, fig.* 271) constitutes the anterior wall of the fourth ventricle. The corresponding peduncles of the cerebellum, or the restiform bodies, embrace them on the outside, and form, as it were, grooves for them.

On examining thoroughly the internal or median surface of each re-enforcing fasciculus of the bulb, it is found that there are two vertical bands upon that surface, one anterior, the other posterior; and that the fibres which pass horizontally from before backward in the median line of the medulla oblongata are situated between the bands of the right and left sides.

Each fasciculus of re-enforcement is divided above into two parts, one of which forms the centre of the corresponding restiform body, while the other becomes continuous with the optic thalamus above the pons Varolii.

I have not alluded to the *olivary fasciculi* admitted by some anatomists, for the white bundles so called do not even come from the olivary body, but form the continuation of the lateral columns of the spinal cord, which embrace the olivary bodies on the outer side, without being re-enforced by any bundles derived directly from them.†

* I have frequently been led to regard the white medullary substance which is situated between the olivary bodies, and passes into each of them, as a transverse commissure, which might be called the commissure of the olivary bodies.

† [The bundles, named faisceaux innomminés in the text (*fasciculi teretes* of some other authors), which M. Cruveilhier describes as taking their rise at the lower end of the medulla oblongata, are more generally considered to be prolonged from the lateral columns of the cord; and on comparing the statements of recent inquirers concerning the anatomy of the medulla oblongata, the following appears to be the arrangement which the columns of the cord undergo in passing through it, viz., the posterior columns (including the posterior median fasciculi, which correspond with the posterior pyramids) separate laterally from one another (*e, figs.* 273,

Development of the Spinal Cord.

As soon as the spinal cord has passed through its original condition of an almost transparent pulp, it assumes the appearance of a lamina, the edges of which are rolled back upon themselves so as to enclose a canal, continuous with the cavity of the fourth ventricle, which might be regarded as the expanded extremity of the canal. This canal is narrowed along the middle by the reflection of the pia mater into it: it is thus converted into two canals, the walls of which are at first thin, but afterward increase in thickness, gradually encroach upon the caliber of the canals, which finally disappear between the sixth and seventh month. At this period a thin, white, outer layer covers the whole medulla: the posterior median columns are very large, and of a white colour, while the antero-lateral columns are still semi-transparent, the gray matter is soft and diffluent, like a pulp; and, by the slightest insufflation, a canal may be formed along the centre of each half of the cord.

The spinal cord occupies the whole length of the vertebral canal until the third month; but after this time, its lower extremity becomes relatively higher up to the period of birth, when it corresponds to the second lumbar vertebra.

The spinal cord is larger, in proportion to the brain, during the early periods of fœtal life, than afterward. The more rapid development of the brain, at later periods, gives that organ the advantage.

From studying the development of the spinal cord, Tiedemann infers that the white substance exists before the gray, and therefore that the latter cannot be the nutritious organ or matrix of the white substance, as Gall had affirmed.

It is quite certain that the white parietes of the medullary canal are developed previously to the gray matter.

Development of the Medulla Oblongata.

During the first three months of intra-uterine life, the upper limit of the medulla oblongata is not defined, because there is no pons Varolii. The fœtal brain, therefore, in this condition, resembles the brains of birds, reptiles, and fishes. The transverse fibres of the pons make their appearance during the fourth month, and the upper limit of the medulla oblongata is then established.

The two halves of the medulla oblongata are perfectly distinct, and each half is divided into three columns: one for the brain properly so called, viz., the anterior pyramidal bundle; another for the tubercula quadrigemina, which may be called, with Tiedemann, the olivary bundle, remembering, at the same time, that this term has a very different meaning from what was attached to it by Gall; and a third or cerebellar bundle, which is the restiform body.

The anterior pyramidal bodies are at first flattened like those of mammalia, but during the latter months they acquire their characteristic size and prominence. In the medulla oblongata of a fœtus, from the seventh to the ninth month, the anterior pyramids are of a reddish-gray colour, while the anterior columns of the spinal cord are as white as they appear afterward. Those pyramids, therefore, are not the continuation of the anterior columns of the cord.

The decussation of the pyramids is perfectly distinct after the fourth week of fœtal existence.*

The olivary bundles of Tiedemann, which are situated to the outer side of the anterior pyramids, and, like them, traverse the pons, gain the sides of the tubercula quadrigemina, beneath which they form an arch, which constitutes the upper wall of the aqueduct of Sylvius. The olivary bodies, which are wanting in birds, reptiles, and fishes, do not appear until the end of the sixth or the commencement of the seventh month of fœtal life.

The cerebellar bundles, or restiform bodies, are perfectly distinct from the preceding. The small mammillated bundles which bound the sides of the posterior longitudinal groove can also be distinguished in the fœtus.

Comparative Anatomy of the Spinal Cord.

Mammalia.—The spinal cord of mammalia precisely resembles that of the human sub-

274), and enter the cerebellum, forming the principal part of its inferior peduncle (*n*). The fibres of the lateral columns are disposed of in three ways: 1. A part of them cross the median plane to the opposite side (*w*, *fig.* 273), and form the chief part of the pyramidal body (*b*) of that side. 2. Another set join the inferior peduncle of the cerebellum. 3. The remaining fibres are continued along the floor of the fourth ventricle (*p*, *fig.* 271), as the fasciculi innominati or fasciculi teretes. The anterior columns (*a*, *fig.* 273) of the cord, on entering the medulla oblongata, are thrown aside by the decussating fibres coming from the lateral columns, and then one portion of each anterior column forms the outer part of the corresponding pyramid (*b*); another portion (*c*, *fig.* 274) passes partly behind and partly on the outer side of the olivary body, and is then chiefly continued into the fillet (*h*); the remaining part passes into the cerebellum, joining its inferior peduncle (*n*). The connexion of the cerebellum with the anterior columns of the cord was pointed out by Mr. Solly.—(*Phil. Trans.*, 1836, p. 567.) Arnold describes the posterior pyramids (*fasciculi graciles*) as passing into the crura cerebri. For farther details on the anatomy of the medulla oblongata, the reader is referred to Arnold's *Bemerkungen über den Bau des Hirns und Rückenmarks*, Zurich, 1838; also his *Icones Anatomicæ*, fasc. i., and to a paper by Dr. J. Reid in the *Edin. Med. and Surg. Journ.* for January, 1841.]

* [The fourth or fifth month, according to Tiedemann; though in one part of his work "week" has been, by an error, printed for "month."]

ject: its length, its size, its enlargements, are exactly proportioned to the size and activity of the muscles, and to the sensibility of the organs with which it is connected by means of the nerves.

Birds.—The spinal cord in birds is proportionally both longer and larger than in other animals; and this has reference to the enormous muscular effort required in flying. It presents two great enlargements; one of these corresponds to the wings, and the other, which is larger, and contains a ventricle, corresponds to the lower extremities; this ventricle was known to Steno, who described it under the name of the *rhomboidal sinus*.

According to Nicolai (*Dissertatio de Medullâ Spinali Avium*, Halle, 1811) and Tiedemann, the spinal cord of birds contains a central canal, which is lined by a thin layer of gray matter, not only in the embryo, but also in the adult.

Reptiles.—In all reptiles the spinal cord contains a canal, which is lined, according to Tiedemann, by a thin layer of gray substance. In the batrachian reptiles (the toad, frog, &c.), the spinal cord occupies only the anterior or upper part of the vertebral canal. M. Desmoulins says (t. i., p. 187) that the gray matter in these species surrounds the white substance. This opinion appears to me to be erroneous.

In ophidian reptiles (serpents), the spinal cord occupies the whole length of the vertebral canal; there is no gray matter,* but its place is occupied by a fluid, so that each half of the medulla contains a canal.

In the saurians (crocodiles, lizards), the spinal cord is slender, of almost uniform size throughout, and occupies the whole length of the vertebral canal.

The spinal cord of the chelonian (tortoises, &c.) is the most remarkable of all, as regards its shape, and is peculiarly illustrative of the law which regulates the dimensions of this organ. There are three fusiform enlargements separated from each other by two very narrow portions; the middle enlargement corresponds to the upper extremities, and the inferior one to the lower extremities; the first constriction corresponds to the neck, the second to the thorax.

Fishes.—In all *fishes* the spinal cord occupies the entire length of the vertebral canal. It is of uniform size in its anterior five sixths, but diminishes like a cone in the posterior sixth. There is no gray matter,† so that the cord is hollow. According to Arsaky (*Dissert. de Piscium Cerebro*) and Tiedemann, the medullary canal is lined by a thin layer of gray matter.

The lophius piscatorius and the male tetrodon present remarkable anatomical peculiarities; in the lophius, the spinal cord is diminished in size opposite the third cervical vertebra; all at once it becomes extremely slender, and then terminates in a point opposite the eighth cervical vertebra. Twenty-six pairs of nerves arise from the enlarged portion, and only five or six pairs from the slender portion. In the tetrodon there is no spinal cord, properly so called, or, rather, this part of the cerebro-spinal axis is reduced to a medulla oblongata, from which arise thirty-two pairs of nerves.

From these facts, it follows that the length and size of the spinal cord bear an exact proportion to the muscular power and sensibility of the parts supplied by it; and farther, that the gray matter of the cord is not nearly so important as the white substance, since it is absent in a great number of species.‡

Comparative Anatomy of the Medulla Oblongata.

In the *mammalia* the medulla oblongata is constructed upon the same plan as in the human subject, but the anterior pyramids are much smaller, and the olivary bodies appear to be completely effaced. The tubercula cinerea of Rolando exist only in man; in whom alone do we find those white streaks of medullary substance upon the anterior wall of the fourth ventricle, which are regarded as forming, at least in part, the origins of the auditory nerves.

The medulla oblongata of *birds* and *reptiles* presents no striking peculiarities. In the different species its size is always in proportion to that of the fifth, and especially the eighth pair of nerves, which take their origin from this part.

In *fishes* a peculiar pair of lobes correspond to the medulla oblongata; these lobes were for a long time erroneously supposed to be the lateral lobes of the cerebellum, and have thus led to much obscurity concerning the anatomy of the encephalon in these animals. Desmoulins calls them the lobes of the fourth ventricle; we shall call them the lobes of the eighth pair of nerves. In the ray and sturgeon this lobe is so highly developed, that it forms half of the encephalic mass. In the carp, besides the lateral lobes which are traversed by some white fibres, there is also a median lobe. Moreover, as a general rule, whenever the spinal cord has to furnish any nerves, there is an enlargement or a lobe. In the torpedo, in which the eighth pair of nerves are of enormous size, and supply the electrical organ, these lateral lobes are in an extraordinary degree developed. In the trigla there are certain small lobes behind the cerebellum, which correspond to the peculiar digitiform prolongations serving as organs of progression in the animals in question.

* [The spinal cord of serpents forms no exception to the general rule; gray matter has been recognised in it, as in the cord of other vertebrated animals. The same is true of fishes.—(See Leuret, *Anatomie Comparée du Système Nerveux, &c.*, Paris, 1839.)] † See note, *supra*. ‡ See note, *supra*.

The olivary bodies are most highly developed in the human subject; they exist also, but are very small, in some mammalia; they disappear in birds, reptiles, and fishes. I consider the olivary bodies as lobes in a rudimentary state.

THE ISTHMUS OF THE ENCEPHALON.

General Description and Division.—The Pons Varolii and Middle Peduncles of the Cerebellum—the Peduncles of the Cerebrum—the Superior Peduncles of the Cerebellum and the Valve of Vieussens—the Corpora Quadrigemina.—Internal Structure of the Isthmus, viz., of its Inferior, Middle, and Superior Strata.—Sections.—Development.—Comparative Anatomy.

I SHALL, with Ridley, apply the term *isthmus of the encephalon* to that narrowed and constricted portion of the encephalic mass which is situated between the cerebrum, cerebellum, and medulla oblongata, which corresponds to the free margin of the tentorium cerebelli, and comprises the pons Varolii and middle peduncles of the cerebellum, the peduncles of the cerebrum, the tubercula quadrigemina, the superior peduncles of the cerebellum, and the valve of Vieussens.

The isthmus of the encephalon is the common point of union between the three great divisions of the cerebro-spinal axis, viz., the medulla spinalis, the cerebrum, and the cerebellum. It contains within it the media by which they all communicate, or, as it may be said, the elements of each reduced to their most simple expression.

It is of a cuboid form, and therefore presents six surfaces for our consideration:

An *inferior surface* (*fig.* 276), on which we observe the pons Varolii, or tuber annulare (*d*), the middle peduncles of the cerebellum (*m*), and the peduncles of the cerebrum (*f f*).

A *superior surface* (*fig.* 271), which is covered by the superior vermiform process of the cerebellum, by the velum interpositum, and by the posterior border of the corpus callosum. In order to expose this surface, supposing the brain to be with its base upward, the cerebellum must be turned forward, and the pia mater should be separated, taking care to lift up with it the pineal gland. Proceeding from before backward, the following parts come into view: the tubercula quadrigemina (*f g*), resting upon them the pineal gland (*c*), the superior peduncles of the cerebellum (shown in cut at *r*; also *r*, *fig.* 272), and the valve of Vieussens (*l*, *fig.* 271).

The *lateral surfaces* (*fig.* 272) are each divided into two distinct parts or stages, by a furrow which runs from before backward (the lateral furrow of the isthmus); the inferior stage consists of the pons Varolii (*a*) and the middle peduncles of the cerebellum (*m*), while the superior is narrower, lies closer to the median line than the preceding, and presents a *triangular fasciculus* (*h*), having its base directed downward, and its apex turned upward, so as to reach the corresponding inferior quadrigeminous tubercle or testis (*g*).

The *anterior surface* of the isthmus is continuous with the optic thalami (*s*, *fig.* 272).

The *posterior surface* is much narrower than the anterior, and is continuous with the base of the medulla oblongata.

We shall examine the several parts of the isthmus in the following order: the *pons Varolii* and *middle peduncles of the cerebellum*, *the peduncles of the cerebrum*, *the superior peduncles of the cerebellum*, *the valve of Vieussens*, *and the tubercula quadrigemina*. The *inferior peduncles of the cerebellum* have been already described with the rest of the medulla oblongata, under the name of the *restiform bodies*.

The Pons Varolii and Middle Peduncles of the Cerebellum.

The *pons Varolii*, or *tuber annulare*,* is that white cuboid eminence (*d*, *fig.* 276) situated between the cerebrum and cerebellum, upon the base of the encephalon, and forming, as it were, its centre (mésocéphale, *Chauss.*; nodus encephali, *Sœmm.*). From this centre the several parts proceed as follows: backward, the medulla oblongata (*e*); forward, two thick white bundles, which pass into the brain, and form the *anterior* or *cerebral peduncles* (*f f*); laterally, two thick bundles, which enter the cerebellum, and are named the *posterior* peduncles, or middle *cerebellar peduncles* (*m*).

The pons Varolii, the cerebral and cerebellar peduncles, and the medulla oblongata proper, are together called the *medulla oblongata* by some authors; several of the older anatomists, in fact, compared the pons to the body of an animal, of which the anterior peduncles represented the arms; the posterior, the legs; and the medulla oblongata proper, the tail; and hence the terms still in use of the *arms*, *legs*, and *tail* of the so-called medulla oblongata. It was Varolius who compared this part to a bridge, under which the several branches of a stream, supposed to be represented by the peduncles and the medulla oblongata, joined each other; hence the terms *pons Varolii* and *pons cerebelli*.

The pons is free below, but is blended above with the upper portion of the isthmus; it is bounded in front by the peduncles of the cerebrum, and behind by the medulla oblongata; and it is continuous, laterally, with the middle peduncles of the cerebellum (*m*),

* The term tuber annulare is derived from the fact that this part of the encephalon seems to embrace the several prolongations of the medulla oblongata like a ring.

forming with them but one system of fibres; its lateral boundaries are, therefore, altogether artificial.

The *size* of the pons, which is very considerable in the human subject, is always in relation with the development of the lateral lobes of the cerebellum; comparative anatomy, embryology, and the study of malformations completely establish this fact.*

Its *inferior surface* is covered by the pia mater, which can be easily stripped off; it rests upon the anterior part of the basilar groove, and slopes backward and downward like the inclined plane of that groove.

It presents along the median line a slight furrow, which is broader in front than behind, and corresponds to the basilar artery: this groove appears as if it were caused by the presence of the artery; nevertheless, I must say, that not unfrequently the basilar artery is found to deviate to one side or the other, or to be more or less tortuous, and yet that the median groove is as distinctly marked as usual.

I believe there is good ground for entertaining the opinion that this groove results from the prominence of the anterior pyramids, which raise up the surface of the pons on each side of the median line.

The inferior surface of the pons presents certain transverse bundles or fibres, which appear to cross each other at very acute angles, and which, according to Rolando, may be divided into three sets: *superior bundles*, which turn upward, to constitute the upper part of the middle peduncles of the cerebellum; *inferior bundles*, which pass transversely outward; and *middle bundles*, which are directed obliquely downward and outward, pass in front of the inferior bundles, and then form the anterior border of the cerebellar peduncles. The origin of the fifth pair of nerves is between the superior and middle sets of fibres. Not unfrequently the middle bundles are not to be seen.

It follows, therefore, that the middle peduncles of the cerebellum are merely the transverse fibres of the pons condensed and twisted upon themselves. The pons and these peduncles of the cerebellum constitute one and the same system of fibres. We might therefore, with Gall, designate the pons and the middle peduncles of the cerebellum as the *commissure of the cerebellum*, or *corpus callosum of the cerebellum.*

The Peduncles of the Cerebrum.

The peduncles of the cerebrum (*f f*, *fig.* 276), sometimes regarded as prolongations of the cerebrum to the medulla oblongata (*processus cerebri ad medullam oblongatam, ad pontem Varolii*), sometimes as the arms, legs, or thighs of the cerebrum (*brachia, crura, femora, cerebri*), and by others as prolongations of the medulla towards the cerebrum (*processus medullæ oblongatæ ad cerebrum*), are two thick, white, fasciculated columns, which arise from the anterior angles of the pons Varolii, and enter the substance of the cerebrum, after a course of about six lines.

They are cylindrical, and in contact with each other as they emerge from the pons; and they gradually increase in size, and become flattened as they advance forward, upward, and outward. The optic tracts (*s* 2, *fig.* 272) circumscribe and bound them in front.

Their size corresponds to that of the cerebral hemispheres. They are of equal dimensions in a well-formed brain, but they are liable to become atrophied with their corresponding hemisphere, as I have had frequent occasion to observe.

Each of them is free below, and on its outer and inner side, but is blended above with the upper portion (*h i f g*, *fig.* 272) of the isthmus of the encephalon.

Their white fasciculi are slightly divergent, and are often intersected at right angles by certain white tracts, some of which emerge from the testes and the valve of Vieussens, while others proceed from the internal surfaces of the peduncles themselves. This arrangement Gall and Spurzheim have named the *transverse interlacement of the great fibrous bundles* (see *fig.* 272). Owing to the oblique and diverging direction of the cerebral peduncles, there is left between them a triangular *inter-peduncular space* (between *r* and *t*, *fig.* 276), which is occupied in front by the corpora mammillaria or albicantia (*z*) and the tuber cinereum (*v*), and in which is observed behind two white triangular bundles, separated from the peduncles by a blackish line. We shall see that these inter-peduncular bundles are merely the under surface of the bundles of re-enforcement of the medulla oblongata, or the "faisceaux innominés" (*l*, *fig.* 274).

The Superior Peduncles of the Cerebellum and the Valve of Vieussens.

The *superior peduncles of the cerebellum* (*r*, *figs.* 271, 272, 280) are more commonly known as the *processus cerebelli ad testes*, a name given to them by Pourfour Dupetit. I should observe, however, that this name sanctions an anatomical error; for the superior peduncles of the cerebellum do not go to the *testes* at all, but pass under them, and are covered by the corresponding lateral triangular bundle of the isthmus; they should rather be called *processus cerebelli ad cerebrum* (*Drelincourt.*)

The inferior peduncles of the cerebellum consist of two lamellæ, which arise from the

* Animals which have no lateral lobe of the cerebellum have no pons Varolii, and this part is small in such as have very small lateral cerebellar lobes. In a young girl ten years of age, who had no cerebellum, I found that the pons was also wanting.

interior of the cerebellum, one on each side of the median line, pass upward and forward parallel to each other, and appear to be continuous with the testes.

Their *upper convex surface* is covered by the cerebellum (see *fig.* 280), and is separated from it by a double layer of the pia mater. Their *inferior surface* is free, and assists in forming the upper wall of the aqueduct of Sylvius. Their external borders are each separated from the pons by a furrow, which we have already described under the name of *lateral furrow of the isthmus*. Their *internal* borders are connected together by means of the valve of Vieussens, which is distinguished by its colour from the peduncles.

Their *inferior extremities* pass deeply into the central white substance of the cerebellum.

The *valve of Vieussens* (*valvula magna cerebri*, *l*, *fig.* 271 ; *v*, *fig.* 280 ; *g* to *w*, *fig.* 282) is a thin, semi-transparent lamina, which occupies the interval between the two superior peduncles of the cerebellum ; it is the *velum medullare* or *velum interjectum* of Haller.

Its *posterior surface* is concave, and is in relation above with the superior vermiform process ; in its lower portion it adheres to the transversely-notched imperfect lamella (linguetta laminosa, *Malacarne*), in which the superior vermis ends.

The *median line* of this posterior surface is marked by a line (*fig.* 271), which Rolando considers as the trace of the line of junction between the two laminæ, of which, according to him, the valve consists.

The *anterior surface* is convex, and forms the posterior wall of the aqueduct of Sylvius (leading from *v* to *l*, *fig.* 282).

The *borders* of the valve are not only in juxtaposition with the corresponding borders of the superior peduncles of the cerebellum, but appear to be continuous with them.

The *superior extremity* is narrow, and presents a transverse band, which may be regarded as the commissure of the superior peduncles of the cerebellum and of the fourth pair of nerves.

The *inferior extremity* is broad, very thin, and continuous with the central portion of the median lobe of the cerebellum (*w*).

The Tubercula Quadrigemina.

Dissection.—Place the brain with its base upward, turn the cerebellum forward, and remove the pia mater.

The term *tubercula quadrigemina* or *bigemina* (corpora bigemina, *Sœmmering*, *optic lobes* of the lower animals) is applied to four tubercles (*f g f g*, *figs.* 271, 272) situated regularly upon the upper surface of the isthmus, two on each side of the median line. They form two pairs : the anterior or superior (*f*) are the larger, and are called the *nates* (*eminentiæ natiformes*) ; the posterior or inferior (*g*) are the smaller, and are called the *testes* (*eminentiæ testiformes*).

These tubercles are placed between the cerebrum and cerebellum, and are situated above the peduncles of the cerebrum, and, consequently, upon a plane anterior to that of the pons, and cannot consistently be named the *tubercles of the mesocephalon*, as was done by Chaussier. The anterior part of the *aqueduct of Sylvius* passes beneath them (*f g*, *fig.* 282), and establishes a communication between the third (*l*) and fourth (*v*) ventricles.

They are comparatively small, indeed merely rudimentary in the human subject, for their development in the animal series is inversely as that of the cerebrum and cerebellum. The space which they occupy is a parallelogram of ten lines by eight.

The *anterior* tubercles are always larger than the posterior ;* they are of a gray colour, oblong, ellipsoid, and diverging ; their longest diameter is directed obliquely forward and outward. The *posterior* tubercles are smaller, and more detached ; they are almost hemispherical, and of a white colour ; but not so white as the fasciculated medullary substance.

A furrow, curved like a parabola opening forward, separates the anterior from the posterior tubercles. The antero-posterior furrow along the median line separates the tubercles of the right from those of the left side. From this furrow, a small, grayish, and tolerably dense cord proceeds backward, and descends perpendicularly upon the valve of Vieussens, or, rather, upon the transverse commissure by which it is surmounted, and then divides into two or three branches. This cord might be named the *pillar of the valve of Vieussens* (*columella frenulum*).

The *lateral triangular bundle* (*h*, *figs.* 271, 272) *of the isthmus* terminates in the posterior tubercle. This fasciculus, which was pointed out by Reil (" schleife," lemniscus, fillet), Tiedemann, and Rolando, who described it as arising from the olivary bodies, presents an *anterior* border, which is directed obliquely forward and outward, proceeds along the anterior tubercle, and terminates in a small body called the *corpus geniculatum internum* (*i*, *figs.* 271, 272). Its *posterior* border inclines downward, backward, and outward, and forms a slight prominence above the superior peduncle of the cerebellum, which is covered by it. Its *base* corresponds to the lateral groove of the isthmus, which separates it from the pons and the peduncle of the cerebrum. Its *apex* extends to the corre-

* The relative size of the tubercula quadrigemina varies somewhat in different animals. The anterior tubercles are much larger than the posterior in ruminants, solipeds, and rodentia ; they are smaller than the posterior in carnivora—in the dog, for example.

sponding posterior tubercle or testis. The anterior tubercles or nates are continuous with the optic thalami (*a*, *fig.* 271), being separated from them by a slight depression. Some white fibres proceed from the anterior extremity of these tubercles, and, as we shall afterward see, form a thin layer above the corresponding corpus geniculatum externum (*j*), and assist in the formation of the optic nerves. These white bands are generally proportioned to the size of the nates.*

The Internal Structure of the Isthmus of the Encephalon.

Dissection.—By antero-posterior and transverse sections of the isthmus. The parts to be examined by laceration, by submitting them to the action of a stream of water, and also after they have been hardened in alcohol, or by being boiled in oil, or a solution of salt.

The internal structure of the isthmus presents three very distinct strata placed one upon the other: an *inferior*, formed by the pons, the middle peduncles of the cerebellum, and the fasciculated portion of the peduncles of the cerebrum; a middle stratum, formed by the prolongation of the bundles of re-enforcement of the medulla oblongata; and a *superior* stratum, which consists of the triangular lateral bundles of the isthmus, the superior peduncles of the cerebellum, the valve of Vieussens, and the tubercula quadrigemina.

Internal Structure of the Pons and the Peduncles of the Cerebellum.

It has been stated that the lower surface of the pons presents some white transverse fibres (see left side, *fig.* 273), which twist upon each other to form the middle peduncles of the cerebellum. On making a very superficial incision into the pons, we find, beneath the external layer of white matter, which is very thin behind, and a little thicker in front, a grayish-yellow substance, which is traversed by the transverse fibres of the pons, so that the part (*m*, *fig.* 274) has a striated appearance.

Fig. 273.

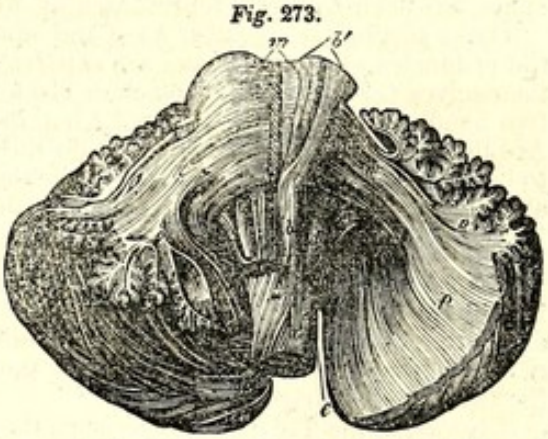

If the handle of the scalpel be passed beneath the anterior border of the pons, so as to remove all that part which projects beyond the level of the peduncles of the cerebrum, it will be seen that the pons is traversed longitudinally by certain white bundles of fibres (*b'*, *figs.* 273, 274); and if, moreover, the handle of the scalpel be insinuated beneath the posterior border of the pons, and all that part be removed which projects beyond the pyramidal bodies of the medulla oblongata, these white longitudinal bundles which traverse the pons are found to be the prolongation of the pyramids (*b*), and are themselves continuous with the peduncles of the cerebrum (*n*, *fig.* 282). By thus separating the pons into very thin horizontal layers, it will be found that the longitudinal (*b'*) and transverse (*m*) fibres form several alternate layers, above which we arrive at the middle stratum of the isthmus.

The peduncles of the cerebrum are continuous with the longitudinal fibres of the pons, and the middle cerebellar peduncles with the transverse fibres of the same part; the gray matter of the pons extends into the substance of the latter, and gives them a striated appearance. At the boundary between the pons and the middle peduncles of the cerebellum there is on each side a very considerable longitudinal bundle, which forms the origin of the fifth nerve, and which, therefore, does not belong to the anterior pyramidal bodies.† ш

The absolute continuity of the anterior pyramids with the peduncles of the cerebrum, through the pons, may be regarded as a type of the structure of the nervous centre. The two sets of fibres are intermixed in the pons, so as to intersect each other at right angles, but they maintain their individuality.‡

The pons presents neither a raphé nor a septum in the median line: the fibres of the right half are continuous with those of the left. The white fasciculated fibres (*b'*) of the

* They are very large in the sheep; it appears that it was chiefly from the anatomy of the brain in this animal that Gall founded his opinions as to the optic nerves, which he regards as arising from the tubercula quadrigemina. This opinion is very doubtful as far as concerns the human subject.

† The most anterior and the most posterior transverse fibres of the pons have a very peculiar arrangement: the anterior are inflected (*o*, *fig.* 282) between the peduncles of the cerebrum, and completely occupy the interval between them; so that each of these peduncles is embraced by a distinct ring, formed by the fibres of the pons; and, again, the most posterior fibres of the pons dip between the anterior pyramids, each of which is also embraced by a distinct ring.

‡ The continuity of the pyramids with the peduncles of the cerebrum, through the inferior portion of the pons, was accurately described and figured by Varolius (*De Nervis Opticis nonnullisque aliis*, 1573), by Vieussens (*Neurographia Universalis*, tab. 16), by Morgagni (*Adversaria Anatomica*, v.), and by Vicq d'Azyr. Vieussens showed this continuity by lacerating the pons. Vicq d'Azyr showed it by successively removing the thin layers of the pons by means of a cutting instrument. The plates given by Gall surpass those of his predecessors in execution, but not in a scientific point of view.

peduncles of the cerebrum, which are continuous with the anterior pyramids (*b*), form part of the inferior stratum of the isthmus; these fasciculated fibres are parallel and perfectly white, without any intermixture of gray matter.

Internal Structure of the Middle Stratum of the Isthmus.

When the pons, or, in other words, the successive layers of the inferior portion or stratum of the isthmus, have been removed, the middle stratum is exposed. This may be very easily displayed in a brain that has been well hardened in alcohol. It is then seen that this middle stratum is formed by a prolongation of the fasciculi of re-enforcement (*faisceaux innominés*) of the medulla oblongata, which becomes enlarged in passing above the pons, and still more so opposite the peduncles of the cerebrum, above which we shall trace them presently. This prolongation (*l*, *fig.* 274) then passes through the pons at right angles. It was doubtless to illustrate this arrangement that Varolius described the medulla, when viewed from below, as passing beneath the pons like the water of a canal under a bridge. This re-enforcing bundle, pointed out by Rolando (*Recherches sur la Moelle Alongée*, 1822) under the appellation of the middle fasciculus, has been correctly represented by Mr. Herbert Mayo.

Fig. 274.

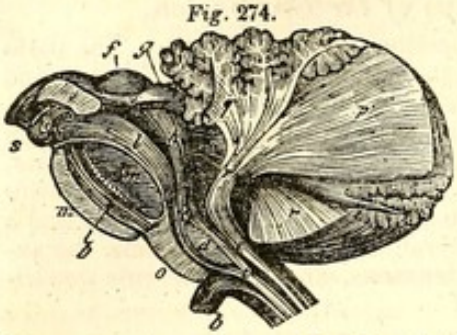

Those portions (*c*, *fig.* 269, A) of the bundles of re-enforcement which correspond to the peduncles of the cerebrum are separated from the superficial part of the peduncles themselves (*a*) by a layer of black or blackish matter (*b*): opposite the peduncles, these two bundles are intimately united,* but they soon diverge to enter the optic thalami. Are they simply in juxtaposition, or do they interlace at the point in which they appear to be blended? I am inclined to believe that they do interlace; but I have not yet been able to demonstrate this clearly, because they do not consist of very distinct bundles.

The Internal Structure of the Upper Stratum of the Isthmus.

The *superior peduncles of the cerebellum* are fasciculated: their lower extremities (*r*, *fig.* 274) assist in forming the central nucleus of the cerebellum; their upper extremities (*r'*) expand into a great number of fibres, some of which terminate upon the anterior wall of the fourth ventricle, on each side of the median line, while others form a *loop* below the tubercula quadrigemina.

Structure of the Tubercula Quadrigemina.—Reil, who first examined the structure of the tubercula quadrigemina, considers them as consisting of four rounded masses of gray matter, placed upon the radiated fibres of a white bundle, which spreads out beneath them. This white bundle (forming part of the bundle *h*, *fig.* 274), which he calls the *fillet* or *loop*, is derived (*c*), according to him, partly from the anterior pyramidal, and partly from the olivary body (*d*). It appears to me to be nothing more than the above-mentioned loop formed by the superior peduncles of the cerebellum, below the tubercula quadrigemina.

The tubercula quadrigemina themselves seem to me to be rather of a laminated than of a fasciculated structure. Mayo represents them as having a fasciculated texture.

The *triangular lateral fasciculus of the isthmus* (*h*, *fig.* 272) passes in one direction between the upper and middle strata of the isthmus, and in another it may be traced (forming the other part of the bundle *h*, *fig.* 274) downward as far as the olivary body. The anterior fibres extend from the testis (*g*) to the corpus geniculatum internum (*v*), pass beneath that body, and penetrate into the interior of the optic thalamus. This triangular fasciculus forms a layer upon the superior peduncle of the cerebellum, from which it is perfectly distinct.

Sections of the Isthmus of the Encephalon.

A vertical section made from before backward through the median line of the isthmus will give an excellent view of its three portions or strata: the section should include the medulla oblongata (see *fig.* 274). Upon it are seen the white and gray striated mass (*m b' m*) which constitutes the pons, the re-enforcing fasciculus (*l*) of the medulla oblongata becoming much thicker opposite the peduncles of the cerebrum than in the pons.

Transverse vertical sections will display the arrangement of the pyramidal bodies and the re-enforcing fasciculi as they pass from the medulla oblongata into the isthmus. In these sections a thick bundle belonging to the fifth nerve is always seen.

Sections of the tubercula quadrigemina show that they are neither distinct from each other, nor from the external and internal corpora geniculata, nor from the re-enforcing fasciculi of the medulla oblongata; but that these latter fasciculi and the tubercula quadrigemina form a single system, surmounted by masses of nervous matter, which are the tubercles themselves.

* [They here constitute the so-called *integumentum* (*c*, *fig.* 269, A): the black substance is called the *locus niger* (*b*), and the superficial part of the peduncle is named the *crust* or *basis* (*a*).]

Development of the Isthmus Encephali.

The development of the pons and of the peduncles of the cerebellum is in relation with that of the cerebellum; and the development of the cerebral peduncles with that of the cerebrum.

In the embryo of two months, the tubercula quadrigemina consist merely of two laminæ, which curve upward and outward, and become united at the end of the third month.

At this period the tubercula quadrigemina of the human subject are in the same condition as those of the lower animals. They are as yet, indeed, only two in number, one on each side of the middle line; and they are hollow, as in birds. At first they are completely exposed, but are gradually covered by the hemispheres of the cerebrum, as those parts are prolonged backward.

The transverse groove which divides the hitherto single pair of tubercles into an anterior and a posterior tubercle on each side does not appear until about the sixth month, at which time the cavity in their interior has been obliterated by the thickening of their parietes.*

Comparative Anatomy of the Isthmus.

The *pons Varolii and middle peduncles of the cerebellum* exist only in the human subject and in mammalia generally; these structures, which may be regarded as forming the commissure of the cerebellum, are developed exactly in proportion to the size of the lateral lobes of that organ; so that they attain their utmost development in the human subject, and are smallest in rodentia. The pons and cerebellar peduncles do not exist in the remaining three classes of vertebrata (birds, reptiles, and fishes), because those animals have no lateral lobes of the cerebellum.

The *tubercula quadrigemina* are less developed in man than in the lower animals. It may even be said that the development of these tubercles is inversely in proportion to that of the lateral lobes of the cerebellum and the hemispheres of the cerebrum.

The anterior tubercles are a little larger than the posterior in the human subject: in the ruminants, solipeds, and rodentia, on the contrary, the anterior tubercles are twice or three times as large as the posterior. In the carnivora the posterior are somewhat larger than the anterior.

They are covered by the cerebrum in the human subject and the highest orders of mammalia, but are in a great measure exposed in the rodentia and cheiroptera.

In birds, reptiles, and fishes, the tubercles are only two in number (the *tubercula bigemina*), and attain their maximum development: sometimes they are even larger than the cerebral hemispheres; they are hollow, and form true lobes, which are called the *optic lobes*, because, in fact, the optic nerves arise exclusively from them.

In *birds*, the optic lobes are situated at each side of the base of the cerebrum. The optic lobes of birds are not the thalami optici, as was at first believed: in this class of animals the optic thalami are thrown forward.

In *reptiles*, the tubercula quadrigemina consist, as in birds, of two large, ovoid, and contiguous lobes.

In *fishes*, it is extremely difficult to determine what are the tubercula quadrigemina; so much so, indeed, that the lobes of which they are composed have been taken sometimes for the cerebral hemispheres, and sometimes for the optic thalami. M. Arsaky (*De Piscium Cerebro*) has successfully refuted both of these errors.

THE CEREBELLUM.

General Description.—External Characters and Conformation—Furrows, Lobules, Laminæ, and Lamellæ.—Internal Conformation—the Fourth Ventricle, its Fibrous Layers, its Inferior Orifice, and its Choroid Plexus.—Sections of the Cerebellum, Vertical and Horizontal.—Examination by Means of Water, and of the Hardened Cerebellum.—General View of the Organ.—Development.—Comparative Anatomy.

The *cerebellum* (παρεγκεφαλις, *Aristotle*, *l l*, *fig.* 276; *h h*, *fig.* 280), or little brain, is that part of the encephalon which occupies the right and left inferior occipital fossæ. It exists in all animals which have a cerebrum and spinal cord, and, therefore, in all the vertebrata.

Cases of congenital absence of the cerebellum are extremely rare.†

Though for a long time neglected, the anatomical examination of the cerebellum was commenced with considerable talent by Petit, of Namur (*Lettre d'un Médécin des Hôpitaux du Roi*, Namur, 1710), and Malacarne (*Encephalotomia nuova Universale*, Torino, 1780). Vicq d'Azyr and Chaussier have described its external conformation with extraordinary accuracy; and Reil, Gall, and Rolando, have more particularly investigated its structure.

* In a fœtus of seven months, I found the tubercula quadrigemina not yet divided into the nates and testes.

† *Vide* Anat. Pathol., avec fig., for a case of absence of the cerebellum.

The External Characters and Conformation of the Cerebellum.

Situation.—The cerebellum is enclosed between the inferior occipital fossæ and the process of the dura mater, called the tentorium cerebelli. It is placed (see *fig.* 282) at the top of and behind the spinal cord, and the isthmus of the encephalon. It is covered by the cerebrum in the human subject only, whence the name *cerebrum inferius.* It is posterior to the brain in the lower animals, and is therefore called *cerebrum posterius.*

The dura mater, the arachnoid, and the pia mater form a threefold investment around it, the arrangement of which has been already described.

Size and Weight.—The cerebellum is larger in man than in any other species. It has been stated by Cuvier, that its size in the human subject is so exactly proportioned to that of the brain, that correct tables may be formed of their relative weights; but it appears to me that facts are opposed to this view.

The mean weight of the cerebellum, including the pons Varolii and medulla oblongata, is from four to five ounces; the proportion between the cerebrum and cerebellum may be estimated approximately to be as 7 to 1.*

According to Gall and Cuvier, the cerebellum of the female is proportionally larger than that of the male. Gall believes that its size is in a direct ratio with the energy of the generative function, and that this is indicated externally by the relative size of the inferior occipital protuberances.†

The cerebellum is proportionally much smaller in the infant than in the adult; the relation between the cerebrum and cerebellum in the infant is as 20 to 1.

Density.—The consistence of the cerebellum has been much studied by anatomists, who are far from being agreed upon this subject. The great difficulty depends upon the want of accurate means of estimating its consistence. In fact, it may be readily conceived that the conversion of its substance into a pulp, by letting weights fall upon it from a determinate height, is at once a most inconclusive and almost inapplicable method of ascertaining the point. Another source of difficulty consists in the fact that the cerebellum is not homogeneous; so that results obtained in reference to the gray matter do not apply to the white substance. Out of fifty cerebella which Malacarne compared with the corresponding brains, twenty-three were softer than the brains in both the medullary and cortical substances; in thirteen the cortical substance was equally firm, but the medullary substance more consistent and elastic than that of the brain; ten were more dense in texture, and the remaining five were much harder than the corresponding brains. In some cerebella one of the hemispheres was much more firm than the other.

The results of my observations are, that the medullary centre of the cerebellum is of a firmer consistence than that of the cerebrum; that the gray substance of the cerebellum is softer than that of the cerebrum; and that the gray substance of the former becomes softened in the dead body with such extreme rapidity, that it is difficult to meet with a cerebellum in which this substance is in the normal state.

Form.—The general outline of the cerebellum is that of an ellipsoid flattened from above downward; its long diameter is transverse, and measures from three and a half to four inches; its antero-posterior diameter is from two to two and a half inches, and its vertical diameter two inches in the thickest part, and about six lines in the thinnest part, that is, at its circumference. The figure of the cerebellum may also be compared to that of a heart on playing cards, the notch of which is directed backward, and the truncated apex forward; or, rather, as was done by the old anatomists, to two flattened spheroids, united together at their points of contact.

The cerebellum is perfectly symmetrical, but yet a marked difference between the right and left half of this organ is not unfrequently observed.‡

The cerebellum presents for our consideration an upper and a lower surface, and a circumference.

The *upper surface* (*h h, fig.* 280) presents along the median line an antero-posterior eminence (*d*), which is rather prominent in front, but gradually disappears as it extends backward: it is named the *superior vermiform process* (*vermis superior*). This eminence, which covers the valve of Vieussens and the tubercula quadrigemina, should be regarded, as Malacarne states, as the upper part of the *median lobe of the cerebellum.*

On each side (*h h*) the upper surface of the cerebellum forms an inclined plane. This surface is separated from the posterior lobe of the cerebrum by the tentorium cerebelli.

* Chaussier says, "In a considerable number of comparative experiments, we sometimes found that the adult cerebellum was $\frac{1}{6}$th or $\frac{1}{7}$th, and at other times, but rarely, $\frac{1}{10}$th or $\frac{1}{11}$th the weight of the cerebrum. In the infant, at birth, we found it to be $\frac{1}{13}$th, $\frac{1}{14}$th, $\frac{1}{17}$th, $\frac{1}{21}$st, $\frac{1}{26}$th, and, in one case, even $\frac{1}{33}$d the total weight of the brain."—(*De l'Encéphale*, p. 77.)

† In my opinion, this idea can only be regarded as an ingenious hypothesis. The aptitude for the generative act is not dependant upon the cerebellum, for all invertebrate animals are destitute of this organ; and in certain vertebrata, where the generative orgasm is quite remarkable, the cerebellum is extremely small. Some observations, however, are quoted, which appear to show that diminution of the occipital protuberance has followed extirpation of the corresponding testicle: but it must first be proved that these observations are correct; for example, that the inequality of the occipital protuberances did not exist previously to the castration.

‡ In four cases which have come under my own observation, atrophy of the right hemisphere of the cerebrum coexisted with atrophy of the left hemisphere of the cerebellum; I am, therefore, led to conclude that there are certain intimate relations between the opposite hemispheres of these two portions of the encephalon.

The *lower surface* of the cerebellum (*figs.* 275, 276) is received into the concavity of the occipital fossæ, to which it is exactly fitted: it is divided into two rounded, lateral halves (*h*, *fig.* 275), the lobes of the cerebellum, by an antero-posterior fissure (*a* to *n*), the *great median fissure of the cerebellum* (vallecula, *Haller*).

The back part of the cerebellum is completely subdivided by this fissure (see *fig.* 282), which receives the falx cerebelli; in front, the fissure opens into a wide furrow, into which the medulla oblongata is received (see *fig.* 276); in the middle of the fissure is a lozenge-shaped interval, at the bottom of which is seen the base of a pyramidal eminence (*a b c*, *fig.* 275), divided transversely into rings like a silkworm, and named, accordingly, by the older anatomists, the *inferior vermiform process* (*vermis inferior*, *pyramid* of Malacarne). This eminence is developed into four prolongations or branches, arranged in the form of a cross; the posterior prolongation (*c*) is tapering, and occupies the back part of the great median fissure; the two lateral processes dip (on each side of *b*) into the adjacent portion of the fourth ventricle; and the anterior (*b*) tapers from behind forward, and terminates in a mammillary enlargement (*a*), which is free, and projects into the fourth ventricle. It has been unnecessarily distinguished from the rest of the inferior vermiform process by Malacarne and Chaussier, under the name of the *laminated tubercle of the fourth ventricle* (*tubercle lamineux du quatrième ventricule*).*

Fig. 275.

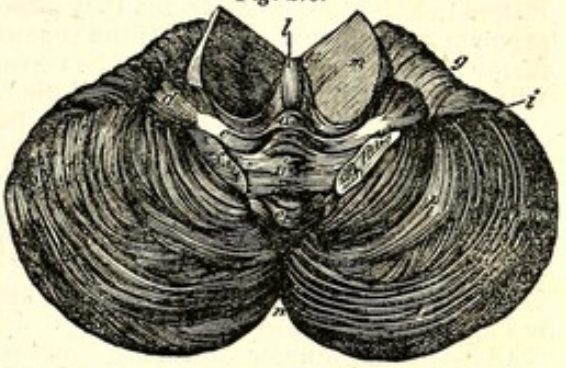

The inferior vermiform process is merely the lower part of the *median lobe of the cerebellum*, of which the superior vermis constitutes the upper part. The superior vermis is continuous, without any line of demarcation, with the two hemispheres of the cerebellum, so that the upper part of that organ appears undivided. The inferior vermis, which seems at first sight to be intended to separate the two hemispheres, nevertheless forms the means of connexion between them, as may be easily seen by drawing them apart from each other.

The *circumference* of the cerebellum is somewhat elliptical, or, rather, resembles the heart upon playing cards; behind and in the middle line it presents a *notch* (*n*), between the convex margins of which a triangular interval is left, into which the falx cerebelli and the internal occipital crest are received. At the bottom of this notch the surface of the cerebellum is transversely grooved; this part unites the superior to the inferior vermiform process, and belongs to the median lobe of the cerebellum.

The rounded margins of the *notch* are continuous with the circumference of the cerebellum. In front, the circumference of the cerebellum appears to be formed by the pons Varolii (*d*, *fig.* 276) and middle cerebellar peduncles (*m*), which are in relation with the posterior surface of the petrous portion of the temporal bones, and are therefore straight, and form a truncated angle, which projects forward, and corresponds to the pons Varolii.

All the bundles of fibres which connect the cerebellum with the cerebrum and spinal cord enter at the anterior part of its circumference: thus, besides the middle peduncles of the cerebellum, we find in this situation its superior peduncles (*r*, *fig.* 272), or *processus ad testes*, and its inferior peduncles (cut at *n*), or *processus ad medullam oblongatam*, to which we shall presently return.

The Furrows, Lobules, Laminæ, and Lamellæ of the Cerebellum.

The whole surface of the cerebellum is traversed by curved lines or furrows, which are, for the most part, concentric and horizontal, but not very regular.

These furrows are not parallel, but are inflected towards each other, and intersect at very acute angles.

They may be divided into four sets, according to their depth. The first set of furrows are the deepest: they reach as far as the central nucleus, and divide the cerebellum into *segments* or *lobules* (*g*, *h*, *l*, *fig.* 275).

These segments are divided into *secondary segments* by the second set of furrows.

The secondary segments are again subdivided into *laminæ* or *folia*, and these laminæ into *lamellæ*, by two sets of yet smaller furrows.

Pourfour du Petit, Malacarne, and Chaussier have studied the segments, laminæ, and lamellæ of the cerebellum with great care, and have even counted them. The differences in their results† are not so much a proof of varieties in the structure of the organ as of the want of some uniform method of enumeration.

* [The inferior vermiform process is usually described as consisting of three portions: the *pyramid* (*c*, *fig.* 275), the *uvula* (*b*), and the *nodulus* (*a*).]

† Winslow admitted 3 lobules, Collins 6, Pourfour du Petit 15, Malacarne 11, and Chaussier 16. Chaussier counted 60 laminæ, and from 600 to 700 lamellæ; Malacarne had previously counted from 700 to 800 lamellæ. It is a very curious fact that Malacarne only found 324 lamellæ in an individual labouring under mental alienation

The segments which occupy the circumference of the organ are the largest: they represent segments of an ellipsoid, and are very broad in the middle, and narrowed at each extremity. The segments of the upper surface are concentric, and their curvature corresponds to that of the entire cerebellum. The segments of the lower surface are also concentric in each half or lobe of the cerebellum, but the curves of one side are independent of those of the other.

The laminæ or folia of the cerebellum are applied to each other like the leaves of a book; they are separated from each other in their whole length, and are attached to the rest of the cerebellum by their adherent borders only. The lamellæ, however, are arranged in a different manner, for they pass from one lamina to another, and even from segment to segment. In fact, if the segments of the cerebellum be drawn asunder, the furrows between them are seen to be traversed obliquely by a great number of lamellæ, which extend from one segment to another.

The arrangement of the segments, laminæ, and lamellæ in the median line deserves particular attention. Opposite the superior vermiform process, they are not interrupted, but are merely bent slightly, so that the middle portion of each of the anterior segments is, as it were, drawn forward, so as to describe a curve, having its concavity turned backward. Upon this surface some slight peculiarities are observed in the arrangement of the parts. Along the median line there seems, indeed, to be an interchange of laminæ and lamellæ, some of each of which become thin, and end in points, from which others appear to originate.

Opposite the inferior vermiform process the two hemispheres of the cerebellum are connected together by means of the lateral prolongations of that process. But in front, *i. e.*, opposite the medulla oblongata, the two hemispheres of the cerebellum are perfectly distinct from each other (see *fig.* 275). From these facts we may estimate to what extent the comparison is correct which was drawn by Haller between the superior vermiform process and the corpus callosum.

At the back part of the cerebellum, opposite the notch in that situation, the two hemispheres are connected by means of certain small transverse rings, of which we have already spoken.

The superior and inferior vermiform processes and the portion situated at the bottom of the notch constitute together the *middle lobe of the cerebellum*, which Gall and Spurzheim named the *primitive* or *fundamental part of the cerebellum*, because it exists in all vertebrata, and because, in a great number of them (as in birds, reptiles, and fishes), where the lateral lobes of this organ are altogether wanting, it constitutes the entire cerebellum. It is well to add, that the lateral lobes are relatively larger, and the median lobe smaller in man than in other mammalia.

A rudimentary median lobe, and very large lateral lobes, are the characteristics of the human cerebellum, while a very large median lobe, and rudimentary lateral lobes, form the characters of the cerebellum of the lower animals.

All the segments of the cerebellum, of which there are from ten to twelve, might with propriety be distinguished by particular names. The following segments, however, require special mention: the *segment* or *lobule of the circumference* (*l*, *fig.* 275), which is the largest; the *lobules of the medulla oblongata* (lobuli medullæ oblongatæ), which are situated behind that part (see *fig.* 276), are concave on their internal surface, which is accurately adapted to the medulla, and convex on their external and posterior surface, which dips slightly into the foramen magnum. These lobules (removed from *f*, *fig.* 275), which have been noticed by all anatomists, are separated from one another by the inferior vermiform process (the uvula, *b*), and each of them terminates in front and on the inner side by a mammillated extremity (called the amygdala or tonsil), which partially fills up the fourth ventricle. The other inferior segments of each lobe of the cerebellum describe concentric curves around this segment. *The lobule of the pneumogastric nerve* (*d*) is a sort of prominent tuft (flocculus), situated (*u*, *fig.* 276) behind the pneumogastric nerve (8), and below the facial and auditory nerves (7).

The Internal Structure of the Cerebellum.

It is convenient to include under this head the description of the fourth ventricle, as well as that of the substance of the cerebellum.

The Fourth Ventricle.

Dissection.—Divide the median lobe of the cerebellum vertically; make a vertical section of the pons along the median line; draw asunder the medulla oblongata from the cerebellum. By means of the first section the anterior wall of the fourth ventricle is exposed, and by the second its posterior wall; by drawing apart the medulla oblongata and cerebellum, the ventricle is reached by its inferior extremity, and its whole depth can be seen. It is important to examine the fourth ventricle in all its aspects.

The *fourth ventricle* (*v* to *y*, *fig.* 282) is that rhomboidal cavity situated between the medulla oblongata and isthmus of the encephalon (*q n*), which forms its anterior wall, and the cerebellum (*w*), which constitutes its posterior wall. The old anatomists follow-

ed Galen in calling it the *ventricle of the cerebellum*. Tiedemann speaks of it as the *first ventricle*, because it is developed before the other ventricles, and is constant in all mammalia.

The fourth ventricle terminates in a point below, expands considerably in the middle, and is again contracted at its upper part, where it becomes continuous with the third ventricle.

We shall consider separately its anterior and posterior walls.

The *anterior* or *inferior wall* is formed by the posterior surface of the medulla oblongata (see *fig.* 271) and that part of the upper surface of the isthmus of the encephalon which corresponds to the pons. In shape it resembles a lozenge or diamond, truncated at its upper point; the upper borders of the lozenge being represented by the superior peduncles of the cerebellum (*r* to *g*), and the lower by the restiform bodies (*e*): the posterior surface of the re-enforcing fasciculi (*faisceaux innominés*) of the medulla oblongata constitutes this anterior wall, which is lined by a dense and easily separable membrane.

The *posterior* or *superior wall* represents a vaulted roof, which is formed above by the superior peduncles of the cerebellum (*r* to *g*) and the valve of Vieussens (*l*, *fig.* 271; *l*, *fig*, 275; *g w*, *fig.* 282), lower down by the cerebellum (*w*), and below by a fibrous membrane, continuous with the neurilemma of the spinal cord.

Opposite the middle, *i. e.*, the broadest part of this posterior wall (see *fig.* 275), are situated three mammillary projections—one median and two lateral: the first (*b*, the uvula) is the anterior segment of the median lobe of the cerebellum; the other two (the amygdalæ) are formed by the innermost laminæ of the lobule of the medulla oblongata (cut away at *f*). These latter are not bathed in the fluid of the ventricle, but are separated from it by the fibrous membrane lining that cavity.

The median mammillary projection (*b*), named by Malacarne and Chaussier the *laminated tubercle of the fourth ventricle*, resembles a movable valve. It is attached to the cerebellum by two white pedicles, which pass outward and backward upon the lateral processes of the crucial eminence formed by the inferior vermis. Connected to its anterior extremity (the nodulus, *a*) are seen two broad folds (*semilunar folds*, *c*), which arise from it, one on each side, and become continuous with the roots of the corresponding sub-peduncular lobules or flocculi (*d*).

These folds, which are quite distinct from the valvulæ Tarini, are extremely thin and semi-transparent; their convex borders adhere to the back part of the fourth ventricle; the concave margins and their two surfaces are free.* The two semilunar folds and the intermediate projection, or the nodule, may be compared to the soft palate, the mammillary projection representing the uvula.†

Opposite the *upper angle* of its rhomboidal cavity, the fourth ventricle (*v*, *fig.* 282) becomes continuous with the third (*l*), through a canal, named *iter à tertio ad quartum ventriculum*, or the *aqueduct of Sylvius*, which, however, had been described by Galen: this aqueduct is formed beneath the tubercula quadrigemina (*f g*) and the valve of Vieussens (*g w*).

The *lateral angles* of the fourth ventricle are much elongated, and reach as far as opposite the inner extremity of the corpus dentatum of the cerebellum.

At the *inferior angle* (*y*) of the fourth ventricle is situated a fibrous layer, which constitutes its floor, and also an orifice of communication between the ventricle and the sub-arachnoid space.

The Fibrous Layers of the Fourth Ventricle.

Floor of the Fourth Ventricle.—On carefully drawing the medulla oblongata away from the cerebellum, a fibrous layer is seen extending from one to the other, and forming, as it were, the floor of the fourth ventricle. This layer, which is continuous with the neurilemma of the medulla oblongata, consists of three very distinct parts: of a median portion, shaped like a triangular tongue, which passes horizontally backward, and is applied to the anterior extremity of the inferior vermis, to which it adheres; and of two triangular lateral portions, which form the sides of the orifice of the fourth ventricle, and which were described by Tarin as the *valves of the base of the fourth ventricle*.

Besides this fibrous layer, there is another on each side, situated behind the roots of the pneumogastric nerve: these layers adhere to those roots, and we shall therefore name them the *fibrous layers of the pneumogastric nerves*; they close the fourth ventricle upon the sides of the medulla oblongata, and when they are removed the ventricle is quite open. They extend from the restiform bodies to the lobules of the pneumogastric nerves, and are prolonged upward upon the auditory nerves.

The Inferior Orifice of the Fourth Ventricle.

If the medulla oblongata and cerebellum be drawn apart, there is seen in the median

* [These two folds constitute the posterior medullary velum of the cerebellum, the valve of Vieussens forming the anterior velum.]

† [The terms uvula and amygdalæ, or tonsils, have, as already noticed, been applied to another series of three bodies which are arranged behind the nodule, the flocculi and the posterior vela, and consist of the laminated tubercle of the fourth ventricle, and of the inner portions of the lobes of the medulla oblongata (see p. 718).]

line, between the inferior cerebellar arteries, a lozenge-shaped opening (at *y*, *fig.* 282), bounded, in front, by the base of the calamus scriptorius; behind, by the anterior prolongation of the inferior vermiform process, which is covered by the median tongue of the fibrous layer; and upon the sides, in front, by the ragged edges of the lateral portions of the fibrous layer, and by the internal surfaces of the lobules of the medulla oblongata.

This opening was pointed out by M. Magendie as establishing a communication between the general ventricular cavity and the sub-arachnoid space. It has been asked, Is it a natural opening, or is it produced accidentally by the very means employed in its demonstration? The following are the arguments on both sides of the question:

In opposition to the existence of an opening in this situation, it is urged that the margin of the orifice has none of the characters of that of a natural opening, the edges of which are generally smooth and rounded; but in this orifice they are lacerated, and there is almost always some membranous shreds at the point of the calamus scriptorius. If the median triangular tongue of the fibrous layer, which is applied to the inferior vermis, be detached, it is seen to be merely a flap of that membrane, the size of which exactly corresponds to that of the opening, so as to close it completely. This point may be rendered still more evident by tracing the membrane from before backward, after having divided the pons and medulla oblongata.

Again, the fibrous layer, which forms the floor of the fourth ventricle, is entire in the dog and sheep; I have found it in the same condition five or six times in the human subject; and if it be objected that, in this case, there might have been an accidental obliteration of the opening, I could answer that there was no trace of disease, either in the cerebro-spinal axis, or in the membranes.

I may also mention that, in several cases of chronic hydrocephalus, several pounds of fluid were found in the ventricles, and none whatever in the sub-arachnoid space.

Lastly, in the brains of several infants, who had died with all the symptoms of acute ventricular hydrocephalus, I have found the lateral ventricles very large, but empty; and in these cases, it has occurred to me that the fibrous layer might have been perforated opposite the inferior angle of the fourth ventricle, and have thus allowed the fluid to escape, which, in the greater number of cases, is retained by this layer within the ventricular cavity.

Such are the facts which appear to me to militate against the idea of the existence of an opening in the floor of the fourth ventricle; but, on the other hand, if we consider that, in an immense majority of instances, whatever care may be taken in removing the brain from the cranium, we always find this opening both in the fœtus and in the adult; that in apoplectic effusions into the ventricles, we always find some bloody serum in the sub-arachnoid space; and that if a coloured fluid be injected into the ventricles of the cerebrum, or into the sub-arachnoid space around the cord, it will in either case pass freely from one into the other, we shall be led to conclude that there is a regular communication between the cavity of the ventricles and the sub-arachnoid space, and that the orifice just described is the channel of communication between them.*

The Choroid Plexuses of the Fourth Ventricle.

The *choroid plexuses of the fourth ventricle* are two in number; they commence one on each side, by a very slender extremity, upon the anterior surface of the sort of fibrous tongue which is attached to the inferior vermis; from this point they pass in a diverging course upward, are then inclined outward, turn round the sides of the median eminence of the fourth ventricle, pass horizontally outward behind the restiform bodies, and then behind the fibrous layer of the corresponding pneumogastric nerve, where they become considerably enlarged, and at length terminate upon the sub-peduncular lobes.

The inner surface of the fourth ventricle is smooth, in consequence of being lined by a membrane resembling a serous membrane, which is much stronger over the posterior surface of the medulla oblongata than at any other point.

Sections of the Cerebellum.

On cutting through the cerebellum, it is found to be composed (see *figs.* 273, 274) of two substances, an *external cortical* or *gray* substance, and a *central* or *medullary* substance, which is *white;* the gray substance is soft, and is almost always torn off with the membranes, however slightly the cerebellum may be altered by decomposition. The white substance is compact, and resists a tolerably firm pressure.†

Between the gray and white substances there is seen, upon a section of the cerebellum, a narrow yellowish band or streak, which depends on the existence of a layer of a yellow substance, of much greater firmness than the gray matter, and strongly adherent to the white substance. By laceration the gray matter is destroyed, and this yellow layer is exposed. There are, therefore, three substances in the cerebellum: the *gray*, the *yellow*,

* See note on the sub-arachnoid space (p. 690).

† For an account of the minute structure of these substances, see note, p. 701.

and the *white*. I would compare the yellow layer of the cerebellum to the yellow folded membrane of the olivary bodies.*

A question here arises, What is the proportion between the gray and the white matter? The most superficial examination of the cerebellum will show that the gray matter predominates; and this can be clearly demonstrated by macerating the cerebellum for several days. The gray matter, which is more easily decomposed, becomes converted into a pulp, and the remaining nucleus of white substance scarcely represents a third, either of the weight or bulk of the cerebellum.

We shall now proceed to describe the appearance of vertical and horizontal sections of the cerebellum.

Vertical Sections.

Upon *longitudinal vertical sections* of the cerebellum, the gray and white substances present a very elegant arrangement, known by the picturesque name of the *arbor vitæ*; a title derived either from the importance which has been attached to this structure, or from its resemblance in figure to the foliage of the tree so called. Upon a section made through the median line, the *arbor vitæ of the middle lobe* (*w*, *fig.* 282) is seen; and upon one made on either side, the *arbor vitæ of the lateral lobes*.

The *arbor vitæ of the median lobe* consists of a central nucleus of white substance, of a triangular form, from which two principal branches proceed: one inferior, which is distributed to the whole of the inferior vermis and the back part of the median lobe; the other superior, which passes into the whole of the superior vermis. These two branches subdivide into six others, which vary in direction, length, and thickness, and are themselves subdivided into still smaller branches, and these, again, into the smallest ramifications. A slight enlargement of the white substance is always observed opposite the points of division.

A very thin yellowish layer, and outside this a layer of gray matter, about a line in thickness, covers each of the ramifications of the white substance, and thus forms the lamellæ, laminæ, and segments of the median lobe.

This section enables us to prove the existence of the middle lobe of the cerebellum and the continuity of the superior and inferior vermis; it also shows the general form of the middle lobe, which is rotate or wheel-shaped (the anterior extremity of the inferior vermis, *i. e.*, the nodule, comes into contact with the valve of Vieussens); the number and arrangement of the segments, laminæ, and lamellæ of the cerebellum; and, lastly, the nature of the valve of Vieussens, which is nothing more than the uppermost subdivision of the central nucleus, and may be regarded as one half of a lamella of the cerebellum.

The Arbor Vitæ of the Lateral Lobes.—A vertical section from the middle peduncles of the cerebellum towards the circumference displays the arbor vitæ of the lateral lobes.

In the centre of each lobe is seen a white central nucleus, from which fifteen or sixteen principal branches are given off, to form the nuclei of a corresponding number of the segments. These branches are subdivided into secondary branches, and those into the ultimate ramifications. A yellowish layer covers each of these successive divisions, and upon that a gray layer, about a line in thickness, is accurately moulded.

Upon sections of this kind it is easily seen that the segments of the cerebellum are very unequal in size, in direction, and in their manner of division; that the superior segments are the smallest, the segments of the circumference the largest,† and the inferior segments of an intermediate size; that there is no vacant space between the segments, but that both laminæ and lamellæ occupy the intervals; and, lastly, that all of these segments curve forward upon themselves, so as to form a series of horizontal wheels or circles, the plane of which is at right angles to that of the wheel-shaped mass of the middle lobe.

In the centre of the white nucleus of each half of the cerebellum is the *corpus rhomboideum*, or *corpus dentatum*:‡ these bodies are of an ovoid form; their yellowish investing layer is dense, and folded backward and forward upon itself, and exactly resembles that of the olivary bodies; and I have been accustomed to speak of these bodies as the olivary bodies of the cerebellum. Gall and Spurzheim regarded them as ganglions of re-enforcement, and called them the *ganglions of the cerebellum*. Their shortest or vertical diameter is about one third of their long or horizontal diameter; in one case, where the latter was fifteen lines, the former was five lines: moreover, the size of the corpora dentata of the cerebellum varies in different subjects, and is in proportion to the size of

* Rolando (*Osservazioni sul' Cervelette*, p. 187, 1823) appears to me to have been the first to establish the fact of the existence of three substances: the *medollare*, the *cinereo rossigna*, and the *cinerea esterna e corticale*.

† The segment of the circumference, which is the largest of all, immediately divides into two smaller segments; it has been incorrectly stated that there is a horizontal fissure along the circumference of the cerebellum, extending from one of the middle peduncles to the other.

‡ In order to divide the corpus dentatum, the section must be made opposite the corresponding inferior peduncle of the cerebellum. I would recommend that one section be made to extend through the corpus dentatum of the cerebellum, and also through the olivary body, so that some idea may be formed of the analogy between these two parts.

the lateral lobes of that organ: they are, therefore, much less developed in the lower animals than in man.

The *peduncles of the cerebellum* are six in number, three on each side, namely, a *superior*, a *middle*, and an *inferior*; they all originate, or, it may be said, terminate in the central nucleus.

The *superior peduncles of the cerebellum* are generally known as the *processus cerebelli ad testes*; they are seen (*r*, *fig.* 280) in front of the superior vermiform process, and seem to pass up to the tubercula quadrigemina. We shall afterward see that this is only apparent.

The *inferior peduncles* (*processus cerebelli ad medullam oblongatam*) are, in fact, the restiform bodies; they establish a direct and intimate communication between the cerebellum and the spinal cord.

Lastly, the *middle peduncles* (*m*, *fig.* 276), which are anterior to the two preceding sets, occupy the fore part of the circumference of the cerebellum, and are continued into the pons Varolii without any line of demarcation. They are called also the *cerebellar peduncles* (*processus cerebelli ad pontem*), and the *crura* or legs of the medulla oblongata.

Horizontal Sections.

Horizontal sections of the cerebellum have been studied with very great care, and have been well figured by Vicq d'Azyr; they show that the dimensions of the central nucleus are much greater in the horizontal than in the vertical direction.*

Upon these sections, which should be made parallel to the upper surface of the cerebellum, is seen the relative disposition of the laminæ, which are sometimes parallel and sometimes oblique in reference to each other, and which either extend around the entire circumference of the organ, or terminate in tapering extremities and again commence, and pass from one segment to another.

Lastly, these horizontal sections show the continuity of the right and left lobes of the cerebellum by means of the middle lobe. In this middle lobe the lamellæ are more irregular than in the lateral lobes; they intersect each other at various angles, and become again united into new combinations, so that several anatomists have admitted the existence of a true decussation in this middle portion of the cerebellum.

The middle lobe also has its medullary centre, which connects the lateral medullary centre in such a manner that, by a successful section, a sort of cerebellar centrum ovale is obtained, analogous to the centrum ovale of Vieussens in the cerebrum.

Examination of the Cerebellum by means of a Stream of Water, and Dissection of the Hardened Cerebellum.

A stream of water directed upon vertical sections of the cerebellum decomposes the white nucleus of each lateral lobe into a great number of extremely thin leaves, which constitute the different laminæ or lamellæ of the cerebellum. All these laminæ and lamellæ terminate in the central nucleus of the corresponding lobe. Each lamella is fan-shaped, its adherent border being very narrow, concave, and applied to the central nucleus, with which it is evidently continuous, while its convex margin corresponds to the surface of the cerebellum. The arrangement of these lamellæ is very beautiful and curious: some of them ascend to form the segments, laminæ, and lamellæ of the upper surface of the cerebellum; others descend to form the corresponding parts of the lower surface, and the intermediate ones pass horizontally to the circumference, and are disposed in a similar manner. Opposite each point of subdivision there seems to be an enlargement of the white substance, but this depends not upon an actual increase of that substance, but upon the divergence of the lamellæ.

The structure of the cerebellum, therefore, considered generally, is laminated. From the central white nucleus proceed innumerable laminæ, which, though in juxtaposition, are never blended together, and which form groups, that are themselves subdivided again and again, like the branches of a tree, the ultimate lamella always containing at least two leaflets. Can anatomy teach us anything beyond this laminated arrangement? In each lamella certain radiated striæ are seen; and it may be asked, Whether these prove the existence of a linear or fibrous structure? It is certainly true that the lamellæ may be divided in the direction of these striæ, but it is far from being evident that they consist of linear fibres.

In the central nucleus, the laminæ, being more firmly pressed together, are separated by the stream of water with greater difficulty than the laminæ near the surface: the corpora dentata of the cerebellum are peculiarly firm. The stream of water insinuates itself into these bodies opposite their internal extremity, which appears to be naturally open, and divides them into two halves, a superior and an inferior. It is then seen that the dentated appearance of their section results from the reduplication of the dense yellowish layer in which they are enclosed; also, that the white substance penetrates into the interior of these bodies at their internal surface, accompanied by a great number of

* In each lobe of the cerebellum there is a *medullary centre*, that is, a spot in which the section of the white substance is larger than at other points.

vessels; and that this white substance is arranged in lamellæ, which terminate at three different points of the yellowish layer, so that each of the corpora dentata resembles a small cerebellum.

Examination of the Hardened Cerebellum.—The examination of the cerebellum, when hardened by alcohol, or by boiling in oil, or salt and water, or by maceration in a solution of salt and bichloride of mercury, of the strength recommended by Rolando, confirms all the results which have been obtained by the preceding method of investigation.

These modes of preparation, moreover, enable us to examine more completely than in any other way the relations of the central nuclei of the lobes to the peduncles of the cerebellum. It is seen most distinctly that these peduncles (*m n, fig.* 273; *n r, fig.* 274) emerge from or terminate in the central nuclei (*p p*), but it is very difficult to ascertain their precise arrangement within the nuclei. All that we know is the fact that, as soon as they emerge from the central nuclei, they assume a fasciculated character, and that all the lamellæ and laminæ of the cerebellum seem to terminate in the fibres of the middle peduncles.

General View of the Cerebellum.

From the preceding statements we may draw the following conclusions: The cerebellum consists of two lateral lobes and a middle lobe; the lobes are formed by a considerable number of segments, which are subdivided into smaller segments, and these into laminæ and lamellæ; each lobe contains a central medullary nucleus, upon which all the segments rest, and which constitutes the termination or the origin of the several peduncles; the substance of these peduncles is fibrous or fasciculated, and that of the central nucleus has a similar character, but not so well marked; the medullary substance of each segment is formed by laminæ applied to each other, but not actually continuous; each of these laminæ is fan-shaped, and those which constitute the central nucleus of each segment become separated from each other to form the secondary segments, the laminæ, and the lamellæ; the ultimate lamellæ of the cerebellum consist of two leaflets of white matter covered externally by a very thin yellowish layer, which is itself covered by a rather thick layer of gray matter;* the corpora dentata, or olivary bodies of the cerebellum, consist of fibres or laminæ of medullary substance, which are spread out so as to terminate at different points upon the inner surface of the dense yellow membranous layer which constitutes their external investment.

A very ingenious explanation of the structure of the cerebellum has been proposed by Gall, and is now rather generally adopted.

The opposite directions of the inferior and middle peduncles of the cerebellum suggested to him the idea of *diverging and converging fasciculi*, and to this he has added his theory regarding the ganglia, which he considered as apparatuses of re-enforcement, that is to say, as points of origin for new fasciculi.

According to Gall, then, the inferior peduncles of the cerebellum or the restiform bodies (*n, fig.* 274), which he calls the *primitive fasciculi of the cerebellum*, are the roots, or fasciculi of origin of the cerebellum. After they have penetrated a few lines into the substance of the organ, they meet with and join the corpus dentatum, which Gall regards as a *true ganglion*, or *apparatus of origin and re-enforcement for a great part of the nervous mass of the cerebellum.* According to him, a principal nervous fasciculus corresponds to each of the folds of the corpus dentatum, from which ganglion arise all those prolongations of medullary substance which, together with the gray matter upon them, constitute the middle and lateral lobes of the cerebellum.

Besides the preceding fasciculi, which are named by Gall the *diverging fasciculi*, and are said by him to constitute the *formative system* of fibres, there are certain *converging fasciculi*, which constitute the *uniting system of fibres*, or the *commissures of the cerebellum.* These are supposed to have no direct connexion either with the primitive fasciculi or the corpus dentatum, but to emanate from the gray matter upon the surface of the cerebellum, and to pass in different directions (*p q, fig.* 273) between the diverging fasciculi, so as to enter into and constitute the middle peduncles of the cerebellum (*m*) and the pons Varolii, which Gall regarded as forming together the commissure of the cerebellum.

The superior peduncles of the cerebellum (*r'*, *fig.* 274) he considered as fasciculi of communication between the middle median lobe of the cerebellum and the corpora quadrigemina, and the valve of Vieussens as the commissure of these peduncles.

We can only regard Gall's view concerning the structure of the cerebellum as an ingenious speculation. Why should the inferior fasciculi be the roots or primitive bundles of the cerebellum rather than the superior? Who has seen the re-enforcement of these primitive fasciculi in the corpus dentatum? Why should the corpus dentatum be regarded as a ganglion? Whence is this distinction between converging and diverging fasciculi?† and, finally, Why are figure and metaphor employed in reference to strictly anatomical questions?

* [The white substance of the laminæ is said to consist of two sets of fibres—one coming from the central mass, and passing up the centre of the laminæ, and the other set lying upon the first, and passing from one lamina to another.]

† "These converging fibres," says Tiedemann (French translation by Jourdan, p. 169), "are merely chimer-

Another theory regarding the structure of the cerebellum has been offered by Rolando, who, by combining the results derived from an examination of the human cerebellum, when hardened in a strong saline solution, with those furnished by the anatomy of the brain of the shark, and those obtained by studying the development of the brain of the fowl, was led to regard the human cerebellum as formed by the folding and refolding upon themselves of the parietes of a large bladder or vesicle, so as to give rise to innumerable laminæ.*

The facts we have already stated sufficiently refute this hypothesis. It is quite certain that the cerebellum is formed by the union of one middle and two lateral lobes : the lobes themselves are composed of a considerable number of segments, which are subdivided into smaller segments, laminæ, and lamellæ. The general structure of the cerebellum is laminated, and these laminæ are striated ; each lamella contains two leaflets of white substance covered with gray matter. The cerebellum is connected with the medulla oblongata by the inferior peduncles, and with the brain by the superior peduncles ; the middle peduncles and the transverse fibres of the pons establish an intimate connexion between the two lobes of the cerebellum.†

Development of the Cerebellum.

The cerebellum does not appear until some time after the spinal cord : it consists, at first, of two laminæ and plates prolonged from the cord, which approach each other towards the median line ; these are the inferior peduncles of the cerebellum, or the restiform bodies. The human cerebellum in this condition has a close resemblance to the same organ in fishes and reptiles. At the fourth month, the cerebellum forms a sort of uniform girdle, four lines in width, around the tubercula quadrigemina and the medulla oblongata ; the pons Varolii is already visible ; there is a rudiment of the corpus dentatum, and the surface of the cerebellum is entirely devoid of fissures. At the fifth month there are four transverse fissures : a vertical section of the cerebellum presents five branches ; but there are as yet neither laminæ nor lamellæ, nor is there any distinction between the middle and lateral parts. At the sixth month, the cerebellum is divided by the posterior notch, the different orders of fissures are visible, and the corpus dentatum has acquired considerable size. During the last three months of intra-uterine existence, the lateral lobes generally acquire that predominance over the middle lobe which is found to hold after birth.

As the development of the spinal cord precedes that of the cerebellum, and as the cerebellum appears to be formed by a prolongation of the posterior fasciculi of the cord, does it follow that that organ is a production or an expansion of the cord ? Certainly not ; all that we can conclude is, that they are developed in succession.

Reil and Tiedemann have advanced the opinion that the cerebellum is secreted by the pia mater, and that the gray matter is deposited the last ; but this is only an assertion without demonstration.

The cortical substance is formed at the same time as the medullary, and neither of them can be considered as the product of the other.

Comparative Anatomy of the Cerebellum.

In fishes the cerebellum is generally small, but in the ray and shark it is large, subdivided into convolutions, and prolonged above the optic lobes in front, and above the lobe of the eighth pair of nerves behind. In the silures, as Weber has observed, the cerebellum is relatively as large as the human cerebrum ; for it covers the posterior half of the cerebral lobes, as the cerebrum in man covers the cerebellum. In all fishes the cerebellum contains a considerable cavity. In some of this class of animals it is subdivided into segments, laminæ, and lamellæ.‡

Reptiles.—There is no cerebellum in the *batrachia* (as in the frog, toad) and ophidia (serpents) ; most anatomists, however, admit its existence in a rudimentary state. It is very small, and shaped like a roof, or vaulted, in the chelonians (tortoise) ; it is very long in the saurians (lizard, crocodile).

Birds.—The cerebellum is very large, and represents an ellipsoid, having its long diameter directed vertically. It is deeply and regularly traversed by horizontal fissures, which are curved downward on the upper half, and upward on the lower half of the or-

ical ; for the pons Varolii, and the medullary fibres of which it consists, are found in the fœtus at the fourth month, that is, at a period when there are no laminæ nor lamellæ, nor even any leaflets covered with gray matter. Gall, therefore, assumes these converging fibres to originate from parts which do not appear until after those fibres themselves." The refutation of Tiedemann appears to me to be itself founded on an assumption, for there is no proof that the gray matter is formed after the white.

* Osservazioni sul' Cerveletto, p. 187. In the shark, the cerebellum consists of a gray and a white layer united together and folded a great number of times upon themselves.

† It is not yet ascertained whether the lateral halves of the cerebellum act upon the same or opposite sides of the body ; some cases, in which atrophy of one hemisphere of the cerebrum coexisted with atrophy of the opposite hemisphere of the cerebellum, would appear to show that the action of the latter is not crossed. The laminated structure of the cerebellum and its twofold composition suggested to Rolando the idea of comparing it to a voltaic pile, or electro-motive apparatus.

‡ [It is divided into segments by deep transverse furrows in some cartilaginous fishes.]

gan. They all terminate opposite two small tubercles or appendages, situated one at each extremity of the transverse diameter. Upon a section of the cerebellum of birds is seen an arbor vitæ, composed of white substance covered with gray matter.

Mammalia.—In the three classes already examined, the cerebellum has merely a middle lobe: in all mammalia there are also *lateral lobes*. They are at first small, like appendages, as in the rodentia, in which the cerebellum differs but little from that of birds; they gradually increase in size as we proceed upward in the scale, until they reach their highest state of perfection in man, the development of whose cerebrum and cerebellum exceeds that of the same parts in all the lower animals. In mammalia the size of the lateral lobes of the cerebellum is directly proportioned to that of the olivary bodies, the existence of which in this class Vicq d'Azyr has erroneously denied.

THE CEREBRUM, OR BRAIN PROPER.

Definition—Situation—Size and Weight—General Form.—The Superior or Convex Surface.—The Inferior Surface or Base—its Median Region, containing the Inter-peduncular Space, the Corpora Albicantia, the Optic Tracts and Commissure, the Tuber Cinereum, Infundibulum, and Pituitary Body, the Anterior Part of the Floor of the Third Ventricle, the reflected Part of the Corpus Callosum, the Anterior Part of the Longitudinal Fissure, the Posterior Part of the Longitudinal Fissure, the Posterior Extremity of the Corpus Callosum and Median Portion of the Transverse Fissure, and the Transverse Fissure.—The Lateral Regions, including the Fissure of Sylvius and the Lobes of the Brain.—The Convolutions and Anfractuosities of the Brain, upon its Inner Surface, its Base, and its Convex Surface—Uses of the Convolutions and Anfractuosities.—The Internal Structure of the Brain—Examination by Sections—Horizontal Sections showing the Corpus Callosum, the Septum Lucidum, the Fornix and Corpus Fimbriatum, the Velum Interpositum, the Middle or Third Ventricle, the Aqueduct of Sylvius, the Pineal Gland, the Lateral Ventricles, their Superior and Inferior Portions, the Choroid Plexus, and the Lining Membrane and the Fluid of the Ventricles—Median Vertical Section—Transverse Vertical Sections—Section of Willis.—General Remarks on this Method of Examining the Brain.—Methods of Varolius, Vieussens, and Gall.—Gall and Spurzheim's Views on the Structure of the Brain.—General Idea of the Brain.—Development.—Comparative Anatomy.

The *cerebrum* or *brain*, strictly so called, is that portion of the encephalon which occupies the whole of the cavity of the cranium, except the inferior occipital fossæ. It forms, as it were, the crown or summit of the spinal axis, surmounting it (*cerebrum superius*), and, at the same time, lying in front of (*cerebrum anterius*) the spinal cord, as the origin and termination of which it has been alternately regarded. By the pons Varolii and the anterior or cerebral peduncles it is intimately connected with the cerebellum and the spinal cord. The tentorium cerebelli completes the cavity in which it is enclosed, and separates it from the cerebellum, which is situated below its posterior lobes. The cranium, the dura mater, the arachnoid, and the pia mater form a fourfold investment for it.

Size and Weight of the Cerebrum.

The great *size* of the cerebrum is undoubtedly one of the most characteristic points in the structure of man: in several animals, the entire encephalon is relatively as large, and even larger (*ex.*, the canary bird, the sapajou, the dolphin); but in reference to the size of the brain properly so called, *i. e.*, of the cerebral hemispheres, even the most favoured animals are much inferior to man.*

In the adult, the weight of the cerebrum, detached from the cerebellum and the pons by a section through its peduncles, varies from two to three pounds.† I believe it to be impossible to construct a table of the comparative size and weight of the brain and of the body. Is it not evident, indeed, that one element in the comparison, namely, the weight of the body, is subject to great variety? Haller has recorded the results of all the calculations which have been made upon this subject, and the diversity of those results is the best comment that can be made upon this mode of comparison.

These remarks do not apply to the relative proportions between the cerebrum and

* The weight of the cerebrum of the horse and the ox is scarcely half that of the human cerebrum.

† [From the statements given by Tiedemann (*Hirn des Negers*, &c., p. 6, Heidelb., 1837), it appears that the prevalent weight of the brain (entire encephalon) in the adult male is about from 44 to 48 oz. troy: in the adult female, from 40 to 44 oz. The results deducible from Dr. Sims's tables do not materially differ from the above.

In thirty-nine males, varying in age from 22 to 80, Tiedemann found the minimum weight of the brain 38 oz. 20 gr., the maximum 59½ oz.

In eleven females, from 20 to 80 years of age, the minimum was 32 oz. 5 drs. 50 grs., the maximum 46 oz. 2 drs.

The extremes, according to Dr. Sims's observations, were in about seventy males from 20 to 91 years, lowest, 33 oz. 80 grs.; highest, 54 oz. 6 drs., troy weight. In ninety females, between the ages of 20 and 89, the lowest was 27 oz. 80 grs., the highest 51 oz. 6 drs.]

cerebellum. According to my own observations, the weight of the cerebellum is from the twelfth to the eighth part of that of the cerebrum.*

It is important to obtain some approximation to the relative size of the brain in different individuals in the two sexes, and at different ages.

It results, from a great number of facts, that the size of the brain is independent of the stature of the individual; that the size of the brain is also independent of sex, although, since the time of Aristotle, it has been the custom to repeat that the female brain is smaller than that of the male; that in the fœtus and the infant the cerebellum is relatively much larger than the adult; and that in old age the brain is often atrophied like other organs, and then does not completely fill the cranial cavity.

Can the size of the brain be increased by exercise, and diminished by inaction? It cannot be doubted that the brain must, in this respect, obey the laws which regulate all other organs; but the bony parietes of the cranium must offer great obstruction to its development; indeed, examples have been recorded of compression of the brain, and even of death, produced by hypertrophy of this organ.

If it be true that the power of an organ depends upon its size, it follows that the size of the brain, and, consequently, the capacity of the cranium, must have a tolerably close ralation to the development of the cerebral functions; but the activity of these functions is connected with so many circumstances besides the size and quantity of brain, that any estimate of the intellectual powers founded exclusively upon these data is very often faulty and inexact.†

The specific gravity of the brain, as compared with that of water, is, according to Muschenbroek, as 1030 to 1000. It would be interesting to determine whether its specific gravity varies according to age and in disease, and also whether it differs in different animals. According to Sœmmering, the specific gravity of the brain in old persons is less than in those of middle age.

General Form of the Cerebrum.

The form of the cerebrum corresponds exactly to that of the cranial cavity, which is, as it were, moulded on it; it is, therefore, variable like that of the cavity itself, which, during early infancy, is capable of assuming all sorts of shapes from the application of external pressure.

If the entire cranial cavity, exceping the posterior occipital fossæ, be filled with plaster of Paris, an exact representation will be obtained of the general form of the brain which had been removed. The cerebrum, therefore, is like the cranium of an ovoid figure, having its large end turned backward, and its small one forward. It is divided on its under surface into *lobes*, which occupy the different compartments in the base of the cranium. The entire surface is marked by deep tortuous furrows (see *figs.* 276, 282), called *anfractuosities*, which occasion an appearance like that of the convolutions of the small intestines, and hence the term *convolutions* is applied to the eminences resembling folds, by which the anfractuosities are bounded.

The Superior or Convex Surface of the Brain.

A *median vertical fissure* running from before backward, called the *longitudinal fissure*, divides the cerebrum into two exactly similar lateral halves, which are improperly called *cerebral hemispheres*, for each of them resembles the fourth part of an ovoid; but would be more correctly designated the right and left brain, as was done by Galen.‡ The longitudinal fissure divides the cerebrum in its whole depth, both in front and behind (*x y*, *fig.* 277; also *fig.* 282); but in the middle it is interrupted by the *corpus callosum* (*d d*). There are two brains, as there are two spinal cords and two cerebella.§

The cerebrum is therefore *symmetrical*, but it is less completely so than the spinal cord; I should even say that a decided disproportion is very commonly observed between the right and left hemispheres. It does not appear that this want of symmetry exerts that influence upon the intellectual faculties which was imagined by the ingenious Bichat, whose own unsymmetrical brain was in direct contradiction to his doctrine. It is, nevertheless, possible that a want of symmetry, when carried to a certain point, may affect the intellect; in the brains of several idiots, their want of symmetry has been very re-

* In three young subjects I found as follows:

	lb.	oz.		oz.
Cerebrum	2	2	Cerebellum	4½
"	2	8½	"	3½
"	2	5	"	5

† Persons endowed with strong memories have always appeared to me to have large brains; and the part which the memory performs in the exercise of mind is of such a nature that we cannot be surprised if the persons alluded to are frequently men of superior intellect. I have known many persons, having heads of considerable size, who had merely a good memory, but none of the characteristics of genius. Those in whom the brain is large seem to me to resist the power of disease better than such as have small brains.

‡ Chaussier applies the term *lobe* to the hemispheres, reserving that of *lobule* for the secondary divisions.

§ Galen inquires why there should be two brains; and replies, that it is to ensure a more perfect performance of the cerebral functions. I have seen several hemiplegic individuals in whom the whole of one hemisphere was atrophied, but who, notwithstanding, possessed ordinary intellectual faculties.

markable. I have seen the longitudinal fissure of the brain deviate to the right or left side at an angle of from 15° to 20° degrees from its usual direction.

Each cerebral hemisphere presents three surfaces for our consideration:

An *internal surface* (*fig.* 282), which is flat, vertical, and separated from that of the opposite hemisphere by the falx cerebri; but as the falx does not extend so low as the corpus callosum, it follows that the two hemispheres are in contact below, the pia mater, however, intervening between them. In those rare cases of absence of the falx cerebri, the corresponding faces of the two hemispheres are in contact with each other throughout their whole extent. I have seen one case in which the falx was imperfect, and the two hemispheres were united.

An *external surface*, which is convex, and resembles the surface of the fourth part of an ovoid, having its great end directed backward; it corresponds to the concavity formed by the frontal, parietal, and occipital bones.

An *inferior surface*, which forms part of the base of the brain in general, and will be next described.

The Inferior Surface or the Base of the Brain.

The *base of the brain* (*fig.* 276), admirably described and correctly figured by Sœmmering in a special treatise upon the subject,* presents a great number of objects for our consideration. In order to obtain a perfect knowledge of it, it is advisable to examine it while the brain is still enclosed in its membranes, and placed in the scull-cap, with its base uppermost; and also upon a brain from which the membranes have been removed, and which is placed in the same position, but on a flat surface. In the former case, the parts forming the base of the brain are pressed together, and may be studied as a whole; and in the latter, they are separated, and may be examined in detail.

Fig. 276.

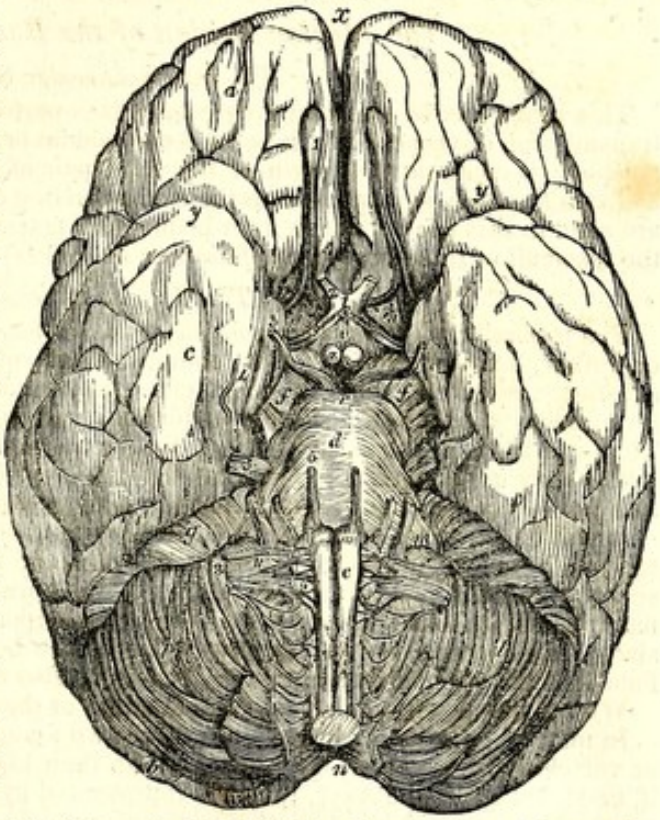

It is at its base that the brain is connected with the other parts of the cerebro-spinal axis by means of the right and left *peduncles* (*f f*), which may be regarded as the roots of the two hemispheres.

The Median Region.—In the median line, opposite the centre of the base of the brain, and in front of the pons Varolii (*d*), is situated an excavation, which may be called the *median excavation of the base of the brain.* This excavation has already been alluded to in the description of the arachnoid membrane and the sub-arachnoid fluid, with which this excavation is filled: it is formed by the brain being curved upon itself, and is partially effaced when that organ is placed with its base uppermost upon a flat surface: this excavation is of a pyramidal form, the apex being directed upward and the base downward. The borders of the excavation form a hexagon, and contain the arterial hexagon of the base of the cranium, named the *circle of Willis.* The posterior borders of the hexagon are formed by the peduncles of the brain, the lateral borders by the inner part of the posterior lobes [*c*, middle lobes†] of the cerebrum, and the anterior borders by the inner and back part of the anterior lobes (*a*) of the cerebrum.

From the six angles of this hexagon, six furrows proceed in different directions: from the anterior angle, the fissure which separates the anterior lobes, or the great longitudinal fissure (*x*) of the brain; from the two anterior lateral angles, *the corresponding fissures of Sylvius* (*y y*); from the posterior lateral angles, the two extremities (external to *f f*) of the *great cerebral fissure*, or *great transverse fissure* of the brain; and from the posterior angle (*r*), which corresponds to the interval between the cerebral peduncles, the longitudinal groove (*d*) upon the pons Varolii.

* De basi Encephali (*Ludwig, Scriptores Neurologici*, t. ii.).

† *I. e.*, of the *middle* lobes of anatomists generally (*c*, *fig.* 276), which, it must be remembered, the author, agreeing with Sœmmering, does not regard as distinct from the posterior lobes (*b*), and to which, therefore, he does not apply the term "middle lobes." This term is, however, for the most part added [between brackets] in the translation, as it is generally used in anatomical descriptions in this country.]

In the area of this median excavation are seen the *inter-peduncular space* (above *r*), the *mammillary tubercles* (*z*, *corpora mammillaria vel albicantia*), the *optic tracts* (*s*) and *optic commissure* (*t*), the *posterior part of the floor of the third ventricle*, or the *tuber cinereum* (*v*), the *infundibulum* (*i*), and the *pituitary body*.*

In front of the median excavation are situated, counting from behind forward, the *anterior part of the floor of the third ventricle* (*lamina cinerea*, *m*, *fig.* 282), the *under or reflected portion of the corpus callosum* (*e*), and the *inferior part of the longitudinal fissure of the cerebrum* (*x*, *fig.* 276).

Behind the median excavation is the pons Varolii, and, behind that, the middle part (*r*, *fig.* 282) of the *great transverse fissure*, by which the pia mater enters (above *p*) the third ventricle, the thick *posterior extremity* (*f*) *of the corpus callosum*, and the *posterior part of the longitudinal fissure of the cerebrum*.

The Lateral Regions of the Base of the Brain.—Upon each of these regions are seen the *inferior surface of the corresponding anterior lobe* (*a*) *of the cerebrum*, the *fissure of Sylvius* (*y*), by which this lobe is separated from the posterior lobe [middle lobe of others, *c*], and the inferior *surface of the posterior* lobe itself (*c b*). There is no distinct middle lobe.†

I shall now describe, successively and in detail, the several parts just enumerated, with the exception of the cerebral peduncles and the pons Varolii, which have already been noticed as constituent parts of the isthmus of the encephalon.

The Median Region of the Base of the Brain.

The Inter-peduncular Space.

This space (above *r*) is of a gray colour, it is perforated by numerous openings for the transmission of vessels, and is termed the middle or posterior perforated spot (*locus perforatus*); it contains the origin of the third pair of nerves (3). A longitudinal groove and two fasciculi, separated from the corresponding cerebral peduncle by a blackish line, are seen in this spot. These inter-peduncular fasciculi are formed by a prolongation of the fasciculi of re-enforcement (*faisceaux innominés*) of the medulla oblongata.

The Corpora Albicantia.

The *mammillary tubercles* (*corpora albicantia vel mammillaria*, *z*) are two small pisiform, or, rather, hemispherical globules, composed externally of white, and internally of gray substance, situated behind the tuber cinereum, which is accurately adapted to their anterior surface, also behind the infundibulum, and between the peduncles of the brain. They are separated from each other by a deep fissure, excepting at their highest part, where they are connected by means of a thin layer of gray matter, which is very easily torn; they correspond (*z*, *fig.* 282) to the floor of the third ventricle (*l*).

It will be hereafter seen that the white covering of these small bodies is formed by the termination of the anterior pillars of the fornix, and hence the name given them by Casserius, the bulbs of the anterior pillars of the fornix (*bulbi priorum crurum fornicis*), a name which should be preserved. The two corpora albicantia are generally of equal size. In several cases of atrophy of one of the hemispheres of the cerebrum, I have found the corresponding mammillary tubercles also atrophied.

We are completely ignorant of the function of these bodies.

In man and the carnivora only are there two mammillary tubercles, and in all the other vertebrata there is but one. They attain their highest state of development in fishes, if, as stated by Vicq d'Azyr, they are represented by the two larger lobes, which occupy a corresponding situation in that class of animals. During the early periods of fœtal life they are blended together into one tolerably large mass, and do not become distinct from each other until about the seventh month.

The Optic Tracts and Commissure.

At the point where the peduncles of the cerebrum pass into the brain, each of them is surrounded by a white band, named the *optic tract*, or *tract of the optic nerve*. Each of those tracts commences, behind, at an eminence called the *corpus geniculatum externum* (*j*, *fig.* 271), which will be seen, hereafter, to be an appendage of that part of the brain named the *optic thalamus*. The corpus geniculatum internum (*i*, *figs.* 271, 272) of authors is merely a tubercle inserted into the bend or knee formed by the corpus geniculatum externum. The optic tract (2, *fig.* 272), then, is the continuation of the corpus geniculatum externum, from which it is distinguished by its whiteness, which contrasts strongly with the gray colour of that body: it is at first broad, flattened, and thin, and is applied to the corresponding cerebral peduncle, being distinguished from the peduncle only by the direction of its fibres. It then turns horizontally around the peduncle, is detached from it, and at the same time becomes narrower and thicker; having reached the front of the peduncle, it changes its direction, passes forward and inward (*s*, *fig.* 276), and is united with its fellow of the opposite side, to form the *commissure* or *chiasma* (*t*) of the optic nerves (2). The optic tracts may be regarded as forming a *commissure to the two optic thalami*.

* [To avoid confusion in the drawing, the pituitary body is not represented in *fig.* 276; its point of attachment is to the infundibulum (*i*).]

† See note, p. 727.

These tracts and the cerebral peduncles of the two sides enclose a lozenge-shaped interval, in which are situated the posterior perforated spot, the corpora albicantia, the tuber cinereum, the infundibulum, and the pituitary body.

The Tuber Cinereum, the Infundibulum, and the Pituitary Body.

The term *tuber cinereum* (*v*) has been applied by Sœmmering to the soft gray mass which occupies the triangular interval between the corpora albicantia and the optic tracts. It is also called *the floor of the third ventricle*, because it closes that cavity behind and below, and the *base of the infundibulum*, because that part is attached to it.

The *infundibulum* (la tige pituitaire, *Lieutaud*; la tige sus-sphénoidale, *Chauss.*) is a reddish process (*i*), about two lines in length, directed very obliquely downward and forward (*i*, *fig.* 282), and applied to the lower surface of the tuber cinereum: it is broad at its upper extremity, but soon diminishes in diameter, and descends, to be inserted into, and become continuous with, the pituitary body.

Is the infundibulum hollow, or is it a solid stem? The term infundibulum, or funnel, applied to this part by the older anatomists, and the following synonymes, *pelvis colatoria*, *scyphus*, *aquæ ductus*, *encephali sentina*, afford ample evidence of both their anatomical and physiological views regarding it. Galen and Vesalius, who are so often at variance, are perfectly agreed upon this subject, and describe the infundibulum with a minute exactness; but since the communication supposed by Galen to exist between the nasal fossæ and the brain by means of passages through the ethmoid and sphenoid bones, and the equally hypothetical communication admitted by Vesalius, are known to have no existence, anatomists have rejected the notion of the passage of a fluid from the brain in this direction, and they no longer regard the infundibulum as a funnel intended for its transmission. Haller has collected, in some learned notes, the contradictory opinions of his predecessors, but has left the question still in doubt. Nor has Sœmmering himself, after a long detail of investigation into the subject, arrived at a more satisfactory result.*

A careful examination of the infundibulum has convinced me that there is, at least in a certain number of cases, a funnel-shaped canal, precisely similar to that which was described and figured by Vesalius: it is wide above, where it communicates with the third ventricle, and narrow below, where it reaches the pituitary body, a body which the ancients had not named, but which Vesalius called *glans pituitam excipiens*. In order to demonstrate this canal, the optic tract must be turned backward, and the semi-transparent corneous lamina, which forms the anterior part of the floor of the third ventricle, must be divided; behind a white band, which is quite distinct from the anterior commissure of the brain, there is then seen a circular opening sufficiently wide to admit the blunt end of a large probe, which may accordingly be passed through the entire length of the infundibulum as far as the pituitary body. Again: by cutting the infundibulum across, and then blowing upon it through a blowpipe, or letting some drops of water fall upon it, a perfectly circular opening may be demonstrated, which cannot be produced by the means employed in the demonstration.

Lastly, we may adopt the method of Vesalius, who filled the third ventricle with a coloured liquid, which soon reached the pituitary body. The same experiment succeeds still better with mercury. Nevertheless, I ought to state, that in two cases of dropsy of the third ventricle, no fluid escaped from the infundibulum when it was cut across.

It is easy to show the structure of the infundibulum. A fibrous and vascular membrane, continuous with the pia mater, forms its external covering, and this is lined by a thin layer of gray matter, which is continuous with that of the floor of the third ventricle. This gray matter forms a solid cord when the infundibulum is not tubular.

The *pituitary body*† is a small body, weighing from five to ten grains, which occupies the sella turcica, or supra-sphenoidal fossa (appendice sus-sphénoidale du cerveau, *Chauss.*; hypophysis, *Sœm.*). The better to appreciate its size, it is convenient to break down, with a chisel, the quadrilateral plate which forms the posterior wall of the sella turcica or pituitary fossa, and which is itself hollowed in front, so as to increase the antero-posterior diameter of that cavity.‡

Enclosed in the sella turcica, the pituitary body is kept in that situation on each side by the fold of the dura mater, which constitutes the cavernous sinus, and above by a portion of the same membrane, which forms a circular orifice around the infundibulum.

The coronary sinus, which is situated between the pituitary body and the margin of the sella turcica in front and behind, and the cavernous sinuses on each side, form a vascular circle around this body, but it is not bathed in the blood, as stated by some.

* Ludwig, Script. Neurolog.; Sœmmering, De basi Encephali, p. 41. "Quibus omnibus *absque partium studio* rite mecum perpensis, non potui non complecti illorum virorum sententiam, qui infundibulum, si non perfecte solidum, certe *non adeo conspicuo*, uti veteres opinati sunt, *canali perforatum* esse, censuerunt." Hunter and Cruickshank say that the infundibulum is sometimes solid, and sometimes tubular.

† Not shown in *figs.* 276, 282.

‡ In order to obtain a perfect examination of the pituitary body and infundibulum, it is well to sacrifice a brain and the base of the cranium, and to remove, by a circular incision, the body of the sphenoid bone, together with the corresponding part of the base of the brain.

The upper surface of the pituitary body is slightly excavated, still it is not unfrequently convex, so as to project more or less above the level of its fossa.

On removing the pituitary body, it is seen to be formed of two distinct lobes, of which the anterior is the larger, while the posterior occupies the small cavity in the quadrilateral plate. These two lobes have been very well described by the brothers Wenzel; they are not of the same colour, the posterior lobe being grayish white, like the gray substance of the brain, and the anterior yellowish gray.

If the anterior lobe be pressed between the fingers, a yellowish-white pulp escapes from it, very nearly resembling mixed plaster of Paris. An antero-posterior section of the pituitary body shows, also, that the two lobes are perfectly distinct, being separated by a fibrous layer. They are provided with a great number of small vessels. It has been stated, but not proved, that the infundibulum contains two canals, one for the anterior, and the other for the posterior lobe. It is extremely rare to find any hard concretions in the pituitary body like those met with in the pineal gland.

It is, perhaps, not uninteresting to remark, that the pituitary body is most highly developed in fishes, in which animals it forms a true lobe; and that it is proportionally more developed in mammalia, birds, and reptiles, than in the human subject. It is hollow in all the lower animals.

It is larger at the fourth, fifth, and sixth months of fœtal life than after birth, and contains a cavity which communicates with the third or middle ventricle. I once found a considerable cavity in the pituitary body of an adult.

The *functions* of the pituitary body are enveloped in the greatest obscurity. Its constancy in all vertebrated animals and its great vascularity are sufficient evidence of its importance. It certainly communicates with the third ventricle, but for what purpose? Does it pour a peculiar fluid into that cavity, or does it absorb a portion of the ventricular fluid? Whatever may be the use of the communication just alluded to, the pituitary body does not communicate directly with the venous sinuses around it: it is not a lymphatic gland, as maintained by Monro; nor is it a nervous ganglion of the great sympathetic, as some have recently conjectured, because they fancied they saw some very fine nervous filaments anastomosing upon it. The branches of the fifth and sixth nerves, which Litre and Lieutaud say they have seen penetrating this body, have not been demonstrated.

The Anterior Part of the Floor of the Third Ventricle.

The *anterior part* (*m*, *fig.* 282) *of the floor of the third ventricle*, which cannot be well seen until the commissure of the optic nerves is turned backward, forms an inclined plane directed downward and backward. It consists of a fibrous layer, which is continuous with the neurilemma of the optic nerves; and of a very thin, semi-transparent, but very strong corneous layer (*lamina cinerea*), from which prolongations are given off to the upper surface of the optic commissure, and continued upon the optic nerves: these prolongations might be called the *gray roots of the optic nerves*. On dividing this horny layer, the third ventricle (*l*) is laid open; and it is seen that this layer forms a part of the general system of gray substance, which, on the one hand, is prolonged upon the lateral wall of the third ventricle, and surrounds the anterior pillars of the fornix, and, on the other, is continuous with the tuber cinereum, above the optic commissure.

The Reflected Portion of the Corpus Callosum.

In front of the anterior part of the floor of the third ventricle is a transverse white mass, which is nothing more than the fore part (*e* to *m*) of the reflected corpus callosum. Terminating at this cross tract are two white fasciculi, which commence on each side at the point where the corresponding fissure of Sylvius meets the great transverse fissure of the brain; they then pass inward and forward, along the outside of the optic tracts, form the lateral boundaries of the anterior part of the floor of the third ventricle, and terminate by becoming applied to, but not blended with each other, behind the reflected portion of the corpus callosum. Vicq d'Azyr has described these bands as the *peduncles of the corpus callosum.*

The Anterior and Inferior Part of the Longitudinal Fissure.

This (*x*, *fig.* 276) is situated in front of the reflected portion of the corpus callosum, and can only be seen in its entire extent after the removal of a very dense fibrous layer which connects, sometimes very firmly, the back part of the right and left anterior lobes of the cerebrum. Not unfrequently one of these lobes is seen to encroach upon the other: the falx cerebri, which is very narrow in front, occupies only a very small portion of this fissure.

All the parts belonging to the median region of the base of the brain, which we have hitherto described, are situated in front of the pons Varolii; those which remain to be examined are placed behind it: they are, counting from behind forward, the *back part of the longitudinal fissure*, the *posterior extremity of the corpus callosum*, and the *great horizontal* or *transverse fissure.*

The Back Part of the Longitudinal Fissure.

This is bounded in front by the posterior extremity of the corpus callosum (*f*); and as that extremity is at a greater distance from the back of the cerebrum than the anterior extremity of the corpus callosum is from the front of the brain, it follows that the back part of the longitudinal fissure is of much greater extent than the fore part (see *figs.* 277, 282). Moreover, this part of the fissure is free throughout its whole extent, for it is entirely occupied by the base of the falx cerebri, while the fore part is only partially filled with the apex of the falx: it might even be said that the posterior lobes have a tendency to separate from each other in this situation.

The Posterior Extremity of the Corpus Callosum, and Middle Portion of the Great Transverse Fissure.

The *posterior extremity* (*f*, *fig.* 282) *of the corpus callosum* is named the *bourrelet*,* in consequence of its being so much enlarged. This enlarged extremity, which we shall afterward find is continuous with the posterior pillars of the fornix, constitutes the upper border of a fissure (*r*), the lower border of which is formed by the tubercula quadrigemina (*f g*). The pia mater (*r* to near *k*) enters at this *median fissure*, and forms the velum interpositum, or *tela choroïdea:* in this situation, also, is found the *conarium* or *pineal gland;* and it is here that Bichat described the orifice of his *arachnoid canal.* This median fissure becomes continuous with a lateral fissure on each side, so as to form the *great transverse cerebral fissure.*

The Great Transverse Cerebral Fissure.

The *great cerebral fissure* (*Bichat*), or the *great transverse* or *horizontal fissure*, follows a semicircular direction, having its concavity directed forward; it commences at the fissure of Sylvius on one side (*h*, *fig.* 276; above 2, *fig.* 282), turns round the opposite cerebral peduncle, and ends at the opposite Sylvian fissure.

The peduncle of the cerebrum and the optic thalamus may be regarded as forming the root of each cerebral hemisphere. Now the lateral part of the great transverse fissure passes round the posterior half of this root, because it is in this situation that the corresponding cerebral hemisphere is turned inward upon itself. It is this reflected and concave surface of the hemisphere that forms the outer border of the corresponding lateral portion of the transverse fissure, while the optic thalamus forms its inner border. This fissure communicates directly with the inferior cornua of the lateral ventricles, and through it the pia mater enters those ventricles, to form the *internal pia mater of the brain.*

The Lateral Regions of the Base of the Cerebrum.

The base of the cerebrum is divided on each side into two lobes, an *anterior* and a *posterior*, separated by the *fissure of Sylvius.*†

The Fissure of Sylvius.

This is a fissure of considerable size (grande scissure interlobulaire, *Chauss.*), which commences at the corresponding anterior extremity of the great transverse fissure, with which it forms an obtuse angle. At the point where they meet is found a white substance,‡ perforated with large openings for bloodvessels; this Vicq d'Azyr has named the *anterior perforated substance;* it is the *locus perforatus anterior* (*h*).

The fissure of Sylvius (*y*, *fig.* 276) is directed outward, and describes a slight curve, having its convexity turned forward: it corresponds to the posterior border of the lesser wings of the sphenoid bone, which are received into it.

The fissure of Sylvius cannot be properly examined until both the arachnoid and pia mater have been removed. It is then found to be very deep; it is seen that the middle cerebral artery runs along the bottom of it, that the pia mater lines it throughout, and that it soon divides into two branches, of which the anterior is the smaller, and continues in the original course of the fissure; while the posterior, which is of much greater extent, passes upward and backward, along the convex surface of the hemisphere, and terminates after proceeding a variable distance; the interval between these two secondary furrows is occupied by a sort of *island* (insula, *Reil*), which might be called the *lobule of the fissure of Sylvius*, or the *lobule of the corpus striatum.*

This lobule is of a triangular form, having its base directed upward and its apex downward; it is marked by certain small superficial convolutions, which radiate from below upward. It will be found immediately that this lobule corresponds to and is moulded upon the corpus striatum, which is sometimes so large as to push the lobule beyond the fissure, so that it reaches the surface of the brain, and appears to belong to the anterior lobe.

The Anterior and Posterior Lobes of the Cerebrum.

Several anatomists describe three lobes in each hemisphere upon the base of the brain,

* Cushion, thick border.

† [Three, according to other anatomists: an anterior (*a*, *fig.* 276), a middle (*c*), and a posterior (*b*); the anterior separated from the middle by the fissure of Sylvius (*y*), the posterior resting on the cerebellum, or, rather, on the tentorium.]

‡ [Light gray.]

namely, an *anterior* (*a*), a *middle* (*c*), and a *posterior* (*b*); but there are only two: an *anterior* (*a*), which rests upon the orbital plate of the frontal bone, is moulded upon its irregularities, and is received into the concavity of that bone; and a *posterior* (*c b*), which rests upon the corresponding spheno-temporal fossa and the tentorium cerebelli. The anterior third of this posterior lobe, or the portion which corresponds to the spheno-temporal fossa, is convex, and projects from six to nine lines below the level of the inferior surface of the anterior lobe. The posterior two thirds are slightly concave; they correspond to the tentorium cerebelli, and are placed upon the same level as the anterior lobe.

The convex sphenoidal portion of the posterior lobe forms what is generally called the *middle lobe*, and the posterior, or cerebellar portion, what is then named the *posterior lobe*. I believe that it is useful, in many respects, to apply the terms *frontal horn* (cornu frontale) to the anterior extremity of the cerebrum, which is received into the concavity of the frontal bone, *sphenoidal horn* to the anterior extremity of the posterior lobe, and *occipital horn* to the posterior extremity of the same lobe.

The Convolutions and Anfractuosities of the Cerebrum.

The entire surface of the cerebrum is marked by a great number of deep, winding furrows, which divide it into as many oblong eminences, turned in different directions, and themselves subdivided by secondary furrows. These eminences have some resemblance to the convolutions of the small intestine, and have been named, on this account, *convolutions*, *gyri*, *meandri*, *processus enteroidei*. The furrows by which they are separated are called *anfractuosities* or *sulci*.

A more accurate notion of the general character of these convolutions and anfractuosities may be obtained by supposing a bladder to be expanded round a compact central mass, at a certain distance from it, and in this condition too large to be contained within the cranium; and then, that by means of threads proceeding from different points of the centre, the corresponding parts of the bladder are drawn inward, so that it is folded upon itself, and can now be contained within the cranial cavity. The various winding folds and furrows produced in the walls of the bladder by drawing them from above and from all sides towards the centre, will give some idea of the arrangement of the surface of the cerebrum.

Some of the convolutions and anfractuosities are *constant*, because their forms are determined by those of the central mass; others are subject to *variety*, and seem to depend upon no determinate cause: these varieties occur not only in different brains, but also in the two hemispheres of the same brain. In this respect the human brain differs from that of the lower animals, in which the cerebral convolutions present much less variety, though they are not so constant as Vicq d'Azyr has stated.

The human brain is distinguished from the brains of the lower animals, not only by its size and weight, but also by the number and size of its convolutions. Tiedemann has given excellent representations of the progressive diminution of the cerebral convolutions (which is accompanied by a diminution of the cerebellum) from the apes to the rodentia and edentata.* In the human subject, as in the series of lower animals, the development of the convolutions has always appeared to me to be directly proportioned to the development of the entire brain.

In this point of view, as in many others, the human fœtus presents a similar structure to that found in the lower animals. The furrows or anfractuosities in the brain of the human fœtus at the fifth month are neither deeper nor more numerous than those in the brain of the rabbit; and it is important to study these primitive furrows, because they correspond to certain anfractuosities which ultimately regulate the whole system of convolutions. Thus, at the fifth month, the great anfractuosity, which is called the fissure of Sylvius, exists, but its borders are apart from each other; the island of Reil, or the lobule of the corpus striatum, is found upon the surface of the brain, and there is a longitudinal furrow at the lower and back part of the internal surface of each hemisphere, it corresponds to the occipital prolongation or posterior cornu of the lateral ventricle; there is also a furrow above the corpus callosum; and, lastly, the furrow of the olfactory nerve is visible. At birth, all the convolutions exist, but they are not completely developed until about the age of six or seven years.

It is impossible to determine the *number* of the convolutions, for they have no appreciable limits; and although some of them end between two adjacent ones, it is easy to see that this termination is merely apparent, and that near the point where it seems to take place, the convolution is continued into another without any line of demarcation. The ancient comparison, therefore, between the convolutions of the brain and those of the intestines, not only applies to their direction, but also to their continuity.

There are several *orders* of convolutions. In fact, simple convolutions are seen to be divided, excavated, and furrowed, more or less deeply; but there are no regular and consecutive subdivisions, as in the laminæ of the cerebellum. Vertical sections made in

* [See also Leuret's figures in the work already referred to, in which will be found a comparative view of the number and arrangement of the convolutions of the brain in man and mammalia.]

different directions will show the arrangement of the convolutions much better than the most careful observations of the external surface of the brain.

Each convolution presents to our notice *two surfaces*, a *base* or *adherent border*, and a *free border*. The *surfaces* of the corresponding convolutions are moulded upon each other, and separated by a duplicature of the pia mater.

The *base* or *adherent border* of each convolution is continuous with the central portion of the hemisphere (see section, *fig.* 277).

The *free border* is slightly rounded, so that between any two contiguous convolutions there is a small groove, which is very distinct in cases of purulent infiltrations or depositions of lymph in the sub-arachnoid cellular tissue.

At the points where these convolutions meet, a triangular depression is observed. These spaces are small in the natural state, but become very evident in cases of atrophy of the convolutions.

The free border of some convolutions is frequently marked by an oblong depression or groove, varying in depth and extent, and following the direction of the convolutions; these depressions are sometimes sharp, and radiate into three or four branches; at other times they are superficial, or, lastly, deep and narrow. The arteries and veins which pass over the free borders of the convolutions form grooves upon them of various depths.

The free borders of most of the convolutions generally reach the surface of the brain; but besides the secondary convolutions, several of which remain concealed throughout their whole length, between two adjacent convolutions, there are some principal convolutions, which descend at one of their extremities between two adjacent convolutions; and there are others, again, which are depressed at one or at several points of their extent.

The *depth* of the convolutions varies from ten to fourteen lines, but it is extremely variable in different individuals; moreover, there are perhaps not two convolutions, nor two parts of the same convolution, which correspond in thickness in the same brain; some are considerably swollen, while others are narrow; there is almost always an enlargement at the point where two convolutions become continuous. Eustachius and Vieussens have erred, then, in representing all the convolutions as perfectly similar.

It would be undoubtedly curious to describe minutely all the convolutions. Vesalius, who appears to have entertained the idea of so doing, likened the appearance of the surface of the brain to those irregular forms which are traced by unskilful painters in delineating clouds. Vicq d'Azyr made an unsuccessful attempt to elucidate this subject; Gall and Spurzheim, who were interested in giving a minute description of each convolution, abandoned the task; I have myself attempted, and so has Rolando, to describe and name some of them. The description, however, to be understood, would require the assistance of figures; I shall, therefore, content myself with noticing, in this place, the most important convolutions upon the internal surface, upon the inferior surface, and upon the external surface, or convexity of each hemisphere.

Convolutions and Anfractuosities upon the Internal Surface.

The *convolution of the corpus callosum* is one which predominates over all those of the internal surface of the hemisphere; it is that which embraces the corpus callosum, and hence its name. It commences in front, below the reflected extremity of that body, to which it adheres, passes forward and upward, turns round its anterior extremity, then extends backward, and having reached beneath the posterior extremity of the corpus callosum, continues its course, and is arranged, in a manner to be presently described, upon the lower surface of the cerebrum.

It is narrow at its anterior extremity, which Rolando regards as the principal root of the olfactory nerve; it increases in size as it proceeds, and opposite the middle of the corpus callosum it is elevated like a crest, becomes much broader, and is marked by several furrows, of which some are superficial and others deep. The circumference of this broad crest is divided into several branches, which become continuous either with the superior convolutions of the convex surface, or with the posterior and superior convolutions of the internal surface of the hemisphere. Vicq d'Azyr first pointed out this crest of the convolution of the corpus callosum, and it was named by Rolando *processo enteroido cristato.*

The *internal convolution of the anterior lobe* is eccentric in reference to the one just described, upon which it is moulded, a deep anfractuosity intervening between them. It is very large at its origin in front of the fissure of Sylvius; it forms the internal part of the anterior lobe of the cerebrum, and having arrived in front of the crest of the convolution of the corpus callosum, it passes upward, and becomes continuous with the convolutions of the convex surface of the hemisphere.

This convolution is divided throughout its entire extent by a secondary anfractuosity, which is at first straight, and then sinuous.

Convolutions and Anfractuosities of the Digital Cavity.

A very deep longitudinal furrow, which corresponds to the digital cavity of the lateral ventricle, and, like it, constantly exists, extends from the convolution of the corpus cal-

losum, near the posterior extremity of that body, directly backward along the posterior lobe of the brain, which it divides into a superior and inferior portion. This *anfractuosity of the digital cavity* forms a division between the internal and inferior surfaces of the hemisphere.

The *convolutions of the digital cavity* are the two longitudinal and tortuous convolutions which bound this anfractuosity; the upper convolution belongs to the internal surface of the hemisphere, while the lower one forms part of the inferior surface.

Convolutions and Anfractuosities upon the Inferior Surface.

The great anfractuosity, called the *fissure of Sylvius*, divides the convolutions of the inferior surface into those of the anterior and those of the middle and posterior lobe.

The *convolutions of the anterior lobe* constantly found are, the two small, straight, longitudinal convolutions which bound the groove of the olfactory nerve (*l*, *fig.* 276), and the flexuous convolution, which extends obliquely forward and outward, along the border of the fissure of Sylvius, and is continuous behind with the external straight convolution of the olfactory nerve.

The small convolutions and intervening anfractuosities are very irregular, and differ in different individuals, and even on the two sides in the same individual; into the depressions formed between these convolutions are received the prominent ridges seen upon the orbital plate of the frontal bone.

The Convolutions of the (Middle and) Posterior Lobe.—The convolution which runs along the great transverse fissure is the continuation of the convolution of the corpus callosum, and terminates in front by an unciform enlargement, which corresponds to the dilated extremity of the cornu Ammonis; it forms the outer boundary of the great transverse fissure. The convolution of the corpus callosum and its continuation, viz., that of the transverse fissure, represent an ellipse, which is broken only at the fissure of Sylvius.

On the outer side of this convolution is a longitudinal anfractuosity, which corresponds to the lower wall of the inferior cornu of the lateral ventricle.

This anfractuosity is bounded by certain longitudinal convolutions, all of which proceed from the convolution of the transverse fissure, and are remarkable for their size and windings.

The most internal of these convolutions forms the lower boundary of the anfractuosity which I have said corresponds to the posterior cornu of the lateral ventricle.

From the anterior part of the convolution of the transverse fissure some extremely flexuous convolutions proceed from behind forward, assist in forming the sphenoidal horn (point of the middle lobe), and become continuous with the convolutions of the external face of the hemisphere.

Convolutions and Anfractuosities of the Convex Surface.

The convolutions upon the convex surface of the hemisphere are, undoubtedly, the most complicated; on separating the borders of the fissure of Sylvius, within which the island of Reil is contained, it is seen that the fissure is triangular, and presents three sides: an *inferior border*, formed by the external convolution of the anterior lobe of the cerebrum; a *posterior border*, directed very obliquely upward and backward, which appears to receive all the occipital convolutions, and consists of a very tortuous convolution; and a *superior border*, also consisting of a very winding convolution, in which the majority of the superior convolutions terminate.

The convolutions upon the convex surface of the brain may be divided into the *frontal*, the *parietal*, and the *occipital*.

The *frontal convolutions* are three or four in number, and are directed from before backward. The *parietal convolutions* are three in number; they pass in a serpentine direction from within outward, and become continuous with the convolution which forms the superior border of the fissure of Sylvius. The *occipital convolutions* are directed from before backward, and proceed either from the posterior parietal convolution, or from the posterior border of the fissure of Sylvius.

The occipital convolutions are the narrowest and the most sinuous of all, so that the sides of the sinuosities of each convolution are in mutual contact in the greatest part of their extent, and touch the adjacent convolutions only at the points at which they are bent.*

The frontal convolutions are also very flexuous, and have similar characters to the occipital, but not so distinctly marked. They are larger than the occipital convolutions, but smaller than the parietal, which are, moreover, less tortuous than either of the others.

The unusual details with which I have described the convolutions can only be justified by the importance which has recently been attached to them. In the preceding description the following points have been noticed: Their general disposition, their windings, and their mutual adaptation; their continuity, and the impossibility of drawing any precise limits between them; their general configuration, according to a common type, and the want of uniformity in their details, not only in different brains, but also in the oppo-

* In senile atrophy, the occipital convolutions are chiefly affected.

site hemispheres of the same brain; their variable dimensions in different individuals, both in respect of depth and width, these being always directly proportioned to the size of the cerebral hemisphere: the individual differences both in the size of the brain and in that of the convolutions are very great.* We have also seen that the internal surface of the cranium is exactly moulded upon the surface of the brain, the digital impressions in the cranial bones corresponding to the convolutions, and the ridges or eminences to the small spaces intervening between the free borders of the convolutions.

Functions of the Convolutions and Anfractuosities.

The convolutions and anfractuosities render the surface of the brain of much greater extent than it would otherwise have been. According to Vesalius, they are of use in multiplying the surface, through which the bloodvessels carry nutritious matter into the interior of the organ.†

The opinion that the anfractuosities and convolutions are intended to increase the surface has been lately revived; but the supposed object of this increase is very different from that stated by Vesalius: thus, it has been agreed that, as there is an undoubted analogy between electrical phenomena and those manifested by the nervous system, and as electrical phenomena are developed, not in proportion to the quantity of matter concerned, but in proportion to the extent of surface, so the energy of the brain's action may be in a direct ratio with the extent of its surface. In support of this opinion, the phenomena of arachnitis are quoted, in which disease delirium more frequently occurs than in inflammation of the cerebral substance itself. Allusion is also made to the folds observed in the retinæ of birds, which greatly increase the intensity of vision: M. Desmoulins, who is a principal supporter of this theory regarding the use of the convolutions, states that he has observed these folds to disappear in birds which had been kept in the dark, in the same way that the cerebral convolutions become atrophied, either from the continued absence of all cerebral excitement, or from any other cause of intellectual weakness.

The anatomists and philosophers of antiquity, considering that the convolutions were more highly developed in man than in the lower animals, concluded that the intellectual superiority of the former was owing to this circumstance. Such was the opinion of Erasistratus, facetiously refuted by Galen.‡

Gall and Spurzheim have recently revived this old opinion, and assuming, with some philosophers, the existence of a plurality of mental functions, they have arrived at the conclusion that there is also a plurality of material instruments or organs, by which those functions are performed. These material organs are supposed by them to be the convolutions, upon which they accordingly placed numbers corresponding to the different mental faculties admitted by their philosophy: the difficulty was to settle on the number of primitive mental faculties and their corresponding organs. According to Gall and Spurzheim, the highest intellectual faculties of man are seated in the anterior lobes of the cerebrum.

On the other hand, from an examination of the brains of fifty insane patients, M. Neumann has been led to think that the occipital portion of the cerebrum is the seat of intelligence: this opinion derives some support from a fact which I have myself often observed, viz., that atrophy of the brain of old persons in insanity affects the occipital more than the frontal convolutions; and also by the fact, that, as we descend in the animal series, the posterior part of the brain is observed to be the first to diminish, and then entirely to disappear.

It is unfortunate for the system of Gall that the convolutions form a continuous whole, and are not separated into distinct organs; and it is also unfortunate that, upon the base of the cerebrum, and upon the internal surface of each hemisphere, there are convolutions as distinctly marked as those upon the convex surface; and yet, in the system of Gall, the convolutions upon the base and internal surface of the hemispheres have been, so to speak, disinherited; for all the mental faculties have been located by him in the convolutions of the convex surface.

THE INTERNAL STRUCTURE OF THE CEREBRUM.

In order to make as complete an examination of the internal conformation of the brain as is possible in the actual state of science, it should be prosecuted by means of sections

* Comparative anatomy fully confirms this fact: the convolutions of a small hemisphere are very slightly developed, and they do not exist at all when the hemispheres are very thin, as in birds.

† The substance of the brain, says Vesalius, is not firm enough for the arteries and veins to traverse it with impunity; on the other hand, it is so thick that bloodvessels distributed over its surface would not have been sufficient to nourish the entire mass; and, therefore, nature has provided certain deep and winding furrows upon the brain, into which the pia mater can penetrate, so as to convey to the deep-seated parts the materials for their nutrition; for the same reason, the cerebellum has been divided into laminæ and lamellæ. Vesalius even states that the division of the cerebrum into two hemispheres is for no other purpose (lib. vii., cap. 4, p. 542).

‡ "Quum asini etiam admodum multipliciter cerebrum habent complexum quod deceret, quantum ad morum ruditatem attinet, omnifariam simplex et minime varium nancisi cerebrum." If this theory be true, says Galen, the ass ought to have a brain with a smooth surface, and no convolutions; but it has numerous and deep convolutions: the intellectual faculties, therefore, are independent of the convolutions. The conclusion is not obviously contained in the premises.

in different directions; by tearing the brain, and by acting upon it with streams of water; and by dissecting brains that have been hardened by alcohol, or by being boiled in oil or in a strong solution of salt.

Examination of the Internal Structure of the Brain by Sections.

This mode of examining the brain was the one employed by Galen; it was revived by Vicq d'Azyr, and is now generally adopted.

By means of these different sections it is easy to study the internal conformation of the brain in its principal details. The other methods are more especially adapted for determining the connexions of the several parts of the cerebrum with each other, or with the other portions of the cerebro-spinal axis. I shall commence by an examination of horizontal sections of the brain.*

Horizontal Sections of the Brain.

On making an incision into the brain, this organ is found to consist of two substances: a *gray cineritious* or *cortical* substance, and a *white* or *medullary* substance, which is surrounded on all sides by the gray.†

First Section.—A horizontal section, made so as to remove the *upper half* of the superior *convolutions* of the cerebrum, shows that each convolution consists of a central white portion, surrounded on all sides with a layer of gray substance; that the gray substance is accurately moulded upon the white, the form of which determines that of the corresponding convolution; that the thickness of the gray matter varies from half a line to a line and a half; and that it is far from being uniform, either in the same or in different convolutions. In judging of the thickness, it is important to have regard to the direction of the section; for it is easy to understand that an oblique section of the gray matter will give a very different result from one made perpendicularly. The section described above also shows that the convolutions are continuous with each other, and it enables us to comprehend their irregular, complex, and sinuous arrangement better than could be done without cutting into the brain.

The relative *proportion* of the gray and white substances in each convolution may be determined approximately by macerating a brain for some days; the gray substance being softer and more readily decomposed, is thus converted into pulp, and may be easily removed. The convolutions being thus reduced to the white substance only, appear like short, white lamellæ, arising from different points of the surface of the central medullary mass. I estimate the gray matter at about five sixths of each convolution.

Second Section.—A horizontal section made beneath the base of the convolutions of the convex surface of the hemispheres presents an appearance like that of a geographical chart of a deeply and irregularly indented coast; an appearance which cannot be described without figures. It consists of a central mass of medullary substance, which is narrowed like an isthmus behind: extending from this central mass are certain prolongations, which may be divided into several orders, and which are themselves subdivided, so as to form the medullary centre of each convolution.

Fig. 277.

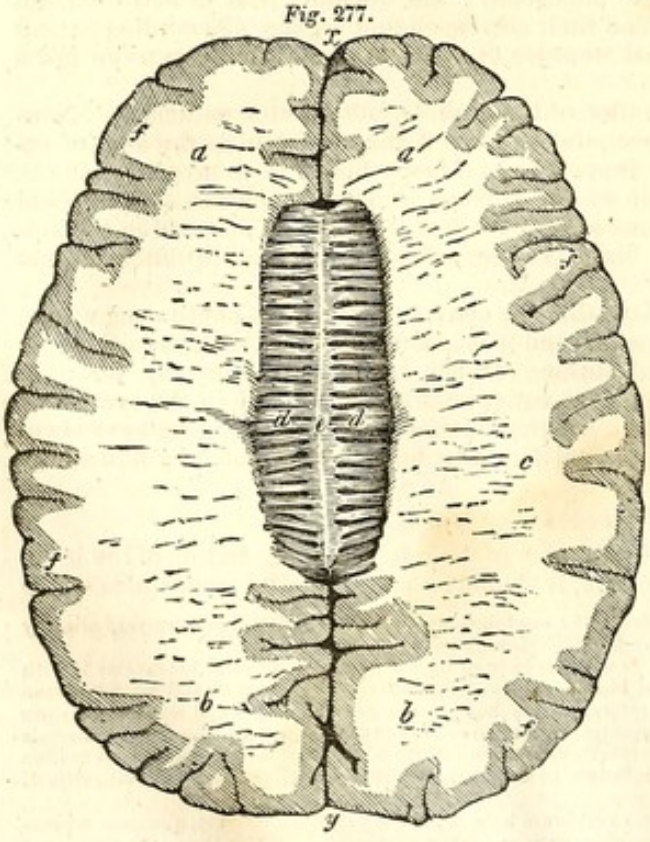

Third Section.—A horizontal section, made on a level with, or, rather, just above, the corpus callosum, displays a great medullary centre in each hemisphere (centre médullaire hémisphéral; centrum ovale minus; *a c b, a c b, fig.* 277).

The two centres of the opposite sides, together with the corpus callosum (*d d*), form the *centrum ovale of Vieussens.*

The *centrum ovale of Vieussens* is contracted in the middle line, where it is formed by the corpus callosum, but is much larger in each hemisphere. The anfractuosities by which the circumference of this section is indented are seen to be deeper on the outside and behind, than on the inside and in front.

* The sections should be made with a very sharp instrument, a razor, for example. † See note, p. 701.

By the three horizontal sections just described, it is shown that each convolution (*f f f*) consists of a white, central portion, surrounded by a thick layer of gray substance, having a precisely similar shape; that it is the gray matter which predominates in the convolutions; that the central portions of all the convolutions are continuous with each other, and form the most complicated windings; that they all rest upon a hemispherical central mass, which becomes larger and larger towards the corpus callosum, on a level with which it attains its greatest dimensions; that the centrum ovale of Vieussens, which, however, is not oval, represents the largest medullary surface of the brain, and might be regarded as a centre, from which all the radiations that enter the convolutions are given off in one direction, and, in the other, all those which establish connexions between the brain and the other parts of the cerebro-spinal axis; lastly, that the centrum ovale and the convolutions are always developed in a corresponding ratio.

The Corpus Callosum.

If, when the brain is resting upon its base, the two hemispheres be drawn asunder, a transverse white band is seen at the bottom of the longitudinal fissure, extending from one hemisphere to the other, and connecting them together, and forming their commissure: this band is the *corpus callosum** (mésolobe, *Chaussier*; commissura cerebri magna, maxima, *Reil*, *Sœmmering*, *d d*). On removing the upper part of the two hemispheres by a horizontal section made about a line or two above the corpus callosum, it is seen that each hemisphere encroaches upon the corpus callosum, and overhangs it without adhering to it: the interval between the hemisphere and the corpus callosum has been improperly termed the *ventricle of the corpus callosum*. But there is no cavity here, nor is there a smooth exhalant and absorbing surface; it is merely an anfractuosity, separating the corpus callosum from the convolutions, and lined by the pia mater, like all other anfractuosities. On continuing to remove successive portions of the hemisphere, it is found that it can be separated without any laceration from the corpus callosum, much farther than the point at which the pia mater is reflected, and that the hemisphere and corpus callosum are simply in contact with each other; the fibres of the hemisphere are seen to be longitudinal, while those of the corpus callosum are transverse.

From this observation, it follows that the middle or free portion of the corpus callosum (shown in *fig.* 277) is but a small part of that body.

The corpus callosum reaches much nearer to the anterior (*x*) than to the posterior (*y*) extremity of the cerebrum, being an inch and some lines distant from the former, and from two to three inches from the latter.

Its *length* is about three inches and a half; it is *broader* behind than in front; its breadth behind varies from eight to ten lines, if we include the part which is covered by the hemispheres: its *thickness*, which can be properly shown only upon a vertical section (see *fig.* 282), along the middle line, is not uniform throughout; its thickest part is at the posterior extremity (*f*), which is about three lines thick: in front of this extremity it diminishes abruptly, and is scarcely a line or a line and a half in thickness (*d*); it then gradually increases from behind forward, and is about two lines thick at its anterior extremity, opposite the point of its reflection (*e*).

In *form* the corpus callosum resembles an arch or *vault*, so that it would deserve the name of vault or fornix better than the part usually so called.

Its vaulted form is distinctly shown upon a longitudinal vertical section (*fig.* 282), and at the same time it is seen that the posterior extremity of the corpus callosum is rolled up, as it were, so as to form an enlargement, while its anterior extremity is merely reflected downward and backward, and after its reflection becomes gradually thinner as it descends, and terminates in a very delicate lamella.

The corpus callosum presents for our consideration a superior and an inferior surface and two extremities. The *superior surface* is convex, and, as it were, arched from before backward (*medullaris arcus*); it has no raphé along the median line, but presents in that situation a slight groove (*e*, *fig.* 277), depending on the existence of two white longitudinal tracts, one on each side the middle line, which were regarded by Lancisi as constituting a nerve, *the longitudinal nerve of Lancisi*.

These tracts are subject to variations: thus, they are sometimes slightly flexuous, and contiguous to each other, and at other times they unite, and then separate. Duverney has described certain ash-coloured longitudinal tracts, but their existence has been denied by most anatomists.

The white longitudinal tracts are intersected at right angles by transverse fasciculi, which constitute the corpus callosum.

The upper surface of the corpus callosum corresponds to the hemispheres on each side; it is free in the middle, where it corresponds to the arteries of the corpus callosum and to the free margin of the falx, which has appeared to me to approach very closely to

* According to Haller, its name is derived from its whiteness, which has been compared to the colour of a cicatrix; according to others, it was given on account of the consistence of this part, which has been erroneously regarded as exceeding that of other parts of the brain

the posterior extremity of this body, but not to touch it, so that it could not occasion any depression upon it.

The *inferior surface of the corpus callosum* is concave, and is free over a greater extent than the superior; it forms the upper wall or roof of the lateral ventricles (*i i*, *fig.* 278, in which figure only the anterior and posterior extremities, *e* and *d*, of the corpus callosum are left).* This surface is covered by the serous membrane of the ventricles, and, like the superior surface, it is fasciculated.

Along the median line it corresponds, in front, to the septum lucidum (*t*, *figs.* 278, 282), and behind to the fornix (*k*), with which it even seems to be united at this point. In consequence of the somewhat regular arrangement of the fibres constituting the two posterior pillars of the fornix (*r r*, *figs.* 278, 279), which diverge in this situation, and also of that of the transverse fibres of the corpus callosum, the back part (*s*, *fig.* 279) of the inferior surface of the corpus callosum has received the names of *lyra*, *corpus psalloides*, *psalterium*.

The *posterior extremity* of the corpus callosum (bourrelet, *Reil*), which, as we have already stated, is its thickest part, is slightly concave transversely, but presents no other notch, excepting the median depression, between the longitudinal tracts.†

The *anterior extremity of the corpus callosum* does not terminate in an enlargement, like the posterior, but it is reflected, and embraces the anterior extremity of the corpus striatum: it then passes downward and backward (*e*, *fig.* 282), and terminates insensibly in front of the anterior portion (*m*) of the floor of the third ventricle. Reil applies the term *knee* (*genu*) to the point of reflection, and that of *beak* (*rostrum*) to the posterior and thin extremity of the reflected portion. This reflected portion of the corpus callosum is seen upon the base of the brain, between the anterior lobes; the convolution of the corpus callosum also accompanies its reflected portion, and, instead of being merely in contact, becomes continuous with it, so that the gray matter rests immediately upon the corpus callosum. The longitudinal tracts arise from the reflected portion of the corpus callosum; and the inferior peduncles of the corpus callosum (*Vicq d'Azyr*), already mentioned, terminate upon this portion.

The right and left borders of the corpus callosum enter deeply into the substance of the hemispheres.

Beneath the corpus callosum are situated, in the median line, the *septum lucidum* (*t t*, *fig.* 278), the *fornix* (*k*), the *velum interpositum* (*v*, *fig.* 279), and the *median* or *third ventricle* (*c* to *x*, *fig.* 280); and at the side, the *lateral ventricles* (*i i*, *fig.* 278). We shall proceed to examine these different parts in the above-mentioned order. To obtain a good idea of their form and relations, it is important to study them upon two brains, one resting upon its convex surface, and the other upon its base.

The Septum Lucidum.

The *septum lucidum*, or transparent septum, so called because it separates the lateral ventricles from each other and is semi-transparent, is situated in the median line (septum médian, *Chauss.*). It is very well seen (*t*, *fig.* 282) when the corpus callosum has been divided longitudinally on each side of the middle line. It appears like a thin lamina given off from the anterior and inferior part of the corpus callosum, and passing vertically downward in front of the fornix; it is of a triangular shape, broad in front and narrow behind; its lateral surfaces constitute the internal walls of the lateral ventricles; its upper border is continuous with the corpus callosum, its posterior with the fornix, and its inferior with the reflected portion of the corpus callosum in front, and with the inferior peduncles of that body farther back. Hence Vicq d'Azyr imagined that the septum lucidum was a continuation of these peduncles.

The septum lucidum is composed of two very delicate and completely distinct lamellæ (*t t*, *fig.* 278), between which, in front, a cavity is enclosed, containing a few drops of a serous fluid; this small cavity is called the *ventricle of the septum*, the *first ventricle* (*Wenzel*), the *fifth ventricle* (*Cuvier*), and the *sinus of the median septum* (*Chauss.*); it is not very unfrequently the seat of dropsical effusion. I have found it filled with blood in several subjects after death from apoplexy.

As to whether this ventricle of the septum communicates with the other ventricles, opinions are divided. Tarin describes a small fissure opening between the anterior pillars of the fornix, but the majority of anatomists have not been able to demonstrate it. It appears to me that the absence of all communication is a well-ascertained fact.

Each of these lamellæ of the septum lucidum consists of a medullary layer, covered on the outside by the membrane of the corresponding lateral ventricle, and on the inside by the membrane of the fifth ventricle. The existence of this last-mentioned membrane is proved by the smooth appearance of the ventricle, and it may be demonstrated by re-

* The best mode of examining the lower surface of the corpus callosum is to view it by opening the ventricles from the base of the brain.

† One is astonished to read, in Chaussier's work, that the notch of the posterior extremity of the corpus callosum is caused by the alternate movements of elevation and depression of the brain. At each elevation, according to him, this extremity of the corpus callosum strikes against the free margin of the falx cerebri, although that margin is at some slight distance from it.

moving, in succession, layers from the outer surface of the lamella. The gray matter of the third ventricle is prolonged upon the external surface of each lamella of the septum.

The Fornix and Corpus Fimbriatum.

The *fornix* (la voute à trois piliers, *k*, *r r*, *fig.* 278) is a medullary arch, situated (*k*, *fig.* 282) beneath the corpus callosum, with which it is continuous behind, but which it leaves in front, and then passes perpendicularly downward, describing a curve within the curvature of the corpus callosum. The interval between the anterior part of the fornix and the corpus callosum is occupied by the septum lucidum. To the term fornix, used by the older writers, the epithet *à trois piliers* has been improperly added by Winslow, inasmuch as it expresses a mere appearance; for there are in reality *four* pillars, the two anterior of which are closely approximated to each other, while the two posterior are widely apart.

Fig. 278.

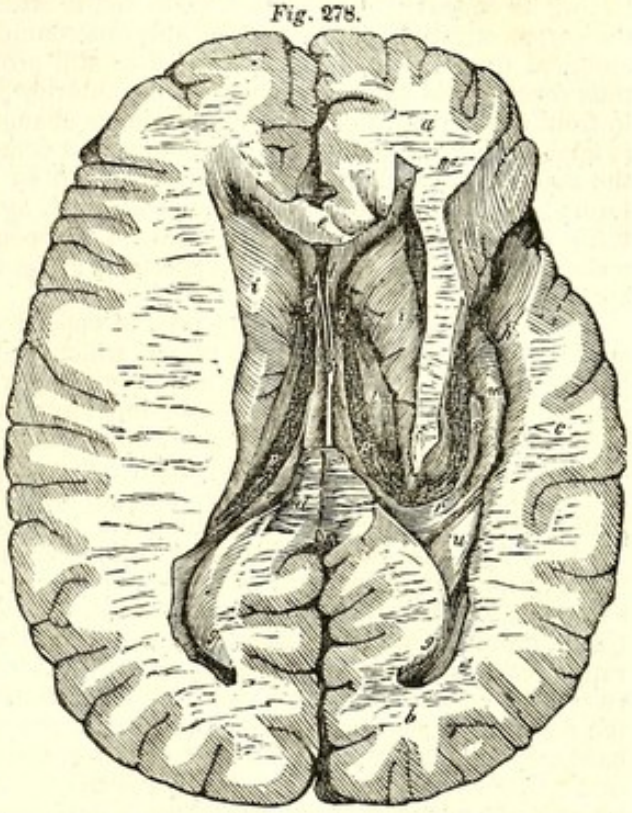

The fornix resembles an isosceles triangle (*trigone cérébral*), having the anterior angle very much elongated and soon bifurcated; its posterior angles suddenly diverge, pass downward and outward, and are prolonged (*r r*) into the inferior or reflected portions or descending cornua of the lateral ventricles, where they constitute the *corpora fimbriata* (*s*); or, rather, the fornix may be said to be composed of two perfectly distinct medullary cords, which are applied closely to each other, become broader and flatter as they proceed backward and downward, and separate from each other opposite the reflected portions of the lateral ventricles, into which they enter. The fornix, therefore, resembles the letter X placed horizontally, the anterior limbs of which are close to each other (between *q q*) and very short, while the posterior limbs (*r r*) are very long and widely apart. The term fornix is really applicable only to that portion which is applied to the corpus callosum. Reil, who has described and figured this part better than any of his predecessors, not even excepting Vicq d'Azyr and Sœmmering, calls the fornix the twain-band.

The *superior surface* of the fornix corresponds, in the median line, to the septum lucidum in front, and to the corpus callosum behind: on each side it is free, and forms a part of the floor of the lateral ventricles. The choroid plexuses (*p p*) are sometimes reflected upon the surface of the fornix.

In order to understand the relations of the fornix with the corpus callosum, it is necessary to bear in mind that it is composed of two flat medullary bands. Now the internal contiguous borders of these bands are turned upward, and adhere to the lower surface of the corpus callosum, so as to form a small vertical septum, which is continuous with the back part of the septum lucidum. The medullary fibres of the septum lucidum are therefore generally considered to be continuous with those of the fornix.

The *inferior surface of the fornix* (*r r*, *fig.* 279) rests upon the *velum interpositum* (*v*), which separates it from the third ventricle (*c b x*, *fig.* 280) and the optic thalami (*l l*), the internal portion of which bodies is covered by the fornix (see *fig.* 278). It is upon the posterior portion of this inferior surface, where the two medullary bands of the fornix separate from each other to enter the descending cornua of the lateral ventricles, that we find that regular though variable arrangement of transverse fibres (*s*), abutting on certain longitudinal fibres (*r r*), which has been named the *lyra*, *corpus psalloïdes* or *psalterium*. I have already noticed this structure, which was erroneously regarded by Gall as composed of the uniting fibres of the fornix.

The *edges* of the fornix are thin and free, and are bordered by the choroid plexuses.

The *anterior pillars* of the fornix (*k*, *figs.* 279, 280), which Vieussens, Tarin, and others described as arising almost indifferently either from the cerebral peduncles, or from the anterior commissure (*c*, *fig.* 280, situated in the third ventricle), can only be well seen in a longitudinal vertical section of the cerebrum made exactly in the median line. Each half of the cerebrum will contain the corresponding band of the fornix; and it will then be seen, as was first described by Santorini, that each anterior pillar (seen below *k* and behind *c*, *fig.* 282) arises from the corpus albicans (*z*) of its own side: hence these bodies

have been called the *bulbs of the fornix*. The whole of the white covering of each of the corpora albicantia (*l*, *fig.* 283) appears to be formed into a thick white fasciculus or cord, which passes upward, and may be very easily traced with the handle of the scalpel through the soft gray matter which forms the inferior and anterior portion of the wall of the third ventricle. While passing through this gray matter the cord describes a curve, having its concavity turned backward, and is situated between the optic thalamus and the corpus striatum, and behind the anterior commissure (*c*, *fig.* 282; *m*, *fig.* 283); having emerged from the gray matter, which is still prolonged along its anterior surface and thus reaches the septum lucidum (*t*), the anterior pillar is reflected backward (*h*, *fig.* 283) in front of the optic thalamus, and becomes changed into a flat band (*k*, *fig.* 282), which is applied to the thalamus (*l*), and follows the contour of that body: at the point where the anterior pillar of the fornix changes from an ascending to a horizontal direction, it forms half a ring (situated behind and below *k*, *fig.* 282), which is completed by the anterior part of the optic thalamus. This is the opening of the *foramen of Monro*, by which a communication is established (opposite *q q*, *fig.* 278) between the third and the corresponding lateral ventricles.

The Posterior Pillars.—Having arrived opposite the back part of the optic thalamus, each of the lateral bands of the fornix, which had already been directed somewhat obliquely outward, passes abruptly and very obliqely outward and downward (*r r*) into the descending cornu (*h*) of the corresponding lateral ventricle, and is there divided into two parts, one of which forms the superficial medullary substance of the cornu ammonis, or hippocampus major (*m*), while the other follows the concave border of the hippocampus, and takes the name of *corpus fimbriatum* (*s*), *corps frangé*, *corps bordé*. We shall again allude to these parts in describing the lateral ventricle.

I have said that the anterior pillars arise from the corpora albicantia, but they have a much deeper origin, which was figured by Vicq d'Azyr, and has been still better described by Reil. According to that anatomist, they arise within the optic thalami. I have traced them much farther than Reil, as far as the *tænia semicircularis* on each side; or, rather, each *tænia semicircularis* (*n*, *fig.* 278), which is situated in the lateral ventricle between the corpus striatum (*i*) and the optic thalamus (*l*), and which is continuous with the anterior corpus quadrigeminum or natis of its own side, becomes subdivided into two bands, which may be regarded as the roots of the corresponding anterior pillar of the fornix. Of these two roots, one is superficial (*n*), and easily seen without dissection; the other is deep-seated (*v*, *fig.* 283), enters into the substance of the optic thalamus, runs forward to the corpus albicanus (*l*), spreads out and forms the surface of that body, and then curves upward to constitute the anterior pillar of the fornix (*h*), at the point where it emerges from the gray matter.

The two bands of the fornix also receive some other white fibres, which greatly multiply its connexions. Thus, as they are traversing the gray matter, the anterior pillars receive additional medullary fibres, some arising from the gray matter itself, and others from the commissure of the optic nerves; again, just as they emerge from the gray matter to become horizontal, they receive a considerable cord, formed conjointly by the white fibres covering the optic thalamus (*g*, *fig.* 283) by a white band, which runs longitudinally along the optic thalamus, and is continuous with the corresponding peduncle of the pineal gland, and by the superficial fibres of the tænia semicircularis, of which I have already spoken. These three sets of fibres form a cord of considerable size, which is bent abruptly backward, and becomes continuous with the fornix. Lastly, the fornix receives, or, perhaps, it gives origin to, the white radiated fibres of the septum lucidum.

Fig. 279.

The Velum Interpositum.

Beneath the fornix is situated a vascu ar memorane, a prolongation of the external pia mater: this is the *velum interpositum*, or *tela choroidea* (*v*, *fig.* 279), so named by Herophilus from its tenuity, which he compared to that of the fœtal membrane called the chorion.

It is thus formed: the external pia mater, having arrived below the enlarged posterior extremity of the corpus callosum, penetrates (at *r*, *fig.* 282) into the interior of the brain between that body and the tubercula quadrigemina, and forms a sort of triangular web (*v*, *fig.* 279), the base of which is turned backward, and the truncated and bifurcated apex forward. The *upper surface* of the velum is covered by the fornix (reflected at *r r*), to which it transmits a great number of vessels. Its *inferior surface* forms the root of the third ventricle, and corresponds on each side to the upper and to a small part of the inner surface of the optic thalami (*l l*). The velum is also in relation with the venæ Galeni and with the pineal gland (*p*, *fig.* 282), adhering very closely to that body, and forming a nearly complete investment for it, so that they are almost always removed together.

Bichat described his so-called arachnoid canal as passing beneath the velum interpositum. Upon the lower surface of the velum, which can only be properly examined from below, are found two small trains of red granulations, precisely similar to the choroid plexuses of the lateral ventricles, with which they are continuous in front : they may be called the *choroid plexuses of the third ventricle.*

The lateral *borders* of the velum are continuous with the upper part of the choroid plexuses (*p p, figs.* 278, 279) of the lateral ventricles.

The *anterior extremity*, or apex of the velum, is bifid ; each branch of the bifurcation passes from the third into the corresponding lateral ventricle (behind *k, fig.* 282, opposite *q q, fig.* 278), behind the anterior pillar of the fornix, and constitutes the anterior extremity of the choroid plexus.

The velum interpositum is formed by the pia mater, supported by a tolerably strong fibrous layer.

When the fornix and the velum (as in *fig.* 280) are removed, we arrive at a cavity called the *middle* or *third ventricle.*

The Middle or Third Ventricle.

Dissection.—In order to expose the third ventricle from the base of the brain, the right peduncle of the cerebrum and the right corpus albicans should be separated from those of the left side by a longitudinal section in the median line. There is another section, which I recommend as exceedingly well adapted to exhibit all the parts contained in the third ventricle ; it is made from before backward, and on either the right or left side of the median line, so as to leave both of the lateral walls of the third ventricle uninjured.

Fig. 280.

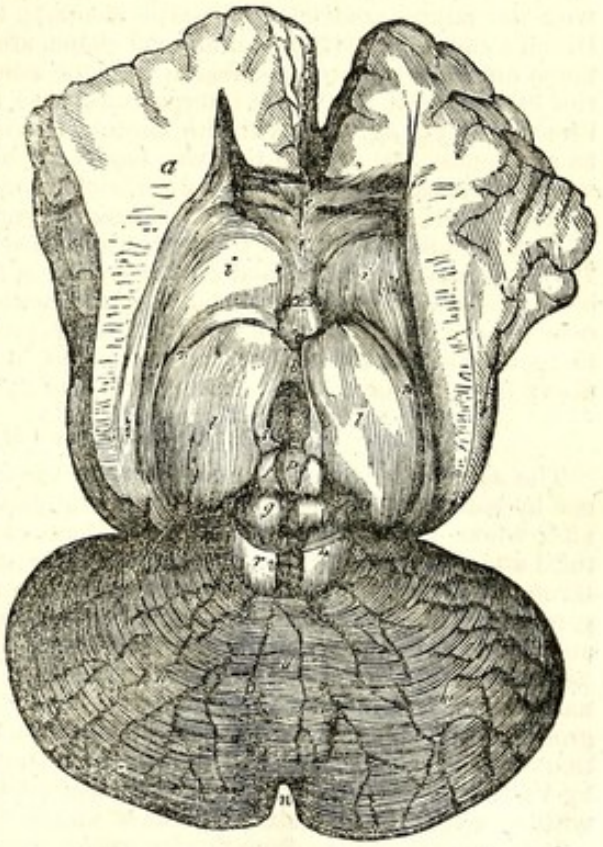

The *third ventricle* (*c* to *x*, *figs.* 280, 282) is situated in the median line, near the base of the brain, between the optic thalmi (*l l, fig.* 280) and in front of the tubercula quadrigemina (*f g*) : it appears like a very narrow cavity, oblong from before backward, and of greater extent below than above ; it is not so much a cavity as a fissure between the two optic thalami. Vesalius compared this ventricle to a valley, the hills on either side of which were very closely approximated to each other, and united by a sort of bridge, represented by the commissura mollis (*b*).

The *superior orifice* of the third ventricle is surrounded by a white rim or border (*s*), which forms, behind and on either side, the peduncles of the pineal gland.

The *lateral walls* (*l, fig.* 282) are plane, smooth, and of a gray colour ; they are formed by two very distinct parts, viz., above and behind by the internal surface of the optic thalamus, and below and in front by the internal surface of a gray mass, which appears to me to deserve a particular description under the name of the gray mass of the third ventricle.

That part of the internal wall of the ventricle which is formed by the optic thalamus is marked off by a horizontal groove from the part formed by this gray mass.

The internal surface of this gray mass is smooth, and lined by the membrane of the ventricle. The external surface is continuous with the rest of the brain ; below, it forms the tuber cinereum, or base of the infundibulum, passes around the corpora albicantia, the anterior pillars of the fornix and their roots, is prolonged upward upon the sides of the septum lucidum, and downward as far as the upper surface of the optic commissure, the posterior border of which is imbedded in this gray mass, and receives from it a short white root on each side.

The lateral walls of the third ventricle are united together, opposite the anterior part of the optic thalami, by a gray substance called the *soft commissure, commissura mollis* (*b*), the *gray commissure*, and also the *vascular commissure of the optic thalami ;* it varies much in size, and is very easily torn ; but I have always found the remains of it in those cases

in which it appeared at first sight to be wanting.* I regard the soft commissure as a prolongation of the gray mass of the third ventricle, and this substance appears to me to be of the same nature as the gray matter of the convolutions.

The *floor of the third ventricle* is of greater extent than the walls of that cavity; it is concave upon its upper or ventricular surface, and convex below. We shall divide it into three portions: the *posterior portion of the floor* (above *n*, *fig.* 282) is deeply grooved along the median line, forms an inclined plane sloping downward and forward, and corresponds to the interval between the peduncles of the cerebrum; its white colour, which is scarcely concealed by the thin layer of gray matter upon it, contrasts strongly with the distinct gray colour of the lateral walls. The *middle portion of the floor* is funnel-shaped, and corresponds to the corpora albicantia (*z*), and to the infundibulum (*i*); it leads to the canal in the infundibulum. The *anterior portion of the floor* (*m*) is inclined downward and backward, and is formed by a very thin, semi-transparent layer of gray substance (*lamina cinerea*), which we may call, with Tarin, the *pars pellucida*, and which is supported by a fibrous layer derived from the pia mater.

In front, the third ventricle presents the *anterior pillars* (*k*, *fig.* 280, below *k*, and behind *c*, *fig.* 282) of the fornix, in front of which is situated a white cylindrical cord (*c*), directed transversely, and visible only in its middle portion; this is the *anterior commissure*, beneath which the ventricle extends as far as opposite the posterior border of the optic commissure. Behind the anterior pillars of the fornix, and somewhat above the anterior commissure, are the *two openings* by which the third ventricle communicates with the lateral ventricles (*foramen Monroi*); these openings (of which one is seen between *b* and *k*, *fig.* 282) are of an oval shape, are sometimes of unequal size, and become much enlarged in chronic effusion into the ventricles. The two divisions of the anterior extremity of the velum interpositum pass through these openings, to become continuous (at *q q*, *fig.* 278) with the choroid plexuses. Haller erroneously regarded them as accidental; an opinion that was founded upon several pathological observations, from which it appeared that the lateral ventricles were distented with a considerable quantity of fluid, while the third ventricle remained empty.

At the back part of the third ventricle is seen the *posterior commissure* (*x*, *figs.* 280, 282), a transverse cylindrical cord, situated in front of the tubercula quadrigemina, and below the commissure of the pineal gland, with which it is continuous. The posterior commissure is smaller than the anterior; it may be regarded as a white commissure of the optic thalami, for its extremities are lost in their interior. It forms a sort of bridge above the anterior orifice of the aqueduct of Sylvius.

The Aqueduct of Sylvius.

The *aqueduct of Sylvius*, or aqueduct of the corpora quadrigemina, which was described by both Galen and Vesalius, and by the latter quite as perfectly as by the anatomist after whom it was named, is a canal which establishes a communication between the third and fourth ventricles (*l v*, *fig.* 282)—*iter a tertio ad quartem ventriculum*; it passes through the isthmus of the encephalon, in the median line, below the tubercula quadrigemina (*f g*). It is directed obliquely downward and backward. Its walls are dense, and lined by the membrane of the ventricles. This canal presents both on its upper and its lower wall a longitudinal groove or median furrow, bounded by two small longitudinal cords. The median furrow on the lower wall is continuous with the longitudinal groove of the calamus scriptorius. The brothers Wenzel have given a minute description of these two furrows, and they have also noticed two lateral furrows. It was stated by Vieussens that the opening of the aqueduct into the fourth ventricle was provided with a valve. But his statement is at variance with the results of observation.

It follows, therefore, from the preceding description, that the third ventricle has four openings, two of which communicate with the lateral ventricles, the third opens into the fourth ventricle, and the fourth (between *b* and *x*, 280) leads into the infundibulum.

The third ventricle, moreover, has three commissures: one composed of gray matter, viz., the commissura mollis, or commissure of the optic thalami; the other two of white substance, one being anterior and the other posterior.

The Conarium, or Pineal Gland.

The *conarium*, *pineal gland*, or pineal body, is a small grayish body (*p*, *figs.* 280, 282) situated in the median plane, behind the posterior commissure of the third ventricle, and between the nates, upon which it rests.

It is retained in this situation by two small medullary cords, which are called its peduncles, and by the velum interpositum, below which it is placed, and by which it is almost completely invested as with a closely-adherent sheath: the adhesion between these parts is so intimate that they are almost always removed together; and hence some anatomists have regarded the conarium as a dependance of that membrane, and others, who

* Out of sixty-six brains of subjects of all ages examined by the brothers Wenzel, the soft commissure was found in fifty-six. It was, therefore, wanting in ten cases. The facility with which it is lacerated may have misled these industrious investigators into a belief that its absence was more frequent than it actually is.

have not been careful in their examinations, have declared that it is sometimes wanting in the human subject. This body, however, always exists in man and the mammalia. It is wanting in birds and fishes, and in reptiles, with the exception of the tortoise, in which it is so remarkably large that it forms by itself a kind of brain.—(Desmoulins, *Anat. du Syst. Nerv.*, t. i., p. 211.)

This body is shaped like a cone, having its adherent base turned forward and its free apex backward; hence its name of *conarium* (*Oribasius, Galen*); it has also been compared to a pine cone, and has been named the *pineal gland*, or *pineal body*. Its form, however, is subject to some variety; it is sometimes spheroidal, and at other times cordiform, from being notched at the base.

The pineal body is small, being only about four lines in length, and from two to three lines wide at the base. Its size, in the animal series, does not appear to bear any proportion to the size of the cerebrum, or of the cerebellum, or of the tubercula quadrigemina, so that comparative anatomy throws no light upon this obscure subject. Neither age nor sex has any influence upon the development of this small body.

Relations.—The conarium or pineal gland, enclosed in the pia mater, like the cerebrum and cerebellum, rests upon the slight triangular depression between the nates: the venæ Galeni run along its sides.

When stripped of the pia mater, it is free in all directions, excepting at its base, which is connected with the encephalon by a *transverse commissure*, situated above the posterior commissure of the cerebrum, and by *four slender peduncles*, two of which are superior and two inferior. The *superior peduncles* (*s*, *figs.* 280, 282), which are the only ones generally described, form together a sort of loop, the two ends of which run along the tops of the optic thalami; they have been named the reins of the pineal body (*habenæ*). We have already seen that they are continuous with the fornix. The *inferior peduncles*, which are distinctly seen only upon a longitudinal vertical section through the middle of the cerebrum, arise from the base of the pineal body, pass vertically downward upon the back part of the internal wall of the third ventricle, and may be traced to the lower part of that cavity.*

Colour and Consistence.—The reddish-gray colour of the pineal body contrasts strongly with the whiteness of its commissure and peduncles. The colour and consistence of this body exactly resemble those of the gray matter of the cerebral convolutions. If it be compressed between the fingers, a viscid juice exudes, and certain small concretions are found in it, which I shall notice after having described the structure of this organ.

Structure.—At the base of the pineal body are seen some white or medullary fibres, which arise from the commissure and from the superior peduncles of that organ. These white fibres spread out into a tuft, and terminate abruptly. All the rest of the conarium consists of gray matter. On making a horizontal section of this body, it is sometimes found to be solid, and sometimes to be hollow, and to contain a transparent, viscid fluid. The cavity is lined by a vascular membrane, and, according to Meckel, by a layer of medullary substance, which I have never seen. It has been stated that it communicates with the third ventricle; but I am inclined to believe, with Santorini and Gerardi, that the communicating orifice admitted by some authors is the result of traction upon the base of the conarium in attempting to remove the pia mater.

When the pineal body contains no distinct cavity, which is not unfrequently the case, the viscid fluid is distributed through it as through a sponge.

As to the nature of this body, it appears to consist of a soft gray substance, traversed by a great number of bloodvessels, having a very close resemblance to the gray matter of the brain, but none whatever to glandular tissues.

Concretions of the Conarium.—One of the most curious circumstances in regard to this body is the existence in it of certain hard concretions, which Ruysch and others regarded as small bones, an error which was successfully combated by Sœmmering. The use of them is utterly unknown.

Are these concretions constant? The brothers Wenzel found them wanting in six brains out of one hundred. Sœmmering states that he found them in fifteen brains, among which were some of very young infants, and he adds that they exist in the fœtus before the full period. Meckel says they do not appear until the sixth or seventh year, beyond which age he always found them.

These concretions sometimes form a single mass (acervulus, *Sœmmering*), resembling a granular lump of salt; sometimes, and most commonly, there are a great number of them.

They appear as aggregated granules, which the Wenzels believed to be connected by means of a proper membrane.

Seat of the Concretions.—When the pineal body is hollow, they are found in its interior; but when it is solid, they are situated upon the surface of this body. I have found them several times upon its peduncles.

* Ridley describes certain white striæ, arising from the pineal body, and terminating in the testes. Gall says that the inferior peduncles are directed backward, and somewhat downward, to become continuous with the subjacent white lamina. Plate xi., text, p. 223.

They are of an opaline yellow colour in old subjects, and are whitish in the young. According to Pfaff, they consist of phosphate of lime, carbonate of lime, and an animal matter.

They were incorrectly regarded as morbid deposites by Morgagni, who supposed, without proof, that they might produce cerebral affections of greater or less severity.

Function of the Pineal Gland.—The hypothesis of Des Cartes concerning the function of this body, which was so completely refuted by Steno, is a striking example of the abuse of an imperfect knowledge of anatomy; according to Des Cartes, the soul is seated in the pineal gland, and it directs all the movements of the body by means of the peduncles, which he regarded as the gubernacula or reins of the soul. M. Magendie thinks that this body performs certain functions having reference to the cerebro-spinal fluid: he has regarded it as a kind of plug, which would obstruct the orifice of communication between the third and fourth ventricles; but, in the first place, it is completely fixed by the pia mater; and in the second case, even if it were free, it could not in any case close the orifice alluded to. Morbid conditions of this body will perhaps throw some light upon its functions, but they have not yet been sufficiently studied. The existence of a cavity within the pineal gland, added to the fact that it is sometimes the seat of dropsy, would seem to indicate that its functions are connected with secretion.

The Lateral Ventricles.

Dissection.—The lateral ventricles are exposed by the same dissection as that which we have pointed out for the examination of the fornix and septum lucidum, that is to say, by removing the upper parts of the hemispheres and dividing the corpus callosum on each side of the median line (as in *fig.* 278, on the left side). In order to trace the reflected portion or descending cornu, it should be laid open by cutting through its outer wall from behind forward. There is also a great advantage in studying this part of the lateral ventricles from the base of the brain.

The *lateral ventricles* (*f i g h, fig.* 278) are two in number; they are much larger than the other ventricles; are placed symmetrically one on each side of the median line; they are separated from each other, but communicate through the medium of the third ventricle; their upper part is nearer to the base of the brain than to its upper surface, and they approach still nearer to the base by their reflected portion or descending cornu.

Each lateral ventricle commences (*f*) in the substance of the anterior lobe (*a*), a little in front of the third ventricle, and behind the anterior reflected extremity of the corpus callosum (*e*), by which it is bounded in front; from this point it passes vertically upward and backward, describing a curve with its convexity directed inward; having reached (*r*) opposite the posterior part of the third ventricle, it changes its direction, so as to turn downward and forward round the optic thalamus (*l*), and then terminates (*h*) in the substance of the sphenoidal portion of the posterior lobe [*i. e.*, in the middle lobe] (*c*) behind the fissure of Sylvius, and, consequently, a little below and behind the point (*f*) at which it commences. At the point of its reflection it also sends a prolongation (*g*) backward into the occipital portion of the posterior lobe (*b*). From this it will be understood why each lateral ventricle has been compared to a capital italic £ turned upside down, and why the cavity is said to have three cornua, viz., an *anterior* or *frontal* (*f*), *an inferior, descending* or *sphenoidal* (*h*), and a *posterior* or *occipital cornu* (*g*); on this account the lateral ventricles are frequently denominated *ventriculi tricornes.*

It is also seen that the ventricles are applied to each other at their anterior extremities, but diverge behind like the limbs of the letter *x*.

The general form of the lateral ventricles is very well shown upon a longitudinal section of the cerebrum through the median line; each of these ventricles is then seen to be nothing more than an elliptical canal or passage, which runs around the large ellipsoid mass formed by the optic thalamus and corpus striatum. This elliptical canal is only interrupted below and in front opposite the fissure of Sylvius. Anatomists describe in each lateral ventricle a *superior portion*, an *inferior portion*, and a *posterior portion* or *digital cavity.*

The Superior Portion of the Lateral Ventricle.

This portion, called the body of the ventricle (*i*), is broader in front than behind, and presents for our consideration a superior, an inferior, and an internal wall.

The *superior wall*, or the *roof*, is formed by the *under surface of the corpus callosum.*

The *inferior wall*, or the *floor*, is formed by the *ventricular surfaces of the corpus striatum* (*i*) and *optic thalamus* (*l*); between these two bodies are found the *lamina cornea* and *tænia semicircularis* (*n*).

The Corpus Striatum.—When examined from the lateral ventricle, each of the *corpora striata* (*i i, figs.* 278, 280) appears like a pear-shaped or conoidal eminence, having its larger end turned forward, and its other end, which is very narrow, prolonged backward, into the reflected portion of the ventricle. Its gray colour contrasts with the whiteness of the surrounding parts. Its free surface is covered by the lining membrane of the ventricles, and is very regularly marked by certain large veins which run across it.

The ventricular surface of the corpus striatum forms only one portion of this body, which has received its name from the white bundles or striæ which traverse the gray matter, of which it is principally composed.

The corpus striatum, considered as a whole, is an ovoid gray mass, lodged in a deep excavation formed opposite the *insula* or *island* of Reil, which is situated in the fissure of Sylvius, and which I propose to name the *lobule of the corpus striatum*. It will be seen, hereafter, that the corpus striatum is covered on the outer side by the convolutions of the *insula*, that it corresponds on the inner side with the optic thalamus and the gray matter of the third ventricle, and that it is exposed below, at the back part of the anterior lobes of the brain, behind the convolutions which form the sides of the furrow for the olfactory nerve.

The *optic thalami* (*l l*, *fig.* 280), which, as we have already seen, constitute the lateral walls of the third ventricle, form also, by their upper surface, a part (*l*, *fig.* 278) of the floor of the corresponding lateral ventricle; this surface, which is oblong from before backward, commences about six lines from the anterior extremity of the lateral ventricle: it is covered by the choroid plexus (*p*) and the fornix (*k*): the corresponding anterior pillar of the fornix turns round its anterior extremity, and the interval between the pillar and the thalamus forms the opening of communication between the third and the corresponding lateral ventricle. The brownish-white colour (*couleur café au lait*) of the optic thalamus distinguishes it from the corpus striatum, which lies along its outer side, the lamina cornea and the tænia semicircularis marking the limits between these two bodies.

The *lamina cornea* is a thick, semi-transparent band, of a horny aspect, which was compared by Tarin to a plate of horn, and which appears to be nothing more than a thickened portion of the lining membrane of the ventricle. Beneath and protected by it is found the *vein of the corpus striatum*, which receives the venous branches already described upon the surface of that body. Beneath the vein is seen a small, white, linear band (*n*), to which Willis first directed attention as the *limbus posterior*, and which is now called the *tænia semicircularis*.

I would observe, that the lamina cornea and the tænia semicircularis are two very distinct structures, which most anatomists have erroneously confounded.

More deeply, the limits between the corpus striatum and optic thalamus are marked by a white layer, described by Vieussens as the *geminum centrum semicirculare*, or *double semicircular centre*.

The lateral portion of the fornix and the choroid plexus (see *fig.* 278) must also be regarded as entering into the formation of the floor of the lateral ventricle. This lateral portion of the fornix resembles a band applied upon the optic thalamus, but separated from it by a fissure through which the choroid plexus becomes continuous with the velum interpositum:* the choroid plexus runs along the free edge of this band, and is sometimes turned up on to its upper surface.

The *internal wall*, or *septum of the lateral ventricles*, is much deeper in front, where it is formed by the *septum lucidum*, than behind, where it consists of a small vertical portion of the fornix, with which it terminates. We ought also to regard as forming a part of the septum of the lateral ventricles a prolongation on each side of the gray matter of the third ventricle, which passes round the corresponding anterior pillar of the fornix, and upon the lower part of the septum lucidum.

The Inferior or Reflected Portion of the Lateral Ventricle.

Dissection.—As the reflected portion or descending cornu belongs to the base of the brain, it is well to place the brain upon its convex surface, and then proceed to open it.

This cornu may also be reached from the great transverse fissure, by first removing the pia mater which enters there, and then partially dividing the lower wall of the cornu from the fissure of Sylvius backward, and turning back the lower wall on itself.

The *descending cornu* (*h*, *fig.* 278) *of the lateral ventricle* has two walls, a superior and an inferior. The superior wall (*b*, *fig.* 281) is concave, and, being moulded upon the *pes hippocampi* or *cornu ammonis* (*m*), which forms the inferior wall, is named *the sheath of the pes hippocampi*.

Upon the inferior wall are found the *pes hippocampi* or *cornu ammonis*, the *corpus fimbriatum*, the *fascia dentata*, the *great cerebral fissure*, and the *reflected portion of the choroid plexus*.

The *cornu ammonis* or ram's horn, *pes hippocampi*,† or *foot of the sea-horse*, is a conoidal eminence (*m*, *fig.* 278)‡ curved upon itself, and having its larger end turned forward, and

* [A comparison of *figs.* 278 and 279 will facilitate the comprehension of this statement; in the latter *fig.* the fornix is reflected backward, and the continuity of the choroid plexus (*p*) with the velum (*v*) is shown.]

† [The term *pes hippocampi* is generally applied to the anterior part only of this structure, the whole being usually called hippocampus major.

‡ I have not found, like Treviranus, the medullary substance of the anterior extremity of the cornu ammonis either continuous or communicating in any manner with the external root of the olfactory nerve; I cannot, therefore, admit that the functions of the cornu ammonis have any relation with those of the nerves in question. Treviranus believes that it assists in the remembrance of olfactory impressions. It is unfortunate for

its small end backward. Its concave border, which is directed inward and forward, is bounded by a narrow, thick, and dense band, which forms a continuation of the posterior pillar of the fornix; this is the *tænia hippocampi*, so improperly named the *corpus fimbriatum*, or *fringed body* (*s*).

On raising up the tænia hippocampi (*s*, *fig.* 281), there is seen beneath it a band of gray matter (*d*), which runs along the inner border of the cornu ammonis: this gray matter, which is, as it were, crenated by transverse furrows, has been well described by Vicq d'Azyr, under the name of *corps godronné*, or *fascia dentata*.

Fig. 281.

To obtain an accurate idea of the cornu ammonis, it is necessary to examine vertical sections of it, as was done by Vicq d'Azyr, who has given very good figures of such sections: it is then seen (as in *fig.* 281) that the hippocampus major (*m*) is formed by a reflection of the hemisphere inward upon itself, as the brothers Wenzel have very well shown; and that it is composed of a convolution doubled or turned upon itself like a horn, so that the white convex part expands in the interior of the lateral ventricle, while the gray concave part is upon the surface of the cerebrum.*

The surface of a vertical section of the hippocampus major also presents a white spiral line (below *m*), which is the section of the white covering of this eminence, and a rather thick gray layer (*a*), which is subdivided into two smaller layers by a white streak (*c*); all these are arranged in a spiral manner.

The white layer which forms the covering of the cornu ammonis is continuous, on the one hand, with that which lines the rest of the lateral ventricle, and on the other (by means of the corpus fimbriatum, *s*) with the corpus callosum and the fornix. Not unfrequently a second pes hippocampi is found on the outer side of the first, to which it is concentric; it is called *pes accessorius* (*eminentia collateralis*). Meckel erroneously regards it as the result of an arrested development.

The inferior wall of the descending portion of the lateral ventricle farther presents for our consideration,

The *reflected* or *descending portion of the choroid plexus* (see *fig.* 278); and also the *great transverse fissure*, through which the choroid plexus becomes continuous (opposite *s*, *fig.* 281) with the external pia mater: the lower border of this fissure is formed by the hippocampus major and corpus fimbriatum; and the upper border by the lower surface of the optic thalamus, which presents in this situation the *corpus geniculatum externum* (*j*, *fig.* 271), an oblong eminence, which is continuous with the optic tract, and the *corpus geniculatum internum* (*i*), a small rounded eminence, which is circumscribed by the corpus geniculatum externum.

The Posterior Portion of the Lateral Ventricle.

The *digital* or *ancyroid cavity* (ἄγκυρα, a hook) is the occipital portion (*g*, *fig.* 278) of the lateral ventricle. The term digital cavity has arisen from its having been compared to the impression which the finger would leave if pushed backward into the substance of the brain. It commences at the point where the ventricle is reflected upon itself, passes horizontally backward, describing a curve with the convexity turned outward, and becomes gradually narrower, until it terminates in a point. The dimensions of this cavity are extremely variable, not only in different individuals, but even in the same subject. Thus, a very large digital cavity is often found on the right side, while on the left there is only a trace of it.

Acute ventricular hydrocephalus affects the digital cavity more than any other part of the ventricle.† In some cases the bottom of the digital cavity is not more than half a line from the surface of the brain.

In the natural state, the upper wall of the digital cavity is exactly fitted to a conoidal eminence, which occupies the lower wall or the floor of that cavity, and which differs in its dimensions according to the size of the cavity itself. This eminence (*n*), which is variously named the *unciform eminence*, *colliculus*, *calcar*, *unguis*, was very well described by Morand,‡ under the name of the *ergot*, and is therefore generally called the *ergot of Morand*.

In form it rather closely resembles the hippocampus major, so that we ought, perhaps, to prefer, with Vicq d'Azyr, the name of *hippocampus minor*. There is not only a correspondence in form, but also in structure, between the two hippocampi; and the brothers Wenzel appear to me to have clearly shown that the ergot of Morand, like the hip-

this hypothesis, that the animal in which the cornu ammonis is most developed, viz., the hare, is precisely that in which there is least evidence of memory.

* I could never perfectly understand the structure of the cornu ammonis until I had examined it in ruminantia and rodentia, but especially in the latter, in which it is most developed. In the rodentia the reflected portion of the hemisphere is almost as large as the hemisphere itself, and the connexions of the cornu ammonis with the fornix are seen most distinctly. It is quite evident that the fornix, the cornu ammonis, and the corpus fimbriatum, form only one system of fibres, and are continuous with each other.

† It is probable that this is simply the mechanical effect of long-continued lying upon the back.

‡ Mem. de l'Acad. des Sciences, 1744. Observ. Anatomiques sur Quelques Parties du Cerveau.

pocampus major, is nothing more than a special convolution projecting into the ventricle. It, in fact, consists of a white layer, enclosing a thick mass of gray substance. A longitudinal anfractuosity, the depth of which depends on the prominence of the ergot, denotes on the surface of the brain the situation of the digital cavity: this anfractuosity is constant, and I have already described it as the *anfractuosity of the digital cavity*. There is also another circumstance which favours the analogy between the ergot and the hippocampus major, and that is their continuity; for there is only a depression between them, and the white layer which connects them is continuous in both cases with the fornix.

Gredinsh as described several varieties of the ergot; not unfrequently it is double, and, as we have mentioned, so is the hippocampus major. The absence of the ergot is regarded by Tiedemann as the result of defective development.

The ergot and the digital cavity scarcely exist except in man, doubtless because he alone has the occipital portion of the brain greatly developed.

The Choroid Plexuses.

The *choroid plexuses of the brain*, which have already been noticed in the descriptions of the third and lateral ventricles, form a continuous system of vessels, as can be easily shown by examining the brain from the base upward. Upon the under surface of the velum interpositum, and on each side of the median line, are two small, red, granular bands, running from behind forward, bordered by the veins of the corpora striata, and terminating in front upon the convexity of an arch which forms the boundary of the velum in that direction. This arch is formed by the junction of the anterior extremities of the choroid plexuses. It is situated behind the anterior pillars of the fornix, at the point where those pillars unite, and is crossed at right angles by the veins of the corpus striatum, which pass above it; after this junction, the choroid plexuses again separate and enter the lateral ventricles through the foramen (foramen of Monro) which leads from the third to the lateral ventricles; within each of the lateral ventricles they describe an elliptical curve (*p*, *fig.* 278), which is accurately moulded upon the optic thalamus, and runs along the fornix in the upper part of the ventricle, and along the corpus fimbriatum in the descending cornu or reflected portion.

The upper part of the choroid plexus is very narrow; the lower part is three or four times broader than the upper; its upper and under surfaces are free, and also its outer border, which contains a large vessel; its inner border is continuous with the velum interpostum* in the upper part of the lateral ventricle, and in the descending cornu with the pia mater, at the base of the brain.

The lining membrane of the ventricle adheres intimately to the inner border of each choroid plexus, so that the lateral ventricles are completely closed, and no fluid can escape through the semicircular fissure which extends along their entire course.

The choroid plexuses are granular, or, rather, consist of vascular tufts, which are unlike any other structure in the body, and their uses are quite unknown.

The Lining Membrane and the Fluid of the Ventricles.

The middle and lateral ventricles are lined by a transparent and tolerably strong membrane, of which the horny lamina between the corpus striatum and thalamus opticus is a part. On tracing this membrane from the third ventricle, it is seen to pass into the lateral ventricles through the foramen (of Monro), behind the anterior pillar of the fornix. From the third ventricle it also descends into the fourth through the aqueduct of Sylvius.

It is extremely easy to demonstrate this membrane, especially upon the septum lucidum and corpora striata, and in the digital cavities.

In order to separate it to any extent, it must be dissected from without, by gradually removing the layers of cerebral substance by which it is covered. This separation occurs in acute ventricular hydrocephalus, in consequence of the pultaceous softening of the surrounding tissue. In the fœtus and new-born infant, this membrane can be separated with the greatest facility, on account of its density and the softness of the surrounding parts.

Three questions present themselves regarding the ventricular membrane: Is it a serous membrane? Does it communicate with the arachnoid, so that it ought to be regarded as a continuation of that membrane? How is it arranged along the fissure of each lateral ventricle?

That the ventricular membrane is a serous membrane is shown by the nature of the fluid exhaled into the cavity of the ventricles; by the structure of the membrane itself, which consists entirely of lymphatic cellular tissue; and by the diseases of the ventricles, which are precisely similar to those of other serous cavities.†

* Compare *figs.* 278 and 279.

† The occurrence of acute and chronic serous effusions, of purulent formations, and of miliary granulations in the ventricles, are proofs of the serous nature of their lining membrane.

[The ventricular membrane has a ciliated epithelium on its inner surface.]

The number of veins which are situated beneath the ventricular membrane has suggested the notion that it was a prolongation or continuation of the pia mater; but these vessels do not belong to the membrane.

The continuity of the ventricular membrane with the arachnoid on the surface of the brain has not been demonstrated. I have already said that the so-called canal of Bichat does not exist.

It has been stated that each lateral ventricle is divided, both in its direct and reflected portions, by a circular fissure which turns round the optic thalamus, and through which the pia mater becomes continuous with the choroid plexus. This fissure is closed by blood-vessels, and some very dense cellular tissue, and in the interior of the ventricle by the lining membrane, which is firmly attached on both sides of the fissure to the adherent borders of the corresponding choroid plexus. It cannot be admitted that it passes from one side of the fissure to the other, so as to enclose the plexus.

It is this membrane which prevents any fluid contained in the ventricles from infiltrating into the sub-arachnoid cellular tissue at the base of the brain.

The very frequent coincidence of ventricular dropsy with the formation of false membrane in the cellular tissue at the base of the brain shows the relation between that tissue and the lining membrane of the ventricles, but by no means establishes the existence of any direct communication between the ventricular cavities and the cellular tissue at the base of the brain.

The Ventricular Fluid.—The existence of a serous fluid in the ventricles was generally admitted by the older anatomists, who named it *pituita*, and considered it to be an excrementitious fluid, which was evacuated through the nasal fossæ. During the last century, anatomists were so convinced of its existence in all subjects, that they regarded those cases in which it was not found as exceptions; *a recentissimis cadaveribus abest nonnunquam*, says Haller, in speaking of an observation made by Verduc upon the brain after death by decapitation. But the anatomists of the last century differed from the ancients in regarding the existence of fluid in the ventricles as a post-mortem phenomenon, depending on the condensation, by cold, of a vapour which, in their opinion, alone exists in the ventricles during life. This vapour, the only use of which, according to the view stated, would be to prevent adhesion of the opposite walls of the ventricles, was compared by them to that which is found in the pleura, pericardium, and peritoneum of a living animal.

The experiments of M. Magendie have proved the existence of a ventricular fluid during life; and farther, that it may flow backward and forward into the spinal sub-arachnoid space, through the opening (*y*, *fig.* 282) in the lower part of the fourth ventricle.

The quantity of fluid in the several spaces found in the cranial cavity is extremely variable, for it increases or diminishes according to the relative bulk of the brain in reference to the osseous case of the scull.

Having thus examined the brain by horizontal sections, made at different heights from the convex surface towards the base, it is important, in order thoroughly to understand the parts we have described, to study them under different aspects, either by means of particular sections, or by the aid of the various methods adopted by different anatomists.

A Median Vertical Section of the Brain.

Upon this section (*fig.* 282), which divides the brain into two perfectly similar halves, a great many objects are seen: and first, the optic thalamus and corpus striatum, which might be said to form the central nucleus or root of the cerebrum.

Fig. 282.

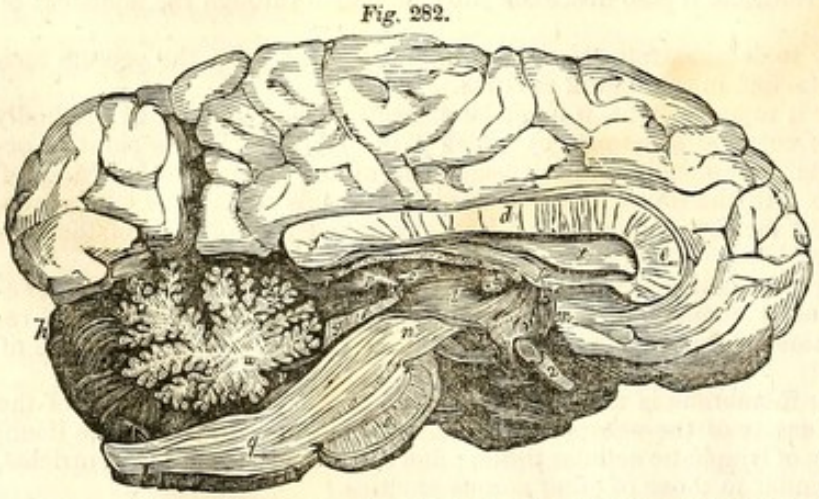

The optic thalamus is now seen to be smooth and free on its inner surface, where it forms the lateral wall (*l*) of the third ventricle; it is convex and free above, where it forms part of the floor of the lateral ventricle, and it is also free below, where it presents to our notice the corpora geniculata. Behind, it is continuous with the tubercula quadrigemina, and in front with the corpus striatum; on the outer side it is blended with the corresponding cerebral

hemisphere, and below it is deeply notched for the reception of the corresponding cerebral peduncle.

The corpus striatum forms a concentric curve along the outer side of the opic thalamus; it commences in front by a large pyriform extremity, diminishes in size as it proceeds backward, and terminates in a very narrow gray band, which turns round the optic thalamus as far as the termination of the descending cornu of the lateral ventricle, *i. e.*, as far as the large end of the cornu ammonis.

The lateral ventricle forms a circular or elliptical trench around this central nucleus, formed by the thalamus opticus and corpus striatum (see *fig.* 278). It commences in the substance of the anterior lobe of the cerebrum (*anterior* or *frontal cornu*), mounts up upon the corpus striatum, passes horizontally backward, and, becoming widened, divides into two prolongations: one horizontal (*digital cavity, occipital* or *posterior cornu*), which dips into the substance of the posterior lobe, and terminates near the surface of the brain; the other reflected, which runs from behind forward, and terminates behind the fissure of Sylvius, so that the lateral ventricle would describe an almost complete ellipse if it were not for the layer of cerebral substance which forms the bottom of the fissure of Sylvius, and which separates the commencement (*f*) from the termination (*h*) of the ventricle.

Upon the longitudinal section is also seen the regular curve of the corpus callosum (*e d f, fig.* 282), which runs around the central nucleus. The unequal thickness of the different parts of the corpus callosum, its reflection in front so as to embrace the anterior extremity of the corpus striatum, its posterior enlarged extremity or protuberance, and its continuity with the fornix, are shown; and farther, it is seen that the space between the corpus callosum and the central nucleus of the brain constitutes the upper part of the lateral ventricle, and that the interval between the cornu ammonis and the nucleus constitutes its reflected portion.

In this section we also notice the septum lucidum (*t*), the fornix (*k*), the mammillary tubercle (*z*), the tuber cinereum, the gray commissure (*b*) and gray mass of the third ventricle, the infundibulum (*i*), the optic nerve (2), the section of the anterior commissure (*c*), also that of the posterior commissure (*x*), and the peduncle (*s*) of the pineal gland (*p*).

The longitudinal section also shows that the third ventricle is formed by the juxtaposition of the two central nuclei of the cerebral hemispheres; that these hemispheres are only connected to each other by the corpus callosum and the commissures, and therefore that it is by studying these parts that the system of communicating fibres between the two hemispheres is displayed.

It is moreover seen that each hemisphere may be regarded as composed of a white and gray covering which surrounds a central nucleus. And it is between the general central nucleus and the hemispheres, or, rather, between the fornix and its prolongations on the one hand, and the optic thalami on the other (as at *s, fig.* 281, for example), that the ventricles would communicate with the exterior if the ventricular membrane were not firmly attached to the choroid plexus: it is also in the same situation that the external pia mater passes into the internal.

The Central Nucleus.—A very curious preparation may be very easily made upon this vertical median section, to show the central nucleus separated from the other parts. If the handle of a scalpel be introduced between the corpus striatum and the reflected portion of the corpus callosum, it will be found that the ventricular membrane is the only means of connexion between them, and that the corpus callosum forms, at this point, a sort of outer case of medullary substance for the corpus striatum, the entire anterior portion of which may be exposed without breaking through any connecting fibres. The anterior part of the corpus striatum may also be exposed from below, that is to say, by dissecting from the base of the anterior lobe of the cerebrum towards the lateral ventricle; for this purpose, the handle of the scalpel must be inserted along a curved whitish line, the concavity of which is turned forward, and which limits the anterior lobe behind.

The corpus striatum can be completely isolated only in front and opposite the fissure of Sylvius, in which situation it is covered by only a slight thickness of cerebral substance, which is seen to consist of four very distinct layers, viz., the external gray layer of the convolutions; a very thin white layer; an equally thin gray layer; and, lastly, another layer of medullary substance.

Transverse Vertical Sections.

I am in the practice of making five transverse sections of the cerebrum: the first, immediately in front of the corpus callosum; a second through the largest part of the corpora striata; a third through the anterior part of the optic thalami; a fourth through the middle of the thalami; and a fifth through the occipital portion of the posterior lobes. I shall not here enter into a detailed description of these several sections, which appear to me to convey a more correct idea of the structure of the brain than any other sections, but which cannot be well understood without figures. They disclose, in fact, a medullary centre giving off three or four prolongations of white substance, which constitute, in their turn, the medullary centres of a certain number of convolutions to which they are distributed; this ramified disposition of the medullary substance warrants the

application of the tern *arbor vitæ of the cerebrum* to the appearances seen upon these different sections.

The most interesting of these sections is undoubtedly that which passes through the cerebral peduncles, and which discloses the following appearances :

Each hemisphere is formed by a medullary centre, which gives off three principal prolongations, around which all the convolutions are arranged, and are thus collected into three groups, viz., a superior, an external, and an inferior group ; the last of these is connected with the medullary centre by a long narrow pedicle which corresponds to the white matter on the outside of the corpus striatum. The corpus striatum and optic thalamus are situated opposite to this pedicle or prolongation of the medullary centre.

The medullary centres of the two hemispheres are connected together by the corpus callosum, which forms an arch with the concavity directed downward. Moreover, either the section of the septum lucidum, or of the fornix, is seen according to the point at which the knife has been carried through.

The transverse section through the corpora striata and optic thalami deserves special attention. If the section be made through the anterior part of the corpus striatum, and therefore in front of the optic thalamus, the former body presents an oval gray surface, dotted with white points, which are sections of medullary fibres ; the middle of this oval surface is traversed by a series of small, parallel, white fasciculi, which are sections of the medullary bands that pass through the corpus striatum. On the outer side of the corpus striatum are seen distinctly the four layers formerly mentioned as corresponding to the island of Reil. The white layer which turns round the outer surface of the corpus striatum may be said to be reflected upward to form the septum lucidum.

Several of these sections appear to me to show that certain white fibres, which arise in the interior of the corpora striata, pass to the circumference of the optic thalami ; or it may be said that certain white fibres arise in the optic thalami, spread out, and are lost in the substance of the corpora striata, beyond which it is impossible to trace them. This beautiful section suggested to M. Foville* some ideas respecting the structure of the brain, to which I shall presently have occasion to refer.

The Section of Willis.

Previously to the time of Varolius and Willis, anatomists were contented with making successive horizontal sections of the brain from the vertex towards the base, and studying minutely the parts thus exposed; and each anatomist believed that he had described different objects when chance presented him with some arrangement that had not been previously described. Willis insisted upon the necessity of carefully removing the membranes from the surface of the brain, and he objected to the usual method of examining this organ by making sections, which destroy the connexions between its different parts ; he considered the brain to be composed of *parts folded* upon themselves, collected into a globular form, and connected to each other by mutual prolongations. He also pointed out the importance of first examining the brains of animals, which are much more simple than the brain of man, the size and complexity of which render its study one of great difficulty.

After having made these judicious remarks, Willis proceeds to describe the following mode of making the section which he had contrived, for the purpose of unfolding the cerebrum and opening out this spheroidal mass into a flat surface :†

Place the brain, completely stripped of its membranes, upon its convex surface ; turn forward the cerebellum and the medulla oblongata ; introduce the knife into the fissure of Sylvius, and carry it backward as far as the digital cavity ; a flap will thus be detached, comprising all the lower wall of the descending cornu of the lateral ventricle. Repeat this section on the opposite side ; and, after having turned backward the flaps thus formed, another section must be made on each side of the brain, extending from behind forward along the corpus striatum, on a level with the outer border of the corpus callosum, and reaching to the anterior extremity of the lateral ventricle. Turn forward the intermediate flap, which will comprise the cerebellum, the pons Varolii and peduncles, the optic thalami, and the corpora striata.

The whole of the interior of the ventricle is thus exposed, so that we can examine the lower surface of the corpus callosum, and its continuity with the centrum ovale of each hemisphere, or the centrum ovale of Vieussens seen from below. The continuity of the fornix with the cornu ammonis is also well displayed.‡

* Note sur la Structure du Cerveau, 24e Bulletin de la Société Anatomique.—(*Nouvelle Bibliothèque Médicale.*)

† The brains of animals being much less complicated than that of man, are more convenient for this purpose. The brain of a sheep thus unfolded is represented by Willis in his *Cerebri Anatome*, fig. vii.

‡ This section, which, however, like all similar methods, is liable to the objection that it destroys the connexion of parts, suggested to M. Laurencet the idea of comparing the cerebral mass to a nervous loop, analogous to the loops described by MM. Prevost and Dumas as forming the terminations of the nerves. According to this view, the nervous system would represent an elongated ellipse, one end of which would be represented by the brain and the other by the extremities of all the nerves ; but both loops are equally inadmissible.

General Remarks upon the Method of examining the Brain by successive Sections.

The method of examining the brain by successive sections has been carried farthest by Vicq d'Azyr, whose beautiful plates are entirely devoted to the demonstration of the objects seen upon various sections of the brain made in succession either from below or from above. This method unfolds to us the relative disposition of the gray and white substances, shows the manner in which the ventricles are formed, and displays to us the real nature of parts which, in consequence of their projecting and being free at some part of their surface, have received particular names.

But this mode of examining the brain can only be regarded as a preliminary means calculated to give an idea of this organ as a whole; and it tends to perpetuate the erroneous opinion that the brain is a pulpy mass, consisting of a semi-fluid substance, and displaying no more evidence of contrivance in its structure than a ball of wax.

The method adopted by Varolius and Vieussens, which fell into disuse after the publication of the beautiful work of Vicq d'Azyr, and which consisted in determining the connexion of the different parts of the brain, has been revived and improved by Gall and Spurzheim, who have thus opened up the path which modern anatomists have so eagerly pursued.

Methods of Varolius, of Vieussens, and of Gall, or the Examination of the Connexions of the Different Parts of the Brain.

Varolius was the first to perceive that the essential point in the study of the brain was to ascertain the connexion of its several parts. He was also the first who dissected the brain from below, and who specially examined its connexion with the spinal cord; he described the spinal cord as originating from the brain, not opposite the foramen magnum, but from the lower part of the cerebral ventricles.

Vieussens traced the bundles of the pyramids through the pons Varolii to the peduncles of the brain, and followed these peduncles through the optic thalami and the corpora striata into the centrum ovale, which is named after him. But there his inquiries ended, for, according to him, it was in this centre that the linear or radiated structure terminated; and his preconceived notion of a nervous centre (centrum ovale), from which, with Varolius, he described all the fibres as proceeding downward, prevented him from carrying his researches farther.

Gall followed up the investigations of Varolius and Vieussens, but instead of dissecting the fibres from above downward, or from the brain towards the medulla, he traced them from below upward, or from the medulla towards the brain, and followed them through the centrum ovale as far as the convolutions.

The method adopted by Gall in order to separate the fibres of the cerebrum and show their connexions was to scrape them with the handle of a scalpel. But, from the nature of this proceeding, only those white fibres can be conveniently traced which pass through gray matter, but the white fibres themselves can never be separated from each other. Hardening the brain in strong alcohol, in nitric or muriatic acid, or by boiling it in oil, or by macerating, or boiling it in a solution of salt, facilitates the separation of its fibres; but, as the results obtained in these modes might be considered as purely artificial, the action of a stream of water is preferable to any of them.

The results obtained by acting on the brain by streams of water fully confirm those which are arrived at by the examination of the hardened brain.

Again, the anatomy of the fœtal brain and comparative anatomy have also aided in throwing light upon the connexion between the different parts of the brain.

As the works of Gall were the commencement, if not the foundation, of all that has since been done, I have thought it necessary to give a brief summary of his views regarding the structure of the brain; and as a knowledge of its structure consists in a great measure in that of its connexions with the cerebellum and spinal cord, the examination of these two subjects cannot properly be separated.

Gall and Spurzheim's Views of the Structure of the Brain.

Gall and Spurzheim commence by stating, 1. That as the brain consists of several departments, the functions of which are totally different, there are several primitive fasciculi which, by their development, assist in the formation of that organ. 2. That these fasciculi are composed of medullary fibres arising successively from the gray matter, which, with Vicq d'Azyr, they regard as the matrix or generator of the white substance. 3. That there exist in the brain a formative system of fibres, or a formative apparatus, and systems of uniting fibres, called commissures. In the first, or formative system, Gall describes four primitive fasciculi; namely, the anterior pyramids, the posterior pyramids, the olivary fasciculi, the longitudinal fasciculi, which assist in forming the fourth ventricle, and some others which are yet imperfectly understood.*

* It will be observed that Gall's fundamental statements are hypothetical: that the brain is developed from certain primitive fasciculi, that there is a successive increase of these fasciculi from below upward, and that

Formative System of Fibres.—The anterior pyramidal fasciculi decussate at their origin, but the other fasciculi arise on the same side as the hemisphere to which they belong.

The anterior pyramidal fasciculi (*b'*, *figs.* 273, 274) are re-enforced as they pass through the pons Varolii (*m*), which is therefore, according to Gall's view, a ganglion, named by him the ganglion of the anterior pyramidal fasciculi; these pyramidal fasciculi constitute the cerebral peduncles (*x*, *fig.* 283), and diverge (*y y'*) so as to enter the inferior, anterior, and external (*i* and *m*, *fig.* 284) convolutions of the anterior and middle lobes.

Gall, in his beautiful plate, No. V., shows the expansion of the fibres of the peduncles, their distribution, their unequal lengths, and the manner in which their expanded extremities are covered with gray matter to form the convolutions.

It still remains to determine how the superior convolutions and those of the posterior lobe are formed: the following are the statements of Gall on this point:

The olivary bodies of the medulla oblongata are nothing more than ganglia, from each of which a very strong bundle, the *olivary fasciculus* (see p. 708), emerges, and ascending behind the pons, where it is considerably re-enforced, passes through the gray matter which lies upon the white fibres of the cerebral peduncle, where it again receives some additional fibres; this gray matter constitutes a rather firm ganglion on each side; these are the *optic thalami*, which, according to Gall, do not assist in the formation of the optic nerves, and bear no proportion to them in size.

The olivary fasciculi, which are divided into very delicate filaments in traversing the optic thalamus, are again collected together as they emerge from its upper border. They then pass through a thick mass of gray matter, the *corpus striatum*, half of which projects into the ventricular cavity, while the other half is surrounded by the convolutions of the island of Reil. The radiated fasciculi (*k*, *fig.* 284) are again re-enforced in traversing the corpus striatum, which is regarded by Gall as another ganglion, and are then sufficient to form all the posterior convolutions, and also those which are situated along the upper border of each hemisphere, in the median line (*h h h*).

It therefore follows, according Gall, that the convolutions are nothing more than the perfecting of all the preceding structures, which should be regarded as preparatory systems of fibres destined to form a whole.

Fig. 283.

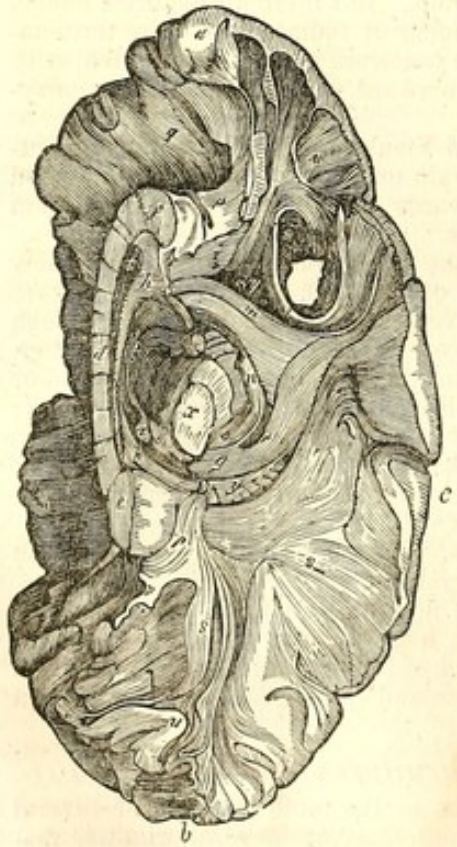

Uniting System of Fibres or Commissures.—Even the oldest anatomists regarded the corpus callosum as the connecting medium between the two hemispheres; Vicq d'Azyr, who described several other commissures besides the corpus callosum, regarded them as intended to establish sympathetic connexions between the different parts of the brain. Gall, taking a more comprehensive view of this subject, attempted to determine what parts of the brain were connected by this means, and to discover the general law which governs the arrangement of the commissures, which he believed to be formed by a system of fibres and bundles, named by him *faisceaux rentrans ou convergens*.

We have seen that Gall traces the pyramidal and olivary fasciculi to the gray matter of the convolutions. According to him, all the extremities of the medullary fibres penetrate the gray matter, which is therefore whiter internally than on the surface. Gall acknowledges that he has not been able to determine their ultimate distribution; he *does not know* whether they terminate in the gray matter, or turn back again towards the interior. Nevertheless, he considers it *very probable* that new medullary filaments originate in this gray layer, and that there is thus *produced a system of fibres which re-enforces the preceding* one, and is connected with it internally.*

the gray substance is the matrix of the white, are so many suppositions. Of the primitive fasciculi, the anterior pyramids alone are well defined; the inaccuracy in the representation of the posterior pyramids disfigures his sixth plate.

* Nothing certain appears likely to arise from this proposition, and yet Gall immediately adds (p. 202), "It is certain that the existence of two systems of fibres in the brain can be distinctly demonstrated, and that the converging system contains more fibres and stronger fasciculi than the radiating system." On seeking for his proofs, we find that he infers that converging fibres must necessarily exist, from the disproportion between the white matter of the hemispheres and the fibres which come to them from the fasciculi of origin. "The converging fibres," says he, "at the bottom of all the convolutions, are seen to enter between the diverging fibres, and interlace with them." It is very evident, from an examination of the proofs adduced by Gall in support of the existence of converging fibres, that the distinction between the converging and diverging fibres is purely hypothetical.

According to Gall, the commissures are, the *corpus callosum*, the *fornix*, and the *anterior* and *posterior commissures*.

The corpus callosum (*f d e*, *fig.* 283) is intended to unite the convolutions of the two hemispheres. Its anterior reflected portion unites the inferior convolutions of the two anterior lobes (*f p a a*). The enlarged posterior extremity (*e*) receives the fibres (*s s*) of the posterior convolutions (*b*) and the middle portion of those of the middle convolutions (*c*).

The anterior commissure, which can be so easily traced (*m*) through the corpus striatum into the convolution of the sphenoidal extremity of the posterior [middle] lobe, is regarded by Gall as the means of connecting certain corresponding convolutions in the sphenoidal portions of the two posterior [middle] lobes.

The posterior commissure, which is lost in the substance of the optic thalami, and which is much smaller than the anterior, fulfils the same purpose for those bodies.

The posterior pillars (*k*) of the fornix are regarded by Gall as forming a commissure for the posterior convolutions of the two middle lobes. The fornix appears to him to result from the connexion of these parts, and he considers the interlacement called the *lyra* to be composed of the connecting filaments. His error here is evident, for the fornix results from the juxtaposition of two medullary cords. The fornix may be regarded as an antero-posterior (*h h*), but not as a transverse commissure.

The Ventricles and Convolutions.—The formation of ventricles is considered by Gall to be the *necessary* result of the divergence of some fasciculi and the convergence of others.

His description of the convolutions is entirely new, and one cannot but regret that it should be disfigured by the hypothesis of converging and diverging fibres. The following is his mode of describing these parts, which he regards as the completion and final object of the organization of the brain, and as performing the most elevated functions.

Gall admits two layers in each convolution; and he finds that these two layers can always be readily separated, *but only* in the median line. He successfully proves, in opposition to the commission of the Institute, that the convolutions are not composed of a white, soft, and pulpy matter, resembling pomade or jelly, but that they have a fibrous or linear structure.*

Unfolding of the Cerebrum.—The idea of unfolding the brain, which is nothing more than opening out the convolutions, was derived by Gall from his view of the structure of the convolutions, which he regarded as formed of two layers united by very delicate cellular tissue. It was also suggested to him by the examination of hydrocephalic brains, in which he conceived there was no disorganization, but merely an unfolding of the convolutions. The following is his method of unfolding the brain: after having very carefully removed the meninges, he introduced his fingers into the great transverse fissure between the optic thalamus and the hippocampus major, and thus penetrated into the lateral ventricles: he then pressed gently against the outside of the ventricles; he broke down the white matter of the hemispheres until he reached the base of the convolutions, which then necessarily became unfolded, so as to be moulded upon the back of his hand; the astonished spectators would have wondered less if they had seen the lacerations necessary to produce this result.

The unfolding of the brain is impossible if Gall's views be correct; for, according to him, the white fibres of the brain are not all of equal length, and those which correspond to the anfractuosities are much shorter than those corresponding to the convolutions; besides, I am convinced that, in hydrocephalus, the convolutions are not unfolded, but are atrophied, flattened, and compressed against each other.

Such are the principal ideas of Gall regarding the structure of the brain.† His system undoubtedly contains numerous errors and imperfections; but, nevertheless, it has established a new era in the study of the anatomy of this organ.

General Idea of the Brain.

1. The decussation of the pyramidal fasciculi of the medulla oblongata, their passage through the pons Varolii, their continuity with the cerebral peduncles, of which they form the lower portion, their passage through the optic thalamus, and their expansion within the corpora striata (*k*, *fig.* 284), through which they may be traced (*h h h*) as far as the convolutions, are incontestable facts.

2. Again: it is no less certain that the fasciculi of re-enforcement of the medulla are

* See note, p. 756.

† The following is the completion of these ideas: 1. As the peripheral extremities of the nerves expand in all the organs of our body to form an immense surface (and of this expansion the retina is an excellent example), so do the primitive fasciculi of the brain, after being re-enforced in their passage through the different masses of gray substance, finally expand in the convolutions, and receive a covering of gray matter. 2. There are as many particular systems as there are different functions, but they are all connected together by anastomoses. 3. The nervous system is double, but is united into one whole by the commissures. 4. There is not, and there cannot be, any common centre of all the sensations, thoughts, and volitions. 5. Personal unity will always remain a mystery.

Each of these propositions might form the subject of ample commentary. I will merely remark the incongruity between the acknowledged fact of personal unity, and the singular proposition that there neither is, nor can be, any common centre of all the sensations, thoughts, and volitions.

prolonged above the pons into the cerebral peduncles, of which they form the upper portion (*x*, *fig.* 283), and become continuous, without any line of demarcation, with the optic thalamus. Do these fasciculi decussate? They remain distinct until they reach opposite the pons, behind the tubercula quadrigemina, where they unite; they appear to me to decussate, but not so evidently as the anterior pyramids, and I cannot venture to state this positively.

3. Fasciculi of white fibres radiate in all directions (*y y'*, *fig.* 283) from every part of the surface of the optic thalamus (*g g*), excepting its inner side, which is free, and corresponds to the third ventricle; the anterior of these fibres pass directly forward, the middle fibres outward, and the posterior fibres backward, forming the radiating crown of Reil (*k*, *fig.* 284).

Fig. 284.

As these radiating fibres emerge from the optic thalamus, they are bound down, as it were, by certain white curved fibres, which constitute the tænia semicircularis.

4. *All the white fasciculi of the corpora striata*, excepting those which are continuous with the anterior pyramids, proceed from the optic thalami. Some of them appear to me to terminate in the corpora striata in the form of extremely delicate filaments, but the greater number pass through the corpora striata without either increase or diminution, and then pass into the hemispheres. The corpora striata of Willis are, therefore, nothing more than gray pulpy masses, which are traversed both by the white fibres radiating from the circumference of the optic thalami, and by those which are derived from the anterior pyramids. The gray matter is not arranged in alternate linear striæ with the white substance. So far from thinking, with Reil, Gall, and Tiedemann, that the fibres which emerge from the corpora striata are much more numerous than those which enter it, I have been led to a precisely opposite conclusion, namely, that a certain number of fibres, proceeding from the optic thalami, terminate in the interior of the corpora striata, the gray matter of which, in reference to these fibres, represents the gray substance in the convolutions.

5. From the anatomical fact that a certain number of white fibres terminate in the corpora striata, and also from the size of those bodies being in some animals inversely proportioned to that of the hemispheres, it appears to me to follow that the corpora striata may be regarded as internal convolutions, in which a certain number of medullary fibres terminate.*

6. It is extremely easy, by means of a stream of water, to separate, and, as it were, enucleate the corpus striatum from the sort of shell formed for it by the cerebrum opposite the fissure of Sylvius. The corpus striatum is only connected with the cerebrum by the radiating fibres which emerge from its upper circumference near the corpus callosum.

The optic thalamus and its fasciculus of origin present no trace of a linear structure. Nor can we discover in it the concentric layers admitted by Herbert Mayo. With a little attention, certain extremely delicate white filaments are seen in the optic thalamus, which cannot be separated, on account of their tenuity and the adhesion of the surrounding tissue to them. If the term *ganglion* be applicable to any part of the cerebrum, it certainly is so to the optic thalamus; for a nervous ganglion is nothing more than a peculiar apparatus in which nervous filaments become separated and spread out, in order to enter into new combinations. We must agree with Reil and Tiedemann in regarding the optic thalami as appendages of the cerebral peduncles: Tiedemann calls them the *enlargements of the cerebral peduncles.*

7. The essential points to be made out in the structure of the cerebrum are the ultimate course of the fibres radiating from the optic thalami and corpora striata, and the relations of those fibres with the convolutions of the brain and the corpus callosum. I by no means agree with Reil in thinking that we must not attach so much importance to the continuity of fibres in the cerebrum, and that their contiguity is a sufficient guide to its anatomy: on the contrary, I regard the determination of their continuity as the key to the structure of this organ.

8. There is no median raphé in the corpus callosum, the right half of its transverse fasciculi being continued into the left half, without any line of demarcation.

* In several cases of chronic hydrocephalus, in which the hemispheres were reduced to a very thin lamina, I have found the optic thalami atrophied, and the corpora striata of enormous size.

9. It appears, at first sight, that the fibres of the corpus callosum (*e d f, fig.* 284), and the white radiating fibres (*k*), which emerge from the optic thalami and corpora striata, decussate (as at *g*); but on separating the fibres of the cerebrum, either after it has been hardened in alcohol or by the action of a stream of water, it is most distinctly shown that these two sets of fibres are continuous.

10. Again: the continuity of the fibres of the corpus callosum with those of the hemispheres is no less evident; the middle fibres (*s, fig.* 283) of the hemispheres are seen to pass transversely inward, the anterior fibres (*a p*) backward, the posterior fibres (*s*) forward, and the inferior fibres to bend and turn upward, to become continuous with the corpus callosum.

I have in vain endeavoured to determine by actual dissection whether there is a decussation of the fibres of the corpus callosum itself; I still entertain many doubts regarding this subject; we shall presently find, when speaking of the development of the brain, that the corpus callosum does not appear until after the hemispheres; and that comparative anatomy, by showing that the corpus callosum does not exist in the three lower classes of vertebrate animals, is opposed to the idea that the hemispheres are composed of certain fibres which decussate in the corpus callosum.

11. The doctrine of converging and diverging fibres, advanced by Gall and Reil,* cannot explain the continuity of the fibres of the corpus callosum with the radiating fibres of the corpora striata and optic thalami.

Tiedemann, from his researches into the anatomy of the fœtal brain, states that the corpus callosum is formed by the reunion of the fibres of the cerebral peduncles after they have expanded to form the hemispheres. He says that he has traced the fibres of the peduncles as far as the median line of the corpus callosum, where those of one side unite and are blended with those of the other; but a careful examination of the cerebrum, either by means of a stream of water, or by hardening it, shows that the fibres of the corpus callosum terminate in the convolutions, without presenting any sort of reflection, or forming any median raphé.

12. The dissections of M. Foville seem to establish the continuity of the corpus callosum both with the radiating fibres of the corpora striata and with the fibres of the hemispheres. According to his dissections, which consist essentially in transverse vertical sections, the radiating fibres of the optic thalami and corpora striata divide immediately into three very distinct superimposed planes.

The *first* or *superior plane* is reflected upward and then inward, so as to describe a curve with its convexity turned outward, passes horizontally inward to form the corpus callosum, and unites with the corresponding fibres of the opposite side.

The *second* or *middle plane*, the plane of the hemisphere, ascends parallel to the corpus callosum up to the point where the fibres of that body are reflected inward; it then continues in an almost vertical direction, and thus reaches the gray matter.

The *third* or *inferior plane*, much smaller than either of the preceding, is extremely thin, and follows a very different course: immediately after emerging from the common place of origin, it descends on the outer side of the corpus striatum, turns round its lower part, approaches the median line, and then mounts upward, in contact with the corresponding plane of the opposite side, through the middle of the ventricles, where the two juxtaposed planes form the septum lucidum.

13. Is the fornix an antero-posterior commissure? In support of this opinion, I may state, that I have seen the right half of the fornix atrophied in a case of destruction of the convolutions corresponding to the tentorium cerebelli.

14. The anterior commissure (*m, fig.* 283), which was regarded by Willis as the commissure of the corpora striata, and by Reil as intended to connect the anterior convolutions of the middle lobe and some convolutions situated at the bottom of the fissure of Sylvius, belongs to the system of converging fibres, according to Gall, who describes them as commencing in the gray matter of the convolutions. According to Tiedemann, this commissure is a continuation of the cerebral peduncles, each of which, after having traversed the corpora striata, expands in the corresponding hemispheres, and gives off several radiating fasciculi which incline forward and inward, are collected together into a cord, and unite with those of the opposite side; the anterior commissure, therefore, according to this view, is a bond of union between the radiating fibres of the cerebral peduncles and those of the right and left middle lobes of the brain. Chaussier had already derived the fibres of this commissure from the cerebral peduncles. All that is certainly known regarding it is, that the cord of which it consists passes through the anterior portion of each corpus striatum, and expands in the anterior and inferior convolutions of the sphenoidal horn of the posterior [middle] lobes, behind the fissure of Sylvius.

15. The cornu ammonis is formed by the reflection of the lower part of the hemisphere: the white laminæ which cover it, the corpus fimbriatum along its border, and the

* The following is Reil's statement on this subject: "Both of these two systems of fibres spread out into rays and meet each other; the cerebral peduncles ascend from below, and expand into the form of an inverted cone; the system of the corpus callosum, on the contrary, comes from above, and its fibres insinuate themselves between the preceding ones (see *g, fig.* 284), and form, as it were, the lid of the cup."

fornix, constitute but one system, which evidently belongs to the antero-posterior commissures.

16. Each convolution is composed of two precisely similar semi-convolutions; the two halves, which can be readily separated by a stream of water, may be decomposed into a considerable number of striated lamellæ, arranged like a fan, the margin of which would correspond to the free border of the convolution, and the narrow end to the adherent border; these striated lamellæ are separated from each other by vascular filaments; their number seems to vary in different subjects; they seem, moreover, to be altogether independent of each other. The stream of water detaches a corresponding layer of gray matter with each white lamella. This layer of gray matter is also striated, and appears to be composed of fibres implanted upon the white matter, as Mr. Herbert Mayo has very clearly pointed out.

17. It follows, therefore, that in the convolutions, a lamellar striated arrangement succeeds to the fibrous or linear arrangement of the medullary centres and radiating fibres of each hemisphere.*

These lamellæ are evidently continuous with the radiating fibres of the corpus striatum and optic thalamus. Still, there is in each convolution a proper lamella, the continuity of which with the radiating system of the hemispheres I have not been able to trace.

18. We should not regard the convolutions as so many sinuous eminences separated by the anfractuosities: on the contrary, the bottom of the anfractuosity forms the middle part or fold of a layer of white and gray matter, half of which layer belongs to one convolution and half to the next convolution (*n n*, *fig.* 284). Now it is these white lamellæ which line the gray matter that appear to be proper to each convolution; and between these proper lamellæ are situated the white striated plates that are continuous with the radiating fibres of the hemispheres,† which fibres are not arranged in lamellæ, but merely in lines.

It follows from all that has been stated, that there are yet several deficiencies in our knowledge of the anatomy of the brain, which prevent us from forming a complete idea of its structure.

Development of the Cerebrum.‡

In the early periods of fœtal life, about the end of the second month, the hemispheres are represented by a very thin membrane, which is turned backward and inward, so as to cover the corpora striata.

The optic thalami, which appear as enlargements of the cerebral peduncles, the tubercula quadrigemina, and the cerebellum, are completely exposed. The corpus callosum does not yet exist. The human brain may, then, be considered as resembling the brain of fishes.

Towards the end of the third month, the membrane of the hemispheres has acquired a farther development, and covers not only the corpora striata, but also the optic thalami. The tubercula quadrigemina and the cerebellum are still exposed. The anterior lobes only of the cerebrum are formed. The posterior lobes seem to be merely appendages. The hemispheres, then, constitute at this period a membranous sac, which is open on the inner side and behind, and may be regarded as representing the brain of reptiles. The

* M. Leuret has been led to the same conclusion regarding the lamellar structure of the convolutions, by studying the brain hardened by boiling it in a solution of salt.

† Mr. Herbert Mayo (a series of engravings intended to illustrate the structure of the brain and spinal cord in man, 1825), who has followed the example of Reil, in examining the brain with so much care after it has been hardened in alcohol, admits the existence of three sorts of fibres in each convolution, viz., fibres which pass from one convolution to the next (*u u*, *fig.* 283), and also to more distinct convolutions; fibres which come from the commissures (*s s p*); and fibres derived from the spinal cord. According to this anatomist, the fibres which pass from one convolution to another constitute the principal part of each convolution; the other white fibres which form the centre of each convolution are derived partly from the commissures and partly from the optic thalami and corpora striata.

According to him, the white fibres (*y' q*) which form the inferior layer of the cerebral peduncles radiate in the substance of the cerebrum, and constitute its anterior and middle fibres. The fibres proceeding from the optic thalami form the posterior cerebral fibres (*y*). There is, he affirms, one point in which *the radiating fibres evidently decussate* with the fibres from the great commissure of the brain or corpus callosum (as at *g*, *fig.* 284). The posterior radiating fibres do not present this decussation.

The two most remarkable fasciculi of communication between the convolutions are the following: that which occupies the bottom of the fissure of Sylvius (*l*, *fig.* 283; *m*, *fig.* 284), and which unites the convolutions of the anterior and posterior lobes; and that (*p p*, *fig.* 283; *l*, *fig.* 284) which runs above the corpus callosum, crossing at right angles the direction of its fibres, and connects the anterior and superior with the posterior and inferior convolutions.

Rolando has not been so successful in his researches into the structure of the cerebrum as in his investigations into that of the cerebellum: the following are the results which he obtained by tearing the brain, and by examining this organ in the fœtus. According to him, the brain is composed of fibres arranged in layers in the following order, proceeding from without inward: 1. A white layer reaching into the fissure of Sylvius, and covered by gray matter; 2. A layer from which the fibres of the external convolutions arise; 3. A layer which is formed by the fibres of the peduncles, and supplies the convolutions of the inner border of the hemisphere; 4. A plane which extends from the optic thalami to the parietes of the lateral ventricles, to form the corpus callosum; 5. A system of longitudinal fibres which form the convolutions situated upon the inner surface of the hemispheres; 6. A system of medullary fibres which constitute the fornix and cornu ammonis; 7. Internal and external corpora striata, to which must be added the anterior commissures, the perforated layer, and the fasciculus of the external corpus geniculatum.

‡ *Vide* Tiedemann (translated by M. Jourdan).

corpus callosum begins to appear under the form of a narrow commissure, which unites the two hemispheres in front, they being completely separated behind.

In the fourth and fifth months, the cerebrum covers the anterior part of the tubercula quadrigemina. The posterior lobe exists, the fissure of Sylvius, which is well-marked, separating it from the anterior lobe. We observe here and there some small depressions, the traces of anfractuosities. The olfactory nerves, which are very large, and are said to have been found hollow, as in the lower animals, appear to arise from the Sylvian fissure. The corpus callosum is still very small, so that the optic thalami and the third ventricle are exposed. At this period the human brain has some analogy with that of the rodentia.

In the sixth month, the cerebrum covers the tubercula quadrigemina and the greater part of the cerebellum. The only traces of convolutions are found upon the internal surface of the hemispheres. The corpus callosum is prolonged backward with the hemispheres, and from being vertical, now becomes horizontal.

At the seventh month, the corpora albicantia, which had hitherto formed a single mass, as in the lower animals, become separated. The convolutions are defined, and the cerebrum projects behind the cerebellum.

The changes occurring in the eighth and ninth months appear to be the development of the convolutions and the perfection of the other parts of the brain. At this period the characters of the human brain are well-defined. It may not be impossible, perhaps, to recognise, in the rapid phases of this development, the characters of the brain in the different orders of mammalia, but it is necessary to observe greater caution in admitting these analogies than has been evinced by various naturalists.

As the corpus callosum continues to be developed backward, it ends by reaching the anterior tubercula quadrigemina.

The corpora striata do not exhibit their white, radiating fibres until near birth, or soon after it. The originating fasciculi of the fornix are not seen in the interior of the optic thalami until the latter months of intra-uterine life; and until then, also, the transverse commissures and the white fibres of the optic commissure do not appear.*

The lateral ventricles are formed by the turning backward and inward of the membrane which constitutes the hemispheres. And as this membrane is very thin until the end of the third month, it follows that at this period the lateral ventricles are proportionally much larger than they are afterward. The anterior cornua of these ventricles are developed before the descending cornua, and these before the posterior cornua. During all this period, the anterior cornua communicate with the cavities in the olfactory nerves. At the sixth month, the lateral ventricles are completely closed. The choroid plexuses, which exist in all animals provided with lateral ventricles, begin to appear as soon as these cavities.

The distinction between the gray and white matter does not become evident until after birth. Tiedemann is of opinion that the formation of the gray matter takes place after that of the white. This appears to me a pure hypothesis. The two substances are formed at the same time; but, properly speaking, they are neither white nor gray, and they do not acquire their distinctive characters until some little time afterward.

Comparative Anatomy of the Cerebrum.

The Optic Thalami and Corpora Striata.

In analyzing the brains of the lower animals, it is of the utmost importance clearly to distinguish the hemispheres, properly so called, from the optic thalami and corpora striata.

The *optic thalami* are recognised by their having a ventricle (the third) between them, by being connected by an anterior and a posterior commissure, and, moreover, by being continuous with the cerebral peduncles.

The size of the optic thalami is always proportioned to that of the hemispheres. In fishes, the cerebrum appears to be almost entirely formed by the optic thalami.

There are no traces of corpora striata in fishes. Their existence in reptiles cannot be doubted. They are of enormous size in birds, in which they constitute almost the entire hemispheres. If it be true that, in the animal series, the size of the hemispheres is always directly proportioned to that of the optic thalami, such is not the case with the corpora striata, which, as I have already stated, are a kind of internal convolutions, and are often inversely proportioned, in size, to the hemispheres, properly so called.

Thus, the corpora striata are very large in proportion to the hemispheres in the rodentia: in this respect, as in many others, the brain of this order of mammalia approaches very near to that of birds. In the higher orders of mammalia, as the carnivora and quadrumana, the proportion between the corpora striata and the hemispheres is nearly the same as in the human subject.

* [Tiedemann describes fibres as distinctly appearing in the corpus striatum in the sixth month, though not so abundantly as afterward. He recognised the anterior and posterior commissures before the end of the third month; at the same time, also, the anterior pillars of the fornix rising from the united mass of the corpora albicantia; the fasciculi from the thalami to the corpora albicantia were quite distinct in the fifth month, and could be recognised even somewhat earlier.]

The Cerebral Hemispheres and Olfactory Lobes.

In Mammalia.—Man surpasses all the mammalia in regard to the size of the *cerebral hemispheres* and the number of their convolutions.

The quadrumana stand next to man. The dolphin, perhaps, exceeds the ape in both respects, and this would tend to support the relations of travellers respecting the wonderful intelligence of this cetaceous animal.

In the carnivora and ruminantia the hemispheres are smaller, the occipital lobe of the cerebrum does not exist, and the anterior part only of the cerebellum is covered. There is no fissure of Sylvius, and no lobe of the corpus striatum. In all these animals, the number of the convolutions and the depth of the anfractuosities have appeared to me to be as great as they are in man, in proportion to the size of the hemispheres. I have not observed that regularity of the convolutions which several anatomists have pointed out as contrasting with their irregularity in man.

The lowest order of mammalia, namely, the rodentia, have the least complicated brain. It is shaped like the heart on playing cards, almost resembling the brain of birds. The cerebellum is completely exposed, and the tubercula quadrigemina are but partially covered by the cerebrum. There are scarcely any traces of convolutions, and the hemispheres are reduced to a membrane folded upon itself.

The corpus callosum is extremely small, but the cornu ammonis is very large. These two parts seem to be developed inversely to each other. Thus, the corpus callosum is larger and the cornu ammonis is smaller in man than in the lower animals.

In the rodentia, the gray matter of the convolutions is reflected beneath the fornix.*

In all mammalia, excepting the dolphin, the olfactory nerves, which are so delicate in man, form two thick pedicles lying under the anterior lobes of the cerebrum, and terminating in front by large ovoid bulbs, corresponding in size to that of the ethmoidal fossæ; these enlargements are named *olfactory lobes*. They are continuous with the innermost convolutions of the sphenoidal horn of the posterior lobe, which presents, above and below, certain white fibres or striæ, that are continuous with the cerebral peduncles.

The olfactory lobes have no relation with the corpora striata, as Cuvier was the first to observe. In the dolphin, as in man, the corpora striata are very much developed.

The development of the olfactory lobe is inversely proportioned to that of the cornu ammonis.

In Birds.—The *cerebral hemispheres* in birds are shaped like a heart on playing cards, as in the rodentia; there are no lobes and no convolutions, excepting a very superficial longitudinal furrow, situated on each side of the median line. The brain almost entirely consists of the corpora striata. The hemisphere is formed by a very thin gray lamina, upon which are observed certain white radiated fibres. This lamina commences at the inner part of the corpus striatum, turns outward round that body, and is continued to the upper part. The interval between this lamina and the corpus striatum forms the lateral ventricle. There is no trace of the corpus callosum, but there is evidently an anterior commissure, which expands in the corpora striata.

In all birds of prey, two medullary bands arise in front of the commissure of the optic nerves, and, having reached the front of the hemispheres, are expanded to form the *olfactory lobes*. In the other tribes, as in the gallinaceæ, there are no olfactory lobes, but certain small cords, which are merely the tapered extremities of the hemispheres.

In Reptiles.—The hemispheres are larger in the *chelonians* (tortoise) than in birds, though they are very similar in many respects: as in birds, there are no olfactory lobes, but merely two bands. In the saurians (crocodile, lizard) the olfactory lobe is continued into the tapering point of the cerebral lobe by a very long pedicle. The *batrachians* and *ophidians* have olfactory lobes in front of the hemispheres, from which they are separated by a circular constriction.

In Fishes.—Like reptiles, fishes have sometimes a single pair, sometimes two pairs of lobes in front of the optic lobes. When there is only one pair, it must not be concluded that they represent the cerebral hemispheres; if that pair is continuous with the olfactory nerves, they constitute the olfactory lobes. Whenever there is a pair of lobes between the olfactory and the optic lobes, such pair belongs to the hemispheres.

The olfactory lobes and the cerebral hemispheres are so independent of each other, that they are often inversely proportioned in regard to size, so that the cerebral hemispheres are larger in man than in any of the lower animals, while the olfactory lobes are smaller. On the other hand, the olfactory lobes are the most highly developed in the ray; they are united together, are hollowed in the centre, grooved on the surface, according to the observation of Vicq d'Azyr, and present some traces of convolutions. Now, in the ray, there are no cerebral hemispheres, at least, unless we agree with Tiedemann in regarding the olfactory lobes as anologous to the corpora striata. In some fishes the olfactory lobe is supported by a pedicle of variable length. As to the cerebral hemisphere, it is a mere tubercle, which appears to represent the optic thalamus.

* [Mr. Owen has discovered that the brain of marsupial animals resembles that of birds, in wanting the corpus callosum (see his Memoir in *Phil. Trans.*, 1837).]

The corpus callosum, the fornix, and the septum lucidum do not exist either in birds, reptiles, or fishes.

The corpora albicantia, which are wanting in birds and reptiles, are of enormous size in fishes, and constitute a true lobe, according to Vicq d'Azyr and Arsaky.

The encephalon of fishes presents five pairs of lobes, which are, proceeding from behind forward, 1. The lobes of the pneumogastric nerve, or lobe of the medulla oblongata; 2. The cerebellum; 3. The optic lobes; 4. The cerebral hemispheres; 5. The olfactory lobes.

If we now generalize, with M. de Blainville, the notions we have formed respecting the encephalon of vertebrate animals, we may regard the different pairs of lobes of the encephalon as so many pairs of ganglia situated upon the prolongation of the spinal cord; these he names *ganglions sans appareil extérieur*. The first or the most anterior pair consists of the olfactory lobes, which are rudimentary in man. The second is the cerebrum, properly so called. The third is formed by the tubercula quadrigemina or optic lobes, which are rudimentary in man. The fourth is the cerebellum. The ganglia which constitute each pair communicate with each other; each ganglion communicates with that which precedes and that which follows it · and, lastly, they all communicate with the spinal cord.*

THE NERVES, OR THE PERIPHERAL PORTION OF THE NERVOUS SYSTEM.

General Remarks.—History and Classification.—Origin, or Central Extremity.—Different Kinds.—Course, Plexuses, and Anastomoses.—Direction, Relations, and Mode of Division.—Termination.—Nervous Ganglia, and the Great Sympathetic System.—Connexions of the Ganglia with each other, and with the Spinal Nerves.—Structure of Nerves.—Structure of Ganglia.—Preparation of Nerves.

General Remarks.

The *nerves*, which are concerned in the transmission of sensations and of motor influence, are white cords, attached to the cerebro-spinal axis by one extremity (the central extremity), and distributed to the different organs by the other, or peripheral extremity. They have a pearly-white aspect, like the tendons, with which they were for some time confounded. Their surface is smooth, and presents a number of folds or zigzag marks, which are effaced by extension.† Lastly, if a nerve be cut across, it is seen to be composed of a certain number of cords, the divided ends of which project beyond the cut surface. By these characters it will always be easy to distinguish a nerve from any other white tissue in the body.

All the nerves are arranged in pairs: they differ from each other in their point of junction with the central portion of the nervous system; in their consistence; in the place at which they emerge from the cranio-vertebral cavity; in their distribution; and in their functions. These points of difference have served as the foundations of the different classifications of the nerves proposed at various periods.

History and Classification of the Nerves.

The nerves, which had been at first confounded with the tendons and ligaments under the name of white tissues, were distinguished from those parts by Herophilus and Galen. The subdivision of the nerves into the *cerebral* or *cranial* nerves, which pass out of the foramina in the base of the scull, and the *spinal* or *rachidian* nerves, which emerge from the inter-vertebral foramina, was so natural, that it suggested itself to the earliest anatomists who directed their attention to this system. The cranial nerves alone have presented some difficulties in their study and their classification. Marinus, whose work has been long regarded as classical, admitted only seven pairs of cranial nerves, among which neither the olfactory nor the pathetic were included. Achillini was the first who described the latter as a special nerve; and it was Massa who classed the olfactory rib-and among the nerves. Willis divided the cranial nerves (and his division is still adopted) into ten pairs, including the sub-occipital nerve. He also, like his predecessors, admitted thirty pairs of spinal nerves, and regarded the great sympathetic as forming the forty-first pair. According to Willis, the olfactory nerves form the first cranial pair; the optic nerves, the second; the common motor nerves of the eyes, the third; the pathetic nerves, the fourth; the trigeminal nerves, the fifth; the external motor nerves, the sixth; the facial and auditory nerves together, the seventh; the pneumogastric, glosso-pharyngeal, and spinal accessory, the eighth; the hypoglossal nerves, the ninth; and the sub-occipital nerves, the tenth. This last pair, which was with so much reason

* [There is still considerable uncertainty as to the parts of the encephalon which correspond in the higher and lower vertebrata. For farther information on this point, as well as on the comparative anatomy of the brain generally, see Leuret, *Anatomie Comparée du Système Nerveux*, Paris, 1839.]

† [These zigzag folds led some anatomists to believe that the nerves have a sinuous arrangement. Monro has even commemorated this anatomical error by a figure. The sinuous appearance common to the nerves and tendons disappears in both by stretching.]

classed by Haller among the spinal nerves, has been alternately and arbitrarily removed from one to the other class of nerves. Sœmmering divided the seventh pair of Willis into two distinct pairs: the seventh, or the facial nerves; and the eighth, or the auditory nerves: he subdivided the eighth pair of Willis into three pairs, namely, the ninth, or the glosso-pharyngeal; the tenth, or the pneumogastric; and the eleventh, or the spinal accessory nerves of Willis. But Sœmmering's modification, as well as Malacarne's, who admitted fifteen pairs of cranial nerves, and also Paletta's, who described as a particular nerve that branch of the fifth pair which is distributed to the temporal and buccinator muscles, appear to me to be faulty, because they cause a confusion of ideas without leading to any advantage. We shall, therefore, adhere to the classification of Willis, which is most generally adopted. Nevertheless, with Vicq d'Azyr, we shall prefer a nomenclature founded upon the distribution of the nerves to one which is purely numerical.

Willis conceived the grand idea of separating the nerves of voluntary from those of involuntary motion. Bichat seized upon this idea, which had already been rendered fruitful by Winslow and Reil; he unfolded it even to the minutest details, and appropriated to himself, in some measure, the distinction of the nerves into those of organic and those of animal life. The cerebro-spinal nerves constitute the nervous system of animal life; the great sympathetic nerve forms by itself the nervous system of organic life. This last-named nerve consists of a series of ganglia, or small nervous centres, distinct from each other and from the brain. Bichat, moreover, anticipating all the importance of the origin of the nerves, endeavoured to class them, not according to the points at which they emerged from the cranium, but according to their origin, viz., into the nerves of the cerebrum, which are ten in number; the nerves of the pons Varolii, six in number; and the nerves of the spinal marrow, thirty-four in number; the only disadvantage of this classification consists in its having been premature.

Other less important, and, in general, rather physiological than anatomical subdivisions of the nerves, have been established. Thus, in reference to their consistence, the nerves have been divided into the *hard*, which are motor nerves, and the *soft*, which are sensory; the former are said to come from the spinal cord, the latter from the brain. The old distinction of the nerves into *nerves of sensation* and *nerves of motion* has been lately revived; and we shall have occasion to recur to it, as well as to Sir Charles Bell's classification of the nerves into the *symmetrical* or *primitive*, and the *superadded* or *respiratory* system.

The nerves might also be classified according to their size, but this mode of distinction would be completely useless. Every nerve presents for our consideration a central extremity, a course, and a peripheral extremity.

The Central Extremity of the Nerves.

The central extremity of the nerves is that part by which they communicate or are connected with the cerebro-spinal axis. It is generally called the *origin* of the nerves. The use of such metaphorical expressions as origin, production, and efflorescence, has not been without disadvantage to science; for by the majority of anatomists they are employed not in a figurative, but in a literal sense.*

The examination of the central extremity of the nerves is, perhaps, the most important part of their study, because the properties of the nerves depend in a great measure upon their point of connexion with the central part of the nervous system. This point is, in reference to each nerve, constant and invariable, not only in man, but throughout the animal kingdom, so that its exact determination enables us to establish what are the analogous parts of the encephalon in different species.

Each nerve has an *apparent* and a *real* central extremity or origin. The apparent origin is the exact point at which the nerve is given off from the surface of the cerebro-spinal axis; but, as several nerves can be traced into the substance of the cerebro-spinal axis to a variable depth, it is probable that all of them have a much deeper *real origin*. The older anatomists proceeded on this supposition, when they described all the nerves as originating from the cerebrum, and more particularly from the corpus callosum, or, rather, from the optic thalami and corpora striata. We are still ignorant of any central point, or *sensorium commune*, forming the point of termination or of origin to all the nerves of the body,

In respect of their origin, we might regard all the nerves as proceeding from the spinal cord: the nerves of the face, and those of the organs of respiration and deglutition, arise from the medulla oblongata and its cranial prolongations; the nerves of the upper extremity proceed from the cervico-dorsal enlargement of the cord; and the nerves of the lower extremity from the lumbar enlargement: the nerves of the trunk arise from the spinal cord, between its three enlargements. The optic and olfactory nerves alone appear to form exceptions to this rule.

All the spinal nerves present the greatest uniformity in reference to their origin,

* Comparative anatomy, and the anatomy of the fœtus, prove the independent formation of the different parts of the nervous system.

course, and termination. The arrangement of the cranial nerves, which appears at first sight to be uninfluenced by the laws which regulate the distribution of the spinal nerves, may yet be referred to those laws to a certain extent, notwithstanding its apparent irregularity and complexity.

The general remarks which follow apply more particularly to the spinal nerves.

The spinal nerves arise by two sets of roots, the *anterior* (*a*, *fig.* 267) and the *posterior* (*b*).

Gall advanced the notion that the posterior roots of the spinal nerves preside over extension, and the anterior roots over flexion of the trunk and limbs, and he explained the predominance of extension over flexion by the greater size of the former roots.* Although the fact of this predominance appears to me indisputable, Gall's explanation is nevertheless rendered void, for it supposes a separation of the fibres of the anterior and posterior roots in reference to their distribution, and no such a separation exists.

Sir Charles Bell, having proved by experiments that the facial nerve and the fifth cerebral nerve had different properties, the former being devoted to motion and the latter to sensation, was led to examine whether there did not exist something analogous in the other parts of the body; and the double roots of the spinal nerves must have naturally suggested themselves to his mind. Might not the object of this double origin be to concentrate a double property in each pair of nerves? Experiments were instituted, and they confirmed the preconceived ideas of this ingenious physiologist. They were soon followed by the perfectly confirmatory experiments made by Magendie, who, by also adducing facts in pathological anatomy, threw so much light upon this subject, that most modern physiologists have admitted that the *posterior roots belong to sensation*, and the *anterior to motion*.

Now, notwithstanding the imposing authorities which I have quoted, I must say that I am by no means convinced of the reality of this distinction, and that, in repeating both Bell's and Magendie's experiments, the section of the anterior and that of the posterior roots appeared to me to produce precisely the same effects.†

I have also endeavoured to determine the question anatomically.

Some anatomists have thought that, after emerging from the ganglion, the filaments from the two roots become so intimately mingled that the smallest nervous cord would contain filaments from both the anterior and the posterior roots; as far as I have been able to ascertain, the filaments are interlaced, but never enter into a regular combination. Again, in order to render the dissection more easy and conclusive, having macerated a portion of a body in water containing nitric acid, and having thus destroyed the neurilemma or fibrous covering of the nerves, I endeavoured to trace some nervous filaments, both cutaneous and muscular, to their origin; but I never could succeed in this, so numerous are the combinations into which the filaments enter. However, having directed my attention more particularly to certain filaments given off from the cervical nerves to be distributed to the scaleni muscles, I succeeded in tracing them into the corresponding spinal gangli. Now the filaments which proceed directly from the spinal ganglia are, according to the theory just alluded to, exclusively connected with sensation, and, consequently, should not be distributed to the muscles.

The question of the anterior and posterior roots is connected with another more general question, viz., Are there different kinds of nerves?

Different Kinds of Nerves.

The natural distinction of the nerves into those of sensation and of motion dates as far back as Erasistratus, who described the sensory nerves as arising from the meninges, and the motor from the cerebrum and cerebellum. This opinion was often revived and always abandoned, and it was only when direct experiment appeared to confirm the anticipations of theory that it became generally adopted.

Bichat, after the example of Winslow and Reil, divided the nervous system into two great sections, one of which belongs to animal and the other to organic life. The spinal cord and encephalon form the common centre of the *nervous system of animal life*; the organs of the senses and the muscles are under its influence. All the organs supplied by it are subject to volition and consciousness. The *nervous system of organic life* is formed by the ganglia of the great sympathetic, which Bichat agrees with Winslow in regarding as so many little brains. The organs of digestion, respiration, circulation, and secretion are under its influence. All of the organs which it supplies are withdrawn from the control of the will and of consciousness.

The subdivision adopted by Reil and Bichat prevailed in the science until Sir Charles Bell was led back to the opinion of the ancients by some highly interesting observations and experiments; he associated with that opinion the ideas of Bichat, and also estab-

* In this matter Gall has caught sight of a truth which I believe I have established upon incontestable evidence, in describing the apparatus of locomotion; namely, that in all parts of the body, excepting in the muscles of the fingers, the extensors are more powerful than the flexors.

† [The accuracy of the experiments has now been amply confirmed; and there is no doubt that the anterior are the motor, and the posterior the sensory roots: no difference of structure has been detected between them.]

lished an entirely new class of nerves, which he named *nerves of expression* or *respiratory nerves*. According to this view, there are five kinds of nerves: *nerves intended for special sensations*, as the nerves of smell, of vision, and of hearing; *nerves of common sensation; nerves of voluntary motion; nerves of the respiratory movements;* and *sympathetic nerves*, which appear to unite the body into a whole in relation to its nutrition, its growth, and its decay. By a still wider generalization, Sir Charles Bell admits two systems of nerves, viz., the *the primitive* or *symmetrical nerves*, which exist in all animals, and by the aid of which they feel and move; and, secondly, the *superadded, irregular*, or *respiratory nerves*, the number of which is proportioned to the perfection of the general organization. It is the latter system of nerves that regulates the partly voluntary and partly involuntary act of respiration, and also the several movements connected with it, such as those of speaking, laughing, sighing, and sneezing. According to Bell, these nerves arise from a special tract in the cord, and sometimes proceed separately or distinct from he other nerves, and are sometimes blended with them, this occurring in such a manner that neither their union nor their separation in any way impedes their functions.

This theory of superadded or respiratory nerves is very ingenious, but altogether hypothetical. Besides, it is only strictly applicable to the case of four nerves, viz., the pneumogastric, the glosso-pharyngeal, the spinal-accessory, and the facial. Sir C. Bell's opinion concerning the existence of a column situated between the anterior and posterior roots of the nerves, along the whole extent of the spinal cord, and giving origin to certain filaments which combine with those coming from the two roots so as to cause them to participate in the great phenomenon of respiration, is quite gratuitous.

On endeavouring to decide whether there are several kinds of nerves, by anatomical investigation, it is found that, excepting the olfactory, optic, and acoustic nerves, which have altogether a peculiar arrangement, and the ganglionic nerves, which are generally grayer and more slender, there is no difference in the character and structure of the nerves of different parts of the body. The cutaneous nervous filaments are exactly similar to the muscular nervous filaments.

From the law of organization, that identity of structure is always connected with identity of function, I have been led to admit that the nerves are *homogeneous;* that the different properties attributed to them belong to the organs to which they are distributed; and that they perform no other office in the economy than that of *conductors—conductors of sensation* when they are distributed to a *sensory* organ, and *conductors of motor influence* when they enter a *motor* organ.* This view of the homogeneous structure of the nerves explains much more readily than the opposite one all the phenomena of innervation, and, in particular, the unity of all parts of the nervous system.

Moreover, if we admit the existence of special nerves to preside over some special phenomena, and to be distributed to particular organs, why not admit them for all special actions and for all organs? There would then have to be digestive nerves, generative nerves, and secreting nerves of different kinds.

Course, Plexuses, and Anastomoses of the Nerves.

The course of the nerves must be examined both while they are within and while they are outside the cranio-vertebral cavity. Within this cavity the extent of their course is variable; and their distribution, after they have emerged from it, is more or less complicated. All, or nearly all, the cerebro-spinal nerves communicate with the great sympathetic system. When the parts to which they are destined are not complicated, their distribution is very simple, as, for example, the nerves of the thoracic and abdominal parietes; but when those parts are complicated, the arrangement of the nerves is proportionally intricate; and they then unite so as to form certain interlacements called *plexuses*, as, for example, the thoracic and abdominal plexuses.

The nervous *plexuses*, which Bichat regarded as so many centres in which the branches of origin of the nerves ended, and from which their terminal branches commenced, are formed by the division and subdivision of a certain number of nerves, which enter into new combinations, and form an almost inextricable interlacement.

Within these plexuses there is generally so intimate a combination of the different elements of which they are composed, that it is almost impossible to determine exactly what branches of origin are concerned in the formation of any particular terminal branch. A branch of a nerve issuing from a plexus belongs, therefore, to all the nerves which enter into the composition of that plexus.

The plexuses do not consist of actual anastomoses of the nervous cords; nor do they, as Monro believed, contain any gray matter: they do not afford origin to any new nervous filaments, but they merely give off those which they have received. The most careful examination reveals nothing more than an interchange of nervous cords, which, although they enter into new combinations, still remain independent of each other.

* The homogeneous structure of the different nerves is proved by the anatomical fact, that the same nerve is distributed to a great number of organs having very different functions, as, for example, the eighth pair; and also by a fact in comparative anatomy, namely, that the same pair of nerves may, in different species, preside over totally different functions; for example, the fifth pair.

The term *nervous anastomoses* is applied to the communications by loops, or at more or less acute angles, which take place between the nervous filaments. The older anatomists, governed by the idea that there existed a fluid circulating in the nerves, supposed that in the anastomoses of nerves there was a mixture of nervous fluids, nearly similar to that which takes place in vascular anastomoses, where two different columns of blood are intermixed. They regarded the nervous anastomoses as the most active source of sympathies. Bichat also admits the existence of these anastomoses, in which, he says, there is not only a contiguity, but also a continuity of nervous filaments. Béclard* defends the use of the term anastomosis, and endeavours to define its meaning thus: "There is not merely an application of nervous filaments in the anastomoses, but a true communication, a junction (*abouchement*) of their canals, which, in truth, contain a fixed substance, not a circulating fluid, as was formerly believed."

But, on examining the structure of the nervous anastomoses, it is seen that there is simply a juxtaposition of filaments derived from two different sources. The examination also proves most distinctly that the anastomoses are merely small plexuses, so that the only difference between them is, that *in the plexuses there is an interchange of nervous cords, while in the anastomoses there is an interchange of nervous filaments or of primitive fibres.* The anastomoses, like the plexuses, are intended to concentrate the action of several nerves upon any given point, as on a centre, from which their action may extend to certain parts necessarily connected in function.

The nervous loops described by Bichat upon all points of the median line of the body, and by the existence of which he supposed that he could explain the return of sensation and voluntary motion to paralytic parts of the body, do not exist. The only anastomoses in the middle line with which I am acquainted are those of the two pneumogastric nerves behind the lower extremity of the trachea, that of the two solar plexuses, and that of the cardiac nerves.

The Direction, Relations, and Mode of Division of the Nerves.

The nerves are very deeply situated at their egress from the cranio-vertebral cavity. Thus, the brachial plexus is protected by the osseous girdle of the shoulders, and the sacral plexus by the pelvic bones. The nerves then pass into the great cellular intervals, which we have already described as existing in the limbs for the reception of the principal vessels and nerves, and for the preservation of those parts from pressure.

The direction of the nerves is generally *straight*, and their length corresponds exactly with the distance from their point of origin to that of their termination, so that, if the movements of the limbs exceed their ordinary extent, the nerves may suffer severe injury by being stretched. This *straight direction* is, in general, an essential character of a nerve. Nevertheless, a considerable number of nerves deviate from their primitive direction,† so as to describe a portion of a circle, or are seen reflected upon themselves in a direction precisely opposite to their original one. Others describe a zigzag course, like the arteries; but these flexuosities are effaced in certain positions of the body, or during the distension of particular organs.

Although there is but one arterial trunk for each limb, there are always several nerves, the number of these being variable. As the arteries often deviate from their original direction, they describe certain turns, so as to occupy alternately the opposite sides of a limb. Now, as the nerves pass in a straight direction, and the arteries describe certain curves, it follows that the same nerves cannot accompany the same arteries during the whole of their course. Thus, when an artery deviates from its primitive direction, it has two satellite nerves, one during the first, and the other during the second part of its course. For instance, the crural nerve accompanies the femoral artery, and the sciatic nerve the popliteal artery. When an artery bifurcates or otherwise divides, there is often a particular nerve for each subdivision: thus, the median nerve is the satellite of the brachial artery, the radial nerve accompanies the radial artery, and the ulnar nerve the ulnar artery.

It follows, also, from what has been said, that the nerves have no accompanying vessel for a more or less considerable portion of their course; such is the case with the great sciatic and the pneumogastric nerves.

The relations of the arteries with the nerves are constant, so that modern surgeons attach great importance to these relations; in fact, as a nerve, on account of its whiteness, is more easily recognised than an artery, as soon as the former is exposed the latter is immediately met with. It is important, moreover, to determine with the greatest accuracy what nerves are contained within, and what nerves are situated without, the sheath of their corresponding artery. Besides its principal nervous trunk, an artery is also accompanied by certain nervous filaments, which are closely applied to the vessels, which are very difficult to separate from it, and which often escape observation

* Anat. Générale, p. 659.

† I do not think that a straight direction is necessary for the transmission of the nervous influence, for this takes place in a flexed limb along a curved nerve, as well as in an extended limb along a straight nerve; but it is probable that it shortens the duration of this transmission.

from their tenuity. These are the filaments which render ligature of the arteries so painful.

Division of the Nerves.—During their course, the nerves do not divide, like the vessels, by ramifying into smaller and smaller branches; but they give off in succession, as they proceed, branches to the different parts through which they are passing, and thus become gradually exhausted, until, reduced to mere filaments themselves, they terminate in the same manner as their branches. *The subdivision of nerves, therefore, does not consist in a ramification, but in a process of separation or emission.* There is one circumstance which has attracted the attention of all anatomists, viz., that the nerves do not diminish in size in proportion to the number of filaments given off from them: some of them even appear to increase in size after having given off several filaments. This apparent singularity is explained, not by the fact that new filaments are added, but by the flattening of the nerve, the separation of its filaments, the addition of a certain quantity of adipose tissue, or the thickening of the neurilemma.

Termination of Nerves.

The distribution of the nerves is perfectly determinate: each nerve, indeed, has its own distinctly limited department; an arrangement which, connected with what has already been said regarding the anastomoses, explains why the nerves cannot supply the place of each other. When the principal arterial trunk of a limb is tied, the circulation is re-established by the collateral vessels; but when a nerve is cut across, all the parts to which it is distributed are paralyzed.

The termination of the nerves is, undoubtedly, one of the most important points in their anatomy. In the skin, the nerves terminate in the papillæ, not one of which is destitute of them; in the muscles, they terminate in extremely delicate filaments, which pursue a very long course in the substance of these organs, before they become invisible to the naked eye or to the eye aided by a lens: it has appeared to me that each nervous filament was so arranged as to be in contact with a very great number of muscular fibres, situated either in the same or in different planes.

It is probable that there is not a single muscular fibre which is not thus lightly touched by a nervous filament; this anatomical fact may suggest, instead of Reil's ingenious hypothesis of an atmosphere of activity around each nervous filament, the important *conclusion that the nerves act upon the muscular fibre by the effect of contact.**

MM. Prévost and Dumas believe that the nervous filaments terminate by loops in the substance of muscles; and upon their incomplete observations they have founded a theory of muscular contraction. Nervous loops may certainly be observed in the substance of the recti muscles, which they selected as examples; but these loops are not the termination of the nerves, for a number of filaments are seen to issue from them, and to be distributed in the manner just pointed out.†

The different organs vary much in regard to the number of nerves which they receive; the organs of the senses—the eyes, the ears, the nasal fossæ, the tongue, and the skin—stand first in this respect. Next to these rank the muscles, which receive nerves in proportion to the number of their fibres and to their activity. The organs of nutritive life are far removed from the preceding in regard to the quantity of nerves distributed to them. No proper nerves have yet been discovered in cellular tissue, serous membranes, tendons, aponeuroses, and articular cartilages. All the articulations are provided with nerves, called *articular*, which may be traced into the ligaments, and even upon the synovial membranes.

The long bones, in addition to their central or medullary nerve, have certain periosteal nerves which are lost in the periosteum, and also proper nerves of the spongy tissue, which enter the foramina at the extremities of these bones.

The Nervous Ganglia and the Great Sympathetic System.

The *nervous ganglia* are certain grayish knots or swellings situated along the course of the nerves, and having a rather close resemblance to the lymphatic glands or ganglia. Considered generally, the ganglia are a kind of nervous centres, towards which a certain number of filaments converge, and from which they again pass out under new combinations. Hence arose the ingenious idea of Winslow, who compared the ganglia to little

* This hypothesis of a nervous atmosphere was suggested to Reil by the theory of a *nervous fluid*, which he regarded as analogous to and almost identical with the electric fluid; and also by the fact that the nervous apparatus is not able to supply filaments to all the muscular fibres.

† [The loops described by Prévost and Dumas seem to have consisted of small nervous cords; but Valentin, Emmert, and Burdach have observed that the ultimate filaments (primitive fibres of Müller) have a loop-like termination in the muscles. In reference to the nerves of sensation, it has been observed by Valentin and Burdach, that in the frog's skin the primitive fibres end in loops; this mode of termination has also been seen by Schwann in the tail of the larva of the toad, and in the frog's mesentery. Schwann farther states, that in both these cases the nervous fibres gave off exceedingly small fibrils, on which minute swellings (ganglia) were placed, and which in some situations formed a network. In the papillæ of the human skin, Breschet thought he saw the nerves ending in loops; and Gherber believes that he has seen these terminal loops in the skin of quadrupeds. Observers differ in their account of the mode of termination of the optic and auditory nerves (see ORGANS OF SIGHT AND HEARING).]

brains; an idea which was revived under a modified form by Bichat, who made it the basis of his admirable chapter upon the nervous system of organic life.

The nervous system of invertebrate animals is reduced to a series of ganglia and ganglionic nerves; Swammerdam, Haller, and the older anatomists regarded this series of ganglia as a spinal cord enlarged at intervals. But there is no point of comparison between these two parts; in a word, the enlargements of the spinal cord and brain cannot be likened in any respect to the ganglionic enlargements.

There are three series, or, as some say, three kinds of ganglia: viz., the *spinal* or *rachidian ganglia*; the *intercostal ganglia*; and the *splanchnic ganglia*; these last are situated near the viscera for which they are intended.

The first series, or the spinal ganglia, belong to the organs of relation. They are constant, regular, and symmetrical, like the nerves upon which they are placed. The other two series are destined for the apparatus of nutritive life, and constitute the *great sympathetic* system, improperly called the *ganglionic system.*

The identity in nature between the spinal ganglia and the ganglia of the great sympathetic, and also between the cerebro-spinal and the ganglionic system of nerves, is demonstrated by the fact that in a great number of animals the ganglia are blended, or, as it were, fused together. M. Weber (*Anat. Comparée du Nerf Sympathique*, 1817) has observed, that in animals the development of the great sympathetic is always inversely proportioned to that of the spinal cord. He has established a similar relation between the great sympathetic and the pneumogastric nerve; and, indeed, in certain species the latter nerve entirely replaces the former.

The experiments of M. Legallois upon the spinal cord led him to admit that the visceral nerves are under the influence of the spinal cord, and that the roots of the great sympathetic are in the cord.

There are as many spinal ganglia on each side as there are spinal nerves. The ganglia of the great sympathetic in the sacral, lumbar, and dorsal regions, are as numerous as the spinal ganglia; in the cervical region, there are only two or three sympathetic ganglia to correspond to the eight spinal ganglia. The superior cervical ganglion may be supposed to represent several ganglia.

In the cranium it is difficult to find any ganglia corresponding to the spinal; still, the Gasserian ganglion, and the ganglion of the eighth pair, may be regarded as analogous to them.

On the other hand, we may regard the ophthalmic ganglion, the spheno-palatine or Meckel's ganglion, the otic ganglion, and even the upper part of the superior cervical ganglion, as forming the cranial ganglia of the sympathetic system.

Nevertheless, it would, perhaps, be more rational to regard the ophthalmic and otic ganglia as quite independent of the three above-mentioned series of ganglia, and as connected with certain local functions. There are a considerable number of these local ganglia, which have received no particular names, and which I shall hereafter point out.

Connexions of the Ganglia with each other, and with the Cerebro-spinal Nerves.

The spinal ganglia belong specially to the posterior roots of the spinal nerves; but it will presently be seen that the anterior roots are not altogether unconnected with them.

From the *spinal ganglia* proceed three branches, viz., a middle branch, forming the continuation of the spinal nerve; an anterior or ganglionic branch, proceeding to the corresponding ganglion of the great sympathetic; and a posterior branch, which is distributed to the muscles and skin on the posterior region of the trunk.

Each of the *ganglia of the great sympathetic* receive one or several filaments from the spinal ganglia, and also a connecting cord from the sympathetic ganglion immediately above it; and each of them gives off a connecting cord to the ganglion next below it, and also certain visceral branches, which sometimes terminate directly in the viscera, and sometimes, when their distribution is complicated, proceed to the splanchnic ganglia.

Not unfrequently the communicating cords between some of the ganglia of the sympathetic are wanting, and the continuity of this nerve is then interrupted. Bichat relies chiefly upon this interruption in support of his opinion, that the great sympathetic is not a nerve properly so called, but that each of its ganglia is the centre of a small special nervous system, equally distinct from the cerebro-spinal system and from the other ganglia.

The *splanchnic ganglia* are the centres or points of convergence of a great number of nerves, of which some are derived directly from the cerebro-spinal system, and others from the ganglia of the great sympathetic. In those splanchnic ganglia which approach the median line, the nerves of the right side become blended with those of the left by a great number of plexiform branches, which have a ganglionic aspect, surround the visceral arteries, and are subdivided with them to enter the substance of the viscera.

It follows, then, from what has been just stated, that the great sympathetic is neither a continuous nerve, differing from other nerves only by having enlargements, as was believed by the older anatomists, who described the right and left sympathetic as consti-

tuting a special pair; nor is it, as Bichat conceived, a linear series of small nervous centres or little brains, which give off in all directions connecting filaments, both to the spinal and to the visceral nerves; it is a series of ganglia connected with one another in their action, and originating from each of the spinal nerves given off from the cerebro-spinal axis. It does not arise from the sixth cerebral nerve, nor from the vidian or carotid filaments, more than from any other spinal nerve; but it takes its origin from the whole spinal cord; and if it does not diminish in size as it recedes from the brain, but even increases at some points, this is because it receives new filaments of origin during its course.

According to an ingenious hypothesis, which is fully confirmed by anatomical facts, the viscera, which receive their nerves from the ganglia of the great sympathetic, derive their principle of action from the whole spinal cord, so that an affection of one nerve, or of one visceral ganglion, must affect the whole ganglionic system, in consequence of the intimate connexions between all the ganglia; and also the cerebro-spinal system, from the connexions between the sympathetic ganglia and the spinal cord. It would follow from this, that the sympathetic and the splanchnic ganglia together constitute one vast plexus, which connects, in an intimate manner, the several viscera with each other and with the rest of the body. This mutual dependance and sympathy is the chief characteristic of the organs of nutritive life, that is to say, of the organs which receive their nervous filaments from the splanchnic and sympathetic ganglia.

Structure of the Nerves.

Prochaska was the first to throw any light upon the obvious structure of the nervous cords, and to prove that they consisted of true plexuses. Reil, not being contented with noticing the plexiform arrangement of the nervous cords, endeavoured especially to determine their structure; and he failed only because he selected the optic nerve as the type of the other nerves, whereas its structure happens to be exceptional.

Each nerve consists of a plexus enveloped in a common fibrous sheath. If this sheath be opened, and the small nervous cords contained within it are spread out by tearing the cellular tissue, it is found that these small cords, which at first seem to be parallel and in juxtaposition, anastomose in a great number of ways, so as to form an extremely complicated plexus. It is also seen that the cords are of unequal size, not only in the same nerve, but also in different nerves; they are smallest in the branches of the great sympathetic and pneumogastric, and are largest in the nerves of the arm and in the great sciatic nerves.

On spreading out a nerve, with its component cords separated from each other, upon a plate of wax, and keeping those cords asunder by pins stuck at intervals, the absolute impossibility of following them through their successive subdivisions, and the multiplicity of their combinations, will become quite apparent.

The nerves consist essentially of two parts, viz., the *nervous matter properly so called*, and its *envelope* or *fibrous sheath*, which has been called the *neurilemma*.

There is a common neurilemma or common fibrous sheath for each nerve. Besides this, each small nervous cord and each fibre is provided with a proper sheath or neurilemma. The neurilemmatic canals divide, subdivide, and anastomose like the small nervous cords themselves.

The neurilemmatic canals are composed of fibrous tissue: their shining aspect (which has caused them to be frequently mistaken for tendons), their strength, their inextensibility, their low degree of vitality, in fact, all their characters, clearly prove their fibrous nature and exclusively protective function.*

The neurilemma of the nerves is continuous with the neurilemma of the spinal cord.

Nervous Matter.—If, as was shown by Reil, a nerve be immersed in diluted nitric acid, its neurilemma will be dissolved (rendered transparent), while its nervous matter will become remarkably dense and opaque. We shall hereafter see how valuable is this double property of acids in their action upon nerves for determining the true character of fibres supposed to be nervous. In a nerve thus prepared, it is seen most clearly, that the nervous filaments of which it is composed are continually anastomosing by loops or at certain angles; and that the addition of one set of filaments to the trunk of the nerve, or the separation of others from it, necessarily interrupts the chain of their relations at the very point where it seemed possible to ascertain them, so that, after every few inches, the component parts of a nerve are completely changed.

What is the structure of the nervous matter? It is not a pulp, but is composed of pencils of exceedingly fine filaments, which may be compared to the fibres of raw silk: these filaments are parallel and in juxtaposition; they are free throughout the whole length of the nerve, and may be distinctly separated from each other; when not stretched, they are flexuous like a waved line. Each nervous filament reaches the entire length of the nerve. In each nerve, the filaments of which the fibres are composed pass con-

* It may be said that the neurilemma owes its fitness as a protecting organ as well to its low vitality as to its strength. This low degree of vitality of the neurilemma is the cause why nerves are constantly seen passing through inflamed or degenerated parts without being affected themselves.

tinually from one fibre to another, and enter into an immense number of combinations, without ever becoming blended together.

This structure, which is so evident in a nerve hardened by nitric acid, is not less distinct in nerves which have undergone no preparation.* On puncturing the neurilemma, the nervous matter protrudes through the opening, precisely in the same way as the substance of the spinal cord protrudes under similar circumstances. On dividing the neurilemma along the whole length of the nerve, the nervous matter appears like long, parallel filaments, of a milk-white colour, which float in water if the nerve be immersed in that fluid.

Every nervous filament (and this is a fundamental point in their anatomy) has its central extremity in the cerebro-spinal axis, and its peripheral extremity at its point of termination. During the whole of its long course, it only enters into new combinations, without ever being interrupted.

Continuity is a law of the structure of the nervous filaments.†

Can the nerves be injected?

The doctrine of a nervous fluid, which so long prevailed in the schools, led physiologists to admit the existence of canals for the circulation of this fluid. Several experimentalists stated that they had collected the nervous fluid, and they even described its properties; and anatomists instituted no researches to confirm or refute these assertions. Malpighi himself, who, in reference to the study of anatomy, carried to such an extent that system of philosophical skepticism which has completely revolutionized all science, believed that he saw the nervous fluid escape from the cut end of a nerve, like a glutinous juice, which he compared to spirits of turpentine.‡

Reil and some others have injected the neurilemma. Reil describes a very ingenious method of injecting the optic nerve, which consists in opening the transparent cornea, and injecting mercury into the globe of the eye: the mercury passes through the foramina, which transmit the filaments of the optic nerve at the point where these become continuous with the retina.

Such was the state of our knowledge when Bogros, prosector to the Faculty, having accidentally punctured a nerve with the tube of a mercurial injecting apparatus, observed that the mercury ran along the punctured nervous fibre, and also into the adjacent nervous fibres; he repeated and varied his experiments in a great number of ways, and soon published a memoir, in which he formally announced as a demonstrated fact that, in each nervous fibre, there was a central canal capable of being injected; and, in his enthusiasm at his discovery, he thought that he had realized the desire of Ruysch,‡ and that he could henceforth trace the nerves to their very finest terminations.

The work of Bogros was in general received with little favour, and, I think, has not been estimated at its real worth. Having renewed his experiments, I have arrived at the following result: If, with a pair of blunt pincers, a nervous fibre be raised from the centre of the nerve to which it belongs (from the middle of the median nerve, for example), and if the tube of the lymphatic injecting apparatus be inserted accurately *into its centre*, the mercury will be seen to run by jerks, either downward or upward, along the centre of the nervous fibre, and to pass into a variable number of the adjacent fibres; if the injection be a successful one, the greater number of the fibres of the nerve will be injected throughout their whole length. Gentle pressure with the finger, or with the handle of the scalpel, greatly facilitates the progress of the mercury; but it often happens that the parietes of the canal through which the mercury is passing yield at some point, a rupture ensues, and the fluid is extravasated.

When the nervous fibre has not been punctured in the centre, the mercury is seen to run along the injected fibre, and even into some of those near it; but the mercurial column is never regular; it does not occupy the centre of the fibre, but only one side of it; and it is soon extravasated into the neurilemmatic sheath, which in a short time bursts.

This second kind of injection, which may be made at will by puncturing the fibre su-

* I have also examined this structure in living animals, while endeavouring to determine the insensibility of the neurilemma and the sensibility of the nervous filaments.

† [The nervous filaments (primitive fibres of Müller) are simple tubes, containing a thread of a soft, semi-transparent substance; they are continuous with the white fibres of the brain and spinal cord at the apparent origin of the nerves. The primitive fibres of the nerves resemble those of the brain and cord in the nature of their contents, but they are larger, and their tubular, homogeneous sheath is much more distinct, and is firmer, so that they do not become varicose. The olfactory, optic, and auditory nerves, however, are exceptions to this rule; their fibres resembling those of the brain and cord, in their size, delicacy, and liability to become varicose. No differences have been observed between the fibres of the other cranial and spinal nerves, nor yet between those of the motor and sensory roots. The sympathetic nerve, and all which receive fibres from it, contain, besides the ordinary nervous fibres, a greater or less number of jointed fibres (gray fibres, *Müller;* organic nervous fibres, *Schwann;* cellular tissue, *Valentin*), exactly like those found in the ganglia and in the gray matter of the brain and spinal cord.]

‡ But, as Haller remarks, Malpighi only saw this upon cutting through the cauda equina, and never observed it in the section of any other nerves; now, it is extremely probable that he saw merely the serous fluid which is most commonly found in the lower infundibuliform portion of the spinal dura mater: "Quàm vehementer suspicor eum clarum virum humorem vidisse viscidum, quo infundibulum duræ membranæ spinalis frequentissimè plenum est, et qui idem in spinam bifidam auctus abit."—(Haller, *Elem. Physiol.*, t. iv., p. 197.)

ϕ Ruysch said that he should have nothing to desire if he could succeed in injecting the nerves as he had done the vessels.

perficially, differs essentially from the former one, obtained by introducing the pipe into the centre of the fibre. In the latter case, the small column of mercury is uniform and regular, and its metallic lustre is, as it were, observed; the fluid runs rapidly; the nervous canal is less easily ruptured; and, when this does happen, it is preceded by a protrusion of the nervous matter; then the mercury is extravasated into the neurilemmatic sheath, and it pursues the same course as it would have taken if the nervous fibre had been punctured superficially in the first instance.

Where do the injections pass in these two cases? In the second method, that is to say, when the nerve is punctured superficially, it is the neurilemma that is injected. But in the method of central injection, is the nervous matter itself injected? Bogros believed that it was, and he even asserted that he had seen a central canal with the naked eye; but no such canal exists; and the one which he showed after desiccation of an injected nerve was artificially made, as we shall immediately find. How, indeed, can we admit the existence of a canal in nervous matter, which we have shown to consist of a pencil of parallel and juxtaposed filaments?

If, therefore, in the central injection, the mercury neither enters into the nervous matter, nor is contained in the neurilemma, where is it situated? Is it in lymphatic vessels? We do not know; for lymphatics have not been shown by any one. Are they arteries or nerves? To this it may be answered, that the bloodvessels do not follow the direction of the nerves.

All this is explained by the following fact: each nervous fibre, besides its common neurilemmatic sheath, has also a *proper sheath*, in contact with the neurilemma by its outer surface, and with the bundle of nervous filaments by its inner surface, which is smooth and moist. This sheath may be demonstrated by cutting a nerve across, and seizing one of the tufts which project beyond the retracted neurilemma; a nervous fibre can then generally without effort be drawn out several inches, having a smooth surface, and being completely freed from its common neurilemma. Now this fibre consists not only of nervous matter, but also of a *proper sheath* perfectly distinct from the neurilemma. It may now be injected, and will then present all the characters of the central injection already mentioned; and, upon examining it with a lens, it will be seen that the nervous filaments of which it is composed are regularly distributed around the column of mercury.

It follows, then, that, in the central injection of a nerve, it is neither the neurilemma, nor the nervous matter, nor the vessels that are injected, but *the proper sheath of each nervous fibre*; and that the passage of the injection from one fibre to a great number of others depends on the canals formed by the proper sheaths anastomosing with each other.

I shall farther remark, that in this injection the mercury evidently penetrates into a regular canal, and not into one produced by its own weight, for a column of a few lines is sufficient for the purpose.

Again, the mercury runs more easily from the peripheral towards the central extremity of a nerve than in the opposite direction, and when the injection is successful, the spinal ganglia are filled with the mercury, which is then either extravasated into the cavity of the dura mater, or escapes by the veins. If it be asked why the mercury does not pass into the anterior and posterior roots of the nerves? I should answer, that it is not certain that the fibres of these roots have any proper sheaths; or, if so, they are very readily lacerated. As to the passage of the mercury from the nervous ganglia into the veins, it is probable that the proper sheaths terminate in the ganglia, so that the mercury is extravasated into the tissue of which the ganglia consist.

Injections afford a good means of tracing the nervous filaments into the substance of organs. An injection thrown into the lingual branch of the fifth nerve penetrates as far as the papillæ of the tongue.

Structure of the Ganglia.

Meckel, in his excellent monograph upon the fifth pair, advanced the opinion that the nerves divided in the ganglia into a multitude of fibres which are intended for a great number of parts.

Zinn (Acad. Berlin, 1755) said that the nerves not only divided within the ganglia into a great number of fibres, and were directed by them from the centre to the circumference, but that they were also mingled and combined in the ganglia in such a manner that a great number of fine fibres united into a smaller number of fibres of greater diameter.

But this doctrine, however specious it may be, not resting upon any anatomical fact, was rejected by Haller. Scarpa undertook a series of researches in order to render our knowledge more complete regarding this subject. Instead of boiling the ganglia or macerating them in vinegar, urine, and other liquids, Scarpa was contented with macerating them in pure water frequently renewed—a method practised by Ruysch in his delicate investigations; by means of this simple proceeding, he was able to demonstrate that the ganglia are formed by a number of nervous filaments surrounded by cellular tissue, and by a gray matter which is destroyed by maceration.*

* [The gray matter of the ganglia consists, like that of the brain and spinal cord, of reddish nucleated glob-

He carried his researches not only into the anatomy of the spinal, but also into that of the visceral ganglia, and he discovered a wonderful uniformity in the structure of the one and the other. He compared their structure to that of the plexuses; both of them receive nerves from all sides, which nerves are then intermixed without becoming united; and both generally give off a greater number of nerves than have assisted in their formation.

The injection of the nervous ganglia from the nerves has enabled me to discover that these ganglia have a precisely similar structure to that of the lymphatic glands; they are composed of cells communicating with each other, and among which the nervous fibres are scattered.

In attempting to draw a comparison between the nervous plexuses, anastomoses, and ganglia, it might be said that in the plexuses there was an exchange of nervous cords, in the anastomoses, an exchange of nervous fibres, and in the ganglia, an exchange of nervous filaments.

Preparation of the Nerves.

For dissecting the nerves, a very emaciated subject, either young or old, should be chosen. Old wasted subjects appear to me at least as favourable as young subjects.

The dissection of the spinal nerves is easy. Such is not the case with the cranial nerves, the dissection of which is undoubtedly the most difficult part of practical anatomy. In order to facilitate the study of these nerves, and to aid in the distinction of the nervous filaments from small vessels and portions of fibrous tissue with which they are often confounded, I am in the habit of submitting the head to the action of diluté nitric acid. After having macerated it for some time in this acidulated fluid, I immerse the preparation in pure water, which I renew from time to time: the tissues generally, as well as the neurilemma, become perfectly transparent, and like jelly; the nervous matter alone remains whiter and more consistent, and then all error becomes impossible. Besides, the bones, when thus deprived of their phosphate of lime, may be cut like the soft parts. In this way I have succeeded in separating the entire cerebro-spinal nervous system from the other organs, retaining the great sympathetic in connexion with the rest of the nervous system.

DESCRIPTION OF THE NERVES.

General Remarks.—Division into Spinal, Cranial, and Sympathetic Nerves.

The nerves are divided into two very distinct sets: the *cerebro-spinal nerves*, which have their origin or central extremity in the spinal cord or its cranial prolongations: these are the nerves of relation or of animal life; and the *ganglionic nerves*, or *nerves of the great sympathetic*, which end in or emanate from certain ganglia: these belong to the system of nutrition or of organic life.

The cerebro-spinal nerves are divided into the *spinal* or *rachidian*, and the *cranial nerves:* the first consist of all those which emerge from the inter-vertebral foramina;* the second, so improperly termed the cerebral or encephalic nerves, emerge from the foramina at the base of the cranium.

As the line of demarcation, which seems, at first sight, to separate the cranium from the spinal column, disappears on an analytical study of the scull and on a comparison of it with the vertebræ, so it will be found that the cranial nerves, notwithstanding their apparent irregularity, approach, in many respects, to the simplicity and regularity of the spinal nerves. From such a comparison of the cranial with the spinal nerves we shall derive the general principle, that the situation at which the nerves emerge from their osseous cavities is altogether of secondary importance, while the fundamental points in their anatomy are the exact situation of their *central extremity*, and their mode of distribution to their peripheral extremity; we shall also find that the only rational basis of a good classification of the nerves must be derived from the consideration of their origin.

In my opinion, the only difference between the cranial and spinal nerves is, that the former arise from the medulla oblongata and its cranial prolongations, while the latter arise from the spinal cord below the medulla oblongata. Just as in the osteological division of this work I have described the vertebra before the cranium, so I shall now describe the spinal before the cranial nerves; this slight modification in the order generally adopted will enable the student to pass from the simple to the complex, and to defer the study of the very complicated nerves of the cranium until he has been accustomed to the dissection and examination of other nerves.

The following is, therefore, the order I shall adopt in describing the nerves: the *spinal nerves*, the *cranial nerves*, the *ganglionic* or *visceral nerves*.

ules, and of gray, jointed fibres, which surround and adhere to the globules, and which are most abundant in the ganglia of the sympathetic. The white fibres in the ganglia are like those of the nerves with which they are continuous; they interlace among the globules, but do not anastomose: it has been supposed that some white fibres may originate or terminate in the ganglia, but this is not established.]

* It will be recollected that we have included the sacral foramina among the invertebral.

THE SPINAL NERVES.

Enumeration and Classification.—The Central Extremities or Origins of the Spinal Nerves —Apparent Origins — Deep or Real Origins. — The Posterior Branches of the Spinal Nerves—Common Characters—the Posterior Branches of the Cervical Nerves, their Common and Proper Characters—the Posterior Branches of the Dorsal, Lumbar, and Sacral Nerves.—The Anterior Branches of the Spinal Nerves—their General Arrangement.

The number of the *spinal nerves*, that is to say, of the nerves which pass through the inter-vertebral foramina, including the sacral foramina, is entirely dependant on the number of the vertebræ.*

There are eight pairs (1 to 8, *fig.* 268) of cervical nerves, including the sub-occipital; twelve of dorsal (9 to 20); five of lumbar (21 to 25); and six of sacral nerves (26 to 31); in all, thirty-one pairs.

They all have certain characters in common; and there are also characters proper to certain regions, and, lastly, characters proper to each nerve.

We shall proceed to examine, under these three points of view, the central extremity, the course, and the termination of the spinal nerves.

The Central Extremities or Origins of the Spinal Nerves.

The Apparent Origins of the Spinal Nerves.

Dissection.—The same as that of the spinal cord.

Common Characters.

There are very close analogies, and only slight differences, between the different spinal nerves, in regard to their origin and course within the spinal canal. This circumstance, added to the fact that the same dissection is required to expose the origins of the whole series of spinal nerves, has appeared to me a sufficient reason for including them all in one common description. Such a plan, the object of which is to study analogous parts by comparison, is infinitely preferable to one in which the origin of each pair of nerves is separately described.

The spinal nerves arise from the spinal cord by a double row of filaments, or by two series of *roots*. These roots are distinguished into the *anterior* (*a a*, *fig.* 267), which come off from each side of the anterior surface of the cord, and the *posterior* (*b b*), which come off also from each side of the posterior surface. The latter are also named the *ganglionic roots*, because they are more particularly connected with the spinal nervous *ganglia* (*b b*).

The ligamentum denticulatum (*c c*) is situated between these two series of roots.

Immediately after leaving the cord, both the anterior and posterior roots are collected into a number of groups corresponding to the number of the spinal nerves; the nervous cords of which each group consists converge towards each other, the superior cords descending to meet the inferior, which is soon accomplished from the latter being less oblique in their direction. It follows, therefore, that the filaments of each root, situated one above the other, widely separated from each other on the inside, and approximated on the outside, represent a triangle, the general inclination of which to the axis of the cord varies in each particular region. Not unfrequently the filaments, especially those of the anterior roots, form two secondary groups.

As they are about to enter the separate fibrous canal formed for them by the dura mater, the fibres of each of the anterior roots, and also those of each posterior root, are collected into a flattened cord. There is one fibrous canal for each cord of the anterior roots, and another for each cord of the posterior roots. The arachnoid membrane, which forms a common funnel-shaped sheath for both roots of each spinal nerve, is reflected from them at the points where they enter the fibrous canals of the dura mater, to which the nervous cords are rather firmly attached.

Although the corresponding groups of anterior and posterior roots approach each other to pass through the fibrous canals of the dura mater, there is never the slightest communication between them. It is curious to see the long and numerous cords or filaments which constitute the *cauda aquina* running parallel to each other without any anastomoses, while, as soon as they emerge from the spinal canal, their communications are almost continual.

Communications between the filaments of the same series, whether anterior or posterior, are not rare; they take place in several different ways: thus, sometimes two filaments belonging to the same nerve unite, sometimes the filaments of two different nerves are combined, and at others, again, a filament intermediate to two nerves bifurcates and is divided between them.

Moreover, the oblique direction of the roots of the spinal nerves, and the variable length of their course within the spinal canal, are the necessary consequences of the

* This relation between the number of the spinal nerves and the number of the vertebræ prevails throughout the whole series of vertebrate animals; and, accordingly, there are about sixty spinal nerves in certain mammalia, and several hundred in some serpents.

relative shortness of the cord, which, as it terminates opposite the first lumbar vertebra, cannot give origin to all the nerves opposite the inter-vertebral foramina, through which they have to pass.*

The *differences* between the anterior and posterior roots may be collected under the following heads:

The anterior roots arise nearer to the median line than the posterior; they approach nearer and nearer to that line, towards the lower part of the cord, so that in this situation they arise from each side of the median fissure.

While all the posterior roots are given off from a longitudinal furrow of gray substance, from which they never deviate, the anterior roots arise somewhat irregularly, and, as it were, confusedly, from a small white column about half a line in breadth.

In regard to size, the posterior roots, taken separately, are much larger than their corresponding anterior roots; besides this, the filaments of the posterior roots are more numerous, so that the posterior roots, taken together, are larger than the anterior, as Sœmmering, Chaussier, and Gall have very well established. It is difficult to conceive how some authors should have entertained the opinion that the proportion between them is just the reverse, at least in some regions; this error has, doubtless, arisen from the varieties which exist in different regions of the medulla, in the relative sizes of the anterior and posterior roots, but which are never such as to give the advantage in point of size to the anterior roots: opposite the inter-vertebral foramina, the series of cords formed by the anterior roots have a different arrangement from those formed by the posterior roots.

The cord formed by each of the posterior roots immediately swells out and forms an olive-shaped ganglion, which is called a *vertebral* or *spinal ganglion* (*b b*, *fig.* 267). Haase, and then Scarpa, clearly proved that, in general, the posterior roots alone passed into the spinal ganglia, and hence they are often denominated the *ganglionic roots:* the spinal ganglia are situated in the inter-vertebral foramina, those of the sacral region are enclosed in the sacral canal.

Though it is generally to the nervous cord which emerges from this ganglion that the cord of the anterior root is applied and united, yet I would hasten to observe, that the anterior root is not so completely unconnected with the ganglion as *is* commonly stated; thus, not unfrequently the fibres of the anterior root are united either to the *outer end* or to the middle of the ganglion; and, moreover, in the lumbar and sacral regions there is half a ganglion on each root.

There are thirty pairs of spinal ganglia, and occasionally thirty-one, when the first pair of cervical nerves or the sub-occipital nerves are provided with them: the size of the ganglia bears no proportion to the diameter of the inter-vertebral foramina, but depends on the number and size of the filaments of origin which pass into them, and of the nerves which are given off from them.

The cord which emerges from the ganglion is cylindrical, has a plexiform structure, and a furrowed aspect; it is impossible to ascertain what part of it belongs to the anterior and what to the posterior root; it gives off three sets of branches: the *posterior spinal branches*, which supply the muscles and integuments of the posterior spinal region; the *anterior spinal branches* (see *fig.* 268), the true continuation of the nerve, which are distributed to the lateral and anterior parts of the trunk, and to the upper and lower extremities; and the *ganglionic spinal branches*, which pass to the ganglia of the great sympathetic (*f i u*).

The *ganglionic branches* will be described with the ganglia of the great sympathetic.

As the *posterior branches* have a close analogy in their mode of distribution, and may be exposed in the same dissection, they will be described under one head.

The *anterior branches* being destined for dissimilar parts, their individual distribution is exceedingly varied and complicated, so that a particular description is requisite, if not of the anterior branches of each nerve, at least of those of the several sets of nerves.

Such are the characters common to all the spinal nerves at their central extremities, during their course within the vertebral canal, and at their exit from the inter-vertebral foramina. Let us next examine the characters proper to the nerves of each region.

Proper Characters of the Apparent Origins of the Nerves.

Proper Characters of the Cervical Nerves.—The roots of these nerves (1 to 8, *fig.* 268) are much less oblique than those of the other spinal nerves. The first cervical nerve slopes a little upward and outward, like the cranial veins, which it resembles in this respect. The second nerve is transverse; the succeeding nerves slope downward and outward, the lowest being the most oblique; but their obliquity never exceeds the depth of a single vertebra.

The proportion between the size of the posterior and anterior roots is as 3 to 1; and

* Gall believed that he had solved this question, by saying that the length and obliquity of the course of the spinal nerves is a necessary result of the erect position of man. It is certain that the nerves are less oblique and have a shorter course within the vertebral canal in the lower animals; but this difference is explained by the greater length of the spinal cord in them, and has nothing to do with the attitude.

this difference, which is much greater than is observed in any other region, obtains not only in reference to the filaments taken altogether, but also to each particular filament.

The cervical nerves increase rapidly in size from the first to the fifth, and then maintain the same size to the eighth.

The first cervical nerve, so well described by Asch, has some peculiarities: its posterior filaments of origin are much less numerous than the anterior, the spinal accessory of Willis appearing to supply this deficiency; it is also frequently without a ganglion.*

Proper Characters of the Dorsal Nerves.—Excepting the first, which has all the characters of the cervical nerves, the roots of the dorsal pairs of nerves (9 to 20) present the following peculiarities:

A small number of filaments or roots; so that, with the exception of the sacral, the dorsal are the smallest of all the spinal nerves.

Uniformity in the number of the filaments, *i. e.*, in the size of their roots. The dorsal nerves are almost of equal size, the twelfth nerve alone being somewhat longer than the rest.

A considerable interval between their roots, and a want of regularity in this interval. Frequently a portion of the spinal cord, from eight to ten lines in length, gives origin to only a small pair of nerves.

A more marked slenderness of the filaments of origin than in any other region.

The slight disproportion between their anterior and posterior roots when compared filament for filament.

The direction of their roots, which remain in contact with the cord for some distance, and then leave it; this circumstance is calculated to give rise to errors concerning the precise situation of their origin.

The length of their course within the spinal canal; this length is equal to the height of at least two vertebræ.

Proper Characters of the Lumbar and Sacral Nerves.—The roots of these nerves form the cauda equina; their characters are, the great number of their filaments of origin, which exceeds those of the dorsal, and even those of the cervical nerves.

The extreme closeness of these filaments, which form an uninterrupted series.

The proportion between the filaments of the anterior and those of the posterior roots, which is as 2 to 1.

The uniformity in point of size between the two sets of filaments, the anterior filaments, taken individually, being as large as the posterior.

The continuance of the origin of the posterior roots to take place at the groove, while the anterior approach nearer and nearer to the median line towards the lower part of the cord, and almost touch those of the opposite side.

The concurrence of both the anterior and posterior roots in the formation of the spinal ganglia.

The almost vertical direction of the roots, a character common to both the lumbar and sacral pairs of nerves.

The singular length of their course before they emerge from the spinal canal.†

The Real Origins of the Spinal Nerves.

The *apparent central extremity* or *origin of the spinal nerves* is very different from their *real central extremity* or *real origin*. On examining the spinal cord of an adult, for the purpose of determining this important point, one is inclined to admit that the point of contact between any nerve and the cord is the real origin of the nerve, so readily can the latter be separated from the cord without leaving any trace of the separation.

It has even been stated by some that the nerves arise from the neurilemma of the spinal cord.

Chaussier believed that the two series of roots arose from two lateral furrows, one anterior and the other posterior; but Gall has with reason regarded these furrows as formed by pulling off the roots.

Others agree with the older anatomists in regarding the spinal cord as a large nerve formed by the junction of all the nervous filaments which are given off from it. But this idea is refuted by the fact that the cord does not progressively diminish in size from above downward, as it must have done if formed by the junction of the roots of the spinal nerves.

The ingenious and correct observation made by Vicq d'Azyr, that the gray matter is always found in large quantity at those parts from which a great number of nerves originate, and that it bears a proportion to the number of these nerves, and the confirmatory observations of Gall and Spurzheim, seem to prove that the nerves originate from the gray matter. This presumption is also strengthened by the consideration, that the

* According to the principles of classification which I have already stated, I should range the spinal accessory nerve among the cervical nerves, because it originates from the cervical portion of the spinal cord: in classing it among the cranial nerves, I yield to general usage.

† [Lastly, the situation of the ganglia of the sacral nerves within the sacral canal, and of the lowest of them within the cavity of the dura mater.]

central gray substance of the cord is more abundant opposite the posterior roots, which are the larger, than opposite the anterior roots, which are the smaller. On examining the spinal cord of an adult by means of a stream of water, it is seen that, after tearing away the filaments of the nerves, a small conical depression remains where each filament had been attached, and that the real origin of the filaments is not in this depression, but is much more deeply seated. This is all that can be discovered from an examination of the spinal cord of the adult; but in the fœtus, at the seventh or eighth month, a considerable part of the cord is semi-transparent, so that the already white filaments by which the nerves arise can be traced into its interior. On making a vertical section transversely through the spinal cord of the fœtus, just level with the commissure, and then directing a strong light on the surface of the section, it will be seen that the great number of very delicate filaments of which the anterior and posterior roots of the spinal nerves are composed traverse the central gray matter, are arranged like the teeth of a comb, and may be traced into the posterior median columns; these small filaments are, moreover, all parallel. The white commissure might almost be regarded as the commissure of these nerves.

This view is very different from that of Bellingeri, who, entertaining certain physiological ideas, supposes that the anterior as well as the posterior roots of the spinal nerves consist of three sets of filaments, some of which come from the surface of the cord, others from the interior of the white matter, while the third set traverse the white matter, so as to reach the extremities of the cornua of the gray substance.

Lastly, some anatomists agree with Santorini in believing that the nerves decussate at their origin; but they have not attempted to demonstrate this.

The Posterior Branches of the Spinal Nerves.

Dissection.—Divide the integuments from the external occipital protuberance down to the coccyx. Dissect off the skin over the spinous processes with great care, especially opposite the trapezius. Be particularly cautious opposite the cellular interval between the sacro-lumbalis and the longissimus dorsi.

Common Characters.

The *posterior branches of the spinal nerves*, which are generally smaller than the anterior branches, emanate from the plexiform cords which form the continuation of the corresponding spinal ganglia, are directed backward, and immediately pass through the foramina, which I may regard as *posterior inter-vertebral foramina.** These branches subdivide into several twigs, which enter the great cellular intervals between the long muscles of the back, and are distributed to the muscles of the integuments. The greatest uniformity prevails among such of these nerves as are distributed to the same kinds of organs, and their differences depend on peculiarities in the parts to which they belong.

We shall now study in succession the posterior branches of the cervical, dorsal, and lumbar spinal nerves.

The Posterior Branches of the Cervical Nerves.

Common Characters.

All the posterior branches of the cervical nerves (*i* to *o'*, *fig.* 300) pass transversely inward between the complexus and the semi-spinalis colli, having first given off some very small twigs: having reached the sides of the posterior cervical ligament, they perforate the aponeurotic attachments of the trapezius from before backward, lie close beneath the skin, and are directed transversely outward. The course of these branches, therefore, is at first inward, and then outward. The posterior branch of the first cervical nerve is the only one which presents any exception to these general characters.

Proper Characters.

The Posterior Branch of the First Cervical Nerve.

The *posterior branch* of the first cervical or sub-occipital nerve, larger than the anterior branch, escapes between the occipital bone and the posterior arch of the atlas, on the inner side of the vertebral artery, with which it is in contact, below the rectus capitis posticus major, and in the area of the equilateral triangle formed by that with the two oblique muscles; in this situation (*i*, *fig.* 300) it is concealed by a large quantity of fatty tissue, which renders it rather difficult of dissection; and it immediately divides into several branches, which may be arranged into the *internal*, which go to the great and small recti muscles; *external*, which supply the great and small oblique muscles; and *inferior* or *anastomotic*, which, by uniting with the second cervical nerve, assist in the formation of the *posterior cervical plexus*.

The branch to the rectus minor passes at first between the rectus major and the complexus, and then reaches the rectus minor.

* Vide OSTEOLOGY (vertebral column in general). These foramina are situated between the transverse processes, and in the dorsal region are completed on the outside by the superior costo-transverse ligament.

The principal branch for the inferior oblique, before ramifying in that muscle, forms an arch or loop, which has been well described by Bichat.

It follows, therefore, that both of the recti and both of the oblique muscles are supplied by the first cervical nerve, which gives no filament to the complexus,* and none to the skin.

The Posterior Branch of the Second Cervical Nerve.

This is the largest of all the posterior branches of the cervical nerves, and is three or four times larger than the anterior branch of the same nerve; it emerges (*g*, *fig.* 300) from the spine, between the posterior arch of the atlas and the corresponding lamina of the axis, in the same line as the posterior branch of the first nerve, immediately below the lower border of the obliquus major, and is reflected upward between the hairy scalp on the one hand, and the occipitalis muscle and epicranial aponeurosis on the other; it passes horizontally inward between the obliquus major and the complexus, perforates this last muscle in the outer side of its digastric portion (the biventer cervicis), then changes its direction, and turns outward between the complexus and the trapezius, through which latter it passes to become sub-cutaneous and accompany the occipital artery; it is here called the great occipital nerve (occipitalis major, *a*, *fig.* 285). Hitherto cylindrical, this nerve, on becoming sub-cutaneous, is flattened, and increased in width, and then, passing upward, spreads out into a considerable number of diverging branches, internal, middle, and external, which cover the occipital region with their ramifications, and may be traced even to the parietal region: the internal branches are the shortest, and are successively lost in the skin of the occipital region.

It supplies several *branches*, as follows: *Some anastomotic branches* to the first and third cervical nerves.

Opposite the lower border of the obliquus major, it gives off a considerable *muscular branch* (*w*, *fig.* 300), which is distributed to that muscle, to the complexus, and especially to the splenius (*w*, *fig.* 298); the branches to the splenius are of great size, and spread upon its deep surface into diverging twigs, which anastomose both with each other and with branches derived from the third cervical nerve.

During its passage between the obliquus major and the complexus, and between the last-named muscle and the trapezius, the posterior branch of the second cervical nerve supplies these different muscles with a rather large number of nervous twigs.

Its sub-cutaneous portion is distributed exclusively to the hairy scalp. The occipitalis muscle, upon which it ramifies, does not receive any branch from it: as we shall elsewhere show, this muscle is supplied by the auricular branch of the facial nerve. The subdivisions of the sub-cutaneous portion of the second cervical nerve may be traced into the hair follicles, and several of its external branches anastomose with the mastoid branch of the anterior cervical plexus.

The Posterior Branch of the Third Cervical Nerve.

The *posterior branch of the third cervical nerve*, smaller than that of the second, but much larger than that of the fourth nerve, and partially intended for the occipital region, emerges between the transverse process of the atlas and that of the third cervical vertebra, and, consequently, farther outward than the posterior branches of the first and second nerves; it is immediately curved, and passes transversely inward (*t*, *fig.* 300) between the complexus and the semi-spinalis colli. Having reached the inner border of the complexus, it divides into two cutaneous branches: an *ascending* or *occipital*, which perforates the innermost fibres of the complexus, passes vertically upward upon one side of the median line, applied to the under surface of the skin, and ramifies upon the occipital region, near the median line, and to the inner side of the branch from the second cervical nerve; and a *horizontal* or *cervical branch*, which perforates the aponeurosis of the trapezius between the complexus and the posterior cervical ligament, and passes horizontally outward beneath the skin, to which it adheres, and in the substance of which it terminates.

As the posterior branch of the third cervical nerve emerges from the posterior intervertebral foramen, it gives off an ascending branch, which forms an anastomotic arch with the descending branch of the second nerve: the succession of arches formed by the anastomoses of the first, second, and third nerves, and the very numerous branches which arise from their convexities, constitute a plexus, which may be called the *posterior cervical plexus:* it is situated beneath the complexus, near its external attachments, and it supplies both that muscle and the splenius. The direct anastomoses between the posterior branches of the three superior cervical nerves appear to me to be sometimes wanting; but then the branches given off from them still exist, and form a plexus between the splenius and the complexus.

The Posterior Branches of the Fourth, Fifth, Sixth, Seventh, and Eighth Cervical Nerves.

The *posterior branches of the fourth, fifth, sixth, seventh, and eighth cervical nerves* are much smaller than the preceding, and diminish in size successively from the fourth to the

* [Asch saw and has described *a twig* (*m*, *fig.* 300) proceeding from the posterior branch of the first cervical nerve to the complexus muscle; Swan and Arnold lso observed it.]

seventh. Immediately after their exit from the posterior inter-vertebral foramina, they are reflected inward and downward in the following manner: the fourth and fifth (*o'*) incline downward upon the semi-spinalis colli, between it and the complexus; the sixth, seventh, and eighth descend almost vertically beneath the lowest fasciculi of the semi-spinalis colli, supply that muscle and the multifidus spinæ, and having reached the side of the median line, perforate the aponeuroses of the splenius and trapezius, become applied to the skin, and ramify in it.

The Posterior Branches of the Dorsal, Lumbar, and Sacral Nerve.

The Posterior Branches of the Dorsal Nerves.—These are intended for the dorsal region of the trunk, and resemble each other closely in their distribution, presenting only a few differences connected with the arrangement of the particular muscular layers of each region.

The *posterior branch* of the *first* dorsal nerve has the same muscular and cutaneous relations as the corresponding branches of the lower cervical nerves; it is of the same size, and is distributed in precisely the same manner.

The *posterior branches* of the *second*, *third*, *fourth*, *fifth*, *sixth*, *seventh*, and *eighth* dorsal nerves are destined for the thorax, properly so called, and present the greatest uniformity in their size and distribution.

They all emerge from the posterior inter-vertebral foramina, immediately on the outer side of the semi-spinalis dorsi and multifidus spinæ, and divide into two branches. The *external* or *muscular* branch is directed towards the cellular interval between the sacro-lumbalis and longissimus dorsi, and subdivides into a great number of twigs, which are distributed to these two muscles [and to the levatores costarum]. The *internal* or *musculo-cutaneous branch* has a very remarkable course. It is reflected inward over the semi-spinalis dorsi, embracing the outer border of that muscle, and supplying it with nervous twigs; having reached the side of the spinous process, it is reflected backward along that process, perforates the spinal attachments of the latissimus dorsi, and thus gains the under surface of the trapezius; in this situation it is reflected outward between the latissimus dorsi and the trapezius, perforates the latter muscle very obliquely, and becomes sub-cutaneous; it then passes horizontally outward in the form of a small nervous riband, the distinct fibres of which do not disunite and spread out in the substance of the skin until they have arrived at the scapular region. The cutaneous branch, which belongs to the second dorsal nerve, always corresponds to the triangular surface on the spine of the scapula, over which the aponeurosis of the trapezius glides.

In one subject which I examined, the musculo-cutaneous divisions of the posterior branches of the third, fourth, and fifth dorsal nerves presented two ganglia at the point where they bifurcated into their muscular and cutaneous branches; in another, the ganglia were situated upon the cutaneous branches belonging to the first and third dorsal nerves. All these cutaneous branches are horizontal, parallel, and separated from each other by an interval corresponding to the height of one vertebra. Such of the posterior branches of the dorsal nerves as are in relation with the trapezius always present the preceding arrangement. But the branches lower down than that muscle are distributed in the following manner:

The *posterior branches* of the *ninth*, *tenth*, *eleventh*, and *twelfth dorsal nerves* are distributed in precisely the same way as the *posterior branches* of the *lumbar nerves*, and, like them, are intended for the abdominal parietes.

There is no longer any internal or musculo-cutaneous branch, the external branch representing both the muscular and the cutaneous branch.*

Immediately after emerging from the inter-vertebral foramina, these posterior branches pass very obliquely downward and outward, gain the cellular interval between the sacro-lumbalis and the longissimus dorsi, or, rather, pass very obliquely through the common mass formed by the union of the sacro-lumbalis and longissimus dorsi, and almost always communicate with each other during their long course through the fleshy fibres: having arrived opposite the outer border of the latissimus dorsi, or of the common mass, these branches, diminished fully one third in consequence of having supplied the posterior spinal muscles, perforate very obliquely the aponeurotic layer formed by the union of the aponeuroses of the latissimus dorsi and serratus posticus inferior, with those from the internal, oblique, and transverse muscles of the abdomen, and become sub-cutaneous; they then divide into some very small *internal cutaneous filaments*, which are directed inward upon the side of the spinous processes, and some large *external cutaneous filaments*, which descend to terminate in the skin of the gluteal region. I would especially notice several large nerves, which, either joined together, or only in contact, descend vertically, cross perpendicularly over the crest of the ilium in front of the outer border of the common mass of the lumbar muscles, and become applied to the integuments of the gluteal region, upon which they may be traced as far as the great trochanter.

* [The internal branches of the four lower nerves are not absent, but are much reduced in size, do not reach the surface, and are distributed principally to the multifidus spinæ: the external branches give the cutaneous twigs. (*Demonstrations of Anatomy*, by G. V. Ellis, of whose labours in reference to the anatomy of the nerves, free use has been made in this and many of the succeeding notes.)]

The Posterior Branches of the Lumbar Nerves.—These resemble in their distribution the corresponding branches of the four lower dorsal nerves; they gradually diminish in size from above downward; the fifth is extremely small, and is entirely expended in the common mass of the lumbar muscles.

The Posterior Branches of the Sacral Nerves.—These branches emerge from the posterior sacral inter-vertebral foramina. It is difficult to dissect them, because they are extremely small, and penetrate immediately into the muscular mass which occupies the sacral groove; they moreover decrease in size from above downward, and are uniformly arranged in the following manner: immediately after their exit from the posterior inter-vertebral foramina, they form anastomotic arches with each other, from which muscular and cutaneous filaments are given off. The former are distributed to the common mass and the glutæus maximus, and the latter are intended for the skin of the sacral region.*

The Anterior Branches of the Spinal Nerves.

The *anterior branches of the spinal nerves*, which are generally larger than the posterior, are the true continuations of these nerves, and supply the lateral and anterior parts of the trunk, and also the upper and lower extremities.

Such of these branches as are intended for the trunk of the body have an extremely uniform and very simple mode of distribution; to this class belong the *intercostal nerves:* those, on the other hand, which are intended for the upper and lower extremities, present, in their distribution, a degree of complexity which depends on that of the parts which they supply. To this class belong the *anterior cervical*, *anterior lumbar*, and *anterior sacral branches.*

The three last-named sets of branches, almost immediately after their exit from the spinal canal, communicate with each other, so as to form interlacements or *plexuses*, from which are given off the nerves, that ultimately ramify in all parts of the body.

There are four great plexuses: two for the region of the neck and the upper extremity, viz., the *cervical plexus* (*x*, *fig.* 268) and the *brachial plexus* (*h*), which might be regarded as a single plexus, the *cervico-brachial;* and two for the lumbar region and the lower extremity, viz., the *lumbar* (*l*) and the *sacral* or *crural plexus* (*s*), which also might be regarded as one, the *lumbo-sacral plexus.*

After these preliminary observations, I shall now describe, in succession, the anterior branches of the cervical, dorsal, lumbar, and sacral nerves.

THE ANTERIOR BRANCHES OF THE CERVICAL NERVES.

Dissection.—Anterior Branch of the First, Second, Third, and Fourth Cervical Nerves.—The Cervical Plexus—Its Anterior Branch, the Superficial Cervical—Its Ascending Branches, the Great Auricular and the External or Lesser Occipital—Its Superficial Descending Branches, the Supra-clavicular—Its Deep Descending Branches, the Nerve to the Descendins Noni and the Phrenic—Its Deep Posterior Branches.—The Anterior Branches of the Fifth, Sixth, Seventh, and Eighth Cervical, and First Dorsal Nerves.—The Brachial Plexus.—Its Collateral Branches above the Clavicle—Its Muscular Branches, Posterior Thoracic, Supra-scapular, opposite to the Clavicle, the Thoracic, below the Clavicle, the Circumflex—Its Terminal Branches, the Internal Cutaneous and its Accessory, the Musculo-cutaneous, the Median, the Ulnar, the Musculo-spiral or Radial.—Summary of the Distribution of the Branches of the Brachial Plexus.

Dissection.—It is convenient to dissect the sub-cutaneous branches which emerge from the cervical plexus before examining the anterior branches of the cervical nerves: one side of the neck may be reserved for the superficial, and the other for the deep branches.

The Anterior Branches of the First, Second, Third, and Fourth Cervical Nerves.

The Anterior Branch of the First Cervical Nerve.—This branch (*u*, *fig.* 300) emerges from between the occipital bone and the posterior arch of the atlas in the groove for the vertebral artery, and beneath that vessel; opposite the foramen in the transverse process of the atlas, it leaves the artery, passes in front of the base of that process, is reflected downward, and descends to form an anastomotic arch with the anterior branch of the second nerve. As all the branches belonging to the first nerve come off from this anastomotic arch, they will be described with the second nerve.

The Anterior Branch of the Second Cervical Nerve.—This is much smaller than the posterior branch of the same nerve; it passes horizontally forward between the transverse processes of the atlas and axis, is reflected in front of the axis, and divides into an *ascending* and a *descending* branch.

* Among the cutaneous filaments which proceed from the arch formed by the posterior branches of the first and second sacral nerves, there is one which passes below the posterior and inferior spinous process of the ilium, is directed vertically downward between the glutæus maximus and the lesser sacro-sciatic ligament, perforates the glutæus maximus, and is then reflected outward in contact with the skin.

The *ascending branch* curves upward in front of the transverse process of the atlas, and anastomoses in an arch with the anterior branch of the first nerve.

The *descending branch* (*z*, *fig.* 298) subdivides into two others of almost equal size: the one *internal* (see also *fig.* 300), which constitutes the *internal descending cervical nerve* (before *s*, *fig.* 298); the other *external* (behind *s*), which anastomoses with the third nerve (above *s*), to form the *superficial cervical nerve* (*k*) and the great *auricular nerve* (*q*).

Several large filaments for the *rectus capitis anticus major* are given off from the angle of bifurcation of the ascending and descending branches.

The anastomotic arch formed by the anterior branches of the first and second cervical nerves gives off three or four very large grayish branches and several small white filaments, which go to the superior cervical ganglion of the sympathetic; above these it gives a short gray filament, which almost immediately swells into a ganglion, from which a long, slender, descending filament proceeds to join the *internal descending nerve*; lastly, it furnishes two ascending filaments, the lower one of which joins the pneumogastric nerve, and the upper one the hypoglossal or ninth nerve.

The Anterior Branch of the Third Cervical Nerve.—This (above *s*, *fig.* 298) is twice as large as the preceding; it at first passes forward to emerge from the inter-transverse space, then downward and outward, and having gained the under surface of the sterno-mastoid muscle, it expands into a great number of branches, which constitute the cervical plexus properly so called, and may be divided into a *superior* and an *inferior* portion.

The *superior division* passes outward and backward beneath the sterno-mastoid muscle, and bifurcates upon its posterior borders. One of the branches of the bifurcation ascends, and is called the *mastoid nerve* (*y*); the other, which is reflected over the posterior border of the muscle, anastomoses by one or two filaments with the anterior branch of the second cervical nerve, and subdivides into the *superficial cervical nerve* (*k*) and the *auricular nerve* (*q*): both of the branches of the bifurcation anastomose with the second cervical nerve. This superior division, moreover, gives off a small nerve, which ascends between the auricular and mastoid nerves; also a communicating branch to the superior cervical ganglion; and, lastly, a series of branches (*v*), which anastomose with the spinal accessory nerve of Willis (*t*), some immediately, and others while within the substance of the sterno-mastoid muscle. This superior division of the third nerve sometimes joins the lowest branch of the second nerve.

The *inferior* or *descending portion* passes vertically downward in front of the scalenus anticus, gives off a long slender filament to the *internal descending cervical nerve*, and terminates partly by anastomosing with the fourth cervical nerve (below *s*), and partly by becoming continuous with the clavicular nerves (*u*).

A considerable branch which enters the levator anguli scapulæ may be regarded as belonging to this inferior portion. This branch for the angularis sometimes arises at the point of bifurcation of the anterior branch of the third nerve.

The Anterior Branch of the Fourth Cervical Nerve.—This branch (below *s*) is of the same size as the preceding; it gives off the *phrenic nerve* (*l*), which sometimes arises in the inter-transverse space; it then passes downward and outward in contact with the scalenus anticus for about ten lines, and divides into two terminal branches, the one internal, the other external, which soon subdivide and cover the supra-clavicular triangle with their diverging ramifications: these branches constitute the *supra-clavicular* and *acromial* nerves (*u*). Just opposite its division the anterior branch of the fourth cervical nerve receives a branch from the third, which appears to be shared between its two terminal divisions.

The fourth cervical generally sends off a small communicating branch to the fifth cervical nerve.

The Cervical Plexus.

The term *cervical plexus* is applied to the series of anastomoses (*z s*) formed by the anterior branches of the first, second, third, and fourth cervical nerves.

Some anatomists call it the *deep cervical plexus*, in contradistinction to the superficial branches given off from it, which, according to this view, constitute the *superficial cervical plexus*.

This plexus, which occupies the anterior and lateral aspect of the four superior cervical vertebræ, is situated beneath the posterior border of the sterno-cleido-mastoid muscle, to the outer side of the internal jugular vein, between the rectus capitis anticus major and the cervical attachments of the splenius and levator anguli scapulæ: it is concealed by a considerable quantity of fat, and by a great number of lymphatic glands: it is also covered by an aponeurotic lamina, which adheres to it intimately, and is prolonged upon the nerves which emanate from it.

After the example of Bichat, this plexus may be regarded as a centre in which the anterior branches of the four superior cervical nerves terminate, and from which a great number of branches proceed. This plexus is by no means inextricable; it is always easy to determine the origin of the branches which come from it.

These branches consist of one anterior branch, the *superficial cervical* (*k*); of ascending

branches, viz., the *great mastoid* (*y*), the *small mastoid*, and the *great auricular* (*q*); and of descending branches, subdivided into the deep and the superficial; the deep ones consisting of the *internal descending branch* (before *s*), the *phrenic* nerve (*l*), and the *branches for the trapezius, levator anguli scapulæ*, and *rhomboideus;* the superficial descending branches are the *supra-clavicular* and the *acromial* (*m*).

According to their distribution, they may also be divided into *muscular* and *cutaneous* branches; the muscular consist of the internal descending, the phrenic, the branches for the trapezius, the levator anguli, and the rhomboideus; all the others are cutaneous, and are flattened like ribands.

The Anterior Branch.

The Superficial Cervical Nerve.

The *superficial cervical nerve* (superficialis colli, *s*, *fig.* 285), which is often double, in consequence of dividing earlier than usual, is destined exclusively for the skin of the neck and lower part of the face (sous-mentonnière, *Chauss.*), and is formed by the anastomoses of the second and third cervical nerves; it emerges from the plexus opposite the middle of the neck, beneath the posterior border of the sterno-mastoid, around which it turns in the form of a loop, and then passes horizontally forward between that muscle and the platysma, runs at right angles beneath the external jugular vein, and divides into two branches—one *ascending* and larger, the other *descending;* these two branches often form two distinct nerves.

Fig. 285.

The *descending branch* passes downward and inward between the sterno-mastoid and the platysma, is reflected upward so as to form a loop, having its concavity turned upward, perforates the platysma, and then lies in contact with the skin, beneath which it may be traced as far as opposite the os hyoides.

One of its twigs, which appears to me to be constant, having reached the side of the median line, is reflected upward in front of the anterior jugular vein, ascends vertically, and may be traced into the skin of the supra-hyoid region.

The *ascending branch*, which sometimes arises by a common trunk with the auricular nerve, immediately divides into four or five very slender and slightly waving filaments, which, situated at first between the sterno-mastoid and the platysma, generally perforate the last-named muscle, to become sub-cutaneous; two of these diverging filaments, which remain subjacent to the platysma, are very slender, and run along the external jugular vein, one in front of and the other behind that vessel.

All the other filaments pass upward and inward in contact with the skin, and subdivide into a great number of filaments, which may be traced as far as the skin of the chin and lower part of the cheek; I have seen two of these filaments anastomose with the facial nerve. It is important to observe, that the cervical filaments of the facial nerve occupy a deeper plane than those of the superficial cervical nerve, and are separated from these latter in front by the platysma.

The Ascending Branches.

The Auricular Nerve.

The *auricular nerve* (auricularis magnus, *d*, *fig.* 285), the ascending anterior branch of the cervical plexus, arises from the second and third cervical nerves by a trunk which is common to it and to the superficial cervical; it emanates from the plexus immediately above the last-named nerve, like which it embraces the posterior border of the sterno-mastoid so as to form a loop with the convexity turned backward, and then passes upward and a little forward between the platysma and the sterno-mastoid, and reaches the anterior border of that muscle opposite the angle of the lower jaw. In this situation it gives off several *facial* or *parotid* filaments, and terminates by dividing into a *superficial* and a *deep* branch.

The *facial* or *parotid branches* are very slender; some of them pass between the parotid and the skin, with which they are in contact; the others pass through the parotid gland from behind forward, and from below upward, to be distributed to the skin of the cheek; I have traced them as far as the skin which covers the malar bone; it has not been shown that some of them terminate in the substance of the parotid, as has been stated.*

The *superficial auricular branch* ascends vertically, in the substance of the very dense

* I have seen two of these parotid filaments terminate in a small abnormal ganglion, from which other filaments were given off and distributed in the manner above described.

fibrous tissue which connects the parotid to the skin; it gains the lower part of the concha opposite to the anti-tragus, and then divides into several filaments, the distribution of which is remarkable: the largest passes above the lobule in the fissure between the concha and the caudal extremity of the helix, and is distributed to the skin on the concave surface of the auricle, and especially to the skin of the concha; another filament turns round the margin of the auricle, and gains the groove of the helix, which it follows even to its upper part.

The *deep auricular branch*, which may be called the *anterior mastoid*, perforates the substance of the parotid gland, and gains the front of the mastoid process; here it crosses at an acute angle over the auricular branch of the facial nerve, which is more deeply seated, and with which it anastomoses by a rather large branch; it then passes behind the posterior auricular muscle, and divides into two secondary branches: a *posterior*, which passes upward and backward, and may be traced as far as the outer border of the occipitalis muscle, where it anastomoses with a very delicate filament of the external occipital nerve; and an *anterior*, which runs upon the upper part of the cranial surface of the auricle. The superior filaments are reflected over the upper margin of the auricle, and are distributed to the skin which covers its external or concave surface.

From what has been just stated, it follows that the auricularis magnus gives off no muscular filament. The posterior auricular and occipitalis muscles are supplied entirely from the auricular branch (*v*) of the facial nerve.

The Mastoid or External Occipital Nerve.

The *mastoid* or *external occipital nerve* (occipitalis minor, *b*), the posterior ascending branch of the cervical plexus, rises from the second cervical nerve; it comes off from the plexus above the preceding nerve, describes a loop with the convexity turned upward upon the posterior border of the sterno-mastoid, ascends almost vertically, parallel to the great occipital nerve and to the posterior border of the sterno-mastoid, crosses the posterior occipital attachments of that muscle, continues to ascend upon the occipital region, and then upon the parietal region, and may be traced as far as opposite the anterior border of the parietal bone. During this course it is situated between the splenius and occipitalis muscles and epicranial aponeurosis on the one hand, and the skin on the other.

This nerve gives off in the occipital region some *external branches*, which are distributed to the skin, and anastomose with a filament of the auricular nerve, but none of them pass to the auricle. The term *occipito-auricular* (*Chauss.*) is, therefore, not applicable to it; it should rather be called the *external occipital* (occipitalis minor, *b*),* to distinguish it from the *internal occipital* (occipitalis major, *a*), given off by the posterior branch of the second cervical nerve.

It also supplies some *internal branches*, which anastomose several times with the internal occipital nerve, and are distributed to the skin.

It gives no filament to the occipitalis muscle, nor does it anastomose with the facial nerve. The mastoid or external occipital nerve is essentially a cutaneous nerve.

We sometimes find a small supplementary branch between the great auricular and external occipital nerves, which runs parallel to them, and may be called the *small mastoid nerve* (*c*).

The Superficial Descending Branches.

The Supra-clavicular Nerves.

The Supra-clavicular Nerves (*e*, *fig.* 285; *u*, *fig.* 298).—The terminating branches of the cervical plexus are two in number: one internal, or the *supra-clavicular nerve*, properly so called; the other external, or the *acromial nerve;* they come off from the plexus at the posterior border of the sterno mastoid, descend perpendicularly towards the clavicle, and divide into several branches, which again subdivide before reaching that bone, so that they cover the supra-clavicular triangle with their diverging filaments. All these branches cross over the clavicle at almost regular intervals, and are lost upon the upper and anterior part of the thorax.

The innermost or *sternal branches* cross very obliquely over the external jugular vein, then over the clavicular and sternal attachments of the sterno-mastoid, and ramify in the skin, where they may be traced as far as the median line.

The external or *acromial branches* pass obliquely over the external surface of the trapezius, cross the outer end of the clavicle, and are distributed to the skin over the acromion and the spine of the scapula. I have followed some filaments over the top of the shoulder as far as the lower borders of the pectoralis major.

The intermediate or *clavicular* branches cross the clavicle at right angles, are in contact with the skin upon the upper part of the thorax, and may be traced to within a short distance of the nipple.†

* The name mastoid branch is bad, for this branch has no relation with the mastoid process.

† Not unfrequently the supra-clavicular nerve passes through a foramen in the clavicle, at the junction of the external third with the internal two thirds of that bone; sometimes, instead of a bony canal, there is a

All these branches lie at first beneath the platysma, and then become sub-cutaneous. A layer of fascia and the omo-hyoid muscle are interposed between them and the scaleni muscles and brachial plexus. Some loose cellular tissue separates them from the clavicle, upon which they glide with the greatest freedom.

The Deep Descending Branches.

The Internal Descending Cervical Nerve.

The *internal descending cervical nerve* (before *s*, *fig.* 298), which is destined exclusively for the muscles of the sub-hyoid region, may be considered as the inferior branch of the bifurcation of the second cervical nerve, although the first and third nerves each give to it a small re-enforcing filament.

It passes vertically downward, on the outer side of the internal jugular vein, along which it runs, is joined on its inner side by a filament from the first cervical nerve, and having reached a little below the middle of the neck, is reflected inward in front of the internal jugular vein, and forms an anastomotic loop, which is sometimes plexiform, with the descending branch (descendens noni, *h*) of the hypoglossal nerve ; this is a remarkable anastomosis, and presents many varieties in its arrangement. The convexity of this loop is turned downward, and from it arises a branch, which sometimes scarcely exceeds in size either of the formative branches of the loop, and which expands into several filaments (*g*). One of these ascends and supplies the superior attachments of the sterno-hyoid and omo-hyoid ; a transverse filament proceeds to the bodies of the sterno-hyoid and sterno-thyroid muscles. Several filaments can be traced as far as the lower part of the latter muscle, that is to say, down to opposite the second rib. The inferior fleshy belly of the omo-hyoid is supplied by some twigs derived from the filaments which enter its superior belly.

The Phrenic or Diaphragmatic Nerve.

The *phrenic nerve* (*l*, *figs.* 298, 302) is a branch derived from the fourth cervical nerve, sometimes re-enforced by a very small filament from the third nerve, and almost always by a larger branch from the fifth.* Not unfrequently one of the formative branches of the loop of the hypoglossal nerve just described joins the phrenic nerve. The right and left phrenics are rarely of the same size.

After its origin, the phrenic nerve descends vertically in front of the inner border of the scalenus anticus, with which it is held in contact by a fascia. It is round at first, but becomes flattened as it passes between the sub-clavian vein and artery (I have seen it pass in front of the vein), and is then inclined slightly inward, to enter the superior orifice of the thorax. In the thorax (*l*, *fig.* 302) it continues its vertical direction, runs along the brachio-cephalic vein on the left side, and along the vena cava superior on the right side, is then applied against the pericardium, to which it is bound down by the pleura, and, having reached the diaphragm, ramifies in that muscle. It is accompanied by the superior phrenic artery, which is a branch of the internal mammary, and the superior phrenic vein.

The phrenic nerve gives off no branches in the thorax : at a short distance from its origin, it anastomoses with the great sympathetic by a transverse branch : at the lower part of the neck, it sometimes gives off a filament, which forms an anastomotic arch with a branch derived from the fifth and sixth cervical nerves. I have never seen it communicate with the inferior cervical ganglion.

The distribution of this nerve in the diaphragm is curious. Some of its expanded, diverging, and generally very long filaments, run between the pleura and the diaphragm, and enter the muscle from its upper surface ; others pass through the diaphragm, run between it and the peritoneum, and enter the fleshy fibres from below ; they may be traced as far as the costal attachments of the muscle. The right phrenic nerve terminates by a transverse branch which passes behind the vena cava, and anastomoses with certain transverse branches of the left phrenic, before it enters the pillars of the diaphragm, in which it terminates. I have never seen any filament of the phrenic nerve pass either to the œsophagus or to the solar plexus.

The Posterior Deep Cervical Branches.

These are, an *anastomotic branch* (*v*, *fig.* 298) from the cervical plexus to the spinal accessory nerve of Willis (*t*) ; it is of considerable size ; it comes off from the second nerve at the same point as the external occipital nerve, and anastomoses at an acute angle

tendinous arch upon the posterior border of the bone. In this case the clavicular branches are not scattered, but closely aggregated together : the internal branches then pass horizontally inward between the clavicle and the skin as far as the sternum ; and I have even seen a small twig enter the attachments of the pectoralis major. The external branches proceed horizontally outward upon the anterior border of the clavicle as far as the acromion.

* The communication between the phrenic nerve and the fifth cervical nerve occurs in many different modes. Sometimes the phrenic supplies the communicating filament, instead of receiving it ; most commonly the phrenic branch of the fifth arises by a common trunk with the nerve for the sub-clavius muscle, crosses in front of the sub-clavian vein, between it and the cartilage of the first rib, with which it is in contact, and passes behind the internal mammary artery, to join the phrenic nerve at a very acute angle.

with the spinal accessory, between the cervical fasciculi of the splenius and the sterno-mastoid.

Also, *a branch for the trapezius*, which arises from the third nerve, passes obliquely downward and backward to the deep surface of the muscle, and anastomoses with the spinal accessory of Willis, which it re-enforces, and with which it may be traced as far as the lower angle of the muscle.

Lastly, the *branches for the levator anguli scapulæ* and the *rhomboideus;* these are rather small branches, which arise from the back part of the third and fourth cervical nerves, as they emerge from between the transverse processes of the vertebræ, pass obliquely downward and backward, turn round the scalenus posticus in contact with it, and are distributed to the levator anguli scapulæ and the upper part of the rhomboideus. The same branches appear to supply both muscles.

The Anterior Branches of the Fifth, Sixth, Seventh, and Eighth Cervical and First Dorsal Nerves.

These branches are remarkable for their size, in which respect they surpass the preceding, and are almost all equal. On emerging from the inter-vertebral foramina, they come into relation with the two scaleni muscles, which are separated from each other, and sometimes are perforated by them; they give off some very slender filaments to these muscles, and, converging, anastomose together so as to form the *brachial plexus*, from which all the nerves of the upper extremity are derived.

The Brachial Plexus.

The *brachial plexus* (*h*, *fig.* 268) extends obliquely from the lateral and inferior part of the neck to the cavity of the axilla, or, rather, to the inner side of the head of the humerus, where it terminates by dividing into the nerves of the upper extremity; it is formed in the following manner:

The fifth and sixth cervical nerves (5, 6, *fig.* 286) unite at a short distance from the scaleni, and the cord thus formed passes very obliquely downward and outward, and then *bifurcates*.

Again, the eighth cervical (8) and the first dorsal (1) nerves unite immediately after converging from the scaleni, and sometimes even between those muscles; and the common cord passes almost horizontally outward, and *bifurcates* near the head of the humerus.

Between these two anastomotic cords is the seventh cervical nerve (7), which pursues a much longer course than the others, and *bifurcates* on a level with the clavicle; the upper branch of its bifurcation joins the lower branch of the bifurcation of the first-named cord, and its lower branch unites with the upper branch of the second-named cord.

From these several bifurcations and subsequent anastomoses, all of which take place at very acute angles, results the interlacement known as the *brachial plexus*.

The brachial plexus is broad at its upper part, contracted in the middle, and broad again at its lower part, on account of the divergence of its terminating branches; it communicates with the cervical plexus by a considerable branch, which it receives from the fourth cervical nerve, and also by the filament which it gives to the phrenic nerve; it is not so complicated but that the origins of the branches which emanate from it may be traced; I shall take care to do this for each nerve.

Relations.—At its origin it is situated between the scaleni, which cover it for a greater extent below than above. A very strong aponeurosis, which extends over it and the scaleni also, completely isolates it from the surrounding parts.

Lower down, it is situated between the clavicle and sub-clavius muscle on the one hand, and the first rib and upper part of the serratus magnus on the other.

Still lower, it is contained in the cavity of the axilla, separated from the pectoralis major in front by the costo-clavicular aponeurosis, and resting upon the scapulo-humeral articulation behind, from which it is separated by the tendon of the sub-scapularis.

The following are its relations with the *axillary artery:* Between the scaleni and below them, the artery is situated upon the same plane as the brachial plexus, and lies between the plexus and the first rib. Lower down it is placed on the anterior part of the plexus; at the lower extremity of the plexus it passes under the angle of union of the two roots of the median nerve, by which it is embraced; the axillary vein always lies in front of the artery, and therefore has less direct relations with the plexus.

Fig. 286.

The branches of the brachial plexus may be divided into the *collateral* and the *terminal*.

The *terminal branches* are five in number, namely, the *internal cutaneous* (*g*, *fig.* 286) and its *accessory*, the *musculo-cutaneous* (*b*), the *median* (*c*), the *radial* or musculo-spiral (*f*), and the *ulnar* (*d*) nerves.*

The *collateral branches* may be divided into those giv-

* I think it right to class the circumflex nerve among the collateral branches, and not, like most authors, among the terminal branches of the plexus.

en off above the clavicle, namely, the nerve for the *sub-clavius*, those for the *levator angu li scapulæ* and *rhomboideus*, the *posterior thoracic* or *nerve for the serratus magnus*, the *supra-scapular nerve* (*a*) or *nerve for the supra- and infra-spinati muscles*, and the *superior subscapular nerve*; those given off opposite the clavicle, namely, the *thoracic branches*; and those given off in the axilla, namely, the *circumflex nerve* (*c*) and the *sub-scapular branches*, which comprehend the *nerve for the latissimus dorsi*, the *nerve for the teres major*, and the *inferior scapular nerve*.

One branch only, namely, the nerve for the sub-clavius muscle, arises from the front part of the brachial plexus: all the other collateral branches are given off from the back of the plexus.

The Collateral Branches of the Brachial Plexus.

The Branches given off below the Clavicle.

The Nerve for the Sub-clavius Muscle.—This is a small but constant branch, which comes off from the fifth cervical nerve, immediately before its junction with the sixth, passes vertically downward in front of the sub-clavian artery, and then enters perpendicularly into the middle of the sub-clavius muscle.

This small nerve, before reaching the sub-clavius, always gives off a *phrenic branch*, which passes obliquely inward in front of the sub-clavian vein, and anastomoses with the phrenic nerve.

The Nerve for the Levator Anguli Scapulæ.—This branch arises as frequently from the cervical as from the brachial plexus; in the former case, it arises from the fourth cervical nerve, in the latter from the fifth. It arises from the nerve immediately after its exit from the canal of the transverse processes, turns round the scalenus posticus to gain the deep surface of the levator anguli scapulæ, enters the muscle, supplies it with a great number of filaments, and perforates it to reach the rhomboideus, under which it passes. One of its terminating filaments anastomoses with a filament from the proper nerve for the rhomboideus.

The Nerve for the Rhomboideus.—This arises from the fifth cervical nerve, immediately below the preceding; I have seen it arise by a common trunk with the superior branch of origin of the nerve for the serratus magnus; it passes downward and backward between the scalenus posticus and the levator anguli scapulæ, and then beneath the last-mentioned muscle, nearly as far as its scapular attachments, in order to get between the rhomboideus and the ribs; it may be traced as far as the lower part of that muscle. One of its filaments perforates the rhomboideus, and anastomoses in the trapezius with the posterior spinal nerves.

The Nerve for the Serratus Magnus (*Posterior Thoracic Nerve* of authors; *External Respiratory Nerve*, Sir C. Bell).—This branch, which is very remarkable for the length of its course, is derived from the fifth and sixth cervical nerves, immediately after their exit from the canal of the transverse processes; it arises by two roots, which are sometimes equal and sometimes unequal in size; it passes vertically downward behind the brachial plexus and the axillary vessels, in front of the scalenus posticus, reaches the side of the thorax (*c'*, *fig.* 287), between the sub-scapularis and the serratus magnus, runs the whole length of the last-named muscle, and ramifies in its lower portion.

During this course, it gives off a great number of filaments to the muscle: the lowest of these may be traced as far as the lowest digitation. The branch which it gives to the upper part of the muscle is remarkable for its size.

I have seen a branch from the seventh cervical nerve join the external thoracic nerve upon the upper part of the serratus magnus, so that this nerve would then be derived from the fifth, sixth, and seventh cervical nerves.

The Supra-scapular Nerve, or Nerve for the Supra- and Infra-spinati Muscles.—This branch (*a*, *fig.* 286) is given off from the back part of the fifth cervical nerve at its junction with the sixth; it passes obliquely backward, outward, and downward, dips beneath the trapezius, and then under the omo-hyoid, the direction of which it nearly follows, and gradually increases in size as it approaches the coracoid notch of the scapula, and passes by itself under the ligament which converts this notch into a foramen; the supra-scapular artery and vein, which had hitherto been in contact with the nerve, leave it opposite this notch to pass above the ligament, and then join it again in the supra-spinous fossa.

The nerve then runs from before backward in the supra-spinous fossa, protected by a thick fibrous lamella, reaches the free concave border of the spine of the scapula, against which it is held by a fibrous band, is then reflected inward and downward over this concave border to gain the infra-spinous fossa, and immediately divides into two branches, one of which spreads out in the upper part, and the other in the lower part of the infra-spinatus muscle.

During its course through the supra-spinous fossa, the supra-scapular nerve gives off two supra-spinous branches, one of which is detached opposite the coracoid notch, and the other upon the spine of the scapula. They both enter the supra-spinatus muscle.

The supra-scapular nerve is exclusively destined for the supra- and infra-spinati muscles. It gives no filament to the sub-scapularis.

The Superior Sub-scapular Nerve.—This is a very small branch which arises immediately above the clavicle, and passes downward and forward to reach the upper border of the sub-scapularis, and then enters that muscle.

The Branches given off opposite to the Clavicle.

These, which are named the *thoracic branches*,* are generally two in number, one *anterior*, the other *posterior:* they arise from the anterior part of the brachial plexus, opposite the sub-clavius muscle. The *anterior branch*, or *nerve for the pectoralis major*, which is the larger, passes downward and forward between the sub-clavius muscle and the subclavian vein, and divides into two branches: an *external*, or anastomotic, which sometimes arises directly from the brachial plexus, and forms a loop around the axillary artery, by anastomosing with the posterior thoracic branch; and an *internal*, which runs along the deep surface of the pectoralis major, and expands into a great number of remarkably long and slender filaments, which enter the muscle very obliquely, and may be traced as far as its sternal attachments. A very slender filament is constantly found running along the clavicle.

The *posterior thoracic branch*, or *nerve for the pectoralis minor*, passes behind the axillary artery, below which it curves forward, to form, with the external branch of the anterior thoracic, the anastomotic loop of which I have already spoken. From this loop or arch, in forming which the nervous filaments are separated from each other, two sets of branches proceed: the one set runs between the pectoralis major and minor, closely applied to the former muscle, which they then enter, diverging to its lowest part; the others pass beneath the pectoralis minor, and penetrate its deep surface; some of them pass obliquely through this muscle and join the anterior thoracic branches in the pectoralis major.

The Branches given off below the Clavicle.

The Axillary or Circumflex Nerve.—This is no less remarkable for its great size, which has led some anatomists to regard it as a terminal branch of the brachial plexus, than for its reflected course: it comes off from the back of the plexus, behind the musculo-spiral nerve, or, rather, the circumflex and musculo-spiral nerves (*e* and *f*, *fig.* 286) appear to be the two divisions of a trunk formed by filaments from the five branches of the brachial plexus.

Immediately after its origin, the circumflex nerve passes downward and outward (*g*, *fig.* 288) in front of the sub-scapularis, which separates it from the shoulder-joint, turns obliquely round the lower border of that muscle, round the back part of the articulation, and, lastly, round the surgical neck of the humerus, is then reflected upward, so as to describe a curve with the concavity turned in the same direction, and terminates by ramifying in the deltoid.

During this curved course, the circumflex nerve, accompanied by the posterior circumflex vessels, passes at first between the sub-scapularis and the teres major, then below the teres minor, on the outer side of the long head of the triceps (*i. e.*, next to the bone), and then lies in contact with the deep surface of the deltoid, against which it is held by a very dense layer of fascia.

The relation of the circumflex nerve to the articulation explains the possible occurrence of laceration of this nerve in luxations of the humerus downward.

The *collateral branches of the circumflex nerve* are three in number. One branch almost always goes to the sub-scapularis. I have already said that the sub-scapular nerves might be regarded as branches of the circumflex.

As it turns round the lower border of the sub-scapularis, the circumflex gives off a *branch for the teres minor* and the *cutaneous branch of the shoulder*.

The *nerve for the teres minor* enters that muscle by its lower border; it almost always arises by a common trunk with a deltoid branch, which runs upward and backward to supply the back part of the deltoid muscle.

The *cutaneous nerve of the shoulder* frequently arises by a common trunk with the two preceding, and, in this case, the circumflex nerve appears to bifurcate; it passes under the posterior border of the deltoid, then lies in contact with the skin covering the back part of the top of the shoulder, and divides into diverging branches, some ascending, others descending, and others running horizontally. A second, and sometimes a third cutaneous branch perforates the fleshy fibres of the deltoid, and is distributed to the corresponding skin.

The *terminal* or *deltoid branches of the circumflex nerve* are given off as that nerve is turning round the neck of the humerus, in which situation it divides into several diverging branches, the superior of which *ascends*, and appears like the continuation of the nerve, while the others *descend*, and may be traced as far as the insertion of the muscle into the humerus.

* The anterior thoracic nerves of those who name the nerve for the serratus magnus the posterior thoracic.

The Sub-scapular Nerves.—The *nerve for the latissimus dorsi* is the largest of the nerves generally described as the *sub-scapular;* it comes off at an acute angle from the inside of the circumflex nerve, and descends vertically in the midst of the cellular tissue of the axilla, between the sub-scapularis and serratus magnus, parallel to the external thoracic nerve, which it greatly resembles in size and direction as well as in its length; it then passes in front of the latissimus dorsi, reaches its outer border, and may be traced down to the lower part of that muscle.

The *nerve for the teres major* arises at a very acute angle from the preceding nerve, to the inner side of which it runs; it passes to the sub-scapularis, turns round its outer border, and enters the anterior surface of the teres major by a great number of filaments.

The *inferior sub-scapular nerve* (*l*, *fig.* 288) is sometimes multiple, and presents many varieties in its origin and number. Thus, it sometimes curves directly from the brachial plexus; sometimes from a common trunk with the circumflex nerve. Again, it often arises by a common trunk with the nerve for the teres major. Whatever be its origin, and whether it be single or multiple, it enters immediately into the sub-scapularis, and terminates there.

We have seen that a small branch given off from the brachial plexus above the clavicle, the *superior sub-scapular nerve*, enters the same muscle at its upper border.

The Terminal Branches of the Brachial Plexus.

The Internal Cutaneous Nerve and its Accessory.

Fig. 287.

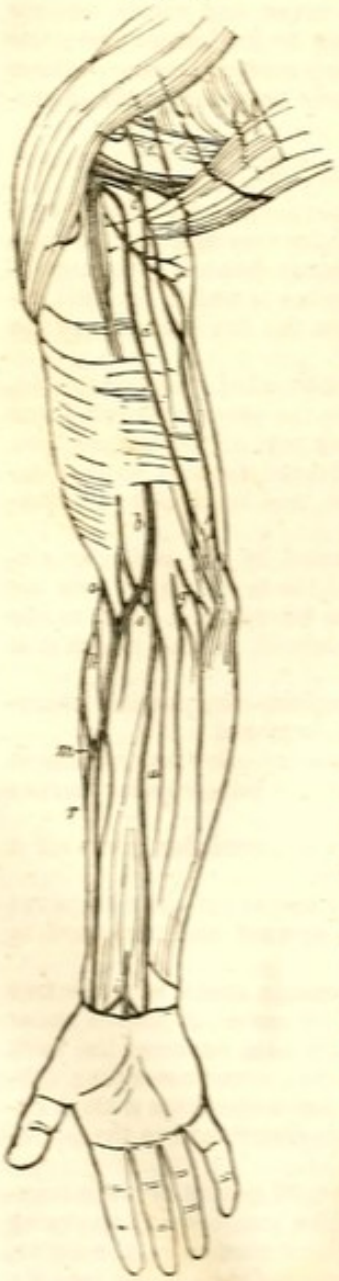

The *internal cutaneous nerve* (*g*, *fig.* 286), the most internal and the smallest of the terminal branches of the brachial plexus, arises by a common trunk with the ulnar nerve (*d*) and the internal root of the median (*c*): concealed at first by the axillary artery, it descends vertically (*a*, *fig.* 288) to the inner side of the median nerve, and in front of the basilic vein: at the upper part of its course it lies beneath the fascia, but it becomes sub-cutaneous at the same time as the basilic vein (*b*, *fig.* 287), and is then separated from the median nerve by the brachial aponeurosis; at the middle of the arm, it divides into two terminal branches, an *external, anterior* or *ulnar*, and an *internal, posterior* or *epitrochlear*. The internal cutaneous gives off only one branch during its course along the arm, namely, a *cutaneous branch*, which varies in size as well as in the situation at which it is given off: this cutaneous branch arises in the cavity of the axilla, often anastomoses with an intercostal nerve, is applied against the skin on the inner aspect of the arm, and may be traced as far as the elbow.*

Terminal Branches.—The *anterior, external* or *ulnar branch*, which is the larger, continues in the vertical direction of the trunk of the nerve, and divides into two branches, which descend in front of the elbow-joint, sometimes before, and sometimes behind the median basilic vein (*e*), and again subdivide into a great number of filaments which diverge, and are arranged in the following manner: the internal filaments pass obliquely downward, inward, and backward, crossing the ulnar vein (*u*), and then the ulna, and supply the skin covering the inner and back part of the forearm; they can be traced nearly as far as the region of the carpus: the external filament, which might be called median, because it follows the median vein, descends vertically, and may be traced as far as the upper part of the palm of the hand; one of these filaments always anastomoses with a twig from the ulnar nerve at the lower part of the forearm.

The *posterior, internal* or *epitrochlear branch* (*g*), descends vertically behind the median basilic vein, in front of the epitrochlea, and then below it, so as to embrace it in a sort of loop; it then passes very obliquely downward and backward, crosses the ulna below the olecranon, gains the dorsal aspect of the forearm, and runs vertically (*a*, *fig.* 289) down to the wrist. Around the epitrochlea, this internal branch gives off several branches, which ramify upon the skin that covers the inner side of the elbow-joint: one of these branches is reflected upward between the epitrochlea and the olecranon, and anastomoses with the accessory nerve of the internal cutaneous.

* I have always found a remarkably long and slender filament arising from the internal cutaneous nerve at the upper part of the arm; it runs along that nerve, passes beneath the basilic vein, and then lies in contact with the fascia, which it perforates near the epitrochlea, and is lost upon the synovial membrane of the elbow-joint.

Frequently, before reaching the epitrochlea, this branch has already given off a twig which anastomoses with the same nerve.

Summary.—The internal cutaneous nerve, then, is exclusively intended for the skin. It only gives one small branch to the arm: its other divisions are intended for the forearm. One of them belongs to the dorsal, and the other to the internal aspect.

The Accessory Nerve of the Internal Cutaneous.—I have applied this term to a small branch (cutaneus minor internus, *Wrisberg*), which it is difficult to discover, and which would be more properly classed among the collateral than the terminal branches of the brachial plexus: it arises above and sometimes below the clavicle, from the back part of the nervous cord formed by the junction of the eighth cervical and first dorsal nerves: it passes downward upon the sides of the thorax, and divides into two branches, an *external* and an *internal*.

The *external branch* (*a'*, *fig.* 287), which is the smaller one, passes vertically downward, and crosses the conjoined tendons of the teres major and latissimus dorsi at right angles; it lies in contact with the skin covering the inner and back part of the arm, and may be traced as low as the elbow.

The *internal branch* (*c*) anastomoses with the second intercostal nerve, descends vertically, crossing the conjoined tendons of the latissimus dorsi and teres major, becomes applied to the skin, and divides into several very slender filaments, which correspond to the internal, anterior, and posterior regions of the arm, and may be traced as far as the region of the elbow; one of these filaments anastomoses with the internal cutaneous.*

The Musculo-cutaneous Nerve.

The *musculo-cutaneous nerve* (*b*, *fig.* 286), the most external of the terminal branches of the brachial plexus, and, with the exception of the internal cutaneous, the smallest, arises by a common trunk with the external root of the median nerve (*c*), passes downward and outward, in front of the humeral insertion of the sub-scapularis, and on the inner side of the coraco-brachialis, which is perforated by it, and is therefore called the *perforated muscle of Casserius*.† After emerging from the muscle, through which it passes very obliquely,‡ the musculo-cutaneous nerve (*h*, *fig.* 288) is situated between the biceps and the brachialis anticus, continues its oblique course, escapes from beneath the outer border of the tendon of the biceps, and then becomes sub-cutaneous.

During its course along the arm it gives off the following branches

The *branches for the coraco-brachialis* are two in number: one *superior*, which enters the upper part of this muscle, and is then lost in the short head of the biceps; the other *inferior*, which, in some subjects, after having furnished a certain number of filaments to the coraco-brachialis, becomes applied to the trunk of the musculo-cutaneous nerve itself.

The *branches for the biceps* are very numerous: not uncommonly they arise by a common trunk, which then appears to result from the bifurcation of the musculo-cutaneous. One of these branches perforates the biceps, and passes transversely outward to reach the elbow-joint, to which it is distributed.

The *branches for the brachialis anticus* almost always arise by a large common trunk which appears to result from a farther bifurcation of the nerve, already diminished one half, after it has supplied the branches for the biceps. While these last-named branches enter the posterior surface of the corresponding muscle, the branches for the brachialis anticus penetrate that muscle by its anterior surface.

After having given off all these muscular branches, the musculo-cutaneous nerve, reduced to a fourth or a fifth of its original size, is distributed entirely to the skin; it passes vertically downward in front of the elbow-joint, behind the median cephalic vein (*a*, *fig.* 287), and divides into two terminal branches, of which the *internal* (*h*) runs along the inner, and the *external* along the outer side of the radial vein.

These two branches, during their course along the forearm, lie between the fascia of the forearm and the superficial fascia; they gradually diminish in size as they give off their filaments to the skin, and terminate in the following manner:

The *external branch* passes to the dorsal surface of the forearm, and may be traced as far as the skin which covers the carpus.

The *internal branch* has a more extensive distribution; it anastomoses with a branch of the radial nerve at the lower part of the forearm, and gives off a deep or articular branch, which divides into several twigs that surround the radial artery. One of these twigs expands into a number of filaments which enter the fore part of the radio-carpal articulation; the others accompany the radial artery in its oblique course upon the outer side of the carpus, and then spread out to terminate on the back part of the synovial membrane of the wrist-joint. After having given off this very remarkable articular branch,◊ the internal terminal division of the musculo-cutaneous nerve passes in front

* [And with the internal cutaneous branch of the musculo-spiral nerve.]

† [The nerve is also called *perforans Casserii*.]

‡ Not unfrequently the nerve does not perforate the coraco-brachialis. [It sometimes has an anastomosis with the median nerve after emerging from the coraco-brachialis.]

◊ In one subject, the articular filaments had some gangliform enlargements on their sides precisely similar

of the tendons of the extensor brevis pollicis and abductor longus pollicis, in front of and more superficially than the corresponding branch of the radial nerve, and then divides into several twigs, which are intended for the skin of the thenar eminence. One of these branches, which runs along the outer side of that eminence, may be traced into the skin upon the first phalanx of the thumb.

Summary.—The musculo-cutaneous nerve, then, supplies certain *muscular branches*, which belong exclusively to the coraco-brachialis, the biceps, and the brachialis anticus; the section of this nerve would, therefore, destroy the power of flexing the forearm: certain *cutaneous branches* to the skin on the outer side of the forearm and hand; and, lastly, some *articular branches* to the elbow and to the wrist.

The Median Nerve.

The *median nerve* (*c*, *fig.* 286), one of the terminal branches of the brachial plexus, arises from the plexus by two very distinct roots between the musculo-cutaneous (*b*) on the outer side, and the ulnar nerve (*d*) on the inner.* The internal root arises from a nervous cord which is common to it, to the ulnar, and to the internal cutaneous (*g*). The external root arises from a cord common to it and to the musculo-cutaneous. The axillary artery passes between these two roots.

The trunk resulting from the union of these two roots is situated on the inner side of the axillary artery; it is at first grooved to receive the inner half of the artery, but it soon forms a rounded cord, proceeds vertically downward (*c*, *fig.* 288), gains the middle and fore part of the elbow-joint, dips between the muscles on the anterior region of the forearm (*d*), and passes behind the annular ligament to enter the palm of the hand (*r*), where it terminates by dividing into six branches. We shall examine it in the arm, the forearm, and the hand.

Fig. 288.

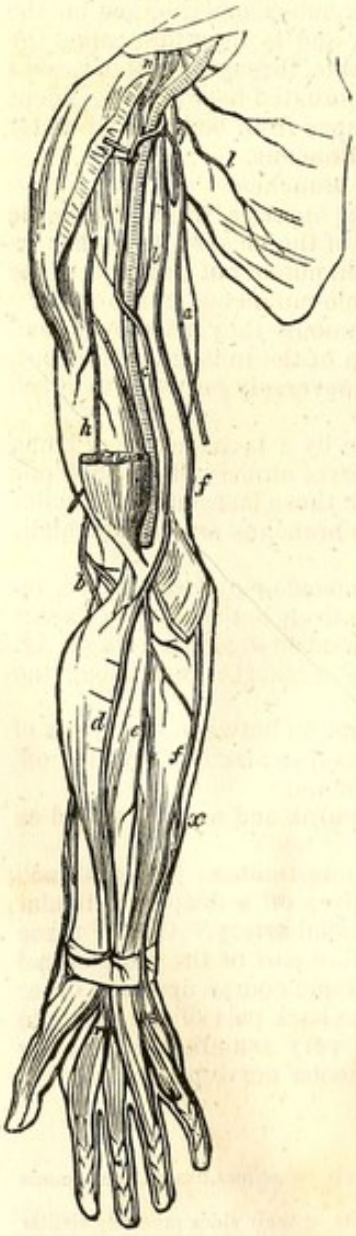

In the Arm.

The median nerve (*c*), which is straight and vertical, and the satellite nerve of the brachial artery, passes somewhat obliquely downward, forward, and outward, to the middle and fore part of the elbow-joint.

Relations.—On the *inner side* it is sub-aponeurotic, so that when the arm is held away from the side, and the forearm is extended upon the arm, it projects below the skin like a tense cord, which is very distinctly seen in emaciated subjects.

On the *outside*, it corresponds at first to the brachialis anticus, and is then received in the sort of groove formed between the inner border of the biceps and the brachialis anticus.

In *front*, it is covered by the inner border of the biceps, excepting in emaciated subjects.

Behind, it is in relation with the ulnar nerve (*f*), and then with the brachialis anticus.

Its *relations with the brachial artery* are of the greatest importance, in reference to the application of a ligature to that vessel. The nerve is at first situated to the outer or radial side of the axillary artery, but soon passes in front of the vessel, and then it crosses over slightly, so that at the bend of the elbow it is situated about two lines to the inner or ulnar side of the artery. This last relation is not constant: I have seen the nerve on the outer side of the artery at the bend of the elbow.

The following are its *relations with the other nerves:* the internal cutaneous nerve runs along its inner side, at first immediately in contact with it, and then separated from it by the fascia of the arm.

The ulnar nerve runs behind it in the upper third of the arm, and is then separated from it, so that the two nerves bound the sides of a triangular interval, the base of which is below and the apex above.

The median nerve does not give any branch in the arm.†

to those which are met with on the cutaneous nerves in the palm of the hand; the articular filaments, moreover, have almost always the grayish aspect of the nerves of organic life.

* These two roots of the median nerve, when united to the musculo-cutaneous and the ulnar, represent very nearly a capital M. Not unfrequently there is a third internal root for the median nerve.

† [Except, occasionally, an anastomotic branch to the musculo-cutaneous, after the latter has emerged from the coraco-brachialis.]

In the Forearm.

The median nerve, like the brachial artery, to the inner side of which it is generally situated, passes beneath the tendinous expansion of the biceps, and is separated from the elbow-joint by the brachialis anticus.

It almost always perforates the pronator teres in such a manner as to leave only a very small tongue of fleshy fibres behind it;* it then passes (*d*, *fig.* 288) between the flexor sublimis and flexor profundus digitorum, opposite the cellular interval between the latter muscle and the flexor longus pollicis: at the lower part of the forearm it runs along the outer border of the flexor sublimis, where it might be easily exposed between the tendon of the palmaris longus on the inside, and of the flexor carpi radialis on the outside. I have seen this nerve perforate the upper part of the flexor sublimis, which formed a sheath for it.

Branches.—These are muscular, excepting the palmar cutaneous, which arises at the lower part of the forearm: they supply all the muscles of the anterior region of the forearm except a part of the flexor profundus, and the whole of the flexor carpi ulnaris, which receive branches from the ulnar nerve. Lastly, with the exception of the palmar cutaneous, the branches arise near the bend of the elbow.

The *branch for the pronator teres* comes off from the anterior part of the median nerve, a little above the elbow-joint, and passes downward to enter the substance of the muscle. It gives off several *articular filaments*, which dip from before backward, around the termination of the brachial artery and the commencement of the radial and ulnar arteries, form loops with their concavities turned upward in the angle of bifurcation of the brachial, and then enter the articulation.

The other collateral branches of the median in the forearm arise from its posterior aspect: they are the *branch for the superficial layer of muscles*, which arises opposite the elbow-joint, and then divides successively into several others, which enter the *pronator teres*, the *flexor carpi radialis*, the *palmaris longus*, and the *flexor sublimis*. The filaments for the flexor sublimis are remarkably slender, and are reflected upward below the epitrochlea: they belong to the upper part only of this muscle, which is also supplied by two or three other branches, given off in succession from the median, a little below the bend of the elbow.

The *branch for the deep layer of muscles* is a large trunk, which soon divides into several branches, viz., one *external*, for the *flexor longus pollicis*, the upper extremity of which it enters; two *internal*, which enter the *flexor profundus*, but only supply its inner half, the other half receiving its nerves from the ulnar;† and a *middle* branch, the *interosseous nerve* (*e*), which requires a particular description. It passes vertically downward, in front of the interosseous ligament, between the flexor profundus and the flexor longus pollicis, to both of which it gives several filaments; having reached the upper borders of the pronator quadratus, it passes behind that muscle and divides into a great number of filaments, some of which penetrate the muscle from behind, while others descend to gain the lower part of the muscle. I have seen the interosseous nerve perforate the interosseous ligament, run a very short distance upon its posterior surface, then pass through it again, and ramify in the pronator muscle.

The *palmar cutaneous branch* (*i*, *fig.* 287) comes off from the median nerve opposite the junction of the three upper fourths with the lower fourth of the forearm, runs along the median nerve, and divides into two branches, which perforate the fascia of the forearm immediately above the annular ligament. The *external branch* is the smaller, and crosses obliquely over the tendon of the flexor carpi radialis, and terminates in the skin upon the ball of the thumb;‡ the *internal branch*, which is larger, descends vertically in front of the annular ligament and beneath the skin, from which it is separated by a layer of adipose tissue, and is lost in the palm of the hand, much sooner than might be expected from its size;◊ it can scarcely be traced as far as the middle of the palm.

In the Hand.

The median nerve, while passing behind the annular ligament of the carpus, becomes considerably wider and flattened; it might even be said to increase gradually in size. Immediately after it has passed below the ligament, still flattened out, it divides (*r*) into two branches, one *internal*, the other *external*, which are themselves subdivided; the internal into two, and the external into four branches, so that in all there are six terminal branches.

* In one case, in which the humeral attachments of the pronator teres were as high as those of the supinator longus, the median nerve passed through the highest attachments of the pronator teres, and was situated between the brachialis anticus and that muscle, which also covered it at the bend of the elbow; in this same case, the brachial artery divided into the radial and ulnar at the middle of the arm; and the ulnar artery applied against the nerve had the same relations as the brachial artery in ordinary cases.

† All the deep branches may be traced as far as the periosteum of the bones of the forearm. [Some of them have been seen to communicate with filaments of the ulnar nerve.]

‡ [This branch anastomoses with the terminal cutaneous division of the musculo-spiral or radial nerve.]

◊ This sudden mode of termination is common to all nerves of sensation, which are often lost almost immediately in the skin; the nerves of motion, on the other hand, run a very long course as filaments before they terminate in the muscles.

The *terminal branches* of the median nerve. Of these one only is muscular, and belongs to the muscles of the ball of the thumb; the other five are intended for the integuments of the fingers, of which they form the palmar collateral nerves.

The *branch for the muscles of the ball of the thumb* is a recurrent nerve; it arises from the front of the median, passes upward and outward, forming a horizontal curve with the concavity turned upward, perforates the superficial layers of the flexor brevis, immediately gives off a descending branch to that muscle, and, continuing to ascend itself, is divided almost equally between the abductor brevis and the opponens pollicis.

*The External Collateral Branch of the Thumb.**—This nerve passes obliquely downward and outward, on the inner side of the tendon of the flexor longus pollicis, crosses the metacarpo-phalangal articulation, to gain the external border of the anterior surface of the thumb, and, running along the outer side of the tendon of the long flexor, arrives at the ungual phalanx. On this phalanx, it divides into two branches, a *dorsal* or *ungual*, properly so called, which turns round the side of the phalanx, anastomoses with the dorsal collateral branches of the radial nerve, and is distributed to the dermis beneath the nail; and a *palmar*, which is lost in the skin covering the pulp of the thumb. Some of these latter filaments turn round the tip of the phalanx, and are distributed to the skin beneath the nail. None of the filaments of the external collateral branch anastomose with those of the internal collateral.

The *internal collateral branch for the thumb* is less oblique in its course and larger than the preceding; it runs along the first interosseous space in front of the adductor pollicis, and reaches the inner side of the anterior surface of the thumb, along the tendon of the long flexor, and terminates like the preceding branch. This branch gives off a twig to the adductor pollicis.

The *external collateral branch for the index finger* sometimes arises by a common trunk with the preceding; it runs along the first interosseous space in front of the adductor pollicis, on the outer border of the first lumbricalis muscle, to which it gives a filament, and then divides into two branches, a *dorsal* and a *palmar:* the *dorsal branch*, which is the smaller, passes backward and downward, along the outer border of the first phalanx, unites with the dorsal collateral branch derived from the radial nerve, gains the posterior surface of the second phalanx, and terminates upon the third, near the nail. The *palmar branch*, which forms the true continuation of the trunk of the nerve, is arranged like the corresponding nerve of the thumb, and does not anastomose with the internal collateral branch.

The *common trunk of the internal collateral branch of the index finger*, and *external collateral branch of the middle finger*, passes vertically downward, in front of the second interosseous space, at the middle of which it divides into two branches, one of which forms the *internal collateral branch of the index finger*, and the other the *external collateral branch of the middle finger*. These collateral nerves, like the preceding, divide into a dorsal and a palmar branch, the latter of which again subdivides into a sub-ungual branch and a branch for the pulp of the finger.

The common trunk of these two collateral nerves, before bifurcating, gives off a twig to the second lumbricalis.

The *common trunk of the internal collateral branch of the middle finger*, and *external collateral branch of the ring finger*, passes somewhat obliquely inward, in front of the third interosseous space, and is distributed in the same way as the preceding branches; before bifurcating, it sometimes gives a twig to the third lumbricalis; it receives an anastomotic filament from the ulnar nerve. The bifurcation of this sixth branch takes place a little below the metacarpo-phalangal articulations.

Relations.—The following are the relations of the palmar and digital portions of the median nerve:

Behind the anterior annular ligament of the carpus, the median nerve is situated on the outer side of the tendons of the flexor sublimis and in front of those of the flexor profundus: like the tendons among which it is placed, it is at first covered by the synovial membrane in front and behind.

In the *palm of the hand*, the median nerve is covered by the palmar fascia, and is situated in front of all the flexor tendons. The superficial palmar arch lies in front of it, and crosses at right angles over its three internal branches.

The *collateral nerves of the fingers* accompany the collateral vessels, and pass with them from the palm of the hand opposite the intervals between the metacarpo-phalangal articulations. Like the vessels which run along their outer side, these nerves occupy the borders of the palmar aspect of the fingers, one on each side of the tendinous groove.

Summary.—From what has been stated, it follows, then, that the median nerve gives off no branch in the arm;† that, in the forearm, it gives no nerve to the skin, but supplies all the muscles of the anterior region, excepting the flexor carpi ulnaris and the inner half of the flexor profundus, which we shall see are supplied by the ulnar; and, lastly, that, in the hand, it supplies the cutaneous nerves of the palm, the external and

* I have seen it arise after the third branch, and upon a plane anterior to that branch, the origin of which it then crossed.

† See note, p. 786.

internal collateral nerves of the thumb, index finger, and middle fingers, and the external collateral nerve of the ring finger, and also the muscular nerves of the ball of the thumb and the nerves of the two outer lumbricales, and sometimes that of the third lumbricalis.

The Ulnar Nerve.

The *ulnar nerve* (*d*, *fig.* 286), a little smaller than the preceding, behind which it is situated, arises by a trunk which is common to it, to the internal root of the median nerve (*c*), and to the internal cutaneous nerve (*g*); it passes vertically downward behind, and at first in contact with the median, but soon leaves that nerve, and runs somewhat backward (*f*, *fig.* 288), while the median is directed forward and outward; it perforates the upper fibres of the internal head of the triceps, and enters the sheath of that muscle, behind the internal inter-muscular septum. It thus gains the groove between the inner condyle of the humerus and the olecranon, passes between the two origins of the flexor carpi ulnaris, and is reflected from behind forward in this groove, and then upon the inner side of the coronoid process: having thus reached the anterior aspect of the forearm, it passes vertically downward (*f*) between the flexor carpi ulnaris and the flexor profundus, and gains the palm of the hand (*s*), where it divides into its terminal branches. As with the median nerve, we shall examine the ulnar in succession in the arm, the forearm, and the hand.

In the Arm.

The most important relation of this nerve (*f*) in the arm is that at its upper part with the median nerve and brachial artery. It runs along the inner side of the artery, while the median nerve is situated in front of the vessel, or, rather, the artery is situated between the median and ulnar nerves, so that it may be exposed immediately below the axilla, by separating these two nerves.

The ulnar nerve gives off no branch in the arm; the error of those who have stated the contrary has arisen from the fact that the branch given from the musculo-spiral nerve to the internal portion of the triceps lies in contact with the ulnar nerve for a great part of its extent, so that it would seem at first sight to come off from it.

The Forearm.

The ulnar nerve in the forearm (*f*) is at first covered by the fleshy belly of the flexor carpi ulnaris, which separates it from the skin; it becomes sub-aponeurotic below, where the fleshy fibres of that muscle cease, and is found between the tendon of the flexor carpi ulnaris on its inner side, and those of the flexor sublimis on its outer side.

Its relation with the ulnar artery is remarkable. This vessel describes a curve so as to reach the outer or radial side of the nerve; but the nerve and artery are in contact in the lower third only of the forearm.

The *branches* of this nerve in the forearm are somewhat numerous. Between the internal condyle and the olecranon, the ulnar nerve gives several very delicate *articular filaments*, which pass into the elbow-joint; it also gives off branches for the *flexor carpi ulnaris*; one of which is very large, and may be traced as far as the lower part of the fleshy belly of the muscle.

After its reflection, the ulnar nerve gives a branch to the *flexor profundus digitorum*, subdivides, and enters the substance of that muscle. Its divisions run upon the anterior surface of the muscle before penetrating it. This branch is intended for the two inner portions of the flexor profundus, the two outer portions receiving their filaments from the median nerve.*

At the middle of the forearm, a small, long, and slender branch is given off from the anterior part of the ulnar nerve, and divides into two filaments, one of which follows the ulnar artery (*filament of the ulnar artery*), while the other perforates the fascia of the forearm, and anastomoses with the internal cutaneous nerve (*anastomotic filament*).

The *internal dorsal nerve of the hand* (*x*) is the largest of the branches of the ulnar nerve, so that it might be regarded as a terminal branch of that nerve; it is exclusively intended for the skin of the dorsal region of the hand. It comes off opposite the junction of the two upper thirds with the lower third of the forearm, passes obliquely downward, backward, and inward between the ulna, over which it crosses, and the flexor carpi ulnaris, and emerges (*x*, *fig.* 289) from below the tendon of that muscle, a very short distance above the lower end of the ulna. It then descends vertically between the skin and that part of the bone, runs along the inner side of the carpus, and divides into two *dorsal branches*, an *internal* and an *external*.

The *internal dorsal branch* is the smaller; it runs along the ulnar border of the fifth metacarpal bone, and along the internal or ulnar side of the dorsal region of the little finger, of which it forms the *internal collateral dorsal nerve*.

The *external dorsal branch* is much larger; it first gives off a small *anastomotic twig*, which crosses obliquely over the metacarpal bone, and anastomoses with a correspond-

* [The ulnar may communicate in this position with filaments of the anterior interosseous.]

ingly oblique branch from the radial nerve, opposite the lower part of the second interosseous space. It then descends vertically along the fourth interosseous space, and divides into two secondary branches, which again subdivide to form the *dorsal collateral* nerves, in the following manner: one forms the *external collateral nerve of the little finger*, and the *internal collateral nerve of the ring finger*; and the other the *external collateral nerve of the ring finger*, and the *internal collateral nerve of the middle finger.**

In the Hand.

The ulnar nerve enters the palm of the hand (*s, fig.* 288), not by passing behind the anterior annular ligament, but in a special sheath, which is common to it and to the ulnar artery, is situated on the inner side of the annular ligament, and has the pisiform bone to its inner side, and unciform bone to its outer side. This sheath is completed behind by the ligament which extends from the pisiform to the unciform bone, and in front by a sort of annular ligament. The nerve is covered by a synovial membrane during its passage through this sheath.

As soon as it leaves this sheath, the ulnar nerve divides into two *terminal branches*, the one *superficial*, and the other *deep*.

The *superficial terminal branch*, or *trunk of the palmar collateral nerves of the fingers*, immediately gives off a branch which passes beneath the flexor brevis digiti minimi, penetrates the deep surface of that muscle, and immediately divides into two other branches, an *internal* and an *external*. The *internal* is the smaller branch; it crosses over the muscles of the ball of the little finger, beneath the palmaris brevis, when it exists, gains the inner side of the anterior surface of the little finger, and forms its *internal palmar collateral nerve*.† The *external* is larger; it sends a communicating twig to the median nerve, and bifurcates to form the *external palmar collateral nerve of the little finger*, and the *internal palmar collateral nerve of the ring finger*.

The *deep terminal* or *muscular branch* is somewhat larger than the superficial branch. Immediately after its origin, it is reflected outward below the unciform bone, perforates the flexor brevis digiti minimi, and passes deeply into the palm of the hand, so that it cannot be exposed without dividing all the tendons of the palmar region.

This branch describes a transverse curve or arch with the concavity directed upward, in front of the metacarpal bones, corresponding to and situated within the curve described by the deep palmar arterial arch, which crosses it at an acute angle.

No branch arises from the concavity of this nerve, but from its convexity a great number are given off, in the following order:

During the passage of the nerve between the pisiform and unciform bones, three branches for *the three muscles of the hypothenar eminence*.

Two very remarkable descending filaments, which supply the *palmar interossei* of the *third* and *fourth* spaces, and end in the *third* and *fourth lumbricales*. The first and second lumbricales, and frequently the third also, are supplied by the median nerve.

Three *perforating branches* pass backward between the upper ends of the metacarpal bones, give some branches to the palmar interossei, proceed along the cellular interval between the palmar and dorsal interossei, supply the last-mentioned muscles, and terminate by anastomosing with the dorsal collateral branches of the ulnar and radial nerves.

We may regard as terminal divisions of the deep branch, two branches, which are given to the two portions of the adductor pollicis,‡ and a branch for the *first dorsal interosseous muscle*, from which a filament is given off that enters the adductor pollicis near its lower border.

Summary.—From what has been stated, it appears that the ulnar nerve gives off no branch in the arm; that in the forearm it supplies some articular branches to the elbow-joint, certain muscular branches for the flexor carpi ulnaris, and the inner half of the flexor profundus, and a cutaneous filament which anastomoses with the internal cutaneous nerve; that it gives off to the hand a *dorsal cutaneous branch*, from which the dorsal collateral nerves of the little and ring fingers, and the internal dorsal collateral of the middle finger, proceed; a *palmar cutaneous division*, which supplies the palmar collateral nerves of the little finger, and the internal palmar collateral nerve of the ring finger; and a *muscular division*, which is distributed to the three muscles of the hypothenar eminence, to all the interossei, among which we may include the adductor pollicis,◊ and to the two internal lumbricales.

* [This latter branch often anastomoses with the dorsal cutaneous branch of the radial nerve.]

† I have observed that it supplies the palmaris brevis, when that muscle exists.

‡ The reader must here be reminded, that I have regarded all that portion of the flexor brevis pollicis (of authors) which is situated to the inner side of the tendon of the flexor longus pollicis, or, in other words, all that portion which is attached to the internal sesamoid bone, as belonging to the adductor pollicis. (See MYOLOGY, p. 190.) The distribution of the nerves favours this view; for the flexor brevis is supplied by the median nerve, while the two portions of the adductor receive their nerves from the ulnar. [This general statement is not quite correct; the outer portion of the adductor (the inner head of the flexor brevis of authors generally) also receives a small branch from the median nerve (see p. 787; also Swan and Ellis).]

◊ It is perfectly rational to consider the adductor pollicis as the first palmar interosseous muscle, which, for the sake of increased power of adduction, is attached to the third metacarpal bone.

Musculo-spiral Nerve.

The *musculo-spiral* or *radial nerve*, which is the largest of the terminal divisions of the brachial plexus, is intended for the triceps extensor cubiti, for the muscles of the posterior and external region of the forearm, and for the skin of the arm, the forearm, and dorsal region of the hand.

It arises (*f*, *fig.* 286) from all the five nerves of which the brachial plexus is composed, by a trunk which is common to it and to the circumflex nerve, and it issues from the plexus behind the ulnar nerve, to which it is closely applied. Immediately after its origin, it passes downward, backward, and outward (*b*, *fig.* 288), in front of the conjoined tendons of the latissimus dorsi and teres major, to gain the groove of torsion or spiral groove of the humerus, into which it enters, passing between the long head of the triceps and the bone, then between the external head and the bone; it traverses the whole extent of this groove, and is in relation with the profunda humeri artery and vein. Leaving this groove, opposite the junction of the two upper thirds with the lower third of the humerus, it lies on the external and anterior aspect of the arm, descends vertically between the supinator longus and brachialis anticus, and next between the brachialis anticus and extensor carpi radialis longior, crosses the elbow-joint (at *b*), passing in front of the outer condyle of the humerus and the upper extremity of the radius, and then divides into two terminal branches.

Collateral Branches of the Musculo-spiral Nerve.

During its winding and spiral course along the arm, this nerve gives off a great number of collateral branches in the following order:

Branches given off by the Musculo-spiral Nerve before it enters the Spiral Groove.—The first is the *internal cutaneous branch* (*f'*, *fig.* 287) of the musculo-spiral, which is subaponeurotic at its commencement, but perforates the fascia, becomes applied to the skin, and divides into two filaments, which pass obliquely backward, and may be traced as far as the olecranon.*

There are several considerable *branches to the long head of the triceps*; the highest of which is recurrent, and may be traced as far as the scapular attachments of the muscle. A very large descending branch may be traced to the olecranon.

There is *a branch for the internal head of the triceps*, one division of which is rather large, and runs along the inner border of the humerus in front of the muscle, which it does not enter until it approaches the elbow.

Branches given off by the Musculo-spiral after leaving the Spiral Groove.—These are the *external cutaneous branch of the musculo-spiral*, a very large branch which perforates the muscular fibres of the triceps and the brachial aponeurosis, then lies in immediate contact with the skin of the external region of the arm, passes obliquely backward, and divides into a great number of filaments, which supply the skin of the posterior region of the forearm, and may be traced down to the carpus.

The *branch for the external head of the triceps and for the anconeus*, which is remarkable for its length, descends vertically between the external and long heads of the triceps, supplies the former of these, enters the anconeus, and may be traced as far as the lower part of that muscle.

All these branches are remarkable for being given off at nearly the same height; that is to say, near the shoulder-joint, and for accompanying the trunk of the musculo-spiral nerve.

Branches given off by the Musculo-spiral Nerve in the Forearm.—These are the branches for the *supinator longus*, and those for the *extensor carpi radialis longior*, which enter the inner surface of the upper part of those muscles.

Terminal Branches of the Musculo-spiral Nerve.

Reduced to one half, or less, of its original size, by the successive emission of the preceding branches, the musculo-spiral or radial nerve divides in front of the elbow (*b*, *fig.* 288) into two unequal branches, the one *deep* or *muscular*, the other *superficial* or *digital*.

The *deep* or *muscular division* of the musculo-spiral nerve, or the *posterior interosseous*, is larger than the superficial division; it immediately gives off a branch which passes vertically in front of the extensor carpi radialis brevior, and soon dips into that muscle; the nerve then becomes flattened, perforates the supinator brevis, and pursues a very oblique and spiral course around the radius and within that muscle, to which it gives branches (*branches for the supinator brevis*): it then emerges from the posterior aspect of this muscle, and immediately divides into a great number of diverging branches, some of which are intended for the superficial, and the others for the deep layer of muscles on the posterior region of the forearm.

The branches given to the superficial layer are, those *for the extensor communis digitorum*, which are very numerous and diverging, the superior being also recurrent; the *branch for the extensor proprius digiti minimi*; and *the branch for the extensor carpi ul-*

* [Anastomosing with the accessory of the internal cutaneous.]

naris: all these branches arise by a common trunk, and enter the deep surface of the muscles.

The *branches for the deep layer* also arise by a common trunk (*i*, *fig.* 289), which may be regarded as the continuation of the muscular division of the musculo-spiral, considerably diminished in size. This common trunk passes vertically downward between the superficial and deep layers of muscles, gives off a branch, which enters the superficial aspect of the *extensor longus pollicis*, then passes between the adductor longus and extensor brevis pollicis on the one hand, and the extensor longus pollicis on the other, runs in contact with the interosseous ligament, and gives off a first branch to the *extensor longus pollicis*, a second which enters the deep surface of the same muscle, and a small branch which enters the outer border of the *entensor proprius indicis*.

Fig. 289.

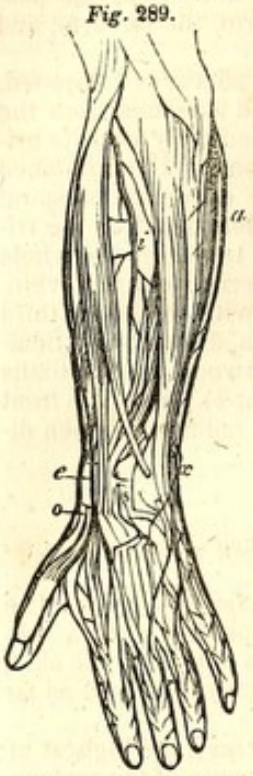

Reduced at length to a very small branch, the muscular division of the musculo-spiral nerve enters the groove (at *s*) for the tendons of the extensor communis digitorum, lying beneath them, in contact with the periosteum; it runs over the carpus, and expands into a number of *articular filaments*, which enter the radio-carpal, carpal, and carpo-metacarpal articulations; in this latter portion of its course, the nerve is of a grayish colour, swollen, and, as it were, knotted; a condition which is observed in all articular nerves.

The *superficial, cutaneous, or digital division of the musculo-spiral nerve*, or the *radial nerve* properly so called, forms the *external dorsal nerve of the hand*, and is about half the size of the muscular division. It passes vertically downward, between the supinator longus and the extensor carpi radialis longior, along the outer side of the radial artery: having reached the middle of the forearm, it escapes from beneath the tendon of the supinator longus, and runs along the outer border of that tendon.

Situated at first beneath the fascia, it soon perforates it, becomes sub-cutaneous, runs vertically downward, and, about an inch and a half above the styloid process of the radius, divides into an *external* and an *internal* branch.

The *external branch* (*o*, *figs.* 288, 289), which is the smaller, runs along the outer side of the styloid process of the radius, and then along the outer border of the carpus,* of the first metacarpal bone, and of the first and second phalanges of the thumb, and terminates in the skin beneath the nail; it is the *external dorsal collateral branch of the thumb.*

The *internal branch* (*e*, *fig.* 289), which is much larger, passes obliquely behind the radius, crosses the tendons of the adductor longus and extensor brevis pollicis, and divides into three secondary branches, namely, counting from without inward, the *internal dorsal collateral nerve of the thumb*, and *the external and internal dorsal collateral nerves of the index* finger.†

Summary.—The musculo-spiral nerve gives off, *in the arm, two cutaneous branches,* one internal, the other external, the latter of which is much the larger, and may be traced as far as the carpus; and also *muscular branches* to the three portions of the triceps and to the anconeus: to the *forearm*, it supplies *muscular branches* to all the muscles of the deep and superficial layers of the posterior and external regions; and to *the hand*, certain cutaneous branches, namely, the dorsal collateral nerves of the thumb and index finger.

General Summary of the Distribution of the Nerves of the Brachial Plexus.

The preceding description shows that the brachial plexus supplies the skin, the muscles, and the articulations of the upper extremity, including the shoulder. We shall briefly recapitulate, first the muscular and then the cutaneous branches.

The Muscular Branches.—By its collateral branches, the brachial plexus supplies the scaleni and all the muscles which move the shoulder, excepting the trapezius, which receives its nerves from the brachial plexus and from the spinal accessory nerve of Willis; by its *terminal branches* it supplies all the muscles of the arm, the forearm, and the hand.

Each of the *muscles which move the shoulder* receive a special nerve; thus, besides the nervous filaments for the scaleni, there is the nerve for the sub-clavius; the nerve for the levator anguli scapulæ; the nerves for the rhomboideus; the nerve for the serratus magnus, which is better known as the external thoracic nerve; the nerve for the latissimus dorsi, which is generally described as a branch of the sub-scapular; and the nerves for the pectoralis major and minor.

The *muscles which move the arm* upon the shoulder also receive their nerves from the

* [Where it sends an anastomotic filament to the palmar cutaneous branch of the median.]

† [It also supplies the external dorsal collateral of the middle finger, and often unites with the ulnar cutaneous, to form the dorsal collaterals for the contiguous sides of the middle and ring fingers.]

brachial plexus; sometimes there is a separate nerve for each muscle, sometimes the same nerve supplies two muscles. The nerve for the deltoid, or the circumflex nerve, also supplies the teres minor. The supra-spinatus and infra-spinatus receive their filaments from the same branch, viz., the supra-scapulum nerve. The teres major receives a branch from the sub-scapular nerve.*

Of the *muscles which move the forearm upon the arm.* Those of the anterior region, or the flexors, viz., the biceps, coraco-brachialis, and brachialis anticus, receive their filaments from the musculo-cutaneous nerve; the muscle of the posterior region, the triceps, is supplied entirely by the musculo-spiral nerve. The ulnar nerve gives no branch in the arm.

The *muscles which move the radius upon the ulna*, and those *which move the hand and the fingers*, are thus supplied. The interosseous division of the musculo-spiral nerve supplies the muscles of the posterior region of the forearm, viz., in the *superficial layer*, the common extensor, the extensor proprius digiti minimi, and the extensor carpi ulnaris; in the *deep layer*, the supinator brevis, the adductor longus, extensor brevis, and extensor longus pollicis, and the extensor proprius indicis.

The *muscles of the exterior region of the forearm*, namely, the two supinators, and the two radial extensors of the carpus, also receive their branches from the musculo-spiral nerve.

The *muscles of the anterior region of the forearm* receive their filaments from the median nerve, excepting the flexor carpi ulnaris and the internal half of the flexor profundus, which are supplied by the ulnar nerve. The flexor profundus, then, by a peculiarity which not unfrequently occurs in regard to compound muscles, receives its nerves from two different sources.

The *intrinsic muscles of the hand* are supplied in the following manner: Those of the ball of the thumb by the median nerve; those of the ball of the little finger by the ulnar nerve; the two external lumbricales by the median nerve; the two internal lumbricales by the ulnar nerve; all the interossei, including the adductor pollicis, by the ulnar nerve.

The Cutaneous Branches.†—The skin which covers the shoulder on the outer side receives its nerves from the cervical plexus.

The skin of the external surface of the arm receives its nerves from the cutaneous branches of the circumflex nerve, and from the external cutaneous branch of the musculo-spiral. The skin of the anterior and internal regions of the arm receives its nerves from the internal cutaneous branch of the musculo-spiral, from the accessory nerve of the internal cutaneous, which anastomoses with the second intercostal, from a small branch of the internal cutaneous, and from the humeral branch of the third intercostal.

The skin of the forearm receives its filaments from the internal cutaneous, which anastomoses with the cutaneous filaments of the musculo-spiral, ulnar, and musculo-cutaneous nerves.

The skin of the dorsal region of the hand and of the fingers receives its filaments from the dorsal branches of the radial nerve, in the two external thirds of that region, and from the dorsal branch of the ulnar nerve in the internal third.

The skin of the *palmar region* of the hand and fingers receives its filaments from the median nerve in the two external thirds, and from the ulnar in the internal third, or, to speak more precisely, the median nerve supplies the external and internal collateral branches of the thumb, the index, and the middle fingers, and the external collateral nerve of the ring finger; the ulnar nerve supplies the external and internal collateral nerves of the little finger, and the internal collateral branch of the ring finger.

Some of the terminal branches of the median nerve, and the terminal divisions of the internal cutaneous and musculo-cutaneous, are lost in the skin of the upper part of the palm of the band.

The palmar collateral nerves of the fingers offer the following peculiarities: the branches which they give to the skin are placed either opposite to each other, or alternately; each of these branches terminates separately in a pencil of filaments; the twigs from the internal branches do not anastomose with those from the external; lastly, the terminal extremities of the external and internal collateral branches do not anastomose with each other in the pulp of the finger, but expand separately, and are distributed to the skin of the pulp and to the skin under the nail.

The branches which supply the palmar aspect of the fingers present a very remarkable condition,‡ consisting in the presence of small, grayish, gangliform bodies, always of a crescentic form. These bodies are very numerous; they are sometimes separate,

* The teres minor and the infra-spinatus are, therefore, supplied by two different branches, which would induce us to describe these muscles separately, did we not see that compound, and sometimes even simple, muscles receive two or more distinct nerves.

† A beautiful preparation of the cutaneous nerves of the upper extremity may be made by removing the skin, either by turning it inside out, in the same way as an eel is skinned, or by making a longitudinal incision along the outer side of the limb. In both cases the fascia should be removed with the skin. In the first method, by which a very fine preparation may be made, the everted skin represents a kind of glove, the inner surface of which is formed by the epidermis, and the outer by the deep surface of the skin.

‡ This was pointed out in one of the last concours of the assistants (aides) of the Faculty, by MM. Andral, Camus, and Lacroix, who had to dissect the cutaneous nerves of the hand.

and sometimes arranged in groups; they do not essentially belong to the nerves, but are applied to them, and may be separated from them by slight force. They are, therefore, not ganglia.

If we consider that these gangliform bodies occupy the palmar region only, and are never found in the dorsal region, that they exist in the sole of the foot as well as in the palm of the hand, that they have been found upon the nerves which surround the articulations, and, consequently, upon nerves which are subject to constant pressure, that I have even found them upon an intercostal nerve which was reflected over the side of the sternum, and, lastly, that they do not exist in the infant at birth, and are more numerous in proportion as the palm of the hand is more callous we shall be warranted in concluding that they are the result of external pressure.

THE ANTERIOR BRANCHES OF THE DORSAL NERVES, OR THE INTERCOSTAL NERVES.

Dissection.—Enumeration.—Common Characters.—Characters proper to each.

Dissection.—Search carefully for the cutaneous branches, some of which are to be found opposite the sides of the sternum, and others about the middle of the intercostal spaces. Saw through the sternum in the median line, and open the abdomen through the linea alba. Sacrifice one half of the thorax, or, rather, break the ribs through the middle, so as to trace the nerves from within outward.

The *anterior branches of the dorsal nerves*, twelve in number, are intended for the parietes of the thorax and abdomen.*

These branches offer at once a great uniformity, and a great simplicity in their distribution. I shall first explain their common characters, and shall then notice the peculiarities presented by each.

Common Characters.

The *anterior branches of the dorsal nerves*, or the *intercostal nerves*, separated from the posterior branches by the superior costo-transverse ligament, appear like flattened cords, which pass to the middle of the corresponding intercostal space (see *fig.* 268); there they are situated between the pleura and the aponeurosis, which is continuous with the internal intercostal muscle. After proceeding for a certain distance, they pass between the external and internal intercostal muscles, and approach the groove of the rib above, but they are not lodged in it, for they always lie below the intercostal vessels.

At about the same situation in each space, that is to say, about half way between the vertebral column and the sternum, the intercostal nerves divide into two branches, the one *intercostal*, and the other *perforating* or *cutaneous*.

The *intercostal branch* is the continuation of the trunk of the nerve, and is distinguished from it only by its smaller size. It runs along the lower border of the rib above, and then that of the corresponding costal cartilage; it is sometimes situated on the internal surface of the cartilage, and having reached the forepart of the intercostal space, it perforates this space from behind forward, runs along the sternum, is inclined somewhat inward over that bone, and is then reflected outward, between the pectoralis major and the skin, to which latter it is distributed. These small filaments may be called the *anterior perforating filaments*. During its course, the intercostal nerve and its continuation give off a great number of nervous filaments. Not unfrequently the intercostal nerve gives off, in the back part of the space, a small branch, which reaches the upper border of the rib below. When this branch does not exist, its place is supplied by several twigs which have a similar distribution, some of which even pass to the intercostal space below, crossing obliquely over the internal surface of the rib. In like manner, we sometimes find some small twigs proceeding from the upper side of the nerve over the internal surface of the rib above, and reaching the next intercostal space. Lastly, from the lower side of the intercostal nerve and its continuation a series of twigs are given off, which divide into filaments that curve towards each other so as to form arches or loops, from which the terminal filaments proceed. In no part of the body are there found longer or more delicate nervous filaments; some of them run through half the length of an intercostal space without diminishing in size, and several evidently belong to the periosteum.

The *perforating* or *cutaneous branches* are often larger than the intercostal branches; they pass very obliquely through the external intercostal muscles, and after running for a certain distance between those muscles and the serratus magnus, each of them divides into two smaller branches, the one *anterior*, and the other *posterior* or *reflected:* the *anterior branches* run horizontally forward, become sub-cutaneous by escaping between the digitations of the serratus magnus in the eight superior intercostal spaces, and between the digitations of the obliquus externus abdominis in the four lower spaces, and then,

* Haller only admits eleven dorsal nerves, because he considers, and not without reason, the twelfth as a lumbar nerve.

becoming applied to the skin, spread into a number of filaments, which almost always anastomose with the adjacent filaments of the nerves above and below.

The *posterior* or *reflected branches* immediately perforate the serratus magnus and the obliquus externus abdominis, are reflected upon themselves, pass backward between the latissimus dorsi and the skin, and after running horizontally for a distance of one or two inches, are again reflected forward, and are then lost in the skin.

Proper Characters of each of the Anterior Branches of the Dorsal Nerves.

The First Dorsal Nerve.—This nerve belongs to the brachial plexus, into which it enters immediately after its escape from the inter-vertebral foramen, crossing over the neck of the first rib at an acute angle. From its size, it resembles the lower cervical nerves, and differs widely from the remaining dorsal nerves. It becomes intercostal only by giving off a small intercostal twig at its exit from the inter-vertebral foramen. This *intercostal branch* is applied to the under surface of the first rib, which it crosses obliquely from behind forward, so that it does not reach the first intercostal space until opposite the junction of the rib with its cartilage; it gains the middle of this space near the sternum, at which point it passes forward through the space, like the other intercostal nerves, and ramifies in the muscles and the skin.

The Second Dorsal Nerve.—This nerve crosses obliquely over the second rib, on the outer side of its neck, to reach the first intercostal space, and then recrosses the same rib, about its middle, to gain the second intercostal space, where it divides into two branches: the *intercostal*, which follows the lower border of the second rib, and presents nothing remarkable; and the *perforating* or *cutaneous* branch, which requires a special description.

The *perforating* or *cutaneous branch*, which is destined exclusively for the skin of the arm, is much larger than the other branches of the same kind. It emerges from the thorax at the middle of the second intercostal space, immediately below the second rib, passes directly through that space, is reflected at right angles over an aponeurotic arch, runs outward, and immediately subdivides into two branches of equal size, the one *external* and the other *internal*.

The *external* or *intercosto-humeral branch* (to the left of *d*, *fig.* 287) traverses the axilla, receives an anastomotic twig from the accessory nerve (*c*) of the internal cutaneous of the arm, reaches and crosses over the outer border of the latissimus dorsi, and divides into two cutaneous filaments, one of which is distributed to the skin of the posterior region of the arm, while the other lies in contact with the skin of the internal region of the arm, runs parallel to the accessory nerve of the internal cutaneous, and may be traced as low down as the elbow.

The *internal branch* crosses the outer border of the latissimus dorsi, lower down than the preceding branch, becomes applied to the skin, and divides into internal and posterior filaments, which are lost in the skin of the arm.

The perforating branch, therefore, of the second dorsal nerve completes the system of cutaneous nerves of the arm.

The *third dorsal nerve* is precisely similar to the others, excepting in its *perforating*, *cutaneous*, or *intercosto-humeral branch*, which is distributed to the integuments both of the thorax and arm. It is much smaller than the preceding; it emerges (*d*, *fig.* 287) from between the digitations of the serratus magnus, is reflected backward upon itself, gives a small branch to the mamma, crosses the outer border of the latissimus dorsi, below the perforating branch of the preceding nerve, and having reached the upper part of the shoulder, is reflected upon itself, describing a curve with the concavity turned upward, and terminates in the skin of the inner and upper part of the arm.

The *fourth*, *fifth*, *sixth*, and *seventh dorsal nerves* agree exactly with the general description. The intercostal muscles, the triangularis sterni, the serratus magnus, the obliquus externus abdominis, the upper part of the recti abdominis, and the integuments of the thorax, are supplied with nerves from these branches, in the order and manner already pointed out. I would direct attention to the considerable number of filaments distributed to the skin of the mamma in the female. The perforating branches of the fourth and fifth dorsal nerves each give a branch to the mamma, and a posterior branch, which crosses the latissimus dorsi, and is distributed to the skin over the scapula; the skin of the mamma receives nerves from the third, fourth, and fifth dorsal nerves.

The *eighth*, *ninth*, *tenth*, and *eleventh dorsal nerves* belong to the intercostal spaces formed by the false ribs: they leave those spaces at the point where the costal cartilages change their direction to bend upward; they perforate the costal attachments of the diaphragm, without giving that muscle any filaments, continue their oblique course in the substance of the parietes of the abdomen, for which they are destined, and are distributed to these parts, in the same way as the nerves in the intercostal spaces, with some slight modifications. Thus, the *perforating branches* perforate the external intercostals and the obliquus externus abdominis in the same line as the perforating branches of the preceding nerves; the *intercostal branches*, properly so called, having thus become *abdominal*, run between the external and internal oblique muscles, just as, in the upper spa-

ces, they ran between the external and internal intercostals. Having reached the rectus abdominis, they give off a *cutaneous* or *perforating branch*, and then enter the sheath of that muscle, through certain openings at its outer border, and proceed between the muscle and the posterior layer of the sheath: at the junction of the two external thirds with the internal third of the rectus, these branches pass through it very obliquely towards the middle line, and divide into *muscular filaments*, which are lost in the muscle, and the lowest of which pass vertically downward, and *cutaneous filaments*, which perforate the anterior layer of the sheath of the rectus, on each side of the linea alba, but not always at the same distance from it, and are reflected horizontally outward in the sub-cutaneous cellular tissue lying immediately in contact with the skin.

The *twelfth dorsal nerve* (*d*, *fig.* 290) might, according to the opinion of Haller, be regarded as the first lumbar nerve. It is larger than the other dorsal nerves; it emerges from the vertebral canal between the last rib and the first lumbar vertebra, passes in front of the costal attachments of the quadratus lumborum, runs along the lower border of the twelfth rib, proceeds very obliquely downward, like that rib, perforates the aponeurosis of the transversalis muscle, and, like the preceding nerves, divides almost immediately into two branches. The *abdominal branch*, which corresponds to the intercostal branch of the other nerves, passes horizontally forward between the transversalis and obliquus internus, supplying those muscles, and almost always gives off, below, an anastomotic branch to the abdominal or ilio-inguinal branch of the lumbar plexus, and then penetrates the sheath of the rectus, where it is arranged like the preceding nerves.

The *perforating* or *cutaneous branch* is remarkable for being larger than the abdominal branch, and for its distribution; it perforates very obliquely, and at the same time gives branches to the external and internal oblique muscles, becomes sub-cutaneous, passes vertically downward, crosses at right angles over the crest of the ilium, and divides into *anterior*, *posterior*, and *middle branches*, which are distributed to the skin of the gluteal region.

Not unfrequently this gluteal cutaneous branch is given off by the first lumbar nerve, and then the cutaneous branch of the twelfth dorsal nerve is arranged like those of the preceding nerves, and ramifies in the skin between the last rib and the crest of the ilium. There is a mutual relationship between the twelfth dorsal and the first lumbar nerves, so that they are often inversely developed; they always communicate with each other by a branch called the *dorsi-lumbar*, but the mode and place of communication are subject to many varieties: thus, it is sometimes effected by a winding branch which runs along the outer border of the quadratus lumborum, at other times it takes place in the substance of the abdominal muscles.*

Summary of the Dorsal or Intercostal Nerves.

These nerves are distributed to the parietes both of the thorax and the abdomen, which in all respects may be regarded as constituting a single cavity, the thoracico-abdominal. The muscular and cutaneous thoracic branches from the brachial plexus, some small branches derived from the lumbar plexus, and the posterior spinal branches of the dorsal nerves, complete the nervous system of the thoracic and abdominal parietes.

The dorsal nerves are divided into *muscular nerves*, for the muscles of the thoracico-abdominal parietes, and for the muscles which lie upon them, and into *cutaneous* nerves. To obtain a good idea of the latter, they should all be displayed in the same preparation. Several rows of parallel cutaneous filaments will then be seen, in the following order, proceeding from before backward.

The anterior perforating or *cutaneous nerves*, which are extremely small, emerge at the sides of the sternum and of the linea alba, and are reflected forward.

The *perforating* or *cutaneous nerves*, which might be called *middle*, divide into one set of *branches*, which run parallel to each other forward, towards the sternum, and another set, also parallel, which run backward, towards the vertebral column.

We have elsewhere stated that other *posterior cutaneous branches* are given off from the posterior branches of the dorsal nerves. They are parallel, and run outward, and may be traced as far as on a level with the axilla.

THE ANTERIOR BRANCHES OF THE LUMBAR NERVES.

Enumeration.—The Lumbar Plexus—Collateral Branches, Abdominal and Inguinal.—Terminal Branches—the Obturator Nerve—the Crural Nerve and its Branches, viz., the Musculo-cutaneous—the Accessory of the Internal Saphenous—the Branch to the Sheath of the Vessels—the Muscular Branches—the Internal Saphenous.

Dissection.—In order to see these nerves at their exit from the inter-vertebral foramina, and also to obtain a view of the lumbar plexus, it is necessary carefully to divide the

* In a subject which had a thirteenth or lumbar rib, there was a thirteenth dorsal nerve, of large size, which crossed the supernumerary rib, and which corresponded in its distribution with both the twelfth dorsal and the first lumbar nerves; it only communicated with the first lumbar nerve by a very small filament; it gave off a deep perforating or cutaneous branch to the gluteal region, and also an ilio-scrotal branch. In this subject there were only four lumbar nerves.

psoas muscle, in which they are situated; the branches which emerge from the plexus must be dissected with the greatest care as they are passing under the femoral arch, and then to their final distribution.

The *anterior branches of the lumbar nerves* (21 to 25, *fig.* 268) are five in number, and are distinguished as the first, second, third, fourth, and fifth: they gradually increase in size from the first to the fifth, and form a continuation of the series of anterior branches of the dorsal nerves: after having given off one or two branches to the lumbar ganglia (*u*) of the sympathetic, and some branches to the psoas muscle, they end by anastomosing so as to form the lumbar plexus (*l*).

The *anterior branch of the first lumbar nerve* (1 *l*, *fig.* 290) is the smallest of all, and is almost equal in size to the anterior branch of the twelfth dorsal nerve; immediately after emerging from the inter-vertebral foramen, it divides into three unequal branches; two of these (*a* and above *b*) are external and oblique, and constitute the *abdominal branches* (*ilio-scrotal nerves* of some authors); the third is internal, vertical, and often very small; it is the *anastomotic branch* which joins the second nerve.

Fig. 290.

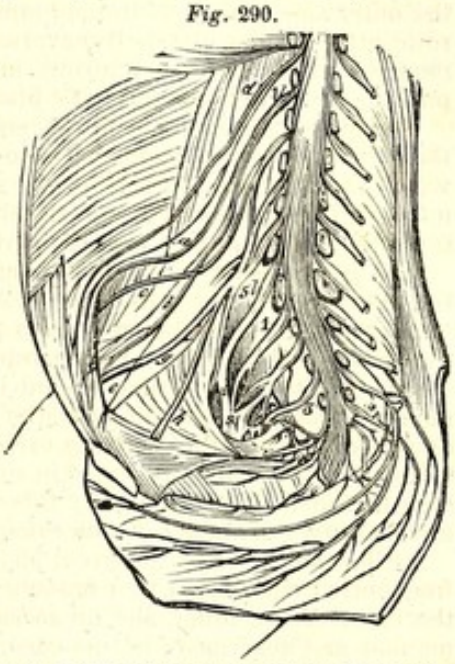

The *anterior branch of the second lumbar nerve* is at least twice as large as the preceding; it passes almost vertically downward, and gives off an anterior branch, the *internal inguinal* (*génito-crural* of Bichat, *b*), and an external branch, the *external inguinal* (*inguino-cutaneous* of Chaussier, *c*). It is scarcely diminished in size by giving off these nerves, but becomes flattened, plexiform, and riband-shaped, furnishes some large branches to the psoas, and anastomoses with the third nerve.

The *anterior branch of the third lumbar nerve* is twice as large as the preceding, passes obliquely downward and outward, and is joined by the branch from the second nerve, which greatly increases its size. The large trunk thus formed, after a short course divides into two unequal branches, which diverge at a very acute angle, and anastomose with two branches derived from the fourth nerve, to constitute the *crural* (*g*) and the *obturator* (*h*) *nerves*.

The *anterior branch of the fourth lumbar nerve* is a little larger than the third; it divides after a short course into three branches: an external, which unites with the external bifurcation of the third to form the *crural nerve*; a middle, which unites with the internal bifurcation of the same nerve to form the *obturator nerve*; and an internal, vertical, *anastomotic* branch, which joins the fifth nerve.

The *anterior branch of the fifth lumbar nerve* (5 *l*) is somewhat larger than the fourth; it receives the internal branch of that nerve, and with it forms a large trunk, which enters the sacral plexus, and was named by Bichat the *lumbo-sacral nerve* (*i*).

The Lumbar Plexus.

The *lumbar plexus* (*fig.* 290) (lumbo-abdominal, *Bichat*) is a rather complicated interlacement, formed by the anastomoses of the anterior branches of the lumbar nerves. It is narrow above, where it consists of the sometimes slender communicating cord between the first and second lumbar nerves, and it becomes wider towards its lower part, so as to have a triangular form; it is situated upon the sides of the lumbar vertebræ, between the transverse processes and the fasciculi of the psoas muscle.

The branches which emanate from the lumbar plexus are divided into *terminal branches*, namely, the *crural* (*g*), *obturator* (*h*), and *lumbo-sacral nerves* (*i*); and *collateral branches*, improperly named *musculo-cutaneous*; these are four in number; they run between the psoas and iliacus and the peritoneum, and reach the femoral arch. I shall divide these collateral branches into two sets: an *abdominal* set, subdivided into the *great* (*a*) and *small* (above *b*); and an *inguinal* set, subdivided into the *internal* (*b*) and *external* (*c*).*

Of these collateral branches, the abdominal only run in the sub-peritoneal adipose tissue, the inguinal branches being covered by a layer of fascia, which keeps them in contact with the psoas iliac muscle.

Collateral Branches of the Lumbar Plexus.

Abdominal Branches.

The *abdominal branches* of the lumbar plexus are intended for the parietes of the abdo-

* A change in the nomenclature of the collateral branches of the lumbar plexus appeared to me to be necessary. Bichat, who first distinguished them by special names, divides them into external or musculo-cutaneous branches, and an internal or genito-crural branch. Of the three external branches, Chaussier named the external the *ilio-scrotal*, and the internal the *inguino-cutaneous*; the intermediate one, to which he gave no particular name, retaining its old appellation of the *middle branch*.

men, and form a continuous series with the dorsal nerves, to which they are very analogous as regards their distribution.*

The *great abdominal nerve* (*a*, *fig.* 270) is the most external, or, rather, the highest of the branches which come from the lumbar plexus (it is the *superior musculo-cutaneous nerve* of Bichat); the terms *ilio-inguinal* and *ilio-scrotal*, which are generally applied to it, are derived from the fact of its giving a small cutaneous branch to the pubic region.†

It arises from the first lumbar nerve, of which it may be regarded as a continuation; it immediately perforates the psoas, becomes sub-peritoneal, runs in front of the quadratus lumborum obliquely downward and outward, through the sub-peritoneal adipose tissue, parallel to the twelfth dorsal nerve, and thus reaches the crest of the ilium to the outer side of the quadratus lumborum. It next passes obliquely through the aponeurotic attachments of the transversalis, runs along the crest of the ilium between that muscle and the obliquus internus, and divides into two branches, the *abdominal branch*, properly so called, and the *pubic* branch.

The *abdominal branch*, properly so called, runs inward between the transversalis and the internal oblique, parallel to the abdominal branch of the twelfth dorsal nerve, with which it almost always anastomoses, and soon divides, like the lower intercostal nerves, into two filaments, one of which perforates the rectus, while the other, after having entered the sheath of that muscle, perforates it and ramifies upon the skin.

The *pubic branch* (*a*, *fig.* 292) continues in the original course of the nerve: opposite the anterior superior spinous process of the ilium, and often much beyond that point, it receives an anastomotic twig from the small abdominal nerve (*b'*), and sometimes even the whole of that nerve, runs parallel to the femoral arch, at a variable distance above it, meets with the spermatic cord in the male, and the round ligament in the female, emerges from the anterior orifice of the inguinal canal (*a*, *fig.* 291), is reflected outward upon the superior angle of that orifice, and then expands into *internal* or *pubic filaments*, which are distributed to the skin of the pubes, and *external filaments*, which supply the skin of the fold of the groin; this pubic branch sometimes divides behind the femoral arch into two filaments, which escape separately from the inguinal ring.

At the point where the great abdominal nerve reaches the crest of the ilium, it very frequently divides into two branches, a *gluteal cutaneous*, which crosses obliquely over the crest of the ilium, and an *abdominal*, properly so called, which is distributed in the manner just described; in this case, the great abdominal nerve has an analogous distribution to that of the dorsal nerves.

The *small abdominal* or small musculo-cutaneous nerve (above *b*, *fig.* 290), the second branch derived from the lumbar plexus, counting from without inward (the *middle musculo-cutaneous* of Bichat), is merely an accessory of the great abdominal nerve, sometimes arising from it, often applied to it, and always anastomosing with it. It crosses obliquely over the anterior surface of the quadratus lumborum, and then over the iliacus, and is sometimes directed obliquely outward towards the anterior superior spine of the ilium, to join the pubic branch of the great abdominal nerve, with which it is blended; it sometimes runs alone between the transversalis and internal oblique: having reached the middle of the femoral arch, it anastomoses (*b'*, *fig.* 291) by a single twig with the pubic branch of the great abdominal nerve, runs along the femoral arch below and parallel to that branch, and terminates in the same manner, that is to say, in the skin of the pubes and groin. I have seen it give off a small branch to the lower part of the rectus abdominis. The small abdominal nerve deserves the name of *ilio-scrotal* as much as the great abdominal. If this denomination is to be preserved, it might be called the *small ilio-scrotal*.

The Inguinal Branches.

The *external inguinal*, or *external cutaneous nerve* (*c*, *fig.* 290), the third branch of the lumbar plexus, counting from without inward (inguino-cutaneous, *Chauss.*; inferior musculo-cutaneous, *Bichat*), is intended exclusively for the integuments of the external and posterior regions of the thigh. It generally comes off from the second lumbar nerve: I have seen it arise by a common trunk from the second and third lumbar nerves, and I have also seen it come off from the outer side of the crural nerve. It arises by one and often by two cords, which unite as they emerge from the psoas, or within the substance of that muscle. In either case, the nerve passes obliquely through the back part of the psoas, crosses the iliacus, being bound down by a layer of fascia, and then gains the anterior superior spinous process of the ilium, below which it emerges (*c fig.* 291) from the abdomen, passing behind the femoral arch, and apparently increasing in size during its passage.

Below the femoral arch the nerve is sub-aponeurotic, or, rather, is situated in a sheath

* The varieties which they present as to their number, origin, and divisions, render their description difficult; I shall point out the most important varieties as we proceed.

† I have frequently found the great abdominal branch divided into two distinct branches, which anastomosed upon the crest of the ilium, and then had a common distribution. I have seen the uppermost division lying so close to the twelfth dorsal nerve that it might have been taken for a branch of that nerve.

formed by the deepest layers of the fascia lata, and divides into two cutaneous branches (*c c, fig.* 292), a *posterior* or *gluteal*,* and an *anterior* or *femoral*.

The *posterior* or *gluteal branch* turns very obliquely outward, downward, and backward, crosses the tensor vaginæ femoris, and is distributed to the skin of the posterior region of the thigh. It is sometimes derived from the internal inguinal nerve, and then emerges from the abdomen on the outer side of the external inguinal nerve, crossing obliquely in front of it. When the great abdominal nerve (ilio-scrotal of authors) gives off a cutaneous gluteal branch, there is only a trace of this posterior branch of the external inguinal nerve.

The *anterior* or *cutaneous branch* divides into two others, which diverge at an acute angle: one is *external*, the other *internal*; the *external* branch gives off a series of filaments, which pass backward and downward, forming loops with their concavities turned upward, and is then lost towards the lower third of the thigh; its place is then supplied by the *internal* branch, which had at first descended vertically, but now turns outward and backward, and is distributed over the outer and fore part of the knee.

These several divisions of the external inguinal nerve lie in contact with the femoral fascia, and their ultimate filaments are applied to the skin.

The *internal inguinal nerve* (branche genito-crurale, *Bichat*; rameau sous-pubien, *Chauss.*, *b, fig.* 290) arises from the second lumbar nerve, passes directly forward through the psoas, from which it emerges at the side of the bodies of the lumbar vertebræ, runs vertically downward upon the anterior surface of the muscle covered by a very thin layer of fascia, and having arrived within a greater or less distance from the femoral arch, divides into two branches, an *internal* or *scrotal*, and an *external* or *femoral cutaneous branch* (*e*). Not unfrequently this division takes place as the nerve emerges from the psoas. Sometimes, indeed, the genito-crural nerve is double, but this arises merely from its early subdivision. During its course, the internal inguinal nerve is crossed by the ureter and covered by the spermatic vessels.†

The *internal* or *scrotal branch* (*e, fig.* 290) crosses over the front of the femoral artery, gains the internal orifice of the inguinal canal, crosses the epigastric artery, and, before entering the inguinal canal, gives off several filaments, which are reflected upward, and dip into the substance of the internal oblique and transversalis; the scrotal branch is placed below the spermatic cord, from which it is perfectly distinct, runs with it through the whole length of the inguinal canal (*b, fig.* 291), rests upon the reflected portion of the femoral arch or Gimbernat's ligament, and emerges from the external orifice of the inguinal canal, opposite the lower end of the external pillar: at this point it is reflected, passes vertically downward behind the cord, and ramifies in the skin of the scrotum of the male, and of the labia majora in the female.

The *femoral cutaneous branch* gains the crural ring; but before entering the ring, it gives off a great number of very delicate filaments, which are reflected upward behind the arch, to be distributed to the lower part of the psoas-iliac and transverse muscles: it then passes through the crural ring, in contact with its outer angle, and crosses the circumflex ilii artery at its origin, just as we have shown that the scrotal nerve crosses the epigastric artery; after leaving the crural ring (*e, figs.* 291, 292), it lies beneath the fascia, but soon becomes sub-cutaneous, anastomoses with a cutaneous branch of the crural nerve, and may be traced beyond the middle of the thigh.‡

I have already stated, in describing the external inguinal nerve, that the posterior or gluteal cutaneous branch of the external inguinal nerve is often given off by the internal inguinal nerve. In that case, this branch runs outward, crosses the external nerve at a very acute angle under the femoral arch, and escapes from below the arch on the outer side of that nerve to turn round the tensor vaginæ femoris. Not unfrequently the filaments for the lower part of the internal oblique and transverse muscles arise by one or more distinct branches.

The Terminal Branches of the Lumbar Plexus.

These are three in number, viz., the *obturator nerve*, the *crural nerve*, and the great communicating branch between the lumbar and sacral plexus, called the *lumbo-sacral trunk* or *nerve*, which I regard as a dependance of the sacral plexus.

The Obturator Nerve.

The *obturator nerve* (*h, fig.* 290), which is distributed exclusively to the external obtu-

* Not unfrequently the external inguinal nerve gives off a third and very small internal branch, which lies immediately in contact with the skin of the anterior region of the thigh, and may be traced as far as the lower third of that region. This branch always anastomoses with a cutaneous branch of the crural nerve.

† Sometimes a small filament comes off from the genito-crural nerve while it is still within the substance of the psoas, descends vertically on the inner side of this nerve, gives off a filament which is lost upon the external iliac artery, and then again becomes united with the nerve from which it had been given off.

‡ In order to assist the memory, by connecting these nerves with important parts, I am in the habit of calling the femoral cutaneous branch of the internal inguinal nerve the *branch of the crural ring*, and the scrotal branch, the *branch of the inguinal canal*. The scrotal branch may be cut, in relieving the stricture in inguinal hernia, by the division of Gimbernat's ligament; and the femoral cutaneous branch may be wounded when the external angle of the crural ring is divided for the relief of femoral hernia.

rator muscle, to the three adductors of the thigh, and to the gracilis, is the smallest of the terminal branches of the lumbar plexus; it arises from the third and fourth lumbar nerves by two equal branches, which unite at an acute angle; it perforates the psoas, passes under the angle of bifurcation of the common iliac artery and vein, runs along the inner surface of the psoas, crosses very obliquely over the sides of the brim of the pelvis, and is then placed below the external iliac vessels, with which it forms an acute angle, and above the obturator artery: throughout the whole of this course, it is enveloped in the sub-peritoneal cellular tissue of that region, and, thus flattened and enlarged, reaches the internal orifice of the obturator or sub-pubic canal, on emerging from which it expands into diverging branches (*h*, *fig.* 291) for the adductors and the gracilis muscle of the thigh.

Fig. 291.

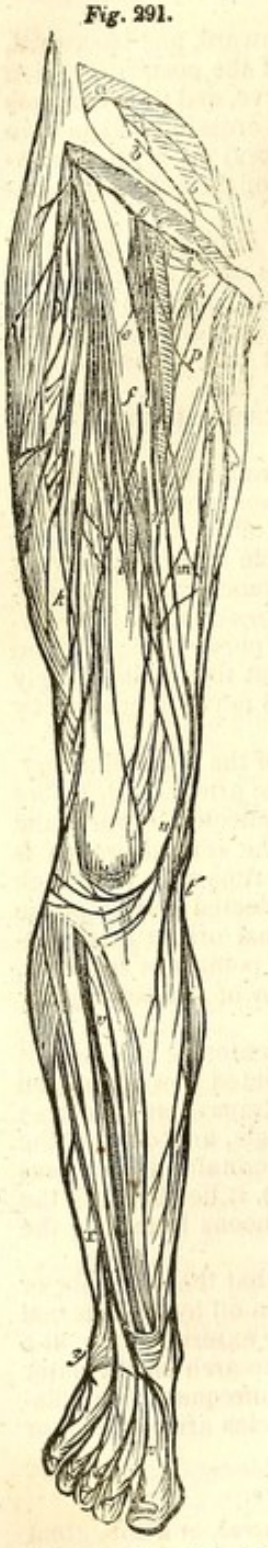

Collateral Branch.—The obturator nerve gives off no branch in the pelvis: during its passage through the obturator or sub-pubic canal, it gives two filaments to the *obturator externus*; one of these penetrates the upper border of the muscle, and the other enters at its anterior surface.* The obturator internus receives no filament from the obturator nerve.

Terminal Branches.—These are four in number;† three of them, constituting a *superficial set*, pass under the pectineus, and are distributed as follows: the *internal* to the gracilis, the *external* to the adductor longus, and the *middle* to the adductor brevis; the fourth, which is more *deeply* seated, belongs to the adductor magnus.

The *branch for the gracilis* expands, as it enters the muscle, into several filaments, the largest of which (*r*, *fig.* 291) runs for some distance upon the internal surface of the muscle before terminating in it.

The *branch for the adductor longus* enters the upper border and deep surface of the muscle: a rather large division (*q*) of this branch, taking a different course, passes sometimes in front of and sometimes behind the muscle, which is crossed by the nerve in the first case, and perforated by it in the second; the nerve then divides into several filaments, some of which anastomose with the accessory branch (at *m*) of the internal saphenous nerve, while another anastomoses with the saphenous nerve itself, and a third terminates in the synovial membrane of the knee-joint: this is an articular nerve; it may unite with the articular branch of the nerve for the vastus internus. The anastomotic division of the branch for the adductor longus is sometimes as large as the muscular branch itself.‡

The *branch for the adductor brevis* crosses the upper border of that muscle, expands upon it, but does not enter it until it reaches the middle; there is almost always an anastomotic twig, which joins the internal saphenous branch of the crural nerve.◊

The *fourth branch*, or *branch for the adductor magnus*, is the *deepest*; it passes between the adductor brevis and magnus, and ramifies in the last-mentioned muscle.‖

* [It also gives off, in this situation, articular filaments to the hip-joint; these are small or absent when the articular branches of the accessory to the obturator are large.]

† [Before dividing into its terminal branches, the obturator is joined by its accessory nerve (see notes, *infrà*); it supplies a separate branch to the pectineus when that from the accessory nerve is wanting.]

‡ See note, *infrà*.

◊ In a great number of subjects I have found a small nervous cord, which sometimes came off from the third lumbar nerve, sometimes from the obturator itself, and which may be called the *accessory of the obturator nerve*, or the *nerve of the coxo-femoral articulation*; it perforates the psoas to reach its inner surface, runs parallel to and above the obturator nerve, gains the pubes, which it crosses on the inner side of the ilio-pectineal eminence, with which it is in contact, dips beneath the pectineus, and anastomoses with the internal saphenous nerve, passing into the angle of bifurcation of the femoral artery, where it gives off the profunda. Opposite the pubes it gives off several branches, which perforate the fibrous capsule of the coxo-femoral articulation, and are distributed to the synovial membranes. [This small accessory nerve was first described by Schmidt. As it passes under the pectineus it partially supplies that muscle: its anastomotic branch is described as uniting with the obturator nerve beneath the pectineus, and not with the internal saphenous (see also notes, p. *infra*, et 803). The articular branch was believed by Schmidt to end in the fat near the acetabulum. When the accessory nerve is small, the articular filaments and the branch to the pectineus are replaced by others from the trunk of the obturator itself. In the pelvis the nerve has been seen to give filaments to the levator ani.—(Schmidt, *De Nervis Lumbalibus eorumque Plexu*, 1794; Dr. Alex. Thomson, *Lond. Med. and Surg. Journal*, Nos. 95, 96; Ellis, *Demonstrations of Anatomy*).]

‖ [In the dissections of Schmidt, Thomson, and Ellis, the branches of the obturator nerve were found to have a much more extensive distribution than that described in the text. According to their observations, one of the *superficial* branches, which is named the *long cutaneous* nerve (*q*, *fig.* 291), and which corresponds

The Crural Nerve.

The *crural nerve* (*g*, *fig.* 290) is the external terminal branch of the lumbar plexus; the third and fourth lumbar nerves are almost entirely devoted to the formation of this large branch, which supplies all the muscles of the anterior region of the thigh, and the integuments of the anterior regions of the thigh, leg, and foot.

After emerging from the psoas, the crural nerve is lodged in the groove between the psoas and iliacus; it escapes from the pelvis with this muscle, in the sheath of which it is contained: having arrived below the femoral arch (*g*, *fig.* 291), it turns slightly outward, becomes flattened and widened, and immediately divides into a great number of diverging branches. The nerve sometimes bifurcates, and then gives off these different branches.

Relations.—In the iliac fossa, the crural nerve is covered by the iliac fascia, and is separated by the psoas from the external iliac artery and vein. Opposite the femoral arch it always occupies the groove between the psoas and iliacus, and is situated on the outer side of the femoral artery, being separated from the vessel by the psoas, which is very narrow at that point. It is of importance to remark, that the crural nerve is not contained in the sheath of the femoral vessels, but is separated from them by the iliac fascia (see *fig.* 136).

Collateral Branches.—In the pelvis, the crural nerve gives off from its outer side a great number of small branches (*iliac branches*), which enter separately into the iliacus muscle, after having run for some distance obliquely downward and outward upon the surface of that muscle. Only *one* branch enters the psoas. One of the branches for the iliacus is very long, and descends vertically in front of that muscle, into which it enters, after having turned round its outer border. I have already said that the external inguinal nerve (*inguino-cutaneous* of authors) not unfrequently arises from the crural nerve.

Of the *terminal branches of the crural nerve* there are two which arise in *front* of the others: these are, the *musculo-cutaneous nerve*, and the *small nerve for the sheath of the femoral vessels.** The other branches are, proceeding from without inward, the *branch for the rectus*, the *branches for the vastus externus*, the *branches for the vastus internus*, and the *cutaneous branch*, called the *internal saphenous* nerve.

The Musculo-cutaneous Crural Nerve.

This nerve passes obliquely downward and outward between the sartorius and the psoas and iliacus, and immediately expands into *muscular branches*, distributed exclusively to the sartorius, and *cutaneous branches*.

The *muscular branches* may be divided into the *short*, which enter the upper part of the sartorius, and the *long*, which run for some distance upon the deep surface of that muscle, before passing into it.

The *cutaneous branches* are three in number; two of them perforate the sartorius at different points, and may be called *perforating branches*. I shall call the third the *accessory branch of the internal saphenous nerve*.

The *superior perforating cutaneous* or *middle cutaneous nerve* (*f*, *fig.* 291) passes, very obliquely, through the upper part of the sartorius, and often, as it emerges from that muscle, anastomoses with a branch from the internal inguinal (genito-crural) nerve; it then passes vertically downward, parallel to and on the inner side of the external inguinal (external cutaneous) nerve; it lies in contact with the femoral fascia (*f*, *fig.* 292), or, rather, is contained in a proper fibrous sheath. During its course, the superior perforating cutaneous nerve gives off internal and external cutaneous filaments, and bifurcates, opposite the middle of the thigh, into two branches of equal size, which run parallel to each other, gradually diminishing in size, and may be traced down to the skin over the patella.

to the anastomotic division of the branch for the adductor longus, gives off cutaneous branches (*q*, *fig.* 292), which perforate the fascia to the inner side of the sartorius muscle, and supply the skin on the inner part of the thigh; it also gives anastomotic branches to the plexus (*m*, *fig.* 291) formed in the middle of the thigh, and sometimes an articular filament to the knee (these anastomotic and articular branches are described in the text, p. 800); it then ends in a descending cutaneous branch, which perforates the fascia near the knee (*r*, *fig.* 292), communicates with the internal cutaneous and internal saphenous nerves, and is distributed to the skin on the inner and back part of the two upper thirds of the leg. The *deep* branch of the obturator gives off within the upper part of the adductor magnus an articular filament destined for the knee-joint; this filament descends in the substance of the adductor near the linea aspera, and enters the popliteal space, either by perforating the tendinous insertion of the muscle about its lower third, or by coming forward on the front of that insertion, and then passing backward through the opening for the femoral artery: having reached the popliteal space, it surrounds the artery with small filaments, and enters the back part of the knee-joint.

The cutaneous branches just stated to be given off by the superficial part of the obturator to the thigh and leg, and the articular filament given by the deep branch of the obturator to the knee-joint, correspond, in *their distribution*, with the three collateral branches described by M. Cruveilhier (p. 803) as arising from the internal saphenous nerve *after it has received a remarkable branch of origin from the obturator nerve*, opposite to the commencement of the profunda artery: these collateral branches of the internal saphenous were never met with in Mr. Ellis's dissections. In some cases, then, it seems that part of the obturator joins the internal saphenous, which afterward gives off cutaneous branches to the thigh and leg, and an articular filament to the knee; in other cases, again, the obturator does not join the internal saphenous, the above-mentioned branches arise directly from the obturator, and the internal saphenous gives no collateral branches.]

* [The crural nerve also gives some small branches (*s*, *fig.* 292), which pass inward behind the femoral vessels, enter the pectineus muscle, and sometimes the psoas also.]

The *inferior perforating cutaneous* or *internal cutaneous nerve* (*l*, *fig.* 291) run along the inner border of the sartorius, enclosed in its sheath, passes obliquely through the muscle at the middle of the thigh, but perforates the femoral fascia much lower down (*l*, *fig.* 292); it descends vertically, in contact with that fascia, and having arrived opposite the internal condyle of the femur, is reflected forward upon itself, describing a loop with the concavity turned upward; it thus gains the patella, runs between the skin and the sub-cutaneous bursa, and expands into a number of diverging filaments, which anastomose with the reflected branch (*l l*) of the internal saphenous nerve on the inner side of the patella. A small filament often remains in the sheath of the sartorius, anastomoses upon that muscle with a branch from the accessory of the internal saphenous nerve, perforates the sheath of the sartorius opposite the knee, and anastomoses, on the inner side of the joint, with the reflected branch of the internal saphenous.

The *accessory cutaneous branch of the internal saphenous nerve* arises from the musculo-cutaneous nerve on the inner side of the perforating branches, descends vertically, and divides into two branches. The smaller of these is *superficial* (*n*, *fig.* 291); it enters the sheath of the sartorius, runs along the inner border of the muscle, escapes from the sheath below the middle of the thigh, crosses the adductor and the gracilis, and is in contact with the internal saphenous vein until it reaches the inner side of the knee, where it anastomoses with the internal saphenous nerve. The other branch, the *satellite nerve of the femoral artery*, crosses obliquely over the nerve for the vastus internus and the internal saphenous nerve, and is situated in front of the latter, runs along the femoral artery, covering the lower fourth of that vessel, and crosses very obliquely over it, then passes over the tendon of the adductor magnus, and, having reached the fibrous ring through which the femoral artery passes, it expands into a great number of filaments, of which one anastomoses with the preceding branch (*n*), another joins the obturator nerve (at *m*), and a third unites with the internal saphenous nerve; a sort of plexus is thus formed which gives origin to several nerves that cross obliquely over the gracilis, to be distributed to the skin upon the posterior region of the leg.

The Small Nerve for the Sheath of the Femoral Vessels.

This branch, which often comes off separately from the lumbar plexus, is situated, like the musculo-cutaneous, in front of the other branches of the crural nerve; it then expands into a great number of very slender filaments, which surround the femoral artery and vein. Two of these filaments, of which one passes in front of and the other behind the femoral artery, unite to form a small nerve (*p*, *figs.* 291, 292), that escapes by the opening (*p*) for the internal saphenous vein, and accompanies the vein for a great part of its course. Not unfrequently, the filaments which have passed between the artery and vein perforate a lymphatic ganglion. Two other filaments are distributed to the adductor brevis and adductor longus; several of them turn round the deep femoral artery and vein, to become sub-cutaneous, and anastomose with other accompanying branches of the femoral vessels, and more particularly with the internal saphenous nerve.

This small branch presents many varieties. I have seen it arise separately from the fourth lumbar nerve, and it then runs along the anterior surface of the crural nerve.

The Nerve for the Rectus Femoris.

The *nerve for the rectus femoris* arises on the inner side of the preceding, enters the upper part of the deep surface of the muscle, and divides into a *superior* or short branch, which passes horizontally outward in the substance of the muscle, and an *inferior* or long branch, which lies in contact with its inner border, and enters the muscle at the middle of the thigh.

The Nerve for the Vastus Externus.

The *nerve for the vastus externus* sometimes arises by a common trunk with the preceding, passes obliquely downward and outward beneath the rectus, to which it gives a filament, and then divides into two branches: one of these immediately enters the upper part of the vastus externus, and gives off, before penetrating it, a cutaneous branch, which perforates the fascia lata and lies in contact with the skin of the external region of the thigh: the other is longer, dips between the vastus externus and internus, and enters the middle of the former muscle. This last branch almost always gives off a small twig to the vastus internus.

*The Nerves for the Vastus Internus.**

These are two in number; the one is *external*, and descending vertically, enters that portion of the vastus internus which corresponds to the anterior surface of the femur (the crureus of authors), and may be traced as far as the lower part of the muscle: this nerve furnishes several *periosteal* and *articular filaments*; the other is *internal*, and much larger; it often arises by a common trunk with the internal saphenous nerve, runs vertically downward in front of the vastus internus, parallel to and on the outer side of the

* It will be remembered that, according to my views, the portion of the triceps which is called the *crureus* is not distinct from the vastus internus (see MYOLOGY).

femoral artery, being in contact with that vessel above, but separated from it below, where it enters the vastus internus. Before penetrating it, it gives off a very remarkable *articular* and *periosteal branch*, which runs along the surface of the muscle, to the aponeurosis of which it is applied:* opposite to the knee-joint it is reflected forward, perforates the thick fibrous layer which invests the inner side of the joint, and divides into two filaments, of which one, the *articular*, is lost behind the ligamentum patellæ in the quantity of adipose tissue which is found there; while the other, or the *periosteal*, gains the anterior surface of the patella, and is lost in the periosteum. This last filament is re-enforced upon the inner border of the patella by another which passes out from the substance of the vastus internus.

The Internal Saphenous Nerve.

The *internal saphenous nerve* (*t t'*, *fig.* 291), the satellite nerve of the femoral artery in the thigh, and of the internal saphenous vein in the leg, is at first situated on the outer side of the artery, but soon passes in front of that vessel, and is contained in the same fibrous sheath; when the artery passes through the tendon of the adductor magnus to enter the popliteal space, the nerve continues its vertical course in front of that tendon, and crossing it very obliquely from before backward, gains the back of the internal condyle of the femur, situated in front of the tendon of the gracilis, and separated from the skin by the sartorius; it then divides into two terminal branches (*u*, *t'*, *figs.* 291, 292). This division often takes place as the nerve is crossing the tendon of the adductor magnus.

Collateral Branches.—At its upper part, the internal saphenous nerve receives from the obturator nerve a remarkable branch of origin, which passes from behind forward in the angle formed by the femoral artery and the profunda.† It then gives off from its inner side, at the middle of the thigh, a *cutaneous femoral branch*, which passes between the sartorius and the gracilis, runs backward and downward, and is distributed to the skin of the posterior and internal region of the thigh. Several filaments continue their course to the inner and back part of the knee, anastomose with some branches given off from the saphenous nerve in the leg, and are distributed to the skin of the internal and posterior region of the leg.

At the point where the femoral artery perforates the adductor magnus, the internal saphenous nerve gives off a *second* or *tibial cutaneous branch*, which passes between the sartorius and gracilis, turns round the inner border of the latter muscle, passes vertically downward parallel to the saphenous nerve, and divides into several filaments, some of which anastomose with that nerve, while the others are distributed to the skin upon the internal and posterior region of the leg.

In the sheath of the adductor magnus the saphenous nerve gives off an *articular filament*, which passes vertically downward in the substance of the internal inter-muscular septum, gains the knee-joint, perforates the fibrous layer, and may be traced into the synovial adipose tissue.‡

Terminal Branches.—The *anterior, reflected*, or *patellar branch* (*u*, *figs.* 291, 292) perforates the sartorius◊ opposite to the back of the internal condyle, is reflected forward and downward in a flattened form upon the inner side of the knee-joint, parallel to and above the tendon of the sartorius, and expands widely into *ascending filaments*, which pass in front of the ligamentum patellæ, and turn round the lower and then the outer borders of the patella; into *descending filaments*, which cross obliquely over the crest of the tibia, and ramify in the skin which covers the external region of the leg; and into *middle filaments*, which occupy the space between the two preceding sets; they are all distributed to the skin, and several of them anastomose with the cutaneous filaments upon the external region of the patella.

Fig. 292.

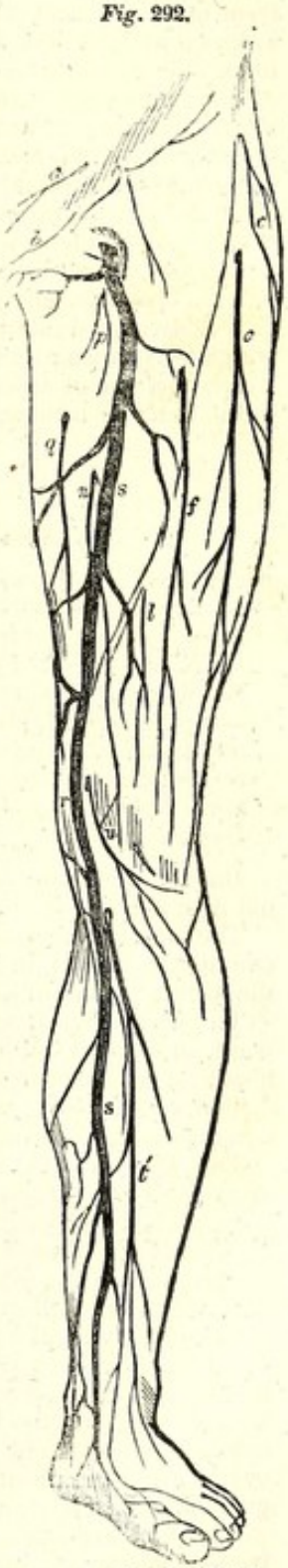

* [In this situation it sometimes receives the articular filament of the anastomotic or long cutaneous branch of the obturator nerve.]

† [This junction of part of the obturator with the internal saphenous nerve was never seen in the dissections of Mr. Ellis, nor did the saphenous give any collateral branch in the thigh; but branches corresponding in their distribution to the three collateral branches described in the text arose from the obturator itself (see also note, p. 800.)]

‡ See note, p. 800.

◊ The sartorius is, therefore, perforated in succession by three cutaneous branches, namely, two perforating branches from the musculo-cutaneous nerve, and one from the internal saphenous.

The *posterior* or *straight branch* (*t'*) is larger than the preceding, and continues in the original course of the nerve; it almost always receives an anastomotic branch from the obturator nerve, passes in front of the tendon of the gracilis, then between the sartorius and that tendon; which it crosses very obliquely, to meet the internal saphenous vein (*s*), whose direction it then follows: having arrived opposite the junction of the three upper fourths with the lower fourth of the leg, it divides into two branches: the one, *posterior* and smaller, passes vertically downward in front of the internal malleolus, upon which it ramifies, some of the filaments reaching as far as the skin upon the inner side of the sole of the foot; the other branch, which is *anterior* and larger, runs along the internal saphenous vein, like it, is situated in front of the internal surface of the tibia, then in front of the internal malleolus, and expands into *articular branches*, which enter the tibio-tarsal articulation, and into cutaneous filaments, which ramify in the skin upon the inner side of the tarsus.

The following are the relations of the saphenous nerve with the internal saphenous vein: the nerve is at first placed in front of the vein, then crosses obliquely under it to get behind it, and, lastly, it again returns to its position in front of the vessel.

During its course along the leg, the posterior branch of the saphenous nerve gives off some internal and some external branches: the *internal branches* are very small; the upper ones anastomose with the *tibial cutaneous branch* of the trunk of the internal saphenous nerve, and concur with it in supplying filaments to the skin of the back of the leg. The *external branches*, three or four in number, are large, and, in this respect, diminish from above downward; their direction is obliquely downward and outward, in front of the tibia, which they cross; their course is a long one, and they are distributed extensively to different portions of the skin of the leg. All these divisions are parallel to each other, and to the anterior reflected or patellar branch of the saphenous nerve.

THE ANTERIOR BRANCHES OF THE SACRAL NERVE.

Dissection.—Enumeration.—The Sacral Plexus.—Collateral Branches, viz., the Visceral Nerves—the Muscular Nerves—the Inferior Hemorrhoidal—the Internal Pudic and its Branches—the Superior Gluteal Nerve—the Inferior Gluteal, or Lesser Sciatic Nerve—the Nerves for the Pyramidalis, Quadratus Femoris, and Gemelli.—Terminal Branch of the Sacral Plexus, or the Great Sciatic Nerve.—The External Popliteal and its Branches—the Peroneal Saphenous, Cutaneous, and Muscular Branches—the Musculo-cutaneous—the Anterior Tibial.—The Internal Popliteal and its Branches—the Tibial or External Saphenous—Muscular and Articular Branches—the Internal Plantar—the External Plantar.—Summary of the Nerves of the Lower Extremity.—Comparison of the Nerves of the Upper with those of the Lower Extremity.

Dissection.—Make an antero-posterior section of the pelvis, as in dissecting the internal iliac artery.

The *anterior branches of the sacral nerves* (26 to 31, *fig.* 268), which are six in number, communicate with the sacral ganglia of the sympathetic, after they have emerged from the sacral foramina, and present the following arrangement:

The *first nerve* (1, *fig.* 290), which is very large, passes obliquely downward and outward, in front of the pyriformis, and is joined at a very acute angle by the lumbo-sacral nerve (*i*), to assist in the formation of the sacral plexus.

The *second nerve*, which is as large as the preceding, passes much more obliquely downward and outward, and immediately enters the sacral plexus.

The *third nerve* (3), which is scarcely one fourth as large as the second, passes more horizontally outward to enter the sacral plexus. A considerable interval, in which is a large part of the pyriformis, separates it from the second nerve. A filament stretched in front of this muscle passes from the second to the third sacral nerve.

The *fourth nerve* (4), which is only one third the size of the third, is divided and distributed in the following manner: One of its divisions assists in forming the sacral plexus; it gives off several visceral branches, which enter the hypogastric plexus; it communicates with the fifth sacral nerve by another division; it gives off one or two branches to the coccygeus muscle; and, lastly, it gives a cutaneous coccygeal branch, which runs along the border of the sacrum, penetrates the great sacro-sciatic ligament, crosses that ligament very obliquely, and turns round its lower edge, perforates the coccygeal attachments of the glutæus maximus, passes very obliquely through the muscle, gives branches to it, and then ends in the integuments.

The *fifth and sixth nerves*, which have no connexion with the sacral plexus, are extremely small; the fifth is not more than half the size of the fourth; the sixth is so very slender a filament, that it has often escaped the notice of anatomists, and hence the incorrect but prevalent opinion that there frequently exist only five sacral nerves.

The *fifth nerve*, at its exit from the anterior sacral foramen, divides into an *ascending branch*, which communicates with the fourth, and a *descending branch*, which passes di-

rectly downward to anastomose with the sixth, of which it appears to form the ascending branch.

The *sixth nerve* consists of a mere filament, which divides, while still contained within the sacral foramen, into an *ascending* or anastomotic branch, which is merely the descending branch of the fifth; a *descending* or *inferior coccygeal branch*, which passes vertically downward along the coccyx in the substance of the sacro-sciatic ligament, and is distributed to the skin; and certain *external branches*, which perforate the sacro-sciatic ligament, and terminate in the glutæus maximus.

The Sacral Plexus.

The *sacral plexus* (*fig.* 290) is formed by the four upper sacral nerves (1 to 4) and the lumbo-sacral nerve (*i*) from the lumbar plexus; the three superior sacral nerves pass entirely into this plexus; the fourth nerve only sends one of its divisions to it. The lumbo-sacral trunk or nerve, which emanates from the lumbar plexus, is formed by the whole of the fifth lumbar nerve added to a branch from the fourth. This great nervous trunk establishes a free connexion between the lumbar and sacral plexuses, which, in fact, constitute only one plexus, which may be called the lumbo-sacral. I would here recall to mind that there is a precisely similar arrangement with regard to the cervical and brachial plexuses, to which the lumbar and sacral plexuses have an undoubted analogy.

The sacral plexus is distinguished by its simplicity from most other plexuses, which are always more or less complicated. It is formed by the convergence of five cords towards the sciatic notch. As the lumbo-sacral cord is vertical, and the third and fourth sacral nerves are horizontal, it follows that the form of the sacral plexus resembles a triangle, the base of which measures the entire length of the sacrum, while its apex corresponds to that portion of the sciatic notch which is situated above the spine of the ischium. The great sciatic nerve (*s*) is the continuation of this plexus, which, as Bichat judiciously remarked, is merely the sciatic nerve itself flattened from before backward, the intricacy of arrangement so evident in the plexus representing that which exists in all nervous cords.

The following are the relations of the sacral plexus: It rests behind upon the pyriformis, and it corresponds in front to the internal iliac vessels, from which it is separated by a layer of fascia: these vessels also separate the plexus from the rectum and peritoneum.

Of the *collateral branches*, some are *anterior*, namely, the visceral nerves, which enter the hypogastric plexus; the nerve for the levator ani; the nerve for the obturator internus; the internal pudic nerve: the other collateral branches are *posterior*, namely, the superior gluteal nerve; the inferior gluteal or lesser sciatic nerve; the nerve for the pyriformis; the nerve for the gemelli; and the nerve for the quadratus femoris. The great sciatic nerve is the only *terminal branch* of the sacral plexus.

The Collateral Branches of the Sacral Plexus.

The Visceral Nerves.

Dissection.—After having made a section of the pelvis at one side of the symphysis, turn the bladder and the rectum over to the same side; carefully detach the peritoneum, which is reflected from the pelvis upon these viscera; lacerate the cellular tissue to reach the branches given off from the fourth nerve; and then trace the rectal and visceral nerves, following the annexed description. It is advantageous to empty the large veins of the pelvis, and to soak it in water for some time previously to dissecting these nerves.

The *visceral nerves* do not, properly speaking, come from the sacral plexus, but rather directly from the fourth and fifth sacral nerves; they are three or four in number, and pass upward upon the sides of the rectum and bladder in the male, and of the rectum, vagina, and bladder in the female; some of them are distributed directly to those organs, but the greater number (*y*, *fig.* 302) enter the hypogastric plexus (*m*), which will be described with the sympathetic system.

The Nerves for the Levator Ani.

Besides several rectal and vesical filaments which go to the levator ani, this muscle receives two filaments directly from the fourth sacral nerve (4, *fig.* 290): the larger of these filaments enters the middle of the muscle; the other, which is smaller, passes upon the sides of the prostate in the male, and of the vagina in the female, and terminates in the anterior portion of the muscle.

The Nerve for the Obturator Internus.

It arises from the anterior part of the sacral plexus, and more particularly from that portion which belongs to the lumbo-sacral cord and the first sacral nerve; it passes immediately behind the spine of the ischium, is reflected forward through the small sciatic

notch, and expands into three diverging branches, which are distributed within the muscle. In order to expose this nerve, the lesser sacro-sciatic ligament may be divided.

The Inferior Hemorrhoidal Nerve.

This nerve, which is intended for the sphincter ani and the adjacent skin, arises (from 4, *fig.* 290) on the inner side of the internal pudic nerve, of which it is sometimes a branch, passes, like that nerve, behind the spine of the ischium, and then between the two sacro-sciatic ligaments, reaches the front of that portion of the glutæus maximus which projects below the great sacro-sciatic ligament, communicates with the superficial nerve of the perineum, gains the side of the rectum, and opposite the upper border of the sphincter expands into a great number of branches; of these, some are *anterior*, and often anastomose with one of the divisions of the superficial perineal nerve; others are *median*, and pass upon the sides of the sphincter ani as far as the skin, in which they terminate; lastly, others are *posterior*, and proceed to the back part of the sphincter. The hemorrhoidal or anal nerve is sometimes distributed exclusively to the skin round the anus; it may then be named the *anal cutaneous nerve.*

The Internal Pudic Nerve.

Dissection.—It is convenient to commence the dissection of this nerve from within outward, by dividing the lesser sacro-sciatic ligament, and separating the obturator fascia from the obturator internus muscle. The superior branch of the nerve upon the dorsum of the penis may then be traced without taking it away. The perineal branches must then be very carefully dissected, and the continuity of these branches with those already dissected within the pelvis should be made out.

The internal pudic nerve (*d*, *fig.* 293) arises from the lower border of the flattened band formed by the nerves of the sacral plexus opposite to their junction; it passes behind the spine of the ischium, and then enters the ischio-rectal fossa through the lesser sciatic notch, that is, between the two sacro sciatic ligaments, on the inner side of the internal pudic artery, and divides into two branches (*l*, *fig.* 290), the *inferior branch*, or *perineal nerve*, and the *superior* or *deep branch*, or the *dorsal nerve of the penis.*

The Perineal Nerve.

The *inferior branch* or *perineal nerve* corresponds to the trunk of the internal pudic artery, and to all its divisions, excepting the dorsal artery of the penis. It is the true continuation of the nerve, and accompanies the trunk of the internal pudic artery, being situated below that vessel; it runs forward and then upward between the obturator internus and the obturator fascia, describes a curve having its concavity directed upward, and placed on the inner side of the tuberosity of the ischium, perforates the obturator fascia, opposite to the junction of the tuberosity with the ascending ramus of the ischium, and immediately divides into two branches: an *inferior* or anterior superficial perineal, which corresponds to the superficial artery of the perineum; and a *superior*, which corresponds to the artery of the bulb, but which has a much more extensive distribution; I shall call it the *bulbo-urethral nerve.*

The Collateral Branches of the Perineal Nerve.—During its course, the perineal nerve gives off a branch which might be called the *external perineal* (*posterior superficial perineal*); this branch perforates the great sacro-sciatic ligament, passes by the internal surface of the tuberosity of the ischium, turns inward and downward, and then beneath the tuberosity, runs along the crus of the corpus cavernosum, and is lost in the dartos and scrotum in the male, and in the substance of the labia majora in the female. I have seen this nerve give a branch to the coccygeus, and two branches to the sphincter.

This external perineal branch, moreover, presents many varieties. In some cases it terminates by anastomosing with the superficial branch of the perineum. In one case, in which the external perineal branch was very small, it was re-enforced by a branch from the inferior gluteal or lesser sciatic nerve, which crossed the outer side of the tuberosity of the ischium, and united, in front of that tuberosity, with the external perineal branch.

The Terminal Branches of the Perineal Nerve.—The *superficial* (*anterior superficial*) *perineal nerve* follows the superficial artery of the perineum, passes, like it, obliquely inward and forward, through the cellular interval between the ischio-cavernosus, and bulbo-cavernosus, receives a rather large filament from the external perineal branch, and almost always divides into several remarkably long filaments, which pass through the dartos, some reaching the bottom of the scrotum, while others, running along the lower surface of the penis, are distributed to the skin of that organ, and may be traced as far as the prepuce.

The *bulbo-urethral nerve*, the second terminal branch of the perineal nerve, passes above and sometimes through the fibres of the transversus perinei muscle, supplies some small branches to the anterior part of the compressor urethræ and the posterior part of the bulbo-cavernosus, furnishes a bulbar branch which dips into the substance of the bulb, and then expands into very delicate filaments on the corpus spongiosum.

The Deep Branch of the Internal Pudic, or the Dorsal Nerve of the Penis.

This is the highest of the terminal divisions of the internal pudic nerve, and corresponds to the deep branch of the internal pudic artery. It is at first applied, together with that vessel, against the internal surface of the tuberosity of the ischium, and passing upward between the levator ani and obturator internus, gains the arch of the pubes; it then runs forward among the sub-pubic veins through the several ligamentous structures below the arch, and reaches the dorsum of the penis, where it is situated at the side of the suspensory ligament. Having now become the dorsal nerve of the penis, it runs along that organ in the median line, like the dorsal artery, but superficially to that vessel, and divides into an *internal* and an *external branch*.

The *internal branch*, or *branch for the glans penis*, continues in the original course of the nerve upon one side of the median line, becomes more deeply seated as it runs forward, but without entering the corpus cavernosum, and thus arrives at the corona glandis; at this point it expands and passes deeply between the base of the glans and the corpus cavernosum, gives no filament to the latter, but is entirely distributed to the glans, penetrating that part by extremely delicate filaments, which traverse the spongy tissue, and may be traced, at least in a great measure, to the papillæ on the surface of the glans.

The *external* or *cutaneous branch*, which is more superficial, comes off from the preceding at a very acute angle, passes obliquely upon the sides of the penis, and expands into a number of very long and slender filaments, some of which lie in contact with the corpus cavernosum, and supply it with very slender filaments, while others run into the sub-cutaneous cellular tissue, and are distributed to the skin of the penis; a considerable number terminate in the prepuce. The external branch of the dorsal nerve of the penis supplies the skin upon the three upper fourths of the circumference of the penis. The perineal branches supply that of the lower fourth. I have not found any branch of the internal pudic nerve corresponding to the artery of the corpus cavernosum.

In the female, when this nerve reaches the clitoris, it becomes very small; it passes under the arch of the pubes, between it and the crus of the clitoris; it runs along that crus, becomes curved like the clitoris itself, upon the side of which it expands into filaments, and then ramifies in the substance of that organ; several of the filaments run forward to the skin of the anterior part of the labia majora.

The superficial perineal branch passes between the constrictor muscle and the bulb of the vagina, and then terminates in these parts.

The internal pudic nerve in the female does not appear to me to be half the size of the internal pudic nerve of the male. In one case I found that it consisted only of the branch for the clitoris, the superficial branch being supplied by the inferior gluteal nerve.

The Superior Gluteal Nerve.

The *superior gluteal nerve*, which is intended for the glutæus medius and minimus, and the tensor vaginæ femoris, arises from the back of the lumbo-sacral trunk, before its junction with the first sacral nerve. I have seen it arising by two roots, of which one came from the lumbo-sacral nerve and the other from the posterior surface of the plexus: it emerges from the pelvis (*a*, *fig.* 293) by the upper and fore part of the great sciatic notch, in front of the pyriformis, is reflected upon this notch to pass between the glutæus medius and minimus, and divides into two branches: the one *ascending*, which encircles the origin of the glutæus minimus, like the corresponding branch of the gluteal artery; and the other *descending*, which passes obliquely downward and outward, between the glutæus medius and minimus, to which it gives off numerous filaments, and thus, gradually diminished in size, it embraces, as it were, the posterior surface of the glutæus minimus, and having reached the external border of that muscle, it passes downward, and enters the sheath of the tensor vaginæ femoris, in which it terminates. Before entering the sheath of the tensor vaginæ it gives off a remarkable branch, which turns round the anterior border of the glutæus minimus, and ramifies in that muscle.

The Nerve for the Pyriformis.

This little nerve arises separately from the posterior surface of the sacral plexus, and more particularly from the third sacral nerve; it divides into two branches, which immediately enter the anterior surface of the muscle.

The Inferior Gluteal Nerve.

The *inferior gluteal nerve* (*Bichat*), or the *lesser sciatic nerve* (*Boyer*), is intended for the glutæus maximus, the integuments of the posterior region of the thigh, and for a part of the skin of the leg. It arises from the back of the sacral plexus, sometimes by one cord, sometimes by several very distinct cords. It emerges from the pelvis (near *c*, *fig.* 293), below the pyriformis, together with and on the inner side of the great sciatic nerve, to which it may be regarded as an accessory; it passes behind that nerve, and divides into two sets of branches, viz., *muscular* and *cutaneous*.

The *muscular branches* (*c*) are numerous, although exclusively intended for the glutæus maximus; they divide into *ascending* and *external* branches, which run along the ante-

rior surface of the muscle, spread out upon it, and may be traced as far as its upper border, and *descending* and *internal* branches, which pass between the tuberosity of the ischium and the muscle, and then enter the latter.

The *cutaneous branch* (*b*) continues in the original course of the nerve, behind the great sciatic, and in front of the glutæus maximus; it crosses obliquely, downward and inward, over the tuberosity of the ischium and the origins of the biceps and semi-tendinosus muscles; considerably reduced in size, from having given off several branches, it assumes the name of lesser sciatic (*f*), runs vertically downward, becoming smaller and smaller, and may be traced down to the posterior region of the leg.

The cutaneous branch, as it emerges from the glutæus maximus, gives off a considerable *recurrent branch* (*e*), which might be regarded as a terminal branch of the nerve. This branch is reflected upward so as to describe a curve having its concavity turned upward, and subdivides into two secondary branches, an internal and an external: the *external branch* is the larger, and ramifies in the skin of the gluteal region; the *internal* or *scrotal branch* (pudendalis longus inferior, *Sœmmering*) is a very remarkable one; it is reflected forward upon the under surface of the tuberosity of the ischium, runs along at some distance from the ascending ramus of the ischium and the descending ramus of the os pubis, anastomoses with the superficial perineal nerve, reaches the scrotum above the testis, and divides into two branches—an external, which passes on the outer side, and an internal, which runs on the inner side of the testis; having embraced this organ, they are distributed to the skin of the anterior part of the scrotum and the lower part of the penis. In the female, this branch belongs to the labia majora.

All along the thigh, the cutaneous branch of the inferior gluteal nerve gives off some very small external branches, and some larger internal branches, which are reflected forward, describing curves having the concavity turned upward, and supply the skin of the internal region of the thigh.

In the popliteal space, the cutaneous branch divides into two filaments, one sub-cutaneous, which may be traced, notwithstanding its extreme tenuity, as far as the middle of the posterior region of the leg; and the other sub-aponeurotic, which perforates the fascia of the leg, runs along the external saphenous vein, and anostomoses with the external saphenous nerve.

The Nerves for the Quadratus Femoris and the Gemelli.

The *superior gemellus* receives a special nerve from the anterior part of the sacral plexus. The nerve for the *inferior gemellus* is a branch of the nerve for the quadratus femoris.

The *nerve for the quadratus femoris* is remarkable. It arises from the front of the sacral plexus, or, rather, from the limit between this plexus and the great sciatic nerve, passes vertically downward in front of the gemelli and obturator internus, by which it is separated from the great sciatic nerve, and it is placed in contact with the os innominatum, to the outer side of the tuberosity of the ischium. It gives off some *external periosteal and osseous* branches, which enter the foramina in the tuberosity of the ischium; some *internal* or *articular* branches, which perforate the fibrous capsule of the hip-joint; a branch for the inferior gemellus; and then terminates in the quadratus femoris, which it enters by its anterior surface.

The Terminal Branch of the Sacral Plexus, or the Great Sciatic Nerve.

The *great sciatic nerve* (grand fémoro-poplité, *Chauss.*) is intended for the muscles of the posterior region of the thigh, and for the muscles and integuments of the leg and foot: it is the termination (*s*, *fig.* 290) of the sacral plexus, or, rather, it is the sacral plexus itself condensed into a nervous cord. The fifth lumbar nerve, a branch of the fourth lumbar, the three superior sacral nerves, and a branch from the fourth, form the origins of this great nerve, which is the largest in the body.

It emerges from the pelvis, through the great sciatic notch, below the pyriformis immediately above the spine of the ischium, passes vertically downward (*s*, *fig.* 293) between the tuberosity of the ischium and the great trochanter, both of which project so as to separate it from the skin, or, more exactly, it runs along the outer side of the tuberosity of the ischium, in a very deep groove between that process and the margin of the cotyloid cavity. At its exit from the pelvis, it is a flat, riband-shaped nerve, six lines in breadth, but it soon becomes rounded, runs vertically downward along the back of the thigh, sloping, however, a little outward; having arrived about three or four fingers' breadth above the knee-joint, it divides into two branches, which are called the *external popliteal sciatic* or the *peroneal nerve* (*i*), and the *internal popliteal sciatic* or *tibial nerve* (*h*).

The sciatic nerve sometimes divides at its exit from the pelvis, but it may do so at any other point between that and the popliteal space. This premature division is of no importance; in fact, it always exists; for when there is apparently only one trunk, the two branches of the bifurcation are perfectly distinct through the whole length of the thigh, and are merely in contact with each other.*

* When the great sciatic nerve divides within the pelvis, the upper division perforates the pyriformis, while the lower emerges from below that muscle.

Relations.—Behind, the great sciatic nerve is covered by the glutæus maximus, and then by the long head of the biceps and the semi-tendinosus; lower down it occupies the cellular interval between these two last-named muscles, and when they separate from each other to form the borders of the popliteal space, it becomes sub-aponeurotic.

In *front*, it corresponds to the gemelli and obturator internus, by which it is separated from the os coxæ, to the quadratus femoris and the adductor magnus. During its course it is surrounded by a large quantity of adipose cellular tissue, but has no accompanying vessel.*

Collateral Branches of the Great Sciatic.—The great sciatic nerve gives off in the thigh five muscular and three articular branches; they sometimes arise separately, sometimes by a common trunk. They are the following:

The *nerve for the long head of the biceps*, which divides into two *ascending branches* for the origin of that muscle from the ischium, and *descending branches*, which run for a long time in front of the muscle, and then enter it by a series of filaments.

The *nerve for the semi-tendinosus*, which runs upon the anterior surface of the muscle, and does not enter it until it reaches the lower third of the thigh.

The *nerves for the semi-membranosus* are two in number; they almost always anastomose and enter the internal surface of the muscle at two different points.

A *nerve for the adductor magnus*, which runs forward and then inward, and enters near the inner border of the muscle. We have seen that the adductor magnus receives most of its nerves from the obturator nerve. All the preceding branches arise from the upper part of the sciatic nerve, opposite to the quadratus femoris, and often by a common trunk.

A *nerve for the short head of the biceps* sometimes arises at the same height as the preceding, but is most commonly given off from the sciatic nerve at the middle of the thigh. When the sciatic nerve divides prematurely, the branch we are now describing comes from the external popliteal. This nerve enters the upper extremity of the muscle, expanding into diverging filaments.

An *articular nerve of the knee*, which often arises by a common trunk with the preceding, and is not unfrequently given off from the external popliteal; it passes vertically downward in front of the great sciatic nerve, through some adipose tissue, to gain the outer side of the joint; having arrived above the external condyle, it turns and divides into several filaments, which perforate the fibrous tissue of the joint, and are distributed to the articular adipose tissue, where they are scattered, some above, others below, and others on the outer side of the patella.†

Fig. 293.

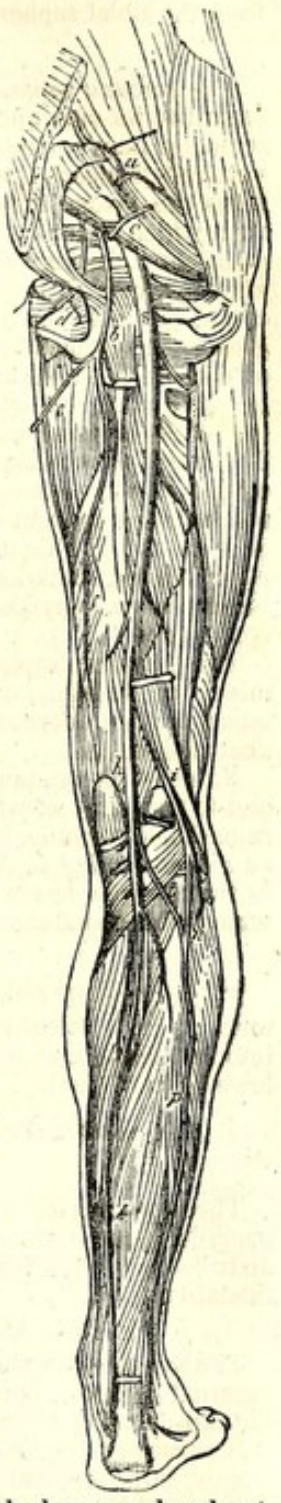

The External Popliteal Sciatic or Peroneal Nerve.

The *external popliteal sciatic*, *external popliteal*, or *peroneal nerve* (*i*, *fig.* 293), the external terminal branch of the great sciatic, is intended for all the muscles of the anterior and external region of the leg, and for the skin on the leg and on the dorsum of the foot. It is scarcely half the size of the internal popliteal; it runs obliquely downward and outward, behind the external condyle of the femur through the popliteal space, and is placed nearer to the surface than the internal popliteal nerve, which is lodged in the intercondyloid fossa; it then crosses obliquely over the origin of the outer head of the gastrocnemius, passes behind the head of the fibula, from which it is separated by the origin of the soleus, turns horizontally upon the neck of that bone (at *v*), between it and the peroneus longus, and expands into four branches, two superior or recurrent, for the tibialis anticus, and two inferior and larger, which form the true terminations of the nerve.

Collateral Branches.

During this course, the external popliteal nerve gives off two superficial collateral

* In three instances I have found the great sciatic accompanied by a large vein, which was continuous with the popliteal vein, and perforated the upper part of the adductor magnus, like the profunda artery. In two of these cases the sciatic nerve divided at its exit from the pelvis. I did not note the arrangement of the nerve in the third case. It was a remarkable circumstance that there was another popliteal vein accompanying the artery: in one of the cases the vein was in front instead of behind the artery.

† See note, p. 812.

nerves: a *saphenous nerve*, which we shall call the *peroneal saphenous*, to distinguish it from the tibial saphenous, and the *peroneal cutaneous branch*.

The Peroneal Saphenous Nerve.

The *peroneal saphenous nerve* (*n*) presents many varieties in different subjects, both in regard to its size and origin. It is generally smaller than the tibial saphenous (*l*), of which it may be regarded as an accessory; it arises in the popliteal space, descends vertically beneath the fascia, between the external and internal popliteal nerves, perforates the fascia opposite the middle of the leg, to join the external saphenous vein, with which it runs along the tendo Achillis, and terminates upon the outer side of the os calcis. During this course, it gives off several cutaneous filaments and a communicating branch to the tibial saphenous nerve: this branch is of considerable size, and comes off while the nerve is still beneath the fascia. Having become very slender after giving these branches, the peroneal saphenous nerve subdivides opposite the lower part of the tendo Achillis, and upon the outer side of the os calcis, into several *calcaneal branches*, one of which turns obliquely round the posterior surface of the os calcis, while the others descend vertically, are reflected upon the under surface of that bone, and are distributed to the skin of the heel. Not unfrequently the peroneal saphenous nerve gives off a *malleolar branch*, which passes between the external malleolus and the skin, and anastomoses in front of the ankle-joint (*y*, *fig.* 291) with a twig from the musculo-cutaneous nerve. This malleolar branch, which often comes from the last-mentioned nerve, is, moreover, remarkable, like all nerves which are subjected to strong pressure, for its thickness, its grayish colour, and, lastly, for its knotted, and, as it were, ganglionated appearance.

The peroneal saphenous nerve is often very small, and is lost in the skin upon the middle of the leg: its place is then supplied in the lower two thirds of the leg by the tibial saphenous nerve, the size of which is always in an inverse ratio to that of the peroneal saphenous.

No nerve presents more varieties than the peroneal saphenous; they relate to its size and to the point at which it anastomoses with the tibial saphenous. One of the most remarkable varieties is that in which the peroneal and tibial saphenous nerves, those called *communicating saphenous branches* (*communicans fibulæ*, *n*; *communicans tibiæ*, *l*) unite in the popliteal space into a single trunk, the *external saphenous* (*p*), the distribution of which corresponds to the ordinary distribution of the two nerves.

The Peroneal Cutaneous Branch.

This comes off from the external popliteal nerve, behind the outer condyle of the femur, passes vertically downward along the fibula, in contact with the skin, and divides into ascending and descending branches, the latter of which may be traced as far as the lower part of the leg.

The Terminal Branches of the External Popliteal Nerve.

The Branches for the Tibialis Anticus.

The two *superior* or *recurrent branches*, resulting from the subdivision of the external popliteal, pass horizontally inward, behind the extensor communis digitorum, and are distributed to the tibialis anticus; one of these branches supplies the peroneo-tibial articulation.

The Musculo-cutaneous Branch, or External Peroneal Nerve

The *musculo-cutaneous branch* (*x*, *fig.* 291), the lowest of the terminal branches of the external popliteal, is intended for the muscles of the external region of the leg, and for the skin upon the dorsum of the foot (prétibio-digital, *Chauss.*; peroneus externus, *Sœmm.*).

It passes at first obliquely, then vertically downward in the substance of the peroneus longus, turns forward to enter between the extensor longus digitorum and the peroneus longus and brevis, and perforates the fascia of the leg, above the ankle-joint: having thus become sub-cutaneous, it passes obliquely downward and inward, following the direction of the extensor longus digitorum, becomes flattened and widened, and divides a little below the tibio-tarsal articulation into an internal and an external branch; the latter subdivides into three other branches, so that there are in all four terminal branches, which form the dorsal collateral nerves of the toes.

Not unfrequently the musculo-cutaneous nerve bifurcates as it escapes from beneath the fascia of the leg, and its two branches reunite opposite to the tibio-tarsal articulation, so as to describe an elongated ellipse.

Collateral Branches.—There are two *branches for the peroneus longus*, of which one comes off from the nerve immediately after its origin, while the other arises lower down, and runs a very long course in the substance of the muscle; there is also a branch *for the peroneus brevis*, which often arises by a common trunk with the preceding.

In its sub-cutaneous portion, the musculo-cutaneous nerve supplies several filaments to the skin, among which we should distinguish an *external malleolar filament*, which passes between the external malleolus and the skin, increases considerably in size, and becomes

grayish and knotted, like all nerves subjected to pressure. This filament often anastomoses with the malleolar branch of the peroneal saphenous nerve, and sometimes supplies the place of that malleolar branch.

Terminal Branches.—There are four terminal branches of the musculo-cutaneous nerve, distinguished numerically as the first, second, third, and fourth (see *fig.* 291). The *first* or *internal* branch passes very obliquely forward and inward, to form the *internal dorsal collateral nerve* of the great toe; this nerve, like all nerves subjected to pressure, increases in size and becomes grayish, and, as it were, knotted opposite the metatarso-phalangal articulation. The *second* branch, which often arises by a common trunk with the first, supplies the *external dorsal collateral nerve* of the great toe, and the *internal collateral nerve* of the second toe. The *third* branch supplies the *external collateral nerve* of the second, and the *internal collateral nerve* of the third toe. These two large branches are often replaced by one (*v*) from the anterior tibial nerve, with which they anastomose. The fourth terminal branch or *internal branch* supplies the *external dorsal collateral* nerve of the third, and the *internal dorsal collateral* nerve of the fourth toe.

All the filaments from these branches are distributed to the skin upon the dorsal region of the foot and digital phalanges.

In a great number of subjects, the tibial or external saphenous nerve supplies the internal collateral nerve of the little toe, and the external collateral nerve of the fourth toe: but in others, these nerves are furnished by an additional terminal branch of the musculo-cutaneous nerve; in all cases the nerves anastomose with each other.

The Anterior Tibial, or Interosseous Nerve.

The *anterior tibial* or *interosseous nerve* (*v v*, *fig.* 291), intended for the muscles on the anterior region of the leg, for the extensor brevis digitorum, and for the interosseous muscles in the foot, is as large as the musculo-cutaneous nerve just described; it runs to the inner side of that nerve, beneath the extensor communis digitorum, and passes along the interosseous ligament, together with the anterior tibial artery lying in front of that vessel. It is placed, like the artery, between the tibialis anticus and the extensor communis digitorum, from which it is separated below by the extensor proprius pollicis pedis; it supplies a great number of filaments to all these muscles, passes with the artery under the annular ligament of the tarsus, in the sheath of the extensor proprius pollicis, and divides into two branches:

The *internal deep branch of the dorsum of the foot* (*v*), which is the true continuation of the nerve, passes horizontally forward, under the arteria dorsalis pedis, over the first interosseous space, gives off a small twig to the muscles of that space, and divides into two branches, which form the *deep external dorsal collateral nerve* of the great toe, and the *internal dorsal collateral nerve* of the second toe. These branches communicate with the superficial dorsal branches of the musculo-cutaneous nerve, and sometimes supply their place.

The *external* and *deep nerve of the dorsum of the foot* runs outward between the tarsus and the extensor brevis digitorum, in which it terminates; it gives off in front, opposite the interosseous spaces, a series of very delicate filaments, which enter the posterior extremities of those spaces. The filaments for the fourth and fifth spaces often arise by a common trunk. They are extremely delicate, and are closely applied to the tarsus.

The Internal Popliteal Sciatic, or Tibial Nerve.

The *internal popliteal sciatic*, *internal popliteal*, or *tibial nerve* (*h*, *fig.* 293), is intended for all the muscles of the back of the leg, and for the skin of the sole of the foot; both in direction and size it appears to be the continuation of the great sciatic nerve. It passes vertically downward in the inter-condyloid fossa of the femur; it is at first placed between the heads of the gastrocnemius, it then passes under that muscle and under the arch formed by the soleus, descends, under the name of the *posterior tibial* nerve (*k*), between the soleus and the deep layer of muscles, inclines a little inward, and, having reached the termination of the fleshy belly of the soleus, gains the inner side of the tendo Achillis; lower down, it passes behind the internal malleolus, against which it is flattened and widened, and divides into the *internal* and *external plantar nerves* (*a*, *b*, and *c*, *fig.* 294).

In the popliteal space it is sub-aponeurotic, in the fleshy portion of the leg it is separated from the fascia by the double layer formed by the gastrocnemius and the soleus, and it again becomes sub-aponeurotic along the tendo Achillis. It is in relation, in front, with the popliteal and posterior tibial vessels, which separate it, above, from the knee-joint and popliteus muscle, and lower down, from the deep layer of muscles in the leg.* Behind the internal malleolus, and under the groove upon the os calcis, it is enclosed in a common fibrous sheath with the posterior tibial vessels, which are placed in front of it; this sheath is behind that for the tendons of the tibialis posticus and flexor communis digitorum.

* [The nerve is at first at a short distance to the outer side of the artery; lower down it lies immediately behind the vessel, and still lower crosses to the inner side of the artery, and is separated from it by the vein.]

Its *collateral branches* are very numerous. I shall divide them into those given off opposite the knee-joint, and those supplied along the leg.

The Collateral Branches of the Internal Popliteal Nerve, behind the Knee-Joint.

These are six in number, namely, two anterior, which are very small, one for the plantaris longus, and one for the knee-joint; two internal, namely, the tibial saphenous nerve, and the nerve for the inner head of the gastrocnemius; two external, namely, the nerve for the outer head of the gastrocnemius, and the nerve for the soleus.

The Tibial Saphenous Nerve.

This is generally known as the *external saphenous*. It is much larger than the peroneal saphenous, which always anastomoses with it. I have already said that the mode and situation of this anastomosis present many varieties. The tibial saphenous nerve (*communicans tibiæ*, *l*, *fig.* 293) arises in the popliteal space, passes vertically downward between the two heads of the gastrocnemius, and then upon their posterior surface, along their fibrous septum, between them; it is here situated in a small fibrous canal common to it and to a small artery and vein; it receives, at a variable height in the leg, a more or less considerable filament from the peroneal saphenous nerve (or *communicans fibulæ*, *n*); it then becomes sub-cutaneous, forming the external saphenous nerve (*p*), runs along the outer side of the tendo Achillis, just as the posterior tibial runs along its inner side; it now accompanies the external saphenous vein, which is accompanied above this point by the peroneal saphenous nerve; it is reflected behind the external malleolus, in the same manner as the tibial nerve is reflected upon the internal malleolus, then runs forward and downward (*y*, *fig.* 291) upon the outer side of the os calcis, where it gives off several very large *external calcaneal nerves*, and terminates differently in various subjects. In some it terminates by forming the dorsal collateral nerve of the fifth toe; in others it is larger, and divides into two branches, of which the external forms the external collateral nerve of the fifth toe, while the internal, which receives an anastomotic branch from the musculo-cutaneous nerve (*x*), passes horizontally forward, crosses the extensor brevis digitorum, and the tendons of the long extensors, and divides into two secondary branches, of which one constitutes the internal dorsal collateral nerve of the little toe, and the other the external dorsal collateral nerve of the fourth toe. I may point out the thickening, the gray colour, and the knotted, and, as it were, ganglionated structure of the external collateral nerve of the little toe opposite to the articulations.

The *external calcaneal nerves*, which may be regarded as forming the termination of the tibial saphenous, are very remarkable; they pass vertically along the outer side of the os calcis, expand into several filaments, which are reflected upon the ridge which separates the external from the inferior surface of that bone, and are distributed to the skin upon the heel.

During its course along the leg, the tibial saphenous gives off scarcely a single filament, but along the outer border of the foot it supplies a great number, which run downward and forward, and terminate in the skin covering the external plantar region.

The size of the tibial saphenous nerve is inversely proportioned to that of the peroneal saphenous and musculo-cutaneous nerves. Thus, when the peroneal saphenous nerve is large, it furnishes most of the external calcaneal branches; and when the musculo-cutaneous nerve is large, it supplies, besides the external calcaneal, the internal dorsal collateral nerve of the little toe, and the external dorsal collateral nerve of the fourth toe.

The Nerves for the two Heads of the Gastrocnemius and for the Soleus.

The nerve for the inner head of the gastrocnemius often arises by a common trunk with the tibial saphenous; again, the nerves for the outer head of the gastrocnemius and for the soleus often arise by a common trunk: the nerves for the gastrocnemius enter the anterior surface of the head of that muscle, and immediately ramify. The nerve for the soleus is the largest, and enters the muscle at its upper arch; all these nerves ramify as soon as they enter the muscles which they supply.

The Articular Nerve and Nerve for the Plantaris Longus.

The *posterior articular nerve of the knee* runs forward to enter the posterior ligament of the articulation: one of its filaments follows the direction of the internal articular artery, and is lost in the popliteus.*

* [From the dissections of Mr. Ellis, it appears that there is an articular nerve to the knee-joint with each articular artery. The *superior external articular* nerve is the one described at p. 809; it most commonly arises from the external popliteal. The *inferior external articular* also arises from the external popliteal, and sometimes from the sciatic nerve; it is a long branch which descends towards the external condyle, passes below it on the outer side of the joint, and perforates the capsule. The *superior internal articular* is very small, and is not constant; it arises from the internal popliteal nerve, and passes on the outer side, and then in front of (*i. e.*, deeper than) the popliteal vessels, and reaches with its artery the inner side of the joint. The *inferior internal articular* is the largest of all; it arises from the internal popliteal above the joint, descends on the outer side, and then in front of the popliteal vessels, is applied to the corresponding artery upon the popliteus muscle, passes beneath the internal lateral ligament, and enters the inner side of the joint. The *posterior articular*, or *azygos*, is given off opposite the joint from the internal popliteal, or from the inferior internal articular; it perforates the posterior ligament.—(*Ellis's Demonstrations of Anatomy*, p. 675, 676.)]

The *nerve for the plantaris longus* always arises separately from the posterior tibial nerve, and immediately dips into the substance of the muscle.

Collateral Branches of the Internal Popliteal Nerve in the Leg.

There are three sets of collateral branches given off by the posterior tibial nerve in the leg: namely, the nerve for the popliteus; the nerves for the deep layer of muscles; the internal calcaneal nerve. Lastly, several very small filaments come off from the nerve, run along the posterior tibial artery, and, after a course of variable length, perforate the aponeurosis and ramify in the skin.

The *nerve for the popliteus* arises opposite the knee-joint, runs forward on the outer side of the popliteal vessels to gain the lower border of the muscle, around which it turns; before entering the muscle, the nerve expands into several branches, all of which pass horizontally forward opposite to the interosseous ligament, which they appear to perforate. But with a little care it is seen that almost all of these filaments are lost in the muscle. I have, however, seen one of them perforate the interosseous ligament together with the anterior tibial artery, and then, leaving that vessel, return through the substance of the ligament, and terminate in the tibialis posticus; several filaments of the popliteal nerve are also evidently distributed to the peroneo-tibial articulation, and to the periosteum of the tibia and fibula.

The *nerves for the deep layer of muscles of the leg* consist of two sets. The *nerve for the tibialis posticus* almost always arises by a common trunk with the preceding, runs downward and forward, is applied to the posterior surface of the muscle, to which it gives a series of filaments from its anterior aspect; the continuation of the nerve enters the muscle about its middle, and may be traced in it as far as its lower part. The *nerves for the flexor longus pollicis* and for the *flexor communis* arise by a common trunk a little below the preceding; the nerve for the flexor longus pollicis, which is larger than those for the flexor communis and tibialis posticus, accompanies the peroneal artery as far as the lower part of the leg.

The Internal Calcaneal Nerve.—This is a large branch which comes off from the inner side of the posterior tibial nerve, and which, in cases of premature bifurcation of that nerve into the internal and external plantar, comes from the external plantar; it passes vertically downward, on the inner side of the os calcis, and divides into two diverging branches, which are applied to the inner side of the bone, are reflected upon its lower surface, and are distributed to the skin of the heel, one in front, and the other behind.

The Terminal Branches of the Internal Popliteal Nerve.

The Internal Plantar Nerve.

The *internal plantar nerve*, which is intended for the muscles and skin of the sole of the foot, is larger than the external plantar; at its origin it is situated behind the internal malleolus, in front of the posterior tibial vessels, which cross it at an acute angle, and occupies a groove which is common to it and to those vessels, and which is quite distinct from and lies behind the groove for the tendons. It is reflected beneath the internal malleolus, becomes horizontal, reaches the calcaneal groove, perforates the posterior extremity of the flexor brevis digitorum, and during this passage through the groove is protected by a fibrous canal, which is subjacent to the grooves for the tendons.

At its exit from this fibrous canal, the internal plantar nerve is situated upon the boundary, between the internal and middle plantar regions, between the flexor brevis pollicis on the inside, and the flexor brevis digitorum on the outside; having given off a considerable branch (*a*, *fig.* 294), which becomes the *internal plantar collateral nerve of the great toe*, it perforates the aponeurosis of the flexor brevis digitorum to enter the same sheath as that muscle, and runs (*b*) along its inner border. Having reached the posterior extremity of the metatarsal bones, it divides into three branches, which form the collateral nerves of the toes. Sometimes there is a fourth branch (*d*), which passes outward, to anastomose with the external plantar nerve.

Fig. 294.

The *collateral branches* are very numerous. Some of them are *cutaneous*, and perforate the plantar fascia to ramify in the skin. The most remarkable are, a small *calcaneal cutaneous nerve*, which crosses the posterior tibial vessels, to supply the skin upon the inner side of the os calcis; and a *plantar cutaneous nerve*, which emerges between the flexor brevis pollicis and the flexor brevis digitorum, and divides into two small cutaneous branches, one of which proceeds forward, while the other runs backward, like a recurrent nerve. There are also some *muscular collateral branches*, namely, *for the flexor brevis pollicis*, the *abductor pollicis*, and *the flexor brevis digitorum*. Lastly, the *internal plantar collateral nerve of the great toe* (*a*), which is so large that it might be regarded as a terminal branch of the internal plantar nerve; it comes off from the last-

named nerve, at its exit from the covered canal formed for it by the flexor brevis pollicis, passes forward along the outer side of the tendon of the flexor longus pollicis, below, *i. e.*, superficial to the inner portion of the adductor pollicis (oblique adducteur, *Cruveilhier*), and gains the inner and under surface of the metatarso-phalangal articulation of the great toe; in this place it is situated in the furrow between the internal and external sesamoid bones of that articulation; it runs forward below the inner border of the former, and then of the second phalanx of the great toe, and, having arrived below that bone, it divides, like the collateral nerves of the fingers, into two branches, the one *dorsal* or *ungual*, and the other *plantar*.

The *terminal branches of the internal plantar nerve* are three in number, and are distinguished as the first, second, and third, counting from within outward.

The *first terminal branch*, which is the largest, runs along the outer side of the tendon of the flexor longus pollicis, gives filaments to that muscle, passes between the metatarso-phalangal articulations of the first and second toes, under an arch which is common to it and the corresponding vessels, and divides into two secondary branches, which form the *external collateral nerve of the great toe*, and the *internal collateral nerve of the second toe*. Not unfrequently this branch gives an anastomotic filament to the internal collateral nerve of the great toe, which passes beneath the metatarso-phalangal articulation of that toe.

The first terminal branch of the internal plantar nerve gives off the *filament for the first lumbricalis*; it then supplies several *articular twigs* to the metatarso-phalangal articulation of the great toe, and a very numerous series of *cutaneous* filaments.

The *second terminal branch*, much smaller than the preceding, passes somewhat outward, crossing below, *i. e.*, superficial to the flexor tendon of the second toe, and then forward, and bifurcates opposite the metatarso-phalangal articulations, to constitute the *external plantar collateral nerve* of the second toe, and the *internal plantar collateral nerve* of the third.

During its course, this branch supplies filaments to the *second lumbricalis*, to the metatarso-phalangal articulation of the second toe, and also to the integuments.

The third terminal branch passes very obliquely outward, crosses below the flexor tendon of the third toe, and bifurcates to form the *external collateral nerve of the third* and the *internal collateral nerve of the fourth toe*.

This branch supplies the metatarso-phalangal articulations of the third and fourth toes, and the corresponding integuments.

Summary.—The internal plantar nerve, therefore, supplies branches to the skin on the inner part of the sole of the foot, also the plantar collateral nerves of the first, second, and third toes, and the internal collateral nerve of the fourth toe, all of which are cutaneous branches.

It gives *muscular branches* to the flexor brevis pollicis, the abductor pollicis, the flexor brevis digitorum, and to the two internal lumbricales.

Lastly, it gives off a great number of *articular filaments* to the tarsal, tarso-metatarsal, metatarso-phalangal, and phalangal articulations.

The External Plantar Nerve.

The *external plantar nerve* (*c*, *fig.* 294), which is smaller than the internal, is placed with it in the groove of the os calcis, and perforates the flexor brevis, under an arch distinct from that for the internal plantar, and which is common to it and the external plantar vessels; it then runs downward and outward, between the flexor brevis and flexor accessorius, is reflected forward, and divides into two branches, a *superficial* and a *deep*.

Collateral Branches.—During its course, the external plantar nerve gives off, immediately after its origin, one large branch, which runs horizontally outward, in front of the tuberosities of the os calcis, passes under the flexor accessorius, and is reflected forward to enter the *abductor minimi digiti*. At the point of its reflection, it gives off a transverse branch, which is lost in the posterior attachment of the muscle. The external plantar also supplies the nerve or *nerves for the flexor accessorius*.

Terminal Branches.—The *superficial terminal branch* (*c*, *fig.* 294), which is the continuation of the trunk of the nerve, divides into two others, one external, the other internal.

The *external branch* passes very obliquely outward, below the flexor brevis digiti minimi, crosses the tendon of the abductor brevis obliquely, then runs along the outer side of the fifth metatarso-phalangal articulation, and forms the *external collateral nerve of the little toe*. It supplies a great number of cutaneous nerves, also the nerves for the *flexor brevis digiti minimi*, those for the *interosseous muscles* of the fourth space, and, lastly, some *articular filaments*.

The *internal branch* passes forward, below the flexor tendon, following the original direction of the superficial branch of the external plantar, and, after a rather long course, bifurcates to form the *internal collateral nerve of the little toe*, and the *external collateral nerve of the fourth toe*; like the external branch, it also gives off some cutaneous and articular nerves.

The *deep terminal branch* of the external plantar passes above, *i. e.*, deeper than the

flexor accessorius, changes its direction, so as to describe an arch, having its concavity turned inward and backward, and the convexity outward and forward, enters, together with the external plantar artery, above which it is situated, between the adductor pollicis and the interossei, and is lost in the former muscle.

Before reaching the adductor pollicis it gives off some *articular filaments* to the metatarsal and tarso-metatarsal articulations, and also a filament for the fourth lumbricalis. Beyond the adductor pollicis the nerve gives off the *filament for the third lumbricalis*; this filament, which is remarkable for the length of its course, passes horizontally forward, opposite to the third interosseous space, and passes through the fibres of the transversus pedis, to reach its destination; it then gives off the *filaments for the transversus*, and those for the *interosseous muscles of the third, second, and first spaces*.

Summary of the External Plantar Nerve.—The external plantar nerve, therefore, supplies *cutaneous filaments* to the outer side of the sole of the foot, to the fifth toe, of which it forms both collateral nerves, and to the fourth toe, of which it forms the external collateral nerve. It also gives off *muscular nerves* to the flexor accessorius, the flexor brevis, and abductor digiti minimi, to the adductor pollicis, and transversus pedis, to all the interossei, and to the two external lumbricales. Lastly, it furnishes some *articular filaments*.

Summary of the Nerves of the Lower Extremity.—The lower extremity is supplied with nerves from the lumbar and sacral plexuses.

The Lumbar Plexus.—The lumbar plexus gives almost all its branches to the lower extremity, viz., the external and internal inguinal nerves, the obturator nerve, and the crural nerve; the lumbo-sacral cord is also distributed to the lower extremity through the medium of the sacral plexus.

The external and internal inguinal nerves are the principal cutaneous nerves of the anterior and external regions of the thigh; the obturator nerve is a muscular nerve intended for the obturator externus, the three adductors, and the gracilis.*

The crural nerve is a musculo-cutaneous nerve which supplies the following parts: its cutaneous portion is distributed to the skin upon the anterior region of the thigh, upon the internal region of the leg, and internal dorsal region of the foot; its muscular portion supplies all the muscles of the anterior region of the thigh;† it also gives several articular nerves to the hip and knee joints.

The Sacral Plexus.—The sacral plexus is entirely distributed to the lower extremity, excepting the internal pudic nerve and certain rectal and vesico-prostatic branches in the male, and rectal, vaginal, and uterine branches in the female.

The obturator internus, the pyriformis, the gemelli, and the quadratus femoris, are each provided with a special nerve from the sacral plexus; the glutæus medius and minimus, and the tensor vaginæ femoris, are especially supplied by the superior gluteal nerve, and the glutæus maximus by the inferior gluteal or lesser sciatic nerve. The last-named nerve also furnishes the cutaneous nerves of the posterior region of the thigh.

The great sciatic is the nerve of the posterior region of the thigh, and of the entire leg and foot. It supplies all the muscles of the posterior region of the thigh; thus, its *external popliteal* or *peroneal division* supplies the muscles of the external region of the leg by its musculo-cutaneous branch, and the muscles of the anterior region by its interosseous branch; it also supplies the external region of the leg, and the dorsal region of the foot.

Its *internal popliteal* or *tibial division* supplies all the muscles of the posterior region of the leg, the skin upon the internal and external calcaneal regions, and that upon the external dorsal region of the foot.

Of its terminal branches, the *internal plantar nerve* is distributed to the muscles of the internal plantar region of the foot, to the flexor brevis digitorum, to the two internal lumbricales, and to the skin of the internal plantar region; lastly, it gives off the collateral branches of the toes, excepting the two for the fifth toe, and the external collateral branch of the fourth.

The *external plantar nerve* is distributed to the muscles of the external plantar region, to the flexor accessorius, to all the interossei, to the two external lumbricales, to the adductor pollicis and transversus pedis, and to the skin of the external plantar region: it also gives the internal and external collateral nerves of the fifth toe, and the external collateral nerve of the fourth.

Comparison of the Nerves of the Upper and Lower Extremities.

The lumbo-sacral plexus, which supplies the whole of the lower extremity, precisely corresponds to the cervico-brachial, which supplies the upper extremity. The lumbar corresponds to the cervical, and the sacral to the brachial plexus. The connexion, or sort of fusion of the cervical with the brachial plexus, and of the lumbar with the sacral plexus, explains why it is found, on comparing the nerves of the upper and lower extrem-

* [The obturator also supplies part of the pectineus, and sometimes gives cutaneous branches to the thigh and leg, and an articular filament to the knee (see note ‖, p. 800).]

† [And also a few filaments to the iliacus, psoas, and pectineus.]

ity, that several of the nerves arising from the brachial plexus are represented by nerves from the sacral plexus, and that several of those from the cervical plexus have their representatives in nerves derived from the lumbar plexus. It will be seen, moreover, that this analogy ought not to be carried too far, and that it is necessary, in making the comparison, to exclude all nerves which belong to peculiar organs in both regions. Thus, the phrenic, occipital, and auricular nerves, branches of the cervical plexus, have no representatives in the lower extremity, nor is there any nerve in the upper extremity corresponding to the internal pudic.

On the other hand, there is no objection to admitting that the external and internal inguinal nerves in the lower extremity are represented by the clavicular nerves in the upper extremity.

The crural nerve, a branch of the lumbar plexus, has no corresponding branch in those of the cervical plexus, but its muscular branches are represented by the brachial portion of the musculo-spiral nerve, and its cutaneous branches by the internal brachial cutaneous. The crural nerve, in fact, supplies the muscles which extend the leg upon the thigh, in the same way that the musculo-spiral nerve supplies the muscles which extend the forearm upon the arm; the internal saphenous nerve supplies the skin of the leg, just as the internal brachial cutaneous is distributed to the skin of the forearm.

The obturator nerve, which supplies the adductors of the thigh, is represented by the thoracic nerves and the nerve for the latissimus dorsi, which supply the pectoralis major and latissimus dorsi, the adductor muscles of the arm.

The gluteal nerves are analogous to the supra-scapular and circumflex nerves. The superior gluteal, which is distributed to the glutæus medius and minimus, corresponds to the supra-scapular, which belongs to the supra- and infra-spinatus; and the inferior gluteal or lesser sciatic nerve, which supplies the glutæus maximus and the skin of the thigh, corresponds to the circumflex nerve, which is distributed to the deltoid, and the skin of the arm.

The trunk of the great sciatic nerve represents by itself the musculo-cutaneous, the ulnar, and the median nerves, and the musculo-spiral in the forearm.

The muscles of the anterior region of the arm, that is to say, the muscles that flex the forearm upon the arm, receive their branches from the musculo-cutaneous nerve, just as the muscles of the posterior region of the thigh, or the flexors of the leg upon the thigh, receive theirs from the great sciatic.

The external popliteal nerve represents the musculo-spiral in the forearm: the former supplies the muscles of the anterior and external regions of the leg, while the latter is distributed to the muscles of the posterior and external regions of the forearm; the former gives off the dorsal cutaneous nerves of the foot, and the latter furnishes the dorsal cutaneous nerves of the hand.

The internal popliteal nerve represents the median and ulnar nerves together. The muscles of the posterior region of the leg are supplied by the internal popliteal, as the muscles of the anterior region of the forearm are supplied by the median and the ulnar.

The internal popliteal nerve completes the series of dorsal cutaneous nerves of the foot, just as the ulnar nerve completes the dorsal nerves of the hand.

Lastly, the internal plantar nerve gives off all the plantar collateral nerves of the toes, excepting those for the little toe, and the external plantar collateral of the fourth toe; it therefore represents the palmar portion of the median nerve; and so the external plantar represents the palmar portion of the ulnar nerve, and completes the series of plantar collateral nerves.

THE CRANIAL NERVES.

Definition and Classification.—The Central Extremities of the Cranial Nerves—viz., of the Olfactory—of the Optic—of the Common Motor Oculi—of the Pathetic—of the Trigeminal—of the External Motor Oculi—of the Portio Dura and Portio Mollis of the Seventh—of the Glosso-pharyngeal, Pneumo-gastric, and Spinal Accessory Divisions of the Eighth—and of the Ninth Nerves.

The *cranial nerves* are those which pass through the foramina in the base of the cranium, not those which arise from the brain, as the rather generally adopted terms *cerebral nerves* and *encephalic nerves* would seem to indicate.

We shall follow Willis and the majority of anatomists in admitting nine pairs of cranial nerves, which are almost indifferently named, either numerically, from the order of their origin, counting from before backward, or they are named from their distribution and uses. The following exhibits their nomenclature upon both principles:

First pair, or olfactory nerves.
Second pair, or optic nerves.
Third pair, or common motor nerves of the eyes.
Fourth pair, or pathetic nerves, nervi trochleares.
Fifth pair, or trifacial nerves, nervi trigemini.

Sixth pair, or external motor nerves of the eyes, nervi abducentes.

Seventh pair, divided into { portio mollis, or auditory nerve, / portio dura, or facial nerve.

Eighth pair, divided into { pneumogastric nerve, or par vagum, / glosso-pharyngeal nerve, / spinal accessory nerve of Willis.

Ninth pair, or hypoglossal nerve.

Sœmmering has introduced the following modification of this nomenclature. He has divided the seventh pair into two, viz., the facial nerves, which form his seventh pair, and the auditory nerves, which he calls the eighth; and then he has divided the eighth pair into three others, namely, a ninth pair formed by the glosso-pharyngeal nerves, a tenth formed by the pneumogastric nerves, an eleventh by the spinal accessory nerves; the hypoglossal nerves, therefore, constitute his twelfth pair.

This modification is founded on the separation of nerves so completely distinct as the facial and the auditory, which have only been described together because they enter the same canal in the base of the cranium, namely, the internal auditory meatus.

Still, this modification is a useless one, and it has the greater inconvenience of rendering the language employed obscure, from giving a double acceptation to the same terms.

It would be more philosophical to name and describe the cranial nerves from behind forward, so that the hypoglossal nerves would constitute the first pair, and the olfactory the last.

The indisputable analogy which exists between the posterior cranial and the spinal nerves, and, moreover, the example of J. F. Meckel, would fully warrant this innovation. Nevertheless, I think it right to retain the old usage, and to proceed from before backward, in the enumeration as well as in the description of the nerves.

As the origins or central extremities of all the cranial nerves and their course within the cranium can be studied upon the same brain, I have thought it right to describe, in one article, all these origins or central extremities, which will mutually illustrate each other by their differences and their analogies: the experience of the dissecting-room proves, moreover, that, from want of a sufficient number of brains to study the origin of each nerve in particular, this part of anatomy is generally neglected.

The Central Extremities of the Cranial Nerves.

Dissection.—Two preparations are required, namely, a brain removed from the cranium, together with the origins of the nerves perfectly preserved; and the base of a cranium, together with those parts of the brain which are near the origin of the nerves. The first will serve for the examination of the central extremities of the nerves; and the second for tracing their course within the cranium.

While the origin of all the spinal nerves is uniform and regular, that of the cranial nerves appears to be subject to no rule; so that the cranial nerves differ as much from each other in regard to their origin as they differ collectively from the spinal nerves in the same particular. We shall see presently, however, that the origins of all but the special nerves of the head may, to a certain extent, be referred to the same law of double roots (one of which is ganglionic) which presides over the origin of the spinal nerves.

The Central Extremity of the Olfactory Nerve.

The *olfactory nerves*, or the *first pair of cranial nerves* (nerfs ethmoidaux, *Chauss.*, 1, *fig.* 276) are two bands, composed of white and gray substance, which arise from the hindermost convolution of the anterior lobe of the brain, run forward in the anfractuosity already described as the *anfractuosity of the olfactory nerves*, and expand in the ethmoidal groove into a sort of ganglion or *bulb*, from which filaments are given off to be distributed to the pituitary membrane.

In regard to their central extremity and their course within the cavity of the cranium, the olfactory nerves are singular, and their peculiarities justify the uncertainty which has for a long time prevailed, and still prevails, concerning their true character. The old anatomists did not regard them as nerves, but as prolongations of the brain, named by them *carunculæ* or *processus maxillares*, and believed to be intended to drain off the mucosity of that organ: it was Massa, according to Sprengel, and Zerbi, according to Haller, who first connected them with the other cranial nerves as the first pair. Comparative anatomy, which probably suggested to the older anatomists the opinion which they held concerning these nerves, has now caused some doubts as to the propriety of considering them as nerves, and has given rise to the opinion that they are the representatives of the *olfactory lobes* of the lower animals.* Without entering here into discussions which belong to philosophical anatomy, let us examine the most remarkable circumstances connected with the origin and cranial course of this nerve.

Apparent Origin.—The olfactory nerves arise from the cerebrum, and this is a char-

* When speaking of the comparative anatomy of the brain, it was mentioned that in a great number of animals there existed, in front of the cerebral lobes or hemispheres, a pair of lobes (*olfactory lobes*), which were continuous with the nerves distributed to the pituitary membrane, and the development of which corresponded to the size of those nerves, and to the relative state of perfection of the sense of smell.

acter which belongs exclusively to them; they are the only cerebral nerves, properly so called.

They arise from the hindermost convolution of the anterior lobe, in front of the anterior locus perforatus (*h*, *fig.* 276), which is situated behind that convolution. This origin consists of a mammilla or pyramidal enlargement, *gray pyramid*, which is regarded as the *gray root* of the nerve. This grayish enlargement, which can be very well seen by reflecting the nerve backward, is prolonged as a linear tract of gray substance upon the upper surface of the nerve.

Besides this gray enlargement or origin, which was so well described by Scarpa, there are two or three white roots, or, rather, certain white striæ, very accurately represented by Vicq d'Azyr; these are the *external* or *long root*, which is concealed in the fissure of Sylvius, and appears to me to arise from the posterior lobe [middle lobe] of the cerebrum, or, more exactly, from the posterior lip of the fissure of Sylvius; and the *internal* or *short root*, which arises from the innermost convolution of the anterior lobe and joins the long root at an acute angle; between these roots we often see one, two, or even three striæ, which come from the back part of the anterior lobe. It would be both useless and tedious to describe all the varieties of this origin.

Real Origin.—Anatomists have not confined themselves to the investigation of the apparent origin of the olfactory nerves, but have also endeavoured to ascertain their deep or real origin. Willis described them as arising from the medulla oblongata, Ridley from the corpus callosum, Vieussens, Winslow, and Monro from the corpora striata.*

If, after the example of Scarpa, a transverse perpendicular section of the brain be made opposite the junction of the gray and white roots of the olfactory nerves, or if a stream of water be directed upon the pyramidal mammilla above described, or, lastly, if Herbert Mayo's method be adopted, and the origin of this nerve be examined in a brain hardened in alcohol, it will be seen that, besides the white superficial striæ, there are a great number of deep and diverging white roots, which appear to me to come from the anterior commissure, and not from the corpus striatum.†

It would follow, therefore, that the olfactory nerves arise by a commissure like the optic nerves.

Cranial Course.—Having arisen in this manner by a sort of bulb or gray enlargement (*enlargement* or *bulb of origin*), the olfactory nerve immediately tapers, and is received into the antero-posterior sulcus intended for it, which conducts it as far as the ethmoidal groove or fossa (1, *fig.* 296), where it forms an enlargement or bulb, named the *ethmoidal bulb*, which is analogous in many respects to its bulb of origin.

When seen from below, the olfactory nerve has the appearance of a soft, smooth band, grooved longitudinally along the middle.‡

But, on reflecting the nerve backward, it is found to be prismatic and triangular, that its two lateral surfaces are concave and correspond to the convolutions which bound the antero-posterior sulcus for the nerve, and that its upper ridge is formed by a linear tract of gray matter which connects the gray substance of its bulb of origin with that of the ethmoidal bulb.

The arachnoid has a peculiar arrangement in relation to this nerve: instead of immediately forming a sheath for it, the arachnoid passes below it, and maintains it in contact with its protecting sulcus; while the pia mater passes above it, and lines the sulcus. The nerve is not entirely separated from the brain until about a few lines from the ethmoidal bulb.

In the human subject the olfactory nerve is not hollow in its centre, as in the mammalia; when hardened by alcohol, it may be decomposed into white parallel fibres, exactly similar to the fibres of the white substance of the brain.

The Ethmoidal Bulb or Enlargements.—The olfactory nerves, converging towards each other, reach the ethmoidal fossæ, where each immediately expands into an olive-shaped, ash-coloured, and extremely soft bulb (the ethmoidal bulb, 1, *fig.* 276), to which Malacarne first applied the term ganglion, and which is formed in the following manner: The white filaments of which the olfactory band or prism is composed spread out like a palm branch as they are about to enter the bulb, and dip into the gray or ash-coloured substance, which occupies the intervals between them: this substance is precisely analogous to the gray matter of the brain, but is less consistent; it also resembles the substance of the nervous ganglia, so that Scarpa does not hesitate to regard the ethmoid bulb as a ganglion. From this enlargement are given off the olfactory nerves properly so called, which seem as if they were pressed through the foramina of the cribriform

* Chaussier, who adopted the latter opinion, called the corpora striata the *olfactory lobes*, in contradistinction to the optic thalami, which he terms the optic lobes. But comparative anatomy shows that there is no relation in point of development between the corpora striata and the olfactory nerves.

† Scarpa says that the deep roots come from a white cord placed in front and below the corpora striata. Herbert Mayo, in his beautiful plates, has represented these roots as coming from the corpora striata.

‡ Willis and Santorini have noticed this groove. Scarpa has observed three grooves, which he regards as corresponding to as many lines of gray substance. M. Hippolyte Cloquet (*Anat. Descript.*, t. ii., p. 88) goes still farther than Scarpa, and describes seven longitudinal striæ, three of which are gray, and four white. Scarpa has very justly remarked, that the proportion of ash-coloured or gray substance is much more considerable in the fœtus, that it diminishes in the adult, and that it scarcely, if at all, exists in the old subject.

plate of the ethmoid bone. It is said that the gray matter sends prolongations through these foramina, but this has not been demonstrated.

The Central Extremity of the Optic Nerve.

The *optic nerves*, or *second pair* (2, *fig.* 276), present certain peculiarities in their texture, and in their cranial course, which distinguish them from all other nerves.

They have this peculiar character, that they arise by a commissure (the optic commissure), or, rather, the two optic nerves unite before they pass to their respective destinations.

On turning the cerebellum forward, it is seen that the optic tracts (2, *fig.* 295) are continuous with the corpora geniculata externa (*b*), and, consequently, take their origin from the optic thalami (*a*), of which these bodies are a dependance. In some cases, the white riband-like band, or *optic tract*, which constitutes the origin of the optic nerve, is also continuous with the corpus geniculatum internum (*c*). In the human subject, the optic nerves never arise, either entirely or in part, from the anterior tubercula quadrigemina (nates); it is only by induction that this mode of origin has been admitted in the human subject.*

The optic tract (2, *fig.* 272), having arisen from the corpus geniculatum externum (above *i*), with which it is continuous, without any other line of demarcation excepting the difference of colour, assumes the appearance of a thin and broad riband, which turns round the cerebral peduncle (*v*), parallel to and on the inner side of the great transverse fissure of the brain. During this course, it lies in contact with the peduncle of the cerebrum, from which it may be separated without laceration, excepting at its outer border, by which it adheres so intimately that the peduncle has been supposed to supply it with several roots.

As soon as it gets beyond the peduncle, the optic tract (*s*, *fig.* 276) is condensed into a flat cord, which leaves the peduncle, passes inward and forward, and unites with its fellow of the opposite side to form the *chiasma* (square space of Zinn, *t*), or, rather, to form, with the optic tract of the opposite side, a commissure which is convex in front and concave behind.

On leaving the commissure, it completely changes its direction (2), passing forward and outward, to enter almost immediately into the optic foramen (2, *fig.* 296).

During its course in front of the peduncle of the cerebrum, it is in relation with the following parts: *behind*, with the tuber cinereum (*v*), from the interior of which some white fibres arise, and pass to the chiasma; *in front*, with the membrane which forms the anterior portion of the floor of the third ventricle, and which is prolonged upon the upper surface of the chiasma.

An important question here presents itself, viz., Is there a complete or partial decussation of the optic nerves in the commissure? Do these two nerves interlace without decussating, or, rather, is there an intimate mixture of their fibres? Are the nerves placed in simple juxtaposition and united by a transverse band? Lastly, does the chiasma constitute a commissure in which the two optic tracts terminate, or, rather, which serves as a point of origin for the optic nerves? All these opinions have found supporters, and facts have been quoted in favour of each; a circumstance which proves, not that there are anatomical varieties in the structure of the chiasma, but that its structure is of a complex nature.

Comparative anatomy proves that the optic nerves decussate in the commissure: in fishes, the two nerves cross without uniting: it is also proved by pathological facts; in a great number of cases of atrophy of one eye, atrophy of the nerve extended, beyond the commissure, to the opposite optic tract.

On the other hand, in an equally large number of cases of atrophy of one eye, the disease affected the optic tract of the same side, so that this would seem to show that there was no decussation.

Lastly, in all cases of atrophy of one eye, the disease affects one of the optic nerves in particular, but the other has always appeared to me to be evidently reduced in size.

On attempting to determine the point, either by the dissection of optic nerves hardened in alcohol, or unravelled by means of a stream of water, it is seen that these nerves present the following threefold arrangement at the commissure: The external fibres of

* The origin of the optic nerves varies in the different classes of animals. In birds, in which these nerves are at their maximum development, they arise entirely from the tubercula quadrigemina, which are the *optic lobes* in these animals, and are transposed from the side to the base of the brain. The optic thalami do not assist in forming these nerves. In rodentia, a small number of fibres from the optic thalami join the mass of those which are derived from the nates. In carnivora, the number of filaments from the tubercula quadrigemina and from the optic thalami are almost equal. Moreover, if it be remembered that the tubercula quadrigemina, the corpora geniculata externa and interna, and the optic thalami themselves, belong to the same system of organs, and form a continuation of the re-enforcing fasciculi (*faisceux innominés*) of the medulla oblongata; and if other facts confirmatory of the preceding also be taken into consideration, namely, that a white band proceeds on each side from the natis to the corpus geniculatum externum, and another from the testis to the corpus geniculatum internum, it will be easy to account for these varieties of origin, which can all be reduced to the same type. It is of some importance in regard to this question, that in a great number of cases of atrophy of the optic nerve, which I have had occasion to examine in the human subject, the corpus geniculatum was affected, and not the natis.

the commissure do not decussate ; the internal fibres (and these are the most numerous) do decussate ; and the posterior fibres are continued from one side to the other like a commissure.

Structure.—The optic nerve has a peculiar structure. It does not commence by filaments of origin or distinct cords, like the other nerves, but the optic tracts and the optic commissure are composed of two medullary bands, the fibres of which are parallel and in immediate contact with each other, precisely as in the olfactory nerves, and in the cerebral substance ;* after leaving the commissure, the optic nerves are enveloped in a neurilemmatic sheath, from the internal surface of which certain prolongations or septa are given off, which divide the interior of the nerve into longitudinal canals, in which the medullary substance is contained.

The optic nerve, therefore, does not consist, like other nerves, of a plexiform group of nervous filaments or cords, but of a collection of canals closely applied to each other, so that it has the appearance of the pith of the rush ; hence, doubtless, the opinion of Eustachius and some other authors who conceived that the optic nerve was traversed by canals ; and hence, also, the error of Reil, who, having taken the structure of the optic nerve as the type of that of all nerves, regarded each nervous cord as containing a central canal.†

The Central Extremity of the Common Motor Nerve of the Eye.

The *apparent origin* of the *motor nerves of the eyes* (3, *fig.* 276), motores oculorum, *common oculo-muscular* nerve, or third pair, have a penicillate character ; these origins consist of a linear series of very delicate filaments proceeding from the fasciculi found between the peduncles of the cerebrum, in the depression between the pons Varolii and the corpora albicantia. Some filaments converge from the cerebral peduncles themselves.‡ This origin extends about a line and a half, in a direction obliquely inward and forward. The internal filaments of origin reach the middle line, so that Varolius and Vieussens believed that the nerves of the right and left sides are continuous, and explained the simultaneous action of the two eyes by this anatomical arrangement.

Real Origin.—In a brain hardened by alcohol, or, still better, in the brain of a fœtus, the filaments of origin of the nerve (3, *fig.* 295) can be easily traced into the substance of the median fasciculi (*d*) found between the peduncles of the cerebrum, and which have already been shown to be prolongations of the fasciculi of re-enforcement (*faisceaux innominés*) of the medulla oblongata. The filaments of the nerves traverse these fasciculi in a diverging manner, and descend to a level with the pons, beyond which I have not been able to trace them, on account of their slenderness and divergence. I have never observed any of them running towards the corpora albicantia, and reaching the walls of the third ventricle or the anterior commissure, as has been stated by some. Nor have I found that they are re-enforced, as Gall believed, in the blackish substance (*locus niger*) which separates the peduncles of the cerebrum, properly so called, from the prolongations of the re-enforcing fasciculi of the medulla oblongata.

Fig. 295.

Cranial Course.—Having arisen in this manner, the fibres of the motor oculi nerve converge into a flat bundle, which passes between the posterior cerebral and the superior cerebellar arteries, upon which latter it is reflected : on emerging from the interval between these two vessels it becomes rounded, and then passing upward, outward, and forward, enters the reticular sub-arachnoid cellular tissue at the base of the brain, and gains the side of the sella turcica (3, *fig.* 296), where it enters a proper sheath formed for it by the dura mater.

The Central Extremity of the Pathetic Nerve.

The *nervi pathetici* (4, *fig.* 276), *nerves of the superior oblique muscle of the eyes, nervi trochleares, the internal and superior oculo-muscular* nerves, or the fourth pair, as they are variously called, are the smallest of the cranial nerves, and are as remarkable for being

* See note, p. 767.

† In most fishes, whose faculty of vision is exercised in a less transparent medium than air, the optic nerve is formed by a membrane folded upon itself. In birds of prey, the membrane is sometimes folded like a fan, sometimes like the leaves of a book. These folds are intended to increase the extent of surface, and to augment the power of vision. Malpighi first made this observation upon the optic nerve of some fishes. Desmoulins, who has studied the point more carefully, has shown that it is in relation with the perfection of the sense of sight. The same thing is also observed in the retina : thus, in the eagle, the retina presents two, three, or four superimposed folds, so that each luminous ray acts upon sixteen surfaces instead of upon two.

‡ In fact, the external filaments often arise from the inner border, and even from the lower surface of the cerebral peduncle, at a certain distance from the inner border ; in this case, they do not arise from the peduncles, but merely pass through them. The same is doubtless the case with the filaments of origin which Ridley and Molinelli state that they have seen coming from the pons. I have never met with this origin from the pons, nor with that accessory nerve which Malacarne has described as proceeding from the upper part of the peduncle of the cerebellum, turning round the border of the pons, and joining the motor oculi nerve.

exclusively distributed to the superior oblique muscle of the eyes, as for their origin and for the length of their course within the cranium. The term *patheticus* is derived from the opinion that the superior oblique muscle is especially concerned in the expression of love and of compassion. According to Bell, this nerve is the *respiratory nerve of the eye.*

The *apparent origin* of this (4, *fig.* 280) nerve is below the tubercula quadrigemina, on each side of the valve of Vieussens, sometimes by one, sometimes by two, and even by three or four roots. Occasionally there are several roots on one side, and only a single root on the other. The nerves of the two sides are often united by some white streaks, which form a transverse commissure; at other times they do not arise at the same level.

Real Origin.—It has been supposed that some fibres come from the testes, others from the cerebellum, and that others commence much lower down than the apparent origin: all that can be seen is, that these nerves (4, *fig.* 295) arise from the valve of Vieussens, to which they adhere so slightly that the least force is sufficient to detach them.

Cranial Course.—Immediately after its origin, the pathetic nerve turns forward and downward, around the isthmus of the encephalon, in front of the anterior border of the cerebellum, and thus reaches the base of the cranium (4, *fig.* 276), accompanied by the superior cerebellar artery, between the fifth and third cranial nerve, but much nearer to the fifth; it then passes directly forward upon the side of the sella turcica (4, *fig.* 296), and perforates the dura mater, considerably below the third nerve. During its whole course, it is situated between the arachnoid and the pia mater, in the reticular cellular tissue found in this region.

Wrisberg says that the right pathetic nerve is larger than the left. Ruysch states that he found this nerve double, which it is difficult to believe, unless he meant to say that it bifurcated at its origin. Vesalius regarded this nerve as a root of the third cranial nerve; other anatomists have considered it as a dependance of the fifth.

The Central Extremity of the Trigeminal Nerve.

Apparent Origin.—The *trigeminal* or *trifacial nerves* (5, *fig.* 276), the *middle sympathetic*, or the fifth pair, are the largest of the cranial nerves, excepting the optic: they arise at the sides of the pons Varolii, at the point where the pons becomes continuous with the corresponding peduncles of the cerebellum, and exactly where the middle fibres of the pons cross in front of the inferior, to form that peduncle, so that the fasciculi of origin appear to converge from a narrow slit in the pons itself. This origin (5, *fig.* 295) consists of two roots, the *large* and the *small* root, which have a small prominence between them. The *large* or *ganglionic root* is a thick, fasciculated mass, which is, as it were, constricted at its point of emergence, but immediately expands into a thick, flat bundle, in which we may count about 100 fibres. On tearing off this bundle, all the fibres do not give way opposite the same place, and a sort of mammillary prominence is left, which Bichat regarded as belonging to the pons, as intended for the nerve to arise from, and as having the effect of multiplying the surfaces of origin, in consequence of its convexity.

The *small root*, which is non-ganglionic, is composed of small and very distinct bundles, which arise from the pons, above and behind the great root, by several cords; it emerges from the pons through a fissure distinct from that for the great root, and gains the upper border of that root.

It will hereafter be seen that the small root has no share in the formation of the gangliform plexus known by the name of the *semilunar* or *Gasserian ganglion*, and that it goes exclusively to assist in forming the *inferior maxillary* division of the fifth nerve.

Real Origin.—Until modern times, the origin of the fifth nerve had not been traced beyond the point of its emergence. Late authors have described its real origin with so much detail that little remains to be desired. Gall, while examining the fifth nerve, first in mammalia and then in the human subject, saw that in many the origin of the nerve is concealed by certain transverse fibres of the pons which do not exist in the lower animals. Having traced the nerve by clearing off the fibres of the pons, he thought he observed that the great root divided into three principal fasciculi, which he conceived arose in succession from the gray matter of the pons, and which he succeeded in tracing as far as to the outer side of the olivary body.*

Rolando, by successive sections made through the pons towards the medulla oblongata, has clearly shown that the great root of the fifth nerve consists of only one fasciculus, which runs downward and backward, under the form of a thick cord (see *fig.* 295), in the substance of the pons, or, rather, at the boundary between the pons and the middle peduncle of the cerebellum, parallel to the fasciculi of the anterior pyramid, and that it progressively diminishes in size, until it disappears opposite to the inferior angle of the fourth ventricle. The examination of this origin in a brain hardened by alcohol, or, still better, in the fœtal brain, confirms Rolando's observations, and proves that the great root of the

* In the human subject, the origin of the fifth nerve is extremely deep-seated; it is not so deep in the carnivora, and still more superficial in ruminantia. In oviparous animals, which have neither a pons Varolii, nor lateral lobes of the cerebellum, nor pyramids, nor olivary bodies, the origin of the fifth pair is seen without any dissection.

Fig. 296.

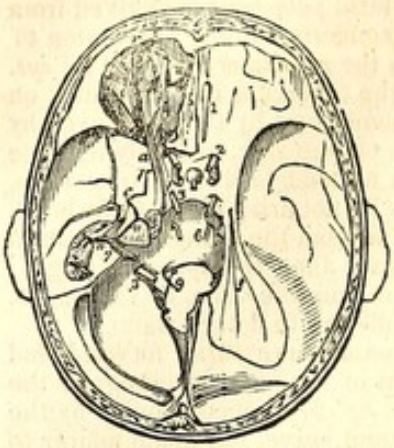

fifth nerve comes from the back part of the medulla oblongata, from the interior of its fasciculi of re-enforcement (*faisceaux innominés*).* As to the small root, it cannot be traced beyond the surface of the pons.†

Cranial Course.—After emerging from the pons, the fifth nerve passes upward, outward, and forward, under the form of a flattened bundle, gains the upper border of the petrous portion of the temporal bone (5, *fig.* 296), on which there is a depression that is converted into a canal for the nerve by a fold of the dura mater; the nerve is reflected upon this border, and proceeds as will presently be described.

The Central Extremity of the External Motor Nerve of the Eye.

The *external motor nerves of the eye* (6, *figs.* 276, 295), *external oculo-muscular* nerves, nervi abducentes, or the sixth pair, which are distributed exclusively to the external rectus or abductor muscle of each eye, and which are so remarkable for their communications with the sympathetic system, are smaller than all the cranial nerves, excepting the pathetic.

Apparent Origin.—The statements of authors regarding the apparent origin of this nerve have been singularly various: some, with Morgagni, describe it as arising both from the pons and the anterior pyramids; others, with Vieussens, from the pons alone; and others, with Lieutaud, from the anterior pyramids only. Winslow states that it arises between the pons Varolii and the olivary body, and Haller, that it proceeds from the furrow between the anterior pyramid and the pons.

The fact is that this nerve, among some varieties of origin, presents two very distinct roots (see *fig.* 276): one *internal* and smaller, which arises from the pons, either at or near its lower border; the other *external* and larger, which appears to emerge on the outer side of the upper part of the anterior pyramid. These two roots are fasciculated: not unfrequently some fibres are seen arising from the olivary body, or from the furrow between the two pyramids.

Real Origin.—This is more easily seen in mammalia generally than in man. In the former, Gall has traced it along the side of the pyramids. Mayo believes that the fibres traverse the pons, and pass to the back part of the medulla oblongata. From the tenuity and whiteness of the fibres of this nerve, I have not been able to trace their course in the substance of the medulla.

Cranial Course.—This nerve runs upward and a little outward, on the side of the basilar groove, and perforates the dura mater (6, *fig.* 296) opposite to and above the apex of the petrous portion of the temporal bone, to enter the cavernous sinus: the two roots of the nerve often unite before perforating the dura mater, but they usually pass separately through it and unite within the sinus.

The Central Extremity of the Seventh Nerve.

The *central extremity of the facial nerve*, or *portio dura of the seventh nerve* (7, *fig.* 270, 276). The facial nerve (on the inner side of 7) arises in the deep depression between the middle peduncle of the cerebellum and the pons in front of the auditory nerve (on the outer side of 7): it emerges from the front of the restiform body, under the form of a fasciculated band, some fibres of which are at first situated at a distance from the general mass, but soon join it; it then turns round the lower borders of the peduncle of the cerebellum, against which it is closely applied, and then becoming free, passes outward and upward. It has no neurilemma up to the point where it becomes free.

The *real origin* of this nerve (7, *fig.* 295) is much deeper; it may be traced through the restiform body into the fasciculus of re-enforcement, near the median furrow of the calamus scriptorius.

The Central Extremity of the Auditory Nerve.—The *auditory nerve*, or *portio mollis of the seventh* (on the outer side of 7, *fig.* 275), is riband-shaped, and non-fasciculated at its origin: it arises (7′, *fig.* 295) in the same depression as the facial nerve, but behind that nerve, and opposite to the restiform body: it presents two very distinct roots: an anterior, which is arranged like the facial nerve; and a posterior, which turns horizontally round the back part of the restiform body, appears upon the posterior surface of the medulla oblongata (see *fig.* 271), and separates into fibres, which may be traced as far as the me-

* Vicq d'Azyr says that the roots of this nerve extend as far as the cerebellum, but this assertion has not been verified. The same anatomist declares that he has often seen the fifth nerve of the right side larger than that of the left.

† According to Dr. Alcock, there is a slight enlargement at the origin of the large root of the fifth nerve, in the lower part of the floor of the fourth ventricle; he has also traced the small root to this enlargement, from which he states that two cords descend, one to the anterior, the other to the posterior column of the cord.—(*Cyclop. of Anat. and Phys.*, art. FIFTH PAIR OF NERVES.)

dian furrow of the calamus scriptorius, and which represent some of the barbs of the quill. It is very generally admitted that the auditory nerves have a tranverse commissure, but this does not appear to me to be clearly demonstrated.

The portio dura and the portio mollis of the seventh nerve, which arise so near to each other, follow the same *cranial course:* they arise at the same height from the medulla oblongata, pass outward and upward in front of the pneumogastric or sub-peduncular lobule of the cerebellum, and enter the internal auditory meatus (7, *fig.* 296). During this course, the portio dura always lies in front of the portio mollis.

The auditory nerve is the softest of all the cranial nerves; the difference between it and the facial nerve, in this respect, has led, in a great measure, to the subdivision of the nerves into the soft or sensory, and the hard or motor.

The Central Extremity of the Eighth Nerve.

Of the three nerves on each side which together constitute the eighth nerve (8, *figs.* 270, 276, 295), the *glosso-pharyngeal* is the highest, the *pneumogastric* is the next, and the *spinal accessory* is the lowest.

The Central Extremity of the Glosso-pharyngeal and Pneumogastric Nerves.—The *glosso-pharyngeal* and *pneumogastric nerves* have a common origin. They arise, like the spinal nerves, by a linear series of funiculi (see *fig.* 270), which come off, not from the furrows between the olivary and restiform bodies, but from the restiform body itself, on a line with the auditory nerves. Sœmmering states that he has seen some of these funiculi arise from the anterior wall of the fourth ventricle.

Moreover, as in the spinal nerves, each funiculus of origin is formed by the union of two or three converging filaments; the funiculi of the glosso-pharyngeal nerve, which are the highest, and which come off immediately below the auditory nerve, are not distinct at their origin from those of the pneumogastric; nor, as will presently be stated, are the funiculi of origin of the pneumogastric distinct from those of the spinal accessory. The *division* into the three nerves cannot be made until after the funiculi are finally grouped.

It has been stated, but without proof, that the fibres of the glosso-pharyngeal and pneumogastric nerves might be traced through the restiform body as far as the back of the medulla oblongata. The funiculi of origin of these nerves, which are enveloped by the neurilemma at the point where they emerge from the medulla, are so small that, when torn off, scarcely any trace of their points of attachment can be detected even by the aid of a lens.

The Central Extremity of the Spinal Accessory Nerve of Willis.—The *origin of the spinal accessory nerve* (*s*, *fig.* 295) is quite peculiar, and has obtained much notice from modern anatomists.

It arises from the sides of the cervical region of the spinal cord, between the anterior and posterior roots of the cervical nerves, and behind the ligamentum denticulatum. Sir C. Bell, who classes it among the respiratory nerves, strongly insists upon its origin from that column of the cord which is situated between the anterior and posterior columns, in a line with the pneumogastric and facial nerves, which column (the *respiratory tract*) he assumes to give origin solely to the respiratory nerves. The funiculi of origin of the spinal accessory vary much both in number and size, and are widely separated from each other: the lowest as well as the highest funiculi appear to me to be continuous with the posterior roots of the spinal nerves; and, again, the highest are continuous above with those of the pneumogastric nerve, and appear to me to establish a transition between the origin of that nerve and the posterior roots of the spinal nerves.

The lowest funiculus of the spinal accessory is generally situated not lower than the fifth cervical nerve; it has been seen to arise opposite the sixth, and even the seventh cervical nerve; the latter is the normal condition in the ox.

It is of importance to remark the connexion which exists between the spinal accessory nerve and the first cervical or sub-occipital nerve. Almost always one or two, and frequently all of the posterior funiculi of the sub-occipital, join the spinal accessory. Not unfrequently a small funiculus joins the spinal accessory from the second cervical nerve. Opposite its connexion with the sub-occipital nerve, the spinal accessory sometimes presents a gangliform enlargement, which was well described by Huber (*in ganglion vix hordeaceum intumescit nervus accessorius*). In some cases a filament proceeds from this ganglion and joins the anterior roots of the sub-occipital nerve. Winslow believed that the funiculi of origin of the spinal accessory communicated with the hypoglossal: this is an error. The greater number and even the whole of the funiculi of the sub-occipital nerve have been seen to join the spinal accessory, in which case, filaments from the latter nerve always supply the place of those which are usually furnished by the first cervical.*

The Cranial Course of the Glosso-pharyngeal and Pneumogastric Nerves.—They pass horizontally outward, in contact with the lateral fibrous layer of the fourth ventricle, forming two groups having a very small interval between them. The two, three, or four small bundles which constitute the glosso-pharyngeal nerve pass through a special

* Lobstein, *De Nervo Spinali.* Vide Scriptor. Neurol., Minor de Ludwig., t. ii.

opening in the upper part of the foramen lacerum posterius (8, *fig.* 296). The bundles which form the pneumogastric nerve are collected together and pass through the same foramen, but by a distinct opening from the preceding one.

The *cranial*, or, rather, the *vertebral course of the spinal accessory nerve of Willis*, is remarkable. This nerve, which is very small below, where it is formed by one or two funiculi, ascends vertically upon the side of the cervical region of the spinal cord, to which it is closely applied below, just behind the ligamentum denticulatum, and from which it is separated above, where it is immediately in front of the posterior roots of the cervical nerves; it goes on increasing in size as it receives additional funiculi, which are blended with it; having arrived a few lines below the posterior lacerated foramen, it passes upward and outward to enter the same opening as the pneumogastric, being situated below that nerve, and emerging with it from the cranium.

The Central Extremity of the Hypoglossal Nerve.

The *hypoglossal nerves* (9, *figs.* 276, 295), or *ninth pair*, arise on each side, from the furrow between the olivary and pyramidal bodies, in the same manner as the spinal nerves, *i. e.*, by a linear series of funiculi placed one above the other.

The furrow from which the funiculi of the ninth nerve arise is continuous with the line formed by the origins of the anterior roots of the spinal nerves; no funiculus arises from the line formed by the posterior roots.* The relation of the origin of the ninth nerve with the vertebral artery in front, and the vascular ramifications which surround the funiculi of this origin, require to be mentioned.

The *real origin* of the ninth nerve cannot be traced beyond its apparent origin. It is certain that no fibres come from the pyramids; it has appeared to me that the fibres entered the substance of the olivary bodies, in which they could not be traced to any depth.

Cranial Course.—All the funiculi of origin of the hypoglossal nerve commence by two or three filaments, which are immediately covered by the neurilemma; they are then grouped into two or three bundles, which pass horizontally outward to the anterior condyloid foramen, through which (9, *fig.* 296) they almost always pass separately. Thus the dura mater forms two and sometimes three distinct canals for the hypoglossal nerve.

DISTRIBUTION OF THE CRANIAL NERVES.

The First Pair or Olfactory Nerves.—The Second or Optic Nerves.—The Third or Common Motor Nerves.—The Fourth or Pathetic Nerves.—The Fifth or Trigeminal Nerves—the Ophthalmic Division of the Fifth, and its Lachrymal, Frontal, and Nasal Branches—the Ophthalmic Ganglion—the Superior Maxillary Division of the Fifth, and its Orbital Branch—the Spheno-palatine Ganglion, and its Palatine, Spheno-palatine, and Vidian Branches—the Posterior and Anterior Dental, and the Terminal Branches of the Superior Maxillary Nerve—the Inferior Maxillary Division of the Fifth—its Collateral Branches, viz., the Deep Temporal, the Masseteric, Buccal, and Internal Pterygoid, and Auriculo-temporal—its Terminal Branches, viz., the Lingual and Inferior Dental—the Otic Ganglion.—The Sixth Pair or External Motor Nerves.—The Seventh Pair—the Portio Dura or the Facial Nerve—its Collateral Branches—its Terminal Branches viz., the Temporo-facial and Cervico-fascial—the Portio Mollis or Auditory Nerve.—The Eighth Pair—its First Portion of the Glosso-pharyngeal Nerve—its Second Portion or the Pneumogastric Nerve, divided into a Cranial, Cervical Thoracic, and Abdominal Part—its Third Portion, or the Spinal Accessory Nerve.—The Ninth Pair or the Hypoglossal Nerves.—General View of the Cranial Nerves.

The First Pair, or the Olfactory Nerves.

Dissection.—Harden the nerve in dilute nitric acid. Examine the pituitary membrane, not from its free surface, but from the surface which adheres to the periosteum. The nerve ramifies between the periosteum and the pituitary membrane.

Before the time of Scarpa, the olfactory pedicles or bands and the ethmoidal bulb were the only parts well known; the passage of the olfactory nerves through the foramina of the cribriform plate, and their distribution in the pituitary membrane, were scarcely noticed.

Passage of the Olfactoy Nerves through the Cribriform Plate.—I must here remind the student that the cribriform plate of the ethmoid bone is perforated by foramina, or, rather, by different sets of canals which ramify in its substance; that some of these canals terminate directly upon the roof or upper wall of the nasal fossæ, and that the others are divided into an internal set, which pass along the septum and end by becoming grooves, and an external set, which descend on the superior and middle turbinated bones, and on the rough quadrilateral surface in front of them.

The olfactory nerves arise from the ethmoidal bulb (1, *figs.* 296, 297) by a considera-

* [In the ox and dog Mayer discovered a small posterior root with a ganglion for this nerve; and he states that he once found a small posterior root on one side in the human subject.]

Fig. 297.

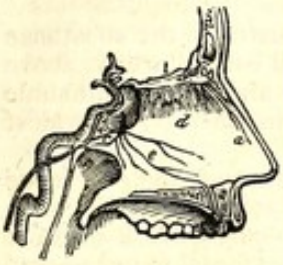

ble number of white bundles, which immediately pass through the cribriform plate, and divide and ramify (*d*, *fig.* 297) in the same way as the bony canals themselves; the dura mater forms a sheath for each of the subdivisions of the nerve, and supports their soft substance. All these nervous filaments are distributed upon the septum (*d*) and upon all the external wall (*a*, *fig.* 299) of each nasal fossa; the anterior run forward, the middle vertically downward, and the posterior backward. Some of them only interlace as they leave the cribriform plate. They all expand into very delicate pencils. They are situated between the periosteum and the pituitary membrane, and none of them reach either the inferior turbinated bone, or the maxillary, sphenoidal, or ethmoidal sinuses; on the inner wall of each fossa they do not pass lower than the middle of the septum; and on the outer wall they do not descend below the middle turbinated bone.*

With regard to the ultimate termination of the fibres of the olfactory nerve, there has been a difference of opinion; some believe that they terminate in papillæ like those of the skin; and others imagine that they expand into a membrane, like the optic nerve in the retina and the auditory nerve in the membranous labyrinth. I have never seen them terminate otherwise than by pencils of extremely delicate filaments very closely applied to each other.

Function.—The olfactory nerves are the essential organs of smell. Their distribution proves that the sense of smell resides essentially and exclusively in the roof of the nasal fossæ and the immediately adjacent parts.

The Second Pair, or the Optic Nerves.

The optic nerves have already been described from their origin to the optic commissure, and from the commissure to the optic foramina (2, *fig.* 296); they pass through these foramina together with the ophthalmic arteries which are below them; they are also accompanied by a sheath formed by the dura mater and by a prolongation of the arachnoid, the latter being immediately reflected from them.

The optic nerve, which is flattened up to this point, becomes rounded on emerging from the optic foramen, and is received in a fibrous ring formed by the origins of the muscles of the eye; it here, also, changes its direction slightly, for, instead of passing obliquely forward and outward, it runs almost directly forward to the globe of the eye, which it enters behind, and somewhat below, and to the inner side (see *o*, *figs.* 237, 238, 240). There is a very evident circular constriction at the point where the optic nerve enters the eye.†

During its course in the orbit, the optic nerve is surrounded by a great quantity of adipose tissue, which separates it from the muscles and nerves. The ophthalmic ganglion and the ciliary nerves and vessels are in immediate contact with it. It is accompanied, as far as the sclerotic, by a fibrous sheath given off from the dura mater, so that this nerve differs from all others, in being provided with two protecting sheaths, namely, a proper neurilemma, and a sheath formed by the dura mater. A section of the optic nerve also presents throughout its course that peculiar appearance resembling the pith of the rush, which we have already described as commencing at the commissure (see Central Extremity of the Optic Nerve).

As it enters the ball of the eye the nerve loses its two sheaths, which appear to become continuous with the sclerotic, and is thus reduced to its pulp, which spreads out to form the retina. In some subjects the retina presents a distinctly radiated appearance around the abrupt termination of the nerve (see Globe of the Eye—Retina).

Function.—The optic nerves are the nerves of vision; their continuity with the retina leaves no doubt of this being their function.

The Third Pair, or the Common Motor Nerves of the Eyes.

Dissection.—All the nerves of the orbit should be studied together. The frontal and lachrymal branches of the ophthalmic nerve and the fourth nerve may be first examined; then the orbital portion of the nasal branch of the ophthalmic, which will afterward be traced into the nasal fossæ; next, the common and external motor nerves; and, lastly, the ophthalmic ganglion and the optic nerve.

The *common motor nerve* has already been traced (3, *figs.* 298, 301) from its origin within the peduncles of the cerebrum to the side of the quadrilateral plate of the sphenoid bone, below and to the outer side of the posterior clinoid process; in this situation (3, *fig.* 296) it is received into a groove formed for it by the dura mater; it then perforates that membrane, enters the cavernous sinus, passes through it from behind forward and

* In mammalia, and particularly in the horse, a cord arises from the olfactory nerve, runs downward and forward along the septum, parallel to and in front of the naso-palatine nerve, and terminates in the small incisory cavity which exists in the arch of the palate in the lower animals, and is thought by M. Jacobson to be the seat of a sixth sense.

† M. Arnold, in his beautiful plates of the nerves of the head, has represented two very delicate filaments as establishing a communication between the superior maxillary and the optic nerves.

a little outward, and before entering the orbit divides into two branches of unequal size, of which one is *superior* and the other *inferior*.

The following are its *relations* in the cavernous sinus: it is situated in the substance of the external wall of the sinus, to the outer side of the internal carotid artery, above the external motor nerve, and to the inner side of the fourth nerve and of the ophthalmic branch of the fifth; it enters the orbit at the innermost, and, consequently, the widest part of the sphenoidal fissure.

It has no immediate relations with the other nerves that pass through the cavernous sinus, until it is about to enter the orbit; at this point it receives some very delicate filaments from the cavernous plexus of the sympathetic, and an equally small filament from the ophthalmic branch of the fifth nerve; after which, the external motor nerve* becomes situated below the common motor, while the frontal and pathetic nerves cross above it; the nasal branch of the ophthalmic is in contact with its outer side, and then passes between its two divisions.

As the common motor nerve passes through the sphenoidal fissure, the tendon of the external rectus forms a fibrous ring around it, which is quite distinct from the ring belonging to the optic nerve; this fibrous ring also surrounds the external motor nerve and the nasal branch of the ophthalmic.

The *superior terminal division* of the third nerve is much smaller than the inferior; it passes below the superior rectus of the eye, and immediately expands into a great number of filaments, one of which is very large, and runs along the outer border of that muscle. Almost all these filaments are intended for the superior rectus, which they enter by its under surface. Several of them are very small, and run along the inner border of the superior rectus, to be distributed to the levator palpebræ superioris. The filaments for this last muscle are proportionally much smaller and less numerous than those for the superior rectus.

The *inferior terminal division* is the true continuation of the nerve both as regards its size and direction; it runs between the optic nerve and the external motor nerve, which is in contact with it, and which lies between it and the external rectus muscle, and almost immediately subdivides into three branches: an *internal*, which, passing beneath the optic nerve, gains the internal surface of the internal rectus, and ramifies in that muscle; a *median*, which penetrates the inferior rectus; and an *external branch*, which is the smallest, and runs along the outer side of the inferior rectus as far as the inferior oblique, and enters that muscle at its posterior border, and almost at right angles. The *short, thick filament* which enters the ophthalmic ganglion proceeds from the branch for the inferior oblique muscle. This filament for the ganglion sometimes arises separately, and appears to be a fourth branch of the inferior division of the third nerve.†

Function.—The common motor nerve supplies all the muscles of the eye, excepting the superior oblique and the external rectus. It is remarkably large, and is proportioned to the activity and frequency of contraction in these muscles. That the muscular nerves do not terminate in loops or arches may be well seen in these muscles.

The Fourth Pair, or the Pathetic Nerves.

The *pathetic nerve* (4, *figs.* 298, 301) is remarkable for its extreme slenderness, for its origin upon the side of the valve of Vieussens, for the length of its cranial portion, and for its winding course around the peduncle of the cerebrum; it enters (4, *fig.* 296) an opening in the dura mater upon the anterior extremity of the inner or concave border of the tentorium cerebelli, on the outer side of the common motor nerve; it runs in the substance of the external wall of the cavernous sinus, to the outer side and a little below the level of the common motor nerve (3), and directly above the ophthalmic division (*a*) of the fifth, to which it sends off a filament, and then, running along the upper surface of that nerve, communicates with it by several twigs; it then enters the orbit together with the frontal nerve, the principal branch of the ophthalmic, through the widest part of the sphenoidal fissure, passes inward and forward, leaves the frontal nerve, crosses obliquely over the superior branch of the common motor nerve and the back part of the levator palpebræ superioris and superior rectus of the eye, to reach the superior oblique, and, having previously ramified, enters the upper border of that muscle. During its course in the orbit, this nerve, like the frontal branch of the ophthalmic, is in contact with the periosteum.

The union of the ophthalmic branch and the pathetic nerve is so intimate that it has been imagined that the lachrymal nerve is always derived entirely from the pathetic, and not from the ophthalmic itself. But a careful dissection shows that this is generally incorrect. However, I have found the pathetic nerve in several subjects giving off a branch,

* It appears to me that there is a communication between the common and external motor nerves in the cavernous sinus.

† I have seen the branch for the inferior rectus arise by two roots, one from the branch for the internal rectus, and the other from the branch for the inferior oblique. I have seen the branch for the inferior oblique give off a supernumerary branch to the inferior rectus. Lastly, sometimes the branches for the inferior oblique and inferior rectus are united, so that the inferior division of the third nerve was subdivided into two branches only.

which united with another from the ophthalmic nerve to constitute the lachrymal nerve. This anastomosis took place at the bottom of the orbit. Another and well-founded view regards the pathetic nerve and the ophthalmic branch of Willis as forming a single nerve ; in fact, in certain subjects they interlace so intimately that it is impossible to separate them.

The Branch for the Tentorium Cerebelli.—The pathetic nerve, while still contained in the substance of the external wall of the cavernous sinus, gives off a branch which runs backward in the substance of the tentorium cerebelli, and may be traced as far as the lateral sinus, near which it divides into two or three filaments. In several subjects I found that the branch for the tentorium was formed by a twig which arose from the ophthalmic nerve, became applied to the pathetic nerve, then diverged from it, and passed backward in the substance of the tentorium. It appears, then, that the nerve of the tentorium has a retrograde course.*

Function.—The fourth pair of nerves is intended for the superior oblique muscle only of the eye. It has been supposed that this muscle has a special nerve to enable it to express certain mental emotions, and especially love and pity ; but, as Sœmmering remarks, it exists in all mammalia, in birds, and even in fishes.

Camper states that the vital functions of the pathetic survive those of the other nerves, and that this circumstance influences the direction of the eyes in dying persons.

According to Sir C. Bell, the pathetic is the respiratory nerve of the eye. Its origin is situated at the highest part of the respiratory tract. According to the same physiologist, it is the nerve of expression ; it associates the muscles of the eye, and establishes certain relations between the eye and the respiratory system.

The Fifth Pair, or the Trigeminal Nerves.

The *nervus trigeminus* (trifacial, *Chauss.*, 5, *fig.* 296), which, as already stated, arises from the side of the pons Varolii by two distinct roots, gains the upper border of the petrous portion of the temporal bone, over which it is reflected, and near the apex of which there is a depression for the reception of the nerve : a bridge-like fold of the dura mater converts this depression into a canal. The nerve, which increases in width as it passes over the upper border of the petrous bone, continues to get wider while upon the upper surface of the same bone, and runs downward, forward, and outward ; its fibres immediately spread out and interlace to enter the concave surface of a grayish semilunar enlargement called the *semilunar* or *Gasserian ganglion*. All the fibres of origin of the fifth nerve do not assist in the formation of this ganglion ; for, on reflecting the nerve from within outward, a flat cord (*b*, *fig.* 299) is seen below the ganglion, and giving no fibre to it ; and, on tracing this cord upon the side of the pons Varolii, it is found to consist of the small root of the fifth nerve, which is at first placed on the inner side of this nerve, and then turns round it to gain its under surface.

This very remarkable disposition establishes a complete analogy between the fifth cranial nerve and the spinal nerves, which, as we have seen, have ganglionic roots (the posterior roots) and non-ganglionic roots (the anterior).

The *Gasserian ganglion* (behind *a b c*, *fig.* 298 ; *c*, *fig.* 299) is lodged in a special depression in the petrous portion of the temporal bone (*fig.* 296), and it adheres so closely to the dura mater that it is impossible to separate the ganglion without tearing it. From its convex surface, which is directed forward and outward, proceed three plexiform nervous trunks, which diverge like the toes of a bird ; these are, proceeding from before backward, the *ophthalmic nerve of Willis* (*a*, *figs.* 296, 298, &c), the *superior maxillary nerve* (*b*), and the *inferior maxillary nerve* (*c*) : the non-ganglionic root (*b*, *fig.* 299) of the fifth nerve goes directly to the inferior maxillary division (*c*) of the nerve : the ophthalmic and the superior maxillary divisions often arise by a common trunk. Several scattered filaments are given off from the three divisions of the nerve, but soon join them again. Communicating filaments are sometimes seen between the superior and inferior maxillary divisions as these latter enter their respective foramina.

Fig. 298.

The ganglionic nature of the Gasserian ganglion cannot be doubted ; for, like all ganglia, it consists of a grayish, pulpy matter, in which the nervous fibres are spread out, and, as it were, entangled, to enter into new combinations.

The Gasserian ganglion† gives off several filaments for the dura mater, which may be traced into the substance of the tentorium cerebelli : a certain number of filaments appear to be destined

* Arnold has described the branch (*f*, *fig.* 296) for the tentorium cerebelli, which is derived from the fifth nerve, and not that which comes from the pathetic.

† The Gasserian ganglion might serve as a type for demonstrating the structure of all ganglia, so easy is the separation of the gray matter and white fibres.

for that part of the dura mater which covers the petrous portion of the temporal bone and the sphenoid bone. In order to demonstrate these twigs, the dura mater must be previously rendered transparent by maceration in diluted nitric acid.

The Ophthalmic Division of the Fifth Nerve.

The *ophthalmic nerve of Willis*, or *ophthalmic division of the fifth nerve* (nerf orbitaire, *Winslow;* orbito-frontal, *Chauss.*, *a*, *fig.* 296, &c.), is the highest and smallest of the three divisions: it passes forward, outward, and upward, in the substance of the external wall of the cavernous sinus, in which situation it has a plexiform structure. It is there divided into an *external* branch, called the *lachrymal nerve* (*e*, *fig.* 296), a *middle branch*, the *frontal nerve* (continuation of *a*), and an *internal branch*, or the *nasal nerve;* these three branches enter the orbit through different parts of the sphenoidal fissure. Before this division, the ophthalmic nerve gives off a retrograde filament (nervus recurrens inter laminas tentorii, *Arnold*, *f*, *fig.* 296), which passes backward, closely applied to the twig furnished by the pathetic nerve to the tentorium cerebelli, and running parallel to that twig, enters the tentorium.

The Lachrymal or Lachrymo-palpebral Nerve.

Dissection.—First expose the nerve in the orbit, and then trace it backward to its origin. This dissection is difficult, unless the parts have been macerated in diluted nitric acid. The nerve is then to be traced into the substance of the upper eyelid.

The *lachrymal nerve* (*e*, *fig.* 296), the smallest of the three branches of the ophthalmic, comes off from the outer side of that nerve, in the substance of the external wall of the cavernous sinus, where it is difficult to discover its origin and course, on account of its intimate adhesion to the dura mater; it enters the orbit through the narrowest part of the sphenoidal fissure, runs along (below *s*, *fig.* 300) the upper border of the external rectus, passes through the lachrymal gland, to which it gives several filaments, pierces the fibrous layer of the upper eyelid, descends vertically within that eyelid, between its fibrous layer and the orbicularis muscle, and divides into two principal cutaneous filaments: a *palpebral*, which runs along the lower border of the tarsal cartilage; and an ascending *temporal*, which is lost in the integuments upon the anterior temporal region. During its course, the lachrymal nerve gives off a *malar branch*, which may be regarded as resulting from a bifurcation of the nerve. This branch perforates the malar bone, and anastomoses with the facial nerve upon the cheek.*

The *lachrymal branches*, properly so called, are extremely small. The real termination of the lachrymal nerve is in the upper eyelid, and hence the term *lachrymo-palpebral* has been given it.

I have already said that the lachrymal nerve not unfrequently arises by two filaments, one of which is derived from the ophthalmic of the fifth, and the other from the pathetic nerve (Mr. Swan describes this as the usual condition). In a specimen which I have now before me, there are two lachrymal nerves, one of which arises in the ordinary manner, that is to say, from the ophthalmic division of the fifth, while the other, which is external and smaller, arises both from the pathetic and the frontal nerve. These two lachrymal nerves anastomose with each other.

The Frontal Nerve.

The *frontal nerve* (fronto-palpebral, *Chauss.*) may be regarded as the continuation of the ophthalmic (*a*, *fig.* 296) both in size and direction; it enters the orbit at the highest and broadest part of the sphenoidal fissure, together with the pathetic nerve.†

It passes horizontally forward, between the periosteum and the levator palpebræ superioris, crossing that muscle at an acute angle, and divides at the bottom of the orbit into two unequal branches, which do not diverge until they reach the front of that cavity; these are the *internal frontal* and the *external frontal*.‡

The External Frontal or Supra-orbital Nerve (*r*, *figs.* 296, &c.).—This is larger than the internal branch; it passes out of the orbit through the supra-orbital foramen, and expands into *ascending* or *frontal*, and *descending* or *palpebral* branches. The *palpebral branches* are very numerous, and descend vertically in the substance of the upper eye-

* Authors speak of a filament from the lachrymal nerve which anastomoses with the superior maxillary nerve near the anterior extremity of the infra-orbital fissure. I have never seen this filament.

[Before reaching the lachrymal gland, the lachrymal nerve may give off one or two communicating filaments, to join the temporal filaments of the orbital branch (*t*, *fig.* 300) of the superior maxillary nerve, before these latter perforate the outer wall of the orbit.]

† The orbital nerves which enter the sphenoidal fissure are divided into two sets: those which pass through the fibrous ring of the external rectus, namely, the common motor nerve, the nasal branch of the ophthalmic, and the external motor nerve; and those which pass above and to the outer side of the preceding, immediately below the lesser ring of the sphenoid bone, between the periosteum and the superior rectus, namely, the frontal branch of the ophthalmic, the pathetic, and the lachrymal branch of the ophthalmic: the latter nerve passes separately through the sphenoidal fissure.

‡ Not unfrequently a third branch arises from the inner side of the frontal nerve; this might be called the *fronto-nasal;* it passes obliquely inward and forward, crosses over the superior oblique, anastomoses with the external nasal nerve, emerges from the orbit below the pulley for the tendon of the superior oblique, and terminates with the external nasal nerve in the upper eyelid. [This fronto-nasal branch may arise from the internal frontal nerve.]

lid; one of these branches runs horizontally outward under the orbicularis palpebrarum, to anastomose with the branches of the facial nerve. The *frontal branches* are generally two in number, an external and an internal. They form the true continuation of the external frontal nerve, which almost always bifurcates as it passes through the supra-orbital foramen; they are reflected upward; the *external*, which is the larger, passes between the frontal muscle and the periosteum; the *internal* (*h*, *fig.* 285) lies between the muscle and the skin; they both run somewhat obliquely upward and outward, spread out into ramifications, which diverge from each other at acute angles, and may be traced as far as the lambdoidal suture. Almost all these ramifications are distributed to the skin. Some of them are periosteal, and these require for their proper demonstration that the parts should be macerated in diluted nitric acid: it is doubtful whether any of them terminate in the frontal portion of the occipito-frontalis muscle. In some subjects there is a very remarkable *osseous frontal branch*, which enters an opening in the supra-orbital foramen, and passes along a canal formed in the substance of the frontal bone; it ascends vertically like the canal, gives off a succession of small periosteal filaments, and at length, emerging from the canal opposite to the frontal eminence, becomes sub-cutaneous.

The Internal Frontal or Supra-trochlear Nerve (*s*, *figs.* 296, 301).—This is almost always smaller, but is sometimes as large as the external frontal; its size appears to me to be inversely proportioned to that of the external nasal and external frontal nerves together; it is often divided into two branches; it passes out of the orbit between the supra-orbital foramen and the pulley of the superior oblique (hence it is called the *supra-trochlear nerve*), and divides into *ascending* or *frontal filaments*, which ramify in all that portion of the integuments of the forehead which lies between the branches of the right and left external frontal nerves, and into *descending* or *palpebral* and *nasal filaments*, which descend vertically; the former set in the upper eyelid, and the latter upon the dorsum of the nose, where they anastomose with the branches of the nasal nerve.*

When there are two internal frontal nerves, the inner one of them enters a fibrous ring formed in the upper part of the pulley for the superior oblique, and divides into *palpebral* and *nasal* twigs, while the outer one supplies the *frontal* filaments. This outer nerve sometimes perforates the orbital arch from behind forward in a special canal: I have seen it pass from without inward to enter the frontal sinus, then run along the anterior wall of the sinus, and finally emerge through a special foramen at the side of the nasal eminence. This nerve gave no branch in the sinus, although it was situated between its anterior wall and the lining membrane.

I have seen the frontal nerve divided, from its entrance into the orbit, into four branches, of which the two outer ones corresponded to the external frontal, and the two inner ones to the internal frontal nerve.

The Nasal Nerve.

Dissection.—The orbital portion of this nerve is easily exposed between the optic nerve and the superior rectus. The external nasal branch can also be easily traced upon the frontal region. In order to see the internal nasal branch in the corresponding nasal fossa, an antero-posterior vertical section of the head must be made on one side of the septum nasi; this section will also serve for the demonstration of all the deep nerves of the face.

The *nasal nerve* (above *t*, *fig.* 301), which is intermediate in size between the other two branches of the ophthalmic, viz., the frontal and lachrymal nerves, arises from the inner side of the ophthalmic, sometimes even as that nerve is entering the cavernous sinus; it is at first applied to the inner side of the ophthalmic nerve, and then to the outer side of the common motor nerve, together with which it enters the orbit, passing between the superior and inferior branches of that nerve. It then runs inward and forward, crosses obliquely over the optic nerve, passes below the superior rectus, then below the superior oblique, gains the internal wall of the orbit, and divides, near the upper border of the internal rectus, into two branches, named the *internal* and the *external nasal* nerve.

Before its entrance into the orbit, the nasal nerve gives off a *long* and *slender filament* (sometimes two), which enters the ophthalmic ganglion; it also furnishes one or more ciliary nerves, which run on the inner side of the optic nerve, and are distributed like the ciliary nerves derived from the ophthalmic ganglion.

The *external nasal nerve* (palpebral, *Chauss.*). This branch (*t*, *figs.* 296, 301) runs forward, following the original direction of the nerve below the superior oblique, and emerges from the orbit by passing under the cartilaginous pulley for the tendon of that muscle (infra-trochlearis nerve, *Arnold*); it is sometimes joined by that division of the frontal nerve which I have named the fronto-nasal (note, p. 828),† and divides into the following branches: *palpebral* filaments, which run downward and outward in the orbicularis palpebrarum, and form anastomotic arches at the free margin of the upper eyelid; a great number of *nasal* twigs, which pass upon the dorsum of the nose, and anastomose

* [The supra-trochlear nerve supplies filaments to the corrugator supercilii, and to the orbicularis.]

† I have seen the external nasal nerve give off a branch which ran inward, anastomosed with the fronto-nasal, perforated the roof of the orbit, ran for about an inch beneath the dura mater, perforated the frontal bone above and to the outer side of the frontal sinus, and was distributed to the skin upon the forehead.

with the filaments of the facial nerve, which accompany the angular vein; and *frontal* twigs, which anastomose with those of the internal frontal nerve.*

The Internal Nasal or Ethmoidal Nerve (*u*, *fig.* 296).—The course of this nerve is very remarkable. It enters the anterior internal orbital canal, which conducts it into the ethmoidal groove, on the internal surface of the basis cranii;† it is then reflected forward upon the side of the crista galli, passes through the ethmoidal fissure into the corresponding nasal fossa, becomes sensibly increased in size, and divides into two filaments, an *internal*, or *nerve for the septum*, and an *external*, or *naso-lobar* nerve.

The *internal filament*, or *anterior nerve of the septum nasi* (*a*, *fig.* 297), enters the fibro-mucous membrane upon the anterior part of the septum, and divides into several very slender filaments, which may be traced below the middle of the septum.

The *external filament*, or *nerve of the external wall of the nasal fossa* (*u*, *fig.* 299), runs along the anterior border of the septum, and divides into two terminal filaments, one of which passes upon the fore part of the external wall of the nasal fossa, and ramifies upon the turbinated bones; while the other and larger filament (*e*, naso-lobaire, *Chauss.*) follows the original course of the nerve, and passes behind the nasal bone, which is marked with a groove, and frequently even by a canal for the reception of the nerve; from this latter filament several twigs proceed, which perforate the nasal bone more or less obliquely, and are distributed to the skin of the nose; having reached the lower border of the nasal bone, it passes forward, increasing in size, through the fibrous tissue which unites the bone to the lateral cartilage of the nose, and then ramifies in the skin covering the ala and lobe of the nose, where I have seen it anastomose with the facial nerve.

While within the cavity of the cranium, the internal nasal nerve lies beneath the dura mater, and is perfectly distinct from the olfactory nerve, with which it never anastomoses.

The Ophthalmic Ganglion and its Branches.‡

Dissection.—The ophthalmic ganglion may be exposed in several ways: for example, either in dissecting the branch given by the common motor nerve to the inferior oblique muscle, or directly by removing the adipose tissue between the external rectus and the optic nerve. The long branch from the nasal nerve to the ophthalmic ganglion and the ciliary nerves can also be exposed with the greatest ease.

The *ophthalmic* or *ciliary ganglion* (behind *i*, *fig.* 298) is a small, grayish, and flattened enlargement, of a lenticular form (the *lenticular ganglion*), applied to the outer side of the optic nerve, and situated about two or three lines from the optic foramen, in the midst of a great quantity of adipose tissue, which renders its dissection difficult. It varies much in size, and sometimes consists of a simple miliary enlargement, which forms a point of origin and termination for a certain number of nerves. For the convenience of description, this ganglion is said to have four angles, two posterior and two anterior; by its *posterior and superior angle* it receives a long slender branch (*its long root*), given off from the nasal nerve while still contained within the cavernous sinus. Not unfrequently a second long, but extremely slender root, is furnished by the nasal nerve to the ophthalmic ganglion. By its *posterior and inferior angle* it receives a short, thick branch, which comes from the inferior division of the common motor nerve (*its short root*). From its two *anterior angles* it gives off two small bundles of nerves, named the *ciliary nerves* (*i*, *fig.* 298; *x*, *fig.* 301). Lastly, the ophthalmic ganglion has a ganglionic or *soft root*, or, rather, a communicating filament, between this ganglion and the superior cervical ganglion of the sympathetic; this soft root arises from the cavernous plexus, and passes sometimes to the long or nasal root of the ophthalmic ganglion, and sometimes to the ophthalmic ganglion itself.

The ciliary nerves are remarkable for their tortuous course, in which respect they resemble the ciliary arteries; and also for being collected into two bundles, the one *superior*, which is generally composed of four filaments, and the other *inferior*, composed of five or six. The ciliary nerves do not anastomose before they reach the globe of the eye, with the exception, however, of the ciliary nerve, which is derived directly from the nasal nerve, and which anastomoses with an inferior ciliary nerve from the ophthalmic ganglion. Having reached the sclerotic, the ciliary nerves perforate the coat more or less obliquely, around the entrance of the optic nerve, excepting two or three, which enter the globe of the eye near the attachment of the muscle; after having perforated the sclerotic, they become flattened or riband-shaped, and run forward (*a*, *fig.* 242) parallel to each other, between the sclerotic and the choroid coats, slightly adhering to the former of these membranes, on which grooves exist for their reception; on approaching the ciliary circle or ligament (*b*), they bifurcate, and divide into filaments, which anastomose with the neighbouring filaments, and appear to be lost in the ciliary circle, which

* [It also supplies branches to the lachrymal sac and caruncula, and to the parts of the inner canthus.]

† Not unfrequently the internal nasal nerve, while within the ethmoidal groove, gives off a recurrent nervous twig, which enters the orbit by a small canal, in front of the anterior internal orbital canal, and anastomoses with the external nasal or infra-trochlear nerve. I have seen this small nerve anastomose with the fronto-nasal branch, which I have already described (note, p. 828) as an unusual branch of the frontal nerve.

‡ The connexions of the ophthalmic ganglion with the nasal nerve, as well as with the common motor nerve, have induced me to describe it here.

has been, and not without some reason, considered by modern anatomists as a nervous ganglion, *ganglion annulare* (annulus gangliformis seu ganglion annulare, *Sœmmering*). I have seen some of these ciliary nerves pass through the ciliary circle and enter the iris; they are not distinctly seen to enter the ciliary processes.*

The Superior Maxillary Division of the Fifth Nerve.

Dissection.—Saw through the zygomatic arch, turn down the masseteric muscle, and remove the roof of the orbit; first dissect the lachrymal, malar, and temporal twigs of the orbital branch of the nerve; then clean out the orbital cavity, remove the upper wall of the zygomatic fossa to reach the spheno-maxillary fossa by means of two cuts joined at an acute angle in the foramen rotundum. Detach the origins of the pterygoid muscles; lastly, trace the nerve into the infra-orbital canal and on the face.

The *superior maxillary nerve* (*b*, *figs.* 298, 300, 301), the second or middle division of the fifth nerve, both in position and size, runs forward to enter, after a very short course, the foramen rotundum, by which it is conducted into the spheno-maxillary fossa; from thence it passes into and traverses the whole length of the infra-orbital canal, where it is named the *infra-orbital nerve* (*f*); having reached the fore part of that canal, it bends downward, and ramifies in the cheek. It is plexiform at its origin and in the foramen rotundum, but is fasciculated throughout the rest of its course.

Its *collateral branches*, taken in the order of their origin, are the orbital nerve; certain nerves which are given off from the enlargement called Meckel's ganglion, namely, the palatine, spheno-palatine, and vidian or pterygoid nerves; the posterior dental nerves, and the anterior dental nerve; lastly, several small filaments come off either from the ganglion of Meckel or from the superior maxillary nerve itself, and, surrounding the internal maxillary artery, assist in the formation of its plexus.

The Orbital Nerve.

This branch (*t*, *fig.* 300) comes off immediately in front of the foramen rotundum, from the upper side of the superior maxillary nerve, passes through the spheno-maxillary fissure, along which it proceeds to enter the orbit; it then runs along the floor of the orbit, and divides into two branches: the one ascending, the *lachrymal branch of the orbital nerve*, which enters the lower surface of the lachrymal gland, anastomoses with the lachrymal branch (*s*) of the ophthalmic nerve (*a*), and sends off some branches to the upper eyelid, near its external angle; the other branch is the *temporo-malar*, which passes horizontally forward, enters a small canal in the malar bone, and subdivides into a *malar filament*, which perforates the bone, and is distributed to the skin upon the malar region,† and a *temporal filament*, which perforates the orbital portion of the malar bone, and dips into the anterior part of the temporal muscle, in which it anastomoses with the anterior deep temporal nerve, a branch of the inferior maxillary. I have sometimes seen two temporal filaments pass through the malar bone at two different points.‡

The Spheno-palatine Ganglion and its Branches.

After having given off the orbital nerve, and while it is still contained in the spheno-maxillary fossa, the superior maxillary nerve gives off from its lower side a thick branch, frequently two, and occasionally several branches, from which a great number of diverging nerves immediately proceed; these are the three palatine nerves, the spheno-palatine nerves, and the vidian nerve; at the point where these nerves diverge is found an enlargement which the elder Meckel,◊ whose name is connected with the description of the fifth pair, regarded as a ganglion, and which is, therefore, called *Meckel's ganglion*, or the *spheno-palatine ganglion* (situated before *s*, *fig.* 299; below *b*, *fig.* 301).

In a certain number of cases, I have sought in vain for the ganglionic structure in this enlargement, *i. e.*, for gray matter with white filaments scattered through it. It appeared then to be nothing more than the common trunk or starting-point of a great number of nerves; in the majority of cases, however, a quantity of gray matter certainly exists, but is so arranged that the nerves may generally be traced quite through the enlargement, so that they clearly are not given off from the ganglion itself, but come directly from the superior maxillary nerve.‖

* Tiedemann, from the results of observations in comparative anatomy, believes that the arteries which ramify in the retina are accompanied by very delicate nervous filaments, derived from the ophthalmic ganglion and the ciliary nerves: he has seen a nervous filament penetrate the optic nerve with the arteria centralis retinæ; and he states that the ciliary arteries are accompanied by very delicate nervous filaments, which he has traced into the retina as far as the zone of Zinn. Tiedemann also says that he has seen, only once, it is true, a rather large nervous filament proceed from Meckel's ganglion, and join the thick and short branch which is given off from the third pair to assist in the formation of the ophthalmic ganglion.

† It is said that this twig anastomoses with the facial nerve in the malar region; I have never been fortunate enough to discover this anastomosis.

‡ [Both of these temporal filaments may be joined by communicating twigs from the lachrymal nerve within the orbit; one of them anastomoses with the anterior deep temporal nerve, as above mentioned; the other, having entered the temporal fossa through the malar bone, ascends on the temporal surface of that bone, turns outward, perforates the temporal fascia about an inch above the zygoma, anastomoses with filaments of the facial nerve, and of the auriculo-temporal branch of the inferior maxillary nerve, and is lost in the skin on the temple.]

◊ Mem. de l'Acad. de Berlin, 1749

‖ In one case the ganglion of Meckel was in contact with the internal surface of the superior maxillary nerve In the same case a filament proceeded from the upper part of the ganglion, and joined the branch

I shall now describe, in succession, the branches which proceed from Meckel's ganglion.

The Palatine Nerves.

These nerves (*g g, fig.* 299; *g, fig.* 301) are three in number: an *anterior* palatine, which is the largest, a *posterior* palatine [the *middle* of some authors], which is the next in size, and an *intermediate* nerve [the *posterior* of some authors], which is the smallest; these nerves are continuous with Meckel's ganglion; it is most evident that, in the greater number of cases, they arise directly from the lower part of the superior maxillary nerve.

The *anterior* or *great palatine nerve* immediately enters the posterior palatine canal, through the whole length of which it passes, and, having reached the lower orifice of that canal, is reflected forward, and terminates by bifurcating on the hard palate.

During its course, it gives off an *inferior nasal branch* (lower *f, fig.* 299), which is distributed over the middle meatus and the middle and inferior turbinated bones: the twig for the inferior turbinated bone may be traced to the fore part of that bone; it also gives off the anterior palatine, and several small twigs, which perforate the inner wall of the maxillary sinus, and are distributed to the last molar teeth; lastly, at its exit from the posterior palatine canal, and even sometimes while yet within that canal, it sends off a *staphyline* branch, which spreads into several filaments, all of which run backward in the soft palate, and divide into *superior* filaments distributed to the mucous membrane on the nasal surface; and *inferior*, which run beneath the mucous membrane on the buccal surface of the soft palate. Of the two terminal branches of the anterior palatine nerve, both of which occupy the hard palate, the external runs near the alveolar border, and the internal near the median line; they enter into the midst of the glandular layer of the palate, and are ultimately distributed to the glands, to the mucous membrane of the hard palate, and to the gums.

Fig. 299.

The *posterior* [middle] *palatine nerve*, the next in size, enters a special canal: on escaping from which it passes backward, beneath the mucous membrane of the nasal surface of the soft palate, to which it is distributed.

The same is the case with the *intermediate* [posterior] or *small palatine nerve*, which is extremely slender.

I have seen a palatine nerve enter the maxillary sinus, run beneath its lining membrane, pass vertically through the maxillary tuberosity behind the last molar tooth, and ramify upon the hard palate.

The Spheno-palatine or Posterior Nasal Nerves.

Dissection.—Make a vertical section of a head, previously macerated in dilute nitric acid, strip off the pituitary membrane lying upon the septum and the turbinated bones, and examine the nerves from the internal or deep surface of that membrane.

The spheno-palatine nerves are very slender; they enter the corresponding nasal fossæ through the spheno-palatine foramen, and have been traced by Scarpa with his customary exactness. They are all situated in the pituitary membrane, or, rather, between the periosteum and the mucous membrane, and cannot be readily seen until this fibro-mucous membrane has been removed from the bones which it covers; the nervous filaments are then seen through the semi-transparent fibrous layer. For this purpose, preparations macerated in diluted nitric acid are indispensable. The spheno-palatine nerves are distributed to the septum nasi and the external wall of the corresponding nasal fossa; they are divided into *internal* and *external*.

There is only one *internal spheno-palatine nerve*, viz., the *nerve of the septum* nasi, or the *naso-palatine* of Scarpa (*b, fig.* 297); it passes inward, in front of the sphenoidal sinus, and below the orifice of that sinus, to gain the septum nasi; it is then directed at first almost vertically downward, but afterward almost horizontally forward, as far as the superior orifice of the anterior palatine canal, which it enters, and then passes into a special canal, quite distinct from the anterior palatine canal, and parallel to the one for the naso-palatine nerve of the opposite side. According to M. Hippolyte Cloquet, the two naso-palatine nerves terminate in the upper part of a ganglion, which he calls the *naso-palatine*, and do not reach the mouth; but in some researches which I have made on the subject, I have failed in detecting this ganglion.†

The nerves can be distinctly seen to enter the mucous membrane of the hard palate behind the incisor teeth, and upon that prominence of the mucous membrane against which the point of the tongue is so often applied. I have never seen any anastomoses either between the two naso-palatine nerves, or between these and the anterior palatine nerves.

given by the external motor nerve to the sympathetic. I have not been able to discover the filaments which are said to establish a communication between Meckel's ganglion and the optic nerve.

† I find that it is stated by Arnold, whom I have so often quoted, because his works are above all praise for their rigorous accuracy, that the spheno-palatine ganglion does not exist; and he observes, with reason, that the subjoined description of M. Hippolyte Cloquet is very imperfect. "It consists of a small, reddish, fungous mass, rather hard, as if fibro-cartilaginous, and surrounded by adipose cellular tissue."

Anatomists are not agreed as to whether the naso-palatine nerve gives off any filaments upon the septum. I have failed in detecting any ramification of the nerve in a great number of preparations, in which the pituitary membrane had been rendered transparent by long maceration in diluted nitric acid. Rather frequently a filament was given off from the upper part of the nerve, and then joined it again. Three times only did I observe a twig running upward from the anterior part of the nerve.

The *external spheno-palatine*, or *superior nasal nerves* (upper *f*, *fig.* 299), so called to distinguish them from the inferior nasal branch of the anterior palatine nerve, are three or four in number; they are directed vertically along the back part of the outer wall of the corresponding nasal fossa, and spread out into filaments, which extend over the turbinated bones and the meatus; these filaments can only be seen from the deep surface of the pituitary membrane.*

I have never been able to find the anastomoses between the internal and external spheno-palatine nerves and the divisions of the olfactory nerve, which are admitted by some anatomists.

The Vidian or Pterygoid Nerve.

The *vidian nerve* (*v*, *figs.* 300, 301) arises from the back part of Meckel's ganglion, and enters the vidian or pterygoid canal, after emerging from which it perforates the cartilaginous plate of the foramen lacerum anticus, and divides into a *superior cranial* branch, the great *superficial petrosal* nerve, and an *inferior, deep*, or *carotid* branch. The subdivision of the pterygoid nerve often occurs at its origin from Meckel's ganglion.

The *inferior* or *carotid branch*, which is much larger than the superior, forms the continuation of the nerve: it enters the carotid canal, and is applied to the outer side of the carotid artery, where it anastomoses with the nerves which establish a communication between the superior cervical ganglion and the external motor nerve of the eye, and assists in the formation of the carotid plexus; a flattened gangliform enlargement is seen at the point of anastomosis. I have sometimes seen two carotid branches, one of which was very small.

The *superior* or *cranial branch*, the *great superficial petrosal nerve*, enters the cranium between the temporal and sphenoid bones, runs backward and outward (*v*, *fig.* 296) beneath the dura mater, in a groove on the upper surface of the petrous portion of the temporal bone, passes through the hiatus Fallopii into the aqueductus Fallopii or canal for the facial nerve (part of 7), and anastomoses with that nerve.† I say that it anastomoses, because there is a sort of fusion of the two nerves, and not a simple juxtaposition. The branch called the chorda tympani, which comes off from the facial nerve at some distance from the point of fusion, should not be regarded as a prolongation of the superficial petrosal nerve, supposed in that case to be merely applied to the facial nerve.‡

The Posterior Dental Nerves.

Dissection.—These nerves can be readily seen without any dissection through the bone, when this is rendered transparent by nitric acid. They must be examined both from the external surface of the bone, and from the interior of the sinus.

The *posterior dental* or alveolo-dental nerves (*e*, *figs.* 298, 300, 301) are two in number, a superior and an inferior; sometimes there are three; they arise from the superior maxillary nerve, sometimes by a common trunk, sometimes separately, just as that nerve is about to enter the infra-orbital canal: they run forward and downward, at first in contact with the maxillary tuberosity, and give off some filaments to the buccinator muscle, and to the gums, and some which are distinctly distributed to the mass of fat in the cheek; they then enter certain canals in the substance of the maxillary tuberosity, and become flattened or riband-shaped.

The *posterior and superior dental nerve* passes from behind forward, through the base

* Bock, and Arnold after him, have described, under the name of the *pharyngeal branch*, a rather large branch, which may be regarded as belonging to the external spheno-palatine nerves; it enters into the pterygo-palatine canal, formed between the under surface of the sphenoid and the sphenoidal process of the palate bone, passes backward and inward, and divides into several filaments, which are distributed to the upper part of the pharynx. [Some of these *superior nasal* branches are said to supply the lining membrane of the posterior ethmoidal and the sphenoidal sinuses.]

† I have seen the superior branch of the vidian formed by three very distinct filaments: anatomists are still undecided as to whether the inferior or carotid branch is derived from the ganglion of Meckel, or from the superior cervical ganglion. According to Arnold, it resembles the organic system of nerves in its colour, softness, and structure. I cannot coincide in this opinion, for it appears to me that the cranial and carotid branches of the vidian are analogous in every respect.

‡ Arnold, who regards this opinion of Hippolyte Cloquet, which is adopted by Hirsel, as erroneous, states that, at the junction of the cranial branch of the vidian with the facial nerve, there is a gangliform swelling, in which he finds some analogy to the inter-vertebral ganglia, and which he considers to be a transition between a gangliform stalk and a true ganglion.

According to Arnold, the superficial or cranial branch, and the deep or carotid branch of the vidian, do not come from a common trunk, but are merely juxtaposed, and are distinct throughout their entire extent. The carotid branch is soft and reddish, presents all the characteristics of the ganglionic nerves, and is intended to establish a communication between the superior cervical and the spheno-palatine ganglion. The cranial or superficial petrosal branch, on the contrary, presents all the characters of the cerebro-spinal nerves; it is of a white colour and firm consistence.

of the malar eminence of the superior maxillary bone, and anastomoses on a level with the canine fossa with a filament from the anterior dental nerve.

The *posterior and inferior dental nerve*, which is larger than the preceding, runs in a curved direction below the malar eminence, the concavity of the curve being directed upward, and anastomoses with the posterior and superior dental nerve, on a level with the canine fossa. No filament is given off from the upper side of these nerves, but they give off a great number of filaments downward, which anastomose, and form a series of very remarkable meshes or areolæ; these meshes, and the dental nerve which come from them, are situated within the substance of the bone, but are much nearer to the sinus than to the outer surface of the bone. It is from these meshes that the extremely delicate filaments arise which form the dental nerves of the molars and bicuspids; their number corresponds to that of the fangs of these teeth.*

Some filaments evidently terminate in the substance of the superior maxillary bone; no other bone in the body has so large a number of proper filaments.

The Anterior Dental Nerve.

The *anterior* dental or alveolo-dental nerve (*j, fig.* 298) is the only branch given off by the superior maxillary nerve while within the infra-orbital canal;† it arises about five or six lines from the anterior orifice of that passage. It is so large that it may be regarded as resulting from the bifurcation of the infra-orbital nerve. It soon enters a special canal formed for it in the superior maxillary bone, gives off on the outer side a small branch which anastomoses with the posterior and superior dental nerve, passes at first horizontally inward, and then vertically downward, turning round the margin of the anterior opening of the corresponding nasal fossa, and is reflected upon the floor of that fossa; during the whole of this course, it is situated within the substance of the superior maxillary bone; its horizontal portion is superficial, and its vertical portion is deep-seated, having merely a thin bony lamella between it and the pituitary membrane. Having arrived on a level with the floor of the nasal fossa, about two lines from its anterior opening, it expands into a great number of ascending and descending filaments; the *ascending* filaments are reflected upward within the anterior nasal spine, where they terminate. They appear to me to send off a small ramification to the pituitary membrane. The *descending filaments* terminate by supplying the dental nerves for the incisor, canine, and first bicuspid teeth. A great number of filaments are also lost in the substance of the bone.

I have never seen any filaments from the dental nerves entering the membrane of the maxillary sinus.

The Terminal Branches of the Superior Maxillary Nerve.

Having reached the anterior orifice of the infra-orbital canal, the superior maxillary nerve, the component bundles of which had been merely in juxtaposition, immediately expands (*i, fig.* 301) into a pencil of diverging filaments beneath the levator labii superioris. These filaments (*i, fig.* 285) may be divided into *ascending* or *palpebral*, which pass upward and outward beneath the orbicularis palpebrarum, and are distributed to the skin and conjunctiva of the lower eyelid; a great number of *internal* or *nasal* filaments, which run upon the side of the nose, and are distributed to the skin of that organ; one of them runs along beneath the septum; and, lastly, into *descending* or *labial* filaments, which are the most numerous, and which enter the substance of the upper lip, and are distributed to the skin and the mucous membrane: all these filaments, and especially the labial, interlace and anastomose with the facial nerve, so as to form a plexus, named the *infra-orbital*, to which we shall return in describing the facial nerve.

I have seen the nasal and the palpebral filaments arise together from the superior maxillary nerve, before it had given off the anterior dental, enter a special canal situated on the inner side of the infra-orbital canal, emerge opposite the line of demarcation between the cheek and the nose, and then expand into their nasal and palpebral divisions; while the labial filaments had their usual arrangement.

The Inferior Maxillary Division of the Fifth Nerve.

Dissection.—As this nerve must be examined both upon its internal and its external aspect, it must be dissected in both directions. An antero-posterior section of the head in the median line will enable us to see, on the internal surface of the nerve, the chorda tympani, the otic ganglion, and the origins of all the other branches which come from the inner side of the inferior maxillary nerve, viz., the nerve of the internal pterygoid, the lingual nerve, and the dental nerve. In order to see the distribution of the deep temporal, the masseteric, the buccal, the internal pterygoid, and the auriculo-temporal nerves, the inferior maxillary nerve must be exposed from its outer side, by breaking down the zygomatic arch, reflecting down the masseter, which is to be detached as far

* In those molar teeth which have two or three roots, the nervous filaments subdivide and anastomose with each other in the substance of the dental pulp.

† Sometimes, however, I have seen the posterior and superior dental nerve arise within the infra-orbital canal.

back as the sigmoid notch, by sawing through the base of the coronoid process, and turning the temporal muscle upward, and then by carefully dividing the external pterygoid muscle, through which the buccal nerve passes.

The *inferior maxillary nerve* (*c*, *figs.* 296, &c.), the most posterior and the largest division of the fifth nerve, passes outward and a little forward, and, after a very short course within the cranium, escapes through the foramen ovale into the zygomatic fossa, where it divides successively into seven branches. The non-ganglionic root (*b*, *fig.* 299) of the fifth nerve is connected exclusively with the inferior maxillary division (*c*) of its other root, beneath which it lies, from which it can be distinguished by not having a plexiform structure, with which it is not blended until it emerges from the foramen ovale. Of the seven branches of the inferior maxillary nerve, three are *external*, namely, the anterior and posterior deep temporal, the masseteric, and the buccal; one is *posterior*, namely, the auriculo-temporal; one is *internal*, the internal pterygoid; and two are *inferior*, the lingual or gustatory, and the inferior dental. These nerves may also be divided into *collateral* branches, including the first five, and the *terminal* branches, namely, the lingual and the inferior dental; the *otic ganglion*, described by Arnold, is connected with this nerve.*

The Collateral Branches of the Inferior Maxillary Nerve.

The Deep Temporal Nerve.

The first *external* branch, or the *deep temporal nerve*, arises from the outer side of the inferior maxillary nerve, passes horizontally outward and forward between the roof of the zygomatic fossa, with which it is in contact, and the eternal pterygoid muscle. Having arrived at the ridge which separates the temporal from the zygomatic fossa, it anastomoses with several temporal branches derived from the buccal and masseteric nerves, and forms a sort of plexus with them. The branches which emerge from this plexus ascend vertically in the deep layers of the temporal muscle, in which most of them terminate.

Some twigs anastomose with the temporal filaments derived from the lachrymal branch of the ophthalmic nerve, and from the orbital branch of the superior maxillary nerve.† One and sometimes two filaments perforate the temporal fascia, about a finger's breadth above the zygomatic arch, and then ascend beneath the skin, to anastomose with the auriculo-temporal and the facial nerves.‡

The Masseteric Nerve.

The second *external* branch, or the *masseteric nerve*, arises from the same point as the last nerve, and greatly exceeds it in size; it comes off at an acute angle, passes horizontally backward and outward in contact with the roof of the zygomatic fossa, between it and the external pterygoid muscle; it is then reflected downward over the upper part of that muscle to gain the sigmoid notch of the lower jaw, upon which it is again reflected, and then descends vertically, between the ramus of the jaw and the masseter, or, rather, in the substance of the deep layers of that muscle, down to the insertion of which it may be traced. During its course along the upper wall of the zygomatic fossa, the masseteric nerve gives off a small, deep temporal branch, which runs along the periosteum, passes into the temporal fossa, and sends off an articular branch to the temporo-maxillary articulation.

The Buccal or Bucco-labial Nerve.

The third *external* branch (*g*, *fig.* 300), the *buccal*, or, rather, the *bucco-labial nerve* (*Chauss.*), is very remarkable on account of its size and the extent of its distribution, which gives it some resemblance to the corresponding portion of the facial nerve. It arises from the outer side of the inferior maxillary nerve, by one, two, and sometimes three roots, which perforate the external pterygoid, and join together as they emerge from that muscle; from thence it runs downward between the coronoid process of the lower jaw and the tuberosity of the upper jaw, gives several twigs to the external pterygoid muscle, and also some branches to the temporal muscle, of which one ascends and anastomoses with the deep temporal nerve, while another descends and is distributed to the same muscle, near its insertion into the coronoid process; the buccal nerve itself sometimes perforates the lowest part of the insertion of the temporal muscle, and having reached the back part of the buccinator, it expands into a great number of diverging branches, like the facial nerve.

The *ascending* branches are distributed to the skin of the malar and buccal regions; one of them forms an anastomic arch with the facial nerve behind the duct of Steno. This anastomosis is very remarkable. The *middle* branches pass horizontally forward on a level with the commissure of the lips, and terminate in the skin; several of them form a sort of plexus around the inferior coronary artery of the lip. The lowest of the *descending* branches pass vertically downward, and even a little backward, upon the outer surface of the buccinator, also beneath the deep surface and upon the outer surface of

* We sometimes find a communicating filament between the superior and inferior maxillary nerves immediately before they enter their respective foramina.

† [There is hence a communication between the branches of the three divisions of the fifth nerve.]

‡ [This cutaneous filament is one of the temporal filaments of the orbital branch of the superior maxillary nerve.—(*Ellis's Demonstrations*; see note, p. 831.)]

the triangularis oris, and are entirely lost either in the skin or in the mucous membrane. It is doubtful whether the buccal nerve partially terminates in the orbicularis oris, the triangularis oris, and the zygomaticus major. All the filaments which enter these muscles, and which appear at first sight to terminate in their substance, pass through them to supply the mucous membrane; their branches anastomose with the mental nerve beneath the triangularis oris; several filaments are lost in the buccinator.

The Internal Pterygoid Nerve.

The *internal* collateral branch (*t*, *fig.* 299), or *nerve for the internal pterygoid muscle*, which is very slender, comes off from the inner side of the inferior maxillary nerve in contact with a grayish body, named the otic ganglion, runs downward and inward along the inner surface of the internal pterygoid muscle, and ramifies in it.

The Auriculo-temporal Nerve.

The *posterior* collateral branch, or the *auriculo-temporal nerve* (the *auricular* or *superficial temporal* nerve of authors), is very large, flattened, and plexiform at its origin (behind *c*, *fig.* 298; *r*, *fig.* 299); it sometimes arises by a great number of distinct roots; it passes backward and a little downward behind the neck of the condyle of the lower jaw, and divides into two branches, a *superior* or *ascending*, and an *inferior* or *descending* branch.

The *superior* or *ascending* branch, the superficial *temporal nerve*, turns round the back of the neck of the condyle, and ascends vertically between the articulation and the external auditory meatus; having become sub-cutaneous, it divides into several filaments (*r*, *fig* 285), which may be traced up to the highest part of the temporal fassa.

During its course this nerve gives off a very remarkable anastomotic branch, which arises behind the neck of the condyle, and is reflected upon it so as to run forward beneath the facial nerve, with which it is blended opposite to the posterior border of the masseter. This anastomotic branch is sometimes double. It may be regarded as one of the origins of the facial nerve, which increases considerably in size after having received it.

This branch is one of the principal communications between the facial nerve and the fifth nerve, and modern physiologists have justly attached great importance to it.

The ascending branch also gives off some plexiform branches to the temporo-maxillary articulation, and several filaments to the auditory meatus and the auricle. In the temporal region it anastomoses with a very small filament, which is derived from the deep temporal nerve, and which perforates the temporal fascia.*

It accompanies the temporal artery, for which it forms a sort of plexus, and then divides into cutaneous filaments, which reach the crown of the head.

The *inferior*, *descending*, or *auricular* branch is as large as the preceding; it forms a plexus around the internal maxillary artery, behind the condyle, and sometimes presents small ganglia; it divides into several branches, some of which pass through the parotid gland and are distributed to the lobe of the ear, while the others anastomose with some filaments of the auricularis magnus nerve derived from the cervical plexus. One of these branches joins the dental nerve, before that nerve enters the dental canal; another branch terminates in the temporo-maxillary articulation.

The Terminal Branches of the Inferior Maxillary Nerve.

The Lingual Nerve.

The *lingual* or *gustatory nerve* (*n*, *figs.* 298, 300; *n n'*, *fig.* 301) passes downward and forward: it is at first situated between the external pterygoid muscle and the pharynx, but it soon passes between the two pterygoids (*fig.* 300), then between the internal pterygoid and the ramus of the lower jaw (*fig.* 298), and then runs forward along the upper border of the sub-maxillary gland, between it and the buccal mucous membrane, and above the mylo-hyoid muscle; it then passes beneath the sub-lingual gland, which it crosses, to pass to its inner side, and, accompanied by the Warthonian duct, which lies to its inner side and crosses it at a very acute angle, it gains the corresponding border of the tongue, and ramifies in the substance of that organ.

Fig. 300.

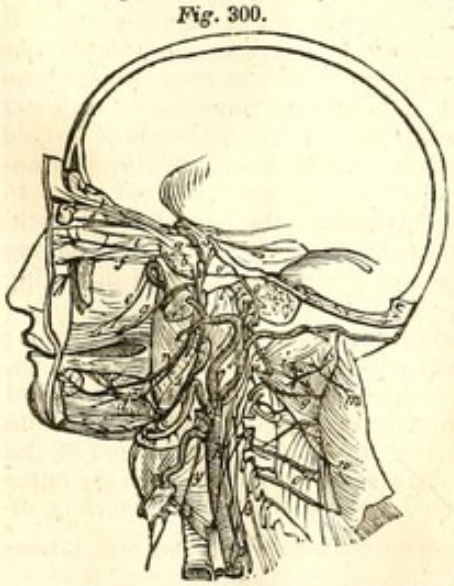

During its passage between the two pterygoids the lingual nerve is joined by that branch of the facial nerve which is known as the *chorda tympani* (*x*, *fig.* 298), and which unites to it behind, forming a very acute angle opening upward; this branch of the facial, which may be regarded as one of the roots

* [This perforating cutaneous filament is one of the temporal filaments of the orbital branch of the superior maxillary nerve (see notes, p. 831, 835).]

of the lingual, remains in contact with that nerve for some time, and is at last blended with it.

The lingual nerve also receives, sometimes before, and sometimes after being joined by the chorda tympani, a very considerable anastomotic branch from the inferior dental: this branch is rarely wanting.

After receiving these two branches, the lingual nerve becomes considerably increased in size, and during its course gives off several filaments to the tonsils, the mucous membrane of the cheeks and the gums.

Opposite the sub-maxillary gland, the lingual nerve presents a very remarkable ganglion, generally described as the *sub-maxillary ganglion* (situated behind *x*, *fig.* 300); the trunk of the nerve does not enter into its formation, but it appears to be formed only by its inferior filaments. It has been gratuitously supposed that this ganglion is formed exclusively by the chorda tympani, which, according to such a view, after running in mere contact with the lingual nerve, becomes detached from it (opposite *n*) to enter the ganglion (*x*): we have stated that there was equally little reason to suppose that the chorda tympani was the continuation of the cranial branch of the vidian. The sub-maxillary ganglion, the size of which is very variable, gives off a great number of filaments, most of which are distributed to the sub-maxillary gland; one of these filaments accompanies the Warthonian duct.

Having reached the sub-lingual gland, the lingual nerve supplies that gland with a great number of filaments, which dip into it and form a plexus of very delicate meshes.

In the tongue, the lingual nerve is situated at the lateral border of that organ, and on a plane above that of the hypoglossal nerve, with which it communicates by an anastomotic branch, forming a loop. It becomes gradually diminished in size by giving off a very numerous series of filaments (*n'*, *fig.* 301), which turn round the border of the tongue, pass forward and upward, perforate the muscles of that organ, and spread out into pencils, the filaments of which may be traced into the papillæ of the mucous membrane. The nerve, reduced to a single filament, terminates at the point of the tongue

The Inferior Dental Nerve.

The *inferior dental nerve* (*m*, *fig.* 298), larger* than the lingual, descends with it, at first between the two pterygoid muscles, and then between the internal pterygoid and the ramus of the lower jaw: in this situation it is kept in contact with the bone by a layer of fibrous tissue, which is improperly called the internal ligament of the temporo-maxillary articulation, and which separates the nerve from the lingual nerve and the internal pterygoid muscle; it soon enters the dental canal, which it traverses (*m*) throughout its entire extent, accompanied by the inferior dental artery, and protected by a fibrous canal; during its course it supplies the molar and the bicuspid teeth, giving a twig to each prong, and having reached the mental foramen, divides into a *mental* and an *incisor* branch.

The Myloid Branch.—As it enters the inferior dental canal, the nerve gives off a small branch, the *myloid branch* (*z*, *fig.* 300), which arises from its posterior border, opposite the corresponding artery, is received into a furrow upon the inner surface of the ramus of the jaw, against which it is retained by a layer of fibrous tissue, and then, emerging from this furrow, passes upon the upper surface of the mylo-hyoid muscle, in which it ramifies. A great number of filaments from the myloid nerve enter the anterior belly of the digastric muscle.†

The *mental branch* (*t*, *fig.* 285), the continuation of the inferior dental nerve, as far as size is concerned, passes through the mental foramen, and expands into diverging filaments, which are distributed, in reference to the lower lip, in the same way as the infra-orbital branch is to the upper lip. These filaments interlace with the facial nerve, and form with it a sort of *mental* plexus; they are intended for the skin and the mucous membrane of the lower lip: most of them pass to the free border of that lip.

The *incisor dental branch*, which is extremely small, continues in the original course of the inferior dental nerve, and subdivides to supply the canine and two corresponding incisor teeth.

The inferior dental nerve represents in the lower jaw the infra-orbital portion of the superior maxillary nerve in the upper jaw.

The Otic Ganglion.

I cannot terminate the description of the inferior maxillary nerve without noticing a ganglion recently described by Arnold, under the name of the *otic ganglion*, which he compares to the ophthalmic ganglion, and which has served him as the basis of an ingenious theory respecting the nerves of the head. The following is the position of the ganglion, as indicated by Arnold: "The otic ganglion is situated (behind *l*, *fig.* 299) immediately below the foramen ovale, on the inner side of the third or inferior maxillary

* I have observed that this nerve was much smaller in old than in young subjects.

† [Filaments are also given to the sub-maxillary gland; according to Ellis, some branches pass through the mylo-hyoid muscle and enter the genio-hyoid; and it is stated by Alcock that a branch reaches the depressor labii inferioris.]

division (*c*) of the fifth nerve, a little above the origin of the superficial temporal or auricular nerve (auriculo-temporal), at the spot where the inferior maxillary nerve gives off from its external surface the deep temporal and buccal nerves, and where the small root of the fifth unites intimately with the large root. On the inner side, this ganglion is covered by the cartilaginous portion of the Eustachian tube, and by the origin of the external peristaphyline (*circumflexus palati*) muscle ; behind, it is in contact with the middle meningeal artery. Its external surface rests upon the inner side of the inferior maxillary nerve."

There can be no doubt that in the situation indicated by Arnold, there is a thin and not very well-defined layer of reddish, pulpy tissue, placed upon the inner side of the internal pterygoid nerve, and which presents the chief characters of ganglionic tissue ; for it is traversed by nervous filaments, which proceed from it as from a centre, and run in various directions.

Its connexions with the inferior maxillary nerve are effected by its direct adhesion to that nerve, which adhesion, according to Arnold, takes place by means of several very short, nervous filaments (*short root*), which appear to come from the small root of the fifth pair, and also by its adhesion to the internal pterygoid nerve ; so that, at first sight, the ganglion would appear to originate from that nerve, or the nerve from the ganglion.

The otic ganglion is also connected with the glosso-pharyngeal by means of a filament, which Arnold describes under the name of the *small superficial petrosal nerve*, to distinguish it from the great superficial petrosal, or cranial branch of the vidian. This filament, which proceeds from *the nerve of Jacobson*, or tympanic branch of the glosso-pharyngeal, is compared by Arnold to the *long root* of the ophthalmic ganglion : it passes out of the cavity of the tympanum by a special canal, in front of the hiatus Fallopii, runs forward and outward (from 7 towards *c*, *fig.* 296), emerges from the cranium through a special foramen, between the petrous portion of the temporal bone and the spinous process of the sphenoid, and proceeds (above *l*, *fig.* 300) to enter the otic ganglion.* Arnold admits a third root for the otic ganglion, namely, a soft root, which he traces from the nervous plexus that surrounds the middle meningeal artery, and is derived from the great sympathetic.

The preceding filaments may be regarded as the filaments of origin of the otic ganglion.†

The Branches which proceed from the Otic Ganglion.—The principal filament from the otic ganglion runs backward and upward towards the canal which contains the internal muscle of the malleus, and is lost in that muscle. This twig must be carefully distinguished from the small superficial petrosal nerve, which is placed above it. Some other filaments join the auriculo-temporal nerve, which generally arises by two roots.

Lastly, the otic ganglion sends off a twig to the circumflexus palati muscle.

The Sixth Pair, or External Motor Nerves of the Eyes.

The very simple distribution of the external motor nerve of the eye, or sixth cranial nerve, contrasts strongly with that of the fifth nerve ; it arises from the furrow between the pons Varolii and the medulla oblongata, immediately forms two fasciculi or roots, a large and a small, which unite in the cavernous sinus ; they pass vertically upward, perforate the dura mater (*b*, *fig.* 296) at the side of the basilar groove by one or two openings, to the inner side of and below the fifth nerve, gain the apex of the petrous portion of the temporal bone, over which they turn, and then pass horizontally forward to enter the cavernous sinus. During the course of the nerve through that sinus, it rests upon its lower wall, crosses (above 6, *fig.* 301) on the outer side of the vertical portion of the internal carotid artery, around which it turns, and then runs along its horizontal portion. The sixth nerve forms a most important anastomosis, on account of which it was for a long time regarded as the origin of the great sympathetic. As it crosses the internal carotid in the cavernous sinus, it communicates by one or two filaments with the superior cervical ganglion. It also communicates, at the same point, with the ophthalmic division of the fifth nerve.

Lastly, it enters the orbit through the widest part of the sphenoidal fissure, passes through the fibrous ring which is common to it and to the inferior division of the common motor nerve, crosses, at an acute angle, beneath the ophthalmic nerve, and gains the inner surface of the external rectus, and penetrates that muscle, after having expanded into a pencil of very delicate filaments.

We shall again advert to the communication between this nerve and the superior cervical ganglion.

* This small superficial petrosal nerve is very distinct from the great superficial petrosal nerve, being situated in front of and parallel to that nerve. In a subject which I dissected in 1826, I found this small nerve presenting the following peculiarity : it had a well-marked nodule or ganglion, which gave off a filament to the middle meningeal artery, and some small twigs, which appeared to me to be lost in the substance of the sphenoid bone ; but I did not discover the connexions of this nerve.

† Arnold admits an indirect communication between the otic ganglion and the acoustic nerve through the intervention of the facial nerve. The existence of this communication appears to me very doubtful, as well as the communication of the otic ganglion with the great sympathetic, by means of the twigs on the middle meningeal artery.

The Seventh Pair of Nerves

The Portio Dura, or the Facial Nerve.

We have already traced the *facial nerve*, or the *portio dura of the seventh*, from its origin to the internal auditory meatus, which it enters together with the auditory nerve (7, *fig.* 296), which nerve lies below and behind the facial, and forms a groove for its reception. Having reached the bottom of the internal auditory meatus, this nerve follows the long course of the facial canal,* or *aqueduct of Fallopius*, a winding passage which is formed in the petrous portion of the temporal bone, and which opens by one end into the internal auditory meatus, and, by the other, upon the lower surface of the pars petrosa at the stylo-mastoid foramen.

The facial nerve traverses this canal, which is exclusively appropriated to it; it is at first directed outward (*n*, *fig.* 296), and, after proceeding for about a line, bends suddenly, and runs backward, in the substance of the internal wall of the cavity of the tympanum, above the fenestra ovalis. Having reached the back of the tympanum, it forms another bend, and passes vertically downward (*o*, *figs.* 298, 300) to the stylo-mastoid foramen. It follows, therefore, that the facial nerve describes two curves, like the aqueduct of Fallopius, and is horizontal in its first two portions and vertical in the third.

On emerging from the stylo-mastoid foramen, the facial nerve runs forward in the substance of the parotid gland, and, after a course of about five or six lines, divides into two terminal branches, the *temporo-facial* (*g*, *fig.* 285) and the *cervico-facial* (*f*), which expand into a great number of diverging filaments, and cover the temples, the whole of the face, and the upper part of the neck, with their radiations and anastomoses.

The facial nerve gives off and receives certain collateral branches before and others after its exit from the stylo-mastoid foramen.

The Collateral Branches of the Facial Nerve, before its Exit from the Stylo-mastoid Foramen.

In the *internal auditory meatus* the facial nerve receives some twigs from the auditory, a remarkable anastomosis, which deserves the attention of physiologists.

Opposite to the hiatus Fallopii, *i. e.*, at the first bend formed by the Fallopian aqueduct, the facial nerve is joined by the cranial branch of the vidian, or the great superficial petrosal nerve (*v*, *figs.* 296, 300). According to MM. Ribes, Hippolyte Cloquet, and Hirzel, this branch is applied to the facial nerve, but does not anastomose with it, and is detached from it lower down to constitute the chorda tympani nerve; and as the cranial branch of the vidian arises from the spheno-palatine ganglion, and the chorda tympani is supposed to enter the sub-maxillary ganglion, it is seen that, according to this view, the cranial branch of the vidian and the chorda tympani, which is regarded as its prolongation, would establish a communication between the spheno-palatine and sub-maxillary ganglia. It is by no means proved, however, that the chorda tympani enters the sub-maxillary ganglion; and, again, the supposed connexion between the cranial branch of the vidian and the chorda tympani is opposed to facts. The cranial branch of the vidian and the facial nerves, indeed, are not in mere juxtaposition, but anastomose and are blended with each other, and the chorda tympani has no sort of relation to the former of these nerves. This independence of the branch of the vidian nerve and the chorda tympani can be most clearly seen when the parts have been macerated in diluted nitric acid.†

If an explanation must be given of this remarkable anastomosis between the vidian and facial nerves, I would say that the cranial branch of the vidian may be regarded as a remote origin or a re-enforcing branch of the facial nerve.

The facial nerve, according to Sœmmering and those who have followed him, gives off a twig to the internal muscle of the malleus, and another to the small muscle of the stapes; but, in the first place, the existence of a stapedius muscle is doubtful, and, consequently, the existence of a corresponding nervous twig must also be so, and, in the second place, the internal muscle of the malleus is not supplied from the facial nerve, but from the inferior maxillary division of the fifth nerve, and more especially from that pulpy, reddish tissue, named by Arnold the otic ganglion.

Before leaving the aqueduct of Fallopius, the facial nerve (*n*, *fig.* 296) gives a remarkable filament, named the *chorda tympani*, which pursues a recurrent course (*y*) from below upward in a peculiar canal, parallel to the aqueduct of Fallopius, enters the cavity of the tympanum through an opening to the inner side of and behind the attachment of the membrana tympani, passes downward and forward through the cavity of the tym-

* For what purpose is this long course within the petrous portion of the temporal bone? Those physiologists who believe the facial nerve to be of a mixed nature, that is, both sensory and motor, have laid great stress upon this point, which they conceive to be favourable to their views; but there is not the slightest shadow of a proof that the facial nerve possesses these two properties.

† Arnold has pointed out, at the junction of the cranial branch of the vidian with the facial nerve, a *gangliform swelling*, which he regards as a transition between a gangliform enlargement and a true ganglion; from this swelling, which he compares to the ganglia of the posterior roots of the spinal nerves, he says a filament is given off to anastomose with the auditory nerve at the bottom of the internal auditory meatus. I have not been fortunate enough to discover this filament; nor have I ever seen any gangliform appearance at the junction of the vidian and facial nerves.

panum, between the handle of the malleus and the vertical ramus of the incus, and emerging from that cavity (*x*, *fig.* 298), not through the Glasserian fissure, but through a special opening already described (see ORGAN OF HEARING—*Cavity of the Tympanum*), is applied to the lingual nerve (*n*), of which it may be regarded as a late origin, or re-enforcing branch.

The facial branch also receives, in the aqueduct of Fallopius, opposite to where it gives off the chorda tympani, a very remarkable branch from the pneumogastric nerve, which Arnold has named the *auricular branch of the pneumogastric.*

The Collateral Branches of the Facial Nerve, after its Exit from the Stylo-mastoid Foramen.

Before its terminal division, the facial nerve gives off two branches, the *posterior auricular* and the *styloid.* I have never seen any parotid branch, properly so called.

The *posterior auricular*, which would be better named the *auriculo-occipital*, comes off from the nerve within the stylo-mastoid foramen, and is immediately applied against the mastoid process, turning round over its anterior and then its outer surface ;* as it lies in front of the mastoid process, it anastomoses with a remarkable twig from the deep auricular branch of the auricularis magnus from the cervical plexus ;† after this, it divides into two branches : an *ascending* or *auricular* branch (*m*, *fig.* 299), properly so called, which, having first supplied, then perforates the posterior auricular muscle, turns round the auricle, and terminates in the superior auricular muscle ; and a *horizontal* or *occipital* branch (*v*, *fig.* 285), which is larger, and forms the continuation of the nerve ; it passes immediately beneath the posterior auricular muscle, to which it gives some filaments, then runs exactly along the superior semicircular line of the occipital bone, and terminates by giving off from its upper side a series of small filaments, which are lost in the occipital portion of the occipito-frontalis : they can be traced as far as the median line, but none of them are distributed to the skin.

The *styloid branch* arises from the back of the facial nerve, at its exit from the stylo-mastoid foramen, and enters the stylo-hyoid muscle, after having run along its upper border.

The *posterior mastoid* or *digastric branch* often arises by a common trunk with the preceding, enters the posterior belly of the digastric muscle, and sends off an anastomotic twig to the glosso-pharyngeal nerve.

The Terminal Branches of the Facial Nerve.

The Temporo-facial Nerve.

The *temporo-facial nerve* (*g*, *fig.* 285) passes upward and forward in the substance of the parotid, forming, with the trunk of the facial nerve, an arch having its concavity turned upward ; it crosses the neck of the condyle of the lower jaw, and receives in this situation, by its deep surface, one, or sometimes two branches from the auriculo-temporal nerve, a branch of the inferior maxillary. This anastomotic branch establishes a very important connexion between the fifth and facial nerves.

The temporo-facial nerve, which is flattened and plexiform where it is joined by the branch from the fifth, afterward expands into a number of filaments, which anastomose with each other, so as to form arches, from the convexity of which a number of diverging filaments of unequal size proceed like rays, and cover the whole space comprised between a vertical line drawn in front of the ear, and a horizontal line corresponding to the base of the nose.

All these branches, which anastomose several times with each other, and form a succession of arches somewhat resembling those of the mesenteric arteries, may be divided into the *temporal*, the *orbital*, and the *infra-orbital* or *buccal* branches.

The *temporal branches* ascend, cross over the zygomatic arch at right angles, and cover with their ramifications the whole of the temporal and frontal regions, anastomosing with filaments from the frontal branch of the first [from the orbital branch of the second], and from the auriculo-temporal branch of the third division of the fifth nerve.

All these branches lie between the skin and the temporal aponeuroses : some of them supply the skin, but the majority are distributed to the frontal portion of the occipito-frontalis muscle, below which they are situated, and may be traced as far as the median line.

The *orbital branches* may be divided into the *superior palpebral*, which are remarkably long, and pass beneath the orbicularis palpebrarum, to ramify in that muscle and the corrugator supercilii. Several of these anastomose with twigs from the supra-orbital nerve : the *middle palpebral branches*, which gain the outer angle of the eyelids, and are distributed between the upper and lower eyelids, and the *superior palpebral branches*, which are generally named the *malar* branches ; they pass horizontally forward, opposite to the lower part of the orbicularis palpebrarum, and are reflected upward, to enter the

* This little nerve is lodged in the furrow between the mastoid and vaginal processes (see OSTEOLOGY, p. 43).

† [It is also joined, according to Arnold, by a filament from the auricular branch of the pneumogastric (see note, p. 844).

substance of the lower eyelid, between the palpebral aponeurosis and the palpebral portion of the orbicularis, in which they terminate.

They may be traced as far as the free border of the tarsal cartilage, where they anastomose with each other.

The *infra-orbital* or *buccal branches* of the temporo-facial are given off from one or two large branches which accompany the Stenonian duct; they expand into a great number of filaments, which may be divided into a *superficial* and a *deep set*: the *superficial* branches run beneath the skin, and above the orbicularis oris, the two zygomatic, and the levator labii superioris, all of which they supply; there can be no doubt that they also give cutaneous filaments; these are very small, and very long, and may be followed as far as the hair follicles in the upper lip; some of these superficial branches reach the lower eyelid, several accompany the facial and angular veins, anastomose with twigs from the infra-trochlear branch of the nasal nerve, and ascend as far as the pyramidalis nasi, in which they terminate.

The *deep branches* pass beneath the levator labii superioris, send off numerous filaments to that and the levator anguli oris, and form, together with the terminal divisions of the infra-orbital branch of the superior maxillary, a very remarkable plexus, which may be called the infra-orbital.

This plexus is formed by the interlacement of the radiating branches of the facial nerve with those of the infra-orbital branch of the superior maxillary division of the fifth nerve. Now, as the facial nerve radiates from without inward, and the infra-orbital from above downward, it follows that the branches of these two nerves meet each other at right angles. This arrangement can be rendered more evident by pulling the two sets of nerves in the direction of their length. Most of these branches interlace without anastomosing, and proceed directly to their destination. The destination of the facial nerve is evidently rather to the muscles than to the skin; that of the infra-orbital branch of the fifth nerve is rather to the skin and mucous membrane than to the muscles; nevertheless, it cannot be doubted that the facial nerve supplies some cutaneous filaments, and that the fifth nerve gives some twigs to the muscles. Besides, there are some undoubted anastomoses between these two nerves. The facial also communicates very freely with the buccal nerve, a branch of the inferior maxillary.

The infra-orbital branches of the temporo-facial nerve supply the two zygomatics, the levator labii superioris, the levator labii superioris alæque nasi, the depressor alæ nasi, the transversalis nasi, the levator anguli oris, and the orbicularis oris. I would also point out a very remarkable branch, which enters the substance of the ala of the nose, and appears to be intended for that sort of sphincter muscle found in the cutaneous fold of the alæ. This branch anastomoses with the naso-lobar branch of the internal nasal nerve.

The infra-orbital branches of the fifth nerve are distinguished from the infra-orbital branches of the facial nerve, by their direction; by being more deeply seated; by being much larger; and by being arranged in successive layers, which are three in number: a sub-cutaneous, a sub-mucous, and a muscular; this last set perforates the orbicularis oris, in which some filaments appear to terminate. Among the infra-orbital branches of the fifth nerve, there is one which may be called the *nerve of the sub-septum*, which runs on the side of the median line, as far as the tip of the nose, where it terminates. Lastly, the infra-orbital branches of the fifth give a dorsal branch for the nose, and two ascending palpebral branches, which can be easily distinguished from the palpebral branches of the facial nerve.

The Cervico-facial Nerve.

The *cervico-facial nerve* (*f*, *fig.* 285), which is smaller than the temporo-facial, follows the original course of the facial nerve, and, like it, runs downward and forward in the parotid gland; opposite to the angle of the lower jaw it divides into three or four branches, which subdivide into secondary branches, which may be arranged into the *buccal*, *mental*, and *cervical* sets.

The *buccal branches* run horizontally forward in front of the masseter, to which they give off some small filaments, and then anastomose with each other and with the infra-orbital branches of the temporo-facial nerve. A very beautiful anastomosis is found between the buccal branch of the inferior maxillary and one of these buccal branches of the cervico-facial nerve: we have already pointed out a similar anastomosis between an infra-orbital branch of the temporo-facial and this same buccal branch of the inferior maxillary.

The *mental branches* are intended for the lower lip. They are reflected upward, so as to describe an arch having its concavity directed upward; they are at first situated beneath the platysma myoides, then pass beneath the triangularis oris, and form, with the mental branch of the inferior maxillary division of the fifth nerve, an interlacement or mental plexus, which has a close analogy with the interlacement of the infra-orbital branches of the facial with those of the superior maxillary division of the fifth nerve, but is less complicated.

Thus, the mental branches of the facial nerve are more superficial than those of the fifth, and their filaments are smaller; the radiating branches of the facial nerve run at first forward and then upward, while those of the fifth nerve run directly upward. The mental branches of the facial nerve perforate the quadratus menti and the orbicularis oris, to which muscles they are almost entirely distributed; they also send several long and slender filaments to the point of the chin, some of which are cutaneous. The mental branches of the fifth nerve are chiefly situated between the muscles and the mucous membrane, to which latter they are distributed, more especially to the free borders of the lower lip.

The *cervical branches* of the cervico-facial run forward in the supra-hyoid region, beneath the platysma, and, describing arches with their concavities turned upward, they pass upward and forward to terminate near the chin. Among these branches, there is one which passes vertically downward to anastomose with the superficial cervical nerve of the cervical plexus.

The cervical branches of the facial nerve are separated from the cervical branches of the cervical plexus by the platysma, and they are all distributed to that muscle and the levator labii superioris.

Summary.—The facial nerve supplies all the cutaneous muscles of the cranium and of the face, and, therefore, section and compression of this nerve cause complete paralysis of these muscles: it is the nerve of expression, or the respiratory nerve of the face (*Bell*); it also evidently gives off some cutaneous filaments, especially near the commissure of the lips, and this may explain the numbness which I have known to occur in individuals affected with hemiplegia of the face; lastly, it furnishes a great number of anastomotic filaments (whence it has been called the small sympathetic); these are given to the branches of the cervical plexus, to the auditory nerve, to the pneumogastric, and more especially to the fifth nerve.

The anastomoses of the facial with the fifth nerve merit special notice; they are effected with the frontal and nasal nerves of the ophthalmic or first division of the fifth; with the superior maxillary or second division by means of the infra-orbital nerves and the cranial branch of the vidian, which latter I even regard as one of the origins of the facial nerve; and with the inferior maxillary or third division of the fifth by means of the mental nerve, the buccal nerve, and more especially the auriculo-temporal nerve. The branch given by the auriculo-temporal to the facial nerve may be regarded as one of the origins of the last-mentioned nerve.

Notwithstanding these numerous anastomoses, the facial nerve and the fifth nerve cannot supply the place of each other. Anatomy shows no difference in the structure of these nerves, but a great difference in their distribution; the facial nerve being intended for the muscles, while the fifth is distributed to the integuments and the organs of the senses.

Function.—The facial is a nerve of motion. This fact may be deduced from its anatomical description no less than from physiological experiments and the effects of disease.

The Portio Mollis, or the Auditory Nerve.

The *auditory nerve* (7, *figs.* 296, 301), which we have already traced as far as the internal auditory meatus, enters that canal with the facial nerve, for which it forms a groove, and divides into two cords, which remain distinct throughout the whole extent of the passage, but continue in contact with each other, and at length pass through the foramina in the cribriform plate already described as existing at the bottom of the meatus (see OSTEOLOGY).

In order to understand the farther distribution of the auditory nerve, the cribriform plate of the auditory meatus must be examined with the same attention as was devoted by Scarpa to the cribriform plate of the ethmoid, with which it has so many analogies. As the cribriform plate of the ethmoid presents a particular fissure for the passage of the ethmoidal branch of the ophthalmic nerve, so the cribriform plate of the internal auditory meatus presents a special opening for the passage of the facial nerve; and again, the auditory, like the olfactory nerve, seems as if it were pressed through the foramina of the cribriform plate to enter the internal ear.

Of the two terminal branches of the auditory nerve, the anterior is intended for the *cochlea*, the posterior for the *vestibule* and *semicircular canals*.

The *cochlear branch* turns spirally, like that part of the bottom of the auditory meatus to which it belongs, and which is called the tractus spiralis. It then turns upon itself, as observed by Valsalva, and presents somewhat of a ganglionic appearance. From this sort of enlargement the cochlear filaments proceed; those which belong to the first turn of the cochlea run along the surface of the modiolus; the others enter the canals of the modiolus, and are distributed on the second, and the succeeding half turn at the summit of the cochlea. I have already described the very regular manner in which these filaments spread upon the spiral septum, the subdivision of each of them into two or three filaments, which anastomose with each other like the ciliary nerves, and the gradual diminution in the length of these filaments from the base to the apex of the cochlea; so that,

if we suppose the spiral septum spread out, it might be compared to a harpsichord, the longest strings of which would be represented by the filaments at the base of the triangle formed by the septum, and the shortest by those at its apex (see INTERNAL EAR, p. 681).

The *vestibular branch* divides into three parts, the largest of which enters the *utricle* and the *ampullæ* of the superior vertical and horizontal membranous canals, the middle-sized branch passes to the *sacculus*, and the smallest branch to the *ampulla* of the posterior or inferior vertical semicircular canal.

Function.—The auditory nerve is exclusively the nerve of hearing.

THE EIGHTH PAIR OF NERVES.

The First Portion, or Glosso-Pharyngeal Nerve.

Dissection.—Remove, by a triangular section, the posterior half of the border of the foramen lacerum posterius; carefully detach the jugular vein, in front of which the nerves are situated, examine the connexions of the glosso-pharyngeal with the pneumogastric and spinal accessory nerves.

The *glosso-pharyngeal nerve* (*pharyngo-glossal*), the *anterior portion of the eighth nerve* (8, *figs.* 296, 301), the *ninth nerve of some authors*, is intended for the pharynx and the tongue.

Having arisen from the restiform body, above and on a line with the pneumogastric,* by a series of roots which are continuous with the roots of that nerve, the glosso-pharyngeal emerges from the foramen lacerum posterius through a fibrous canal which is proper to it, and which is situated in front of the canal that is common to the pneumogastric and spinal accessory nerves; it is placed to the inner side of the internal jugular vein, from which it is separated by a cartilaginous and sometimes osseous lamina.

During its passage through this canal it presents a ganglionic enlargement, which was described by Andersh under the name of *ganglion petrosum*, and is now more generally known as the *ganglion of Andersh*.

This ganglion is situated in a depression on the petrous portion of the temporal bone (*receptaculum ganglii petrosi*); from it the nerve proceeds as a rounded cord, which descends vertically (*l*, *fig.* 301) behind the styloid muscle in front of the internal carotid, then between the stylo-pharyngeus and the stylo-glossus, and passing forward so as to describe a curve with its concavity turned upward, runs in front of the posterior pillar of the fauces and behind the tonsil, and then passing beneath the hyo-glossus muscle (*z*), ramifies, to enter the base of the tongue and supply the mucous membrane.

Fig. 301.

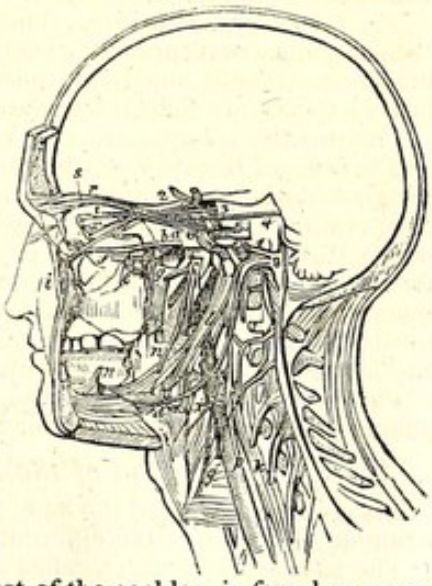

During this course it gives off the nerve of Jacobson, and an anastomotic twig to the facial nerve; it communicates with the spinal accessory and the pneumogastric; it gives off a muscular branch to the digastricus and stylo-pharyngeus, and it supplies some carotid filaments, and some pharyngeal and tonsillar branches.

The Nerve of Jacobson.—In order to facilitate the study of the course of this nerve, I shall first describe the canals through which it passes:

Upon the ridge which separates the jugular fossa from the carotid canal, to the outer side of the aqueduct of the cochlea, is found an opening, which is the inferior orifice of the canal of Jacobson. This canal runs backward and upward into the substance of the internal wall of the cavity of the tympanum, in front of the fenestra rotunda; there it branches into three canals: one *descending*, which opens into the carotid canal; and two ascending canals, an anterior, which runs forward and upward, and opens into the groove for the great superficial petrosal or cranial branch of the vidian nerve, and a posterior, which at first ascends vertically behind the fenestra ovalis, then curves suddenly and becomes horizontal, and opens upon the upper surface of the pars petrosa in a groove parallel to and on the outer side of the groove for the cranial branch of the vidian nerve.

The nerve of Jacobson, which comes off from the petrosal ganglion, or ganglion of Andersh, enters this canal. In one subject I found it to consist of two filaments, one from the pneumogastric, and the other from the glosso-pharyngeal.†

This nerve soon divides into three filaments corresponding to the three branches of the

* Several modern physiologists, believing the glosso-pharyngeal to be a mixed nerve, sensory in its lingual portion, and motor in its pharyngeal, have, therefore, supposed it to have two distinct roots: a larger, which is near the par vagum, and a smaller, which lies near the facial nerve; and, from analogy, they regard the former as the sensory, and the latter as the motor root.

† In another subject it was formed by the anastomoses of a twig from the auricular branch of the pneumogastric with a twig from the glosso-pharyngeal.

canal; the descending filament joins the carotid plexus; of the two ascending filaments, one anastomoses with the cranial branch of the vidian, or the great superficial petrosal nerve (*v*, *fig.* 300), while the other constitutes the small superficial petrosal nerve, which reaches the upper surface of the pars petrosa in front of the preceding, and terminates in the reddish tissue known as the otic ganglion.*

It follows, therefore, that the nerve of Jacobson connects the glosso-pharyngeal nerve with the superior maxillary division of the fifth nerve (especially with the spheno-palatine ganglion through the intervention of the vidian nerve), with the otic ganglion of the inferior maxillary division, and with the superior cervical ganglion of the sympathetic.

The *anastomotic branch* to the *facial* nerve arises from the ganglion of Andersh immediately below the nerve of Jacobson; it runs downward and outward behind the styloid process, is then reflected upward, so as to describe a loop with its concavity turned upward, and anastomoses with the facial immediately after the exit of that nerve from the stylo-mastoid foramen. This branch appears to me to be the remaining trace of a considerable branch of the facial nerve, which I have seen partially supplying the place of the glosso-pharyngeal (see the TONGUE, p. 646).

The Anastomosis of the Glosso-pharyngeal with the Spinal Accessory and Pneumogastric Nerves.—Most commonly the glosso-pharyngeal runs along the pneumogastric, or, more correctly, along the anastomotic branch of the spinal accessory. Sometimes it is completely separated from these nerves, and merely communicates with them by means of its pharyngeal branches.

The Branch for the Digastricus and Stylo-hyoideus.—This branch comes off from the outer side of the nerve, and bifurcates; one of its divisions enters the posterior belly of the digastricus, and the other supplies the stylo-pharyngeus and stylo-hyoideus. It has already been stated that this branch anastomoses with the facial nerve in the digastric muscle.

The Carotid Filaments.—These are very numerous; they descend along the internal carotid artery, and, having reached the point of bifurcation of the common carotid, anastomose with the carotid filaments of the superior cervical ganglion, and assist in forming the arterial plexus. I have not been able to trace them below the bifurcation of the common carotid. Some of these filaments are described as joining the cardiac nerves.

The Pharyngeal Branches.—These are two or three in number; they anastomose with the pharyngeal branches of the pneumogastric, to constitute the pharyngeal plexus. These branches evidently supply the middle and superior constrictors. The filaments for the latter muscles are reflected upward upon the posterior surface of the pharynx.

The *tonsillar branches* are very numerous, and form a sort of plexus.

The Lingual Branches.—After having given off the different branches above mentioned, the glosso-pharyngeal, reduced to half its original size, enters the base of the tongue, and then ramifies; some of its lingual branches lie close beneath the mucous membrane; others traverse the upper layers of the muscular substance of the tongue to proceed to the mucous membrane in front of the preceding branches; they are all intended for the mucous membrane; the internal branches proceed from without inward at the side of the median line, while the external runs along the border of the tongue; I have never seen any filament terminating in the muscular fibres.

Function.—From its distribution, this nerve must be regarded as a motor nerve for the pharynx, and a sensory nerve for the base of the tongue.

The Second Portion of the Eighth Nerve, or the Pneumogastric Nerve.

Dissection.—Lay open the back part of the foramen lacerum posterius, and afterward examine the nerve in the different parts of its course successively.

The *pneumogastric nerve*, called also the vagus nerve, the *par vagum*, and the *tenth cranial nerve* of some modern authors, is the principal branch of the eighth nerve (8, *fig.* 301), and is one of the most remarkable nerves in the body, both on account of the extent of its distribution, and of the importance of the organs supplied by it. It supplies branches, on the one hand, to the larynx, the lungs, and the heart; and, on the other, to the pharynx, the œsophagus, the stomach, and the solar plexus.

It has already been stated that this nerve arises from the upper part of the medulla oblongata, upon the restiform bodies, and in a line with the posterior roots of the spinal nerves; that its filaments of origin converge, and then unite at first into seven or eight fasciculi, and then into a single cord, which passes towards the foramen lacerum posterius, through which it emerges from the cranium. The pneumogastric nerve then runs vertically (*p*, *fig.* 301) in the neck along the vertebral column, enters the thorax, runs along the œsophagus, with which it passes through the diaphragm, and terminates on the stomach and in the solar plexus.

We shall now proceed to examine this nerve while it is within the foramen lacerum

* Arnold admits six filaments for the nerve of Jacobson, and, consequently, six small ducts as branches of the canal of Jacobson; these six filaments consist of the three described in the text above, and of a twig for the fenestra rotunda, one for the fenestra ovalis, and one for the Eustachian tube. I have distinctly seen the twig for the fenestra ovalis, that is to say, a twig which reaches the margin of the fenestra ovalis, but cannot be traced any farther. I have also seen the twig which passes to the Eustachian tube; but I have not yet been able to find the twig for the fenestra rotunda.

posterius ; as it is emerging from that foramen ; and as it descends in the neck, in the thorax, and in the abdomen.

The Pneumogastric Nerve within the Foramen Lacerum Posterius.

At the foramen lacerum posterius, the pneumogastric nerve passes through the same opening as the spinal accessory, which lies in contact with it ; a fibrous, cartilaginous, or bony septum separates it from the glosso-pharyngeal, which lies in front of it ; and another cartilaginous and often bony septum separates it from the internal jugular vein.

As it is passing through the foramen it presents a well-marked ganglionic structure ; I would say, rather, a gray substance containing white nervous filaments, but without any observable swelling : hence most anatomists have denied the existence of a ganglion at this spot.

To this ganglion, the *ganglion of the pneumogastric*, which may be compared to the Gasserian ganglion and to the inter-vertebral ganglia, the spinal accessory nerve is applied, and is connected with it by several very delicate filaments. I have already stated that, not unfrequently, the highest roots of the spinal accessory nerve join the pneumogastric directly.

This ganglion gives off an anastomotic twig, which enters the petrosal ganglion of the glosso-pharyngeal : I have not always found this filament ; it also gives an *anastomotic branch* to the *facial nerve*, viz., the *auricular* branch of the *pneumogastric* of Arnold. This branch might be called the *branch of the jugular fossa ;* it can be very well seen through the coats of the jugular vein when that vessel is laid open. It runs along the anterior part of the jugular fossa, between it and the internal jugular vein, gives off an anastomotic twig to the nerve of Jacobson, enters the temporal bone through an opening in the jugular fossa, near the styloid process, and traverses a very short canal, which conducts it directly into the Fallopian aqueduct, in which it anastomoses with the facial nerve.*

The Pneumogastric Nerve, at its Exit from the Foramen Lacerum Posterius.

At its exit from the foramen lacerum posterius, the pneumogastric nerve presents the appearance of a plexiform cord, which is often accompanied by the gray matter of the ganglion for the space of about six lines or an inch. This plexiform cord has certain important connexions with the spinal accessory, the ninth or hypo-glossal nerve, the glosso-pharyngeal nerve, and the superior cervical ganglion.

It is joined by one of the branches of bifurcation of the spinal accessory, which we shall name the *internal* or *anastomotic branch* of the spinal accessory nerve ; it becomes applied to the pneumogastric nerve, and may be distinguished from it for a considerable distance.

It also anastomoses with the hypo-glossal, at the point where it is crossed by that nerve, and at other times above that point. This anastomosis, moreover, is subject to great variety ; sometimes it takes place by a very small filament, at other times by two or three twigs, which form a sort of plexus.

It also anastomoses with the glosso-pharyngeal. The examination of this anastomosis, after the parts had been macerated in diluted nitric acid, enabled me to see that it is not, properly speaking, effected with the pneumogastric nerve, but with the anastomotic branch of the spinal accessory. Nothing can be more variable than these anastomoses, which are sometimes wanting on one side, and which are rather frequently effected through the intervention of the pharyngeal branches.

Lastly, the pneumogastric nerve communicates with the great sympathetic by one or two branches in man and some mammalia ;† in the other classes of animals the connexion is so intimate that it is altogether impossible to separate the pneumogastric from the superior cervical ganglion.

The connexions of the pneumogastric with the spinal accessory and superior cervical ganglion are two very important points in its anatomy.‡

The Pneumogastric Nerve in the Neck.

In the cervical region, the pneumogastric nerve (*p, figs.* 298, 300, 301) is situated in front of the vertebral column, the prævertebral muscles intervening between them, upon the side of the pharynx and œsophagus, and between the internal and then the common carotid, which are on its inner side, and the jugular vein, which is on its outer side ; it is placed behind these vessels. It is closely applied to the carotid artery, being in the same

* I have seen this branch, immediately after its origin, enter the sheath of the glosso-pharyngeal nerve, run along its ganglion, and then curve backward to enter the jugular fossa. Arnold, who first described this anastomotic branch, represents it as divided into three filaments : an ascending, which anastomoses with the trunk of the facial nerve ; a descending, which anastomoses with the posterior auricular branch of the same nerve ; and a middle (*u, fig.* 299), which ramifies upon the external auditory meatus.

† I have seen the pneumogastric nerve communicate with the great sympathetic, by filaments which come off at different heights from the cervical ganglion ; two proceeded from the upper part of the superior cervical ganglion, and then ascended ; and two came from the lower part of the ganglion, and descended to unite with the pneumogastric. I have met with a case in which the superior cervical ganglion was applied in its whole extent so closely to the pneumogastric that it was impossible to separate them.

‡ [The pneumogastric also receives a filament from the anastomotic loop of the first and second cervical nerves (see p. 777).]

sheath: it is separated from the cervical portion of the great sympathetic (*k*), which lies behind and to the outer side of it, by a great quantity of cellular tissue.

During this course it supplies the pharyngeal branch, the superior laryngeal nerve, and the cardiac filaments.

The Pharyngeal Branch, or Small Pharyngeal Nerve.—This is often double, and is then distinguishable into a superior and an inferior; it comes off at a little distance from the foramen lacerum posterius, but its real origin is variable. In some cases it arises exclusively from the pneumogastric; at other times exclusively from the anastomotic branch of the spinal accessory, which, as already stated, does not become immediately blended with the pneumogastric; and it often arises both from the pneumogastric and the spinal accessory: lastly, the glosso-pharyngeal sometimes gives it a filament. It passes behind the internal carotid, gives off some carotid filaments, which join the more numerous twigs from the glosso-pharyngeal, and then anastomoses with the ramifications of the glosso-pharyngeal, and with several large branches from the superior cervical ganglion, to form the *pharyngeal plexus*, which is one of the most remarkable plexuses in the body, and to which the varied and frequent nervous phenomena observed in that region must be referred. I shall recur to this plexus when describing the great sympathetic.

The Superior Laryngeal Nerve (*x'*, *fig.* 301).—This is larger than the pharyngeal branch; it comes off from the inner side of the pneumogastric* as a rounded cord, which may be traced as high as the ganglion of the nerve; it passes downward and inward upon the side of the pharynx, behind the internal and external carotid arteries, which it crosses obliquely: it then turns forward and inward to gain the thyro-hyoid membrane, passing above the upper margin of the inferior constrictor of the pharynx; it runs for some time between the thyro-hyoid muscle and the thyro-hyoid membrane, perforates the latter at the side of the median line, and then enters the substance of the aryteno-epiglottid fold of mucous membrane, where it terminates by dividing into a great number of filaments.

During its course, it gives off a branch which is called the *external laryngeal* (*y*), and which I have seen arise directly from the pneumogastric itself; this branch communicates with the superior cervical ganglion by one or two filaments, and passes inward and downward upon the side of the larynx. It gives off one or two filaments, which anastomose with the superior cardiac nerve, behind the common carotid; Haller calls this communication between the external laryngeal and the great sympathetic the *laryngeal plexus*.† The external laryngeal nerve also gives off several branches to the inferior constrictor of the pharynx, some to join the pharyngeal plexus, and some twigs to the thyroid gland; it then passes downward and forward between the inferior constrictor and the thyroid cartilage, and terminates by ramifying in the *crico-thyroid* muscle.

The *terminal expansion* of the superior laryngeal nerve is remarkable for its radiated arrangement; it is preceded by a flattening and thickening of the nerve. These expanded branches are all sub-mucous, and may be arranged into the *anterior* or *epiglottid*, and the *posterior*.

The *anterior* or *epiglottid branches* are numerous and small; they run upon the margin, and on the fore part of the epiglottis; some of them reach its free extremity, others run between the fibro-cartilage of the epiglottis and the adipose tissue, called the epiglottid gland; some of them perforate the epiglottis, and ramify upon its posterior surface.

Among these anterior terminal filaments of the superior laryngeal nerve there is at least one which runs forward under the mucous membrane covering the base of the tongue, and may be traced as far as the two rows of glands, which are arranged like the letter V. These filaments of the superior laryngeal nerve to the tongue are placed between the lingual branches of the right and left glosso-pharyngeal nerves, with which they have probably been confounded.

The *posterior* or *laryngeal filaments* contained in the aryteno-epiglottid fold are more numerous than the anterior branches; they are divided into the *mucous filaments*, the *arytenoid filament*, and the *anastomotic* or *descending filament*.

The *mucous filaments* are very numerous, and run upward in the aryteno-epiglottid fold; some of them lie beneath the external, and others beneath the internal layer of mucous membrane of this fold. They are intended for these two layers, and they terminate, for the most part, at the superior orifice of the larynx: their number explains the exquisite sensibility of this opening. Some of these mucous filaments may be traced into the substance of the arytenoid glands.

The *filament for the arytenoid muscle* is very liable to be confounded with the mucous

* It arises, therefore, on the opposite side to the anastomotic branch of the spinal accessory, which has not appeared to me to assist in its formation. I have seen the superior laryngeal arise by two roots, the larger of which came from the pneumogastric, while the other, which was very small, came from the glosso-pharyngeal. It appears to me that M. Bischoff's remarks concerning the origin of the superior laryngeal nerve on a level with the spinal accessory, would apply to the pharyngeal branch of the pneumogastric.

† The superior laryngeal nerve (*x'*, *fig.* 301) forms a loop behind the carotids, like that formed by the hypoglossal (*d*) in front of them, but lower down in the neck; that portion of the nerve which runs between the thyro-hyoid membrane and the thyro-hyoid muscle is exceedingly tortuous in some positions of the larynx.

filaments; it perforates the muscle from behind forward, and is partly distributed to it and partly to the lining membrane of the larynx.

The *descending* or *anastomotic filament*, which is small, but of variable size, descends vertically, between the mucous membrane on the one hand, and the thyro- and crico-arytenoid muscles on the other, gains the posterior surface of the cricoid cartilage, and anastomoses upon it with the recurrent laryngeal nerve. This remarkable anastomosis was known to Galen.*

Thus, the superior laryngeal nerve chiefly belongs to the mucous membrane of the larynx; but it gives branches to the arytenoid and crico-thyroid muscles: the branch for the latter comes from the external laryngeal division of this nerve.

The Cardiac Branches of the Pneumogastric Nerve of the Neck.—These vary both in number and size in different subjects, and even upon the two sides of the same body: they come off at different heights from the trunk of the pneumogastric; some of them, after a course of variable extent, join the superior cardiac nerves, either in the neck or in the thorax; the others pass directly to the cardiac plexus. The most remarkable of the cervical cardiac branches of the pneumogastric is that which comes off at the lower part of the neck, a little above the first rib; on the right side, it descends in front of the common carotid, and then in front of the brachio-cephalic artery, below which it anastomoses with the superior cardiac nerve. On the left side, it passes in front of the arch of the aorta, and anastomoses below that vessel with the superior cardiac nerve of that side. This branch sometimes goes directly to the cardiac plexus: it is sometimes double.

The Pneumogastric Nerve in the Thorax.

The *thoracic portion of the pneumogastric nerve* presents this peculiarity, that it differs remarkably on the right and left sides.

On the *right side*, the nerve (*p*, *fig.* 302) enters the thorax between the sub-clavian vein and artery: lower down, it passes behind the brachio-cephalic vein and the superior cava, and behind the phrenic nerve, at the side of the trachea, or, rather, in the groove between the trachea and œsophagus: it then passes behind the root of the lung, where it becomes flattened and enlarged, gives off a great number of branches, and appears to expand, in order to unite in a different arrangement. Below the root of the lung the right pneumogastric is always divided into two flattened branches, which run along the right side of the œsophagus, join together at a short distance from the diaphragm, and pass behind the œsophagus, with which canal the common trunk enters the abdomen.

On the *left side*, the pneumogastric enters the thorax between the common carotid and the sub-clavian artery, in the triangular interval between those vessels, internal to and then behind the phrenic nerve, behind the brachio-cephalic vein, and to the left of the arch of the aorta;† it then passes behind the left bronchus, upon which it ramifies, and unites again into one or two branches, which pass in front of the œsophagus, and enter the abdomen with it.

In the thorax the pneumogastric gives off the *recurrent* or *inferior laryngeal nerve*, a *cardiac branch*, some *tracheal* and *œsophageal branches*, and branches to the anterior and posterior pulmonary plexuses.

The Recurrent or Inferior Laryngeal Nerve.‡

This nerve (*r*, *fig.* 302), so called on account of its reflected course, arises in front of the arch of the aorta on the left side, and of the sub-clavian artery on the right side: it is sometimes so large that it may be regarded as resulting from the bifurcation of the pneumogastric: it is reflected below and then behind the arch of the aorta on the left side, and the sub-clavian artery on the right, so as to form a loop or arch, which has its concavity turned upward, and which embraces the corresponding vessel. Having thus changed its course from a descending to an ascending one, the recurrent nerve enters the groove (*q*, *fig.* 301) between the trachea and the œsophagus, and continues to ascend as high as the lower border of the inferior constrictor muscle of the pharynx; it then passes beneath that muscle, gives some filaments to it, runs behind the lesser cornu of the thyroid cartilage and the crico-thyroid articulation, along the outer border of the posterior crico-arytenoid muscle, and terminates by ramifying in the muscles of the larynx.

During its course, the recurrent nerve gives off the following *collateral branches:* at the point of its reflection, it gives *several cardiac filaments*, which unite with the cardiac branches of the pneumogastric and great sympathetic. It is important to remark the intimate connexion which exists between the recurrent and the cardiac nerves: some very considerable anastomoses are almost always found between the superior and infe-

* See note, p. 848.

† The relation of the pneumogastric with the arch of the aorta explains the stretching and atrophy of this nerve in aneurisms of that portion of the vessel.

‡ Those anatomists who regard the superior laryngeal nerve as a dependance of the spinal accessory believe that the inferior or recurrent laryngeal has a similar origin. I may repeat, and with still more reason, in reference to this nerve, what I have already stated in regard to the superior laryngeal, that it is impossible to demonstrate this continuity by dissection.

rior cardiac nerves and the recurrent nerve: sometimes, indeed, the recurrent nerve forms the point at which the superior and middle cardiac nerves meet, and from which the inferior cardiac nerve is given off; the anastomoses between the recurrent and cardiac nerves sometimes form a true plexus.

The recurrent also gives *œsophageal branches*, which are much more numerous on the left than on the right side, so that the left recurrent nerve is much smaller in the larynx than the right nerve.

It also gives *tracheal branches*, which chiefly supply the posterior or membranous portion of that canal.

And, lastly, some *pharyngeal filaments*, all of which are destined for the inferior constrictor.

Excepting an anastomotic branch* for the superior laryngeal nerve, all of the *terminal branches* of the recurrent nerve are intended for the muscles of the larynx, and are thus distributed:

The *branch for the posterior crico-arytenoid* simply enters that muscle.

The *branch for the arytenoid* runs between the cricoid cartilage and the posterior crico-arytenoid muscle, and then ramifies in the arytenoid. It has already been stated that the last-named muscle is also supplied by the superior laryngeal nerve.

The *branch for the lateral crico-arytenoid* and *thyro-arytenoid* muscles is the true termination of the nerve; it passes on the outer side of these two muscular bundles, which, as formerly stated, constitute a single muscle in the human subject, and then enters them by very delicate filaments. I have distinctly seen a very delicate filament entering the crico-thyroid articulation.

After the pneumogastric has given off the recurrent nerve, and often before doing so, it furnishes certain cardiac branches (*thoracic cardial*); these are subdivided into the *pericardial*, which run upon the outer surface of the pericardium, and are lost in it and in the cellular tissue which replaces the thymus; and into the *cardiac* branches, properly so called, which assist in the formation of the cardiac plexus.

The pneumogastric also gives off certain *anterior pulmonary branches*, which run in front of the bronchus and of the pulmonary arteries and veins, cross obliquely over them, and then enter the substance of the lung, following the ramifications of the air-tubes and bloodvessels; these pulmonary branches form what is called the *anterior pulmonary plexus*. I have seen several of them extend some considerable distance beneath the serous membrane, covering the inner surface of the lungs, before they entered the substance of those organs.

Behind the bronchus, and along the œsophagus, the pneumogastric nerve gives off posterior branches, consisting of a great number of *œsophageal branches*; of some *tracheal branches*, which principally supply the back or membranous portion of the trachea; and, lastly, of *posterior pulmonary* or *bronchial branches*, which form the posterior *pulmonary plexus*.

The *posterior pulmonary plexus* is one of the most remarkable in the body; in it the pneumogastric nerve appears to be decomposed and expanded; there is a *right* and a *left pulmonary plexus*. The left is much larger than the right. The two plexuses are not independent of each other, but are connected by free anastomoses: this remarkable disposition establishes a community of function between the two nerves, and explains how one of them may supply the place of the other.

The pulmonary plexuses, which are completed by filaments from the great sympathetic, are situated behind the root of each lung, or, to speak more exactly, behind the bronchi (whence the name of *bronchial plexuses*). A few of the twigs emerging from them follow the pulmonary arteries, and appear to be lost in their coats; the others accompany the bronchi, some of them passing behind these canals, and others, being reflected forward in the angles formed by their bifurcation, run along their anterior aspect, and terminate in their parietes. They may be traced as far as the ultimate ramifications of the air-tubes. In large animals they can be easily seen entering the circular muscular fibres which surround the bronchial tubes.†

Below the pulmonary plexus, the pneumogastric merely gives off certain *œsophageal branches*, which surround the œsophagus in very great numbers. The right and left pneumogastric nerves anastomose with each other; but the communicating arches do not constitute those circular anastomoses, which have been so decidedly said to explain the pain caused by swallowing too large a morsel of food.

The Pneumogastric Nerve in the Abdomen.

The two pneumogastrics enter the abdomen with the œsophagus, the left nerve being in front and the right nerve behind that canal, and are distributed in the following manner:

* [This anastomotic branch is superficial, and joins the descending filament from the superior laryngeal nerve, beneath the mucous membrane on the back of the larynx, and sometimes sends filaments into the arytenoid muscle; there is, generally, a second anastomosis between the superior and inferior laryngeal nerves on the side of the larynx, between the thyroid cartilage and the thyro-arytenoid muscle.]

† I have seen a nerve from the pulmonary plexus pass through some of the fibres of the œsophagus and ramify in the aorta.

The left nerve (*q*, *fig.* 302), which is situated in front of the cardia, expands into a very great number of diverging filaments, some of which extend over the great cul-de-sac, and others over the anterior surface of the stomach; but the greater number gain the lesser curvature, and divide into two sets or groups; one of these leaves the lesser curvature, enters the gastro-hepatic omentum, is conducted by it to the transverse fissure of the liver, and enters that gland. The other group continues in the lesser curvature, and may be traced as far as the duodenum.

The *right pneumogastric* (*p'*), situated behind the cardia, gives a much smaller number of branches to the stomach than the left, and joins the solar plexus (*x*), of which it may be regarded as one of the principal origins.

Summary of the Distribution of the Pneumogastric Nerve.—This nerve, it will be seen, has an extremely complicated distribution.

Within the *foramen lacerum posterius*, it anastomoses with the spinal accessory; with the facial nerve by means of the auricular branch of Arnold, or the branch of the jugular fossa; and with the nerve of Jacobson, and, therefore, with the glosso-pharyngeal nerve, by a twig from the same auricular branch.

At its exit from the foramen lacerum posterius, it anastomoses with a large branch of the spinal accessory; with the hypo-glossal; with the glosso-phyrangeal; and with the superior cervical ganglion.

In the neck, it gives off the pharyngeal branch or small pharyngeal nerve, the superior laryngeal nerve, and the superior cardiac branches of the pneumogastric.

In the thorax, it gives off the recurrent or inferior laryngeal nerve, which supplies some cardiac, œsophageal, pharyngeal, tracheal, and laryngeal branches; the inferior cardiac branches; and the pulmonary or bronchial branches.

In regard to its *structure*, the pneumogastric differs essentially from the other cerebro-spinal nerves, by the tenuity of its filaments and by their plexiform arrangement; and in both of these particulars, as well as in its distribution, it rather resembles the nerves of organic than those of animal life. In the description of the sympathetic it will be seen how intimate are its relations with the pneumogastric nerve.

Functions of the Pneumogastric.—From the manner in which the pneumogastric is distributed, it follows that it is a nerve both of sensation and of motion; for it supplies both the lining membrane of the respiratory and digestive passages, and the muscles and muscular coats of the same canals. Anatomy does not confirm the ingenious idea of Bischoff, that the pneumogastric is essentially a nerve of sensation, and that the portion which appears to be motor really belongs to the spinal accessory. Physiologists have studied the influence of the pneumogastric upon the larynx, the lungs, the heart, and the stomach in an infinite variety of ways; it appears, from some experiments which I made upon this subject, that animals in which both pneumogastrics are simultaneously cut die almost immediately, when they are permitted to eat as much as they please; for, the contractility of the stomach and œsophagus being destroyed, the food, after having filled the stomach, distends the œsophagus, and passes from it into the larynx.

The Third Portion of the Eighth Nerve, or the Spinal Accessory Nerve of Willis.

We have already described the very remarkable origin of the spinal accessory nerve at the side of the cervical portion of the spinal cord, between the anterior and posterior roots of the spinal nerves, or, rather, immediately in front of the posterior roots, of which it appears to be a dependance: we particularly alluded to the arrangement of its highest filaments of origin, which come from the restiform bodies, and are continuous above with the roots of the pneumogastric, so that they sometimes even join that nerve, and below with the posterior roots of the spinal nerves.

Lastly, we have pointed out the varieties of its origin, its connexions with the first pair of cervical nerves, of which it almost always forms the posterior roots, its ascending course to the foramen magnum, through which it enters the cranium, and its exit from the scull by the foramen lacerum posterius.

It emerges from the foramen lacerum posterius by an opening quite distinct from that for the glosso-pharyngeal, but common to itself and the pneumogastric nerve, behind which it is situated (8, *fig.* 301). While passing through the foramen lacerum posterius, it lies in contact with the ganglionic enlargement of the pneumogastric, and is connected with the ganglion by very delicate filaments, but it neither assists in the formation of that enlargement, nor is blended with it: at its exit from the foramen it divides into two branches of equal size; an *internal* or *anastomotic*, which remains in contact with the pneumogastric, and is distributed with it, and a *muscular* branch* (cut off in *fig.* 301).

The Anastomotic Branch.—So intimately are the spinal accessory and pneumogastric nerves connected, or, as it were, fused together, that, up to the time of Willis, they were

* It is well to observe, that as they are passing through the foramen lacerum posterius, the pneumogastric and spinal accessory nerves adhere to the dura mater, in the same manner as the Gasserian ganglion.

regarded as a single nerve. Willis first described the former, perhaps erroneously, as a separate nerve, under the name of *nervus accessorius ad par vagum, sive nervus spinalis.* In an excellent thesis, published in 1822,* M. Bischoff endeavoured to prove that the pneumogastric or par vagum and spinal accessory form but a single nerve, analogous to the spinal nerves in every respect; the spinal accessory being the nerve of motion, and the par vagum the nerve of sensation: "Nervus accessorius Willisii est nervus motorius, atque eandem habet rationem ad nervum vagum quam antica radix nervi spinalis ad posticam. Omnis motio cui vagus præesse videtur, ab illâ portione accessorii quæ ad vagum accidit, efficitur. Itaque vox quoque, sive musculorum laryngis et glottidis motus, ab accessorio pendet, et eo nomine accessorius nervus vocalis vocari potest."

To this view there are serious objections: in the first place, it is opposed to the law that the anterior roots preside over motion and the posterior over sensation; for the filaments of origin of the spinal accessory evidently form part of the posterior roots. Again, how can it be supposed that two nerves, which, like the spinal accessory and pneumogastric, arise so distinctly from the same line, that it is often difficult to separate them, can have such opposite functions!

Must we suppose that the law which regulates the anterior and posterior roots of the spinal nerves ceases to operate at the medulla oblongata! or must we admit, with Arnold, that there is not only a decussation of fibres from side to side in the medulla oblongata, but also from before backward, so that the posterior columns of the medulla oblongata become the motor and the anterior the sensory! Still, even with this hypothesis, it must be remembered that the spinal accessory arises in part below the point where this antero-posterior decussation is supposed to exist. There evidently is an antero-posterior decussation opposite to the two anterior pyramids, as I have elsewhere stated (see MEDULLA OBLONGATA), but the other columns of the spinal cord are not concerned in it.

However this may be, the anastomotic branch of the spinal accessory may be traced, after maceration in dilute nitric acid, along the outer side of the pneumogastric. In a great number of cases, it evidently gives off the *small pharyngeal nerve*, which sometimes arises exclusively from the pneumogastric, and sometimes from both the pneumogastric and the spinal accessory. Scarpa declares the last arrangement to be constant and normal, and has represented it in several figures. In some subjects, the spinal accessory appears to have no share in the pharyngeal nerve, but then its anastomotic branch becomes applied to the pneumogastric below the origin of the pharyngeal nerve.

The anastomotic branch appears to me to have no share in the formation of the superior laryngeal nerve; and the same is the case with regard to the recurrent nerve. It appears to me anatomically impossible to prove the continuity of the spinal accessory and the superior and recurrent laryngeal nerves; I cannot, therefore, admit that the spinal accessory supplies the intrinsic muscles of the larynx.

The spinal accessory generally gives off a number of twigs, which unite in front of the reddish, and, as it were, ganglionic trunk of the pneumogastric nerve, to form a small plexus, which adheres to that nerve, and ends in the hypo-glossal nerve.

Lastly, there are so many varieties in the mode of communication between the pneumogastric and spinal accessory nerves, that it is extremely difficult to refer them to any general law.

The Muscular Branch.—This nerve descends vertically between the internal jugular vein and the occipital artery, beneath the digastric and stylo-hyoid muscles; it runs backward and outward (*t, figs.* 285, 298), beneath the sterno-mastoid, generally perforating that muscle, but sometimes merely running along its deep surface, passes obliquely across the supra-clavicular triangle, and terminates in the deep surface of the trapezius.

While perforating the sterno-mastoid, the spinal accessory nerve gives several branches to that muscle, which anastomose with others from the third cervical nerve, and form a sort of plexus within the muscle.

On emerging, somewhat reduced in size, from the sterno-mastoid, it receives a branch (*v, fig.* 298) from the anastomosis, between the second and third cervical nerves, by which its size is greatly increased: it assists in the formation of the cervical plexus, and sometimes of the posterior auricular nerve.

Having reached the anterior surface of the trapezius, it receives two considerable branches, derived from the third, fourth, and fifth cervical nerves, which appear to me to re-enforce it. It gives off ascending filaments to the occipital portion of the muscle; and descending filaments, which continue in the original course of the nerve in front of the muscle, approach its scapular attachments, and may be traced down to its inferior angle. The muscular branch of the spinal accessory belongs exclusively to the sterno-mastoid and trapezius muscles. It has been incorrectly stated that it supplies other muscles, such as the rhomboidei, the levator anguli scapulæ, the complexus, the splenius, and the sub-scapularis, and that it is also distributed to the skin.

In front of, or, rather, in the substance of the trapezius, the spinal accessory anastomoses with the posterior branches of the spinal nerves.

* Nervi Accessorii Willisii Anatomia et Physiologia. Bischoff. Darmstadii.

Summary.—The spinal accessory gives branches to the sterno-mastoid, the trapezius, and the pharynx; it is believed also to send some to the larynx by means of its anastomotic branch with the pneumogastric. It communicates with the second, third, fourth, and fifth cervical nerves.

Function.—In reference to its muscular branch, Sir C. Bell has classed the spinal accessory among the respiratory nerves, under the name of the *superior respiratory nerve of the trunk*; for, according to that anatomist, it arises from the lateral column of the cord, between the anterior and posterior columns.

With regard to the anastomotic branch of this nerve, which becomes blended with the par vagum, M. Bischoff lays down the following proposition (page 95): "Nervum accessorium nimirum nervum motorium esse, ideoque in partes vagi adscisci, ut motus, quibus hic qui sensificus tantummodo nervus est, præesse videatur, ipse perficiat: eundem ergo præesse motibus quoque musculorum laryngis, indeque nervum esse vocalem." This idea, which was suggested to him by theory, he endeavoured to confirm by experiment. The section of all the roots of the spinal accessory proved to be very difficult; but, after many fruitless attempts, he at length succeeded in dividing them on both sides. The hoarseness produced by section of all the roots of the right side gradually increased as he divided those of the left side, and when all had been cut, the natural voice of the animal was changed to a very hoarse sound, which could not be called the voice.

I have already said that anatomy affords no proof that the laryngeal nerves are derived from the spinal accessory; nor does it show that the muscular fibres of the bronchi, œsophagus, and stomach, receive their filaments from it.

The Ninth Pair, or Hypo-glossal Nerves.

The *hypo-glossal*, or great hypo-glossal nerve, the ninth cranial, or the twelfth nerve of some modern authors, arises on each side from the furrow between the olivary and pyramidal bodies, by a row of filaments collected into two very distinct fasciculi, which proceed to the anterior condyloid foramen (*q*, *fig.* 296), perforate the dura mater separately, and join together so as to emerge from the canal in the form of a rounded cord.*

After leaving the anterior condyloid canal, the hypo-glossal nerve (*d*, *fig.* 301) descends vertically between the internal carotid, which is on its inner side, and the internal jugular on its outer side. At first it lies behind the pneumogastric (8 to *p*); it then crosses very obliquely over the outer side, and lower down it gets in front of that nerve, around which, therefore, it describes a semi-spiral.

Having arrived below the posterior belly of the digastric muscle, the hypo-glossal changes its direction and runs forward and downward (*d*, *fig.* 300), crossing in front of the internal and external carotids [and hooking beneath the occipital artery]; it is then reflected upward to reach the under surface of the tongue (*d*, near *x*), and thus describes a loop having the concavity turned upward, parallel to and below the digastricus, and almost ten lines above the os hyoides.

Relations.—It is situated deeply in its vertical portion, where it runs along the vertebral column, becomes superficial in its middle portion (*d*, *fig.* 298), where it is merely separated from the skin by the platysma and the prominence of the sterno-mastoid, and again becomes deep-seated anteriorly, where it rests on the hyo-glossus muscle, and is covered by the anterior belly of the digastricus and by the stylo-hyoideus, and then by the sub-maxillary gland and the mylo-hyoideus, after which it enters the genio-glossus, and is lost in the substance of the tongue.

The relations of the hypo-glossal nerve and the lingual artery are worthy of remark. The nerve is at first parallel to and above the artery, is soon separated from it by the hyo-glossus, and then rejoins it in front of that muscle. In the substance of the tongue, the artery lies to the outer side of the genio-glossus, while the nerve runs forward through the fibres of the muscle.

The Collateral Branches of the Hypo-glossal Nerve.

Some of these are *anastomotic*. Thus, as it crosses the three divisions of the eighth nerve, the hypo-glossal lies in contact with the pneumogastric nerve, with which it sometimes communicates by very delicate filaments. Most commonly the anastomosis between these two nerves forms a true plexus.† This communication is sometimes effected with the anastomotic branch of the spinal accessory, sometimes with the pneumogastric itself.

The hypo-glossal is also connected by a very small anastomotic twig to the superior cervical ganglion.

It also receives three filaments from the nervous loop formed by the union of the first and second cervical nerves, namely, two from the first nerve and one from the second. The superior filament from the first nerve ascends, an arrangement which it is difficult to understand, for it passes in a direction towards the roots of the hypo-glossal; if it be

* The vertebral artery is situated in front of the filaments of the hypo-glossal.

† [In connexion with this fact, it may be observed that the descendens noni (a branch of the hypo-glossal nerve) sometimes arises in part or entirely from the pneumogastric, lower down in the neck.]

supposed that this filament is derived from the hypo-glossal, then it is directed towards the roots of the first cervical nerve.

Opposite to the anterior border of the hyo-glossus it gives off a very remarkable anastomotic branch, which forms an arch with the lingual nerve.

The other collateral branches which it gives off are the *descending branch*; a *small muscular infra-hyoid branch*; and the *branches for the hyo-glossus* and *stylo-glossus*.

The *descending branch* (*ramus descendens noni*, *h*, *figs.* 298, 300, 301). This is the most remarkable branch of the hypo-glossal nerve.* It comes off at the point where the nerve changes its direction, descends vertically in front of the internal carotid and then of the common carotid, curves outward, and anastomoses upon the internal jugular vein with the descending branch of the cervical plexus (*z*, *fig.* 298), so as to form a loop, having its concavity turned upward. From the convexity of this loop two branches proceed, of which one is distributed to the omo-hyoid, while the other (*g*) divides into two twigs, one of which enters the outer border of the sterno-hyoid, while the other penetrates the deep surface of the sterno-thyroid muscle. I have seen one of these branches come directly from the hypo-glossal.†

It is equally important to study both the mode of origin and anastomosis of the descending branch of the ninth nerve.‡ The *origin* of this branch is, in fact, almost entirely from the anastomotic branches of the first and second cervical nerves, which, after having been in contact with the hypo-glossal, are given off from it to constitute the descending branch. This arrangement is especially evident in preparations that have been macerated in diluted nitric acid. I should state, however, that it is not equally evident in all subjects; and that some filaments, derived from the hypo-glossal itself, always join those from the cervical nerves. It has appeared to me that the most internal of the filaments derived from the hypo-glossal nerve itself followed a retrograde course; that is to say, that it ran from below upward, as if it arose at the terminal extremity of the hypo-glossal, and then left that nerve to join the descendens noni at the point where that branch is given off.

The branches from the first and second cervical nerves to the hypo-glossal should be regarded as late origins of that nerve, which is sensibly increased in size after being joined by them. I have seen the third and even the fourth cervical nerve assist in the formation of the descendens noni; the branch from the fourth nerve arose partly from the phrenic.

The *mode of anastomosis* of the descendens noni with the descending branch of the cervical plexus, or, rather, of the third cranial nerve, is subject to much variety.

The following is the most frequent arrangement:

All the filaments composing these two descending branches unite together, with the exception of the uppermost filament, which describes a loop having its concavity turned upward, and resembling a vascular anastomosis: so that, if we suppose it to be derived from the loop of the hypo-glossal, it would be directed towards the origin of the cervical nerves; and if, on the contrary, we suppose it to arise from the cervical nerves, it would be directed towards the origin of the hypo-glossal. This arrangement, which I have had the opportunity of observing in many parts of the nervous system, appears to me to constitute a mode of anastomosis well worthy the attention of physiologists. I am induced to regard it as intended to establish connexions between the different points of the spinal cord.◊

* See note, last page.

† [Another branch is described and figured by Arnold as descending in front of the vessels, and joining the *cardiac* nerves in the thorax.]

‡ There are certain cases in which the descendens noni is analyzed by nature; namely, when the branch from the second cervical nerve is not applied to the hypo-glossal, but remains at a distance from it. In this case, the filaments derived from the hypo-glossal join themselves to this branch; one of them ascends towards the origin of the second cervical nerve, and the others proceed towards its termination. In one case, the hypo-glossal gave a very small twig to the first cervical nerve, before receiving its accustomed branch from that nerve; the descending branch from the cervical plexus was replaced by three branches derived from the first, second, third, and fourth cervical nerves, which formed, together with the descendens noni and its branches, a succession of loops, in front of the external and common carotids. In another case, the three superior cervical nerves assisted in forming the descendens noni. The following is a detailed description of that case, which throws considerable light upon the connexions between the hypo-glossal and cervical nerves. One large branch proceeded from the anastomotic arch of the first and second cervical nerves; this large branch, as soon as it reached the hypo-glossal nerve, divided into three filaments of unequal size: an ascending, which was directed towards the origin of the hypo-glossal nerve; a middle, which became blended with that nerve; and a descending, which was the largest, and which merely ran along in contact with the same nerve. At the point where this last-named filament left the hypo-glossal to form the descendens noni, it evidently received a twig from the hypo-glossal itself, which came from the lower part of that nerve, and was reflected upon the descendens noni in a retrograde manner, so that this twig, derived from the hypo-glossal, had one end at the terminal extremity of that nerve, *i. e.*, in the muscles of the tongue, and the other end in the muscles of the infra-hyoid region. In this same case, the descending branch of the second cervical nerve divided into three filaments, one of which joined the hypo-glossal nerve, another formed an anastomotic arch with the third cervical nerve, while the third filament passed downward to assist in forming the descending branch of the cervical plexus. Lastly, the third cervical nerve in this case gave off an ascending branch, which anastomosed with the second, and a descending branch, which assisted in forming the descending branch of the cervical plexus; there were therefore two loops or arches, one internal and the other external; they were situated opposite to the bifurcation of the common carotid artery.

◊ This mode of anastomosis may, perhaps, have some relation to that *reflex action of the spinal cord*, which

The Small Muscular Branch of the Infra-hyoid Region.—This nerve comes off at the posterior border of the hyo-glossus, and ramifies in the upper part of the muscles of the infra-hyoid region; a small transverse filament runs along the hyoid attachments of these muscles. This small nerve may be regarded as an accessory to the descendens noni.

The Branches for the Hyo-glossus and Stylo-glossus.—As the hypo-glossal nerve comes into contact with the hyo-glossus, it becomes flattened and widened, and gives off several ascending branches, most of which ramify in the hyo-glossus, though several end in the stylo-glossus.

The Terminal Branches of the Hypo-glossal Nerve.

Opposite to the anterior border of the hyo-glossus the hypo-glossal nerve gives off some twigs to the under surface of the genio-hyoideus; it then enters the genio-hyo-glossus, and expands (*d*, near *x*, *fig.* 300) into a great number of filaments, which run forward, perforate that muscle at successive points, and are lost in the substance of the tongue. It is impossible to follow these filaments to the papillary membrane of the tongue. Some of them anastomose with the lingual (*n*) nerve, a branch of the inferior maxillary division of the fifth; several accompany the lingual artery.

The relations of the lingual portions of the hypo-glossal nerve with the lingual of the fifth are worthy of attention. The lingual nerve occupies the under part of the border of the tongue, runs along the stylo-glossus, and may be traced as far as the apex of the organ: it is sub-mucous in the whole of its extent. The hypo-glossal nerve is situated on a much lower plane, and occupies the under surface of the tongue, on each side of the median line.

Function.—The hypo-glossal is a muscular nerve: it regulates the movements of the tongue, while the lingual of the fifth and the glosso-pharyngeal confer sensibility upon it. This fact is most clearly established by anatomical, physiological, and pathological observations. Like all nerves having a simple distribution, the hypo-glossal has not a plexiform structure.

General View of the Cranial Nerves.

All the spinal nerves present the greatest regularity in arising from two series of roots, in having a ganglionic enlargement on their posterior roots, and even in their course and termination, the differences or modifications of which depend on the different structure of the parts to which they are distributed; but the greatest irregularity appears to prevail in reference to the origin, the course, and the termination of the cranial nerves. From the comparison which has been made between the scull and the vertebræ, and from the possibility of resolving the bones of the cranium into a certain number of cranial vertebræ, anatomists have entertained the idea of drawing a parallel between the cranial and the spinal nerves. It has been conceived that the number of cranial nerves ought to be regulated by the number of cranial vertebræ admitted by different anatomists; and, moreover, that in order to draw a fair comparison between these two sets of nerves, the special nerves of the face, namely, the olfactory, the optic, and the auditory nerves, should be entirely disregarded.

Now we have already shown (see Osteology) that there are three cranial vertebræ, between which there are two inter-vertebral foramina; that the anterior inter-vertebral foramen is represented by the sphenoidal fissure, to which we must annex the foramen rotundum and the foramen ovale; and that the posterior inter-vertebral foramen is represented by the foramen lacerum posterius, together with the anterior condyloid foramen.

This being premised, we shall admit two pairs of cranial nerves, an anterior and a posterior.

The *posterior cranial pair* consists on each side of the eighth and ninth nerves, namely, of the pneumogastric, glosso-pharyngeal, spinal accessory, and hypo-glossal nerves. The pneumogastric and the glosso-pharyngeal, each of which has a ganglion analogous to the inter-vertebral ganglia, represent the posterior roots of a spinal nerve, while the spinal accessory and the hypo-glossal, which have no ganglion, represent the anterior root. The two last-named nerves are exclusively motor, while the pneumogastric and the glosso-pharyngeal appear to me to be mixed nerves, that is, both sensory and motor.

The *anterior cranial pair* is composed on each side of the fifth nerve, the ganglion of which is quite analogous to the inter-vertebral ganglia, and the large portion of the root of which accurately represents the posterior root of a spinal nerve; and of the third or common motor nerve of the eye, of the fourth or pathetic nerve, of the sixth or external motor nerve of the eye, of the portio dura of the seventh, and, lastly, of the non-ganglionic portion of the fifth. All these last-named nerves are the nerves of motion; while the ganglionic portion of the fifth is the nerve of sensation.

Moreover, as the spinal nerves communicate with the ganglia of the great sympathetic, it is of importance, for the completion of our comparison, to determine the communications of the two cranial pairs of nerves with the same system of ganglia. Now

Dr. Marshall Hall believes to be the cause of certain instinctive motions. ("On the Reflex Functions of the Medulla Oblongata and Medulla Spinalis."—*Phil. Trans.*, 1833.)

I regard the *superior cervical ganglion* of the great sympathetic as common to the two supposed cranial pairs and to the three superior cervical pairs; in fact, the superior cervical ganglion communicates with all the branches of the posterior cranial pair, excepting the spinal accessory, viz., with the pneumogastric, the glosso-pharyngeal, and the hypo-glossal; and it also communicates with the anterior cranial pair, and more particularly with the fifth and sixth nerves.

As to the ophthalmic, spheno-palatine, otic, and sub-maxillary ganglia, which Arnold regards as annexed to the organs of the senses, viz., the ophthalmic to the eye, the spheno-palatine to the nose, the otic to the ear, and the sub-maxillary to the organ of taste, and which Bichat described as the cephalic portion of the great sympathetic, I am of opinion that they are mere local ganglia, which do not form part of the general sympathetic system: besides, the ophthalmic and the otic ganglion only can be shown to be connected with the organs of any sense: it is impossible to show that the spheno-palatine ganglion, the very existence of which as a ganglion is often doubtful, has any connexions with the organ of smell, or that the sub-maxillary ganglion, which is much more closely connected with the sub-lingual gland, has any relations with the organ of taste.

THE SYMPATHETIC SYSTEM OF NERVES.

General Remarks.—The Cervical Portion of the Sympathetic.—The Superior Cervical Ganglion—its Superior Branch, Carotid Plexus, and Cavernous Plexus—its Anterior, External, Inferior, and Internal Branches.—The Middle Cervical Ganglion.—The Inferior Cervical Ganglion.—The Vertebral Plexus.—The Cardiac Nerves: Right, Superior, Middle, and Inferior, Left.—The Cardiac Ganglion and Plexuses.—The Thoracic Portion of the Sympathetic.—The External and Internal Branches.—The Splanchnic Nerves, Great and Small.—The Visceral Ganglia and Plexuses in the Abdomen, viz., the Solar Plexus and Semilunar Ganglia.—The Diaphragmatic and Supra-renal; the Cœliac, the Superior Mesenteric, the Inferior Mesenteric, and the Renal, Spermatic, and Ovarian Plexuses.—The Lumbar Portion of the Sympathetic.—The Communicating, External, and Internal Branches.—The Lumbar Splanchnic Nerves and Visceral Plexuses in the Pelvis.—The Sacral Portion of the Sympathetic.—General View of the Sympathetic System.

We have seen that the nerves arising from the cerebro-spinal axis are distributed to the organs of the senses, to the skin, to the muscles, in short, to all the organs of animal life. The pneumogastric nerve alone is distributed to the organs of respiration, and the upper part of the alimentary canal, viz., the pharynx, the œsophagus, and the stomach. We shall now see that all the internal organs, which are beyond the influence of volition and consciousness, are provided with a special nervous apparatus, which is called the *great sympathetic*, the *sympathetic system*, the *ganglionic system*, or the *nervous system of organic or nutritive life*.

The *sympathetic system* consists of two long, knotted cords (*f* to *v*, *fig.* 268, in which figure these cords are represented as if drawn outward away from their natural position) extended one on each side of the vertebral column, from the first cervical to the last sacral vertebra; these cords are enlarged opposite each vertebra, to form a series of ganglia, which communicate with all the spinal and cranial nerves on the one hand, and give off all the visceral branches on the other. The sympathetic system consists essentially of two distinct parts: of a *central portion*, formed by the two cords; and of a *visceral*, *median*, or *prævertebral portion*, consisting of certain plexuses and ganglia, which communicate with the central cords, surround the arteries as if in sheaths, penetrate the viscera with them, and establish a communication between the sympathetic cords of the right and left sides. We cannot pay too much attention to the connexion between the ganglionic nerves and the arteries, which always serve as a support for these nerves, and for which, according to some anatomists, the nerves are exclusively destined.

Each half of the sympathetic system may be described in two ways: either as a continuous cord, having ganglia at intervals upon it, or as a series of ganglia or centres, which may first be examined independently of each other, and around which all the filaments that enter or emerge from them may then be arranged.

The first method, which is the more natural one, was adopted by the older anatomists, who described the sympathetic in the same way as other nerves; according to the second method, which is the one adopted by Bichat, all the ganglia, whatever situation they may occupy, are included in the sympathetic system; the ophthalmic, the spheno-palatine, and other cranial ganglia would, according to this view, be comprised in the sympathetic system.

I believe that the better mode of description is one which associates the idea of a centre with that of a cord. In fact, as the sympathetic system consists of a double line, it is natural to describe it as a nervous cord, having two extremities, one cephalic, the other pelvic; and as each ganglion forms the point of termination or of origin to a great

number of nervous filaments, these bodies may very properly be regarded as central points. The visceral portion of the sympathetic nerves will be described with the ganglia to which they are connected.

I shall describe in succession the cervical, the thoracic, the abdominal, and the pelvic portion of the sympathetic. I have already said that I do not recognise any proper cephalic portion of this system of nerves, for the ophthalmic and the other cranial ganglia seem to me to belong to a totally different class.

The Cervical Portion of the Sympathetic System.

The *cervical portion of the sympathetic* (*f i, fig.* 302) has this peculiarity, that, instead of being composed of as many ganglia as there are vertebræ, it has only two or three. This may be explained by supposing that the superior cervical ganglion represents by itself the ganglia which are wanting. It will hereafter be seen that the lumbar ganglia are rather frequently fused in a similar manner. The cervical portion of the sympathetic is situated on the anterior region of the vertebral column, behind the internal and common carotid arteries, the internal jugular vein, and the pneumogastric nerve (*p*). It is connected to all these parts, and to the prævertebral muscles, by some very loose cellular tissue, a layer of fascia intervening between them; it commences by a large fusiform ganglion, the *superior cervical ganglion* (*f*); this is succeeded by a nervous cord of variable size, which terminates in the *middle cervical ganglion* (*a*) when that exists, but when it is absent in the *inferior cervical ganglion* (*i*), which is continuous with the first thoracic ganglion, either directly or through the medium of two or three very remarkable nervous loops, or frequently by both methods of connexion. We shall proceed to examine the three cervical ganglia.

Fig. 302.

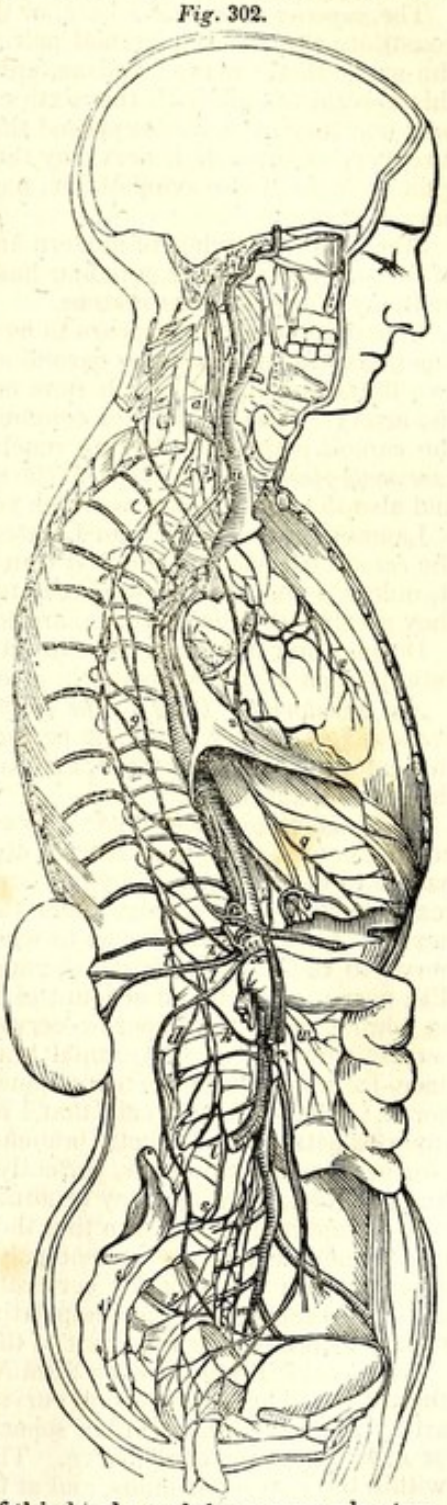

The Superior Cervical Ganglion.

Dissection.—Remove the corresponding ramus of the lower jaw; separate the ganglion very carefully from the pneumogastric, glosso-pharyngeal, and hypo-glossal nerves, behind which it is placed. In order to trace the superior or carotid branch, make an antero-posterior median section of the head; open the foramen lacerum posterius from behind, in the manner indicated for exposing the pneumogastric, and then examine the ganglion and its superior branch from the inner side.

The *superior cervical ganglion* (*f*) is olive-shaped or fusiform: it is situated in front of the second and third cervical vertebræ, from which it is separated by the rectus capitis anticus; it is behind the internal carotid artery, and the glosso-pharyngeal, pneumogastric, and hypo-glossal nerves; its upper extremity is about ten or twelve lines distant from the lower orifice of the carotid canal; it is said to have been found two inches from it.

It is larger than the other cervical ganglia (*ganglion cervicale magnum*), but it varies much both in its length and its other dimensions; thus, its lower extremity has been seen to reach the fourth, fifth, and even the sixth cervical vertebra. Its colour is grayish, and its surface smooth: not unfrequently it is bifurcated at its lower extremity; it is rather often double. Lobstein has figured a case of this kind; and there were also two superior cervical ganglia, one placed above the other, in a case of hypertrophy of these ganglia, examined and represented by myself.—(*Anat. Path.*, liv. i., pl. 3.)

These cases of a double superior cervical ganglion evidently depend on subdivision of the single ganglion usually existing.

The branches which end in or emerge from the superior cervical ganglion may be divided into *superior*, *inferior*, *external*, *internal*, and *anterior*. I shall divide them into those

which communicate with the cranial and cervical nerves, those which communicate with the other cervical ganglia, and into arterial and visceral branches. The superior cervical ganglion also gives off several twigs to the muscles of the prævertebral region.

The superior cervical ganglion communicates with the cranial nerves by means of its superior or carotid branch and its anterior branches. It communicates with the cervical nerves by its external branches. It communicates with the other cervical ganglia by its inferior branch. Its visceral and arterial branches are the pharyngeal, the cardiac, and the branches for the external carotid.

The Superior or Carotid Branch from the Inferior Cervical Ganglion.

The *superior* or *carotid branch*, or the branch of communication with the nerves which constitute the anterior cranial pair, has been for a long time regarded as the origin of the sympathetic nerve; and as, previously to the time of Meckel, the anastomosis of this carotid branch with the sixth cranial nerve, or external motor of the eye, was the only one known, it was supposed that the sympathetic arose from the sixth nerve; the discovery of the vidian nerve by the elder Meckel has led to the admission of two origins or roots of the sympathetic, namely, one from the fifth and another from the sixth cranial nerve.

Since the researches of modern anatomists, the study of the superior or carotid branch of the superior cervical ganglion has become one of the most complicated points in the anatomy of the nervous system.

This carotid branch appears to be a prolongation of the superior cervical ganglion; it tapers as it approaches the carotid canal, into which it enters, after having divided into two branches, one of which runs on the inner side and the other on the outer side of the artery. These branches communicate with each other, subdivide, and unite to form the *carotid plexus*, and having reached the cavernous sinus, form a plexus, named the *cavernous plexus*, which gives off the communicating branches to the sixth and fifth nerves, and also the small plexuses which surround the internal carotid and its branches.*

Laumonier, and after him Lobstein and several others, described a ganglion, named the *carotid ganglion*, in the first turn of the carotid canal; but it is in vain to search for it, unless some slight enlargements on the external and internal branches, wherever they give off or receive twigs, are to be regarded as ganglionic.†

During their course in the carotid canal, the external and internal divisions of the carotid portion of the sympathetic give off the following branches:

An Anastomotic Twig to the Nerve of Jacobson.—This comes off from the external branch, and is very small; it perforates the external wall of the carotid canal, enters the cavity of the tympanum, and anastomoses with the nerve of Jacobson, a branch of the glosso-pharyngeal.

An Anastomotic Twig to the Spheno-palatine, or Meckel's Ganglion.—This, like the preceding, comes from the external division of the carotid branch of the sympathetic, and passes to the vidian or pterygoid branch of the superior maxillary nerve. We have already spoken of this twig, under the name of the carotid or deep branch of the vidian nerve. Anatomists differ as to whether it should be regarded as passing from the fifth nerve to the superior cervical ganglion, or from the superior cervical ganglion to the fifth nerve. Arnold, on account of its grayish colour and slight consistence, regards it as coming from the superior cervical ganglion, while he believes the great superficial petrosal nerve, *i. e.*, the cranial branch of the vidian, also from its colour and consistence, to belong to the cerebro-spinal system of nerves, and to be a branch of the fifth nerve. I have already said that I have never found sufficient difference between the superior petrosal and carotid branches of the vidian to warrant this distinction. These two nerves are, moreover, perfectly distinct from each other as far as the spheno-palatine ganglion, in which they terminate.

It is important to observe that the two branches of the vidian nerve terminate in the enlargement called the spheno-palatine, or Meckel's ganglion: the connexion of this ganglion with the superior cervical ganglion has not been overlooked by those anatomists who regard the spheno-palatine enlargement as a ganglion, and who consider the cranial ganglia as forming part of the sympathetic system.

Anastomotic Branches to the Sixth Nerve.—Several branches, generally three, turn round the convex side of the second curve of the internal carotid, reach the outer side of that artery, and anastomose, either separately, or, after having united together, with the sixth or external motor oculi nerve. The nerves join at an acute angle opening backward, within the cavernous sinus, and at the point where the sixth nerve crosses the carotid: as this nerve becomes flattened and widened opposite to the artery, it has been imagined that it was really enlarged, and that this augmentation was due to the addition of filaments from the sympathetic nerve; but the enlargement is only apparent, and, notwithstanding the difference in colour, I should be inclined to admit that the communicating

* The carotid branch is sometimes single, and turns spirally around the artery, being placed at first behind, then on the outer side, next on the inner, and again on the outer side of the vessel.

† Arnold, whose authority upon such a subject is of great weight, has never seen this ganglion; he very properly remarks, that even those anatomists who admit the existence of it are not agreed as to its situation

filaments between the sixth nerve and the carotid branches of the sympathetic are furnished by the sixth nerve, and have a reflected course. I have seen the three communicating filaments between the upper part of the sympathetic and the sixth nerve form a gangliform enlargement as they were about to join the latter; and it was this gangliform enlargement which gave origin to the plexus surrounding the internal carotid artery and its branches.

The Cavernous Plexus.

The *cavernous plexus*, in which the two divisions of the carotid branch of the superior cervical ganglion at length terminate, is situated on the inner side of the carotid artery, at the point where that vessel enters the cavernous sinus. From this grayish plexus, which is intermixed with small vessels (plexus nervoso-arteriosus, *Walter*), a considerable number of filaments proceed, some of which establish a communication between it and the fifth nerve, while others surround the internal carotid, and accompany all its ramifications. The following very numerous branches emerge from the cavernous plexus:

Some communicating Filaments to the Third Nerve or External Motor Oculi, before the Division of that Nerve.—These filaments pass above the sixth nerve, to which they appear to be applied.*

A Filament of Communication with the Ophthalmic Ganglion.—This arises from the anterior part of the cavernous plexus, enters the orbit between the third nerve and the ophthalmic division of the fifth, and unites sometimes with the long root of the ophthalmic ganglion, which we have stated to be derived from the nasal branch of the ophthalmic, and sometimes with the ophthalmic ganglion itself.

This root had been described and figured by Lecat, before Bock, Ribes, and Arnold recalled the attention of anatomists to it.

It follows, from the arrangement just described, that the ophthalmic ganglion has three roots, two cerebro-spinal and one ganglionic.

Communicating Filaments of the Fifth Nerve.—Some of these pass to the Gasserian ganglion, and others to the ophthalmic division of the fifth.†

The Filaments which accompany the Internal Carotid Artery and its Branches.—These are extremely delicate, but they are beautifully distinct in some subjects. They may be followed even upon the branches of the internal carotid.

Anatomists admit the existence of a plexus for the ophthalmic artery, and for each of its subdivisions. It is even supposed that there is one for the arteria centralis retinæ.‡

Several authors have described a certain number of filaments proceeding from the cavernous plexus to the pituitary body (filets sus-sphénoidaux, *Chaussier*). I have never been fortunate enough to discover them, nor yet the ganglion (the ganglion of Ribes) which is said to exist upon the anterior communicating artery of the brain, and which is found at the point of junction of the right and left trunks of the sympathetic.

It follows, from what has been stated, that the superior cervical ganglion, by means of its upper or carotid branch, communicates with most of the nerves of the anterior cranial pair; namely, with the fifth nerve, by means of the Gasserian ganglion, of the ophthalmic division of the fifth, and of the ophthalmic ganglion, either directly or indirectly; also by means of the superior maxillary division of this nerve, through the intervention of the spheno-palatine ganglion; secondly, with the third nerve; and, lastly, with the sixth.

The Anterior Branches from the Superior Cervical Ganglion.

The *anterior branches* of the superior cervical ganglion establish a *communication* with the different nerves of the *posterior cranial pair*, excepting the spinal accessory nerve, which does not appear to have any direct communication with it.

The glosso-pharyngeal and pneumogastric nerves communicate with the superior cervical ganglion at two different points, viz., at their ganglia, and by their branches.

The communication of the superior cervical ganglion with the *ganglia* of the glosso-pharyngeal and pneumogastric nerves has been pointed out by Arnold; it is difficult to demonstrate it through the dense tissue which surrounds these ganglia.

On the contrary, it is extremely easy to demonstrate the communications of the glosso-pharyngeal nerve and the plexiform cord of the pneumogastric with the superior cervical ganglion. I have already said (see PNEUMOGASTRIC NERVE) that in one case I found the pneumogastric so closely applied to the whole length of the superior cervical ganglion, that it was impossible to separate them. The communication of the superior cervical ganglion with the hypo-glossal is quite as evident as the preceding.

The filaments of communication with the nerves forming the posterior cranial pair do not always proceed from the superior cervical ganglion itself, but sometimes from its carotid branch.

* I have never seen the communication between the superior cervical ganglion and the facial nerve noticed by some anatomists.

† I may here again notice, that in two subjects I have seen a twig from the spheno-palatine ganglion join the communicating branches between the sixth nerve and the sympathetic.

‡ M. Ribes, Mémoires de la Société Médicale d'Emulation, t. vii.

The External Branch from the Superior Cervical Ganglion.

The *external branches* of the superior cervical ganglion establish a *communication* between it and the *first, second, and third cervical nerves;* they are large, have a gray colour, and a ganglionic structure; we may regard them as true prolongations of the superior cervical ganglion; the principal of them enter the angle of bifurcation of the second cervical nerve, into its ascending and descending branches; the others, which are very small, join the first cervical nerve. They constitute a true ganglionic plexus, and often form two distinct groups.

Frequently the superior cervical ganglion communicates only with the first and second cervical nerves. At other times it also communicates with the third and fourth nerves by means of a long and very oblique branch. In one case it communicated directly with the phrenic nerve.

The Inferior Branch from the Superior Cervical Ganglion.

The inferior branch from the superior cervical ganglion, or the branch of communication with the middle cervical ganglion, is a white cord, resembling a spinal nerve, excepting in a few cases, in which it appears to be a prolongation of the tissue of the ganglion itself: when the lower extremity of the superior cervical ganglion is divided into two parts, its inferior branch arises from the external division. It varies much in size in different subjects: it descends vertically in front of the spinal column, behind the common carotid, the internal jugular vein, and the pneumogastric nerve, to which it is united by a very loose cellular tissue.

Having reached the inferior thyroid artery, the cord of the sympathetic passes behind that vessel, and enters the middle cervical ganglion, when that exists; but when it is absent, the cord continues on to join the inferior cervical ganglion. As it descends, it most commonly receives some twigs from the third and fourth cervical nerves, which twigs we have already said occasionally enter the superior cervical ganglion. At its origin, it gives off on the inner side two filaments, which join the superior cardiac nerve, and increase its size; and an anastomotic twig to the external laryngeal nerve, a branch of the superior laryngeal. Not unfrequently the superior cardiac nerve arises entirely from the communicating branch between the superior and middle cervical ganglia, that branch appearing to bifurcate.

The communication between the superior and middle cervical ganglia is subject to much variety. I have seen a small ganglion upon it opposite to the inferior thyroid artery; from this ganglion, which rested upon the artery, and which might be regarded as the vestige of a middle cervical ganglion, two cords proceeded, an anterior, which joined the cardiac nerve, and a posterior, which ended in the inferior cervical ganglion: both of these had a gangliform structure. The cord of the sympathetic is not uncommonly found enlarged at intervals into ganglionic nodules.

The Internal Branches, or Carotid and Visceral Branches.

The *internal branches from the superior cervical ganglion* are divided into those which accompany the external carotid and its ramifications, and those which are distributed to the viscera.

The Carotid Branches.—It has been stated that from the upper extremity of the superior cervical ganglion certain branches are given off, which surround the internal carotid, and are prolonged upon its ramifications.

From the inner border of the same ganglion other branches proceed, which embrace the external carotid and the ramifications of that vessel.

These nerves are of a gray colour (*subrufi*), of a soft texture (nervi molles et pene mucosi, *Scarpa*), and of a knotted and gangliform structure (rami gangliformes, *Neubauer*); they come off from the ganglion opposite to the origin of the facial artery; they pass inward behind the external and internal carotids, and form a sort of gray plexus, which extends as far as the origin of the internal and external carotid;* they turn like a loop around the former of these vessels, and anastomose with the carotid filaments from the glosso-pharyngeal, and from the pharyngeal and superior laryngeal branches of the pneumogastric. None of the branches from this plexus are prolonged upon the common carotid; they all pass upon the external carotid and its different ramifications, forming as many plexuses as there are vessels, and are distributed with those vessels to the neck and the face. Thus, there is a *thyroid plexus*, which surrounds the superior thyroid artery, and may be traced into the thyroid body; a *lingual plexus*, which enters the substance of the tongue, and is supposed to anastomose with the lingual branch of the inferior maxillary division of the fifth, and even with the hypo-glossal nerve; and a *facial plexus*, which is supposed to anastomose with the facial nerve. Anatomists have particularly directed their attention to the branches which enter the sub-maxillary gland; some imagining, and others regarding it as certain, that these branches communicate with the sub-maxillary ganglion. I have never been fortunate enough to discover this communication.

* At this division there is frequently a gangliform enlargement, which Arnold proposes to call the *inter-carotid ganglion.*

There is, moreover, a *pharyngeal plexus*, an *occipital plexus*, and an *auricular plexus:* the elder Meckel* has even described an anastomosis between the facial nerve and the sympathetic filament which accompanies the posterior auricular artery. Lastly, the temporal artery, and the internal maxillary artery and its divisions, are also surrounded (hederæ ad modum, *Scarpa*) by small nervous plexuses; these plexuses are sometimes so well developed, that the elder Meckel states that the arteries of the face have larger nervous plexuses than any others in the body. These plexuses appear to me to be peculiarly remarkable for containing a mixture of white fibres and nervi molles, which proves their double origin.

All these plexuses present gangliform enlargements at various points, as is shown in the splendid plate in Scarpa's work.† This author has figured, after Andersh, a ganglion which he believes to be constant at the division of the external carotid and temporal arteries. A twig from the facial nerve terminates in this ganglion.‡

The Visceral Branches.—All these come off from the inner side of the ganglion, and divide into pharyngeal, laryngeal, and cardiac branches.

The *pharyngeal branches* are certain thick ganglionic cords which arise from the upper and inner part of the superior cervical ganglion, pass transversely inward, and combine with the pharyngeal branches of the glosso-pharyngeal and pneumogastric nerves to form one of the most remarkable plexuses in the body, which is distributed to the pharynx. To this plexus must be referred all those highly important nervous phenomena which are manifested in connexion with the pharynx, more particularly the sensation of thirst.

The *laryngeal branches* unite with the superior laryngeal nerve and its divisions. In a case in which the external laryngeal nerve arose separately from the pneumogastric and not from the superior laryngeal, it had as many filaments of origin from the superior cervical ganglion as from the pneumogastric itself.

The *cardiac branches* form the superior cardiac nerve, to which I shall recur after having described the middle and inferior cervical ganglia.

The Middle Cervical Ganglion.

The *middle cervical ganglion* (*a*, *fig.* 302) is wanting in a great number of subjects, and then the branches usually given off from and received by it are given off and received by the cords which connect the superior and inferior cervical ganglia, or by the inferior cervical ganglion itself. The middle cervical ganglion is sometimes double; at other times it is in quite a rudimentary state.

It is situated on a level with the fifth or sixth cervical vertebra, in front of the inferior thyroid artery, opposite to the first curve of that vessel, and sometimes behind it; its relation to this artery, which is very nearly constant, induced Haller to name it the *thyroid ganglion:* however, I have frequently seen it eight lines above that artery. Its form and size are extremely variable, not only in different subjects, but even upon opposite sides of the same subject. Sometimes it is a simple gangliform enlargement. Scarpa has figured a middle cervical ganglion almost as large as the superior, and, like it, olive-shaped. I have never seen it as large as this.◊

The middle cervical ganglion, when it exists, receives,

Above, the cord which communicates with the superior cervical ganglion; *below*, the cord of communication, often multiple, with the inferior cervical ganglion; *on the outside*, three branches, derived from the third, fourth, and fifth cervical nerves: not unfrequently the communicating branch from the fourth cervical nerve belongs to the phrenic; on the *inside*, the *middle cardiac nerve*, or *great cardiac of Scarpa*, which I shall presently describe.

The size of the middle cervical ganglion has always appeared to me to be proportioned to that of its filaments of communication with the cervical nerves.

The Inferior Cervical Ganglion.

Neubauer has given an excellent description of the inferior cervical ganglion, under the name of the first *thoracic ganglion*, rather an appropriate title for it, because it is frequently continuous with the first thoracic ganglion (as at *i*, *fig.* 302); and, secondly, because it is situated in front of the transverse process of the seventh cervical vertebra and of the head of the first rib. This ganglion is constant; it is deeply seated behind the origin of the vertebral artery, by which it is completely concealed.‖

* Mémoires de l'Acad. de Berlin, 1752. † Tabulæ Neurologicæ, tab. iii., 1794.

‡ Arnold has described and figured a twig from the plexus which surrounds the middle meningeal or sphenospinous artery, and which, according to this laborious inquirer, terminates in the otic ganglion; he also describes some nervous twigs passing from the plexus of the ascending palatine artery to the sub-maxillary ganglion. In this way he establishes a connexion between the sympathetic system and these two cranial ganglia. I have devoted great care to this subject, but have never been able to make out these communicating filaments, even though all the difficult dissections have been made upon specimens previously macerated in diluted nitric acid.

◊ I believe that it is incorrect to regard as a middle cervical ganglion those ganglionic nodules, without either afferent or efferent filaments, which are rather frequently found at various points on the trunk of the sympathetic.

‖ It is not rare to see the inferior cervical ganglion describe around the vertebral artery a half ring, which is completed in front by a gray cord extended from one end of the ganglion to the other.

It is of a semilunar shape, its concave border being turned upward and its convex one downward; at its internal extremity it receives the trunk of the sympathetic; at its external extremity it receives a large nerve which accompanies the vertebral artery, and which may be called the *vertebral nerve;* at the same extremity it also receives some communicating branches from the fifth, sixth, and seventh cervical nerves, and often from the first dorsal. Several branches proceed from its convex border, which is turned downward; some pass in front of and others behind the sub-clavian artery, which they embrace like loops. Most of these inferior branches are the communicating branches between the inferior cervical and the superior thoracic ganglion, and they exist even when the two ganglia are directly continuous with each other. One of the branches sometimes joins the recurrent laryngeal branch of the pneumogastric; the most remarkable of the inferior branches constitutes the *inferior cardiac nerve*, which is rather frequently derived from the superior thoracic ganglion.

To complete the description of the cervical portion of the sympathetic, we have now only to speak of the *vertebral nerve* and of the *cardiac nerves.*

The Vertebral Plexus.

The *vertebral plexus* or *vertebral nerve* occupies the canal which is formed for the vertebral artery in the transverse processes. It is generally said that this nerve arises from the inferior cervical ganglion; that it traverses the entire length of the canal formed for the vertebral artery, enters the cranium with that vessel, and then unites with its fellow of the opposite side to form the basilar plexus, which divides and subdivides around the terminal ramifications of the basilar artery, like the plexuses which are formed around the internal carotid; but such is not a correct description of the nerve. It appears to me to be formed by the junction of filaments derived from the third, fourth, and fifth cervical nerves, gradually to increase in size from above downward as it receives new filaments, then to pass behind the artery, to emerge from the canal also behind the vessel, and, finally, to enter the inferior cervical ganglion. I conceive that this branch is intended to establish a communication between the third, fourth, and fifth cervical nerves and the inferior cervical ganglion. I have never found upon these branches the swellings or gangli which, according to M. Blainville's ingenious idea, might be intended to supply the place of the cervical sympathetic ganglia, and to destroy the appearance of irregularity which exists in the cervical region in this respect.

The Cardiac Nerves.

Dissection.—This comprises the dissection of the cardiac nerves, from their origin to the point where the aorta and pulmonary artery cross each other; and from that point to the extreme divisions of the nerves. For this purpose, after having previously exposed the cervical ganglia and the cardiac nerves, the preparation should be macerated in diluted nitric acid; all the internal nerves which proceed from the ganglion should then be carefully dissected, so as to preserve their relations with the cardiac branches of the pneumogastric and recurrent nerves; we must then examine the nerves which pass in front of the aorta, those which run between that vessel and the pulmonary artery and trachea, and, lastly, those which pass behind the pulmonary artery; we should study, at the same time, their relations with the anterior and posterior cardiac plexuses.

The *cardiac nerves*, or *nerves of the heart*, which are distinguished into the *right* and the *left*,* arise essentially from the cervical ganglia. These ganglionic nerves are then joined by several branches from the pneumogastric; they all converge upon the origin of the aorta and pulmonary artery to form the *cardiac plexuses*, which give off the *right* and *left coronary plexuses;* these latter plexuses surround the coronary arteries, and their branches are scattered over the surface of the heart, but do not enter its substance until they have advanced a considerable distance beneath the serous membrane by which the heart is covered.

Such is the most general idea that can be given of the cardiac nerves and plexuses, which afford one example of the most remarkable of the median anastomoses. Scarpa first described and figured them correctly in his plates, which will always be models for anatomical drawings. No nerves present so many varieties, in number, size, and origin, as the cardiac nerves; and on this subject especially, the want of a work upon anatomical varieties is especially felt. For my part, I declare that I have never found the cardiac nerves in my dissections as they are represented in Scarpa's magnificent plates,

* The history of the nerves of the heart is singular. The ancient philosophers, with Aristotle, influenced by certain preconceived ideas, stated that the heart was the source of all the nerves in the body. Galen refuted this opinion, and admitted that the heart had but one very small nerve, which descended from the brain. Vesalius considered that this slender nerve came from the recurrent, and represented it in a figure. Fallopius first described the nerves of the heart, and says that he showed his audience "*insignem nervorum plexum a quo abundans copia nervosæ materiæ totam cordis basim complexatur, perque ipsam plures propagines parvorum nervorum dispergit.*" Behrends, in 1792, defended a thesis in which he endeavoured to demonstrate that the *heart has no nerves, cor nervis carere.* Such was the amount of knowledge on this subject when, in 1794, Scarpa published his splendid work, and settled the state of science on this point.—(*Tabulæ Neurologicæ ad Illustrandam Anatomiam Cardiacorum Nervorum, Noni Nervorum Cerebri, Glosso-pharyngæi et Pharyngæi ex Octavo Cerebri.*)

which have served as the type for all descriptions. I have minutely described the cardiac nerves in eight different subjects; these eight descriptions present very great differences, at least, until one arrives at the account of the cardiac plexuses; the ultimate distribution of the nerves of the heart appeared to be the same in all these subjects.

All the cardiac nerves are gray, but they are not all soft, as declared by Scarpa, who called them *nervi molles*. Sometimes the right, and sometimes the left cardiac nerves, are the larger; the nerves of the two sides are inversely proportioned to each other in this respect, and there is evidently a mutual dependance between them. In one case, in which the middle and inferior cardiac nerves of the right side were wanting, and the superior cardiac nerve very small, their places were supplied by some large branches from the right recurrent nerve, and by the left cardiac nerves, which were largely developed.

Anatomists follow Scarpa in describing three cardiac nerves on each side: a *superior*, named by him the *superficial* cardiac nerve, which is derived from the superior cervical ganglion; a *middle*, called by him the *great* or *deep cardiac nerve*, which arises from the middle cervical ganglion; and an *inferior*, or *small* cardiac nerve, proceeding from the inferior cervical ganglion. Although this is the usual arrangement, it is often impossible to distinguish three nerves, in consequence of the anatomical varieties which I have already mentioned. There is frequently no middle cardiac nerve properly so called; at other times there is no inferior cardiac nerve, or, rather, they are both in a rudimentary state; lastly, the superior cardiac nerve, if not entirely wanting, may be extremely small, and may join the middle cardiac nerve. Sometimes all the cardiac nerves of one side unite into a single trunk, or else into a plexus situated behind the sub-clavian artery, upon the side of the trachea; the recurrent nerve assists in forming this plexus, from which three, four, or more branches are given off to be distributed to the heart in the usual manner. One of the most important points in the history of the cardiac nerves is their sort of fusion with the pneumogastric, which is so intimate that the cardiac branches of the pneumogastric, and those which come from the ganglia, form a single system. There is a similar fusion between the superior, middle, and inferior cardiac nerves of each side, and between the nerves of the two sides.

The recurrent nerve, in particular, appears sometimes to be distributed equally to the larynx and the heart, so large and numerous are the cardiac branches given off from it; it will hereafter be seen that there is an equally intimate connexion between the pneumogastric nerve and the solar plexus.

I shall first describe in detail the right cardiac nerves, and shall then briefly point out the differences between them and the left cardiac nerves.

The Right Cardiac Nerves.

The Superior Cardiac Nerve.—Its origin is very variable. Most commonly, it arises from the internal division of the bifurcated lower extremity of the superior cervical ganglion, the cord of communication between the superior and the next cervical ganglion forming the external division. At other times it arises from the communicating cord. In a great number of cases it has several origins, being formed by two or three very small filaments, which come from the inner side of the superior cervical ganglion; by a branch, often a large one, from the cord of communication; and by two filaments from the pneumogastric nerve. In one of these latter cases the cardiac branch from the cord of communication presented a very distinct ganglion.

Whatever may be its origin, the superior cardiac nerve passes obliquely downward and inward, behind the common carotid, from which it is separated by a very thin layer of fascia, so that it is almost impossible to include it in applying a ligature to that artery; it runs along the trachea, very often receives a branch from the trunk of the sympathetic, and crosses in front of the inferior thyroid artery, or sometimes divides into two branches, one of which, the *anterior*, passes in front of the artery, while the *posterior* joins the recurrent nerve.* At the lower part of the neck the superior cardiac nerve runs along the recurrent laryngeal nerve, with which it may be confounded; it enters the thorax, passing behind and sometimes in front of the sub-clavian artery,† runs along the brachio-cephalic trunk, gains the back of the arch of the aorta, gives off a certain number of filaments, which pass in front of that part of the vessel, then runs obliquely downward and to the left between the arch of the aorta and the trachea, anastomoses very frequently with the middle and inferior cardiac nerves and with the branches of the recurrent, and divides into two sets of filaments; some of these pass between the aorta and the pulmonary artery, and others between the right pulmonary trunk and the trachea; they both

* The trunk of the sympathetic, having reached the inferior thyroid artery, sometimes divides into two branches, one of which passes in front of that artery, to join the superior cardiac nerve, while the other passes behind it to the inferior cervical ganglion; not unfrequently the superior cardiac nerve presents a ganglionic enlargement, which occupies the whole or a part of the thickness of the nerve.

† The superior cardiac nerve often bifurcates so as to embrace the sub-clavian artery in a complete ring. At other times the superior cardiac nerve passes behind the sub-clavian artery, and the cardiac branch of the pneumogastric in front of it, so as to form beneath the sub-clavian an anastomotic loop, which lies to the inner side of the one formed by the recurrent nerve. Most commonly the cardiac branch of the pneumogastric anastomoses with the superior cardiac nerve, between the arch of the aorta and the trachea.

anastomose with the left cardiac nerves, and are arranged as we shall soon describe. In some rare cases, the right superior cardiac nerve goes directly to the cardiac plexus, without anastomosing with the middle and inferior cardiac nerves.

During its course along the neck, the right superior cardiac nerve receives the small superior cardiac branches of the pneumogastric, and gives off several filaments, some to the pharynx, others to the trachea and the thyroid body, while several assist in forming the plexus of the inferior thyroid artery; it often gives off three or four branches which anastomose with the recurrent nerve.

In the thorax, the superior cardiac nerve is joined by the cardiac branch given off by the pneumogastric in the lower part of the neck, and which is sometimes of very considerable size, and evidently re-enforces the cardiac nerve; this branch of the pneumogastric sometimes terminates directly in the cardiac plexus.

The Middle Cardiac Nerve.—This nerve arises from the middle cervical ganglion, or, when that is absent, from the trunk of the sympathetic, at a variable distance from the inferior cervical ganglion. It is rather frequently the largest of the cardiac nerves, and has, therefore, been called by Scarpa the *great* cardiac nerve (*magnus, profundus*). At other times it is in a rudimentary state, and is replaced either by the superior or the inferior cardiac nerve, or by branches from the recurrent: it frequently divides into several twigs, between which the sub-clavian passes; it almost always anastomoses with the superior and inferior cardiac nerves of the same side, runs along the recurrent nerve, for which it might be mistaken, and with which it is always connected, and then terminates in the cardiac plexus.

The Inferior Cardiac Nerve.—This is generally smaller (*cardiacus minor*) than the preceding nerve, though it is sometimes larger; it usually arises from the inferior cervical ganglion, but rather fequently from the first thoracic; it accompanies the middle cardiac nerve, anastomoses with that nerve, and, like it, descends vertically in front of the trachea, and terminates in the cardiac plexus.

The connexion of the middle and inferior cardiac nerves with the recurrent nerve demands especial attention. Sometimes the recurrent sends off certain large branches which join the cardiac nerves, and form their principal origin. I have seen the middle and inferior cardiac nerves united together, crossing over the recurrent nerve at right angles, and adhering intimately to it without presenting that admixture of filaments which constitutes an anastomosis.*

The Left Cardiac Nerves.

The peculiarities of the left cardiac nerves may be stated in a few words:† in the neck, they are situated in front of the œsophagus, on account of the position of that canal. The connexions between the cardiac nerves and the recurrent on the left side appear to me more numerous than those on the right. In one case, the superior and inferior cardiac nerves gave off a series of four rather large filaments, which ran along the recurrent, left that nerve opposite to its point of reflection, and then terminated in the usual manner. I ascertained that, in this case, the two nerves were merely in contact, and did not anastomose.

In the thorax, the superior and middle cardiac nerves of the left side descend between the carotid and sub-clavian, and then run upon the concavity of the arch of the aorta; the inferior cardiac nerve, which is the largest of all the cardiac nerves in a subject which I have now before me, passes to the left of the trunk of the pulmonary artery, turns round its back part, and embraces it in a loop, so as to enter that portion of the cardiac plexus which is situated between the aorta and the right division of the pulmonary artery. Lastly, on the left side, more commonly than on the right, the anterior pulmonary plexus sends off some flaments to this same part of the cardiac plexus.

The Cardiac Ganglion and Plexuses.

We have seen that the cardiac nerves of the same side anastomose with each other on the sides or in front of the trachea. Besides this, the right cardiac nerves anastomose with the left upon the concavity of the arch of the aorta; also in front of the trachea, above the right pulmonary artery; and, lastly, in the anterior and posterior coronary plexuses.

Wrisberg was the first to describe a ganglion in the situation of the first-named anastomosis, that is to say, upon the concavity of the arch of the aorta, between that vessel and the pulmonary artery, to the right of the remains of the ductus arteriosus. This ganglion, which is by no means constant, is named the *cardiac ganglion*; it is joined [so as to form the superficial cardiac plexus] by the superior cardiac nerve of the right side,

* It is especially in these anastomoses between the cardiac and recurrent nerves that I have been able, from the different aspect of the filaments of each, to ascertain that the anastomoses of nerves are often merely apparent, and consist of a simple juxtaposition of two nerves without any communication of their component fasciculi, which can be traced uninterruptedly from their entrance to their emergence. The same observation applies also to some of the anastomoses between nerves of the same kind.

† In one subject, three filaments arose from the left superior cervical ganglion, and united in a small ganglionic nodule, which also received a twig from the laryngeal nerve. This ganglionic nodule gave off several pharyngeal twigs, and also the superior cardiac nerve.

by the same nerve of the left side, and sometimes also by the right and left cardiac branches given off from the pneumogastric nerves in the lower part of the neck.

The second anastomosis, or that which takes place in front of the trachea, above the right pulmonary artery, and behind the arch of the aorta, has been known, since the time of Haller, as the *great cardiac plexus* (magnus, profundus plexus cardiacus, *Scarpa*). A ganglionic enlargement is not unfrequently found at the junction of the principal branches. This great cardiac plexus is chiefly formed by the middle and inferior cardiac nerves of both sides: [it also receives part of the right superficial nerves.] Lastly, all the cardiac nerves end in the third set of anastomoses, namely, those upon the anterior and posterior coronary arteries around the root of the aorta.

Great as the variety may be in the course and size of the cardiac nerves up to the origin of the great vessels from the heart, there is as constant a uniformity in their arrangement around those vessels, and in their ultimate distribution to the heart.

Upon the origin of the great vessels, the cardiac nerves are arranged in three layers or sets.

The *superficial layer of nerves* is the smallest; it occupies the anterior surface of the arch of the aorta, and especially its right side; the nerves are visible without any dissection through the transparent pericardium; they all pass (*v*) to the anterior coronary artery, to the right side of the infundibulum of the right ventricle. In this superficial layer, *the superficial cardiac plexus*, may be included the ganglion of Wrisberg, when it exists, and its several branches, which in a great measure assist in forming the anterior coronary plexus.

The *middle layer of nerves* is composed of two very distinct parts, viz., of the great or *deep cardiac plexus* of Haller, which is situated between the trachea and the arch of the aorta, above the right pulmonary artery; and of a much smaller part, situated below the great cardiac plexus, from which it is derived, and between the right pulmonary artery and the arch of the aorta. In order to obtain a good view of this layer, the arch of the aorta must be cut through.

The *deep layer of nerves* is situated between the right pulmonary artery and the bifurcation of the trachea. The trunk of the pulmonary artery must be divided in order to expose it.

The Anterior and Posterior Coronary Plexuses.—The whole of the superficial cardiac plexus or superficial layer of nerves ends in the anterior coronary plexus (*v*) which surrounds the right coronary artery. The middle and posterior layers unite below the right pulmonary artery, in front of the auricles, to form a plexus, which might more properly be named the great or deep cardiac plexus than the interlacement so called by Haller. From this plexus, into which the left inferior cardiac nerve enters directly, the following branches proceed: *anterior auricular branches*, which are very numerous; certain branches which pass between the aorta and the pulmonary artery to gain the right side of the infundibulum, and join the *anterior coronary plexus*, which, as we have seen already, is derived from the superficial cardiac plexus; lastly, the branches for the *posterior coronary plexus*, which surrounds the origin of the left coronary artery, and divides, like that vessel, into two secondary plexuses, one of which runs round the left auriculo-ventricular furrow, while the other (*v'*) enters the anterior ventricular furrow.

The nervous filaments from these plexuses soon leave the ramifications of the arteries; they proceed separately; they are all equally small, and can be seen without any dissection, like white lines, extending from the base towards the apex of the heart. They all belong to the ventricular portion of the heart; a few of them, however, ascend on the posterior surface of the auricles, which are much more abundantly supplied upon their anterior surface.

The cardiac nerves are not entirely distributed to the heart; several of them are lost in the coats of the aorta, some join the anterior pulmonary plexus, and some ramify in the pericardium.

The Thoracic Portion of the Sympathetic System.

In *the thorax*, the trunk of the sympathetic (*i t, fig.* 302) consists, on each side, of a grayish cord, having as many nodules or ganglia upon it as there are vertebræ. This cord is situated, not in front of the dorsal vertebræ, but in front of the heads of the ribs, to which the ganglia for the most part correspond: the two superior thoracic ganglia are the largest, and are almost always united; the succeeding ganglia are almost of equal size, the twelfth being next in size to the first and second. The ganglionic structure is observed throughout the whole extent of this part of the sympathetic, so that the cords of communication between the ganglia may be said to be merely prolongations of the ganglia. In some subjects the ganglia cannot be distinguished from the portions of the sympathetic trunk above and below them, except by the branches which enter and converge from those points; it would, therefore, be a serious anatomical error to regard the portions of the trunk between the ganglia as mere filaments of communication. In some subjects the cords between the ganglia are divided into two or three filaments. The varieties observed in the number of the thoracic ganglia are rather appa-

rent than real: they depend, some upon fusion of the first thoracic ganglion with the inferior cervical ganglion, or of the first and second thoracic ganglia; others upon fusion of two central ganglia, or upon that, which is more common, of the last thoracic with the first lumbar ganglion; upon a transposition of the last thoracic ganglion, which is then found upon the first lumbar vertebra; and, lastly, upon the two inferior thoracic ganglia being situated in the last intercostal space. Besides this, the three lowest thoracic ganglia are subject to much variety, both in situation and in shape; and the same may be said of the mode of connexion between the twelfth thoracic and the first lumbar ganglion.

The thoracic portion of the sympathetic lies beneath the pleura and the very thin fibrous layer by which that membrane is strengthened. It can be distinctly seen without any dissection, in consequence of the transparency of these layers. The intercostal arteries and veins pass behind it; on the right side, the vena azygos runs along it.

The thoracic portion of the sympathetic gives off *external branches*, or branches of communication with the dorsal nerves; and the *internal branches*, which are intended for the aorta and the abdominal viscera.

The External or Spinal Branches.

There are at least two spinal branches from each ganglion, one superficial and larger, which is connected to the outer angle of the ganglion; the other deep and smaller, which is attached to its posterior surface: there is sometimes a third filament of communication. Not unfrequently these branches unite into a single trunk, before reaching the ganglion.

I regard these anastomotic branches (*e e*), between the spinal nerves and the ganglia of the sympathetic, not as branches furnished by the ganglia to the spinal nerves, nor simply as means of communication between one and the other, but rather as branches of origin of the sympathetic: this, indeed, is clearly demonstrated by the arrangement of these spinal branches of the sympathetic, which are always proportioned to the size of the ganglia from which they arise. In general, each ganglion communicates only with the corresponding spinal nerve; not unfrequently, however, a ganglion receives a twig from the intercostal nerve immediately below it.*

The branches of communication from the dorsal nerves to the thoracic ganglia of the sympathetic are horizontal, or, rather, they are inclined obliquely downward and inward, excepting those which ascend to the first thoracic ganglion, and those which descend to join the last thoracic ganglion. These branches are white, like the nerves of the cerebro-spinal system, and not gray, like the ganglionic nerves. On examining their ultimate distribution in the sympathetic ganglia, and their connexions with the dorsal and intercostal nerves, after the parts have been macerated, first in diluted nitric acid and then in water, it is seen that these branches are evidently reflected funiculi of the spinal nerves; and that the nerves, immediately after having given off these branches, are proportionally diminished in size; that, having reached the ganglia, the communicating branches divide into filaments, of which some *ascend*, and may be traced upon the trunk of the sympathetic above the ganglion, and appear to be continuous with the descending filaments derived from the spinal nerve above, while the others *descend* to pass upon the portion of the sympathetic trunk below the ganglion; and, lastly, that these white filaments run upon the surface of the sympathetic, and contrast with the gray colour of the central portion of that nerve.

The Internal, or Aortic and Splanchnic Branches.

The *internal branches of the first five or six thoracic ganglia* are exclusively intended for the aorta; some of them appear to enter the pulmonary plexus.

Some of the *internal branches of the last six thoracic ganglia* are intended for the aorta, and the remainder, which are the principal, unite to form the *splanchnic nerves* or nerves of the *abdominal viscera*. I have never seen any of them pass to the œsophagus.

The Aortic Branches.—The *aortic branches* consist of very small filaments, of which two or three proceed from each ganglion. They accompany the intercostal arteries, around which they form small plexuses. These filaments are much longer on the right than on the left side, on account of the position of the aorta; they pass, some in front and others behind that vessel, upon which it soon becomes impossible to follow them. The aortic branch from the fourth thoracic ganglion is the only one of any considerable size; it appears to be shared between the aorta and the pulmonary plexus. A number of these aortic filaments sometimes converge towards certain small knots or ganglia, which are arranged in front or along the sides of the aorta, and give off a number of filaments.

The first thoracic ganglion sends some twigs to the cardiac plexuses; and not unfre-

* In one subject I found a very remarkable disposition of the branches for the four inferior thoracic ganglia. Some small twigs from these four ganglia terminated in a minute gangliform structure, which gave off the branches to the spinal nerves. It will be seen that the same arrangement frequently occurs in the lumbar region.

quently the inferior cardiac nerve proceeds from this ganglion. Some filaments from the same ganglion are distributed to the lower part of the longus colli muscle.

Lobstein (*De Nervo Magno Sympathetico*, p 19) describes a very delicate filament from this ganglion, which perforates the anterior common vertebral ligament, and enters the substance of one of the vertebræ. A similar filament appears to me to be given off by all the cervical, thoracic, lumbar, and sacral sympathetic ganglia. The vertebræ, like the other bones, are provided with nerves, which are overlooked in a hasty examination, from their excessive tenuity.

The Splanchnic Branches.—These constitute the splanchnic nerves, which require a separate description.

The Splanchnic Nerves.

The *splanchnic nerves* are divided into the great splanchnic and the small splanchnic, or renal.

The Great Splanchnic Nerve.—The great splanchnic is a white nerve, and has no resemblance to the ganglionic nerves. It is formed in the following manner: a thick branch derived from the sixth and seventh thoracic ganglia, sometimes also from the fifth, and even from the fourth ganglion (see *fig.* 302), passes downward and inward upon the side of the dorsal vertebræ: this branch is joined by a series of three or four smaller branches given off not only from the succeeding thoracic ganglia, but also from the communicating cords between them; these branches (*g g*) are parallel to each other, and pass obliquely downward and inward. The eleventh and twelfth thoracic ganglia never assist in the formation of the great splanchnic nerve.

The branches just mentioned unite on each side to constitute the *great splanchnic nerves*, which have the same relation to the thoracic ganglia that the cardiac nerves have to the cervical ganglia: it is important to remark that the ganglionic nerves of the thoracic viscera are derived from the cervical ganglia of the sympathetic, and that the ganglionic nerves of the abdominal viscera are given off from the thoracic ganglia.

In general, the great splanchnic nerve arises by four roots; but not unfrequently it arises only by two, which then represent the four origins.

If, after having macerated the parts in diluted nitric acid, an attempt be made to determine exactly the highest point from which the great splanchnic nerve originates, it will be seen that the white filaments of which this nerve is composed are already distinct opposite the third thoracic ganglion, and, moreover, that they are merely in contact with the trunk of the sympathetic and with the ganglia, and are continuous with the communicating branches from the spinal nerves. Anatomy, therefore, most clearly proves that the splanchnic nerve is continuous with the spinal nerves.

Thus formed and completed opposite to the eleventh rib, the great splanchnic nerve passes downward and inward in front of the vertebral column; it becomes flattened and widened, perforates the diaphragm, the fibres of which separate to allow it to pass through, and immediately terminates in the semilunar ganglion (*x*). An olive-shaped ganglion is not unfrequently found upon the great splanchnic, at a short distance before the nerve passes through the diaphragm.*

The Small Splanchnic, or Renal Nerves.—I think it proper to include in the same description the *lesser splanchnic nerve* of authors, and the *posterior renal* nerves of Walter, the distinction between these nerves appearing to me to be quite arbitrary. They are two, and sometimes three in number. The highest is named the *small splanchnic* (*h*); it arises from the eleventh thoracic ganglion, and sometimes from both the tenth and the eleventh. The lowest, which is the *renal nerve* of authors, is larger than the preceding, and is derived from the twelfth thoracic ganglion (*i*): it often gives off a small filament to the first lumbar ganglion, and in a great number of cases this is the only means of communication between the thoracic and the lumbar ganglia of the sympathetic. In such a case, the series of ganglia is said to be interrupted; but a complete interruption never exists.

The small splanchnic or renal nerves exactly resemble the separate or single origins of the great splanchnic, with which they form a continuous series. They arise in the same manner, from the two or three inferior thoracic ganglia. They pass inward and downward, parallel to and on the outer side of the great splanchnic, perforate the crus of the diaphragm either to the outer side of or at the same point as the great nerve, and enter the renal and aortic plexuses; they are often shared between these two plexuses and the great splanchnic nerve. The highest of the small splanchnic nerves rather frequently anastomoses with the great splanchnic, or even becomes entirely blended with it.†

* Lobstein has recorded a case (p. 2) in which this unusual ganglion on the great splanchnic was of a semilunar shape, and gave off, from its convex side, seven or eight slender filaments, which accompanied the aorta and were all lost in the diaphragm; he has also mentioned another case, in which three filaments arose from this ganglion, two going to the solar plexus, and the third to the mesenteric plexus.

† Among the numerous varieties which I have observed in the formation of the small splanchnic nerves, I would especially notice the following: a twig from the eleventh thoracic ganglion, and one from the great splanchnic nerve, terminated in a small ganglion; from this ganglion were given off several filaments that were lost upon the aorta, and also a small cord which joined with a twig from the twelfth thoracic ganglion, and was distributed in the ordinary manner.

The Visceral Ganglia and Plexuses in the Abdomen.

As the *semilunar ganglia* and the *visceral plexuses in the abdomen* form the continuation of the splanchnic nerves, it is not only theoretically, but practically convenient to enter upon their description now.

The central point of all these ganglia and plexuses is situated at the epigastrium, and is formed by a ganglionic plexus, named the *solar* or *epigastric plexus*.

The Solar or Epigastric Plexus.

The *solar plexus* (opposite *x*, *fig.* 302) is formed by an uninterrupted series of ganglia, extending from the great splanchnic nerve of the one side to its fellow of the opposite side. From this point as from a centre proceed a great number of branches, which have been compared to the rays of the sun, and hence the term *solar plexus*.

This solar plexus, which is regarded by physiologists as the centre of the nervous system of nutritive life, is deeply seated in the epigastric region, and might therefore be called the *epigastric nervous centre;* it is situated in the median line, in front of the aorta, around the cœliac axis, and above the pancreas ; it is bounded on each side by the supra-renal capsules, and is of too irregular a shape to be clearly defined. The ganglia of which it is composed, the *solar ganglia*, are as irregular and variable as the plexus itself. They consist of thick and swollen cords, or ganglionic arches or circles, arranged in a network, in the meshes of which are found some lymphatic glands easily distinguishable from the nervous ganglia and cords. Anatomists, in general, describe only the two extreme ganglia of the solar plexus, in which the great splanchnic nerves terminate ; these are the *semilunar ganglia* (*x*), so called from their shape, but which are subject to much variety both in form and size. Their convex border, which is turned downward, is divided into several teeth, from each of which a pencil of nerves is given off; a great number of filaments are also given off from their concave border, which is directed upward. These ganglia are situated close to the supra-renal capsules ; they are often without any regular form, and, as it were, divided into fragments.

A single glance at the solar plexus will suffice to convince us of the impossibility of extirpating it, as some experimenters pretend to have done, in living animals.

The great splanchnic nerve of each side (*g*), a part of the small splanchnic nerves (*h*), and the right pneumogastric nerve (*p'*), end in the solar plexus. I have also seen the right phrenic enter this plexus.

From it, as from a centre, plexuses are given off for all the arteries arising from the fore part of the aorta, and also for the renal and spermatic arteries. The plexuses for the renal arteries and the inferior mesenteric artery are completed by the visceral nerves derived directly from the lumbar ganglia. There are two diaphragmatic plexuses, a cœliac plexus, a superior and an inferior mesenteric plexus, renal plexuses, spermatic or ovarian plexuses, and supra-renal plexuses.

All the nerves given off from the solar ganglia are gray, and very small ; they are always plexiform, and are generally strong on account of the thickness of their neurilemma.

The Diaphragmatic and Supra-renal Plexuses.

The *diaphragmatic* or *phrenic plexuses* are small ; they are given off from the upper part of the solar plexus, and reach the phrenic arteries, with which they enter the diaphragm ; they at first lie beneath the peritoneum, but afterward dip into the substance of the fleshy fibres of the muscle, and do not exactly follow the course of the vessels. In some cases I have been able to ascertain that they anastomose with the filaments of the phrenic nerve : they always run in nearly the same direction.

The diaphragmatic plexus of the right side is larger than that of the left. I have seen two ganglia, upon the right crus of the diaphragm, which formed the origin of the right diaphragmatic plexus and of some hepatic nerves.

I arrange the *plexuses of the supra-renal bodies* with the preceding, because they have so many relations with them. They arise directly from the semilunar ganglia, by two very delicate pencils of nerves, which reach the back of the supra-renal arteries, and are lost in the substance of the supra-renal bodies. Several filaments from the diaphragmatic plexuses join them, passing in front of the arteries. The supra-renal plexuses are large in proportion to the size of the organs they supply.

The Cœliac Plexus.

The cœliac plexus is one of the principal divisions of the solar plexus, of which it is the immediate prolongation, so that it is almost impossible to distinguish one from the other ; it surrounds the cœliac axis, and immediately divides, like it, into three plexuses, the *coronary* of the *stomach*, the *hepatic*, and the *splenic*.

The Coronary Plexus of the Stomach.—This is given off from the upper part of the solar plexus ; it receives some filaments from the right pneumogastric, before that nerve joins the solar plexus ; of these filaments, some ramify upon the cardia, while the remainder follow the coronary artery along the lesser curvature of the stomach, and anastomose with the pyloric filaments of the hepatic plexus. It follows, therefore, that the stomach

is principally supplied by the pneumogastric nerve. The filaments from the coronary plexus of the stomach, as well as those of the pneumogastric nerve, after having run for some distance beneath the peritoneum, perforate the muscular coat of the stomach, and appear to be partly lost in it and partly in the mucous membrane.

The *hepatic plexus* is of very considerable size, and might be divided, after the example of Lobstein, into an *anterior* and a *posterior* plexus. The *anterior* accompanies the hepatic artery, and is formed by some twigs from the right pneumogastric, and by seven or eight large gray, cylindrical filaments from the left semilunar ganglion, which are joined by two or three branches from the right semilunar ganglion.

The *posterior hepatic plexus* accompanies the vena portæ, and is derived almost entirely from the right semilunar ganglion; it is also composed of grayish, thick, cylindrical cords. I would especially notice one cord, which is remarkable both from its size and its course; it arises directly from the solar ganglion of the right side, passes in a horizontal and curved direction to reach the gastro-hepatic omentum, and continues horizontally between the layers of that omentum, in front of the lobulus Spigelii; it then ascends to the transverse fissure of the liver, becomes situated beneath the vena portæ, and may be traced along that vein into the interior of the liver. I have seen this great hepatic branch come directly from two ganglia situated upon the right crus of the diaphragm.

Before reaching the liver, the hepatic plexus gives off a secondary plexus of considerable size, around the right gastro-epiploic artery, the *right gastro-epiploic plexus*; it is considerably augmented by filaments which are derived immediately from the solar plexus, and perforate the pancreas.

The hepatic plexus also furnishes branches to the pylorus and the lesser curvature of the stomach, to the pancreas, to the great curvature of the stomach, and to the great omentum. The pylorus, therefore, and the great curvature of the stomach, are supplied almost exclusively by the hepatic plexus.*

The hepatic plexus likewise gives off a small *cystic plexus*, which is easily seen beneath the peritoneum, surrounding the cystic artery as far as the gall-bladder.

Diminished in size, from having given off a series of branches and plexuses, the hepatic plexus gains the transverse fissure of the liver, divides like the hepatic artery and vena portæ, and may be traced for some distance in the capsule of Glisson.

All the nerves of the liver are gray, but very strong.

The Splenic and Pancreatic Plexuses.—The splenic plexus is not so remarkable for the number as for the size of the filaments of which it is composed; it surrounds the splenic artery, furnishes some twigs to the pancreas, and it also gives off the *left gastro-epiploic plexus*, which is smaller than the right, is situated upon the great curvature of the stomach, and supplies that organ and the great omentum. The splenic plexus also gives off nervous filaments to the great cul-de-sac of the stomach, and being thus very much diminished in size, reaches the hilus of the spleen, within which organ it can be easily traced in man, and still more easily in the larger animals, along the ramifications of the bloodvessels.

These nerves are gray, and very strong. The numerous filaments which pass to the pancreas, and form a plexus around its arteries, constitute the pancreatic plexus, which may be regarded as a dependance of the splenic plexus.

The Superior Mesenteric Plexus.

The *superior mesenteric plexus*, which may be regarded as the lower division of the bifurcation of the epigastric plexus, is the largest of all the abdominal plexuses; it surrounds the superior mesenteric artery, forming an extremely thick plexiform sheath for it; it passes below the pancreas, enters the substance of the mesentery (*w*) with the artery, and divides, like that vessel, into a great number of secondary plexuses, which are distributed to all the parts supplied by the artery, namely, to the whole of the small intestine, excepting the duodenum, and to the right portion of the great intestine.

Without entering into tedious and useless details, I shall content myself with a few remarks upon the general distribution of these nerves.

The mesenteric nerves are remarkable for their length, their number, and their strength. I am certain that their neurilemmatic sheath is proportionally much thicker than that of other nerves. They are placed at variable distances from the vessels, and proceed in a straight line in the substance of the mesentery towards the intestine, without giving off any filaments: at a short distance from the concave border of the intestine, they either pass directly to the bowel, or else they anastomose at an angle or in an arch; from the convexity of these anastomotic arches the filaments for the intestine are given off.

There is never more than one series of anastomotic nervous arches in the mesentery, whatever may be the number of rows of vascular arches; the single nervous arch al-

* The cardia and the lesser curvature of the stomach are the parts which are the most abundantly provided with nerves. The pylorus, to which we attribute such great sensibility, has incomparably fewer.

ways corresponds to the vascular arch nearest to the intestine: the filaments which proceed from it are exceedingly minute.*

The nervous filaments penetrate the intestine by its adherent border, run for some time between the serous and muscular coats, perforate the latter, to which they give some twigs, then spread out in the fibrous coat, and finally terminate in the mucous membrane

The Inferior Mesenteric Plexus.

The *inferior mesenteric plexus* (*n*) is formed by some twigs from the epigastric plexus, or, rather, from the superior mesenteric plexus, with which it is continuous on the front of the abdominal aorta; and, secondly, by some branches from the lumbar sympathetic ganglia, which, as hereafter stated, constitute the *lumbo-aortic plexus*. The meshes of the inferior mesenteric plexus are by no means so close as those of the superior mesenteric plexus.

The inferior mesenteric plexus, like the artery by which it is supported, supplies the left half of the transverse arch of the colon, the descending colon, the sigmoid flexure, and the rectum: of its filaments, those which accompany the left colic arteries are remarkable for their tenuity, their length, and for giving no branches in their course to the intestine. I would particularly notice the twig which accompanies the left superior colic artery. It is not uninteresting to remark, that these nerves are more numerous in the iliac meso-colon, which supports the sigmoid flexure, than at any other point.

The inferior mesenteric plexus, thus diminished by having given off other smaller plexuses, terminates, like the inferior mesenteric artery, by bifurcating; the two divisions of this bifurcation are called the *hemorrhoidal plexuses;* they surround the two divisions of the artery, viz., the superior hemorrhoidal arteries, and terminate partly in the hypo-gastric plexus and partly in the rectum.

The Renal and Spermatic, or Ovarian Plexuses.

The *renal plexuses* are extremely complicated: they are formed by branches from the solar plexus, and by the two or three small splanchnic or renal nerves, and terminate almost exclusively by surrounding the renal artery.

The two *spermatic plexuses* in the male, and *ovarian plexuses* in the female, are derived principally from the renal plexuses. The *spermatic plexuses* are destined exclusively for the testicles; the *ovarian plexuses*, like the arteries of the same name, are distributed both to the ovaries and the uterus. The intimate connexions between the nerves of the kidneys and testicles in the male, and those of the kidneys, ovaries, and uterus in the female, deserve the most particular attention of anatomists.

The Lumbar Portion of the Sympathetic System.

The *lumbar portion of the trunk of the sympathetic* (*l l, fig.* 302) is situated in front of the vertebral column, along the inner border of the psoas muscle. The ganglia of this region are therefore nearer the median line than the thoracic ganglia; but the inferior lumbar ganglia not unfrequently deviate from their ordinary position, and approach the lumbar nerves as these emerge from the spinal canal: in this case, they are concealed by the psoas muscle. The lumbar ganglia of the sympathetic vary much in size; some of them are so small that they would escape notice, if their grayish colour did not distinguish them from the rest of the trunk of the sympathetic.

The number of these ganglia is also variable; there are rarely more than four. Two or three ganglia are often blended into a gangliform cord; this fusion may be easily recognised by the arrangement of the communicating filaments between it and the lumbar spinal nerves.

In one subject, the twelfth thoracic ganglion on the right side was blended with the first lumbar ganglion: a small filament, corresponding in length to the thickness of two vertebræ, established a communication between this ganglion and a large gangliform cord, which represented by itself the four inferior lumbar ganglia. On the left side, the second and third lumbar ganglia were united, and the fifth was blended with the first sacral. This fusion of the lumbar ganglia almost constantly exists, and it establishes a close analogy between the lumbar portion of the sympathetic and the cervical portion, which, as we have already seen, has only three, and frequently only two ganglia. It proves that the superior cervical ganglion may be regarded as representing five superior cervical ganglia and the ganglia corresponding to the two sets of cranial nerves, and that the inferior cervical ganglion may be viewed as the representative of two lower cervical ganglia, when the middle ganglion is wanting.

Moreover, the trunk of the sympathetic is not unfrequently interrupted either between the twelfth thoracic and the first lumbar ganglion, or between the last lumbar and the

* In one case I found a very remarkable anastomosis. Four filaments, proceeding from four opposite points, converged towards a common centre; but, as they were about to cross, they diverged from one another so as to intercept a lozenge-shaped space. Two of these might be regarded as filaments of origin, and the other two as terminating filaments

first sacral ganglion: this interruption is, however, more apparent than real, for, as I have already stated, the continuity between the twelfth thoracic and the first lumbar ganglion is always established by means of a small twig from the renal nerve.

The branches of the lumbar ganglia may be divided into the branches of communication between the ganglia; the external branches, and the internal branches: besides these, there are some small and very delicate filaments, which enter the bodies of the vertebræ.

The Communicating Branches between the Ganglia.

These communicating branches consist of one or more white cords extending between every two ganglia; they scarcely ever have the gray appearance and ganglionic structure usually found in similar branches of communication: the communicating filament between the fourth and fifth lumbar ganglion is often wanting.

The External Branches.

These are the branches (at *d*) which communicate with the lumbar nerves. I conceive that they are furnished by the lumbar spinal nerves to the lumbar ganglia of the sympathetic. There are generally two, but sometimes three for each ganglion; they arise from the anterior branches of the several lumbar nerves, as they emerge from the inter-vertebral foramina;* they accompany the lumbar arteries, along the grooves upon the bodies of the lumbar vertebræ, and terminate in the corresponding ganglia; they are usually directed obliquely downward.

In general, each ganglion receives branches not only from the corresponding lumbar nerve, but also from the nerve next above it. Thus, two branches end in the second lumbar ganglion, one from the first, and another from the second lumbar nerve; the third ganglion receives filaments from the second and third lumbar nerves; when one ganglion is wanting, its place is supplied by the next, which receives its own proper branches, and also those belonging to the absent ganglion. One ganglion not unfrequently communicates with three lumbar nerves.

When several ganglia are united into one, it is easy to conceive that this single ganglion must receive all the filaments corresponding to those ganglia. It is also easy to understand that these filaments must be directed more or less obliquely either upward or downward, and that they will correspond in length to the distance between the lumbar nerves and the single ganglion, the superior filaments being directed downward, and the inferior filaments upward.

A very remarkable condition of the branches of communication between the lumbar nerves and the sympathetic ganglia consists in the existence of certain ganglia or swellings upon them; and the almost indefinite anomalies observed in this particular are no less remarkable. I have found as many as three ganglionic nodules upon the same communicating branch: sometimes, when the two or three communicating branches reach the side of a vertebra, they unite in a ganglion, from which two or three other branches are given off to the proper sympathetic ganglion.†

Moreover, these ganglia, like all the irregular ganglia, rarely present that peculiar character which is common to the regular ganglia, namely, that of forming a centre in which a certain number of filaments end, and from which others are given off.

The Internal, or Aortic and Splanchnic Branches.

The *internal branches* from the lumbar ganglia are the *aortic* and the *lumbar splanchnic branches*, and form a continuous and uninterrupted series with the aortic and splanchnic branches from the thoracic ganglia; so that the internal branches from the first (*l*) and sometimes from the second lumbar ganglion join the branches from the eleventh and twelfth thoracic ganglia, to form a small splanchnic nerve, which is shared between the solar and the renal plexus. Some small gangliform nodules are occasionally found upon the course of these branches, among which are some very delicate filaments, which evidently pass into the bodies of the lumbar vertebræ. All these internal branches assist in the formation of the *lumbar splanchnic*, or *pelvic visceral* nerves.

The Lumbar Splanchnic Nerves and the Visceral Plexuses in the Pelvis.

The lumbar splanchnic nerves (at *k*) pass inward in front of the aorta, below the superior mesenteric artery, and anastomose with each other and with those of the opposite side to form a very complicated plexus, which is completed by a very considerable prolongation from the superior mesenteric plexus.

This plexus (*n*), which may be called the *lumbo-aortic* plexus, surrounds all that portion of the aorta which is included between the superior and inferior mesenteric arteries; in the intervals between the nervous filaments are found lymphatic glands, which should be carefully distinguished from some nervous ganglia which form part of the plexus.

The lumbo-aortic plexus is bifurcated below; one portion of it passes upon the infe-

* These communicating branches frequently arise in the substance of the psoas muscle from twigs derived from the lumbar plexus.

† This disposition is well seen in the beautiful plate of the sympathetic published by M. Manec.

rior mesenteric artery to constitute the greater part of the inferior mesenteric plexus (below *n*); while the other portion descends upon the aorta, and even a little below the bifurcation of that vessel, and ends between the common iliac arteries, in front of the sacro-vertebral angle, from which it is separated by the common iliac veins. Some filaments are prolonged around the common iliac and the external and internal iliac arteries and their branches.

The aortic portion of the lumbo-aortic plexus bifurcates below into *two secondary plexiform cords*, one *right* and the other *left*, which pass downward upon the sides of the rectum and bladder, and enter the right and left hypogastric plexuses, which are almost entirely formed by these cords.

The Hypogastric Plexuses.

The hypogastric plexuses (*m*) are among the great plexuses of the body; they supply the rectum and the bladder in both sexes, and also the prostate and testicle in the male, and the vagina, uterus, and Fallopian tubes in the female.

There are two hypogastric plexuses, one on the right, the other on the left side. They are situated upon the lateral and inferior surfaces of the rectum and bladder in the male, and of the rectum, vagina, and bladder in the female; they are distinct from each other, and are connected not by median anastomoses, which I have never been able to detect, but through the lumbo-aortic plexus, by the bifurcation and spreading out of which they may be said to be formed. The hypogastric plexuses, from the enlargement and areolar disposition of their component cords, very closely resemble the solar plexus.

Each plexus is formed essentially by one of the two divisions of the lumbo-aortic plexus; it is also joined by some filaments from the inferior mesenteric plexus, by some very small twigs from the sacral ganglia, among which those derived from the third sacral ganglion are especially remarkable; and, lastly, by some twigs from the anterior branches of the sacral nerves (see SACRAL NERVES).

Formed by a combination of filaments from these different sources, each hypogastric plexus gives off a hemorrhoidal, a vesical, a vaginal, a uterine, and a spermatic or ovarian plexus; all of these plexuses, like the hypogastric plexus itself, are found on each side of the body.

The *inferior hemorrhoidal plexuses* are blended with the superior hemorrhoidal plexuses, which, as already stated, are the terminations of the inferior mesenteric plexus; they pass behind and in front of the rectum. The filaments belonging to the anterior branches of the sacral nerves may be distinguished from those belonging to the sympathetic system by the difference in the colour of the two kinds of nerves.

The *vesical plexuses* are composed of a great number of exceedingly small filaments. They are situated upon the sides of the posterior fundus (bas-fond) of the bladder, on the outer side of the ureters, and are divided into two sets, viz., *ascending vesical* nerves, which pass upward upon the sides of the bladder, embrace the outer and inner surfaces of the ureters, and ramify upon the anterior and posterior surfaces of the bladder; and *horizontal vesical* nerves, which run forward upon the sides of the fundus of the bladder, externally to the large plexus of veins found in that situation, and spread out into extremely delicate filaments, of which some enter the substance of the bladder, especially at its neck, while the others, in considerable numbers, turn round the prostate gland, and are distributed within it; one of the *prostatic filaments* may be traced into the membranous portion of the urethra.

The Plexuses for the Vesiculæ Seminales, and Vasa Deferentia, and Testicles.—Some of the filaments situated on the inner side of the ureters surround the vesiculæ seminales, and are lost in them; these are very small; two or three remarkably large filaments run upward along each vas deferens; having reached the inguinal ring, they unite with the corresponding spermatic plexus, which is a production of the renal plexus, and descend to the testicle.

The branches for the prostate, vesiculæ seminales, vasa deferentia, and testicles, are represented in the female by the utero-vaginal, ovarian, and tubal nerves.

The Uterine Nerves.—Notwithstanding the figures of the sympathetic published by Walter, in which the nerves of the uterus are well represented, and notwithstanding the still more explicit description given of them by Hunter, most anatomists continue to entertain doubts regarding the existence of the uterine nerves. Lobstein, in his work on the Sympathetic, published in 1822, even denied them altogether; but Tiedemann, in the same year, published two beautiful figures, representing the nerves of the gravid uterus.*

The uterine nerves are derived from several sources. I have already stated that the plexuses surrounding the ovarian arteries, which are productions of the renal plexuses, are distributed, like the vessels by which they are supported, both to the uterus and the ovaries.

It appears to me that the ovarian nerves and vessels have a similar arrangement, that is to say, that the uterine branches derived from the ovarian plexuses are larger than the ovarian nerves properly so called.

* Tabulæ Nervorum Uteri, Heidelberg, 1822, folio.

The tubal nerves are also derived from the ovarian plexuses.

The uterine nerves derived from the hypogastric plexuses are divided into *ascending* branches, which run upward along the lateral borders of the uterus, pass forward and backward upon the surfaces of that organ, and terminate in its substance; and into *descending* branches, which run along the sides of the vagina, and terminate in it. These vaginal nerves appear to be inseparably blended with the vesical and hemorrhoidal nerves.*

Such are the divisions of the hypogastric plexuses; analogy, rather than direct observation, has led to the admission of the existence of gluteal, ischiatic, and internal pudic plexuses; in fact, of plexuses around all the branches of the internal iliac arteries.

The Sacral Portion of the Sympathetic System.

The *sacral portion of the sympathetic* (*s s, fig.* 302) is formed on each side by a cord enlarged at intervals, and situated on the inner side of, and along the anterior sacral foramina.

It forms a continuation of the lumbar portion of the sympathetic; but sometimes there appears to be an interruption in the ganglionic chain, between the fifth lumbar ganglion and the first sacral. This interruption is merely apparent; it is never complete. The sacral trunks of the sympathetic of the right and left sides gradually approach each other as they descend, corresponding in this respect to the anterior sacral foramina.

The sacral ganglia, which are rarely five, more commonly four, and sometimes three in number, are occasionally collected into a small gangliform enlargement, situated between the first and second anterior sacral foramen; the first sacral ganglion is sometimes double, and at other times it rather resembles a gangliform cord than a true ganglion.

The mode of connexion between the first sacral and the last lumbar ganglion is subject to much variety.† The manner in which the sacral portion of the sympathetic terminates is also somewhat variable. The following is the arrangement most generally admitted: a filament proceeds from the last sacral ganglion, which is usually the fourth, and forms an anastomotic arch with its fellow of the opposite side, in front of the base of the coccyx. At their point of junction is often found a small ganglion (*ganglion impar, c*), from which certain terminal filaments are given off. Sometimes there is neither a coccygeal ganglion nor any anastomosis, properly so called, but the terminal filaments are distributed in the usual way. I have not been able to trace these filaments beyond the periosteum of the coccyx and the sacro-sciatic ligaments.

Like the other ganglia of the sympathetic, the sacral ganglia present *communicating branches* with each other; rather large *external branches* derived from the corresponding sacral nerves; *internal branches*, which anastomose with those of the opposite side, in front of the sacrum, and surround the middle sacral artery. Some of these filaments I have distinctly seen entering the substance of the sacrum; and, lastly, very small *anterior branches* (*y*), some of which join the hypogastric plexuses, while the others terminate directly upon the rectum.

General View of the Sympathetic System.

The following dissection is necessary, in order to present a correct general idea of the sympathetic system.

Take a spinal column which has been macerated in diluted nitric acid, remove the bodies of the vertebræ, leaving, if it be wished, the inter-vertebral substances; be very careful to preserve the branches of communication between the sympathetic and the cranial and spinal nerves.

It is then clearly seen that the two gangliated trunks of the sympathetic are connected with the cerebro-spinal axis by as many roots, or small groups of roots,‡ as there are cranial and spinal nerves; it is, moreover, no less evident that the communicating branches between the ganglionic chain and the spinal nerves do not proceed from the ganglia, but from the spinal nerves; so that it may be stated as a demonstrated anatomical fact, that the *sympathetic system has its origin in the cerebro-spinal system.* ◊

* [Dr. Lee has recently examined minutely the distribution of the nerves of the unimpregnated and gravid uterus. He has described (*Anatomy of the Nerves of the Uterus*, with plates, 1841, and Proceedings of the Royal Society, No. 49) several large uterine plexuses; also, several "large ganglia on the uterine nerves, and on those of the vagina and bladder;" and, farther, "two great ganglia situated on the sides of the neck of the uterus."]

† In one case, the continuation of the lumbar portion of the sympathetic deviated outward, and joined the fifth lumbar nerve; a very small filament only formed the communication between the last lumbar ganglion and the first sacral. In another case, these two filaments proceeded from the last lumbar ganglion of the right side, the inner of which joined the first sacral ganglion of the opposite side, crossing over the sacro-vertebral angle.

‡ It must be remembered that there are always two, and sometimes three communicating branches between the sympathetic and each of the spinal nerves.

◊ These facts in human anatomy are in perfect accordance with the observations in comparative anatomy made by Meckel and Weber, namely, that the development of the sympathetic system is in direct ratio with that of the cerebro-spinal system; that the former is more developed in man than in any other animal, and is proportionally larger in the fœtus than in the adult.

The sympathetic trunks of the right and left side generally anastomose below in front of the coccyx; it has been somewhat hastily affirmed that they anastomose above, either upon the pituitary body, or upon the anterior communicating artery of the brain; the true anastomoses of the two halves of the sympathetic system are in the central and median plexuses.

If, after having acquired this general idea of the trunks of the sympathetic, its neurilemma be removed by continued maceration in water, the connexions of the branches given from the spinal nerves to the ganglia, with the branches given from the ganglia to the viscera, may then be ascertained: it then becomes evident, that the greater number of the branches from the spinal nerves do not penetrate to the centre of the ganglia, but expand, as it were, upon their surface, and divide into two sets of filaments; of these, some are applied to the surface of a ganglion, and proceed directly to form the internal or visceral branches;* while the others assist in forming the cords of communication between one ganglion and another, and divide into ascending and descending filaments, of which the latter are the more numerous. They all run along the outer side of the cords of communication, and afterward become visceral branches themselves; it is doubtful whether any filament arises in the interior of a ganglion; the continuity of them all can be traced completely through these bodies.

It follows, therefore, that it is anatomically shown that the visceral nerves given off from the sympathetic are connected or belong to a very great number of spinal nerves at once, and always to spinal nerves much higher than that portion of the sympathetic from which the visceral branches are immediately given off; and again, that the visceral or splanchnic nerves, the actual origins of which we have seen to be so complicated and so remote from their apparent origins, always run a very long course before reaching their destination. Thus, the splanchnic nerves of the thorax or the cardiac nerves are derived from the cervical ganglia; the splanchnic nerves of the abdomen are given off, for the most part, by the thoracic ganglia; and most of the splanchnic nerves of the pelvis proceed from the lumbar ganglia. Nevertheless, the proper ganglia of each splanchnic cavity complete the visceral nerves belonging to that cavity. Thus, the first thoracic ganglion assists in the formation of the cardiac nerves; the superior lumbar ganglia in that of the visceral nerves of the abdomen; and the sacral ganglia in that of the pelvic nerves.

The visceral nerves sometimes pass directly to the viscera from the ganglia of the sympathetic, and sometimes indirectly, after being mingled and combined in plexuses.

There is no relation between the branches which enter and those which pass out of the several visceral plexuses, so that the branches which proceed from the ganglia and trunk of the sympathetic to those plexuses must be regarded, not as branches of formation, but as branches of communication.

The visceral plexuses are also formed in a very peculiar manner, not only by interlaced nerves, but by nerves and ganglia, and these nerves themselves present a ganglionic structure altogether different from the fasciculated and plexiform structure of other nerves.

There are four great visceral plexuses: the pharyngeal plexus, the cardiac plexus, the solar plexus, and the hypogastric plexus; the largest of all these is the solar plexus, which, both in an anatomical and in a physiological point of view, deserves the title of the *abdominal brain*, which was given to it by Wrisberg. These four great plexuses may also be very properly regarded as nervous centres, to which all the physiological and pathological phenomena of the nutritive system are singly or collectively referred.

These visceral plexuses differ as much from the ganglionic chain formed by the two trunks of the sympathetic as these trunks differ from the spinal cord itself: in these plexuses a sort of fusion is effected between the cerebro-spinal and the sympathetic systems, and also between the trunks of the sympathetic belonging to the two sides of the body.

The pneumogastric assists in the formation of three of these plexuses; namely, the pharyngeal, the cardiac, and the solar plexus. In man there is a tendency to fusion of the pneumogastric with the sympathetic, and in the lower animals this fusion is still more complete; it is in those animals in which the sympathetic is the least developed that the par vagum acquires its greatest development, and supplies the place of the former in reference to the intestinal canal.

The glosso-pharyngeal nerve also assists in the formation of the pharyngeal plexus, and the sacral nerves contribute to that of the hypogastric plexus.

The visceral plexuses differ essentially from those formed by the cerebro-spinal nerves. In the latter, the branches which emerge from the plexus are precisely the same branches that entered it, only combined in a different manner. However inextricable they may be, the plexuses of the spinal nerves are merely points in which a number of afferent branches converge and combine together. In the visceral plexuses, on the contrary, there is no relation, either in size or structure, between the afferent branches and the plexuses themselves.

* Some filaments from the spinal nerves are seen to cross at right angles over the anterior surface of the ganglia, and then to join the visceral nerves directly.

The nerves derived from the sympathetic system differ also in their mode of distribution from the nerves of the cerebro-spinal system. In general, they form a plexiform sheath around the vessels, and enter with them into the substance of organs. This arrangement has induced some anatomists to believe that the sympathetic nerves belong essentially and exclusively to the vascular system, and are lost upon the coats of the arteries; others hold an opposite opinion, and deny altogether that the sympathetic nerves enter the coats of those vessels. From some researches which I have made on this subject, I believe that there are proper filaments for the coats of the vessels, but that these are very few in number, and that by far the larger number of the nervous filaments are intended for the several organs. It is not uninteresting to remark, that the sympathetic nerves always accompany the arteries, and never the veins; the trunk of the vena portæ forming the only exception to this rule.

A *gray colour* and a *soft* texture are not, as is generally stated, the peculiar characteristics of the nerves of the sympathetic system; the gray colour is observed only in a portion of this system; and the softness, which only very rarely accompanies the gray colour, is confined to a very minute portion of it indeed.

There are gray cords, which are nothing more than prolonged ganglia, and are not nerves, properly so called; when examined they present no nervous structure, that is to say, they contain no white funiculi which can be decomposed into primitive filaments as fine as the silk fibre. Almost all the sympathetic nerves are of a white colour, which is sometimes concealed by an unusually thick neurilemma. The structure of the white nerves of the sympathetic system does not differ from that of the cerebro-spinal nerves; except that the funiculi of the former are smaller, and their arrangement is more decidedly plexiform.* Lastly, there are some mixed nerves, partly gray and partly white, which partake of the structural characters of both the gray and the white nerves.†

* See note, p. 840.

† I am much indebted to M. C. Bonamy, my private prosector, for the zeal and ability with which he has assisted me in the numerous dissections required for the compilation of this work.

SOURCES FROM WHICH THE ILLUSTRATIVE ENGRAVINGS HAVE BEEN TAKEN.

Figs. 1 to 7, 8†, 9 to 20, 24, 25, 28 to 30, 33, 34, 36, 38, 41 to 45, 47, 48†, 49 to 53, 57 (*Sue*).
Figs. 21 to 23, 37 (*Gordon*).
Figs. 26, 27, 35, 58† to 60†, 61 to 70, 71†, 72 to 84, 106 to 110, 111†, 112, 113, 114†, 115, 116† to 123†, 124 to 126, 127†, 128 to 133, 141†, 147†, 155, 161, 163†, 169†, 170, 171†, 191†, 192, 194, 195 (*Bourgery*).
Figs. 39, 40, 46†, 54 to 56 (*Cheselden*).
Figs. 85 to 94 (*Hunter*).
Fig. 95 (d.) (*Retzius*).
Fig. 97 (d.) (*Goodsir*).
Fig. 98 (*Serres*).
Figs. 99, 101, 102 (*Blake*).
Fig. 100 (*T. Bell*).
Figs. 103 (d.) to 105 (d.), 286 (*Cloquet*).
Figs. 136†, 138, 181 (*Morton*).
Fig. 140† (*Watts*).
Figs. 142, 173 to 175, 178, 231, 233, 234, 257 (*Sœmmering*).
Figs. 145, 160, 182, 187, 189, 220, 221, 223† (*Weber*).
Figs. 152, 153 (*Boyd*).
Figs. 154†, 198 to 206, 208 to 218 (*Tiedemann*).
Fig. 156 (No. 2) (*Krause*).
Fig. 156 (No. 2) (*Dœllinger*).
Figs. 157 to 159, 162 (*Boehm*).
Figs. 165 to 168 (*Kiernan*).
Fig. 172 (*Reisseissen*).
Fig. 180 (d.) (*Wagner*).
Fig. 183 (*A. Cooper*).
Fig. 185 (*Haller*).
Figs. 207, 232†, 235 to 240, 242 to 246, 248, 249, 251†, 252 to 256, 258 to 265, 266, 269 to 275, 284, 285, 296† to 301† (*Arnold*).
Fig. 219† (*Walter*).
Fig. 222† (*Caldani*).
Fig. 226 (*Harvey*).
Figs. 227, 228 (*Gurlt*)
Fig. 250 (*Brewster*).
Fig. 268 (*Cruveilhier*).
Figs. 281†, 283, 295 (*Mayo*).
Figs. 289†, 290† (*Swan*).
Fig. 302† (*Manec*).
Figs. 143 (d.), 144 (d.), 164* (d.), 179 (d.), 193†, 197, 241 (d.), 276 to 280, 282 (*Models, Casts, and Diagrams in the Museum of Anatomy, University College*).
Figs. 31, 32, 96, 98* (d.), 134 (d.), 135 (d.), 137 (d.), 139 (d.), 146 (d.), 148 (d.), 149 (d.) to 151 (d.), 156 (No. 1, d.), 164, 176 (d.) to 178 (d.), 184 (d.), 186 (d.), 190 (d.), 196 (d.), 218* (d.), 224 (d.), 225 (d.), 229 (d.), 230 (d.), 247 (d.), 267 (d.), 287 (d.), 288 (d.), 291 (d.) to 293 (d.) (*Original*).

The mark (†), affixed to the number of a figure, indicates that such figure differs in some respects from the original. The letter (d.), similarly affixed, signifies that the figure is intended as a *diagram* or *plan*. The asterisk (*), used occasionally, serves to distinguish between two figures bearing the same number.

INDEX.

Abdomen, aponeurosis of, anterior, 300.
——————— posterior, 305.
——————— superficial, 297.
——-—— regions of, 352.
Abducens, nerve. See *Nerve, Motor Ocul.*
Abductor muscles. See *Muscles.*
Accessory ligaments. See *Ligaments.*
——————— nerves. See *Nerves.*
Acetabulum, 88.
Acini of glands. See those glands.
Acromion process, 76.
Adductor muscles. See *Muscles.*
Adipose tissue, 175.
Alæ of sphenoid bone, lesser, 37.
——————————— greater, 37.
—— vespertilionis, 475.
Alimentary canal, 322.
——————————— appendages of, 384.
——————————— coats of, 322.
——————————— direction and situation of, 323.
——————————— divisions of, 322.
——————————— dimensions of, 323.
——————————— form of, 323.
——————————— membranes of, 323.
——————————— muscular fibres of, 323.
——————————— structure of, 323.
Alveoli, 53, 58.
Amphiarthroses, 113.
——————————— characters, ligaments, and motions, 113.
Ampullæ of semicircular canals, 677.
Amygdalæ, 333. See *Tonsils.*
Amygdaloid fossa, 331.
Anastomoses of arteries, 496.
——————————— lymphatics, 614.
——————————— nerves, 762.
——————————— veins, 574.
Anastomotic artery, brachial, 544.
——————————— femoral, 565.
Anatomy, objects and divisions of, 1, 2.
——————— descriptive, 1.
——————— general, 1, 2.
Anfractuosities. See *Cerebrum.*
Angeiology, 479.
Angle, sacro-vertebral, 26.
——— of the femur, 93.
——— facial, of Camper, 45.
——— occipital, of Daubenton, 45.
——— of the jaw, 58.
——————————— changes during growth, 59.
——— of the pubes, 89.
Angles of bones, 9.
Ankle joint, 168.
——————————— ligaments of, 169.
Ankle. See *Tarsus.*
Annular ligaments. See *Ligaments.*
Anti-helix, and its fossa, 666.
—— tragus, 666.
Antrum Highmori, 52.
——————— pylori, 355.
Anus, 380.
——— muscles of, 380.
——— structure of, 380.
Aorta. See *Arteries.*
Aponeurology, 294.
Aponeuroses in general, 294.
——————————— classification of, 294.
——————————— containing, 294.
——————————— definition of, 294.
——————————— functions of, 296.
——————————— insertion of, 294.
——————————— structure of, 296.
——————————— tensor muscles of, 295.
Aponeuroses in particular, 297.
——————————— abdominal anterior, 300.
——————————————————— layers of, 301.
——————————————————— posterior, 305.
——————————————————— superficial, 297.
——————————— brachial, 316.
——————————— buccinator, 298.
——————————— buccinato-pharyngeal, 235.
——————————— cervical, deep, 299.
Aponeuroses, cervical, superficial, 299.
——————————— cephalo-pharyngeal, 346.
——————————— costo-clavicular, 137.
——————————— of the cranium, 299.
——————————— cremasteric, 302.
——————————— cribriform, 309.
——————————— deltoid, 315.
——————————— dorsal of the foot, 314.
——————————————————— metacarpus, 318.
——————————————————— interosseous, of foot, 314.
——————————————————— hand, 318.
——————————— epicranial, 298.
——————————— external oblique, 301.
——————————— of the eyelids, 647.
——————————————————— face, 299.
——————————— femoral, 309.
——————————————————— septa of, 310.
——————————————————— sheath for vessels, 310.
——————————————————— muscles, 311.
——————————— of the fore-arm, 316.
——————————— gluteal, 311.
——————————— hypothenar, 319.
——————————— iliac, 306.
——————————— infra-spinous, 315.
——————————— intercostal, 360.
——————————— inter-muscular of thigh, 310.
——————————— of internal oblique, 304.
——————————— of the leg, 312.
——————————————————— lower extremity, 309.
——————————————————— superficial, 297.
——————————— lumbar, or posterior abdominal, 306.
——————————— lumbo-iliac, 306.
——————————— masseteric, 298.
——————————— of the neck, 299.
——————————— obturator, 309.
——————————— occipito-frontal, 298.
——————————— occipito-pharyngeal, 346.
——————————— palmar, 319.
——————————— parotid, 298.
——————————— pedal, 314.
——————————— pelvic lateral, 308.
——————————————————— superior, 308.
——————————— of the pelvis, 306.
——————————————————— proper, 307.
——————————— perinæal, deep, 307.
——————————————————— superficial, 306.
——————————— petro-pharyngeal, 346.
——————————— of the pharynx, 346.
——————————— plantar, external, 314.
——————————————————— internal, 314.
——————————————————— interosseous, 315.
——————————————————— middle, 314.
——————————— prævertebral, 299.
——————————— of the quadratus lumborum, 306.
——————————— recto-vesical, 308.
——————————— of the serratus posticus, 300.
——————————————————— shoulder. 315.
——————————————————— spermatic cord, 304.
——————————— sub-peritoneal, 305.
——————————— sub-scapular, 315.
——————————— superficial, 297.
——————————————————— of abdomen, 297.
——————————— supra-clavicular, 299.
——————————— supra-spinous, 315.
——————————— temporal, 298.
——————————— thenar, 319.
——————————— of the thorax, 300.
——————————— of transversalis, 305.
——————————— of the upper extremity, 316.
——————————————————— superficial, 297.
——————————— of velum palati, 346.
——————————— vertebral, 205.
——————————— vesical, 309.
Aponeurotic sheaths for muscles, 296
——————————————————— tendons, 296.
——————————————————— vessels, 296.
Apparatus, hyoid, 109.
Apparatuses of human body, general view of, 3, 4.
Appendices epiploicæ, 372.
Appendix, ensiform, or xiphoid, 65.
——————————— vermiformis, 373

Appendix, vermiformis, development of, 384.
——— structure of, 373.
Aqueductus Fallopii, 43, 839.
——— vestibuli, 44.
——— cochleæ, 44.
——— Sylvii, 719, 742.
Aqueous humour, 655.
——— membrane of, 655.
Arachnoid, 687.
——— canal (of Bichat), 687.
——— cranial portion of, 687.
——— internal, 691.
——— loose, 690.
——— membrane of eye, 656 (note).
——— spinal portion of, 690.
——— uses of, 692.
Arbor vitæ uterina, 465.
Arch, aortic, 502.
—— of colon, 374.
—— crural, 302.
—— femoral, 302.
—— gluteal, 311.
—— orbital, 36.
—— palatine, 329.
—— pubic, 89.
—— sub-pubic, 307.
—— zygomatic, 61.
Arches, alveolar, 174.
——— dental, 174.
——— zygomatic, 61.
Arm, bone of, 78.
——— compared with thigh bone, 107.
Arteries in general, 496.
——— anastomoses of, 496.
——— branches of, 497.
——— coat of, external or cellular, 498.
——— internal, 498.
——— middle, proper, or elastic, 498.
——— course or direction of, 496.
——— definition of, 496
——— division of, 496.
——— form of, 496.
——— nerves of, 497.
——— nomenclature of, 495.
——— origin of, 496.
——— preparation of, 497.
——— relations with other parts, 497.
——— retia mirabilia of, 496.
——— satellite muscles of, 497.
——— sheaths for, 499.
——— structure of, 499.
——— termination of, 498.
——— varieties of, 496.
——— vasa vasorum of, 499.
——— venæ comites of, 497.
——— vessels of, 499.
Artery or Arteries in particular, 497.
——— of particular organs or tissues. See those organs, &c.
——— acromial, descending, 542.
——— supra-scapular, 538.
——— transverse, 542.
——— acromio-thoracic, 542.
——— of ala nasi, 518.
——— alar thoracic, 542.
——— alveolar, 524.
——— anastomotic, brachial, 544.
——— great, of thigh, 564.
——— angular, of face, 517, 529.
——— aorta, 501.
——— abdominal, 503.
——— arch of, 502.
——— ascending, 503.
——— branches of, 503
——— descending, 502.
——— sinuses of, 501.
——— thoracic, 503.
——— valves of, 486.
——— arising from abdominal aorta, 506.
——— arch of aorta, 513.
——— varieties of, 513.
——— origin of aorta, 504.
——— termination of aorta, 552.
——— thoracic aorta, 505.
——— articular, of hip, 564.
——— knee, inferior, 565.
——— middle, or azygos, 565.
——— superior, 565.
——— ascending cervical, 538.
——— pharyngeal, 520.
Artery, auricular, anterior, 521.
——— posterior, 519.
——— axiliary, 531, 542.
——— axis, cœliac, 507.
——— thyroid, 535.
——— azygos, or middle articular of knee 565.
——— basilar, 534.
——— brachial, 543.
——— brachio-cephalic, 531.
——— bronchial, 505.
——— distribution of, 421.
——— buccal, 524.
——— of bulb, 558.
——— calcaneal, external, 570.
——— inferior, 571.
——— capsular, inferior, 513.
——— middle, 513.
——— superior, 513.
——— cardiac, 503.
——— carotid, common, left and right, 514.
——— general distribution of, 530.
——— external or facial, 515.
——— internal, 525.
——— superficial, 515.
——— carpal, radial, anterior, 546.
——— posterior dorsal, 546.
——— ulnar, anterior, 549.
——— posterior dorsal, 549.
——— central of retina, 527, 665.
——— cerebellar, inferior, anterior, 534.
——— posterior, 534.
——— superior, 535.
——— cerebral, anterior, 529.
——— communicating anterior, 529.
——— posterior, 529.
——— middle, 530.
——— posterior, 537.
——— cervical, ascending, 538.
——— deep, 540.
——— princeps, 519.
——— superficial, 539.
——— cervico-spinal, 538.
——— choroid, anterior, 530.
——— posterior, 536.
——— ciliary, anterior, 527.
——— middle, or long, 528.
——— posterior, or short, 528, 665.
——— circle of Willis, 536.
——— circumflex, femoral, external, 564.
——— internal, 563.
——— iliac, 560.
——— humeral, anterior, 543.
——— posterior, 543.
——— of clitoris, 558.
——— coccygeal, 552.
——— cœliac (axis), 507.
——— colic, left, 511.
——— right, 510.
——— collateral, of fingers, radial, 547.
——— ulnar, 549.
——— humeral, external, 543.
——— internal, 543.
——— of knee. See *Articular*.
——— of toes, from external plantar, 572.
——— internal plantar, 572.
——— comites. See *Satellite*.
——— communicating, cerebral, anterior, 529.
——— posterior, 529, 535.
——— palmar, 548.
——— plantar, 572.
——— of Willis, 529.
——— coronary of heart, left or anterior, 504.
——— right or posterior, 504.
——— lips, inferior, 517.
——— superior, 518.
——— stomach, 507.
——— of corpus callosum, 529.
——— cavernosum, 558.
——— cremasteric, 560.
——— crural, 560.
——— cystic, 508.
——— deep, brachial or humeral, 544.
——— cervical, 540.
——— femoral, 563.
——— temporal, 522.
——— deferential, 452.
——— dental, anterior, 524.
——— inferior, 523.
——— superior, 524.
——— diaphragmatic, inferior, 506.

Artery, diaphragmatic, superior, 539.
——— digital, collateral, radial, 547
——— ulnar, 549.
——— of foot, 572.
——— dorsal, carpal, radial, 547.
——— ulnar, 549.
——— of foot, 568.
——— index finger, 548.
——— metacarpal, radial, 547.
——— ulnar, 549.
——— metatarsal, 569.
——— of nose, 529.
——— penis, 558.
——— scapula, 538.
——— tarsus, 572.
——— thumb, 548.
——— toe, great, 572.
——— tongue, 518.
——— dorsi-spinal, of inferior intercostals, 507.
——— superior intercostals, 540
——— emulgent, 512.
——— epigastric, 559.
——— superficial, 562.
——— epiploic, 510.
——— ethmoidal, anterior, 528.
——— posterior, 528.
——— facial, 517.
——— femoral, 559.
——— deep, 563.
——— of fissure of Sylvius, 529.
——— of frænum linguæ, 519.
——— frontal, 528.
——— of temporal, 520.
——— gastric, inferior, 509.
——— superior, 509.
——— gastro-duodenal, 508.
——— epiploic, left, 509.
——— right, 508.
——— hepatic, 508.
——— gluteal, inferior, 556.
——— superior, 556.
——— hemorrhoidal, 557.
——— inferior, 557.
——— middle, 554.
——— superior, 511.
——— helicine, 456.
——— hepatic, 508.
——— in the liver, 391, 392.
——— humeral, 543.
——— deep, inferior, 544.
——— deep, superior, 544.
——— hyoid, of lingual, 518.
——— superior thyroid, 515 (note).
——— hypogastric, 553.
——— iliac, common, 552.
——— external, 559.
——— internal, 553.
——— general distribution of, 558.
——— ileo-colic, 511.
——— ilio-lumbar, 555.
——— incisory, inferior, 523.
——— superior, 524.
——— infra-orbital, 524.
——— or sub-scapular, 542.
——— spinous, 542.
——— innominate, 531.
——— intercostals, anterior, 540.
——— aortic or inferior, 505.
——— superior, 540.
——— interlobular, of liver, 391.
——— interosseous, dorsal, of foot, 569.
——— hand, 547.
——— of forearm, anterior, 548.
——— posterior, 549.
——— palmar, 547.
——— plantar, 572.
——— recurrent, of forearm, 549.
——— of the intestines, great, 511.
——— small, 510.
——— intra-spinal, 534.
——— ischiatic, 556.
——— of labia pudendi, 558.
——— labial, inferior, 517.
——— superior, 517.
——— lachrymal, 526.
——— laryngeal, inferior, 516.
——— superior, 516.
——— lingual, 518.
——— lumbar, 506.
——— magna pollicis, of foot, 572.
Artery, magna pollicis, of hand, 547.
——— malar cutaneous, 521.
——— malleolar, external, 567.
——— internal, 567.
——— mammary, external, 542.
——— internal, 539.
——— masseteric, 521, 523.
——— mastoid, 520.
——— posterior, 519.
——— maxillary, external, 517.
——— internal, 522.
——— general distribution of, 525.
——— of median nerve, 549.
——— mediastinal, 540.
——— medullary, 506.
——— meningeal, anterior, 528.
——— middle or great, 522.
——— of ascending pharyngeal, 520.
——— posterior, 519, 534.
——— small, 523.
——— mental, 523.
——— mesenteric, inferior, 511.
——— superior, 510.
——— metacarpal, radial, 546.
——— ulnar, 549.
——— metatarsal, 569.
——— muscular, of orbit, 528.
——— thigh, 562.
——— musculo-phrenic, 540.
——— for mylo-hyoideus, 523.
——— nasal, 528.
——— dorsal, 529.
——— lateral, 518.
——— of pterygo-palatine, 524.
——— of septum, 518.
——— nutritious, of femur, 542.
——— fibula, 570.
——— humerus, 545.
——— tibia, 569.
——— obturator, 554.
——— occipital, 519.
——— œsophageal, 505.
——— omphalo-mesenteric, 511.
——— ophthalmic, 525.
——— orbital, of temporal, 521.
——— ovarian, 512.
——— palatine, inferior, 517.
——— superior, 524.
——— palmar, deep, 546.
——— palmar, interosseous, 548.
——— superficial, 547.
——— recurrent, 547.
——— palpebral, inferior, 528.
——— superior, 528.
——— pancreatic, great (from splenic), 509.
——— small (from mesenteric), 510.
——— pancreatico-duodenal, 508.
——— parietal, 519, 521.
——— parotid, 520.
——— of penis, 558.
——— dorsal, 558.
——— perforating, of forearm, 549
——— palmar, 548.
——— peroneal, 570.
——— plantar, anterior and posterior, 569, 572.
——— of thigh, 564.
——— pericardiac, 495.
——— perinæal, superficial, 557.
——— transverse, 557.
——— peroneal, 570.
——— anterior, 570.
——— perforating, 570.
——— pharyngeal, ascending or inferior, 520.
——— pharyngo-meningeal, 520.
——— phrenic, inferior, 507.
——— superior, 539.
——— for phrenic nerve, 539.
——— plantar, external, 571.
——— internal, 571.
——— popliteal, 564
——— prævertebral, 520.
——— princeps cervicis, 519.
——— pollicis, 547.
——— profunda cervicis, 549.
——— femoris, 563.
——— humeri, inferior, 545.
——— superior, 544.
——— pterygoid, of facial, 517.
——— internal maxillary, 523.

Artery, pterygo-palatine, 524.
——— pudic, external inferior, 562.
——— superior, 562.
——— internal, 557.
——— in the female, 558.
——— pulmonary, 500.
——— left branch of, 501.
——— right branch of, 501.
——— distribution of, 421.
——— pyloric, inferior, 508.
——— superior, 508.
——— radial, 546.
——— collateral of fingers, 547.
——— recurrent, 546.
——— radialis indicis, 548.
——— radio-cubital, 549.
——— palmar, 547.
——— ranine, 518.
——— of receptaculum, 525.
——— recurrent interosseous, of forearm, 549.
——— palmar, 547.
——— radial, 546.
——— tibial, anterior, 568.
——— internal, 569.
——— ulnar, anterior, 549.
——— posterior, 549.
——— renal, 512.
——— distribution of, 439.
——— of retina, central, 527.
——— sacral, lateral inferior, 556.
——— superior, 556.
——— middle or anterior, 552.
——— satellite of median nerve, 549.
——— phrenic, 540.
——— sciatic, 556.
——— ulnar, 548.
——— scapular, inferior, 542.
——— posterior, 538.
——— superior, 538.
——— sciatic, 556.
——— for sciatic nerve, 556.
——— scrotal, 557.
——— of septum of nose, 518.
——— ventricles of heart, 504.
——— short, of stomach, 511.
——— sigmoid, 511.
——— spermatic, 511.
——— spheno-palatine, 524.
——— spinous, 522.
——— spinal, 534, 609.
——— anterior, 534.
——— general distribution of, 609.
——— posterior, 534.
——— re-enforcing, cervical, 534.
——— lumbar, 504.
——— thoracic, 504.
——— of spinal cord, 504, 534.
——— splenic, 509.
——— in spleen, 405.
——— for sterno-mastoid, 516, 519.
——— stylo-mastoid, 519.
——— sub-clavian, left and right, 531.
——— sub-diaphragmatic, 504.
——— sub-lingual, 518.
——— for sub-maxillary gland, 517.
——— sub-mental, 517.
——— sub-scapular, 542.
——— superciliary, 527.
——— superficial, of neck, 546.
——— palm, 547.
——— perineum, 556.
——— superficialis volæ, 547.
——— supra-orbital, 527.
——— renal, inferior, 512.
——— middle, 512.
——— superior, 512.
——— scapular, 538.
——— spinous, 538.
——— sural, 565.
——— tarsal, dorsal, or external, 568.
——— internal, 568.
——— temporal, 521.
——— deep anterior, 524.
——— middle, 521.
——— posterior, 523.
——— superficial, 521.
——— testicular, 511.
——— distribution of, 536.
——— thoracic acromial, 542.
——— alar, 542 (note).
Artery, thoracic humeral, or deltoid, of acromio-thoracic, 542.
——— inferior, 542.
——— long, 542.
——— thymic, 540.
——— thyroid axis, 537.
——— inferior, 537.
——— middle, 515.
——— of Neubauer, 537.
——— superior, 516.
——— tibial, anterior, 567.
——— posterior, 570.
——— recurrent, 567.
——— tibio-peroneal, 569.
——— tonsillar, 521.
——— transverse, of perineum, 556.
——— neck, 539.
——— face, 521.
——— shoulder, 538.
——— tympanic, 522.
——— ulnar, 548.
——— collateral, 543.
——— of fingers, 549.
——— recurrent, anterior, 549.
——— posterior, 549.
——— umbilical, 553.
——— uterine, 554.
——— vaginal, 554.
——— of liver, 392.
——— vasa brevia, of stomach, 509.
——— for vertebræ, 504.
——— vertebral, 533.
——— vesical, 553.
——— vidian, 524.
Arthrodia, 114.
——— characters, ligaments, and motions, 115
Arthrology, 111.
Articular surfaces, in general, 111.
——— of particular articulations. See those articulations.
——— borders, 112.
——— structure of, 177.
——— cartilages, 111.
——— structure of, 177.
——— cavities, 10.
——— supplementary, 128.
——— processes, or eminences, 10.
——— of vertebræ, 20, 22.
——— union of, 116.
Articular arteries. See *Arteries*.
——— nerves. See *Nerves*.
Articulations in general, 111–116.
——— amphiarthroses, 113.
——— arthrodia, 114.
——— classification of, 113.
——— condylarthrosis, 114.
——— definition of, 111.
——— diarthroses, 113.
——— enarthrosis, 114.
——— ginglymus, 114.
——— gomphosis, 114.
——— harmonia, 114.
——— immovable, 113.
——— meningoses, 113
——— mixed, 113.
——— movable, 112.
——— movements of, 113.
——— by mutual reception, 113.
——— schindylesis, 114.
——— sutures, 114.
——— symphyses, 114.
——— synarthroses, 114.
——— synchondroses, 113.
——— syneuroses, 113.
——— syssarcoses, 113.
——— trochlear, 114.
——— trochoid, 114.
Articulations in particular, 113.
——— acromio-clavicular, 135.
——— mechanism of, 136.
——— of ankle. See *Tibio-tarsal*.
——— astragalo-scaphoid, 171.
——— of astragalus with os calcis, 170.
——— movements of, 153.
——— atlanto-axoid, 117.
——— mechanism of, 124.
——— odontoid, 117.
——— of atlas and axis, 117.
——— articular processes of, 118.

Articulations, calcaneo-cuboid, 173.
——— carpal, in general, 147.
——— mechanism of, 148.
——— of each row, 147.
——— of two rows together, 147.
——— pisiform and cuneiform, 147.
——— carpo-metacarpal, in general, 149.
——— mechanism of, 150.
——— first, 149.
——— mechanism of, 150.
——— fifth, 150.
——— mechanism of, 150.
——— second, third, & fourth, 150.
——— carpo-metacarpal, of the thumb, 150.
——— mechanism of, 150.
——— chondro-costal, 132.
——— sternal, in general, 131.
——— in particular, 131.
——— movements of, 133.
——— coccygeal, 120.
——— condyloid, of occiput and atlas, 116.
——— coraco-clavicular, 135.
——— mechanism of, 136.
——— of the costal cartilages, 132.
——— movements of, 132.
——— costo-clavicular, 138.
——— mechanism of, 138.
——— costo-transverse, 131.
——— vertebral, 131.
——— in general, 131.
——— in particular, 131.
——— movements of, 131.
——— proper, 131.
——— of first rib, 131.
——— of eleventh and twelfth ribs, 131.
——— coxo-femoral, 159.
——— movements of, 161.
——— cranial, 124.
——— mechanism of, 125.
——— cranio-vertebral, 120.
——— mechanism of, 123.
——— crico-arytenoid, 426.
——— thyroid 426.
——— of the elbow, 143.
——— of the extremities, upper, 135.
——— lower, 153.
——— of the face, 126.
——— of the fingers, in general, 151.
——— of the head, with vertebral column. See *Cranio-vertebral.*
——— of the hip. See *Coxo-femoral.*
——— humero-cubital, 141.
——— movements of, 142.
——— of jaw, lower. See *Temporo-maxillary*, 128.
——— upper, 126.
——— with cranium, 126.
——— of the knee, 162.
——— mechanism of, 166.
——— of larynx, 425.
——— of metacarpal bones, carpal ends of, 148.
——— digital ends of, 149.
——— with carpus, 149.
——— metacarpo-phalangal, 151.
——— movements of, 152.
——— of metacarpus in general, 148.
——— of metatarsal bones, tarsal ends of, 175.
——— digital ends of, 175.
——— mechanism of, 175.
——— metatarso-phalangal, 175.
——— movements of, 177.
——— occipito-atlantoid, 116.
——— mechanism of, 122.
——— axoid, 117.
——— peroneo-tibial, inferior, 167.
——— middle, 168.
——— superior, 168.
——— mechanism of, 168.
——— of the pelvis, 154.
——— mechanism of, 156.
——— phalangal, of fingers, 153.
——— movements of, 153.
——— toes, 177.
——— movements of, 177.
——— pubic, 155.
——— radio-carpal, 145.
——— movements of, 145.
——— radio-cubital, 142.
Articulations, radio-cubital, mechanism of, 144.
——— inferior, 142.
——— movements of, 144.
——— middle, 143.
——— movements of, 143.
——— superior, 142.
——— movements of, 144.
——— sacro-coccygeal, 120.
——— iliac, 154.
——— sciatic, 155.
——— vertebral, 120.
——— scapulo-humeral, 138.
——— movements of, 139.
——— of the shoulder, 135.
——— sterno-clavicular, 136.
——— mechanism of, 137.
——— syndesmo-odontoid, 117.
——— tarsal, in general, 170.
——— mechanism of, 173.
——— of first row, 171.
——— of second row, 171.
——— movements of, 173.
——— of two rows together, 172.
——— movements of, 173.
——— tarso-metatarsal, in general, 174.
——— movements of, 173.
——— in particular, 173.
——— temporo-maxillary, 128.
——— mechanism of, 129.
——— of the thorax, 130.
——— mechanism of, 132.
——— movements of, 134.
——— thyro-hyoid, 425.
——— tibio-tarsal, 168.
——— mechanism of, 169, 170.
——— tracheo-cricoid, 426.
——— of the vertebral column, 115.
——— mechanism of, 121–123.
——— movements of, 122.
——— of the vertebræ with each other, 115.
——— bodies of, 115.
——— articular processes of, 116.
——— laminæ of, 116.
——— spinous processes of, 116.
——— peculiar, 116.
——— of the wrist, 145. See *Radio-carpal.*
Astragalus, 100.
Atlas, 23.
Auditory process, 44.
——— meatus, internal, 44.
——— external, 44.
——— nerve. See *Nerve, portio mollis.*
Auricle or auricula of ear, 666. See *Ear.*
Auricles of heart. See *Heart.*
Auricular surface of os coxæ, 91.
Axis (vertebra), 24.

Basilar process, 34.
——— groove, 35.
Bicipital groove, 78.
——— tuberosity, 81.
Bi-parietal suture, 46.
Biventer cervicis, 205.
——— maxillæ inferioris, 245.
Bladder, 440.
——— bas-fond of, 442.
——— coats of, 442.
——— development of, 443.
——— functions of, 444.
——— fundus, inferior, 442.
——— superior, or summit, 442.
——— ligaments of, anterior, 441.
——— posterior, 441.
——— sacculated and fasciculated, 444.
——— sphincter of, 443.
——— structure of, 443.
——— trigone of, 443.
——— uvula of, 443.
——— vessels and nerves, 444.
Bones in general, 5–18.
——— arteries of, three kinds, 14, 15.
——— asymmetrical, 8.
——— broad or flat, 9.
——— diploe of, 13.
——— ossification of, 17.
——— structure, internal, 13.
——— tables of, 13.
——— vitreous, 35.

Bones, cavities of, 9, 10.
——— articular, 10.
——— alveolar, 10.
——— cotyloid, 10.
——— glenoid, 10.
——— trochleæ, 10.
——— non-articular, 10.
——— canals or conduits, 10.
——— fossæ, 10.
——— furrows, grooves, or channels, 10.
——— notches, 10.
——— sinuses or cells, 10.
——— ossification of, 17.
——— changes in, after maturity, 18.
——— chemical composition of, 14.
——— description of, mode of, 11.
——— development of, 15.
——— cartilaginous stage, 15.
——— mucous stage, 15.
——— osseous stage, 16.
——— symmetry of, 17.
——— direction of, absolute and relative, 7.
——— eminences of, 9.
——— articular, 9.
——— condyles, 9.
——— heads and necks, 9.
——— non-articular, 9.
——— apophyses, 9.
——— epiphyses, 9.
——— marginal, 18.
——— lines and crests, 9.
——— mammillary processes, 9.
——— processes, 10.
——— prominences, 9.
——— spines or spinous processes, 9.
——— tuberosities, 9.
——— ossification of, 16.
——— foramina of, 11.
——— growth, mode of, 18.
——— long, 8.
——— extremities and shafts of, 9.
——— marrow or medulla of, 10.
——— medullary canal of, 10.
——— membrane of, 13.
——— structure of, internal, 10.
——— ossification of, 16.
——— nerves of, 14.
——— nomenclature of, 6.
——— number of, 6.
——— nutrition of, 18.
——— ossific points of, 16.
——— ossification of, 16, 17.
——— eminences and cavities of, 17.
——— three kinds of, 17.
——— regions of, 9.
——— shape and symmetry of, 8.
——— short, 9.
——— ossification of, 18.
——— structure, internal, of, 13.
——— situation of, general, 6.
——— size, weight, and density of, 7.
——— structure of, internal, 13.
——— microscopic, 11.
——— substance of, areolar, 11.
——— cancellated, or spongy, 11.
——— compact, 11.
——— reticulated, 11, 13.
——— surfaces, angles, and borders of, 8.
——— symmetrical, 8.
——— torsion of, 99.
——— veins and lymphatics of, 14.
Bones in particular, 18–111.
——— of arm, 78.
——— astragalus, 100.
——— atlas, 23.
——— development of, 31.
——— axis, 24.
——— development of, 31.
——— calcaneum, 100.
——— of carpus or wrist, 82.
——— development of, 84.
——— first row of, 83.
——— second row of, 83.
——— clavicle, 74.
——— development of, 75.
——— coccyx, 20.
——— development of, 31.
Bones, coronal, 35.
——— costæ. See *Ribs*.
——— of cranium, 33.
——— cubital, 79.
——— cuboid, 101.
——— cuneiform, carpal, 83.
——— tarsal, external, 102.
——— internal, 102.
——— middle, 102.
——— of ear, 673.
——— epactal, 50.
——— ethmoid, 40.
——— development of, 41.
——— of face, 51.
——— femur, 93.
——— development of, 95
——— fibula, 98.
——— development of, 99.
——— of fingers. See *Phalanges*.
——— of foot, 99.
——— of forearm, 79, 80.
——— frontal, 35.
——— development of, 36.
——— of hand, 82.
——— of haunch, 89.
——— humerus, 78.
——— development of, 79.
——— hyoid, 109.
——— development of, 111.
——— ilium, 89.
——— incus, 674.
——— ischium, 89.
——— of jaw, lower, 57.
——— upper, 51.
——— jugal, 54.
——— lachrymal, 56.
——— development of, 56.
——— of leg, 96.
——— lenticular, 674.
——— malar, 54.
——— development of, 55.
——— malleus, 673.
——— maxillary, inferior, 57.
——— development of, 58.
——— superior, 51.
——— development of, 53.
——— of metacarpus, 84.
——— development of, 85.
——— first, 85.
——— second, third, and fourth, 85.
——— fifth, 85.
——— of metatarsus, 103.
——— development of, 104.
——— first, 103.
——— second, third, and fourth, 103
——— fifth, 103.
——— nasal, 55.
——— development of, 56.
——— navicular, of carpus, 83.
——— tarsus, 101.
——— occipital, 33.
——— development of, 34.
——— orbicular, 674.
——— os calcis, 100.
——— carinæ, 33.
——— hyoides, 110.
——— innominatum, 89.
——— development of, 90.
——— magnum, 83.
——— planum, 40.
——— proræ, and os puppis, 33.
——— quadratum, 53.
——— unguis, 55.
——— ossa triquetra, or Wormiana, 50
——— ossicula auditûs, 673.
——— palate, 53.
——— development of, 54.
——— parietal, 41.
——— development of, 42.
——— patella, 95.
——— development of, 96.
——— of pelvis, 87.
——— perone. See *Fibula*.
——— phalanges of fingers, 86.
——— development of, 87.
——— toes, 104.
——— development of, 104.
——— pisiform, 83.
——— of pubes, 90.
——— radius, 81.

Bones, radius, development of, 82.
——— ribs, 67.
——————— development of, 68.
——————— false and true, 67.
——— rotula, 95.
——— sacrum, 26.
——————— development of, 32.
——— scaphoid of carpus, 83.
——————————— tarsus, 101.
——— scapula, 75.
——————— development of, 75.
——— semilunar, 83.
——— sesamoid, 96.
——————————— of foot, 176.
——————————— of gastrocnemius, 165.
——————————— of hand, 152.
——————————— of knee or patella, 96.
——— of shoulder, 73.
——— sphenoid, 36.
——————————— development of, 38.
——— spheno-occipital, 36.
——— spongy. See *Turbinated*.
——— sternum, 64.
——————————— development of, 65.
——— styloid, 43.
——— of tarsus, 99.
——————————— development of, 102.
——————————— first row of, 100.
——————————— second row of, 101.
——— temporal, 42.
——————————— development of, 44.
——————————— mastoid portion of, 43.
——————————— petrous portion of, 43.
——————————— squamous portion of, 43.
——— of thigh, 93.
——— of thorax, 64.
——— tibia, 96.
——————————— development of, 98.
——— of toes. See *Phalanges*.
——— trapezium, 83.
——— trapezoid, 83.
——— turbinated, ethmoidal, 41.
——————————— inferior, 56.
——————————— development of, 56.
——————————— middle, 41.
——————————— sphenoidal, 37.
——————————— superior, 41.
——— tympanic, 45.
——— ulna, 79.
——————————— development of, 81.
——— unciform, 83.
——— of vertebral column. See *Vertebra*, *Vertebræ*, and *Vertebral Column*.
——— vomer or ploughshare, 57.
——————————— development of, 57.
——— Wormian, 50.
——— zygomatic, 54.
Borsa appiattita, 706.
Brain. See *Cerebrum*, *Cerebellum*, *Isthmus*, and *Medulla Oblongata*.
Bronchi, 417.
——————— structure of, 420.
Bronchia or bronchial tubes, 418.
——————— relations of, with lobules, 418.
——————— structure of, 420.
Bronchial arteries, 420.
——————————— ultimate distribution, 420
——————— glands (lymphatic), 420.
——————— tubes, 418.
——————— veins, 420.
——————————— ultimate distribution, 420
——————— mucous membrane, 342.
——————————— characters of, 342.
Bucco-labial furrow, 326.
Bulbs of fornix, or corpora albicantia, 728.
Bulbus arteriosus, 494.
Bursa synovial of tendo Achillis, 283.
——————— of ligamentum patellæ, 164.
——————— over patella, 311.
Bursæ mucosæ (so called), 175.
——————— synovial, 175.
——————— around eyeball, 649.
——————— near shoulder joint, 142.
——————————— hip joint, 161.
——————————— knee joint, 164.
——————— sub-cutaneous, 630.
Calamus scriptorius, 703.
Calcaneum, 100.
Calcar, 736.
Canal, alimentary. See *Alimentary Canal*.
Canal, for anterior muscle of malleus, 672.
——— arachnoid, of Bichat, 978.
——— carotid, 43.
——— for chorda tympani, 672.
——— crural, 310.
——— dental, inferior, 59
——— of Fontana, 656.
——— godronné, 661.
——— hyaloid, 661.
——— incisive, 52.
——— infra-orbital, 51.
——— inguinal, 306.
——— for internal muscle of malleus, 43, 672.
——— of Jacobson, 671.
——— maxillary, superior, 51.
——————————— inferior, 60.
——— medullary of long bones, 13.
——— nasal, 653.
——— of Nuck, 465.
——— palatine, anterior, 52.
——————————— posterior, 54.
——— of Petit, 661.
——— pterygo-palatine, 38.
——— pterygoid, 38.
——— sacral, 27.
——— for tensor tympani muscle, 43, 671.
——— tympanic, 673.
——— vertebral, 30.
——— vidian, 38.
——— of Wirsung, 401.
——— zygomatic, 55.
Canals of bones, 12.
——— dental, superior, 51.
——— lachrymal, 652.
——— palatine, accessory, 54.
——— semicircular, 576. See *Semicircular Canals*.
Canine fossa, 51.
Canthi of eyelids, 647.
Capitula laryngis, 426.
Capitulum costæ, 68.
——————— ligaments. See *Ligament*
Capsule of Glisson, 478.
——————— lens, 663.
Capsules, synovial, 114.
——————— of particular joints. See those joints.
——————— supra-renal, 445. See *Supra-renal Capsules*.
——————— atrabiliary, 445.
Caput cœcum coli, 371.
——————— gallinaginis, 464.
Cardia, 442.
——————— nerves. See *Nerves*.
Carotid arteries. See *Arteries*.
——————— nerves. See *Nerves*.
Carpal arteries. See *Arteries*.
Carpus, bones of, 82.
——————— bones of first row of, 83.
——————————— compared with first row of tarsus, 108.
——————— second row of, 83.
——————————— compared with second row of tarsus, 108.
——————— compared with tarsus, 107.
——————— sheaths for tendons on, 316.
Cartilage, chemical composition of, 174.
——————— cricoid, 423.
——————— of ear, 666.
——————— ensiform, 65.
——————— structure of, 174.
——————— thyroid, 423.
——————— xiphoid, 65.
Cartilages, articular, 111.
——————————— characters of, 111.
——————————— structure of, 174.
——————————— chemical composition of, 174.
——————— arytenoid, 424.
——————— costal, 69.
——————————— articulations of, 133.
——————— falciform, of knee, 162.
——————— inter-articular, 112.
——————————— structure of, 174.
——————————— temporo-maxillary, 128.
——————————— acromio-clavicular, 136.
——————————— sterno-clavicular, 137.
——————————— of wrist, 143.
——————————— of knee joint, 162.
——————— inter-osseous, 112.
——————————— structure of, 174.
——————— of larynx, 423.
——————————— ossification of, 435.
——————— of nose. See *Nose*.

Cartilages, semilunar, of knee, 162.
——— tarsal, of eyelids, 647.
Caruncula lachrymalis, 647.
Carunculæ myrtiformes, 468.
Cauda equina, 770.
Caudal extremity of helix and antihelix, 667.
Cavernous body. See *Corpus Cavernosum*.
Cavity, coronoid, 80.
——— cotyloid, 88.
——— digital or ancyroid, 947.
——— glenoid, of scapula, 76.
——— ——— ——— temporal bone, 43.
——— olecranoid, 80.
——— of omentum, 478.
——— sigmoid, great and lesser, 81.
——— supplementary, of temporo-maxillary articulation, 128.
——— of shoulder joint, 139.
——— trochanteric, 95.
Cavities, articular, 10.
——— supplementary, 128.
——— orbital, 62.
——— glenoid, of tibia, 97.
——— non-articular, 11.
Cells of bones, 11.
——— ethmoidal, 42.
——— frontal, 36.
——— sphenoidal, 39.
Cellular tissue, 298.
——— lymphatics of, 613.
Central foramen of retina, 661.
Centrum ovale minus, 736.
——— of Vieussens, 736, 752.
——— semicirculare geminum, 746.
Cerebellar arteries. See *Arteries*.
——— veins. See *Veins*.
Cerebellum, 715.
——— arbor vitæ, lateral and median, 721.
——— commissures of, 723.
——— comparative anatomy, 724.
——— corpus callosum of, 711.
——— dentatum or rhomboideum, 721.
——— development of, 724.
——— falx of, 684.
——— fasciculi, converging and diverging, 724.
——— fibres of, formative and uniting, 724.
——— fissure of, median, 717.
——— furrows of, 717.
——— Gall's views of, 724.
——— ganglia of, 721.
——— general view of, 724.
——— internal structure of, 718.
——— examined by hardening, 722.
——— sections, 721.
——— water, 722.
——— laminæ and lamellæ of, 717.
——— structure of, 722 (note).
——— lobe, sub-peduncular, 718.
——— lobes, lateral and median, 717.
——— lobule of circumference, 718.
——— medulla oblongata, 718.
——— pneumogastric nerve, 718.
——— lobules or segments, 717.
——— medullary centre of, 722.
——— peduncles of inferior, 704, 722.
——— middle, 710, 722.
——— superior, 711, 722.
——— sections of, 720.
——— horizontal, 722.
——— vertical, 721.
——— size and weight of, 716.
——— substances, gray, white, and yellow, 721.
——— surface, upper, 716.
——— lower, 717.
——— tentorium of, 684.
——— ventricle of. See *Ventricle, fourth*.
Cerebral arteries. See *Arteries*.
——— nerves. See *Nerves, cranial*.
——— peduncles, substance, &c. See *Cerebrum*.
——— veins. See *Veins*.
Cerebro-spinal axis, 681.
——— divisions of, 682.
——— membranes of, 682. See *Arachnoid*, *Dura Mater*, and *Pia Mater*.
Cerebrum, 725.
——— anfractuosities or sulci, 732.
——— of digital cavity, 733.
——— inferior surface, 733.
——— internal surface, 734.
——— superior surface, 734.
Cerebrum, anfractuosities, uses of, 735.
——— arbor vitæ of, 750.
——— base of, 727.
——— lateral regions, 731.
——— median excavation of, 727.
——— region, 727.
——— commissures, 753. See *Commissure*.
——— comparative anatomy of, 757.
——— convolutions or gyri, 732.
——— of digital cavity, 733.
——— inferior surface, 733.
——— superior surface, 734.
——— internal surface, 733.
——— structure of, 755.
——— uses of, 734.
——— Gall's views of, 754.
——— crura of, 723.
——— development of, 756.
——— falx of, 684.
——— fibres of, formative or diverging, 752.
——— radiating, 754.
——— uniting or converging, 752.
——— general idea of, 754.
——— fissure, longitudinal, 726.
——— Sylvian, 727.
——— transverse, great, 727.
——— ganglia of, 752.
——— hemispheres of, 726.
——— nucleus of, 749.
——— internal structure of, 735.
——— examined by hardening, 750.
——— sections of, 736.
——— water, 750.
——— Foville's views of, 755.
——— Gall's views of, 751.
——— general idea of, 753.
——— Mayo's views of, 754.
——— Rolando's views of, 755.
——— lobes of, 731 (note), 735.
——— medullary centres of, 737.
——— peduncles of, 710.
——— transverse fibres of, 711.
——— course of, in brain, 753.
——— structure of, 713.
——— section, vertical median, 748.
——— Willis's, 750.
——— sections of horizontal, 736.
——— vertical, transverse, 750.
——— general remarks on, 751.
——— size and weight, 725.
——— compared to that of cerebellum, 725.
——— substance, gray or cortical, 702 (note).
——— white or medullary, 702 (note).
——— surface, inferior, or base, 727.
——— superior, or convex, 727.
——— unfolding of, by Gall, 753.
——— ventricles of, 753. See *Ventricle*.
Cervical arteries. See *Arteries*
——— ganglia. See *Ganglion*.
——— nerves. See *Nerves*.
——— plexuses. See *Plexuses*.
——— vertebræ. See *Vertebra* and *Vertebræ*.
Cervix uteri, 465.
Cheeks, 328.
——— development of, 328.
——— muscles of, 328.
——— structure of, 328.
——— vessels of, 328.
Chemical composition of tissues, &c. See those tissues, &c.
Chiasma, optic, 728, 819.
Chorda tympani nerve, 836.
——— canal for, 672.
Chordæ tendineæ, 483.
——— vocales, 426.
——— inferior or true, 427.
——— superior or false, 427.
Chorion, 631.
Choroid coat of eye, 657.
——— structure of, 657.
——— pigment, 659.
——— plexuses, 747. See *Plexuses*.
——— veins of brain, 586.
——— eye, 657.
Ciliary body, crown, or disc, 656.
——— canal, 656.
——— circle, ligament, or ring, 656.
——— processes of the choroid coat, 656.
——— zone of Zinn, 657.

Circle of Willis, 727.
Circular sinus of Ridley, 587.
Circumflex arteries. See *Arteries.*
——— veins. See *Veins.*
Clavicle, 74.
Clitoris, 471.
——— artery of, 558.
——— crura, glans and prepuce of, 471.
——— ligaments and muscles of, 471.
——— nerve of, 807.
Cochlea, 677.
——— aqueduct of, 679.
——— axis, columella, or modiolus of, 678.
——— lamina gyrorum, or tube of, 678.
——— spiralis of, membranous and osseous, 678.
——— nerves of, 681.
——— scalæ of, tympanic and vestibular, 677.
Cochleariform process, 44.
Coccygeal vertebræ, 18, 27.
Coccyx, 27.
Cæcal appendix, 373.
Cæcum, 371.
——— appendix vermiformis of, 373.
——— development of, 383.
——— internal surface, 373.
——— structure, 378.
Collateral arteries. See *Arteries.*
——— nerves. See *Nerves.*
Colon, 373.
——— arch of, 374.
——— ascending, 374.
——— descending, 374.
——— development of, 384.
——— flexures of, iliac and sigmoid, 371.
——— internal surface of, 376.
——— longitudinal bands of, 374.
——— lumbar, left and right, 374.
——— structure of, 378.
——— transverse, 375.
Columella of cochlea, 708.
——— valve of Vieussens, 712.
Columnæ carneæ, 483.
——— of rectum, 377.
Columns, fronto-nasal, 127.
——— zygomato-jugal, 127.
——— jugal, 127.
——— pterygoid, 127.
——— of face, 127.
——— of vagina, 469.
——— of spinal cord. See *Spinal Cord.*
Comites, arteriæ. See *Arteries, satellite.*
——— nervi. See *Nerves, satellite.*
——— venæ, 572.
Commissura mollis, 740.
Commissure, anterior, of brain, 741.
——— antero-posterior, 753.
——— external and internal, of eyelids, 647.
——— great transverse, of brain, 735.
——— of lips, 326.
——— longitudinal, of brain, or fornix, 737.
——— optic, 729.
——— of pineal body, 742.
——— posterior, of brain, 742.
——— soft or gray, 741.
——— of spinal cord, anterior, 698.
——— gray and white, 699.
——— at Sylvian fissure, 746.
Commissures of brain, 742. See *Commissure.*
Common mass of posterior spinal muscles, 201.
Communicating arteries. See *Arteries.*
——— nerves. See *Nerves.*
Comparison of arm-bone with thigh-bone, 105.
——— arteries of upper and lower extremities, 572.
——— bones of upper and lower extremities, 105.
——— carpus and tarsus, 107.
——— development of upper and lower extremities, 109.
——— enamel and ivory of teeth, 183.
——— first rows of carpus and tarsus, 108.
——— hand and foot, 107.
——— leg with forearm, 105.
——— lower parts of radius and tibia, 107.
——— metacarpus and metatarsus, 108.
——— nerves of upper and lower extremities, 815.
——— permanent and temporary teeth, 187.
——— phalanges of fingers and toes, 109.
Comparison of second rows of carpus and tarsus, 108.
——— shoulder with pelvis, 105.
——— teeth and bones, 177.
——— epidermoid appendages, 177
——— upper and lower molar teeth, 181.
——— upper parts of ulna and tibia, 107.
Compressor muscles. See *Muscles.*
Conarium, 742.
Concha of ear, 666.
——— tragic fossa of, 668.
——— nose, inferior, 56.
——— middle, 41.
——— superior, 41.
Conchæ, ethmoidal, 41.
Condylarthrosis, characters, &c., 114.
Condyle, 10.
——— humeral, 78.
Condyles, occipital, 34.
——— of lower jaw, 58.
——— femur, 95.
——— tibia, 97.
Condyloid foramen, anterior, 34.
——— posterior, 34.
——— fossæ, 34.
Confluences of the sinuses, 588.
Coni vasculosi testis, 452.
Conjunctiva, 648.
Constrictor muscles. See *Muscles.*
Conus arteriosus, 481.
Convolutions of brain. See *Cerebrum.*
——— small intestines, 364.
Coracoid process, 76.
Cordiform tendon of diaphragm, 212.
Cornea, opaque, 655.
——— transparent, 655.
Cornicula laryngis, 424.
Cornu Ammonis, 745.
Cornua of hyoid bone, 109.
——— lateral ventricle. See *Ventricle.*
——— styloid, 109.
——— thyroid cartilage, 424.
Corona ciliaris, 656.
——— radians of Reil, 755.
——— of glans penis, 461.
Coronal bone, 35.
Coronary arteries. See *Arteries.*
——— ligaments. See *Ligaments.*
——— veins. See *Veins.*
Coronoid cavity, 80.
——— process of lower jaw, 58.
——— ulna, 80.
Corpora albicantia, 728.
——— structure of, 738.
——— Arantii, 486.
——— bigemina, 712.
——— lutea, 462.
——— mammillaria, 728.
——— olivaria, or ovata, 706.
——— quadrigemina, 712.
——— restiformia, 707.
Corpus bulbosum, 461.
——— artery of, 558.
——— nerve of, 806.
——— callosum, artery of, 529.
——— bourrelet or cushion of, 731.
——— of cerebellum, 711.
——— extremity, anterior, 737.
——— posterior, 731.
——— genu or knee, 737.
——— peduncles of, 730.
——— reflected portion, anterior, 730.
——— rostrum or beak, 737.
——— convolution of, 733.
——— ventricle of, 737.
——— longitudinal tracts of, 737.
——— fibres of, 753.
——— cavernosum penis, 455.
——— crura of, 455.
——— nerves, 456.
——— structure, 455.
——— vessels, 456.
——— dentatum cerebelli, 721.
——— medullæ, 705.
——— fimbriatum, 739.
——— uteri, 464.
——— geniculatum externum, 728.
——— internum, 712.
——— Highmori, 450.
——— luteum, 462.
——— mucosum of skin, 635.

Corpus papillare of skin, 632.
——— psalloides, 738.
——— reticulare of skin, 635.
——— spongiosum urethræ, 460.
——— striatum, 744.
——— ——— fibres of, 753.
——— ——— lobule of, 731.
——— ——— vein of, 745.
Costal cartilages, 69.
Costæ, 67. See *Ribs.*
——— of scapula, 76.
Cotyloid cavity, 88.
——— cavities in general, 11.
Crania, national, 44.
Cranial nerves, in general. See *Nerves.*
——— in particular. See *Nerves.*
——— ganglia. See *Ganglia.*
——— arachnoid. See *Arachnoid.*
——— dura mater. See *Dura Mater.*
Cranium, aponeuroses of, 299.
——— area of, 45.
——— articulations of, 125.
——— base of, exterior of, 45.
——— interior of, 46.
——— bones of, 34.
——— circulation of, arterial, 531.
——— ——— venous, 562.
——— development of, 50.
——— external surface of, 45.
——— lymphatic system of, 627.
——— in general, 45.
——— internal surface of, 46.
——— mechanism of, 126.
——— regions of, 45.
——— sutures of, in general, 154.
——— particular. See *Sutures.*
——— varieties of, 45.
——— vault of, 45.
Crest of ilium, 89.
——— pubes, 89.
——— tibia, 97.
——— urethra, 459.
Crests, occipital, 35.
Cribriform plate of ethmoid bone, 40.
Crista galli, 40.
——— ilii, 89.
——— vestibuli, 676.
Crura of clitoris, 471.
——— corpus cavernosum, 455.
——— diaphragm, 212.
——— cerebri, 711.
Crural arch, 309.
——— ring, 310.
——— septum, 310.
Crust of cerebral peduncles, 713 (note).
Crusta petrosa, 182.
Crypts of Lieberkuhn, 369.
Cuneiform bone of carpus, 83.
Cutaneous nerves. See *Nerves.*
Cuticle, 633.
Cutis, or cutis vera, 631.
——— anserina, 630.
Cystic duct, 397.
Cystis fellea, 396.

Dartos, 446.
——— tissue of, 446 (note).
Deltoid impression, 78.
Dental arteries. See *Arteries.*
——— canal, inferior, 57.
——— canals, superior, 51.
——— nerves. See *Nerves.*
——— veins. See *Veins.*
Dentata (vertebra), 24.
Dentes. See *Teeth.*
Depressor muscles. See *Muscles.*
Development of particular bones, organs, or parts of body. See those bones, organs, &c.
Diaphragm, 212.
Diarthroses, 114.
Digastric fossa, 43.
——— groove, 43.
Digestive apparatus, general view of, 3.
Digital arteries. See *Arteries.*
——— nerves. See *Nerves.*
Diploe, 14.
Diploic canals, 591.
——— veins, 585, 591.
Dissection of different parts. See those parts.
Dorsal arteries. See *Arteries.*
Dorsal ligaments. See *Ligaments.*
——— nerves. See *Nerves.*
——— veins. See *Veins.*
——— vertebræ. See *Vertebra* and *Vertebræ.*
Dorsum ilii, or external iliac fossa, 88.
——— linguæ, 337.
——— manus, 82.
——— nasi, 641.
——— pedis, 99.
Duct, common biliary, 398.
——— ——— internal surface, 399.
——— ——— structure, 399.
——— cystic, 397.
——— structure, 399.
——— ejaculatory, 452.
——— hepatic, 395.
——— internal surface, 399.
——— structure, 399.
——— lymphatic, right, 619.
——— nasal, 653.
——— pancreatic, 402.
——— parotid, 341.
——— Stenonian, 341.
——— thoracic, 618.
——— right, 619.
——— Warthonian, 342.
Ducts, biliary, 398.
——— lactiferous or galactophorous, 473.
——— prostatic, 458.
——— of Rivinus, 342.
Ductus arteriosus, 500.
——— communis choledochus, 398.
——— ejaculatorius, 452.
——— venosus, 600.
Duodenum, 361.
——— curvatures of, 362.
——— glands of, 370.
——— lymphatic glands of, 625.
——— structure of. See *Small Intestine.*
Dura mater, 682.
——— cranial portion of, 683.
——— cranial nerves of, 686.
——— sinuses of, 584.
——— structure of, 685.
——— uses of, 686.
——— vessels of, 686.
——— dissection of, 682.
——— spinal portion of, 686.
——— vessels of, 687.

Ear, auricle of, 666.
——— cartilage of, 666.
——— ligaments of, 667.
——— muscles of, extrinsic. See *Muscles, auricular.*
——— intrinsic, 668.
——— skin of, 668.
——— vessels and nerves, 668.
——— drum of. See *Tympanum.*
——— external. See *auricle* and *meatus of.*
——— general view of, 666.
——— internal, or labyrinth of. See *Labyrinth.*
——— meatus of external, 668.
——— cartilaginous and fibrous portion of, 668.
——— glands of, 669.
——— osseous portion of, 44.
——— skin of, 6.
——— internal, 44.
——— bottom of, 680.
——— middle. See *Tympanum.*
——— ossicula of, 673.
——— movements of, 674.
——— muscles belonging to, 674.
——— tympanum of. See *Tympanum.*
——— vessels of, 680.
Eighth cranial nerve. See *Nerves, glosso-pharyngeal, pneumogastric, and spinal accessory.*
Ejaculatory duct, 452.
Elastic tissue, structure of, 174.
——— chemical composition of, 174.
——— ligaments, general characters of, 112.
——— of vertebræ, 115.
Elbow-joint, 143.
Eminence, jugular, 34.
——— nasal, 35.
——— frontal, 35.
——— ilio-pectineal, 89.
——— hypothenar, 261.
——— thenar, 260.
——— unciform of lateral ventricle, 730.

Eminentia collateralis, 746.
Eminentiæ natiformes, 712.
——— testiformes, 712.
Enamel of teeth. See *Teeth.*
Enarthroses, 114.
Encephalic nerves. See *Nerves, cranial.*
Encephalon, arteries of, in general, 535.
——— isthmus of. See *Isthmus.*
Endo-cardium, 488.
—— lymph, 680.
Ensiform process, cartilage or appendix, 65.
Epactal bones, 50.
Epicondyle, 79.
Epidermis, 633.
Epididymis, 451.
——— globus major, 451.
——— minor, 451.
——— structure, 451.
Epigastric region, 352.
Epiglottis, 425.
Epiploon, 478. See *Omentum.*
Epithelium ciliated, 323.
——— columnar, 323.
——— squamous, 323.
——— of particular membranes. See those membranes.
Epitrochlea, 80.
Erectores muscles. See *Muscles.*
Ergot, 736.
Ethmoid bone, 40.
Ethmoidal bulb, 818.
——— cells or sinuses, 40.
——— fossa, 48.
——— groove, 40.
——— labyrinth, 40.
Eustachian tube, or trumpet, 672.
——— cartilaginous and fibrous portion, 672.
——— mucous membrane, 673 (note).
——— osseous portion, 44, 672.
Extensores muscles. See *Muscles.*
Extremities, lower, aponeuroses of, 306.
——— articulations of, 153.
——— arteries of, 557.
——— bones of, 87.
——— development of, 104.
——— lymphatic system of, 619.
——— nerves of, 797.
——— veins of, 603.
——— upper, aponeuroses of, 315.
——— arteries of, 531.
——— articulations of, 135.
——— bones of, 74.
——— development of, 87.
——— lymphatic system of, 628.
——— nerves of, 781.
——— veins of, 593.
——— upper and lower, arteries of, compared, 572.
——— bones of, compared, 105.
——— development of, compared, 109.
——— nerves of, compared, 815.
Eye, 645.
—— appendages of, 646.
—— brows, 646.
—— chamber of, anterior, 658.
——— posterior, 658.
—— globe of, 654.
—— humours of, aqueous, 664.
——— crystalline, 662.
——— vitreous, 661.
—— lashes, 646.
—— lids, 646.
——— cartilages of, 647.
——— commissures or canthi, 647.
——— glands, 648.
——— mucous membrane, 647.
——— muscles of, 647.
——— uses of, 647.
——— vessels and nerves, 648.
—— membranes of, 654.
——— of aqueous humour, 655.
——— arachnoid of, 656 (note).
——— capsule of lens, 662.
——— choroid coat, 656.
——— cornea, 655.
——— hyaloid, 661.
——— iris, 657.
——— Jacob's, 661.
——— pupillary, 659.
——— retina, 660.
Eye, membrane, Ruysch's, 659.
——— sclerotic coat, 654.
——— of vitreous humour, 661.
—— muscles of, oblique, 651.
——— recti, or straight, 651.
——— action of, 651.
—— nerve of. See *Nerve, optic.*
—— pigment of, 660.
—— vessels of, 665.

Face, area of, 46.
—— bones of, 51.
—— cavities of, 62.
—— circulation of, arterial, 530.
——— venous, 593.
—— development of, general, 63.
——— regions of, 63, 64.
—— in general, 60.
—— lymphatic system of, 626.
—— movements of, 238.
—— muscles of, 231.
—— regions of, 60.
Facial angle of Camper, 45.
——— nerve. See *Nerve, portio dura.*
Fallopian aqueduct, 43.
——— hiatus, 44.
——— ligament, 302.
——— tubes, 463.
——— fimbriæ of, 463.
——— structure and uses of, 463.
Falx of umbilical vein, 475.
——— cerebelli, 684.
——— cerebri, 684.
Fascia. See *Aponeurosis.*
——— cervical, 209.
——— cremasteric, 302.
——— cribriform, 309, 621.
——— dentata, 476.
——— iliac, 302.
——— infundibuliform, of cord, 302.
——— intercolumnar, of inguinal ring, 301.
——— lata, 309.
——— iliac portion, 310.
——— pubic portion, 311.
——— structure, 311.
——— obturator, 308.
——— propria (sub-peritoneal fascia), 303-305.
——— recto-vesical, 308.
——— spermatic, 304.
——— superficial, 297, 630.
——— tensor muscles of, 294.
——— transversalis, 305.
Fasciculi, muscular, 193.
——— of medulla. See *Medulla.*
Fauces, arches of, 330.
——— isthmus of, 330.
——— pillars of, 330.
Femur, 93.
Fenestra ovalis, 670.
——— rotunda, and its fossa, 671.
Fibres, muscular, involuntary, 324.
——— voluntary, 193.
——— nervous, 767.
Fibrous tissue, 298.
Fibro-cartilage of epiglottis, 425.
—— cartilages, 177.
——— of particular joints. See those joints.
Fibula, 98.
Fifth cranial nerve. See *Nerve, trifacial.*
Filaments, muscular, 193.
——— nervous, 767.
Fillet, 712.
Fimbriæ of Fallopian tubes, 463.
Fingers, 86.
——— phalanges of, 86.
——— and toes, phalanges of, compared, 120.
First cranial nerve. See *Nerve, olfactory.*
Fissure, Glasserian, 43.
——— glenoidal, 43.
——— incisive, 53.
——— orbital, 53.
——— pterygo-maxillary, 55.
——— spheno-maxillary, 39, 52, 55.
——— sphenoidal, 39.
——— Sylvian, 730.
Fissures of brain, liver, &c. See those organs.
Flexor muscles. See *Muscles.*
Flocculus, 718.
Fluid, ventricular, 744.
—— of Scarpa, 680.

Fluid, sub-arachnoid, 144.
Folds, aryteno-epiglottid, 433.
——— glosso-epiglottid, 336.
——— pharyngeo-epiglottid, 426.
Follicles, dental, 184.
——— ——— of Goodsir, 183.
——— intestinal. See *Intestines*.
——— Lieberkuhn's, 379.
——— sebaceous, 635.
——— solitary, 370.
——— of stomach, 360.
——— tubular, 360.
——— uterine, 471.
Fontanelles of scull, 49.
Foot, bones of, 99.
——— compared with hand, 106.
Foramen, of Bichat, 688.
——— of Botal, 486.
——— centrale of retina, 660.
——— cæcum of frontal bone, 36.
——— Morgagni (in tongue), 333.
——— medulla oblongata, 703.
——— condyloid, anterior, 34.
——— posterior, 34.
——— infra-orbitary, 59.
——— lacerum superius, 39.
——— posterius, 44, 47, 49.
——— anterius, 47.
——— magnum, 34.
——— mastoid, 43.
——— mental, 57.
——— of Monro, 740.
——— nutritious of humerus, 78.
——— ulna, 79.
——— radius, 81.
——— femur, 93.
——— tibia, 96.
——— fibula, 99.
——— obturator, 88.
——— occipital, 34.
——— optic, 37.
——— orbital, internal anterior, 36.
——— posterior, 36.
——— ovale of heart, 487.
——— sphenoid bone, 38.
——— parietal, 42.
——— rotundum, 38.
——— spheno-palatine, 54.
——— spheno-spinosum or spinosum, 38.
——— stylo-mastoid, 43.
——— superciliary, 36.
——— supra-orbitary, 36.
——— vertebral, 20, 21.
——— of Winslow, 476.
Foramina Thebesii, 488.
——— malar, 54.
——— of bones, 11.
——— inter-vertebral, 20, 30.
——— posterior, 775 (note).
——— sacral, 27.
Forearm, bones of, 79.
——— compared with leg, 105.
Fornix, 739.
——— bulbs of, 740.
——— pillars of anterior, 739.
——— posterior, 740.
Fossa, amygdaloid, 331.
——— canine, 51.
——— digastric, 43.
——— ethmoidal, 48.
——— iliac, external, 88.
——— internal, 88.
——— infra-spinous, 76.
——— ischio-rectal, 309.
——— jugular, 43.
——— lachrymal, 36.
——— mental, 58.
——— myrtiform, 49.
——— navicularis of urethra, 461.
——— vulva, 470.
——— ear, 670.
——— ovalis of heart, 488.
——— parietal, 43.
——— perineal, 309.
——— pituitary, 37, 48.
——— pterygoid, 38.
——— scaphoid. See *Navicularis*.
——— spheno-maxillary, 60.
——— sub-lingual, 57, 60.
——— sub-maxillary, 57, 60.
Fossa, sub-pyramidal, 671.
——— sub-scapular, 75.
——— supra-sphenoidal, 37.
——— supra-spinous, 76.
——— temporal, 47.
——— zygomatic, 60.
Fossæ of bones, 11.
——— condyloid, 34.
——— frontal, 36.
——— internal iliac, 91.
——— nasal, 62.
——— middle lateral, or spheno-temporal, 48.
——— occipital, 35.
Fourchette of sternum, 65.
——— vulva, 470.
Fourth cranial nerve. See *Nerve, pathetic*.
Fovea hemispherica, 676.
——— semi-elliptica, 676.
Frænum labii, 324.
——— linguæ, 336.
——— præputii, 455.
Frontal bone, 35.
——— cells or sinuses, 37.
——— eminence, 35.
——— fossæ, 36.
Fronto-jugal suture, 48.
——— maxillary suture, 59.
——— nasal suture, 59.
——— columns, 127.
——— parietal suture, 45, 47.
——— sphenoidal suture, 48.
Fundus of stomach, bladder, &c. See those organs.
Furrow, mylo-hyoidean, 57.
——— mento-labial, 326.
——— bucco-labial, 326.
Furrows of heart and spinal cord. See those organs.

Galactophorous ducts, 473.
Galea capitis, 208.
Gall-bladder, 396.
——— structure of, 397.
——— use of, 400.
Ganglia, lymphatic. See *Lymphatic Glands*.
Ganglia, nervous, in general. See *Nerves, ganglia of*.
Ganglia, nervous, in particular, 765.
——— abdominal, 865.
——— of brain, 753.
——— cervical, sympathetic. See *Ganglion*.
——— cranial, 765.
——— sympathetic, 854.
——— intercostal, 765.
——— lumbar, sympathetic, 868.
——— external and internal branches of, 869.
——— spinal or rachidian, 765.
——— splanchnic, 765.
——— sympathetic, 765.
——— connexions of, 766.
——— structure of, 768.
——— thoracic, 864.
——— external branches, 864.
——— internal branches, 864.
——— vertebral, 761.
Ganglion of Andersh, 843.
——— annulare (of eye), 831.
——— cardiac, 862.
——— carotid, 856.
——— of cerebellum, 722.
——— cervical, inferior, 859.
——— middle, 859.
——— superior, 855.
——— branches of, anterior, 857.
——— external, 858.
——— inferior, 858.
——— internal, 858.
——— superior, 856.
——— ciliary, 830.
——— Gasserian, 827.
——— of glosso-pharyngeal, 843.
——— impar, 871.
——— inter-carotid, 858.
——— lenticular, 830.
——— Meckel's, 831.
——— naso-palatine, 831.
——— ophthalmic, and branches, 830.
——— otic, and branches, 837.
——— petrosal, 843.
——— of pneumogastric, 845.
——— of Ribes, 857.
——— of root of hypoglossal, 823 (note).

Ganglion of root of spinal accessory, 823.
——— semilunar abdominal, 866.
——————— of fifth nerve, 827.
——— solar, 866.
——— spheno-palatine, and branches, 831.
——— sub-maxillary, 837.
——— thoracic, first, 859.
——— thyroid, 859.
Gasserian ganglion, 827.
Genial processes, 58.
Ginglymus, angular and lateral, 114.
Glabella, 35.
Gland, accessory, of parotid, 341.
——— epiglottid (so called), 430.
——— lachrymal, 652.
——— parotid, 340. See *Parotid Gland.*
——— pineal. See *Pineal Gland.*
——— pituitary, 729.
——— prostate, 459.
——————— structure, 459.
——— sub-lingual. See *Sub-lingual Glana.*
——— sub-maxillary, 342. See *Sub-maxillary Gland.*
——— thymus, 415.
——— thyroid, 433.
Glands, agminated, 370.
——— arytenoid, 433.
——— Brunner's, 370.
——— buccal, 329.
——— ceruminous, 669.
——— conglobate (lymphatic), 614.
——— Cowper's, 460.
——— duodenal, 370.
——— epiglottid, 430.
——— of Havers, 113.
——————— in knee, 163.
——— intestinal. See *Intestines.*
——— labial, 328.
——— laryngeal, 432.
——— lingual, 337.
——— lymphatic, in general, 616.
——————— particular. See *Lymphatic Glands.*
——— mammary, 472.
——— Meibomian, 648.
——— molar, 329.
——— odoriferous, of prepuce, 453.
——— œsophageal, 352.
——— of Pacchioni, 585, 685.
——— palatine, 329.
——— Peyer's, 370.
——— salivary, 340. See *Salivary Glands.*
——— solitary, 370.
——— sudoriferous, 633.
——— synovial (so called), 113.
——— of trachea, 416.
——— tubular, 360, 370.
——— Tyson's, 454.
——— of uterus, 467.
——— of Vesalius (bronchial), 625.
Glandula socia parotidis, 341.
Glans clitoridis, 471.
——— penis, 460.
——————— corona of, 460.
——————— structure of, 461.
Glasserian fissure, 43.
Globuli Arantii, 486.
Globus major, 451.
——— minor, 451.
Glomeruli, 437.
Glosso-epiglottid folds or ligaments, 430.
——— pharyngeal nerve. See *Nerve.*
Glenoid cavities in general, 11.
——— ligaments. See *Ligaments.*
Glottis, 430.
——— differences in size of, 435.
Gomphosis, 114.
Groove, basilar, 34.
——— bicipital, 78.
——— cuboid, 100.
——— dental primitive, 184.
——————— secondary, 184.
——— digastric, 43, 47.
——— ethmoidal, 40.
——— inferior petrosal, 49.
——— lachrymo-nasal, 51.
——— longitudinal, of cranium, 47.
——— mylo-hyoidean, 50.
——— obturator, 88.
——— optic, 37.
——— sub-pubic, 88.
Groove, superior petrosal, 44.
——— of torsion, of humerus, 78.
Grooves of bones, 12.
——— calcaneal, 100.
——— carotid, 37.
——— cavernous, 37.
——— for lateral sinuses, 34.
——— on back of radius, 81.
——— sacral, 92.
——— of spinal cord. See *Spinal Cord.*
——— vertebral, 29.
Gubernaculum dentis, 189.
——————— testis, 446.
Gula, 344.
Gulf of the internal jugular, 583.
Gums, 329.

Habenæ of pineal body, 742.
Hamular process of sphenoid bone, 37.
——————— cochlea, 678.
Hand, bones of, 82.
——— compared with foot, 107.
Hairs, description of, general, 638.
——— follicles of, 638.
——— structure and growth, 638 (note).
Harmonia, 114.
Harmonic sutures, 114.
Haunch bone, 89.
Heads of bones, 9.
——————— particular. See those bones.
Heart, 479.
——— auricles of, external surface, 482.
——————— interior of, 486.
——————— muscular fibres of, 490.
——————— musculi pectinati, 404.
——————— orifices of, 484.
——— auriculæ of, 482.
——————— interior of, 487.
——— bone in, 489.
——— cellular tissue, 493.
——— chordæ tendineæ, 483.
——— columnæ carneæ, 483.
——— conformation of, external, 480.
——————— internal, 482.
——— development of, 492.
——— fibrous framework of, 488.
——— foramen of Botal, 486.
——————— ovale, 486.
——————— remains of, 486.
——— foramina Thebesii, 487.
——— fossa ovalis, 486.
——— function, 492.
——— furrow, auriculo-ventricular, 481.
——————— inter-auricular, 482.
——————— ventricular, anterior and posterior, 481.
——— muscular fibres of, 488.
——————— structure of, 488.
——— nerves of, 492.
——— separation of, into right and left hearts, 490.
——— septum, inter-auricular, 482.
——————— ventricular, 481.
——— serous coat, external, 487.
——————— internal, 487.
——— sounds of, 493.
——— structure of, 487.
——— tubercle of Lower, 486.
——— valve, Eustachian, 486.
——————— mitral, 484.
——————— of Thebesius, 486.
——————— tricuspid or triglochin, 484.
——— valves of, auriculo-ventricular left, 484.
——————— right, 485.
——————— semilunar. See *Sigmoid.*
——————— sigmoid, aortic, 484.
——————— pulmonary, 484.
——— ventricles of, external surface, 480.
——————— interior of, 483.
——————— muscular fibres of, 488.
——————— musculi papillares, 484.
——————— orifices of, 483.
——— vessels of, 491.
——— zones, fibrous, of, 488.
Heel, bone of, 100.
Helicotrema, 679.
Helix, and its furrow or groove, 666.
——— cartilaginous process of, 667.
Hemorrhoidal arteries. See *Arteries.*
——————— nerves. See *Nerves.*
Hepatic artery, in the liver, 394, 395.

Hepatic duct, 395.
——— in the liver, 394, 395.
Hiatus Fallopii, 44.
Hilus of spleen, &c. See those organs.
Hip-joint, 159.
——— ligaments of, 160.
Horizontal plate of palate bone, 53.
Human body, general view of, 1–4.
Humerus, 78.
Humours of eye. See *Eye*.
Hymen, 469.
Hyoid bone or apparatus, 109.
Hypo-glossal nerve. See *Nerve*.

Ileo-cœcal valve, 372.
——— development of, 384.
——— structure of, 373.
——— uses of, 373.
—— colic valve, 372.
Ileum, 362.
——— structure of. See *Intestine, small*.
Iliac arteries. See *Arteries*.
—— flexure, 371.
—— fossa, external, 88.
——— internal, 88.
—— region, 352.
—— veins. See *Veins*.
Ilio-pectineal eminence, 89.
Ilium, 89.
Impression, deltoid, 78.
Incisive canal, 52.
——— fissure, 53.
Incisura tragica, 666.
Incus, 674.
Indented sutures, 115.
Infra-orbital canal, 51.
——— foramen, 59.
——— nerves. See *Nerves*.
—— spinous fossa, 76.
Infundibula of kidneys, 439.
Infundibulum of base of brain, 729.
——— cochlea, 678.
——— nasal fossa, 41, 62.
——— right ventricle of heart, 481.
Inguinal canal, 304.
——— ring, 303.
Insula of Reil, 745.
Integumentum, 713 (note).
Inter-articular cartilages. See *Cartilages*.
—— auricular furrow, 482.
——— septum, 482.
—— columnar fascia, 301.
—— condyloid notch, 95.
—— costal arteries. See *Arteries*.
——— nerves. See *Nerves*.
—— spaces, 71.
—— lobular fissures, spaces, and vessels of liver, 301.
——— of lungs, 414.
—— osseous arteries. See *Arteries*.
——— cartilages, 112.
——— ligaments. See *Ligaments*.
——— muscles. See *Muscles*.
——— nerves. See *Nerves*.
——— spaces of hand, 84.
——— foot, 106.
—— peduncular space, 711, 728.
—— spinous ligaments, 119.
—— trochanteric line, 94.
—— ventricular furrow, 480.
——— septum, 480.
—— vertebral foramina, 20, 30.
——— substance or disc, 115.
——— ligaments, 115.
Intestine, large, 370.
——— coats of, 378, 379.
——— development of, 383.
——— divisions of, 371.
——— follicles of, 379.
——— functions of, 382.
——— lymphatic glands and vessels, 379.
——— structure of, 378.
——— tubuli of, 379.
——— vessels and nerves of, 379.
Intestine, small, 361.
——— coats of, 366.
——— convolutions of, 364.
——— crypts of, 370.
——— development of, 383.
——— divisions of, 361.
——— follicles of, agminated, 369.
Intestine, small, follicles of, Lieberkuhn's, 370.
——— solitary, 369.
——— functions of, 370.
——— glands of, 366.
——— lymphatic glands of, 624.
——— lymphatics of, 624.
——— papillæ of, 367.
——— properly so called, 363.
——— structure of, 365.
——— tubuli of, 370.
——— valves of, 366.
——— vessels and nerves of, 370.
——— villi of, 367.
Intestines in general, 361.
——— development of, 383.
Intra-lobular veins of liver, 395 (note).
—— spinal veins. See *Veins*.
Iris, 657.
—— layers of, 659.
—— muscular fibres of, 658 (note).
—— structure, 658.
—— uses of, 659.
—— vessels and nerves of, 659.
Ischiadic notch, 89.
Ischio rectal fossæ, 308.
Ischium, 89.
Island of Reil, 745.
Isthmus faucium, 325.
——— ovalis (heart), 486.
——— of the encephalon, 710.
——— comparative anatomy, 715.
——— development of, 715.
——— divisions of, 710.
——— fasciculus of, triangular, 710–712.
——— furrow, lateral, of, 710.
——— internal structure of, 713.
——— lower stratum, 713.
——— middle stratum, 713.
——— upper stratum, 713.
——— sections of, 713.
Iter dentis, 188.
Ivory of teeth. See *Teeth*.

Jacob's membrane, 660.
——— structure of, 661.
Jaw, lower, 57.
——— articulations of, 128.
—— upper, bones of, 51.
——— articulations of, 126.
Jejunum, 362.
——— structure of. See *Small Intestine*.
Joints. See *Articulations*.
Jugal columns, 127.
—— bone, 54.
Jugular eminence, 34.
——— fossa, 43.
——— veins. See *Veins*.
——— internal, sinus of, 583.

Kidneys, 436.
——— acini, 438.
——— adipose capsule of, 437
——— calyces of, 439.
——— coat of, 437.
——— cortical substance of, 438.
——— development of, 440.
——— functions of, 440.
——— glomeruli, 437.
——— hilus or fissure, 436.
——— papillæ, 437.
——— pelvis of, 440.
——— pyramids of, Ferrein's, 437.
——— Malpighi's, 437.
——— tubes of, convoluted, 437.
——— straight, 437.
——— tubular portion, 438.
——— structure of, 438.
——— vessels and nerves, 438.
Knee-joint, arteries, ligaments, and nerves. See those parts.

Labia pudendi, 470.
Labyrinth, ethmoidal, 40.
——— fluids of, 679.
——— lining membrane of, 680.
——— membranous, 679.
——— osseous, 675. See *Cochlea*, *Semi-circular Canals*, and *Vestibule*.
Lacerated, foramen anterior, 47.
——— posterior, 44.

Lacerated, foramen superior, 39.
Lacerti teretes of heart, 483.
Lachrymal bone, 56.
——— canals, 651.
——— caruncula, 647.
——— gland, 651.
——— groove, or fossa, 36, 651.
——— papillæ, or tubercles, 645.
——— passages, 651.
——— mucous coat of, 654.
——— puncta, 652.
——— sac, 653.
Lachrymo-nasal groove, 51.
——— canal, 652.
Lacteals, 611.
——— of intestines, 612.
Lactiferous ducts, 473.
Lacuna magna, 460 (note).
Lacunæ of urethra, 460.
Lacus lachrymalis, 647.
Lambdoidal suture, 46.
Lamina cinerea, 730.
——— of cornea, 745.
——— cribrosa of ethmoid, 40.
——— of internal auditory meatus, 678, 680.
——— gyrorum, 677.
——— papyracea, 41.
——— spiralis, membranous and osseous, 677.
Laryngeal nerves. See *Nerves*.
Larynx, 422.
——— articulations of, 426.
——— cartilages of, 423.
——— ossification of, 435.
——— development of, 435
——— functions of, 435.
——— glottis, 430.
——— in general, 429.
——— ligaments of, 425.
——— mucous membrane and glands of, 475.
——— muscles of, 427.
——— sinus of, 434.
——— surface, external, 429.
——— internal, 430.
——— ventricle of, 427.
——— vessels and nerves, 435.
Leg, articulations of, 168.
—— bones of, 96.
—— compared with forearm, 105.
—— fascia of, 311.
Lemniscus, 711.
Lens. See *Crystalline Lens*.
Levator muscles. See *Muscles*.
Levers, three orders of, in body, 199.
Ligamenta-lata of uterus, 475.
——— subflava, general characters, 112.
——— of vertebral column, 115.
Ligaments in general, 112.
——— articular, 112.
——— capsular, 112.
——— interosseous, 112.
——— membranous, 112.
——— structure of, 174.
——— yellow or elastic, 112.
Ligaments in particular, 113.
——— accessory, of shoulder-joint, 139.
——— hip-joint, 160.
——— knee-joint, 165.
——— Weitbrecht, 144.
——— alar, of axis (or odontoid), 119.
——— of knee, 165.
——— of ankle-joint, lateral, anterior external, 169.
——— external proper, 169.
——— internal, 169.
——— posterior, 169.
——— annular, of radius, 142.
——— atlas, 117.
——— carpus, anterior, 318.
——— dorsal, 318.
——— tarsus, dorsal and lateral, 313.
——— aryteno-epiglottid, 426.
——— astragalo-calcaneal, interosseous, 171.
——— external, 171.
——— posterior, 171.
——— scaphoid, superior, 172.
——— atlanto-axoid, anterior, 117.
——— posterior, 117.
——— capsular, 117.
——— odontoid, transverse or annular, 117.
——— crucial, 117.
——— of auricle, anterior and posterior, 667.
Ligaments of auricle, intrinsic, 667.
——— of bladder, anterior, 308, 440.
——— posterior, 440, 475.
——— broad, of liver, 386.
——— uterus, 465.
——— calcaneo-cuboid, inferior, 173.
——— internal, 173.
——— superior, 172.
——— scaphoid, inferior, 172.
——— superior, 172.
——— of canthus, external, 647.
——— capsular, acromio-clavicular, 135.
——— atlanto-axoid, 119.
——— carpo-metacarpal of thumb, 150.
——— of little finger, 150.
——— hip-joint, 160.
——— knee-joint, 166.
——— occipito-atlantoid, 118.
——— axoid, 119.
——— scapulo-humeral, 137.
——— sterno-clavicular, 136.
——— of each row of carpal bones, 147.
——— two rows of carpal bones, 147.
——— carpo-metacarpal, dorsal, 150.
——— palmar, 150.
——— interosseous, with os magnum, 150.
——— of little finger, 150.
——— thumb, 150.
——— cervical, posterior, of quadrupeds, 117.
——— check, of axis (or odontoid), 119.
——— chondro-sternal, anterior, 131.
——— interosseous, 131.
——— posterior, 131.
——— superior and inferior, 131.
——— xiphoid, 131.
——— ciliary, 656.
——— conoid, 135.
——— coraco-acromial, 140.
——— clavicular, anterior, or trapezoid, 136
——— posterior, or conoid, 136
——— coraco-humeral, 139.
——— coracoid, 139.
——— costo-clavicular, 138.
——— coracoid, 139.
——— transverse, interosseous, 131.
——— posterior, 131.
——— superior, 131.
——— vertebral, anterior, 131.
——— inferior, 131.
——— interosseous, 131.
——— stellate, 131.
——— superior, 131.
——— cotyloid, of hip-joint, 159.
——— crico-arytenoid, 426.
——— thyroid, middle and lateral, 426
——— crucial, of atlas, 117.
——— knee-joint, 164.
——— of cuneiform bones of tarsus, 170.
——— and scaphoid, 171
——— third and cuboid, 171.
——— deltoid, 169.
——— dorsal, annular, of carpus, 318.
——— tarsus, 313.
——— carpo-metacarpal, 149.
——— of carpus, 149.
——— metacarpus, 149.
——— metatarsus, 175.
——— tarso-metatarsal, 175.
——— of tarsus, 171.
——— elbow-joint, external lateral, 141.
——— internal lateral, 141.
——— anterior, 141.
——— posterior, 142.
——— falciform, 303.
——— Fallopius's, 302
——— of Ferrein, 427.
——— Gimbernat's, 303.
——— glenoid, carpal anterior, 148.
——— posterior, 148.
——— metacarpo-phalangal, 152.
——— metatarso-phalangal, 175.
——— phalangal, of fingers, 153.
——— toes, 176.
——— scapulo-humeral, 138.
——— glosso-epiglottid, 425.
——— of hip-joint, anterior superior, 160.
——— accessory, 160.
——— cotyloid, 160.
——— inter-articular, 161.

Ligaments of hip-joint, round, 161.
——— capsular, 160.
——— of humero-cubital, 141.
——— hyo-epiglottid, 425.
——— ilio-lumbar, 156.
——— inter-articular, acromio-clavicular, 135.
——— of hip-joint, 160.
——— of shoulder-joint, 137.
——— sterno-clavicular, 136.
——— temporo-maxillary, 128.
——— of wrist, 143.
——— osseous, astragalo-calcaneal, 171.
——— of carpal bones, 147.
——— carpo-metacarpal, 149.
——— costo-transverse, 131.
——— vertebral, 131.
——— of forearm, 144.
——— knee-joint, 164.
——— leg, 169.
——— os magnum and metacarpus, 149.
——— metacarpal, 149.
——— metatarsal, 175.
——— peroneo-tibial, 168.
——— pubic, 156.
——— radio-cubital, 143.
——— sacro-iliac, 155.
——— tarsal, of first row, 171.
——— second row, 171.
——— tarso-metatarsal, 175.
——— vertebral, 115.
——— clavicular, 137.
——— spinous, 116.
——— vertebral, 115.
——— of knee-joint, 163.
——— accessory, 166.
——— adipose (so called), 166.
——— alar, 166.
——— anterior, 163.
——— capsular, 163.
——— crucial anterior, 164.
——— posterior, 163.
——— inter-articular, 163.
——— osseous, 164.
——— lateral, external, 163.
——— internal, 163.
——— mucous (so called), 166.
——— posterior, 163.
——— transverse, 163.
——— of larynx, 425.
——— malleus, 673.
——— metacarpo-phalangal, glenoid, 152.
——— lateral, 152.
——— of thumb, 152.
——— of metacarpus, 148.
——— metatarso-phalangal, glenoid, 176.
——— lateral, 176.
——— of metatarsus, 175.
——— occipito-atlantal anterior, superficial, 116.
——— deep, 116.
——— capsular, 117.
——— lateral, 117.
——— posterior, 116.
——— axoid, lateral, 120.
——— middle, 120.
——— odontoid, lateral, 120.
——— middle, 120.
——— orbicular, of acromio-clavicular articulation, 137.
——— of hip-joint, 158.
——— scapulo-humeral, 139.
——— sterno-clavicular, 137.
——— palmar of carpo-metacarpal joints, 149.
——— carpus, 147.
——— metacarpus, 148.
——— of patella, 164.
——— perinæal, 307.
——— peroneo-tarsal, anterior external, 170.
——— external, 170.
——— posterior, 170.
——— of peroneo-tibial articulations, 167, 168.
——— perpendicular, 170.
——— phalangal of fingers, glenoid, 153.
——— lateral, 153.
——— toes, glenoid, 177.
——— lateral, 177.
——— of pisiform and cuneiform bones, 147.
——— plantar inferior, 174.
——— of metatarsus, 176.
——— tarso-metatarsal, 176.
Ligaments, plantar of tarsus, 172.
——— Poupart's, 302.
——— proper, of scapula, anterior, 140.
——— posterior, 140.
——— pterygo-maxillary, 235.
——— pubic anterior, 155.
——— inferior, 155.
——— interosseous, 155.
——— posterior, 155.
——— superior, 155.
——— triangular, 155.
——— radiated chondro-sternal, 133.
——— of radio-carpal articulation, 145.
——— cubital articulations, 144.
——— recto-uterine, 467.
——— round, of forearm, 144.
——— hip-joint, 161.
——— uterus, 466.
——— sacro-coccygeal, anterior, 120.
——— posterior, 120.
——— iliac, anterior, 154.
——— interosseous, 154.
——— posterior vertical, 155.
——— superior, 154.
——— sciatic, great, 155.
——— small, 155.
——— vertebral, 120.
——— scaphoid and cuboid, 172.
——— of shoulder-joint, 136.
——— spheno-maxillary, 129.
——— stellate, costo-vertebral, 130.
——— or radiated, chondro-sternal, 131.
——— stylo-maxillary, 129.
——— mylo-hyoid, 129.
——— sub-pubic, or inferior pubic, 156.
——— supra-spinous, 119.
——— suspensory of clitoris, 471.
——— penis, 456.
——— liver, 386, 475.
——— of first row of tarsal bones, 171.
——— second row of tarsal bones, 171.
——— tarso-metatarsal, dorsal, 174.
——— interosseous, 174.
——— oblique of fifth toe, 175.
——— plantar, 174.
——— of temporo-maxillary articulation, lateral external, 128.
——— internal, 129.
——— thyro-arytenoid, or chordæ vocales, 427.
——— epiglottid, 425.
——— hyoid, middle and lateral, 425.
——— tibio-tarsal, anterior, 169.
——— internal, 169.
——— posterior, 169.
——— of tragus, 667.
——— transverse of atlas, 117.
——— knee, 163.
——— metacarpus, 149.
——— trapezoid, 136.
——— triangular of perinæum, 307.
——— penis, 455.
——— symphysis pubis, 156.
——— urethra, 307.
——— wrist, 143.
——— of two rows of tarsal bones, 171.
——— vertebral, anterior common, 116.
——— interosseous, 116.
——— posterior, 116.
——— yellow elastic, 117.
——— vesico-uterine, 467.
——— of Weitbrecht, 144.
——— Winslow, 164.
——— wrist-joint, external anterior, 146.
——— internal anterior, 146.
——— middle anterior, 146.
——— external lateral, 146.
——— internal lateral, 146.
——— posterior, 146.
——— of Zinn, 650.
Ligamentum arcuatum of diaphragm, 213
——— denticulatum, 694.
——— fibulæ anterius, 170.
——— medium, 170.
——— perpendiculare, 170.
——— posterius, 170.
——— gastro-phrenicum, 354.
——— latum pulmonis, 413.
——— longum plantæ, 173.
——— mucosum of knee-joint, 164.
——— nuchæ, 202.

Ligamentum patellæ, 164.
——— phrenico-lienale, 403.
——— proprium anterius scapulæ, 140.
——— posterius scapulæ, 140.
——— teres of forearm, 144.
——— hip-joint, 161.
Limbs. See *Extremities*.
Limbus luteus, 660.
Line, inter-trochanteric, 94.
—— mylo-hyoidean, 57.
—— naso-labial, 327.
Lines, semicircular of occipital bone, 33.
——— os coxæ, 88.
Linea alba, 301.
——— cervical, 300.
—— aspera, 94.
Lips, 325.
—— development of, 326.
—— movements of, 238.
—— muscles of, 326.
—— structure of, 326.
—— uses of, 327.
—— vessels of, 327.
Liquor Cotunni, 680.
——— Morgagni, 663.
——— of Scarpa, 680.
Liver, 385.
——— acini of, 390.
——— circumference of, 389.
——— coats of, 390.
——— colour and fragility, 389.
——— development of, 399.
——— ducts of, 391 (notes).
——— excretory apparatus of, 395.
——— figure, 386.
——— fissures, 387.
——— functions, 400.
——— groove for vena cava, 389.
——— hilus of, 388.
——— ligament, broad or suspensory, 386.
——— coronary, 390.
——— falciform, 386.
——— triangular, left and right, 390.
——— lobes, 387.
——— lobules or granules, 388.
——— arrangement of, 391.
——— structure of, 394 (note).
——— lymphatics of, 393.
——— nerves of, 393.
——— porta of, 388.
——— proper tissue, 390 (note).
——— situation, 385.
——— size, 385.
——— structure of, 390.
——— surface, inferior or plane, 386.
——— superior, 386.
——— vessels of, 392.
——— arrangement of, 393.
Lobes and lobules of organs. See those organs.
Lobule of ear, 666.
Lobulus caudatus, 389.
——— quadratus, 389.
——— Spigelii, 389.
Locus niger, 751.
——— perforatus anterior, 731.
——— middle or posterior, 727.
Longissimus dorsi. See *Muscles*.
Longitudinal fissures of liver, &c. See those organs.
——— vein of spine. See *Veins*.
Luette of bladder, 459.
Lumbar nerves. See *Nerves*.
——— region of abdomen, 352.
——— veins. See *Veins*.
——— vertebræ. See *Vertebra* and *Vertebræ*.
Lungs, 409.
——— air-cells of, 415.
——— air-tubes of, 416.
——— cellular tissue of, inter-lobular, 415.
——— development of, 421.
——— external conformation of, 411.
——— fissures of, inter-lobular, 411.
——— fœtal, 421.
——— functions, 422.
——— lobes of, 411.
——— lobules of, 415.
——— structure of, 419.
——— lymphatic system of, 421.
——— root of, 412.
——— size of, 409.
——— structure of, 413.
Lungs, vessels and nerves of, 421.
——— weight of, absolute and specific, 410.
Lymphatic duct, right, 619.
——— glands in general, 616.
——— preparation of, 617.
——— structure of, 617.
——— in particular, 619.
——— axillary, 628.
——— bronchial, 625.
——— cervical, deep, 628.
——— superficial, 627.
——— of cranium, 626.
——— duodenal, 624.
——— of face, 626.
——— ileo-colic, 624.
——— iliac, external, 622.
——— internal, 622.
——— inguinal, 619.
——— intercostal, 625.
——— of intestine, great, 624.
——— small, 624.
——— of liver, 623.
——— of lower extremity, 620.
——— lumbar, 621.
——— mammary, 625.
——— mediastinal, 625.
——— mesenteric, 625.
——— meso-colic, 624.
——— of pancreas, 624.
——— parotid, 627.
——— of pelvis, 621.
——— popliteal, 619.
——— pulmonary, 625.
——— sacral, 621.
——— of spleen, 624.
——— of stomach, 624.
——— sub-maxillary, 627.
——— sub-sternal, 625.
——— tibial anterior, 619.
——— tracheal, 627.
——— of upper extremity, 628.
——— part of trunk, 628.
——— hearts of lower animals, 617.
——— networks, superficial and deep, 612.
——— plexuses, 612.
——— system, 611.
——— vessels in general, 611.
——— afferent, 614.
——— anastomoses of, 614.
——— branches of, 614.
——— coat of external, 616.
——— internal, 616.
——— course and direction, 614.
——— deep and superficial sets of, 612.
——— efferent, 614.
——— origin of, in different tissues, 612.
——— preparation of, 617.
——— structure of, 616.
——— terminations of, 614.
——— valves of, 617.
——— vessels of, 616.
——— in particular, 618.
——— of bones, 16.
——— of brain, 628.
——— of cellular tissue, 612.
——— cervical, 628.
——— posterior, 629.
——— of cranium, 627.
——— dorsal, 629.
——— of dura mater, 627.
——— epigastric, 622.
——— of external genitals, male and female, 620.
——— of face, 627.
——— gluteal, 620.
——— of heart, 626.
——— ilio-lumbar, 622.
——— intercostal, 626.
——— of intestines, great, 625.
——— small, 625.
——— of kidneys, 622.
——— of lining membrane of bloodvessels, 613.
——— of liver, deep, 623.
——— superficial, 623.
——— of lower extremity, deep and superficial, 619.
——— lumbar, lateral, 622.
——— superficial, 620.
——— of lungs, deep and superficial, 626.

Lymphatic vessels, mammary, internal, 626.
——— meningeal, 627.
——— of mucous membranes, 612.
——— occipital, 627.
——— of pelvis, 621.
——— pericardiac, 626.
——— perinæal, 620.
——— peroneal, 620.
——— of serous and synovial tissues, 613.
——— of skin, 613.
——— of spleen, 624.
——— of stomach, 624.
——— sub-sternal, 626
——— supra-renal, 622.
——— temporal, 626.
——— of testicles, 622.
——— thorax, 625.
——— thymic, 626.
——— thyroid, 627.
——— tibial, anterior and posterior, 620.
——— of upper extremity, 628.
——— part of trunk, 628.
——— uterine 622.
Lyra, 738.

Macula cribrosa, 676.
Malar foramina, 54.
——— process, 51.
——— bone, 54.
Malleolus, external, 97.
——— internal, 98.
Malleus, and ligament of, 673.
——— muscles of, 673.
Mamma, 471.
——— adipose tissue of, 473.
——— development of, 474.
——— fibrous tissue of, 473.
——— glandular tissue of, 473.
——— lactiferous ducts of, 473.
——— of the male, 473.
——— vessels and nerves of, 474.
Mammary gland. See *Mamma*.
Mammillæ. See *Nipples*.
Mammillary enlargements of posterior median columns of spinal cord, 704.
——— of inferior vermis, 716, 718.
——— tubercles, 426.
Manubrium of malleus, 673.
——— of sternum, 65.
Marrow of bones, 12.
Massa carnea Jacobi Sylvii, 291.
Mastoid foramen, 43.
——— portion of temporal bone, 43.
——— process, 43.
Maxillary arteries. See *Arteries*.
——— bone, inferior, 57.
——— superior, 51.
——— canal, superior, 51.
——— inferior, 58.
——— nerves. See *Nerves*.
——— tuberosity, 51.
Margo-dentatus, 660.
Meatus of nose, inferior, 54.
——— middle, 41.
——— superior, 41.
——— auditorius externus, 44. See *Ear*.
——— internus, 44. See *Ear*.
——— urinarius, female, 471.
——— male, 461.
Mechanism of particular joints. See those joints.
Mediastinum, anterior, 414.
——— posterior, 413.
Medulla oblongata, 702.
——— comparative anatomy of, 709.
——— development of, 708.
——— external conformation of, 702.
——— anterior surface, 703.
——— lateral surfaces, 704.
——— posterior surface, 704.
——— faisceaux innomines of, 706.
——— at base of brain, 706.
——— in isthmus, 715.
——— fasciculi graciles, 708 (note).
——— olivary, 708 (note).
——— re-enforcing, 708.
——— teretes, 708 (note).
——— pyramidal, 702, 704, 708.
——— fibres of, antero-posterior, 707.
——— arched, 704.
——— decussation of, 706.
Medulla oblongata, foramen cæcum of, 703.
——— furrow of median, anterior, 703.
——— posterior, 704.
——— internal structure of, 705.
——— examined by hardening, 706.
——— sections, 705.
——— water, 706.
——— neck of, 702.
——— sections of, 705.
——— of long bones, 12.
——— spinalis. See *Spinal Cord*.
Medullary canal of long bones, 13.
——— membrane, 14.
Meibomian glands, 648.
Membrana nictitans, 648.
——— pupillaris, 659.
——— Ruyschiana, 657.
——— sacciformis, 143.
——— tympani, 669.
——— secundaria, 670.
——— uvea, 659.
Membrane, hyaloid, 661.
——— obturator, or sub-pubic, 155.
Membranes of cerebro-spinal axis. See *Arachnoid*, *Dura Mater*, and *Pia Mater*.
——— of eye. See *Eye*.
——— fibro-mucous See *Fibro-mucous Membranes*.
——— fibro-serous. See *Fibro-serous Membranes*.
——— mucous. See *Mucous Membranes*.
——— serous. See *Serous Membranes*.
——— synovial. See *Synovial Membranes*.
Membranous labyrinth, 679.
——— part of urethra, 458.
Meningeal arteries. See *Arteries*.
Meninges, 681.
Meningoses, 113.
Meniscus, 113.
Mental fossa, 57.
——— foramen, 57.
——— process, 56.
Mesentery, 364, 477.
——— left layer, 475.
——— right layer, 475.
Meso-cæcum, 471.
——— colon, iliac, 475.
——— left and right, 475.
——— transverse, 375.
——— layer, inferior, 476.
——— superior, 477.
——— gastrium, 478.
——— rectum, 475.
Metacarpus, bones of, 84.
——— differential characters, 85.
——— general characters, 85.
——— compared with metatarsus, 109.
Metatarsus, bones of, 103.
——— characters, general, 103.
——— differential, 102.
——— compared with metacarpus, 109.
Milk teeth. See *Teeth*.
Modiolus of cochlea, 678.
Mons Veneris, 470.
Morsus diaboli, and fimbriæ of Fallopian tube, 463.
Motores oculi nerves. See *Nerves*.
Mouth, component parts of, 422.
——— situation, dimensions, &c., 422.
Movements of joints. See *Articulations*.
——— in general, 148.
——— lips and face, 238.
Mucous bursæ (so called), 175.
——— membranes, in general, 421.
——— chemical composition, 421.
——— epithelium, 421.
——— of particular organs. See those organs.
——— structure, 421.
Mucro, 65.
Multifidus spinæ. See *Muscles*.
Muscles in general, 190.
——— action of, 194.
——— angle of incidence on bones, 195.
——— antagonist, 196.
——— aponeuroses of, 193.
——— arrangement, physiological, of, 291.
——— attachments of, 192.
——— fixed, 193.
——— movable, 193.
——— broad, 190.
——— congeneric, 197.

Muscles, direction of, 191.
——— figure of, 191.
——— insertion of, into other parts, 192.
——— long, 191.
——— momentum of, 195.
——— nerves of, 763.
——— nomenclature of, 190.
——— number of, 190.
——— order of description of, 197.
——— origin and termination of, 193.
——— preparation of, 197.
——— relations of, to other parts, 191
——— satellite, 192.
——— sheaths for, 296.
——— short, 191.
——— structure of, 193.
——— tendons of, 193.
——— uses of, 194.
——— volume of, 190.
——— in particular, 196–291.
——— of particular organs, parts, or regions. See those organs, parts, or regions.
——— abductor brevis pollicis, 260.
——— digiti minimi, 262.
——— pedis, 289.
——— indicis, 264.
——— longus pollicis, 258.
——— oculi, 650.
——— pollicis, 287.
——— pedis, 277.
——— accelerator urinæ, 456.
——— accessorious pedis, 280.
——— ad sacro-lumbalem, 277.
——— adductor brevis femoris, 276.
——— digiti minimi (opponens), 281.
——— longus femoris, 276.
——— magnus femoris, 276.
——— oculi, 650.
——— pollicis manûs, 288.
——— pedis, 288.
——— anconeus, 258.
——— anterior auriculæ, 230.
——— antitragicus, 667.
——— articulo-spinalis, 201.
——— arytenoideus, 429.
——— obliquus, 429.
——— transversus, 430.
——— aryteno-epiglottideus, 430.
——— attollens auriculam, 231.
——— oculum, 650.
——— attrahens auriculam, 231.
——— auricularis anterior, 231.
——— posterior, 231.
——— superior, 231.
——— azygos uvulæ, 332.
——— basio-glossus, 338.
——— biceps cruris vel femoris, 269.
——— flexor cubiti, 245.
——— biventer cervicis, 201.
——— brachialis anticus, 246.
——— buccinator, 235.
——— bulbo-cavernosus, 456.
——— caninus, 236.
——— cerato-glossus, 338.
——— chondro-glossus, 338.
——— ciliaris, 232.
——— circumflexus palati, 332.
——— coccygeus, 381.
——— complexus, 205.
——— minor, 205.
——— compressor narium, 233.
——— urethræ, 460.
——— in the female, 470.
——— venæ dorsalis penis, 460.
——— constrictor inferior, 346.
——— medius, 347.
——— superior, 347.
——— vaginæ, 469.
——— coraco-brachialis, 246.
——— corrugator supercilii, 232.
——— cremaster, 210, 450.
——— crico-arytenoideus lateralis, 428.
——— posticus, 428.
——— œsophageus, 352.
——— thyroideus, 421.
——— crotaphyte, 240.
——— crureus, 273.
——— cutanei, 294.
——— deltoideus, 241.
——— depresssor alæ nasi, 234.
Muscles, depressor anguli oris, 237.
——— labii inferioris, 237.
——— superioris alæque nasi, 234.
——— oculi, 650.
——— urethræ (Santorini), 460.
——— in the female, 470.
——— diaphragma, 212.
——— digastricus, 228.
——— elevatores urethræ (Santorini), 460.
——— erector clitoridis, 471.
——— penis, 456.
——— spinæ, 202.
——— extensor brevis digitorum pedis, 286.
——— pollicis, 259.
——— carpi radialis brevior, 255.
——— longior, 255.
——— ulnaris, 258.
——— communis digitorum, 256.
——— digiti minimi, 257.
——— indicis, 259.
——— longus digitorum pedis, 278.
——— pollicis, 259.
——— ossis metacarpi pollicis, 258.
——— primi internodii pollicis, 258.
——— proprius auricularis, 256.
——— indicis, 259.
——— pollicis pedis, 279.
——— secundi internodii pollicis, 258.
——— flexor accessorius, 290.
——— brevis digiti minimi, 262.
——— minimi pedis, 289.
——— digitorum pedis, 289
——— pollicis, 262.
——— pedis, 287.
——— carpi radialis, 250.
——— ulnaris, 250.
——— longus digitorum pedis, 285.
——— pollicis, 253.
——— pedis, 285.
——— perforans, 251.
——— pedis, 285.
——— perforatus, 252.
——— pedis, 290.
——— profundus digitorum, 252.
——— sublimis digitorum 251.
——— frontalis, 230.
——— gastrocnemius, 281.
——— gemellus inferior, 267.
——— superior, 267.
——— genio-hyoglossus, 338.
——— hyoideus, 229.
——— glosso-staphylinus, 332.
——— glutæus maximus, 264.
——— medius, 265.
——— minimus, 266.
——— gracilis, 275.
——— helicis major, 667.
——— minor, 667.
——— Horner's, 653.
——— Houston's, 457.
——— hyo-glossus, 338.
——— iliacus, 215.
——— indicator, 260.
——— infra-costales, 222.
——— spinatus, 243.
——— inter-costales externi, 222.
——— interni, 222.
——— ossei manûs, 262.
——— dorsales, 264.
——— palmares, 264.
——— pedis dorsales, 290.
——— plantares, 290.
——— spinales colli, 286.
——— transversales colli, 217.
——— lumborum, 218.
——— ischio-bulbosus, 457.
——— in the female, 470.
——— cavernosus, 456.
——— in the female, 471.
——— coccygeus, 380.
——— latissimus dorsi, 198.
——— laxator tympani, 675.
——— levator anguli oris, 236.
——— scapulæ, 201.
——— ani, 380.
——— labii inferioris, 237.
——— superioris, 236.
——— alæque nasi, 233.
——— menti, 237.
——— oculi, 649.

Muscles, levator palati, 332.
——— palpebræ superioris, 233, 648.
——— prostatæ, 382.
——— uvulæ, 337.
——— levatores costarum breviores, 222.
——— longiores, 222.
——— lingualis (Albinus and Douglas), 337.
——— inferior, 337.
——— superficialis, 337.
——— longissimus dorsi in the loins, 202.
——— neck, 203.
——— thorax, 203.
——— accessory fibres to, 203, 204.
——— longus colli, 218.
——— lumbricales manûs, 253.
——— pedis, 290.
——— mallei externus magnus, 673.
——— parvus, 673.
——— internus, 674.
——— masseter, 239.
——— multifidus spinæ in the loins, 202, (note).
——— back, 203.
——— neck, 204.
——— mylo-hyoideus, 229.
——— myrtiformis, 234.
——— naso-labialis, 234.
——— obliquus abdominis externus, 208.
——— internus, 209.
——— capitis inferior, 206.
——— superior, 206.
——— oculi inferior, 651.
——— superior, 651.
——— obturator externus, 268.
——— internus, 267.
——— occipitalis, 230.
——— occipito-frontalis, 230.
——— pharyngeus, 338.
——— omo-hyoideus, 226.
——— opponens digiti minimi, 262.
——— pollicis, 260.
——— orbicularis oris, 235.
——— palpebrarum, 231.
——— palato-glossus, 332.
——— pharyngeus, 332.
——— staphylinus, 332.
——— palmaris brevis, 261.
——— longus, 250.
——— palpebralis, 231.
——— patheticus, 651.
——— pectineus, 275.
——— pectoralis major, 220.
——— minor, 221.
——— perforatus Casserii, 253.
——— peri-staphylinus externus, 332.
——— internus, 332.
——— peroneus brevis, 280.
——— longus, 280.
——— tertius, vel anticus, 279.
——— petro-pharyngeus, 348.
——— pharyngo-staphylinus, 332.
——— plantaris, 282.
——— platysma myoides, 224.
——— popliteus, 283.
——— pronator quadratus, 253.
——— radii teres, 249.
——— rotundus, 249.
——— psoas-iliacus, 214.
——— magnus, 215.
——— parvus, 216.
——— pterygoideus externus, 241
——— internus, 240.
——— pterygo-pharyngeus, 347.
——— pubio-urethralis, 457.
——— pyramidalis abdominis, 212.
——— nasi, 233.
——— pyriformis, 266.
——— quadratus femoris, 268.
——— lumborum, 216.
——— menti, 237.
——— rectus abdominis, 210.
——— capitis anticus major, 218.
——— minor, 218.
——— lateralis, 217.
——— posticus major, 206.
——— minor, 206.
——— femoris, 270.
——— internus, 272.
——— oculi externus, 650.
——— internus, 650.
——— inferior, 650.
Muscles, rectus oculi superior, 649.
——— retrahens auriculam, 230.
——— rhomboideus major, 200.
——— minor, 200.
——— risorius Santorini, 284.
——— sacro-lumbalis, in the loins, 203.
——— in the thorax, 204.
——— on the chest, 204.
——— salpingo-pharyngeus, 338.
——— sartorius, 272.
——— scalenus anticus, 217.
——— posticus, 218.
——— scalptor ani, 275.
——— scapulo-hyoideus, 226.
——— semi-spinalis colli, 204 (note).
——— dorsi, 204 (note).
——— membranosus, 270.
——— tendinosus, 270.
——— serratus anticus, 223.
——— parvus, 223.
——— magnus, 221.
——— posticus inferior, 201.
——— superior, 201.
——— soleus, 282.
——— spheno-pharyngeus, 338.
——— sphincter ani externus, 380.
——— internus, 380.
——— œsophagi, 350.
——— vaginæ, 470.
——— vesicæ, 442.
——— spinales posteriores, 201.
——— action of, 203.
——— general view of, 203.
——— in the loins, 201.
——— neck, 204.
——— thorax, 204.
——— spinalis dorsi, 204.
——— cervicis, 204.
——— splenius capitis, 202.
——— colli, 202.
——— stapedius, 671.
——— sterno-cleido-mastoideus, 224.
——— hyoideus, 226.
——— thyroideus, 227.
——— stylo-glossus, 337.
——— hyoideus, 229.
——— alter, 230.
——— pharyngeus, 346.
——— sub-clavius, 221.
——— scapularis, 244.
——— super-ciliaris, 232.
——— supinator radii brevis, 256.
——— longus, 254.
——— supra-costales, 221.
——— spinatus, 243.
——— suralis, 281.
——— temporalis, 239.
——— tensor palati, 332.
——— tarsi, or Horner's, 653.
——— tympani, 671.
——— vaginæ femoris, 271.
——— tensors of fasciæ, 296.
——— teres major, 198.
——— minor, 243.
——— thyro-arytenoideus, 428.
——— epiglottideus, 428.
——— hyoideus, 227.
——— tibialis anticus, 278.
——— posticus, 284.
——— trachelo-mastoideus, 204.
——— tragicus, 667.
——— transversalis abdominis, 210.
——— cervicis, 205.
——— colli, 204.
——— nasi, 234.
——— transverso-spinalis, 202.
——— in the loins, 202.
——— in the neck, 204.
——— in the thorax, 204.
——— transversus auriculæ, 667.
——— nasi, 234.
——— pedis, 290.
——— perinæi, 381.
——— alter, 457.
——— pollicis pedis, 290.
——— trapezius, 198.
——— triangularis nasi, 234.
——— oris, 237.
——— sterni, 223.
——— triceps adductor femoris, 274.

Muscles, triceps extensor cruris, 272.
——— cubiti, 247.
——— femoralis, 272.
——— femoris (auctor), 272.
——— suralis, 281.
——— trochlearis, 651.
——— of the ureters, 445.
——— vastus externus, 273.
——— internus, 273.
——— Wilson's, 457.
——— which move the arm upon the shoulder, 292.
——— fingers, 293.
——— foot upon the leg, 293.
——— forearm upon the arm, 293.
——— hand upon the forearm, 293.
——— leg upon the thigh, 292.
——— lower jaw, 292.
——— os hyoides, 292.
——— pelvis, 292.
——— radius upon the ulna, 293.
——— ribs, 292.
——— shoulder, 292.
——— skin, 293.
——— thigh upon the pelvis, 292.
——— toes, 293.
——— vertebro-cranial column, 292.
——— walls of thorax and abdomen, 292.
——— zygomaticus major, 236.
——— minor, 236.
Muscular fibres, filaments, and fasciculi, 198 (note).
——— fibres of particular organs. See those organs.
——— sheaths, 296.
——— tissue, involuntary, 198.
——— structure, 322.
——— voluntary, 198.
——— chemical composition, 199.
——— structure, 198.
Musculi pectinati, 486.
——— papillares, 484.
Musculo-cutaneous nerves. See *Nerves*.
Myology, 190.

Nails, 636.
——— lunule of, 636.
——— matrix, 636.
——— structure and growth of, 637.
Nares, anterior, 60.
——— posterior, 60.
Nasal arteries. See *Arteries*.
——— bone, 55.
——— cartilages. See *Nose*.
——— duct and canal, 653.
——— eminence, 35.
——— fossæ, 62.
——— meatuses, 41.
——— nerves. See *Nerves*.
——— process, 51.
——— spine, anterior and posterior, 52, 54.
Nates (of brain), 712.
Navicular fossæ. See *Fossa*.
Necks of bones, 10.
——— particular. See those bones.
Nerves in general, 759.
——— anastomoses of, 762.
——— of animal life, 761.
——— central extremity of, 760.
——— classification of, 759.
——— course of, 762.
——— cranial, 759.
——— different kinds of, 761.
——— direction of, 763.
——— division of into sets, 769.
——— fibres and filaments of, 767.
——— ganglia of, 765.
——— connexions of, 765.
——— different kinds of, 765.
——— structure of, 768.
——— ganglionic, 764.
——— mode of division of, 764.
——— motor, 759.
——— neurilemma of, 766.
——— of organic life, 761.
——— origin of, apparent and real, 758.
——— plexuses of, 762. See *Plexuses*
——— preparation of, 769.
——— relations of, 763.
——— respiratory, 760, 762.
——— roots of, anterior or motor, 762.
——— posterior or sensory, 762.
Nerves, sensory, common, 759, 762.
——— special, 762.
——— spinal, 759.
——— structure of, 766.
——— symmetrical, 760.
——— sympathetic, 762, 764.
——— structure of, 767.
——— termination of, 764.
——— in particular, 769.
——— abdominal, great, 798.
——— small, 799.
——— abducens oculi. See *Motor Oculi, external*.
——— accessory, of internal cutaneous, 785.
——— saphenous, 801.
——— obturator, 801 (note).
——— spinal, distribution of, 849.
——— function of, 851.
——— ganglion of, 824.
——— origin of, 823.
——— vertebral course, 824.
——— acromial, 778.
——— alveolo-dental, anterior, 834.
——— posterior, 834.
——— anal cutaneous, 806.
——— aortic, sympathetic, 863.
——— articular of ankle, 812.
——— of elbow, 785, 786.
——— hip-joint, 800.
——— of knee, anterior, 802.
——— external, 808.
——— internal, 812.
——— from obturator, 801.
——— recurrent, 809.
——— posterior, or azygos, 812.
——— of wrist, 785.
——— auditory. See *Portio Mollis*.
——— auricular, anterior, 836.
——— great, 778.
——— of pneumogastric, 845.
——— posterior, 840.
——— auriculo-occipital, 840.
——— temporal, 836.
——— axillary, or circumflex, 783.
——— azygos, of knee-joint, 813.
——— buccal, 835.
——— of facial, 841.
——— bucco-labial, 835.
——— bulbo-urethral, 806.
——— calcaneal, external, 812.
——— internal, 813.
——— cardiac, great, 861.
——— inferior, left, 861.
——— right, 861.
——— lesser, 861.
——— middle, left, 862.
——— right, 861.
——— of pneumogastric, in neck, 847.
——— in thorax, 837.
——— of recurrent laryngeal, 837.
——— superficial, 861.
——— superior, left, 861.
——— right, 860.
——— of sympathetic, 860.
——— carotid branch of vidian, 833.
——— of sympathetic, 765.
——— cerebral. See *Cranial*.
——— cervical, branches of, anterior, 776, 781.
——— posterior, 773.
——— number of, 771.
——— roots of, 771.
——— cervical, first, anterior branch of, 776.
——— posterior branch of, 773.
——— second, anterior branch, 776.
——— posterior branch, 774.
——— third, anterior branch, 777.
——— posterior branch, 774.
——— fourth, anterior branch, 777.
——— posterior branch, 774.
——— fifth to eighth, anterior branches, 781.
——— posterior branches, 774.
——— of facial, 841.
——— internal descending, 780.
——— superficial, 778.
——— cervico-facial, 839, 841.
——— chorda tympani, 836.
——— canal for, 672.
——— ciliary, 659, 830.
——— nasal, 830.
——— ophthalmic, 830.
——— circumflex, 782.

Nerves, clavicular, 783.
——— of clitoris, 807.
——— for cochlea, 842.
——— collateral dorsal of fingers, 790.
——— of thumb, 792.
——— of toes, 811.
——— palmar of fingers, 788, 790.
——— thumb, 788.
——— communicating fibular, 811.
——— tibial, 811.
——— for complexus, 773.
——— for coxo-femoral articulation, 800 (note).
——— cranial, in general, 816.
——— central, extremities of, 817.
——— classification of, 816.
——— distribution of, 832.
——— general view of, 853.
——— nomenclature of, 817.
——— cranial, in particular, 832.
——— first. See *Olfactory*.
——— second. See *Optic*.
——— third. See *Motor Oculi, common*.
——— fourth. See *Pathetic*.
——— fifth. See *Trifacial*.
——— sixth. See *Motor Oculi, external*.
——— seventh. See *Portio Dura* and *Portio Mollis*.
——— eighth. See *Pneumogastric, Glosso-pharyngeal*, and *Spinal Accessory*.
——— ninth. See *Hypo-glossal*.
——— crural, 801.
——— for crureus, 802.
——— cutaneous, accessory of saphenous, 801.
——— anal, 806.
——— external, of arm, 785.
——— of musculo-spiral, 791.
——— of thigh, 799.
——— of intercostal, 794.
——— internal, of arm, 784.
——— accessory of, 785.
——— of musculo-spiral, 791.
——— of thigh, 801.
——— of Wrisberg, 785.
——— long, of obturator, 801 (note).
——— middle, of thigh, 801.
——— of musculo-cutaneous of arm, 785.
——— palmar, 787.
——— perforating, of intercostal, 794.
——— of thigh, 802.
——— plantar, 813.
——— radial, 792.
——— of shoulder, 784.
——— of Sœmmering, 807.
——— tibial, 803.
——— ulnar, dorsal, 789.
——— deep palmar, 789.
——— plantar, 814.
——— temporal, 835.
——— dental, anterior, 834.
——— inferior, 837.
——— posterior, 833.
——— descendens noni, 853.
——— descending cervical, 779.
——— internal, 777.
——— diaphragmatic, 780.
——— digastric, 840.
——— digital, of median, 788
——— of radial, 792.
——— of ulnar, 789.
——— dorsal, branches of, anterior, 794.
——— posterior, 775.
——— number of, 771.
——— roots of, 772.
——— collateral of fingers, 790, 792.
——— toes, 811.
——— of foot, deep external, 811.
——— internal, 811.
——— of hand, external, 792.
——— internal, 790.
——— intercostal. See *Intercostal*.
——— of penis, 806.
——— dorsi-lumbar, 796.
——— to dura mater, 835.
——— encephalic. See *Cranial*.
——— ethmoidal, 830.
——— facial. See *Portio Dura*.
——— branches, collateral, 839.
——— summary of, 842.
——— to femoral artery, 802.
——— frontal, 828.
Nerves, frontal, external, 829.
——— internal, 829.
——— osseous, 829.
——— fronto-nasal, 829 (note).
——— for gastrocnemius, 812.
——— for gemelli, 808.
——— genito-crural, 799.
——— glosso-pharyngeal, distribution of, 843.
——— function of, 845.
——— ganglion of, 844.
——— origin and cranial course, 823.
——— gluteal, inferior, 807.
——— superior, 807.
——— gustatory, 836.
——— hemorrhoidal, inferior, 806.
——— to hip-joint, 800 (note).
——— hypo-glossal, distribution, 851.
——— function, 853.
——— ganglion, 823.
——— origin and cranial course, 824
——— ilio inguinal, 798.
——— scrotal, 798.
——— small, 798.
——— incisor, 837.
——— infra-hyoid, of hypo-glossal, 852.
——— orbital, 831, 841.
——— of facial, 841.
——— trochlear, 830.
——— inguinal, external, 797.
——— internal, 797.
——— inguino-cutaneous, 797.
——— intercostal, 794.
——— muscular, 794.
——— perforating, 794.
——— summary of, 796.
——— costo-humeral, 795.
——— osseous, anterior, of forearm, 795.
——— of leg, 811.
——— posterior, of forearm, 790.
——— ischiadic, 802.
——— lesser, 802.
——— of Jacobson, 838.
——— lachrymal, 828.
——— of orbital, 831.
——— lachrymo-palpebral, 828.
——— laryngeal, anastomotic, 847.
——— external, 846.
——— inferior, or recurrent, 847.
——— superior, 846.
——— of sympathetic, 859.
——— to latissimus dorsi, 784.
——— levator anguli scapulæ, 782.
——— ani, 805.
——— lingual, 836.
——— of glosso-pharyngeal, 844.
——— longitudinal, of Lancisi, 737.
——— lumbar, branches of, anterior, 796.
——— posterior, 776.
——— number of, 772.
——— roots of, 772.
——— lumbo-sacral, 797.
——— malar, 831.
——— of facial, 840
——— masseteric, 835.
——— mastoid, great, 779.
——— small, 780.
——— maxillary, inferior, 834.
——— superior, 831.
——— terminal branches of, 834.
——— median, 786.
——— in arm, 786.
——— in forearm, 787.
——— in hand, 787.
——— mental, 837.
——— of facial, 841.
——— motor oculi, common, distribution of, 825.
——— function of, 826.
——— origin and cranial course, 820.
——— external, distribution, 838.
——— origin and cranial course, 822.
——— musculo-cutaneous, brachial, 786.
——— crural, 801.
——— dorsal, 775.
——— of leg, 810.
——— lumbar, inferior, 798.
——— middle, 798.
——— superior, 798.

Nerves, musculo-spiral, 786, 791.
——— myloid, 837.
——— nasal, 829.
——— external, 829.
——— internal, 830.
——— posterior, 832.
——— superior, 833.
——— of nasal fossa, external, 830.
——— naso-lobar, 830.
——— palatine, 832.
——— obturator, 799.
——— accessory of, 800 (note).
——— articular of, to hip, 800.
——— knee, 801 (note).
——— long cutaneous, 801 (note).
——— to obturator internus, 805.
——— occipital, external, 779.
——— great, 777.
——— small, 780.
——— oculo-muscular. See *Motor Oculi* and *Pathetic*.
——— œsophageal, 847.
——— olfactory, bulb of, 817.
——— distribution of, 824.
——— function of, 825.
——— origin and cranial course, 818.
——— structure of, 818.
——— ophthalmic, 827.
——— optic, chiasma or commissure of, 819.
——— distribution of, 825.
——— function, 825.
——— origin and cranial course, 819.
——— roots of, gray, 608.
——— structure, 820.
——— terminations of, 671.
——— tracts of, 819.
——— orbital, 831.
——— of facial, 840.
——— palatine, anterior, 832.
——— middle, 832.
——— posterior, 832.
——— palmar collateral, 769, 790.
——— cutaneous, 768.
——— palpebral, inferior, 840.
——— superior, 840.
——— of particular organs, parts, or tissues. See those organs, &c.
——— par vagum. See *Pneumogastric*.
——— pathetic, distribution, 826.
——— function, 826.
——— origin and cranial course, 820.
——— to pectineus, 801 (note), 802 (note).
——— pectoralis major, 783.
——— minor, 783.
——— perforans Casserii, 786.
——— perforating, of hand, 790.
——— cutaneous, of inter-costals, thigh, 802.
——— perineal, 806.
——— superficial, anterior, 806.
——— posterior, 806.
——— peroneal, 808.
——— cutaneous, 810.
——— external, 810.
——— saphenous, 810.
——— petrosal, superficial, great, 833.
——— small, 838.
——— pharyngeal, of glosso-pharyngeal, 844.
——— pneumogastric, 846.
——— small, 846, 850.
——— of spheno-palatine, 833 (note).
——— sympathetic, 859.
——— phrenic, 780.
——— plantar, collateral, 813, 814.
——— external, 814.
——— deep, 814.
——— internal, 813.
——— for plantaris longus, 812.
——— pneumogastric, in abdomen, 848.
——— anastomoses of, 845.
——— cranial course, 823.
——— fibrous layers of, 719.
——— in foramen lacerum, 845.
——— functions of, 849.
——— ganglion of, 845.
——— in neck, 845.
——— origin of, 823.
——— summary of, 849.
——— in thorax, 847.
——— popliteal, external, 808.
——— internal, 812.
Nerves, popliteal, sciatic, external, 808.
——— internal, 811.
——— portio dura, distribution, 839.
——— function, 843.
——— origin and cranial course, 822.
——— mollis, distribution, 681, 842.
——— function, 842.
——— origin and cranial course, 822.
——— structure, 768.
——— pterygoid, 833.
——— internal, 836.
——— pudendal, long, 808.
——— pudic, internal, 806.
——— in female, 807.
——— pulmonary, anterior and posterior, 848.
——— to pyriformis, 807.
——— for quadratus femoris, 808.
——— radial, or musculo-spiral, 790.
——— proper, 791.
——— to rectus femoris, 802.
——— recurrent, of knee, 810.
——— laryngeal, 848.
——— lesser sciatic, 808.
——— renal, 865.
——— respiratory, external, 782.
——— of eye, 821.
——— superior, of trunk, 850.
——— to rhomboideus, 782.
——— sacral, branches of, anterior, 804.
——— posterior, 777.
——— number of, 772.
——— roots of, 772.
——— saphenous, external, 812.
——— internal, 803.
——— accessory, of, 802.
——— peroneal, 810.
——— satellite, of femoral artery, 802.
——— ulnar artery, 790.
——— sciatic, great, 808.
——— lesser, 801.
——— of septum nasi, anterior, 830.
——— posterior, 832.
——— to serratus, 782.
——— of sheath of femoral vessels, 802.
——— soft (nervi molles), 845.
——— spheno-palatine, external, 833.
——— internal, 832.
——— spinal, 770.
——— accessory of Willis. See *Accessory*.
——— branches of, in general, 771.
——— anterior, 771.
——— ganglionic, 771.
——— posterior, 773.
——— classification of, 770.
——— number of, 770.
——— origin of, apparent, 770.
——— real, 772.
——— plexuses of, 776.
——— roots of, anterior, or non-ganglionic, 771.
——— roots of, posterior, or ganglionic, 771.
——— splanchnic, great, 865.
——— lesser, 865.
——— lumbar, 869.
——— splenic, 867.
——— to splenius, 843.
——— sternal cutaneous, 780.
——— styloid, 840.
——— to sub-clavius, 782.
——— sub-occipital, anterior branch, 778.
——— posterior, 776.
——— scapular, inferior, 784.
——— superior, 783.
——— of sub-septum, 841.
——— superficial cardiac, 862.
——— cervical, 776.
——— petrosal, great, 833.
——— lesser, 837.
——— temporal, 835.
——— supra-clavicular, 779.
——— orbital, 828.
——— scapular, 782.
——— trochlear, 829.
——— to supra and infra-spinati, 782.
——— sympathetic, in general, 761.
——— characters of, 871.
——— structure of, 766.
——— in particular, 854.
——— abdominal, 851.
——— cervical, 855.
——— lumbar, 848.

Nerves, sympathetic, sacral, 871.
——————— thoracic, 868.
——— temporal, deep, 835.
——————— of facial, 839.
——————— superficial, 836.
——— temporo-facial, 839.
——————— malar, 831.
——— to tensor tympani, 837.
——————— vaginæ femoris, 807.
——————— tentorium cerebelli, 827.
——————— teres major, 874.
——————— minor, 783.
——— thoracic, 783.
——————— anterior, 783.
——————— posterior, 782.
——— tibial, 811.
——————— anterior, 811.
——————— cutaneous, 802.
——————— posterior, 811.
——————— saphenous, 812.
——— to trapezius, 781.
——— trifacial, distribution of, 827.
——————— divisions of, 827.
——————— ganglion of, 821.
——————— origin and cranial course, 821.
——————— root of, large, 821.
——————— small, 821.
——— trigeminal. See *Trifacial*.
——— trochlear. See *Pathetic*.
——— tympanic, of Jacobson, 838.
——— ulnar, 789.
——————— in the arm and forearm, 789.
——————— hand, 790.
——— for ulnar artery, 790.
——— uterine, 870.
——— vaginal, 870.
——— for vasti femoris, 802.
——— vertebral (sympathetic), 860.
——— vesical, 870.
——— vestibular, 843.
——— vidian, 833.
——— visceral, abdominal, 866.
——————— cervical, 845.
——————— pelvic, 869
——————— sacral, 805
Nervi molles, 845.
Nervous system, central portion, 681.
——————— peripheral portion, 759.
Nervus impar, 698.
Neurilemma of nerves, 766.
——————— spinal cord, 697.
Neurology, 629.
Ninth nerve. See *Nerve, hypoglossal*.
Nipples, 472.
——— glands and papillæ of, 473.
Noduli Arantii, 479.
Nodulus of cerebellum, 716 (note).
Nodus encephali (Sœmmering), 844.
Nœud de l'encephale, 844.
Nose, general description, 641.
——— bones of, 55, 641.
——— cartilages of, 641.
——— mucous membrane of, 642.
——— muscles of, 643.
——— septum of, 56, 642.
——— skin of, 643.
Nostrils, 641.
——— cartilages of, 641.
Notch, inter-condyloid, 91.
——— ischiatic, 89.
——— sacro-sciatic, 89.
——————— great, 155.
——————— small, 155.
——— sciatic, 89.
——— sigmoid, 57.
Notches, vertebral, 20, 21.
Nutritious arteries. See *Arteries*.
——————— foramina of bones. See *Foramen*.
Nymphæ, 471.

Oblique muscles. See *Muscles*.
Obturator foramen and groove, 88.
——————— nerve. See *Nerves*.
Occipital angle of Daubenton, 45.
——————— bone, 33.
——————— condyles, 33.
——————— crests, 34.
——————— foramen, 34.
——————— fossæ, 34.
——————— nerves. See *Nerves*.
Occipital protuberances, 34.
——————— veins. See *Veins*.
Occipito-atlantoid articulations, 118.
——————————— ligaments, 118.
——————— axoid articulations, 119.
——————————— ligaments, 120.
——————— parietal suture, 46.
Oculo-muscular nerves. See *Nerves, Motor Oculi* and *Pathetic*.
Odontoid process, 26.
Odontogeny, 184.
Odontology, 177.
Œsophagus, 350.
——————— glands of, 352.
——————— mucous membrane, 352.
——————— muscular coat, 351.
——————— structure of, 351.
——————— uses, 352.
——————— vessels and nerves, 352.
Olecranoid cavity, 80.
Olecranon process, 80.
Olfactory nerve. See *Nerve*.
——————— lobes, 758.
Olivary process, 37.
——————— bodies, 703.
——————— corpus dentatum of, 704.
——————— sections of, 704.
——————— structure of, 705.
——————— fasciculi, 705.
Omentum, colic, 478 (note).
——————— gastro-colic, 478.
——————— hepatic, 476.
——————— splenic, 403.
——————— great, 476.
——————— layers of, anterior, 476.
——————————— posterior, 476.
——————— sac of, 477.
——————— vessels and nerves of, 478.
——————— lesser, 476.
——————— layer of, anterior, 476.
——————————— posterior, 476.
Operculum laryngis, 426.
Ophthalmic nerve, 828.
Optic thalami, 727, 745.
——————— fibres of, 746.
——— tracts, 820.
Orbicular ligaments of joints. See *Ligaments*.
Orbital arch, 36.
——————— cavities, 6
——————— fissure, 53.
——————— foramina, internal, 36.
——————— process of palate bone, 55.
——————— processes of frontal bone, 36.
——————— plate, 36.
Orbits, 62.
Organ of hearing, 665. See *Ear*.
——————— sight, 615. See *Eye*.
——————— smell, 641. See *Nose*, and *Pituitary Membrane*.
——————— taste, 639. See *Tongue*.
——————— touch, 629. See *Skin*.
——————— the voice, 422. See *Larynx*.
Organs, anatomical elements of, 320.
——————— colour and consistence of, 321.
——————— development of, 321.
——————— of digestion, 322.
——————— direction and relations of, 321.
——————— dissection of, 322.
——————— functions of, 322.
——————— of generation, female, 461.
——————————— male, 446.
——————— genito-urinary, 435.
——————— nomenclature, 320.
——————— number, 320.
——————— of respiration, 409.
——————— of the senses, 629.
——————— situation, 320.
——————— size and figure, 321.
——————— structure of, 321.
——————— urinary, 435.
Os, bone. See *Bone, os*.
——— tincæ, 465.
——— uteri, 465.
Ossa pisiformia, or lingualia, 111.
——— triquetra, or Wormiana, 50.
Ossicula auditûs, 669.
——————————— movements of, 675.
——————————— muscles belonging to, 674.
Ossification of bones. See those bones.
Osteology, 5.
Osteogeny, 16.

Ostia of Fallopian tube, 463.
Ostium internum of uterus, 465.
Otoconia and otolithes, 843.
Ova of Naboth, 466.
Ovarian vesicles, 463.
Ovaries, 461.
——— ligaments of, 461.
——— structure, 462.
Ovum, 462.

Palate, bone, 53.
——— hard, 330.
——— development, 330.
——— structure, 330.
——— uses, 330.
——— soft, 330.
——— aponeurosis of, 331.
——— development of, 333.
——— glands of, 333.
——— mucous membrane of, 333.
——— muscles of, 331.
——— pillars of, 331.
——— structure of, 331
——— uses of, 331.
——— vessels, &c., of, 333.
Palatine aponeurosis, 331.
——— arch, 329.
——— canals, 52, 54.
——— accessory, 52, 54.
——— glands, 330.
——— process, 52.
Palm of hand, 83.
Palmar arteries. See *Arteries.*
——— ligaments. See *Ligaments.*
——— nerves. See *Nerves.*
Pancreas, 400.
——— development of, 402.
——— duct of, 402.
——— function of, 402.
——— lesser, 402.
——— structure of, 401.
——— vessels and nerves of, 402.
Panniculus adiposus, 629.
——— carnosus, 629.
Papillæ, conjunctival, 648.
——— dental, 181.
——— (Goodsir), 183.
——— of kidney, 437.
——— lachrymal, 646.
——— of skin, 630.
——— of small intestine, 367.
——— of stomach, 361.
——— of tongue, 333.
Par vagum. See *Nerve, pneumogastric.*
Parietal bone, 41.
——— foramen, 41.
——— fossa, 41.
——— protuberance, 41.
Parotid duct, 341.
——— gland, 340.
——— development of, 340 (note).
——— structure of, 340.
Pars mastoidea of temporal bone, 43.
——— petrosa of temporal bone, 43.
——— squamosa of temporal bone, 43.
Patella, 95.
——— ligament of, 97.
Pathetic nerve. See *Nerves.*
Patte d'oie, 270, 271.
Peduncles of cerebellum and cerebrum. See those organs.
Pelvis, aponeuroses of, 306.
——— articulations of, 154.
——— axes of, 90.
——— circumferences of, 92.
——— compared with shoulder, 105.
——— development of, general, 93.
——— in general, 90.
——— great or false, 90.
——— of the kidney, 439.
——— structure of, 439.
——— little or true, 90.
——— brim of, 92.
——— strait, superior, 92.
——— inferior, 92.
——— excavation or cavity of, 122.
——— outlet of, 92.
——— mechanism of, 158–159.
——— regions of, 90.
——— varieties of, sexual, 90.
Penis, 454.
——— corpus cavernosum of, 455.
——— glans of, 461.
——— ligament, suspensory or triangular, 456
——— muscles of, 457.
Perforated spot, anterior, 734.
——— posterior, 730.
Perforating arteries. See *Arteries.*
——— nerves. See *Nerves.*
Peri-cardium, 494.
——— structure, 494.
——— vessels, 495.
——— glottis, 640.
——— lymph, 679.
——— osteum, 296.
——— alveolo-dental, 338.
Peritoneum, 474.
——— folds of, 478.
——— general description of, 478.
——— portion of, parietal, 478.
——— sub-umbilical, 474.
——— supra-umbilical, 475.
——— visceral, 477.
——— structure of, 479.
Permanent teeth. See *Teeth.*
Perone, 98.
Peroneal arteries. See *Arteries.*
——— nerve. See *Nerves.*
Pes accessorius, 746.
——— hippocampi, 745.
Petrosal nerves. See *Nerves.*
Petrous portion of temporal bone, 43.
——— process, 43.
Pharyngeal nerves. See *Nerves.*
Pharynx, 344.
——— aponeuroses of, 346.
——— development of, 349.
——— mucous membrane of, 349.
——— muscles of, 346.
——— extrinsic, 346.
——— intrinsic, 346.
——— supernumerary, 346.
——— uses, 349.
——— vessels and nerves, 349.
Pia mater, 692.
——— cerebral, 692.
——— spinal, or rachidian, 697.
Pigmentum of skin, 632 (note).
——— eye, 659.
Pillar of valve of Vieussens, 712.
Pillars of diaphragm, 212.
——— fauces, or palate, 331.
——— fornix, 740.
Pineal gland or body, 742.
——— commissure and peduncles of, 743.
——— concretions, 743.
——— function of, 744.
Pisiform bone, 83.
Pituita, 749.
Pituitary body or gland, 729.
——— fossa, 37.
——— membrane, 643.
——— follicles of, 645.
——— nerves of, 645.
——— structure, 644.
——— vessels of, 645.
Plantar ligaments. See *Ligaments.*
——— nerves. See *Nerves.*
Plaques gaufrées, 366.
Plate, cribriform, of ethmoid bone, 40.
——— horizontal, of palate bone, 53.
——— orbital, 35.
——— perpendicular, of ethmoid bone, 41.
Pleura, costal, diaphragmatic, mediastinal, and pulmonary, 413.
——— structure and uses of, 413.
Pleuræ, 413.
Plexuses of lymphatics, 614.
——— of nerve, 762, *et infrà.*
——— auricular, 858.
——— brachial, 781.
——— general view of nerves of, 792.
——— bronchial, 848.
——— cardiac, deep, 860.
——— great, 863.
——— superficial, 862.
——— carotid, 856.
——— cavernous, 856.
——— cervical, 777.
——— deep, 777.

Plexuses, cervical, posterior, 774.
——— superficial, 777.
——— cervico-brachial, 776.
——— cœliac, 866.
——— coronary, of heart, anterior and posterior, 863.
——— of stomach, 866.
——— diaphragmatic, 866.
——— epigastric, 866.
——— facial (sympathetic), 858.
——— gastro-epiploic, left, 868.
——— right, 867.
——— hemorrhoidal, inferior, 890.
——— superior, 868.
——— hepatic, 867.
——— hypogastric, 870.
——— infra-orbital, 841.
——— laryngeal, 846.
——— lingual, 858.
——— lymphatic, 612.
——— lumbar, 797.
——— lumbo-aortic, 868, 869.
——— sacral, 776.
——— mental, 837.
——— mesenteric, inferior, 868.
——— superior, 867.
——— nervous, 762.
——— occipital, 859.
——— ovarian, 868.
——— pharyngeal, 846, 859.
——— phrenic, 866.
——— pulmonary, anterior and posterior, 848.
——— renal, 868.
——— sacral, 805.
——— solar, 866.
——— spermatic, 868.
——— splenic, 867.
——— supra-renal, 866.
——— thyroid, 858.
——— tympanic, 843.
——— uterine, 870.
——— vertebral, 860.
——— vesical, 870.
——— visceral of abdomen, 866.
——— pelvis, 805, 869.
——— of veins, 575, *et infrà*.
——— alveolar, 589.
——— choroid, of brain, 747.
——— fourth ventricle, 720.
——— third ventricle, 741.
——— reflected portion of, 746.
——— hemorrhoidal, 601.
——— intra-spinal, 609.
——— lingual, 590.
——— masseteric, 590.
——— pampiniform, 598.
——— pharyngeal, 591.
——— pterygoid, 590.
——— spermatic, 598.
——— spinal, deep, 609.
——— longitudinal, 609.
——— transverse, 609.
——— tonsillar, 333.
——— uterine, 602.
——— vaginal, 602.
——— vesico-prostatic, 601.
——— urethral, 602.
Plica semilunaris, 648.
Pneumo-gastric nerve. See *Nerve*.
Pomum Adami, 424.
Pons Varolii, or cerebelli, 710.
——— internal structure of, 713.
Porta, 388.
Portio dura nerve. See *Nerve*.
——— mollis nerve. See *Nerve*.
Prepuce, 454.
——— of clitoris, 471.
——— frœnum of, 454.
Process, acromion, 76.
——— auditory, 44.
——— basilar, 34.
——— cochleariform, 44, 672.
——— coracoid, 76.
——— coronoid, of lower jaw, 58.
——— of ulna, 80.
——— ensiform, 65.
——— of fifth metatarsal bone, 104.
——— genial, 58.
——— gracilis of Raw, 673.
——— hamular, of sphenoid bone, 37.
——— of cochlea, 678.
Process, of helix, 667.
——— malar, 51.
——— mastoid, 43.
——— mental, 58.
——— nasal, 51.
——— odontoid, 26.
——— olecranon, 80.
——— olivary, 37.
——— orbital, external, 36.
——— internal, 36.
——— of palate bone, 54.
——— palatine, 52.
——— petrous, 43.
——— pyramidal, 54.
——— scaphoid, 101.
——— styloid, of temporal bone, 43.
——— ulna, 80.
——— radius, 81.
——— fibula, 99.
——— vaginal, of temporal bone, 44.
——— vermiform, inferior, 716.
——— superior, 716.
——— zygomatic, of temporal bone, 42.
——— of malar bone, 55.
Processes of bones, 9.
——— ciliary, of choroid coat, 656.
——— vitreous humour, 661.
——— calcaneal, 101.
——— clinoid, 37.
——— pterygoid, 37.
——— spinous, of ilium, 89.
——— spinous, of vertebræ, 21.
Processus a cerebello ad medullam, 704.
——— pontem, 721.
——— testes, 711.
——— a cerebro ad medullam, 710.
——— arciformes, 703.
——— gracilis of Raw, 673.
Profunda artery. See *Arteries*.
——— vein. See *Veins*.
Promontory of sacrum, 26, 92.
——— tympanum, 671.
Pronator muscles. See *Muscles*.
Protuberances, occipital, 34.
——— parietal, 42.
Psalterium, 738.
Pterygoid canal, 37.
——— columns, 126.
——— fossa, 37.
——— processes, 37.
Pterygo-maxillary fissure, 52.
——— palatine canal, 38, 52.
Pubes, 90.
Pubic arch, 89.
Pudic arteries. See *Arteries*.
Pulmonary arteries. See *Arteries*.
——— veins. See *Veins*.
Puncta lachrymalia, 647.
Pupil of eye, 657.
Pupillary membrane, 659.
Pyloric valve, 355.
Pylorus, 354.
——— antrum of, 354.
Pyramid of cerebellum, or of Malacarne, 717.
——— of tympanum, and its canal, 671.
Pyramids, anterior, 703.
——— decussation of, 706.
——— sections of, 706.
——— of kidney, 437.
——— posterior, 704.
——— sections of, 706.

Quadrati muscles. See *Muscles*.

Rachis. See *Vertebral Column*.
Rachidian bulb, proper. See *Medulla Oblongata*.
——— bulbs, 697.
——— veins. See *Veins, spinal*.
Radial nerve. See *Nerve*.
Radiating crown of Reil, 744.
Radius, 81.
——— and tibia, lower parts of, compared, 107.
Rami of lower jaw, 57.
Ramus of pubes, 90.
——— ischium, 91.
Receptaculi arteriæ, 525.
Receptaculum chyli, 618.
——— ganglii petrosi, 843.
Recess of tympanum, 672.
Recessus sulciformis, 676.

Recti muscles. See *Muscles.*
Rectum, 376.
——— columnæ of, 377.
——— curves of, 377.
——— internal surface, 378.
——— muscular coat of, 377.
——— structure of, 377.
Recurrent arteries. See *Arteries.*
——— nerves. See *Nerves.*
Renes. See *Kidneys.*
——— succenturiati. See *Supra-renal Capsules.*
Respiratory apparatus, 409.
——— nerves, in particular. See *Nerves.*
Restiform bodies, 704.
Rete of Malpighi, 640.
—— mucosum, 640.
——— of tongue, 646.
—— vasculosum testis, 451.
Retia mirabilia, 496.
Retina, 660.
——— artery of, 660.
——— folds of, 660.
——— foramen centrale, and limbus luteus of, 660.
——— margo dentatus, 660.
——— structure of, 660 (note).
——— termination of, 660 (note).
Ribs, angles of, 68.
—— characters of, general, 67.
——— special, 68.
—— false, 67.
—— movements of, 134.
—— supernumerary, 32.
—— true, 67.
—— torsion of, 67.
—— tubercle of, 68.
Rima glottidis, 434.
—— palpebrarum, 646.
Ring, crural, 310.
—— inguinal, 310.
—— umbilical, 308.
Rostrum of cochlea, 678.
——— of corpus callosum, 737.
Rotula, 95.
Rugæ, vaginal, 468.

Sac, lachrymal, 652.
Sacculus vestibuli, 680.
——— or sinus laryngis, 434.
Sacral arteries. See *Arteries.*
——— canal, 27.
——— foramina, 27.
——— nerves. See *Nerves.*
——— vertebræ. See *Vertebra* and *Vertebræ.*
Sacro-coccygeal vertebræ, 26.
—— sciatic notch, 92.
—— vertebral angle, or promontory, 26.
Sacrum, 26.
——— promontory of, 26.
——— small cornua of, 27.
Saliva, 396.
Salivary glands, 340.
Saphenous nerves. See *Nerves.*
Satellite arteries. See *Arteries.*
——— nerves. See *Nerves.*
Scaphoid bone of carpus, 83.
——— of tarsus, 101.
——— process, 101.
Scapula, 75.
Scapular arteries. See *Arteries.*
Schindylesis, 114.
Sciatic notch, 89.
—— spine, 89.
Scrobiculis cordis, 354, 482.
Scrotum, 447.
Second cranial nerve. See *Nerve, optic.*
Sella turcica, 37.
Semen, 453.
Semi-circular canals, and their ampullæ, 677.
——— membranous, 680.
——— lines of occipital bone, 33.
——— os coxæ, 89.
—— lunar bone, 83.
——— ganglion, of fifth nerve, 843.
Seminiferous tubes, 454.
Septa, inter-muscular, 294.
——— of arm, 315.
——— of thigh, 306.
Septum crurale, 303.
——— of dartos, 446.
——— inter-auricular, 482.
Septum, inter-ventricular (of brain), 518.
——— (of heart), 481.
——— lucidum, 738.
——— layers of, 738.
——— ventricle of, 738.
——— nasal, artery of, 518.
——— cartilaginous, 642.
——— osseous, 56, 62.
——— pectiniforme, 454.
Serrati muscles. See *Muscles.*
Sesamoid bones, 96.
——— of hand, 153.
——— of foot, 177.
——— of gastrocnemius, 164.
Seventh cranial nerve. See *Nerve, Portio Dura*, and *Portio Mollis.*
Sheath of brachial vessels, 316.
——— femoral vessels, 310.
——— for muscles, 296.
——— of arm, 316.
——— thigh, 311.
——— synovial, 178.
——— for tendons, 397.
——— around carpus, 319.
——— tarsus, 314.
——— structure of, 397.
——— for vessels, 396.
Shoulder, aponeuroses of, 315.
——— bones of, 73.
——— compared with pelvis, 105.
——— development of, general, 77.
——— in general, 77.
Sigmoid cavities, great and small, 80.
——— flexure, 371.
——— notch, 57.
——— valves, 484.
Sinus, or sinuses, aortic, 498.
——— basilar, 587.
——— of bones, 11.
——— of bulb of urethra, 459.
——— cavernous, 587.
——— circular, of Ridley, 588.
——— common, of vestibule, 680.
——— confluences of, 588.
——— coronary, of heart, 577.
——— of Ridley, 587.
——— of dura mater, 583.
——— ethmoidal, 43.
——— frontal, 36.
——— of internal jugular, 583.
——— lateral, or transverse, 584.
——— of larynx, or sinus of Morgagni, 584.
——— longitudinal, inferior, 586.
——— superior, 584.
——— maxillary, 52.
——— of Morgagni, 461.
——— occipital, anterior, 587.
——— posterior, 587.
——— ophthalmic, 587.
——— petrosal, inferior, 586.
——— superior, 586.
——— prostatic, 459.
——— sphenoidal, 40.
——— straight, 585.
——— transverse, or lateral, 584.
——— of urethra, 459.
——— uterine, 602.
——— of Valsalva, 498.
——— of veins, 575.
——— of vena portæ, 599.
——— venosus (heart), 492.
Sixth cranial nerve. See *Nerve.*
Skeleton, general view of, 5.
——— natural, 5.
——— artificial, 5.
Skin, 629.
—— appendages of, 635.
—— characters, external, 629.
Spine, cutis or dermis of, 630.
——— epidermis of, 632 (note).
——— follicles, sebaceous, 627.
——— functions of, 627.
——— glands, sudoriferous, 632.
——— lymphatics of, 631.
——— papillæ of, 639.
——— pigmentum of, 631, 632 (note).
——— pores of, 632.
——— rete mucosum, 633 (note).
——— structure of, 630–634.
——— true, 630.

Skull, 33. See *Cranium* and *Face.*
Socia parotidis, 341.
Sole of foot, 102.
Solitary glands. See *Glands.*
Space, inter-peduncular, 711, 728.
Spaces, inter-costal, 71.
——— osseous, hand, 84.
——— ——— ——— foot, 106.
——— sub-arachnoid, 688.
Sphenoidal cells, or sinuses, 39.
——— fissure, 39.
Sphenoid bone, 37.
Spheno-frontal suture, 47.
——— jugal suture, 47.
——— maxillary fissure, 39, 55.
——— ——— ——— fossa, 60.
——— occipital bone, 36.
——— ——— ——— suture, 47.
——— palatine foramen, 54.
——— parietal suture, 47.
——— spinous foramen, 39.
——— temporal fossæ, 48.
——— ——— suture, 47.
Sphincter muscles. See *Muscles.*
Spinal accessory nerve. See *Nerve, accessory.*
——— arteries. See *Arteries.*
——— cord, 693.
——— arachnoid of, 690.
——— enlargements of, cervical, lumbar, and occipital, 697.
——— enveloped in its proper membrane, 697.
——— extent and situation of, 694.
——— form, direction, and relations of, 696.
——— furrows or grooves, 698.
——— membrane proper, or neurilemma of, 697.
——— pia mater of, 697.
——— sections of, 700.
——— structure of, internal, 700.
——— examined by hardening, 702.
——— sections, 700.
——— water, 701.
——— substance, gray and white, 702.
——— minute structure, 702 (note).
——— ventricles of, 702.
——— muscles, posterior. See *Muscles.*
——— nerves. See *Nerves.*
——— veins and plexuses. See *Veins.*
Spine, nasal, anterior, 52.
——— ——— posterior, 54.
——— of ischium, 89.
——— of pubes, 89.
——— of scapula, 75.
——— sciatic, 89.
——— or spinal column, 18. See *Vertebral Column.*
——— of tibia, 97.
Spinous foramen of sphenoid, 39.
——— processes of ilium, 89.
——— ——— of vertebræ, 19, 21.
Splanchnic nerves. See *Nerves.*
Splanchnology, 320.
Spleen, 403.
——— cells of, 405.
——— coats of, 405.
——— corpuscules of, 407.
——— development of, 407.
——— fissure, or hilus, 405.
——— functions, 408.
——— lymphatics of, 407.
——— size of, differences in, 403.
——— structure of, 405.
——— vessels and nerves, 405, 408.
Spleens, supernumerary, 403.
Splenic artery, 406.
——— omentum, 405.
——— veins, 406.
Spongy bones. See *Bones.*
Stapes, 674.
Stenonian duct, 341.
Sternum, 64.
Stomach, 352.
——— alveoli of, 361.
——— coat of, cellular or fibrous, 357.
——— ——— mucous, 356.
——— ——— muscular, 356.
——— ——— nervous (so called), 356.
——— ——— serous, or peritoneal, 357.
——— culs-de-sac of, 354.
——— curvatures of, 354.
——— development of, 361.
——— extremities of, 354.
Stomach, follicles of, 360.
——— function, 361.
——— glands of, 360.
——— granular appearance of, 357.
——— lymphatic system of, 360.
——— orifices of, 355.
——— papillæ or villi, 359.
——— structure of, 356.
——— surface of, external, 353.
——— ——— ——— internal, 355.
——— tuberosity of, 355.
——— tubuli of, 360.
——— vessels and nerves of, 360.
Structure of tissues and organs. See those organs and tissues.
Styloid bone, 43.
——— process of temporal bone, 43.
——— ——— fibula, 99.
——— ——— radius, 81.
——— ——— ulna, 80.
Sub-arachnoid fluid, 690.
——— ——— uses of, 692.
——— space, cranial, anterior, 688.
——— ——— posterior, 688.
——— spinal, 689 (note).
——— lingual fossa, 58.
——— gland, 343.
——— ducts of, 343.
——— maxillary fossa, 58.
——— gland, 342.
——— ——— ——— duct of, 342.
——— synovial adipose tissue, 113.
Sulci. See *Cerebrum, anfractuosities of.*
Super-ciliary foramen, 36.
——— ridge, 35.
Superficial petrosal nerves. See *Nerves.*
Supplementary cavity of shoulder-joint, 139.
——— ——— of temporo-maxillary joint, 128.
Supra-orbitary foramen, 36, 59.
——— renal capsules, development of, 445.
——— ——— structure, 446.
——— sphenoidal fossa, 37.
——— spinous fossa, 76.
Sustentaculum tali, 101.
Suture, coronal, or fronto-parietal, 45, 47.
——— ethmoido-frontal, 48.
——— ethmo-sphenoidal, 48.
——— fronto-jugal, 48, 59.
——— ——— maxillary, 59.
——— ——— nasal, 59.
——— ——— sphenoidal, 48.
——— lambdoidal, or occipito-parietal, 46.
——— maxillary, 59.
——— palatine, 60.
——— petro-occipital, 47.
——— ——— sphenoidal, 48.
——— sagittal or bi-parietal, 46.
——— spheno-frontal, 47.
——— ——— jugal, 47.
——— ——— parietal, 47.
——— ——— temporal, 48.
——— squamous, 47.
——— temporo-parietal, 47.
——— transverse or spheno-occipital, 46, 49.
Sutures, 114.
——— indented, squamous, and harmonic, 114.
——— cranial, in general, 154.
Sympathetic ganglia in particular. See *Ganglia.*
——— nerves. See *Nerves.*
——— plexuses, in particular. See *Plexuses.*
——— system, in particular. See *Ganglia* and *Nerves.*
Symphyses, characters of, 114.
Symphysis menti, 57.
——— pubis, 89, 155.
——— sacro-iliac, 155.
Synarthroses, 114.
——— characters, ligaments, and motions, 115.
Synchondroses, 113.
Syndesmology, 111.
Syneuroses, 113.
Synovia, 112.
Synovial bursæ, 178.
——— capsules, 112.
——— ——— of particular joints. See those joints.
——— fringes, 112.
——— ——— in the knee, 164.
——— glands (so-called), 112.
——— membranes, articular, general characters of, 112.

Synovial membranes, bursal, 178, 298.
——— minute structure of, 178.
——— vaginal, 178, 299.
——— sheaths for tendons, 178, 298.
Syssarcoses, 114.

Tænia hippocampi, 746.
——— semicircularis, 740, 745.
Tarsus, bones of, 99.
——— first row of, 100.
——— compared with first row of carpus, 107.
——— second row of, 101.
——— compared with second row of carpus, 107.
——— compared with carpus, 108.
——— sheaths for tendons on, 313.
Teeth, 177.
——— arteries of, 182.
——— bicuspid, 179.
——— bulbs of, 181.
——— canine, 180.
——— cement of, 182.
——— changes in, after eruption, 190.
——— characters of, general, 179.
——— differential, 179.
——— classification of, 178.
——— compared with bones, 183 (note).
——— epidermoid appendages, 177.
——— compound, 182.
——— conformation of, external, 179.
——— internal, 181.
——— cortical portion of, 181.
——— substance of, proper, 182.
——— crowns of, 179.
——— crusta petrosa of, 182, and note.
——— cuspid, 179.
——— development of, 183.
——— different stages of, 184.
——— distinguished from bones, 177.
——— enamel of, 182.
——— chemical composition of, 182.
——— development of, 186.
——— structure of, 183 (note).
——— fangs of, 178.
——— formation of, 186.
——— follicles of, 185.
——— (Goodsir), 183 (note).
——— general idea of, 190.
——— incisor, 179.
——— ivory of, 183.
——— chemical composition of, 182.
——— development of, 185.
——— structure of, 182 (note).
——— milk. See *Temporary*.
——— molar, 180.
——— great and small, 180.
——— upper and lower compared, 181.
——— multi-cuspid, 181.
——— nerves of, 181.
——— number of, 177.
——— permanent, 177.
——— decadence of, 190.
——— development of, 190.
——— differences of, from temporary, 190.
——— eruption of, 189.
——— follicular stage of, 184.
——— origin of pulps and sacs of, 184.
——— papillary stage of, 184.
——— saccular stage of, 185.
——— provisional. See *Temporary*.
——— pulps of, 181.
——— origin of, 184.
——— quadri-cuspid, 181.
——— sacs of, 186.
——— origin of, 184.
——— simple, 183.
——— structure, general, 181.
——— minute, 183.
——— supernumerary, 187.
——— tartar of, 183.
——— temporary, 177.
——— development of, 183.
——— differences of, from permanent, 190.
——— eruption of, 183.
——— follicular stage of, 180.
——— origin of pulps and sacs of, 184.
——— papillary stage of, 184.
——— saccular stage of, 184.
——— shedding of, 188.
Teeth, wisdom, 181.
——— uses of, 189.
——— two sets of, 189.
Tela choroidea, 731.
Temporal arteries. See *Arteries*.
——— bone, 42.
——— fossa, 47.
——— nerves. See *Nerves*.
Temporo-parietal suture, 47.
Tendo Achillis, 283.
Tendon of Zinn, 650.
——— straight of orbicularis palpebrarum, 653.
Tendons of muscles, 193.
——— structure of, 299.
Tensor muscles. See *Muscles*.
Tentorium cerebelli, 684.
Testes (of brain), 712.
Testicles, 446.
——— coverings of, 446.
——— excretory duct of, 452.
——— proper coat of, 449.
——— structure of, 449.
——— tubuli of, 450.
——— tunica albuginea, 449.
——— erythroides, 447.
——— propria, 449.
——— vaginalis, 447.
——— vessels and nerves of, 451.
Testis, coni vasculosi of, 452.
——— mediastinum, 450.
——— rete vasculosum, 451.
——— tubuli, 450.
Testicular artery, 451.
Thalami optic, 742.
——— structure of, 744.
Thigh bone, 93.
——— compared with arm bone, 105.
Third cranial nerve. See *Nerve*.
Thoracic arteries. See *Arteries*.
Thorax, aponeuroses of, 300.
——— articulations of, 130.
——— bones of, 64.
——— development of, general, 72.
——— general description of, 70.
——— mechanism of, 132.
——— movements of, in general, 134.
——— one rib of, 132.
Thyro-arytenoid ligaments. See *Chordæ Vocales*.
Thyroid arteries. See *Arteries*.
——— veins. See *Veins*.
Tibia, 96.
——— and ulna, upper parts of, compared, 107.
——— radius, lower parts of, compared, 107.
Tibial arteries. See *Arteries*.
——— nerves. See *Nerves*.
Tissue, adipose, 175.
——— bony, 12, 13.
——— cartilaginous, 174.
——— cellular, 298.
——— elastic, 174.
——— fibro-cartilaginous, 174.
——— cellular, 298.
——— fibrous, 298.
——— ligamentous, 174.
——— muscular, 198.
——— nervous, 757.
——— tendinous, 289.
Toes, articulations of, 174.
——— bones of, 104.
——— phalanges of, 104.
Tongue, 332.
——— bone of, 333.
——— development of, 336.
——— dorsum of, 332.
——— frænum of, 333.
——— lymphatics of, 646.
——— median cartilage of, 333.
——— mucous membrane of, 646.
——— muscles of, 333.
——— extrinsic, 334.
——— intrinsic, 334.
——— nerves of, 646.
——— papillæ of, 333.
——— rete mucosum of, 646.
——— structure of, 334.
——— uses of, 339.
——— vessels, 339.
Tonsils, 333.
——— of cerebellum, 718.
Torcular Herophili, 588.

Trabeculæ of corpus cavernosum, 455.
——— spleen, 405.
Trachea, 416.
——— cervical portion, 416.
——— glands of, 416.
——— structure of, 416.
——— thoracic portion, 416.
——— vessels and nerves, 416.
Tractus spiralis foraminulentus, 678.
Tragic fossa, 668.
Tragus, 666.
——— ligament of, 666.
Transversales muscles. See *Muscles.*
Transverse arteries. See *Arteries.*
——— muscles. See *Muscles.*
——— suture, 46, 47.
——— veins. See *Veins.*
Transverso-spinalis muscle. See *Muscle.*
Trapezium, 83.
Trapezoid bone, 83.
——— ligament, 136.
Triangulares muscles. See *Muscles.*
Triceps muscles. See *Muscles.*
Trifacial, or trigeminal nerve. See *Nerve.*
Trochanteric cavity, or fossa, 95.
Trochanters of femur, 95.
——— of humerus, 79.
Trochlea, femoral, 95.
——— humeral, 79.
——— of orbit, 651.
Trochlear articulations, characters of, &c., 114.
——— nerve. See *Nerve, pathetic.*
Trochoid articulations, characters of, &c., 114.
Tube, Eustachian. See *Eustachian Tube.*
——— Fallopian, 463.
Tuber annulare. See *Pons Varolii.*
——— cinereum, 729.
Tubercle, ash-coloured, of Rolando, 703.
——— lachrymal, 645.
——— laminated, 717.
——— of Lower, 488.
Tubercles of Santorini, in larynx, 424.
——— in nose, 640.
Tubercula quadrigemina, or bigemina, 712.
——— structure of, 714.
Tuberosities, calcaneal, 102.
——— of femur, 95.
——— of humerus, 79.
——— of tibia, 97.
Tuberosity, bicipital, 81.
——— of ischium, 89.
——— maxillary, 51.
Tubes of Bellini, 437.
Tubuli of intestine. See *Intestine.*
——— recti, of kidney, 437.
——— of testicle, 452.
——— seminiferi, 452.
——— of stomach, 361.
——— uriniferi, convoluted, 437.
——— straight, 437.
Tubulus centralis modioli, 679.
Tunica adnata, 648.
——— albuginea testis, 449.
——— conjunctiva, 648.
——— erythroides, 448.
——— propria testis, 449.
——— Ruyschiana, 657.
——— sclerotica, 654.
——— vaginalis testis, 448.
——— vasculosa testis, 449 (note).
Tunics of eye. See *Eye.*
Turbinated bone, inferior, 56.
——— middle, 41.
——— superior, or ethmoidal, 41.
——— sphenoidal, 38.
Tympanic bone, circle, or ring, 45.
Tympanum, bones in, 674.
——— circumference of, 672.
——— lining membrane of, 670.
——— membrane of, 675.
——— secondary, 671.
——— orifice of, cochlear, 671.
——— vestibular, 670.
——— recess of, 672.
——— wall of, external, 669.
——— internal, 670.

Ulna, 79.
——— and tibia, upper parts of, compared, 107.
Umbilicus, 308.
Unciform bone, 83.
——— eminence, 730.
Unguis, 730.
Urachus, 443.
Ureter, 440.
——— structure of, 441.
——— orifices of, 444.
——— muscles of, 445.
——— valve of, 444.
Urethra, female, 469.
——— muscles of, 470.
——— male, 457.
——— bulb of, 459.
——— dilatations, or sinuses, 459.
——— internal surface, 459.
——— lacunæ, 460.
——— membranous portion, 459.
——— muscles of, 457.
——— prostatic portion of, 457.
——— spongy portion of, 459.
——— structure of, 460.
Urinary apparatus, 435.
Uterine veins, 467.
Uterus, 464.
——— cavity and mouth of, 465.
——— cervix or neck of, 465.
——— coat, mucous, 467.
——— serous, 467.
——— development, 468.
——— follicles of, 466.
——— functions of, 468.
——— fundus of, 466.
——— glands, tubular, of, 468 (note).
——— gravid, fibres of, 467.
——— sinuses of, 467.
——— vessels and nerves of, 464.
——— ligaments of, broad, 466.
——— round, 466.
——— nerves of, 468.
——— structure of, 466.
——— vessels of, 468.
Utriculus vestibuli, 681.
Uvea, 670.
Uvula, 332.
——— vesicæ, 459.
——— cerebelli, 715 (note).

Vagina, 468.
——— bulb of, 469.
——— columns and rugæ of, 468.
——— development of, 469.
——— mucous membrane of, 469.
——— muscles of, 469.
——— structure of, 468.
Vaginal process of temporal bone, 44.
Valve of Bauhin, 372.
——— Eustachian, 486.
——— ileo-cœcal, 372.
——— colic, 372.
——— mitral, 484.
——— pyloric, 352.
——— of Thebesius, 486.
——— tricuspid, 484.
——— of Vieussens, 711.
——— columella of, 712.
Valves of Kerkringius, 365.
——— of heart. See *Heart.*
——— of intestines. See *Intestine.*
——— of lymphatics, 617.
——— semilunar, or sigmoid, 484.
——— of Tarin, 720.
——— of veins, 575.
Valvulæ conniventes, 365.
Vas aberrans, 452.
——— deferens, 452.
——— structure, 452.
Vasa afferentia, lymphatic, 614.
——— brevia, arterial, 509.
——— venous, 599.
——— efferentia of epididymis, 451.
——— lymphatic, 614.
——— sudatoria, 634.
——— vasorum of arteries, 520.
——— of veins, 576.
——— vorticosa, 587, 665.
Veins, in general, 573.
——— anastomoses of, 574.
——— branches of, 575.
——— coats of, 576.
——— course of, 574.

Veins, deep, 574.
——— method of description of, 577.
——— nerves of, 576.
——— origin of, 574.
——— plexuses of, 574.
——— preparation of, 576.
——— relations of, with arteries, 575.
——— satellite, 574.
——— sinuses of, 575.
——— structure of, 576.
——— sub-cutaneous, 574.
——— superficial, 574.
——— termination of, 575.
——— valves of, 575.
——— varieties of, 575.
——— vasa vasorum of, 575.
——— vessels of, 575.
——— in particular, 577.
——— abdominal sub-cutaneous, 604.
——— of ala of nose, 588.
——— alveolar, 589.
——— angular, 588.
——— of the arm, superficial, 594.
——— articular, of knee, 603.
——— ascending cervical, 580.
——— lumbar, 606.
——— auricular anterior, 590.
——— posterior, 590.
——— axillary, 593.
——— azygos, general remarks on, 607.
——— great, 605.
——— lesser, 606.
——— lumbar, 607.
——— basilic, 595.
——— brachial, 597.
——— brachio-cephalic, left and right, 579.
——— bronchial, left, 420.
——— right, 420, 606.
——— distribution of, 421.
——— buccal, 589.
——— calcaneal, internal, 604.
——— capsular, inferior and middle, 597.
——— cardiac, great, 578.
——— small, 578.
——— cava, ascending or inferior, 596.
——— descending or superior, 578.
——— cephalic, 595.
——— of thumb, 594.
——— cerebral, inferior, anterior, 587.
——— lateral, 584.
——— median, 586.
——— internal, 585.
——— superior, 585.
——— median, 586.
——— cerebellar, anterior lateral, 586.
——— inferior lateral, 584.
——— cervical, ascending, 580.
——— deep, 580.
——— choroid, 586.
——— of eye, 658.
——— ciliary, 587.
——— circumflex, brachial, 598.
——— femoral, 603.
——— iliac, 603.
——— colic, left and right, 599.
——— coronary of the heart, anterior, 578.
——— great, 578.
——— lips, inferior, 589.
——— superior, 589.
——— stomach, 362.
——— of the corpus cavernosum, 601.
——— striatum, 586.
——— deep cervical, 580.
——— femoral, 603.
——— dental, anterior, 589
——— inferior, 590.
——— superior, 589
——— diaphragmatic, 601.
——— diploic, 585, 591.
——— dorsal of the foot, deep, 602.
——— external, 603.
——— internal, 603.
——— nose, 588.
——— penis, 601.
——— dorsi-spinal, 608.
——— of the dura mater, 583.
——— at the elbow, 595.
——— emulgent, 598.
——— epigastric, deep, 603.
——— superficial, 603.
Veins, facial, 588.
——— posterior, 589.
——— of the falx cerebri, 586.
——— femoral, 603.
——— deep, 603.
——— frontal, 587.
——— of Galen in brain, 584.
——— heart, 577.
——— gastro-epiploic, 361.
——— gluteal, 601.
——— of hand, superficial, 594.
——— hemorrhoidal, inferior, 601.
——— middle, 601.
——— superior, 601.
——— head, general remarks on, 592.
——— hepatic, 600.
——— in the liver, 391, 392.
——— hypo-gastric, 601.
——— iliac, common, 600.
——— external, 603.
——— internal, 601.
——— ilio-lumbar, 607.
——— infra-orbital, 589.
——— innominate of Meckel, 579.
——— of Vieussens, 578.
——— inter-costal, 607.
——— superior, left, 606.
——— right, 606.
——— lobular, of liver, 391 (note).
——— of intestines, 599.
——— intra-lobular, of liver, 393 (note).
——— spinal, 609.
——— anterior, longitudinal, 609.
——— transverse, 609.
——— lateral, 610.
——— posterior, longitudinal, 610.
——— transverse, 610.
——— compared with cranial, 610.
——— jugular, 581.
——— anterior, 582.
——— external, 581.
——— internal, or deep, 583.
——— posterior, 607.
——— laryngeal, inferior, 580.
——— superior, 582.
——— lingual, 590.
——— longitudinal of scull, inferior, 586.
——— spine. See *Intra-spinal.*
——— of lower extremity, deep, 602.
——— superficial, 603.
——— lumbar, or vertebro-lumbar, 597.
——— ascending, 606.
——— azygos, 607.
——— mammary, internal, 580.
——— masseteric, anterior, 589.
——— posterior, 590.
——— mastoid, 584, 590.
——— maxillary, external, 588.
——— internal, 589.
——— median of the arm, 595.
——— basilic, 595.
——— cephalic, 595.
——— mediastinal, 580, 606.
——— medullary, 610.
——— meningeal, 591.
——— middle, 590.
——— mesaraic, 599.
——— mesenteric, inferior or small, 599.
——— superior or great, 599.
——— nasal, 588.
——— obturator, 601.
——— occipital, deep, 590.
——— superficial, 589.
——— œsophageal, 606.
——— omphalo-mesenteric, 599.
——— ophthalmic, 587.
——— orbital, external, 589.
——— ovarian, 598.
——— palatine, inferior, 589.
——— superior, 589.
——— palmar, 593.
——— palpebral, external, 589.
——— inferior, 588.
——— pancreatic, 402.
——— parotid, 590.
——— of particular organs or tissues. See those organs or tissues.
——— of pelvis, in female, 602.
——— male, 601.
——— of penis, 601.

Veins, pericardiac, 580.
——— peroneal, 602.
——— pharyngeal, 591.
——— phrenic, inferior, 598.
——— superior, 580.
——— plantar, 602.
——— popliteal, 602.
——— portal, or vena portæ, 597, 599.
——— branches of origin of, 598.
——— in the liver, 390.
——— sinus of, 599.
——— profunda cervicis, 580.
——— femoris, 603.
——— pterygoid, 590.
——— pudic, external, 604.
——— internal, 601.
——— pulmonary, 577.
——— distribution of, 421.
——— rachidian. See *Spinal*.
——— radial cutaneous, 595.
——— deep, 594.
——— ranine, 590.
——— renal, 597.
——— sacral, lateral, 607.
——— middle, 607.
——— salvatella, 594.
——— of Santorini, 585.
——— saphenous, external, 605.
——— internal, 603.
——— second, 604.
——— satellite, of lingual nerve, 590.
——— scapular, superior, 582.
——— posterior, 582.
——— sciatic, 601.
——— scrotal, 601.
——— semi-azygos, 606.
——— short, of stomach, 599.
——— spermatic, left and right, 598.
——— spheno-palatine, 589, 591.
——— spinal, 605.
——— deep. See *Intra-spinal*.
——— general remarks on, 611.
——— posterior, deep. See *Intra-spinal*.
——— superficial, 608.
——— superficial, 605.
——— in neck, 608.
——— posterior, 608.
——— of spinal cord, 610.
——— splenic, 599.
——— distribution of, 406.
——— stylo-mastoid, 590.
——— sub-clavian, left and right, 593.
——— mental, 589.
——— supra-orbital, 588.
——— renal, inferior and middle, 598.
——— scapular, 581.
——— sural, 603.
——— temporal, 589.
——— deep, 590.
——— middle, 589.
——— superficial, 589.
——— temporo-maxillary, 589.
——— of Thebesius, 578.
——— thymic, 580.
——— thyroid, inferior, 580.
——— middle, 591.
——— superior, 591.
——— tibial, anterior, 602.
——— posterior, 602.
——— tibio-peroneal, 602.
——— tonsillar, 333.
——— transverse, cervical, 582.
——— facial, 590.
——— humeral, 582.
——— ulnar cutaneous, anterior, 595.
——— posterior, 595.
——— deep, 592.
——— umbilical, 600.
——— of upper extremity, deep, 592.
——— superficial, 593.
——— uterine, 467, 601, 602.
——— vaginal, 602.
——— vasa brevia, 599.
——— vorticosa, 587.
——— ventricular, cerebral, 586.
——— of vertebræ, 610.
——— vertebral, 581.
——— vertebro-costal, inferior, 606.
——— superior, left, 606.
——— right, 605.
Veins, vertebro-lumbar, 607.
——— vesical, female, 602.
——— male, 601.
——— vidian, 589.
Velum interpositum, 731, 740.
——— medullare, anterior, 713.
——— posterior, 718 (note).
——— palati, 331. See *Palate, soft*.
——— pendulum palati, 331.
Vena cava inferior, or ascending, 596.
——— superior, or descending, 578.
Venæ comites, 572.
——— minimæ, 508.
Venous plexuses. See *Plexuses*.
——— system generally, 572.
Venter ilii, or internal iliac fossa, 88.
Ventricle of Arantius, 704.
——— of corpus callosum, 737.
——— fifth, 738.
——— fourth, 718.
——— choroid plexuses of, 720.
——— fibrous layers of, 719.
——— fossette of, 704.
——— laminated tubercle of, 717.
——— orifice, inferior, 719.
——— semilunar fold of, 719.
——— valves of base of, 719.
——— of larynx, 424.
——— lateral, 744.
——— body of, 744.
——— cornu anterior, 744.
——— descending, 744.
——— posterior, 744.
——— of septum lucidum, 738.
——— third, 729, 741.
——— choroid plexuses of, 741.
——— commissure of, anterior, 742.
——— posterior, 742.
——— soft or gray, 729, 741.
——— floor of, anterior part of, 729.
——— middle and posterior part of, 729.
——— openings of, 742.
Ventricles, cerebral, fluid of, 744.
——— lining membrane of, 747.
——— Gall's views regarding, 750.
——— of heart. See *Heart*.
——— of spinal cord, 701.
Ventriculus, 352.
——— succenturiatus, 362.
Vermiform appendix, 373.
——— process, inferior, 716.
——— superior, 716.
Vertebra, cervical, first, 23.
——— second, 24.
——— seventh, 25.
——— dentata, 24.
——— dorsal, first, 25.
——— eleventh and twelfth, 25.
——— general description of, 19.
——— lumbar, fifth, 26.
——— prominens, 25.
Vertebræ, articular processes of, in different regions, 22.
——— articulations of. See *Articulations*.
——— bodies of, in different regions, 20.
——— cervical, 19.
——— characters of, general, 19.
——— distinctive, 20.
——— proper, 22.
——— coccygeal, 19.
——— development of, 31.
——— dorsal, 19.
——— false, 19.
——— foramen of, in different regions, 19.
——— internal structure of, 31.
——— laminæ of, in different regions, 20.
——— ligaments of. See *Ligaments*.
——— lumbar, 19.
——— notches of, in different regions, 20.
——— number of, 19.
——— sacral, 19.
——— sacro-coccygeal, 26.
——— union of, 32.
——— spinous processes of, in different regions, 22.
——— transverse processes of, in different regions, 23.
——— true, 19.
Vertebral canal, 30.
——— column, 19.
——— articulations of, 115–123.

Vertebral column, curvatures of, 28.
——————— development of, 32.
——————— dimensions of, 28.
——————— figure and aspects of, 29.
——————— movements of entire, 121-123.
——— grooves, 29.
——— ligaments. See *Ligaments*.
Vertebro-costal veins. See *Veins*.
Verumontanum, 461.
Vesica fellea, 394.
—— urinaria, 440.
Vesicles, Graafian, 461.
Vesiculæ seminales, 453.
——————— efferent duct of, 454.
——————— structure, 454.
Vestibule of ear, 676.
——— aqueduct of, 676.
——— calcareous matter of, 681.
——— crista of, 676.
——— foveæ and recessus sulciformis, 676.
——— membranous, 680.
——— openings into, 676.
——— sacculus of, 680.
——— sinus, common, or utricle of, 680.
Visceral nerves. See *Nerves*.
Vitreous table of cranial bones, 35.
Vocal cords, 426.
Vomer, 57.
Vulva, 470.
——— development of, 471.
——— fourchette, 470.
——— mucous membrane, 471.
——— parts of, 470.

Wings of sphenoid bone, lesser, 37.
——————— great, 38.
——— Ingrassius, 37.
Womb. See *Uterus*.
Wormian bones, 50.
Wrist. See *Carpus*.

Xiphoid cartilage, or appendix, 65.

Zinn, zone of, 655.
Zonula Zinni, 655.
Zygoma, 61.
Zygomatic arch, 61.
——— bone, 54.
——— canal, 55.
——— fossa, 61.
——— process of temporal bone, 42.
——————— malar bone, 55.

THE END.

J. A. Brooks
Feby 26th 1845
New York