

**1000 surgical suggestions : practical brevities in diagnosis and treatment /  
by Walter M. Brickner ; with the collaboration of Eli Moschcowitz ; James P.  
Warbasse ; Harold Hays ; Harold Neuhoof.**

### **Contributors**

Brickner, Walter Max, 1870-1930.  
Neuhoof, Harold, 1884-  
Moschcowitz, Eli, 1879-  
Warbasse, James Peter, 1866-1957.  
Hays, Harold, 1880-1940.  
Francis A. Countway Library of Medicine

### **Publication/Creation**

New York : Surgery Publishing Company, 1911.

### **Persistent URL**

<https://wellcomecollection.org/works/ssr2r9jc>

### **License and attribution**

This material has been provided by This material has been provided by the Francis A. Countway Library of Medicine, through the Medical Heritage Library. The original may be consulted at the Francis A. Countway Library of Medicine, Harvard Medical School. where the originals may be consulted. This work has been identified as being free of known restrictions under copyright law, including all related and neighbouring rights and is being made available under the Creative Commons, Public Domain Mark.

You can copy, modify, distribute and perform the work, even for commercial purposes, without asking permission.



Wellcome Collection  
183 Euston Road  
London NW1 2BE UK  
T +44 (0)20 7611 8722  
E [library@wellcomecollection.org](mailto:library@wellcomecollection.org)  
<https://wellcomecollection.org>



1000  
SURGICAL SUGGESTIONS

WALTER M. BRICKNER, M. D.



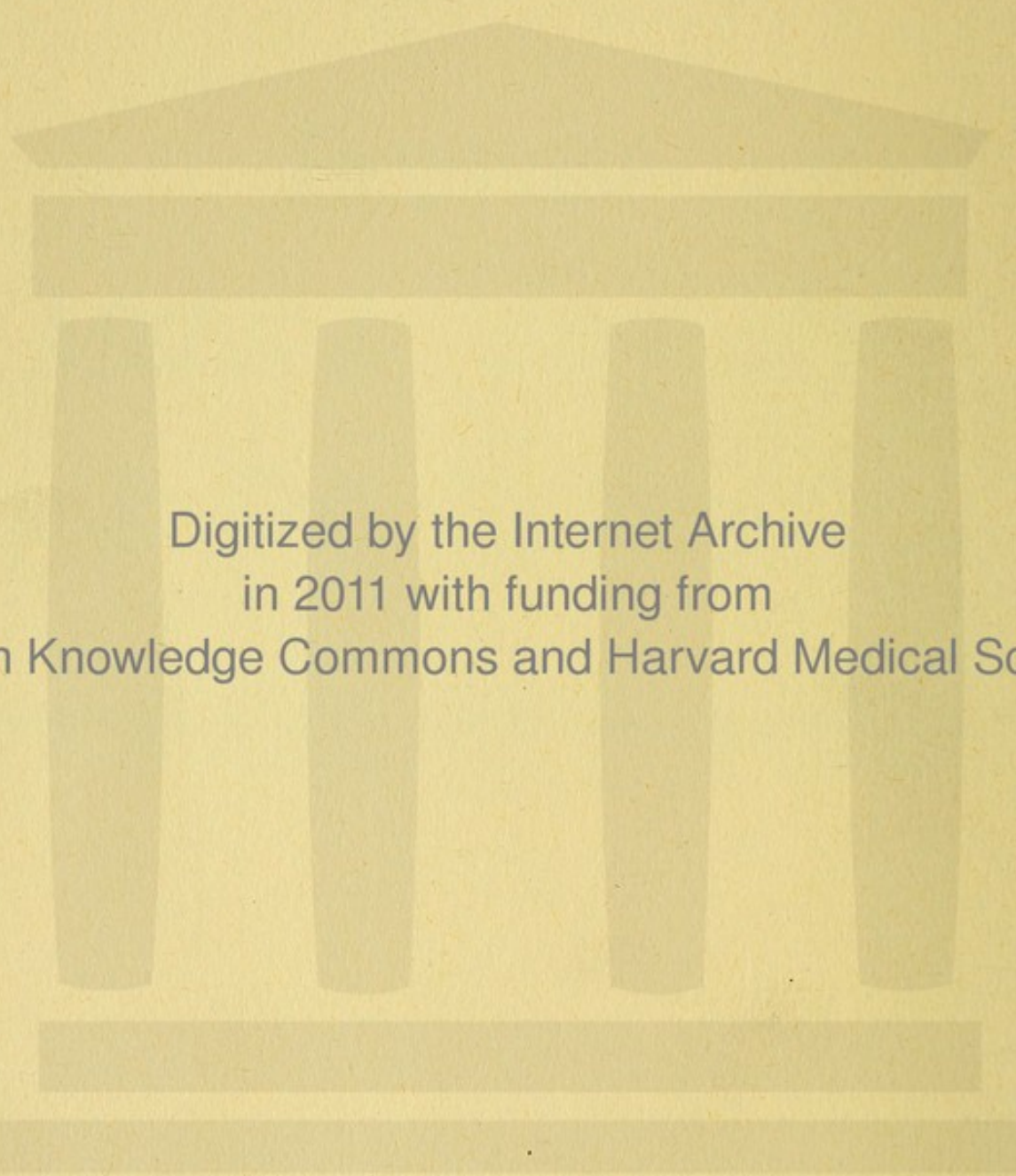


*BOSTON*  
*MEDICAL LIBRARY*  
*8 THE FENWAY*



DR. GEORGE W. KAAH,  
WARREN CHAMBERS,  
419 BOYLSTON ST.,  
BOSTON.





Digitized by the Internet Archive  
in 2011 with funding from  
Open Knowledge Commons and Harvard Medical School



1000  
**SURGICAL SUGGESTIONS**

PRACTICAL BREVITIES  
IN DIAGNOSIS AND TREATMENT

BY  
**WALTER M. BRICKNER, B.S., M.D.**

New York.

*Adjunct Surgeon, Mount Sinai Hospital;  
Editor-in-Chief, American Journal of Surgery.*

With the collaboration of

**ELI MOSCHCOWITZ, M.D.,  
JAMES P. WARBASSE, M.D.,  
HAROLD HAYS, M.D.,  
and  
HAROLD NEUHOF, M.D.**

New York.

*Associate Editors, American Journal of Surgery.*

**FOURTH AMERICAN EDITION**



New York, U. S. A.  
SURGERY PUBLISHING COMPANY  
92 William Street  
1911



23.D.27

Copyright, 1911

By

SURGERY PUBLISHING COMPANY

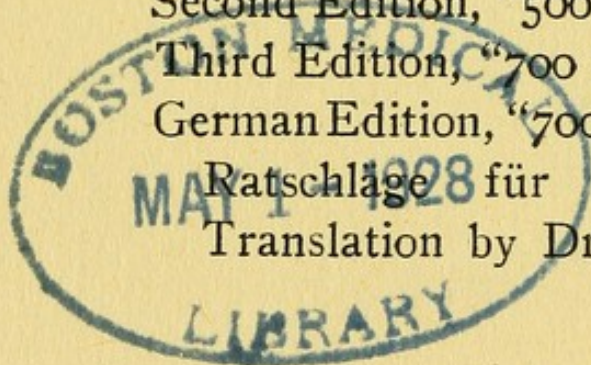
First Edition, "Surgical Suggestions," 1906.

Second Edition, "500 Surgical Suggestions," 1907.

Third Edition, "700 Surgical Suggestions," 1909.

German Edition, "700 Diagnostisch-therapeutische  
Ratschläge für die chirurgische Praxis."

Translation by Dr. Ernst Schümann, 1910.





## PREFACE TO FOURTH EDITION.

"Surgical Suggestions" has quadrupled in size since its first edition in 1906. The continued demand for the exhausted issue of "700 Surgical Suggestions," its translation into German, and the flattering comments of journal reviews have stimulated the publication of this enlarged edition.

The previous "Suggestions" have been revised—some altered, some rearranged and a few omitted. Three hundred have been added, many of them relating to recent surgical innovations.

As before, these suggestions make no effort at completeness and, with some exceptions, they are offered with no pretensions to originality of observation. They are, however, based on experiences in our own practice or on those noted in the practice of our colleagues.

If among these thousand therapeutic hints and diagnostic "wrinkles" each reader finds but a few helpful "tips" that are new to him, this little book will have continued to serve a useful purpose.

W. M. B.

30 West 92d Street,  
New York, March, 1911.



## PREFACE TO FIRST EDITION.

The "Surgical Suggestions" published during the past year in the successive issues of the *American Journal of Surgery* have been extensively quoted in medical journals throughout the United States and Canada. This has suggested to us that their arrangement in logical order, and in a concise form, might prove of value.

These practical brevities make no pretensions to completeness. They are merely observations taken here and there from our own surgical experiences.

W. M. B.  
E. M.

April, 1906.



# CONTENTS


	Page
ASEPSIS - - - - -	7
GENERAL TECHNIQUE - - - - -	9
HEAD - - - - -	10
Scalp - - - - -	10
Cranium - - - - -	15
Brain - - - - -	16
Ear - - - - -	19
Eye - - - - -	26
Nose - - - - -	33
Face - - - - -	38
Maxillæ - - - - -	40
Mouth - - - - -	41
Pharynx - - - - -	43
NECK - - - - -	47
Trachea - - - - -	53
Tracheotomy - - - - -	54
BREAST - - - - -	55
THORAX - - - - -	58
ABDOMEN - - - - -	66
Bile Tract - - - - -	76
Stomach - - - - -	81
Intestines - - - - -	88
Appendix - - - - -	93
HERNIA - - - - -	99
RECTUM - - - - -	104
GENITO-URINARY TRACT - - - - -	110
Kidney and Ureter - - - - -	110
Bladder - - - - -	116
Prostate - - - - -	121
Penis and Urethra - - - - -	123
Scrotum and Testicle - - - - -	127



# CONTENTS—Continued

	Page
FEMALE GENERATIVE ORGANS - -	130
Vulva and Vagina - - - - -	130
Uterus - - - - -	132
Adnexa - - - - -	136
BACK - - - - -	140
EXTREMITIES - - - - -	142
Upper Extremity - - - - -	145
Hand - - - - -	150
Lower Extremity - - - - -	154
Foot - - - - -	160
Bones - - - - -	165
Joints - - - - -	168
FRACTURES - - - - -	170
FOREIGN BODIES - - - - -	181
LYMPHATICS - - - - -	186
SKIN - - - - -	187
WOUNDS - - - - -	189
TUMORS - - - - -	192
TUBERCULOSIS - - - - -	194
SYPHILIS - - - - -	195
ANESTHESIA - - - - -	196
INFUSION AND TRANSFUSION - - -	200
POST-OPERATIVE - - - - -	201
HEMORRHAGE AND SHOCK - - - - -	206
SEPSIS - - - - -	208
INSTRUMENTS - - - - -	208
SUTURES - - - - -	214
EXAMINATIONS - - - - -	215
DRESSINGS - - - - -	218





1000

## SURGICAL SUGGESTIONS.



### ASEPSIS

The essence of asepsis during operations consists in handling nothing, even though sterilized, without a definite reason.

When operating upon or dressing suppurative lesions (especially those of pleura, pericardium, joint, etc.), it is a serious mistake to disregard aseptic technique. The danger of secondary infection must always be borne in mind.

Tincture of iodine painted over the dry skin is the quickest and probably the best means of disinfecting the field of operation. No washing of the skin should be done unless on the day before. If shaving has not been done previously, shave dry before painting with iodine.

At the conclusion of an operation in which iodine has been used to disinfect the skin field, remove the excess of the drug by wiping with



alcohol or ether. This may save the patient much discomfort.

It defeats the very purpose of the "boiled hand" if, in adjusting sterile rubber gloves, any part of their outer surface is allowed to touch any portion of the bare, albeit "scrubbed-up" hands. Following is the ideal method of drawing on sterile gloves: They should be dry (preferably steam-sterilized, or, next best, boiled and dried between towels), with a wide cuff turned back on each. Rub sterile talcum powder over the scrubbed-up hands. With the right thumb and forefinger lift the left glove by the turned-over margin and draw it on the left hand. Now lift up the right glove by passing under its turned-down cuff in front two or three fingers of the left hand. The fingers still in this position, turn back the cuff after the right glove is on. Now turn back the cuff of the left glove in a similar way. Never adjust the glove fingers until both hands are covered; never put the gloved thumb inside the opposite glove.

When rubber gloves are put on wet, add a little lysol to the water; it facilitates the adjustment immensely. Those whose hands are very



sensitive to cresols may use, instead, lubrichondrine or similar lubricant.

If during an operation a rubber glove tears or is cut, change it or draw on a sterile finger cot. The skin exposed by a torn glove is, by reason of the perspiration and the maceration of epithelium, more apt to contaminate the wound than is the well disinfected ungloved hand.

Smearing vaseline over the buttocks in a rectal examination, scratching the furniture with basins, spattering the carpet with plaster of Paris, are some of the "little things" that will lead some patients to consult thereafter surgeons with more neatness, if less skill.

## GENERAL TECHNIQUE

To develop manual dexterity practice tying surgical knots.

Not only in the abdomen but everywhere else in the body—with the sole exception of the brain—when in doubt, drain!

When draining a deep-seated abscess found by aspiration, do not remove the needle until the abscess has been freely opened. One may



replace the needle by a grooved director, however.

The presence of diabetes should not in itself deter the surgeon from giving a patient with that malady the benefit of relief from a surgical disease.

When clamping a vein in continuity secure the proximal end first; otherwise it will empty and may become lost to view.

For temporary occlusion of a large vessel a soft clamp, compressing fingers or angulation by traction on a tape or silk strand placed beneath, are all to be preferred to the application of a ligature, which may damage the vessel wall.

## HEAD

To secure the Trendelenburg position in an emergency without a special table, an assistant may stand between the patient's thighs with his back to the perineum, and hold the legs over his shoulders.

## Scalp

No scalp wound is too small to receive scrupulous aseptic attention.



Transverse scalp wounds require comparatively many sutures, longitudinal wounds but few.

Placing the skin sutures in the scalp obliquely will often control hemorrhage from a wound as well as will ligating separate vessels.

If a scalp wound extends through the periosteum it is safest to sew the periosteal wound at once and leave the scalp unsutured for twenty-four hours. Fracture should be excluded, if possible, before closing the periosteum.

Depilatories are useful in the preparation of the scalp for the treatment of abscesses or infected wounds, when the nature of the infection or the matted condition of the hair makes shaving difficult.

A small, hard, irregularly nodular scalp tumor is very likely an endothelioma. A little section should be removed under local anesthesia for microscopical examination. If the diagnosis is corroborated, radical extirpation is necessary.



Lipomata of the scalp often undergo cystic degeneration. A tumor which grossly may look like a lipoma, may show under the microscope evidences of sarcoma. Fortunately these sarcomata of the scalp do not often form metastases.

Lipoma of the scalp may also simulate a wen. Both grow gradually, are semi-fluctuating and are movable on the deeper parts. Aspiration for diagnostic purposes is not a wise procedure, for if the tumor be a cyst, the contents may readily flow out through a puncture hole, making it difficult to remove the cyst wall at operation.

A small meningocele may resemble a sebaceous cyst. The previous history is important in the diagnosis. A meningocele of this character is present "as long as the patient can remember" and remains about the same size; a cyst begins as a small nodule later on in life and increases in size.

An abscess of the scalp and a suppurating occipital lymph gland may also present the physical characteristics of an inflamed seba-



ceous cyst. It is of some importance to make the differential diagnosis since, although incision and drainage are required for all three, removal of the capsule is to be sought in wens and curettage may be required of the gland abscess.

A severe neuralgia at the back of the head and neck in many instances can be relieved when all other means have failed, by severance of the occipital nerves. A palliative remedy is the injection of cocaine over the seat of the nerve.

Strong antiseptic solutions should be avoided in dressing scalp wounds. For "wet dressings" Thiersch's (boro-salicylic) or Burow's (aluminum acetate) solution is sufficiently antiseptic.

An easy means of holding a small scalp dressing in place consists in tying over it strands of the patient's hair.

If the patient is a brunette and a small scalp dressing is applied without a bandage as above described, the white gauze should be covered



by a piece of black or brown cloth, unless the patient has enough hair to conceal a small dressing. Black bandages may be used to advantage in scalp dressings on dark-haired individuals.

For the retention of an application or dressing on the scalp a gauze cap may be more quickly applied than a bandage and, for children especially, it will be more comfortable and less apt to be disarranged. A single

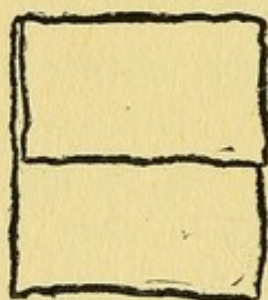


Figure 1

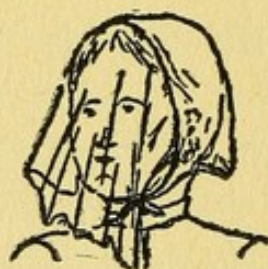


Figure 2

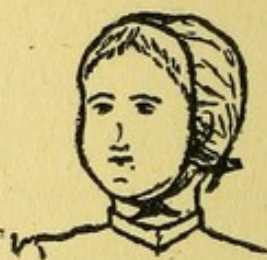

Figure 3

thickness of gauze (cheese cloth) about a yard long and 28 inches wide (for an adult head) is folded on its length, in the manner shown in figure 1. The gauze is then laid on the head, with the long fold next to the scalp and the folded end a little below the occiput, the free end of the long fold thus hanging over the face. The free edge of the short fold is brought to a convenient position,



and its ends are tied snugly under the chin (figure 2). Then the long end is lifted back over the short end and tied snugly beneath the occiput (figure 3). The cap thus adjusted consists of three thicknesses of gauze.

In determining whether or not to operate after injuries to the head, a surgical judgment of the case is usually better than one based strictly on the application of neurological rules.

## Cranium

There is no class of cases in which a prognosis is so often at variance with the extent of the injury as in cranial injuries. The prognosis in such cases should, therefore, always be guarded.

In cases of head traumata, bleeding from the mouth or nose does not necessarily mean that the case is one of fracture at the base. The hemorrhage may be entirely due to a localized injury.

In fractures of the base of the skull with bleeding from the ear it is necessary to keep



the auditory canal absolutely clean in order to prevent infection of the meninges.

In cases of suspected fracture of the skull, percussion-auscultation will be found a valuable diagnostic procedure: The forehead is repeatedly tapped sharply in the median line with the middle finger, the stethoscope being moved from one point to another from before backward. If a fracture be present a cracked-pot sound is elicited just beyond it. The corresponding part of the head on the other side should be auscultated to eliminate possible error.

In searching for signs of fracture of the base of the skull, post-auricular edema should be looked for.

“Egg shell crackle” elicited in palpating a tumor of the cranial bones is diagnostic of sarcoma originating in the diploe.

**Brain** For oozing from the brain surface, during intracranial operations, the application of thin bits of absorbent cotton, as suggested by Cushing, is excellent.



Tumors of the brain frequently simulate, in their earlier stages, diseases of the stomach.

The examination of the eye grounds will often afford the first definite clue to a tumor of the brain.

Unilateral deafness without known cause, associated with facial palsy on the same side, should suggest a lesion in the posterior cerebral fossa.

Increasing deafness and blindness should suggest an intracranial tumor, especially if facial palsy be present.

Blood pressure observations every few minutes are essential to the safe conduct of intracranial operations.

When an operation is performed for removal of a tumor at the base of the brain, one should be careful to retract upward (pressing on the hemispheres) instead of pressing downward (on the medulla), which may paralyze the vital centers.



Sequestration of blood in the lower extremities by compressing the veins at the upper end of the thighs with elastic bandages, will reduce the bleeding in brain operations.

In exploring for tumors of the brain, the best guide for determining an isolated hardness is the finger; the use of a needle is very deceptive.

Preparatory to, and following, operations upon the brain or spinal cord hexamethylenamine ("urotropin") should be administered in liberal doses; Crowe has shown that formaldehyde then appears in the cerebrospinal fluid, and thereby reduces the danger of infection.

In cases of brain tumor lumbar puncture may cause sudden death.

It is to be borne in mind that in seventy-five per cent. of cases of intracranial abscess of otitic origin, the abscess is on the anterior surface of the petrous portion of the temporal bone, and therefore in the middle fossa. Unless there are definite localizing indications elsewhere, the area *above* the petrous bone should



be explored first. First, freely open the antrum, the auditory canal, and the middle ear, and then enlarge the bony opening in an upward direction.

A furuncle deeply situated in the external auditory canal gives signs that may be mistaken for mastoiditis. Great pain when the concha is moved about will serve to differentiate it from the latter.

Ear

Don't incise every furuncle of the auditory canal. Tampon with a wick of cotton or gauze saturated with liquor Burowii (acetate of aluminum), resorcin-alcohol, or balsam of Peru, and wait until pain has disappeared. Hot applications may be needed. A furuncle pointing and threatening to burst may be opened with a superficial cut. Avoid wiping the pus along the canal, as the result is almost inevitably a fresh crop of furuncles.

Persistence of suppuration after incision of a furuncle or abscess of the auditory canal or auricle indicates the development of a localized chondritis.



Pain in the ear, increased on traction of the auricle, with slight, if any diminution of hearing, suggests a furuncle in the meatus. Introduce the speculum with great care. The probe will often reveal a point of marked tenderness.

One should not try to force his way into an auditory canal without first making sure that the patient has no disease of the external ear. The examination under such circumstances will only aggravate the condition.

When attempting to loosen with a hook a foreign body almost or quite obstructing the auditory canal, the passage of the instrument along the antero-inferior aspect of the canal involves the least risk to the drum membrane.

If a foreign body impacted in the auditory canal (especially if symptoms suggest that it has entered the middle ear) resists safe efforts at removal, administer narcosis, turn the ear lobe forward, and open into the canal by a free incision from behind. This procedure, which is simple and leaves only invisible scars, is a very old one, but it is often forgotten.



Severe and repeated headaches may be due to the unsuspected presence of otitis media, with or without mastoiditis.

Sudden one-sided diminution of hearing after bathing may indicate nothing more serious than water in the ear, or a plug of wax which has swelled up and obstructed the canal. If no means of syringing is at hand, the instillation of ether and alcohol, equal parts, will dry up the plug and often cause it to disintegrate, with a corresponding improvement in hearing. Swollen seeds, peas or beans in the external canal may be treated similarly.

Don't pour hot oil into the ear to relieve pain. Heat can be applied much better in a hot mixture of glycerine, alcohol and water, which will not turn rancid or clog up the ear, and can be removed by syringing with water. A towel or large pad of gauze wrung out in boiling water and closely applied over the ear, covered with oiled silk, is better than a hot water bag.

A five per cent. solution of phenol in glycerine dropped warm into the ear will relieve the pain in non-suppurating acute otitis media.



A neuralgic pain in the region of the ear, should suggest a careful examination of the teeth for caries or alveolar inflammation, and of the throat.

Three or four drops of peroxide of hydrogen in the ear followed five minutes later by thorough syringing with a solution of boracic acid or bicarbonate of soda, will readily remove impacted cerumen.

In cases of unaccountable fever, especially in children, never fail to examine the ear.

Tinnitus aurium, present only in the recumbent posture, is suggestive of aneurism of one of the posterior cerebral vessels.

The history of a discharge from an ear appearing a few days to a few weeks after the beginning of a slowly developing deafness in that ear, unaccompanied at any time by pain, is suspicious of tuberculous otitis media.

Intermittent mucoid or mucopurulent discharge from the ear without pain or fever suggests nasopharyngeal disease; in children, adenoids.



Chronic suppuration in the middle ear may be entirely due to an adhesion near the floor of the tympanum and the internal wall, forming a pocket in which pus may lodge.

“Paracentesis” is a misnomer. The drum should be *slit* from below upwards and near the posterior margin, throughout its entire extent. In withdrawing the knife it may be allowed to cut deeply into the upper canal wall near the drum (internal Wilde’s incision).

An old, narrow Graefe cataract knife is an ideal instrument for opening the drum membrane in otitis. Ethyl chloride narcosis is the best for this brief operation.

Irrigation of the ear with a warm boric acid solution (108° F.), is an excellent procedure if there is a discharge of pus. But irrigation of the ear just after a paracentesis of the drum or when there is only a serous discharge, merely predisposes the mucous membrane and the mastoid to greater infection.

Repeated aspiration of an ear discharge, the syringe tip or otoscope snugly fitting the



external canal, greatly accelerates the cure of an otitis media.

When a large amount of pus can be aspirated from the ear the suppurative process has extended beyond the tympanum and mastoid operation is indicated.

Pain and tenderness behind the ear is not always indicative of mastoid disease. One should not forget to look for pediculi in the scalp, for they often lead to an infection of the deep cellular tissues in this region.

A bean-shaped pulsating swelling just below the mastoid apex, in cases of mastoiditis, may be only a lymphatic gland, but it may also be a thrombosed jugular vein. Its nature should therefore be determined before the operation is concluded.

A "positive" blood culture in a case of otitic or mastoid disease is pathognomonic of sinus involvement and an absolute indication to tie off the internal jugular vein.



The cessation of a purulent discharge from the ear should not be taken as a sign of cure. The pus may have found its way into the mastoid cells.

Persistent suppuration in a mastoid wound in most cases means dead bone at the bottom of the cavity.

During mastoid operations always sever with scissors any fragment of tissue attached to a bit of bone loosened with the chisel or rongeur, before removing it. The tearing out of a fiber of the sterno-mastoid muscle, for example, will open a channel of infection in the neck.

Before terminating a mastoid operation scrape clean the exposed bone surface. The wound will granulate more quickly.

The healing of a mastoid wound is often accelerated by lengthening the intervals between dressings, allowing Nature to do her part in repair with minimal disturbance.



If the zygomatic cells are thoroughly laid open, one frequent cause of persistent suppuration requiring secondary mastoid operation, may be avoided.

A persistent elevation of temperature after a radical operation for mastoiditis should lead one to suspect the possibility of a complicating brain abscess. If the fever shows wide fluctuations of temperature a sinus thrombosis is more probably the cause.

Nitrate of silver may be attached in full strength to the end of a probe, as for application in the middle ear, by heating the tip of the instrument and pressing it into the stick of caustic; a little of the latter will melt and form a bead on the probe when it cools.

## Eye

Cystic swellings at the external angle of the eye are usually dermoids. In some cases they communicate by a small opening with an intracranial sac.

An opaque growth on the eyeball in a child is likely to be a dermoid growth—that is, a growth of skin epithelium on the conjunctiva.



A sty is often most easily treated by the removal of the hair in the infected follicle and the application of iced boracic acid compresses.

Clipping the lashes close before ophthalmic operations renders the first dressing easy, as the lids are not glued together, there is no retention of secretion, and, accordingly there is less danger of secondary infection.

A hypodermatic injection of morphine, gr. 1/6, about a half hour before a major eye operation, such as cataract or iridectomy, will keep the patient quiet and make the extraction calm, and free from pain. There is no danger of sudden motion of the head, and the technic is more exact and rapid.

A one-sided conjunctivitis or irritative condition, with tearing, photophobia, and lid-spasm should always suggest the presence of a foreign body on the cornea or behind the lid. In the latter case puffiness of the upper lid develops very rapidly and is a diagnostic aid. A dark body is best seen against the iris; a light one, against the pupil. The patient's eye should be turned accordingly.



In looking for a foreign body on the surface of the eye, examine the tear-points with care. An incarcerated lash or cut end of hair may be the cause of the trouble.

By pressing lightly with the flat end of a wooden toothpick in the region of a foreign body on the cornea, it will often come away. The conjunctiva should first be anesthetized with a solution of cocaine.

After the extraction of a foreign body from the cornea, a drop of castor oil between the lids will ameliorate the pain.

The sensation of a foreign body in the eye may be provoked by the presence of a small tarsal tumor.

"Black eye," developing in an infant without any history of injury, should always arouse suspicion of scurvy (Barlow's disease). It is generally distinguished by lack of swelling, absence of bruise or redness of lids, and rapid gravitation of the blue discoloration to the lower lid and cheek. The orbital hemorrhage



may take place on the other side, after a short interval.

Recurrent attacks of inflamed lids, conjunctivitis, or corneal ulcer *in one eye*, suggest an infected lacrimal sac. Pressure over the inner canthus will generally cause muco-pus to present in the puncta.

Small incised wounds over the eyelid are very prone to infection. Instead of sewing up the wound immediately, put on a wet dressing and wait twenty-four hours.

Constant lacrimation with no other signs or symptoms may be due to a chronic dacryocystitis. Removal of the lacrimal sac will often effect a cure.

Frequent applications of tincture of iodine on a "tooth-pick" swab will often heal a corneal ulcer where other means fail.

A periostitis at the margin of the orbit may resemble a cellulitis. It is often of syphilitic origin.



When a patient complains of a pain in the eye with epiphora, don't always think it is due to conjunctivitis. The cause may be a beginning glaucoma.

When there is a perforating wound of the cornea, necessitating enucleation of the eye, the wound should be closed so that the eyeball does not collapse during the operation.

The most stubborn and inflamed iris will yield and the pupil dilate if a leech be applied just back of the lid-fissure, and a small crystal of atropine be placed in the conjunctival sac. Avoid systemic poisoning by pressure over the inner canthus with the tip of the finger, occluding the tear-ducts and preventing the atropine-laden tears from running down the nose and being swallowed.

Marked exophthalmos with a purulent iritis may be an embolic condition (metastatic chorioiditis) due to septic infection, *e. g.*, of the uterus, as after an induced abortion.

The history of transitory oculo-motor palsy, without known cause, is always suspicious of



syphilis. Examine the eye ground for optic neuritis, and look for signs of tabes.

A diffuse swelling of the orbit, moderate exophthalmos, intense pain and tenderness and marked edema, mean an infection extending deeply into the orbital planes. Unless early treatment is instituted, the eyesight may be lost, or the infection may extend along the course of the optic nerve resulting in meningitis or sinus thrombosis. Wherever there is fluctuation, early incision is necessary; and free drainage of the infected area is of paramount importance.

Wolfe grafts for the lids or for an artificial socket must be made very large to allow for shrinkage. Allow an extra half inch for each inch in length and width of the defect to be covered.

In prescribing eye-drops, order a dropper to be placed in the bottle in place of a cork, as a stopper. It will always be at hand and always clean, and the solution will not be contaminated.



An old Beer's knife that has been ground so often that it is of no use for corneal incisions is excellent for opening styas or chalazia, and a small straight keratome, on account of its double edge, is far better than any scalpel for splitting the lid margin in entropion and trichiasis operations.

Avoid bichloride of mercury solutions in eye work, as much as possible. After cocaine has been used, they may cause a permanent opacity of the cornea.

After using a cocaine solution on the eye, keep it well irrigated, or bandaged, for a while, to prevent dryness and subsequent erosion.

After iridectomy for glaucoma the pupil of the sound eye should be kept contracted by pilocarpine for at least a week, but not bandaged, for it should be open to frequent inspection.

After using a mydriatic in an adult, instil pilocarpine, one per cent., and keep the patient under observation until the pupil contracts.



Test the vision carefully in every case of ocular injury, even if it is apparently nothing but a "black eye."

When a grey or blue eye turns brown and loses sight, after an injury, one may be almost sure of the presence in the globe of a chip of steel or iron that is slowly oxidizing (siderosis).

A large pupil in an aged patient is a danger signal, suggesting glaucoma with insidious onset.

Severe neuralgic pain over the bridge of the nose indicates pressure on the anterior ethmoidal nerve, probably due to a high deviation of the nasal septum.

Nose

Severe pain in the orbit or even in the eye itself should make one think of frontal sinus infection, especially if there is, or recently has been, a nasal discharge. Marked localized tenderness will soon confirm the suspicion, if the disease exist.

A diagnosis of supraorbital neuralgia should not be made until frontal sinusitis has been carefully excluded.



A persistent, chronic discharge from the nose should lead one to suspect chronic disease of the frontal or other accessory sinus.

Transillumination is a method of corroborative value only in the diagnosis of accessory nasal sinus disease. By itself it is of small diagnostic use.

Don't urge the radical operation for frontal sinusitis unless the symptoms are severe or conservative efforts have failed; the operation is disfiguring and the results are not always satisfactory.

If on transillumination the maxillary antra are dark, it does not necessarily mean that pus is present. Granulations may be covering the antral wall.

The best point for entering the maxillary antrum is about one inch from the edge of the nostril, below the inferior turbinate.

If a patient has had a nasal operation performed, especially if the accessory sinuses have been operated upon, severe frontal headaches



may mean thrombosis of the cavernous sinus, even if no fever be present.

A large dose of antipyrine or quinine will often clear up a frontal headache due to acute catarrh of an accessory sinus, by its astringent action on the mucous membrane and the consequent improvement of drainage.

In acute nasal sinus infection spraying with adrenaline and Dobell's solution and steaming with compound tincture of benzoin in boiling water go far towards securing free drainage.

Many a distressing frontal headache may be relieved by reducing the hypertrophy of a middle turbinate, preferably by streaking with trichloroacetic acid.

In every case of injury to the nose, with or without fracture, it is well to examine the septum for displacement. If displaced, it should be carefully restored, using a nasal plug, if necessary, to keep it in place.

In chronic nasal catarrh, the first suggestion of ethmoidal sinus disease may be the appear-



ance of thick, adherent, stringy mucus in the nasopharynx.

Polypi are not merely cystic tumors—they often spring from a base of diseased bone. Removing the polypi does not cure the disease; the affected bone necessarily must be removed.

Pain and swelling of the tip of the nose are often caused by an infection of the hair follicles in the vestibule.

Persistent “nose-picking” often results in a perforation of the septum.

An infection of the hair follicles of the nose is quickly relieved by the application of a 1 per cent. salve of yellow oxide of mercury.

Balsam of Peru will often abort a furuncle in the nostril that has not advanced to softening.

A foreign body in the nose of a child is often suggested by a discharge of mucus from one side only.

Hard foreign bodies in the nose may sometimes be removed, where other means fail, by



wiping the cavity and foreign body dry and applying sealing wax attached to cotton.

When a foreign body in the nose is not easily removable with forceps, remember Felizet's simple method—the injection of warm water into the opposite nostril. Use a syringe or douche nozzle that snugly fits the naris. Begin gently and slowly, then increase the force. As the resistance suddenly ceases, the foreign body is shot out (or at least is dislodged), by the pressure of the fluid reflected from the posterior walls of the pharynx.

The effects of the application of cocaine or adrenaline to the nose or throat may be prolonged by swabbing the parts with sterile vaseline after the application of the medicament.

To render a packing introduced for epistaxis easily removable insert a rubber finger cot into the nose, hold it open with clamps and pack the gauze into this.

When removing a dermoid cyst at the root of the nose don't forget that it may lead through the bone sutures to the meninges.



Especially if the cyst or sinus is infected it is not wise to dissect it out too deeply unless persistent discharge after removal of the presenting portion cannot be cured by cauterization, etc.

When paraffine is injected in the treatment of saddle-nose, pressure should be made at the root of the nose and on both sides, to prevent possible embolism or the escape of the mass into surrounding tissues.

### Face

Non-malignant tumors of the parotid practically never cause pressure effects on the facial nerve. This may be of importance in differentiating them from malignant tumors.

A swelling in the parotid region is not necessarily a part of the parotid gland. It may be an infection of the pre-auricular lymphatic gland. Such an enlargement may be associated with herpes of the forehead, or it may be part of a chain of tuberculous lymph nodes.

A small swelling in the parotid region may be an inflamed lymph node. A single focus



of tuberculous lymphadenitis is sometimes to be found here.

Chronic ulcers of the face situated in the area between lines drawn from the outer end of the eyebrow and the upper border of the ear above, and the angle of the mouth and the lobe of the ear below, are usually epitheliomata of the basal-celled variety and they are comparatively non-malignant.

The position of Steno's duct must be remembered when operating upon the face.

When paraffine is injected subcutaneously it is important to allow for increase of the size of the mass by the growth of connective tissue around it.

A small, tender, usually more or less reddened swelling appearing suddenly in the submental region may follow exposure to the cold. Similar swellings often appear simultaneously over the malar prominences. The best treatment is none.



Infections of the upper lip demand prompt and thorough treatment to avoid cerebral infections. Thrombosis of the naso-labial branch of the facial vein should be watched for. It appears as a reddened cord which can be felt in the groove between the cheek and nose. Serious complications may be averted by excision of the thrombosed vein.

### Maxillae

In chronic osteomyelitis of the jaw it is better to wait months for a sequestrum to form than to operate a dozen times for the removal of necrosed bone.

All swellings of the lower jaw accompanied by a discharging fistula, and especially if there be multiple fistulæ, should be looked upon with the suspicion of actinomycosis until proven to be otherwise.

A tumor in the cheek near a tooth cavity is often a dentigerous cyst.

The lining membrane of a maxillary bone cyst is usually easily removable complete with forceps.



Syphilis may be the cause of a small tumor situated in the masseter muscle. A course of mixed treatment should be resorted to before operation is decided upon.

If a frightened or refractory child will not open its mouth, pass a probe between two teeth and back to the palate. Instantly the mouth will open and a gag may be slipped in.

Mouth and  
Pharynx

The blood should be examined in all cases of gangrenous gingivitis for evidences of acute lymphatic leukemia. A small gangrenous spot may be the beginning of a noma.

To determine how soon a patient's mucous membrane, e. g., of the mouth or urethra, becomes insensitive after the application of cocaine or other anesthetic, the surgeon may employ the device of touching a little of the same solution to his own tongue.

The employment of adrenaline as an application with cocaine to the mucous membrane of the cheek, e. g., for the excision of a leukoplakic ulcer, is not to be advised. There may be severe secondary hemorrhage.



An hypertrophied lingual tonsil sometimes causes much discomfort, giving a heavy, sore feeling to the base of the tongue. It may be necessary to remove it.

When there is bleeding from the tongue, post-operative or otherwise, and one feels reasonably sure that the hemorrhage is arterial, it can, as a rule, be easily arrested by passing the forefinger down to the epiglottis and hyoid bone and drawing the base of the tongue upward toward the chin.

It is wrong to perform any radical operation for an ulcer of the tongue without preliminary microscopical examination. Clinical symptoms, no matter how typical, are often misleading.

Cancer of the posterior part of the tongue invades the lymphatics not only on the side upon which the disease is located, but also upon the opposite side, because of the peculiar anatomy of the lymphatics of this region.

A feeling of discomfort in the mouth while eating may be the first sign of a calculus in one of the salivary ducts.



Persistent hemorrhage after the extraction of a tooth is often relieved by the application of trichloroacetic acid. If the hemorrhage does not cease after its application, tamponade of the cavity is the next best available means of stopping the flow of blood.

A deep ulceration of the fauces or tonsils should not be diagnosed as specific without excluding acute lymphatic leukemia.

## Pharynx

The differentiation between a specific and tuberculous ulcer of the fauces is sometimes very difficult. As a rule the specific ulcer is shallow, grayish, with a regular margin, not very tender and does not cause dysphagia; on the other hand, a tuberculous ulcer is deeper, more sloughy, irregular in outline, has an outer inflammatory zone, is exquisitely tender and causes great pain on swallowing; laryngeal examination may reveal a tuberculous condition of the cords.

Dryness of the pharyngeal wall is usually associated with an atrophic rhinitis.

Soreness in the throat is a common complaint of nervous people. Close inspection



will often show numerous fine white spots with red areolae—herpes.

When there is persistent irritation of the throat without local cause, examine the chest. This may be one of the earliest symptoms of mediastinal tumor or enlarged bronchial glands.

Irrigation of the throat with ice-water from a fountain syringe will relieve the congestion and the pain in acute follicular tonsillitis.

Swabbing the throat with 20 per cent. iodine in glycerine will quickly relieve a pharyngitis.

Small reddish spots interspersed over the tonsils, uvula and anterior pillars, with no signs of inflammation, are usually herpetic.

Before operating for pharyngeal adenoids or hypertrophied tonsils make sure that these are not merely an expression of status lymphaticus. If they are, do not employ an anesthetic. Also determine whether the patient is a hemophiliac. If he is, do not operate at all.

Bilateral, large, smooth swellings of the



tonsils should arouse the suspicion of Hodgkin's disease.

There is less likelihood of injuring the deeper vessels in excising tonsils if the instrument is pressed in deeply to engage the organ rather than exerting pressure from the outside.

Hard tonsils preponderating in connective tissue, are better removed by the cold snare than by a sharp instrument. The snare closes the bloodvessels; the tonsillotome opens them.

A retropharyngeal or peritonsillar swelling that is very edematous may disappear under the administration of large doses of salicylates.

It is almost impossible to successfully anesthetize a peritonsillar abscess. If the patient cannot stand some pain he should be placed under the lightest possible narcosis and the incision made rapidly while the head is suspended over the edge of the table.

When opening a retropharyngeal or peritonsillar abscess in a small child, by the buccal



route, have the head dependent and instruments at hand for tracheotomy. These instruments are needed but rarely, but then urgently.

The surgeon should keep closely in touch with cases of acute retropharyngeal abscess as serious edema of the glottis may develop and require tracheotomy for its relief.

Quinsy is usually more painful than serious, but occasionally such an abscess causes death by suffocation or by erosion of a bloodvessel.

Repeated attacks of quinsy suggest that the tonsil is diseased. If treatment of the gland does not prevent recurrence of the quinsy, tonsillectomy is indicated.

One should not rely on feeling a tonsil engaged in a tonsillotome; he should see that it is if he does not wish to take the chance of cutting away the pillars of the fauces, a portion of the tongue, the floor of the mouth or the uvula.

Always examine a child suffering from



chorea for the presence of adenoids. The removal of the growths in the pharynx may cure a mild case.

Small clinging pieces of adenoid tissue which have not been removed by the curette will very likely set up an inflammatory reaction on the posterior pharyngeal wall which is more distressing than the adenoids themselves.

Torticollis after adenoidectomy means a post-operative infection.

In seeking a cause for torticollis, don't fail to examine the teeth.

In all cases of torticollis, examine for caries of the spine.

Perdiculosis capitis may be the indirect cause of acute torticollis by reason of a developing post-cervical adenitis.

In a child presenting symptoms of tuberculous disease of the cervical spine, it should be remembered that other conditions, such as torticollis, inflamed lymph nodes, and sprain of the cervical ligaments, are capable of giving similar symptoms.



A submaxillary swelling should not be dismissed as a lymphatic adenitis without studying Wharton's duct on the same side. Massage of pus therefrom would demonstrate a salivary gland inflammation, probably due to the presence of a stone.

When confronted by an irregular rounded growth appearing to spring from the sterno-mastoid in the middle third of the neck, bear in the mind the possibility of a carotid gland tumor.

Examination into the nature and cause of discrete hard lymphatic swellings on each side of the neck, along the sterno-mastoid, should include exploration of the pharynx and nasopharynx for possible new growth.

In all glandular affections of the neck it is quite as important to treat the source of infection, *e. g.*, carious teeth, as to treat the inflamed glands.

Pneumogastric paralysis after an operation involving manipulations about the nerve, *e. g.*, the removal of tuberculous cervical lymph nodes,



does not necessarily indicate that the nerve has been accidentally cut or tied. The condition may be transitory and result from traumatic or inflammatory irritation.

To avoid troublesome hemorrhage in operations for tuberculous glands of the neck expose the internal jugular vein early.

In "Ludwig's angina," the cardinal principle in the treatment is extensive incision. An incision that passes no matter how deep into the substance of the submaxillary gland proper, will prove of little avail unless the tissues within the wound have been broken up until they are practically pulpy.

Have the tracheotomy instruments handy before operating upon a case of angina Ludovici.

In cut-throat wounds where the thyro-hyoid membrane has been severed, it is necessary, in order to restore perfect phonation and deglutition, to suture this membrane accurately.




The greatest ultimate danger in cut-throat cases is the onset of a septic pneumonia. This may be obviated in a measure by closing up the pharyngeal wall, and by paying the strictest attention to asepsis.

Avoid the use of peroxide of hydrogen in wounds of the neck. It is too apt to dissect up the loose cellular planes. The same warning applies in many cases of cellulitis of the hand or foot.

In the presence of a hard, diffuse, chronic swelling in the neck having some of the appearances of a malignant growth, the possibility that the tumor is a so-called "wooden phlegmon" of Reclus must be considered.

Phlegmonous processes in the neck, especially suppuration in the deeper planes, cannot be too promptly evacuated—they are often followed by mediastinal or pulmonary infection.

Hard subcutaneous tumors of the upper third of the neck, with signs of malignancy, are often epitheliomata arising from branchial clefts.





An exquisitely tender swelling situated just above the sterno-clavicular articulation may be due to the perforation of the esophagus by a foreign body. If there are evidences of acute laryngitis, with edema of the arytenoid cartilages, the cause may be a perichondritis of one of the tracheal rings or the cricoid cartilage.

Ligation in continuity of the external carotid should not be close to its origin. The proximal clot may extend into the common, and be swept through the internal carotid, to the brain.

Before performing esophagotomy for foreign body, make a final examination (radiographic or otherwise) to determine that the object has not slipped into the stomach.

Any enlargement of the thyroid gland may cause paralysis of one of the vocal cords by pressure on the recurrent laryngeal nerve or may impede respiration by pressure on the trachea itself. But a laryngeal examination should not be omitted, for the whole trouble may be caused by an enlarged accessory thyroid on one of the vocal cords.



Persistent tachycardia should indicate a search for other evidences of hyperthyroidism. A goiter is not essential to the diagnosis.

If the administration of thyroid extract to a patient suspected of exophthalmic goiter increases the symptoms the diagnosis is more probable.

Do not empty a thyro-glossal cyst by aspiration before extirpating it. It is well to inject the cavity with a methylene blue solution first, in order to make sure that all parts of the cyst wall will be extirpated. Another method is to first empty the cyst and then fill it with paraffine.

In all operations in the left subclavian triangle of the neck, the location there of the thoracic duct must not be forgotten.

The best thing to do in such emergencies as air embolism is to apply compression immediately and pour large quantities of solution, preferably salt solution, into the wound.



After an operation for extensive carbuncle of the neck, a comforting support may be supplied by placing under the bandage a piece of heavy manila cardboard (bookbinders' board), wetted and shaped to the back of the head and neck.

Gradually increasing hoarseness in people past middle age, without definite cause, and with a history of pain radiating to the ear, is suggestive of malignancy.

Patients who show a progressive loss of vocal power should be examined most carefully for an intralaryngeal condition. An acute aphonia may be due to an inflammatory condition or paresis of one cord; alcoholism, syphilis, tuberculosis and malignant disease bring on a chronic condition. Two most important causes of chronic laryngitis are thickening due to an old inflammatory process and the presence of a small, hard, nodular tumor on one of the cords, e. g., fibroma.

A small erosion of the trachea may give rise to an hemoptysis, which must be distinguished from a lung hemorrhage by the absence of

Trachea



pulmonary and constitutional symptoms and by the fact that the blood is in small clotted lumps.

### Tracheotomy

In urgent cases high tracheotomy should be performed, not a low tracheotomy. The former can be done very rapidly; the latter requires considerable dissection.

The best site for an urgent tracheotomy is through the crico-thyroid membrane. To hold the opening apart a couple of hairpins, bent at the end, may be used as retractors.

In the performance of high tracheotomy a great deal of room can be gained by dividing transversely the fascia that extends upward from the thyroid.

In fractures of the trachea an immediate tracheotomy is indicated, for emphysema occurs if the mucous membrane is punctured, and the operation is then rendered much more difficult. The mucous membrane is injured in most cases.

After tracheotomy the air of the patient's room should be kept reasonably warm and



moist. Draughts of cold air provoke much irritation.

The greatest immediate danger after a tracheotomy is the possibility of a subsequent pneumonia. This can, in a large measure, be obviated by filtering the inspired air through a soft sponge saturated with warm one per cent. phenol solution.

A trimmed turkey feather, cleaned, is an excellent means of wiping mucous and blood from a tracheotomy tube *in situ*.

Repeated attacks of coughing after tracheotomy may mean irritation of the posterior wall of the trachea by the tube; change the length or shape of the canula.

A "tumor" of the breast occasionally proves to be only a chronic abscess. It has happened that a breast amputated for carcinoma has been found to be the seat of old abscesses only.

In the treatment of a breast abscess the size of the incision is not as important as its location and direction.



A small incision and the proper employment of a Bier-Klapp breast cup will secure exceedingly gratifying results in many cases of mammary abscess.

In the presence of a breast infection that fails to heal within a reasonable time after appropriate incision and dressings, it is well to think of local tuberculosis.

The appearance of pus in the breast of a woman who is not, or has not recently been nursing, is suspicious of some unusual form of infection, e. g., tuberculosis.

A compressive dressing or firm breast binder may close in a few days a small lacteal fistula that has resisted other measures.

A tender, painful swelling just at or beyond the upper, outer border of the breast, and near the edge of the pectoralis major, is usually an inflamed lymphatic gland. In its presence it is well to look for some skin infection about the waist line, e. g., furuncles, which are not rare at this site as a result of irritation by the corset. *Per contra*, with a boil,



abscess, dermatitis or other infection at or above the waist line, one may be on the look-out for glandular enlargement at the point referred to.

In the performance of the radical operation for breast carcinoma it is important to avoid injury to the periosteum of the ribs.

Multiplicity of tumors of the breast usually speaks against carcinoma.

Breast tumors, especially in the early stages, seldom fail to present the classical signs by which their malignancy or non-malignancy may be determined clinically. In all cases where the diagnosis is doubtful, a specimen of the tumor should be removed for microscopic study, before undertaking a radical operation.

Involution growths in the breast are very often cystic, even though the mass appears to the feel to be solid throughout. Carcinomatous degeneration is sometimes found in the cyst wall of these originally benign growths.



## BREAST

The "lymphangeoplastic" operation of Sampson Handley is simple and may prove a great boon to patients suffering from otherwise incurable edemas of the extremities, especially the "brawny arm" of breast cancer.

Persistent lymphedema of the breast may be the first, and for a long time the only sign of a scirrhus carcinoma.

## THORAX

In strapping the chest for fractured rib, two points should be particularly noted: 1. The straps should pass well beyond the median line. 2. They should be applied in full expiration. One or two straps passed over the shoulder help much to secure immobilization.

Cold abscess and lipoma often simulate each other very closely, especially around the chest. If in doubt, aspirate.

Do not be too hasty in making a diagnosis of intercostal neuralgia. With the exception of pulmonary and pleural conditions, ulcer of the stomach simulates intercostal neuralgia more frequently than any other lesion.



It is remarkable how frequently a purulent pericarditis may exist without causing many or severe symptoms. Never neglect an examination of the cardiac area, therefore, in cases of suspected sepsis.

When a patient complains of dysphagia, do not neglect to examine the pericardium for effusion.

Care must be taken in resecting the last true rib not to open the pleural cavity; for not only does this produce a pneumothorax, but an extensive subcutaneous emphysema may also result.

A history of attacks with symptoms of esophageal stricture and intervening periods of well-being is suggestive of cardiospasm.

A history of discomfort and oppression in the chest and throat after eating, relieved by induced vomiting, also suggests cardiospasm.

A satisfactory method of x-ray study of esophageal diverticula and strictures consists in fluoroscopy of the thorax while the patient is



swallowing an emulsion of bismuth. A skia-graph may be made immediately afterwards as a supplementary record.

To perform gastrostomy upon a patient with esophageal obstruction, who can painlessly swallow fluids is a needless, not to say, a cruel, operation—except as a preliminary to a more radical procedure.

Before operating for sarcoma examine the lungs carefully. Do not operate if the patient has persistent cough and blood-stained sputum (not due to tuberculosis), even though no definite signs are found in the lungs—a metastasis has developed.

A fluctuating swelling appearing between the ribs may, of course, be tuberculous or syphilitic in origin, but it may also be an extension of an intrathoracic growth, *e. g.*, dermoid cyst of the mediastinum. In all such cases, therefore, a careful examination, by auscultation and percussion, should be made.

In the presence of subpectoral or parasternal suppuration be on the lookout for a mediastinal abscess.



Clear fluid in the pleural cavity is not always indicative of lung or pleural disease. It may be due to a new growth of the mediastinum pressing upon the venæ cavæ.

A mediastinal tumor may be present for some time without other symptoms than cough, expectoration, loss of flesh and slight fever—thus simulating pulmonary tuberculosis. A skiagraph will determine the condition; laryngoscopy is also helpful for adductor paralysis is frequently an early sign.

A slender fish bone lodged in a bronchus will usually not cast a shadow on the x-ray plate. In such a case bronchoscopy and auscultation are more reliable diagnostic measures. In addition to a variety of moist rales one may hear, associated with the inspiratory or expiratory murmur, or both, a musical or vibratory note, when a bone or pin lies in a bronchus.

A foreign body in a bronchus diminishes the respiratory murmur over the affected side. If the body occludes the bronchus, the respiratory murmur will be absent.



If a patient dates irregular or persistent cough from a time when he thinks he "swallowed" or inspired a foreign body, the fact that the physical signs elicited upon examination of the chest are peculiar—different from those found in ordinary types of bronchitis—points strongly to the presence of a foreign body.

A foreign body lodged in a bronchus may present a symptom-complex identical with pulmonary tuberculosis in a child—the history of aspiration of the foreign body may be wanting.

Bronchiectasis is not rarely complicated by brain abscess.

The chief causative factors in peripleuritic abscesses are actinomycosis and typhoid osteomyelitis. A careful history as to a previous typhoid and a thorough microscopic examination of the pus should be secured.

A peripleuritic abscess due to caries of a rib may give all the signs and symptoms of an encapsulated empyema. Aspiration of the chest usually withdraws clear fluid (an effu-



sion due to the inflammatory process). A positive diagnosis can be made only by exploration of the abscess cavity, when a necrosed rib may be found overlying a thick-walled abscess cavity.

If the physical signs of pneumonia persist for an excessively long period, especially in children, it is wise to aspirate on the suspicion of empyema.

In aspirating the chest, see to it that the syringe is in good condition before inserting the needle. Never apply the syringe to the needle after the latter has been inserted; a severe pneumothorax may result. If the syringe is found to be out of order while the aspiration is being done, withdraw the needle also and reinsert.

There is one point that must always be thought of when pus has been aspirated after an exploratory puncture for either suspected empyema or liver abscess—to make sure that the “pus” does not come from a bronchus. This can be determined, as a rule, by microscopical examination of the aspirated fluid.



Very extensive and rapidly spreading subcutaneous infections may result after an aspiration of a foul-smelling empyema. It is therefore wise to always operate over the site of aspiration, and especially to see that the puncture wound is well drained.

Abscess of the lung should be borne in mind when pus is aspirated from the chest of a patient whose physical signs of empyema are atypical.

Intratracheal anesthesia (Meltzer), promises to supplant the complicated and expensive pressure chambers for intrathoracic surgery. The introduction of the catheter through the direct laryngoscope is not difficult and safeguards against passage of the tube into the esophagus.

After a transpleural intrathoracic operation, as on the esophagus or lung, air-tight drainage of the pleural cavity must be provided for.

When operating for empyema thoracis it is a good rule to aspirate again when the pleura is exposed and before it is incised. This may save some embarrassment.



The shock of evacuating an empyema thoracis may be largely avoided by making but a small opening in the pleura (after resecting the rib) and applying at once several thickness of gauze. At the next dressing much or most of the pus will be found to have escaped into the gauze, and the pleural wound may then be enlarged without producing shock.

After operation for empyema, a cover of oiled silk or gutta-percha over the gauze dressing serves to prevent admission of air into the pleural cavity, while it will not interfere with the escape of air already in the chest. Indeed, a flap of rubber may be laid over the wound and fastened with a little chloroform above. This allows pus to escape from beneath it and excludes the admission of air.

A short drainage tube, and its early post-operative removal, are important in avoiding the formation of an empyema sinus.

The injection of Beck's bismuth paste may obviate an extensive thoracoplasty for the cure of a persistent empyema sinus.



## THORAX

Shallow, catching, irregular breathing is characteristic of diaphragmatic inflammation—either peritoneal or pleural.

There is often a “clear interval” after a stab wound of the heart, similar to that following laceration of the middle meningeal artery.

The “safe triangle” or “interpleural space” for exposing the heart is at the left of the sternum behind the three lower costal attachments.

## ABDOMEN

It is surprising how much information can be derived by abdominal palpation conducted with the patient in a hot bath, the temperature of the water being gradually raised to 105° F. It usually secures as much relaxation as does the administration of an anesthetic, sometimes even more. In addition to the avoidance of the dangers and the disagreeable features of narcosis, it has the important advantage that the patient is able to call the examiner's attention to sensitive areas.

Pulsation in an inflammatory swelling of the abdominal wall is evidence that the lesion is not merely a parietal abscess.



Increase in pulse rate is of far greater significance than temperature elevation in surgical abdominal conditions.

In the presence of a tumor in the mid-line between umbilicus and pubes, the possibility of a cyst of the urachus must be borne in mind. It may simulate an ovarian cyst or other tumor, or a distended bladder.

Eczema of the umbilicus is sometimes merely the expression of an infected dermoid cyst at that site.

A discharge from the umbilicus may be due to an infected dermoid cyst, to an eczema of the umbilicus, to a patent urachus (urine), to a cyst of the urachus (milky discharge); it may be of pus from an abscess within the abdomen or in the abdominal wall, or of feces (Meckel's diverticulum, perforated strangulated hernia, fecal abscess from tuberculosis).

Do not ligate tumors of the navel without making sure that the intestine is not included within the ligature.



## ABDOMEN

A needle buried in the abdominal muscles may have its position shifted considerably by the violence of vomiting or struggling under narcosis or "scrubbing up" the skin. Before operating for the removal of such an object, therefore, administer morphine before narcotizing, disinfect the skin with iodine rather than by scrubbing, and, if possible, secure a final x-ray localization.

In performing paracentesis in the median line for abdominal fluid, be sure that the bladder is empty. When it is necessary to perform paracentesis in the lateral part of the abdomen, be careful to avoid the deep epigastric artery.

When seeking the cause of an obscure or indefinite abdominal pain, and especially of a pain in the loin, make a careful microscopic examination of the centrifugalized urine. Renal calculi sometimes cause only mild, irregular pains, and the finding of a few red blood cells in the urine may be the first clue to their presence.

Unless some other cause is evident don't fail to examine for signs of tabes when an adult



complains of pains about the waist, in the back or in the lower extremities.

Rectal palpation is an essential part of the examination in most acute intraabdominal affections.

Inflation of the colon may clear the diagnosis in a case of an abdominal mass of doubtful nature.

Children who complain frequently of pain in the stomach should be examined for evidence of beginning Pott's disease. Such cases, treated before the development of curvature, usually yield very satisfactory results.

In all cases of acute abdominal pain, never fail to examine the lungs and gums. The onset of pneumonia or pleurisy frequently closely simulates acute appendicitis; lead colic may simulate almost any painful abdominal condition.

A malarial seizure accompanied by vomiting and abdominal pain may simulate appendicitis, cholecystitis, or other acute intra-



abdominal lesion. A leucocytosis even of 20,000, does not gainsay the malarial diagnosis.

Enlargement of the veins at the side of the abdomen is indicative of obstruction to the flow of blood in the inferior vena cava; distention of veins about the umbilicus suggests obstruction in the portal circulation. The former may be associated with varices of the lower extremities, the latter with hemorrhoids.

In all cases of recurrent vomiting examine the midline of the abdomen for a small epigastric hernia.

Catheterization sometimes makes the evidences of "appendicitis" or "abdominal tumor" vanish with the escape of the urine from a distended bladder.

In cases of run-over by vehicles, if the wheels pass over the trunk from right to left the liver is the organ most commonly ruptured, whereas, if the wheels pass from left to right the spleen is more frequently injured.

The hypodermatic injection of eserine (salicylate) gr. 1/30—1/40, during or just after an



abdominal operation, will, in most cases, entirely or largely prevent the distressing tympanites that otherwise usually occurs.

A pulsating swelling in the midline of the abdomen should not be too quickly accepted as an aneurism of the aorta. It may be a retroperitoneal tumor.

In a case of known or suspected visceral carcinoma, the finding of small nodules in or just beneath the skin is of vast diagnostic and prognostic importance. If an excised nodule is shown to be cancerous this will at once establish both the diagnosis and the futility of operation. In cases of intraabdominal carcinoma these superficial metastases are, curiously, most often found in the skin to the left of and below the umbilicus.

In the presence of large masses of glands in the epigastrium, especially on the right side, examine the testicles for new growth.

In a case of abdominal disease a vague mass in the epigastrium associated with exaggerated distinctness of aortic pulsation at that point



suggests pancreatic disease or retroperitoneal lymphatic tumor.

Large, slowly growing, slightly movable abdominal tumors near the median line, causing few symptoms and not accompanied by signs of malignancy, are suggestive of mesenteric cysts.

In the presence of a smooth, hard, fixed and often tender abdominal tumor giving no characteristic symptoms, it is worth while to think of an ectopic or fused kidney—especially if the mass be in the median line or near the pelvis.

A primary tumor of the lateral abdominal region in infants and young children is usually a sarcoma of the kidney.

If rectal examination in a case of intraabdominal carcinoma reveals in the cul-de-sac the infiltration known as "Blumer's shelf" metastasis has developed and radical operation cannot be undertaken.

In operating for perforating gun-shot wounds of the abdomen, find the source of any



bleeding first, before attempting to suture any perforation.

There is much less chance of a subsequent hernia if median abdominal sections are made not through the linea alba, where the aponeuroses are fused into a single layer, but a little to one side where there are three layers external to the transversalis fascia, viz., the anterior rectus sheath, the rectus and, except in the hypogastrium, the posterior rectus sheath.

In suturing a laparotomy wound in the right hypochondrium, remember that the vessel running near the round ligament may be punctured in the peritoneal suture. Its injury usually gives rise to very troublesome hemorrhage.

In suturing the fascial layers of the abdominal wall do not take too large bites with the needle. Necrosis may occur, and sloughing of the fascia predisposes to the formation of hernia.

Feeble, rapid pulse, fever and prostration, developing after laparotomy may be due to a progressive, and usually fatal, peritonitis even



though there are no abdominal signs or symptoms (such as distention, tenderness, pain and vomiting).

When gas comes from an abscess which has been opened in some part of the abdomen, it must not be hastily assumed that the bowel is involved, as many of the abdominal suppurations are associated with gas-forming bacteria. This is notably the case with subphrenic abscesses.

If there is repeated vomiting and the patient shows some evidences of collapse, after a laparotomy, especially after operation in the gastric region, examine for separation of the wound and prolapse of the abdominal contents.

In children, in cases of peritonitis of unknown origin, examine for gonorrheal vulvovaginitis.

A boggy, tender abdomen is often suggestive of a pneumococcus peritonitis. A careful inquiry as to a previous pneumonia or empyema is most important.



If a greatly thickened parietal peritoneum is found at an exploratory laparotomy one may expect to find tuberculous peritonitis.

The presence of an indefinite mass in the abdomen of a child running an intermittent fever may mean a tuberculous peritonitis.

A condition of euphoria is often seen in serious cases of peritonitis and should not be taken as a sign of beginning recovery.

In exploratory laparotomies the seat of disease may often be discovered by tracing the attachment of an adherent portion of omentum.

At least one good surgeon (Treves) never permits an intraabdominal pedicle ligature to include undivided peritoneum. He always exposes the vessel itself, except in omental pedicles.

A diagnosis between a tumor anterior to the rectus muscle and a tumor more deeply seated, can be made by grasping the tumor and then having the patient rise from the recumbent to the sitting posture. Tumors anterior to the rectus muscle do not escape from the grasp of



the fingers during this maneuver, while tumors behind the muscle cannot be firmly held.

Steady loss of weight without other demonstrable cause should lead the physician to look for a possible malignant visceral neoplasm. Persistent "indigestion" due to some condition not positively ascertained, should be submitted to surgical diagnosis.

## Bile Tract

There is such a condition as idiopathic swelling of the liver—an acute hepatitis—due to an unknown cause. The condition gradually subsides without treatment.

Before attributing enlargement of the liver to a surgical condition exclude chronic hepatic congestion of cardiac disease.

Repeated attacks of "indigestion," not obviously due to some other condition, should awaken the suspicion of gall stones. Most of the patients operated upon for cholelithiasis give a history of having been treated for a long time for "dyspepsia," and in many of these cases the correct diagnosis might earlier have been established.



If pressure in the right hypogastrium gives rise to a referred pain in the shoulder region, the offending area is probably the gall-bladder and not the pylorus.

In an attack of cholelithiasis the vomiting as a rule is not attended by relief of pain; the contrary is true in ulcer of the stomach.

In differentiating between gastric ulcer and gall-stone pains, the association of a chill usually points to cholelithiasis.

If one suspects acute cholecystitis and on opening the abdomen does not find the gall-bladder enough diseased to warrant further procedure, it may be well to anchor the organ by suturing it to the abdominal wall. If further symptoms are manifested, the gall-bladder can then be opened without anesthesia and a catheter inserted for drainage.

Tenderness over the gall-bladder region, especially if accompanied by colicky pain, usually means a pathological condition of that organ. But an inflamed retrocecal appendix extending high up, hydronephrosis, acute



pancreatitis, and an inflammatory condition at the pyloric end of the stomach are also to be kept in mind.

In catarrhal icterus the pulse is usually slow; in jaundice from cholelithiasis this is usually not the case.

Gradually increasing jaundice without previous history of pain, or with a history of very slight pain, is very suggestive of malignant disease.

Courvoisier's law is rarely broken—enlargement of the gall-bladder with pronounced jaundice means neoplasm.

Tuberculosis and cholelithiasis are only very rarely associated.

Long pauses between attacks of gastric or abdominal pain speak in favor of cholelithiasis.

In the progress of a cholecystectomy, if a stone slips away after cutting through the cystic duct, and cannot be found, no great anxiety need be felt, for the stone usually comes away spontaneously in the subsequent discharge.



Ligation of the cystic artery at the beginning of a cholecystectomy often makes the removal of the gall-bladder a bloodless procedure.

A gangrenous gall-bladder mucosa is usually easily stripped out (Mayo). It is a quicker procedure than cholecystectomy, and provides more rapid healing than mere cholecystostomy.

When palpating the common bile duct for stone, make sure that a suspected calculus is not a gland.

When removing stones from the gall-ducts don't neglect to explore the hepaticus—with a probe or, better, a narrow blunt spoon.

Moderate bloody discharge after extirpation of the gall-bladder is most often due to oozing from the raw surface of the liver. Sudden, profuse, bloody discharge is more dangerous, for it means that the ligature has slipped from the cystic artery.

Great pain following any operation upon the biliary tract should lead one to suspect leakage of bile below the gall-bladder. If such should be found to be the case insert a drainage tube.



In a case of perforation of the gall-bladder with intraperitoneal abscess or diffuse peritonitis, be content with providing free drainage, leaving more radical procedures for a secondary operation.

Persistent suppuration from a cholecystostomy sinus means the presence of a stone, ulcer or stricture in the gall-bladder or cystic duct.

By frequent feeding (every two hours) an obstinate biliary fistula may often be made to close rapidly.

An amebic colitis that has been quiescent frequently lights up after a complicating liver abscess has been drained. Such patients may recover from the abscess and succumb to the colitis. In all cases of amebic liver abscess, therefore, treat the bowel also, by appendicostomy and irrigation, even though it is giving no symptoms.

Excellent results may be obtained in liver abscess cases (solitary abscesses) that drain for a long time, by applying a Bier cup over the superficial opening once a day for five min-



utes. One must be especially cautious in these cases not to increase the vacuum too rapidly as rupture of the vessels in the liver might easily ensue and cause serious damage.

Unless a liver abscess bulges anteriorly, the safest and most logical route for drainage is the trans- or sub-pleural one.

A biliary fistula with patent cystic and common ducts may be used as a means of introducing medicaments or fluids into the bile tract or upper bowel.

Examine the rectum in all cases of tumor of the liver. Likewise, before operating for cancer of the rectum examine the liver for metastasis.

Examination to determine the possible presence of cardiac disease or aneurism should always be made before passing a stomach tube. In the presence of such lesions the tube should not be employed except as a life-saving measure in an emergency.

Stomach

A hasty diagnosis of ulcer of the stomach should not be made merely because the patient



has vomited suddenly large quantities of blood. If the bleeding occurs at regular intervals the possibility of vicarious menstruation must be considered.

The occurrence after laparotomy of marked distention of the upper abdominal zone, vomiting and collapse, points to acute dilatation of the stomach.

Hemorrhage from an old, indurated gastric ulcer is a much more serious matter than bleeding from a more recent ulcer, since in the former the bloodvessel may be unable to collapse and allow clotting.

If blood is vomited in large quantity it is important to distinguish, by the history and physical signs, between gastric ulcer and ruptured varicosities of the esophagus.

Repeated attacks of "hyperacidity" usually mean gastric or duodenal ulcer—gastric, if the pain is one hour or less after eating; duodenal if three hours or more after eating (Moynihan's "hunger pain"), and perhaps pyloric if about two hours after eating.



It is well to remember that not all ulcers of the stomach are characterized by the classical symptoms of pain, vomiting and hemorrhage. Many patients presenting "dyspeptic" symptoms of only mild grade are afflicted with this disease, and such cases may easily be diagnosed as functional disorders until the persistence of the symptoms leads one to suspect the graver malady.

The thirst following a hemorrhage from gastric ulcer is best relieved by small quantities of cocaine in solution.

Active hemorrhage from a gastric ulcer is rarely fatal; the weight of evidence indicates that it is better to operate after than during the bleeding. Active hemorrhage from a duodenal ulcer is often fatal; operate as soon as the diagnosis is made.

There are exceedingly few authentic cases on record of "idiopathic" gastric hemorrhage.

If an undoubted case of ulcer of the stomach is associated with chills, in most cases it means that the ulcer is adherent to the spleen.



A sudden desire for sharp, sour and spicy articles of food in a middle-aged or elderly person is often the first symptom of a beginning gastric carcinoma.

In a case of gastric disease of doubtful diagnosis, progressive loss of weight is the most important sign in determining the probability of carcinoma.

Gastric peristalsis from left to right, visible through the upper abdomen, is indicative of pyloric obstruction.

Perforation may be the first serious sign of carcinoma of the pylorus as well as of ulcer.

The possibility of gastric cancer must be considered in cases of supposed pernicious anemia.

In persons of middle age presenting gastric symptoms, the diagnosis of cancer should not be excluded because the symptoms have had a sudden onset. Such an onset occurs in a fair proportion of cases.



Vomiting, secondary anemia and absence of free hydrochloric acid in the gastric juice—a triad of symptoms at once suggestive of carcinoma ventriculi—may occur as a result of chronic nephritis. Especially if the urine contain no casts or albumin is the observer apt to be led astray.

If a patient vomits coffee-ground material in which no lactic acid is present, one can almost always exclude carcinoma.

A reasonable suspicion of the presence of a cancer in the stomach or intestine is sufficient indication for exploratory operation.

Operation for cancer of the stomach after the diagnosis has been made by the presence of a palpable tumor can not be hoped to be curative. The hopeful cases are those in which diagnosis is established through an exploratory opening, which may be made under local anesthesia.

Before proceeding with a radical operation for carcinoma of the stomach, examine not only the liver but also the general abdominal cavity,



especially the pelvis, and in females the ovaries, for any sign of metastasis.

Feel for the gland (of Virchow) behind the clavicular insertion of the left sterno-mastoid in every case of suspected gastric carcinoma. It is not infrequently involved by carcinoma quite early, may be of great aid in diagnosis, and may be the single contraindication to a radical operation.

Do not be too sure that a mass in the region of the pylorus is a carcinoma. In some cases the infiltration around a chronic ulcer is very extensive and may simulate the feel of a new growth.

If a patient begins to vomit long after a radical operation for carcinoma of the stomach, do not jump to the conclusion that the cause is a local recurrence. It may be a metastasis in the brain.

In a patient with spondylitis, symptoms simulating acute peritonitis may be due to acute dilatation of the stomach.



It is a peculiar fact that post-operative prolapse through the epigastric wound occurs frequently in operations for malignant disease of the stomach. Such wound therefore should be closed with more than usual firmness and all possible precautions should be taken to guard against post-operative vomiting.

Gastro-enterostomy should not be performed unless there is, or is deliberately made, an obstruction in the duodenum or at the pylorus. If these remain, or become, patent the food will not to be diverted through the artificial channel.

In performing gastro-enterostomy see that the opening in the transverse mesocolon is not so narrow that it may constrict the anastomosed segment of small intestine nor yet so large that it may permit of a possible hernia into the lesser sac. By inserting a number of sutures between the mesocolon and the stomach wall about the anastomosis these possibilities may, in large part, be obviated.

If within a week or two after the performance of gastrostomy the drainage tube should be expelled from the fistula, do not entrust its



re-introduction to inexperienced hands. It has sometimes happened that the tube has been pushed into the peritoneal cavity, instead of into the stomach.

### Intestines

In the presence of anemia or of faintness, without other apparent cause, inquire concerning the passage of black stools. The condition may result from hemorrhages due to an ulcer or neoplasm of the small intestine.

In carcinoma of the bowel local signs appear first and deterioration in health later; in intestinal sarcoma impairment of health is first noted and local signs appear later. In carcinoma obstructive symptoms are the rule, in sarcoma the exception. In carcinoma the growth of the tumor is relatively slow, in sarcoma it is rapid.

A gradually increasing anemia in an elderly person, without any other symptoms, is highly suggestive of a latent carcinoma, often in the intestine.

In typhoid fever spontaneous rupture of the spleen may simulate intestinal perforation.



The triad of symptoms—pain, vomiting and distention—without fever, points to intestinal obstruction.

Attacks of abdominal pain preceded by “rumbling” of the bowels are suggestive of some obstructive condition.

The passage of a small amount of gas or even of feces, after an enema, does not gainsay the presence of intestinal obstruction.

In an acute condition simulating intestinal obstruction if a large mass can be felt in the abdomen think of omental torsion.

Colon irrigation, after the method of gastric lavage, is sometimes effectual when the most actively compounded enemata are not.

In acute intestinal obstruction it is often preferable to relieve the immediate danger to life by tentative enterostomy or colostomy than to hunt for the cause of the obstruction.

Lavage of the stomach preparatory to an operation for intestinal obstruction had best be



done before anesthetizing. Performed during narcosis the procedure may cause alarming embarrassment of respiration and, if the throat should become flooded with mucus or stomach content, as occasionally happens, an aspiration pneumonia is very apt to follow.

Simple or multiple enterostomy, usually with prompt suture of the opening, is many times a life-saving operation in the presence of intestinal paresis, as from general peritonitis.

Post-operative acute intestinal obstruction in rare instances has for its causation an interstitial hernia through the abdominal wall. A mass composed of confined gut is usually present.

An attack of acute intestinal obstruction, with passage of blood, and in the presence of a cardiac lesion, is suggestive of thrombosis of a mesenteric vessel.

Every case of intestinal obstruction of obscure origin should be inquired into closely with reference to a previous history of cholelithiasis. If a definite history of this is obtained, one may suspect obstruction by a gall-stone.



When operating for volvulus of the large intestine, insert a rectal tube as high up as possible before attempting the reduction. The gut will quickly collapse and much manipulation will thus be avoided.

After resection of the small bowel lateral anastomosis possesses several advantages, as to safety, simplicity and patency, over end-to-end union. The gut ultimately becomes a straight tube if the stoma is made near the closed ends.

When performing lateral anastomosis after intestinal resection, make the opening reasonably near the closed ends. Long blind pouches may give trouble.

When resecting the cecum be careful not to tie the mesentery of the ascending colon too close to the bowel—the anastomosing loop of the ileo-colic and colica media lies very near the gut.

When the abdomen is opened to discover the sigmoid, if it is not found at once, search should be made toward the median line.



In infants sudden, severe colic associated with diarrhea or the passage of small quantities of blood, should lead one strongly to suspect an intussusception.

When reducing an intussusception don't pull on the intussusceptum but push on the intussusciens.

When a patient gives all the signs and symptoms of appendicitis, if the stools have been noticeably black, a duodenal ulcer should be kept in mind.

A perforated intestinal ulcer, especially if low down, may simulate acute appendicitis. A very high leucocyte count with a high percentage of polynuclears, and the presence of a large amount of fluid in the peritoneal cavity, accompanied by general rigidity, may suggest the diagnosis.

A palpable tumor in the umbilical region is often a malignant growth of the transverse colon. Benign growths of the mesentery are also found here.



A mesenteric cyst may give the same signs as a small ovarian cyst. Mesenteric cysts, although movable, are usually attached to the ascending colon. When the colon is dilated a direct relation can be made out between the gut and the tumor.

The presence of a tumor of the sigmoid flexure with symptoms of chronic obstruction does not always indicate a cancer. Such a condition may be due to a diverticulitis.

A fecal fistula may be made to heal more quickly by the application of the actual cautery.

In the presence of a movable, sausage-shaped mass in the abdomen, with a history of chronicity, it is well to think of the possibility of its being a case of hyperplastic tuberculosis of the intestine. This diagnosis will be rendered more likely if there are definite signs in the lungs.

At the onset of an attack of acute appendicitis the pain is usually referred to the gastric region.

Appendix



The cessation of severe pain during the course of acute appendicitis often means perforation.

If, in a case of probable "appendicitis" in a child, the history is of several attacks of pain, if these are severe paroxysms with complete remissions, and if there is a comparatively small movable mass in the iliac region, examine the stools for blood. The case may be one of intussuscepted appendix.

Not infrequently shifting dulness in the flanks is the only differential signs between diaphragmatic pleurisy (and beginning pneumonia) and appendicitis.

Meltzer's sign—pain on active flexion of the hip, with the knee extended, while the examiner presses firmly down over McBurney's point—is a most valuable corroborative evidence of appendicitis. It is not intended for cases in which abscess is palpably present.

The pulse rate is a very important guide in determining the necessity for operation in acute appendicitis; but sometimes it should be alto-



gether disregarded. If distinct pain and tenderness have not abated after twenty-four to thirty hours (especially if vomiting and more or less rectus rigidity coexist, but even without these) it is proper to operate without waiting further, no matter what the temperature and pulse rate; a gangrenous appendix may be found in a patient whose pulse is 70 and temperature  $100^{\circ}$ !

In the presence of a tumor in the right iliac region, however large, it is rarely safe to exclude appendicitis from the diagnostic possibilities.

The twisting of the pedicle of an ovarian cyst may simulate both the symptoms and signs of attacks of appendicitis.

A moderately hard, palpable mass in the right iliac region is often diagnosed as acute appendicitis with inflamed omentum around the appendix. But ileo-cecal tuberculosis with inflammatory exudate should be kept in mind.

If a patient with the signs and symptoms of chronic appendicitis is unduly anemic and has lost weight, be prepared for the possibility of



a more serious lesion, e. g., neoplasm, ileo-cecal tuberculosis.

When vomiting and right iliac pain or tenderness are associated with a chill and a pyrexia of  $105^{\circ}$  or  $106^{\circ}$ , exclude pneumonia and malaria before operating for appendicitis. If the appendix is diseased, exclude mesenteric thrombosis before closing the wound.

The tenderness in appendicitis may not be (probably usually is not) just at McBurney's point. The base of the appendix is, however, usually at, or near, that point. The site of greatest tenderness is often over the tip of the appendix. A line drawn between that site and McBurney's point will many times represent the general direction in which the appendix is lying.

In cases of chronic appendicitis, if an examination be conducted with the patient in a hot bath ( $105^{\circ}$  F.), the thickened appendix may sometimes be felt to roll under the finger.

The location of the Head zone will often decide whether a case is one of acute appendicitis with inflammation of the serosa or acute



salpingitis. If the Head zone commences at the level of the umbilicus, extends over to the right lumbar region, and to just below Poupart's ligament, it is probably acute appendicitis. If the Head zone begins two or three inches below the umbilicus with a broad base on the abdomen and extends to a single point midway between the hip-joint and the knee, the case is probably one of acute salpingitis.

In a case of appendicitis, there is great significance in the disappearance of a Head zone which had been present but a few hours before. It means that the tension on the serosa of the appendix has lessened, and may be due to rupture of the appendix.

Attacks of pain on the right side closely resembling renal colic and associated with hematuria, may be due to appendicitis. A calculus in such an appendix will also cause a skiagraph shadow in the path of the ureter!

When the appendix is so placed that its tip is not readily delivered the "retrograde" removal of the organ is often the simplest and safest method.



Congenital absence of the appendix is exceedingly rare. Don't pronounce the appendix "absent" without searching behind the caput coli and without splitting the cecal serosa downward from the ileo-cecal junction—the appendix may be completely subserous, even though no thickening is felt. Moreover, the appendix is occasionally intussuscepted into the cecum. Of course, the organ may have been previously removed through some unusual incision, e. g., inguinal or femoral herniotomy.

Before returning the intestines after appendectomy, make sure of two things: first, that there is no mesenteric thrombosis; second, that there is no bleeding from the mesenterium (one may bleed to death from an untied vessel torn, for example, when preparing the appendix base after tying the mesenterium).

Sudden, marked rise of temperature a few days after an operation for appendicitis, especially if attended by chills, may mean thrombosis of the portal vein, multiple abscesses of the liver, or subphrenic abscess.

Watch for the development of subphrenic abscess when there is persistent pain in the



lower chest and a dry cough several weeks after operation for appendicitis abscess.

If there is a sudden rise of temperature after appendicectomy, examine the rectum. A bulging of the wall of the rectum on the right side or anteriorly indicates the formation of a pelvic abscess.

If during an operation for appendicitis the cecum or ileo-cecal junction ruptures the bowel is profoundly diseased, as by sarcoma, ulcerative typhlitis, etc.

A persistent sinus after an operation for appendicitis in the majority of cases means that a portion of the appendix has been left behind. It may also mean that an exudate has not broken down or that some foreign body has been left in the wound. One should give the sinus an opportunity to close by itself, but if it does not do so, further operation is necessary.

All cases of hernia in which there is a history of frequent urination should lead one to the suspicion that the hernial sac contains part of the bladder.



A properitoneal epigastric hernia may give no external signs. The patient merely complains of pain in the epigastrium.

Vomiting in an insane person should always prompt an examination for hernia.

If a peculiar looking mass is found at the inner side of the ring in the course of an operation for inguinal hernia, do not incise or dissect it before convincing yourself that it is not the bladder.

The surgeon who adopts the rule not to tie off the neck of an inguinal hernia sac until he has dissected from it all doubtful fatty masses will save himself the embarrassment of occasionally injuring the bladder.

Probably the most important step in radical inguinal hernioplasty is the *total* removal of the sac. It should be traced back to the loose peritoneum itself, exposing the deep epigastric vessels, the ligature or sutures to be applied at that level. To leave even a little projecting knuckle of peritoneum invites recurrence.



As part of a hernioplasty it is always worth while to reduce by sutures the hiatus in the transversalis fascia whenever this can be conveniently done.

An inguinal hernia giving signs of obstruction and partially reducible, may empty into a properitoneal sac in Hesselbach's triangle, a loop of gut being compressed against the neck of the sac.

It is a wise rule never to attempt taxis in cases of strangulated hernia. The only exception might possibly arise in a case seen within the first hour.

If a hernia suddenly becomes irreducible, advise prompt operation; if the patient vomits, even once, insist upon it!

In cases of strangulated hernia a simple enterostomy after cutting the neck of the sac will often save a life where a prolonged operation would result in death.

Do not be too hasty in resecting a strangulated loop of intestine. It is remarkable how



often such loops become viable after applications of hot saline solution.

When dealing with a sliding hernia don't attempt to separate the large bowel from the sac; this attachment carries the blood supply of the gut. Free the sac, not the intestine, and reduce with the bowel as much of the sac as is attached to it.

If the sutures in a hernioplasty are tied too tight or too near together, a distressing induration of the tissues will often take place. This may be relieved by opening up the lower angle of the wound so as to let out the serum between the different layers of tissue. A glycerine dressing by its hygroscopic power will provide for speedy absorption.

When operating on a direct inguinal hernia undue enthusiasm to find a sac may lead one into the bladder.

Examine the umbilicus and the inguinal and femoral canals in all cases of obscure intestinal obstruction. Small strangulated femoral herniæ often simulate very closely the feel and appear-



ance of a gland, and in such cases one may be easily misled.

There is no convincing argument in favor of amputating *normal* omentum found in a hernia. There are sound arguments against it.

In ligating the omentum, it is a good rule never to place a ligature around a piece larger than the width of a finger.

Bloody stools after herniotomy in which omentum is amputated are usually due to thrombosis extending to the colon.

Silver wire sutures and wire filigree are useful in those hernioplasties in which a large gap cannot be closed by approximation of the tissues, or in which the tissues are so thin that, when approximated, they cannot be expected to provide support. In all other hernioplasties it has not been demonstrated that wire possesses any advantage over well chromicized catgut or kangaroo tendon. The prevention of recurrence, in hernioplasty, depends not on what the surgeon puts in his suture, but on what he puts his suture in.



Hemorrhage from the bowel in children is not infrequently caused by a polypus in the rectum.

Prolapsus ani is a frequent accompaniment of bladder stone in children.

Prolapsus of the rectum in children usually yields to treatment by strapping or binding the nates together, if carried out intelligently and persistently, for several weeks or months. The child should be obliged to defecate in the recumbent posture and while the strap is on. After defecation the strap is removed, the parts cleaned and a fresh binding applied, all the while the child is recumbent.

A mass protruding from the rectum of an infant or child may be an intussusception and not a mere prolapse.

To protect the hand from soiling and infection during a digital examination of the rectum or other cavity pass the finger through a small hole in a generous square of gauze and slip on a finger cot that will reach over the opening in the gauze.



Don't fail to make a digital rectal examination in cases of appendicitis and in all ailments when the diagnosis is obscure. Nor should it ever be omitted before an operation upon anal disorders. It may save the embarrassment of a subsequent discovery that a patient's hemorrhoids, for example, were but an expression of a carcinoma higher up in the rectum.

A radical operation for hemorrhoids should not be undertaken until the etiology of the piles has been determined. Sometimes the cause is an obstruction in the portal circulation due to hepatic disease. *Per contra*, abscess of the liver may be due to infection from a hemorrhoid operation performed even some months before.

In case of sudden pulmonary infarct, a patient should always be examined for hemorrhoids. A thrombosis of one of the veins of the prostatic plexus may also be the cause.

Bleeding from capillary hemorrhoids high in the rectum usually yields to injections of cold water, or a cold solution of tannic acid. In these cases, however, it is important to exclude the presence of an ulcer further up.



If a thrombosing pile is opened before the clotting is complete, it is very apt to fill up again and may even become edematous and inflamed.

When removing hemorrhoids much after-pain and edema may be obviated by making radiating nicks in the skin margin of the anus.

To relieve the edema following a hemorrhoid operation, apply a glycerine dressing covered with rubber protective.

After an operation for hemorrhoids it is desirable to insert into the rectum a tampon canula, made by smearing with vaseline gauze layers wrapped about a piece of rubber tubing, about three inches long and transfixed at its distal extremity with a large safety pin. The tampon canula prevents oozing by its gentle pressure, allows any considerable hemorrhage to show itself externally, makes the escape of flatus painless and the introduction of an oil enema easy.

A moderate prolapse of the rectum with hemorrhoids may possibly be relieved by the treatment of the hemorrhoids with clamp and cautery.



Blood lost at stool in the form of a jet is practically always from a hemorrhoid.

In suitable cases excision of the tract of a fistula in ano may result in a speedy cure. Persistence of the fistula may follow the operation, but so may it follow the slow healing procedure of free incision.

Injection into a fistula in ano of a staining solution or a colored paste makes it possible for the operator to assure himself that all branches of the tract have been explored.

Bismuth paste injections intelligently used will cure a fair percentage of rectal fistulæ.

Scrutinize carefully every "fistula" near the anus; a skin-lined sinus in the median line, in front of or behind the anus, is congenital and usually leads to a small dermoid.

Although profound anesthesia is required to abolish the anal reflex, chloroform or ether is not always needed in order to divulse the sphincter ani. This may be accomplished



painlessly, and often with fair satisfaction, under ethyl chloride or nitrous oxide narcosis, especially if an opium suppository is introduced a half hour beforehand, and a pledget of cotton wet in cocaine solution is applied just before the operation.

After operations upon the rectum, especially after those involving divulsion of the sphincter ani, voluntary urination is apt to be inhibited for a day or more. This is especially the case when stretching is done in a sagittal direction, *i. e.*, towards the urethra and the coccyx. It may save catheterization, therefore, if the stretching is done only laterally, *i. e.*, towards the tubera ischii.

The only evidence of an acute intussusception may be the passage of a small amount of blood per rectum. One should always make a thorough rectal examination for an intussusception, even high up in the small intestine, may sometimes be felt per rectum.

Stretching the anal sphincter alone will in many instances relieve an intense pruritus or a small prolapse of the anal mucous membrane.



The insertion through the sphincters at night, for a few minutes at a time, of a conical dilator (*e. g.*, of hard rubber), of gradually increasing size, is often a valuable adjunct in the treatment of pruritus ani.

When pruritus ani is caused by a local eczema it is well to remember that the latter may be seborrheal in origin. In such cases other areas of the disease, as on the chest and, especially, the scalp, should be sought for; they will require attention also, in order to effect a cure.

It may be worth while to inaugurate the treatment of an "idiopathic" pruritus ani by the administration of santonin or of enemata of quassia infusion—seat-worms may escape discovery on one or two examinations.

What a patient describes as a diarrhea may be, instead, a fecal-stained mucoid discharge due to the irritation from impacted feces in the rectum.

A complaint of excessive moisture about the anal groove should not be dismissed without a careful examination for a fistula.



## RECTUM

Don't jump to the conclusion that a benign stricture of the rectum is syphilitic. Gonorrheal proctitis causes dense cicatricial infiltration.

By constipating the patient, a high-seated rectal carcinoma may be pushed down within reach of the examining finger in the rectum. A *small* enema may balloon such a tumor within reach of abdominal palpation.

The habit should be developed of examining the lower bowel with a pneumatic procto-sigmoidoscope in all cases in which there is, or may be, a lesion in the sigmoid or rectum.

Severe burning pain in the anus coming on during, or just after defecation, and lasting for but a short time, almost always points to the presence of a fissure or ulcer. It may be very small and thus elude all but a most thorough search.

The cause of an obscure symptomless fever may be a pyelitis. Urinary examination will establish the diagnosis.

Rigidity of the muscles in the flank on deep palpation is as valuable a diagnostic sign as is

## GENITO- URINARY TRACT

Kidney and  
Ureter



rigidity of the anterior abdominal muscles. In the presence of a urinary disturbance (e. g., anuria, pyuria, hematuria) unilateral tenderness and rigidity in the loin are presumptive evidence of affection of the kidney on that side.

It is not sufficiently established that the character of the crystals found in the urine indicates the presence or identity of lithiasis in the urinary tract. When cystin crystals are constantly found in the sediment, however, if symptoms of lithiasis are present, the stone is probably made up of cystin.

An approximate determination of the origin of a hematuria may be obtained by noting the following points: If pure blood is followed by clear urine, the origin is in the urethra; if the patient first passes urine, then blood, the source of bleeding is probably in the bladder; if urine evenly mixed with blood is voided, the kidney is probably responsible for the hemorrhage; if long, fine clots resembling worms are passed, these, usually, are from the ureter.

One of the simplest and best differential signs between renal and vesical hematuria is obtained



by standing the urine in a conical glass for twenty-four hours. In hematuria of vesical origin, all the blood will have settled to the bottom by this time; in renal hematuria, the whole fluid will remain smoky.

The examination of the urine secured from each side by ureter catheterization is the most satisfactory means of determining the condition and functional activity of each kidney. Cryoscopy never earned general acceptation, and the phloridzin and indigo-carmin tests have not an absolute value.

A point worth remembering in the diagnosis of nephrolithiasis is that red blood cells are almost always found in the centrifugalized sediment of the urine even in the interval between attacks of colic.

In a very acid urine red blood cells may be disintegrated and appear under the microscope as an amorphous material. When it is important to determine the presence or absence of blood in the urine it is sometimes necessary, therefore, to resort to a chemical test, *e. g.*, that with guaiac resin.



A radiographic shadow simulating that of a urinary calculus may be produced by an atheromatous plaque, as, for example, in the internal iliac artery, a phlebolith, a calcareous gland, or a calcified enterolith in the appendix.

X-ray shadows of renal calculi very close to the vertebral column should make one suspect stones in one half of a horseshoe kidney.

When skiagraphing for suspected renal calculus the entire urinary tract should be exposed, *i. e.*, the kidney regions, ureters and bladder. Not infrequently a stone supposed to be in the kidney may be lodged in the lower end of the ureter, within reach from the bladder.

The injection through a ureter catheter of sterile olive oil against or, preferably, behind a small stone lodged in the ureter very often determines its expulsion into the bladder.

If a patient prepared for ureterolithotomy has a sudden surcease or an exacerbation of pain—and even without these if the stone is quite small—have a final skiagraphic exposure just before



operating. If the stone has slipped into the bladder it is better for both patient and surgeon to discover this by the x-ray than by the knife.

By a careful study of an x-ray plate it can usually be determined with fair accuracy whether a renal calculus is in the pelvis of the kidney or in the parenchyma, at the upper pole or the lower pole.

In cases of renal colic do not make too positive a pre-operative diagnosis of calculus, no matter how typical the symptoms may be. It has happened very often at the time of operation that no stone is found. Fortunately, these cases are nearly always cured by the exploratory nephrotomy.

Attacks of abdominal pain associated only with intestinal symptoms, may nevertheless be due to a renal or ureteral calculus, even though, in addition, a tender area may be palpated at a point more or less remote from the kidney regions.

The perinephric space is a frequent site of metastatic inflammation after furunculosis or other septic infection.



After nephrotomy, hemorrhage may usually be stopped by inserting deep mattress sutures into the kidney substance followed by superficial sutures of the same kind.

If possible, always tie each component of a kidney pedicle separately, not *en masse*.

If a stump ligature, *e. g.*, of the renal pedicle, is slow to come away, the process may be hastened by fastening it taut to a piece of rubber tubing stretched across the wound.

If pus persists in the urine after the extirpation of a kidney for suppurative disease, it often means that the ureter is involved and will require subsequent extirpation.

When operating upon the ureter for calculus or stricture, avoid undue manipulation; it is important to detach the ureter from its bed as little as possible.

Hypernephroma is distinguished from the other malignant tumors of the kidney by the very early appearance of hematuria.



In nephrectomy for hypernephroma it is very important to remove the renal vein.

The transperitoneal route, with retraction of the colon, affords the best exposure in radical nephrectomy for neoplasm.

Pyuria without symptoms is suspicious of an early tuberculosis of the urinary tract.

“Non-bacterial” pyuria is very suspicious of tuberculosis.

The examination for tubercle bacilli in the urine by the ordinary method of staining is not decisive by any means, even if the bladder has been catheterized and differential stains for smegma bacilli have been employed. Numerous examinations with the aid of these procedures should be made. The surest laboratory test is by injecting a large quantity of the sediment into a guinea-pig. Cystoscopy, however, will probably afford information that will more quickly establish the diagnosis.

### Bladder

Most cases of sudden, unexpected hemorrhage from the urethra are due to malignant



disease, but it is well to remember that there are cases of genito-urinary tuberculosis in which such a hemorrhage is the first symptom.

Hemorrhage from the bladder may yield to irrigations with ice-cold water and with 1-10,000 adrenaline solution, successively.

Never attempt to pack a bladder for hemorrhage without the aid of guy sutures; with them one can make absolutely sure that the gauze goes into the bladder, and not on top of it, pushing the organ away from the space of Retzius.

Post-operative hemorrhage from the base of the bladder that proves inaccessible to ligatures, and uncontrollable by packings, may be checked by the following method: Through several thicknesses of gauze, cut in squares, pass a double strand of heavy silk or of twine fastened on a stout needle. With the patient in Trendelenburg's position and the bladder widely opened, thrust the needle from within directly through the perineum, and bring the gauze firmly against the bleeding surface by pulling upon the threads, which are then to be fastened to an outside dressing.



It is a peculiar fact that many of the cases of tumor of the bladder occur among workers in aniline dyes.

The removal of bladder papillomata by open operation is apt to be followed by recurrences, which acquire malignant characteristics. The complete destruction of these growths by the Oudin high frequency current applied through the cystoscope, as introduced by Beer, promises much better results.

It should be borne in mind that stone in the bladder may be the primary cause in children of enuresis, masturbation or prolapsus recti.

In cases of frequent urination with large prostate exclude calculus before asserting that the symptom is prostatic.

What feels at the other end of the searcher like a stone in the bladder may be a fold of mucous membrane encrusted with urinary deposit.

If skiagraphs show the shadow of a calculus at the neck of the bladder when the patient is exposed lying flat with the organ empty, and in



the same position when the pelvis is elevated and the bladder full, the stone is in the prostate (or prostatic urethra) or in a diverticulum behind the prostate.

In cases of suspected rupture of the bladder, catheterization is not *always* a sure test. The rent may be so large that the catheter draws away urine that has already flowed into the peritoneal cavity.

For the removal of a stone, tumor or foreign body from an uninfected or mildly infected bladder, transperitoneal cystostomy is preferable to the suprapubic infraperitoneal route, in that the bladder can be sutured where it is covered with serosa without subsequent leakage. With proper technique, including protection of the abdominal wound and the intraabdominal field by packings, one need not fear peritonitis or wound infection.

To prevent a suprapubic or other drainage tube from becoming displaced fit another tube over it like a collar; this outer tube is split through half its length and the two portions are spread out over the skin and fastened down with adhesive plaster.



If the bladder does not drain after a suprapubic cystostomy, in all probability the catheter or drainage tube has become displaced into the space of Retzius.

Involuntary urination very often means a distended bladder, and in old men it should at once indicate an examination into the condition of the prostate. Vomiting, too, is often caused by distention of the bladder.

An acutely distended bladder should not be completely emptied in one sitting. Its rapid collapse may produce hemorrhagic cystitis.

Before employing a rubber catheter test its resiliency. If it is brittle or cracked, discard it. Not infrequently a rotten catheter breaks off in the bladder while, of course, a rough catheter or sound may play havoc in the urethra.

An intractable non-gonorrheal cystitis suggests a tuberculous kidney.

It should be remembered that infection of the bladder mucosa is capable of producing symptoms of retention.



One should watch carefully for overdistention of the bladder in all cases of lesions of the spinal cord. In children the bladder has been known to distend sufficiently to hold 20-40 ounces.

Before deciding on the necessity for a laparotomy for some vague abdominal condition, where distention is present, empty the bladder. In many cases the acute abdominal distress will disappear.

Unconscious patients should be catheterized at regular intervals of about eight hours.

Rectal examination sometimes aids in determining the variety of obstruction in prostatic hypertrophy. If the prostate is comparatively small, the obstruction is probably due to the middle lobe; if large, to the lateral lobes.

Prostate

A Mercier catheter is the first kind that ought to be employed in attempting to overcome retention caused by an enlarged prostate. Often it will have to be resorted to in the end; and, therefore, it will save much unsuccessful manipulation to use it at once. Occasionally,



a metal catheter will pass when even a Mercier fails.

In acute posterior gonorrhea with frequent urination and all portions of the urine cloudy, if these symptoms do not respond to irrigations of the bladder and urethra, gently massage the prostate—the expression of pus will indicate repeated massage as the treatment to be pursued.

Prostatic massage for gonorrheal prostatitis is not limited in its usefulness to chronic cases. In *some* cases of fairly acute gonorrheal prostatitis the symptoms do not abate until daily expression of the pus by massage is undertaken, and then they subside very quickly. Such a treatment must be undertaken only upon proper indications, however; otherwise employed in acute cases it will cause mischief.

Never open a prostatic abscess per rectum, no matter how much it bulges; always operate through the perineum.

It is a wise rule to submit all removed hypertrophied prostates to thorough examination by a pathologist. Carcinomatous degeneration may be found in some spot.



An hypertrophied prostate in which nodules can be felt per rectum is carcinomatous.

Carcinoma of the prostate often does not recur for some time; meanwhile the patient may look surprisingly well. This should not beguile the surgeon into a too hopeful prognosis.

Force is never helpful in overcoming the resistance of a stricture to instrumental passage; it is bound to do harm. A combination of patience and hot applications, with a strong admixture of gentleness and judgment, will effect the desired result in most cases.

Penis and  
Urethra

An apparently impermeable stricture of the urethra may yield to the following device: Pass a filiform down to the stricture, then simultaneously forcibly inject 10-20 c.cm. of glycerine and urge the filiform on.

Rupture of the urethra occurring between the posterior layer of the triangular ligament and the scrotum is one of the most serious accidents in surgery, and demands immediate operation.



A swelling or redness behind the scrotum, in cases of urethral stricture or developing after urethral instrumentation, usually means urinary extravasation, which requires prompt and active treatment.

In case of urinary extravasation from rupture of the urethra, make no attempt to pass a catheter, and waste no time in incising the edematous area, but perform perineal urethrotomy at once.

One death from urethral sepsis is enough to impress the importance of the teaching that perineal drainage should always be employed after internal urethrotomy three or more inches from the meatus.

When performing external urethrotomy without a guide it is often possible to trace the continuation of the urethra proximal to the opening, by means of a filiform bougie, even when all devices failed to secure the introduction of a filiform before the operation. If a filiform cannot be thus passed through the urethral wound, suprapubic pressure on the bladder may demonstrate the location of the



urethral orifice by the escape of a drop of urine or by bulging of the membranous urethra.

A constrictor applied too long or too tightly to the penis when performing circumcision, etc., may cause sloughing, or actual gangrene.

After circumcision it is important to prevent adhesion of the reflected mucous fold of the prepuce to the corona glandis, by the daily passage of a probe about the corona, and by the use of vaseline.

Absorbent cotton, so commonly used to catch the discharge of gonorrhea, is very inelegant. It sticks to the glans, allows the meatus to glue together, and is difficult to remove without soiling the fingers. The following is the cleanliest and most surgical dressing: In a six inch square of surgical gauze, of about four thicknesses, cut a slit in the middle just large enough to be passed over the glans and to be held behind the corona. Then simply draw the foreskin forward. Indeed, such a dressing will hold even if the patient has been circumcised, if the slit in the gauze is not too large. With such a simple dressing, there is no retention of the pus, no



irritation from contact with the secretions, the organ is readily inspected and the gauze is easily drawn off by a little pull at one of its clean corners.

If a urethral discharge persists in spite of active treatment, especially if it be by silver salts, discontinue treatment for a while.

If a patient with acute gonorrhea is kept in bed on a restricted diet, the saving of time in the cure will amply repay him for the confinement.

Non-specific urethral discharges in young boys may be due to foreign bodies introduced while masturbating.

Examine the inguinal regions for hernia in all cases of very tight prepuce causing difficulty in micturition.

“Sexual neurasthenia” in the male not infrequently depends on disease in the posterior urethra. Examine this area with the urethroscope and treat it locally.



If difficulty is experienced in reducing a paraphimosis because of swelling, before dividing the constriction apply a rubber bandage around the parts for a few minutes; this may relieve the swelling to such an extent that the paraphimosis can be easily reduced.

A comforting support for the testicles, when a patient is confined to bed with orchitis, is easily furnished by a well-padded cigar box cover, grooved to fit under the scrotum, and laid across the thighs. Adhesive plaster may be used in the same manner.

Scrotum and  
Testicle

In hydrocele the base of the tumor is below, in spermatocele it is usually above. A milky fluid obtained by aspiration usually speaks for spermatocele.

If a cystic swelling in the scrotum is opaque when examined by the well-known transillumination test, especially if a history of traumatism is elicited, it may still be a hydrocele. Admixture of blood in the hydrocele destroys its translucency.

The early reappearance of fluid after tapping a hydrocele does not necessarily mean that



the operation has been a failure. It may be but an inflammatory reaction, subsiding spontaneously or under the application of unguentum iodi.

If a male patient with supposed strangulated hernia complains of pain running down the inner aspect of the thigh it is well to think of torsion of the testicle.

A swelling in the inguinal region, painful to the touch, is, of course, often an inguinal adenitis (e. g., following gonorrhea). But an inflamed undescended testicle should be kept in mind.

Inguinal hernioplasty is a rational part of every operation for undescended testis. A hernia is always present, actually or potentially.

Accumulated experience shows that orchidectomy alone will not cure the great majority of cases of tuberculosis testis. In many, if not most cases, the vas deferens, seminal vesicle or prostate is involved, and it will be necessary to remove one or more of these structures in order to cure. Moreover, the other testicle frequently



becomes tuberculous. Open-air therapy is helpful.

Orchitis after an operation for hernia is best relieved by a wet or glycerine dressing with elevation of the scrotum.

Syphilitic interstitial orchitis resembles closely in appearance new growth of the testicle. Unless the diagnosis of neoplasm is beyond all doubt, and the Wassermann reaction is negative, an active course of specific treatment should be tried before removing the testicle.

In excising a varicocele under local anesthesia, tie the upper ligature first; the pain of tying the lower ligature will then be abolished.

After the open operation for varicocele the scrotum may be shortened by simply sewing the wound together transversely instead of longitudinally.

The presence of varicocele, especially if unilateral, should suggest an examination of the abdomen and pelvis for a possible growth pressing on the spermatic veins.



## FEMALE GENERATIVE ORGANS

### Vulva and Vagina

It is a good rule to always inspect the labia before making a vaginal examination. Many pathological conditions in these parts may otherwise pass unsuspected.

Persistent dyspareunia, with no other ascertainable cause, may often be found to lie in a chronic gonorrhea of Skene's ducts.

A chronic gonorrhea in women may be due to uncured disease of Skene's ducts. After these are slit open with a fine scalpel or with the galvano-cautery knife, the disease will be cured.

Hemorrhage from an accidental wound in the vulva is usually better controlled by gauze packing than by attempts at ligation.

Don't be tempted to exclude gonorrhea because you see no bacterial or other evidences of vaginal or urethral infection. In women the presence of gonorrhea may not make itself known for six weeks or more, and salpingitis may be the first evidence.

When the openings of the Bartholinian glands appear as two sharply defined red spots,



an antedating inflammation may be diagnosed with certainty, and in a great majority of instances a latent gonorrhea is present.

Simple incision is not sufficient in the treatment of Bartholinian abscesses. They should be swabbed out daily with iodine, and if they recur, excised.

Furunculosis vulvæ even when it persists in spite of all other treatment, will often yield to daily scrubbing with green soap and the application of a dressing of sublimate solution.

When cleansing the vagina and vulva in preparation for an operation, a soft cotton mop should be used for the vestibule; a stiff brush is too apt to bruise or lacerate the urethra and cause dysuria for some days thereafter.

The use of any considerable quantity of iodoformized gauze in the vagina involves the risk of a severe dermatitis of the vulva.

In the case of a vesico-vaginal fistula, the vaginal opening can readily be discovered by



## FEMALE GENERATIVE ORGANS

the injection of methylene blue into the bladder and noting its escape through the vagina. If, however, the opening communicates with the ureter, the blue colored fluid cannot be seen. In such a case, a catheter at times can be passed directly from the vaginal opening into the ureter.

One should always examine the anterior vaginal wall carefully when there is any urethral discharge, for it may be due to a periurethral abscess communicating with an infected vaginal cyst.

### Uterus

Uterine curettage has its chief indications in incomplete abortion, metrorrhagia (as from submucous fibroids), inoperable carcinoma, etc. Its indiscriminate employment in chronic endometritis is to be condemned.

Before performing curettage always make a final bimanual examination of the uterus in narcosis. The finding may determine some other form of treatment. Again, after curettage, before allowing the patient to get out of bed, carefully examine the pelvis for signs of a possible exudate.



As a final cleansing step after curettage of the uterus it is well to introduce, and at once withdraw, a packing of gauze. This brings out with it fragments of tissue not washed out by the irrigation.

Simple perforation of the uterus during a curettage in an aseptic field requires no further treatment than a packing of gauze in the uterus.

Cicatricial stenosis of the uterus has been the result of too vigorous curettage and of the intra-uterine application of caustics.

Sudden collapse after a curettage for supposed abortion may mean the rupture of an unsuspected ectopic gestation sac.

A rise of temperature after a curettage may be due to a piece of gauze having been left in the uterus too long.

In trachelorrhaphy care must be taken not to close the cervical canal at any point.

A high temperature just after or during an abortion is evidence of intrauterine manipula-



tion, especially if the discharge from the uterus is fetid.

A troublesome "erosion" of the cervix may disappear without any other treatment than the replacement by pessary of a coexistent retroflexion.

Don't advise curettage for "erosion" of the cervix, unless it resists treatment by caustics (zinc chloride or silver nitrate solutions) and by the correction of associated disturbances.

Bleeding after coitus is sometimes the earliest sign of cancer of the cervix.

Carcinoma of the cervix may remain hidden in the lumen of the cervical canal, which is then eroded and forms an irregular elliptical cavity. While the external os is closed suspicion of the serious condition present will be aroused by the foul or bloody discharge.

Some apparently inoperable carcinomata of the cervix will yield remarkably to repeated cauterization with the actual cautery and zinc chloride.



Sudden anuria may be the first symptom of a carcinoma of the cervix in an apparently healthy woman.

Persistent bleeding or irregular prolonged menstruation is very suggestive of uterine fibroids.

Uterine fibroids may be differentiated from disease of the tubes or ovaries by noting whether or not the cervix moves in the opposite direction when the tumor is pushed from side to side.

An obstinate constipation may be due to an extreme retroflexion of the uterus, the organ lying in the hollow of the sacrum.

Vaginal hysterectomy is more dangerous than abdominal hysterectomy when the uterus is adherent.

No operation for sterility in the female should be performed without first excluding sterility on the husband's part.

In case of hematocolpos and hematometra it is essential to precede all interference by a



## FEMALE GENERATIVE ORGANS

careful rectal examination in order to determine whether the tubes are distended or not. If hematosalpinx exists a laparotomy and salpingectomy must precede the vaginal operation, otherwise a severe peritonitis may be set up by a reflex discharge of infective secretion from the tubes.

Mobile retroflexions that resist manual reposition are often easily and painlessly corrected by placing the patient in the knee-chest position and then depressing the perineum. The sudden inrush of air balloons out the vagina and this effects the desired results.

In the early months of pregnancy examinations should be made to determine that there is no retroversion, or to treat it if it exists. A retroverted gravid uterus impacted in the curve of the sacrum always aborts.

### Female Adnexa

Ascites in the presence of a mass in the pelvis usually, but not necessarily, means malignancy.

Avoid introducing a uterine sound in examinations when pelvic inflammation is suspected. It may set up a parametritis.



Impaction of feces in the sigmoid and rectum, with absorption symptoms, may simulate pelvic peritonitis.

In pulling on the round ligaments in the Alexander operation, use the fingers rather than instruments; a surer hold is given, one can gauge the proper force to employ more readily, and there is less likelihood of the ligaments tearing.

An sudden acute onset of abdominal pain with tenderness over the appendix region but with rigidity of the right rectus low down, is very suggestive of acute salpingitis. The diagnosis is further confirmed if there is high temperature and extremely high leucocyte count (20,000-40,000; polynuclears, 80-90%) even though vaginal examination be inconclusive.

The presence of a Head zone starting in the inguinal region and extending down the thigh in the form of a kite (tail downward) should make one examine the pelvic organs thoroughly, for the lesion very probably is in the adnexa.



## FEMALE GENERATIVE ORGANS

Not infrequently subacute inflammations of the Fallopian tubes will be found to be of tuberculous origin.

When tuberculous involvement of the Fallopian tubes is evident to the naked eye, pan-hysterectomy should be performed.

Twisting of the pedicle of an ovarian cyst often produces all the signs and symptoms of acute or recurrent appendicitis.

An ovarian cyst with a long pedicle may be found in any part of the abdominal cavity. It rarely gives pain unless the pedicle becomes twisted. In such a case, a differential diagnosis between it and a hydronephrosis may be difficult. One may suspect the true condition by the mobility of the tumor.

Any menstrual irregularity or abnormality in a woman who has hitherto been perfectly regular and normal in her menstrual periods, should always suggest the possibility of an ectopic pregnancy.



Do not exclude the diagnosis of extrauterine pregnancy merely because vaginal examination reveals no mass in the pelvis.

The palpation of a pulsating vessel in the vaginal fornix of a woman who has skipped a menstrual period, will often give the clue to a possible ectopic gestation.

In rupture of an ectopic gestation sac and hemorrhage, the patient may refer the pain chiefly to the region of the right hypochondrium, and this may deceive the physician into the belief that he is dealing with a case of cholelithiasis. A careful history, vaginal examination, and the evidences of internal hemorrhage will differentiate the conditions.

An abscess of the right ovary may give the same signs and symptoms as acute fulminating appendicitis. If an incision for appendicectomy is made, it should be of sufficient length and low enough down to allow of careful examination of the right adnexa.

A large tumor supposedly a growth of the ovary may be a retroperitoneal mass, usually



a sarcoma, having no connection with the sexual organs.

### BACK

In all cases of lumbago, especially of the chronic variety, examine the sacro-iliac joints for tenderness. Such cases may sometimes be almost instantaneously relieved by applying broad strips of plaster from beyond one superior iliac spine to the other, across the back. The straps must be applied tightly and with the feet close together.

To locate, as for operation, the level of a certain vertebra in a patient so stout that the spinous processes cannot be satisfactorily counted by palpation, place one or more metal markers on the spine and make a skiagraph. Mark on the skin the position of each marker with silver nitrate or iodine. Then count off the vertebræ or ribs in the x-ray plate, relatively to the shadows of the markers.

A skin-lined sinus opening between the coccyx and the anus, when not very short, usually leads to a dermoid cyst situated close to the coccyx. Frequently, loose hairs from the dermoid may be found in the sinus.



A large abscess in the ischio-rectal region may communicate with an infected dermoid cyst at the base of the spine.

A deep swelling in the gluteal region developing after a fall is apt to be a hydropic bursa—there are several bursae among the glutei.

A uniform, often semi-fluctuating enlargement of one buttock, developing spontaneously and not of subcutaneous origin, is probably due to a subgluteal lipoma. Here, too, however, hygroma must be thought of.

Congenital paralysis of the lower limbs may arise from an internal (anterior) sacral spina bifida. In such cases rectal examination often reveals the trouble.

A congenital lipoma or localized hypertrichosis or nevus, or depression, or a combination of these, situated over the spine indicates a spina bifida occulta beneath. In the absence of any such index it is still worth while to skiagraph the spinal column for evidence of a bifidity in the laminae, when trophic, sensory, or motor disturbances in the lower extremities, or



loss of or incomplete control of bladder or rectum are not satisfactorily accounted for otherwise.

In a case of possible fracture or dislocation of the spine, give instructions that the patient be kept absolutely quiet in order to prevent an aggravation of the deformity.

In injuries to the cord, if the tendon reflexes are preserved, even slightly, one may exclude total severance, but the complete loss of these reflexes for the first few days after the injury does not establish severance of the structure.

A tumor on either side of the vertebral column with a slight bulging in this region and scoliosis, is often a perinephric abscess. But if cord symptoms are present, a sarcomatous growth of the vertebrae should be kept in mind.

## EXTREMITIES

Do not consider too lightly a history of "growing pains" in the extremities in children. These symptoms may be due to an osteomyelitis.

Gangrene of the extremities may be due to senile vessel changes; thrombo-angeitis; me-



chanical injury to bloodvessels; local infection; tumors; diabetes; constitutional infective febrile disease; poisoning with ergot, lead, phenol, arsenic or tobacco; syphilis; trophic cord lesion; Bright's disease; leprosy; embolism; frost; ainhum; or Raynaud's disease.

Do not be in a hurry to perform primary amputations after severe traumata of the extremities. First, combat the shock and prevent hemorrhage. Keep the wound as clean as possible; and only when the patient has quite recovered from his shock (at the end of a few days or more), perform the amputation.

Pulsation in the course of an artery should not lead to the hasty conclusion that one is dealing with an aneurism. A tumor overlying a large vessel, and also a vascular sarcoma of the bone, may simulate an aneurism very closely.

Never incise a swelling in the course of a large artery without first making sure that it is not an aneurism.



A young and apparently healthy individual with tendosynovitis should always be suspected of gonorrhea.

Before operating on a case of prepatellar or olecranon bursitis, symmetrically placed and indolent in course, make a Wassermann test or give the patient thorough antisyphilitic treatment.

When performing amputation, arthrectomy, osteotomy or similar operation it is wiser to leave the constrictor in place until the dressing is partly, or entirely, applied, than to remove it after tying the large vessels, in an effort to secure the small ones. In the former case the snugly applied dressing will safely prevent hemorrhage; in the latter case, there may be an alarming loss of blood from the numerous small vessels in the very time the efforts are made to tie them all.

Do not amputate an extremity for sarcoma without a previous careful examination of the lungs and mediastinum for metastasis. Such symptoms as continued cough, a small hemoptysis or beginning dyspnea, should be regarded as highly suggestive of such a complication.



After major amputations an elastic constrictor should always be left at the head of the bed, so that the nurse can immediately apply it in case of secondary hemorrhage.

One should inquire carefully for the history of the application of carbolic acid to a wound, especially of the finger or toe, when a gangrene with a distinct line of demarkation has developed.

Not all soft swellings of the axilla are to be incised. Aneurism of the axillary artery has been mistaken for abscess.

Upper  
Extremity

An acute non-purulent tenosynovitis may be satisfactorily treated by immobilization with plaster strips.

The superficial location of the ulnar nerve must be borne in mind when incising an abscess about the inner aspect of the elbow.

Persistent or recurrent pain in, or edema of, an arm may be due to a "cervical rib."

Subacromial (subdeltoid) bursitis is probably the most frequent single cause of persistent



shoulder disability after slight trauma. Localized tenderness, frequently disappearing when the arm is raised, is always present in the acute cases. Limitation of abduction and external rotation—by pain or spasm or adhesions—is usually present. In some cases pain or clicking is felt at the end of motion. A skiagraph will definitely establish the diagnosis if it shows thickening or calcareous deposit in the bursa, but a negative x-ray finding does not exclude bursitis. The condition must be differentiated from neuritis, tuberculosis, arthritis, fracture, gumma, etc.

Many, if not most, of the cases of shoulder pain variously diagnosed as circumflex neuritis, rheumatism, etc., are instances of subacromial or subcoracoid bursitis. With involvement of the former bursa there is usually tenderness just beyond the acromion, somewhat anteriorly; in the latter there is marked tenderness just external to the coracoid tip. Pain on rotation of the arm may be present in either; it is most constant in subcoracoid bursitis.

If there is reason to believe that one is dealing with a subacromial bursitis, the presence of



great tenderness on pressure over the humerus in the axilla does not gainsay the diagnosis—although such tenderness has not hitherto been described.

When Kocher's method fails to reduce a recent anterior shoulder dislocation it usually means that the manipulations have been conducted too rapidly. They should be deliberate.

Do not apply an elastic ligature about the arm without first interposing a towel. This may obviate subsequent paralysis.

A sinus leading high up in the axilla and discharging a moderately clear fluid may communicate with the shoulder joint or pleura.

A small, hard, tender nodule situated over the thenar or hypothenar eminences may be a broken-down dermoid cyst.

The injection into a ganglion of the wrist of phenol-camphor, two to ten minims, according to the size, and repeated once or twice if necessary, will cause its complete disappearance in many cases. It often helps to aspirate the ganglion before injecting it.



Chronic tenosynovitis at the wrist may be differentiated from other swellings (e. g., lipoma) by fulness and fluctuation in the palm when the prominent area is pressed upon.

Before anesthetizing a patient to operate upon a wound (e. g., of the wrist), in which tendons are severed, attach forceps or ligaments to any tendon ends that are visible. While struggling during primary narcosis the proximal ends of cut tendons are sometimes drawn up, and the above device will obviate slitting up the sheaths to secure them. Squeezing the extremity proximal to the wound will likewise prevent these retractions.

Never divide the annular ligament of the wrist. The hand is much weaker after it is divided than before.

When an injury to the carpus is suspected, it is important to have skiagraphs of the lateral as well as of the sagittal view. The latter alone may fail to demonstrate a dislocation of one of the bones, and even a fracture may escape detection in it.



Frequently referred to the surgeon because of the constant pain and marked tenderness, is to be noted a group of cases of what might be termed "occupation wrist pain." They differ from the ordinary case of "writer's cramp," "piano-player's cramp," etc., in that, while these latter frequently have pain in, or about, the wrist, the cases here referred to have no spasm, the pain is constant, and it is not of a neuralgic character. Sometimes it radiates along the thumb (as in mail-openers); sometimes it is localized to the inner border of the lower end of the ulna, which is very sensitive to pressure (as in shirt-ironers). The fingers are free. There may be pain in the forearm muscles (flexors).

For a single tenorrhaphy make the incision quite a little to one side of the line of the tendon and perform no more dissection than is necessary. This is to avoid adhesions of the tendon to the skin.

If a tendon has been divided by an incised or lacerated wound and the skin has united over it, it is better to wait a fortnight or more before performing tenorrhaphy. Otherwise or-



ganisms introduced with the traumatism may cause suppuration and sloughing of the tendon, not only defeating the operation, but making a later attempt at approximation difficult or impossible.

**Hand**      The best drainage should be afforded for all punctured wounds of the palm; suppurations in this region are very disagreeable and are followed by severe consequences.

The surgeon should not wait for redness before making a diagnosis of palmar abscess. Owing to the density of the fascial structures this sign is often lacking in the early stages.

In dealing with infections of the hand bear in mind that under a simple bleb may lie an extensive phlegmon, threatening, or actually involving, a tendon or bone and urgently needing a generous but wisely placed incision; while on the other hand, a tendon may be thrust from its protecting sheath into the area of destruction by a knife sweep more earnest than judicious. A crater-like opening in a sodden skin, though freely discharging pus, may need enlarging to protect the tissues underlying;



while another opening, too long continued by unnecessary packing, may cripple a joint or tendon by undue cicatrization.

In the treatment of hand and finger infections, it is very important to release from bandaging as much and as many of the fingers as possible, and as soon as possible. The habit of immovably bandaging up all the fingers, in the treatment of a lesion of some of them, saves the surgeon time, but, except in short cases, it often cripples the hand by stiffening the fingers.

Occasionally, contractures of the fingers following the treatment of a cellulitis of the hand and forearm may be due, not to the cellulitis itself nor to the incisions made to relieve it, but to fibrosis and shortening of the flexors in the forearm, the result of too tight bandaging or strapping. Such a condition—Volkmann's ischemic muscle contracture—must, therefore, be distinguished from the stiff, flexed fingers produced by the cellulitis. Passive motions and massage are helpful in both conditions, but in the former bone shortening (radius and ulna) is often necessary to accommodate the contracted muscles.



Chronic ulcers on the hands are found in brass workers; discontinuance of this occupation is necessary to secure healing.

Indolent sinuses, as of the fingers after deep infections, frequently heal by the daily use of prolonged immersions in hot water.

A subcuticular whitlow is often the superficial expression of a deep infection. After removing the raised epidermis carefully inspect the tissue beneath for a small opening. If this is neglected the process may speedily advance to the tendon sheath.

Paronychia may often be thoroughly drained by gently passing the knife point between the nail fold and the lunula without cutting the true skin. Disinfect with a drop of tincture of iodine, insert a tiny gauze drain and apply a small wet dressing.

If suppuration at the root of the nail does not soon subside after providing drainage, it may be necessary to remove the nail. This should not be done too hastily, however. Persistence in daily disinfection of the space



(iodine, hydrogen peroxide, etc.), and stimulation of the tissues (as by massage) will often be rewarded by saving the nail.

Ichthyol is helpful in the treatment of chronic non-suppurating paronychia. The underlying cause of the affection must be sought—syphilis, eczema, or favus of the nail, the use of caustic alkalies on the hand, etc.

If a patient presents himself with a painless cellulitis of the finger or hand, it is necessary to make a careful examination for the possible presence of syringomyelia.

A felon may frequently be aborted by covering the end of the finger with cotton saturated in alcohol, and protected from the air by a rubber finger cot.

In dealing with infections or injuries of the fingers amputation should be a last resort. This is especially the case with a thumb, the most important of all the fingers.

In a case of fresh traumatic amputation of a part of the finger, if the amputated part has



not been too lacerated or crushed, try to restore the member by cleansing the parts carefully and suturing it to the stump. Once in a while the graft will "take."

Amputation of a finger gangrenous as the result of carbolic acid application should not be performed until the line of demarkation is well established. The necrosis may be superficial and in such an instance the finger may be saved by means of skin graft.

### Lower Extremity

Persistent pains in the leg may be due to "obliterating endarteritis." This occurs occasionally even in young men and often goes on to the production of gangrene. The pathology is a slowly progressive thromboangitis.

Flat-foot is another cause of pains in the leg or thigh.

A psoas abscess may point over the anterior spines of the ilium, simulating osteomyelitis of that bone.

A psoas abscess occasionally points in the outer part of the groin. When there is no evi-



dent spinal deformity to suggest the diagnosis the swelling is apt to be mistaken for a growth.

In cases of pain in the hip of doubtful origin, examination of the kidney regions may discover the cause.

The presence of sciatica demands a careful exploration of the pelvis by rectal or vaginal examination. It should also be remembered that Osler described sciatica as one of the early symptoms of cancer of the breast.

Pains as of sciatica may be caused by a developing lesion in the upper end of the femur or in the ilium.

A large slowly healing superficial ulcer of the leg may be due to a thrombosis of one of the small vessels leading to that part. Of course, syphilitic etiology must be first ruled out.

Instead of suturing the skin after amputation of an extremity, it is sometimes better to bring the flaps together with broad strips of adhesive plaster, especially if the operation is performed for an arteriosclerotic condition.



The best means of securing a painless end-bearing amputation stump consists in covering the raw surface of the bone, whenever there is no contraindication, with an osteo-periosteal flap, after the manner of Bier.

During the course of a pneumonia, severe pain in the leg is indicative of the deposit of a septic embolus in the lumen of one of the veins, which often results in an ascending thrombosis and phlebitis, necessitating amputation.

A rounded swelling situated over the insertion of the hamstrings on either side of the leg is apt to be an hygroma or ganglion derived from the tendon sheaths.

Severe pain in the region of the knee joint with redness and high fever may mean an inflammatory condition of the joint or adjacent bone, but it also may be due to a phlebitis of the superficial veins of the leg.

The following are some of the conditions in the presence of which an examination for tabes dorsalis should never be omitted: 1. All primary swellings of the knee or ankle joint with-



out apparent origin. 2. "Sciatica" and "lumbago." 3. A deep ulcer on the base of the great toe. 4. Repeated vomiting at various intervals, with periods of well-being intervening. 5. Abdominal pains without other evident cause.

Pain in the leg after an abdominal operation often means the development of a femoral vein thrombosis. This occurs usually on the left side.

Lymph-edema of the lower extremity associated with a swelling in the groin (fluctuating or not) is significant of carcinoma of the inguinal glands. The primary lesion may be in the rectum, *e. g.*, an epithelioma of the anus that is giving no symptoms.

When removing a lipoma or other growth from the inner surface of the thigh, a little care should be exercised in order to avoid cutting the long saphenous vein. Ligature of that vessel (especially in ambulant and in non-aseptic cases) may be followed by a distressing phlebitis.



Inflamed areas and abscesses about the knees of creeping infants should be examined for foreign bodies.

Punctured wounds about the knee should be treated with the greatest solicitude and attention to asepsis, in order to prevent infection of the joint.

Neuralgia is differentiated from neuritis by the fact that in the latter pressure upon the nerve increases the pain. The pain of neuritis is more constant, and there are peripheral disturbances in the structures supplied by the affected nerve.

In amputations below the knee, insist on active and passive motion of the knee joint at an early date. If this is not done contracture ensues, which makes the application of an artificial limb difficult.

Nurses should be instructed not to massage the limbs of patients who complain of pain after operation or confinement without the order of the attending surgeon. If phlebitis



and thrombosis are present, the manipulation may loosen a clot and cause instant death.

Acupuncture, followed by the application of the Bier cup is an excellent way of relieving dropsy of the legs.

A hematoma may be produced in the calf muscles by a direct or indirect violence that the patient may pay little attention to at the time or even fail to recall.

Swelling of the leg, associated with febrile disturbances, may be produced by hematogenous infection of a hematoma of the calf muscles. Such a condition may somewhat simulate osteomyelitis or other serious condition. It may be differentiated, however, by the location of the greatest tenderness and swelling and by a careful inquiry into the history. If no distinct traumatism is recalled the condition of the patient's arteries may nevertheless suggest the possibility of the occurrence of such a hematoma.

Patients with varicose veins should be instructed that in case hemorrhage takes place, the best method of stopping it temporarily is to



merely compress the bleeding point with the finger.

Never advise an elastic stocking in cases of varicose veins where recent phlebitis exists. The pressure may detach a part or whole of the thrombus, propelling it into the general circulation.

When a patient with inflamed varicose veins suddenly develops dyspnea and cyanosis, don't sit him up to examine him—the probability of pulmonary embolism is too great.

Chronic leg ulcers very often heal quickly under the Unna zinc oxide-gelatine dressing, when all other efforts have failed.

If a varicose ulcer resists intelligent efforts at cure, it is worth while regarding it as possibly syphilitic.

### Foot

Tenderness in the heel, or pain and tenderness in the sole of the foot is very often, indeed, of gonorrheal origin. It will not be relieved in such cases until treated on that basis. The patient may deny that he ever had gonorrhea. Examine his urine; shreds tell their own story.



Do not be too hasty in ascribing the cause of pain in the tendo Achilles, or Achilles bursa, to an ill-fitting shoe. First exclude gonorrheal infection.

The calcaneus spur is a real condition—especially in people past middle life. It may be associated with flat-foot, but is *not* flat-foot. A properly fitting ring cushion will often give relief.

Pain *under* the heels is also caused by contracture of the plantar fascia, and by calcaneal bursitis.

If the cause of pain in the feet is not otherwise clear, examine them in the dependent position. This may develop the presence of erythromelalgia.

The determination of the presence of a fracture of one of the mid-tarsal bones is extremely difficult, and usually impossible, without x-ray examinations. Yet these examinations have shown the occurrence of such fractures, alone, or associated with injuries to other bones, as the result of slight or severe direct violence.



For this reason and because fractures of the metatarsals by indirect violence are by no means uncommon, it should be practically a routine to submit the foot to skilful skiagraphy in all cases where either form of violence may have occurred. It will save many patients from weeks of suffering and disability. In this region, more than any other, the x-rays are a means of diagnosis that cannot be dispensed with.

It is often desirable to skiagraph both feet where one is injured. This will save the surgeon from mistaking, e. g., a sesamoid bone for a fracture.

Many, at least, of the sprains of the ankle involve a fracture of the tip of the malleolus, and should be treated by immobilization in plaster-of-Paris.

Resection of the head of the projecting phalanx so often yields an entirely satisfactory result that amputation should not be advised for hammer-toe until the less mutilating operation has been tried.

If a patient complains of sharp pain in the big toe, examine the urine for albumin and



sugar in order to exclude a nephritic or diabetic condition.

Perforating ulcers and localized gangrenous processes in one or both feet, without other obvious cause, (e. g., tabes, diabetes, obliteration of bloodvessels, frost-bite) indicate a careful examination of the spine for an evident or concealed spina bifida.

Be very guarded in the prognosis of ulcerations on the sole of the foot in diabetic or tabetic patients, no matter how small or trifling the ulceration may be. They persist for long periods and may even never heal.

In old people, as in diabetics, corns, bunions and wounds of the feet demand the most careful attention. They are often the starting points of gangrene.

Callus about a perforating ulcer of the foot is a trophic disturbance not dependent on pressure for its cause.

A very simple method of curing a corn is to excise it.



The bad habit of trimming the corners is responsible for many cases of ingrowing toe-nails.

In ingrowing toe-nail, evulsion of the nail gives temporary relief, but it does not cure. When the nail grows out again the condition recurs, often in aggravated form.

In mild cases of ingrown toe-nail conservative treatment will usually accomplish much, even in the presence of granulating masses. This treatment includes drawing the flesh away from the nail with a strip of adhesive plaster, insertion of a gauze packing under the nail edge and the application of a very small absorbent antiseptic dressing.

The following is a simple and usually satisfactory operation for ingrown toe-nail that has progressed beyond palliative treatment: Beginning at the free margin of the nail about a quarter of an inch from the offending side, with straight, strong, narrow-bladed, probe-pointed scissors cut through the length of the nail and continue *under the skin*, directly through the root. With forceps loosen and lift out the narrow segment of nail and nail root complete. It



is important to look under the nail fold for any fragments of nail that may remain, and to lift them out, if found. The operation is brief and the pain, even if no anesthetic is used, is not very severe. Lightly pack the narrow wound. If there is much infection apply a small wet dressing, otherwise a simple pledget of gauze fastened with adhesive strips. The patient can at once walk with comfort in his street shoes, and the after-treatment is trifling.

The removal of a wedge of skin at the side of an ingrown nail, as in Cotting's operation, is rarely necessary and usually objectionable. Granulations disappear quickly when the nail segment is withdrawn; if they are exuberant they may be snipped or burned off.

In acute ("septic") osteomyelitis immediate operation is not too radical; in chronic osteomyelitis patient waiting is often not too conservative—the final expulsion of a sequestrum may be all that is necessary to effect spontaneous cure.

## Bones

The sooner a long bone is opened in acute osteomyelitis the less the destruction.



No chronic bone swelling should be subjected to operation without excluding syphilis.

If a chronic localized osteo-periostitis, as shown by the x-ray, continues to give pain in spite of internal (specific) treatment, the bone should be explored. One is very apt to find a small collection of pus in the medulla, of which the radiograph gives no indication.

When dealing with a chronic bone abscess (and often, too, in acuter cases) it saves weeks of after-treatment to work with an osteo-periosteal ("coffin lid") flap, and close the wound completely—as compared with open osteotomy. If infection takes place the wound may be laid open and nothing will have been lost.

The prognosis in tuberculous disease of bones and joints in children has been improved more by the practical application of the fresh air treatment than by any other means. The next step in surgical enlightenment is to apply the same treatment to other surgical diseases.

Osteosarcoma about a joint may closely simulate a rapidly-growing exostosis or arthritis deformans.



Unexplained septic temperatures in an infant should lead to the search for a hidden osteomyelitic focus—especially in the upper end of the femur.

Pulsating bone swellings are usually sarcomata.

Do not advise amputation for every case of bone sarcoma—the results of resection are about as good and not nearly so mutilating.

For wiring bones iron wire is stronger than silver, and can be had at any hardware store. Wire cable (Lilienthal) seldom breaks when twisted, as do single metal sutures.

Tuberculosis of the bones develops in the epiphyses or the joint synovia. An inflammatory lesion in the shaft of a long bone is never tuberculous.

The x-ray is invaluable in the diagnosis of bone cortex and periosteal disease. In bone medulla infections it is of little service.

Subacute osteomyelitis at the mid-shaft of the tibia is often post-typhoidal.



The history of typhoid several years previously will explain many cases of otherwise obscure localized bone abscess. The perforating cortical ("shirt-stud") abscess is characteristic of typhoid infection.

It is well known that trauma may determine a virulent osteomyelitis, requiring prompt attention. It is not so well known that it may determine a milder type of bone infection that soon recedes without operation. The former is most often met with in children, the latter in adults.

Septic endocarditis may result from a localized osteomyelitis that has gone on to spontaneous cure.

### Joints

Suppurating arthritides do not always require exposure of the joint or even large incisions, irrigation and drainage. Such treatment invites mixed infection and ankylosis. If the pus be very thin—even though of streptococcic origin—thorough *aspiration* (which may need to be repeated) and immobilization may effect a rapid cure with perfect function. Purulent arthritis and peri arthritis as it occurs in small



children as a complication of one of the exanthemata (often in connection with trauma) is often quite amenable to conservative, and even ambulant treatment: aspiration, or irrigation and drainage, and immobilization. Judgment is needed, of course, to determine what cases are amenable to this conservative surgery, and at what point in the treatment it must be abandoned in favor of more extensive intervention.

A chronic cystic swelling in the neighborhood of a joint is in the majority of instances a distended bursa.

A chronic synovitis of apparently unknown origin and very rebellious to treatment is sometimes due to a small focus of osteomyelitis just beneath the cartilaginous surface.

A synovitis that persists despite careful treatment should arouse suspicion of tuberculosis.

The presence of shreds in the urine is a presumptive evidence more useful to the surgeon who seeks the etiology of a monarticular inflammation than is the denial by the patient that he has had gonorrhea.



## EXTREMITIES

Bilateral swelling of the knee joints without pain, in a child, is due either to syphilis or tuberculosis, more likely the latter.

In operating for loose bodies within the knee joint, do not be satisfied with removing but one body; a careful examination should be made to determine the presence of more, for they are very frequently multiple.

Do not operate for foreign body in the knee joint without first excluding dislocation of one of the semilunar cartilages.

In immobilizing the knee-joint the patient is more comfortable and better relaxation is secured if a very slight degree of flexion is maintained.

## FRACTURES

Very often the unskilful treatment of a fracture is worse than no treatment at all. Serious deformities may result from the neglect of small details no less than from the violation of important principles.

The important considerations in the treatment of fractures are, at first, relief of pain and



reduction of swelling, and, subsequently, preservation of function of the muscles, the nerves and the neighboring joints. Hence the value of early and frequent massage and passive motion (and in suitable cases, of active motion) and the necessity of avoiding splints that unduly compress the muscles or deprive them of activity.

In the treatment of fractures of the forearm no consideration is more important than the avoidance of contractures of the fingers, by the intelligent use of splints and by means of early, active and passive movements.

Permanent contracture of the muscles, notably of the flexor group in the forearm, may develop within a very short time after the application of a splint that exercises undue compression. It is a wise rule to inspect all fracture dressings within twenty-four hours; and when this is not expedient special care should be exercised, when applying the dressing, to avoid compression.

In very many cases it is not necessary to the diagnosis of fracture to elicit crepitus and ab-



normal mobility—often painful manipulations. In several forms of fracture there are other positive diagnostic evidences. Thus, with Colles' fracture the level of the styloid of the radius will almost always be found to have receded from beyond that of the styloid of the ulna. Moreover, x-ray examinations save much painful manipulation.

Satisfactory reduction is the most important step in the treatment of Colles' fracture. Once reduced the fragments have little tendency to displacement; therefore, prolonged immobilization without frequent movement of the wrist will result in a stiff joint, for which the nature of the injury does not provide excuse.

In an injury to the wrist tenderness just distad to the radius and in the "anatomical snuff box" is significant of fracture of the scaphoid.

After all, the localization of bone tenderness is not only the most useful sign in determining the site of a fracture, but, even in the absence of other signs, it is often, in itself, diagnostic of the presence of a fracture. As instances may be cited greenstick fracture of the clavicle, and fracture of the metacarpal and metatarsal bones.



In all examinations of children, and in the examination of adults for suspected fractures, leave the painful manipulations for the last.

The x-rays have taught us that mathematical reduction is rarely, and even linear reduction is seldom, accomplished even in cases in which excellent functional results are secured. Radiographs have thus frequently been made the basis of blackmailing damage suits. Nevertheless, the x-rays are, of course, of immense value in the treatment of fractures—not only for reference before and after reduction, but during the reduction itself.

A fracture produced by only slight violence should at once raise the suspicion of a malignant growth. In such cases a uniform dark shadow about the bone as seen in the fluoroscope is to be interpreted as a neoplasm rather than as callus, for recent callus is not opaque to the x-rays.

That a bone appears normal by fluoroscopic examination does not gainsay the presence of a fracture. A fracture of the radius, for example, may occur without displacement of the fragments. An x-ray plate will demonstrate the line of fracture when the fluoroscope fails to.



A sharp pain felt at the outer end of the groin upon sudden motion of the thigh, as in starting forward from a crouching position in a foot race, suggests fracture of the anterior spine of the ilium. This occurs usually in adolescents.

Severe localized pain after traumatism, especially in children, may be due to subperiosteal fracture, *e. g.*, near the head of the humerus or the femur. Extreme localized tenderness is the chief sign; abnormal mobility and deformity are absent, and crepitus may not be elicited.

The x-ray shadow of a deposit in the subacromial bursa may easily be mistaken, by the inexperienced, for that of a fracture of the tuberosity of the humerus.

In cases of fracture where the end of the bone lies close beneath the skin do not place a pad or any pressure whatever over this point.

In compound fractures involving loss of continuity do not needlessly remove any piece of bone that has even the smallest attachment. It is surprising how often such pieces heal into



the wound and thereby help to save loss of substance.

When applying a plaster dressing to the leg always include the foot if the patient is to be confined to bed; otherwise "drop foot" will develop.

In cases of fracture of a rib, it is necessary to watch the patient carefully for a couple of days to note the onset of a possible lung complication. Localized pneumonitis sometimes occurs.

In severe falls or blows or fractures of the pelvis, catheterize the patient as soon after the injury as possible in order to discover a possible rupture of the bladder.

Fracture of the outer end of the clavicle may follow a fall upon the shoulder. Unless one makes a careful examination such a fracture may escape observation or be mistaken for a dislocation of the outer end of the clavicle, with which condition, indeed, it may be associated.

Shortening of the shoulder, as measured from the sternal end of the clavicle to the acromion process, is significant of fracture of the clavicle.



In the aged, pain and disability in the arm after traumatism demand especial care in examination of the shoulder. Fracture of the head of the humerus is often overlooked.

In fractures of the anatomical neck of the humerus, examine carefully for injuries to the brachial plexus.

During and after the healing of fractures of the shaft of the humerus, the forearm and hand should be examined for wrist-drop and other evidences of musculo-spiral paralysis.

In an injury to the elbow gentle palpation and study of the relations of the bony landmarks—the olecranon, the condyles, the head of the radius—are usually quite sufficient to establish a diagnosis without painful manipulation.

The radiograph of the elbow of a child shows shadows of numerous epiphyses. One inexperienced with x-ray plates is very apt to mistake one or more of these for fractures. When examining the skiagraph of a child's elbow suspected of fracture or dislocation, it is,



therefore, important to have the normal picture in mind, or better yet in hand, for comparison.

Much information concerning the nature of an injury to the elbow can be derived by comparison of the joints on both sides posteriorly, the patient facing away from the examiner.

If a small child has been pulled by the arm and thereafter has disability in that member, attention should first be directed to the upper end of the radius. Here one is apt to find a subluxation of the head of the bone ("pulled arm") or an epiphyseal separation.

Fractures of the head of the radius are probably more common than generally supposed, being overlooked frequently because of the absence of the ordinary signs of fracture.

A patient should not be considered neurasthenic because he cannot walk after union of a fracture of the os calcis. There is often considerable pain due to adhesions and the incorporation of portions of the tendo Achilles in the callus.



If pain on walking persist after a fracture of the os calcis, or, indeed, after an injury in which fracture may have been overlooked, determine with the x-ray whether there is a projecting fragment or a breaking down of the inferior arch of the bone, or both.

Pain is often present for months after a fracture of the leg, especially in elderly people. This is mainly due to the formation of the callus and needs no operative interference. Of course, a subacute osteomyelitis must be kept in mind.

Marked tenderness over the lower end of the radius, after traumatism, without deformity, is suspicious of fissure of the bone. Mobility or crepitus may be obtainable.

The silver-fork deformity is by no means necessary to the diagnosis of Colles' fracture.

If a patient gives a history of "sprained wrist" that has remained feeble and painful in spite of appropriate treatment for sufficient time, and if the wrist presents thickening and tenderness at its radial aspect, a diagnosis of



fracture of the scaphoid should be entertained. Colles' fracture must be excluded, by the relation of the two styloid processes and the location of the deformity. Fractures of the radius and scaphoid may, however, coexist.

Fractures of the neck of the femur in old people sometimes cause no other symptoms than disability. The mildness of the trauma and the freedom from much pain should not deceive one.

A padded triangular wooden or cardboard splint—one leg of the triangle bandaged to the thigh, and another to the trunk—makes an excellent ambulatory apparatus in the treatment of fractures of the shaft of the femur in small children. It maintains reduction, leaves the leg free and does not interfere with keeping the child clean.

For the diagnosis of fractures of the upper end of the femur careful measurements are often of greater value than any manipulations—and much safer.

Everson of the foot, shortening of the extremity, elevation of the trochanter, spell frac-



ture of the neck of the femur. Manipulation is unnecessary to the diagnosis.

The old treatment of fracture of the neck of the femur by Buck's extension is as bad as it is archaic. In all but very old and very feeble subjects reduction and fixation in plaster by Whitman's method is the treatment of choice.

The administration of thyroid extract in a case of delayed union after fracture will do no harm and may do good. Exclude neoplasm, syphilis and malposition, first.

Cardboard splints can be best molded to an extremity by tearing, instead of cutting them.

When operating upon a fractured patella it is very important to sew the torn lateral ligaments of the joint. These aid largely in the support of the joint.

It must be remembered that fractures of the metatarsal bones may be produced by slight injuries. Thus, the base of the fifth metatarsal may be fractured by a twist of the foot while walking or dancing.



Even in the absence of a suggestive history, one should bear in mind the possibility of a foreign body as the cause of localized pain, tenderness, inflammation or impaired function, when the cause cannot otherwise be determined.

Needle thrusts are often only slightly painful, and thus it occasionally happens that there is buried in the tissues a fragment of needle, the entrance of which the patient did not appreciate or has quite forgotten.

Creeping infants may gather wood splinters or needles in their hands or knees, and abscesses in those localities should suggest such an etiology.

When it causes suppuration, a foreign body is usually easily found, but if there be difficulty in locating it, it is better to be content with drainage for a few days rather than expose uninfected areas by a prolonged search.

Circumscribed tenderness is especially significant of the location of a foreign body. Making allowance for the tenderness due to infection, when this is present, a point of persistent



maximum tenderness is fairly diagnostic of the location of the body beneath that point. By pressure, with the finger tip or a slender instrument, on one spot after another in the suspected region, one may elicit only a single point of tenderness, or a point of maximal, and several adjacent points of lesser tenderness. The single or maximal point indicates usually the location of the most superficial part of the foreign body, especially if it be a needle or sharp splinter of glass, wood, etc.; the points of lesser tenderness map out, in a rough way, the general direction of the body.

Stereoscopic radiographs best demonstrate the position and depth of a needle, piece of glass, etc. If bismuth is rubbed into the skin, the depth of the body from the surface will show more clearly.

Don't attempt to remove a foreign body until it has been definitely localized if possible. If stereoscopic radiography is not available the fluoroscope may be employed, moving the member in various directions before the screen to secure the relations to the bones.



To localize a bullet, needle or other object in the head, neck, thorax, thigh, etc., stereoscopy can be combined, to advantage, with a mathematical localizing method, employing one or more metal markers on the surface.

Sewing machine needles entering the finger tip are often driven through and firmly impacted in the bone. Have a small gouge and mallet and heavy forceps ready before undertaking to remove such a needle fragment.

A needle fragment in the fleshy palm, where the muscles are compact and in more or less constant activity, will be displaced more in a few hours than one in the sole of the foot, where the intrinsic muscles are deeper, less compactly disposed and less active, and where, also, the dense plantar fascia sometimes holds the needle.

In the palm, foreign bodies, by reason of the direction of the thrust, often point towards the dorsum and, in a general way, towards the center of the wrist, and such movements as they undergo by muscular contractions carry them



further in those directions. They most often enter the thenar and hypothenar regions.

Slender objects entering the sole are usually driven upwards and backwards. In the heel there are no muscle bellies to move them and it is unlikely that the impact of walking much disturbs the primary locus.

In the removal of small foreign bodies there is a rule to make the incision at an angle to the long axis of the object, and when the latter is quite superficial this hoary advice is good. But when the object is buried more deeply, the incision should be made parallel to the underlying muscle fibers.

If one end of a needle projects superficially, by squeezing the muscles in the proper direction, from beneath its deeper end, it can often be driven through the skin and extracted without incision.

Unless the object has been definitely localized at some distance from the point of entry, this, when known, should be included in the in-



cision for removal, marking this spot for further reference by a little nick in the skin.

In the digits the dissection for a foreign body should be confined, if possible, to a quadrant bounded by the tendons in the median line and the vessels and nerve on each side.

Splinters of hard wood, like pieces of glass, may become encysted in the tissues, and can often be drawn out whole by one end. But soft wood, and especially old wood, breaks on traction, and unless the wound is made large enough to expose it all, even very large fragments may be left, unrecognized, in the tissues.

When exploring for a needle or other foreign body the finger tip is often far more useful than a probe. It must be remembered, too, that strands of fascia often impart to a probe "the feel" of a foreign body. Cutting and picking at these deceptive strands of tissue soon distort the field of operation and destroy important relations.

It is extremely desirable to conduct a systematic and cleanly dissection when seeking a foreign body.



## FOREIGN BODIES

If combined with a little patience, careful localization and a nice operation will lead to success; unless combined with a great deal of luck, haphazard localization and a haphazard operation will lead to disappointment and disfigurement.

In removing a foreign body from a joint none but an uncontaminated gloved finger should be permitted in the wound, and that no more than is necessary.

## LYMPHATICS

An accurate knowledge of the lymphatic drainage of the various regions of the body is absolutely necessary before one can determine the origin of a glandular infection. This is especially important in cancer, when sometimes the glandular involvement offers the first clue to the primary focus.

Do not advise extirpation of large glands in any particular region without making sure that they are not the early manifestations of leukemia or Hodgkin's disease.

If a bubo shows no signs of disappearing under wet dressings, ice bags, etc., and evi-



dences of suppuration are developing, it is better to make a clean dissection and excise the gland without opening it than to incise and drain.

Exposure to the x-rays causes atrophy of the sweat glands; radiotherapy is proving the most satisfactory treatment for hyperidrosis.

Pure nitric acid, applied on the narrow, blunt tip of a glass rod is successful in the complete destruction of verrucae, but only if it is forced down to their very roots.

Broad sessile warts are best removed by the application, under water, of the Oudin high frequency current by contact with the tip of an insulated copper conducting cord.

The Oudin high frequency current and the x-rays are the treatments of choice for post-operative keloids.

A diffuse blotchy condition of the skin should not be diagnosed as measles until a careful physical examination has been made. The condition may be the expression of a streptococcemia, as from an osteomyelitic focus.



Persistent furunculosis and allied suppurating skin lesions appear to yield in a large percentage of cases to Wright's vaccine treatment. Stock vaccines are usually suitable to such cases. The internal administration of yeast, calcium sulphide, etc., affords only occasional help.

When acne of the back does not respond to other treatment, try a few applications of long strokes with the Paquelin cautery. The results are often excellent.

It is worth while bearing in mind that subcutaneous swellings are sometimes gummata.

Do not treat localized subcutaneous red and tender swellings as infections without first making sure that they are not evidences of gout.

Localized, indurated or softening skin infections ("boils") often disappear completely or open painlessly under an application of emplastrum plumbi in which is incorporated 10 per cent. of salicylic acid; or of 10 per cent. to 20 per cent. salicylated soap plaster. After the boil opens the tiny dressing should be changed every two or three hours.



When shaving the hair in the neighborhood of a boil, draw the razor from the base to the apex so as not to drive microorganisms deeper into the tissues.

What appears like a mild cellulitis or beginning erysipelas following a rat bite is apt to be the local manifestation of a "rat-bite fever."

Stains of aniline dyes may be removed from the fingers with strong hydrochloric acid, stains of iodine with aqua ammonia, and stains by silver nitrate, with potassium iodide solution.

## WOUNDS

If an incised wound in the soft part does not heal as readily as it should, examine the urine for sugar.

When a granulating wound refuses to close without discoverable cause, it occasionally happens that a single x-ray exposure will determine its healing.

In wounds made by coal on the exposed parts of the body, remove all the particles of coal dust; otherwise a disfiguring pigmentation might follow.



A broad clean ulcer on the soft parts may heal *per primam* if its surface is swabbed with iodine and its edges then brought together with adhesive straps.

An ulcer with indolent flabby granulations may be stimulated to renewed activity by a thorough scraping or by vigorously rubbing it with gauze.

Catgut strands do not always make a good drain for wounds; they tend to swell and occlude.

Fresh wounds about a joint should not be probed to see whether the joint has been penetrated or not. This is an excellent way of infecting it.

The appearance of emphysema in the tissues about an infected wound, accompanied by fever and escape of bubbles of gas from the wound, should be regarded as very ominous, and indicative of gas bacillus infection. Such cases should be treated by extensive incisions.

Hydrogen peroxide should not be injected into deep infections in loose areolar tissue, as



the expanding gas pushes the infection into the uninvaded areas. Its most useful field is in open places.

Blank cartridge wounds must be laid wide open, all dirt and wad carefully removed, and the area swabbed out with tincture of iodine, or with pure carbolic acid followed by alcohol. Tetanus antitoxine should be administered.

When dealing with blank cartridge injuries, no consideration for the integrity of the muscles should limit the thorough exposure of every part of the wound; but the larger vessels should be, and the nerves must be, spared.

If the powder grains are not properly removed in gunshot wounds of the exposed part, unsightly discolorations result.

The possible development of a duodenal ulcer in cases of extensive burns must always be borne in mind.

Too prolonged or too rapid and vigorous use of the pump in the Bier apparatus will frequently cause a rupture of the superficial blood-



## WOUNDS

vessels, and in many cases severe sloughing of the superficial parts ensues, the result of the treatment being worse than the primary cause of the trouble. Application of the Bier cup to an abscess for four to five minutes twice a day is more beneficial than a single ten-minute application.

## TUMORS

Soft tumors under the skin, disappearing in the recumbent posture, are usually lymphangiomata.

If a swelling is "fluctuating" do not be too sure that it is not a solid growth. Lymphangiomata fluctuate.

If a spontaneously developing "hematoma" contains shreds of tissue, have these examined for new growth.

Small cystic tumors in the midline of the body are apt to be dermoids.

A subcutaneous tumor with a history of a puncture or the presence of a minute scar in the overlying skin, usually means that one is dealing with an inclusion or so-called Ranvier cyst.



In hard swellings of doubtful nature marked tenderness is significant of actinomycosis, when acute inflammation may be excluded.

Do not give a good prognosis in cases of melanosarcoma of the fingers and toes, no matter how small the tumor may be, and no matter how high the amputation is performed. In the majority of cases, these patients succumb to metastases.

In the presence of a pulsating tumor, especially of the bone, examine the kidneys. Secondary hypernephromata pulsate.

A pulsating tumor of the os ilium (endothelioma, sarcoma) may easily be mistaken for a gluteal aneurism.

The "egg shell crackle" of certain bone tumors is characteristic of multiple myeloma. Examine the urine for albumose.

In cases of bone tumor these organs should never be overlooked in seeking a primary growth—the prostate or mammary glands, according to the sex, and the thyroid.



## TUMORS

An amputation for malignant ulceration should not be performed until the possibility of its being merely a broken-down gumma has been satisfactorily excluded.

A metastatic growth in a superficial lymphatic gland or a gland of the skin may sometimes deceptively simulate the appearance of a sebaceous cyst. In a patient suffering with a malignant neoplasm, therefore, the development of a "wen," especially if at an unusual situation, should be regarded with sufficient suspicion to prompt investigation of its interior.

Don't abandon a case of sarcoma as incurable without a thorough trial of Coley's fluid. The results are sometimes remarkable.

## TUBERCULOSIS

Individuals with bluish sclerotics, and with dark lanugo over the upper part of the back, are usually of tuberculous habitus; and these signs are not inconsequential in making a diagnosis.

Surgical tuberculosis, no less than pulmonary tuberculosis, calls for the most careful general treatment, post-operative and otherwise. Out-of-door life is as important here as for phthisis.



The temptation should not be yielded to, to incise a psoas, hip or other "cold" abscess, except in isolated instances, and then only under the most rigid asepsis. The production of a mixed infection means chronic sinus, chronic invalidism and, often, amyloid disease.

The diagnosis of tuberculosis and cancer will make better progress when family history is utterly ignored.

The presence of papulo-squamous tuberculides may be the only means of recognition of tuberculosis in infancy.

Syphilis simulates nearly every other surgical disease, and the most virtuous are subject to its ravages.

## SYPHILIS

Judgment must be used in employing the iodides to diagnose syphilis, as many other conditions are improved by this treatment, notably actinomycosis, chronic rheumatoid deposits and chronic lymphadenitis. The Wassermann reaction is more certain and quicker.

The absence of a "history" should never be allowed to weigh against the diagnosis of



## SYPHILIS

syphilis—especially hereditary and tertiary syphilis. The disease is often contracted unknowingly as well as innocently, as by nursing infants.

Remember that a syphilitic mucous patch comes quickly, not slowly; it is soft, not indurated; it remains but a short time, not persistently; it is preceded or followed by other mucous patches, and it is apt to be associated with other signs of syphilis.

## ANESTHESIA

In operations upon the head and neck the anesthetist must see to it that no instrument is allowed to lie over the cornea, especially if it is exposed. Ulceration may be caused with ease; it is often healed with difficulty.

During narcosis, when stertorous breathing calls for extension of the jaw, it is well to hold it forward on one side, then on the other, alternating at short intervals. Long continued pressure at the angle or angles of the jaw produces much soreness. Often the jaw can be kept forward by catching the lower incisor teeth in front of the upper ones (if they are strong); a single finger on the chin is enough to maintain this position.



In light narcosis the pupils may dilate reflexly from operative manipulations. This, of course, is not to be confused with the sudden extreme dilatation that occurs when the narcosis has been carried too far.

During the conduct of a narcosis, more important than the activity of the conjunctival reflex or the actual size of the pupil in determining the depth of the anesthesia, are the changes in the reactibility of the lid and the alterations in the size of the pupil. They are reliable indices to fluctuations in the depth of the narcosis. Sometimes a patient is quite relaxed and anesthetic although a fair conjunctival reflex is present; and, again, it may occasionally happen that a patient reacts even when that reflex is abolished.

Avoid touching the cornea during the administration of an anesthetic. The ocular reflex can be obtained just as well through the lids, and the pupils and motions of the globe offer the most definite indications of the degree of narcosis.

During the performance of a hernia operation it is often helpful for the anesthetist to allow



the patient to react sufficiently to strain into view a sac that has slipped back into the abdomen.

A convenient way in which the anesthetist may carry, all sterilized and ready for instant use, his hypodermatic solutions, is the following: Shallow, wide-mouthed, half-ounce bottles are sterilized, labeled and filled. Over the mouth of each bottle is then stretched, and hermetically fastened, a cover of sterilized rubber (dam). Before the narcosis is begun, the anesthetist disinfects his syringe and sets these bottles in a dish of sublimate solution. This sterilizes the surface of the rubber. When a solution is wanted the needle of the hypodermatic syringe is simply thrust through the rubber and as much as is needed is drawn into the barrel. The puncture hole closes without leakage. The covers of the bottles need to be changed only occasionally.

Whenever the arrangement of a patient upon the operating table requires an extremity to occupy a constrained position, that position should be shifted from time to time to avoid pressure paralysis. The anesthetist should



never draw the arms alongside the head, nor permit the strap of a leg-holder to press, for more than a few minutes at a time, upon the brachial plexus in the neck.

Nitrous oxide narcosis can, in most cases, be continued "smoothly," with no cyanosis and with fair degree of relaxation, even for an hour. A laparotomy may thus be performed, if ether and chloroform are contraindicated. To secure such a narcosis it is best to use an apparatus that permits exhalation into the gas bag, and which has a valve for the admission of air. The bag should not be distended fully. After brief air and gas administrations, air is turned off and the patient breathes  $N_2O$  and his own  $CO_2$ . At short intervals, and whenever there is any cyanosis, a single breath of pure air is allowed. Twitching is an indication to give the patient air.

Intratracheal anesthesia (Meltzer) is quite acceptable for operations other than intrathoracic. The etherization is almost automatic, the danger of over-etherization is minimized, and coughing, straining and mucous accumulation are obviated.



Ten grains of medinal (or veronal) the night preceding the operation, and a quarter of a grain of morphine one hour before operation, will make an anesthesia easier and more complete and it will not be followed by the usual after-effects of a complete narcosis.

Local anesthetics cannot be injected painlessly into tense, inflamed areas unless the injection is begun at a point in the skin well beyond the seat of inflammation.

The addition of adrenaline to cocaine solution counteracts much of the depressant effect of the anesthetic and enhances the local vasoconstriction. When the mixture is used on the surface of a mucous membrane, however, as in excising an ulcer in the mouth, one must be prepared for a marked reactionary bleeding.

## INFUSION AND TRANSFUSION

For a single intravenous infusion, as to combat the shock of hemorrhage, it is not essential that the solution contain any of the blood salts but the most abundant one—sodium chloride. For repeated infusions, however, as sometimes used in treating various toxemias, it is better to employ also the other salts, the solution being



made of sodium chloride 0.99, potassium chloride 0.03, and calcium chloride 0.02, water 100.

Intravenous saline infusions in too large volume are harmful by the production of congestion of the internal viscera. One to one and a half pints is enough for an adult of average weight.

In performing subcutaneous infusion do not allow too much fluid to accumulate at one area, otherwise necrosis may occur. Shift the needle to various parts, not by swinging it from side to side, but by partly withdrawing it and reinserting it to another area.

When preparing the radial artery for transfusion it is very important to gently dissect out and tie with very fine ligatures the branches of the vessel in the field. If any of these is torn or bruised a clot will form in it which, by extending into the radial, will interfere with or prevent the flow of blood.

Hemolysis tests are desirable before selecting a donor for transfusion, but if the case is of great emergency this may be dispensed with,



## INFUSION AND TRANSFUSION

since hemolysis is unlikely if the donor is free from malignant growth and tuberculosis. Syphilitic taint must of course be excluded.

### POST- OPERATIVE

Aspirine can replace morphine for many of the post-operative pains, particularly at night.

Passing a catheter often cures post-operative abdominal pain not relieved by other means.

The pain in the lower part of the back that is so frequently complained of after operation, can be best relieved by placing a small pillow in the hollow of the spine.

In determining the cause of post-operative fever never fail to look at the throat.

In post-operative or other simple retention of urine, even if such devices as enemata, hot water bag over the bladder, the administration of spiritus etheris nitrosi, dipping the hands in hot water, and producing the sound of running water, fail to provoke micturition, catheterization may often be obviated in the female by the simple trick of placing the patient on a well warmed bed-pan in which has been poured a little spirits of turpentine.



Post-operative retention of urine may be cured in many instances by injecting into the bladder 15 to 20 c.cm. of glycerine or boroglyceride. A catheter is not necessary to accomplish the injection, if it is made with sufficient force to overcome the sphincter.

If, after a period of post-operative catheterization, the patient finds herself able to pass urine spontaneously, apply hot towels to the vulva.

In any case in which catheterization is required, however careful the nurse or physician, administer hexamethylenamine as a prophylactic against cystitis.

Gastric lavage is the best post-operative anti-emetic.

Vomiting may frequently be controlled by one drop doses of tincture of iodine in water at half-hourly intervals.

The distressing thirst after abdominal operations, where fluid by mouth produces vomiting, is best relieved by subcutaneous infusions of



## POST-OPERATIVE

normal salt solutions or by the insertion of a tube into the rectum connected with a bag of saline solution placed just above the level of the patient's hips, allowing the injection of water drop by drop and so slowly that no irritation of the rectum is set up. The patient may in this manner receive small quantities of water for hours.

Excessive purgation and too frequent enemata before operation may be productive of a great deal of post-operative distention.

The tension on the sutures after an operation for epigastric hernia may be relieved by placing a pillow under the knees and propping the patient up in bed.

A post-operative distention that is not relieved by a high enema can often be reduced by washing out the stomach.

After operating on diseased bone, the wound should not be dressed too often. The fine granulations which form are very liable to be pulled off with the removal of the packing.



Before putting an unconscious patient to bed, the hot water bags should be removed or sufficiently covered to prevent the occurrence of a burn.

In "clean" surgical cases a rise of temperature to even no more than  $99.5^{\circ}$  or  $100^{\circ}$ , during convalescence after operation, always means something—it may be only serous retention.

In post-operative blood examinations it must be remembered that both ether and chloroform narcosis produce a 30 per cent. increase in the leucocytes which lasts for about twenty-four hours, and that leucocytosis is also induced by saline infusion and by purgation.

The occurrence of post-operative phlebitis is often encouraged by keeping the patient too long in bed.

Old people should be allowed to sit up or get out of bed as soon after operation as possible in order to avoid post-operative lung complications.



## POST-OPERATIVE

Do not allow patients to lie on the back immediately after an operation involving the vertebra or the sacrum; a disagreeable necrosis of the skin flaps may rapidly take place.

## HEMORRHAGE AND SHOCK

In differentiating shock and concealed hemorrhage progressiveness of the symptoms is very significant of continued bleeding.

Restlessness, increasing pallor, increasing air-hunger, increasing weakness of the pulse, falling temperature (subnormal), and the ephemeral effect of stimulation, all point to hemorrhage rather than shock. In addition, there is often some local sign or symptom.

In post-operative collapse if, after studying the symptoms, there be doubt whether the condition be due to shock or to concealed hemorrhage, the wound should be opened and bleeding sought for.

In dealing with secondary hemorrhage from the rectum (whether bleeding vessels are tied or not), it is better to tampon with gauze wrapped about a piece of stout rubber tubing, than with gauze alone.



A history of "bleeding" is not always essential to a diagnosis of hemophyilia. The occasional acquired type of hemophyilia must not be forgotten.

The application of elastic bandages to the limbs to cut off their blood supply, will increase the amount of blood going to the vital centers and, therefore, is very beneficial to patients who are being or have been operated upon in a condition of shock.

Raising the foot of the bed twelve inches may combat shock more quickly than the repeated administration of stimulants and, by the way, is far less harmful to the patient. One should not use this means, however, in abdominal cases where pus has been found in the peritoneal cavity, unless the shock is severe.

In many cases of shock, a venous infusion will more often save life than dallying with stimulants which merely, in the end, serve to tire out the heart.

A mild degree of shock causes leucocytosis; severe shock paralyzes the leucoblastic function.



## SEPSIS

Blood cultures may be of very important diagnostic as well as prognostic value in cases of sepsis of unknown origin.

If a sepsis of unknown origin is associated with a positive blood culture, don't fail to examine the ears. Sinus involvement from otitis media may be present with little objective evidence and no other symptoms than fever and chills.

Bone tenderness, especially of the sternum and tibia, is frequently significant of sepsis.

In seeking the source of an obscure sepsis, do not overlook an examination of the ischio-rectal region.

Small petechiæ on the skin may indicate a sepsis of obscure origin.

## INSTRUMENTS

Aluminum instruments should not be boiled in soda solution like other instruments. They are to be sterilized by boiling in plain water or by passing them through an alcohol or Bunsen flame.



Woven catheters may be sterilized by boiling in saturated ammonium sulphate solution. They may also be sterilized in the steam autoclave (and kept aseptic) if, after *thorough* drying, inside and out, they are wrapped in individual envelopes of parchment paper (labeled).

Warming a laryngeal mirror prevents condensation of the breath upon it for only a short time. The mirror will remain bright, however, throughout a prolonged examination if, instead of warming it, its surface is smeared with an invisible film of soap.

Dipping a throat mirror in alcohol will as effectively keep off a film of moisture as heating it.

Cotton will hold more securely on an applicator if the tip of the latter is dipped in collodion before winding it. The employment of this device will afford a sense of security when applications are made in urethra, bladder or deep sinuses.

An "invalid table," the shelf of which projects over the patient's body, will be found a great convenience during operations as a recep-



tacle for instruments in immediate use. It saves time and temper, and avoids accumulation of instruments on the patient's body.

When scissors become "catchy" their edges can often be surprisingly smoothed by carrying each blade repeatedly from lock to tip between the firmly pressing thumb and forefinger. Each kind and size of scissors has its own capacity, and should be used only for what it is intended. Ophthalmic instruments are not intended for ordinary dissections, tissue scissors should not be used for cutting bandages, nor bandage scissors for plaster-of-Paris.

Bandage knives cut best when they have a "saw edge," which is easily secured by sharpening them on a window sill or other rough stone.

A scroll-saw, with an assortment of a dozen saws, can be purchased at the hardware store for twenty-five cents; it is ideal for resection of the small bones of the hand and foot, for amputation of the digits, etc.

Well tempered carpenter's chisels and gouges, and a carpenter's wooden mallet an-



swer the purpose admirably for bone work. A useful bone drill can also be selected from the stock of the hardware dealer.

A gardener's pruning knife and a carpenter's miter saw are the best tools for the removal of plaster dressings.

A cheap potato knife, rough sharpened on a stone, is excellent for cutting through starch bandages.

Crochet needles are most useful for lifting buried stitches out of a sinus.

Knitting needles find another purpose as a means of rupturing the membranes when this is needed in obstetrical work.

Sharp and blunt retractors may be fashioned, in an emergency, by bending the tines of a fork and the handle of a spoon, respectively.

A teaspoon is also useful as an elevator of the eye, when resection of the superior maxilla is performed.



An inverted tea-strainer is useful in the dressing after colostomy, to prevent pressure of the gauze upon the gut.

A spoon-shaped potato cutter may be used, in an emergency, as a wound curette.

The multiple surgical uses of the hairpin are well known. Of stouter material, if necessary, a small self-retaining retractor can be quickly made from steel wire; it often obviates the need of an assistant when searching the hand or foot for a foreign body.

Applicators, probes and depressors may be improvised by twisting stout copper wire.

A wedge of hard wood makes a gag quite useful, often, when administering anesthesia.

A discarded thermometer case (or a hard rubber douche point) is a serviceable handle in which to mount, with paraffine or adhesive plaster, a stick of silver nitrate.

A bright and altogether satisfactory light for throat examinations can be had cheaply by cov-



ering a 16-candle-power Edison electric bulb with a smooth layer of plaster-of-Paris, about three-eighths of an inch thick, leaving on one side an aperture the size of a silver half-dollar, or larger. The white inner surface of the plaster brilliantly reflects the light. The outer surface may be painted black.

Cheap powder blowers, such as are used for insecticides, may be employed as insufflators in surgical work, and pepper boxes are useful for dusting powders.

Steel spring tape-measures are better than the wires often sold for the purpose, for conducting to an x-ray tube the current from the coil or static machine; easily kept taut, and quickly adjusted, they are safest for the patient and most convenient for the operator; that they are not insulated is inconsequential—the coverings on the regular wires do not insulate the induced current.

Wooden skewers are serviceable nail cleaners. Rolling pins and kitchen towel racks are very convenient for adhesive plaster, rubber tissue, etc., especially for hospital dressings.



## INSTRUMENTS

A probe that has become bent and twisted is readily straightened out by rolling under the foot on an even floor.

The weight scale is the most important of all instruments in determining the presence of a latent carcinoma.

Hot bricks or stones retain their heat much longer than hot water bags.

A barrel cut in two on its long axis, makes an excellent holder for bed-clothes in acute affections of the lower extremities. Not only does it obviate the heavy pressure of the coverings but it diminishes the chances for discomfort caused by jarring of the bed.

## SUTURES

The threading of catgut or kangaroo tendon through a needle eye not very roomy may be made easy by cutting the suture end obliquely and flattening it between the handles of the scissors. Silk must not be cut obliquely, however, for this makes it apt to ravel while it is being threaded.

Silkworm-gut is easily dyed, and incidentally impregnated with an antiseptic, by immersing it



for twenty-four hours in one per cent. solution of methyl violet, before the boiling.

When suturing a wound of the scrotum, if the tissue (dartos) is contracted, apply a warm compress for a moment to cause relaxation.

Skin sutures must not be closely placed in fat subjects. Provision should be made for the escape of fat droplets.

In removing a skin suture, pull up on one side and cut it as close to the skin as possible. This is in order to avoid drawing any of the exposed part of the suture through the wound and thus possibly infecting it.

One is wise in making assurance doubly sure by tying each fascial suture with three knots instead of two.

Everything is to be gained and nothing to be lost by having patients remove enough of their clothing to allow of a completely satisfactory examination in all cases. Instances can be called to mind, by any physician, of erroneous judgments arrived at before exposure of other

EXAMINATIONS



parts of the body showed conditions altering one's opinion. Especially is it important to compare the corresponding members of the body on the sound and the affected side, in all doubtful cases.

If one fails to quiet a frightened, crying child sufficiently to determine the presence of a tender area, necessary to diagnosis, the administration of chloroform to the point of *primary* anesthesia will make the examination easy and, at this stage of narcosis, pressure on a tender spot will be answered by reflex movements.

The ophthalmoscope, the sigmoidoscope and, of course, the cystoscope, belong to the equipment of every thorough surgeon, and their frequent use is an important part of his diagnostic examinations.

When a skiagraph shows a condition not recognizable at once as a definite lesion, it is important to make an x-ray picture of the corresponding part of the body on the other side. It may show that the condition is merely a symmetrical peculiarity, and not a pathological one.



Free ammonia in the urine of a diabetic is a prognostic sign and its presence is a contraindication to operation in diabetic gangrene, for it shows the presence of beta-oxybutyric acid in the blood.

Before excluding glycosuria examine both morning and evening specimens of the urine.

If a patient persists in running evening temperatures which cannot be accounted for after a thorough physical examination and blood examination, one should place the patient on increasing doses of the iodides, for the fever may be due to an old syphilitic infection.

Neurasthenics exaggerate their pains and are susceptible to suggestion; but the old observation cannot be too often repeated that the physician who is quick to attribute symptoms to "neurasthenia" is in danger of being frequently put to shame by more painstaking colleagues.

To differentiate a tender spot from a simulated pain, it will often be observed that pressure on the former causes a decided increase of pulse rate, while in simulation it does not.



When performing an office operation, too great care cannot be taken to sufficiently roll back or remove such articles of clothing as might become soiled. The patient may not say much if he is obliged to draw up a garment wet with blood—but he'll probably think a few things.

Tar-paper is a smooth, fairly waterproof material to tack on the floor when preparing a room for operation.

Grocers' paper bags are well adapted receptacles for soiled dressings.

In the Bier treatment, the cup will stay in place without other assistance if zinc oxide salve or vaseline is applied to the skin. Even better than this is a piece of smooth rubber tissue which protects the skin from irritation by the pus.

By adding a one-fourth per cent. or stronger, solution of boracic acid to Burow's solution (aluminum acetate), the latter clears at once, if cloudy, and remains permanently free from turbidity or precipitation.

Yellow salve soon turns brown on exposure to light, if made with lard as a base. Cold



cream or lanoline makes a good base. Keep in a porcelain jar with a screw top.

When a "wet dressing" fails to properly drain a septic wound try a glycerine dressing—gauze wrung out in pure glycerine and covered with waterproof material.

Glycerine dressings covered by rubber tissue are frequently more useful than the ordinary wet dressing in reducing inflammatory swelling and in relieving pain.

When wet dressings are needed on hairy areas it should not be forgotten that they predispose the hair follicles to infection.

Wet dressings, especially the very useful Burow's solution of aluminum acetate, when applied to the hand or foot, usually cause maceration and whitening of the skin, which is apt to alarm the patient. The addition to the solution of one-fourth its bulk of glycerine or alcohol, will obviate this unsightly maceration.

A bichloride of mercury dressing should never be applied on an area of skin on which tincture



or iodine has been recently painted. An iodide of mercury is formed, which is highly irritating.

Ichthyol, if used in ointment sufficiently strong (25 per cent. to 50 per cent.), is perhaps the most useful single medicament in aborting early superficial infections.

The addition of a little oil of citronella to an ichthyol ointment robs it of its disagreeable odor.

The "ichthyol varnish" (50 per cent. aqueous solution of ichthyol) is a very convenient means of applying this drug to the skin when an ointment is not desirable, e. g., to the face (to avoid bandaging) or over an area of periphlebitis where it is desired to also employ a wet dressing.

Eight per cent. ointment of scarlet red in vaseline or zinc oxide frequently yields gratifying results in stimulating the epidermalization of indolent ulcers and granulating wounds.

Subiodide of bismuth dusted on an oozing granulating wound promptly stops the bleeding. It is also a stimulant to the growth of epithelium.



Friar's balsam (tinct. benzoin comp.), to be reapplied from time to time, forms a protective film quite useful for wounds of the mucous membranes (as after operations in the mouth or anus) and for other moist surfaces, e. g., cracked nipples.

An ointment of beta-naphthol, 10; sulphur, 45; lard, 24; green soap, enough to make 100 parts, is useful in removing gunpowder not too deeply situated in the skin. It must be employed cautiously, however, to avoid a destructive dermatitis.

Gauze is preferable to cotton for padding the axilla or breasts in dressings that are not frequently renewed. Cotton easily becomes matted with sour-smelling secretions and thus sets up dermatitis.

The skin over the tendo Achilles and about the heel cannot be too carefully padded when applying an extension apparatus.

When dressing a freely suppurating wound of one of the extremities it is much better to apply the gauze in flat pads than in circular



turns. Soiled gauze wound about an extremity cannot well be removed in a cleanly fashion; and, too, circular turns tend, by spreading the pus over the skin, to set up a pustular dermatitis.

Collodion, commonly used to seal a puncture wound, as after aspiration, will not adhere if the spot is wet or bleeding. To obviate this, pinch up the skin, wipe it dry, apply the collodion and continue the compression a minute or so until the collodion has begun to contract.

When rubber tissue is not at hand to make a "cigarette drain," rubber tubing may be used in its place. Split a piece of tubing of appropriate length, and lay the wick of gauze in the trough thus made, or draw the gauze through the tube with a probe. Fenestræ may be cut as desired.

Swabbing out with glycerine a sinus filled with exuberant granulations will dehydrate them, making them fresh and healthy.

A urethral endoscope will be found a great help as a means of introducing a rubber drainage tube into a narrow, tortuous sinus.



The painfulness of withdrawing packings that have dried in a wound may be avoided by soaking them with peroxide of hydrogen.

The pain of a severe burn may be much relieved by covering the part with flat pieces of gauze soaked in liquor Burowii and protected by rubber tissue, or by the application of a 10 per cent. ichthyol ointment on flat pieces of gauze.

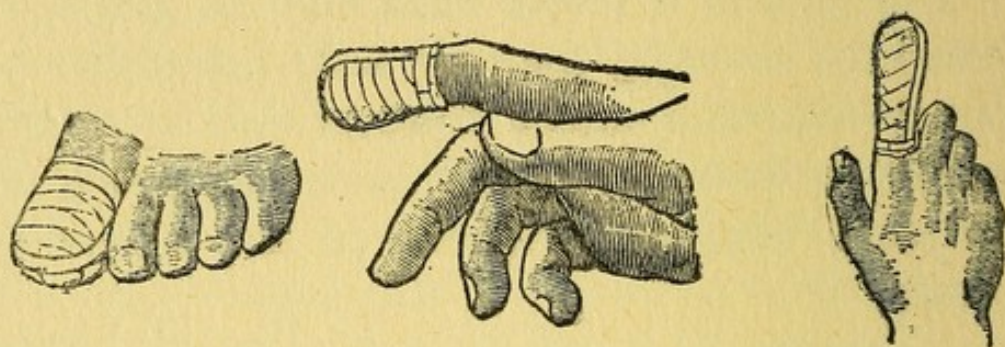
The change of dressings of burns may be made painless, and the growth of epithelium encouraged, by employing next to the wound sterile strips of gutta-percha in the same manner as for skin-grafts.

Patients will appreciate the use of black bandages for the scalp—where they are comparatively inconspicuous, and for the hands—where they do not soil.

Mastoid and scalp dressing may be reduced in bulk, and the uncomfortable neck turns of the bandage avoided, by the use of starch bandages, which hold neatly and firmly.



Bandages may be fastened in place more neatly and more securely with strips of adhesive plaster, than with safety pins. When bandaging a finger or toe, turns about the hand or foot



will be unnecessary if the dressing is fastened down with a narrow strip of plaster run over the top from base to base, and another strip circularly about the dressing at the base of the digit. When using black bandages, employ black adhesive plaster.

If the extremities of the stocking, drawer-leg, stockinette or flannel bandage put next to the skin when a plaster cast is to be applied are turned down over the cast and then a few turns of the plaster bandage are made over them near but not at the edge of the cast, a neat and comfortable cuff or margin will be thus provided.



When applying plaster-of-Paris immerse the bandages, on end, in a basin of water, deep enough to cover, *one at a time as needed*, until bubbling ceases. As the bandage is lifted out cover each end with the fingers to prevent loss of the plaster. Squeeze gently and pull off the unravelled strands.

Crinoline gauze provides a better body for plaster bandages than soft gauze. The plaster should be spread evenly into the meshes.

To be most serviceable a plaster bandage should be very loosely rolled. It may be kept air-tight in gutta-percha sealed with chloroform.



# INDEX

	Page
Abdomen - - - - -	66
Adnexa, Female - - - - -	136
Anesthesia - - - - -	196
Appendix - - - - -	93
Asepsis - - - - -	7
Back - - - - -	140
Bile Tract - - - - -	76
Bladder - - - - -	116
Bones - - - - -	165
Brain - - - - -	16
Breast - - - - -	55
Cranium - - - - -	15
Dressings - - - - -	218
Ear - - - - -	19
Examinations - - - - -	215
Extremities - - - - -	142
Extremity, Upper - - - - -	145
Extremity, Lower - - - - -	154
Eye - - - - -	26
Face - - - - -	38
Foot - - - - -	160
Foreign Bodies - - - - -	181
Fractures - - - - -	170
Gall-Bladder and Ducts - - - - -	76
Generative Organs, Female - - - - -	130
Genito-Urinary Tract - - - - -	110
Glands, Lymphatic - - - - -	186
Hand - - - - -	150
Head - - - - -	10
Hemorrhage - - - - -	206
Hernia - - - - -	99
Infusion - - - - -	200
Instruments - - - - -	208
Intestines - - - - -	88
Joints - - - - -	168
Kidney - - - - -	110



# INDEX—Continued

	Page
Liver - - - - -	76
Lower Extremity - - - - -	154
Lymphatics - - - - -	186
Maxillæ - - - - -	40
Mouth - - - - -	41
Neck - - - - -	47
Nose - - - - -	33
Ovary - - - - -	136
Penis - - - - -	123
Pharynx - - - - -	43
Post-Operative - - - - -	201
Prostate - - - - -	121
Rectum - - - - -	104
Scalp - - - - -	10
Scrotum - - - - -	127
Sepsis - - - - -	208
Shock - - - - -	206
Skin - - - - -	187
Stomach - - - - -	81
Sutures - - - - -	214
Syphilis - - - - -	195
Technique, General - - - - -	9
Testicle - - - - -	127
Thorax - - - - -	58
Trachea - - - - -	53
Tracheotomy - - - - -	54
Transfusion - - - - -	200
Tuberculosis - - - - -	194
Tube, Falloppian - - - - -	136
Tumors - - - - -	192
Upper Extremity - - - - -	145
Urethra - - - - -	123
Ureter - - - - -	110
Urinary Tract - - - - -	110
Uterus - - - - -	132
Vagina - - - - -	130
Vulva - - - - -	130
Wounds - - - - -	189



















