

Physical diagnosis of diseases of the chest / by Richard C. Cabot.

Contributors

Cabot, Richard C. 1868-1939.
Francis A. Countway Library of Medicine

Publication/Creation

New York : W. Wood and company, 1903.

Persistent URL

<https://wellcomecollection.org/works/xq43hnzt>

License and attribution

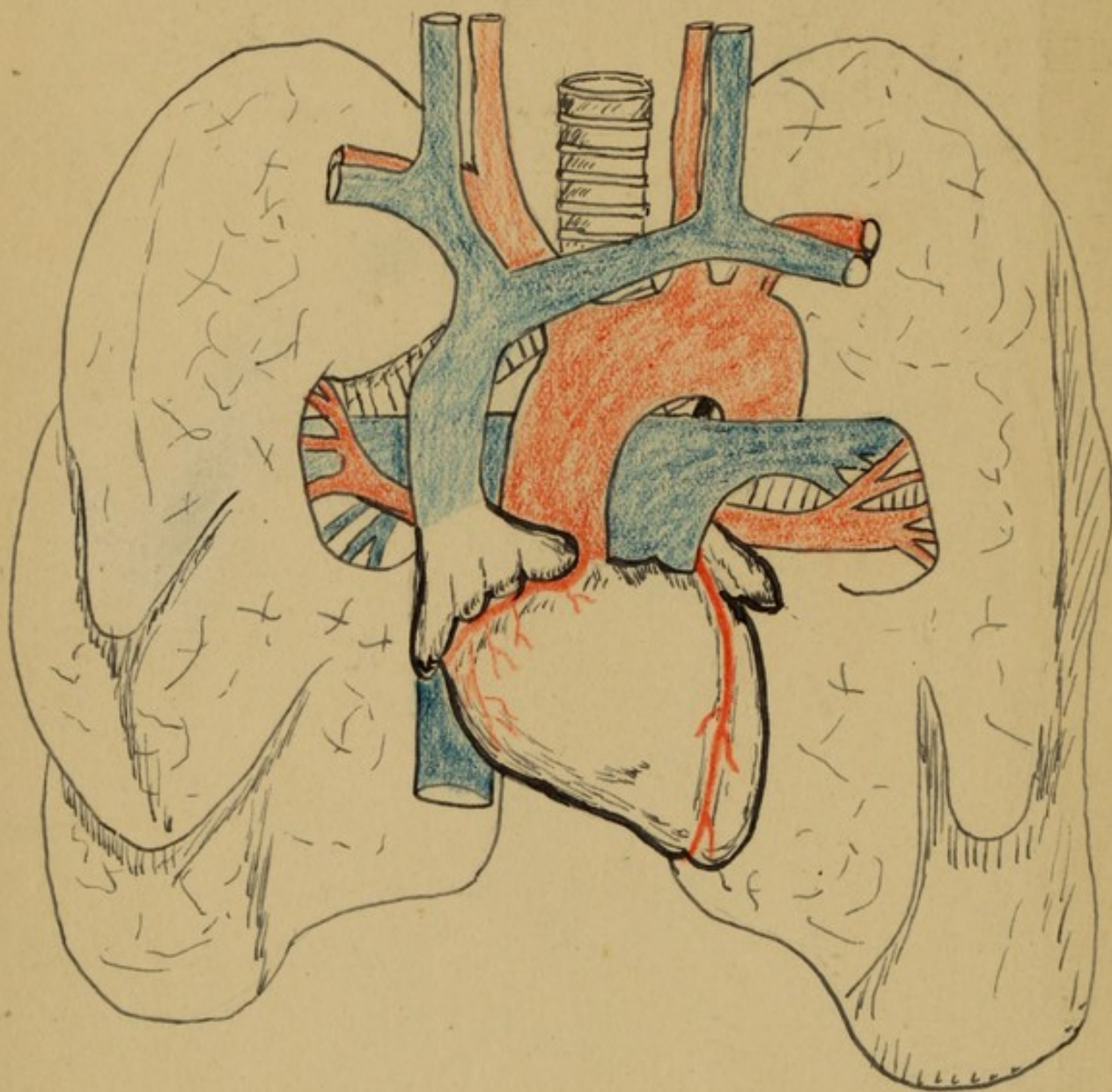
This material has been provided by This material has been provided by the Francis A. Countway Library of Medicine, through the Medical Heritage Library. The original may be consulted at the Francis A. Countway Library of Medicine, Harvard Medical School. where the originals may be consulted. This work has been identified as being free of known restrictions under copyright law, including all related and neighbouring rights and is being made available under the Creative Commons, Public Domain Mark.

You can copy, modify, distribute and perform the work, even for commercial purposes, without asking permission.



Wellcome Collection
183 Euston Road
London NW1 2BE UK
T +44 (0)20 7611 8722
E library@wellcomecollection.org
<https://wellcomecollection.org>





Cf. Gray. Page 974.

James B. Ayer Jr.
518 Beacon St.


Harvard University
Library of
The Medical School
and
The School of Public Health




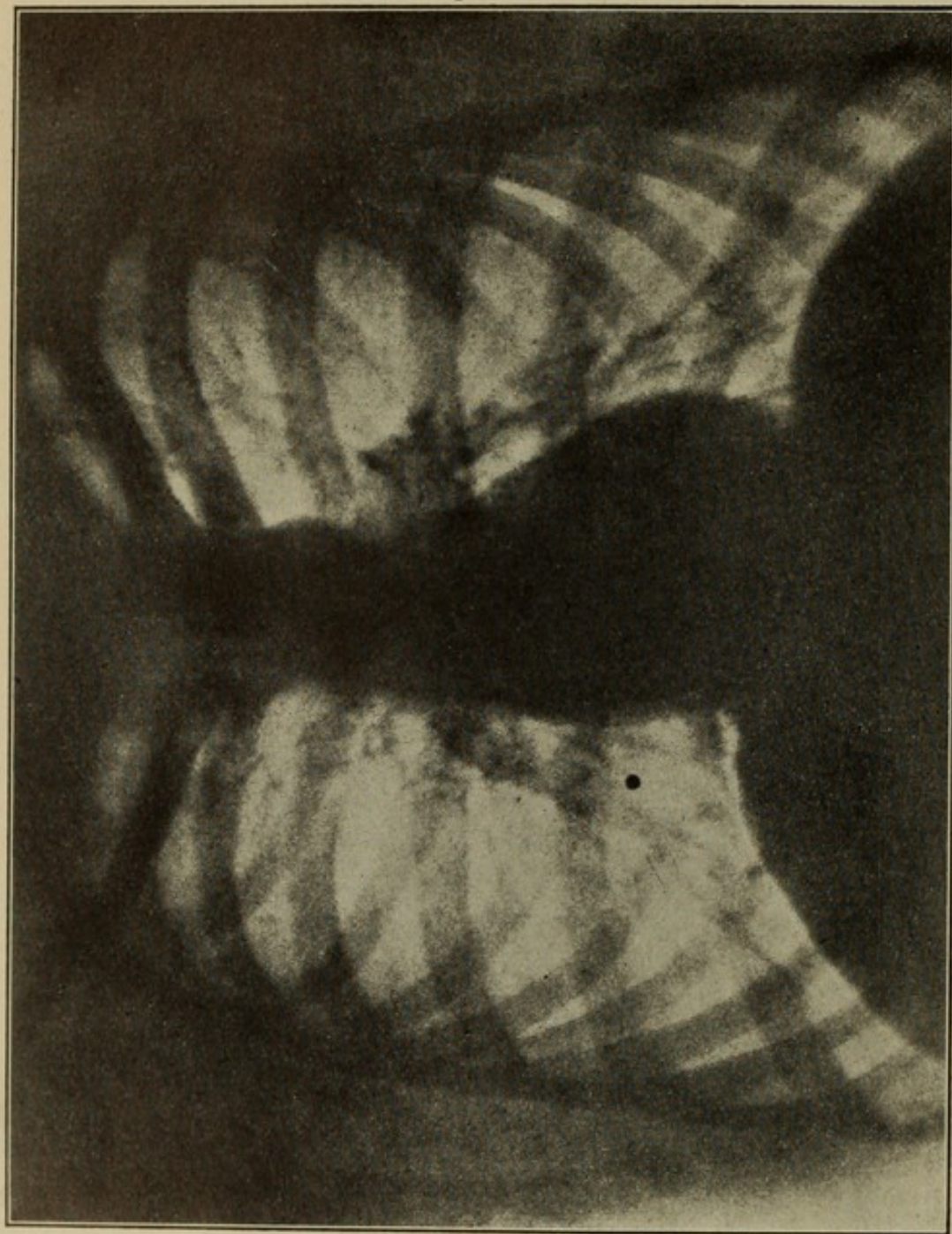
The Gift of

Harvard Medical Library
in the Francis A. Countway
Library of Medicine - Boston

VERITATEM PER MEDICINAM QUÆRAMUS







Instantaneous Radiograph of a Normal Adult Thorax. A dot marks the position of the right nipple. The branchings of the larger bronchi are visible.

(From v. Ziemssen's Atlas.)

PHYSICAL DIAGNOSIS
OF
DISEASES OF THE CHEST

BY
RICHARD C. CABOT, M.D.

PHYSICIAN TO OUT-PATIENTS, MASSACHUSETTS GENERAL HOSPITAL; ASSISTANT IN
CLINICAL MEDICINE, HARVARD MEDICAL SCHOOL

Second Revised Edition

WITH ONE HUNDRED AND FORTY-SEVEN ILLUSTRATIONS

NEW YORK
WILLIAM WOOD AND COMPANY
MDCCCIII

HARVARD UNIVERSITY
SCHOOL OF MEDICINE AND PUBLIC HEALTH


LIBRARY
Gift: Dr. J. B. Ayer
20 FEB 1942

COPYRIGHT, 1903,
BY WILLIAM WOOD AND COMPANY.

TO
FREDERICK C. SHATTUCK, M.D.

*Jackson Professor of Clinical Medicine
in Harvard University*

IN EVIDENCE OF MY APPRECIATION OF
THE EXAMPLE OF SINCERITY, COMMON SENSE, AND ENTHUSIASM
ESTABLISHED BY HIM IN THE TEACHING AND
THE PRACTICE OF MEDICINE



PREFACE.

THIS book is intended for students and, so far as I am aware, contains nothing original. I have written it because I have not been able to find any small work upon the subject which does not contain glaring errors. The correct books are too large; the small books are out of date and repeat such well-worn myths as that the aortic second sound is normally louder than the pulmonic second, that aortic regurgitant murmurs are usually best heard in the second right interspace, that a hypertrophied left auricle can produce dullness and pulsation near the left sternal border, that systolic retraction at the cardiac apex means adherent pericardium, that epigastric pulsation denotes hypertrophy of the right ventricle, etc. Further, none of the smaller text-books contains any adequate account of muscle sounds, of pulmonary atelectasis, or of adherent pericardium. To record the well-known but often forgotten truth on such matters as these has seemed to me of importance in small books as well as in encyclopædic treatises.

The diagrams illustrating respiratory types are modifications of those used by Wylie and Sahli.

I am indebted to Mr. Eliot Alden, of the Harvard Medical School, for his kind assistance in the preparation of the illustrations and to Drs. E. H. Bradford and R. W. Lovett for permission to use three cuts from their well-known work on orthopedic surgery.

I am also indebted to the editor of the *Archives of the Röntgen Ray* for permission to use two radiographs from that journal.



TABLE OF CONTENTS.

	PAGE
INTRODUCTION,	1
I. Methods of Examining the Thoracic Organs,	1
II. Regional Anatomy of the Chest,	2

PART I.

TECHNIQUE AND GENERAL DIAGNOSIS.

CHAPTER I.

INSPECTION.

I. SIZE,	5
II. SHAPE,	6
(a) The Rachitic Chest,	7
(b) The Paralytic Chest,	8
(c) The Barrel Chest,	9
III. DEFORMITIES,	12
(a) Curvature of the Spine,	12
(b) Flattening of One Side of the Chest,	14
(c) Prominence of One Side of the Chest,	14
(d) Local Prominences,	15
IV. RESPIRATORY MOVEMENTS,	16
(a) Normal Respiration,	16
(b) Anomalies of Expansion,	16
1. Diminished Expansion,	17
2. Increased Expansion,	18
(c) Dyspnœa,	18
V. THE RESPIRATORY RHYTHM,	21
(a) Asthmatic Breathing,	21
(b) Cheyne-Stokes Breathing,	21

	PAGE
(c) Restrained Breathing,	22
(d) Shallow and Irregular Breathing,	22
(e) Stridulous Breathing,	23
VI. DIAPHRAGMATIC MOVEMENTS (Litten's Phenomenon),	23
VII. THE CARDIAC MOVEMENTS,	26
1. Normal Cardiac Impulse,	26
2. Displacement of the Cardiac Impulse,	29
3. Apex Retraction,	31
4. Epigastric Pulsation,	32
5. Uncovering of the Heart,	32
VIII. ANEURISM AND OTHER CAUSES OF ABNORMAL PULSATIONS OF THE CHEST WALL,	33
IX. THE PERIPHERAL VESSELS,	34
(a) Venous Phenomena,	35
(b) Arterial Phenomena,	36
(c) Capillary Phenomena,	38
X. THE SKIN AND MUCOUS MEMBRANES,	39
1. Cyanosis,	39
2. Œdema,	40
3. Pallor,	40
4. Jaundice,	40
5. Scars and Eruptions,	41
XI. ENLARGED GLANDS,	41

CHAPTER II.

PALPATION AND THE STUDY OF THE PULSE.

I. PALPATION,	42
1. The Cardiac Impulse,	42
2. Thrills,	43
3. Tactile Fremitus,	44
4. Friction, Pleural or Pericardial,	46
5. Palpable Râles,	47
6. Tender Points,	48
7. Abnormal Pulsations,	48
8. Tumors,	48
9. Temperature and Quality of the Skin,	49
II. THE PULSE,	49
1. The Rate,	51
2. Rhythm,	51

TABLE OF CONTENTS.

ix

	PAGE
3. Compressibility,	52
4. Size and Shape of Pulse Wave,	52
5. Tension,	54
6. Size and Position of Artery,	55
7. Condition of Artery Walls,	56
III. ARTERIAL PRESSURE AND THE INSTRUMENTS FOR MEASURING IT,	57
1. Gaertner's Tenometer,	58
2. The Riva-Rocci Instrument,	59
3. The Instrument of Hill and Barnard,	60
4. The Oliver Instrument,	61

CHAPTER III.

PERCUSSION.

I. TECHNIQUE,	64
(a) { Mediate Percussion,	64
{ Immediate Percussion,	64
(b) Auscultatory Percussion,	71
(c) Palpatory Percussion,	73
II. PERCUSSION-RESONANCE OF THE NORMAL CHEST,	73
(a) Vesicular Resonance,	74
(b) Dulness and Flatness,	74
(c) Tympanitic Resonance,	76
(d) Cracked-pot Resonance,	80
(e) Amphoric Resonance,	81
(f) The Lung Reflex,	82
III. SENSE OF RESISTANCE,	82

CHAPTER IV.

AUSCULTATION.

1. MEDIATE AND IMMEDIATE AUSCULTATION,	83
2. SELECTION OF A STETHOSCOPE,	84
3. THE USE OF THE STETHOSCOPE,	89
A. Selective Attention and What to Disregard,	89
B. Muscle Sounds,	92
C. Other Sources of Error,	93

	PAGE
4. AUSCULTATION OF THE LUNGS,	95
I. Respiratory Types,	96
(a) Vesicular Breathing,	97
(b) Tubular Breathing,	99
(c) Broncho-vesicular Breathing,	100
(d) Emphysematous Breathing,	101
(e) Asthmatic Breathing,	101
(f) Cog-wheel Breathing,	102
(g) Amphoric Breathing,	102
(h) Metamorphosing Breathing,	102
II. Differences between the Right and the Left Chest,	103
III. Pathological Modifications of Vesicular Breathing,	103
(a) Exaggerated Vesicular Breathing,	103
(b) Diminished Vesicular Breathing,	104
IV. Bronchial Breathing in Disease,	106
V. Broncho-vesicular Breathing in Disease,	106
VI. Amphoric Breathing,	107
VII. Râles,	107
(a) Moist,	107
(b) Dry,	108
(c) Musical,	110
VIII. Cough. Effects on Respiratory Sounds,	111
IX. Pleural Friction,	111
X. Auscultation of the Voice Sound,	113
(a) The Whispered Voice,	113
(b) The Spoken Voice,	114
(c) Egophony,	115
XI. Phenomena Peculiar to Pneumo-hydrothorax,	115
(a) Succussion,	115
(b) Metallic Tinkle,	116
(c) The Lung Fistula Sound,	116

CHAPTER V.

AUSCULTATION OF THE HEART.

1. THE VALVE AREAS,	117
2. NORMAL HEART SOUNDS,	118
3. MODIFICATIONS IN THE INTENSITY OF THE HEART SOUNDS,	120

TABLE OF CONTENTS.

xi

	PAGE
(a) Mitral First Sound,	121
1. Lengthening,	121
2. Shortening,	121
3. Doubling,	122
(b) The Second Sounds at the Base of the Heart,	122
1. Physiological Variations,	122
2. Pathological Variations,	124
(a) Accentuation of Pulmonic Second Sound,	124
(b) Weakening of Pulmonic Second Sound,	125
(c) Accentuation of the Aortic Second Sound,	125
(d) Weakening of the Aortic Second Sound,	125
(e) Accentuation of Both Second Sounds,	126
(f) Summary,	126
(c) Modifications in Rhythm of Cardiac Sounds and Doubling of Sec- ond Sounds,	127
(d) Metallic Quality of the Heart Sounds,	128
(e) "Muffled" Heart Sounds,	128
4. SOUNDS AUDIBLE OVER THE PERIPHERAL VESSELS,	128
(a) Arterial Sounds,	128
(b) Venous Sounds,	129

CHAPTER VI.

(AUSCULTATION OF THE HEART, CONTINUED.)

CARDIAC MURMURS.

I. TERMINOLOGY,	130
1. Mode of Production,	130
2. Place of Murmurs in the Cardiac Cycle,	132
3. Point of Maximum Intensity,	133
4. Area of Transmission,	134
5. Intensity, Quality, and Length,	136-139
6. Relation to Heart Sounds,	139
7. Effects of Respiration, Exertion, and Position,	139
8. Metamorphosis of Murmurs,	140
II. FUNCTIONAL MURMURS,	140
III. CARDIO-RESPIRATORY MURMURS,	143
IV. VENOUS MURMURS,	144
V. ARTERIAL MURMURS,	144

PART II.

DISEASES OF THE HEART.

CHAPTER VII.

VALVULAR LESIONS.

	PAGE
1. VALVULAR AND PARIETAL DISEASE,	145
2. THE ESTABLISHMENT AND FAILURE OF COMPENSATION,	148
3. HYPERTROPHY AND DILATATION,	151
4. VALVULAR DISEASE,	156
I. Mitral Regurgitation,	156
(a) Pre-compensatory Stage,	158
(b) Stage of Compensation,	159
(c) Stage of Failing Compensation,	163
(d) Differential Diagnosis,	164
II. Mitral Stenosis,	166
1. First Stage,	168
2. Second Stage,	170
3. Third Stage,	171
4. Differential Diagnosis,	172
III. Aortic Regurgitation,	175
1. Inspection,	176
(a) Arterial Jerking,	177
(b) Capillary Pulsation,	178
2. Palpation,	179
3. Percussion,	180
4. Auscultation,	180
5. Summary and Differential Diagnosis,	183
6. Prognosis,	184
7. Complications,	184
IV. Aortic Stenosis,	185
1. (a) The Murmur,	186
(b) The Pulse,	188
(c) The Thrill,	189
(d) Feeble Aortic Second Sound,	189
2. Differential Diagnosis,	189
V. Tricuspid Regurgitation,	192
1. (a) The Murmur,	193

TABLE OF CONTENTS.

xiii

	PAGE
(b) Venous Pulsation,	193
(c) Cardiac Dilatation,	194
(d) Feeble Pulmonic Second Sound,	194
2. Differential Diagnosis,	195
VI. Tricuspid Stenosis,	196
VII. Pulmonary Regurgitation,	197
VIII. Pulmonary Stenosis,	198
IX. Combined Valvular Lesions,	199
(a) Double Mitral Disease,	200
(b) Aortic and Mitral Regurgitation,	201
(c) Aortic Stenosis and Regurgitation,	202

CHAPTER VIII.

PARIETAL DISEASE AND CARDIAC NEUROSES.

I. PARIETAL DISEASE OF THE HEART,	203
1. Acute Myocarditis,	203
2. Chronic Myocarditis,	204
3. Fatty Overgrowth,	206
4. Fatty Degeneration,	206
II. CARDIAC NEUROSES,	207
1. Tachycardia,	207
2. Bradycardia,	208
3. Arrhythmia,	209
4. Palpitation,	210
5. Congenital Heart Disease,	211

CHAPTER IX.

DISEASES OF THE PERICARDIUM.

I. PERICARDITIS,	214
(a) Dry or Fibrinous,	214
(b) Pericardial Effusion,	217
1. The Area of Dulness,	218
2. The Cardiac Impulse and the Pulse,	220
3. Pressure Signs,	220
(c) Adherent Pericardium,	222
1. Retraction of Interspaces,	222
2. Limitation of Respiratory Movements,	223

	PAGE
3. Absence of Cardiac Displacement with Change of Position,	223
4. Hypertrophy and Dilatation not otherwise Explained, .	223
5. Capsular Cirrhosis of the Liver,	223

CHAPTER X.

THORACIC ANEURISM.

1. Abnormal Pulsation,	226
2. Tumor,	226
3. Thrill,	227
4. Diastolic Shock,	228
5. Tracheal Tug,	228
6. Pressure Signs,	229
7. Percussion Dulness,	230
8. Auscultation,	231
(a) Murmurs,	231
(b) Diastolic Shock Sound,	231
9. Radioscopy,	233
10. Summary,	233
11. Diagnosis,	234

PART III.

DISEASES OF THE LUNGS AND PLEURA.

CHAPTER XI.

BRONCHITIS, PNEUMONIA, TUBERCULOSIS.

1. TRACHEITIS,	239
2. BRONCHITIS,	239
(a) Physical Signs,	239
(b) Differential Diagnosis,	241
3. CROUPOUS PNEUMONIA,	243
(a) Inspection,	243
(b) Palpation,	244
(c) Percussion,	244
(d) Auscultation,	245

	PAGE
(e) Summary,	248
(f) Differential Diagnosis,	248
4. BRONCHO-PNEUMONIA,	250
5. PULMONARY TUBERCULOSIS,	251
(a) Incipient Tuberculosis,	251
(b) Moderately Advanced Cases,	255
(c) Advanced Phthisis,	258
(d) Anomalous Forms of Pulmonary Tuberculosis,	262

CHAPTER XII.

(DISEASES OF THE LUNGS, CONTINUED.)

1. EMPHYSEMA,	264
(a) Small-Lunged Emphysema,	264
(b) Large-Lunged Emphysema,	264
(c) Emphysema with Bronchitis and Asthma,	267
(d) Interstitial Emphysema,	268
(e) Complementary Emphysema,	268
(f) Acute Pulmonary Tympanites,	268
2. BRONCHIAL ASTHMA,	269
3. SYPHILIS OF THE LUNG,	270
4. BRONCHIECTASIS,	270
5. CIRRHOSIS OF THE LUNG,	271

CHAPTER XIII.

DISEASES AFFECTING THE PLEURAL CAVITY.

I. Hydrothorax,	272
II. Pneumothorax,	272
III. Pneumohydrothorax and Pneumopyothorax,	274
Differential Diagnosis of Pneumothorax and Pneumohydrothorax,	276
IV. Pleurisy,	278
1. Dry Pleurisy,	278
2. Pleuritic Effusion,	280
(a) Percussion,	281
(b) Auscultation,	287
(c) Inspection and Palpation,	289
3. Pleural Thickening,	291

	PAGE
4. Encapsulated Pleural Effusions,	291
5. Pulsating Pleurisy and Empyema Necessitatis,	292
6. Differential Diagnosis of Pleural Effusions,	292

CHAPTER XIV.

ABSCCESS, GANGRENE AND CANCER OF THE LUNG, PULMO- NARY ATELECTASIS, ŒDEMA AND HYPOSTATIC CONGESTION.

1. Abscess and Gangrene of the Lung,	296
2. Cancer of the Lung,	297
3. Atelectasis,	298
4. Œdema and Hypostatic Congestion,	299

APPENDICES.

APPENDIX A.—DISEASES OF THE MEDIASTINUM,	301
1. Mediastinal Tumors,	301
2. Mediastinitis,	303
3. Tuberculosis of Mediastinal Glands,	304
APPENDIX B.—ACUTE ENDOCARDITIS,	304
APPENDIX C.—EXAMINATION OF INFANT'S CHESTS,	305
APPENDIX D.—RADIOSCOPY OF THE CHEST,	306
APPENDIX E.—THE SPHYGMOGRAPH,	314

PHYSICAL DIAGNOSIS

OF

DISEASES OF THE CHEST.

INTRODUCTION.

I. METHODS OF EXAMINING THE THORACIC ORGANS.

To carry out a thorough examination of the chest we do five things: 1. We look at it; technically called "inspection." 2. We feel of it; technically called "palpation." 3. We listen to the sounds produced by striking it; technically called "percussion." 4. We listen to the sounds produced within it by physiological or pathological processes; technically called "auscultation." 5. We study pictures thrown on the fluoroscopic screen or on a photographic plate by the Roentgen rays as they traverse the chest; technically called "radioscopy."

Measuring the dimensions or the movements of the chest ("mensuration") is often mentioned as co-ordinate with the above methods, but it yields very little information of practical value, and is at present very little used.

The data obtained by examining the sputa, blood, and urine are frequently of great value in helping us to interpret the signs revealed by examination of the chest, but do not fall within the scope of this book. Accordingly, I shall confine myself in the first part of this book to a description of the methods of inspecting, palpating, percussing, and auscultating the chest, with a brief account of the physical signs which we have learned to appreciate by the use of these methods. (For radioscopy, see Appendix.)

Without some knowledge of the regional anatomy of the chest no intelligent investigation of the condition of the thoracic organs can be carried on. Accordingly, I shall begin by recalling very briefly some of the most essential anatomical relations.

II. REGIONAL ANATOMY OF THE CHEST.

It seems to me a mistake to divide the chest into arbitrary portions and to describe physical signs with reference to such division.

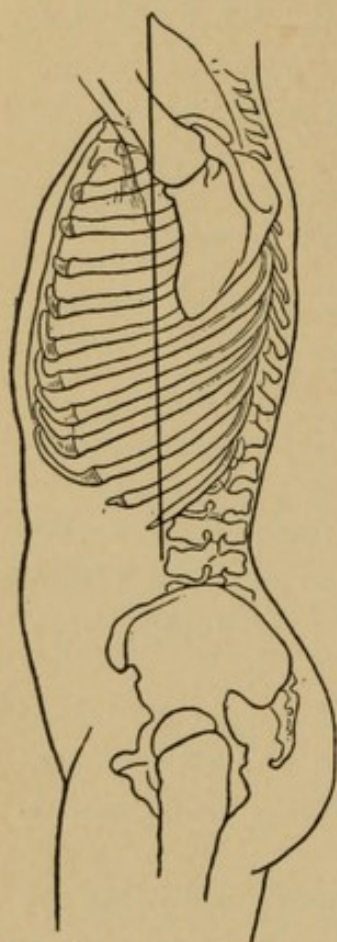


FIG. 1.—The Mid-Axillary Line.

The seat of any lesion can best be described by giving its relation to the clavicle, sternum, or ribs on the front and sides of the chest, and to the scapulæ and ribs behind. Thus we may speak of râles as heard "above the left clavicle in front," "below the right scapula behind," "between the seventh and ninth ribs in the axilla," and so on. When we want to state more exactly what part of the axilla anteroposteriorly is affected, we may refer to the "mid-axillary line" (see Fig. 1); or better, we may place the lesion by measuring the number of centimetres or inches from the median line of the sternum. In a similar way the place of the apex impulse of the heart (whether in the normal situation or farther toward the axilla) can be determined by measuring from the median line of the sternum. Measurements referring to the nipple are entirely useless in women and not very reliable in men. It is better to measure as above.

If, then, we confine ourselves chiefly to the bones of the chest as landmarks, and fix, with reference to them, the position of any portion of the internal organs which we desire to study, it becomes unnecessary to memorize any technical terms or to learn the position of any arbitrary lines and divisions such as are frequently forced upon the

student. The only points which it is necessary to memorize once for all are:

1. The position of the heart, lungs, liver, and spleen with reference to the bones of the chest.

2. The position of certain points which experience has taught us have a certain value in physical diagnosis. I mean (*a*) the so-called "valve areas" of the heart, which do not correspond to the actual position of the valves, for reasons to be explained later

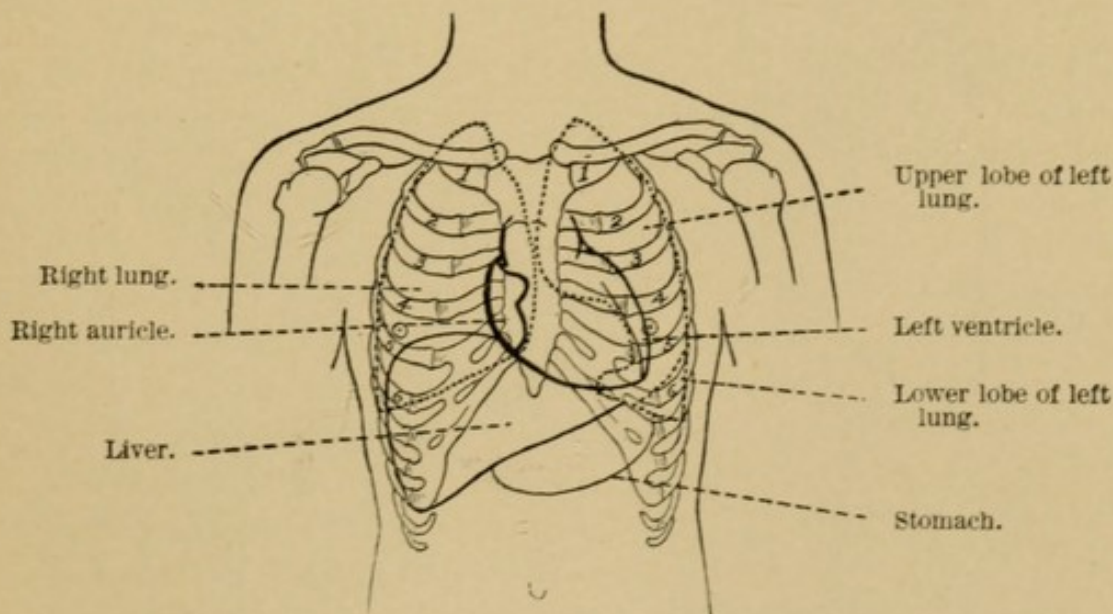


FIG. 2.—Position of the Heart, Lungs, Liver, and Stomach. The dotted lines correspond to the outlines of the lung; the heavy continuous line represents the heart; while the position of the liver and of the lower border of the stomach is indicated by light continuous lines. The ribs are numbered.

on, and (*b*) the percussion outlines of the heart, liver, and spleen. These outlines do not correspond in size with the actual dimensions of the organs within, yet there is a definite relation between the two which remains relatively constant, so that we can infer the size of the organ itself from the outlines which we determine by percussion. The position of the organs themselves is shown in Figs. 2, 3, and 4. It will be noticed in Fig. 2 that the lungs extend up above the clavicles and overlap the liver and the heart—facts of considerable importance in the physical examination of these organs, as will be later seen. It is also to be noticed how small

4 *PHYSICAL DIAGNOSIS OF DISEASES OF THE CHEST.*

a portion of the stomach is directly accessible to physical examination, the larger part of it lying behind the ribs and covered by the

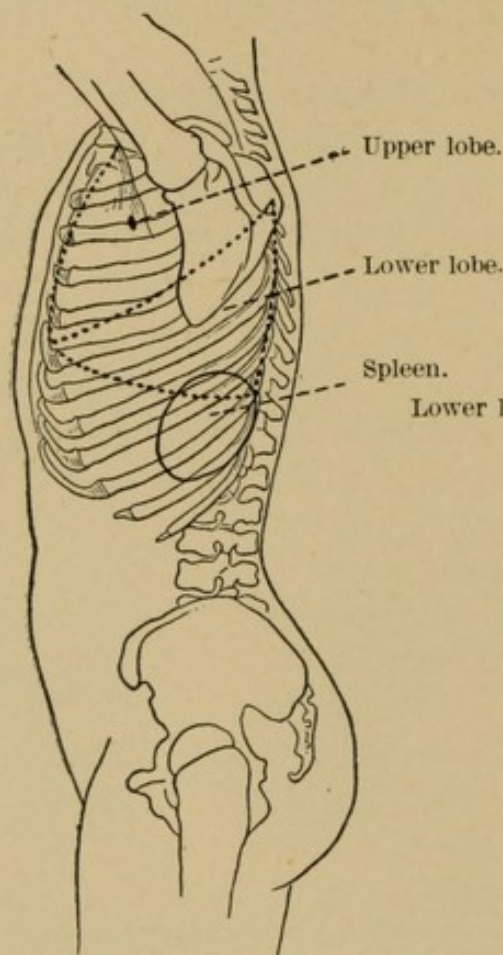


FIG. 3.—Position of the Left Lung from the Sides and of the Spleen.

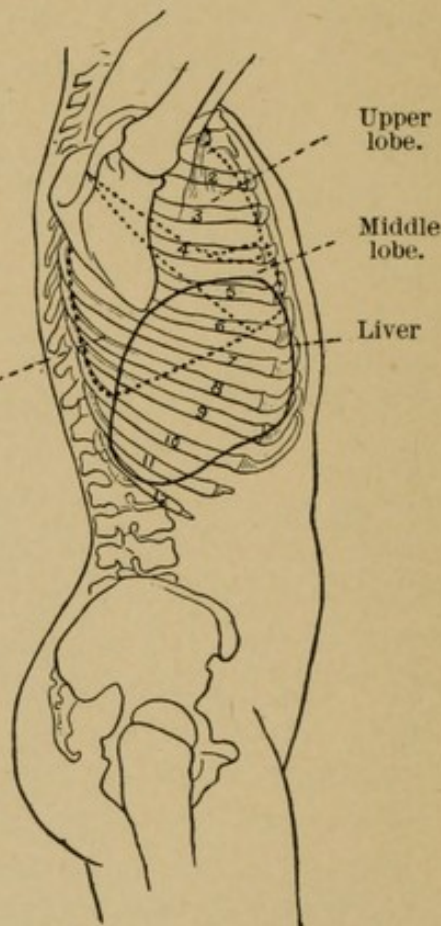


FIG. 4.—Position of the Right Lung from the Side, and of the Liver.

liver. The normal pancreas and kidneys are practically inaccessible to physical examination.

The percussion outlines—corresponding to those portions of the heart, liver, and spleen which lie immediately beneath the chest walls—will be illustrated in the section on Percussion (see page 64).

PART I.

TECHNIQUE AND GENERAL DIAGNOSIS.

INSPECTION.

MUCH may be learned by a careful inspection of all parts of the chest, but only in case the clothes are wholly removed. A good light is essential, and this does not always mean a *direct* light; for example, when examining the front of the chest it is often better to have the patient stand with his side to the window so that the light strikes obliquely across the chest, accenting every depression and making every pulsation a moving shadow. In searching for abnormal pulsations, this oblique light is especially important.

In examining the thorax we look for the following points:

1. The size.
2. The general shape and nutrition.
3. Local deformities or tumors.
4. The respiratory movements of the chest walls.
5. The respiratory movements of the diaphragm.
6. The normal cardiac movements.
7. Abnormal pulsations (arterial, venous, or capillary).
8. The peripheral vessels.
9. The color and condition of the skin and mucous membranes.
10. The presence or absence of glandular enlargement.

I. SIZE.

Small chests are seen in patients who have been long in bed from whatever cause; also in those who have suffered in infancy from rickets, adenoid growths in the naso-pharynx, or a combination of the two diseases. Abnormally large chests are seen chiefly in emphysema. Of course the chests of healthy individuals vary

a great deal in size at any given age, and I have been referring in the last sentences only to variations greater than those normally found.

II. SHAPE.

There are marked differences in shape between the child's and the adult's chest in health. A child's trunk, as compared with

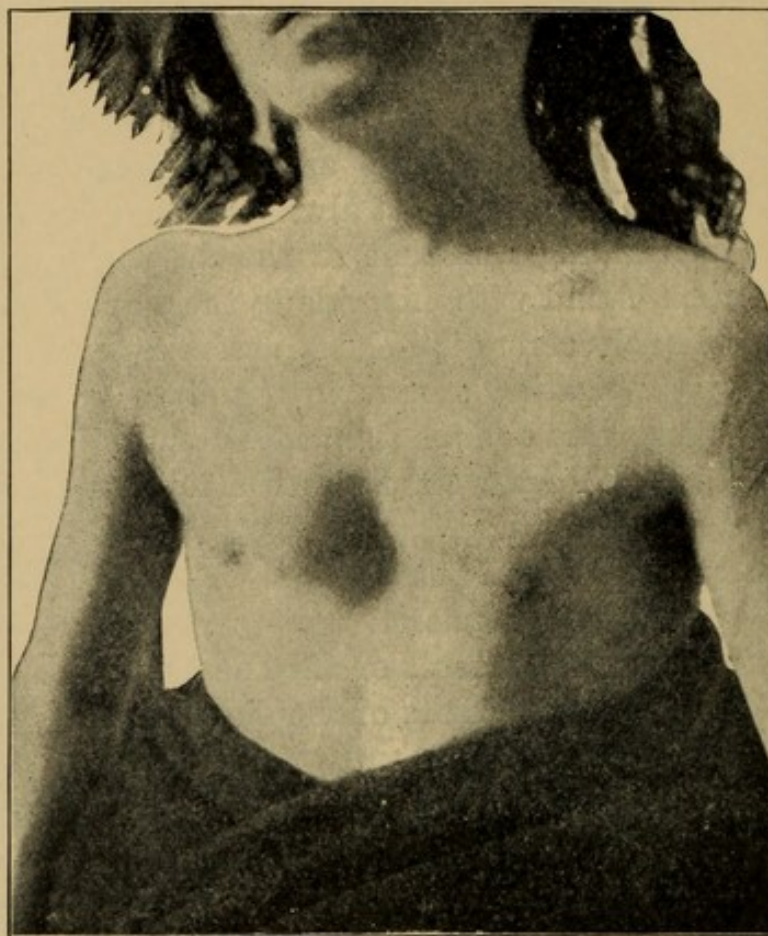

FIG. 5.—Funnel Breast.

that of an adult, is far more nearly cylindrical; that is, the antero-posterior diameter is nearly as great as the lateral. The adult's chest is distinctly flattened from before backward, although individual variations in this respect are considerable, as Woods Hutchinson has shown.

In childhood the commonest pathological modifications are due

to adenoids or to rickets; in middle and later life to emphysema, phthisis, or old pleuritic disease.

(a) *The Rachitic Chest.*

The sternum generally projects ("*pigeon breast*"), but in some cases, especially when rickets is combined with adenoid hypertrophy, there may be a depression at the root of the sternum resulting in the condition known as "*funnel breast*"¹ (Figs. 5 and 6).

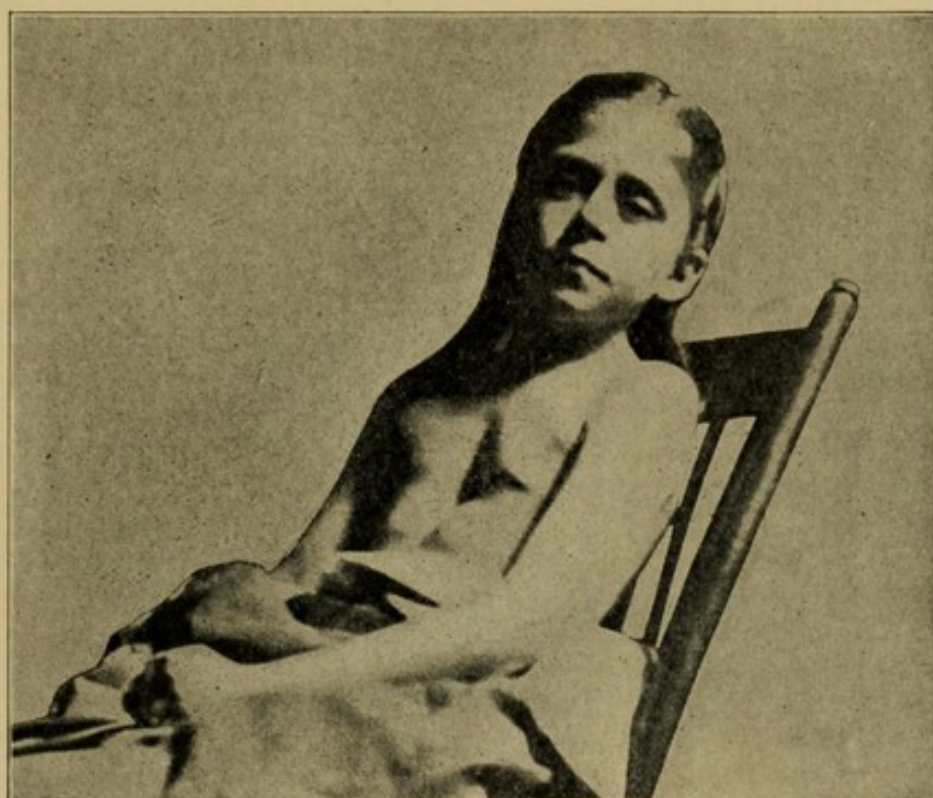


FIG. 6.—Funnel Breast.

The sides of the chest are compressed laterally and slope in to meet the sternum as the sides of a ship slope down to meet the keel (*pectus carinatum*) (Figs. 8, 9 and 10). From the origin of the ensiform cartilage a depression or groove is to be seen running downward and outward to the axilla and corresponding nearly to the attachment of the diaphragm. This is sometimes spoken of as "*Harrison's groove*" (Figs. 11 and 12). The *lower margin of the ribs*

¹ In some cases this condition appears to be congenital.

8 *PHYSICAL DIAGNOSIS OF DISEASES OF THE CHEST.*

in front often *flares out*, owing to the enlargement of the liver and spleen below and the pull of the diaphragm above. Along the line of the chondro-costal articulation there is to be felt, and sometimes

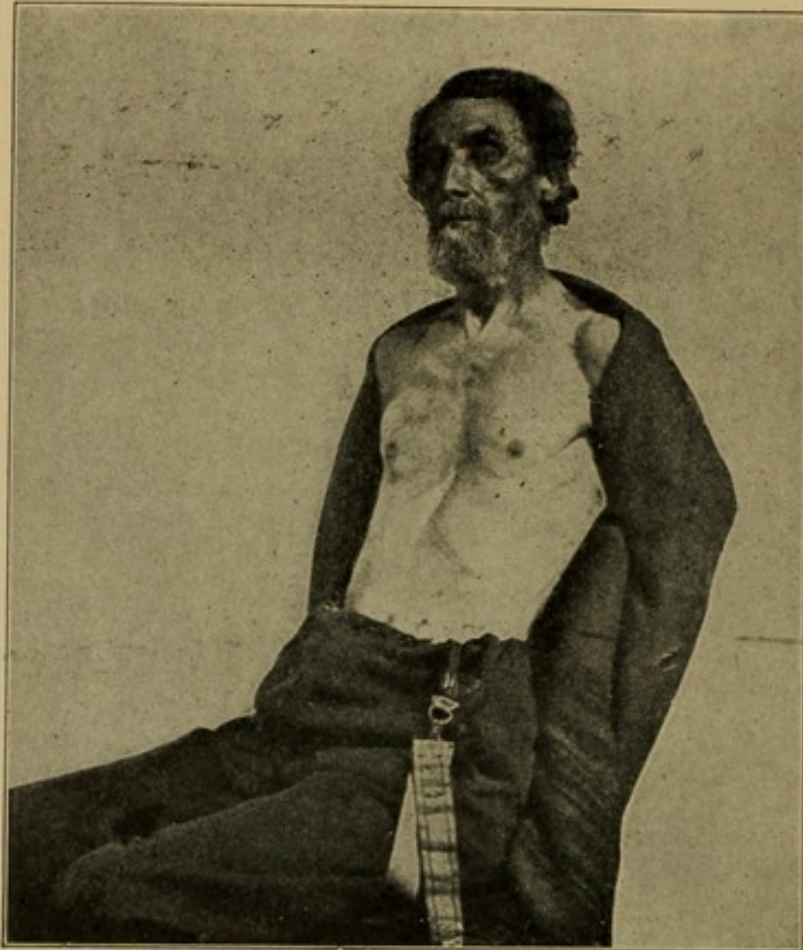


FIG. 7.—Acquired Depression at the Root of the Ensiform Cartilage. The patient is a shoemaker of seventy, who has all his life pressed against his breast bone the shoe on which he worked.

seen, a line of eminences or swellings, to which the name of “*rachitic rosary*” has been given (see Fig. 13).

(b) *The “Paralytic Thorax.”*

Fig. 14 conveys a better idea of this form of chest than any description. The normal anteroposterior flattening is exaggerated so that such persons are often spoken of as “*flat-chested*.” The clavicles are very prominent, owing to falling in of the tissues

above and below them; the shoulders are stooping, the scapulæ prominent, and the neck is generally long. The angle where the ribs meet at the ensiform cartilage, the so-called "*costal angle*," is in such cases very sharp. This type of chest has often been supposed to be characteristic of phthisis, but may be found in persons with perfectly healthy lungs. On the other hand, phthisis frequently

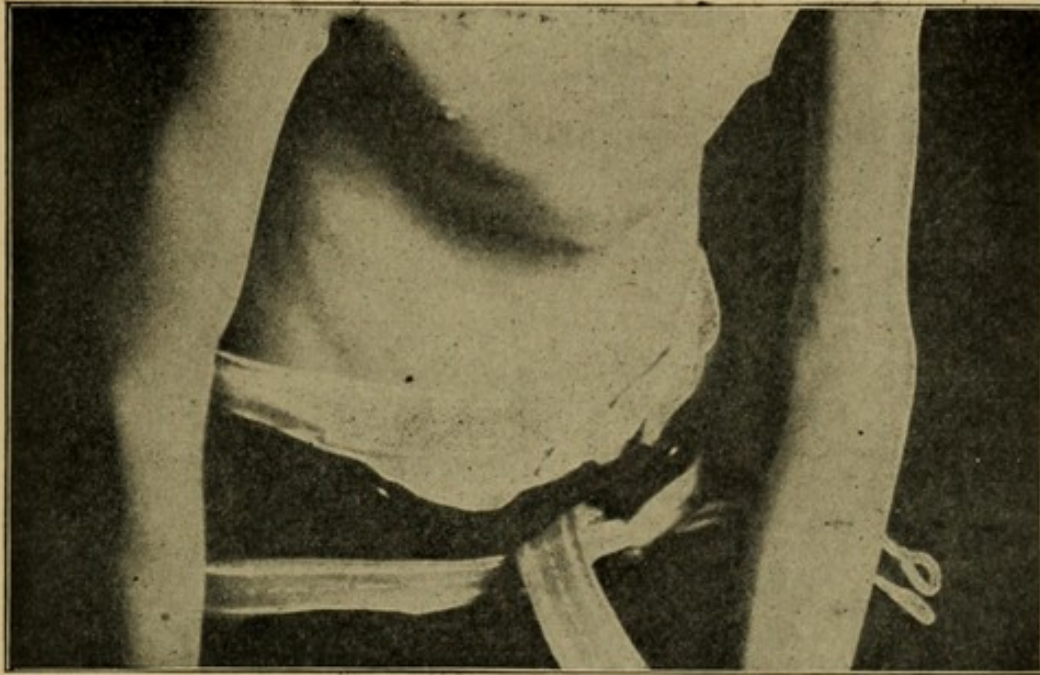


FIG. 8.—Pigeon Breast.

exists in persons with normally shaped chests or with abnormally deep chests (Woods Hutchinson). (See Fig. 129, page 257.)

(c) *The "Barrel Chest."*

Nothing is less like a barrel than the "*barrel chest*." Its most striking characteristic is its greatly increased anteroposterior diameter, so that it approaches the form of the infant's chest. The costal angle is very obtuse, the shoulders are high, and the neck is short. The respiratory movements of the barrel chest will be spoken of later (see Figs. 15 and 16).

Nutrition of the Chest Walls.

Emaciation is readily appreciated by inspection. The ribs are unusually prominent, the scapulæ stand out, and the clavicles project. All this may be seen independently of any change in the

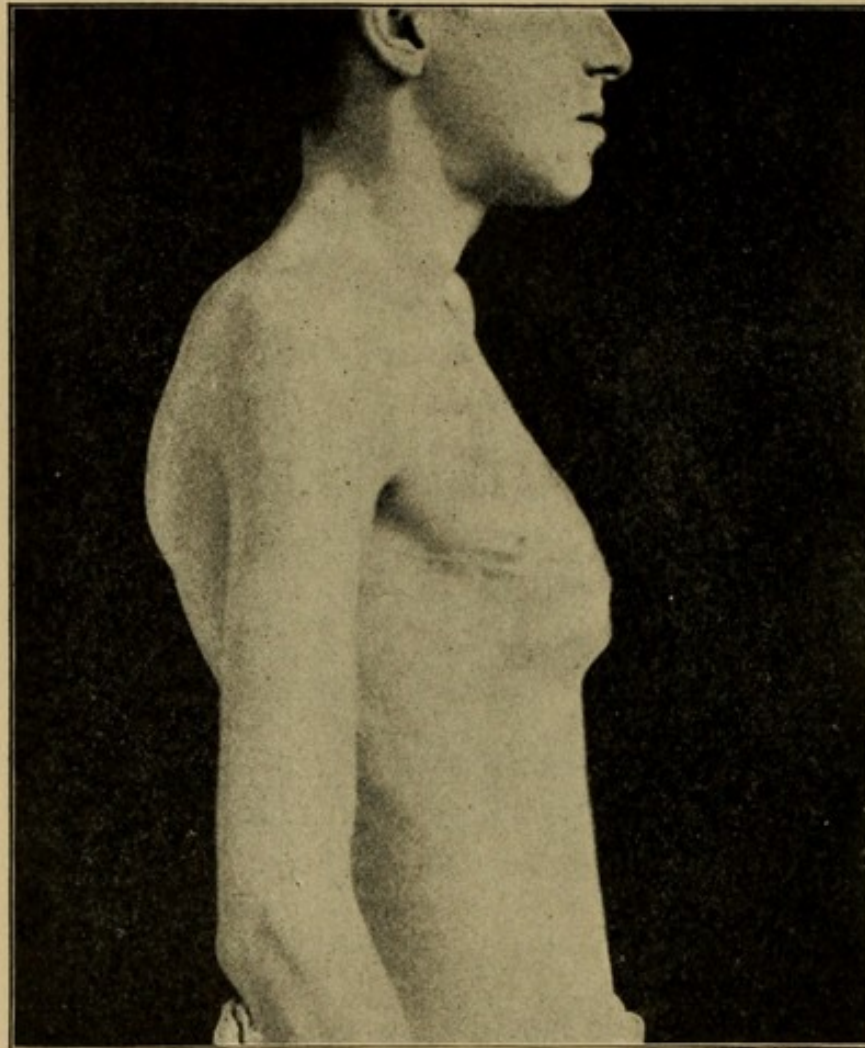


FIG. 9.—Pigeon Breast.

shape of the chest such as was described above under the title of Paralytic Thorax. Tuberculosis of the apices of the lungs may produce a marked falling in of the tissues above and below the clavicle independent of any emaciation of the chest itself.

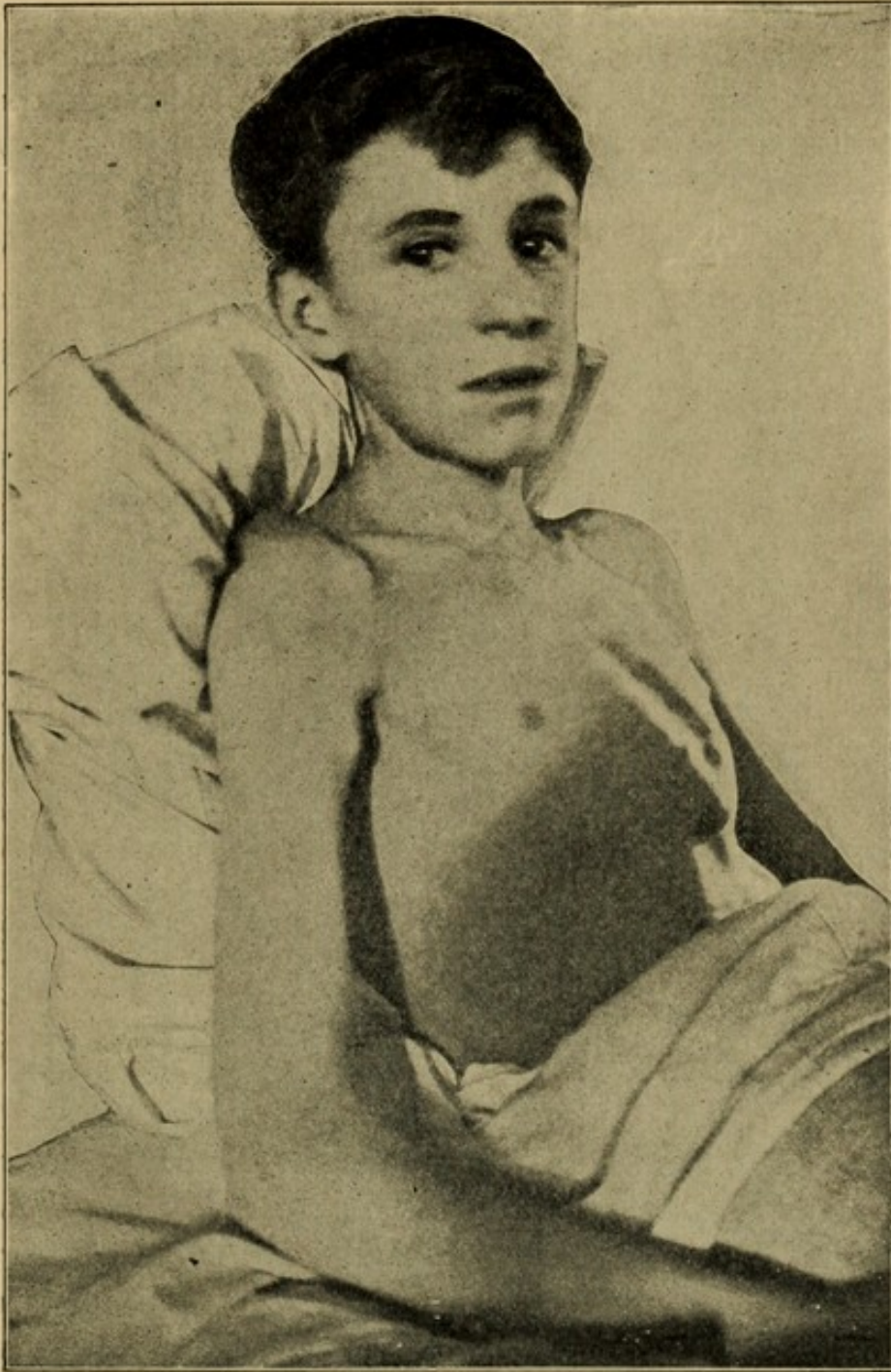

FIG. 10.—Pigeon Breast.

III. DEFORMITIES.

The abnormalities just enumerated are symmetrical and affect the whole thorax. Under the head of Deformities, I shall consider chiefly such abnormalities as affect particular portions of the chest and not the thorax as a whole.

(a) Spinal Curvatures and Twists.

A good view of the patient's *back* brings out best the lesser degrees of lateral curvature, which are not at all infrequent in persons

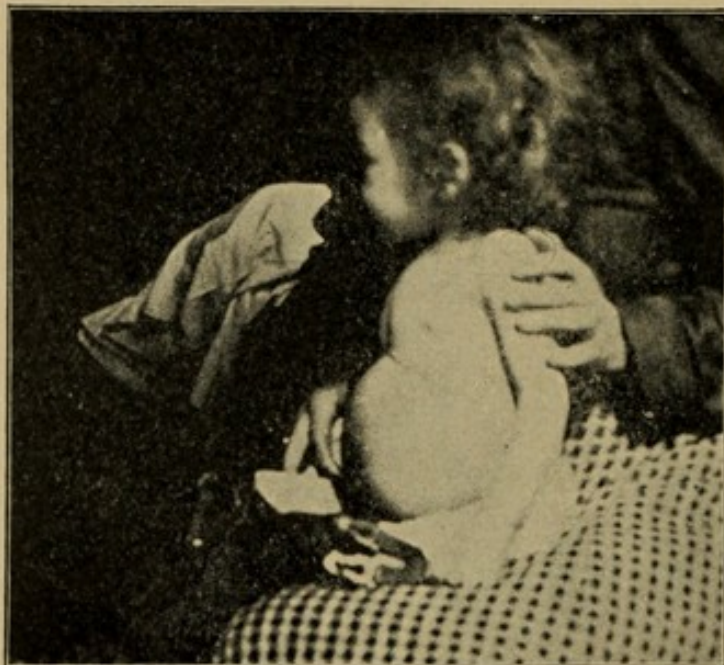


FIG. 11.—Harrison's Groove.

who are not aware of them. Slight degrees of deformity are best seen by marking with a skin-pencil the position of the spinous processes (see Fig. 18). The more marked cases of lateral curvature, which are usually accompanied by a certain amount of *twisting*, give rise to considerable displacement of the thoracic organs and render unreliable the usual bony landmarks, with reference to which we judge of the position of the intrathoracic organs. By such deformities the apex of the heart may be pushed up into the

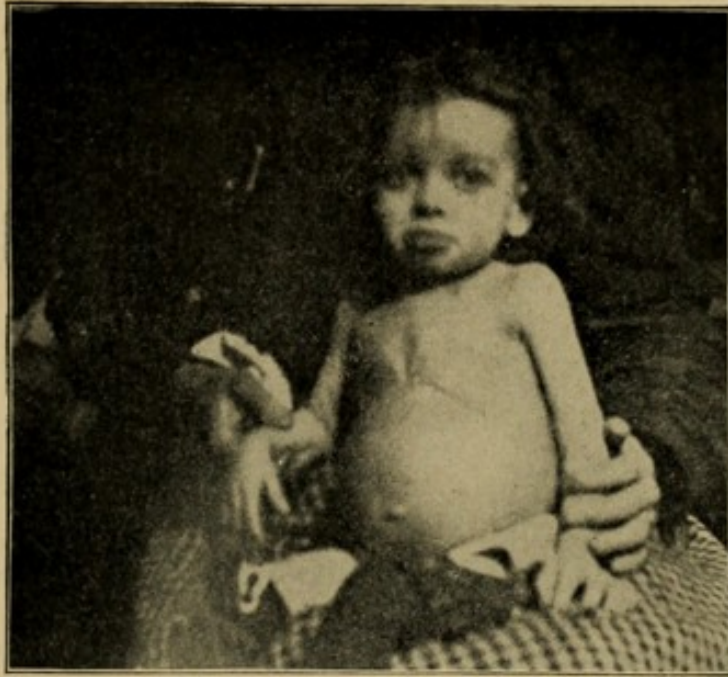

FIG. 12.—Harrison's Groove.

fourth space or out into the axilla, or portions of the lungs may be compressed and made atelectatic.

I. The bulging on the convex side of the curve may simulate an aneurismal tumor.

II. Pott's disease of the spine should be looked for as a part

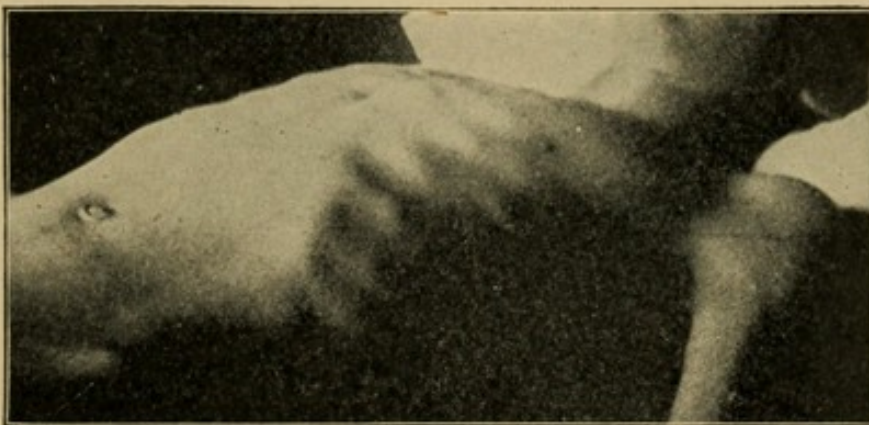

FIG. 13.—Remains of Rachitic Rosary in a Boy of Seventeen.

of the routine inspection of the chest. It is sometimes better felt than seen.

III. Abnormal rigidity of the spine, due to spondylitis deformans, is to be recognized by watching the movements of the spinal column as the patient bends forward and back. Where the vertebræ are locked together, as occurs in moderately advanced cases of

this disease, the spine is maintained rigidly stiff, independent of muscular support. A similar stiffness of the spine may also be seen in early Pott's disease. It is here due mostly to muscular spasm.

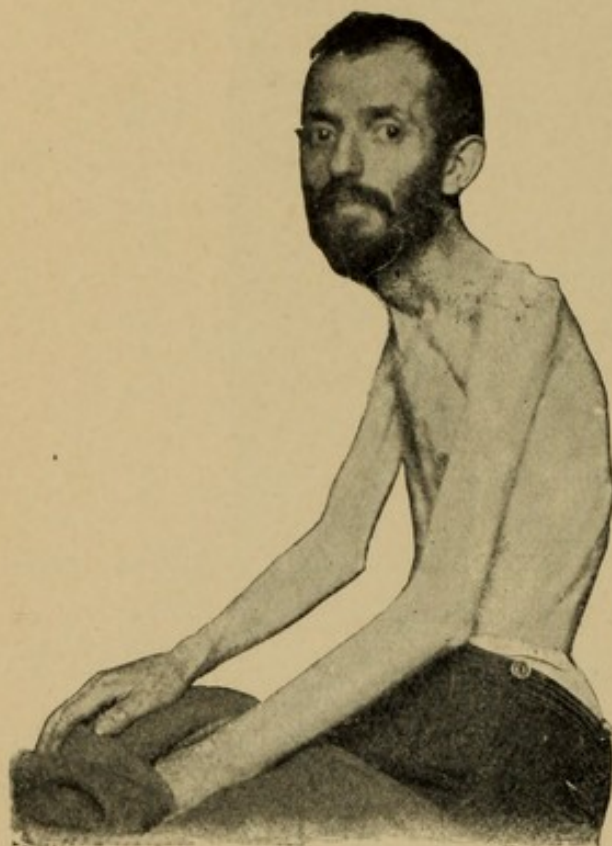


FIG. 14.—The Paralytic Thorax.

(b) *Flattening of One Side of the Chest.*

In chronic phthisis, cirrhosis of the lung, or long-standing pleuritic effusion, marked falling in of one side of the chest is often to be seen. This may be apparent in the upper and front portion, beneath the clavicle, or in the axilla, or in both situations (see Figs.

14 and 20). The shrinkage of the affected side is made more obvious by contrast with the compensatory hypertrophy of the sound lung, which makes the sound side unusually full and prominent.

(c) *Prominence of One Side of the Chest.*

In pneumothorax or pleural effusions, and sometimes in malignant disease of the lung or pleura, there is a marked increase in the size of the affected side of the chest. Very rarely emphysema

may affect one lung predominantly. In pneumothorax or pleuritic effusion we usually see, in addition to the above enlargement of the affected side, a smoothing out of the intercostal depressions so that the surface of that side is much more uniform than the other side. Bulging of the interspaces from great pressure within the chest rarely occurs. I have never seen it.

(d) *Local Prominences.*

In nearly one-quarter of all healthy chests that part of the thoracic wall which overlies the heart (the so-called "precordial region") is abnormally prominent. The cause of this condition is much disputed. A similar prominence may be brought about in children, whose thoracic bones are very flexible (and occasionally in older patients), by the outward pressure of an enlarged heart or of an effusion in the pericardial sac. The prominences due to spinal curvature have been already mentioned. Less common causes of local prominence are:

1. *Aneurism* of the arch of the aorta.

2. *Tumor* of the chest wall (lipoma, sarcoma, gumma) or of the lung, mediastinum, or of the thoracic glands pressing their way outward.

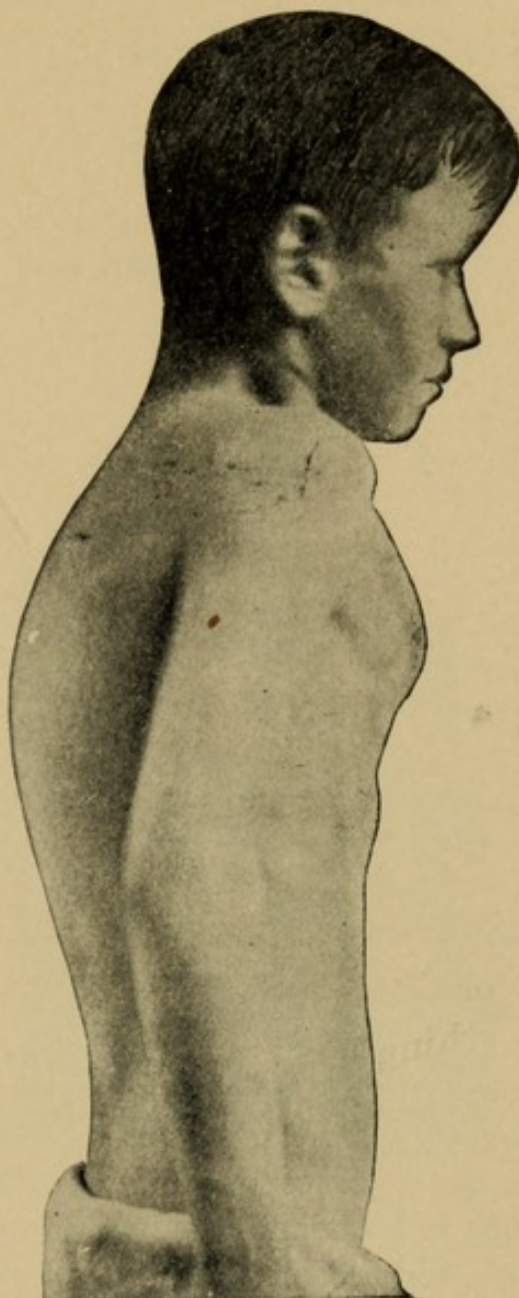


FIG. 15.—Barrel Chest in a Case of Bronchial Asthma (æ. 13).

3. "*Cold abscess*" (tuberculosis) of a rib or of the sternum.

4. *Empyema* perforating the chest wall, the so-called "*empyema necessitatis*."

IV. THE RESPIRATORY MOVEMENTS.

(a) *Normal Respiration.*

During normal respiration, one sees the ribs move outward and upward with inspiration, and downward and inward with expiration.

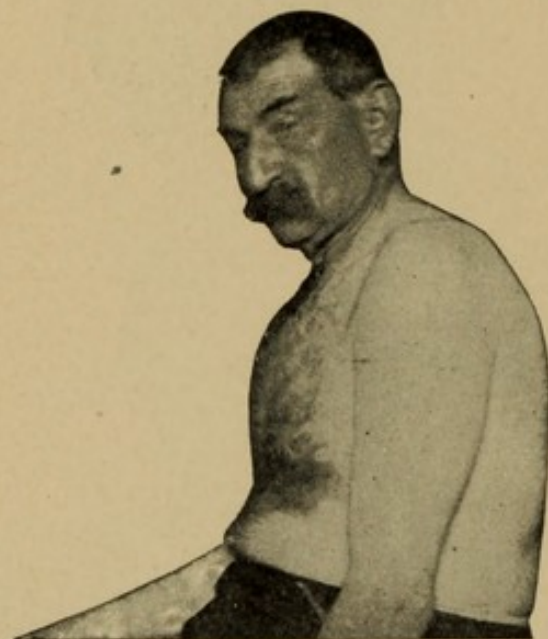


FIG. 16.—Barrel Chest. Chronic bronchitis and emphysema.

Possibly one catches some hint of the movements of the diaphragm at the epigastrium. In men, diaphragmatic breathing is more marked, while in women breathing is mostly of the "*costal type*"; that is, is done by the intercostal muscles. In certain diseases an exaggeration of the costal or of the diaphragmatic type of breathing may be seen. In emphysema, for example, and in some cases of asthma, the ribs move very little, and most of the work of respiration is performed by the diaphragm, whose pull upon the

lower ribs can sometimes be distinctly seen during inspiration. On the other hand, when the movements of the diaphragm are impeded by the presence of fluid or a solid tumor, as in cirrhosis of the liver or leukæmia, the breathing has largely to be performed by the ribs, and becomes, as we say, costal in type (see below, p. 19).

(b) *Anomalies of Expansion.*

If we watch the patient while he takes a full breath, we may notice certain variations from the normal type of respiratory move-

ments. We may see: (1) Diminished expansion of one side (as a whole, or at the apex). (2) Increased expansion of one side.

(1) If *diminished expansion* of one side is due to pleuritic effusion, pneumothorax, or solid tumor of the lung or pleura, the affected side is usually *distended* as well as *immobile*. When, on the other

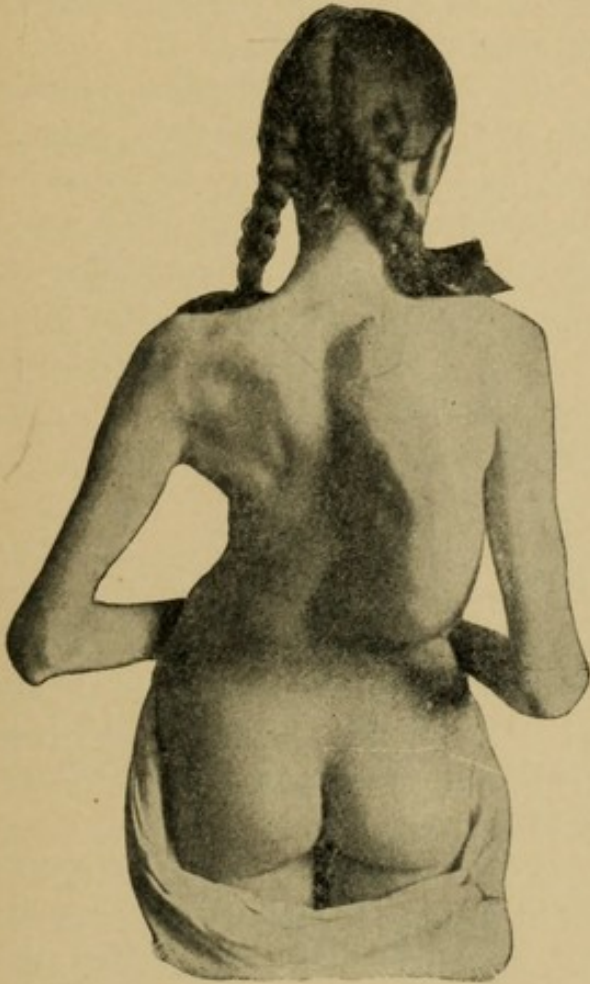

FIG. 17.—Severe Lateral Curvature (Untreated).

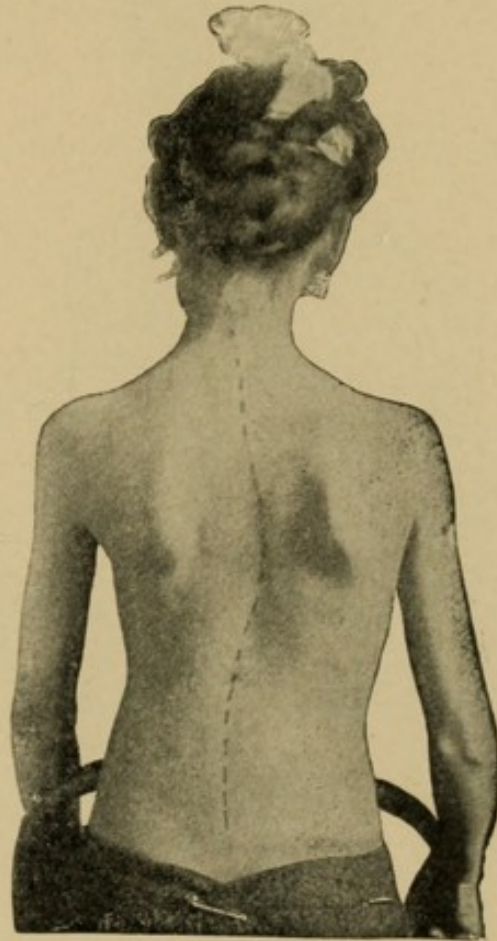


FIG. 18.—Lateral Curvature Three Weeks After Correction.

hand, the lung is retracted or bound down by adhesions, as in phthisis, old pleurisy, occlusion of the bronchus, or from the pressure of an aneurism, we have immobility combined with a *retraction* of the affected side. In tuberculous disease at the apex of the lungs, we may see one side or both sides fail to expand at the top. Restriction of the motion of one side of the chest may also be due

18 PHYSICAL DIAGNOSIS OF DISEASES OF THE CHEST.

pain or to pressure from below the diaphragm. An enlarged liver or spleen and tumors of the hepatic or splenic region may in this way prevent the normal expansion of one or the other side of the thorax.

Occasionally a hemiplegia or a unilateral paralysis of the diaphragm results in diminished movement of one side of the chest.

(2) *Increased expansion* of one side of the chest is observed principally as a compensatory or vicarious overfunctioning of that side when the other side of the chest is thrown out of use by a large pleuritic effusion, by pneumothorax, long-standing pleurisy with contraction, or other causes.

(c) *Dyspnœa*

This term is often used rather loosely to include: (1) Difficult breathing, whether rapid or slow. (2) Unusually deep breathing, whether difficult or not. (3) Rapid breathing.

True dyspnœa or difficult breathing is almost always rapid as well, and does not differ at all from the

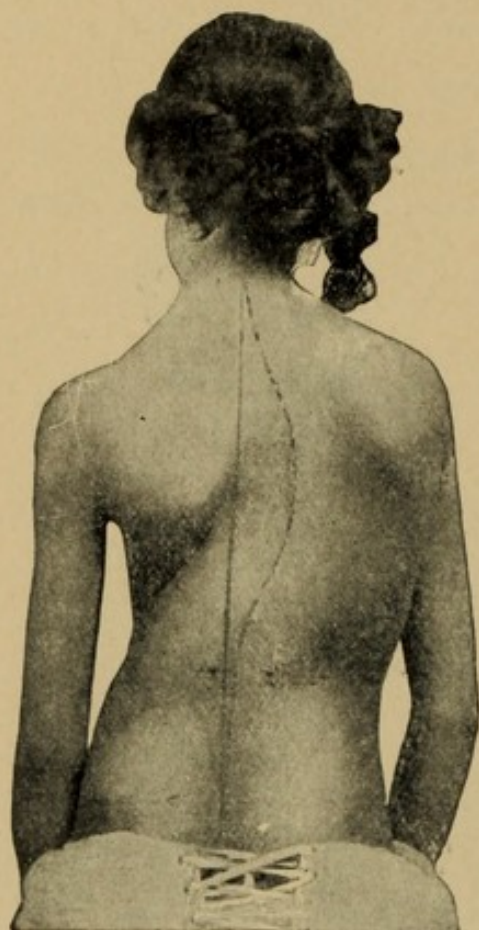


FIG. 19.—Lateral Curvature Before Correction.

well-known phenomenon of being "out of breath" after a hard run or any violent exertion. Conceive these conditions as persisting over hours or days, and we have the phenomenon known as dyspnœa. The breathing is not only thick but labored; that is, performed with difficulty, and unusual muscles, not ordinarily called upon for respiration, come into play and are seen working above the clavicle and elsewhere. More or less distress is generally expressed in the face, and there is often a blueness of the lips or a dusky color throughout the face. The commonest causes of dysp-

nœa are the various forms of heart disease, pneumonia, large pleuritic effusion, emphysema, asthma, and phthisis.

Dyspnœa may affect especially *inspiration*, as, for example, when a foreign body lodges in the larynx, or in ordinary "croup." In such cases we speak of "*inspiratory dyspnœa*," distinguishing it from "*expiratory dyspnœa*" such as occurs in asthma and emphysema. In the latter condition the breath seems to enter the chest readily, but the difficulty is to get it out again. Expiration is greatly prolonged and often noisy.

Combined types also occur in which both respiratory acts are difficult.

Abnormally deep and full respiration, without any appearance of difficulty in the process, is sometimes seen near the fatal termination of cases of diabetes, the so-called *diabetic dyspnœa*.

Simple rapidity of breathing should be distinguished from dyspnœa of any type. In adults the normal rate of respiration is about 22 per minute. In children, it is considerably quicker and more irregular. It is not desirable to attempt here to enumerate all the causes which may lead to a quickening of the respiration. Among the commoner are muscular exertion, emotional disturbance, diseases of the heart and lungs, and fluid or solid accumulations below the diaphragm, which push up that muscle and cause it to encroach abnormally upon the thoracic cavity. Most of the infectious fevers are also apt to be accompanied by quickened breath-

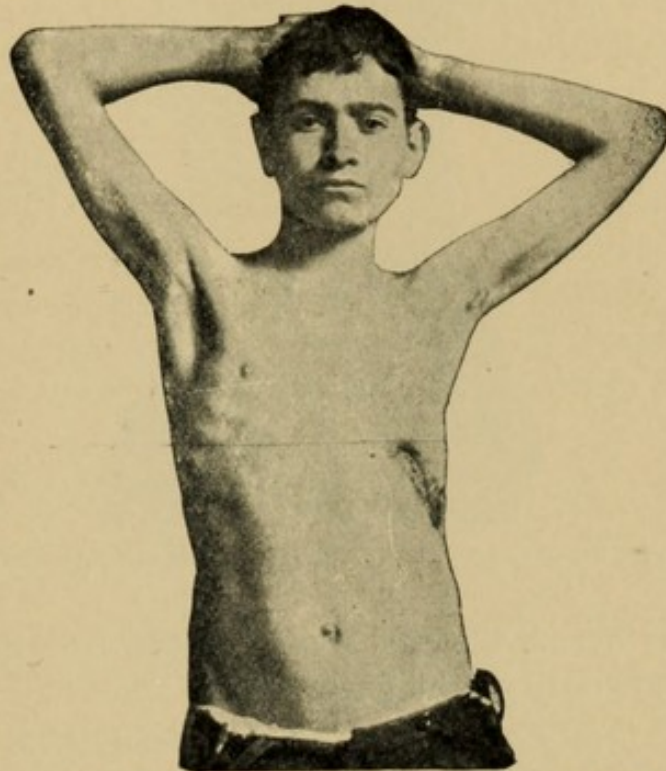


FIG. 20.—Contraction of Left Chest. Empyema.

ing, especially but not exclusively when the fever is associated with a disease of the heart, lung, pleura, or pericardium.

Sucking-in of the interspaces in the lower axillary regions or

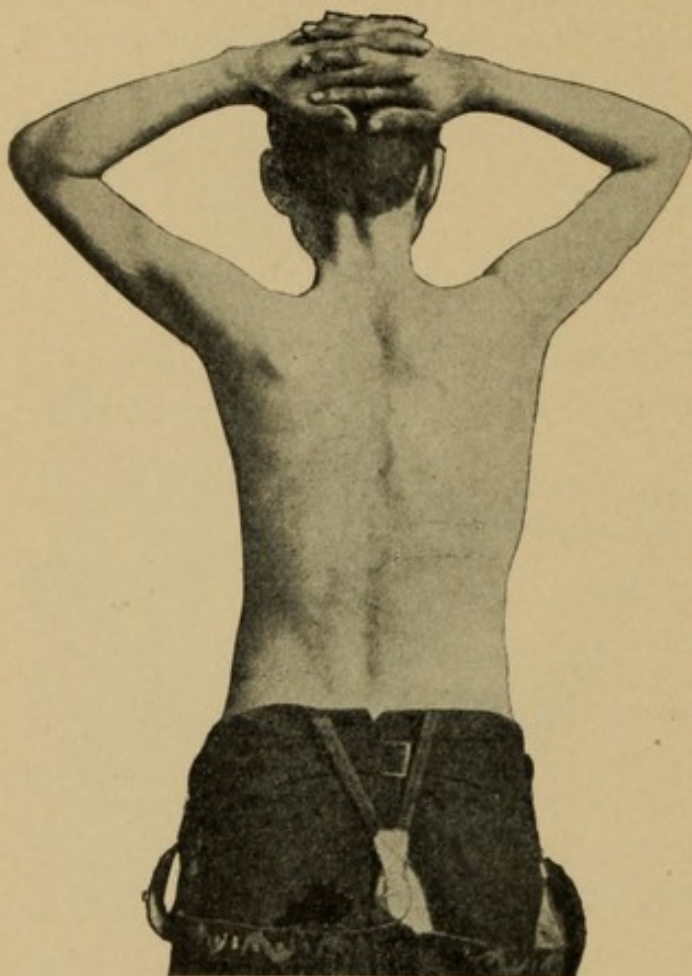


FIG. 21.—Prominence of Right Side. Pleural Effusion.

below the clavicles may be seen in connection with dyspnoea whenever the lungs are prevented by some cause from properly expanding during inspiration. Negative pressure is thus produced within the chest, and the atmospheric pressure without pushes in the more elastic parts of the thorax. This phenomenon is seen in collapse or atelectasis of a portion or the whole of a lung, such as may occur in obstruction at the glottis (in which case both sides are equally retracted) or from occlusion of a bronchus. In the lat-

ter event, the sucking-in of the interspaces during inspiration occurs only on the affected side.¹

¹ Slight retraction of the lower interspaces in the axilla during inspiration is often seen in health. In disease this phenomenon is greatly exaggerated.

V. CHANGES IN THE RESPIRATORY RHYTHM.

(a) Asthmatic Breathing.

In asthma the normal rhythm is reversed and the expiration becomes longer, instead of shorter, than inspiration. Inspiration may be represented only by a short gasp, while expiration becomes a prolonged wheeze lasting several times as long as inspiration. Dyspnœa is usually very marked. In emphysema we get very much the same type of breathing so far as rhythm is concerned, but the dyspnœa is not usually so extreme and the auxiliary muscles of respiration are not so apt to be called into use. In many cases of emphysema one sees the thorax move all as one piece, "*en cuirasse*," owing to a senile fixation of the bones of the thorax from ossification of the cartilaginous portions. In hereditary syphilis or phthisis this fixation may occur in youth or early middle age.

(b) Cheyne-Stokes Breathing.

An anomaly of respiratory rhythm in which short, recurrent paroxysms of dyspnœa are preceded and followed by periods in which no respiration occurs (apnœa). If we represent the normal respiratory movement by an up-and-down line, as seen in Fig. 22,




FIG. 22.—Diagram to Represent Normal Breathing-Rhythm.

the Cheyne-Stokes type of breathing would appear as in Fig 23. The period of apnœa may last from one to ten seconds; then short, shallow respirations begin and increase rapidly, both in volume and in rate, until a maximum of marked dyspnœa is reached, when a diminution in the rate and depth of the act begins, and the patient gradually returns to the apnœic state. The length of the whole paroxysm may be from 30 to 70 seconds. During the apnœic period the patient is apt to drop asleep for a few seconds and the pupils may become contracted. When the paroxysm of dyspnœa

is at its height, he is apt to cough and shift his position restlessly, or in case the whole phenomenon occurs during sleep he moves uneasily in his sleep at this period. Modified types of the phenomenon also occur, in which there is a rhythmic increase and decrease in the depth and rapidity of respiration but without any intervening period of apnœa. This type of breathing is most often seen in severe cases of cardiac, renal, or cerebral disease. It is generally more marked at night and may occur only at that time. In children it appears sometimes to be physiological during sleep. As a




FIG. 23.—Cheyne-Stokes Respiration.

rule, it is a sign of grave prognostic significance, but patients have been known to recover completely after weeks or even months of Cheyne-Stokes breathing.

(c) *Restrained or "Catchy" Breathing.*

When the patient has a "stitch in the side," due to dry pleurisy, intercostal neuralgia, or to other causes, the inspiration may be suddenly interrupted in the middle, owing to a seizure of pain which makes the patient stop breathing as quickly as he can. The same conditions may produce very shallow breathing as the patient tries to avoid the pain which a full inspiration will cause. This type of restrained breathing is often seen in pleurisy and pneumonia, and in the latter disease expiration is often accompanied by a little moan or grunt of discomfort.

(d) *Shallow and irregular breathing* is often seen in states of profound unconsciousness from any cause, such as apoplexy or poisoning. A few deep respirations may be followed by a number of shallow and irregular ones. When death is imminent in any disease, the respiration may become very irregular and gasping, and it is apt to be accompanied by a peculiar nodding movement of the

head, the chin being thrown quickly upward during inspiration, and falling slowly during expiration. I have known but one patient to recover after this type of breathing had set in.

After severe hemorrhage the breathing may be of a *sighing type* as well as very shallow.

(e) *Stridulous Breathing.*

A high-pitched, crowing or barking sound is heard during inspiration when there is obstruction of the entrance of air at or near the glottis. This type of breathing occurs in spasm or oedema of the glottis, "croup," laryngismus stridulus, and forms the "whoop" in the paroxysms of whooping-cough. Laryngeal or tracheal obstructions due to foreign bodies, or tumors within or pressure from without the air-tubes, may cause a similar type of respiration. It is in these cases especially that we see the sucking-in of the inter-spaces mentioned above (see p. 20).

VI. DIAPHRAGMATIC MOVEMENTS.

Litten's Phenomenon.

The normal movements of the diaphragm may be rendered visible by the following procedure, suggested by Litten in 1892: The patient lies upon his back with the chest bared and the feet pointed directly toward a window. Cross lights must be altogether excluded by darkening any other windows which the room may contain¹ (see Fig. 24). The observer stands at the patient's side and asks him to take a full breath. As the ribs rise with the movement of inspiration, a short, narrow shadow moves down along the axilla from about the seventh to about the ninth or tenth rib. During the expiration the shadow rises again to the point from which it started, but is less easily seen. This phenomenon is to be seen on both sides of the chest and sometimes in the epigastrium.

¹ If it is inconvenient to move the patient's bed into the proper position with relation to the window, or if the foot-board interferes, or if the observation has to be made after dark, a dark lantern or other strong light held at the foot of the bed answers very well. All other light must, of course, be excluded.

24 PHYSICAL DIAGNOSIS OF DISEASES OF THE CHEST.

It is best seen in spare, muscular young persons of either sex, and is never absent in health except in those who are very fat, or who cannot or will not breathe deeply. The latter condition occurs in

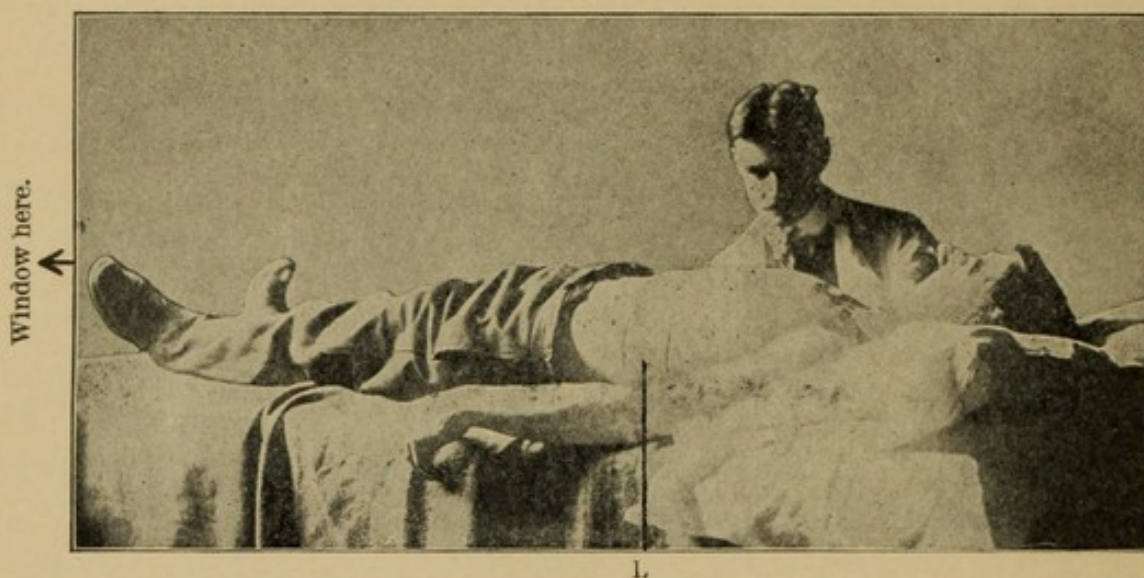


FIG. 24.—Litten's Diaphragm Shadow. Proper position of patient and of observer. The shadow is best seen near L.

hysteria and in some very stupid persons who cannot be made to understand what is meant by a full breath. In the observation of several thousand cases, I have never known it absent in health except under these conditions.

In normal chests, the excursion of the shadow is about two and a half inches; with very forced breathing three and a half inches. The mechanism of this phenomenon is best understood by imagining a coronal section of the thorax as seen from the front or back (see Fig. 25). At the end of expiration, the diaphragm lies flat against the thorax from its attachment up to about the sixth rib. During inspiration it "*peels off*" as it descends and allows the edge of the lung to come down into the chink between the diaphragm and thorax. This "*peeling off*" of the diaphragm and the descent of the lung during inspiration give rise to the moving shadow above described.

By thus observing the excursion of the diaphragm we can obtain a good deal of information of clinical value.

In pneumonia of the lower lobe, pleuritic effusion, extensive pleuritic adhesions, or in advanced cases of emphysema, the shadow is absent. This is explained by the fact that in pneumonia, pleuritic effusion, and emphysema the diaphragm is held off from the chest wall so that its movements communicate no shadow. In pleuritic adhesions the movements of the diaphragm are prevented. In early phthisis I have generally found the excursion of the diaphragm diminished upon the affected side, owing to a loss of elasticity in the affected lung and in part probably to pleuritic adhesions. On the other hand, fluid or solid tumors below the diaphragm, unless very large, do not prevent the descent of that muscle, and so do not abolish the diaphragm shadow. In cases in which the diagnosis is in doubt between fluid in the right pleural cavity and an enlargement of the liver upward or a subdiaphragmatic abscess, the preservation of the Litten's phenomenon in the latter two affections may be of great value in diagnosis. Very large accumulations of ascitic fluid may so far restrain the diaphragmatic movements that no shadow can be seen. Great muscular weakness or debility may greatly diminish, but rarely if ever prevent, the excur-

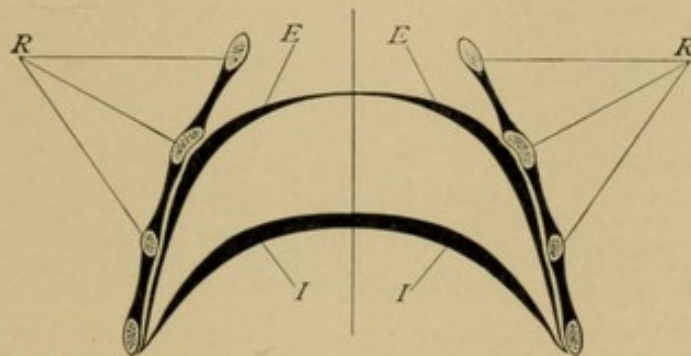


FIG. 25.—Excursion of the Diaphragm during Forced Respiration. *R*, Ribs; *E*, position of the diaphragm at end of expiration; *I*, position of diaphragm at end of inspiration.

sion of the shadow. In persons who cannot be made to breathe deeply enough to bring it out, a hard cough will frequently render it visible.

The use of this method of examination tends, to a certain extent, to free us from the necessity of using the *x*-rays, inasmuch as

it furnishes us with the means of observing the diaphragmatic movements, on the importance of which so much stress has been laid by F. H. Williams and others, much more easily and cheaply than with the *x*-rays, and upon the left side, more plainly as well.

It also frees us to a considerable extent from the need of using the spirometer to determine the capacity of the lungs.

By measuring the excursion of the phrenic shadow and taking account of the thoracic movement, we obtain a very fair idea of the respiratory capacity of the individual.

VII. OBSERVATION OF THE CARDIAC MOVEMENTS.

(1) *The Normal Cardiac Impulse.*

With each systole of the heart there may be seen in the great majority of normal chests an outward movement of a small portion of the chest wall just inside and below the left nipple. This phenomenon is known as the cardiac impulse.¹ It is now generally admitted that the "apex impulse" is caused by the impact of a portion of the right ventricle against the chest wall and not by the apex of the heart itself. [The bearings of this fact, which have not, I think, been generally appreciated, will be discussed presently.] The position of the *maximum* impulse in adults is usually in the fifth intercostal space just inside the nipple line. In children under the age of six it is often in the fourth interspace or behind the fifth rib; while in persons of advanced age it often descends as low as the sixth interspace. In adults it is occasionally absent even in perfect health and under certain pathological conditions to be later mentioned.

(a) The position of the impulse varies to a certain extent according to the position of the body. If the patient lies upon the left side, the heart's apex swings out toward the axilla, so that the visible impulse shifts from one to two and one-half inches to the left (see Fig. 26). A slight shift to the right can also be brought about by lying upon the right side, and, as a rule, the impulse is less visible in the recumbent than in the upright position.

¹ For a more detailed description of the normal position of the cardiac impulse, see next page.

Since the heart is lifted with each expiration by the rise of the diaphragm and falls during inspiration, a corresponding change can be observed in the apex beat, which, in forced breathing, may shift as much as one interspace. Of the changes in the position of the impulse brought about by disease, I shall speak in a later paragraph.

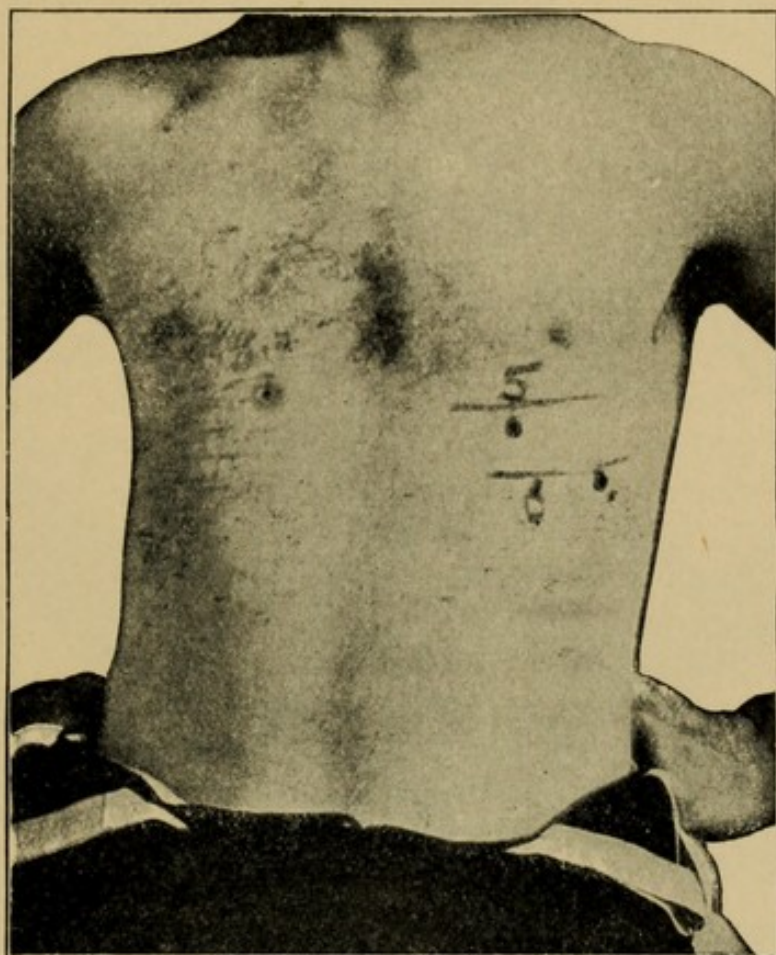


FIG. 26.—Showing Amount of Shifting of the Apex Impulse with Change of Position. The inner dot represents the position of the impulse when the patient lies on his back; the outer dot corresponds to the position of the apex with patient on left side.

(b) *Relation of the maximum cardiac impulse to the apex of the heart.*—I mentioned above that the maximum cardiac impulse is not due to the striking of the apex of the heart against the chest wall, but to the impact of a portion of the right ventricle. The practical importance of this fact is this: When we are trying to localize the apex of the heart in order to determine how far the organ extends to the left and downward, it will not do to be guided by the posi

tion of the *maximum* impulse, for the apex of the heart is almost always to be found three-fourths of an inch or more farther to the left (see Fig. 27). This may be proved by percussion (*vide infra*,

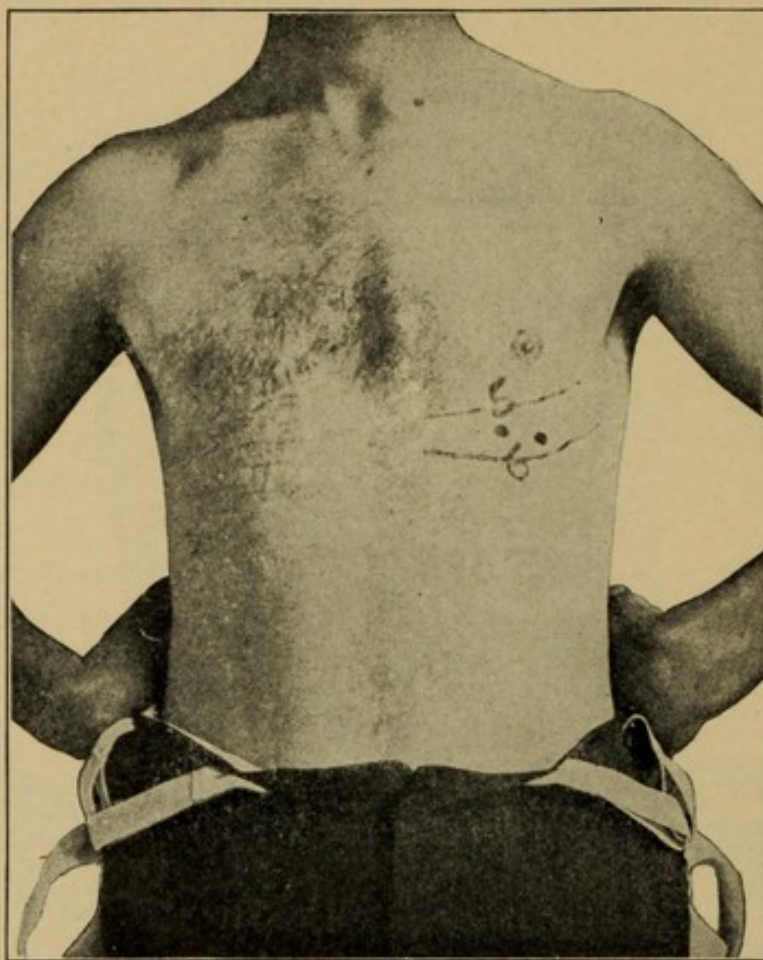


FIG. 27.—The Inner Dot is the Maximum Cardiac Impulse. That to the right is the true apex of the heart, as obtained by percussion. The ribs are numbered.

p. 58). The true position of the cardiac apex thus determined corresponds usually not with the *maximum* impulse, but with the point farthest out and farthest down at which *any rise and fall* synchronous with the heart beat *can be felt* (for further discussion of this point see below, p. 218).

(c) Besides the definite and localized impulse which has just been described, it is often possible to see that a considerable section of the chest wall in the precordial region is lifted "*en masse*." The phenomenon is the "*Herzenstoss*" of the Germans, with which

the "*Spitzenstoss*" or *apex impulse* is contrasted. A variable amount of "*Herzenstoss*" can be seen and felt over any normal heart when it is acting rapidly and forcibly, and in thin, nervous subjects or in children even when the heart is beating quietly. It is more marked in cardiac neuroses or in cases in which the heart is hypertrophied and in which there is more or less stiffening of the ribs with loss of their natural elasticity. At times it may be impossible to localize any one point to which we can give the name of apex impulse, and what we see is the rhythmical rise and fall of a section of the chest as large as the palm of the hand or larger.

(d) *Character of the cardiac impulse.*—Palpation is considerably more effective than inspection in giving us information as to the nature of the cardiac movements which give rise to the "apex beat," but even inspection sometimes suffices to show that the impulse has a heaving character or is of the nature of a short tap, a peristaltic wave, or a diffuse slap against the chest wall. In some cases a distinct undulation can be seen passing from the apex region upward toward the base of the heart, or less often in the opposite direction.

(2.) *Displacement of the Cardiac Impulse.*

To one familiar with the position, extent, and character of the normal cardiac impulse, any displacement of this impulse from its normal site or any superadded pulsation in another part of the chest is apparent at a glance. I will consider first the commonest forms of dislocation of the apex impulse.

(a) *Displacement of the cardiac impulse due to hypertrophy and dilatation of the heart.*—By far the most common directions of displacement are toward the left axilla, or downward. As a rule, it is displaced in both these directions at once. I shall return to this subject more in detail under the heading Cardiac Hypertrophy, but here I may say that enlargements of the left ventricle tend especially to displace the apex impulse downward, while enlargements of the right ventricle are more commonly associated with displacement of the impulse toward the axilla.

(b) Next to hypertrophy and dilatation of the heart perhaps the commonest cause of dislocation of the cardiac impulse is pressure

from below the diaphragm. When the diaphragm is raised by a large accumulation of gas or fluid or by solid tumors of large size, we may see the apex beat in the fourth interspace and often an inch or more inside the nipple line.

(c) Of nearly equal frequency is displacement of the heart due to *pleuritic effusion* or to *pneumothorax*.

When a considerable amount of air or fluid accumulates in the left pleural cavity, the apex of the heart is displaced to the right so that it may be concealed behind the sternum or be visible beyond it to the right; in extreme cases it may be dislocated as far as the right nipple. Right pleuritic effusions have far less effect upon the position of the cardiac impulse, but when a very large amount of fluid accumulates we may see the impulse displaced considerably toward the left axilla.

(d) I have mentioned causes tending to push the heart to the right, to the left, or upward. Occasionally the heart is pushed downward by an aneurismal tumor or a neoplasm of the mediastinum. In these cases there is usually more or less displacement to the left as well. As a result of arteriosclerosis or cardiac hypertrophy the aorta may sag or stretch a little, and the diaphragm stands lower, and hence the apex beat may descend to the sixth interspace, or (more often) it may be lost to sight and touch behind the bunch of convergent costal cartilages just to the left of the ensiform. Very frequently in men past forty-five the whole heart sinks considerably, so that a marked systolic retraction (less often pulsation) is seen below the ensiform in the epigastrium.

(e) Displacement of the cardiac impulse resulting from *adhesions* of the pericardium, or of the pleura, with subsequent contraction, occurs in *fibroid phthisis* and in some cases of long-standing disease of the pleura. Through the effect of negative pressure the heart may be sucked into the space formerly occupied by a portion of the lung, when the latter has become contracted by disease. It seems likely, however, that in the majority of cases adhesions between the pleura and pericardium play a part in such displacement. By these means the heart may be displaced to the right of the sternum, as it is by left-sided pleuritic effusion. It is often drawn upward

as well as to the right in such cases by the contraction which takes place in the upper part of the lung. More rarely we may see the heart drawn toward the left clavicle in fibroid phthisis of the left apex.

(*f*) Distortion of the thorax due to spinal curvature or other causes may bring about a considerable displacement of the heart from its normal position.

(*g*) *Dextrocardia and Situs Inversus*.—In rare cases a displacement of the apex impulse to the right of the sternum may be due either to a *transposition of all viscera* [the liver being found upon the left, the spleen upon the right, etc.], or to *dextrocardia*, in which the heart alone is transposed while the other viscera retain their normal places (see Fig. 143, p. 310).

Summary.

The apex impulse is displaced by

- (*a*) Hypertrophy and dilatation of the heart.
- (*b*) Pressure from below the diaphragm.
- (*c*) Air or fluid in one pleural cavity, especially the left.
- (*d*) Aneurism, mediastinal growths, and sagging of the aorta.
- (*e*) Fibroid phthisis.
- (*f*) Spinal curvature.
- (*g*) Transposition of the heart or of all the viscera.

(3) *Apex Retraction.*

Before leaving the subject of the cardiac impulse it seems best to speak of those cases in which during systole we see a *retraction* of one or more interspaces at or near the point where the cardiac impulse normally appears.

(*a*) In by far the greater number of instances such retraction is due to negative pressure produced within the chest by the vigorous contraction of a more or less hypertrophied and dilated heart. In these cases the retraction is usually to be seen in several interspaces. Such retraction is not at all uncommon and usually attracts no attention.

(*b*) In rarer cases several interspaces, both in the precordial

region and in the left lower axilla and back, may be drawn in as a result of adhesions between the pericardium and the chest wall, such as form in cases of adherent pericardium and fibrous mediastinitis (see below, pages 222 and 303.)

(4) *Epigastric Pulsation.*

In a considerable portion of healthy adults a pulsation or retraction at the epigastrium synchronous with the systole of the heart is to be seen from time to time. Such pulsation has often been treated as evidence of hypertrophy of the right ventricle of the heart, but this I believe to be an error. It is not at all uncommon to find, post mortem, considerable hypertrophy of the right ventricle in cases in which during life no epigastric pulsation has been visible, while, on the other hand, the heart is frequently found normal at autopsy in cases in which during life there has been marked epigastric pulsation. In some cases such pulsation is to be explained as the transmission of the heart's impulse through the liver, or as a lifting of that organ by the movements of the abdominal aorta. In other cases it is due to bathycardia ("low heart"—a condition very common in arteriosclerosis).

(5) *Visible Pulsations due to Uncovering of Portions of the Heart Normally Covered by the Lungs.*

One of the commonest causes of visible pulsations in parts of the chest where normally none is to be seen is *retraction of the lung*.

(a) It is in chlorosis, perhaps, that we most frequently see such pulsations. In that disease, as in other debilitated states, the lungs are often not adequately expanded owing to the superficiality of the respiration, and accordingly their margins do not cover as much of the surface of the heart as they do in healthy adults. This results in rendering visible, in the second, third, or fourth left interspace near the sternum, pulsations transmitted from the conus arteriosus or from the right ventricle. Less commonly, similar pulsations may be seen on the right side of the sternum.

(b) A rarer cause of retraction of the lungs is fibroid phthisis or chronic interstitial pneumonia. In these diseases a very large

area of pulsation may be seen in the precordial region owing to the entire uncovering of the heart by the retracted lung, even when the heart is not drawn out of its normal position.

VIII. ANEURISM AND OTHER CAUSES OF ABNORMAL THORACIC PULSATION.

So far I have spoken altogether of pulsations transmitted directly to the thorax by the heart itself, but we have also to bear in

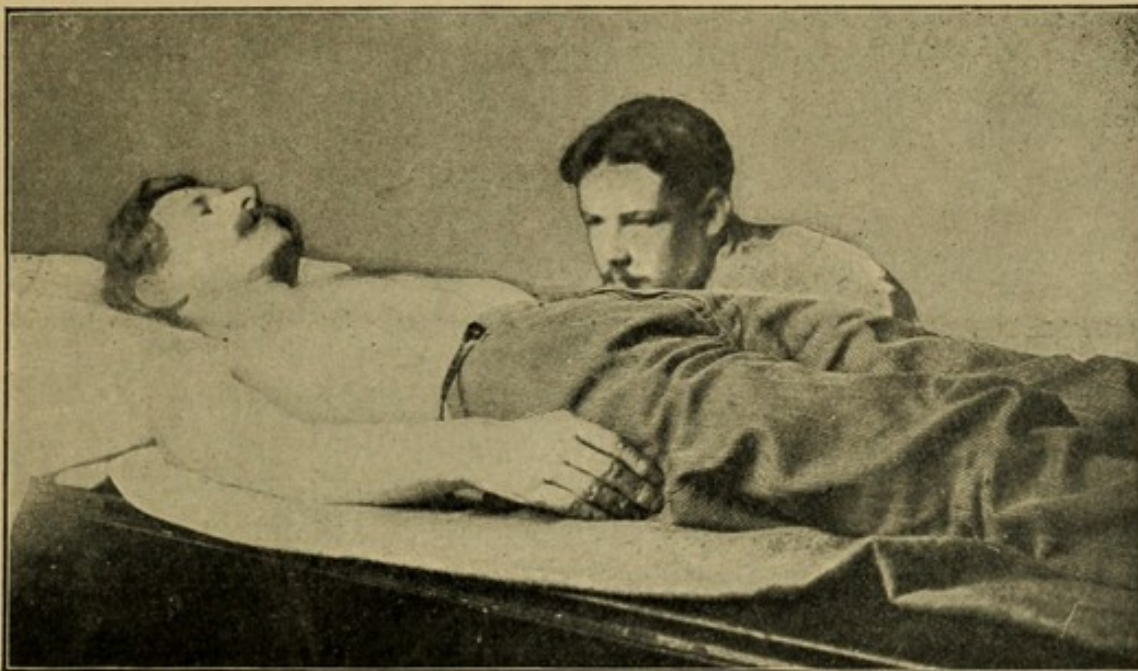


FIG. 28.—Position When Looking for Slight Aneurismal Pulsation.

mind that a dilated aorta may transmit to the chest wall pulsations which it is exceedingly important for us to recognize and properly to interpret. No disease is easier to recognize than aneurism when the growth has perforated the chest wall and appears as a tumor externally, but it is much more important as well as much more difficult to recognize the disease while it is confined within the thorax. In such cases, the movements transmitted from the aorta to the chest wall may be so slight that only the keenest and most thorough inspection controlled by palpation will detect them. When slight pulsations are searched for, the patient should be put in a position

shown in Fig. 28, and the observer should place himself so that his eye is as nearly as possible on a level with the chest and looks across it so that he sees it in profile. In this position, or in a sitting position with tangential light, he can make out pulsations which are totally invisible if the patient sits facing the light.

Pulsations due to aneurism are most apt to be seen in the first or second right interspace near the sternum, and not infrequently the clavicle and the adjacent parts may be seen to rise slightly with every beat of the heart, but in any part of the chest wall pulsations due to an aneurism are occasionally to be seen, and should be looked for scrupulously whenever the symptoms of the case suggest the possibility of this disease (see below, p. 229).

Pulsating Pleurisy.

In cases of purulent pleurisy in which the pus has worked its way out between the ribs so that it is covered only by the skin and subcutaneous tissues, a pulsation transmitted from the heart may become visible, and the resemblance to the pulsation seen in aneurism may be confusing. Such pulsation is apt to be seen in the upper and front portions of the chest. Very rarely a pleuritic effusion which has not burrowed into the chest wall may transmit to the latter a wavy movement corresponding to the motions set up in the fluid by the cardiac contractions.

IX. INSPECTION OF THE PERIPHERAL VESSELS.

In a work dealing with diseases of the heart and lungs it is impossible to avoid reference to vascular phenomena apparent in the neck or in the extremities, since such phenomena have a very direct bearing upon the interpretation of the conditions obtaining within the chest. Inspection plays a very large part in the study of these vascular phenomena. We should look for:

- (a) Venous phenomena.
- (b) Arterial phenomena.
- (c) Capillary phenomena.

(a) Inspection of the Veins.

1. The condition of the veins of the neck is of considerable importance in the diagnosis of diseases of the heart and lungs. Where the tissues of the neck are more or less wasted the veins may be quite prominent even when no disease exists within the chest, and in such cases they may be more or less distended during each expiration, especially if dyspnoea or cough is present. If the overdistended veins are completely emptied during deep inspiration and on both sides of the neck, we can usually infer that there is an overdistention of the right side of the heart. When a similar phenomenon occurs on one side only, it may mean pressure upon one innominate vein. So far I have spoken of venous changes synchronous with respiration, but we may have also

2. *A presystolic pulsation or undulation* seen either in the external jugular vein or in the bulbus jugularis between the two attachments of the sternomastoid muscles. Such pulsation or undulation, which is to be seen just before each systole of the heart, is not necessarily anything abnormal and must be carefully distinguished from

3. *Systolic venous pulsation*, such as occurs in one of the most serious valvular diseases of the heart—tricuspid regurgitation.¹ Systolic venous pulsation is more often seen upon the right side than upon the left side of the neck. There may be a wave during the systole of the auricle and another during the systole of the ventricle, the latter closely following the former. In any case in which a doubt arises whether a pulsation in the veins of the neck is due to tricuspid regurgitation, it is well to try the experiment of emptying the vein by stroking it from below upward. If it immediately fills from below, we may be practically certain that tricuspid regurgitation is present. In the vast majority of cases of venous pulsation due to other causes or occurring in healthy persons

¹ A pulsating carotid may transmit an up-and-down motion to the veins overlying it. In such cases, if the veins be emptied by "milking" them upward, they will not refill from below.

a vein will not refill from below if emptied in the manner above described.

4. Rarely, superficial veins may be seen to pulsate in other parts of the body, especially in aortic regurgitation, and occasionally large and tortuous veins may be seen pulsating upon the thoracic

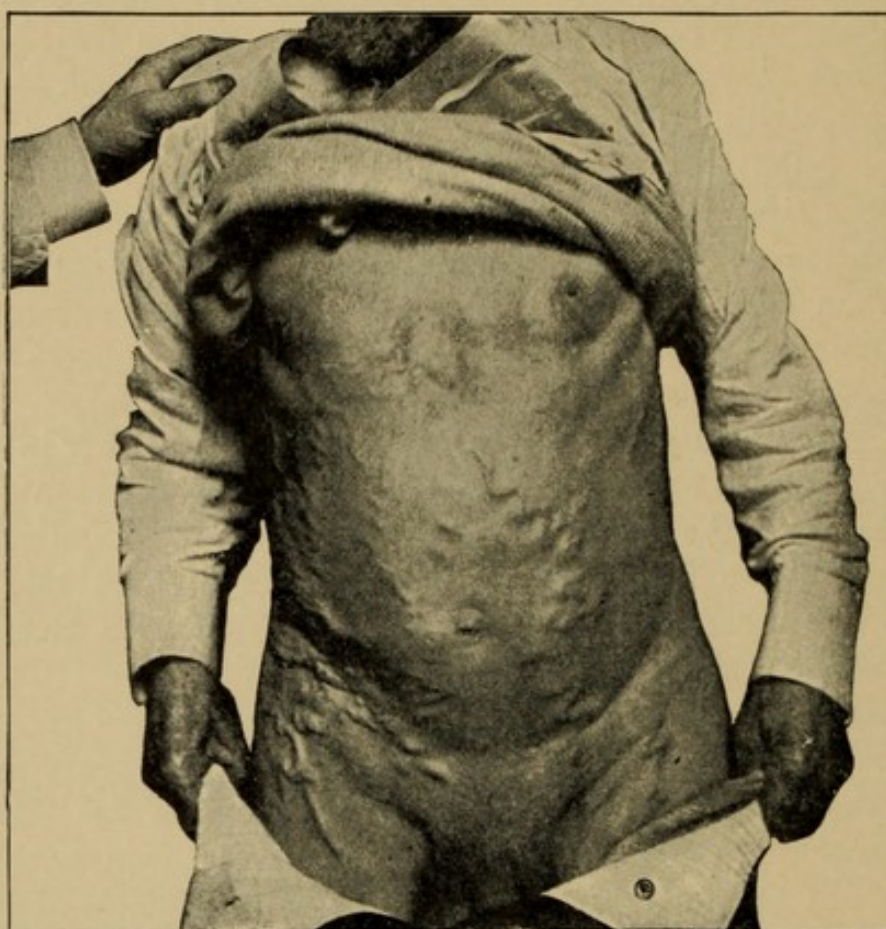


FIG. 29.—Tortuous Veins on Chest and Abdomen. (Autopsy showed obliteration of the vena cava inferior.)

or abdominal wall, representing an attempt at collateral circulation when one or the other vena cava is compressed (Fig. 29).

(b) Arterial Phenomena.

1. In thin or nervous persons pulsations are not infrequently to be seen in the carotids independent of any abnormal condition of the heart.

2. Very violent throbbing of the carotids, more noticeable than

that seen in health, occurs in many cases of aortic regurgitation and occasionally in simple hypertrophy of the heart without any valvular disease. From the same causes, visible pulsation may occur in the subclavian, axillary, brachial, and radial arteries, as well as in the large arterial trunks of the lower extremity.

I lately examined a blacksmith whose heart was considerably enlarged by hard work, but without any valvular disease. Pulsa-

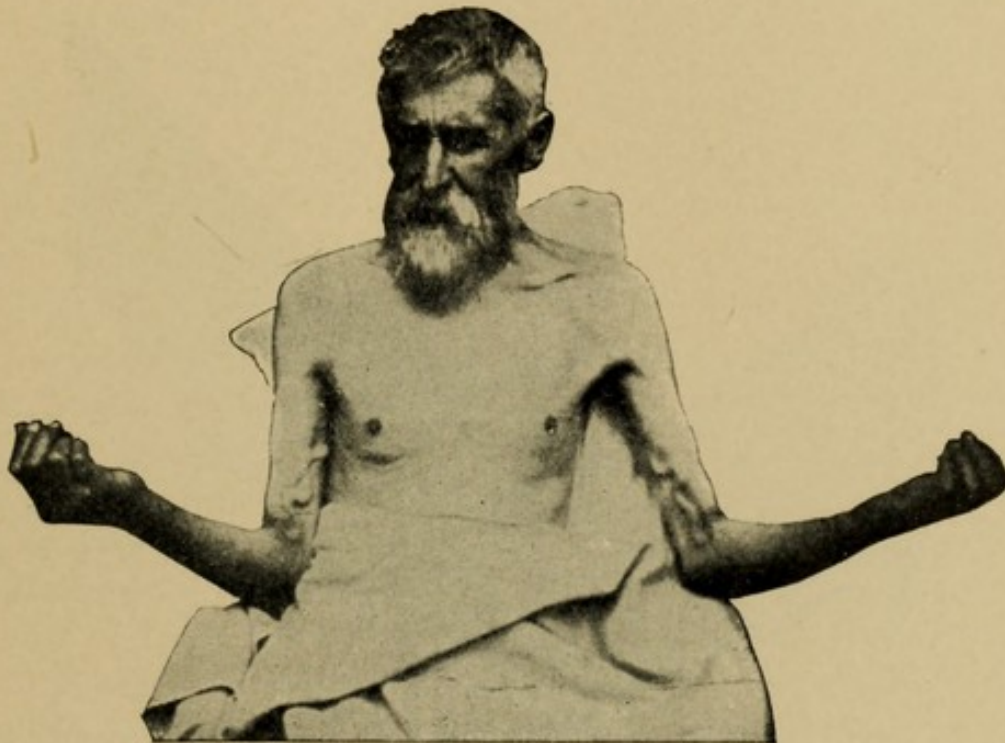

FIG. 30.—Enlarged Tortuous Brachial Arteries (Arterio-sclerosis).

tion was violent in all the peripheral arteries which I have just named.

3. In arterio-sclerosis occurring in spare, elderly men, with or without aortic regurgitation, one often notices a lateral excursion of the tortuous brachial arteries synchronous with every heart beat. An up-and-down pulsation may occur at the same time. Not infrequently the arteries which are stiffened by deposition of lime salts (see below, page 56) stand out visibly as enlarged, tortuous cords upon the temple and along the inner side of the biceps muscle, (see Figs. 30 and 31) and occasionally the course of the radial artery

may be traced over a considerable distance in the forearm. In rare cases inequalities produced in the arterial wall by deposition of lime salts may be visible as well as palpable.

(c) Capillary Pulsation.

If a microscopic slide is placed against the mucous membrane of the lower lip so as partially to blanch its surface, one may see, with

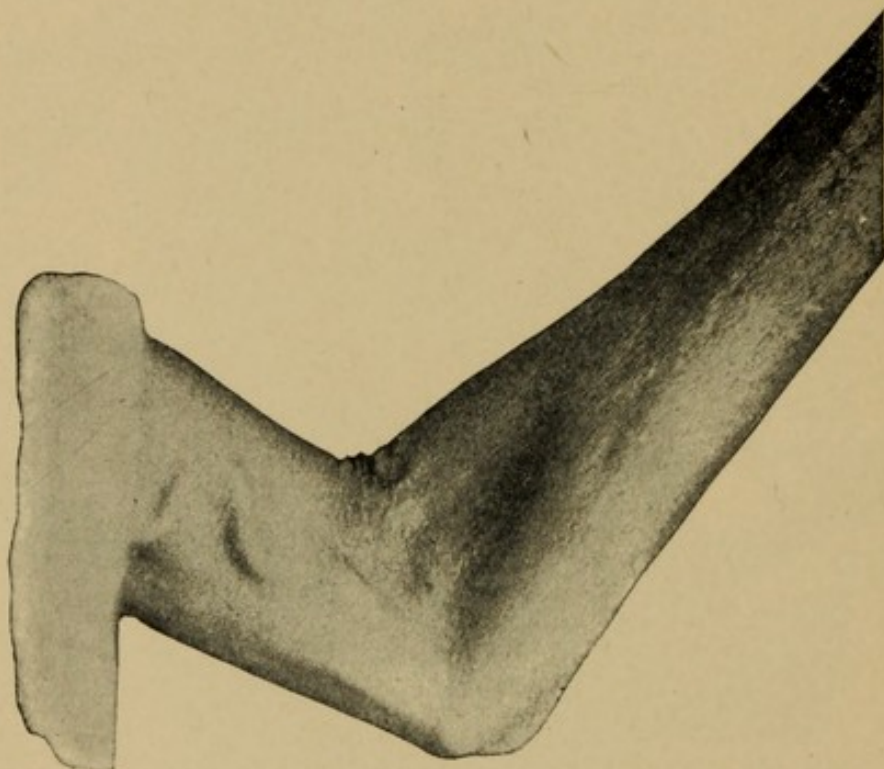


FIG. 31. —Enlarged and Tortuous Brachial Artery (Arterio-sclerosis).

each beat of the heart (in cases of aortic regurgitation and sometimes in other conditions), a delicate flushing of the blanched surface beneath the glass slide. The same pulsation is sometimes to be observed under the finger nails, or may be still better brought out by drawing a pencil or other hard substance across the forehead so as to cause a line of hyperæmia, at the edge of which the systolic flushing occurs. This phenomenon will be referred to again when we come to speak of aortic regurgitation. Here it suffices to say that it is not in any way peculiar to that disease, and occurs occasion-

ally in health in exophthalmic goitre and in conditions associated with low tension in the peripheral arteries, as well as in any area of inflammatory hyperæmia (jumping toothache, throbbing felon, etc.).

X. INSPECTION OF THE SKIN AND MUCOUS MEMBRANES.

Light may be thrown upon the diagnosis of diseases of the chest by observing the color and condition of the cutaneous surfaces as well as of the mucous membranes. We should look for the following conditions:

- (1) Cyanosis.
- (2) Œdema.
- (3) Pallor.
- (4) Jaundice.
- (5) Scars and eruptions.

(1) *Cyanosis.*

By cyanosis we mean a purplish or grayish-blue tint noticeable especially in the face, in the lips, and under the nails. There are many degrees of cyanosis, from the slight purplish tinge of the lips, which a little overexertion or slight exposure to cold may bring out, up to the gray-blue color seen in advanced cases of pulmonary or cardiac disease, or the dark reddish-blue seen in congenital malformations of the heart. Cyanosis makes a very different impression upon us when it is combined with pallor on the one hand or with jaundice on the other. When combined with pallor, one gets various ashy-gray tints, while the admixture of cyanosis and jaundice results in a color very difficult to describe, sometimes approaching a greenish hue. The commonest causes of cyanosis are:

- (a) Valvular or parietal disease of the heart.
- (b) Emphysema.
- (c) Asthma.
- (d) Pneumonia.
- (e) Phthisis.

(f) In some persons a certain degree of cyanosis of the lips exists despite perfect health. This is especially true of weather-beaten faces and those of the so-called "full-blooded" type.

(g) Methæmoglobinæmia, such as occurs after the excessive use of coal-tar analgesics (antifebrine, etc.).

A rare but very striking type of cyanosis is that seen in cases of congenital heart disease, in which the lips may be indigo blue in color or almost black while yet no dyspnœa is present.

(2) *Œdema.*

Œdema, or the accumulation of serous fluid in the subcutaneous spaces, is usually appreciated by palpation rather than by inspection, but sometimes makes the face look very puffy, especially under the eyes. This is not a common occurrence in diseases of the chest, in connection with which such œdema as takes place is usually to be found in the lower extremities and is appreciable rather by palpation than by inspection. If we are not familiar with a patient's face, we often do not perceive in it the changes of outline due to œdema which a friend would notice at once. Clothing is apt to leave grooves and marks wherever it presses tightly upon the œdematous tissues, as around the waist or over the shoulders. In the legs, the presence of œdema may be suggested by an unnaturally smooth, glossy appearance of the skin. Such impressions, however, may be false unless controlled by palpation, for simple obesity may produce very similar appearances.

(3) *Pallor.*

Pallor suggests, though it does not in any way prove, anæmia, and anæmia is a characteristic of the commonest of all diseases of the chest—phthisis. It is also seen in certain varieties of cardiac disease. Pallor of the mucous membranes, as seen in the lips and conjunctivæ, is much more apt to be a sign of real anæmia than is pallor of the skin. At best, pallor is only a sign which suggests to us to look further into the case in one or another direction, and of itself proves nothing of importance.

(4) *Jaundice.*

The yellowish tint which appears in the skin, and especially in

the conjunctivæ, when the escape of bile from the liver is hindered, is sometimes to be seen in connection with uncompensated heart disease when the liver is greatly distended by passive congestion. Pneumonia is occasionally complicated by jaundice; but beyond this I know of no special connection between this symptom and diseases of the chest.

(5) *Scars and Eruptions.*

In cases of suspected syphilis of the lung or bronchi the presence of scars and eruptions suggestive of syphilis may be useful in diagnosis.

XI. ENLARGED GLANDS.

Routine inspection of the chest may reveal the presence of enlarged glands in the neck or axillæ, and may thereby give us a clew to the nature of some intrathoracic disease; for example, the presence of enlarged glands in the neck, especially if there are any scars, sinuses, or other evidence that suppuration is going on or has formerly taken place in them, suggests the possibility of pulmonary tuberculosis or of an enlargement of the bronchial and mediastinal glands. Again, malignant disease of the chest is sometimes associated with the metastatic nodules over the clavicle, and a microscopic examination of them may thus reveal the nature of the intrathoracic disease to which they are secondary. Very large and matted masses of glands above the clavicle, which have never suppurated and have been painless and slow in their growth, suggest the presence of similar deposits in the mediastinum as a part of the symptom complex known as "Hodgkin's disease." The presence of a goitre or enlargement of the thyroid gland may account for a well-marked dyspnœa.

Syphilis produces general glandular enlargement; the posterior cervical and the epitrochlear glands are often involved, but this is also the case in many diseases other than syphilis.

CHAPTER II.

PALPATION AND THE STUDY OF THE PULSE.

I PALPATION.

THE most important points to be determined by palpation—that is, by laying the hand upon the surface of the chest—are:

- (1) The position and character of the *apex beat* of the heart.
- (2) The presence of a “*thrill*” (see below).
- (3) The vibrations of the spoken voice (“*tactile fremitus*”).
- (4) The presence of pleuritic or pericardial *friction*.

Other less important data furnished by palpation will be mentioned later.

(1) *The Apex Beat.*

(a) In feeling for the apex impulse of the heart, one should first lay the palm of the hand lightly upon the chest just below the left nipple. In this way we can appreciate a good deal about the movements of the heart, and confirm or modify what we have learned by inspection. One learns, in the first place, whether the heart beat is *regular* or not, and in case it is irregular, whether the beats are unequal in force or whether some are skipped; further, one gets a more accurate idea than can be obtained through inspection regarding the *character of the cardiac movements*. The powerful heaving impulse suggesting a hypertrophied heart, the diffuse slap often felt in dilatation of the right ventricle, the sudden tap characteristic of mitral stenosis, the deliberate thrust occasionally met with in aortic stenosis, may be thus appreciated.

(b) After this, it is best to lay the tips of two or three fingers over the point where the maximum impulse is to be seen, and follow it outward and downward until one arrives at the point farthest to the left and farthest down at which it is still possible to feel

any up-and-down movement. This point usually corresponds with the apex of the heart, as determined by percussion. *It does not correspond with the maximum cardiac impulse*, but is often to be found at least an inch farther to the left and downward (see above, Fig. 27).

Sometimes one can localize by palpation a cardiac impulse which is not visible; on the other hand, in some cases we can see pulsations that we cannot feel. Both methods must be used in every case.

The results obtained by palpation and inspection of the apex region give us the most reliable data that we have regarding the size of the heart. Percussion may be interfered with by the presence of gas in the stomach, of fluid or adhesions in the pleural cavity, or by the ineptness of the observer, but it is almost always possible with a little care to make out by a combination of palpation and inspection the position of the apex of the heart. When we can neither feel it nor see it, we may have to fall back upon auscultation, considering the apex of the heart to be at or near the point at which the heart sounds are heard loudest. When endeavoring to find the apex of the heart, we must not forget that the position of the patient influences considerably the relation of the heart to the chest walls. If the patient is leaning toward the left or lying on the left side, the apex will swing out several centimetres toward the left axilla.

(2) "*Thrills.*"

When feeling for the cardiac impulse with the palm of the hand, we are in a good position to notice the presence or absence of a very important physical sign to which we give the name of "*thrill.*" The feeling imparted to the fingers by the throat of a purring cat is very much like the palpable "*thrill*" over the precordia in certain diseases of the heart to be mentioned later. It is a vibration of the chest wall, usually confined to a small area in the region of the apex impulse, but sometimes felt in the second right intercostal space or elsewhere in the precordial region. This vibration or thrill almost always occurs intermittently, *i.e.*, only during

a portion of the cardiac cycle. When felt in the apex region, it usually occurs just before the cardiac impulse; this fact we express by calling it a "*presystolic thrill*"; but occasionally we may feel a *systolic* thrill at the apex—one, that is, which accompanies the cardiac impulse. The word *thrill* should be used to denote only a purring, vibrating sensation communicated to the fingers by the chest wall. It is incorrect to speak of a thrill as if it were something audible.

We must also distinguish a purring thrill from the slight shudder or jarring which often accompanies the cardiac impulse in functional neuroses of the heart or in conditions of mental excitement.

As a rule we can appreciate a thrill more easily if we lay the fingers very lightly upon the chest, using as little pressure as possible. Firm pressure may prevent the occurrence of the vibrations which we desire to investigate. Of the thrills felt over the base of the heart, more will be said in Chapter VII.

(3) *Vibrations Communicated to the Chest Wall by the Voice.*

"*Tactile fremitus*" is the name given to the sense of vibration communicated to the hand if the latter is laid upon the chest while the patient repeats some short phrase of words. The classical method of testing tactile fremitus is to ask the patient to count "one, two, three," or to repeat the words "ninety-nine" while the palm of the hand is laid flat upon the chest. The amount of fremitus to be obtained over a given part of the thorax varies, of course, according to the loudness of the words spoken, and is influenced also by the vowels contained in them. A certain uniformity is obtained by getting the patient to repeat always the same formula. Thus, he is likely to use the same amount of force each time he repeats them and to use approximately the same pitch of voice.

Other things being equal, the fremitus is greater in men than in women, in adults than in children, and is more marked in those whose voices are low pitched than in those whose voices are relatively shrill. The amount of fremitus also varies widely in different parts of the healthy chest. A glance at Fig 32 will help us to realize this. The parts shaded darkest communicate to the fingers

the most marked fremitus, while in the parts not shaded at all, little or no fremitus is felt. Intermediate degrees of vibration are represented by intermediate tints of shading. From this diagram we see at once (a) that the maximum of fremitus is to be obtained over the apex of the right lung in front, (b) that it is greater in the upper part of the chest than in the lower, and somewhat greater throughout the right chest than in corresponding parts of the left.

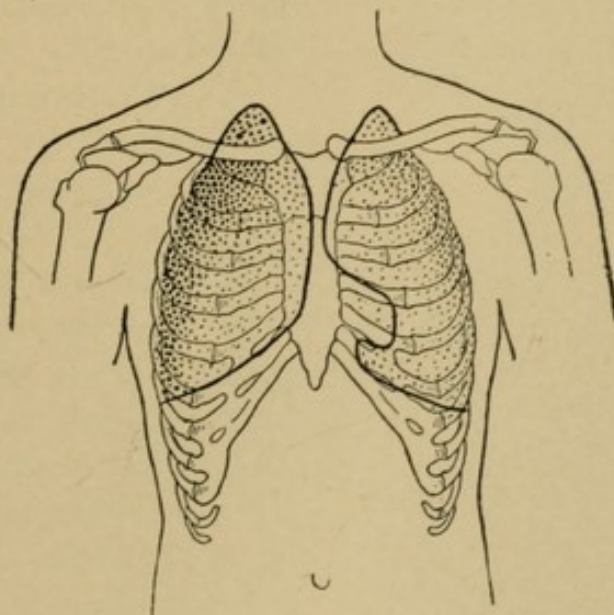


FIG. 32.—Distribution of Tactile Fremitus.

This natural inequality of the two sides of the chest cannot be too strongly emphasized.

Comparatively little fremitus is to be felt over the scapulæ behind, and still less in the precordial region in front. The outlines of the lungs can be quite accurately mapped out by means of the tactile fremitus in adults of low-pitched voice. In children, as has been already mentioned, fremitus is usually very slight and may be entirely absent, and in many women it is too slight to be of any considerable diagnostic value. Again, some very fat persons and those with thick chest walls transmit but little vibration to their chest walls when they speak. On the other hand, in emaciated patients or in those with thin-walled, flexible chests, the amount of fremitus is relatively great.

Bearing in mind all these disparities—disparities both between persons of different age and different sex, and between the two

sides of the chest in any one person—we are in a position to appreciate the modifications to which disease gives rise and which may be of great importance in diagnosis. These variations are:

(a) Diminution or absence of fremitus.

(b) Increase or absence of fremitus.

(a) If the lung is pushed away from the chest wall by the presence of air or fluid or tumor in the pleural cavity, we get a diminution or absence of tactile fremitus—diminution where the layer of fluid or air is very thin, absence where it is of considerable thickness.

(b) Solidification of the lung due to phthisis or pneumonia is the commonest cause of an *increase* in tactile fremitus. Further details as to the variations

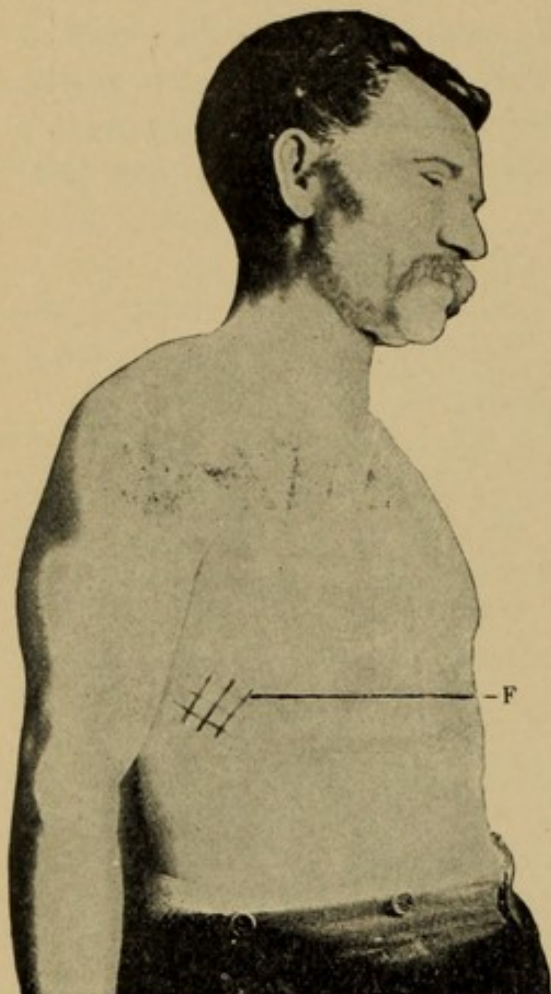


FIG. 33.—Showing Point (F) at Which Pleural Friction is Most Often Heard.

in amount of fremitus in different diseases may be found in later chapters of this book.

(4) *Friction, Pleural or Pericardial.*

In many cases of inflammatory roughening of the pleural surfaces ("dry pleurisy") a grating or rubbing of the two surfaces upon each other may be felt as well as heard during the movements of respiration, and especially at the end of inspiration. Such friction is most often felt at the bottom of the axilla, on one side or

the other, where the diaphragmatic pleura is in close apposition with the costal layer (see Fig. 33, p. 46).

Similarly, in roughening of the pericardial surfaces ("dry" or "plastic" pericarditis) it is occasionally possible to feel a grating or rubbing in the precordial region more or less synchronous with the heart's movements. Such friction is most often to be felt in the region of the fourth left costal cartilage (see Fig. 34).

Palpable friction is of great value in diagnosis because it is a sign about which we can feel no doubt; as such it frequently con-

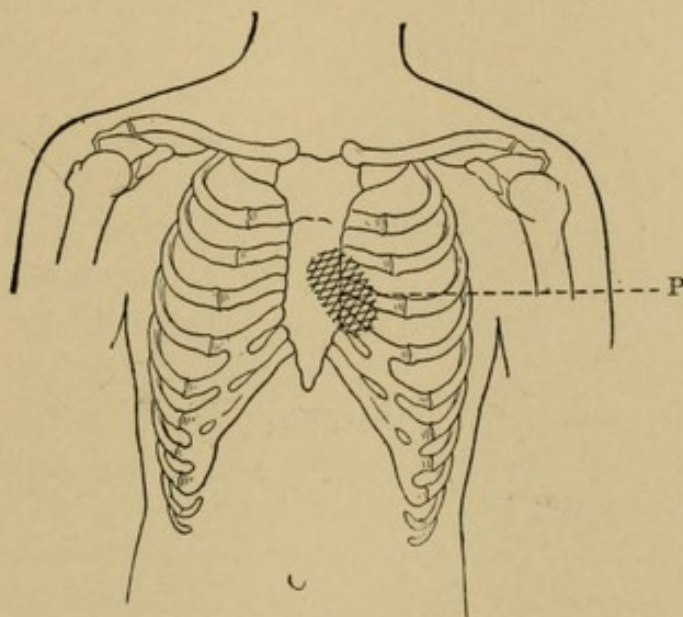


FIG. 34.—Showing Point (P) at Which Pericardial Friction is Most Often Heard.

firms our judgment in cases in which the auscultatory signs are less clear. Friction sounds heard with the stethoscope may be closely simulated by the rubbing of the stethoscope upon the skin, but palpable friction is simulated by nothing else, unless occasionally by

(5) *Palpable Râles.*

Occasionally coarse, dry râles communicate a sensation to the hand placed upon the chest in the region beneath which the râles are produced; to the practised hand this sensation is quite different from that produced by pleural friction, although the difference is hard to describe.

(6) Tender points upon the thorax.

In intercostal neuralgia, dry pleurisy, necrosis of a rib, and sometimes in phthisis, one finds areas of marked tenderness in different parts of the chest. The position of the tender points in intercostal neuralgia generally corresponds with the point of exit of the intercostal nerves. These points are shown in Fig. 35.

The tenderness in phthisis is most apt to be in the upper and front portions of the chest. In neurotic individuals we sometimes find a very superficial tenderness over parts of the thorax; in such

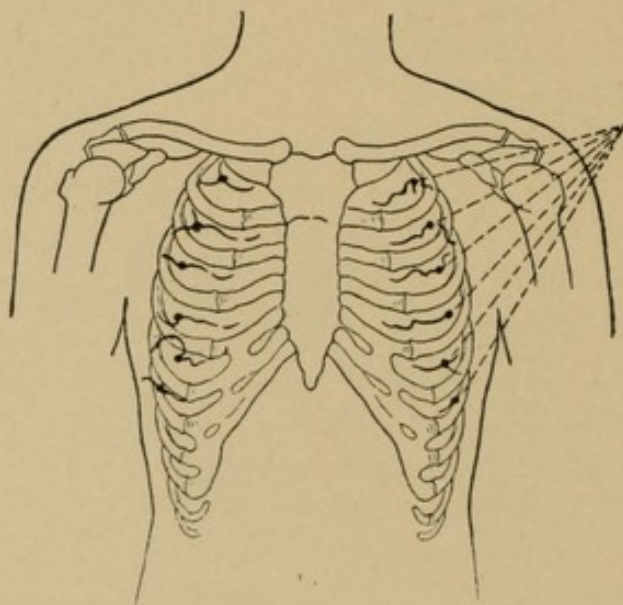


FIG. 35.—Showing Points of Exit of the Intercostal Nerves.

cases pain is produced by very light pressure, but not by firm pressure at the same point.

(7) The presence of pulsations in parts of the chest where normally there should be none is suggested by inspection and confirmed by palpation. It is not necessary to repeat what was said above as to the commonest causes of such abnormal pulsations. When searching for slight, deep-seated pulsation (*e.g.*, from an aortic aneurism), it is well to use bimanual palpation, keeping one hand on the front of the chest and the other over a corresponding area in the back.

(8) Fluctuation or elasticity in any tumor or projection from

the chest is a very important piece of information which palpation may give us.

(9) The temperature and quality of the skin are often brought to our attention during palpation. After a little practice one can usually judge the temperature within a degree or two simply from the feeling of the skin. Any roughness, dryness, or loss of elasticity of the skin (myxœdema, diabetes, long-standing pyrexia, or wasting disease) is easily appreciated as we pass the hand over the surface of the thorax or down the arms. The same manipulation often brings to our attention in cases of alcoholism an unusually smooth and satiny quality of the cutaneous surface.

II. THE PULSE.

Fifty years ago the study of the pulse furnished the physician with most of the available evidence regarding the condition of the heart. At present this is not the case. With the increase of our knowledge of the direct physical examination of the heart and of the various methods of measuring the systolic or diastolic pressure on the peripheral arteries, the amount of information furnished exclusively by the pulse has proportionately decreased, until to-day, I think, it is a fact that there is but little to be learned by studying the pulse which could not be as well or better ascertained by examining the heart and measuring the arterial pressure.

Nevertheless, the radial pulse is still an important factor in diagnosis, prognosis, and treatment, and will remain so, because it gives us quickly, succinctly, and in almost every case a great deal of valuable information which it would take more time and trouble to obtain in any other way. As we feel the pulse, we get at once a fact of central importance in the case; by the pulse the steps of our subsequent examination are guided. In emergencies or accidents the pulse gives us our bearings and tells us whether or not the patient's condition is one demanding immediate succor—*e.g.*, hypodermic stimulation—and whether the outlook is bright or dark. To gather this same information in any other way would involve losing valuable time.

Again, when one has to see a large number of patients in a

short time, as in visiting a hospital ward or on the crowded days of private practice, the pulse is an invaluable short cut to some of the most important data.

Moreover, there are some important inferences which the pulse and *only the pulse* enables us to make. They are not numerous, but their value may be great. Delay in one radial pulse when taken in connection with other signs may furnish decisive evidence of aneurism of the aortic arch; aortic stenosis is a lesion which cannot be diagnosed unless the pulse shows certain characteristic features; arterial degeneration may betray its presence chiefly in the peripheral arteries.

Since, then, the condition of the pulse furnishes information of crucial importance in a few diseases, and is a quick, reliable, and convenient indication of the general condition of the circulation in all cases, it is essential that we should study it most carefully both in health and in disease.

How to Feel the Pulse.

(a) We usually feel for the pulse in the radial artery because this is the most superficial vessel which is readily available. Occasionally, as when the wrists are swathed in surgical dressings or tied up in a straight-jacket, we make use of the temporal, facial, or carotid arteries.

(b) Both radials should always be felt at the same time. By making this a routine practice many mistakes are avoided and any difference in the two pulses is appreciated.

(c) The tips of three fingers (never the thumb) should be laid upon the artery, and the following points noted:

1. The *rate* of the pulse.
2. The *rhythm* of the pulse (regular or irregular).
3. The amount of force necessary to obliterate it (*compressibility*).
4. The *size and shape of the pulse wave*.
5. The extent to which the artery collapses between beats (*tension*).
6. The *size and position of the artery*.

7. The condition of the *artery walls*.

Each of these points will now be considered in detail.

1. *The Rate of the Pulse.*

In the adult male the pulse averages 72 to the minute, in the female 80. In children it is considerably more frequent. At birth it averages about 130, and until the third year it is usually above 100. In some families as low pulse, 60 or less, is hereditary; on the other hand, it is not very rare to observe a permanent pulse rate of 100 or more in a normal adult (see below, p. 207). Exercise or emotion quickens the pulse very markedly, and after food it is somewhat accelerated. Some account of the causes of pathological quickening or slowing of the pulse will be found on pages 207 and 208.

2. *Rhythm.*

The pulse may be irregular in *force*, in *rhythm*, or (as most commonly happens) in both respects. As a rule, irregularities in force are the more serious. Intermittence or irregularity in rhythm *alone*, means that the heart skips one or more beats at regular or irregular intervals. This may be a mere idiosyncrasy not associated with any evidence of disease. I have known several instances in which a perfectly sound person has been aware of such an irregularity throughout life—the heart dropping regularly every third or fourth beat. Such rhythmical intermittence in health is not uncommon.

When beats are dropped, not at fixed intervals, but *irregularly*, the pulse waves usually vary in *force* as well. This combination of irregular cardiac rhythm with variations in the strength of the individual beats is very rarely seen in health and usually points to functional or structural disease of the heart.

Special types of irregularity will be discussed later.

In general it may be said (*a*) that irregularity in the force of the pulse beats is a serious sign, if overexertion and temporary toxic influences (tobacco, tea, etc.) can be ruled out; (*b*) that it is far more serious when occurring in connection with diseases of the

aortic valve than in mitral disease; and (c) that it often occurs in connection with sclerosis of the coronary arteries and myocarditis.

3. *Compressibility, or Systolic Arterial Pressure.*

There is no single datum concerning the pulse more important than the amount of force needed to obliterate its beat. Until recently we have had no more accurate method of measuring the systolic blood pressure than the following: Let the tips of three fingers rest as usual on the radial artery. Then gradually increase the pressure made upon the vessel with the finger nearest the patient's heart until the pulse wave is arrested and cannot be felt by the other fingers which rest loosely on the artery. The degree of force necessary to arrest the wave varies a great deal in different cases and at different times of day, but by trying the above manoeuvre day after day in as many cases as possible, and especially by comparing one's impressions with accurate measurements of blood pressure (*vide infra*), one comes to possess a fairly accurate mental standard or picture of the compressibility of the average pulse, and is then able to estimate in any given case whether it is more or less compressible than usual.

The compressibility of the pulse is a rough measure of the muscular power of the heart's beat, and therefore gives us direct information about this important element in the patient's condition.

4. *The Size and Shape of the Pulse Wave.*

Of the use of the sphygmograph for representing pulse waves I shall speak later. The points discussed in this section are appreciable to the fingers.

I. The size of the pulse wave—the height to which it lifts the finger—depends on two factors:

(a) The force of the cardiac contractions (systolic arterial pressure).

(b) The tightness or looseness of the artery (*tension*, or diastolic pressure).

If the arteries are contracted and small, the pulse wave corre-

sponds, while if they are large and relaxed, it needs only a moderate degree of power in the heart to produce a high pulse wave. If the tension remains constant the size of the pulse wave depends on the force of the heart's contraction. If the heart power remains constant, the size of the pulse wave depends on the degree of vascular tension. Vascular tension is estimated in ways to be described presently, and after allowing for it, we are enabled to estimate the power of the heart's contractions from the height of the pulse wave.

II. The *shape of the pulse wave* is also of importance.

(a) It may have a very sharp summit, rising and falling back again suddenly; this is known as an *ill-sustained* pulse, and may be due to a lack of sustained propulsive power in the contracting heart muscle, to low vascular tension, or to a combination of the two causes. A weak heart with low arterial tension often produces such a pulse wave—deceptively high and giving at first an impression of power in the heart wall, but ill sustained and easily compressible. This is the “bounding pulse” of early infectious processes. An exaggeration of this type of pulse is to be felt in aortic regurgitation (see Fig. 102).

(b) In sharp contrast with the above is the pulse wave which lifts the finger gradually and slowly, sustains it for a relatively long period, and then sinks gradually down again. Such a pulse with a “long plateau” instead of a sharp peak is to be felt most distinctly in aortic stenosis, less often in mitral stenosis and other conditions (see Fig. 107).

(c) The *dicrotic* pulse wave is one in which the secondary wave, which the sphygmograph shows to be present in the normal pulse, is much exaggerated, so that a distinct “echo” of the primary wave is felt after each beat. If the heart is acting rapidly, this dicrotic wave does not have time to fall before it is interrupted by the primary wave of the next beat, and so appears in the sphygmographic tracing as a part of the up-stroke of the primary wave. This is known as the “*anacrotic* pulse.”

(d) The shape of the *high-tension pulse wave* will be described in the next paragraph.

5. *Tension, or Diastolic Arterial Pressure.*

The degree of contraction of the vascular muscles determines the size of the artery and (to a great extent) the tension of the blood within it. But if the heart is acting feebly, there may be so little blood in the arteries that even when tightly contracted they do not subject the blood within them to any considerable degree of tension. To produce high tension, then, we need two factors: a

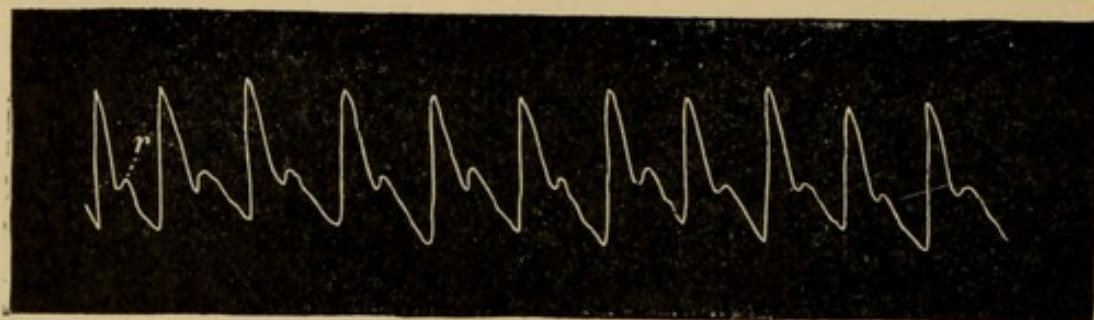


FIG. 36.—Sphygmographic Tracing of Low Tension Pulse.

certain degree of power in the heart muscle, and contracted arteries. To produce low tension we need only relaxation of the arteries, and the heart may be either strong or weak.

The pulse of low tension collapses between beats, so that the artery is less palpable than usual or cannot be felt at all. Normally,



FIG. 37.—Sphygmographic Tracing of High Tension Pulse.

the artery can just be made out between beats, and any considerable lowering of arterial tension makes it altogether impalpable except during the period of the primary wave and of the dicrotic wave, which is often very well marked in pulses of low tension. The shape of the wave under these conditions has already been described (see Fig. 36).

The pulse of high tension is perceptible between beats as a *distinct cord which can be rolled between the fingers*, like one of the tendons of the wrist. It is also difficult to compress in most cases, but this may depend rather on the heart's power than on the degree of vascular tension. A high-tension pulse is often indistinguishable from one stiffened by arteriosclerosis (*vide infra*). The pulse wave is usually of moderate height or low, and falls away slowly with little or no dicrotic wave (see Fig. 37).

6. The Size and Position of the Artery.

I have often known errors to occur because a small *artery* is mistaken for a small *pulse wave*. The size of the branches of the arterial tree varies a great deal in different individuals of the same weight and height, and if the radial is unusually small and a hurried observation gives us the impression (true, so far as it goes) that there is very little in the way of a pulse to be felt, we are apt to conclude (wrongly, perhaps) that the heart's work is not being properly performed. The effort to obliterate such a pulse, however, *may* set us right by showing that despite the small size of the vessel (and consequently of the pulse wave) it takes as much force as it normally does to obliterate it. But in many cases we can determine the question satisfactorily often by using some instrument for measuring arterial pressure. Thus, a *small pulse wave* (in a congenitally small artery) may be distinguished from a *weak pulse*. From the *contracted* artery of high vascular tension we distinguish the *congenitally small* artery because the latter is not to be rolled beneath the fingers, and is not more than normally palpable between the pulse beats.

Not infrequently the nurse reports in alarm that the patient has no pulse, when in reality the pulse is excellent but the artery misplaced so as to be impalpable in the ordinary situation. It may be simply more deeply set than normal, so that the fingers cannot get at it, or it may run superficially over the end of the radius toward the "anatomical snuff box." Other anomalies are less common. As a rule, the other radial artery is normally placed and can be used

as a standard, but occasionally both radials are anomalous and we may be compelled to use the temporal or facial instead.

7. *The Condition of the Artery Walls.*

Arterio-sclerosis is manifested in the peripheral arteries in the following forms:

- (a) Simple *stiffening* of the arteries without calcification.
- (b) *Tortuosity* of the arteries.
- (c) *Calcification*.

Simple stiffening without calcification is due to fibrous thickening of the intima and produces a condition of the arteries not always to be distinguished from high tension. The artery can be rolled under the fingers, stands out visibly between the heart's beats, but is not incompressible, has a smooth surface, and is not always tortuous. If it is tortuous as well as stiff, we may conclude that there is endarteritis at any rate, whether or not there is increased tension as well. In the vast majority of cases the two conditions are associated and do not need to be distinguished.

The normal radial artery is straight; hence any deviation is evidence of changes in its walls and is easily recognized as we run our fingers up and down the vessel.

Calcification of the radial produces usually a *beading* of its surface. As we move the fingers along the artery, quickly and with very slight pressure, a series of transverse ridges or beads can be felt. The qualities of the pulse wave within can usually be appreciated fairly well, in this type of artery, but in very advanced cases the calcification is diffuse and converts the radial into a rigid "pipe stem"—absolutely incompressible—unless we break the calcified coat—and easily mistaken for a tendon. In such an artery no pulse can be felt.

Such are the points to be observed in feeling the pulse. To enumerate the characteristics of the pulse in the many diseases in which it affords us valuable information is beyond the scope of this book. The qualities to be expected in the pulse in connection with the different diseases of the heart are described in the sections on

those diseases. Here it will suffice to enumerate some of the conditions in which vascular tension is usually increased or diminished.

Low tension is produced by moderate exercise, by warmth (*e.g.*, a warm bath), by food. Among pathological conditions we may mention especially debilitated states, mental worry, and fever.

High tension is produced by cold (*e.g.*, cold bathing, malarial chills), and by constipation (in some cases). As a rule, the tension of the pulse increases with age and is high after the fiftieth year. Hysteria and migraine are often associated with increased vascular tension. Most frequent among pathological conditions as causes of high tension are *chronic nephritis* and *arterio-sclerosis* with the various diseases in which arterio-sclerosis is a factor (gout, alcoholism, lead poisoning, diabetes of fat old people, chronic bronchitis with emphysema).

Among valvular heart lesions, aortic and mitral stenosis are especially apt to be associated with increased vascular tension.

ARTERIAL PRESSURE AND THE INSTRUMENTS FOR MEASURING IT.

Within the past few years a number of instruments have come into use, the object of which is to tell us with some approach to accuracy the lateral pressure in the peripheral arteries. We have long attempted to estimate this pressure, by simple digital compression and palpation, and no doubt these methods in the hands of skilled observers will always have a field of usefulness; but it seems to me clear that by the instruments about to be described we can obtain data in regard to the force of the heart's contractions and the tension of the peripheral arteries more accurate and more reliable than those furnished by digital examination. This is especially true of comparative records, as, for example, if one attempts to compare the tension of the pulse to-day with what it was yesterday, when one has felt many pulses in the interim. Another objection to estimates of pulse pressure based on digital examination results from the fact that the size of the artery itself is apt to be a confusing factor.

Among the many instruments introduced within the past few years we may distinguish (1) those which aim to estimate the

amount of compression which has to be exerted upon a given artery in order to arrest the onward flow of blood in it, and (2) those which seek to estimate the amount of pressure in a given artery at the moment when its wall makes the widest excursion or oscillation.

Instruments of the first type are said to measure *systolic pressure*, and those of the second type to measure *diastolic pressure*. Under the first heading I shall describe the Riva-Rocci and Gaertner instruments. Under the second that of Oliver and that of Hill and Barnard.

1. *Gaertner's Tonometer*.—The end of a finger is made bloodless by rolling up over it a tight rubber ring. Over the blanched finger tip one next applies a pneumatic ring, which can be inflated by means of a rubber bulb, while the tension within is measured by a manometer connected with it. The manometer may be either of the mercury or the spring type. To use the instrument we inflate the pneumatic ring until the pressure recorded in the manometer is considerably above what we expect in the case dealt with. (The tip of the finger all this time remains blanched.) Next we relax the tension within the pneumatic ring, by gradually releasing the pressure exerted upon the inflation bulb, until the red color reappears in the finger tip. Just as the color reappears we note the pressure in the manometer. This figure was supposed by Gaertner to represent the average or mean pressure in the arteries, but it has been very generally conceded by other observers that the figures given by this instrument are much nearer to those of *systolic pressure*, that is, to the pressure during the systole of the left ventricle or to the crest of the pulse wave.

The advantages of the Gaertner instrument are its compactness and portability. Its disadvantages are that (in this climate at any rate) it is very apt to get out of order, that it is not suited to estimating pressures in any of the dark-skinned races, and that its readings are very much affected by vasomotor influences, such as nervousness or cold. If the fingers are cold it may be almost impossible to make a satisfactory record with the instrument. Further, the spring manometer, like all instruments of this type, is very apt

to get out of order, and if the mercury manometer is employed the instrument loses its only advantage, namely, its compactness.

2. *The Riva-Rocci Instrument.*—This instrument consists essentially of an inflatable rubber armlet, so arranged that it can be fitted closely around the upper arm, a mercury manometer of the ordinary type, and an air-pump (see Fig. 38). The air forced from the

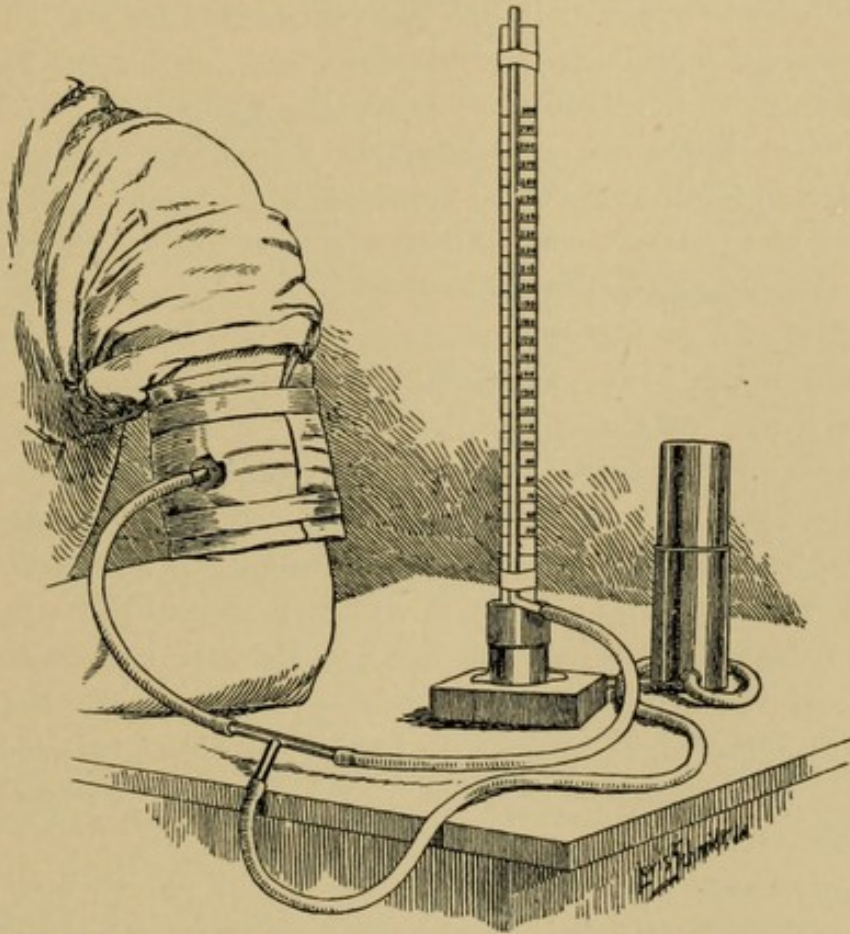


FIG. 38.—Stanton's Modification of the Riva-Rocci Instrument. (By permission from the University of Pennsylvania Medical Bulletin.)

pump is distributed into the rubber armlet and into the manometer at the same time, and experiments have shown that the actual pressure in the armlet is practically identical at any given time with that in the manometer. To use the instrument we pump in air until the radial pulse stops, and at that instant note the height of the mercury column. The reading thus obtained is

taken to represent the systolic or maximum pressure in the brachial artery.

It is true that the air within the rubber armlet has to overcome not only the pressure within the radial artery, but the resistance of the artery wall and the elasticity of the soft parts around it. The former factor has been shown to represent a pressure of not more than 2 or 3 mm. Hg, provided the artery walls are normal. If arterio-sclerosis is present, it has been estimated by von Basch that they may oppose a resistance equivalent to 5 or 6 mm. Hg. The amount of error thus introduced, however, appears to be of no importance, since there are physiological variations of 5 mm. Hg or more, occurring from moment to moment, and dependent on changes in the force of the heart beat and on the respiratory oscillations of pressure.

The resistance of the soft parts around the artery is a factor of considerable importance, provided the compressing armlet is as narrow as many of those supplied with Riva-Rocci instruments. But if an armlet of about three and one-quarter inches width is used, according to the recommendation of von Recklinghausen and Stanton, we find that the pressure is practically the same in a given individual whether the armlet is applied round the upper arm, round the forearm, or round the thigh. Now if the resistance of the tissues of the thigh exerts no greater influence than that of the upper arm or forearm, it seems safe to conclude that this factor may be neglected as a source of error in comparative measurements with arms of different sizes.

The instrument is a very simple and quick one to use, needing very little practice and not more than a minute or a minute and a half for a single reading. The chief objection to it is its bulk and fragility.

3. *The Instrument of Hill and Barnard.*—In essentials this instrument is like the Riva-Rocci, except that all the connecting tubes are rigid, and that in place of the mercury manometer a very delicate aneroid instrument is employed to record the pressures within the armlet (see Fig. 39). The delicacy of this form of manometer is so great that with rigid connections it is possible to register the

oscillations of the artery wall and to estimate the amount of pressure within the armlet at the time when the arterial oscillations are widest; in other words, when the arteries are slackest. The work of Howell and Brush has demonstrated to my satisfaction that the pressure at the time of the maximum oscillation corresponds to the minimum or diastolic pressure within the arteries.

The Hill and Barnard instrument, when in good order, seems to

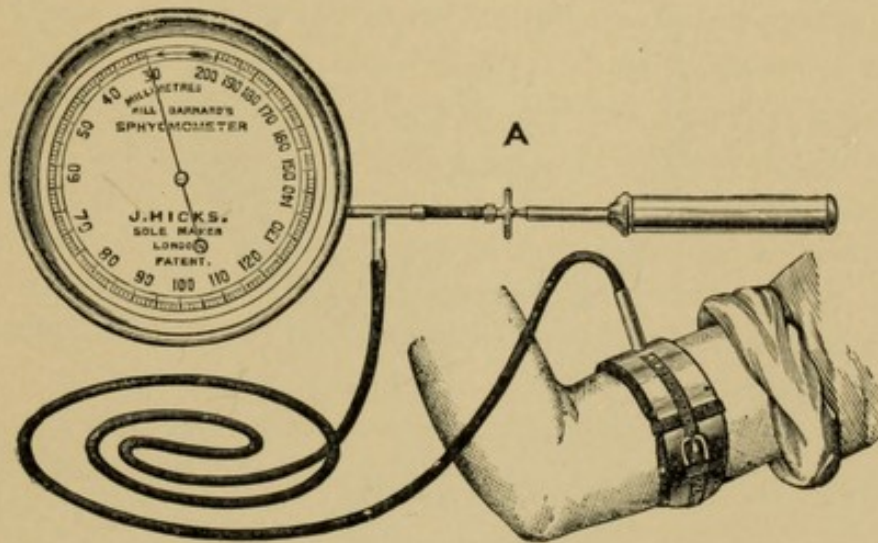


FIG. 39.—Hill & Barnard's Sphygmometer.

me on the whole the best among those that are clinically available for measuring diastolic pressure. The difficulty of reading it is less than with most other instruments designed for this purpose, and the only serious drawback to the instrument is the likelihood that the manometer will get out of order, a difficulty to which all instruments of this type are very prone.

4. *The Oliver Instrument.*—This instrument is intended, like the last, for estimating the pressure in the arteries during the period of maximum oscillation. This, as I have said, corresponds in my opinion to the diastolic and not to the average or mean pressure. A small rubber capsule filled with water is placed upon the radial artery, and through this the pulsations of the artery, under different pressures, are transmitted directly by a straight rod to a spring

manometer, where the oscillations and pressures are recorded in mm. Hg (see Fig. 40). The instrument is a very compact and simple one, and if it were not constantly getting out of order, would be, I think, of considerable value, although it is a difficult instru-

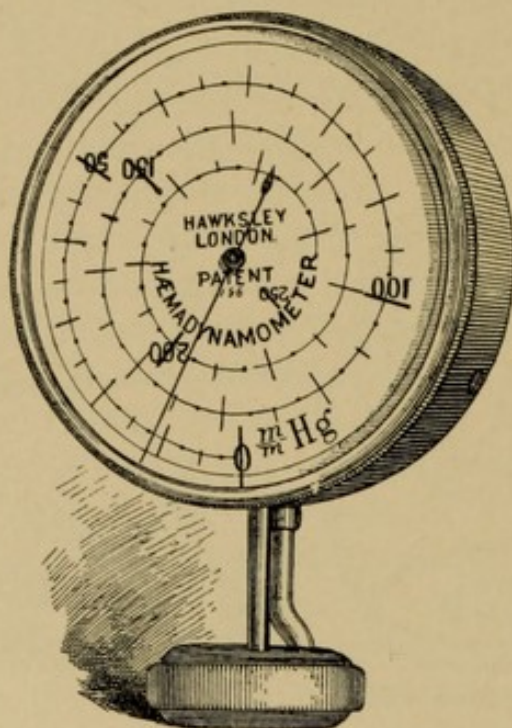


FIG. 40.—Oliver's Hæmodynamometer.

ment to use. Its readings, however, soon become inaccurate and cease to correspond with the mercury column.

Stanton (*University of Penn. Med. Bull.*, February, 1903) has succeeded in fitting a Riva-Rocci instrument with rigid connecting tubes, so that with this single instrument he can record both maximum and minimum pressures. The maximum or systolic pressure he records in the ordinary way. To get the minimum or diastolic pressure he clamps off the tube leading to the inflation bulb, and then lets out the air little by little until the mercury begins to oscillate in the tube. The oscillations increase in extent up to a maximum as the air is steadily let out, and then decrease again until they are lost. The reading for diastolic pressure is taken when the mercury shows the greatest extent of oscillation in the tube.

The Use of the Data Obtained by these Instruments.

The subject is still in its infancy, but in a general way one may say that whenever it is important that we should know the strength of the heart beat or the tension of the peripheral arteries, these instruments are of value. Just which instrument is likely to come into permanent use I cannot venture to prophesy, but it seems to me likely that the charts of pulse rate will be supplemented before long by charts of blood pressure taken at regular intervals as a matter of routine. Especially the investigation of diseases of the heart and kidney, diseases in which involvement of the suprarenal gland is suspected, intracranial hemorrhage or tumor and surgical shock, accurate record of blood pressure will be of value. Even the imperfect instruments now in use are capable of yielding us most important information, if applied in comparative measurements upon the same patient at different times, so that all the elements of error are constant. Thus in the study of drugs like alcohol, digitalis, strychnine, ether, chloroform, nitroglycerin, and others which are supposed either to raise or to lower blood pressure, these instruments have, I think, a great field before them.

CHAPTER III.

PERCUSSION.

I. TECHNIQUE.

THERE is no other method of physical examination which needs so much practice as percussion, and none that is so seldom thoroughly learned. Many physicians never succeed in acquiring a facility in the use of it sufficient to make them rely upon their results. Undoubtedly one of the greatest difficulties arises from the necessity of being at once active and passive—at once the percussor and the one who listens to the percussion. Students half unconsciously get to treat the percussion as an end in itself, and hammer away industriously without realizing that two-thirds of the attention must be given to listening, while the percussion itself should become semi-automatic.

It is undoubtedly an advantage to possess a musical ear, but this is by no means a necessity. Some of the most accurate percussors that I know possess absolutely no musical ear—no ear, that is, for pitch—and form their judgments in percussing upon the quality or intensity of the note, and upon the sense of resistance.

In this country practically all percussion is done with the fingers; in Germany instruments are still used to a considerable extent.

(a) *Mediate and Immediate Percussion.*

Percussion may be either “mediate” or “immediate,” the latter term referring to blows struck directly upon the chest with the flat of the hand, or upon the clavicles with the tip of the second finger.

(b) Methods.

Mediate percussion (which is used ninety-nine hundredths of the time) is performed as follows:

The patient should either lie down or sit with his back against some support. The reason of this is that for good percussion one

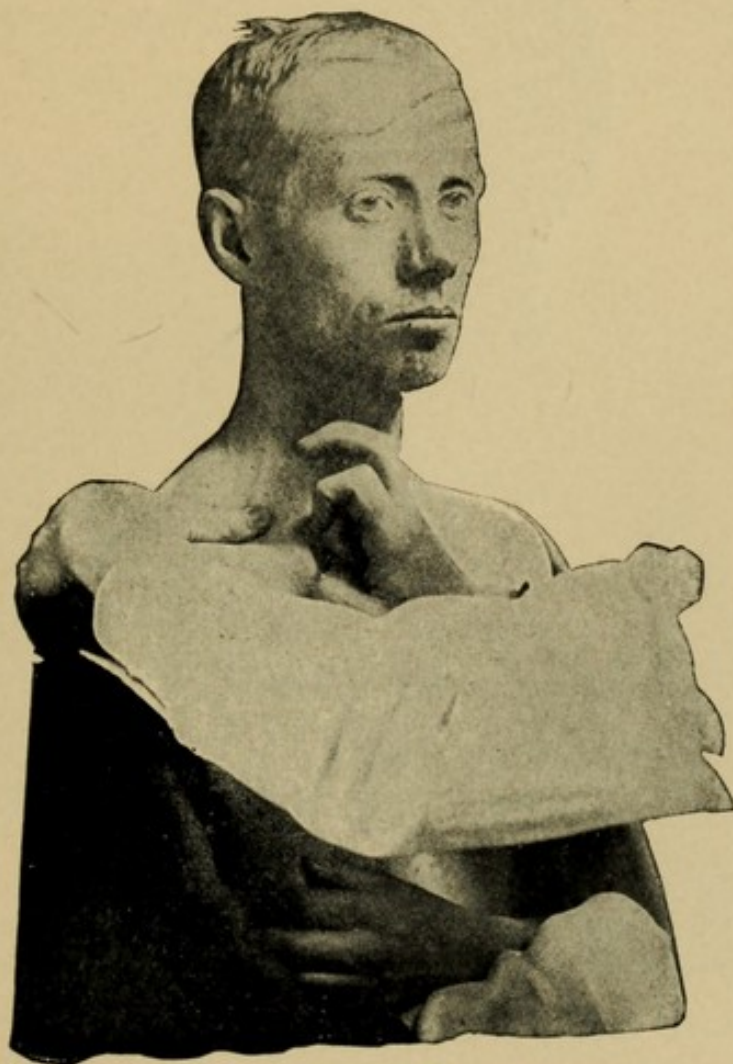

FIG. 41.—Position of the Hands When Percussing the Right Apex.

needs to press very firmly with the middle finger of the left hand upon the surface of the chest, so firmly that if the patient is sitting upon a stool without support for his back, it will need considerable exertion upon his part to avoid losing his balance.

In percussing the front of the chest it is important to have the patient sitting or lying *in a symmetrical position*—that is, without any twist or tilting to one side. His head should point straight forward and *his muscles must be thoroughly relaxed*. Many patients, when stripped for examination, swell out their chests and

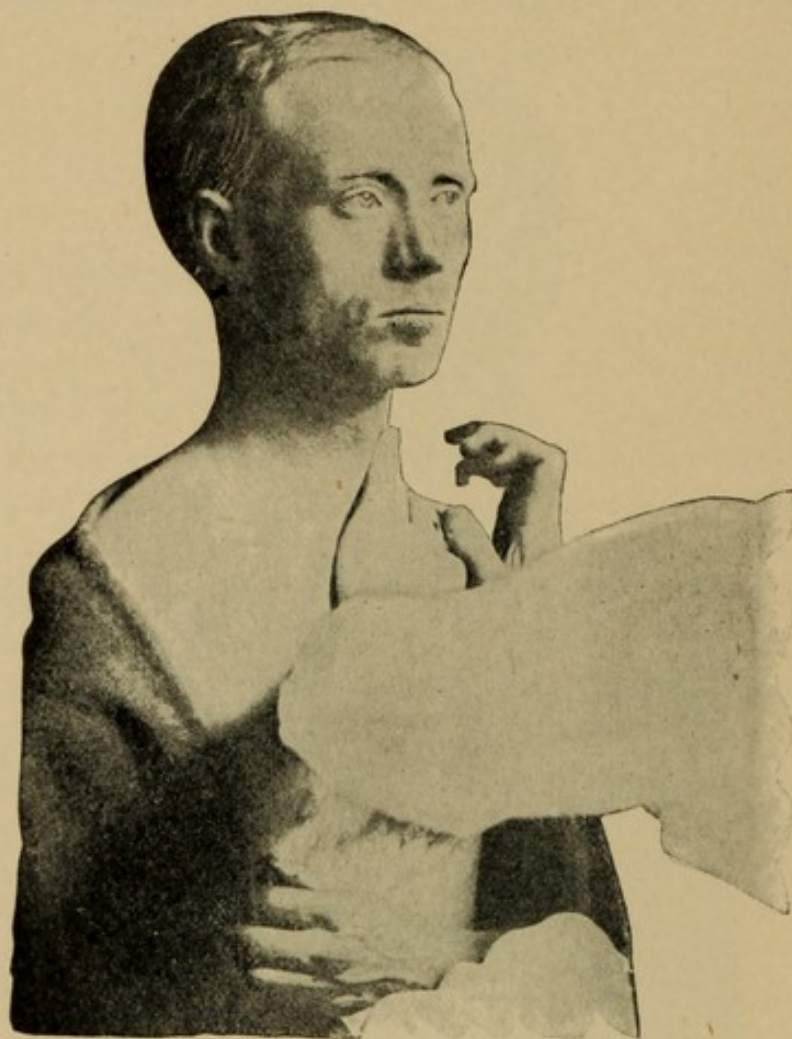


FIG. 42.—Position of the Hands When Percussing the Left Apex.

sit up with a military erectness. The muscular tension thus produced modifies the percussion note and causes an embarrassing multitude of muscle sounds which greatly disturb auscultation.

Having placed the patient in an easy and symmetrical position, our percussion should proceed according to the following rules:

- (1) Always press as firmly as possible upon the surface of the

chest with the second finger of the left hand¹ on the dorsum of which the blow is to be struck. Raise the other fingers of the left hand from the chest so as not to interfere with its vibrations.

(2) Strike a quick, perpendicular, rebounding blow with the tip of the second finger² of the right hand upon the second finger of the left just behind the nail, imitating as far as possible with the right hand the action of a piano-hammer. The quicker the percussing




FIG. 43.—The Right Way to Percuss—*i. e.*, From the Wrist.

finger gets away again after striking, the clearer will be the note obtained.

(3) Let all the blows struck in any one part of the chest be uniform in force.

¹ Left-handed percussors will, of course, keep the right hand upon the chest and strike with the left.

² When percussing the right apex I prefer to strike upon the thumb (see Figs. 41 and 42) as it is almost impossible when standing directly in front of the patient to fit any of the fingers comfortably into the right supraclavicular fossa.

(4) Strike from the wrist and not from the elbow (see Figs. 43 and 44). The wrist must be held perfectly loose.

(5) Keep the percussing finger bent at a right angle as in Fig. 45.

The force to be used in percussion depends upon the purpose

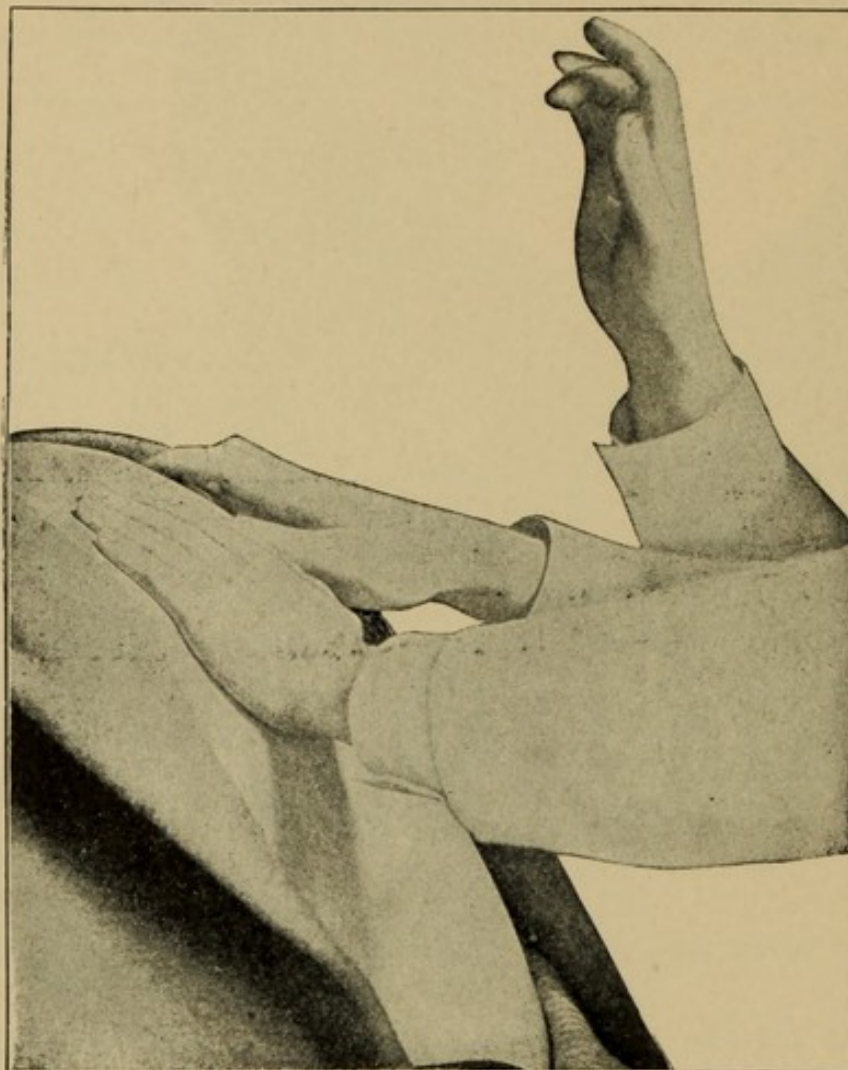


FIG. 44.—The Wrong Way to Percuss—*i. e.*, From the Elbow.

for which the percussion is used—that is, upon what organ we are percussing—and also upon the thickness of the muscles covering that part of the chest. For example, it is necessary to percuss very strongly when examining the back of a muscular man, where an inch or two of muscle intervenes between the finger on which

we strike and the lung from which we desire to elicit a sound. Over the front of the chest and in the axillæ the muscular covering is much thinner, and hence a lighter blow suffices. In children or emaciated patients, or in any case in which the muscular development is slight, percussion should be as light as is sufficient to elicit a clear sound. Heavy percussion is sometimes necessary but always unsatisfactory, in that the sound which it elicits comes from a relatively large area of the chest and does not therefore give us infor-

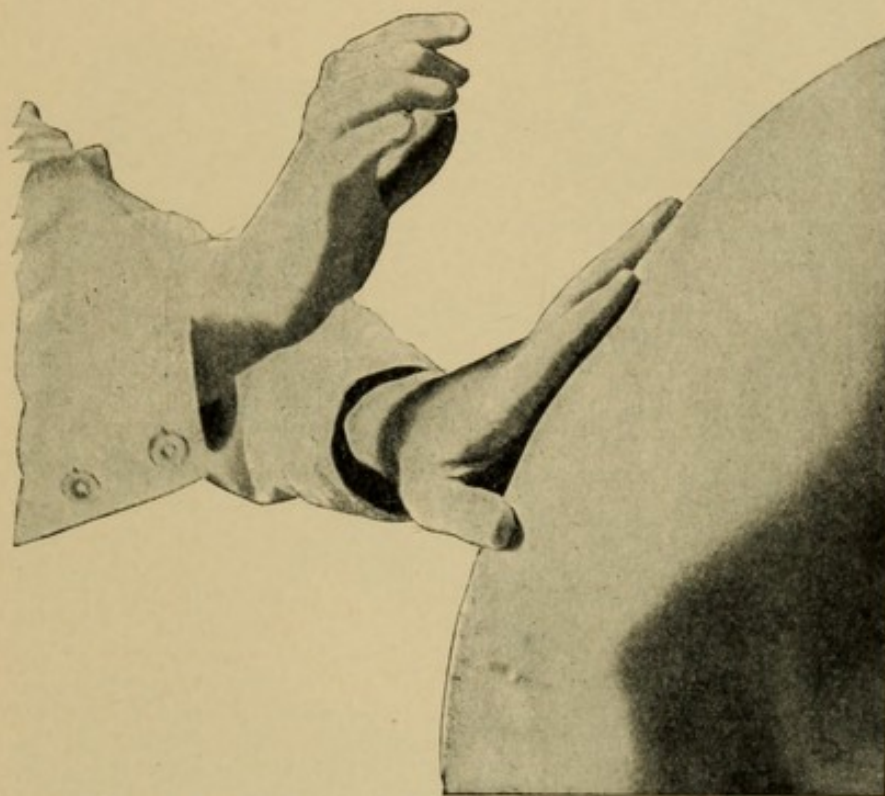


FIG. 45.—Proper Position of the Right Hand During Percussion.

mation about the condition of any sharply localized area. If a carpenter, in tapping the wall to find the position of the studs, strikes too hard, he will fail to find the beam, because the blow delivered over the spot behind which the beam is situated is so forcible as to bring out the resonance of the hollow parts around. It is the same with medical percussion. Heavy percussion is always inaccurate.¹ It may be necessary where the muscles are very thick, but its value

¹ See also below, page 82, the lung reflex.

is then proportionately diminished. On the other hand, it is possible to strike so lightly that no recognizable sound is elicited at all. The best percussion, therefore, is that which is just forcible enough to elicit a clear sound without setting a large area of chest wall in vibration.

The position of the patient above described applies to percussion of the front. When we desire to percuss the back, it is im-

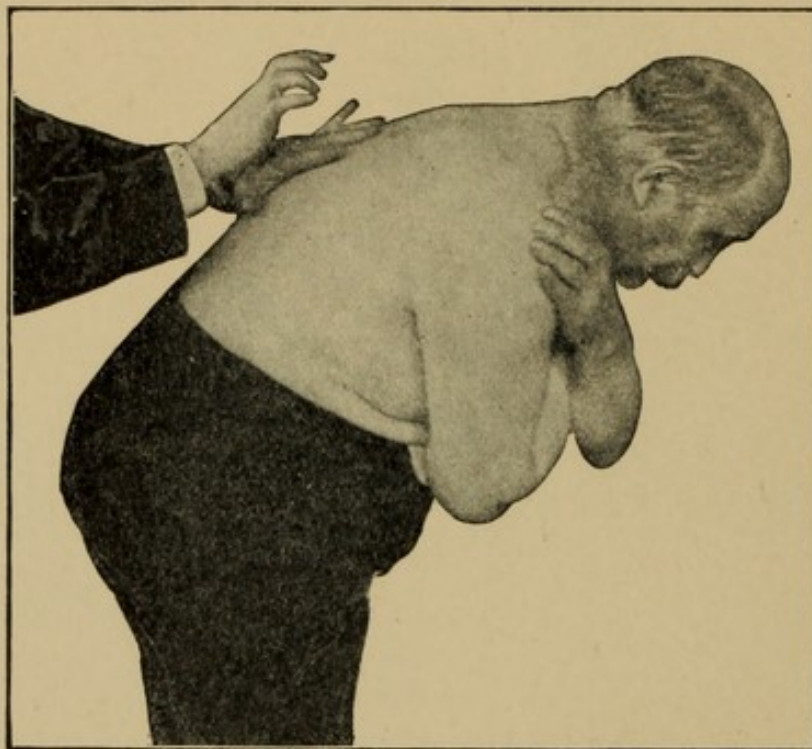


FIG. 46.—Proper Position of the Patient During Percussion of the Back.

portant to get the scapulæ out of the way as far as possible, since we cannot get an accurate idea of sounds transmitted through them. To accomplish this, we put the patient in the position shown in Fig. 46, the arms crossed upon the chest and each hand upon the opposite shoulder. The patient should be made to bend forward; otherwise the left hand of the percussor will be uncomfortably bent backward and his attention thereby distracted (see Fig. 47).

When the axillæ are to be percussed, the patient should put the hands upon the top of the head.

(b) Auscultatory Percussion.

If while percussing one auscults at the same time, letting the chest piece of the stethoscope rest upon the chest, or getting the patient or an assistant to hold it there, the sounds produced by percussion are greatly intensified, and changes in their volume, pitch, or quality are very readily appreciated. The blows must be

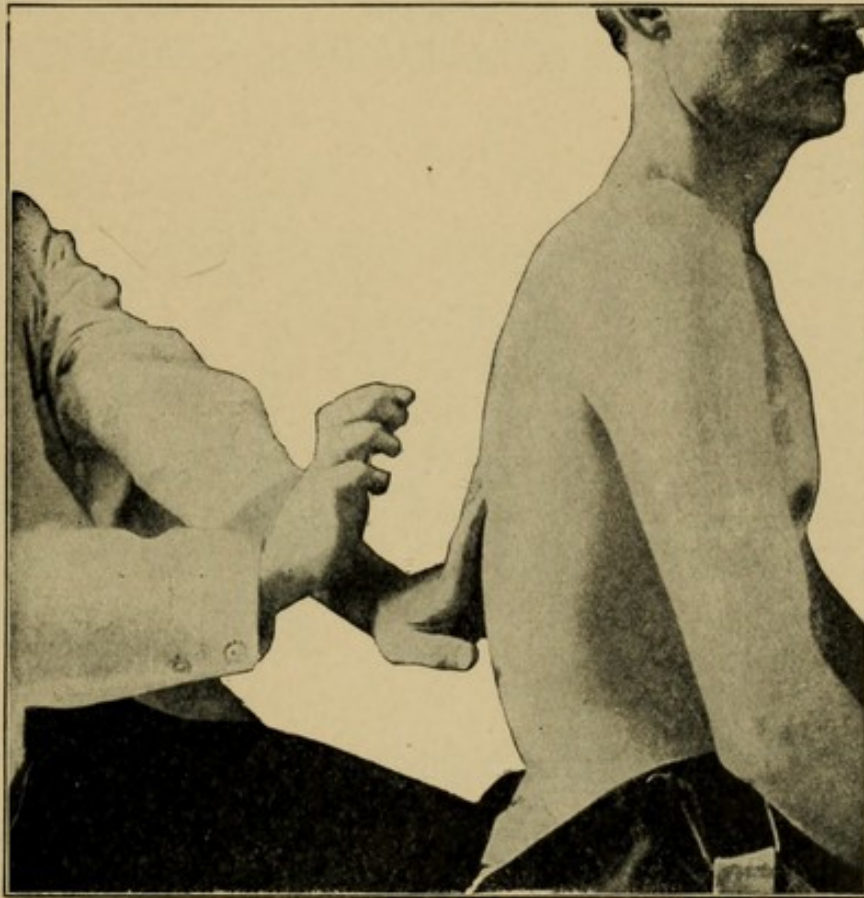


FIG. 47. —Wrong Position for Percussing the Back. The patient should be bent forward.

very lightly struck, either upon the chest itself or upon the finger used as a pleximeter in the ordinary way. Some observers use a short stroking or scratching touch upon the chest itself without employing any pleximeter.

This method is used especially in attempting to map out the borders of the heart and in marking the outlines of the stomach. In the hands of skilled observers it often yields valuable results,

but one source of error must be especially guarded against. *The line along which we percuss, when approaching an organ whose borders we desire to mark out, must neither approach the chest piece of the stethoscope nor recede from it.* In other words, the line along which we percuss must always describe a segment of a circle whose centre is the chest piece of the stethoscope (see Fig. 48). If we percuss, as we ordinarily do, in straight lines toward or away from the border of an organ, our results are wholly unreliable since every straight line must bring the point percussed either closer to

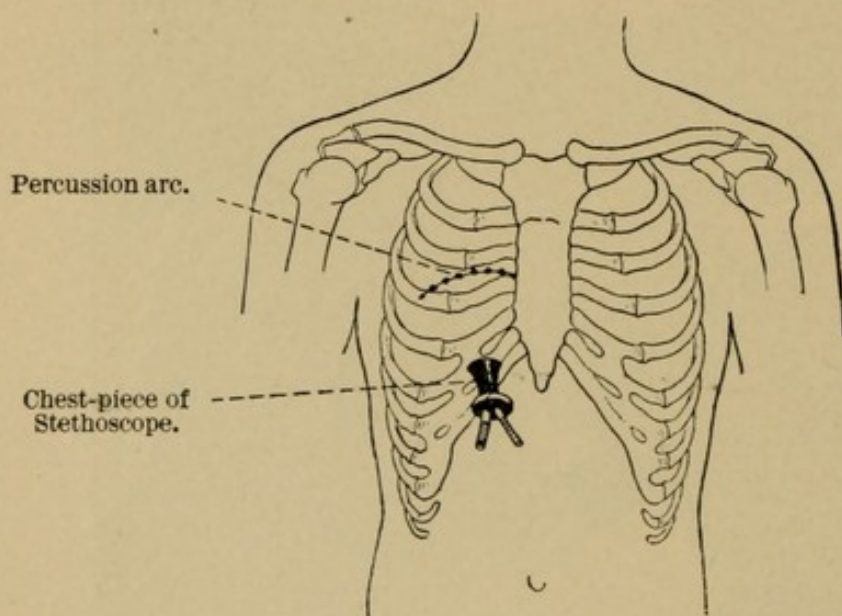


FIG. 48.—Auscultatory Percussion, Showing the Arc along which such Percussion should be made.

the stethoscope or farther from it, and the intensity and quality of the sounds conducted through the instrument to our ears vary directly with its distance from the point percussed.

It will be readily seen that the usefulness of auscultatory percussion is limited by this source of error, and that considerable practice is necessary before one can get the best results from this method. Nevertheless it has, I believe, a place, though not a very important one, among serviceable methods of physical examination.

(c) Palpatory Percussion.

Some German observers use a method of percussion in which attention is fixed directly or primarily on the amount of resistance offered by the tissues over which percussion is made. Even in ordinary percussion the amount of resistance is always noted by experienced percussors, but the element in sound is usually the main object of attention. Palpatory percussion is rather a series of short *pushes* against various points on the chest wall, but some

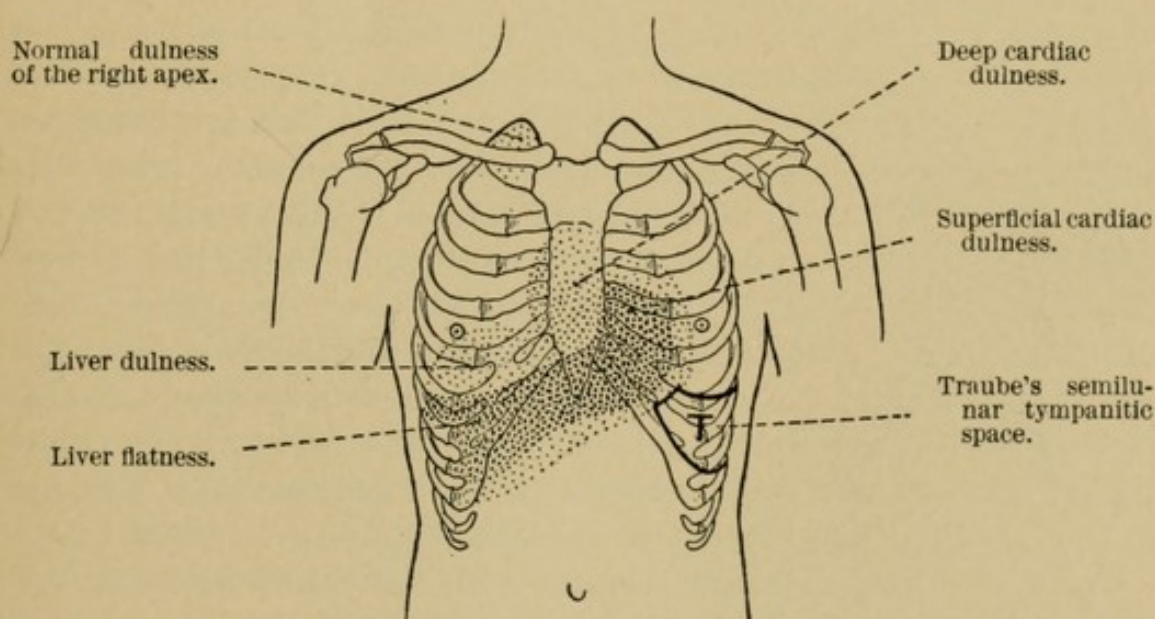


FIG. 49.—Percussion Outlines in the Normal Chest.

sound is elicited and probably enters into the rather complex judgment which follows.

In this country palpatory percussion is but little employed.

II. PERCUSSION RESONANCE OF THE NORMAL CHEST.

The note obtained by percussing the normal chest varies a great deal in different areas. In Fig. 49, the parts shaded darkest are those that normally give least sound when percussed in the manner described above, while from the lightest areas the loudest and clearest sound may be elicited.

(a) The sound elicited in the latter areas is known as normal or "*vesicular*" resonance, and is due to the presence of a normal amount of air in the vesicles of the lung underneath. If this air-containing lung is replaced by a fluid or solid medium, as in pleuritic effusion or pneumonia, it is much more difficult to elicit a

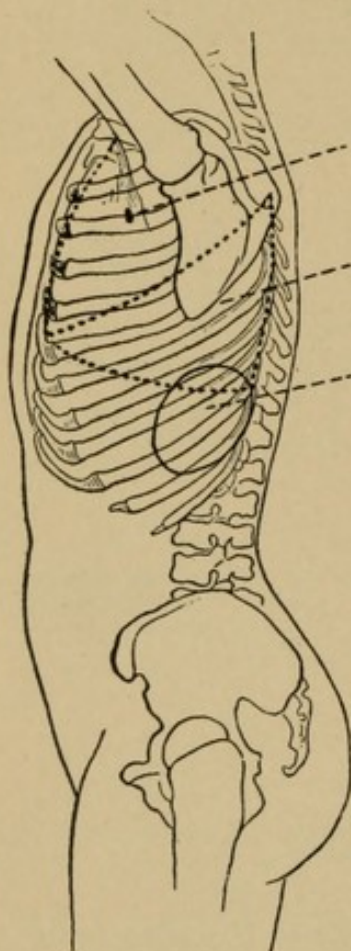


FIG. 50.—Position of the Left Lung in the Axilla.

sound, and such sound as is produced is short, high pitched, and has a feeble carrying power when compared with the sound

elicited from the normal lung. This short, feeble, high-pitched sound is known technically as a "*dull*" or "*flat*" sound, flatness designating the extreme of the qualities that characterize dullness. Over the parts shaded dark in Fig. 49, we

normally get a dull or flat tone, the darkest portions being flat and the others dull. The heavy shadow on the right corresponds to the position occupied by the liver, or rather by that part of it which is in immediate contact with the chest wall. The upper portion of the liver is overlapped by the right lung (see Fig. 49), and hence at this point we get a certain amount of resonance on percussion, although the tone is not so clear as that to be obtained higher up. Below the sixth rib we find true *flatness* near the sternum and for a few inches to the right of this point. As we go toward the axilla, the line of lung resonance slopes down, as is seen in Fig. 50. In the back resonance extends to the ninth or tenth ribs.

Normal Dull Areas.

(b) On the left side, the main dull area corresponds to the heart, which at this point approaches the chest wall, and over the portion shaded darkest is uncovered by the lung. The part here

lightly shaded corresponds to that portion of the heart which is overlapped by the margin of the right and left lungs.

Over the portion of the heart not overlapped by the lung (see Fig. 49, p. 73) the percussion note is nearly flat to light percussion, and very dull even when strongly percussed. This little quadrangular area is known as the "*superficial cardiac space*," and the dulness corresponding to it is referred to as the "*superficial*" cardiac dulness, while the dulness corresponding to the outlines of the heart itself beneath the overlapping lung margins is called the "*deep*" cardiac dulness.

When the heart becomes enlarged, both of these areas, the deep and the superficial, are enlarged, the former corresponding to the increased size of the heart itself, while the superficial cardiac space is extended because the margins of the lungs are pushed aside and a larger piece of the heart wall comes in contact with the chest wall. Accordingly, either the superficial or the deep dulness may be mapped out as a means of estimating the size of the heart. Each method has its advantages and its advocates. The superficial dulness is easier to map out, but varies not only with the size of the heart, but with the degree to which the lungs are distended with air, or adherent to the pericardium or chest wall. What we are percussing is in fact the borders of the lungs at this point.

On the other hand, the deep cardiac dulness is much more satisfactory as a means of estimating the size of the heart but much more difficult to map out. It needs a trained ear and long practice to percuss out correctly the borders of the heart itself, especially the right and the upper borders, since here we have to percuss over the sternum where differences of resonance are very deceptive and difficult to perceive.

It is a disputed point whether light or forcible percussion should be used when we attempt to map out the deep cardiac dulness. Heavy percussion is believed by its advocates to penetrate through the overlapping lung margins and bring out the note corresponding to the heart beneath, a note which, they say, is missed altogether by light percussion. On the other hand, those who employ light percussion contend that heavy percussion sets in vibration so large

an area of lung superficially that fine distinctions of note are made impossible (see above, p. 69).

Good observers are to be found on each side of this question, and I have no doubt that either method works well in skilled hands. Personally I have found light percussion preferable.

Whatever method we use we must percuss successive points along a line running at right angles to the border of the organ which we wish to outline until a change of note is perceived. Thus, if we wish to percuss out the upper border of the liver, we strike successive points along a line running parallel to the sternum and about an inch to the right of it.¹ When a change of note is perceived, the point should be marked with a skin pencil; then we percuss along a line parallel to the first one, and perhaps an inch farther out, and again mark with a dot the point at which the note first changes. A line connecting the points so marked upon the skin represents the border of the organ to be outlined.

If now we look at the upper part of the chest in Fig. 49, we notice at once that the two sides are not shaded alike: the left apex is distinctly lighter colored than the right. This is a very important point and one not sufficiently appreciated by students. The apex of the normal right lung is distinctly less resonant than the apex of the left in a corresponding position.

In percussing at the bottom of the left axilla, we come upon a small oval area of dulness corresponding to that outlined in Fig. 50. This is the area of *splenic dulness*, so called, and corresponds to that portion of the spleen which is in contact with the chest wall. This dull area is to be made out only in case the stomach and colon are not overdistended with air. When these organs are full of gas as is not infrequently the case, there is no area of splenic dulness and the whole region gives forth, when percussed, a note of a quality next to be described, namely, "*tympanitic*."

(c) Tympanitic resonance is that obtained over a hollow body, like the stomach when moderately distended with air.² It is usu-

¹ Or we may reverse the procedure; percuss first over the liver and then work toward the lung above until the note becomes more resonant.

² *Extreme* distention here, as in a snare drum, is associated with a dull percussion note (see below, p. 274)

ally of a higher pitch than the resonance to be obtained over the normal lung, and may be elicited by percussion lighter than that needed to bring out the lung resonance. It differs also from the vesicular or pulmonary resonance in *quality*, in a way easy to appreciate but difficult to describe. Tympanitic resonance is usually to be heard when one percusses over the front of the left chest near the ensiform cartilage and for a few inches to the left of this point over an area corresponding with that of the stomach more or less distended with air. This tympanitic area, known as "*Traube's semilunar space*," varies a great deal in size according to the contents of the stomach. It is bounded on the right by the liver flatness, above by the pulmonary resonance, on the left by the splenic dullness, and below by the resonance of the intestine, which is also tympanitic, although its pitch is different owing to the different size and shape of the intestine.

(The right axilla shows normal lung resonance down to the point at which the liver flatness begins, as shown in Fig. 4.)

In the back, when the scapulæ are drawn forward, as shown in Fig. 46, page 70 percussion elicits a clear vesicular resonance from top to bottom on each side, although the top of the right lung is always slightly less resonant than the top of the left, and sometimes the bottom of the right lung is slightly less resonant than the corresponding portion of the left, on account of the presence of the liver on the right.

It should be remembered, however, that in the majority of cases the resonance throughout the back is distinctly less than that obtained over the front, on account of the greater thickness of the back muscles. Yet in children or emaciated persons, or where the muscular development is slight, there may be as much resonance behind as in front.

Importance of Percussing Symmetrical Points.—Since we depend for our standard of resonance upon comparison with a similar spot on the outside of the chest, it is all-important that in making such comparisons we should percuss symmetrical points, and not, for example, compare the resonance over the third rib in the right front with that over the third interspace on the left, since more resonance can always be elicited over an interspace than over a rib. This

comparison of symmetrical points, however, is interfered with by the presence of the heart on one side and the liver on the other, as well as by the fact that the apex of the right lung is normally less resonant than that of the left. A resonance which would be pathologically feeble if obtained over the left top may be normal over the right. Where both sides are abnormal, as in bilateral disease of the lung, or where fluid accumulates in both pleural cavities, we have to make the best comparison we can between the sound in the given case and an ideal standard carried in the mind.

It must always be remembered that the amount of resonance obtained at any point by percussion depends upon how hard one strikes, as well as upon the conditions obtaining within the chest. A powerful blow over a diseased lung may bring out more resonance than a lighter blow over a normal lung. To strike with perfect fairness and with equal force upon each side can be learned only by considerable practice. Furthermore, the distance from the ear to each of the two points, the resonance of which we are comparing, must be the same—that is, we must stand squarely in front or squarely behind the patient, otherwise the note coming from the part farther from the ear will sound duller than that coming from the nearer side.

The normal resonance of the different parts of the chest can be considerably modified by the position of the patient, by deep breathing, by muscular exertion, and by other less important conditions. If, for example, the patient lies upon the left side, the heart swings out toward the left axilla and its dulness is extended in the same direction. Deep inspiration pushes forward the margins of the lungs so that they encroach upon and reduce the area of the heart dulness and liver dulness. After muscular exertion the lungs become more than ordinarily voluminous, owing to the temporary distention brought about by the unusual amount of work thrown upon them.

The area of cardiac dulness is increased in any condition involving insufficient lung expansion. Thus, in children, in debility, chlorosis, or fevers, the space occupied by the lungs is relatively small and the dull areas corresponding to the heart and liver are

proportionately enlarged. In old age, on the other hand, when the lungs have lost part of their elasticity and sag down over the heart and liver, the percussion dulness of these organs is reduced.

Conditions Modifying the Percussion Note in Health.—The development of muscle or fat as well as the thickness of the chest wall will influence greatly the amount of resonance to be obtained by percussion. Indeed, we see now and then an individual in no part of whose chest can any clear percussion tone be elicited. In women, the amount of development of the breasts has also great influence upon the percussion note. In children, the note is generally clearer, and only the lightest percussion is to be used on account of the thinness of the chest wall. In old people whose lungs are almost always more or less emphysematous, a shade of tympanitic quality is added to the normal vesicular resonance. The distention of the colon with gas may obliterate the liver dulness by rotating that organ so that only its edge is in contact with the chest wall, and if there is wind in the stomach, a variable amount of tympany is heard on percussing the lower left front and axilla or even in the left back.

If a patient is examined while lying on the side the amount of resonance over the lung corresponding to the side on which he lies is usually less than that of the side which is uppermost, because there is more air in the latter. Whatever the patient's position, the amount of resonance is also greater at the end of inspiration than at the end of expiration, for the reason just given. As the lungs expand with full inspiration, their borders move so as to cover a larger portion of the organs which they normally overlap. Portions of the chest which at the end of expiration are dull or flat, owing to the close juxtaposition of the heart, liver, or spleen, become resonant at the end of inspiration. For example, the lower margin of the right lung moves down during inspiration so as to cover a considerably larger portion of the liver.

Percussion as a Means of Ascertaining the Movability of the Lung Borders.—It is often of great importance to determine not merely the position of the resting lung but its power to expand freely. This can be ascertained by percussion in the following way: The

lower border of the lung resonance, say in the axilla, is carefully marked out. Then percussion is made over a point just *below* the level of the resting lung and at the same time the patient is directed to inspire deeply. If the lung expands and its border moves down, the percussion note will change suddenly from dull to resonant during the inspiration. An excursion of two or three inches can often be demonstrated by this method, which is especially important for the anterior and posterior margins of the lung. In the axilla Litten's phrenic shadow will give us the same information.

The mobility of the borders of the lung, as determined by this method, is of considerable clinical importance, for an absence of such mobility may indicate pleuritic adhesions. Its amount depends upon various conditions and varies much in different individuals, but complete absence of mobility is always pathological.

(d) *Cracked-Pot Resonance.*

When percussing the chest of a crying child, we sometimes notice that the sound elicited has a peculiar "*chinking*" quality, like that produced by striking one coin with another, but more muffled. The sound may be more closely imitated, and the mode of its production illustrated, by clasping the hands palm to palm so as to enclose an air space which communicates with the outer air through a chink left open, and then striking the back of the under hand against the knee. By the blow, air is forced out through the chink with a sound like that of metallic coins struck together.

In disease, the cracked-pot sound is usually produced over a pulmonary cavity (as in advanced phthisis) from which the air is suddenly and forcibly expelled by the percussion stroke.

It is much easier to hear this peculiar sound if, while percussing, one listens with a stethoscope at the patient's open mouth. The patient himself holds the chest piece of the instrument just in front of his open mouth, leaving the auscultator's hands free for percussing.

(e) Amphoric Resonance.

A low-pitched hollow sound approximating in quality to tympanitic resonance, and sometimes obtained over pulmonary cavities or over pneumothorax, has received the name of amphoric resonance. It may be imitated by percussing the trachea or the cheek when moderately distended with air.

Summary

The varieties of resonance to be obtained by percussing the normal thorax are:

- (1) *Vesicular resonance*, to be obtained over normal lung tissue.
- (2) *Tympanitic resonance*, to be obtained in Traube's semilunar space
- (3) *Diminished resonance* or *dulness*, such as is present over the scapulæ, and
- (4) Absence of resonance or *flatness*, such as is discovered when we percuss over the lowest ribs in the right front
- (5) *Cracked-pot resonance*, sometimes obtainable over the chest of a crying child.
- (6) *Amphoric resonance*, obtainable over the trachea.

Any of these sounds may denote disease if obtained in portions of the chest where they are not normally found. *Each has its place, and becomes pathological if found elsewhere.* Tympanitic resonance is normal at the bottom of the left front and axilla, but not elsewhere. Dulness or flatness is normal over the areas corresponding to the heart, liver, and spleen, and over the scapulæ, but not elsewhere unless the muscular covering of the chest is enormously thick. Vesicular resonance is normal over the areas corresponding to the lungs, but becomes evidence of disease if found over the cardiac or hepatic areas.

Cracked-pot resonance may be normal if produced while percussing the chest of a child, but under all other conditions, so far as is known, denotes disease.

Amphoric resonance always means disease, usually pulmonary cavity or pneumothorax, if found elsewhere than over the trachea.

(f) The Lung Reflex.

It must also be remembered, when percussing, that in some cases every forcible percussion blow increases the resonance to be obtained by subsequent blows. Any one who has demonstrated an area of percussion dulness to many students in succession must have noticed occasionally that the more we percuss the dull area, the more resonant it becomes, so that to those who last listen to the demonstration the difference which we wish to bring out is much less obvious than to those who heard the earliest percussion strokes. Abrams has referred to this fact under the name of the "lung reflex," believing, partly on the evidence of fluoroscopic examination, that if an irritant such as cold or mustard is applied to any part of the skin covering the thorax, the lung expands so that a localized temporary emphysema is produced in response to the irritation. Apparently percussion has a similar effect.

III. SENSE OF RESISTANCE.

While percussing the chest we must be on the lookout not only for changes in resonance, but for variations in the amount of resistance felt underneath the finger. Normally the elasticity of the chest walls over the upper fronts is considerably greater and the sense of resistance considerably less than that felt over the liver. In the axillæ and over those portions of the back not covered by the scapulæ, we feel in normal chests an elastic resistance when percussing which is in contrast with the dead, woody feeling which is communicated to the finger when the air-containing lung is replaced by fluid or solid contents (pleuritic effusion, pneumonia, phthisis, etc.). In some physicians this sense of resistance is very highly developed and as much information is obtained thereby as through the sounds elicited. As a rule, however, it is only by long practice that the sense of resistance is cultivated to a point where it becomes of distinct use in diagnosis.

CHAPTER IV.

AUSCULTATION.

AUSCULTATION may be practised by placing one's ear directly against the patient's chest (immediate auscultation) or with the help of a stethoscope (mediate auscultation).

Each method has its place. Immediate auscultation is said to have advantages similar to those of the low power of the microscope, in that it gives us a general idea of the condition of a relatively large area of tissue, while the stethoscope may be used, like the oil immersion lens, to bring out details at one or another point.

On the other hand, I have heard it said by E. G. Janeway and other accomplished diagnosticians that the unaided ear can perceive sounds conducted from the interior of the lung—sounds quite inaudible with any stethoscope—and that in this way deepseated areas of solidification may be recognized.

Immediate auscultation may be objected to

(a) On grounds of *delicacy* (when examining persons of the opposite sex).

(b) On grounds of *cleanliness* (although the chest may be covered with a towel so as to protect the auscultator to a certain extent).

(c) Because we cannot conveniently reach the supraclavicular or the upper axillary regions in this way.

(d) Because it is difficult to localize the different valvular areas and the sites of cardiac murmurs if immediate auscultation is employed.

On account of the latter objection the great majority of observers now use the stethoscope to examine the heart. For the lungs, both methods are employed by most experienced auscultators.

(Personally, I have never yet learned to hear anything with my unaided ear which I could not hear better with a stethoscope, and the Bowles stethoscope seems to me to reach as large an area and as deep as the unaided ear. Nevertheless the weight of competent opinion is against me and greater experience will doubtless show me my mistake.)

While learning the use of immediate auscultation it is best to close with the fingers the ear which is not in contact with the chest. With practice one comes to disregard outer noises and does not need to stop the ear.

MEDIATE AUSCULTATION.

1. *Selection of a Stethoscope.*

(1) It is as rash for any one to select a stethoscope without first trying the fit of the ear pieces in his ears as it would be to buy a new hat without trying it on. What suits A. very well is quite impossible for B. It is true that one can get used to almost any stethoscope as one can to almost any hat, but it is not necessary to do so. The ear pieces of the ordinary stethoscope are often too small and rarely too large. In case of doubt, therefore, it is better to err upon the side of getting a stethoscope with too large rather than too small ends.

(2) The binaural stethoscope, which is now almost exclusively used in this country, maintains its position in the ears of the auscultator either through the pressure of a rubber strap stretched around the metal tubes leading to the ears, or by means of a steel spring connecting the tubes. Either variety is usually satisfactory, but I prefer a stethoscope made with a steel spring (see Fig. 51) because such a spring is far less likely to break or lose its elasticity than a rubber strap. A rubber strap can always be added if this is desirable. It is important to pick out an instrument possessing a spring not strong enough to cause pain in the external meatus of the ear and yet strong enough to hold the ear pieces firmly in place. Persons with narrow heads need a much more powerful spring or strap than would be convenient for persons with wide heads.

(3) The rubber tubing used to join the metallic tubes to the chest piece of the instrument should be as flexible as possible (see

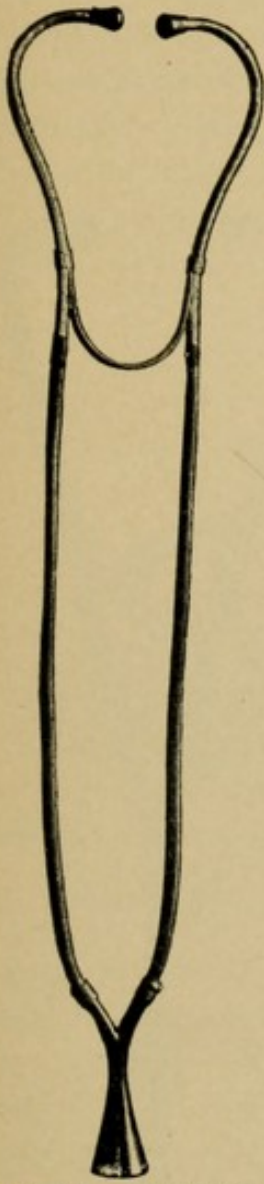


FIG. 51. — Stethoscope Fitted With Long Flexible Tubes, Especially Useful When Examining Children.

Fig. 51). Stiff tubing (see Fig. 52) makes it necessary for the auscultator to move his head and body from place to place as the examination of the chest progresses, while if flexible tubing is used the head need seldom be moved and a great deal of time and fatigue is thus saved. Stiff stethoscopes are especially inconvenient when examining the axilla.

(4) Jointed stethoscopes which fold up or take apart should be scrupulously avoided. They are a delusion and a snare, apt to come apart at critical moments, and to snap and creak at the joints when in use, sometimes producing in this way sounds which may be easily mistaken for râles. Such an instrument is no more portable nor compact than the ordinary form with flexible tubes. It has, therefore, no advantages over stethoscopes made in one piece and possesses disadvantages which are peculiarly annoying.

(5) *The Chest Piece.*—The majority of the stethoscopes now in use have a chest piece of hard-rubber or wood with a diameter of about seven-eighths of an inch. Chest pieces of larger diameter than this are to be avoided as they are very difficult to maintain in close apposition with thin

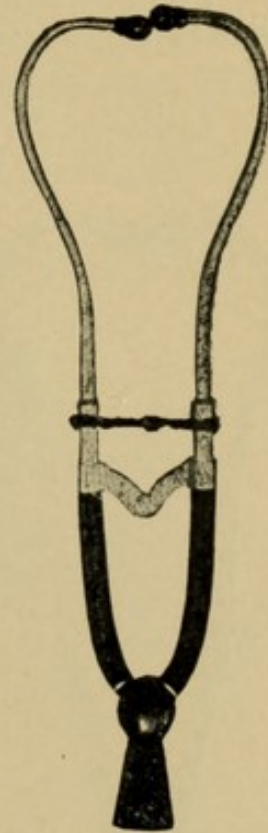


FIG. 52. — Common Stethoscope With Stiff Tubing and Rubber Strap.

chests. To avoid this difficulty the chest piece is sometimes made of soft-rubber or its diameter still further reduced.

(6) *The Bowles Stethoscope.*—(See Figs. 53 and 54.) Within the last year there has been introduced an instrument which, for most purposes, seems to me far superior to any other form of stethoscope with which I am acquainted. Its pe-

culiarity is the chest piece, which consists of a very shallow steel cup (see Fig. 55) over the mouth of which a thin metal plate or a bit of pigskin is fastened. The metal or pigskin diaphragm serves simply to prevent the tissues of the chest from projecting into the shallow cup of the chest piece when the latter is pressed against the chest, and does not in any other way contribute to the sounds which we hear with the instrument. This is proved by the fact that we can hear as well even when the diaphragm is cracked across in several directions.

With this instrument almost all sounds produced within the chest can be heard much more distinctly than in any other variety of stethoscope. Cardiac murmurs

FIG. 53.—Bowles' Stethoscope. Front view.

which are inaudible with any other stethoscope may be distinctly heard with this. Especially is this true of low-pitched murmurs due to aortic regurgitation. Yet it is useful for examination not merely of the heart, but of the lungs as well. For any one

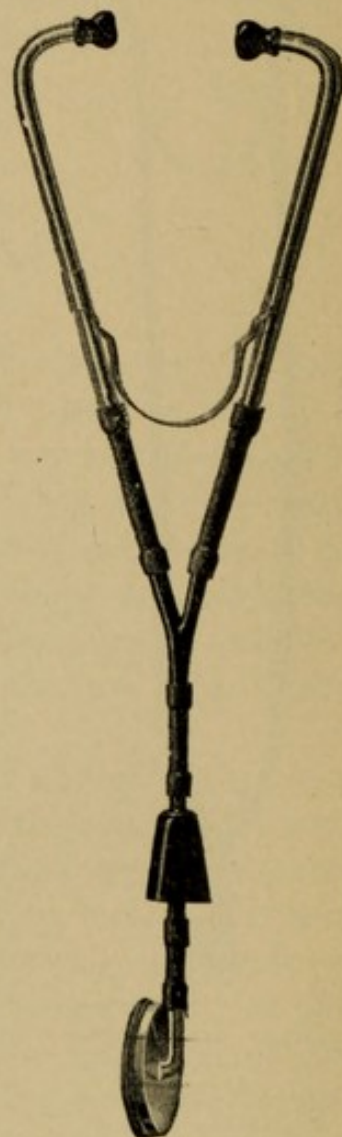
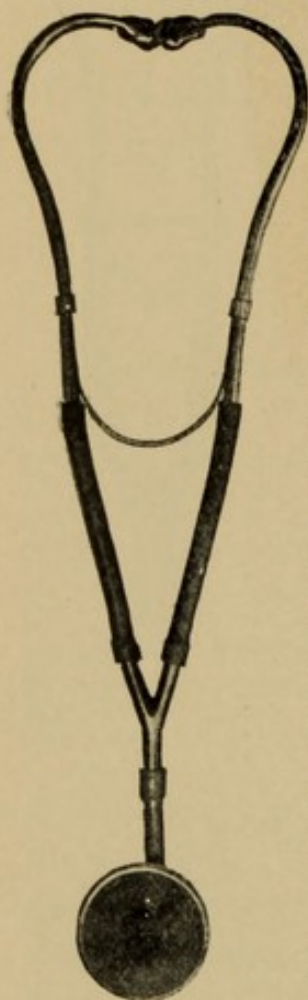


FIG. 54.—Combination Bowles' Stethoscope.

who has difficulty in hearing the ordinary cardiac or respiratory sounds, or for one who is partially deaf, the instrument is invaluable. As the metal rim of the chest is apt to get unpleasantly cold, it is best to cover it with a bit of rubber or kid. This saves the patient some discomfort and also tends to prevent the instrument from slipping on the skin. The flat chest piece makes the instrument very useful in listening to the posterior portions of the lungs in cases of pneumonia in which the patient is too sick to be turned over or to sit up. Without moving the patient at all we can

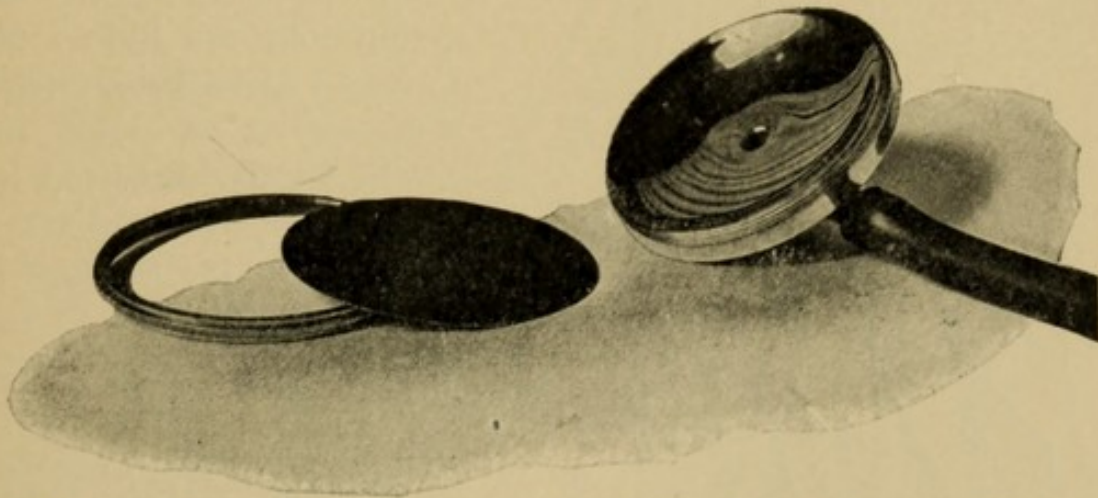


FIG. 55.—Chest Piece of Bowles' Stethoscope. On the right the shallow cup communicating with the ear tubes. On the left the diaphragm which covers the cup, and the ring which holds it in place.

work the chest piece in under the back of the patient by pressing down the bed-clothes, and in this way can listen to any part of the chest without moving the patient. A further advantage of the instrument is that it enables us to gain an approximately accurate idea of the heart sounds without undressing the patient. Respiratory sounds cannot well be listened to through the clothes, as the rubbing of the latter may simulate râles.

There are two purposes for which I have found the Bowles stethoscope inferior to the ordinary stethoscope:

(1) For listening over the apex of the lung for fine râles, *e.g.*, in incipient phthisis.

(2) For listening for *superficial* sounds, such as a friction rub or

a presystolic murmur.¹ When I desire to listen for fine râles at an apex, for a friction rub, or for a presystolic murmur, I separate the chest piece of the Bowles stethoscope from the hard-rubber bell into which it is inserted, thereby converting the instrument into one of the ordinary form. With an extra hard-rubber bell

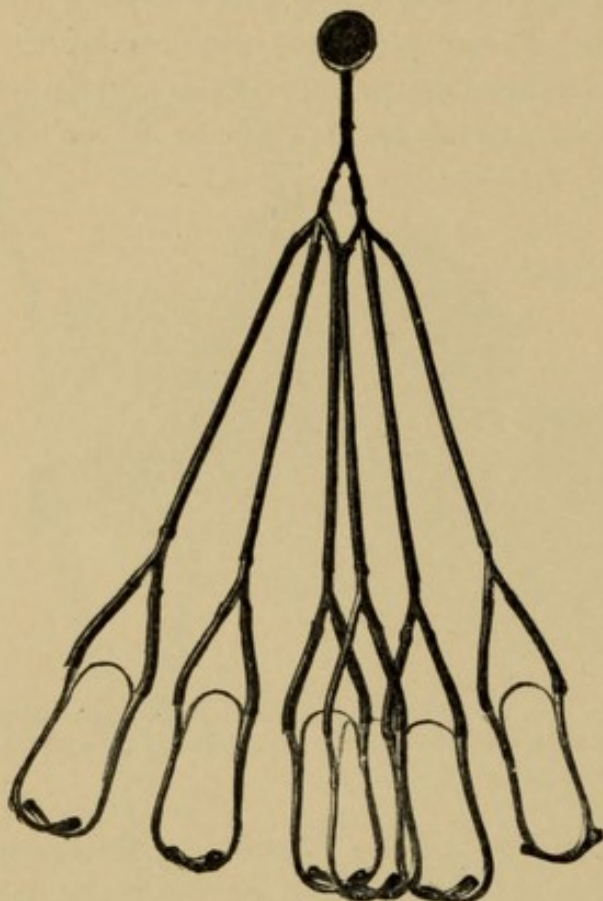


FIG. 56.—Bowles' Multiple Stethoscope for Six Students.

attached, the instrument is no more bulky than an ordinary stethoscope, and far more efficient. When used for listening to the respiration, the Bowles instrument gives us information similar in some respects to that obtained by the use of the free ear—that is, we are through it enabled to ascertain by listening at one spot the condition of a much larger area of the chest than can in any other way be investigated.

Owing to the fact that both cardiac and respiratory sounds are magnified by the Bowles stethoscope, this instrument is especially well adapted for use with some

sort of an attachment whereby several sets of ear pieces are so joined by tubing to one chest piece that several persons may listen at once. Bowles' multiple stethoscope, fitted for six and for twelve observers, is seen in Figs. 56 and 57, and the method of its use in

¹ It has frequently been observed, when listening with the ordinary stethoscope, that a presystolic murmur can be better heard if only the very lightest pressure is made with the stethoscope. The fact that a thrill is communicated to the chest wall, and that that thrill is connected with the audible murmur explains my calling this murmur a superficial one.

Fig. 58. In the teaching of auscultation this instrument is of great value, saving as it does the time of the instructor and of the students and the strength of the patient. The sounds conducted through any one of the twelve tubes used in this instrument are as loud as those to be heard with a single instrument of the ordinary form, although far fainter than those to be heard with a single Bowles stethoscope.

II. *The Use of the Stethoscope.*

Having secured an instrument which fits the ears satisfactorily, the beginner may get a good deal of practice by using it upon himself, especially upon his own heart. The chief

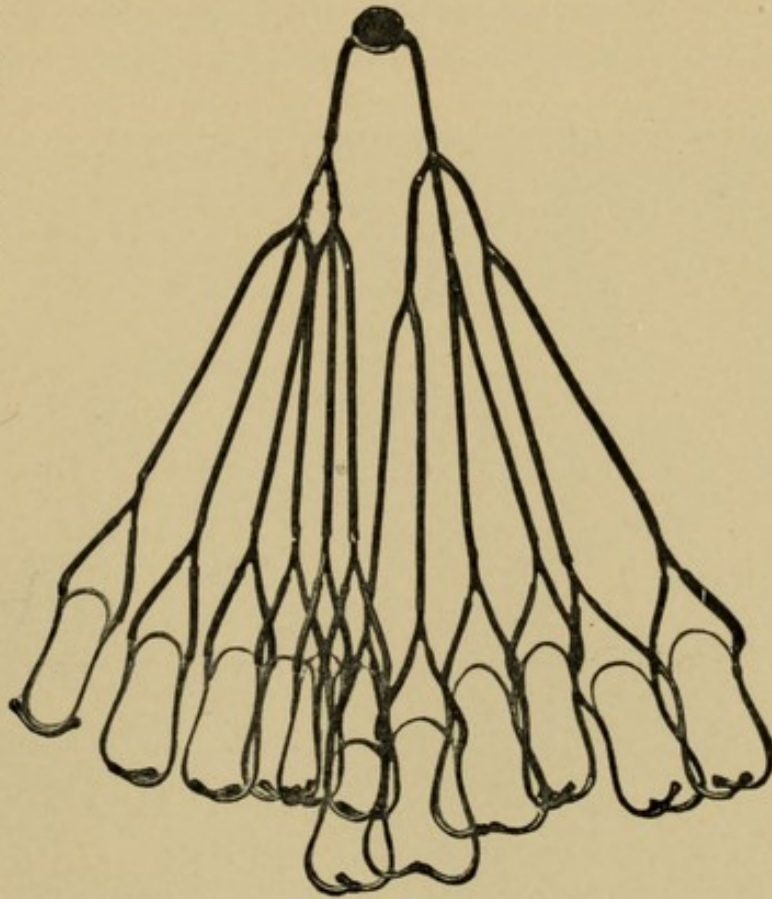


FIG. 57.—Bowles' Multiple Stethoscope for Twelve Students.

point to be learned is to *disregard various irrelevant sounds* and to concentrate attention upon those which are relevant. Almost any one hears enough with a stethoscope, and most beginners hear too much. No great keenness of hearing is required, for the sounds which we listen for are not, as a rule, difficult to hear if attention is concentrated upon them.

A. Selective Attention and What to Disregard.

Accordingly, the art of using a stethoscope successfully depends upon the acquisition of two powers—

- (a) A knowledge of what to disregard. (b) A selective atten-

tion or concentration upon those sounds which we know to be of importance.

Among the sounds which we must learn to disregard are the following:

(1) Noises produced in the room or its immediate neighborhood, but not connected with the patient himself. It is, of course, easier

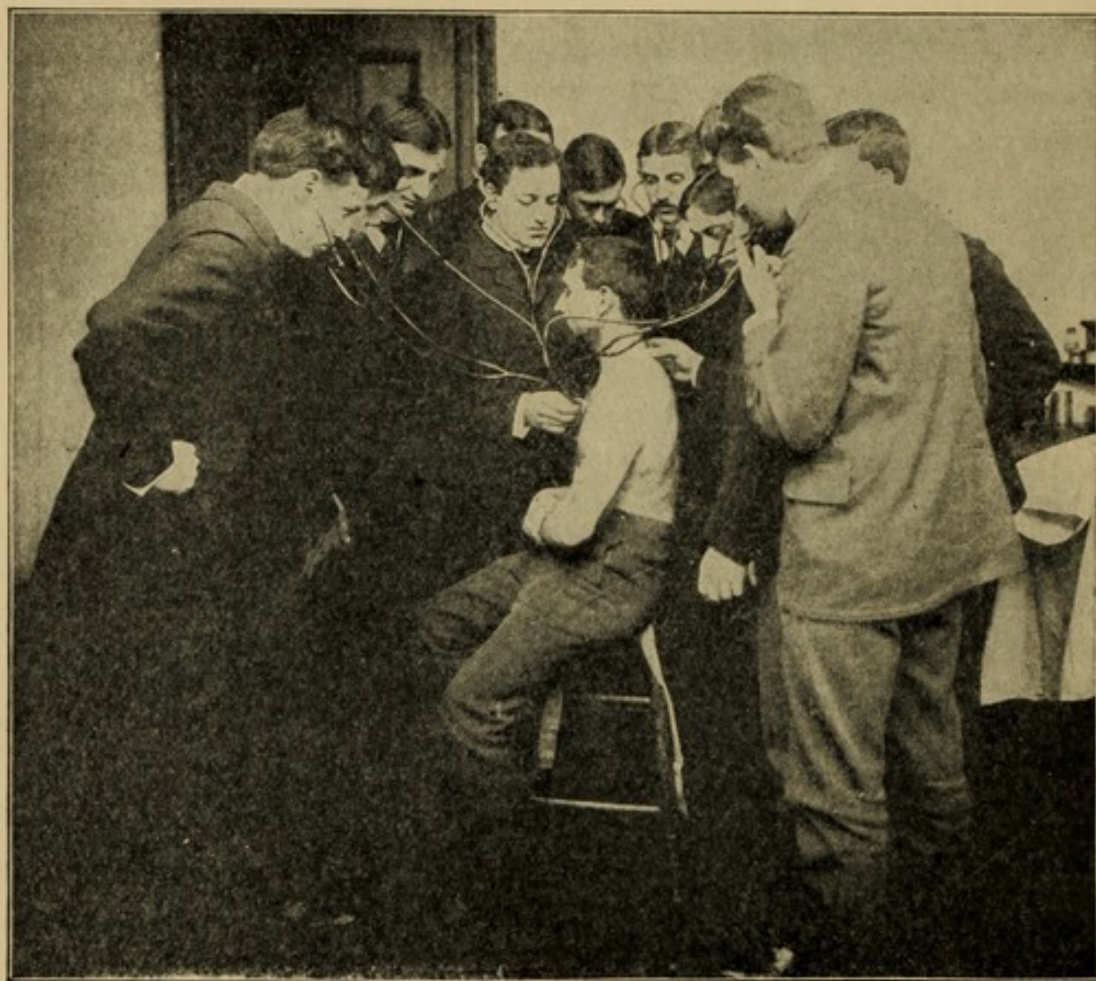

FIG. 58.—Bowles' Multiple Stethoscope in Use. Twelve students listening at once

to listen in a perfectly quiet room where there are no external noises which need to be excluded from attention, but as the greater part of the student's work must be done in more or less noisy places, it is for the beginner a practical necessity to learn to withdraw his attention from the various sounds which reach his ear from the street, from other parts of the building, or from the room

in which he is working. This is at first no easy matter, but can be accomplished with practice.

(2) When the power to disregard external noises has been acquired, a still further selection must be made among the sounds which come to the ear through the tubes of the stethoscope. Noises produced by friction of the chest piece of the stethoscope upon the skin are especially deceptive and may closely simulate a pleural or pericardial friction sound. It is well for the student to experiment upon the nature and extent of such "skin rubs" by deliberately moving the chest piece of the stethoscope upon the skin and listening to the sounds so produced. Mistakes can be avoided in the majority of cases by holding the chest piece of the stethoscope very firmly against the chest. This can be easily done when the patient is in the recumbent position, but when the patient is sitting up it may be necessary to press so hard with the chest piece of the stethoscope as to throw the patient off his balance unless he is in some way supported; accordingly, it is my practice in many cases to put the left arm around and behind the patient so as to form a support, against which he can lean when the chest piece of the stethoscope is pressed strongly against his chest. When listening to the back of the chest, the manœuvre is reversed. If the skin is very dry, the ribs are very prominent, or the chest is thickly covered with hair, it may be impossible to prevent the occurrence of adventitious sounds due to friction of the chest piece upon the chest, no matter how firmly the instrument is held. In case of doubt, and in any case in which a diagnosis of pleural or pericardial friction is in question, the surface of the chest, at the point where we desire to listen, should be moistened and any hair that may be present thoroughly wetted with a sponge, so that it will lie flat upon the chest. Otherwise the friction of the hair under the chest piece of the stethoscope may simulate crepitant râles as closely as "skin rubs" simulate pleural friction.

(3) The friction of the fingers of the auscultator upon the chest piece or on some other part of the stethoscope frequently gives rise to sounds closely resembling râles of one or another description. The nature of these sounds can be easily learned by intentionally moving the fingers upon the stethoscope. They are to be avoided

by grasping the instrument as firmly as possible, and by touching it with as few fingers as will suffice to hold it close against the chest.

(4) Noises produced by a shifting of the parts of the stethoscope upon each other are especially frequent in stethoscopes made in several pieces and jointed together. A variety of snapping and cracking sounds, not at all unlike certain varieties of râles, may thus be produced, and if we are not upon our guard, may lead to errors in diagnosis. Stethoscopes which have no hinges and which do not come apart are far less likely to trouble us in this way.

(5) When a rubber band is used to press the ear pieces more firmly into the ears, a very peculiar sound may be produced by the breathing of the auscultator as it strikes upon the rubber strap. It is a loud musical note, and may be confused with coarse, dry râles.

When one has learned to recognize and to disregard the noises produced in the ways above indicated, there is still one set of sounds which are very frequently heard, yet which have no significance for physical diagnosis, and must therefore be disregarded; I refer to

B. Muscle Sounds.

Patients who hold themselves very erect while being examined, or who for any reason contract the muscles of that portion of the chest over which we are listening, produce in these muscles a very peculiar and characteristic set of sounds. The contraction of any muscle in the body produces sounds similar in quality to those heard over the chest, but of less intensity.

Those who have the faculty of contracting the tensor tympani muscle at will can at any time listen to a typical muscle-sound. Or close both ears with the fingers and strongly contract the masseter muscle, with the teeth clenched. A high-pitched muscle sound will be heard.

It is well also to have a patient contract one of the pectorals and then listen to the sound thus produced. In some cases a continuous, low-pitched roar or drumming is all that we hear; in other cases we hear nothing but the breath sounds during expiration, while during inspiration the breath sound is obscured by a series of

short, dull, rumbling sounds, following each other at the rate of from five to ten in a second. Occasionally the sound is like the puffing of the engine attached to a pile-driver, or like a stream of water falling upon a sheet of metal just slowly enough to be separated into drops and heard at a considerable distance. As already mentioned, we are especially apt to hear these muscle sounds during forced inspiration, owing to the contraction of voluntary muscles during that portion of the respiratory act. They are most often heard over the upper portion of the chest (over the pectorals in front and over the trapezius behind), but in some persons no part of the chest is free from them. It is a curious fact that we are not always able to detect by sight or touch the muscular contractions which give rise to these sounds, and the patient himself may be wholly unaware of them. Under such circumstances they are not infrequently mistaken for râles, and I am inclined to think that many of the sounds recorded as "crumpling," "obscure," "muffled," "distant," or "indeterminate" râles are in reality due to muscular contractions. The adjectives "muffled" and "distant" give us an inkling as to the qualities which distinguish muscular sounds from râles. Râles are more clean cut, have a more distinct beginning and end, seem nearer to the ear, and possess more of a crackling or bubbling quality than muscle sounds.

I have made no attempt exhaustively to describe all the sounds due to muscular contractions and conducted to the ear by the stethoscope, but have intended simply to call attention to the importance of studying them carefully.

C. Other Sources of Error.

Another source of confusion, which for beginners is very troublesome, especially if they are using the ordinary form of stethoscope with a bell-shaped chest piece, arises in case the chest piece is not held perfectly in apposition with the skin. If, for example, the stethoscope is slightly tilted to one side so that the bell is lifted from the skin at some point, or if one endeavors to listen over a very uneven part of the chest on which the bell of the stethoscope cannot be made to rest closely, a roar of external noises reaches the

ear through the chink left between the chest piece and the chest. After a little practice one learns instantly to detect this condition of things and so to shift the position of the chest piece that external noises are totally excluded ; but by the beginner, the peculiar babel of external noises which is heard whenever the stethoscope fails to fit closely against the chest is not easily recognized, and hence he tends to attribute some of these external sounds to diseased conditions within the chest.

Again, it is not until we have had considerable practice that

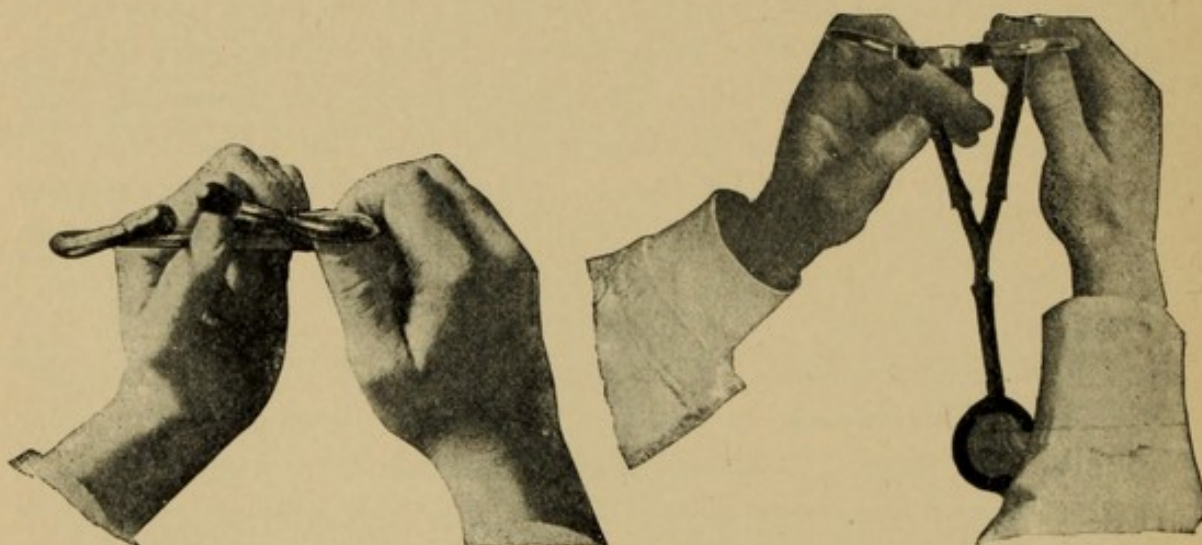


FIG. 59.—Stethoscope Held Right Side Up.

FIG. 60.—Stethoscope Held Wrong Side Up.

our sense of hearing comes instantly to tell us when something is wrong about the stethoscope itself ; when, for example, one of the tubes is blocked, kinked, or disconnected, or when we are holding the stethoscope upside down, so that the ear pieces point downward instead of upward (see Figs. 59 and 60). It is only when we have learned through long practice about how much we ought to hear at a given point in the normal chest that we recognize at once the fact that we are not hearing *as much as we should*, in case some one of the above accidents has happened. Many beginners do not listen long enough in any one place, but move the chest piece of the stethoscope about rapidly from point to point, as they have seen experienced auscultators do ; but it is remarkable how much more one can hear at a given point by simply persevering and

listening to beat after beat, or breath after breath. It is sometimes difficult to avoid the impression that the sounds themselves have grown louder as we continue to listen, especially if we are in any doubt as to what we hear. Therefore, if we hear indistinctly, it is important to keep on listening, and to fix the attention successively upon each of the different elements in the sounds under consideration. In difficult cases we should use every possible aid toward concentration of the attention, and where it is possible, all sources of distraction should be eliminated. Thus, in any case of doubt, I think it is important for the auscultator to get himself into as comfortable a position as he can, so that his attention is not distracted by his own physical discomforts. Many auscultators shut their eyes when listening in a difficult case so as to avoid the distraction of impressions coming through the sense of sight. It goes without saying that if quiet can be secured in the room where we are working, and outside it as well, we shall be enabled to listen much more profitably.

AUSCULTATION OF THE LUNGS.

In the majority of cases ordinary quiet breathing is not forcible enough to bring out the sounds on which we depend for the diagnosis of the condition of the lungs. Deep or forced breathing is what we need.

As a rule, the patient must be taught how to breathe deeply, which is best accomplished by personally demonstrating the act of deep breathing and then asking him to do the same. Two difficulties are encountered:

(a) The patient may blow out his breath forcibly and with a noise, since that is what he is used to doing whenever he takes a long breath under ordinary circumstances; or

(b) It may be that he cannot be made to take a deep breath at all. The first of these mistakes alters the sounds to be heard with the stethoscope in any part of the chest by disturbing both the rhythm and the pitch of the respiratory sounds. In this way the breathing may be made to sound tubular or asthmatic throughout a sound chest. This difficulty can sometimes be overcome by demonstrating to the patient that what you desire is to have him take a

full breath and then simply *let it go*, but *not* blow it forcibly out. In some cases the patient cannot be taught this, and we have to get on the best we can despite his mistakes. When he cannot be made to take a full breath at all, we can often accomplish the desired result by getting him to cough. The breath just before and after a cough is often of the type we desire. The use of voluntary cough in order to bring out râles will be discussed later on. Another useful manœuvre is to make the patient count aloud as long as he can with a single breath. The deep inspiration which he is forced to take after this task is of the type which we desire.

I. RESPIRATORY TYPES.

In the normal chest two types of breathing are to be heard:

- (1) Tracheal, bronchial, or tubular breathing.
- (2) Vesicular breathing.

Tracheal, bronchial, or tubular breathing is to be heard in normal cases if the stethoscope is pressed against the trachea, and as a rule

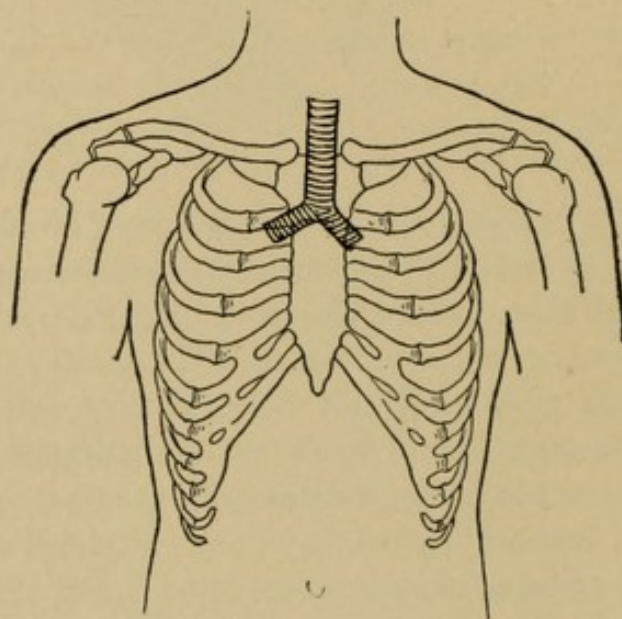


FIG. 61 —Situation of the Trachea and Primary Bronchi.

it can also be heard over the situation of the primary bronchi, in front or behind (see Figs. 61 and 62).

Vesicular breathing is to be heard over the remaining portions of

the lung—that is, in the front of the thorax except where the heart and the liver come against the chest wall, in the back except where the presence of the scapulæ obscures it, and throughout both axillæ.

(1) *Characteristics of Vesicular Breathing.*

Vesicular breathing—that heard over the air vesicles or parenchyma of the lung—has certain characteristics which I shall try to describe in terms of intensity, duration, and pitch.

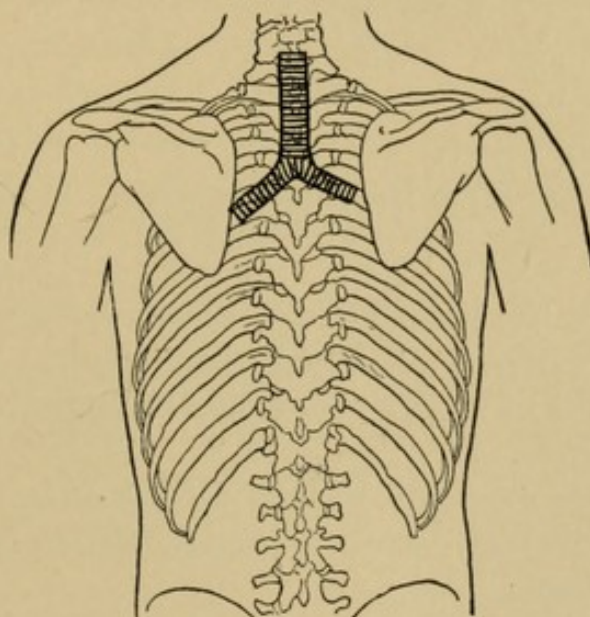


FIG. 62.—Situation of the Trachea and Primary Bronchi.

Of the *quality* of the sounds heard over this portion of the lung there is little can be said; it sounds something like the swish of the wind in a grove of trees some distance off, and hence is sometimes spoken of as “breezy.”

The intensity, duration, and pitch of the inspiration as compared with that of the expiration may be represented as in Fig. 63. In this figure, as in all those to be used in description of respiratory sounds—

(1) I represent the inspiration by an up-stroke and the expiration by a down-stroke (see the direction of the arrows in Fig. 63).

(2) The *length* of the up-stroke as compared with that of the down-stroke corresponds to the *length* of inspiration compared with expiration.

(3) The *thickness* of the up-stroke as compared with the down-stroke represents the *intensity* of the inspiration as compared with the expiration.

(4) The *pitch* of inspiration as compared with that of expiration is represented by the *sharpness of the angle* which the up-



FIG. 63.—Vesicular Breathing.



FIG. 64.—Distant Vesicular Breathing.

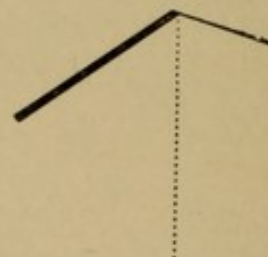


FIG. 65.—Exaggerated Vesicular Breathing.

stroke makes with the perpendicular as compared with that which the down-stroke makes with the perpendicular. The *pitch of a roof* may be thought of in this connection to remind us of the meaning of these symbols.

If now we look again at Fig. 63 we see that when compared with expiration (the down-stroke), the inspiration is—

- (a) More intense.
- (b) Longer.
- (c) Higher pitched.

Our comparison is invariably made between inspiration and expiration, and not with any other sound as a standard.

Now, this type of breathing (which, as I have said, is to be heard over every portion of the lung except those portions immediately adjacent to the primary bronchi), is not heard everywhere with equal intensity. It is best heard below the clavicles in front, in the axillæ, and below the scapulæ behind, but over the thin, lower edges of the lung, whether behind or at the sides, it is feebler, though still retaining its characteristic type as revealed in the inspiration and expiration in respect to intensity, duration, and pitch. To represent distant vesicular breathing graphically we have only to draw its symbol on a smaller scale (see Fig. 64). On

the other hand, when one listens to the lungs of a person who has been exerting himself strongly, one hears the same type of respiration, but on a *larger scale*, which may then be represented as in Fig. 65. This last symbol may also be used to represent the respiration which we hear over normal but thin-walled chests; for example, in children or in emaciated persons. It is sometimes known as "exaggerated" or "puerile" respiration. When one lung is thrown out of use by disease so that increased work is brought upon the other, the breath sounds heard over the latter are increased and seem to be produced on a larger scale. Such breathing is sometimes spoken of as "rough" breathing.

It is very important to distinguish at the outset between the different *types* of breathing, one of which I have just described, and the different *degrees* of loudness with which any one type of breathing may be heard.

(2) *Bronchial or Tracheal Breathing in Health.*

Bronchial breathing may be symbolically represented as in Fig. 66, in which the increased length of the down stroke corresponds to the increased duration of expiration, and the greater thickness



FIG. 66.—Bronchial Breathing of Moderate Intensity.



FIG. 67.—Distant Bronchial Breathing.




FIG. 68.—Very Loud Bronchial Breathing.

of both lines corresponds to the greater intensity of both sounds, expiratory and inspiratory, while the sharp pitch of the "*gale*" on both sides of the perpendicular corresponds to the high pitch of both sounds. Expiration, it will be noticed, slightly exceeds inspiration both in intensity and pitch, and considerably exceeds it in duration, while as compared with vesicular breathing almost all the

relations are reversed. Bronchial breathing has also a peculiar quality which can be better appreciated than described.

In the healthy chest this type of breathing is to be heard if one listens over the trachea or primary bronchi (see above, Fig. 59), but practically one hardly ever listens over the trachea and bronchi except by mistake, and the importance of familiarizing one's self with the type of respiration heard over these portions of the chest is due to the fact that in certain diseases, especially in pneumonia and phthisis, we may hear bronchial breathing over the *parenchyma* of the lung where normally vesicular breathing should be heard.

The student should familiarize himself with each of these types of breathing, the vesicular and the bronchial, concentrating his attention as he listens first upon the inspiration and then upon the expiration, and comparing them with each other, first in duration, next in intensity, and lastly in pitch. To those who have not a musical ear, high-pitched sounds convey the general impression of being shrill, while low-pitched sounds sound hollow and empty, but the distinction between intensity and pitch is one comparatively difficult to master. Distant bronchial breathing may be represented in Fig. 67, and is to be heard over the back of the neck opposite the position of the trachea and bronchi. Fig. 68 represents very loud bronchial breathing such as is sometimes heard in pneumonia.

(3) *Broncho-Vesicular Breathing in Health.*

As indicated by its name, this type of breathing is intermediate between the two just described, hence the terms "mixed breathing," or "atypical breathing" ("unbestimmt"). Its characteristics may be symbolized as in Fig. 69. In the normal chest one can become familiar with broncho-vesicular breathing, by examining the apex of the right lung, or by listening over the trachea or one of the primary bronchi, and then moving the stethoscope half an inch at a time toward one of the nipples. In the course of this journey one passes over points at which the breathing has, in varying degrees, the characteristics intermediate between the bronchial type from which we started and the vesicular type toward which we are

moving. Expiration is a little longer, intenser, or higher pitched than in vesicular breathing, and inspiration a little shorter, feebler,

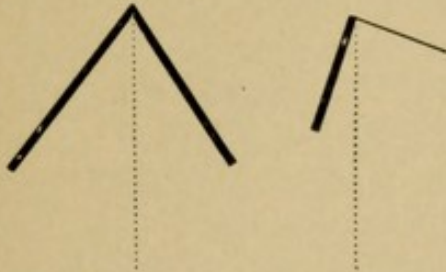


FIG. 69.—Two Common Types of Broncho-Vesicular Breathing.




FIG. 70.—Distant Broncho-Vesicular Breathing.

or lower pitched; but since these characteristics are variously combined, there are many subvarieties of broncho-vesicular breathing. Fig. 70 represents two types of distant broncho-vesicular breathing.

(4) *Emphysematous Breathing.*

A glance at Fig. 71 will call up the most important features of this type of respiration. The inspiration is short and somewhat feeble, but not otherwise remarkable. The expiration is long, feeble, and low pitched. This type of breathing is the rule in elderly persons, particularly those of the male sex.

(5) *Asthmatic Breathing.*

Fig. 72 differs from emphysematous only in the greater intensity of the inspiration. In this type of breathing, however, both sounds

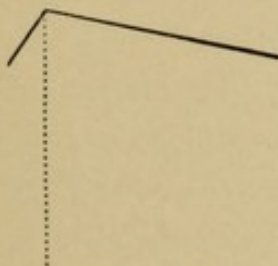


FIG. 71.—Emphysematous Breathing.

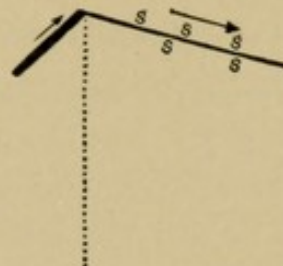


FIG. 72.—Asthmatic Breathing. s, s, s. squeaking (musical) râles.

are usually obscured to a great extent by the presence of piping and squeaking râles (see below).

(6) *Interrupted or "Cogwheel" Breathing.*

As a rule, only the inspiration is interrupted, being transformed into a series of short, jerky puffs as shown in Fig. 73. Very rarely the expiration is also divided into segments. When heard over the entire chest, cogwheel breathing is usually the result of nervousness, fatigue, or chilliness on the patient's part. With the removal of these causes this type of respiration then disappears. If, on the other hand, cogwheel respiration is confined to a relatively small portion of the chest, and remains present despite the exclusion of

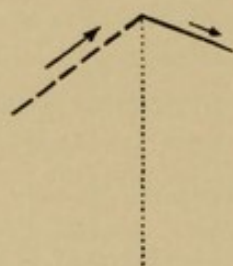


FIG. 73.—Cogwheel Breathing.

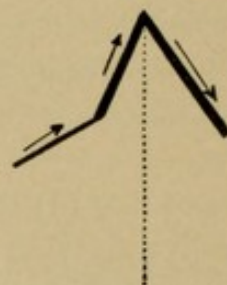


FIG. 74.—Metamorphosing Breathing.

fatigue, nervousness, or cold, it points to a local catarrh in the finer bronchi such as to render difficult the entrance of air into the alveoli. As such, it has a certain significance in the diagnosis of early phthisis, a significance similar to that of râles or other signs of localized bronchitis (see below).

(7) *Amphoric or Cavernous Breathing* (see below, p. 107).(8) *Metamorphosing Breathing.*

Occasionally, while we are listening to an inspiration of normal pitch, intensity, and quality, a sudden metamorphosis occurs and the type of breathing changes from vesicular to bronchial or amphoric (see Fig. 74), or the intensity of the breath sounds may suddenly be increased without other change. These metamorphoses are usually owing to the fact that a plugged bronchus is suddenly opened by the force of the inspired air, so that the sounds conducted through it become audible.

II. DIFFERENCES BETWEEN THE TWO SIDES OF THE CHEST.

Over the apex of the right lung—that is, above the right clavicle in front, and above the spine of the scapula behind—one hears in the great majority of normal chests a distinctly broncho-vesicular type of breathing. In a smaller number of cases this same type of breathing may be heard just below the right clavicle. These facts cannot be too strongly insisted upon, since it is only by bearing them in mind that we can avoid the mistake of diagnosing a beginning consolidation of the right apex where none exists. *Breath sounds which are perfectly normal over the right apex would mean serious disease if heard over similar portions of the left lung.* It will be remembered that the apex of the right lung is also duller on percussion than the corresponding portion of the left, and that the voice sounds and tactile fremitus are normally more intense on the right (see Fig. 32).

Occasionally one finds at the base of the right lung posteriorly a slightly feebler or more broncho-vesicular type of breathing than in the corresponding portion of the left lung.

III. PATHOLOGICAL MODIFICATIONS OF VESICULAR BREATHING.

Having now distinguished the different types of breathing and described their distribution in the normal chest, we must return to the normal or vesicular breathing in order to enumerate certain of its modifications which are important in diagnosis.

(1) *Exaggerated Vesicular Breathing* (“*Compensatory*” *Breathing*).

(a) It has already been mentioned that in children or in adults with very thin and flexible chests the normal breath sounds are heard with relatively great distinctness; also that after any exertion which leads to abnormally deep and forcible breathing a similar increase in the intensity of the respiratory sounds naturally occurs.

(b) The term “*compensatory breathing*,” or “*vicarious*” breathing, refers to vesicular breathing of an exaggerated type, such as is heard, for example, over the whole of one lung when the other lung

is thrown out of use by the pressure of an accumulation of air or fluid in the pleural cavity. A similar exaggeration of the breathing upon the sound side takes place when the other lung is solidified, as by tuberculosis, pneumonia, or malignant disease, or when it is compressed by the adhesions following pleuritic effusion, or by a contraction of the bones of that side of the chest such as occurs in spinal curvature.

(2) *Diminished Vesicular Breathing.*

The causes of a diminution in the intensity of the breath sounds without any change in their type are very numerous. I shall mention them in an order corresponding as nearly as possible to the relative frequency of their occurrence.

(a) *Fluid, Air, or Solid in the Pleural Cavity.*—Probably the commonest cause for a diminution or total abolition of normal breath sounds is an accumulation of fluid in the pleural cavity such as occurs in inflammation of the pleura or by transudation (hydrothorax). In such cases the layer of fluid intervening between the lung and the stethoscope of the auscultator causes retraction of the lung so that little or no vesicular murmur is produced in it, and hence none is transmitted to the ear of the auscultator. An accumulation of air in the pleural cavity (pneumothorax) may diminish or abolish the breath sounds precisely as a layer of fluid does; in a somewhat different way a thickening of the costal or pulmonary pleura or a malignant growth of the chest wall may render the breath sounds feeble or prevent their being heard because the vibrations of the thoracic sounding-board are thus deadened. Which-ever of these causes, fluid or air or solid, intervenes between the lung and the ear of the auscultator, the breath sounds are deadened or diminished without, as a rule, any modification of their type. The amount of such diminution depends roughly on the thickness of the layer of extraneous substance, whether fluid, air, or solid.

Total absence of breath sounds may therefore be due to any one of these causes, provided the layer intervening between the lung and chest wall is of sufficient thickness to produce complete atelectasis of the lung or to deaden the vibrations of the chest wall.

(b) *Emphysema of the lung*, by destroying its elasticity and reducing the extent of its movements, makes the breath sounds relatively feeble, but seldom, if ever, abolishes them altogether.

(c) In *bronchitis* the breath sounds are usually considerably diminished owing to the filling up of the bronchi with secretion. This diminution, however, usually attracts but little attention, owing to the fact that the bubbling and squeaking sounds, which result from the passage of air through the bronchial secretions, distract our notice to such an extent that we find it difficult to concentrate attention upon the breath sounds, even if we do not forget altogether to listen to them. When, however, we succeed in listening *through the râles* to the breath sounds themselves, we usually notice that they are very feeble, especially over the lower two-thirds of the chest. *Œdema of the lung* may diminish the breath sounds in a similar way.

(d) *Pain in the thorax*, such as is produced by dry pleurisy or intercostal neuralgia, diminishes the breath sounds because it leads the patient to restrain, so far as possible, the movements of his chest, and so of his lungs. If, for any other reason, the full expansion of the lung does not take place, whether on account of the feebleness of the respiratory movements or because the lung is mechanically hindered by the presence of pleuritic adhesions, the breath sounds are proportionately feeble.

(e) *Occlusion of the upper air passages*, as by spasm or œdema of the glottis, renders the breathing very feeble on both sides of the chest. If one of the primary bronchi is occluded, as by a foreign body or by pressure of a tumor or enlarged gland from without, we get a unilateral enfeeblement of the breathing over the corresponding lung.

(f) Occasionally a paralysis of the muscles of respiration on one or both sides is found to result in a unilateral or bilateral enfeeblement of the breathing.

It should be remembered, when estimating the intensity of the breathing, that the sounds heard over the right lung are, as a rule, slightly more feeble than those heard over the left lung in the normal chest.

IV. BRONCHIAL OR TUBULAR BREATHING IN DISEASE.

(a) I have already described the occurrence of bronchial breathing in parts of the normal chest, namely, over the trachea and primary bronchi. In disease, bronchial breathing may be heard elsewhere in the chest, and usually points to solidification of that portion of lung from which it is conducted. It is heard most commonly in *phthisis* (see below, p. 251).

(b) *Croupous pneumonia* is probably the next most frequent cause of bronchial breathing, although by no means every case of croupous pneumonia shows this sign. For a more detailed account of the conditions under which it does or does not occur in croupous pneumonia, see below, p. 243. Lobular pneumonia is rarely manifested by tubular breathing.

(c) In about one-third of the cases of pleuritic effusion distant bronchial breathing is to be heard over the fluid. On account of the feebleness of the breath sounds in such cases they are often put down as absent, as we are so accustomed to associate intensity with the bronchial type of breathing. One should be always on the watch for any degree of intensity of bronchial breathing from the feeblest to the most distinct.

(d) Rarer causes of bronchial breathing are hemorrhagic infarction of the lung, syphilis, or malignant disease, any one of which may cause a solidification of a portion of the lung.

V. BRONCHO-VESICULAR BREATHING IN DISEASE.

Respiration of this type should be carefully distinguished from puerile or exaggerated breathing, in which we hear the normal vesicular respiration upon a large scale. I have already mentioned that broncho-vesicular breathing is normally to be heard over the apex of the right lung. In disease, broncho-vesicular breathing is heard in other portions of the lung, and usually denotes a moderate degree of solidification of the lung, such as occurs in early *phthisis* or in the earliest and latest stages of croupous pneumonia. In cases of pleuritic effusion, one can usually hear broncho-vesicular breath-

ing over the upper portion of the affected side, owing to the retraction of the lung at that point.

VI. AMPHORIC BREATHING (*Amphora* = *A Jar*).

Respirations having a hollow, empty sound like that produced by blowing across the top of a bottle, are occasionally heard in disease over pulmonary cavities (*e.g.*, in phthisis) or in pneumothorax, *i.e.*, under conditions in which the air passes in and out of a large empty cavity within the chest. Amphoric breathing never occurs in health. The pitch of both sounds is low, *but that of expiration lower than that of inspiration*. The intensity and duration of the sounds vary, and the distinguishing mark is their quality which resembles that of a whispered "*who*."

VII. RÂLES.

The term "râles" is applied to sounds produced by the passage of air through bronchi which contain mucus or pus, or which are narrowed by swelling of their walls.¹ Râles are best classified as follows:

(1) Moist or bubbling râles, including (*a*) coarse, (*b*) medium, and (*c*) fine râles.

(2) Dry or crackling râles (large, medium, or fine).

The smallest varieties of this type are known as "crepitant" or "subcrepitant" râles.

(3) Musical râles (high or low pitched).

Each of these varieties will now be described more in detail.

(1) *Moist or Bubbling Râles.*

The nature of these is sufficiently indicated by their name. The coarsest or largest bubbles are those produced in the trachea, and ordinarily known as the "*death rattle*." Tracheal râles occur

¹ Râles are of all auscultatory phenomena the easiest to appreciate, provided we exclude various accidental sounds which may be transmitted to the ear as a result of friction of the stethoscope against the skin or against the fingers of the observer. (See above, page 91.)

in any condition involving either profound unconsciousness or very great weakness, so that the secretions which accumulate in the trachea are not coughed out. Tracheal râles are by no means a sure precursor of death, although they are very common in the moribund state. They can usually be heard at some distance from the patient and without a stethoscope. In catarrh of the larger bronchi large bubbling râles are occasionally to be heard. In phthisical cavities one sometimes hears coarse, bubbling râles of a very metallic and gurgling quality (see below, p. 258). The finer grades of moist râles correspond to the finer bronchi.

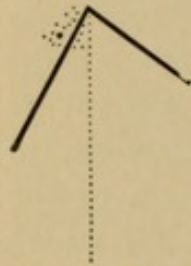


FIG. 75.—Explosion of Fine Râles at End of Inspiration.

In the majority of cases moist râles are most numerous during inspiration and especially during the latter part of this act. Their relation to respiration may be represented graphically as in Fig. 75, using large dots for coarse râles and small dots for fine râles. Musical râles can be symbolized by the letter *S* (squeaks).

(2) Crackling Râles.

These differ from the preceding variety merely by the absence of any distinct bubbling quality. They are usually to be heard in cases of bronchitis in which the secretions are unusually *tenacious and viscid*. They are especially apt to come at the end of inspiration, a large number being evolved in a very short space of time, so that one often speaks of an "*explosion of fine crackling râles*" at the end of inspiration. Crackling râles are to be heard in any one of the conditions in which bubbling râles occur, but are more frequent in tuberculosis than in simple bronchitis.

Crepitant râles, which represent the finest sounds of this type, are very much like the noise which is heard when one takes a lock of hair between the thumb and first finger and rubs the hairs upon each other while holding them close to the ear. A very large number of minute crackling sounds is heard following each other in rapid succession. To the inexperienced ear they may seem to blend into a continuous sound, but with practice the component parts may

be distinguished. This type of râles is especially apt to occur during inspiration alone, but not very infrequently they are heard during expiration as well. From subcrepitant râles they are distinguished merely by their being still finer than the latter.¹ Subcrepitant râles are often mixed with sounds of a somewhat coarser type, while crepitant râles are usually all of a size. If the chest is covered with hair, sounds precisely like these two varieties of râles may be heard when the stethoscope is placed upon the hairy portions. To avoid mistaking these sounds for râles one must thoroughly wet or grease the hair.

Crepitant Râles in Atelectasis.

Crepitant and subcrepitant râles are very often to be heard along the thin margins of the lungs at the base of the axillæ and in the back, especially when a patient who is breathing superficially first begins to take deep breaths. In such cases, they usually disappear after the few first respirations, and are then to be explained by the tearing apart of the slightly agglutinated surfaces of the finer bronchioles.

It is by no means invariably the case, however, that such subcrepitant râles are merely transitory in their occurrence. In a large number of cases they persist despite deep breathing. The frequency of subcrepitant râles, persistent or transitory, heard over the inferior margin of the normal lung at the bottom of the axilla, is shown by the following figures: Out of 356 normal chests to which I have listened especially for these râles, I found 228, or 61 per cent, which showed them on one or both sides. They are very rarely to be heard in persons under twenty years of age. After forty-five, on the other hand, it is unusual *not* to find them. In my experience they are considerably more frequent in the situation shown in Fig. 127 than in any other part of the lung, but they may be occasionally heard in the back or elsewhere. In view of

¹ A distinction was formerly drawn between crepitant and subcrepitant râles, on the ground that the latter were heard during both respiratory sounds and the former only during inspiration, but this distinction cannot be maintained and is gradually being given up.

these facts, it seems to me that we must recognize that it is almost if not quite physiological to find the finer varieties of crackling râles at the base of the axillæ in persons over forty years old. I have supposed these râles to be due to a partial atelectasis resulting from disease in the thin lower margin of the lungs. Such portions of the lung are ordinarily not expanded unless the respirations are forced and deep. This explanation would agree with the observations of Abrams, to which I shall refer later (see below, p. 298).

(b) Crepitant or subcrepitant râles are also to be heard in a certain portion of cases of pneumonia, in the very earliest stages and when resolution is taking place ("crepitans redux"). More rarely this type of râle may be heard in connection with tuberculosis, infarction, or œdema of the lung.

In certain cases of dry pleurisy there occur fine crackling sounds which can scarcely be differentiated from subcrepitant râles. I shall return to the description of them in speaking of pleural friction (see below, p. 278).

(3) *Musical Râles.*

The passage of air through bronchial tubes narrowed by inflammatory swelling of their lining membrane (bronchitis), or by spasmodic contraction (asthma), gives rise not infrequently to a multitude of musical sounds. Such a stenosis occurring in relatively large bronchial tubes produces a deep-toned *groaning* sound, while narrowing of the finer tubes results in *piping*, *squeaking*, *whistling* noises of various qualities. Such sounds are often known as "*dry râles*" in contradistinction to the "*bubbling râles*" above described, but as many non-musical crackling râles have also a very dry sound, it seems to me best to apply the more distinctive term "*musical râles*" to all adventitious sounds of distinctly musical quality which are produced in the bronchi. Musical râles are of all adventitious sounds the easiest to recognize but also the most fugitive and changeable. They appear now here, now there, shifting from minute to minute, and may totally disappear from the chest and reappear again within a very short time. This is to some extent true of all varieties of râles, but especially of the squeaking and groaning varieties.

Musical râles are heard, as a rule, more distinctly during expiration, especially when they occur in connection with asthma or emphysema. In these diseases one may hear quite complicated chords from the combinations of râles which vary in pitch.

VII. THE EFFECTS OF COUGH.

The influence of coughing upon râles is usually very marked. Its effect may be either to intensify them and bring them out where they have not previously been heard, or to clear them away altogether. Other effects of coughing upon physical signs will be mentioned later on in the chapters on Pneumonia and Phthisis.

VIII. PLEURAL FRICTION.

The surfaces of the healthy pleural cavity are lubricated with sufficient serum to make them pass noiselessly over each other during the movements of respiration. But when the tissues become abnormally dry, as in Asiatic cholera, or when the serous surfaces are roughened by the presence of a fibrinous exudation, as in ordinary pleurisy, the rubbing of the two pleural surfaces against one another produces peculiar and very characteristic sounds known as "*pleural friction sounds*." The favorite seat of pleural friction sounds is at the bottom of the axilla, *i.e.*, where the lung makes the widest excursion and where the costal and diaphragmatic pleura are in close apposition (see Fig. 33). In some cases pleural friction sounds are to be heard altogether below the level of the lung. In others they may extend up several inches above its lower margin, and occasionally it happens that friction may be appreciated over the whole lung from the top to the bottom. Very rarely friction sounds are heard only at the apex of the lung in early tuberculosis.

The sound of pleural friction may be closely imitated by holding the thumb and forefinger close to the ear, and rubbing them past each other with strong pressure, or by pressing the palm of one hand over the ear and rubbing upon the back of this hand with

the fingers of the other. Pleural friction is usually a catchy, jerky, interrupted, irregular sound, and is apt to occur during inspiration only, and particularly at the end of this act. It may, however, be heard with both respiratory acts, but rarely if ever occurs during expiration alone. The intensity and quality of the sounds vary a great deal, so that they may be compared to *grazing, rubbing, rasping, and creaking* sounds. They are sometimes spoken of as "*leathery*." As a rule, they seem very near to the ear, and are sometimes startlingly loud. In many cases they cannot be heard after the patient has taken a few full breaths, probably because the rough pleural surfaces are smoothed down temporarily by the friction which deep breathing produces. After a short rest, however, and a period of superficial breathing, pleural friction sounds often return and can be heard for a short time with all their former intensity. They are increased by pressure exerted upon the outside of the chest wall. Such pressure had best be made with the hand or with the Bowles stethoscope, since the sharp edges of the chest-piece of the ordinary stethoscope may give rise to considerable pain; but if such pressure is made with the hand, one must be careful not to let the hand shift its position upon the skin, else rubbing sounds may thus be produced which perfectly simulate pleural friction. In well-marked cases pleuritic friction can be *felt* if the palm of the hand is laid over the suspected area; occasionally the sound is so loud that it can be heard by the patient himself or by those around him.

In doubtful cases, or when a friction sound appears to have disappeared, and when one wishes to bring it out again, there are several manœuvres suggested by Abrams for obtaining this en'

(a) *The Arm Manœuvre.*

The patient suspends respiration altogether, and the arm upon the affected side is raised over the head by the patient himself or by the physician, as in performing Sylvester's method of artificial respiration. During this movement we listen over the suspected area. "By this manœuvre the movement of the parietal against the visceral pleura is opposite in direction to that occurring during the

respiratory act, and for this reason the pleuritic sound may often be elicited after it has been exhausted in the ordinary act of breathing."

(b) *The Decubital Manœuvre.*

"Let the patient lie upon the affected side for a minute or two, then let him rise quickly and suspend respiration. Now listen over the affected area, at the same time directing the patient to take a deep breath."

Pleuritic friction sounds are distinguished from râles by their greater superficiality, by their jerky, interrupted character, by the fact that they are but little influenced by cough, and that they are increased by pressure. It has already been mentioned, however, that there is one variety of sounds which we have every reason to think originate in the pleura, which cannot be distinguished from certain varieties of crackling bronchial râles. Such sounds occur chiefly in connection with phthisical processes, in which both pleurisy and bronchitis are almost invariably present, and it is seldom of importance to distinguish the two.

IX. AUSCULTATION OF THE SPOKEN OR WHISPERED VOICE SOUNDS.

The more important of these is:

(a) *The Whispered Voice.*

The patient is directed to whisper "one, two, three," or "ninety-nine," while the auscultator listens over different portions of the chest to see to what degree the whispered syllables are transmitted. In the great majority of normal chests the whispered voice is to be heard only over the trachea and primary bronchi in front and behind, while over the remaining portions of the lung little or no sound is to be heard. When, on the other hand, solidification of the lung is present, the whispered voice may be distinctly heard over portions of the lung relatively distant from the trachea and bronchi; for example, over the lower lobes of the lung behind. The usefulness of the whispered voice in the search for small areas of solidification or for the exact boundaries of a solidi-

fied area is very great, especially when we desire to save the patient the pain and fatigue of taking deep breaths. Whispered voice sounds are practically equivalent to a forced expiration and can be obtained with very little exertion on the patient's part. The increased transmission of the whispered voice is, in my opinion, a more delicate test for solidification than tubular breathing. The latter sign is present only when a considerable area of lung tissue is solidified, while the increase of the whispered voice may be obtained over much smaller areas. Retraction of the lung above the level of a pleural effusion causes a moderate increase in the transmission of the whispered voice, and at times this increased or bronchial whisper is to be heard over the fluid itself, probably by transmission from the compressed lung above.

Where the lung is completely solidified the whispered words may be clearly distinguished over the affected area. In lesser degrees of solidification the syllables are more or less blurred.

(b) *The Spoken Voice.*

The evidence given us by listening for the spoken voice in various parts of the chest is considerably less in value than that obtained through the whispered voice. As a rule, it corresponds with the tactile fremitus, being increased in intensity by the same causes which increase tactile fremitus, viz., solidification or condensation of the lung, and decreased by the same causes which decrease tactile fremitus—namely, by the presence of air or water in the pleural cavity, by the thickening of the pleura itself, or by an obstruction of the bronchus leading to the part over which we are listening. In some cases the presence of solidification of the lung gives rise not merely to an increase in transmission of the spoken voice, but to a change in its quality, so that it sounds abnormally concentrated, nasal, and near to the listener's ear. The latter change may be heard over areas where tactile fremitus is not increased, and even where it is diminished. Where this change in the quality of the voice occurs, the actual words spoken can often be distinguished in a way not usually possible over either normal or solidified lung. "Bronchophony," or the distinct transmission

of audible words, and not merely of diffuse, unrecognizable voice sounds, is considerably commoner in the solidifications due to pneumonia than in those due to phthisis; it occurs in some cases of pneumothorax and pulmonary cavity.

(c) *Egophony.*

Among the least important of the classical physical signs is a nasal or squeaky quality of the sounds which reach the observer's ear when the patient speaks in a natural voice. To this peculiar quality of voice the name of "egophony" has been given. It is most frequently heard in cases of moderate-sized pleuritic effusion just about the level of the lower angle of the scapula and in the vicinity of that point. Less often it is heard at the same level in front. It is very rarely heard in the upper portion of the chest and is by no means constant either in pleuritic effusion or in any other condition. A point at which it is heard corresponds not, as a rule, with the upper level of the accumulated fluid, as has been frequently supposed, but often with a point about an inch farther down. The presence of egophony is in no way distinctive of pleuritic effusions and may be heard occasionally over solidified lung.

X. PHENOMENA PECULIAR TO PNEUMOHYDROTHORAX AND PNEUMOPYOTHORAX.

(1) *Succussion.*

Now and then a patient consults a physician, complaining that he hears noises inside him as if water were being shaken about. One such patient expressed himself to me to the effect that he felt "like a half-empty bottle." In the chest of such a patient, if one presses the ear against any portion of the thorax and then shakes the whole patient strongly, one may hear loud splashing sounds known technically as "*succussion*." Such sounds are absolutely diagnostic of the presence of *both air and fluid* in the cavity over which they are heard. Very frequently they may be detected by the physician when the patient is not aware of their presence. Oc-

asionally the splashing of the fluid within may be felt as well as heard. It is essential, of course, to distinguish succussion due to the presence of air and fluid in the pleural cavity from similar sounds produced in the stomach, but this is not at all difficult in the majority of cases. It is a bare possibility that succussion sounds may be due to the presence of air and fluid in the pericardial cavity.

It is important to remember that succussion is never to be heard in simple pleuritic effusion or hydrothorax. The presence of air, as well as liquid, in the pleural cavity is absolutely essential to the production of succussion sounds.¹

(2) *Metallic Tinkle or Falling-Drop Sound.*

When listening over a pleural cavity which contains both air and fluid, one occasionally hears a liquid, tinkling sound, due possibly to the impact of a drop of liquid falling from the relaxed lung above into the accumulated fluid at the bottom of the pleural cavity, and possibly to râles produced in the tissues around the cavity. It is stated that this physical sign may in rare cases be observed in large-sized phthisical cavities as well as in pneumohydrothorax and pneumopyothorax.

(3) *The Lung-Fistula Sound.*

When a perforation of the lung occurs below the level of the fluid accumulated in the pleural cavity, bubbles of air may be forced out from the lung and up through the fluid with a sound reminding one of that made by children when blowing soap-bubbles.

¹It is well for the student to try for himself the following experiment, which I have found useful in impressing these facts upon the attention of classes in physical diagnosis: Fill an ordinary rubber hot-water bag to the brim with water. Invert it and squeeze out forcibly a certain amount (perhaps half) of the contents, by grasping the upper end of the bag and compressing it. While the water is thus being forced out, screw in the nozzle of the bag. Now shake the whole bag, and it will be found impossible to produce any splashing sounds owing to the fact that there is no air in the bag. Unscrew the nozzle, admit air, and then screw it in again. Now shake the bag again and loud splashing will be easily heard.

CHAPTER V.

AUSCULTATION OF THE HEART.

I. "VALVE AREAS."

IN the routine examination of the heart, most observers listen in four places:

(1) At the apex of the heart in the fifth intercostal space near the nipple, the "*mitral area*."

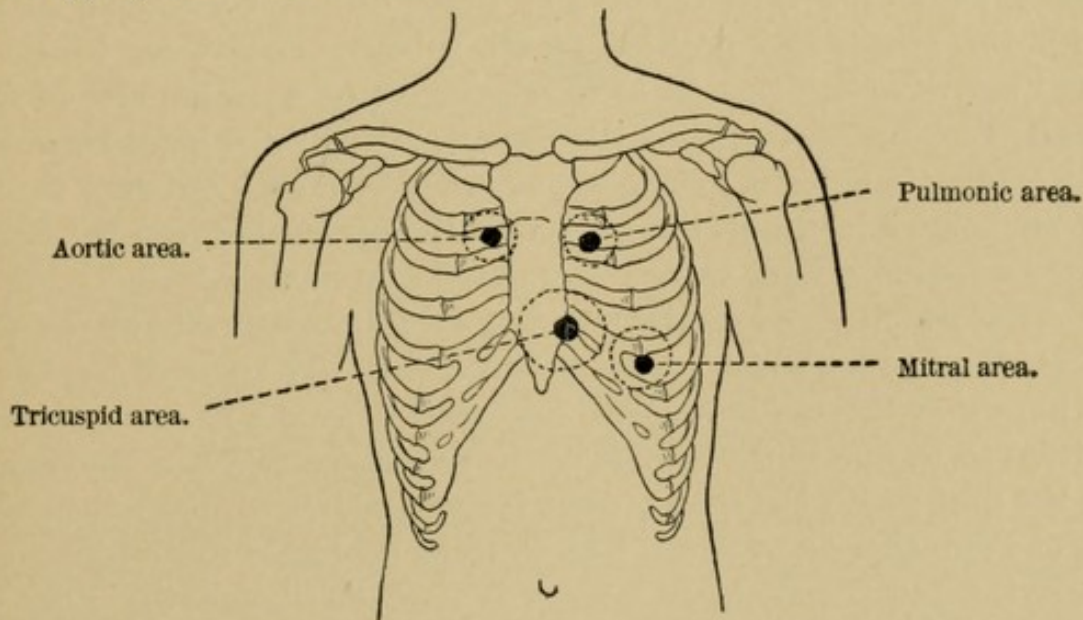


FIG. 76.—The Valve Areas.

(2) In the second left intercostal space near the sternum, the "*pulmonic area*."

(3) In the second right intercostal space near the sternum, the "*aortic area*."

(4) At the bottom of the sternum near the ensiform cartilage, the "*tricuspid area*."

These points are represented in Fig. 76 and are known as

"*valve areas.*" They do *not* correspond to the anatomical position of any one of the four valves, but experience has shown that sounds heard best at the apex can be proved (by post-mortem examination or otherwise) to be produced at the mitral orifice. Similarly sounds heard best in the second left intercostal space are proved to be produced at the pulmonary orifice; those which are loudest at the second right intercostal space to be produced at the aortic orifice;¹ while those which are most distinct near the origin of the ensiform cartilage are produced at the tricuspid orifice.

II. THE NORMAL HEART SOUNDS.

A glance at Fig. 77, which represents the anatomical positions of the four valves above referred to, illustrates what I said above; namely, that the traditional valve areas do not correspond at all with the anatomical position of the valves. If now we listen in the "*mitral area*," that is, in the region of the apex impulse of the heart, keeping at the same time one finger on some point at which the cardiac impulse is palpable, one hears with each outward thrust of the heart a low, dull sound, and in the period between the heart beats a second sound, shorter and sharper in quality.²

That which occurs with the cardiac impulse is known as the *first sound*; that which occurs between each two beats of the heart is known as the *second sound*. The second sound is generally admitted to be due to the closure of the semilunar valves. The cause of the first sound has been a most fruitful source of discussion, and no one explanation of it can be said to be generally received. Perhaps the most commonly accepted view attributes the first or systolic sound of the heart to a combination of two elements—

- (a) The contraction of the heart muscle itself.
- (b) The sudden tautening of the mitral curtains.

Following the second sound there is a pause corresponding to

¹ For exceptions to this rule, see below, page 181.

² The first sound of the heart, as heard at the apex, may be imitated by holding a linen handkerchief by the corners and suddenly tautening one of the borders. To imitate the second sound, use one-half the length of the border instead of the whole.

the diastole of the heart. Normally this pause occupies a little more time than the first and second sounds of the heart taken together. In disease it may be much shortened.

The first sound of the heart is not only longer and duller than the second (it is often spoken of as "booming" in contrast with the "snapping" quality of the second sound) but is also considerably more intense, so that it gives us the impression of being accented like the first syllable of a trochaic rhythm. After a little practice one grows so accustomed to this rhythm that one is apt to rely upon

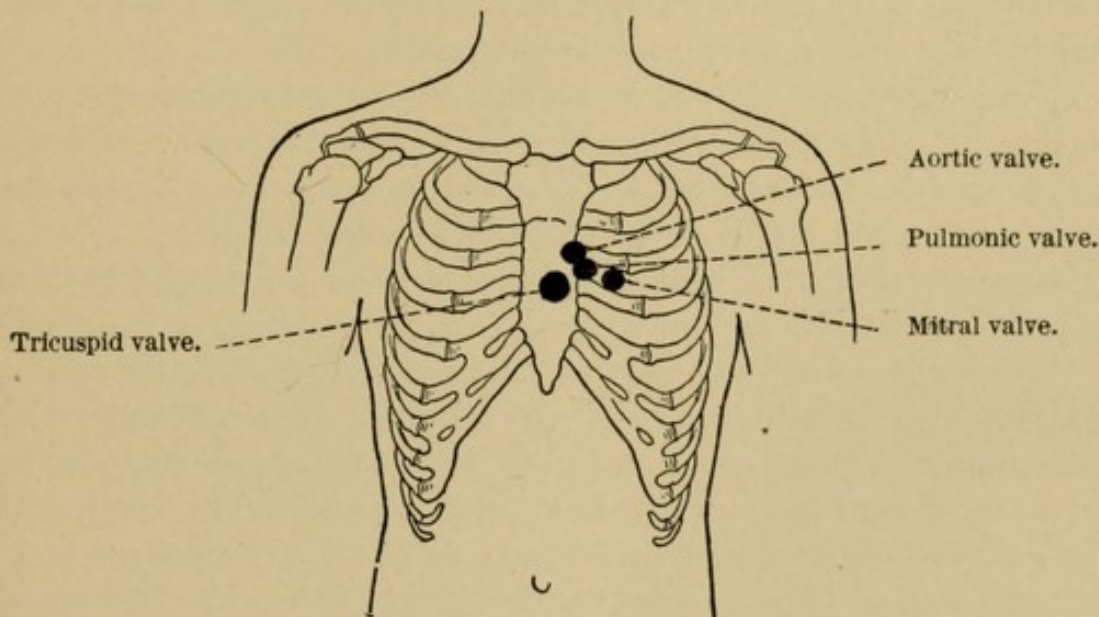


FIG. 77.—Anatomical Position of the Cardiac Valves.

his appreciation of the rhythm alone for the identification of the systolic sound. This is, however, an unsafe practice and leads to many errors. Our impression as to which of the two sounds of each cardiac cycle corresponds to systole should always be verified either by sight or touch. We must either see or feel the cardiac impulse and assure ourselves that it is synchronous with the heart sound which we take to be systolic.¹ This point is of especial importance in the recognition and identification of cardiac murmurs, as will be seen presently.

¹ When the cardiac impulse can be neither seen nor felt, the pulsation of the carotid will generally guide us. The radial pulse is not a safe guide.

So far, I have been describing the normal heart sounds heard in the "mitral area," that is, at the apex of the heart. If now we listen over the pulmonary area (in the second left intercostal space), we find that the rhythm of the heart sounds has changed and that here the stress seems to fall upon the "second sound," *i.e.*, that corresponding to the beginning of diastole; in other words, the first sound of the heart is here heard more feebly and the second sound more distinctly. The sharp, snapping quality of the latter is here even more marked than at the apex, and despite the feebleness of the first sound in this area we can usually recognize its relatively dull and prolonged quality.

Over the *aortic area* (*i.e.*, in the second right interspace) the rhythm is the same as in the pulmonary area, although the second sound may be either stronger or weaker than the corresponding sound on the other side of the sternum (see below, p. 122).

Over the tricuspid area one hears sounds practically indistinguishable in quality and in rhythm from those heard at the apex.

When the chest walls are thick and the cardiac sounds feeble, it may be difficult to hear them at all. In such cases the heart sounds may be heard much more distinctly if the patient leans forward and toward his own left so as to bring the heart closer to the front of the chest. Such a position of the body also renders it easier to map out the outlines of the cardiac dulness by percussion.

In cardiac neuroses and during conditions of excitement or emotional strain, the first sound at the apex is not only very loud but has often a curious *metallic reverberation* ("*cliquetis metallique*") corresponding to the trembling, jarring cardiac impulse (often mistaken for a thrill) which palpation reveals.

III. MODIFICATIONS IN THE INTENSITY OF THE HEART SOUNDS.

It has already been mentioned that in young persons with thin, elastic chests, the heart sounds are heard with greater intensity than in older persons whose chest walls are thicker and stiffer. In obese, indolent adults it is sometimes difficult to hear any heart sounds at all, while in young persons of excitable temperament the sounds may have a very intense and ringing quality. Under dis-

eased conditions either of the heart sounds may be increased or diminished in intensity. I shall consider

(1) *The First Sound at the Apex (sometimes Called the Mitral First Sound).*

(a) Increase in the length or intensity of the first sound at the apex of the heart occurs in any condition which causes the heart to act with unusual degree of force, such as bodily or mental exertion, or excitement. In the earlier stages of infectious fevers a similar increase in the intensity of this sound may sometimes be noted. Hypertrophy of the left ventricle sometimes has a similar effect upon the sound, but less often than one would suppose, while dilatation of the left ventricle, contrary to what one would suppose, is not infrequently associated with a loud, forcible first sound at the apex. In mitral stenosis the first sound is usually very intense and is often spoken of as a "thumping first sound" or as a "sharp slap."

(b) Shortening and weakening of the first sound at the apex.

In the course of continued fevers and especially in typhoid fever the granular degeneration which takes place in the heart muscle is manifested by a shortening and weakening of the first sound at the apex, so that the two heart sounds come to seem much more alike than usual. In the later stages of typhoid, the first sound may become almost inaudible. The sharp "valvular" quality, which one notices in the first apex sound under these conditions, has been attributed to the fact that weakening of the myocardium has caused a suppression of one of the two elements which go to make up the first sound, namely, the muscular element, so that we hear only the short, sharp sound due to the tautening of the mitral curtains. Chronic myocarditis, or any other change in the heart wall which tends to enfeeble it, produces a weakening and shortening of the first sound similar to that just described. Simple weakness in the mitral first sound without any change in its duration or pitch may be due to fatty overgrowth of the heart, to emphysema or pericardial effusion in case the heart is covered by the distended lung or by the accumulated fluid. Among valvular diseases of the heart

the one most likely to be associated with a diminution in intensity of the first apex sound is mitral regurgitation.

(c) Doubling of the first sound at the apex.

It is not uncommon in healthy hearts to hear in the region of the apex impulse a doubling of the first sound so that it may be suggested by pronouncing the syllables "turrupp" or "trupp." In health this is especially apt to occur at the end of expiration. In disease it is associated with many different conditions involving an increase in the work of one or the other side of the heart. It seems, however, to be unusually frequent in myocarditis.

(2) *Modifications in the Second Sounds as Heard at the Base of the Heart.*

Physiological Variations.—The relative intensity of the pulmonic second sound, when compared with the second sound heard in the conventional aortic area, varies a great deal at different periods of life. Attention was first called to this by Vierordt,¹ and it has of late years been recognized by the best authorities on diseases of the heart, though the majority of current text-books still repeat the mistaken statement that the aortic second sound is always louder than the pulmonic second in health.

The work of Dr. Sarah R. Creighton, done in my clinic during the summer of 1899, showed that in 90 per cent of healthy children under ten years of age, the pulmonic second sound is louder than the aortic. In the next decade (from the tenth to the twentieth year) the pulmonic second sound is louder in two-thirds of the cases. About half of 207 cases, between the ages of twenty and twenty-nine, showed an accentuation of the pulmonic second, while after the thirtieth year the number of cases showing such accentuation became smaller with each decade, until after the sixtieth year we found an accentuation of the *aortic second in sixty-six out of sixty-eight cases* examined. These facts are exhibited in tabular form in

¹ Vierordt: "Die Messung der Intensität der Herztöne" (Tübingen, 1885). See also Hochsinger, "Die Auscultation des kindlichen Herzens"; Gibson, "Diseases of the Heart" (1898); Rosenbach, "Diseases of the Heart" (1900); Allbutt, "System of Medicine."

Figs. 78 and 79 and appear to show that the relative intensity of the two sounds in the aortic and pulmonic arteries depends primarily upon the age of the individual, the pulmonic sound predominating in youth and the aortic in old age, while in the period of middle life there is relatively little discrepancy between the two.

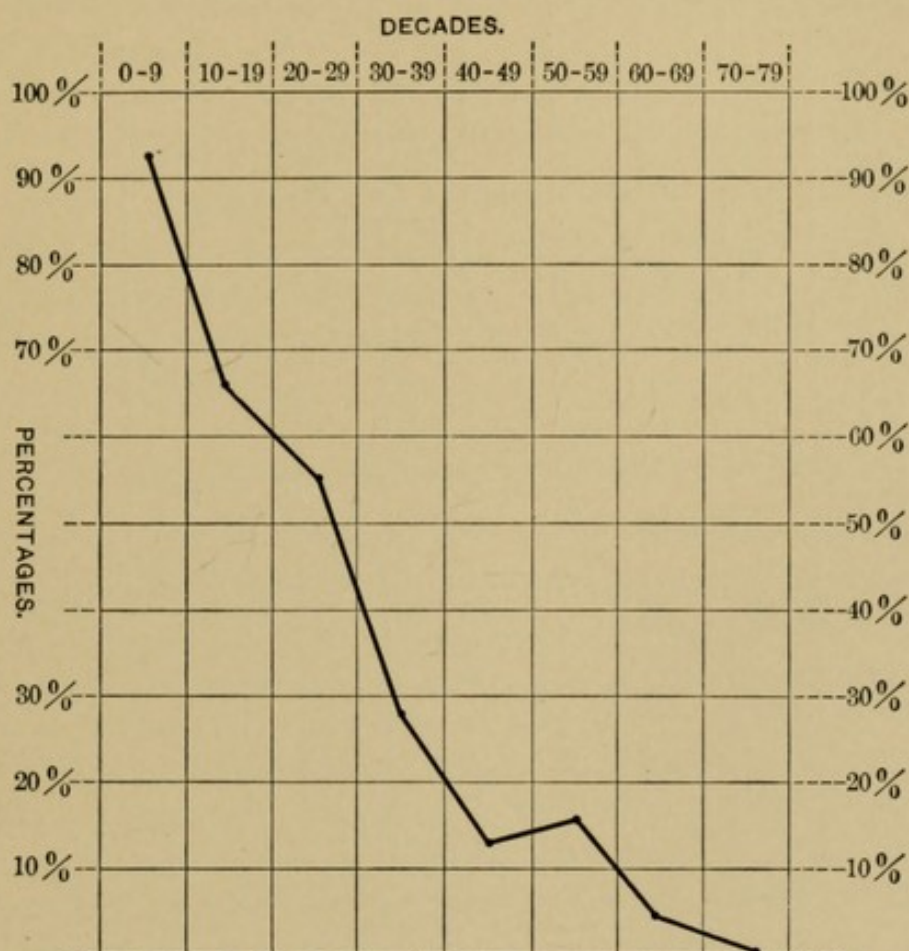


FIG. 78.—Showing the Per Cent of Accentuated Pulmonic Second Sound in Each Decade. Based on 1,000 cases.

It is, therefore, far from true to suppose that we can obtain evidence of a pathological increase in the intensity of either of the second sounds at the base of the heart simply by comparing it with the other. Pathological accentuation of the pulmonic second sound must mean a greater loudness of this sound *than should be expected at the age of the patient in question*, and not simply a greater intensity than that of the aortic second sound. The same

observation obviously applies to accentuation of the aortic second sound.

Both the aortic and the pulmonic second sounds are sometimes

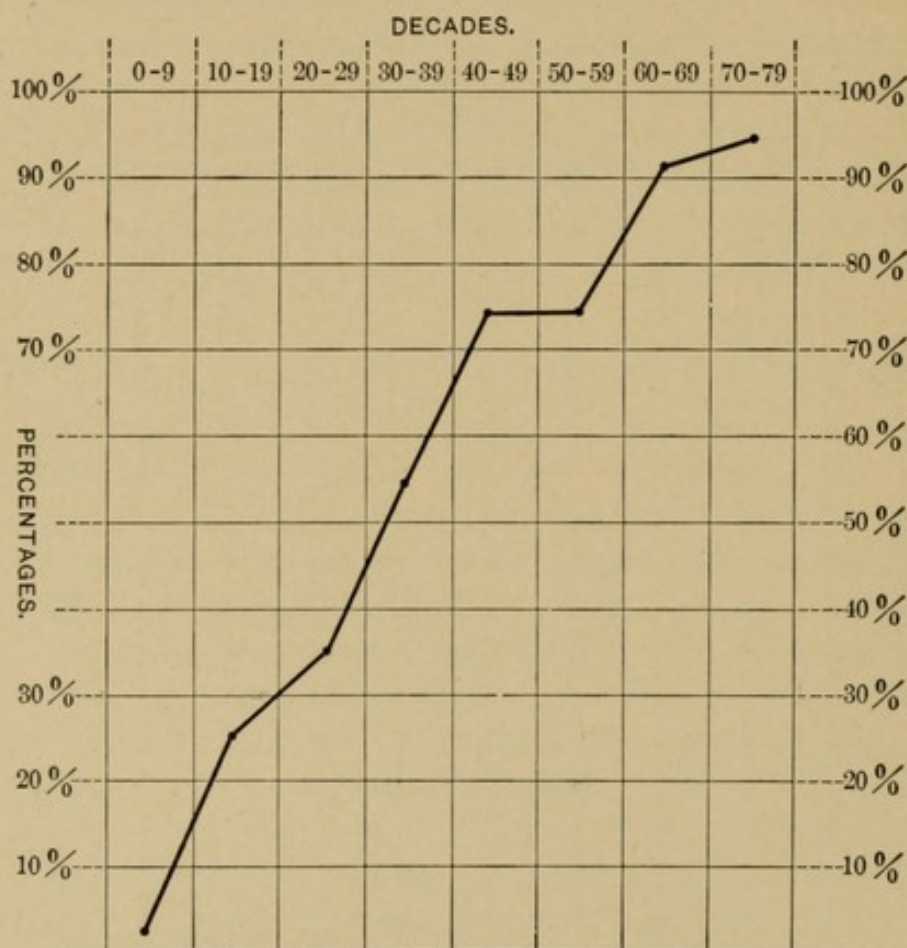


FIG. 79.—Showing the Per Cent of Accentuated Aortic Second Sound in Each Decade. Based on 1,000 cases.

very intense during great emotional excitement or after muscular exertion, and sometimes without any obvious cause.

Pathological Variations.

A. Accentuation of the Pulmonic Second Sound.

Pathological accentuation of the second sound occurs especially in conditions involving a backing up of blood in the lungs, such as occurs in stenosis or insufficiency of the mitral valve, or in obstruc-

tive disease of the lungs (emphysema, bronchitis, phthisis, chronic interstitial pneumonia). Indirectly accentuation of the pulmonic second sound points to hypertrophy of the right ventricle, since without such hypertrophy the work of driving the blood through the obstructed lung could not long be performed. If the right ventricle becomes weakened, the accentuation of the pulmonic second sound is no longer heard.

B. Weakening of the Pulmonic Second Sound.

Weakening of the pulmonic second sound is a very serious symptom, sometimes to be observed in cases of pneumonia or cardiac disease near the fatal termination. It is thus a very important indication for prognosis, and is to be watched for with the greatest attention in such cases.

C. Accentuation of the Aortic Second Sound.

I have already shown that the aortic second sound is louder than the corresponding sound in the pulmonary area in almost every individual over sixty years of age and in most of those over forty. A still greater intensity of the aortic second sound occurs—

(a) In interstitial nephritis or any other condition which increases arterial tension and so throws an increased amount of work upon the left ventricle. Indirectly, therefore, a pathologically loud aortic sound points directly to increased tension in the peripheral arteries and indirectly to hypertrophy of the left ventricle.

(b) A similar increase in the intensity of the aortic second sound occurs in aneurism or diffuse dilatation of the aortic arch.

D. Diminution in the Intensity of the Aortic Second Sound.

Whenever the amount of blood thrown into the aorta by the contraction of the left ventricle is diminished, as is the case especially in mitral stenosis and to a lesser degree in mitral regurgitation, the aortic second sound is weakened so that at the apex it may be inaudible. A similar effect is produced by any disease which weakens the walls of the left ventricle, such as fibrous myo-

carditis, fatty degeneration, and cloudy swelling. Relaxation of the peripheral arteries has the same effect. In conditions of collapse the aortic second sound may be almost or quite inaudible.

In persons past middle life the second sounds are often louder in the third or fourth interspace than in the second, so that if we listen only in the second space we may gain the false impression that the second sounds are feeble.

Accentuation of both the second sounds at the base of the heart may occur in health from nervous causes or when the lungs are retracted by disease so as to uncover the conus arteriosus and the aortic arch. Under these conditions the second sound may be seen and felt as well as heard. In a similar way, an apparent increase in the intensity of either one of the second sounds at the base of the heart may be produced by a retraction of one or the other lung.

Summary.—(1) The *mitral first sound* is increased by hypertrophy or dilatation of the left ventricle, and among valvular diseases especially by mitral stenosis. It is weakened or reduplicated by parietal disease of the heart. Any of these changes may occur temporarily from physiological causes.

(2) The *pulmonic second sound* is usually more intense than the aortic in children and up to early adult life. Later the aortic second sound predominates. Pathological accentuation of the second pulmonic sound usually points to obstruction in the pulmonary circulation (mitral disease, emphysema, etc.). Weakening of the pulmonic second means failure of the right ventricle and is serious.

(3) The *aortic second sound* is increased pathologically by any cause which increases the work of the left ventricle (arteriosclerosis, chronic nephritis). It is diminished when the blood stream, thrown into the aorta by the left ventricle, is abnormally small (mitral disease, cardiac failure).

(4) Changes in the tricuspid sounds are rarely recognizable, while changes in the first aortic and pulmonic sounds have little practical significance.

Modifications in the Rhythm of the Cardiac Sounds.

(1) Whenever the walls of the heart are greatly weakened by disease, for example, in the later weeks of a case of typhoid fever, the diastolic pause of the heart is shortened so that the cardiac sounds follow each other almost as regularly as the ticking of a clock; hence the term "*tick-tack* heart." As this rhythm is not unlike that heard in the foetal heart, the name of "*embryocardia*" is sometimes applied to it. The "*tick-tack*" rhythm may be heard in any form of cardiac disease after compensation has failed, or in any condition leading to collapse.

(2) A less common change of rhythm is that produced by a shortening of the interval between the two heart sounds owing to an incompleteness of the contraction of the ventricle. This change may occur in any disease of the heart when compensation fails.

(3) *The "Gallop Rhythm."*—Shortening of the diastolic pause together with doubling of one or another of the cardiac sounds results in our hearing at the apex of the heart three sounds instead of two, which follow each other in a rhythm suggesting the hoof beats of a galloping horse. Such a rhythm may occur temporarily in any heart which is excited or overworked from any cause, but when permanent is usually a sign of *grave cardiac weakness*. The rhythms so produced are usually anapæstic, $\cup \cup \text{—}'$, $\cup \cup \text{—}'$, $\cup \cup \text{—}'$, or of this type: $\cup \text{—}' \cup$, $\cup \text{—}' \cup$, $\cup \text{—}' \cup$.

Doubling of the Second Sounds at the Base of the Heart.—At the end of a long inspiration this change may be observed in almost any healthy person if one listens at the base of the heart. It is still better brought out after muscular exertion or by holding the breath. In such cases it probably expresses the non-synchronous closure of the aortic and pulmonic valves, owing to increased pressure in the pulmonary circulation. Similarly in diseased conditions, anything which increases the pressure either in the peripheral arteries or in the pulmonary circulation, and thus throws increased work upon one or the other ventricle, will cause a doubling of the second sound as heard at the base of the heart.

In mitral stenosis a double diastolic sound is usually to be

heard at the apex, and in the diagnosis of this disease this "double shock sound" during diastole may be an important piece of evidence, and may sometimes be felt as well as heard. The "double shock sound" of mitral stenosis is not generally believed to represent a doubling of the ordinary second sound, although it corresponds with diastole. Just what its mechanism is, is disputed.

I have said nothing about modifications in the second sound at the apex, since this sound is now generally agreed to represent the aortic second sound transmitted by the left ventricle to the apex. The first sounds at the base of the heart have also not been dwelt upon, since they have no special importance in diagnosis.

Metallic Heart Sounds.

The presence of air in the immediate vicinity of the heart, as, for example, in pneumothorax or in gaseous distention of the stomach or intestine, may impart to the heart sounds a curious metallic quality such as is not heard under any other conditions.

"Muffling," "Prolongation," or "Unclearness" of the Heart Sounds.

These terms are not infrequently met with in literature, but their use should, I think, be discontinued. The facts to which they refer should be explained either as faintness of the heart sounds, due to the causes above assigned, or as faint, short murmurs. In their present usage such terms as "muffled" or "unclear" heart sounds represent chiefly an unclearness in the mind of the observer as to just what it is that he hears, and not any one recognized pathological condition in the heart.

IV. SOUNDS AUDIBLE OVER THE PERIPHERAL VESSELS.

(1) The normal heart sounds are in adults audible over the carotids and over the subclavian arteries. In childhood and youth only the second heart sound is thus audible.

(2) In about 7 per cent of normal persons a systolic sound can be heard over the femoral artery. This sound is obviously not

transmitted from the heart, and is usually explained as a result of the sudden systolic tautening of the arterial wall.

In aortic regurgitation this arterial sound is almost always audible not only in the femoral but in the brachial and even in the radial, and its intensity over the femoral becomes so great that the term "pistol-shot" sound has been applied to it. In fevers, exophthalmic goitre, lead poisoning, and other diseases, a similar arterial sound is to be heard much more frequently than in health.

Venous Sounds.

The violent closure of the venous valves in the jugular is sometimes audible in cases of insufficiency of the tricuspid valve. The sound has no clinical importance, and is difficult to distinguish owing to the presence of the carotid first sound mentioned above.

CHAPTER VI.

AUSCULTATION OF THE HEART: CONTINUED.

CARDIAC MURMURS.

(a) *Terminology.*

THE word "*murmur*" is one of the most unfortunate of all the terms used in the description of physical signs. No one of the various blowing, whistling, rolling, rumbling, or piping noises to which the term refers, sounds anything like a "murmur" in the ordinary sense of the word. Nevertheless, it does not seem best to try to replace it by any other term. The French word "*souffle*" is much more accurate and has become to some extent Anglicized. Under the head of cardiac murmurs are included all abnormal sounds produced within the heart itself. Pericardial friction sounds and those produced in that portion of the lung or pleura which overlies the heart are not considered "murmurs."

(b) *Mode of Production.*

With rare exceptions all cardiac murmurs are produced at or near one of the valve orifices, either by disease of the valves themselves resulting in shrivelling, thickening, stiffening, and narrowing of the valve curtains, or by a stretching of the orifice into which the valves are inserted.

Diseases of the valves themselves may lead to the production of murmurs:

(a) When the valves fail to close at the proper time (incompetence, insufficiency, or regurgitation).

(b) When the valves fail to open at the proper time (stenosis or obstruction).

(c) When the surfaces of the valves or of the parts immediately adjacent are roughened so as to prevent the smooth flow of the blood over them.

(d) When the orifice which the valves are meant to close is dilated as a result of dilatation of the heart chamber of which it forms

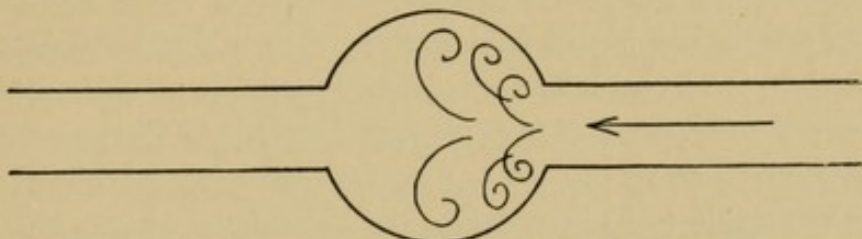

FIG. 80.—Diagram to Illustrate the Production of a Cardiac Murmur Through Regurgitation from the Aorta or in an Aneurismal Sac. The arrow shows the direction of the blood current and the curled lines the audible blood eddies.

the entrance or exit. The valves themselves cannot enlarge to keep pace with the enlargement of the orifice, and hence no longer suffice to reach across it.

The presence of any one of these lesions gives rise to eddies in the blood current and thereby to the abnormal sounds to which we give the name murmurs.¹ (See Figs. 80, 81 and 82). When

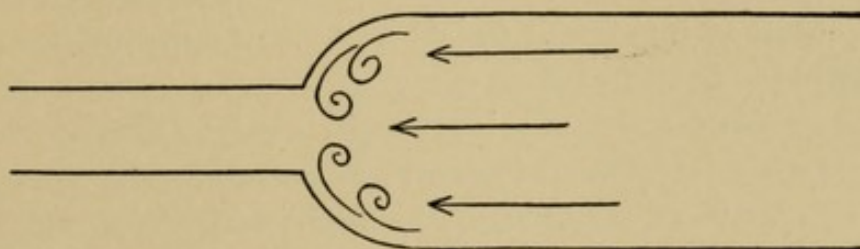


FIG. 81.—Diagram to Illustrate the Production of a Cardiac Murmur Through Stenosis of a Valve-Orifice.

valves fail to close and so allow the blood to pass back through them, we speak of the lesion as *regurgitation*, *insufficiency*, or *incompetence*; if, for example, the aortic valves fail to close after the left ventricle has thrown a column of blood into the aorta, some of this blood regurgitates through these valves into the ven-

¹ The method by which functional murmurs are produced will be discussed later. (See page 140.)

tricle from which it has just been expelled, and we speak of the lesion as "*aortic regurgitation*," and of the murmur so produced as an *aortic regurgitant murmur* or a murmur of aortic regurgitation. A similar regurgitation from the left ventricle into the left auricle takes place in case the mitral valve fails to close at the beginning of systole. If, on the other hand, the mitral valve fails to open properly to admit the blood which should flow during diastole from the left auricle into the left ventricle, we speak of the condition as *mitral stenosis* or *mitral obstruction*. A similar narrowing of the aortic valves such as to hinder the egress of blood during the systole of the left ventricle is known as *aortic stenosis* or obstruction. Val-



FIG. 82.—Diagram to Illustrate the Production of Cardiac Murmurs Through Roughening of a Valve.

vular lesions of the right side of the heart (tricuspid and pulmonic valves) are comparatively rare, but are produced and named in a way similar to those just described.

The facts most important to know about a murmur are :

- (1) Its place in the cardiac cycle.
- (2) Its point of maximum intensity.
- (3) The area over which it can be heard.
- (4) The effects of exertion, respiration, or position upon it.

Less important than the above are :

- (5) Its intensity.
- (6) Its quality.
- (7) Its length.
- (8) Its relation to the normal sounds of the heart.

Each of these points will now be taken up in detail :

(1) *Time of Murmurs*.—The first and most important thing to ascertain regarding a murmur is its relation to the normal cardiac cycle ; that is, whether it occurs during systole or during diastole, or in case it does not fill the whole of one of those periods, in what

part of systole or diastole it occurs. It must be borne in mind that the period of systole is considered as lasting from the beginning of the first sound of the heart up to the occurrence of the second sound, while diastole lasts from the beginning of the second sound until the beginning of the first sound in the next cycle. Any murmur occurring with the first sound of the heart, or at the time when the first sound should take place, or in any part of the period intervening between the first sound and the second, is held to be *systolic*. Murmurs which distinctly follow the first sound or do not begin until the first sound is ended are known as *late systolic* murmurs.

On the other hand, it seems best, for reasons to be discussed more in detail later on, not to give the name of *diastolic* to all murmurs which occur within the diastolic period as above defined. Murmurs which occur during the last part of diastole and which run up to the first sound of the next cycle are usually known as "*presystolic*" murmurs. All other murmurs occurring during diastole are known as *diastolic*.

The commonest of all the errors in the diagnosis of disease of the heart is to mistake systole for diastole, and thereby to misinterpret the significance of a murmur heard during those periods. This mistake would never happen if we were always careful to make sure, by means of sight or touch, just when the systole of the heart occurs. This may be done by keeping one finger upon the apex impulse of the heart or upon the carotid artery while listening for murmurs, or, in case the apex impulse or the pulsations of the carotid are better seen than felt, we can control by the eye the impressions gained by listening. It is never safe to trust our appreciation of the cardiac rhythm to tell us which is the first heart sound and which the second. The proof of this statement is given by the numberless mistakes made through disregarding it. Equally untrustworthy as a guide to the time of systole and diastole is the radial pulse, which follows the cardiac systole at an interval just long enough to mar our calculations.

(2) *Localizations of Murmurs*.—To localize a murmur is to find its point of maximum intensity, and this is of the greatest importance in diagnosis. Long experience has shown that murmurs

heard loudest in the region of the apex beat (whether this is in the normal situation or displaced), are in the vast majority of cases produced at the mitral valve. In about five per cent of the cases mitral murmurs may be best heard at a point midway between the position of the normal cardiac impulse and the ensiform cartilage, or (very rarely) an inch or two above this situation.

Murmurs heard most loudly in the second left intercostal space are almost invariably produced at the pulmonic orifice or just above it in the conus arteriosus.

Murmurs whose maximum intensity is at the root of the ensiform cartilage or within a radius of an inch and a half from this point are usually produced at the tricuspid orifice. Murmurs produced at the aortic orifice may be heard best in the aortic area, but in a large proportion of cases are loudest on the other side of the sternum at or about the situation of the fourth left costal cartilage. Occasionally they are best heard at the apex of the heart or over the lower part of the sternum (see below, Fig. 105).

(3) *Transmission of Murmurs.*—If a murmur is audible over several valve areas, the questions naturally arise: "How are we to know whether we are dealing with a single valve lesion or with several? Is this one murmur or two or three murmurs?" Obviously the question can be asked only in case the murmur which we find audible in various places occupies everywhere the same time in the cardiac cycle. It must, for example, be everywhere systolic or everywhere diastolic. A systolic murmur at the apex cannot be supposed to point to the same lesion as a diastolic murmur, no matter where the latter is heard. But if we hear a systolic murmur in various parts of the chest, say over the aortic, mitral, and tricuspid regions, how are we to know whether the sound is simple or compound, whether produced at one valve orifice or at several?

This question is sometimes difficult to answer, and in a given case skilled observers may differ in their verdict, but, as a rule, the difficulty may be overcome as follows:

(1) Experience and post-mortem examination have shown that the murmur produced by each of the valvular lesions has its own characteristic area of propagation, over which it is heard with an in-

tensity which regularly diminishes as we recede from a *maximum* whose seat corresponds with some one of the valve areas just described. These areas of propagation are shown in Figs. 93, 94, 97, and 102. Any murmur whose distribution does not extend beyond one of these areas, and which steadily and progressively diminishes in intensity as we move away from the valve area over which it is loudest, may be assumed to be due to a single valve lesion and no

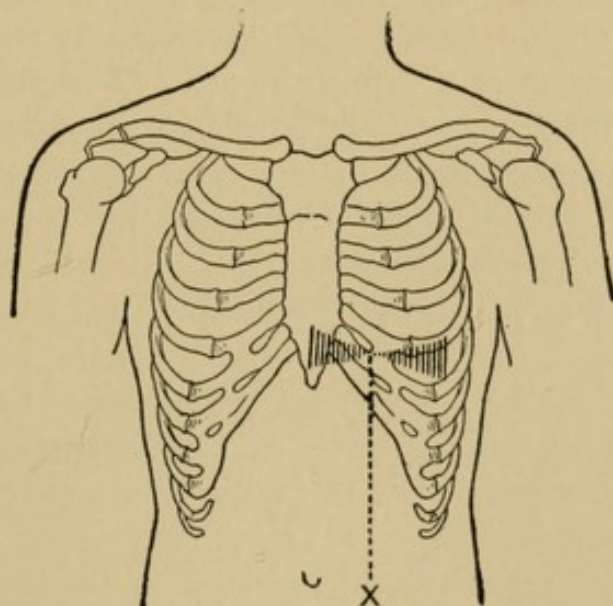


FIG. 83.—Mitral and Tricuspid Regurgitation. The intensity of the systolic murmur is least at the "waist" of the shaded area and increases as one approaches either end of it.

more. Provided but one valve is diseased, this course of procedure gives satisfactory results.

(2) When several valves are diseased and several murmurs may be expected, it is best to start at some one valve area, say in the mitral or apex region, and move the stethoscope one-half an inch at a time toward one of the other valve areas, noting the intensity of any murmur we may hear at each of the different points passed over. As we move toward the tricuspid area, we may get an impression best expressed by Fig. 83. That is, a systolic murmur heard loudly at the apex may fade away as we move toward the ensiform, until at the point *x* (Fig. 83) it is almost inaudible. But as we go on in the same direction the murmur may begin to grow

louder (and perhaps to change in pitch and quality as well) until a maximum is reached at the tricuspid area, beyond which the murmur again fades out.

These facts justify us in *suspecting* that we are dealing with two murmurs, one produced at the tricuspid and one at the mitral orifice. The suspicion is more likely to be correct if there has been a change in the pitch and quality of the murmur as we neared the tricuspid orifice, and may be confirmed by the discovery of other evidences of a double lesion. *No diagnosis is satisfactory which rests on the evidence of murmurs alone.* Changes in the size of the heart's chambers or in the pulmonary or peripheral circulations are the most important facts in the case. Nevertheless the effort to ascertain and graphically to represent the intensity of cardiac murmurs as one listens along the line connecting the valve areas has its value. An "hour-glass" murmur, such as that represented in Fig. 83), generally means *two-valve* lesions. A similar "hour-glass" may be found to represent the auditory facts as we move from the mitral to the pulmonic or to the aortic areas (see Fig. 84) and, as in the previous case, arouses our suspicion that more than one valve is diseased.

It must not be forgotten, however, that "a murmur may travel some distance underground and emerge with a change of quality" (Allbutt). This is especially true of aortic murmurs, which are often heard well at the apex and at the aortic area, and faintly in the intervening space, probably owing to the interposition of the right ventricle.

In such cases we must fall back upon the condition of the heart itself, as shown by inspection, palpation, and percussion, and upon the condition of the pulmonary and peripheral circulation, as shown in the other symptoms and signs of the cases (dropsy, cough, etc.).

(4) *Intensity of Murmurs.*—Sometimes murmurs are so loud that they are audible to the patient himself or even at some distance from the chest. In one case I was able to hear a murmur eight feet from the patient. Such cases are rare and usually not serious, for the gravity of the lesion is not at all proportional to

the loudness of the murmur; indeed, other things being equal, loud murmurs are less serious than faint ones, provided we are sure we are dealing with organic lesions. (On the distinction between the organic and functional murmurs, see below, p. 142.)

A loud murmur means a powerful heart driving the blood strongly over the diseased valve. When the heart begins to fail, the intensity of the murmur proportionately decreases because the blood does not flow swiftly enough over the diseased valve to pro-

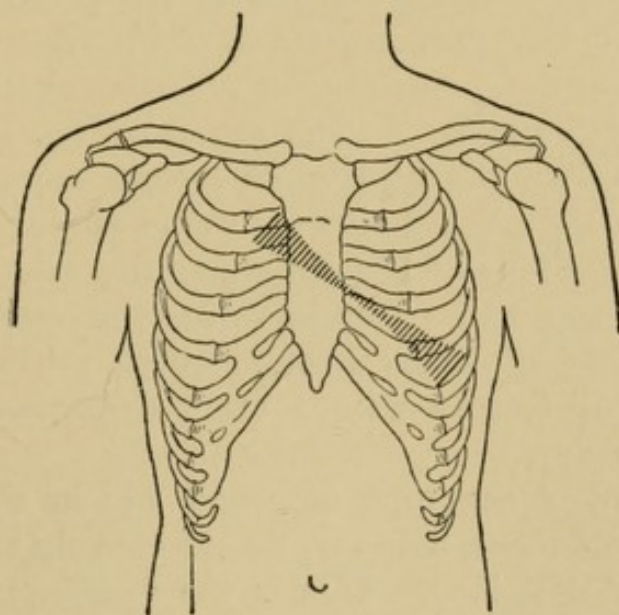


FIG. 84.—Mitral Regurgitation and Aortic Stenosis. The systolic murmur is loudest at the extremities of the shaded area and faintest at its "waist."

duce as loud a sound as formerly. The gradual disappearance of a murmur known to be due to a valvular lesion is, therefore, a very grave sign, and its reappearance revives hope. Patients are not infrequently admitted to a hospital with valvular heart trouble which has gone on so long that the muscle of the heart is no longer strong enough to produce a murmur as it pumps the blood over the diseased valve. In such a case, under the influence of rest and cardiac tonics, one may observe the development of a murmur as the heart wall regains its power, and the louder the murmur becomes the better the condition of the patient. On the other hand, when the existence of a valvular lesion has been definitely deter-

mined, and yet the compensation remains perfectly good (for example, in the endocarditis occurring in children in connection with chorea), an increase in the loudness of the murmur may run parallel with the advance in the valvular lesion.

In general the most important point about the intensity of a murmur is its *increase or decrease while under observation*, and not its loudness at any one time.

(5) *Quality of Heart Murmurs*.—It has been already mentioned that the quality of a heart murmur is never anything like the sound which we ordinarily designate by the word "murmur." The commonest type of heart murmur has a blowing quality, whence the old name of "*bellows sound*." The sound of the letter "f" prolonged is not unlike the quality of certain murmurs. *Blowing murmurs* may be low-pitched like the sound of air passing through a large tube, or high-pitched approaching the sound of a whistle. This last type merges into that known as the *musical* murmur, in which there is a definite musical sound whose pitch can be identified. *Rasping* or tearing sounds often characterize the louder varieties of murmurs.

Finally, there is one type of sound which, though included under the general name murmur, differs entirely from any of the other sounds just described. This is the "*presystolic roll*," which has a *rumbling* or *blubbery* quality or may remind one of a short drum-roll. This murmur is always presystolic in time and usually associated with obstruction at the mitral or tricuspid valves. Not infrequently some part of a cardiac murmur will have a musical quality while the rest is simply blowing or rasping in character. Musical murmurs do not give us evidence either of an especially serious or especially mild type of disease. Their chief importance consists in the fact that they rarely exist without some valve lesion,¹ and are, therefore, of use in excluding the type of murmur known as "*functional*," presently to be discussed, and not due to valve disease. Very often rasping murmurs are associated either with the calcareous deposit upon a valve or very marked narrowing of the valve orifice.

¹ Rosenbach holds that they may be produced by adhesive pericarditis.

Murmurs may be accented at the beginning or the end; that is, they may be of the crescendo type, growing louder toward the end, or of the decrescendo type with their maximum intensity at the beginning. Almost all murmurs are of the latter type except those associated with mitral or tricuspid obstruction.

(6) *Length of Murmurs*.—Murmurs may occupy the whole of systole, the whole of diastole, or only a portion of one of these periods, but no conclusions can be drawn as to the severity of the valve lesion from the length of the murmur. A short murmur, especially if diastolic, may be of very serious prognostic import.

(7) *Relations to the Normal Sounds of the Heart*.—Cardiac murmurs may or may not replace the normal heart sounds. They may occur simultaneously with one or both sounds or between the sounds. These facts have a certain amount of significance in prognosis. Murmurs which entirely replace cardiac sounds usually mean a severer disease of the affected valve than murmurs which accompany, but do not replace, the normal heart sounds. Late systolic murmurs, which occur between the first and the second sound, are usually associated with a relatively slight degree of valvular disease. Late diastolic murmurs, on the other hand, have no such favorable significance.

(8) *Effects of Position, Exercise, and Respiration upon Cardiac Murmurs*.—Almost all cardiac murmurs are affected to a greater or less extent by the position which the patient assumes while he is examined. Systolic murmurs which are inaudible while the patient is in a sitting or standing position may be quite easily heard when the patient lies down. On the other hand, a pre-systolic roll which is easily heard when the patient is sitting up may entirely disappear when he lies down. Diastolic murmurs are relatively little affected by the position of the patient, but in the majority of cases are somewhat louder in the upright position.

The effects of exercise may perhaps be fitly mentioned here. Feeble murmurs may altogether disappear when the patient is at rest, and under such circumstances may be made easily audible by

getting the patient to walk briskly up and down the room a few times. Such lesions are usually comparatively slight.¹ On the other hand, murmurs which become more marked as a result of rest are generally of the severest type (see above, p. 136).

Organic murmurs are usually better heard at the end of expiration and become fainter during inspiration as the expanding lung covers the heart. This is especially true of those produced at the mitral valve, and is in marked contrast with the variations of functional murmurs which are heard chiefly or exclusively at the end of inspiration.

(9) *Sudden Metamorphosis of Murmurs.*—In acute endocarditis, when vegetations are rapidly forming and changing their shape upon the valves, murmurs may appear and disappear very suddenly. This metamorphosing character of cardiac murmurs, when taken in connection with other physical signs, may be a very important factor in the diagnosis of acute endocarditis. In a similar way relaxation or rupture of one of the tendinous cords, occurring in the course of acute endocarditis, may effect a very sudden change in the auscultatory phenomena.

“Functional Murmurs.”

Not every murmur which is to be heard over the heart points to disease either in the valves or in the orifices of the heart. Perhaps the majority of all murmurs are thus unassociated with valvular disease, and to such the name of “accidental,” “functional,” or “hæmic” murmurs has been given. The origin of these “functional” murmurs has given rise to an immense amount of controversy, and it cannot be said that any one explanation is now generally agreed upon. To me the most plausible view is that which regards most of them as due either to a temporary or permanent dilatation of the conus arteriosus, or to pressure or suction exerted upon the overlapping lung margins by the cardiac contractions. This explains only the systolic functional murmurs, which make up ninety-nine per cent. of all functional murmurs. The diastolic functional murmurs, which undoubtedly occur, although with exceeding rarity,

¹ For exception to this see below, page 161.

are probably due in most cases to sounds produced in the veins of the neck and transmitted to the innominate or vena cava.

Characteristics of Functional Murmurs.—(1) Almost all functional murmurs are systolic, as has before been mentioned.

(2) The vast majority of them are heard best over the pulmonic valve in the second left intercostal space. From this point they are transmitted in all directions, and are frequently to be heard, although with less intensity, in the aortic and mitral areas. Occasionally they may have their maximum intensity in one of the latter positions.

(3) As a rule, they are very soft and blowing in quality, though exceptionally they may be loud and rough.

(4) They are not associated with any evidence of enlargement of the heart nor with accentuation of the pulmonic second sound.¹

(5) They are usually louder at the end of inspiration.

(6) They are usually heard over a very limited area and not transmitted to the left axilla or to the back.

(7) They are especially evanescent in character; for example, they may appear at the end of a hard run or boat race or during an attack of fever, and disappear within a few days or hours. Respiration, position, and exercise produce greater variations in them than in "organic" murmurs.

(8) They are especially apt to be associated with *anæmia*, although the connection between anæmia and functional heart murmurs is by no means as close as has often been supposed. The severest types of anæmia, for example pernicious anæmia, may not be accompanied by any murmur, while, on the other hand, typical functional murmurs are often heard in patients whose blood is normal, and even in full health. Yet in three cases of intense anæmia I have heard *diastolic* murmurs loudest at the fourth left costal cartilage and leading to a diagnosis of aortic regurgitation. At autopsy the aortic valves were in each case sound, and I am at a loss

¹ In chlorosis the second pulmonic sound is often very loud (owing to the retraction of the lungs and uncovering of the conus arteriosus) and associated with a systolic murmur.

to account for the murmurs.¹ It should not be forgotten that a real, though temporary, leakage through the mitral or tricuspid valve may be associated with anæmia or debilitated conditions owing to weakening of the papillary muscles or of the mitral sphincter. In such cases we find *not* the signs of a functional murmur, as above described, but the evidence of an organic valve lesion hereafter to be described.

The distinctions between organic and functional heart murmurs may be summed up as follows:

Organic murmurs may occupy any part of the cardiac cycle; if systolic, they are usually transmitted either into the axilla and back or into the great vessels of the neck; they are usually associated with evidences of cardiac enlargement and changes in the second sounds at the base of the heart, as well as with signs and symptoms of stasis in other organs. Organic murmurs not infrequently have a musical or rasping quality, although this is by no means always the case. They are rarely loudest in the pulmonic area and are relatively uninfluenced by respiration, position, or exercise.

Functional murmurs are almost always systolic in time and usually heard with maximum intensity in the pulmonic area. They are rarely transmitted beyond the precordial region and are usually loudest at the end of inspiration. They are not accompanied by evidences of cardiac enlargement or pathological accentuation of the second sounds at the base of the heart, nor by signs of venous stasis or dropsy. They are very apt to be associated with anæmia or with some special attack upon the resources of the body (*e.g.*, physical overstrain or fever), and to disappear when such forces are removed. They are usually soft in quality; never musical. The very rare diastolic functional murmur occurs exclusively, so far as I am aware, in conditions of profound anæmia; *i.e.*, when the hæmoglobin is twenty-five per cent or less. It can be abolished by pressure upon the bulbus jugularis, and can be observed, if followed up into the neck, to pass over gradually into a continuous venous hum with a diastolic accent.

¹ Cabot and Locke, Johns Hopkins Bulletin, May, 1903.

Cardio-Respiratory Murmurs.

When a portion of the free margin of the lung is fixed by adhesions in a position overlapping the heart, the cardiac movements may rhythmically displace the air in such piece of lung so as to give rise to sounds which at times closely simulate cardiac murmurs. These conditions are most often to be found in the tongue-like projection of the left lung, which normally overlaps the heart, but it is probably the case that cardio-respiratory murmurs may be produced without any adhesion of the lung to the pericardium under conditions not at present understood. Such murmurs may be heard under the left clavicle or below the angle of the left scapula, as well as near the apex of the heart,—less often in other parts of the chest.

Cardio-respiratory murmurs may be either systolic or diastolic, but the vast majority of cases are systolic. The area over which they are audible is usually a very limited one. They are greatly affected by position and by respiration, and are heard most distinctly if not exclusively during inspiration, especially at the end of that act. (This fact is an important aid in distinguishing them from true cardiac murmurs, which are almost always fainter at the end of inspiration.) They are also greatly affected by cough or forced respiration or by holding the breath, whereas cardiac murmurs are relatively little changed thereby. Pressure on the outside of the thorax and in their vicinity may greatly modify their intensity or quality, while organic cardiac murmurs are but little influenced by pressure. As a rule, they have the quality of normal respiratory murmur, and sound like an inspiration interrupted by each diastole of the heart.

In case the effect of the cardiac movements is exerted upon a piece of lung in which a catarrhal process is going on, we may have systolic or diastolic explosions of râles, or any type of respiratory murmur except the bronchial type, since this is produced in solid lung which could not be emptied or filled under the influence of the cardiac movements. Cardio-respiratory murmurs have no special diagnostic significance, and are mentioned here only on account of the im-

portance of not confusing them with true cardiac murmurs. They were formerly thought to indicate phthisis, but such is not the case.

Murmurs of Venous Origin.

I have already mentioned that the venous hum so often heard in the neck in cases of anæmia may be transmitted to the region of the base of the heart and heard there as a diastolic murmur owing to the acceleration of the venous current by the aspiration of the right ventricle during diastole. Such murmurs are very rare and may usually be obliterated by pressure upon the bulbus jugularis, or even by the compression brought to bear upon the veins of the neck when the head is sharply turned to one side. They are heard better in the upright position and during inspiration.

Arterial Murmurs.

(1) Roughening of the arch of the aorta, due to chronic endocarditis, is a frequent cause in elderly men of a systolic murmur, heard best at the base of the heart and transmitted into the vessels of the neck. Such a murmur is sometimes accompanied by a palpable thrill. From cardiac murmurs it is distinguished by the lack of any other evidence of cardiac disease and the presence of marked arterio-sclerosis in the peripheral vessels (see further discussion under Aortic Stenosis, p. 185, and under Aneurism, p. 228).

(2) A narrowing of the lumen of the subclavian artery, due to some abnormality in its course, may give rise to a systolic murmur heard close below the clavicle at its outer end. The murmur is greatly influenced by movements of the arm and especially by respiratory movements. During inspiration it is much louder, and at the end of a forced expiration it may disappear altogether. Occasionally such murmurs are transmitted through the clavicle so as to be audible above it.

(3) Pressure exerted upon any of the superficial arteries (carotid, femoral, etc.) produces a systolic murmur (see below, p. 183). Diastolic arterial murmurs are peculiar to aortic regurgitation.

(4) Over the anterior fontanelle in infants and over the gravid uterus systolic murmurs are to be heard which are probably arterial in origin.

PART II.
DISEASES OF THE HEART.

CHAPTER VII.
VALVULAR LESIONS.

CLINICALLY it is convenient to divide the ills which befall the heart into three classes:

- (1) Those which deform the cardiac valves (valvular lesions).
- (2) Those which weaken the heart wall (parietal disease).
- (3) Congenital malformations.

Lesions which affect the cardiac valves without deforming them are not often recognizable during life. The vegetations of acute endocarditis¹ do not usually produce any peculiar physical signs until they have so far deformed or obstructed the valves as to prevent their opening or closing properly.

The murmurs which are often heard over the heart in cases of acute articular rheumatism cannot be considered as evidence of vegetative endocarditis unless valvular deformities, and their results in valvular obstruction or incompetency, ensue. The chordæ tendineæ may be ruptured or shortened, thickened, and welded together into shapeless masses, but if these deformities do not affect the action of the valves we have no means of recognizing them during life. Congenital malformations are practically unrecognizable as such. If they do not affect the valves, we cannot with any certainty make out what is wrong.

For physical diagnosis, then, heart disease means either de-

¹ See Appendix.

formed valves of weakened walls. Whatever else may exist, we are none the wiser for it unless the autopsy enlightens us.

In this chapter I shall confine myself to the discussion of valvular lesions and their results.

Valvular lesions are of two types:

(a) Those which produce partial obstruction of a valve orifice or prevent its opening fully (*"stenosis"*).

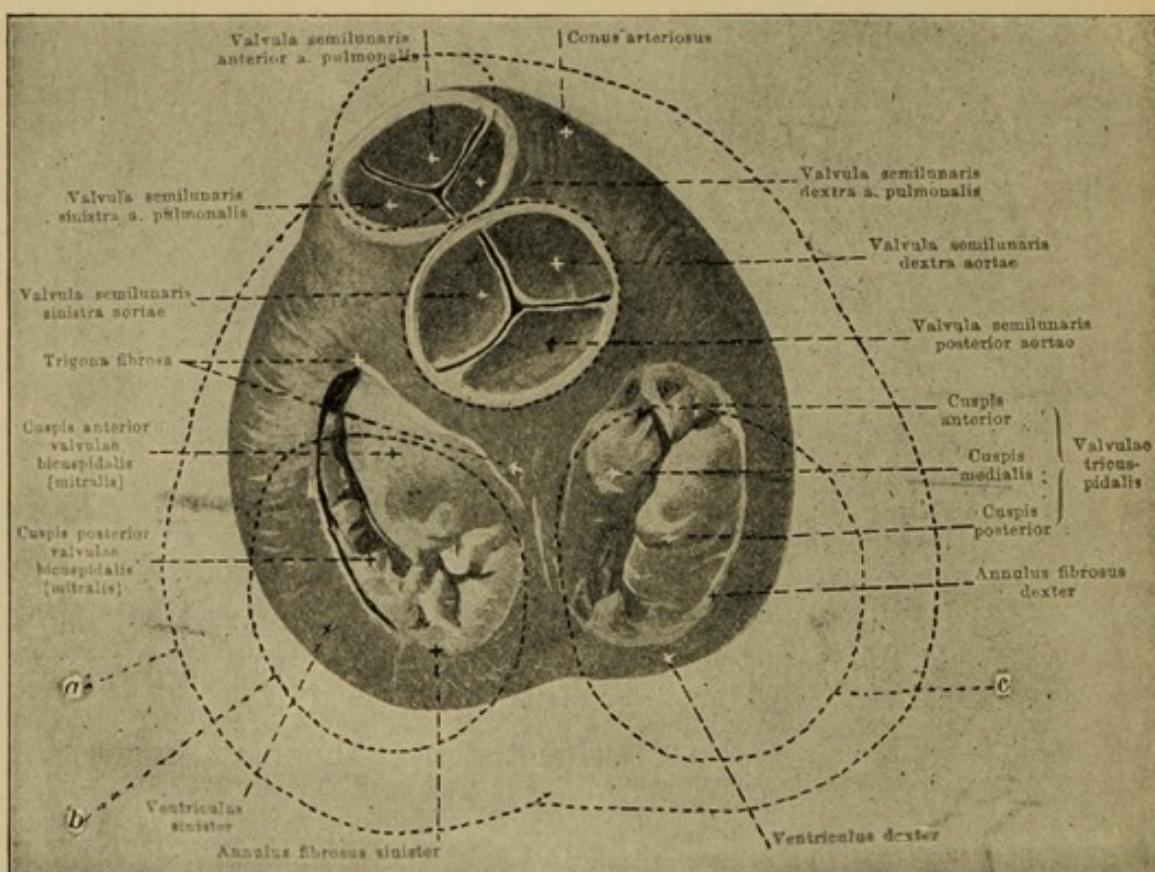


FIG. 85.—The Base of the Contracted Heart Showing Sphincteric Action of the Muscular Fibres Surrounding the Mitral and Tricuspid Valves. The outer dotted line is the outline of the relaxed heart. The inner dotted circles show the size of the mitral and tricuspid valves during diastole. *a*, Outline of the heart when relaxed; *b*, outline of the relaxed tricuspid valve; *c*, outline of the mitral orifice during diastole. (After Spalteholz.)

(b) Those which produce leakage through a valve orifice or prevent its closing effectively (*"regurgitation," "insufficiency," "incompetency"*).

Stenosis results always from the stiffening, thickening, and contraction of a valve.

Regurgitation, on the other hand, may be the result either of—

- (a) Deformity of a valve, or
- (b) Weakening of the heart muscle.

The mitral and tricuspid orifices are closed not simply by the shutting of their valves, but also in part by the sphincter-like

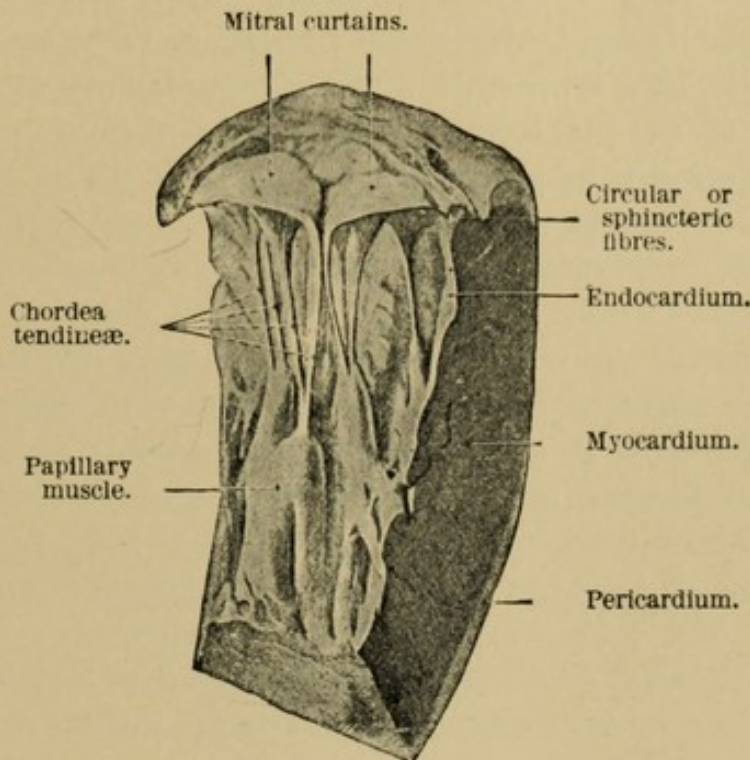


FIG. 86.—The Mitral Valve Closed, Showing the Action of the Papillary Muscles. (After Spalteholz.)

action of the circular fibres of the heart wall (see Fig. 85) and the contraction of the papillary muscles (Fig. 86).

In birds the tricuspid orifice has no valve and is closed wholly by the muscular sphincter of the heart wall.

In conditions of the acute cardiac failure, such as may occur after a hard run, the papillary muscles are in all probability relaxed, so that the valve-flaps swing back into the auricle and permit regurgitation of blood from the ventricle.

Valvular incompetence, then, differs from valvular *obstruction* in that the latter always involves deformity and stiffening of valves, while incompetence or leakage is often the result of deficient muscular action on the part of the heart wall. An obstructed valve is almost always leaky as well, since the same deformities which prevent a valve from opening usually prevent its closure; *but this rule does not work backward*. A leaky valve is often *not* obstructed. It is leaky but not obstructed if the valve curtain has been practically destroyed by endocarditis; or, again, it is leaky but not obstructed if the leak represents muscular weakening of the mitral sphincter or of the papillary muscles. Pure stenosis is very rare. Pure regurgitation is very common.

When valves are so deformed that their orifice is *both* leaky and obstructed, we have what is known as a "combined" or "double" valve lesion.

Since valvular lesions are recognized largely by their *results*, first upon the walls of the heart itself and then upon the other organs of the body, it seems best to give some account of these results before passing on to the description of the individual lesions in the heart itself.

The results of valvular lesions are first conservative and later destructive. The conservative results are known as:

The establishment of compensation through hypertrophy.

The destructive or degenerative results are known as:

The failure of compensation through (or without) dilatation.

I shall consider, then,

(a) The establishment and the failure of compensation.

(b) Cardiac hypertrophy.

(c) Cardiac dilatation.

ESTABLISHMENT AND FAILURE OF COMPENSATION IN VALVULAR DISEASE OF THE HEART.

We may discriminate three periods in the progress of a case of valvular heart disease:

- (1) The period before the establishment of compensation.
- (2) The period of compensation.
- (3) The period of failing or ruptured compensation.

(1) *Compensation Not Yet Established.*

In most cases of acute valvular endocarditis, whether of the relatively benign or of the malignant type, there is a time when the lesion is perfectly recognizable despite the fact that compensatory hypertrophy has not yet occurred. In some cases this period may last for months; the heart is not enlarged, there is no accentuation of either second sound at the base, there is no venous stasis, and our diagnosis must rest solely upon the presence and characteristics of the murmur. For example, in early cases of mitral regurgitation due to chorea or rheumatism, the disease may be recognized by the presence of a loud musical murmur heard in the back as well as at the apex and in the axilla. In the earlier stages of aortic regurgitation occurring in young people as a complication of rheumatic fever, there may be absolutely no evidence of the valve lesion except the characteristic diastolic murmur. In most textbooks of physical diagnosis I think too little attention is given to this stage of the disease.

(2) *The Period of Compensation.*

Valvular disease would, however, soon prove fatal were it not for the occurrence of compensatory hypertrophy of the heart walls. To a certain extent the heart contracts as a single muscle, and increases the size of all its walls in response to the demand for increased work; but as a rule the hypertrophy affects especially one ventricle—that ventricle, namely, upon which especially demand is made for increased power in order to overcome an increased resistance in the vascular circuit which it supplies with blood. Whatever increases the resistance in the lungs brings increased work upon the right ventricle; whatever increases the resistance in the aorta or peripheral arteries increases the amount of work which the left ventricle must do.

Now, any disease of the mitral valve, whether obstruction or leakage, results in engorgement of the lungs with blood, and hence demands an increased amount of work on the part of the right ventricle in order to force the blood through the overcrowded pulmonary vessels; hence it is in mitral disease that we find the greatest compensatory hypertrophy of the right ventricle.

On the other hand, it is obvious that obstruction at the aortic valves or in the peripheral arteries (arterio-sclerosis) demands an increase in power in the left ventricle, in order that the requisite amount of blood may be forced through arteries of reduced calibre, while if the aortic valve is so diseased that a part of the blood thrown into the aorta by the left ventricle returns into that ventricle, its work is thereby greatly increased, since it has to contract upon a larger volume of blood.

In response to these demands for increased work, the muscular wall of the left ventricle increases in thickness, and compensation is thus established at the cost of an increased amount of work on the part of the heart.¹

(3) *Failure of Compensation.*

Sooner or later in the vast majority of cases the heart, handicapped as it is by a leakage or obstruction of one or more valves, becomes unable to meet the demands made upon it by the needs of the circulation. Failure of compensation is sometimes associated with dilatation of the heart and weakening of its walls, but in many cases no such change can be found to account for its failure, and we have to fall back upon changes in the nutrition of the heart wall or upon some hypothetical derangement of the nervous mechanism of the organ as an explanation. Whatever the cause may be, the result of ruptured compensation is *venous stasis*; that is, œdema or dropsy of various organs appears. If the left ventricle is especially weakened, dropsy appears first in the legs, on account of the influence of gravity, soon after in the geni-

¹ Rosenbach brings forward evidence to show that the arteries, the lungs, and other organs actively assist in maintaining compensation.

tals, lungs, liver, and the serous cavities. Engorgement of the lungs is especially marked in cases of mitral disease with weakening of the right ventricle, and is manifested by dyspnoea, cyanosis, cough, and hæmoptysis. In many cases, however, dropsy is very irregularly and unaccountably distributed, and does not follow the rules just given. In pure aortic disease, uncomplicated by leakage of the mitral valve, dropsy is a relatively late symptom, and dyspnoea and precordial pain (angina pectoris) are more prominent.

HYPERTROPHY AND DILATATION.

Since cardiac hypertrophy or dilatation are not in themselves diseases, but may occur in any disease of the heart (valvular or parietal), it seems best to give some account of them and of the methods by which they may be recognized, before taking up separately the different lesions with which they are associated.

1. *Cardiac Hypertrophy.*

Hypertrophy of the heart is usually due to the following causes:

First (and most frequent): Valvular disease of the heart itself. Second: Obstruction of the flow of blood through the arteries owing to increase of arterial resistance, such as occurs in chronic nephritis and arterio-sclerosis. Third: Obstruction to the circulation of the blood through the lungs (emphysema, cirrhosis of the lung, fibroid phthisis). Fourth: Severe and prolonged muscular exertion (athlete's heart).

In valvular disease the greatest degree of hypertrophy is to be seen usually in relatively young persons, and especially when the advance of the lesion is not very rapid.

Hypertrophy of the heart in valvular disease is also influenced by the amount of muscular work done by the patient, by the degree of vascular tension, and by the treatment. In the great majority of cases of hypertrophy, from whatever cause, both sides of the heart are affected, but we may distinguish cases in which one or the other ventricle is *predominantly* affected.

(1) *Cardiac hypertrophy affecting especially the left ventricle.*

(a) The apex impulse is usually lower than normal, often in the sixth space, occasionally in the seventh or eighth.¹ It is also farther to the left than normal, but far less so than in cases in which the hypertrophy affects especially the right ventricle. The area of visible pulsation is usually increased, and a considerable portion of the chest wall may be seen to move with each systole of the heart, while frequently there is a systolic *retraction* of the interspaces in place of a systolic impulse.

(b) Palpation confirms the results of inspection and shows us also that the apex impulse is unusually powerful. Percussion shows in many cases that the cardiac dulness is more intense and its area increased downward and to a lesser extent toward the left.²

(c) If we listen in the region of the maximum cardiac impulse, we generally hear an unusually long and low-pitched first sound, which may or may not be of a greater intensity than normal. A very loud first sound is much more characteristic of a cardiac neurosis than of pure hypertrophy of the left ventricle.

The second sound at the apex (the aortic second sound transmitted) is usually much louder and sharper than usual. Auscultation in the aortic area shows that the second sound at that point is loud and ringing in character. Not infrequently the peripheral arteries (the subelavians, brachials, carotids, radials, and femorals) may be seen to pulsate with each systole of the heart. This sign is most frequently observed in cases of hypertrophy of the left ventricle, which are due to aortic regurgitation, but is by no means peculiar to this disease and may be repeatedly observed when the cardiac hypertrophy is due to nephritis or muscular work. I have frequently observed it in athletes, blacksmiths, and others whose muscular work is severe.

The radial pulse wave has no constant characteristics, but de-

¹ This is due partly to a stretching of the aorta, produced by the increased weight of the heart.

² Post mortem hypertrophy of the left ventricle is often found despite the absence of the above signs in life.

pendents rather upon the cause which has produced the hypertrophy than upon the hypertrophy itself.

(2) *Cardiac Hypertrophy Affecting Especially the Right Ventricle.*

It is much more difficult to be certain of the existence of enlargement of the right ventricle than of the left. Practically we have but two reliable physical signs:

(a) Increase in the transverse diameter of the heart, as shown by the position of the apex impulse and by percussion of the right and left borders of the heart; and

(b) Accentuation of the pulmonic second sound, which is often palpable as well as audible.

The apex beat is displaced both to the left and downward, *but especially to the left*. In cases of long-standing mitral disease, the cardiac impulse may be felt in mid-axilla, several inches outside the nipple, and yet not lower down than the sixth intercostal space. In a small percentage of cases (*i.e.*, when the right auricle is engorged), an increased area of dulness to the right of the sternum may be demonstrated. Accentuation of the pulmonic second sound is almost invariably present in hypertrophy of the right ventricle, though it is not peculiar to that condition. It may be heard, for example, in cases of pneumonia when no such hypertrophy is present, but in the vast majority of cases of cardiac disease we may infer the presence and to some extent the amount of hypertrophy of the right ventricle from the presence of a greater or lesser accentuation of the pulmonic second sound. The radial pulse shows nothing characteristic of this type of hypertrophy.

Epigastric pulsation gives us no evidence of the existence of hypertrophy of the right ventricle, despite contrary statements in many text-books. Such pulsation is frequently to be seen in persons with normal hearts, and is frequently absent when the right ventricle is obviously hypertrophied. It is perhaps most often due to an unusually low position of the whole heart.

DILATATION OF THE HEART.

(1) *Acute Dilatation*.—Immediately after severe muscular exertion, as, for example, at the finish of a boat race, or of a two-mile run (especially in persons not properly trained), an acute dilatation of the heart may occur, and in debilitated or poorly nourished subjects such an acute dilatation may be serious or even fatal in its results.

(2) Chronic dilatation comes on gradually as a result of valvu-

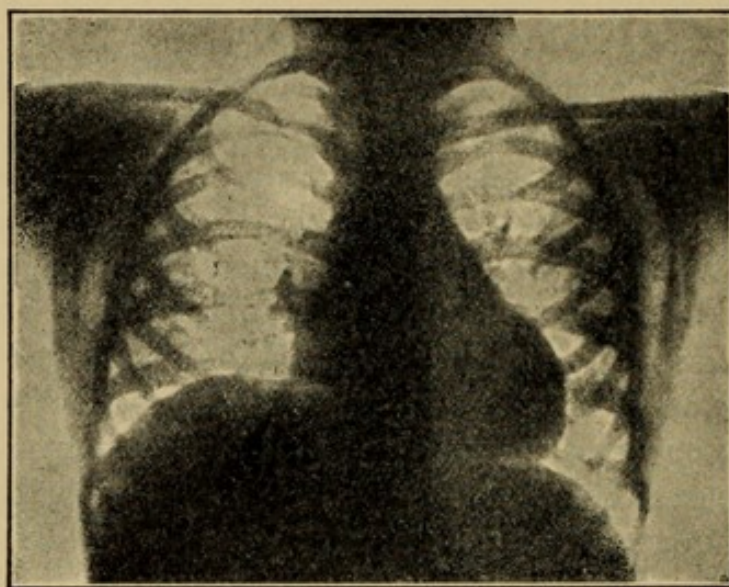


FIG. 87.—Dilated Heart. From v. Ziemssen's Atlas.

lar disease or other cause, and gives rise to practically the same physical signs as those of acute dilatation, from which it differs chiefly as regards the accompanying physical phenomena and the prognosis. Briefly stated, the signs of dilatation of the heart, whether acute or chronic, are:

(a) *Feebleness and irregularity* of the apex impulse and of the radial impulse, (b) *enlargement* of the heart, as indicated by inspection, palpation, and percussion, and (sometimes) (c) *murmurs* indicative of stretching of one or another of the valvular orifices.

Dilatation of the Left Ventricle.

Inspection shows little that is not better brought out by palpation. Palpation reveals a "flapping" cardiac impulse, or a vague shock displaced both downward and to the left and diffused over an abnormally large area of the chest wall. Percussion verifies the position of the cardiac impulse and sometimes shows an unusually blunt or rounded outline at the apex of the heart.

On auscultation, the first sound is usually *very short and sharp*, but *not feeble* unless it is accompanied by a murmur. In case the mitral orifice is so stretched as to render the valve incompetent, or in case the muscles of the heart are so fatigued and weakened that they do not assist in closing the mitral orifice, a systolic murmur is to be heard at the apex of the heart. This murmur is transmitted to the axilla and back, but does not usually replace the first sound of the heart. The aortic second sound, as heard in the aortic area and at the apex, is feeble.

Dilatation of the right ventricle of the heart is manifested by an increase in the area of cardiac dulness to the right of the sternum (corresponding to the position of the right auricle), by feebleness of the pulmonic second sound together with signs of congestion and engorgement of the lungs, and often by a systolic murmur at the tricuspid valve; *i.e.*, at or near the root of the ensiform cartilage. When this latter event occurs, one may have also systolic pulsation in the jugular veins and in the liver (see below, p. 194).

In cases of acute dilatation, such as occur in infectious fevers or at the end of well-contested races, there is often to be heard a systolic murmur loudest in the pulmonary area and due very possibly to a dilatation of the conus arteriosus.

The diagnosis of dilatation of the heart seldom rests entirely upon physical signs referable to the heart itself. In acute cases our diagnosis is materially aided by a knowledge of the cause, which is often tolerably obvious. In chronic cases the best evidence of dilatation is often that furnished by the venous stasis which results from it.

(4) CHRONIC VALVULAR DISEASE.

I. MITRAL REGURGITATION.

The commonest and on the whole the least serious of valvular lesions is incompetency of the mitral. It results in most cases from the shortening, stiffening, and thickening of the valve produced by rheumatic endocarditis in early life. It is the lesion present in most cases of chorea (see Figs. 88 and 89).

Temporary and curable mitral regurgitation may result from weakening of the heart muscle, which normally assists in closing the mitral orifice through the sphincter-like contraction of its circular fibres.

Great muscular fatigue, such as is produced by a hard boat race, may result in a temporary relaxation of the mitral sphincter or of the papillary muscles sufficient to allow of genuine but temporary and curable regurgitation through the mitral orifice. In conditions of profound nervous debility, excitement, or exhaustion, similar weakening of the cardiac muscles may allow of a leakage through the mitral, which ceases with the removal of its cause. Stress has been laid upon these points by Prince, and recently by Arnold.

Mitral insufficiency due to stretching of the ring into which the valve is inserted occurs not unfrequently as a result of dilatation of the left ventricle, and is commonly known as *relative insufficiency* of the mitral valve. The valve orifice can enlarge, the valve cannot, and hence its curtains are insufficient to fill up the dilated orifice. This type of mitral insufficiency frequently results from aortic regurgitation with the dilatation of the left ventricle which that lesion produces, or from myocarditis, which weakens the heart wall until it dilates and widens the mitral orifice.

The *results* of any form of mitral leakage occur in this order:

1. *Dilatation or hypertrophy of the left auricle*, which has to receive blood both from the lungs and through the leaky mitral from the left ventricle.
2. The overfilled left auricle cannot receive the blood from the

lungs as readily as it should; hence the blood "backs up" in the lungs and thereby increases the work which the right ventricle must do in order to force the blood through them. Thus result œdema of the lungs, and—

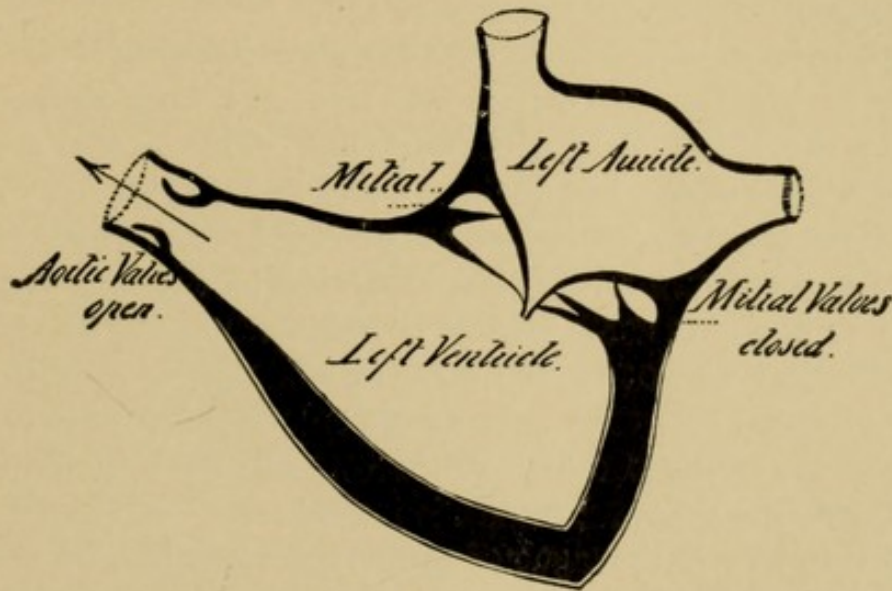


FIG. 88.

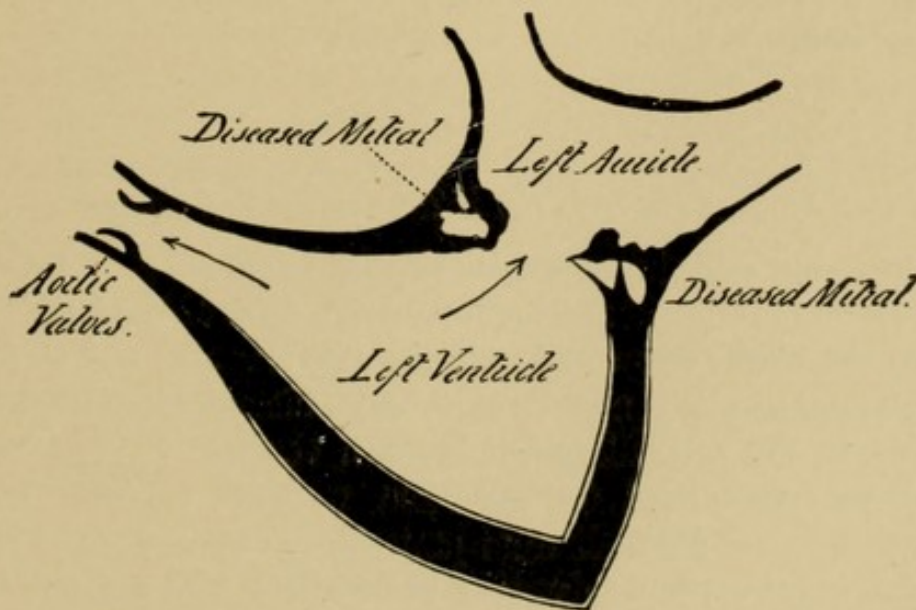


FIG. 89.

FIG. 88.—Normal Heart during Systole. Mitral valve closed; blood flowing through the open aortic valves into the aorta.

FIG. 89.—Mitral Regurgitation. The heart is in systole and the arrows show the current flowing back in the left auricle as well as forward into the aorta.

(3) *Hypertrophy and dilatation* of the right ventricle, which in turn becomes sooner or later overcrowded so that the tricuspid valve gives way and tricuspid leakage occurs.

(4) The capacity for hypertrophy possessed by the right auricle is soon exhausted, and we get then—

(5) *General venous stasis*, which shows itself first as venous pulsation in the jugulars and in the liver and later in the tissues drained by the portal and peripheral veins. This venous stasis increases the work of the left ventricle, and so we get—

(6) *Hypertrophy and dilatation of the left ventricle*. Hypertrophy of the left ventricle is also produced by the increased work necessary to maintain some vestige of sphincter action at the leaky mitral orifice, as well as by the labor of contracting upon the extra quantity of blood delivered to it by the enlarged left auricle.

At last the circle is complete. Every chamber in the heart is enlarged, overworked, and failure is imminent.

Returning now to the signs of mitral regurgitation, we shall find it most convenient to consider first the type of regurgitation produced by rheumatism and resulting in thickening, stiffening, and retraction of the valve.

PHYSICAL SIGNS.

(a) *First Stage—Prior to the Establishment of Compensation.*

We have but one characteristic physical sign:

A systolic murmur heard loudest at the apex of the heart, transmitted to the back (below or inside the left scapula) and to the left axilla. The murmur is not infrequently musical in character, and when this is the case diagnosis is much easier. Systolic musical murmurs so transmitted do not occur without valvular leakage. Rosenbach believes that adherent pericardium is capable of producing such a murmur, but only, if I understand him rightly, in case there is a genuine mitral leakage due to the embarrassing embrace of the pericardium which prevents the mitral orifice from closing.

“Functional” or “hæmic” murmurs are rarely heard in the back, and very rarely, if ever, have a musical quality.

Cases of mitral regurgitation are not very often seen at this stage, but in acute endocarditis after the fever and anæmia have subsided, or in chorea, such a murmur may exist for days or weeks before any accentuation of the pulmonic second sound or any enlargement of the heart appears. I have had the opportunity of verifying the diagnosis at autopsy in two such cases.

(b) Second Stage—Compensation Established.

As long as compensation remains perfect, the only evidence of regurgitation may be that obtained by auscultation, and I shall accordingly begin with this rather than in the traditional way with inspection, palpation, and percussion.

The distinguishing auscultatory phenomena in cases of well-compensated mitral insufficiency are:

(a) A systolic murmur whose maximum intensity is at or near the apex impulse of the heart, but which is also to be heard in the left axilla and in the back below or inside the angle of the left scapula (so far the signs are those of the first stage, above described).

(b) A pathological accentuation of the pulmonic second sound.

This is the minimum of evidence upon which it is justifiable to make the diagnosis of compensated mitral regurgitation. In the vast majority of cases, however, our diagnosis is confirmed by the following additional data:

(c) Enlargement of the heart as shown by inspection, palpation, and percussion.

The pulse in well-compensated cases shows no considerable abnormality. When compensation begins to fail, or sometimes before that time, the most characteristic thing about the pulse is its marked irregularity both in force and rhythm. Such irregularity is at once *more common and less serious in mitral disease than in that of any other valve*; it may continue for years and be compatible with very tolerable health.

Returning now to the details of the sketch just given, we will take up first—

(a) *The Murmur*.—In children the murmur of mitral regurgitation may be among the loudest of all murmurs to be heard in val-




FIG. 90.—Diagram to Represent Systolic Mitral Murmur. The heavy lines represent the normal cardiac sounds and the light lines the murmur, which in this case does not replace the first sound and "tapers" off characteristically at the end.

vular disease, but this does not necessarily imply that the lesion is a very severe one. A murmur which *grows louder* under observation in a well-compensated valvular lesion may mean an advance of the disease, but if the case is first seen after compensation has failed a faint, variable whiff in the mitral area may mean the severest type of lesion. As the patient improves under the influence of rest and cardiac tonics, such a murmur may grow very much louder, or a murmur previously inaudible may appear.

The *length* of the murmur varies a great deal in different cases and is not of any great practical importance. It rarely ends abruptly, but usually "tails off" at the end of systole (see Fig. 90). *Musical* murmurs are heard more often in mitral regurgitation than in any other valve lesion, but the musical quality rarely lasts throughout the whole duration of the murmur, contrasting in this respect with musical murmurs produced at the aortic valve. The




FIG. 91.—Systolic Mitral Murmur Replacing the First Sound of the Heart.

first sound of the heart may or may not be replaced by the murmur (see Fig. 91). When the sound persists and is heard either with or before the murmur, one can infer that the lesion is relatively slight in comparison with cases in which the first sound is wholly

obliterated. *Post-systolic* or *late systolic* murmurs, which are occasionally heard in mitral regurgitation, are said to point to a relatively slight amount of disease in the valve (see Fig. 90). Rosen-




FIG. 92.—Late Systolic Murmur. The first sound is clear and an interval intervenes between it and the murmur.

bach claims that the late systolic murmur is always due to organic disease of the valves and never occurs as a functional murmur.

When compensation fails, the murmur may altogether disappear for a time, and if the patient is then seen for the first time and dies without rallying under treatment, it may be impossible to

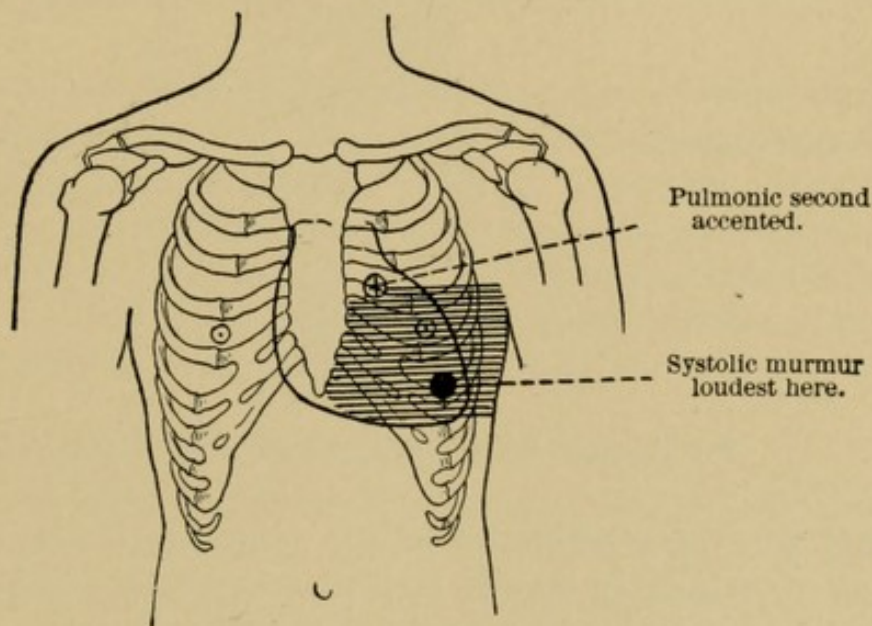


FIG. 93.—Mitral Regurgitation. The murmur is heard over the shaded area as well as in the back.

make the diagnosis. The very worst cases, then, are those in which there is no murmur at all.

The murmur of mitral regurgitation is conducted in all directions, but especially toward the axilla and to the back (*not* around the chest, but directly). In the latter situation it is usually louder

than it is in mid-axilla, and occasionally it is heard as loudly in the back as anywhere else. This is no doubt owing to the position of the left auricle (see Figs. 93 and 94).

(b) After compensation is established and as long as it lasts an *accentuation of the pulmonic second sound* is almost invariably to be made out, and may be so marked that we can feel and see it, as well as hear it. Not infrequently one can also see and feel the pulsation of the conus arteriosus—not the left auricle—in the second and third left intercostal space. (It may be well to mention again

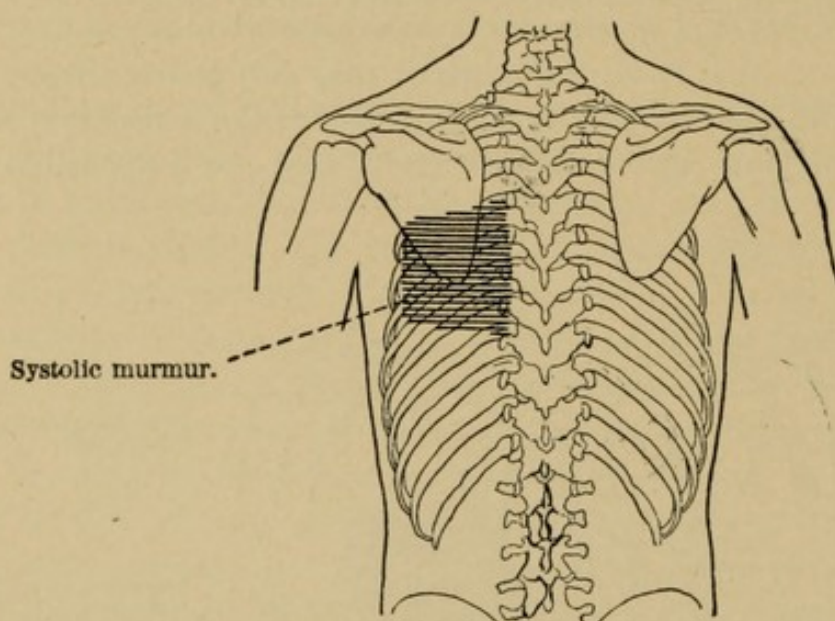


FIG. 94.—Mitral Regurgitation. Murmur heard over the shaded area.

here that by accentuation of the pulmonic second sound one does not mean merely that it is louder or sharper in quality than the aortic second sound, since this is true in the vast majority of cases in healthy individuals under thirty years of age. Pathological accentuation of the pulmonic second sound means *a greater intensity of the sound than we have a right to expect at the age of the individual in question.*) Occasionally the pulmonic second sound is reduplicated, but as a rule this points to an accompanying stenosis of the mitral valve. At the apex the second sound (*i.e.*, the transmitted aortic second) is not infrequently wanting altogether, owing

to the relatively small amount of blood which recoils upon the aortic valves.

(e) *Enlargement of the heart*, and more especially of the right ventricle, is generally to be made out, and in the majority of cases this enlargement is manifested by displacement of the apex impulse both downward and toward the left, but more especially to the left. Percussion confirms the results of inspection and palpation regarding the position of the cardiac impulse. The normal sub-sternal dulness is increased in intensity, and we can sometimes demonstrate an enlargement of the heart toward the right (see Fig. 91).

In children (in whom adhesive pericarditis often complicates the disease) a systolic THRILL may not infrequently be felt at the apex, and the precordia may be bulged, and even in adults such a systolic thrill is not so rare as some writers would have us suppose.

(d) *The pulse*, as said above, shows nothing characteristic at any stage of the disease. While compensation lasts, there is usually nothing abnormal about the pulse, although it may be somewhat irregular in force and rhythm, and may be weak when compared to the powerful beat at the apex in case the regurgitant stream is a very large one. Irregularity at this period is less common in pure mitral regurgitation than in cases complicated by stenosis.

(c) *Third Stage—Failing Compensation.*

When compensation begins to fail, the pulse becomes weak and irregular, and many heart beats fail to reach the wrist, but there is still nothing characteristic about the pulse, which differs in no respect from that of any case of cardiac weakness of whatever nature.

(e) Evidence of *venous stasis*, first in the lungs and later in the liver, lower extremities, and serous cavities, does not show itself so long as compensation is sufficient, but when the heart begins to fail the patient begins to complain not only of palpitation and cardiac distress, but of dyspnoea, orthopnoea, and cough, and examination reveals a greater or lesser degree of cyanosis with pulmo-

nary œdema manifested by crackling râles at the base of the lungs posteriorly, and possibly also by hæmoptysis or by evidences of hydrothorax (see below, p. 272). If compensation is not re-established, the right ventricle dilates, the tricuspid becomes incompetent, the liver becomes enlarged and tender, dropsy becomes general, the heart and pulse become more and more rapid and irregular, the heart murmur disappears and is replaced by a confusion of short valvular sounds, "*gallop rhythm*" or "*delirium cordis*," often considerably obscured by the noisy, labored breathing with numerous moist râles. In a patient seen for the first time in such a condition diagnosis may be impossible, yet mitral disease of some type may usually be suspected, since murmurs produced at the aortic valve are not so apt to disappear when compensation fails. The relative tricuspid insufficiency which often occurs is likely to manifest itself by an enlargement of the right auricle, sometimes demonstrable by percussion and later by venous pulsation in the neck and in the liver.

(d) *Differential Diagnosis.*

The murmur of mitral regurgitation may be confused with

- (1) Tricuspid regurgitation.
- (2) Functional murmurs.
- (3) Stenosis or roughening of the aortic valves.

(1) The post-mortem records of the Massachusetts General Hospital show that in the presence of a murmur due to mitral regurgitation it is very easy to fail altogether to recognize a tricuspid regurgitant murmur. Only 5 out of 29 cases of tricuspid regurgitation found at autopsy were recognized during life. Allbutt's figures from Guy's Hospital are similar. In the majority of these cases, mitral regurgitation was the lesion on which attention was concentrated during the patient's life. This is all the more excusable because the tricuspid area is so wide and uncertain. Murmurs produced at the tricuspid orifice are sometimes heard with maximum intensity just inside the apex impulse, and if we have *also* a mitral regurgitant murmur, it may be impossible under such circumstances to distinguish it from the tricuspid murmur. Some-

times the two are of different pitch, but more often tricuspid regurgitation must be recognized *indirectly* if at all, *i.e.*, through the evidence given by venous pulsation in the jugular veins and in the liver. Tricuspid murmurs are not transmitted to the left axilla and do not cause accentuation of the pulmonic second sound, although they are compatible with such accentuation. They are to be distinguished from the murmurs of mitral regurgitation by their different seat of maximum intensity, possibly by a difference in pitch, but most clearly by the concomitant phenomena of venous pulsation above mentioned.

(2) "Functional" murmurs are usually systolic and may have their maximum intensity at the apex of the heart, but in the great majority of cases they are heard best over the pulmonic valve or just inside or outside the apex beat (Potain). They are faint or inaudible at the end of expiration, and are more influenced by position than organic murmurs are. In the upright position they are often very faint. They are rarely transmitted beyond the precordia and are unaccompanied by any evidences of enlargement of the heart, by any pathological accentuation of the pulmonic second sound,¹ or any evidences of engorgement of the lungs or general venous system.

(3) Roughening or narrowing of the aortic valves may produce a systolic murmur with maximum intensity in the second right intercostal space, but this murmur is not infrequently heard all over the precordia and quite plainly at the apex, so that it may simulate the murmur of mitral regurgitation. The aortic murmur may indeed be heard more plainly at the apex than at any other point *except* the second right intercostal space, owing to the fact that the right ventricle, which occupies most of the precordial region between the aortic and mitral areas, does not lend itself well to the propagation of certain types of cardiac murmurs. Under these circumstances "a loud, rough aortic murmur may be heard at the

¹ It must be remembered that in chlorosis, a disease in which functional murmurs are especially prone to occur, the pulmonic second sound is often surprisingly loud, owing to a retraction of the left lung, which uncovers the root of the pulmonic artery.

apex as a smooth murmur of a different tone" (Broadbent). Such a murmur is not, however, likely to be conducted to the axilla or heard beneath the left scapula, nor to be accompanied by accentuation of the pulmonic second sound nor evidences of engorgement of the lungs and general venous system.

II. MITRAL STENOSIS.

Narrowing or obstruction of the mitral orifice is almost invariably the result of a chronic endocarditis which gradually glues together the two flaps of the valve until only a funnel-shaped opening or a slit like a buttonhole is left (see Figs. 95 and 96). As we examine post mortem the tiny slit which may be all that is left of the mitral orifice in a case of long standing, it is difficult to conceive how sufficient blood to carry on the needs of the circulation could be forced through such an insignificant opening.

Usually a slow and gradually developed lesion, mitral stenosis often represents the later stages of a process which in its earlier phases produced pure mitral regurgitation. By some observers the advent of stenosis is regarded as representing an attempt at compensation for a reduction of the previous mitral leakage. Others consider that the stenosis simply increases the damage which the valve has suffered.

A remarkable fact never satisfactorily explained is the predilection of mitral stenosis for the female sex.¹ A large proportion of the cases—seventy-six per cent in my series—occur in women.

It is also curious that so many cases are associated with pulmonary tuberculosis.

Physical Signs.

Mitral stenosis may exist for many years without giving rise to any physical signs by which it may be recognized, and even after signs have begun to show themselves they are more fleeting and inconstant than in any other valvular lesion of the heart. In the early stages of the disease the heart may appear to be entirely nor-

¹ Fenwick's explanation, viz., that the sedentary life of women favors the slow adhesive inflammation of the valve and its curtains, resulting in stenosis, does not seem to me to be satisfactory.

mal if the patient is at rest, and especially if examined in the recumbent position, characteristic signs being elicited only by exertion; or again a murmur which is easily audible with the patient in the upright position may disappear in the recumbent position; or a murmur may be heard at one visit, at the next it may be im-

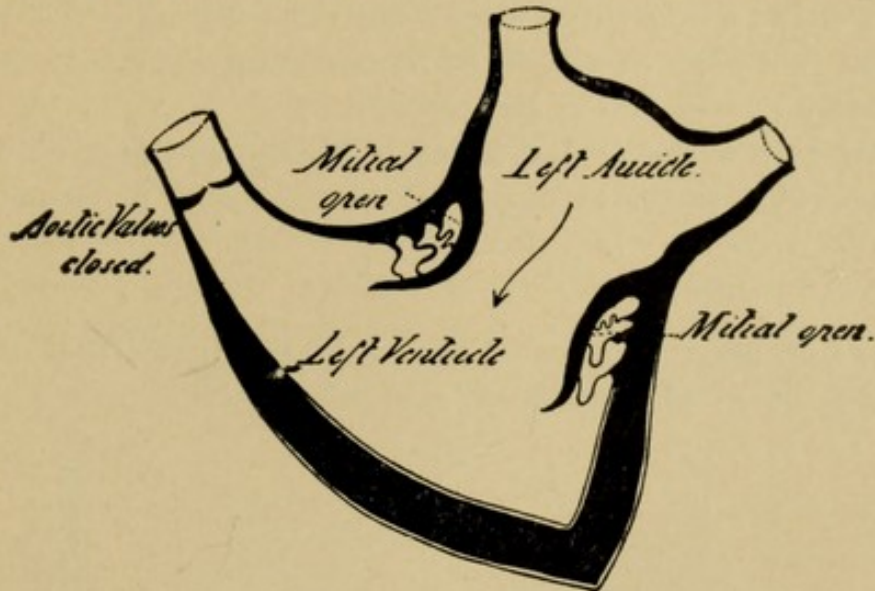


FIG. 95.

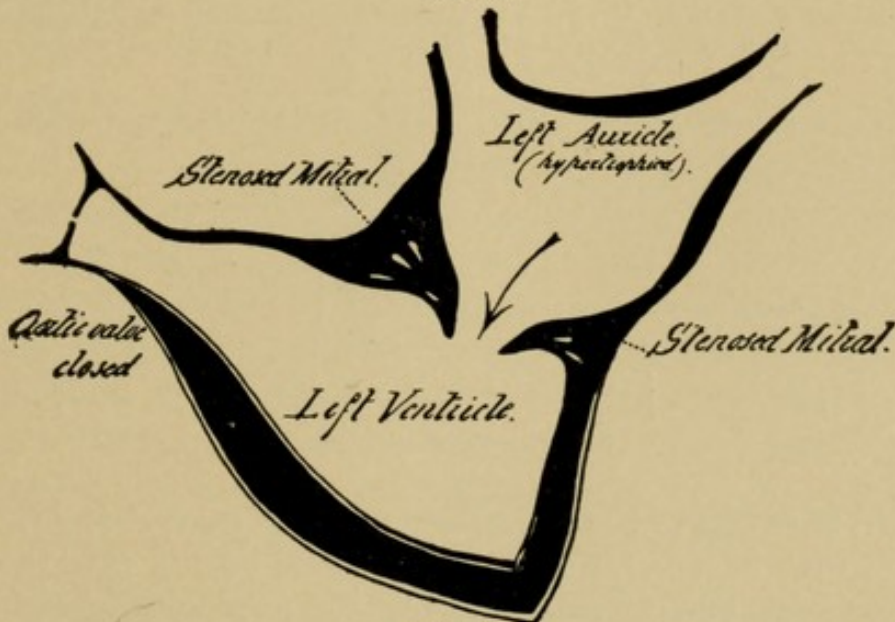


FIG. 96.

FIG. 95.—Diagram to Represent the Position of the Valves in the Normal Heart during Diastole, the Open Mitral Allowing the Blood to Flow Down from the Left Auricle, the Aortic Closed.

FIG. 96.—Mitral Stenosis—Period of Diastole. The blood flowing from the left auricle is obstructed by the thickened and adherent mitral curtains.

possible to elicit it by any manœuvre, while at the third visit it may be easily heard again. These characteristics explain to a certain extent the fact that differences of opinion so often arise regarding the diagnosis of mitral stenosis, and that out of forty-eight cases in which this lesion was found at autopsy at the Massachusetts General Hospital, only twenty-three were recognized during life. No common lesion (with the exception of tricuspid regurgitation) has been so frequently overlooked in our records.

I shall follow Broadbent in dividing the symptoms into three stages, according to the extent to which the lesion has progressed.

I.

In the first stage inspection and palpation show that the apex beat is little if at all displaced, and percussion reveals *no increase*

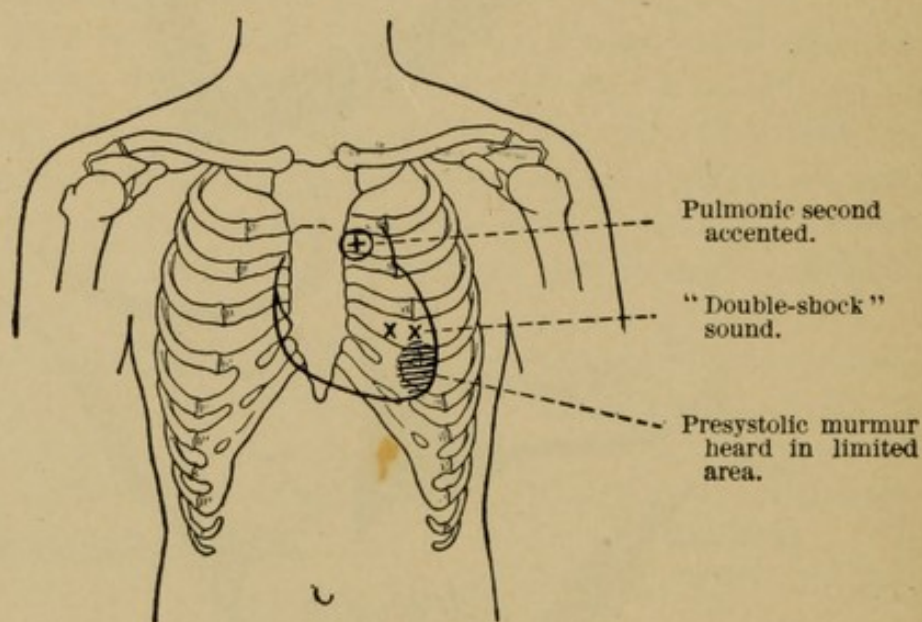


FIG. 97.—Mitral Stenosis.

in the area of cardiac dulness; indeed, in rare cases the heart may be smaller than usual. If one lays the hand lightly over the origin of the apex beat, one can generally feel the *purring presystolic thrill* which is so characteristic of this disease, more common indeed than in any other. This thrill is more marked in the second stage of the disease, but can generally be appreciated even in the first. It runs up to and ceases abruptly with the very sharp first sound,

the sudden *shock* of which may be appreciated even by palpation. The thrill is sometimes palpable even when no murmur can be heard, and often the thrill is transmitted to the axilla when the murmur is confined to the apex region. On auscultation one hears, especially after the patient has been exerting himself, and particularly if he leans forward and to the left, a *short low-pitched rumble or roll immediately preceding the systole* and increasing in intensity as it approaches the first sound. At this stage of the disease the second sound can still be heard at the apex. The first sound is very sharply accented or snapping, and communicates a very decided shock to the ear when a rigid stethoscope is used. As a rule, the murmur is closely confined to the region of the apex beat and not transmitted any considerable distance in any direction. I have seen cases in which it was to be heard only



FIG. 98.—The Murmur of Mitral Stenosis—First Stage. The place of the murmur and its crescendo character are indicated by the position of the light lines just before the first sound and by their increasing length.

over an area the size of a half-dollar.¹ Very characteristic of mitral stenosis is a prolongation of the diastolic pause so that the interval between the second sound of one cycle and the first sound of the next is unduly long. Occasionally the diastolic sound is reduplicated ("double-shock sound"—Sansom) at this stage of the disease, but this is much more frequent in the later phases of the lesion.²

Irregularity of the heart beat both in force and rhythm is very frequently present even in the early stages of the affection. The heart may be regular while the patient is at rest, but slight exertion is often sufficient to produce marked irregularity.

¹ It may, however, be widely transmitted to the left axilla and audible in the back or even over the whole of the left chest, especially when the stenosis is combined with regurgitation.

² This is the opinion of most observers. Sansom states that the "double-shock sound" may precede *all* other evidences of mitral stenosis.

II.

In the *second stage* the murmur and thrill are usually longer and may occupy the whole of diastole, beginning with considerable intensity just after the reduplicated second sound, quickly diminish-




FIG. 99.—Type of Presystolic Murmur Often Heard in the Second Stage of Mitral Stenosis. Here the murmur fills the whole of diastole, with a gradual increase of intensity as it approaches the first sound. No second sound is audible at the apex.

ing until it is barely audible, and then again increasing with a steady crescendo up to the first sound of the next cycle.¹ These changes may be graphically represented as in Figs. 99 and 100. Diastole is now still more prolonged, so that the characteristic rhythm of this lesion is even more marked than in the earlier stages of the disease. In many cases at this stage no second sound is to be heard at all at the apex, although at the pulmonic orifice it is loud and almost invariably double. (This is one of the reasons for believing that the second sound which we usually hear at the apex is the transmitted aortic second sound. In mitral disease the aortic valves




FIG. 100.—Type of Presystolic Murmur Sometimes Heard in the Second Stage of Mitral Stenosis. There is a double crescendo. The second sound seems reduplicated.

shut feebly owing to the relatively small amount of blood that is thrown into the aorta.)

At this stage of the disease enlargement of the heart begins to make itself manifest. The apex impulse is displaced to the left—

¹ Rarely one finds a crescendo in the middle of a long presystolic roll with a diminuendo as it approaches the first sound.

sometimes as far as the mid-axillary line, and often descends to the sixth interspace. Occasionally the cardiac dulness is increased to the right of the sternum.

The instability and fleeting character of the murmur in the earlier stages of the disease are much less marked in this, the second stage. The first sound at the apex still retains its sharp, thumping quality, and is often audible *without the murmur* in the back.

The irregularity of the heart is generally greater at this stage than in the earlier one.

III.

The third stage of the affection is marked by the disappearance of the characteristic murmur, and is generally synchronous with the development of tricuspid regurgitation. The right ventricle becomes dilated sometimes very markedly. Indeed, it may produce a visible pulsating tumor below the left costal border and be mistaken for cardiac aneurism (Osler). The snapping first sound and the "double-shock" sound usually remain audible, but the latter may be absent altogether. Diagnosis in this stage rests largely upon the peculiar snapping character of the first sound, together with the prolongation of diastole and the very great irregularity of the heart, both in force and rhythm. At times a presystolic thrill may be felt even when no murmur is to be heard.

The pulse shows nothing characteristic in many cases except that early and persistent irregularity which has been already alluded to. In other cases the wave is low, long, easily compressed, but quite perceptible between beats; but for the lack of sufficient power in the cardiac contractions the pulse would be one of high tension.

As the disease advances the irregularity of the pulse becomes more and more marked, and sometimes presents an amazing contrast with the relatively good general condition of the circulation. Even when not more than a third of the beats reach the wrist, the patient may be able to attend to light work and feel very well. Such cases make us feel as if a pulse were a luxury rather than a necessity.

Under the influence of digitalis the pulse is especially apt to

assume the *bigeminal* type in mitral stenosis. Every other beat is then so abortive that it fails to send a wave to the wrist, and the weak beat is succeeded by a pause. According to Broadbent the weak beat corresponds to an abortive contraction of the left ventricle accompanied by a normal contraction of the right ventricle, so that for each *two* strong beats of the right side of the heart we have one strong and one weak beat of the left side of the heart.

Mitral stenosis is in the great majority of cases combined with mitral regurgitation, and it often happens that the signs of regurgitation are so much more prominent than those of stenosis that the latter escape observation altogether, especially in the third stage of the disease, when the typical presystolic roll has disappeared. In such cases combined stenosis and regurgitation is to be distinguished from pure regurgitation by the sharpness of the first sound, which would be very unusual at this stage of a case of pure mitral regurgitation. The presence of reduplicated second sound, a "double-shock sound" at the outset of the prolonged diastolic pause, and of great irregularity in force and rhythm, is further suggestive of mitral stenosis.

Mitral stenosis is apt to be associated with hæmoptysis, with engorgement of the liver and ascites, and especially with arterial embolism. No other valve lesion is so frequently found associated with embolism. The lungs are generally very voluminous, and may therefore mask an increase in area or intensity of the cardiac dulness.

Differential Diagnosis.

I have already discussed the difficulty of distinguishing a double lesion at the mitral valve from a simple mitral regurgitation (see above, p. 161).

Other murmurs which may be mistaken for the murmur of mitral stenosis are:

- (a) The Austin Flint murmur.
- (b) The murmur of tricuspid stenosis.
- (c) A rumbling murmur sometimes heard in children, after an attack of pericarditis.

(a) The Austin Flint murmur.

In 1862 Austin Flint studied two cases in which during life a typical presystolic roll was audible at the apex of the heart, yet in which post mortem the mitral valve proved to be perfectly normal, and the only lesion present was aortic insufficiency. This observation has since been verified by Osler, Bramwell, Gairdner, and other competent observers. At the Massachusetts General Hospital we have had seven such cases with autopsy. Yet, despite repeated confirmation, Flint's observation has remained for nearly forty years unknown to physicians at large. Its importance is this: Given a case of aortic regurgitation—a presystolic murmur at the apex does not necessarily mean stenosis of the mitral valve even though the murmur has the typical rolling quality and is accompanied by a palpable thrill. It may be only one of the by-effects of the aortic incompetency. How it is that a presystolic murmur can be produced at the apex in cases of aortic regurgitation has been much debated. Some believe it is due to the impact of the aortic regurgitant stream upon the ventricular side of the mitral valve, floating it out from the wall of the ventricle so as to bring it into contact with the stream of blood descending from the left auricle. Others suppose that the mingling of the two currents of blood, that from the mitral and that from the aortic orifice, is sufficient to produce the murmur.

Between the "Austin Flint murmur" thus defined and the murmur of true mitral stenosis, complicating aortic regurgitation, diagnosis may be impossible. If there are no dilatation of the mitral orifice and no regurgitation, either from this cause or from deformities of the mitral valve itself, any evidence of engorgement of the pulmonary circuit (accentuation of the pulmonic second sound, oedema of the lungs, hæmoptysis, and cough) speaks in favor of an actual narrowing of the mitral valve, while the absence of such signs and the presence of a predominating hypertrophy of the left ventricle tend to convince us that the murmur is of the type described by Austin Flint, *i.e.*, that it does not point to any stenosis of the mitral valve. The sharp, snapping first sound and systolic shock so characteristic of mitral stenosis are said to be

modified or absent in connection with murmurs of the Austin Flint type.

(b) Tricuspid obstruction.

Luckily for us as diagnosticians, stenosis of the tricuspid valve is a very rare lesion. Like mitral stenosis it is manifested by a presystolic rolling murmur whose point of maximum intensity is sometimes over the traditional tricuspid area, but may be at a point so near the mitral area as to be easily confused with stenosis of the latter valve.

The difficulty of distinguishing tricuspid stenosis from mitral stenosis is further increased by the fact that the two lesions almost invariably occur in conjunction. Hence we have two presystolic murmurs, perhaps with slightly different points of maximum intensity and possibly with a difference in quality, but often quite undistinguishable from each other. In the vast majority of cases, therefore, tricuspid stenosis is first recognized at the autopsy, and the diagnosis is at best a very difficult one.

(c) Broadbent, Rosenbach, and others have noticed in children who have just passed through an attack of pericarditis a rumbling murmur near the apex of the heart, which suggests the murmur of mitral stenosis. It is distinguished from the latter, however, by the absence of any accentuation of the first sound at the apex, as well as by the conditions of its occurrence and by its transiency. Such cases are important, since their prognosis is much more favorable than that of mitral stenosis.

Phear (*Lancet*, September 21, 1895) investigated 46 cases in which a presystolic murmur was observed during life and no mitral lesion found at autopsy. In 17 of these there was aortic regurgitation at autopsy; in 20 of these there was adherent pericardium at autopsy; in 9 nothing more than dilatation of the left ventricle was found. In none of these cases was the snapping first sound, so common in mitral stenosis, recorded during life.

It should be remembered that patients suffering from mitral stenosis are very frequently unaware of any cardiac trouble, and seek advice for anæmia, wasting, debility, gastric or pulmonary complaints. This is less often true in other forms of valvular dis-

ease. We should be especially on our guard in cases of supposed "nervous arrhythmia" or "tobacco heart," if there has been an attack of rheumatism or chorea previously. Such cases may present *no* signs of disease except the irregularity—yet may turn out to be mitral stenosis.

IV. AORTIC REGURGITATION.

Rheumatic endocarditis usually occurs in early life and most often attacks the mitral valve. The commonest cause of aortic disease on the other hand—arterio-sclerosis—is a disease of late mid-

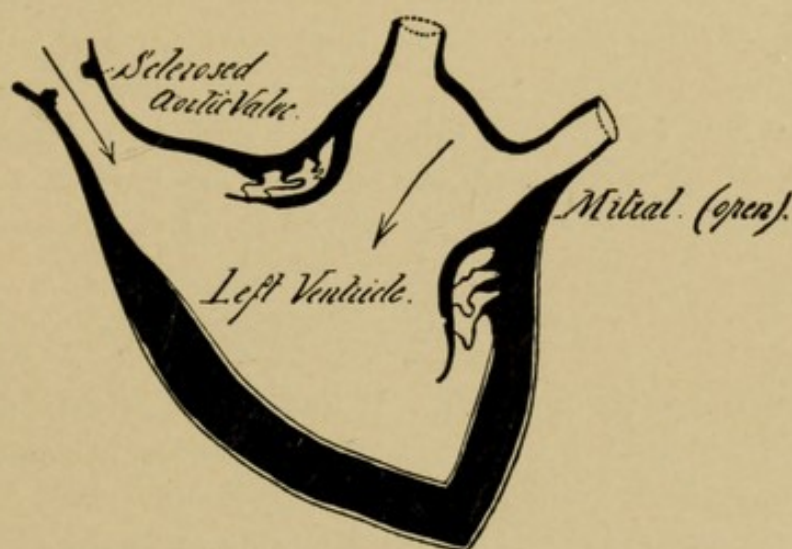


FIG. 101.—Diastole in Aortic Regurgitation. The blood is flowing back through the stumpy and incompetent aortic valves.

dle life, and attacks men much more often than women. When we think of aortic regurgitation, the picture that rises before us is usually that of a man past middle life and most often from the classes who live by manual labor. Nevertheless cases occur at all ages and in both sexes, and rheumatic endocarditis does not spare the aortic cusps altogether by any means.

Whether produced by arterio-sclerosis extending down from the aorta, or by rheumatic or septic endocarditis, the lesion which results in aortic regurgitation is usually a *thickening and shortening of the cusps* (see Fig. 101). In rare cases an aortic cusp may be ruptured as a result of violent muscular effort, and the signs and

symptoms of regurgitation then appear suddenly. But as a rule the lesion comes on slowly and insidiously, and unless discovered accidentally or in the course of routine physical examination it may exist unnoticed for years. Dropsy and cyanosis are relatively late and rare, and the symptoms which first appear are usually those of dyspnœa and precordial distress.

It is a disputed point whether relative and temporary aortic insufficiency due to stretching of the aortic orifice ever occurs. If it does occur, it is certainly exceedingly rare, as the aortic ring is very tough and inelastic.

Dilatation of the aortic arch—practically diffuse aneurism—occurs in almost every case of aortic regurgitation, and produces several important physical signs. This complication is a very well-known one, but has not, I think, been sufficiently insisted on in text-books of physical diagnosis. It forms part of that general enlargement of the arterial tree which is so characteristic of the disease.

Physical Signs.

Inspection reveals more that is important in this disease than in any other valvular lesion. In extreme cases the patient's face or hand may blush visibly with every systole. Not infrequently one can make the diagnosis across the room or in the street by noting the violent throbbing of the carotids, which may be such as to shake the person's whole head and trunk, and even the bed on which he lies. No other lesion is so apt to cause a heaving of the whole chest and a bobbing of the head, and no other lesion so often causes a bulging of the precordia, for in no other lesion is the enlargement of the heart so great (*cor bovinum* or ox-heart). The throbbing of the dilated aorta can often be felt and sometimes seen in the suprasternal notch or in the second right interspace. Not only the carotids but the subclavians, the brachials and radials, the femoral and anterior tibial, and even the digital and dorsalis pedis arteries may visibly pulsate, and the characteristic jerking quality of the pulse may be seen as well as felt. This visible pulsation in the peripheral arteries, while very characteristic of aortic

regurgitation, is occasionally seen in cases of simple hypertrophy of the heart from hard muscular work (*e.g.*, in athletes). If the arteries are extensively calcified, their pulsation become much less marked.

The peculiar conditions of the circulation whereby it is "changed into a series of discontinuous discharges as if from a catapult" (Allbutt) throws a great tensile strain upon all the arteries, and results, in almost every long-standing case, in increasing both their length

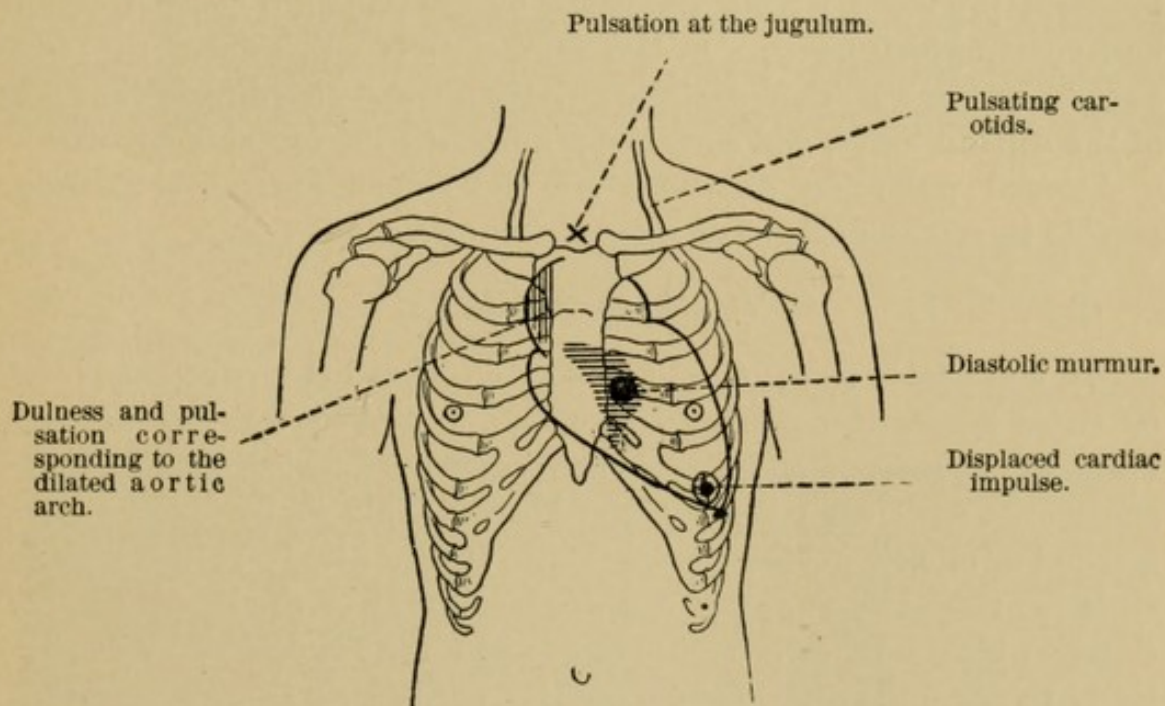


FIG. 102.—Aortic Regurgitation, Showing Position of the Diastolic Murmur and Areas of Visible Pulsation.

and their diameter. The visible arterial trunks become tortuous and distended, while the arch of the aorta is diffusely dilated and becomes practically an aneurism (see Fig. 102). With each heart beat the snaky arteries are often jerked to one side as well as made to throb.

Inspection of the region of the cardiac impulse almost always shows a very marked displacement of the apex beat both downward and outward (but especially the former), corresponding to the hypertrophy and still more to the dilatation of the left ventricle,

which is usually very great, and to the downward sagging of the enlarged aorta. Dilatation is in this disease an essentially helpful and compensatory process. In a small proportion of the cases no enlargement of the heart is to be demonstrated. This was true of 5 out of the last 67 cases which I have notes of, and generally denotes an early and slight lesion. Not at all infrequently one finds a systolic *retraction* of the interspaces near the apex beat instead of a systolic *impulse*. This is probably due to the negative pressure produced within the chest by the powerful contraction of an hypertrophied heart. In the suprasternal notch one often feels as well as sees a marked systolic pulsation transmitted from the arch of the dilated aorta, and sometimes mistaken for saccular aneurism.

Arterial pulsation of the liver and spleen are rarely demonstrable by a combination of sight and touch.

Capillary Pulsation.

If one passes the end of a pencil or other hard substance once or twice across the patient's forehead, and then watches the red mark so produced, one can often see a systolic flushing of the hyperæmic area with each beat of the heart. This is by far the best method of eliciting this phenomenon. It may also be seen if a glass slide is pressed against the mucous membrane of the lip so as partially to blanch it, or if one presses upon the finger-nail so as partially to drive the blood from under it; but in both these manœuvres error may result from inequality in the pressure made by the observer upon the glass slide or upon the nail. Very slight movements of the observer's fingers, even such as are caused by his own pulse, may give rise to changes simulating capillary pulsation. Capillary pulsation of normal tissues is not often seen in any condition other than aortic¹ regurgitation, yet occasionally one meets with it in diseases which produce very low tension of the pulse, such as phthisis or typhoid, anæmic and neurasthenic conditions, and I have twice seen it in perfectly healthy persons. In such cases the pulsation is usually less marked than in aortic regurgitation. Rarely pulsation may be detected in the peripheral veins.

¹ Jumping toothache and throbbing felon are common examples of capillary pulsation in inflamed areas.

Palpation.

Palpation verifies the position of the cardiac impulse and the heaving of the whole chest wall suggested by inspection. The shock of the heart is very powerful and deliberate unless dilatation




FIG. 103.—Sphygmographic Tracing from Normal Pulse.

is extreme, when it becomes wavy and diffuse. In the supraclavicular notch a systolic thrill is often to be felt. A diastolic thrill in the precordia is very rare.

The pulse is important, usually characteristic. The wave rises

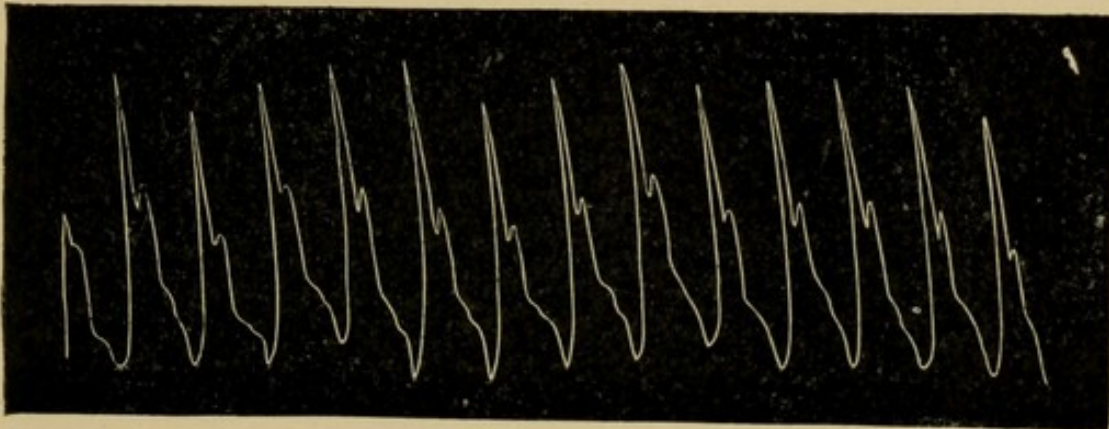


FIG. 104.—Sphygmographic Tracing of the "*Pulsus Celer*" in Aortic Regurgitation. Its collapsing character is well shown.

very suddenly and to an unusual height, then collapses completely and with great rapidity (*pulsus celer*) (see Figs. 103, 104).

This type of pulse, which is known as the "Corrigan pulse" or "water-hammer pulse," is exaggerated if one raises the patient's arm above the head so as to make the force of gravity aid in emptying the artery. The quality of the pulse in aortic regurgitation

is due to the fact that a large volume of blood is suddenly and forcibly thrown into the aorta by the hypertrophied and dilated left ventricle, thus causing the characteristically sharp and sudden rise in the peripheral arteries. The arteries then empty themselves *in two directions at once*, forward into the capillaries and backward into the heart through the incompetent aortic valves; hence the sudden collapse in the pulse which, together with its sharp and sudden rise, are its important characteristics. The arteries are large and often elongated so as to be thrown into curves.

Not infrequently one can demonstrate that the radial pulse is delayed or follows the apex impulse after a longer interval than in normal persons. While compensation lasts, the pulse is usually regular in force and rhythm. *Irregularity is therefore an especially grave sign*, much more so than in any other valvular lesion.

Percussion.

Percussion adds but little to the information obtained by inspection and palpation, but verifies the results of these methods of investigation respecting the increased size of the heart, and especially of the left ventricle, which may reach enormous dimensions, especially in cases occurring in young persons. The heart may be increased to *more than four times its normal weight*.

Auscultation.

In rare cases there may be absolutely no murmur and the diagnosis may be impossible during life, though it may be suspected by reason of the above-mentioned signs in the peripheral arteries. But although the murmur is seldom entirely absent, it is often so faint as to be easily overlooked. This is especially true in cases occurring in elderly people, and when the patient has been for a considerable time at rest. The difficulty of recognizing certain cases of aortic regurgitation during life is shown by the fact that out of sixty-five cases of aortic regurgitation demonstrated at autopsy in the Massachusetts General Hospital, only forty-four were recognized during life.

In the majority of cases, however, the characteristic *diastolic murmur* is easily heard if one listens in the right place, and when heard it is *the most distinctive and trustworthy of all cardiac murmurs*. It almost invariably points to aortic regurgitation and to nothing else.

The murmur of aortic regurgitation, as has been already mentioned, is *diastolic* in time.¹ *Its maximum intensity is usually not*

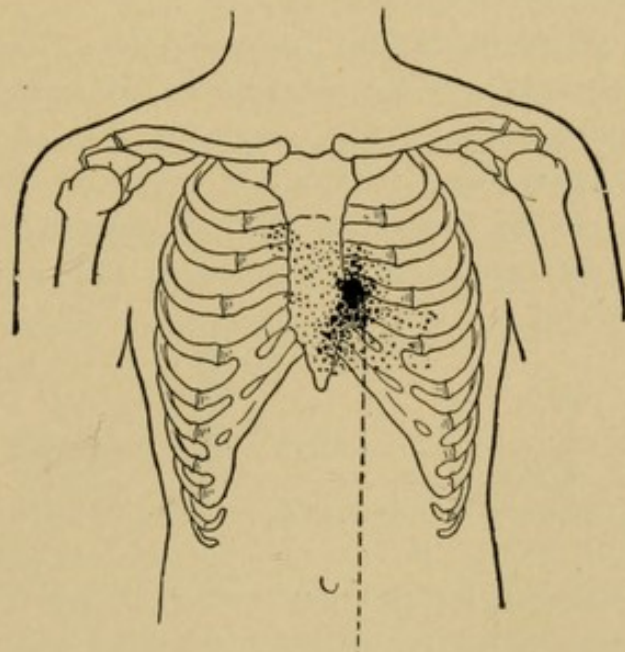


FIG. 105.—Position of the Point of Maximum Intensity of the Murmur of Aortic Regurgitation. The dots are most thickly congregated where the murmur is oftenest heard.

in the conventional aortic area (second right interspace), but on the left side of the sternum about the level of the fourth left costal cartilage. In about one-tenth of the cases, and especially when the aortic arch is much dilated, the murmur is best heard in the conventional aortic area. Occasionally there are two points at which it may be loudly heard—one in the second right interspace and the other at or near the apex of the heart, while between these points

¹ Another murmur, systolic in time, which almost always accompanies the diastolic murmur, is usually due to roughening of the edges of the aortic valves or to dilatation of the aortic arch. This murmur must not be assumed to mean aortic stenosis (see below, p. 189).

the murmur is faint. This is probably due to the fact that the left ventricle, through which the murmur is conducted, approaches the surface of the chest only at the apex, while the intermediate space is occupied by the right ventricle, which often fails readily to transmit murmurs produced at the aortic orifice. Less frequently the murmur of aortic regurgitation is heard with maximum intensity at the second or third left costal cartilage or in the region of the ensiform cartilage (see Fig. 105).

From its seat of maximum intensity (*i.e.*, usually from the fourth left costal cartilage) the murmur is transmitted in all directions, but not often beyond the precordia. In about one-third of the cases it is transmitted to the left axilla or even to the back. It is sometimes to be heard in the subclavian artery and the great vessels of the neck; in other cases two heart sounds are



FIG. 106.—Short Diastolic Murmur Not Replacing the Second Sound.

audible in the carotid, but no murmur. The murmur is usually blowing and relatively high pitched, sometimes musical. Its intensity varies much, but is most marked at the beginning of the murmur, giving the impression of an *accent* there. It may occupy the whole of diastole or only a small portion of it—usually the earlier portion (see Fig. 106). Late diastolic murmurs are rare. The murmur may or may not replace the second sound of the heart. Broadbent believes that when it does not obliterate the second sound, the lesion is usually less severe than when only the murmur is to be heard. Allbutt dissents from this opinion.

In listening for the aortic second sound with a view to gauging the severity of the lesion, it is best to apply the stethoscope over the right carotid artery, as here we are less apt to be confused by the murmur or by the pulmonic second sound.

The position of the patient's body has but little effect upon the murmur—less than upon murmurs produced at the mitral orifice.

The first sound at the apex is generally loud and long. There is no accentuation of the pulmonic second.

Over the larger peripheral arteries, especially over the femoral artery, one hears in most cases a sharp, short systolic sound ("pistol-shot sound") due to the sudden filling of the unusually empty artery; this sound is merely an exaggeration of what may be heard in health. Pressure with the stethoscope will usually bring out a systolic murmur (as also in health), and occasionally a *diastolic murmur* as well (Duroziez's sign). This diastolic murmur in the peripheral arteries, obtained on pressure with the stethoscope, is practically never heard except in aortic regurgitation. It is thought by some to be due to the regurgitant current in the great vessels which in very marked cases may extend as far as the femoral artery. Duroziez's sign is a comparatively rare one, not present in most cases of aortic regurgitation, and usually disappears when compensation fails.

Mich. 28/05
Cutler.

Summary and Differential Diagnosis.

A *diastolic murmur* heard with the maximum intensity about the *fourth left costal cartilage* (less often in the second right interspace or at the apex) gives us almost complete assurance of the existence of aortic regurgitation. From pulmonary regurgitation, an exceedingly rare lesion, the disease is distinguished by the presence of predominating hypertrophy of the left ventricle with a heaving apex impulse and by the following arterial phenomena:

- (a) Visible pulsation in the peripheral arteries.
- (b) Capillary pulsation.
- (c) "Corrigan" pulse.
- (d) "Pistol-shot sound" in the femoral artery.
- (e) Duroziez's sign.

Cardiopulmonary murmurs (see page 143) are occasionally diastolic, but are very markedly influenced by position and by respiration, while aortic murmurs are but slightly modified.

The very rare functional diastolic murmur, transmitted from the veins of the neck and heard over the base of the heart in cases of grave anæmia, may be obliterated by pressure over the bulbus jugularis. Such pressure has no effect upon the murmur of aortic regur-

gitation. I have recently reported (*Johns Hopkins Bull.*, May, 1903) three cases of intense anæmia associated with diastolic murmurs exactly like those of aortic regurgitation, but proved post mortem to be independent of any valvular lesion. The arterial phenomena were not marked, but the diagnosis of such cases is very hard. Luckily they are rare. The origin is obscure.

It must be remembered that aortic regurgitant murmurs are often exceedingly faint, and should be listened for with the greatest care and under the most favorable conditions.

Estimation of the Extent and Gravity of the Lesion.

The extent of the lesion is roughly proportional to—

(a) The amount of hypertrophy of the left ventricle.
(b) The degree to which the pulse collapses during diastole (provided the radial is not so much calcified as to make collapse impossible).

(c) The degree to which the murmur replaces the second sound as heard over the right carotid artery (Broadbent).

Irregularity of the pulse is a far more serious sign in this disease than in lesions of the mitral valve, and indicates the beginning of a serious failure of compensation.

Another grave sign is a diminution in the intensity of the murmur.

Complications.

(1) *Dilatation of the Aorta.*—Diffuse dilatation of the aortic arch is usually associated with aortic regurgitation and may produce a characteristic area of dulness to the right of the sternum (see Fig. 100). Not infrequently this dilatation is the cause of a systolic murmur to be heard over the region of the aortic arch and in the great vessels of the neck.

(2) *Roughening of the Aortic Valves.*—In almost all cases of aortic regurgitation the valves are sufficiently roughened to produce a systolic murmur as the blood flows over them. This murmur is heard at or near the conventional aortic area, and may be transmitted into the carotids. (The relation of these murmurs to the diagnosis of aortic stenosis will be considered with the latter lesion.)

(3) The return of arterial blood through the aortic valves into the left ventricle produces in time both hypertrophy and dilatation of this chamber, and results ultimately in a stretching of the mitral orifice which renders the mitral curtains incompetent. The result is a "*relative mitral insufficiency*," *i.e.*, one in which the mitral valve is intact but too short to reach across the orifice which it is intended to close. Such an insufficiency of the mitral occurs in most well-marked cases; it temporarily relieves the overdistention of the left ventricle and often the accompanying angina, although at the cost of engorging the lungs.¹

(4) *The Austin Flint Murmur*.—The majority of cases of aortic regurgitation are accompanied by a presystolic murmur at the apex, which may be due to a genuine mitral stenosis or may be produced in the manner suggested by Austin Flint. (For a fuller discussion of this murmur see above, p. 173.)

(5) *Aortic stenosis* frequently supervenes in cases of aortic regurgitation, and results in a more or less temporary improvement in the patient's condition. It has the effect of increasing the intensity of the diastolic murmur, since the regurgitating stream has to pass through a smaller opening.

The general visible arterial pulsation becomes much less marked if stenosis supervenes on regurgitation.

AORTIC STENOSIS.

Uncomplicated aortic stenosis is by far the rarest of the valvular lesions of the left side of the heart, as well as the most difficult to recognize. Out of two hundred and fifty-two autopsies made at the Massachusetts General Hospital in cases of valvular disease there was not one of uncomplicated aortic stenosis. Twenty-nine cases occurred in combination with aortic regurgitation. During life the diagnosis of aortic stenosis is frequently made, but often on insufficient evidence—*i.e.*, upon the evidence of a systolic murmur heard with maximum intensity in the second right intercostal space

¹ This relative insufficiency of the mitral valve has been termed its "safety-valve" action, but the safety is but temporary and dearly bought.

and transmitted into the vessels of the neck. Such a murmur does indeed occur in aortic stenosis, but is by no means peculiar to this condition. Of the other diseases which produce a similar murmur more will be said under Differential Diagnosis.

For the diagnosis of aortic stenosis we need the following evidence:

- (1) A systolic murmur heard best in the second right intercostal space and transmitted to the neck.
 - (2) The characteristic pulse (*vide infra*).
 - (3) A palpable thrill (usually).
 - (4) Absence or great enfeeblement of the aortic second sound.
- Of these signs the characteristic *pulse* is probably the most im-

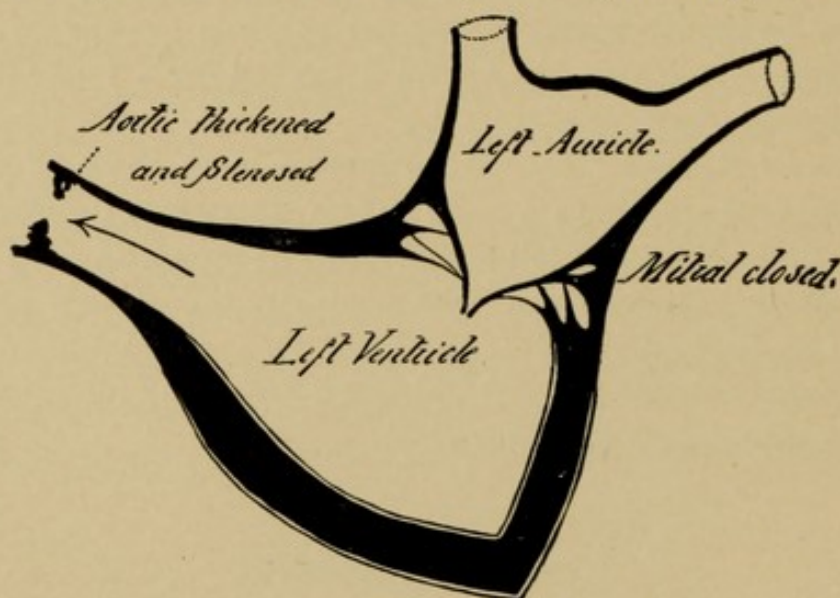


FIG. 107.—Aortic Stenosis. The heart is in systole and the blood column is obstructed by the narrowed aortic ring. The mitral is closed (as it should be).

portant, and no diagnosis of aortic stenosis is possible without it. The heart may or may not be enlarged.

Each of these points will now be described more in detail.

(1) *The Murmur.*

(a) The *maximum intensity* of the murmur, as has already been said, is usually in the second right intercostal space near the sternum or a little above that point near the sterno-clavicular articulation, but it is by no means uncommon to find it lower down, *i.e.*,

in the third, fourth, or fifth right interspace, and occasionally it is best heard to the left of the sternum in the second or third intercostal space. (b) *The time* of the murmur is *late systolic*; that is, it follows the apex impulse at an appreciable interval, contrasting in this respect with the systolic murmur usually to be heard in mitral regurgitation. (c) The murmur is usually *widely transmitted*, often being audible over the whole chest and occasionally over the skull and the arterial trunks of the extremities (see Fig. 108). It is usually heard less well over that portion of the precordia occupied by the right ventricle, while, on the other hand, it is relatively loud in the region of the apex impulse, whither it is transmitted through the left ventricle. The same line of transmission

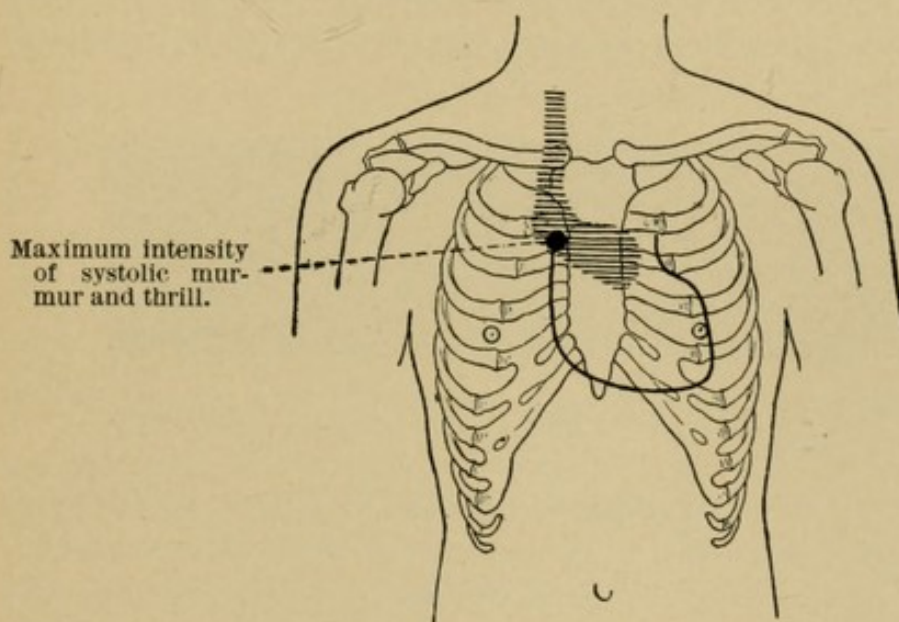


FIG. 108.—Aortic Stenosis. The murmur is audible over the shaded area and sometimes over the whole chest.

was mentioned above as characteristic of the murmur of aortic regurgitation in many cases. The murmur is also to be heard over the carotids and subclavians, and can often be traced over the thoracic aorta along the spine and down the arms.

Until compensation fails the murmur is apt to be a very loud one, especially in the recumbent position; it is occasionally audible at some distance from the chest, and is often rough and vibrating, sometimes musical or croaking. Its length is unusually

great, extending throughout the whole of systole, but to this rule there are occasional exceptions. The first sound in the aortic region is altogether obliterated, as a rule, and the second sound is either absent or very feeble.¹

(2) *The Pulse.*

Owing to the opposition encountered by the left ventricle in its attempt to force blood into the aorta, its contraction is apt to be prolonged; hence the pulse wave *rises* gradually and late, and *falls away slowly*. This is shown very well in sphygmographic tracings (see Fig. 109). But further, the blood thrown into the aorta by the left ventricle is prevented, by the narrowing of the aortic valves, from striking upon and expanding the arteries with its ordinary force; hence the pulse wave is not only slow to rise but *small in*




FIG. 109.—Sphygmographic Tracing of the Pulse in Uncomplicated Aortic Stenosis. Compare with the normal pulse wave and with that of aortic regurgitation (page 174).

height, contrasting strongly with the powerful apex beat ("*pulsus parvus*"). Again, the delay in the emptying of the left ventricle, brought about by the obstruction at the aortic valves, renders the contractions of the heart relatively *infrequent*, and hence the pulse is *infrequent* (*pulsus rarus*) as well as small and slow to rise. The "*pulsus rarus, parvus, tardus*" is, therefore, a most constant and important point in diagnosis, but unfortunately it is to be felt in perfection only in the *very* rare cases in which aortic stenosis occurs uncomplicated. When stenosis is combined with regurgitation, as is almost always the case, the above-described qualities of the pulse are greatly modified as a result of the regurgitation. It

¹ "Occasionally, as noted by W. H. Dickinson, there is a musical murmur of great intensity in the region of the apex, probably due to a slight regurgitation at high pressure through the mitral valve."—OSLER.

is also to be remembered that the pulse of aortic stenosis is by no means unalterable and does not exhibit its typical plateau at all times.

A less characteristic, but decidedly frequent, variation in the pulse wave of aortic stenosis is the *anacrotic* curve. The slow, long pulse with a long plateau at the summit is seen also in some cases of mitral stenosis and renal disease, and is not peculiar to aortic stenosis, but taken in connection with the other signs of the disease it has great value in diagnosis.

(3) *The Thrill.*

In the majority of cases an intense purring vibration may be felt if the hand is laid over the upper portion of the sternum, especially over the second right intercostal space. This thrill is continued into the carotids, can occasionally be felt at the apex, and rarely over a considerable area of the chest. It is a very important aid in the diagnosis of aortic stenosis, but is by no means pathognomonic, since aneurism may produce a precisely similar vibration of the chest wall.

The heart is slightly enlarged to the left and downward as a rule, but the apex impulse is unusually indistinct, "a well-defined and deliberate push of no great violence" (Broadbent). Corresponding to the protracted sustained systole the first sound at the apex is dull and long, but not very loud.

Differential Diagnosis.

A systolic murmur heard loudest in the second right intercostal space is by no means peculiar to aortic stenosis, but may be due to any of the following conditions:

- (a) Roughening, stiffness, fenestration, or slight congenital malformation of the aortic valves.
- (b) Roughening or diffuse dilatation of the arch of the aorta.
- (c) Aneurism of the aorta or innominate artery.
- (d) Functional murmurs.
- (e) Pulmonary stenosis.
- (f) Open ductus arteriosus.
- (g) Mitral regurgitation.

(*a* and *b*) The great majority of such systolic murmurs at the base of the heart, first appearing after middle life, are due to the causes mentioned above under *a*, *b*, and *c*. In such cases it is usually combined with accentuation and ringing quality of the aortic second sound owing to the arterio-sclerosis and high arterial tension associated with the changes which produce the murmur. This *accentuation of the aortic second sound* enables us, except in extraordinarily rare cases, to exclude aortic stenosis, in which the intensity of the aortic second sound is almost always much reduced.

Diffuse dilatation of the aorta, such as often accompanies aortic regurgitation, is a frequent cause of a systolic murmur loudest in the second right interspace. This may be recognized in certain cases by the characteristic area of dulness on percussion and by its association with aortic regurgitation of long standing (see Fig. 102).

Roughening of the intima of the aorta (*endaortitis*) is always to be suspected in elderly patients with calcified and tortuous peripheral arteries, and such a condition of the aorta doubtless favors the occurrence of a murmur, especially when accompanied by a slight degree of dilatation. The absence of a thrill and a long, slow pulse with a low maximum serves to distinguish such murmurs from those of aortic stenosis.

(*c*) Aneurism of the ascending arch of the aorta or of the innominate artery may give rise to every sign of aortic stenosis except the characteristic pulse and the diminution of the aortic second sound. In aneurism we may have a well-marked tactile thrill and a loud systolic murmur transmitted into the neck, but there is usually some pulsation to be felt in the second right intercostal space and often some difference in the pulses or in the pupils, as well as a history of pain and symptoms of pressure upon the trachea and bronchi or recurrent laryngeal nerve. In aneurism the aortic second sound is usually loud and accompanied by a shock, and the pulse shows none of the characteristics of aortic stenosis.

(*d*) Functional murmurs, sometimes known as "hæmic," are occasionally best heard in the aortic area instead of in their usual situation (second left intercostal space). They occur especially in young, anæmic persons, are not accompanied by any cardiac en-

largement, by any palpable thrill, any diminution in the aortic second sound, or any distinctive abnormalities in the pulse.

(e) Pulmonary stenosis, a rare lesion, is manifested by a systolic murmur and by a thrill whose maximum intensity is usually on the left side of the sternum. In the rare cases in which this murmur is best heard in the aortic area it may be distinguished from the murmur of aortic stenosis by the fact that it is not transmitted into the vessels of the neck, has no effect upon the aortic second sound, and is not accompanied by the characteristic changes in the pulse.

(f) The murmur due to persistence of the ductus arteriosus may last through systole and into diastole; it may be accompanied by a thrill, but does not affect the aortic second sound nor the pulse.

(g) The systolic murmur of aortic stenosis may be heard loudly at the apex, and hence the lesion may be mistaken for mitral regurgitation. But the maximum intensity of the murmur of aortic stenosis is almost invariably in the aortic area, and its association with a thrill and a long, slow pulse should enable us easily to differentiate the two lesions.

By the foregoing differentiae aortic stenosis may be distinguished from the other conditions which resemble it, *provided it occurs uncomplicated*, but unfortunately this is very rare. As a rule, it occurs in connection with aortic regurgitation, and its characteristic signs are therefore obscured or greatly modified by the signs of the latter disease. We may suspect it in such cases (provided the mitral valve is sufficient) when we have, in addition to the signs of aortic regurgitation, a systolic murmur and palpable thrill in the aortic area transmitted into the great vessels, a modification of the Corrigan pulse in the direction of the "*pulsus tardus, rarus, parvus*," and less visible arterial pulsation than is to be expected in pure aortic regurgitation.

Occasionally one can watch the development of an aortic stenosis out of what was formerly a pure regurgitant lesion, the stenosis gradually modifying the characteristics of the previous condition. One must be careful, however, to exclude a relative mitral insuffi-

ciency which, as has been already mentioned above, is very apt to supervene in cases of aortic disease, owing to dilatation of the mitral orifice, and which may modify the characteristic signs of aortic regurgitation very much as aortic stenosis does.

TRICUSPID REGURGITATION.

Endocarditis affecting the tricuspid valve is rare in post-fœtal life; in the fœtus it is not so uncommon. In cases of ulcerative or malignant endocarditis occurring in adult life, the tricuspid valve is occasionally involved, but the majority of cases of tricuspid disease occur as a result of disease of the mitral valve and in the following manner: Hypertrophy of the right ventricle occurs as a result of the mitral disease, is followed in time by dilatation, and with this dilatation comes a stretching of the ring of insertion of the tricuspid valve, and hence a regurgitation through that valve. Tricuspid regurgitation, then, occurs in the latest stages of almost every case of mitral disease and sometimes during the severer attacks of failing compensation.

Out of 405 autopsies at Guy's Hospital in which evidence of tricuspid regurgitation was found, 271, or two-thirds, resulted from mitral disease, 68 from myocardial degeneration, 55 from pulmonary disease (bronchitis, emphysema, cirrhosis of the lung). Very few of these cases had been diagnosed during life, and in all of them the valve was itself healthy but insufficient to close the dilated orifice.

Gibson and some other writers believe that temporary tricuspid regurgitation is the commonest of all valve lesions, and results from weakening of the right ventricle in connection with states of anæmia, gastric atony, fever, and many other conditions. It is very difficult to prove or disprove such an assertion.

Tricuspid regurgitation is often referred to as serving like the opening of a "*safety valve*" to relieve a temporary pulmonary engorgement. This "*safety-valve*" action, however, may be most disastrous in its consequences to the organism as a whole, despite the temporary relief which it affords to the overfilled lungs. The engorgement is simply transferred to the liver and thence to the

abdominal organs and the lower extremities, so that as a rule the advent of tricuspid regurgitation is recognized not as a relief but as a serious and probably fatal disaster.

Physical Signs.

- (1) A systolic murmur is heard loudest at or near the fifth left costal cartilage.
- (2) Systolic venous pulsation in the jugulars and in the liver.
- (3) Engorgement of the right auricle producing an area of dullness beyond the right sternal margin.
- (4) Intense cyanosis.

(1) *The Murmur.*—The maximum intensity of the systolic murmur of tricuspid regurgitation is usually near the junction of the fifth or sixth left costal cartilages with the sternum. Leube finds the murmur a rib higher up, but it is generally agreed that the tricuspid area is a large one, so that the murmur may be heard anywhere over the lower part of the sternum or even to the right of it. On the other hand, there are some tricuspid murmurs which are best heard at a point midway between the apex impulse and the ensiform cartilage. The murmur is not widely transmitted and is usually inaudible in the back; at the end of expiration its intensity is increased.

In some cases we have no evidence of tricuspid regurgitation other than the murmur just described, but—

(2) Of more importance in diagnosis is the presence of a systolic pulsation in the external jugular veins and of the liver, which unfortunately is not always present, but which when present is pathognomonic. I have already explained (see p. 35) the distinction between true *systolic* jugular pulsation, which is practically pathognomonic of tricuspid regurgitation, and simple presystolic undulation or distention of the same veins, which has no necessary relation to this disease. The decisive test is the effort permanently to empty the vein by stroking it upward from below. If it instantly refills from below and continues to pulsate, tricuspid regurgitation is almost certainly present. If, on the other hand, it does not refill from below, the cause must be sought elsewhere.

Pulsation in the liver must be distinguished from the "jogging" motion which may be transmitted to it from the abdominal aorta or from the right ventricle. To eliminate these transmitted impulses one must be able to grasp the liver bimanually, one hand in front and one resting on the lower ribs behind, and to feel it distinctly expand with every systole, or else to take its edge in the hand and to feel it enlarge in one's grasp with every beat of the heart.

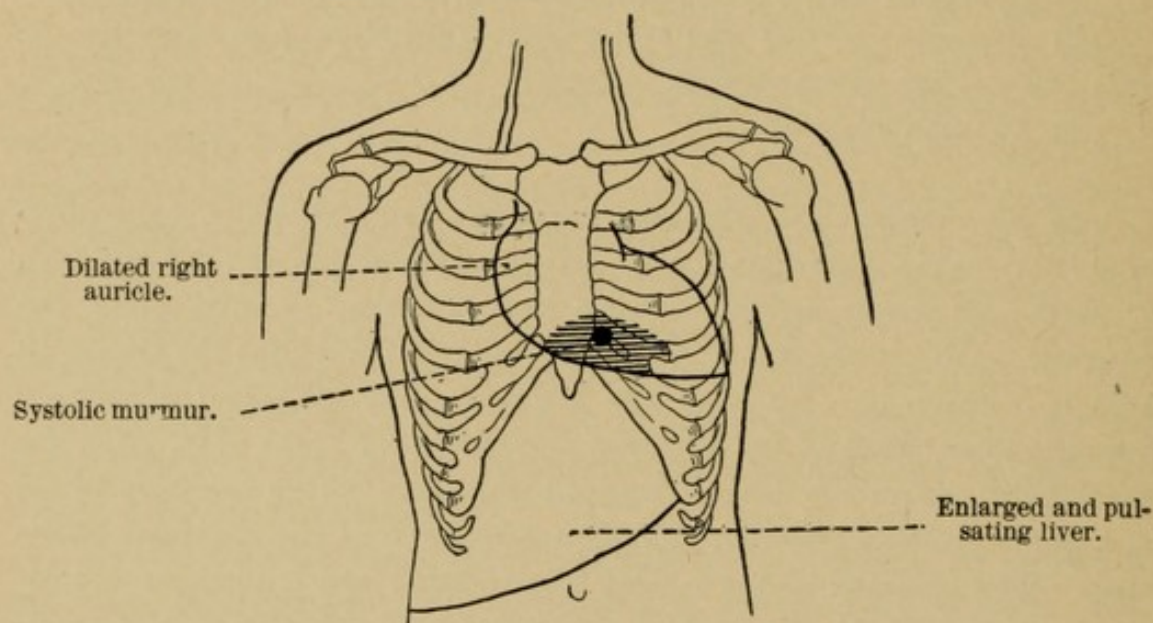


FIG. 110.—Tricuspid Regurgitation. The murmur is heard best over the shaded area.

Pressure upon the liver often causes increased distention and pulsation of the external jugulars if tricuspid regurgitation is present.

(3) Enlargement of the heart, both to the right and to the left, as well as downward, can usually be demonstrated. In rare cases a dilatation of the right auricle may be suggested by a percussion outline such as that shown in Fig. 110.

The pulmonic second sound is usually not accented. The importance of this in differential diagnosis will be mentioned presently. If a progressive diminution in the intensity of the sound occurs under observation, the prognosis is very grave.

(4) Cyanosis is usually very great, and dyspnoea and pulmonary oedema often make the patient's condition a desperate one.

Differential Diagnosis.

The statistics of the cases autopsied at the Massachusetts General Hospital show that tricuspid regurgitation is less often recognized during life than any other valvular lesion. The diagnosis was made ante mortem on only five out of twenty-nine cases. This is due to the following facts:

(a) Tricuspid regurgitation may be present and yet give rise to no physical signs which can be recognized during life.

(b) Tricuspid regurgitation occurs most frequently in connection with mitral regurgitation; hence its signs are frequently masked by those of the latter lesion. It is, therefore, a matter of great importance as well as of great difficulty to distinguish tricuspid regurgitation from

(1) Mitral Regurgitation.

The difficulties are obvious. The murmur of mitral regurgitation has its maximum intensity not more than an inch or two from the point at which the tricuspid murmur is best heard. Both are systolic in time. They are, therefore, to be distinguished only—

(a) In case we can demonstrate that there are two areas in which a systolic murmur is heard with relatively great intensity, with an intervening space over which the murmur is less clearly to be heard (see Fig. 111).

(b) Occasionally the two systolic murmurs are of different pitch or of different quality, and may be thus distinguished.

(c) Tricuspid murmurs are not transmitted into the left axilla and are rarely audible in the back, and this fact is of value in case we have to distinguish between uncomplicated tricuspid regurgitation and uncomplicated mitral regurgitation. Unfortunately these lesions are very apt to occur simultaneously, so that in practice our efforts are generally directed toward distinguishing between a pure mitral regurgitation and one complicated by tricuspid regurgitation.

(d) In cases of doubt the phenomena of venous pulsation in the jugulars and in the liver are decisive if present, but their absence proves nothing.

(e) Accentuation of the pulmonic second sound is almost invariably present in uncomplicated mitral disease and is apt to disappear in case the tricuspid begins to leak, since engorgement of the lungs is thereby for the time relieved, but in many cases the pulmonic second sound remains most unaccountably strong even when the tricuspid is obviously leaking.

(2) From "functional" systolic murmurs tricuspid insufficiency may generally be distinguished by the fact that its murmur is best

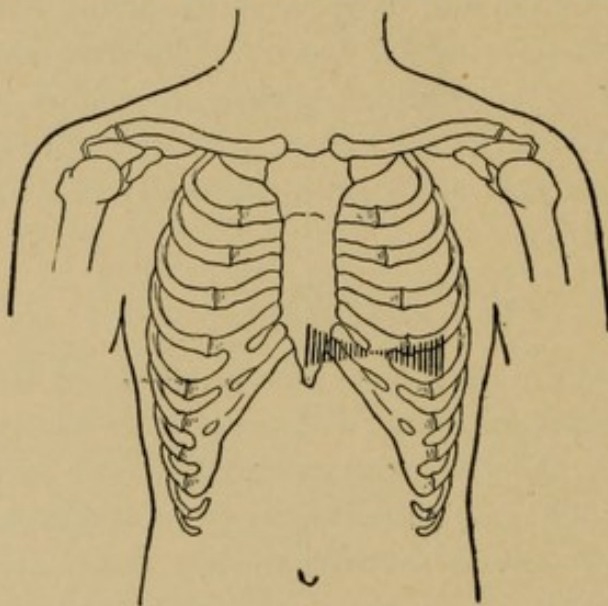


FIG. 111.—Two Systolic Murmurs (Mitral and Tricuspid) with a "Vanishing Point" between.

heard in the neighborhood of the ensiform cartilage, and not in the second right intercostal space where most functional murmurs have their seat of maximum intensity. Functional murmurs are unaccompanied by venous pulsation, cardiac dilatation, or cyanosis.

(3) Occasionally a pericardial friction rub simulates the murmur of tricuspid insufficiency, but, as a rule, pericardial friction is much more irregular in the time of its occurrence and is not regularly synchronous with any definite portion of the cardiac cycle.

TRICUSPID STENOSIS.

One of the rarest of valve lesions is narrowing of the tricuspid valve. No case has come under my observation, and in 1898, Her-

rick was able to collect but 154 cases from the world's literature. Out of these 154 cases, 138, or 90 per cent, were combined with mitral stenosis, and only 12 times has tricuspid stenosis been known to occur alone.⁴ These observations account for the fact that tricuspid stenosis has hardly ever been recognized during life, since the murmur to which it gives rise is identical in time and quality and nearly identical in position with that of mitral stenosis. Narrowing of the tricuspid valve is to be diagnosed, therefore, only by the recognition of a presystolic murmur best heard in the tricuspid area and distinguished either by its pitch, quality, or position from the other presystolic murmur due to the mitral stenosis which is almost certain to accompany it.

The heart is usually enlarged, especially in its transverse direction, but the enlargement is just such as mitral stenosis produces, and does not aid our diagnosis at all.

The diagnosis is still further complicated in many cases by the presence of an aortic stenosis in addition to a similar lesion at the tricuspid and mitral valves, so that it seems likely that in the future as in the past the lesion will be discovered first at autopsy.

PULMONARY REGURGITATION.

Organic disease of the pulmonary valve is excessively rare in post-fœtal life, but may occur as part of an acute ulcerative or septic endocarditis. A *temporary* functional regurgitation through the pulmonary valve may be brought about by any cause producing very *high pressure in the pulmonary artery*. I have known two medical students with perfectly healthy hearts who were able, by prolonged holding of the breath, to produce a short, high-pitched diastolic murmur best heard in the second and third left intercostal spaces and ceasing as soon as the breath was let out. Of the occurrence of a murmur similarly produced under pathological conditions, especially in mitral stenosis, much has been written by Graham Steell.

¹ Out of 87 cases collected from the post-mortem records of Guy's Hospital, 85, or 97 per cent, were associated with still more extensive mitral stenosis.

From the diastolic murmur of aortic regurgitation we may distinguish the diastolic murmur of pulmonary incompetency by the fact that the latter is best heard over the pulmonary valve, is never transmitted to the apex of the heart nor to the great vessels, and is never associated with a Corrigan pulse nor with capillary pulsation.¹ The right ventricle is hypertrophied, the pulmonic second sound is sharply accented and followed immediately by the murmur. Evidences of septic embolism of the lungs are frequently present and assist us in diagnosis. The regurgitation which may take place through the rigid cone of congenital pulmonary stenosis is not recognizable during life.

PULMONARY STENOSIS.

Among the rare congenital lesions of the heart valves this is probably the commonest. The heart, and particularly the right ventricle, is usually much enlarged. There is a history of cyanosis and dyspnœa since birth. Pulmonary tuberculosis complicates from one-fourth to one-third of all cases. A systolic thrill is usually to be felt in the second left intercostal space, and a loud systolic murmur is heard in the same area. The pulmonic second sound is weak.

The region in which this murmur is best heard has been happily termed the "*region of romance*" on account of the multiplicity of mysterious murmurs which have been heard there. The systolic murmur of pulmonary stenosis must be distinguished from

(a) Functional murmurs due to anæmia and debility or to severe muscular exertion, and possibly associated with a dilatation of the conus arteriosus.

(b) Uncovering of the conus arteriosus through lack of expansion of the lung.

(c) Aortic stenosis.

(d) Mitral regurgitation.

(e) Aneurism.

(f) Roughening of the intima of the aortic arch.

¹ By registering the variations of pressure in the tracheal column of air Gerhardt has shown graphically that a systolic pulsation of the pulmonary capillaries may occur in pulmonary regurgitation. With the stethoscope a systolic whiff may be heard all over the lungs.

(a and b) Functional murmurs, and those produced in the conus arteriosus, are rarely if ever accompanied by a thrill, are rarely so loud as the murmur of pulmonary stenosis, and are not associated with dyspnoea, cyanosis, and enlargement of the right ventricle.

(c) The murmur of aortic stenosis is usually upon the right side of the sternum and is transmitted to the neck, whereas the murmur of pulmonary stenosis is never so transmitted and is not associated with characteristic changes in the pulse (see above, p. 188).

(d) The murmur of *mitral regurgitation* is occasionally loudest in the region of the pulmonary valve, but differs from the murmur of pulmonary stenosis in being, as a rule, transmitted to the back and axilla and associated with an accentuation of the pulmonary second sound.

(e) *Aneurism* may present a systolic murmur and thrill similar to those found in pulmonary stenosis, but may usually be distinguished from the latter by the presence of the positive signs of aneurism, viz.—pulsation, and dulness in the region of the murmur, and signs of pressure on the trachea or on other structures in the mediastinum.

(f) Roughening of the aortic arch occurs after middle life, while pulmonary stenosis is usually congenital. The murmur due to roughening may be transmitted into the carotids; that of pulmonary stenosis never. Enlargement of the right ventricle is characteristic of pulmonary stenosis, but not of aortic roughening.

COMBINED VALVULAR LESIONS.

It is essential that the student should understand from the first that the number of murmurs audible in the precordia is no gauge for the number of valve lesions. We may have four distinct murmurs, yet every valve sound except one. This is often the case in aortic regurgitation—systolic and diastolic murmurs at the base of the heart, systolic and presystolic at the apex, yet no valve injured except the aortic. In such a case the systolic aortic murmur is due to roughening of the aortic valve. The systolic apex murmur results from relative mitral leakage (with a sound valve). The presystolic apex murmur is of the “Flint” type. Hence in this

case the *diastolic* murmur alone of the four audible murmurs is due to a valvular lesion.

It is a good rule not to multiply causes unnecessarily, and to explain as many signs as possible under a single hypothesis. In the above example the mitral leak might be due to an old endocarditis, and there *might* be mitral stenosis and aortic stenosis as well, but since we can explain all the signs as results—direct and indirect—of one lesion (aortic regurgitation) it is better to do so, and post-mortem experience shows that our diagnosis is more likely to be right when it is made according to this principle.

The most frequent combinations are:

- (1) Mitral regurgitation with mitral stenosis.
- (2) Aortic regurgitation with mitral regurgitation (with or without stenosis).
- (3) Aortic regurgitation with aortic stenosis, with or without mitral disease.

(1) *Double Mitral Disease.*

(a) It very frequently happens that the mitral valve is found to be both narrowed and incompetent at autopsy when only one of these lesions had been diagnosed during life. In fact mitral steno-



FIG. 112.—Mitral Stenosis and Regurgitation, showing relation of murmur to first heart sound.

sis is almost never found at autopsy without an associated regurgitation, so that it is fairly safe to assume, whenever one makes the diagnosis of mitral stenosis, that mitral regurgitation is present as well, whether it is possible to hear any regurgitant murmur or not (see Fig. 112).

(b) On the other hand, with a double mitral lesion one may have only the regurgitant murmur at the mitral valve and nothing to suggest stenosis unless it be a surprising sharpness of the first mitral sound. In chronic cases the changeableness of the murmurs both in type and position is extraordinary. One often finds at one

visit evidences of mitral stenosis and at another evidences of mitral regurgitation alone. Either murmur may disappear altogether for a time and reappear subsequently. This is peculiarly true of the pre-systolic murmur, which is notoriously one of the most fleeting and uncertain of all physical signs.

As a rule the same inflammatory changes which produce mitral regurgitation in early life result as they extend in narrowing the mitral valve, so that the signs of stenosis come to predominate in later years. Coincidentally with this narrowing of the diseased valve a certain amount of improvement in the patient's symptoms may take place, and Rosenbach regards the advent of stenosis in such a case as an attempt at a regenerative or compensatory change. In many cases, however, no such amelioration of the symptoms follows.

(2) *Aortic Regurgitation with Mitral Disease.*

The signs of mitral disease occurring in combination with aortic regurgitation do not differ essentially from those of pure

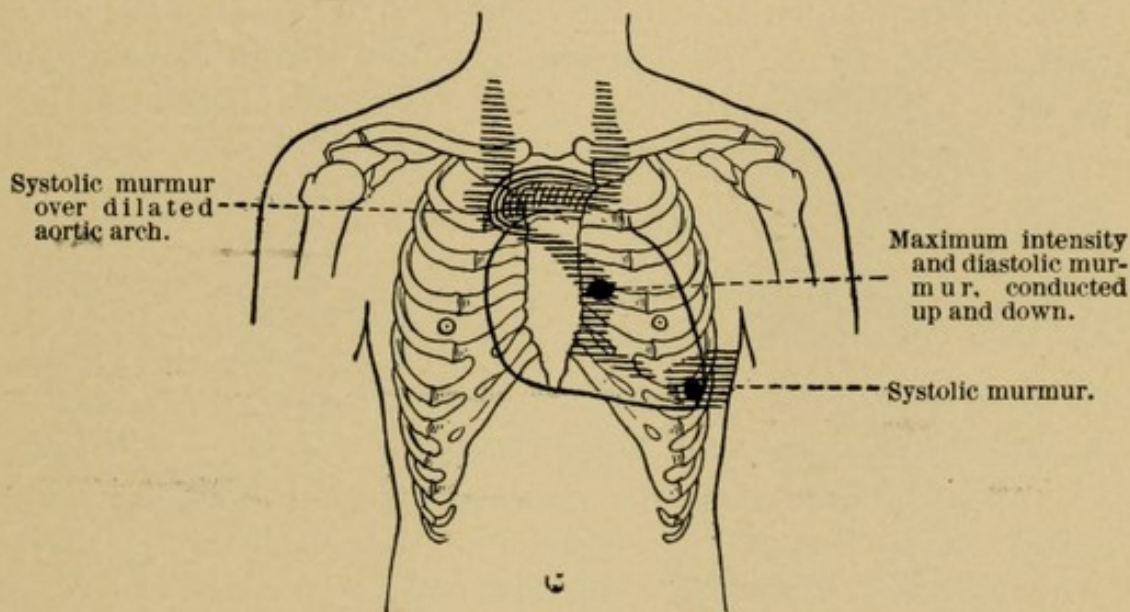


FIG. 113.—Aortic and Mitral Regurgitation. The shaded areas are those in which the murmurs are loudest.

mitral disease except that the enlargement of the heart is apt to be more general and correspond less exclusively to the right ventricle (see Figs. 113 and 114). The manifestations of the aortic le-

sion, on the other hand, are considerably modified by their association with the mitral disease. The Corrigan pulse is distinctly less sharp at the summit and rises and falls less abruptly. Capillary



FIG. 114.—Showing Relation of Murmurs to Heart Sound in Regurgitation at the Aortic and Mitral Valves.

pulse is less likely to be present, and the throbbing of the peripheral arteries is less often visible.

(3) *Aortic Regurgitation with Aortic Stenosis.*

If the aortic valves are narrowed as well as incompetent, we find very much the same modification of the physical signs characteristic of aortic regurgitation as is produced by the advent of a mitral lesion; that is to say, the throbbing in the peripheral arteries is less violent, the characteristics of the radial pulse are less marked, and the capillary pulsation is not always to be obtained at all. Indeed, this blunting of all the typical manifestations of aortic regurgitation may give us material aid in the diagnosis of aortic stenosis, provided always that the mitral valve is still performing its function.

(4) The association of mitral disease with tricuspid insufficiency has been already described on p. 164.

CHAPTER VIII.

PARIETAL DISEASE.—CARDIAC NEUROSES.—CONGENITAL MALFORMATIONS OF THE HEART.

PARIETAL DISEASE OF THE HEART.

Acute Myocarditis.

THE myocardium is seriously, though not incurably, affected in all continued fevers, owing less to the fever itself than to the toxæmia associated with it. "Cloudy swelling," or granular degeneration of the muscle fibres, is produced by relatively mild infections, while a general septicæmia due to pyogenic organisms may produce extensive *fatty* degeneration of the heart within a few days.

The *physical signs* are those of *cardiac weakness*. The most significant change is in the quality of the first sound at the apex of the heart, which becomes gradually shorter until its quality is like that of the second sounds, while in some cases its feebleness makes the second sounds seem accented by comparison. Soft blowing systolic murmurs may develop at the pulmonary orifice, less often at the apex or over the aortic valve.

The apex impulse becomes progressively feebler and more like a tap than a push. *Irregularity* and *increasing rapidity* are ominous signs which may be appreciated in the radial pulse, but still better by auscultation of the heart itself. In most of the acute infections evidence of dilatation of the weakened cardiac chambers is rarely to be obtained during life (although at autopsy it is not infrequently found),¹ but in *acute articular rheumatism* an acute dilatation of the heart appears to be a frequent complication, independ-

¹ Henchen's recent monograph on this subject, "Ueber die acute Herzdilatation bei acuten Infektionskrankheiten," Jena, 1899, does not seem to me convincing.

ent of the existence of any valvular disease. Attention has been especially called to this point by Lees and Boynton (*British Med. Jour.*, July 2, 1898) and by S. West.

INFLUENZA is also complicated not infrequently by acute cardiac dilatation.

Chronic Myocarditis ("Weakened Heart").

Fatty or fibroid changes in the heart wall occurring in *chronic* disease are usually the result of sclerosis of the coronary arteries and imperfect nutrition of the myocardium, but chronic toxæmias, like pernicious anæmia, may also produce a very high grade of fatty degeneration of the heart and especially of the papillary muscles.

Whether fatty or fibroid changes predominate, the physical signs are the same.

Physical Signs of Chronic Myocarditis.

For the recognition of these changes in the myocardium our present methods of physical examination are always unsatisfactory and often wholly inadequate. Extensive degenerations of the heart wall are not infrequently found at autopsy when there has been no reason to suspect them during life. On the other hand, the autopsy often fails to substantiate a diagnosis of degeneration of the heart muscle, although all the physical signs traditionally associated with this condition were present during life.¹ To a considerable extent, therefore, our diagnosis of myocarditis must depend upon the history and symptoms of the case; physical examination can sometimes supplement these, sometimes not. Symptoms of *cardiac weakness* developing in a man past middle life, especially in a patient who shows evidences of arterio-sclerosis or high arterial tension, or who has suffered from the effects of alcohol and syphilis, suggest parietal disease of the heart, fatty or fibroid. The probability is increased if there have been attacks of angina pectoris, Cheyne-Stokes breathing, or of syncope.

Inspection and *palpation* may reveal nothing abnormal, or there

¹ A well-known Boston pathologist recently told me that he had never known a case of myocarditis correctly diagnosed during life.

may be an unusually diffuse, slapping cardiac impulse associated perhaps with a displacement of the apex beat to the left and downward. Marked irregularity of the heart beat, both in force and in rhythm, is sometimes demonstrable by these methods, and an increase in the area of cardiac dulness may be demonstrable in case dilatation has followed the weakening of the heart wall. *Auscultation* may reveal nothing abnormal except that the aortic second sound is unusually sharp; in some cases *feeble and irregular heart sounds* are heard, although the first sound at the apex is not infrequently sharp. Reduplication of one or both sounds and disturbance of rhythm, especially the "gallop rhythm," are not infrequent. If the mitral sphincter is dilated, or the papillary muscles are weakened, as not infrequently happens, we may have evidences of mitral regurgitation, a systolic murmur at the apex heard in the left axilla and back with accentuation of the pulmonic second sound.

Summary.

1. The history and symptoms of the case or the condition of other organs are often of more diagnostic value than is the physical examination of the heart itself, which may show nothing abnormal.

2. Among the rather unreliable physical signs, those most often mentioned are:

- (a) Weakness and irregularity of the heart sounds.
- (b) Accentuation of the aortic second sound.
- (c) A diffuse slapping cardiac impulse.
- (d) Reduplication of some of the cardiac sounds (gallop rhythm).
- (e) Evidences of cardiac dilatation.
- (f) Murmurs—especially the murmur of mitral insufficiency which often occurs as a result of dilatation of the valve orifices and weakening of the cardiac muscle.

Differential Diagnosis.

We have to distinguish myocarditis from—

- (a) Uncomplicated valvular lesions.
- (b) Cardiac neuroses.

(a) It has been already pointed out that valvular lesions do not necessarily give rise to any murmurs when compensation has failed. Under such circumstances one hears only irregular and weak heart sounds, as in myocarditis. The history of a long-standing valvular trouble, a knowledge of the previous existence of murmurs, the age, method of onset, and symptoms of the case may assist us in the diagnosis. Cases of myocarditis are less likely to be associated with extensive dropsy than are cases of valvular disease whose compensation has been ruptured.

(b) Weakness and irregularity of the cardiac sounds, when due to nervous affection of the heart and unassociated with parietal or valvular changes, is usually less marked after slight exertion. The heart "rises to the occasion" if the weakness is a functional one. On the other hand, if fatty or fibroid changes are present, the signs and symptoms are much aggravated by any exertion.

In some cases of myocarditis the pulse is excessively slow and shows no signs of weakness. This point will be referred to again in the chapter on Bradycardia.

Fatty Overgrowth.

An abnormally large accumulation of fat about the heart may be suspected if, in a very obese person, signs of cardiac embarrassment (dyspnœa, palpitation) are present, and if on examination we find that the heart sounds are feeble and distant but preserve the normal difference from each other. When the heart wall is seriously weakened (as in the later weeks of typhoid), the heart sounds become more alike owing to the shortening of the first sound.

In fatty overgrowth this is not the case.

The diagnosis, however, cannot be positively made. We suspect it under the conditions above described, but no greater certainty can be attained.

Fatty Degeneration.

There are no physical signs by which fatty degeneration of the heart can be distinguished from other pathological changes which result in weakening the heart walls. An extensive degree of fatty

degeneration is often seen post mortem in cases of pernicious anæmia, although the heart sounds have been clear, regular, and in all respects normal during life. The little we know of the physical signs common to fatty degeneration and to other forms of parietal disease of the heart has been included in the section on Myocarditis (see p. 203).

CARDIAC NEUROSES.

Tachycardia (Rapid Heart).

Simple quickening of the pulse rate, or tachycardia, which may pass altogether unnoticed by the patient himself, is to be distinguished from palpitation, in which the heart beats, whether rapid or not, force themselves upon the patient's attention.

The pulse rate may vary a great deal in health. A classmate of mine at the Harvard Medical School had a pulse never slower than 120, yet his heart and other organs were entirely sound. Such cases are not very uncommon, especially in women. Temporarily the pulse rate may be greatly increased, not only by exercise and emotion, but by the influence of fever, of gastric disturbances, or of the menopause. Such a tachycardia is not always of brief duration. The effects of a great mental shock may produce an acceleration of the pulse which persists for days or even weeks after the shock.

Among organic diseases associated with weakening of the pulse the commonest are those of the heart itself. Next to them, exophthalmic goitre, tumors or hemorrhage in the medulla, and obscure diseases of the female organs of generation, are the most frequent causes of tachycardia.

The only form of tachycardia which is worthy to be considered as a more or less independent malady is

Paroxysmal Tachycardia.

As indicated in the name, the attacks of this disease are apt to begin and to cease *suddenly*. They may last a few hours or several days. The pulse becomes frightfully rapid, often 200 per minute or more. Bristowe records a case with a pulse of 308 per minute.

In the radial artery the pulse beat may be impalpable. The heart sounds are regular and clear, but the diastolic pause is shortened and the first sound becomes short and "valvular," resembling the second ("*tic-tac heart*"). The paroxysm may be associated with aphasia and abnormal sensations in the left arm. Occasionally the heart becomes dilated, and œdema of the lungs, albuminuria, and other manifestations of stasis appear. As a rule, however, paroxysmal tachycardia can be distinguished from the rapid heart-beat associated with cardiac dilatation by the fact that the heart remains perfectly regular. This same fact also assists us in excluding the cardiac neuroses due to tobacco, tea, and other poisons. From the tachycardia of Graves' disease the affection now in consideration differs by its paroxysmal and intermittent character.

Bradycardia (Slow Heart).

In many healthy adults the heart seldom beats over 50 times a minute.

I. Among the causes which may produce for a short time an abnormally slow heart-beat are:

(a) *Exhaustion*; for example, after fevers, after parturition, or severe muscular exertion.

(b) *Toxæmia*; for example, jaundice, uræmia, auto-intoxications in dyspepsia.

(c) In certain *hysterical and melancholic* states and in *neurotic children*, the pulse may be exceedingly slow. *Pain* has also a tendency to retard the pulse.

(d) An *increase of intracranial pressure*, as in meningitis, cerebral hemorrhage, depressed fracture of the skull. Possibly in this category belong the cases of bradycardia sometimes seen in epileptiform or during syncopal attacks. Bradycardia from any one of these causes is apt to be of comparatively short duration.

II. *Permanent bradycardia* is most often associated with coronary sclerosis and myocarditis. In this disease the pulse may remain below 40 for months or years, though strong and regular, yet the patient may be free from disagreeable symptoms of any kind. The rate of the heart-beat cannot always be estimated by counting

the radial pulse. Not infrequently many pulsations of the heart are not of sufficient force to transmit a wave to the radial artery, and the mistake should never be made of diagnosing bradycardia simply by counting the radial pulse.

Arrhythmia.

1. *Physiological Arrhythmia.*—Arrhythmia, or irregularity in the force or rhythm of the heart-beat, is to a certain extent physiological. The heart normally beats a little faster and a little more strongly during inspiration than during expiration. Any psychical disturbance or muscular exertion may produce irregularity as well as a quickening of the heart-beat. Rarely the pulse may be irregular throughout life in perfectly healthy persons. This irregularity is usually of rhythm alone; every second or third beat may be regularly omitted without the individual knowing anything about it or feeling any disagreeable symptoms connected with it. More rarely the heart's beats may be permanently irregular in force as well as rhythm despite the absence of any discoverable disease.

In children the pulse is especially apt to be irregular, and during sleep some children show that modification of rhythm known as the "*paradoxical pulse*," which consists in a quickening of the pulse with diminution in volume during inspiration.

(2) If we leave on one side diseases of the heart itself, *pathological arrhythmia* is most frequently seen in persons who have used tobacco or tea to excess, or in dyspepsia. In these conditions it is often combined with palpitation and becomes thereby very distressing to the patient. In connection with cardiac disease the following types of arrhythmia may be distinguished:

(a) *Paradoxical Pulse.*—Any cause which leads to weakening of the heart's action may occasionally be associated with paradoxical pulse. Fibrous pericarditis has been supposed to be frequently associated with this type of arrhythmia, but if so it is by no means its only cause.

(b) The *bigeminal pulse* is seen most frequently in cases of uncompensated heart disease (particularly mitral stenosis) after the administration of digitalis. Every other beat is weak or abortive

and is succeeded by an unusually long pause. Sometimes every third beat is of the abortive type, or an unusually long interval may divide the heart-beats into groups of three ("*trigeminal pulse*").

(c) *Embryocardia*, or the "tic-tac heart," represents a shortening of the diastolic pause and of the first sound of the heart so that it resembles the second sound, as in the fœtal heart. Any case of uncompensated heart disease, whether valvular or parietal, may be associated with this disturbance of rhythm.

(d) The *gallop rhythm*.

Owing to a reduplication of one of the heart sounds (usually the second), we may have three sounds instead of two with each beat of the heart, the sounds possessing a rhythm which reminds us of the hoof-beats of a galloping horse (see p. 127). This rhythm is heard especially in the failing heart of interstitial nephritis or coronary sclerosis.

(e) *Delirium cordis* is a term used to express any great irregularity and rapidity of the heart-beats which cannot be reduced to a single type or rhythm. It is seen in the gravest stages of uncompensated heart disease.

Palpitation.

Defined by Osler as "irregular or forcible heart action *perceptible to the individual*." The essential point is that the individual becomes conscious of each beat of his heart, whether or no the heart action is in any way abnormal.

(a) In irritable conditions of the nervous system, such as occur at puberty, at climacteric, or in neurasthenic persons, palpitation may be very distressing. Temporary disturbances, such as fright, may produce a similar and more or less lasting effect.

(b) The effect of high altitudes, or of even a moderate elevation (1,500 feet) is sufficient to produce in many healthy persons a quickening and strengthening of the heart's action, so that sleep may be prevented. After a few nights this condition usually passes off, provided the heart is sound.

(c) Abuse of tobacco and tea have a similar effect.

Auscultation of a palpitating heart shows nothing more than unusually loud and ringing heart sounds, but since palpitation is often associated with arrhythmia of one or another type we must be careful to exclude the palpitation symptomatic of acute dilatation of the heart, such as may occur in debilitated persons after violent or unusual exertion. In this condition the area of cardiac dulness is increased and dyspnœa upon slight exertion becomes marked. It goes without saying that in almost any case of organic disease of the heart palpitation may be a very marked and distressing symptom.

CONGENITAL HEART DISEASE.

From the time of birth it is noticed that the child is markedly and permanently cyanosed, hence the term "blue baby." Dyspnœa is often, though not always, present, and may interfere with sucking. The cyanosis is practically sufficient in itself for the diagnosis.

Among congenital diseases of the heart the commonest and the most important (because it is less likely than any of the others to prove immediately fatal) is:

1. *Pulmonary Stenosis.*

This lesion is usually the result of foetal endocarditis, and is often associated with malformations and defects, such as patency of the foramen ovale and persistence of the ductus arteriosus. The physical signs of pulmonary stenosis are:

(a) A palpable systolic thrill most distinct in the pulmonary area.

(b) A loud murmur (often rough or musical) heard best in the same region, but usually transmitted to all parts of the chest.

(c) A weak or absent pulmonic second sound.

(d) An increased area of cardiac dulness corresponding to the right ventricle.

Unlike most other varieties of congenital heart disease, pulmonary stenosis is compatible with life for many years, and "blue babies" with this lesion may grow up and enjoy good health, al-

though usually subject to pulmonary disorders (pneumonia or tuberculosis). For a discussion of the differential diagnosis of this lesion, see above, p. 198.

2. Defects in the Ventricular Septum.

The loud *systolic murmur* produced by the rush of blood through an opening between the ventricles is heard, as a rule, over the whole precordia. Its point of maximum intensity differs in different cases, but is hardly ever near the apex of the heart. The most important diagnostic point is the *absence* of a palpable thrill. With almost every other form of congenital heart disease in which a loud murmur is audible, there is a thrill as well. Hypertrophy of both ventricles may be present, but is seldom marked in uncomplicated cases.

(*Patency of the foramen ovale*, if unassociated with other defects, does not usually produce any murmur or other signs by which it can be recognized during life, and causes no symptoms of any kind.)

3. Persistence of the Ductus Arteriosus.

The most characteristic sign is a loud, vibratory systolic murmur with its intensity at the base of the heart and *unassociated with hypertrophy of either ventricle*. If complicated with stenosis at or close above the pulmonary valves, persistence of the ductus arteriosus cannot be diagnosed, as the murmur produced by it cannot with certainty be distinguished from that of the pulmonary stenosis, and the presence of hypertrophy of the right ventricle deprives us of the one relatively characteristic mark of a patent arterial duct.

It has been claimed that a murmur persisting through systole and into diastole is diagnostic of an open arterial duct, but this supposition is not borne out by post-mortem evidence.

The signs produced by the other varieties of congenital heart disease, such as aortic stenosis and tricuspid or mitral lesions, do not differ materially from those characterizing those lesions in

adults. Excluding these, we may summarize the signs of the other lesions as follows:

(a) Practically all cases of congenital heart disease, which produce any physical signs beyond cyanosis and dyspnœa, manifest themselves by a loud systolic murmur heard all over the precordia and often throughout the chest. Its maximum intensity is usually at or near the base of the heart.

(b) If there is *no thrill* and *no hypertrophy*, the lesion is probably a defect in the ventricular septum.

(c) If there is a *thrill* but *no hypertrophy*, the lesion is probably a patent ductus arteriosus.

(d) If there is a *thrill* and *hypertrophy* of the right ventricle, the lesion is probably pulmonic stenosis, especially if the pulmonic second sound is feeble.

CHAPTER IX.

DISEASES OF THE PERICARDIUM.

I. PERICARDITIS.

THREE forms are recognized clinically :

- (1) Plastic, dry, or fibrinous pericarditis.
- (2) Pericarditis with effusion (serous or purulent).
- (3) Pericardial adhesions or adherent pericardium.

Fibrinous pericarditis may be fully developed without giving rise to any physical signs that can be appreciated during life. In several cases of pneumonia in which I suspected that pericarditis might be present, I have listened most carefully for evidences of the disease and been unable to discover any; yet at autopsy it was found fully developed—the typical shaggy heart. We have every reason to believe, therefore, that pericarditis is frequently present but unrecognized, especially in pneumonia and in the rheumatic attacks of children. On the other hand, it may give rise to very marked signs which are the result of—

(a) The rubbing of the roughened pericardial surfaces against one another when set in motion by the cardiac contractions.

(b) The presence of fluid in the pericardial sac.

(c) The interference with cardiac contractions brought about by obliteration of the pericardial sac together with the results of adhesions between the pericardium and the surrounding structures.

(1) DRY OR FIBRINOUS PERICARDITIS.

The diagnosis rests upon a single physical sign—“*pericardial friction*”—which is usually to be appreciated by auscultation alone, but may occasionally be felt as well. Characteristic pericardial friction is a rough, irregular, grating or shuffling sound which oc-

curs irregularly and interruptedly during the larger part of each cardiac cycle. It is almost never accurately synchronous either with systole or diastole, but *overlaps* the cardiac sounds, and encroaches upon the pauses in the heart cycle. It is seldom exactly the same in any two successive cardiac cycles and differs thereby from sounds produced within the heart itself. Pericardial friction seems very near to the ear and may often be increased by pressure

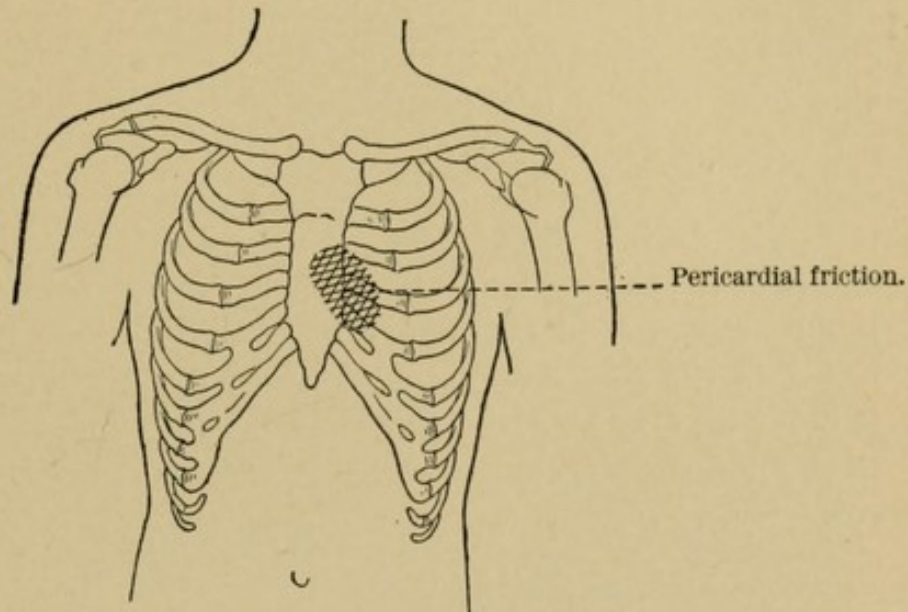


FIG. 115.—Showing Most Frequent Site of Audible Pericardial Friction.

with the stethoscope; it is not materially influenced by the respiratory movements.

It is best heard in the majority of cases in the position shown in Fig. 115; that is, over that portion of the heart which lies nearest to the chest wall and is not covered by the margins of the lungs; but not infrequently it may be heard at the base of the heart or over the whole precordial region. The sounds are fainter if the patient lies on the right side, and sometimes intensified if, while sitting or standing, he leans forward and toward the left, so as to bring the heart into closer apposition with the chest wall.

Pericardial friction sounds often change rapidly from hour to hour, and may disappear and reappear in the course of a day.

In rare cases the friction may occur only during systole or only during diastole. In such cases the diagnosis between pericardial and intracardial sounds may be very difficult.

DIFFERENTIAL DIAGNOSIS.

(a) Pleuro-Pericardial Friction.

Fibrinous inflammation affecting that part of the pleura which overlaps the heart may give rise to sounds altogether indistinguishable from those of true pericardial friction when the inflamed pleural surfaces are made to grate against one another by the movements of the heart. Such sounds are sometimes increased in intensity during forced respiration and disappear at the end of expiration, while true pericardial friction is usually best heard if the breath is held at the end of expiration. If a friction sound heard in the pericardial region ceases altogether when the breath is held, we may be sure that it is produced in the pleura and not in the pericardium, but in many cases the diagnosis cannot be made correctly.

(b) Intracardiac Murmurs.

From murmurs due to valvular disease of the heart, pericardial friction can usually be distinguished by the fact that the sounds to which it gives rise do not accurately correspond either with systole or diastole, and do not occupy constantly any one portion of either of these periods. Cardiac murmurs are more regular, seem less superficial, and vary less with position and from hour to hour. Pressure with the stethoscope does not increase so considerably the intensity of intracardiac murmurs. When endocarditis and pericarditis occur simultaneously, it may be very difficult to distinguish the two sets of sounds thus produced. The pericardial friction is usually recognized with comparatively little difficulty, but it is hard to make sure whether in addition we hear endocardial murmurs as well.

(2) PERICARDIAL EFFUSION.

Following the fibrinous exudation, which roughens the pericardial surface and produces the friction sounds just described, serum may accumulate in the pericardial sac. Its quantity may exceed but slightly the amount of fluid normally present in the pericar-

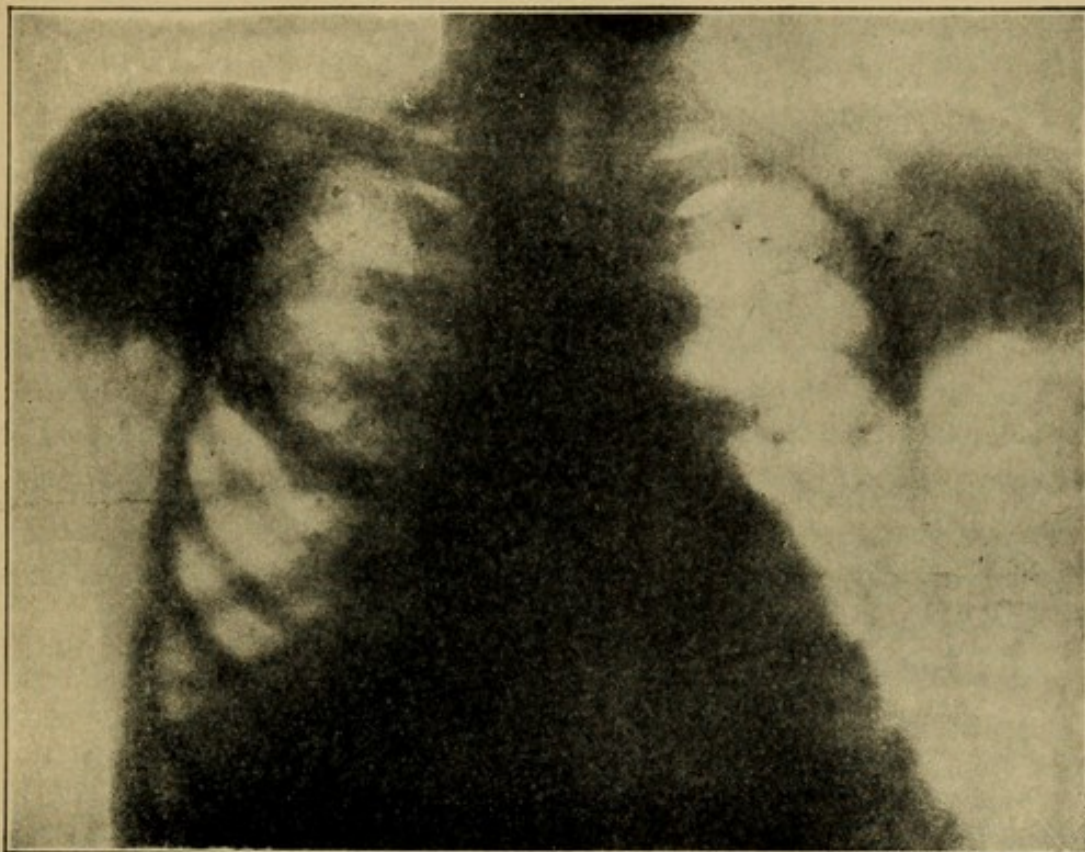


FIG. 116.—Pericardial Effusion, Cardio-hepatic Angle obtuse. (From v. Ziemssen's Atlas.)

dium, or may be so great as to embarrass the cardiac movements and finally to arrest them altogether. In chronic (usually tuberculous) cases, the pericardium may become stretched so as to hold a quart or more without seriously interfering with the heart's action, while a much smaller quantity, if effused so rapidly that the pericardium has no time to accommodate itself by stretching, will prove rapidly fatal.

Hydropericardium denotes a dropsy of the pericardium occurring by transudation as part of a general dropsy in cases of renal disease or cardiac weakness. The physical signs to which it gives rise do not differ from those of an inflammatory effusion, and, accordingly, all that is said of the latter in the following section may be taken as equally an account of the signs of hydropericardium.

Hæmopericardium, or blood in the pericardial sac, due to stabs or to ruptures of the heart, is usually so rapidly fatal that no physical signs are recognizable.

Physical Signs of Pericardial Effusion.

In most cases a pericardial friction rub has been observed prior to the time of the fluid accumulation. The presence of fluid in the pericardial sac is shown chiefly in three ways:

(1) By *percussion*, which demonstrates an area of dulness more or less characteristic (see below).

(2) By *auscultation*, which may reveal an unexpected feebleness in the heart sounds when compared with the power shown in the radial pulse.

(3) By the signs and symptoms of *pressure* exerted by the pericardial effusion upon surrounding structures.

Bulging of the precordia is occasionally to be seen in children; in adults we sometimes observe a flattening of the interspaces just to the right of the sternum between the third and sixth ribs.

(1) *The Area of Percussion Dulness.*—The extent of the dull area depends not only on the size of the effusion and the position of the patient, but also on the amount of “give” in the pericardium and in the lungs as well as on the size of the lingula pulmonalis. Allowing for these uncertain factors, we may say: (*a*) One of the most characteristic points is the unusual¹ extension of the percussion dulness a considerable distance to the left and beyond the cardiac impulse. (*b*) Next to this, it is important to notice a change in the angle made by the junction of the horizontal line correspond-

¹ In health the cardiac dulness extends about three-fourths of an inch beyond the cardiac impulse, but in pericardial effusion the difference is greater.

ing to the upper limit of hepatic dulness and the nearly perpendicular line corresponding to the right border of the heart. In health this cardio-hepatic angle is approximately a right angle; in pericardial effusion it is much more obtuse (see Fig. 117). Rotch has called attention to the importance of dulness in the fifth right intercostal space as a sign of pericardial effusion, but a similar dulness may be produced by enlargement of the liver.

Except for the two points mentioned above (the unusual extension of the dulness to the left of the cardiac impulse and the blunting of the cardio-hepatic angle), there seems to me to be nothing characteristic about the area of dulness produced by pericardial effusion.

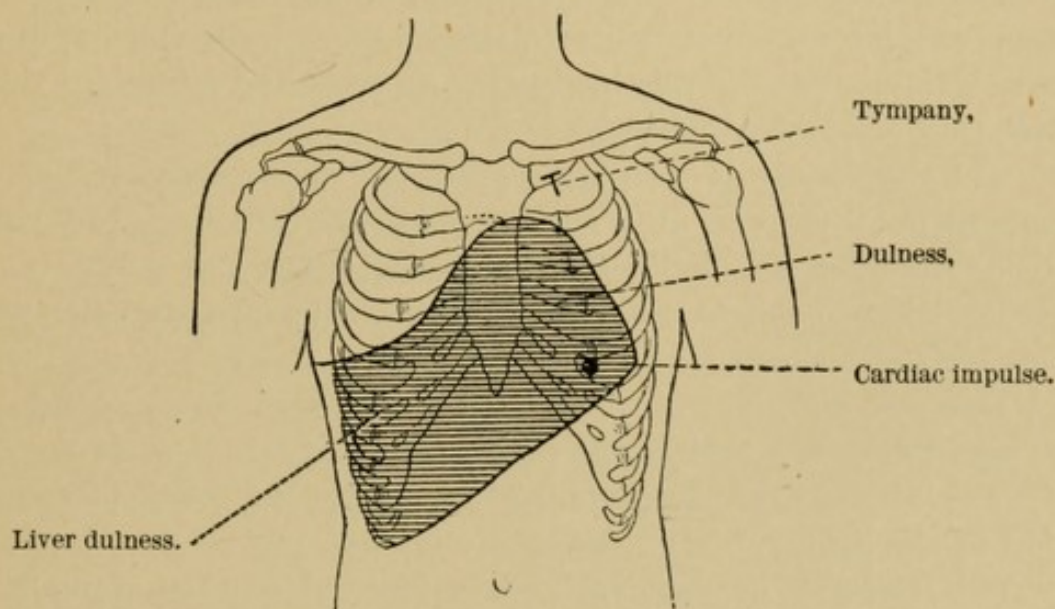


FIG. 117.—Percussion Dulness in Pericardial Effusion, with Tympanitic Resonance Under the Left Clavicle.

The “pear-shaped” or triangular area of percussion dulness mentioned by many writers has not been present in cases which have come under my observation. In large effusions percussion resonance may be diminished in the left back, and under the left clavicle the percussion note may be tympanitic from relaxation of the lung. Traube’s semilunar space may be obliterated, but this occurs also in pleuritic effusions.

In some cases the area of dulness may be modified by change in the patient’s position. After marking out the area of percussion

dulness with the patient in the upright position, let him lie upon his right side. The right border of the area of dulness will sometimes move considerably farther to the right. A dilated heart can be made to shift in a similar way, but to a lesser extent. Comparatively little change takes place if the patient lies on his left side, and no important information is elicited by placing him flat on his back or by getting him to lean forward.

Unfortunately, it is only with moderate-sized effusions occurring in a pericardial sac free from adhesions to the surrounding parts that this shifting can be made out. Large effusions may not shift appreciably, and less than 150 c.c. of fluid probably cannot be recognized by this or by any other method. But with large effusions the lateral extension of the area of dulness may be so great as to be almost distinctive in itself, *i.e.*, from the middle of the left axilla nearly to the right nipple.

(2) Feebleness of the heart sounds and of the apex impulse is of diagnostic importance only when it gradually takes the place of the normal phenomena as one watches the heart from day to day. Under these conditions they have some confirmatory value in the diagnosis of pericardial effusion.

Broncho-vesicular breathing with increased voice sounds may be heard over the tympanitic area below the left clavicle and occasionally between the scapulæ behind. This is a result of compression of the lung.

(3) Pressure exerted by the pericardial exudation upon surrounding structures may give rise to dyspnœa, especially of a paroxysmal type, to dysphagia, to aphonia, and to an irritating cough. The "paradoxical pulse," small and feeble during inspiration, is occasionally to be seen, but is by no means peculiar to this condition and has no considerable diagnostic importance.

(4) *Inspection and palpation* usually help us very little, but two points are occasionally demonstrable by these methods:

(a) A smoothing out of the intercostal depression in the precordial region, especially near the right border of the sternum between the third and the sixth ribs.

(b) A progressive diminution of the intensity of the apex impulse until it may be altogether lost. If this change occurs while

the patient is under observation, and especially if the apex impulse *reappears* or becomes more distinct when the patient lies on the right side, it is of considerable diagnostic value. In conditions other than pericardial effusion, the apex impulse becomes *less* visible in the right-sided decubitus.

Differential Diagnosis.

(1) Our chief difficulty is to distinguish the disease from hypertrophy and dilatation of the heart. In the latter, which often complicates acute articular rheumatism with or without plastic pericarditis, the apex impulse is often very indistinct to sight and touch as in pericardial effusion. But the area of dulness is less likely to extend beyond the apex impulse to the left or to modify the cardio-hepatic angle, or to shift when the patient lies on the right side. Pressure symptoms are absent, and there are no areas of bronchovesicular breathing with tympanitic resonance under the left clavicle or in the axilla. Yet not infrequently these differentiae do not serve us, and the diagnosis can be made only by puncture.

(2) I have twice known cases of encapsulated empyema mistaken for pericardial effusion. In one case a needle introduced in the fifth intercostal space below the nipple drew pus from what turned out later to be a localized purulent pleurisy, but the diagnosis was not made until a rib had been removed and the region thoroughly explored. It is not rare for pleuritic effusions to gather first in this situation, viz., just outside the apex impulse in the left axilla.

Such effusions may gravitate very slowly to the bottom of the pleural cavity or may become encapsulated and remain in their original and very deceptive position. In such cases the signs of compression of the left lung are similar to those produced by a pericardial effusion, and the results of punctures may be equivocal as in the case just mentioned. If there is *any* dulness, even a very narrow zone, in the left axilla between the fifth and eighth ribs, though there be none in the back, the likelihood of pleurisy should be suggested.

As between pleuritic and pericardial effusion the presence of a

good pulse and the absence of marked dyspnoea favors the former. In the two cases above referred to in which encapsulated pleurisy was mistaken for pericarditis, the general condition of the patient struck me at the time as surprisingly good for pericarditis.

If *both* pleurisy and pericarditis are present, the area of pericardial dulness is not characteristic until the pleuritic fluid has been drawn off. The persistence of dulness in the cardio-hepatic angle and beyond the apex beat after a left pleurisy has been emptied by tapping, and after the heart has had time to return to its normal position, should make us suspect a pericardial effusion.

Despite the utmost care and thoroughness in physical examination, many cases of pericardial effusion go unrecognized, especially in infants, in elderly persons, or when the lung borders are adherent to the pericardium or to the chest wall.

In the rheumatic attacks of children, it should be remembered that pericarditis is even more common than endocarditis.

Adherent Pericardium.

In the majority of cases the diagnosis cannot be made during life, unless the pericardium is adherent, not only to the heart, but to the walls of the chest as well. When this combination of pericarditis with chronic mediastinitis is present, the diagnosis may be suggested by

(a) A systolic retraction of the chest wall in the region of the apex impulse, at the base of the left axilla and in the region of the eleventh and twelfth ribs in the left back (Broadbent's sign). Such retraction is more marked during a deep inspiration. (It should be remembered that systolic retraction of the interspaces in the vicinity of the apex is very commonly seen in cases of cardiac hypertrophy from any cause, owing to the negative pressure produced within the chest by the contraction of a powerful heart.) A quick rebound of the cardiac apex at the time of diastole (the diastolic shock) is said to be characteristic of pericardial adhesions, but is often absent.

(b) Collapse of the cervical veins during diastole has been noticed by Friedreich, and the paradoxical pulse, above described, is

said to be more marked in adherent pericardium than in any other known condition. Most recent writers, however, place no reliance upon it.

(c) When the lungs are adherent to the pericardium or to the chest wall, as is not uncommonly the case, the absence of the phrenic phenomenon (Litten's signs) and of any respiratory excursion of the pulmonary margins may be demonstrated. Since pericardial adhesions are most often due to tuberculosis, the discovery of tuberculosis in the lung or elsewhere may be of aid in diagnosis.

(d) Broadbent considers that the absence of any shift in the position of the apex beat, with respiration or change of patient's position, is an important point in favor of mediastino-pericarditis. In health and in valvular or parietal disease of the heart, the apex beat will swing from one to two inches to the left when the patient lies on his left side, and the descent of the diaphragm during full inspiration lowers the position of the cardiac impulse considerably.

(e) The presence of hypertrophy or dilatation affecting especially the right side of the heart, and not accounted for by the existence of any disease of the cardiac valves, of the lung, or of the kidney, should make us suspect pericardial and mediastinal adhesions. Such adhesions embarrass especially the right ventricle, because it is the right ventricle far more than the left which becomes attached to the chest wall. The left ventricle is more nearly free.

(f) Since the space enclosed by the divergent costal cartilage just below the ensiform is but loosely associated with the central tendon of the diaphragm, Broadbent looks especially at this point for evidence of mediastinal or pericardial adhesions, the effect of which is to arrest completely the slight respiratory movements of this part of the abdominal wall.

(g) Adherent pericardium, occurring as a part of a widespread chain of fibrous processes involving the pleura, the mediastinum, and the peritoneum, may give rise in young persons to a train of symptoms and signs suggesting cirrhosis of the liver. Ascites collects, the liver is enlarged, yet there are no signs in the heart, kidneys, or blood sufficient to explain the condition. In any such case adherent pericardium should be considered. Figs. 118 and 119

show the appearance in cases of this kind in which the diagnosis was verified by autopsy.

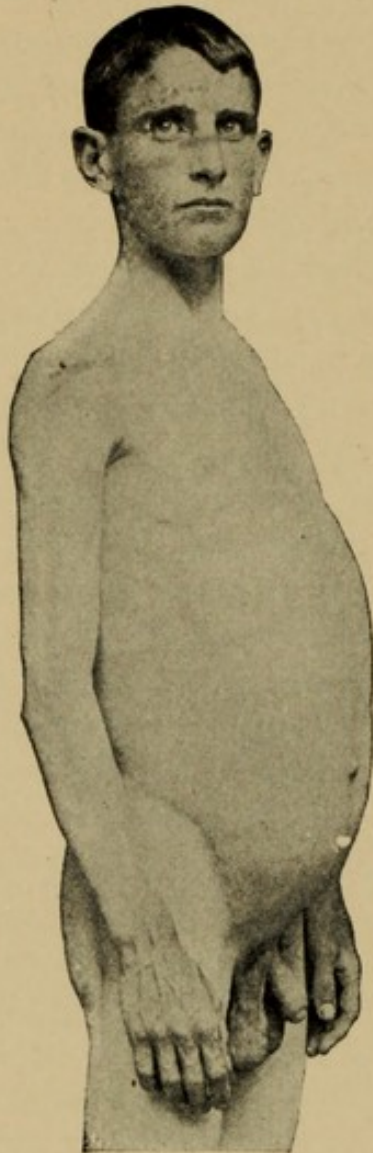


FIG. 118.

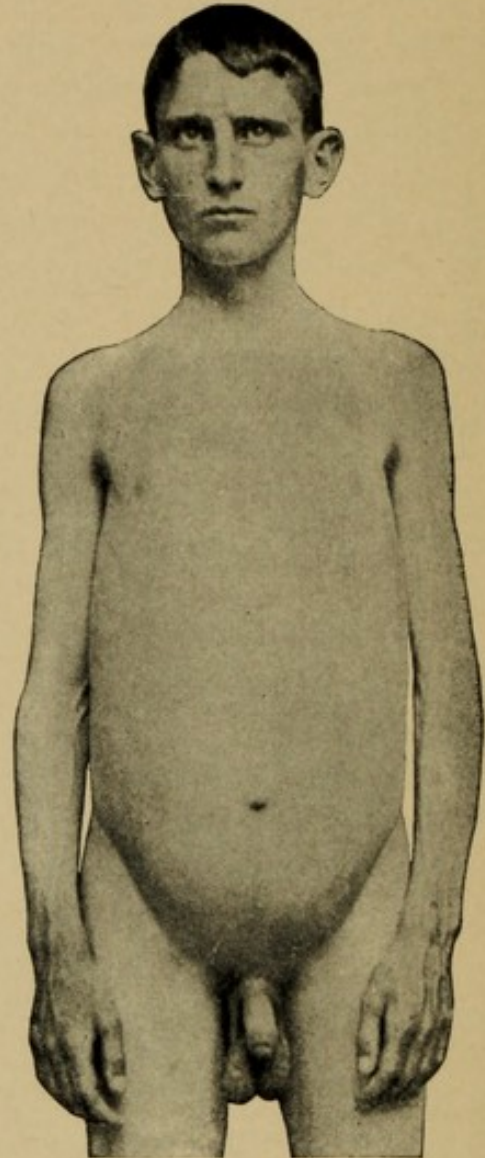


FIG. 119.

FIGS. 118, 119.—Adherent Pericardium, Ascites.

Summary.

The diagnosis of adherent pericardium with chronic mediastinitis is suggested by

(a) Systolic retraction of the lower intercostal spaces in the left axilla and in the left back, followed by a diastolic rebound.

(b) The absence of any change in the position of the apex impulse with respiration or change of position.

(c) The presence of hypertrophy and dilatation of the right ventricle without obvious cause.

(d) The absence of any respiratory excursion of the lung borders near the heart and of the abdominal wall at the costal angle.

(e) The presence of signs like those of hepatic cirrhosis in a young person and without any obvious cause.

(*Perihepatitis*)

CHAPTER X.

THORACIC ANEURISM.

ANEURISM OF THE THORACIC AORTA.

For clinical purposes thoracic aneurisms may be divided into the *diffuse* and the *saccular*. Saccular aneurisms of the ascending or descending portion of the arch of the aorta are apt to penetrate the chest wall, while aneurism of the transverse aorta or diffuse dilatations of the whole aortic arch are more likely to extend within the chest without eroding the thoracic bones. Practically any aneurism which penetrates the thoracic bones may be inferred to be saccular, but if no such penetration takes place, it may be impossible to make out whether the dilatation is diffuse or circumscribed. I shall consider:

I. The signs of the presence of aneurism.

II. The evidences of its seat.

Inspection and *palpation* give us most of the important information in the diagnosis of aneurism. The patient should be placed in the position shown in Fig. 118, so that the light will strike obliquely across the surface of the chest, and the observer should be so placed that his eyes are as nearly as possible at the level at that part of the chest at which he expects to see pulsation.

In the majority of cases of aneurism some *abnormal pulsation* may be made out either to the right of the sternum in front or in **Abnormal** the region of the left scapula behind. If the aneur-
Pulsation. ism is large, a considerable area of the chest wall may be lifted with each beat of the heart; with smaller growths the pulsating area may be small and sharply circumscribed. Not infrequently an abnormal pulsation at the sternal notch or in the

neck may be observed. Other causes of abnormal pulsations in the chest, such as dislocation or uncovering of the heart, must of course be excluded. Pulsations due to aneurism can sometimes be distinctly seen to occur later than the apex impulse of the heart.

Palpation controls the results of inspection, but at times a pulsation may be seen better than felt; at others may be felt better than seen. Bimanual palpation—one hand over the suspected area in front and one in a corresponding position behind—is useful.

If the aneurism involves the ascending portion of the aortic

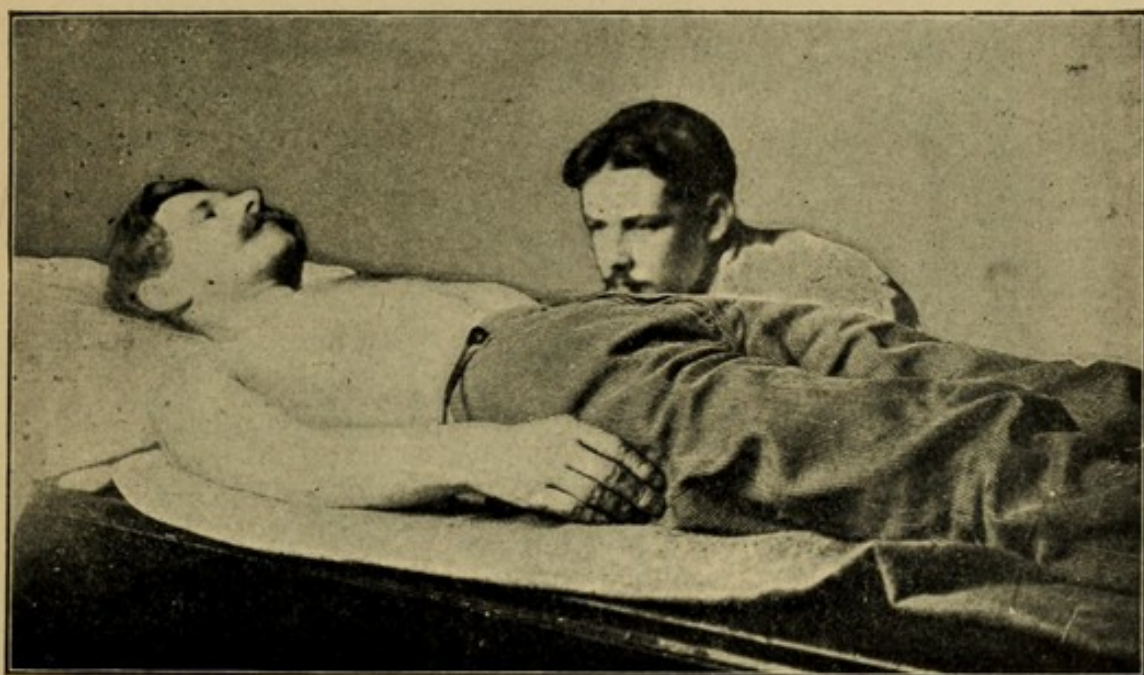


FIG. 120.—Position When Looking for Slight Aneurismal Pulsation.

arch, it is likely sooner or later to erode the right margin of the sternum and the adjacent parts of the second or third costal car-

Tumor. which a systolic pulsation is to be seen and felt. This pulsation is almost always distinctly *expansile* in character, and differs in this respect from the up-and-down motion which may be communicated to a tumor of the chest wall by the beating of a normal aorta. The tumor is usually firm, rarely soft, and may be as hard as any variety of malignant new growth. Occasionally

the thickness of the lamellated clot within it is so great that no pulsations are transmitted to the surface.

Whether the aneurism penetrates the chest or not, it is often possible to feel over it a *vibrating thrill*, usually *systolic* in time. If the layer of lamellated clot in the sac is very thick, the thrill is less apt to be felt.

More important in diagnosis is a *diastolic shock* or tap which is appreciated by laying the palm of the hand lightly over the affected

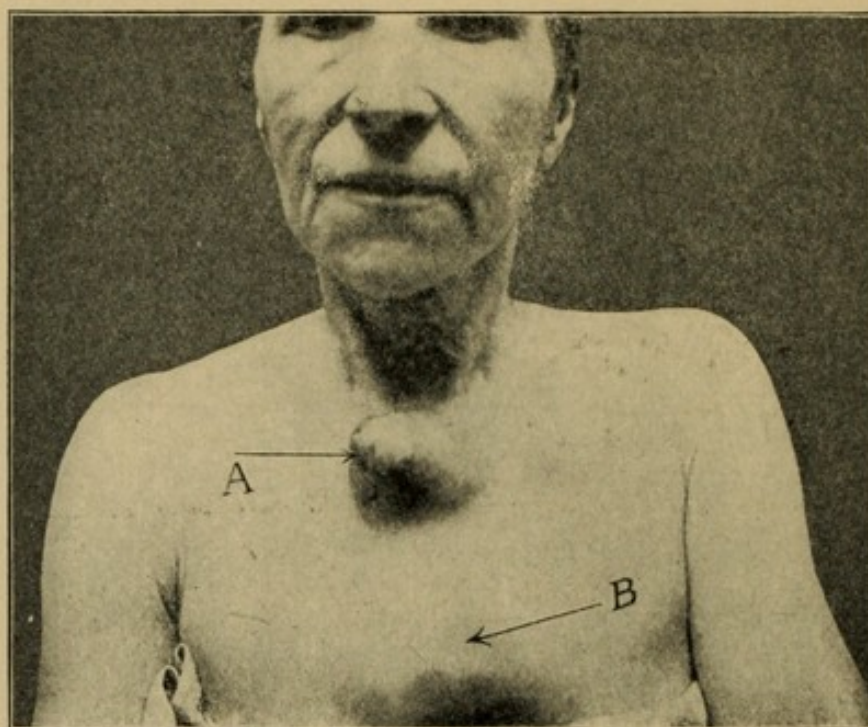


FIG. 121.—Aneurismal Tumor (A). The arrow B points to a gummatous swelling near the ensiform cartilage. The radiographic appearances of this case are shown below (Fig. 121).

area. This diastolic shock is due to the recoil of the blood in the dilated aorta, and is one of the most important and characteristic signs

Diastolic Shock. in aneurism. As the wall of the sac becomes weaker, the intensity of this shock diminishes. This diastolic shock may be appreciated over the trachea also, and is thought by some to have even more significance when felt in this situation.

Of special importance in aneurism of the transverse arch is the sign known as the *tracheal tug*. The arch of the aorta runs over

the left primary bronchus in such a way that when the aorta is dilated, the bronchus is pressed upon with each expansile pulsation

Tracheal Tug. of the artery. This systolic pressure transmitted to the trachea produces a distinct downward tug upon it with each systole of the heart. The tug is best felt by making the patient throw back his head so as to put the trachea upon a stretch. The physician then stands behind him and gently presses the tips of the fingers of both hands up under the lower border of the cri-

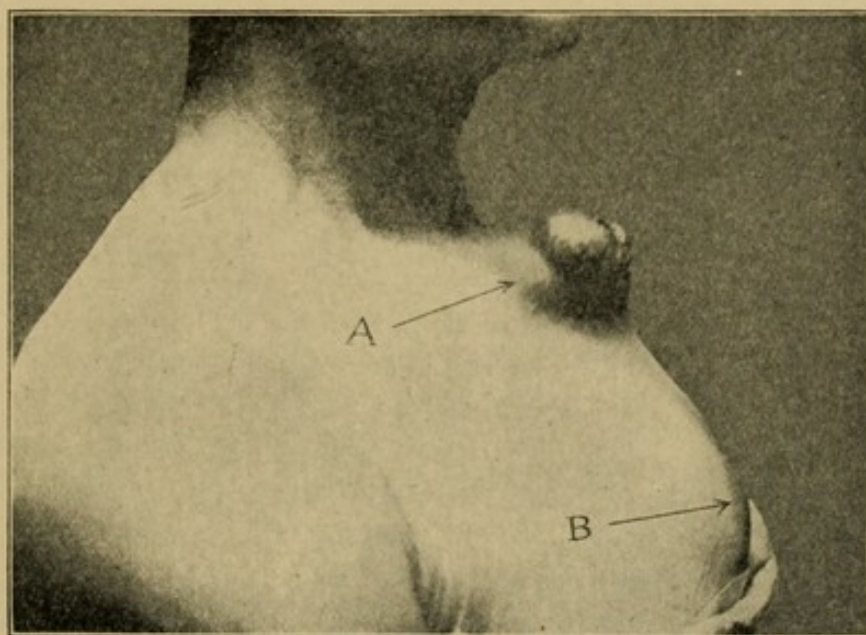


FIG. 122.—Aneurism Tumor Perforating the Sternum at *A*. At *B* there is a gummatous mass. (See below, Fig. 124, a radiograph of this case).

coid cartilage. In feeling thus for the tracheal tug as transmitted to the cricoid cartilage certain precautions must be observed:

(*a*) One must distinguish the tracheal tug from a simple pulsation transmitted to the superficial tissues by the vessels underneath. Such pulsation makes the tissues move *out and in* rather than up and down.

(*b*) A tracheal tug felt only during inspiration has no pathological significance and is frequently present in health.

While preparing to try for the tracheal tug we may notice whether there is any dislocation of the trachea, as shown by the

displacement of Adam's apple. Aphonia, stridor, cough, dysphagia, and other *symptoms* are produced by pressure on gullet and windpipe. Other signs of aneurism, due to the pressure of the dilated aorta upon the nerves or vessels of the mediastinum, are:

- (1) Inequality of the pupils.
- (2) Inequality of the radial pulses.
- (3) Œdema and cyanosis of one arm or of one side of the neck and head.
- (4) Pain in one arm from the pressure of an aneurism involving the subclavian artery upon the brachial plexus.
- (5) Clubbing of the fingers of one hand (rare).
- (6) Prominence of one eye (rare).
- (7) Flushing or sweating of one side of the face (very rare).

Case Dr. Bantel April 3/06 Contraction or dilatation of the pupil is due to an irritative or paralytic affection of the sympathetic nerves. This symptom is much commoner than the other effect of pressure upon the sympathetic nerves; namely, flushing or sweating of one side of the face.

In comparing the pulses in the two radials we must bear in mind the possibility of a congenital difference between them, due to a difference either in the size of the arteries or in their position, and also that a tumor pressing on the subclavian may affect the pulse exactly as an aneurism. The pulse wave upon the affected side (most often the left) may be either less in volume or later in time than the wave in the other radial artery, according as the pulse wave is actually delayed in the aneurismal sac or merely diminished by it. In marked cases the pulse upon the affected side may be nearly or quite absent. On the other hand the inequality of the pulses may be so slight that the sphygmograph has to be employed to demonstrate differences in the shape of the wave not perceptible to the fingers.

Examination of the heart itself may show some dislocation of the organ to the left and downward, owing to the direct pressure of the aneurismal sac, but no enlargement.

II. *Percussion.*

If the aneurism is deep-seated, the results of percussion are negative. If, on the other hand, it be situated immediately be-

neath the sternum or close under the thoracic wall, an area of dulness, not present in the normal chest, may be mapped out. The outlines most commonly seen in such cases are shown in Fig. 123. When the aneurism involves the descending aorta, an area of dulness may be found in the region of the left scapula or below it, and pulsation may be detected in the same area.

III. *Auscultation.*

The signs revealed by auscultation are not of much diagnostic value as a rule. In about one-half of the cases of sacculated aneu-

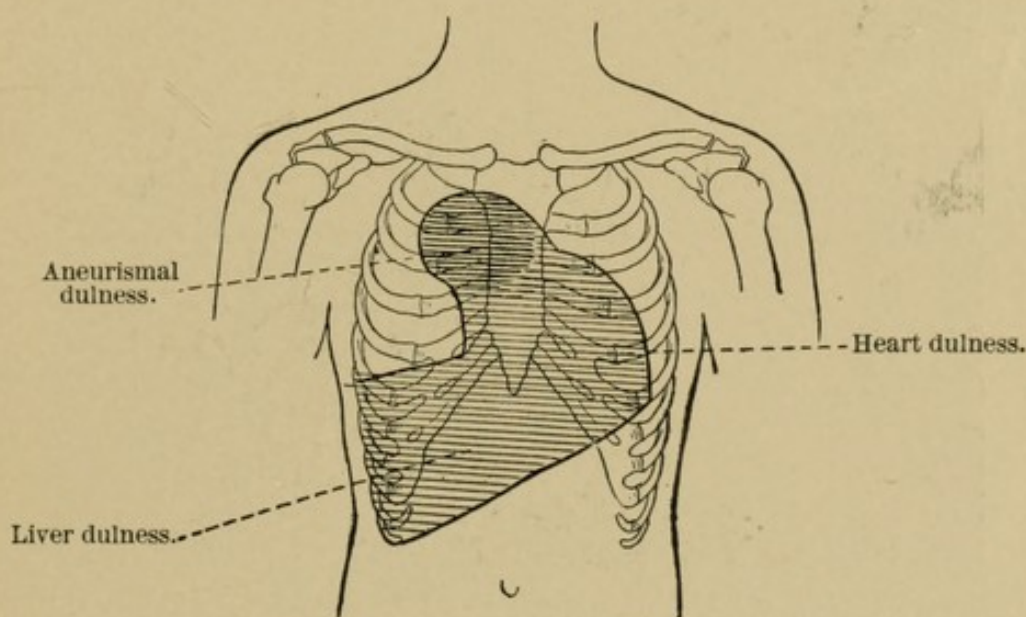


FIG. 123.—Diagram of Percussion Dulness in Aortic Aneurism.

rism there are no sounds or murmurs to be heard over the tumor. In other cases a systolic murmur, the audible counterpart of the vibratile thrill, may be heard over the area of pulsation, tumor, or dulness corresponding to the aneurismal sac. This systolic murmur may be due to many causes other than aneurism, and has nothing characteristic about it. A similar systolic sound is sometimes heard over the trachea (Drummond's sign) or in the mouth, if the patient closes his lips around the pectoral extremity of the stethoscope (Sansom's sign).

A loud, low-pitched diastolic sound, corresponding to the pal-

pable diastolic shock, is generally to be heard in the aortic region. This diastolic sound, which is probably not produced by the aortic valves, is remarkably deep-toned and loud, and is, on the whole, the most important sign of aneurism revealed by auscultation.

If a portion of either lung is directly pressed upon by the aneurismal sac, we may have the signs of condensation of the lung in the area pressed upon (slight dulness, broncho-vesicular breathing, and exaggerated voice sounds). If one of the primary bronchi

From the front.

From behind.

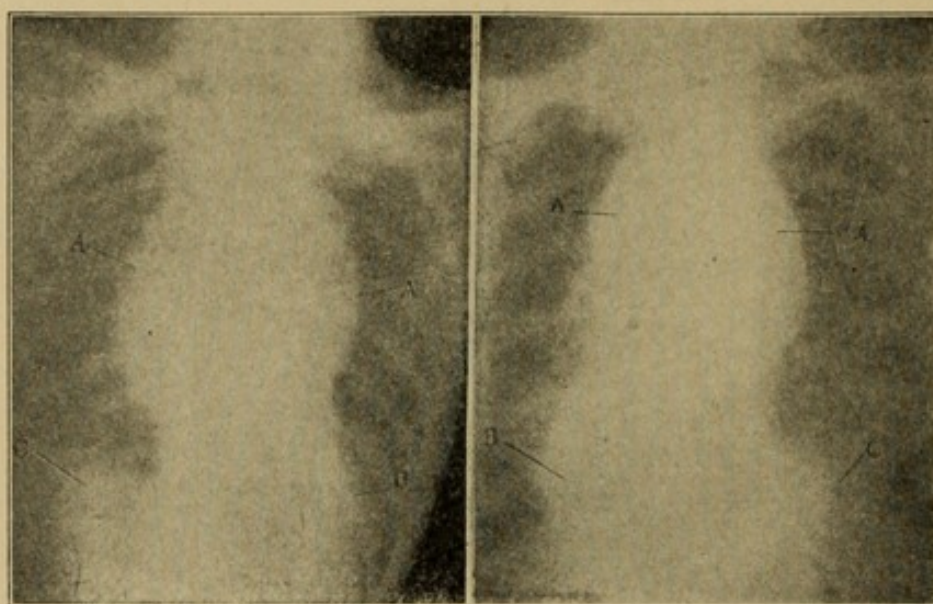


FIG. 124.—Radiograph of Case whose Photograph is Reproduced as Figs. 118 and 119. In the right-hand cut are shown the appearances seen from behind. The left-hand cut, *A, A*, aneurismal sac; *B*, heart displaced; *C*, liver (not in focus).

is pressed upon, as occasionally happens, atelectasis of the corresponding lung may be manifested by the usual signs (dulness, absence of tactile fremitus and of respiratory and vocal sounds).

Since aneurism is frequently associated with regurgitation at the aortic valve, a diastolic murmur is not infrequently to be heard.

If the aneurismal sac is of very great size, the pulse wave in the femorals may be obliterated, as happened in a case described by Osler.

IV. *Radioscopy.*

With the fluoroscope and through photography one can often make out a shadow corresponding to the position of the aneurism.

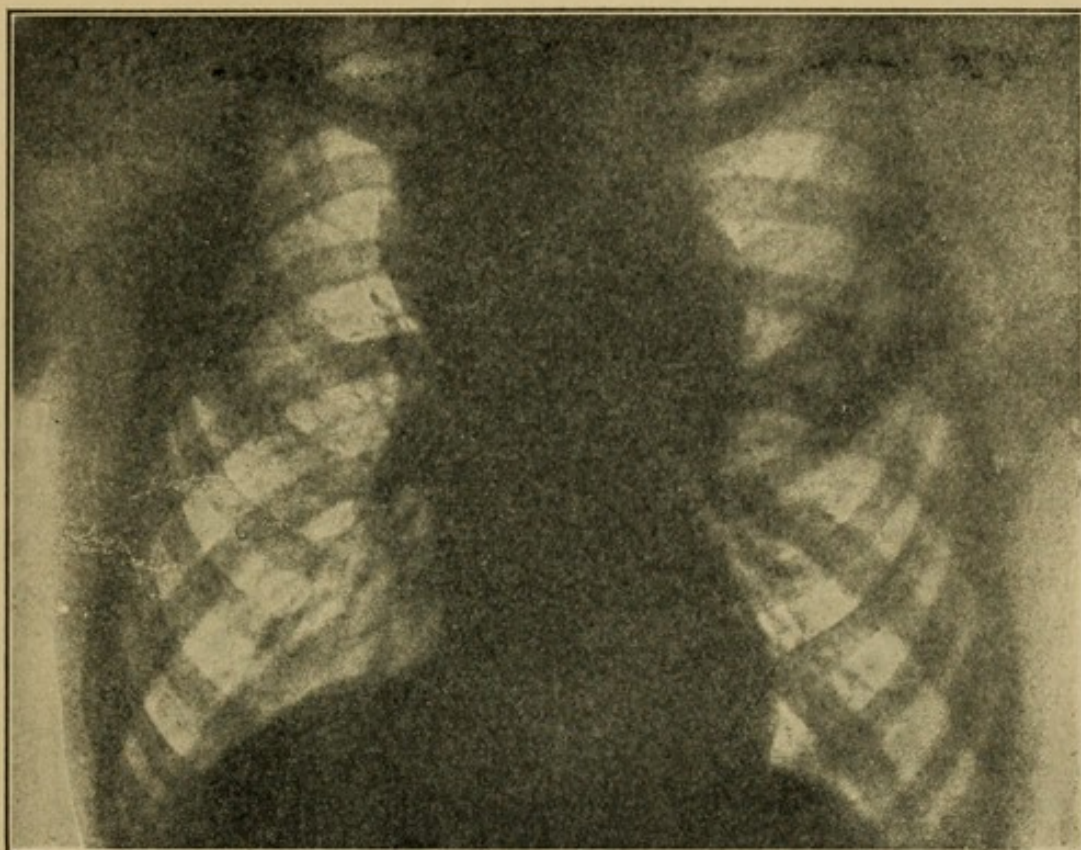


FIG. 125.—Aortic Aneurism. (From v. Ziemssen's Atlas.)

The position of the shadow is best explained by reference to Figs. 124, 125, and 126


Summary.

The most important signs of aneurism are:

1. *Abnormal pulsation*—visible or palpable
2. *Tumor* over which a
3. *Thrill* and a

4. *Diastolic shock* may be felt.
5. *Tracheal tug*. (*is not pathognomonic*)
6. *Pressure signs* (unequal pulses, pupils, hoarseness, pain, etc.).
7. *Dulness* on percussion over the suspected area.
8. *Loud, low-pitched aortic second sound*.
9. *Systolic murmur* (least important of all).

10. *Inequality of pupils*.
11. *Hoarse voice*.



Aneurismal sac.

Heart displaced
downward by
the aneurism.

FIG. 126.—Extensive Aortic Aneurism Displacing the Heart.

10. *Radioscopy* may demonstrate a shadow higher up than that corresponding to the heart and extending beyond that produced by the sternum, spinal column, and great vessels.

Diagnosis of the Seat of the Lesion.

(a) *Aneurism of the ascending arch* generally approaches or penetrates the chest wall in the vicinity of the *second right intercostal space* near the sternum. Previous to perforating the thoracic

parietes, the growth of the aneurism may give rise to pain, pulsation, and dulness and thrill in this region.

(b) *Aneurism of the transverse arch* or diffuse dilatation of the aorta, such as usually occurs in long-standing cases of aortic regurgitation, may not give rise to any visible pulsation of the chest wall, and, if deep-seated, need not produce any abnormal dulness on percussion. In such cases an aneurism is to be recognized, if at all, by *evidences of pressure* on the nerves or vessels of the mediastinum (cough, aphonia, inequality of the pupils, tracheal tug, etc.).

(c) *Aneurism of the descending aorta* gives rise usually to severe and persistent pain in the back, which radiates along the intercostal nerves or downward. Other pressure symptoms are not marked, but in advanced cases an area of abnormal dulness and pulsation may be found in the region of the left scapula or below it.

(d) If the *innominate artery* or one of the carotids is involved, we usually find a pulsating lump in the region of one or the other claviculo-sternal joint or at the root of the neck, and the trachea may be displaced to one side. If the subclavian is involved or pressed upon, there may be pain and œdema in the corresponding arm.

Differential Diagnosis.

(a) Some writers draw a distinction between the diffuse dilatation of the aortic arch, which sooner or later complicates almost every case of incompetency of the aortic valves, and saccular aneurism of the transverse portion of the aorta. Clinically, such distinction seems to be impossible, although if symptoms resembling those of aneurism gradually develop in a case of aortic regurgitation, one may suspect that the dilatation of the aorta is merely part of the distention of the whole arterial tree, which aortic regurgitation tends to produce.

(b) Aneurism is not infrequently mistaken for *aortic stenosis*, in which a systolic murmur and thrill, similar to those occurring in aneurism, are to be heard over the region of the aortic arch. From aortic stenosis aneurism is distinguished by the fact that it does

not produce characteristic changes in the pulse, and by the presence of some one of the symptoms above described, such as tracheal tug, pressure symptoms, abnormal area of percussion dulness, etc.

(c) Simple dynamic throbbing of a normal aortic arch similar to that which occurs in the abdominal aorta may lift the chest wall so as to simulate aneurism. The other positive symptoms and signs of aneurism are, however, absent.

(d) Pulmonary tuberculosis or cancer of the œsophagus, producing as they may substernal pain, cough, and aphonia by pressure upon mediastinal structures, have been mistaken for aneurism, from which, however, they may be distinguished by the absence of the positive signs above described, by the more rapid emaciation of the patient, and by the positive evidences of cancer or tuberculosis.

(e) *Empyema necessitatis* may produce a pulsating tumor like that of aneurism and the area of dulness may be similar, but there is no diastolic shock, no tactile thrill or murmur, and the history of the case is usually very different from that of aneurism. It is perfectly safe to insert a fine hollow needle in doubtful cases. No serious hemorrhage results if aneurism is present, and the diagnosis and treatment may be greatly assisted.


(f) *Mediastinal tumors* are sometimes almost indistinguishable from aneurism during life. They may produce a more intense and widespread dulness which is usually in the median line, while the dulness of aneurism is oftener at one side. The pulsation transmitted to a tumor by the heart has not the expansile character of aneurismal pulsation. Tumors are not associated with any diastolic shock, rarely with a tracheal tug.

The course of most mediastinal tumors is progressive and attended by great cachexia, while the symptoms of aneurism are often more or less intermittent, and unless pain is severe there is no such emaciation or anæmia as is commonly seen with mediastinal tumors. Pressure symptoms may be the same in both diseases, but are usually more marked with mediastinal growths. A metastatic nodule over the clavicle sometimes betrays the presence of a primary focus within the chest.

(g) *Retraction of the right lung* (fibroid phthisis), with or without displacement of the heart toward the diseased side, may uncover the heart so as to produce some of the signs of aneurism, *i.e.*, pulsation and dulness in the upper right intercostal spaces near the sternum, with a loud aortic second sound and sometimes a systolic murmur in the dull area.

The history of the case and a careful examination of the lungs usually suffice to set us right.

(h) *Dilatation of the heart* may be so extreme that pulsation and percussion dulness appear in the characteristic aneurismal area to the right of the sternum, especially if there is solidification of the left lung. But the pulse is in such cases much weaker and more irregular than is to be expected in uncomplicated cases of aortic aneurism, and the history of the case is usually decisive.



PART III.

DISEASES OF THE LUNGS.

CHAPTER XI.

BRONCHITIS, PNEUMONIA, TUBERCULOSIS.

I. TRACHEITIS.

IN connection with bronchitis or as a forerunner thereof, inflammation of the trachea is not uncommon. It gives rise to no characteristic physical signs, but is to be suspected when the patient complains of *cough with pain over the upper portion of the sternum*.

BRONCHITIS.

Inflammation of the larger bronchial tubes is not often the cause of any definite physical signs, but with every paroxysm of coughing the patient may feel pain in an area corresponding exactly to the anatomical position of the primary bronchi. I have seen patients indicate most accurately the situation of the large tubes when pointing out the position of pain produced by coughing.

In the vast majority of cases of *acute bronchitis* the smaller bronchi are involved, and the swelling of their walls, with or without exudation, is manifested by the following physical signs:¹

(1) Diminution in the intensity of vesicular breathing over the area affected (rarely in the earliest stages the breath sounds are exaggerated and harsh, especially in the upper portions of the chest).

¹ Bronchitis may exist without râles, but cannot be diagnosed without them. Occasionally they are present only in the early morning.

(2) *Râles*, which are squeaking or piping over bronchi which are narrowed without any considerable amount of exudation, as is the case in the earliest stages of many cases, and bubbling, crackling, or clicking in later stages, when watery or viscid exudation is present in the tubes. The calibre of the bronchi affected can be estimated from the coarseness or fineness of the râles. Low-pitched groaning sounds point to a stenosis of a relatively large bronchus, while squeaking and whistling sounds are usually produced in the smaller tubes. Large, bubbling râles are much less often heard than the finer, crackling variety. The latter are produced in the smallest tubes, the former in the larger variety.

Simple non-tuberculous bronchitis is almost invariably *bilateral* or symmetrical, and affects most often the lower two-thirds of the lungs, leaving the apices relatively free. It is almost never confined to an apex. When râles are to be heard on one side of the chest only, and when they persist in the same spot for days and weeks, tuberculosis is always to be suspected, especially if the râles are localized at the summit of one or both lungs. It should never be forgotten that the tubercle bacillus is capable of exciting a bronchitis indistinguishable from other varieties of bronchitis, except by its tendency to show itself at the apex of the lung and on one side only; most cases of pulmonary tuberculosis begin in this way.

The only other variety of bronchitis which is often unilateral is that due to the influenza bacillus. In the course of a case of influenza, a unilateral localized bronchitis not infrequently occurs. Over a patch of lung, perhaps the size of the palm of the hand, fine, moist râles may persist for weeks, finally clearing up only after the patient has resumed his ordinary occupation. Doubtless such localized patches of bronchitis are often accompanied by foci of lobular pneumonia too small to be detected by our present methods of physical examination.

Percussion dulness is absent in bronchitis except near the end of fatal cases, when the lung is stuffed with mucus and pus, or when atelectasis has occurred owing to extensive plugging of the larger bronchi. These events are rarely seen, and in general the

negative results of percussion are of great value in excluding solidification or fluid exudation.

Occasionally percussion resonance may be increased owing to a slight temporary overdilatation of the air vesicles from coughing.¹

Inspection usually shows little or nothing of diagnostic importance in acute bronchitis. Long-standing cases, complicated as they almost invariably are by emphysema, present changes in the shape of the thorax; but these are due to the emphysema rather than to the bronchitis. In children acute bronchitis sometimes involves so many of the smaller bronchi that dyspnoea and use of accessory muscles of respiration are notable. But this usually means atelectasis, broncho-pneumonia, or laryngeal spasm, in addition to the bronchitis.

From violent coughing the jugulars may be distended, but no systolic pulsation occurs in them.

Voice sounds and tactile fremitus are normal.

Differential Diagnosis.

Œdema of the lung and bronchial asthma are the only pathological processes (except hemorrhage into the lung substance) which give rise to signs like those of bronchitis.

(1) In *œdema of the lung*, or pulmonary apoplexy, one may find, as in simple bronchitis, a diminished vesicular breathing with crackling râles, but *œdema of the lung* is almost always best marked in the dependent portions; that is, in the posterior parts of the lung if the patient has been lying upon the back, or in the lower lobes if he has been sitting up. The râles of *œdema* are always moist, and are more uniform in size when compared to those of bronchitis. The recognition of a cause for the *œdema*, for example a non-compensated heart lesion, materially aids in the diagnosis.

(2) *Bronchial asthma* or spasm of the finer bronchi produces dry squeaking and groaning sounds similar to those heard in the earlier

¹ In children examined during a crying-spell a cracked-pot sound can usually be elicited by percussion. This is in no way characteristic of bronchitis and can often be obtained in healthy infants.

stages of many cases of bronchitis. But in bronchial asthma the râles are chiefly *expiratory*, and expiration is prolonged and intensified. Moreover, the inhalation of a few drops of amyl nitrite will

temporarily dispel râles due to bronchial spasm, while on the râles of dry bronchitis it has no effect (Abrams).

(3) *Broncho-pneumonia*. In many cases of lobular or broncho-pneumonia the physical signs are exclusively those of the coexisting bronchitis. In such cases the diagnosis of bronchitis is not wrong, but does not cover the whole ground. I shall discuss further under broncho-pneumonia the evidence which leads us to suspect that something more than bronchitis is present.

(4) *Muscle sounds*. Under certain circumstances (cold, nervousness), the rumbling noises produced by muscular contractions in the chest wall may simulate râles so closely that the diagnosis of bronchitis may be strongly suggested. The differentiation between râles and muscle sounds has already been discussed (see above, p. 92).

(5) *Atelectatic crepitation*. Crackling râles heard over the thin margins of the lungs at the base of the axilla or along the edges of the manubrium are often due

to atelectasis (see above). From bronchitis they are distinguished by their situation and by the lack of symptoms. They are best heard at the point shown in Fig. 125.

Chronic Bronchitis.

So far as the bronchitis itself is concerned, there may be no difference in the physical signs between the acute and chronic forms

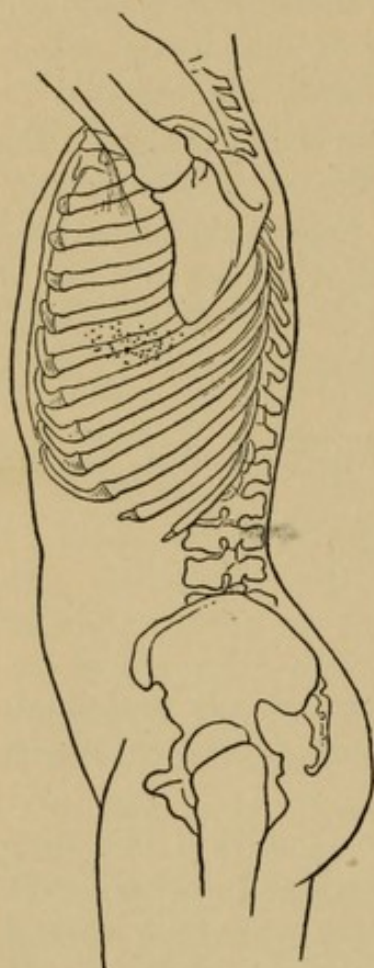


FIG. 127.—The Dots are Placed over the Area where Atelectatic Crepitation is Oftenest Heard.

of the disease; but in the latter one almost invariably finds associated with the bronchitis itself a considerable degree of emphysema, of asthma, or of both conditions. Indeed, the foreground of the clinical picture and the bulk of the physical sign are made up by the emphysema and asthma, rather than by the bronchitis itself. Accordingly, I shall not discuss chronic bronchitis any further at this point, but will return to the subject in the chapter on Emphysema.

CROUPOUS PNEUMONIA.

In its typical form croupous or fibrinous pneumonia produces solidification of one or more lobes, usually the lower, the process being accurately bounded by the interlobular fissures. Although the physical signs of the earlier stages differ considerably from those of the later ones, there seems to be no sufficient ground for marking off stages of engorgement and of red and gray hepatization, for *clinically* these stages cannot be distinguished.

The solidification may begin in the deeper parts of the lung ("*central pneumonia*"), so that no physical signs are obtainable unless, later in the course of the disease, the process extends to the surface of the lung.

Massive pneumonia, in which the bronchi as well as the air cells are plugged with fibrin and leucocytes, is a relatively rare form of the disease, but possesses great clinical importance on account of the marked resemblance between its physical signs and those of pleural effusion.

The frequency of endocarditis and pericarditis in connection with lobar pneumonia, especially with those of the left side, should be borne in mind.

Physical Signs.

(a) *Inspection*.—The aspect of the patient frequently suggests the diagnosis; the face is anxious, often flushed or slightly cyanosed, the flush sometimes affecting most strikingly the side of the face corresponding to the lung affected.¹ Herpetetic vesicles ("cold

¹ Perhaps because the patient is apt to lie upon the affected side.

sores") are often to be seen around the mouth or nose. The rapid, difficult breathing is at once noticable, and expiration is often accompanied by a grunt. The use of the accessory muscles of respiration and the dilatation of the nostrils attract attention.

The combination of marked dyspnœa with absence of dropsy is met with more frequently in pneumonia than in any other disease. Both sides of the chest usually move alike, but occasionally the affected side shows deficient expansion especially in the later stages of the disease, and the other side of the chest shows increased respiratory movements (compensatory). Rarely the pulsations of the heart may be transmitted to the chest wall through the affected lung.

When pneumonia attacks a feeble old man, or follows injuries (surgical pneumonia), its onset may be insidious, and none of the phenomena just described may be seen.

(b) *Palpation.*—*In the great majority of cases tactile fremitus is markedly increased over the affected area,*¹ but in case the bronchi are occluded by secretions or fibrinous exudate, fremitus may be diminished or altogether absent. A few hard coughs will sometimes clear out the tubes and thus materially assist the diagnosis. Occasionally an increase in superficial temperature of the affected side may be noticed by palpation, and rarely one feels a friction rub due to the fibrinous pleurisy which almost invariably accompanies the disease.

(c) *Percussion.*—*Over the area affected the percussion note is generally dull and may be almost flat,* except in the earliest and latest stages of the disease, in which it may have a tympanitic quality with or without an element of slight dulness. More marked tympany is usually present over the unaffected lobes of the diseased lung (that is, over the upper lobes in the great majority of cases.)

The conditions just described represent the great majority of cases, but the following exceptions occur:

(1) In the pneumonias of children, and occasionally in adults, dulness may be absent.

¹ By using the edge instead of the flat of the hand the boundaries of solidified lobes may often be very accurately marked out by means of the tactile fremitus.

(2) When the lower lobe of the left lung is affected, a distinctly tympanitic quality may be transmitted to the consolidated area from a distended stomach or colon.

(3) In rare cases, the percussion over the consolidated area may be of a metallic quality, or produce the "cracked-pot" sound.

(4) In central pneumonia there may be no change in the percussion note, or it may be unusually full and deep so that the sound side seems dull by comparison.

A solidified lobe increases so much in size that the area of dullness corresponding to it often seems incredibly large. Thus, although the lower lobe reaches in health not more than half-way up the scapula, when solidified it produces dullness throughout nearly the whole back.

The right base is the most frequent seat of pneumonic solidifications, but the dullness corresponding to it is often first noticeable in the posterior axillary line. A dullness appreciable only in the front of the chest is almost sure to correspond to the upper lobe, while signs in the lower part of the right axilla correspond to the middle lobe. Many cases of central pneumonia first appear at the surface in one or the other axilla.

As regards the amount of solidification needed to produce percussion dullness, Wintrich says that the minimum is a patch 5 cm. in diameter, 2 cm. deep, and superficially situated.

Percussion often makes us aware of an increased resistance or diminished elasticity of the affected side, although the resistance is seldom as marked as in large pleural effusions.

(d) *Auscultation*.—In the great majority of cases typical tubular breathing is to be heard over the affected area. Since a whisper is practically a forced expiration, this *tubular quality* is very well brought out if the patient is made to whisper "one, two, three," or any other succession of syllables, and by this method the fatigue and pain of deep breathing may be saved. By this use of the whispered voice one may accurately mark out the boundaries of the consolidated area, and demonstrate in many cases that it coincides with the boundaries of one lobe of the lung.

In the earliest stages of the disease the breathing may be bron-

cho-vesicular; more often it is *feeble* or suppressed over the consolidated area, and "crepitant râles," that is, very fine crackling sounds, may be heard at the end of inspiration, but these are much more common in the stage of resolution¹ ("crepitans redux").

If some of the smaller bronchi are blocked, as is not infrequently the case, respiration is absent or very feeble, and such cases are often mistaken for pleuritic effusion. In pneumonia of the upper lobe it is not rare for bronchial breathing to be absent even without plugging of the bronchi.

In cases of "central pneumonia," that is, when the area of solidification is in the interior of the organ, there may be no change in the breath sounds, or a bronchial element may be faintly audible on auscultation with the unaided ear, and only by this method.

The intensity of the spoken or whispered voice is greatly increased over the area of consolidation, and sometimes the words can be distinguished. The nasal twang known as "*egophony*" is occasionally to be heard. In the majority of cases, as has been already stated, the right lower lobe posteriorly is affected, so that the consolidated area is immediately in apposition with the spinal column. Under these circumstances, it is not at all uncommon to hear bronchial breathing transmitted from the consolidated lobe to a narrow zone close along the spinal column on the *sound* side. Such a zone is often mistaken for consolidation (see Fig. 128).

The signs are usually less marked in the axilla and in the front of the lung, but in a minority of cases, and especially when the upper lobes are affected, the signs are wholly in the front. When searching for evidences of consolidation in persons suspected to have pneumonia, one should never omit to examine the apices and *very summit* of the armpit, pressing the stethoscope up behind the anterior fold of the axilla.

In examining the posterior lobes, when the patient is too weak to sit up and is loath even to turn upon the side, the Bowles steth-

¹ Crepitant râles are rarely heard in the pneumonias of infancy and old age. They are not peculiar to pneumonia, but occur in pulmonary œdema or hemorrhagic infarction—conditions easily distinguished from pneumonia.

oscope is a great convenience, owing to the ease with which its flattened extremity may be worked in between the patient and the bed-clothes without causing any discomfort.

When *resolution* begins, the signs may suddenly and completely disappear within a few hours. More frequently the bronchial breathing is modified to broncho-vesicular, dulness and bronchophony become less marked, fine crackling râles (*crepitans redux*) or coarser moist bubbles appear, and the lung gradually returns to its normal condition within a period of three or four days. In the

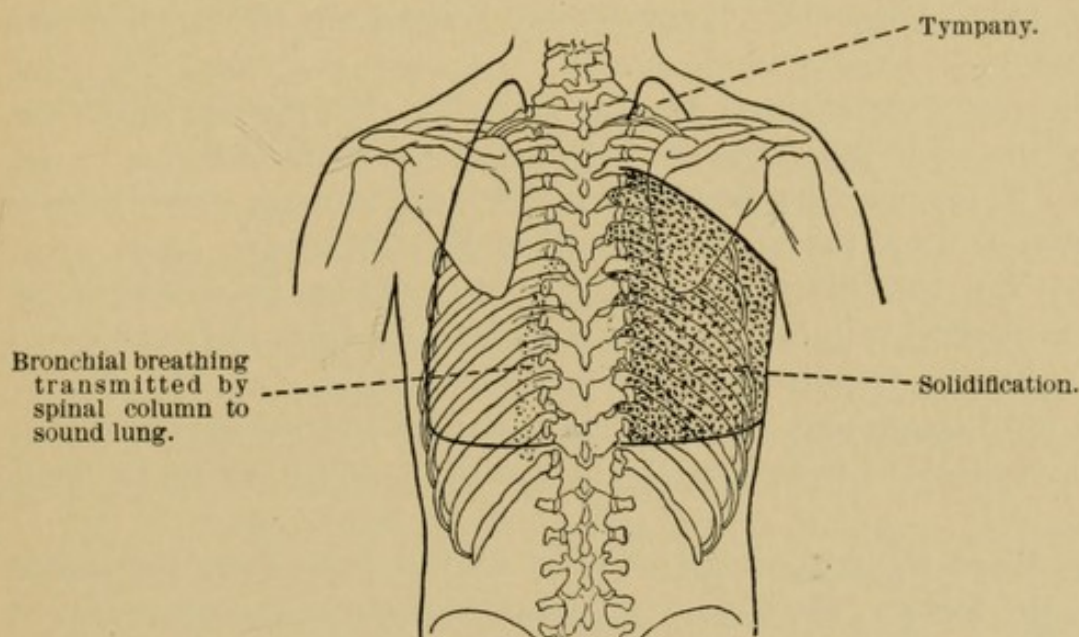


FIG. 128.— Diagram of Signs in Pneumonia.

active stages of the disease the entire absence of râles is very characteristic. In about 19 per cent. of the cases the solidification of the lung persists after the fall of the temperature; indeed, it may be weeks or even months before it clears up, and yet the lung may be perfectly sound in the end. On the other hand, abscess or gangrene may develop in the solidified lobe, or the latter may be transformed into a mass of tough fibrous tissue, and the adjacent portion of the chest may fall in (cirrhosis of the lung, chronic interstitial pneumonia).

“*Wandering pneumonia*” is a term applied to cases in which

the consolidation disappears in one lobe only to reappear in another, or spreads gradually from lobe to lobe. The physical signs in such cases do not differ essentially from those already described.

Summary.

In a typical case one finds (oftenest at the right base behind)

1. Dulness on percussion.
2. Increased tactile fremitus and voice sounds.
3. Tubular breathing and occasionally crepitant râles.

These signs occurring in connection with fever, cough, rusty sputa, pain in the side, dyspnœa, and herpes, are sufficient for the diagnosis.

But many cases—some say the majority—are not typical when first seen. The following are the commonest anomalies:

(a) There may be tympany instead of dulness, especially in children or when the solidification is at the left base.

(b) The breathing may be *feeble* but vesicular in character, or it may be absent, in case bronchi are plugged; from the same cause

(c) Tactile fremitus may be diminished.

A hard cough may clear out the bronchi and produce a sudden metamorphosis of the physical signs with a return to the normal type.

In these atypical cases, we have to fall back upon the symptoms, the history, the blood, and sputa for help in the diagnosis.

Deep-seated pneumonic processes may appear at the surface in out-of-the-way places, *e.g.*, at the summit of the axilla, and the area of demonstrable physical signs may be no larger than a silver dollar. A thorough examination of every inch of the chest is therefore essential in doubtful cases.

In the later stages of the disease crepitant or other fine râles often appear, and the signs of solidification suddenly or gradually disappear.

Differential Diagnosis.

Pneumonic solidification is to be distinguished from

- (1) Pleuritic effusion.
- (2) Tuberculosis of the lung.

(1) From pleuritic effusion, pneumonia is to be distinguished in the great majority of cases by differences in the onset, course, and general symptoms of the disease. In pneumonia the patient is far more suddenly and violently attacked, the dyspnoea is much greater, cough and pain are more distressing and more frequent, the temperature is higher, and the sputum often characteristic. In pleuritic effusion the dulness is usually more intense than in pneumonia. Tactile fremitus and voice sounds are increased in pneumonia (except when the bronchi are plugged); decreased or absent in pleuritic effusion. Bronchial breathing may be heard in both diseases, but is usually feeble and distant when occurring in pleurisy, and loud in pneumonia. If the affection be on the left side, the diagnosis is much aided by the presence of dislocation of the heart, which is produced by pleuritic effusion and never by pneumonia. In cases of pneumonia with occluded bronchi, one may have every sign of pleuritic effusion—flatness, absent breathing, voice and fremitus—and in such cases the absence of any dislocation of the heart, provided the disease is upon the left side, is very important. If a similar condition of things occurs upon the right side, one may have to fall back upon the symptoms and upon such evidence as the blood count, herpes, sputum, etc.

(2) Tuberculosis of the lung causing, as it may, a diffuse solidification of the organ, may be indistinguishable from pneumonia if we take account only of the physical signs, but the two diseases can usually be distinguished without difficulty by the difference in their symptoms and course, and by the presence or absence of tubercle bacilli in the sputum.

INHALATION PNEUMONIA. ASPIRATION PNEUMONIA.

When food or other foreign substances are drawn into the air passages, as may occur, for example, during recovery from ether narcosis, a form of broncho-pneumonia may be set up, in which the solidified patches are not infrequently large enough to be recognized by the ordinary methods of physical examination.

The lesions are usually *bilateral* and accompanied by a general bronchitis. Slight dulness and indistinct bronchial breathing can

usually be made out over an irregular area in the backs of both lungs.

The signs are considerably less marked than in croupous pneumonia, and the boundaries of the irregular patches of disease do not correspond to those of a lobe of the lung.

If not rapidly fatal, the disease may be complicated by pulmonary gangrene or abscess and large quantities of fetid pus may be spit up.

BRONCHO-PNEUMONIA.

(Catarrhal or Lobular Pneumonia.)

Multiple small areas of solidification scattered through both lungs, interspersed with areas of collapse, and usually associated with diffuse bronchitis, occur very frequently in children producing severe dyspnœa, cyanosis, cough, and somnolence, and running a very fatal course.

The solidified lobules may fuse so as to form considerable areas of hepatized lung, or there may be no lesion larger than a pea.

This is the usual type of "lung fever" in infants, although ordinary lobar pneumonia is not rare in infancy and in childhood.

The widespread atelectasis of the lower lobes which is associated with the disease in most cases owing to the plugging of the bronchi with tenacious secretions, is probably as serious in its effects as the pneumonic foci themselves.

The anterior and upper parts of the lungs often become distended with air (vicarious emphysema) and render the physical signs very confusing and deceptive.

Physical Signs.

In the majority of cases there are no characteristic physical signs, and the diagnosis has to be made largely from the symptoms and course of the disease. The consolidated areas are usually too small to give rise to any dulness on percussion, or to any change in the breath sounds, voice sounds, or fremitus, so that auscultation shows, as a rule, nothing more than patches of fine râles occurring at the end of expiration. Localized tympanitic resonance is some-

times present over the diseased area, making the sounder portions of the lungs seem dull by comparison. Occasionally, when many lobules have fused into a single mass of larger area, the ordinary signs of consolidation may be obtained, although they are apt to disappear within twenty-four or forty-eight hours and appear in another situation. As above said, the diagnosis is usually to be made, if at all, from the combination of the *physical signs of a localized bronchitis with the symptoms of pneumonia*. "This patient," we say, "has only the signs of bronchitis, but he is too sick. The cyanosis, dyspnœa, and fever are too marked. He is sicker than simple bronchitis will account for."

Differential Diagnosis.

(a) *Acute pulmonary tuberculosis* may be indistinguishable from broncho-pneumonia by the physical signs alone. The diagnosis must be made from the history and course of the disease or from the presence of tubercle bacilli in the sputa.

(b) The extensive *atelectasis* of the lower lobes which may accompany broncho-pneumonia gives rise to dulness and absence of respiratory and vocal sounds. Thus, the signs of *pleuritic effusion* are simulated, and in children the possibility of empyema should not be forgotten. As a rule, broncho-pneumonia gives rise to much greater dyspnœa, and is associated with a more extensive bronchitis, than usually coexist with pleural effusion. The atelectatic lobules may be expanded by coughing or by the cutaneous stimulus of cold water, and thus resonance and breath sounds may suddenly return. With pleuritic effusions, of course, such a change is impossible.

TUBERCULOSIS OF THE LUNGS.

(1) *Incipient Tuberculosis.*

In the earlier stages of the disease there may be absolutely no recognizable physical signs, and the diagnosis may be established only by the positive result of a *tuberculin* injection or by the combination of *debility with slight fever* not otherwise to be accounted for.

In some cases the earliest evidence of the disease is *hæmoptysis*.¹ When a patient consults a physician on account of hæmoptysis, it is frequently impossible to find any physical signs of disease in the lungs; not until weeks or months later do the characteristic changes recognizable by physical examination make their appearance.

The very *early hoarseness* of the voice in tuberculous patients is of great importance and often attracts our attention to the lungs when the patient has said nothing about them. Definite physical signs in the lungs and tubercle bacilli in the sputa (artificially ob-

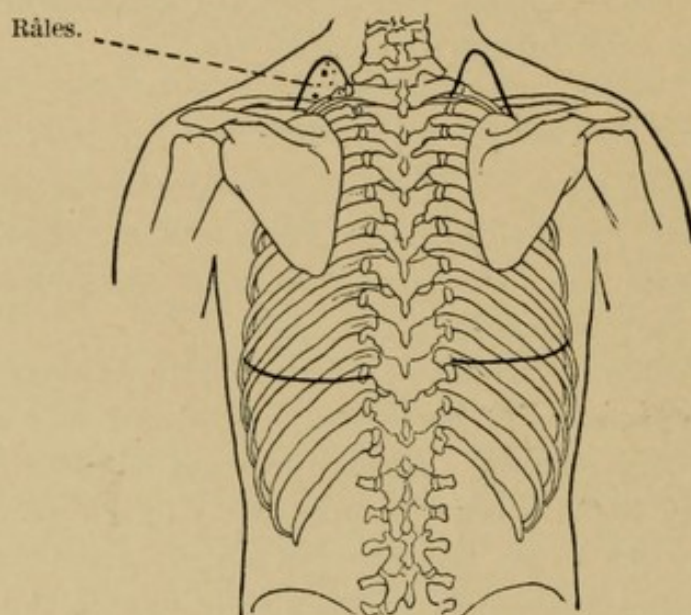


FIG. 129. — Diagram to Show Position of Earliest Signs in Tuberculosis.

tained through the use of potassic iodide, see below) may occasionally be demonstrated before any cough has appeared. On the other hand, the patient may cough for weeks before anything abnormal can be discovered in the lungs. Occasionally tuberculosis begins with an ordinarily bilateral bronchitis. I have found tubercle bacilli in four such cases. More often the earliest physical signs are:

(a) Fine crackling râles at the apex of one lung, heard only

¹ Never percuss a patient within forty-eight hours after a hemorrhage, and never encourage cough or forced respiration in such a one. There is danger of starting a fresh hemorrhage.

with or after cough and at the end of inspiration. [More rarely squeaks may be heard.] (See Fig. 129).

(b) A slight diminution in the excursion of the diaphragm on the affected side, as shown by Litten's diaphragm shadow.

(c) Slight diminution in the intensity of the respiratory murmur, with or without interrupted inspiration ("*cog-wheel breathing*").

(a) In examining the apices of the lungs for evidence of early tuberculosis one should secure if possible perfect quiet in the room, and have the clothes entirely removed from the patient's chest. The ordinary hard-rubber chest-piece is better than the chest-piece of the Bowles instrument when we wish to search the apices for fine râles. After listening during quiet breathing over the apices above and below the clavicle in front, and above the spine of the scapula behind, the patient should be directed to breathe out and then, at the end of expiration, to cough. During the deep inspiration which is likely to precede or to follow such a cough one should listen as carefully as possible at the apex of the lung, above and below the clavicle, concentrating attention especially upon the last quarter of the inspiration, when râles are most apt to appear. Sometimes only one or two crackles may be heard with each inspiration, and not infrequently they will not be heard at all unless the patient is made to cough, but even a *single râle, if persistent*,¹ is important. In children who cannot cough at will, one can accomplish nearly the same result by making them count as long as possible with one breath and then listening to the immediately succeeding inspiration. When listening over the apex of the lung, one should never allow the patient to turn his head sharply in the other direction, since such an attitude stretches the skin and muscles on the side on which we are listening so as to produce annoying muscle sounds or skin rubs.

In cases in which one suspects that incipient tuberculosis is

¹ Râles heard only during the first few breaths and not found to persist on subsequent examinations, may be due to the expansion of atelectatic lobules.

present and yet in which no positive evidence can be found, it is a good plan to give iodide of potassium (gr. vii. three times a day) for a few days. The effect of this drug is often to make râles more distinct, and sometimes to increase expectoration so that tubercle bacilli can be demonstrated when before none were to be obtained.¹

(*b*) The diminution in the excursion of the diaphragm upon the affected side in cases of incipient phthisis has been much insisted upon by F. H. Williams and others who have interested themselves in the radioscopy of the chest. Litten's diaphragm shadow gives us a method of observing the same phenomenon without the need of a fluoroscope. Even very slight tuberculous changes in the lung are sufficient to diminish its elasticity and so to restrict its excursion and that of the diaphragm. Comparisons must always be made with the sound side in such cases, as individuals differ very much in the extent with which they are capable of depressing the diaphragm. It must be remembered that pleuritic adhesions, due to a previous inflammation of the pleura, may diminish or altogether abolish the excursion of the diaphragm shadow, independently of any active disease in the lung itself.

Those who are expert in the use of the fluoroscope believe that they can detect the presence of tuberculosis in the lung by radioscopy at a period at which no other method of physical examination shows anything abnormal. I shall return to the consideration of this point in the section on Radioscopy.²

Interrupted or cog-wheel respiration, in which the inspiration is made up of sharp, jerky puffs, signifies that the entrance of the air into the alveoli is impeded, and such impediment is most likely to be due to tuberculosis when present over a considerable period in a localized area of pulmonary tissue.

¹ Any irritating vapor—for example, creosote vapor—which produces violent cough and expectoration, may be used to expel bronchial secretions in doubtful cases. Tubercle bacilli may then be found in the sputum of patients who, without the irritating inhalation, have no cough and so no sputa.

² See Appendix C.

(2) *Moderately Advanced Cases*

So far I have been speaking of the detection of tuberculosis at a stage prior to the production of any considerable amount of solidification. The signs considered have been those of bronchitis localized at the apex of the lung, or of a slightly diminished pulmonary elasticity, whether due to pleuritic adhesions or to other causes. We have next to consider the signs in cases in which solidification is present, though relatively slight in amount. This condition is comparatively easy to recognize when it occurs at the

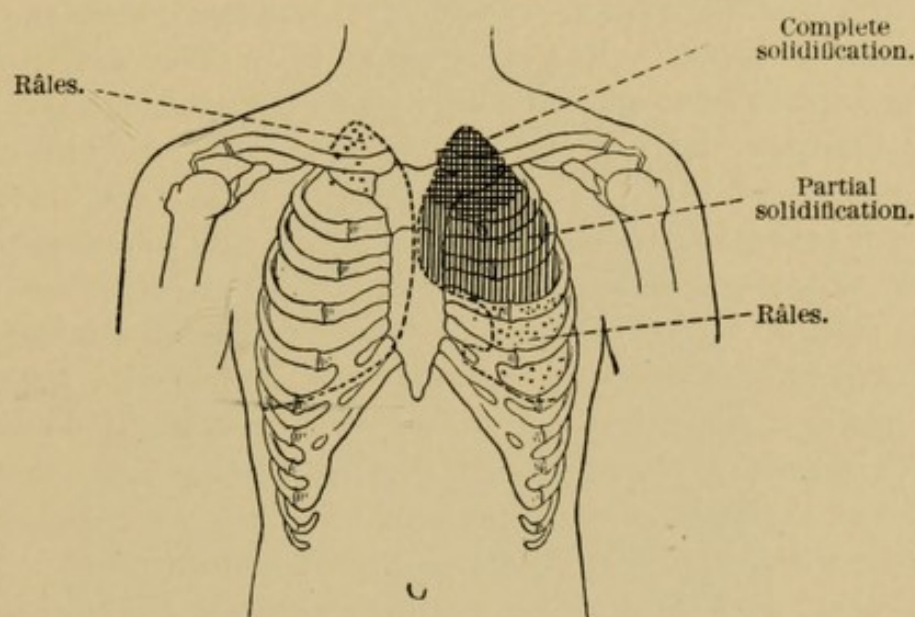


FIG. 130.—Diagram of Signs in Phthisis.

left apex, but more difficult in case only the right apex is diseased. Partial solidification of a small area of lung tissue at the left apex gives rise to

(a) Slight dulness on light percussion,¹ with increased resistance.

(b) Slight increase in the intensity of the spoken and whispered voice, and of the tactile fremitus (in many cases).

¹ Other causes of dulness, such as asymmetry of the chest, pleural thickening, and tumors, must be excluded. Emphysema of the lobules surrounding the tuberculous patch may completely mask the dulness.

(c) Some one of the numerous varieties of broncho-vesicular breathing (true bronchial breathing is a late sign).

(d) Abnormally loud transmission of the heart sounds, especially under the clavicle.

(e) Cardio-respiratory murmurs (*vide* p. 143) are occasionally due to the pressure of a tuberculous lobule upon the subclavian artery. In connection with other signs they are not altogether valueless in diagnosis.

In case there is also a certain amount of secretion in the bronchi of the affected area or ulceration around them, one often hears râles of a peculiar quality to which Skoda has given the name of "*consonating* râles." Râles produced in or very near a solidified area are apt to have a very sharp, crackling quality, their intensity being increased by the same acoustical conditions which increase the intensity of the voice sounds over the same area. When such râles are present at the apex of either lung, the diagnosis of tuberculosis is almost certain, but if, as not infrequently occurs, there are no râles to be heard over the suspected area, our diagnosis is clear *only* in case the signs occur at the left apex. Precisely the same signs, if present at the right apex, leave us in doubt regarding the diagnosis, for the reason that, as has been explained above, we find at the apex of the right lung in health signs almost exactly identical with those of a slight degree of solidification. Hence, if these signs, and only these, are discovered at the right apex, we cannot feel sure about the diagnosis until it is confirmed by the appearance of râles in the same area of the left side (whether under the influence of iodide of potassium or spontaneously), or by the finding of tubercle bacilli in the sputum.¹

A sign characteristic of early tuberculous changes in the lung and one which I have frequently observed in the lower and relatively sounder lobes of tuberculous lungs is a raising of the pitch of inspiration, without any other change in the quality of the breathing or any other physical signs. The importance of this sign in the diag-

¹ The natural disparity between the two apices is less marked in the supra-spinous fossa behind than over the clavicle in front, and hence pathological dulness at the apex is more often demonstrable behind than in front.

nosis of early tuberculosis of the lungs was insisted upon by the elder Flint in his work on "The Respiratory Organs" (1866), and has more recently been mentioned by Norman Bridge.

It must never be forgotten that tuberculosis may take root in

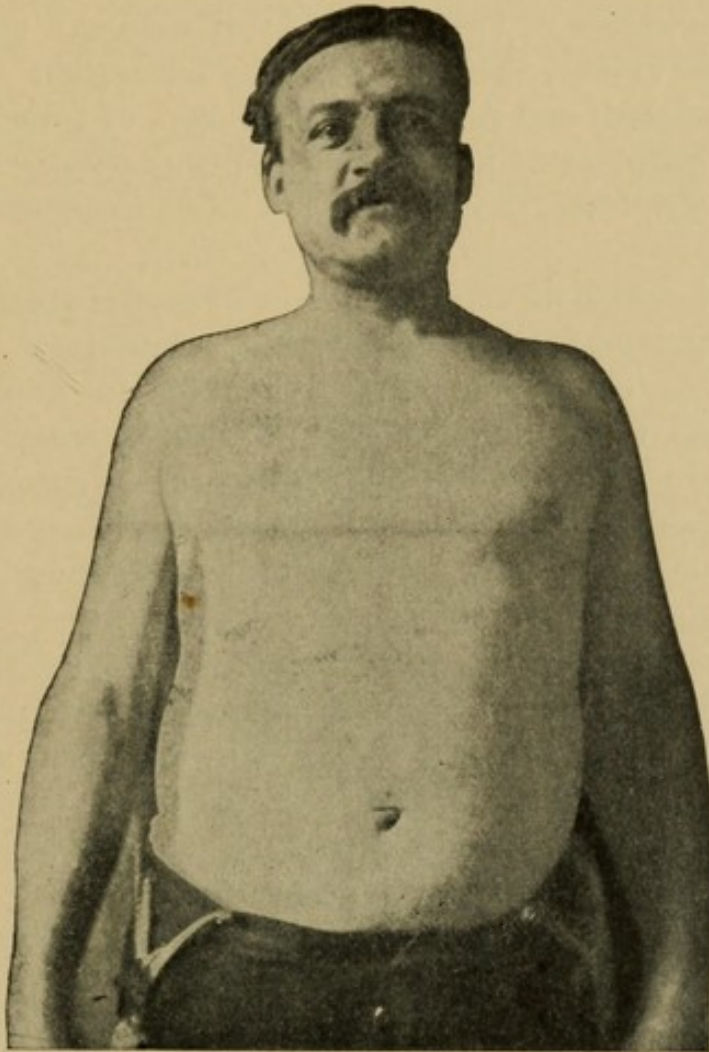


FIG. 131.—This Patient has Solidification at both Apices and Tubercle Bacilli in the Sputa. He feels perfectly well.

the most finely formed chests and in persons apparently in blooming health. The "phthisical chest" and the sallow, emaciated figure of the classical descriptions apply only to very advanced cases. Fig. 131 represents a patient with moderately advanced signs of phthisis and abundant tubercle bacilli in the sputa. He feels perfectly

well and is at work. On the other hand, a patient with very slight signs may be utterly prostrated by the toxæmia of the disease.

(3) *Advanced Phthisis.*

Characteristic of the more advanced stages of tuberculosis in the lungs is the existence of large areas of solidified and retracted lung, and, to a lesser extent, the signs of cavity formation. The patients are pale, emaciated, and feverish. The signs of solidification have already been enumerated in speaking of pneumonia. They are:

1. Marked dulness, or even flatness,¹ with increased sense of resistance.
2. Great increase of voice sounds or of tactile fremitus.
3. Tubular breathing, sometimes loud, sometimes feeble.
4. As a rule, coarse râles, due to breaking down of the caseous tissue, are also to be heard over the solidified areas. Sometimes these râles are produced within the pleuritic adhesions, which are almost invariably present in such cases. If they disappear just after profuse expectoration, one may infer that they are produced within the lung.

Increase in the intensity of the spoken voice, of the whispered voice, or of the tactile fremitus may be marked and yet no tubular breathing be audible. Each of these signs may exist and be of importance as signs of solidification without the others. As a rule, it is true, they are associated and form a very characteristic group, but there are many exceptions to this rule.

The tendency of the spinal column to transmit to the sound lung sounds produced in an area of solidification immediately adjacent to it on the other side, has been already alluded to in the section on pneumonia, and what was then said holds good of tuberculous solidification. Owing to this it is easy to be misled into diagnosing solidification at both apices when only one is affected.

Since solidification is usually accompanied by retraction in the affected lung in very advanced cases, the chest falls in to a greater

¹ Unless senile emphysema masks it. Fibroid phthisis (*vide infra*) may show no dulness. Remember that gastric tympany may be transmitted to the left lung and mask dulness there.

or less extent over the affected area, and the respiratory excursion is much diminished, as shown by ordinary inspection and by the diminution or disappearance of the excursion of the diaphragm shadow. The intensity of the tubular breathing depends on the proximity of the solidified portions to the chest wall and to the large bronchi, as well as on the presence or absence of pleuritic thickening.

It is rare to find a whole lung solidified. The process, beginning at the apex or just below, extends down as far as the fourth

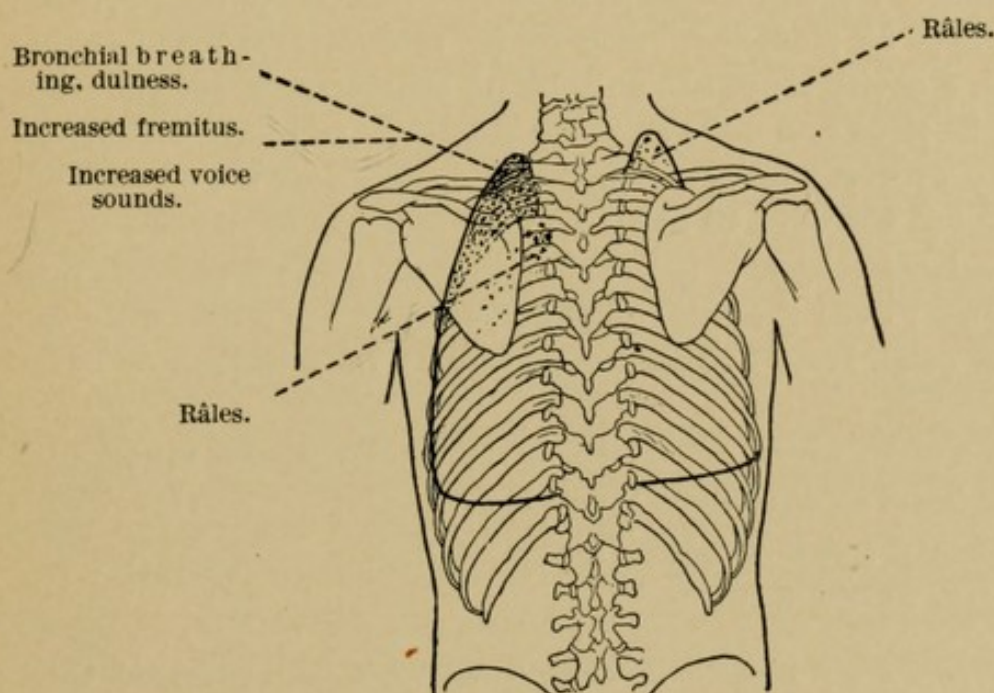


FIG. 132.—To Illustrate Progress of Signs in Pulmonary Tuberculosis.

rib in front, *i.e.*, through the upper lobe, in a relatively short time, but below that point its progress is comparatively slow and the lower lobes may be but little affected up to the time of death. On the relatively sound side the exaggerated (compensatory) resonance may mask the dulness of a beginning solidification there, which sooner or later is almost sure to occur. It is exceedingly rare for the disease to extend far in one lung without involving the other.

About the time that the tuberculous process invades the previously sound lung it is apt to show itself at the apex of the lower lobe

of the lung first affected. Consonating râles appear posteriorly along the line which the vertebral border of the scapula makes when the arm is raised over the shoulder. These points are illustrated in Fig. 132.

Cavity Formation.

Cavities of greater or lesser extent are formed in almost every case of advanced phthisis, but very seldom do they attain such size as to be recognizable during life. Indeed, the diagnosis of cavity in phthisis plays a much larger part in the text-books than it does in the practice of medicine, since to be recognizable by physical examination a cavity must not only be of considerable size but its walls must be rigid and not subject to collapse,¹ it must communicate directly with the bronchus and be situated near the surface of the lung, and it must not be filled up with secretions. It can readily be appreciated that it is but seldom that all these conditions are present at once; even then the diagnosis of cavity is a difficult one, and I have often known skilled observers to be mistaken on this point.

The signs upon which most reliance is usually placed are:

- (a) Amphoric or cavernous breathing.
- (b) "Cracked-pot resonance" on percussion.
- (c) Coarse, gurgling râles.

(a) *Cavernous or Amphoric Respiration.*—When present, this type of breathing is almost pathognomonic of a cavity. It is also to be heard in pneumothorax, but the latter disease can usually be distinguished by the associated physical signs. Cavernous breathing differs from bronchial or tubular breathing in that its pitch is lower and its quality *hollow*. The pitch of expiration is even lower than that of inspiration. Since a pulmonary cavity is almost always surrounded by a layer of solidified lung tissue, we usually hear around the area occupied by the cavity a ring of bronchial breathing with which we can compare the quality of the cavernous sounds.

¹ Yet not so rigid as to be uninfluenced by the entrance and exit of air.

(b) Percussion sometimes enables us to demonstrate a circumscribed area of tympanitic resonance surrounded by marked dullness. More often the "cracked-pot" resonance can be elicited by percussing over the suspected area while the chest-piece of the stethoscope is held close to the patient's open mouth.

Cracked-pot resonance is often absent over cavities; rarely occurs in any other condition (*e.g.*, in percussing the chest of a healthy, *crying* baby, and occasionally over solidified lung).

(c) The voice sounds sometimes have a peculiar hollow quality (amphoric voice and whisper).

(d) Cough or the movements of respiration may bring out over the suspected area splashing or gurgling sounds, or occasionally a metallic tinkle. Flint has also observed a circumscribed bulging of an interspace during cough. Bruce noted a high-pitched sucking sound during the inspiration following a hard cough ("rubber-ball sound").

Very important in the diagnosis of cavity is the *intermittence* of all above-mentioned signs, which are present only when the cavity is comparatively empty, and disappear when it becomes wholly or mostly filled with secretions. For this reason, the signs are very apt to be absent in the early morning before the patient has expelled the accumulated secretions by coughing.

Wintrich noticed that the note obtained when percussing over a pulmonary cavity may change its pitch if the patient opens his mouth. Gerhardt observed that the note obtained over a pulmonary cavity changes if the patient shifts from an upright to a recumbent position. Neither of these points, however, is of much importance in diagnosis. The same is true of metamorphosing breathing (see above, p. 102).

Tuberculous cavities differ from those produced by pulmonary abscess or gangrene in that the latter are usually situated in the lower two-thirds of the lung. Bronchiectasis, an exceedingly rare condition, cannot be distinguished by physical signs alone from a tuberculous cavity.

Fibroid Phthisis.

This term applies to slow tuberculous processes with relatively little ulceration and much fibrous thickening.

In a considerable number of cases the physical signs do not differ materially from those of the ordinary ulcerating forms of the disease, but occasionally when a slow chronic process at the apex of the lung results in the falling-away of the parenchyma of the lung so that we have left a cluster of bronchi matted together by fibrous tissue, the percussion note may be noticeably tympanitic; similar tympany may be due to emphysema of the lobules surrounding the diseased portion. In such cases râles are usually entirely absent; otherwise, the signs do not differ from those of ordinary phthisis, except that falling-in of the chest walls over the retracted lung may be more marked. Occasionally the heart may be drawn toward the affected lobes, *e.g.*, upward and to the right in right-sided phthisis at the apex. In two cases of fibroid disease at the left base, Flint found the heart beating near the lower angle of the left scapula.

Phthisis with Predominant Pleural Thickening.

Tuberculosis in the lung is in certain cases overshadowed by the manifestations of the same disease in the pleura, so that the signs are chiefly those of *thickened pleura*. To this subject I shall return in the section of Diseases on the Pleura (see below, p. 278).

Emphysematous Form of Phthisis.

Tubercle bacilli are not very infrequently found in the sputa of cases in which the history and physical signs point to chronic bronchitis with emphysema. I have seen two such cases within a year. Dulness is wholly masked by emphysema, tubular breathing is absent, and piping and babbling râles are scattered throughout both lungs. The emphysema may be of the senile or small-lunged type, as in one of my recent cases (with autopsy), or it may be associated with huge downy lungs and the "barrel chest." Such cases

cannot be identified as phthisis during life unless we make it an invariable rule to examine for tubercle bacilli the sputa of every case in which sputa can be obtained, *no matter what are the physical signs.*

Phthisis with Anomalous Distribution of the Lesions.

Very rarely a tuberculous process may begin at the base of the lung. When the process seems to begin in this way, a healed focus is often to be found at one apex surrounded by a shell of healthy lung.

The summit of the axilla should always be carefully examined, as tuberculous foci may be so situated as to produce signs only at that point.

Another point often overlooked in physical examination is the *lingula pulmonalis* or tongue-like projection from the anterior margin of the left lung overlapping the heart. Tuberculosis is sometimes found further advanced at this point than anywhere else.

As a rule cases in which signs like those of phthisis are found at the base of the lung turn out to be either empyema, or abscess, or unresolved pneumonia (cirrhosis of the lung).

Acute Pulmonary Tuberculosis.

No one of the three forms in which acute phthisis occurs, viz.,

(a) Acute tuberculous pneumonia,

(b) Acute tuberculous bronchitis and peribronchitis,

(c) Acute miliary tuberculosis, involving the lungs, can be recognized by physical examination of the chest. The first form is almost invariably mistaken for ordinary croupous pneumonia, until the examination of the sputa establishes the correct diagnosis. In the other two forms of the disease, the physical signs are simply those of general bronchitis.

CHAPTER XII.

EMPHYSEMA, ASTHMA, PULMONARY SYPHILIS, ETC.

I. EMPHYSEMA.

For clinical purposes, the great majority of cases of emphysema may be divided into two groups.

(1) *Large-lunged* emphysema, usually associated with chronic bronchitis and asthma.

(2) *Small-lunged*, or senile, emphysema.

Although the second of these forms is exceedingly common, it is so much less likely than the first form to give rise to distressing symptoms that it is chiefly the large-lunged emphysema which is seen by the physician. In both conditions we have a dilatation and finally a breaking down of the alveolar walls until the air spaces are become relatively large and inelastic. In both forms, the elasticity of the lung is diminished; but in the large-lunged form we have an increase in the volume of the whole organ in addition to the changes just mentioned.

Large-Lunged Emphysema.

The diagnosis can usually be made by inspection alone. In typical cases the antero-posterior diameter of the chest is greatly increased, the in-spaces are widened, and the costal angle is blunted, while the angle of Ludwig¹ becomes prominent. The shoulders are high and stooping and the neck is short (see Fig. 133). The patient is often considerably cyanosed, and his breathing rapid and difficult. Inspiration is short and harsh; expiration prolonged and difficult. The ribs move but little, and, owing to the ossification of their car-

¹ Formed by the junction of the manubrium with the second piece of the sternum.

tilages, are apt to rise and fall as if made in one piece (*en cuirasse*). The working of the auxiliary muscles of respiration is not infrequently seen. The diaphragm shadow (Litten's sign) begins its excursion one or two ribs farther down than usual and moves a much shorter distance than in normal cases.

Palpation shows a diminution in the tactile fremitus, throughout the affected portions; that is, usually throughout the whole of both lungs. Sometimes it is scarcely to be perceived at all.

Percussion yields very interesting information. The disease manifests itself—

(a) By hyper-resonance on percussion, with a shade of tympanitic quality in the note.

(b) By the extension of the margins of the lung so that they encroach upon portions of the chest not ordinarily resonant.

The degree of hyper-resonance depends not only upon the degree of emphysema but upon the thickness of the chest

walls. The note is most resonant and has most of the tympanitic quality when the disease occurs in old persons with relatively thin chest walls. The encroachment of the over-voluminous lungs upon the liver and heart is demonstrated by the lowering of the line of liver flatness from its ordinary position at the sixth rib to a point one or two interspaces farther down or even to the costal margin, while the area of cardiac dulness may be altogether obliterated, the lungs completely closing over the surface of the heart. At the apices of the lungs resonance may be obtained one or two centimetres higher than normally and the quality may be markedly tympanitic. In the axillæ and in the back the pulmonary resonance extends down one inch or more below its normal position.

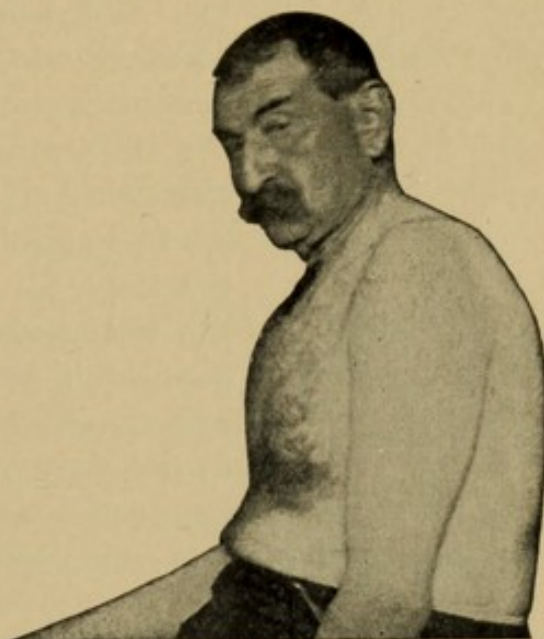


FIG. 133.—Barrel Chest due to Chronic Bronchitis and Emphysema.

Auscultation shows in uncomplicated cases no very marked modification of the inspiratory murmur, which, however, may be shortened and enfeebled. The most striking change is a *great prolongation and enfeeblement of expiration*, with a lowering of its pitch (see Fig. 134).

This type of breathing is like bronchial breathing in one respect; namely, that in both of them expiration is made prolonged, but emphysematous breathing is feeble and low-pitched, while bronchial breathing is intense and high-pitched. At the bases of the lungs the respiration is especially feeble and may be altogether replaced by crackling râles.

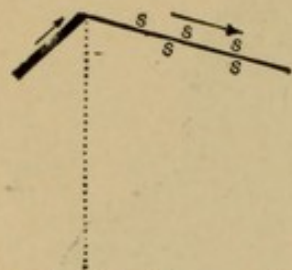


FIG. 134.—Diagram to Illustrate Emphysematous Breathing with Musical Expiratory Râles.

In "small-lunged emphysema" we have precisely the same physical signs, except that the boundaries of the lung are not extended, expiration is less prolonged and less difficult, and inspiration is normal. It does not tend to be complicated by bronchitis and asthma;

indeed the small-lunged emphysema rarely gives rise to any symptoms, and is discovered as a matter of routine physical examination.

Summary.

1. Hyper-resonance on percussion.
2. Feeble breathing with prolonged expiration.
3. Diminished fremitus and voice sounds.
4. Encroachment of the resonant lungs on the heart and liver dulness (in the large-lunged form).

Differential Diagnosis.

(a) *Emphysema* may be confounded with *pneumothorax*, since in both conditions hyper-resonance and feeble breathing are present. But emphysema is usually bilateral, encroaches upon but does not displace neighboring organs, and is not often associated with hydrothorax. Emphysema, if extensive, is usually associated with chronic bronchitis and so with squeaking or bubbling râles, while in

pneumothorax breathing is absent or distant amphoric without râles.

(b) The signs of *aneurism* of the aorta pressing on the trachea or on a primary bronchus are sometimes overlooked because the foreground of the clinical picture is occupied by the signs of a coexisting bronchitis with emphysema. The cough and wheezing which the presence of the aneurism produces may then be accounted for as part of the long-standing bronchitis, and the dulness and thrill over the upper sternum to which the aneurism naturally gives rise may be masked by extension of lung borders. But the evidence of pressure on mediastinal nerves and vessels (aphonia, unequal pulses or pupils, etc.), and the presence of a diastolic shock and tracheal tug are usually demonstrable; the danger is that we shall forget to look for them.

(c) *Uncompensated mitral stenosis* may produce dyspnoea and cyanosis and weak rapid heart action somewhat similar to that seen in emphysema, and may not be associated with any cardiac murmur, but the dyspnoea is not of the expiratory type, and the irregularity of the heart, with evidence of dropsy and general venous stasis, should make it evident that something more than simple emphysema is present.

(d) The occurrence of an emphysematous form of *phthisis* I have already mentioned in discussing the latter disease (see p. 251).

Emphysema with Bronchitis or Asthma.

In the great majority of cases, emphysema of the lungs is associated with chronic bronchitis and very often with asthmatic paroxysms. Such association is especially frequent in elderly men who have had a winter cough for many years and in whom arterio-sclerosis is more or less well marked. In such cases the prolonged and feeble expiration is usually accompanied by squeaking and groaning sounds, or by moist râles of various sizes and in various parts of the chest. When the asthmatic element predominates, dry râles are more noticeable, and occur chiefly or wholly during expiration, while inspiration is reduced to a short, quick gasp.

Interstitial Emphysema.

In rare cases violent paroxysms of coughing may rupture the walls of the alveoli so as to allow the passage of air into the interstitial tissue of the lung, from whence it may work through and manifest itself under the skin, giving rise to a peculiar crackling sensation on palpation, and to a similar sound on auscultation. More frequently the trouble arises in connection with a tracheotomy wound, the air penetrating under the skin and producing a downy, crepitating swelling.

"Complementary Emphysema."

When extra work is thrown upon one lung by loss of the function of the other, as in pleuritic effusion—a considerable stretching of the overworked sound lung may take place. The elasticity of the lung is not diminished as in emphysema, but is greatly increased. Hence the term complementary emphysema should be dropped and the term complementary (or compensatory) *hyper-resonance* substituted.

Like emphysema, this condition leads to hyper-resonance on percussion and to encroachment of the pulmonary margins upon the neighboring organs (as shown by a reduction in the area of dullness corresponding to them), but the respiratory murmur is *exaggerated* and has none of the characteristics of emphysematous breathing.

A word may here be added regarding the condition described by West under the name of

Acute Pulmonary Tympanites.

In fevers and other acute debilitating conditions West has observed that the lungs may become hyper-resonant and somewhat tympanitic on percussion, owing, he believes, to a loss of pulmonary elasticity. The tympanitic note, often observable around the solidified tissue in pneumonia, is to be accounted for, he believes, in the same way. Like the shortening of the first heart sound, acute pulmonary tympanites points to the weakening of muscle fibre which toxæmia is so apt to produce. Apparently the muscle fibres of the lung suffer like those of the heart.

BRONCHIAL ASTHMA.

(PRIMARY SPASM OF THE BRONCHI).

During a paroxysm of bronchial asthma our attention is attracted even at a distance by the loud, wheezing, prolonged expiration preceded by an abortive gasping inspiration. The breathing is labored, much quickened in rate, and cyanosis is very marked. The chest is distended and hyper-resonant, the position of the diaphragm low and its excursion much limited, and the cardiac and hepatic dulness obliterated by the resonance of the distended lungs. On auscultation, practically no respiratory murmur is to be heard despite the violent plunging of the chest walls. We hear squeaks, groans, muscular rumbles, and a variety of strange sounds, but amid them all practically nothing is to be heard of the *breath sounds*. "The asthmatic storm flits about the chest, now here now there," the râles appearing and disappearing.

At the extreme base of the lungs there may be dulness due to atelectasis of the thin pulmonary margins.

Differential Diagnosis.

(a) Mechanical irritation of the bronchi, as by the pressure of an aneurism or enlarged gland, may set up a spasm of the neighboring bronchioles much resembling that of primary bronchial asthma, but thorough examination should reveal other evidence of mediastinal pressure, and the history of the case is very different from that of asthma.

(b) *Spasm of the glottis* produces a noisy dyspnoea, but the difficulty is with *inspiration*, instead of with expiration, and the crowing or barking sound is not like the long wheeze of asthma. No râles are to be heard, and the signs in the lungs are those of collapse instead of the distention characteristic of asthma.

(c) The paroxysmal attacks of dyspnoea, which often occur in chronic nephritis, myocarditis, and other diseases of the heart and kidney, may be entirely indistinguishable from primary bronchial asthma but for the evidence of the underlying cardiac or renal dis-

ease. As a rule, however, the element of spasm is much less marked; the breathing is quick and labored but not wheezing, expiration is less prolonged, and the squeaking and groaning râles of asthma are not present.

SYPHILIS OF THE LUNG.

The diagnosis cannot be made with certainty from the physical signs, and rests entirely (in the rare cases in which it is made at all) on the history, the evidence of syphilis elsewhere in the body, and the result of treatment. Most cases are mistaken for phthisis.

Any case supposed to be phthisis, but in which the examination of the sputa for tubercle bacilli is repeatedly negative, should be given a course of syphilitic treatment.

The physical signs, as in phthisis, are those of localized bronchitis or of solidification, but the lesions are not at the apex but usually about the root of the lung or lower down. Cavities are not formed. Stenosis of a bronchus may occur with resulting atelectasis of the corresponding lobules.

BRONCHIECTASIS (BRONCHIAL DILATATION).

This rare disease is still more rarely to be recognized during life. It is suggested by the history of raising within a few seconds or minutes a large amount of foul sputa, a pint or more in marked cases. The physical signs may not be in any way distinctive, or may be those of pulmonary cavity due to tuberculosis. From the latter bronchiectasis is to be distinguished in some cases by a knowledge of the previous history. Signs of cavity in phthisis are preceded and surrounded by signs of solidification in the same area, while in bronchiectasis this is not the case. Again, a bronchiectatic cavity is apt to occur, not at the apex, as in phthisis, but in the middle and lower thirds of the lung posteriorly. Aside from the history and situation of the cavity and the presence or absence of solidification around it, we cannot tell from physical signs whether it be due to tuberculosis or to dilatation of a bronchus. In either case we have the signs discussed on page 260 (cracked-pot reso-

nance, amphoric breathing and voice sounds, coarse gurgling or splashing sounds on cough)—all these signs disappearing when the cavity becomes filled with secretions.

The disease may cause marked retraction of the chest on the affected side, and neighboring organs may be drawn out of place.

CIRRHOSIS OF THE LUNG.

(*Chronic Interstitial Pneumonia.*)

As an end stage of unresolved croupous pneumonia, or as a result of chronic irritation from mineral or vegetable dust, a shrinkage of a part or the whole of the lung may occur, which progresses until the pulmonary tissue is transformed into a fibrous mass enclosing bronchi.

The side of the chest corresponding to the affected lung becomes shrunken and concave; fremitus is increased, percussion resonance diminished or lost, respiration tubular with coarse râles.

From tuberculosis the condition is to be distinguished solely by the history, the absence of bacilli in the sputa, and the comparative mildness of the constitutional symptoms.

The right ventricle of the heart may become hypertrophied and later dilated with resulting tricuspid insufficiency.

CHAPTER XIII.

DISEASES AFFECTING THE PLEURAL CAVITY.

I. HYDROTHORAX.

IN cases of nephritis or of cardiac weakness due to valvular heart disease a considerable accumulation of serum may take place in both pleural cavities. The physical signs are identical with those of pleuritic effusion (see below, page 278) except that the latter is almost always unilateral, while hydrothorax is usually bilateral. Exceptions to this rule occur, however, especially on the right side or in cases in which one pleural cavity has been obliterated by fibrous adhesions, the results of an earlier pleurisy. The fluid obtained by tapping in cases of hydrothorax is usually considerably lower in specific gravity and poorer in albumin than that exuded in pleuritic inflammation.

The fluid shifts more readily with change of position than is the case with many pleuritic effusions, owing to the absence of adhesions in hydrothorax.

Friction sounds, of course, do not occur, as the pleural surfaces are not inflamed. A few grains of potassium iodide by mouth soon produce a reaction for iodine in the fluid of hydrothorax and not in pleuritic effusion.

II. PNEUMOTHORAX.

Pneumothorax, or the presence of air in the pleural cavity, may result from stabs or wounds of the chest wall, but is usually a complication of pulmonary tuberculosis which weakens the lung until by a slight cough or even by the movements of ordinary respiration the pulmonary pleura is ruptured and air from within the lung leaks into the pleural cavity.

If the opening is of considerable size, and the air is not hindered

or encapsulated by adhesions, great and sudden dyspnoea with pain and profound "shock" may result. More commonly the air enters the pleural cavity gradually, the other lung has time to hypertrophy, and the heart and other organs become gradually accustomed to their new situations.

Physical Signs.

1. *Inspection.*—The affected side may lag behind considerably in the movements of respiration. In very marked cases it is almost motionless and the interspaces are more or less obliterated. The diaphragm is much depressed and Litten's sign absent. In right-sided pneumothorax, which is relatively rare, the liver is depressed and the edge can be felt below the ribs.

The heart is displaced as by pleuritic effusion, but usually to a less extent. With left-sided pneumothorax the cardiac impulse may be lowered as well as displaced, owing to the descent of the diaphragm.

2. *Palpation.*—Fremitus is absent over the lower portions of the chest corresponding to the effused air. At the summit of the chest over the retracted lung, fremitus may be normal or increased. In rare cases when the lung is adherent to the chest wall and cannot retract, fremitus is preserved.

The positions of the heart and liver are among the most important points determined by palpation. Not infrequently no cardiac impulse is to be obtained. Sometimes it may be felt to the right of the sternum (see Fig. 134) or in the left axilla, but not infrequently it is so fixed by pleuropericardial adhesions that it is drawn upward toward the retracted lung or remains near its normal situation. The liver is greatly depressed in cases of right-sided pneumothorax, and may be felt as low as the navel.

3. *Percussion.*—Loud tympanitic resonance is the rule throughout the affected side. Even a small amount of air is sufficient to render the whole side tympanitic and often to obscure the dulness which the frequently associated pleural effusion would naturally produce. Indeed, it is the rule that small effusions are wholly masked by the adjacent tympany.

In no other disease do we get such clear, intense tympanitic resonance over the chest.

The only exception to this rule occurs in cases in which the air within the chest is under great tension, making the chest walls so taut that, like an over-stretched drum, they cannot vibrate properly. Under these conditions the percussion note becomes muffled, at times almost dull.

Areas of dulness corresponding to the displaced organs (heart or liver) may sometimes be percussed out.

4. *Auscultation*.—Respiration and voice sounds are usually inaudible in the lower portions of the chest. At the top of the chest, and rarely in the lower parts, a faint amphoric or metallic breathing may be heard, but as a rule the amphoric quality is brought out much better by cough which is followed by a ringing after-echo. Or the air in the pleura may be set to vibrating and made to give forth its characteristic, hollow, ringing sound if a piece of metal (*e.g.*, a coin) be placed on the back of the chest and struck with another coin, while we listen with the stethoscope over the front of the chest opposite the point where the coin is.

The clear ringing sound heard in this way is quite different from the dull chink obtainable over sound lung tissue.

The "falling-drop sound" or "metallic tinkle," and the lung fistula sound are occasionally audible (see above, p. 116).

On the sound side the breath sounds are exaggerated. At the top of the affected side over the collapsed lung the breathing is bronchial and râles are occasionally heard.

In the great majority of cases pneumothorax is complicated by an effusion of fluid in the affected pleural cavity and we have then the signs of

III. PNEUMOSEROTHORAX OR PNEUMOPYOTHORAX

When both fluid and air are contained in the pleural cavity, the patient may himself be able to hear the splashing sounds which the movements of his own body produce. These are more readily appreciated if the observer puts his ear against the patient's chest and then shakes him briskly. Splashing sounds heard within the

chest are absolutely pathognomonic and point only to the combination of fluid and air within the pleural cavity. One must distinguish them, however, from similar sounds produced in the stomach. By observing the position of maximum intensity of the sounds, this distinction may be easily made. Unfortunately the critical condition of the patient may make it impossible to try succussion, as in the acute cases with great shock it is dangerous to move him at all.

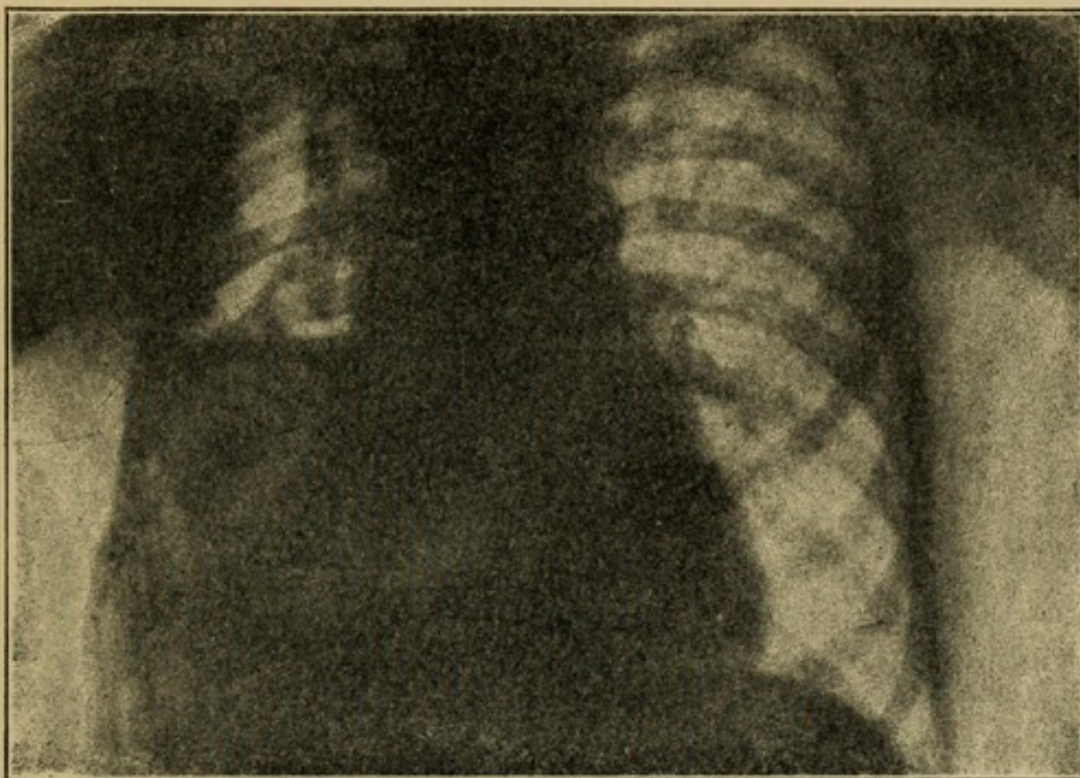


FIG. 135.—Seropneumothorax. Note the horizontal line at the surface of the fluid and the retracted lung just above the inner half of this line. Compare Fig. 141. (From v. Ziemssen's Atlas.)

The movements of breathing or coughing may bring out a "metallic tinkle" (see above, p. 274). At the base of the chest, over an area corresponding to the position of the fluid, an area of dulness may be easily marked out by percussion, and this area *shifts very markedly* with change of position. The shifting dulness of pneumoserothorax is strongly in contrast with the difficulty of obtaining any such shift in ordinary pleuritic effusion (see Fig. 136)

(The distinction between "*open pneumothorax*," in which the rent in the lung through which the air escaped in the pleura remains open, and "*closed pneumothorax*," in which the rent has become obliterated—is one which cannot be established by physical signs alone. It is often said that amphoric breathing, and especially an amphoric ring to the voice and cough sounds, denote an

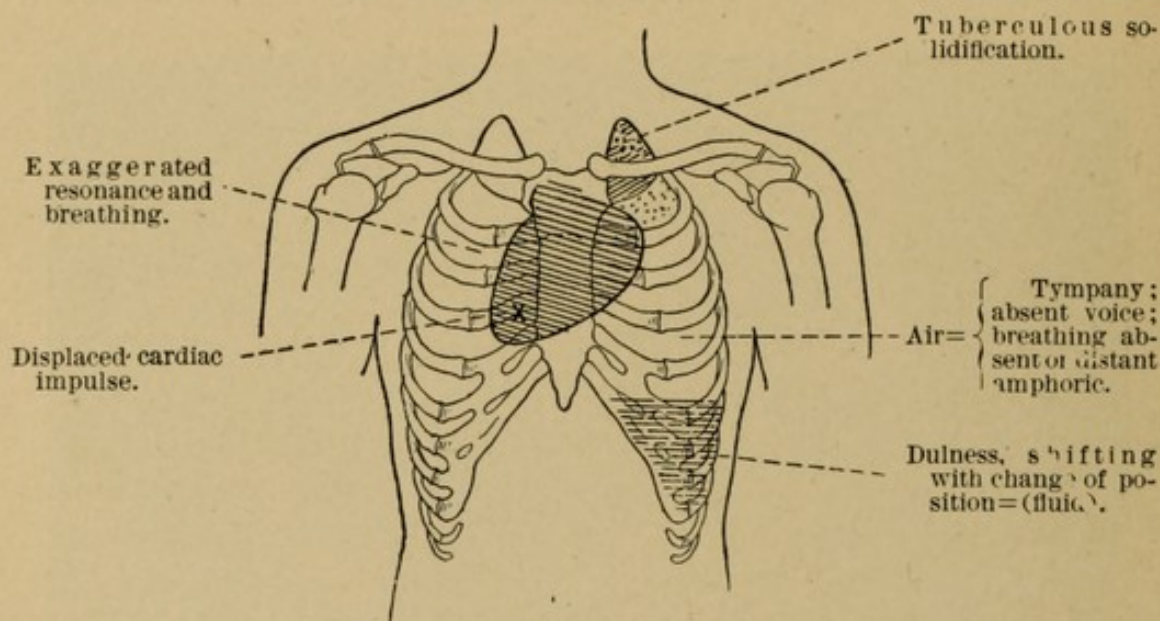


FIG. 136.—Sero-pneumothorax with Displaced Heart.

open pneumothorax, but post-mortem evidence does not bear this out. Practically an open pneumothorax is one in which the amount of effused air increases, and closed pneumothorax is one in which the physical signs remain stationary)

Differential Diagnosis.

The distinction between pneumothorax and emphysema has already been discussed.

(a) When the air in the pleural sac is under such tension that the percussion note is dull, the physical signs may simulate pleuritic effusion, but real flatness, such as characterizes effusion, has not, so far as I know, been recorded in pneumothorax, and the sense of resistance on percussing is much greater over fluid than over air. In case of doubt puncture is decisive.

(b) Acute pneumothorax, coming on as it does with symptoms of collapse and great shock, may be mistaken for angina pectoris, cardiac failure, embolism of the pulmonary artery, or acute pulmonary tympanites (see above, p. 262).

From all these it can be distinguished by the presence of amphoric or metallic sounds, which are never to be obtained in the other affections named.

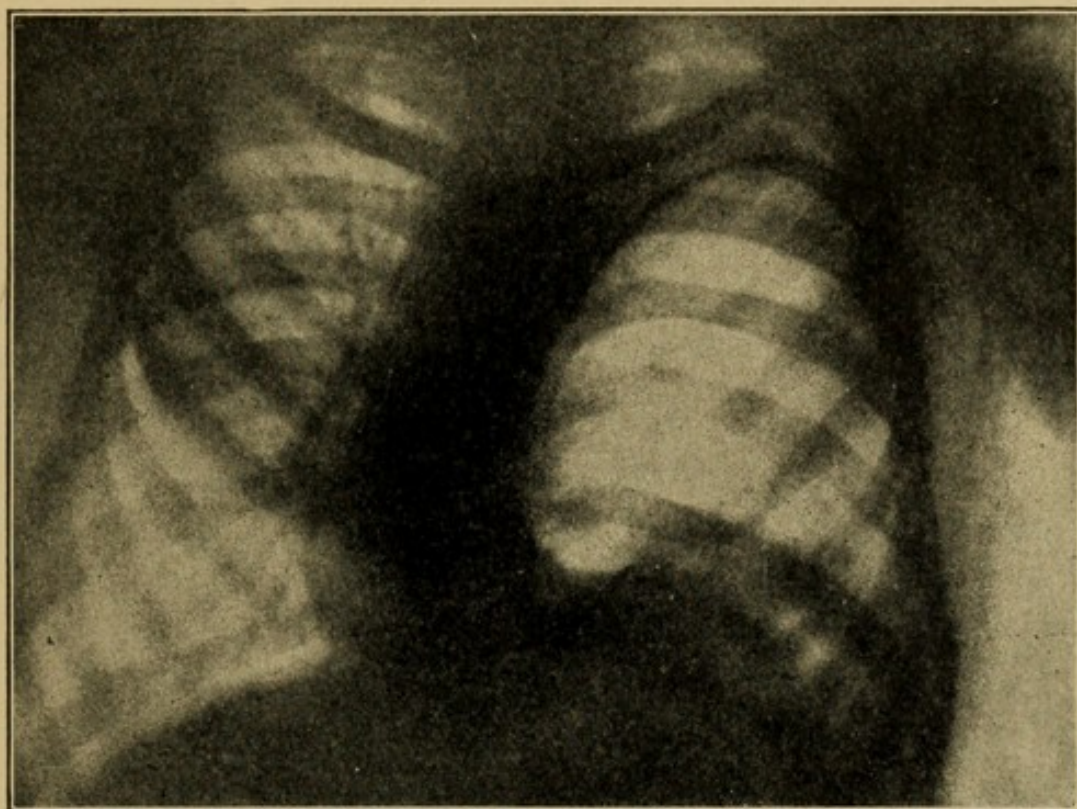


FIG. 137.—Diaphragmatic Hernia. The outline of the displaced diaphragm visible below the left clavicle. Heart displaced to right of sternum. (From v. Ziemssen's Atlas.)

(c) Hernia of the intestine through the diaphragm (see Fig. 137) or great weakening of the diaphragmatic muscular fibres, may allow the intestines to encroach upon the thoracic cavity and simulate pneumothorax very closely. The history and course of the case, the abdominal pain, vomiting, and indicanuria, generally suffice to distinguish the condition. The peristalsis of the intestine may go on even in the thorax, and gurgling metallic sounds corresponding to it and unlike anything produced in the thorax itself may be audible.

The distinction between open and closed pneumothorax, to which I have already alluded, is far less important than the presence or absence of

(a) Pulmonary tuberculosis

(b) Encapsulating adhesions in which the air is confined to a circumscribed area

(a) The examination of the sputa and of the compressed lung may yield evidence regarding tuberculosis. On the sound side the compensatory hypertrophy covers up foci of dulness or râles so that it is difficult to make out much.

(b) Encapsulated pneumothorax gives us practically all the signs of a phthisical cavity, from which it is distinguished by the fact that with a cavity the nutrition of the patient is almost always much worse.

Encapsulated pneumothorax needs no treatment. Hence the importance of distinguishing it from the non-encapsulated form of the disease, in which treatment is essential.

PLEURISY.

Clinically, we deal with three types:

(a) Dry or plastic pleurisy.

(b) Pleuritic effusion, serous or purulent.

(c) Pleural thickening.

(a) DRY OR PLASTIC PLEURISY.

Doubtless many cases run their course without being recognized. The frequency with which pleuritic adhesions are found post mortem would seem to indicate this.

It is usually the characteristic stitch in the side which suggests physical examination. The pain and the physical signs resulting from the fibrinous exudation are usually situated at the bottom of the axilla where the diaphragmatic and costal layers of the pleura are in close apposition. Doubtless the pleuritic inflammation is not by any means limited to this spot, but it is here that the two layers of the pleura make the largest excursion while in apposition with each other. In the vast majority of cases, then, the physical signs are situated at the spot indicated in Fig. 138.

Occasionally pleuritic friction is to be heard in the precordial region, and after the absorption of a pleuritic effusion evidences of fibrinous exudation in the upper parts of the chest are sometimes demonstrable. Most rarely of all, evidence of plastic pleurisy may be found at the apex of the lung in connection with early phthisis. In diaphragmatic pleurisy, when the fibrinous exudation is especially marked upon the diaphragmatic pleura, friction sounds may be heard over the region of the attachment of the diaphragm in front and behind as well as in the axillæ. Hiccup often occurs and gives exquisite pain.

Our diagnosis is based upon a single physical sign, *pleuritic friction*. The nature of this sound and the manœuvres for eliciting it have already

been described (see above, p. 112), and I will here only recapitulate what was there said. During the first few deep breaths one hears, while listening over the painful area, a grating or rubbing sound usually somewhat jerky and interrupted, most marked at the latter part of inspiration, but often audible throughout the whole respiratory act. After a few breaths it often disappears, but will usually reappear if the patient lies for a short time upon the affected side, and then sits up and breathes deeply. In marked cases the rubbing of the inflamed pleural surfaces may be felt as well as heard, and it is not very rare for the patient to be able to feel and hear it himself. Pleuritic friction may be present and loud without giving rise to any pain. On the other hand, the pain may be intense, and yet the friction-rub barely audible. When heard at the summit of the chest, as in cases of incipient phthisis, pleural fric-

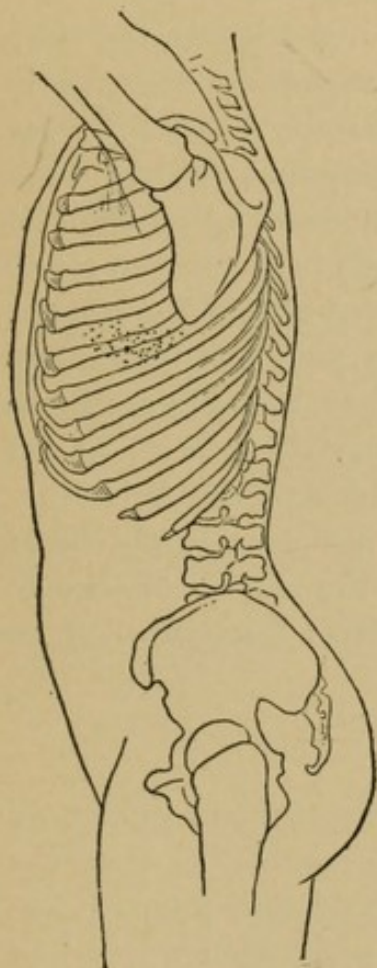


FIG. 138.—Showing the Point at which Pleural Friction is most Often Heard.

tion produces only a faint grazing sound, much more delicate and elusive than the sounds produced at the base of the chest.

Occasionally the distinctive rubbing or grating sounds are more or less commingled with or replaced by crackling sounds indistinguishable from the drier varieties of râles. It is now, I think, generally believed that such sounds may originate in the pleura as well as within the lung. The greatest care should be taken to prevent any shifting or slipping of the stethoscope upon the surface of the chest, as by such means sounds exactly like those of pleural friction may be transmitted to the ear. In case of doubt one should always wet or grease the skin so that the stethoscope cannot slip.

Muscle sounds are sometimes taken for pleural friction, but they are bilateral, usually low-pitched, sound less superficial than pleural friction, and are not increased by pressure. When listening for friction at the base of the left axilla, I have once or twice been puzzled by some low-pitched rumbling sounds occurring at the end of inspiration, and due (as afterward appeared) to gas in the stomach which shifted its position with each descent of the diaphragm.

In children friction sounds and pleuritic pain are much less common than in adults, and the signs first recognizable are those of effusion. In adults the presence of a very thick layer of fat may make it difficult or impossible to feel or hear pleural friction.

The breath sounds over the affected area are usually absent or greatly diminished, owing to the restraint in the respiratory movements due to pain. Not infrequently pleuritic friction may be heard altogether below the level of the lung.

(b) PLEURITIC EFFUSION.

Many cases are latent, and the patients consult the physician on account of slight cough, weakness, or gastric trouble, so that the effusion is first discovered in the course of routine physical examination. Since it is usually the results of percussion which first put us on the right track, I shall take up first

Percussion.

1. A *small effusion* first shows as an area of dulness

(a) Just below the angle of the scapula.

(b) In the left axilla between the fifth and the eighth rib.

(c) Obliterating Traube's semilunar area of tympany; or

(d) In the right front near the angle made by the cardiac and hepatic lines of dulness (see Fig. 139).

In the routine percussion of the chest, therefore, one should never leave out these areas. A small effusion is most easily detected in children or in adults with thin chest walls, provided our percussion is not too heavy. An effusion amounting to a pint should always be recognizable, and smaller amounts have frequently been diagnosed and proved by puncture.

The amount of a pleuritic effusion is roughly proportional to the area of dulness on percussion, but not accurately. It is very common to find on puncture an amount of fluid much greater than

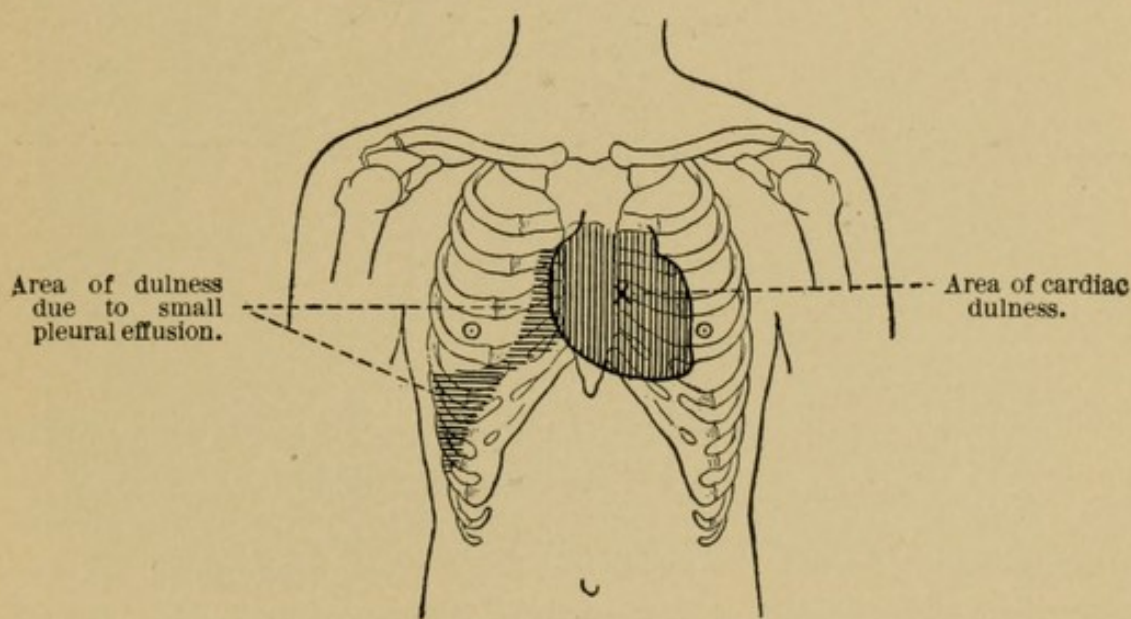


FIG. 139.—Small Pleural Effusion Accumulating (in part) near the Right Border of the Heart.

could have been suspected from the percussion outlines; on the other hand, the dulness may be extensive and intense on account of great inflammatory thickening of the costal pleura, by the accumulation

of layer after layer of fibrinous exudate and its organization into fibrous plates, while very little fluid remains within.

The amount of dulness depends also upon the thickness and elasticity of the chest wall and the degree of collapse of the lung within.

2. *Large Effusions*.—When the amount of fluid is large, the dulness may extend throughout the whole of one side of the chest with the exception of a small area above the clavicle or over the primary bronchus in front. This area gives a high-pitched *tympanitic* note,

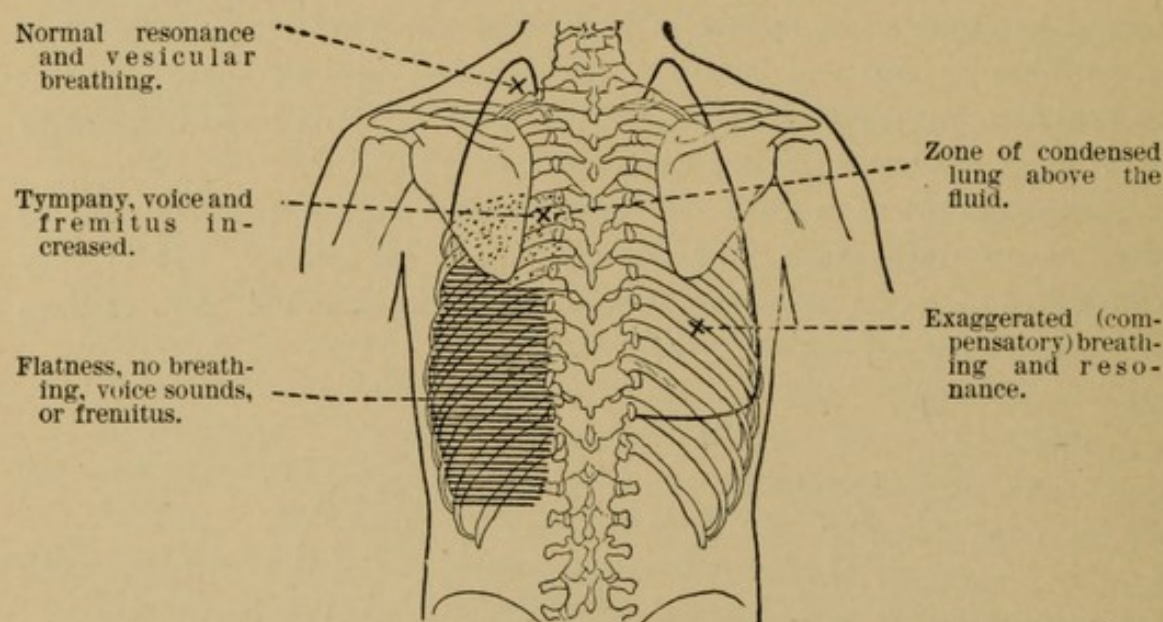


FIG. 140.—Diagram to Illustrate Physical Signs in Moderate-Sized Effusion in the Left Pleura.

provided the bronchi remain open, as they almost always do. This tympany is high-pitched and sometimes astonishingly clear. I recently saw a case in which the note above the clavicle was almost indistinguishable with the eyes shut from that obtained in the epigastrium. Occasionally “cracked-pot” resonance may be obtained in the tympanitic area.

The pitch changes if the patient opens and closes his mouth while we percuss (“Williams’ tracheal tone”).

The dulness over the lower portions of a large effusion is usually *very* marked, and the percussing finger feels a greatly increased

resistance to its blows when compared with the elastic rebound of the sound side.

3. *Moderate Effusions.*—Three zones of resonance can often be mapped out in the back: at the base dulness or flatness, above that a zone of mingled dulness and tympany, and at the top normal resonance. The lowest zone corresponds to the fluid, the middle zone to the condensed lung immediately above it, and the top zone to the relatively unaffected part of the lung (see Fig. 140). Not infrequently there is no middle zone but simply dulness below and resonance above, as is usually the case in the axilla and front.

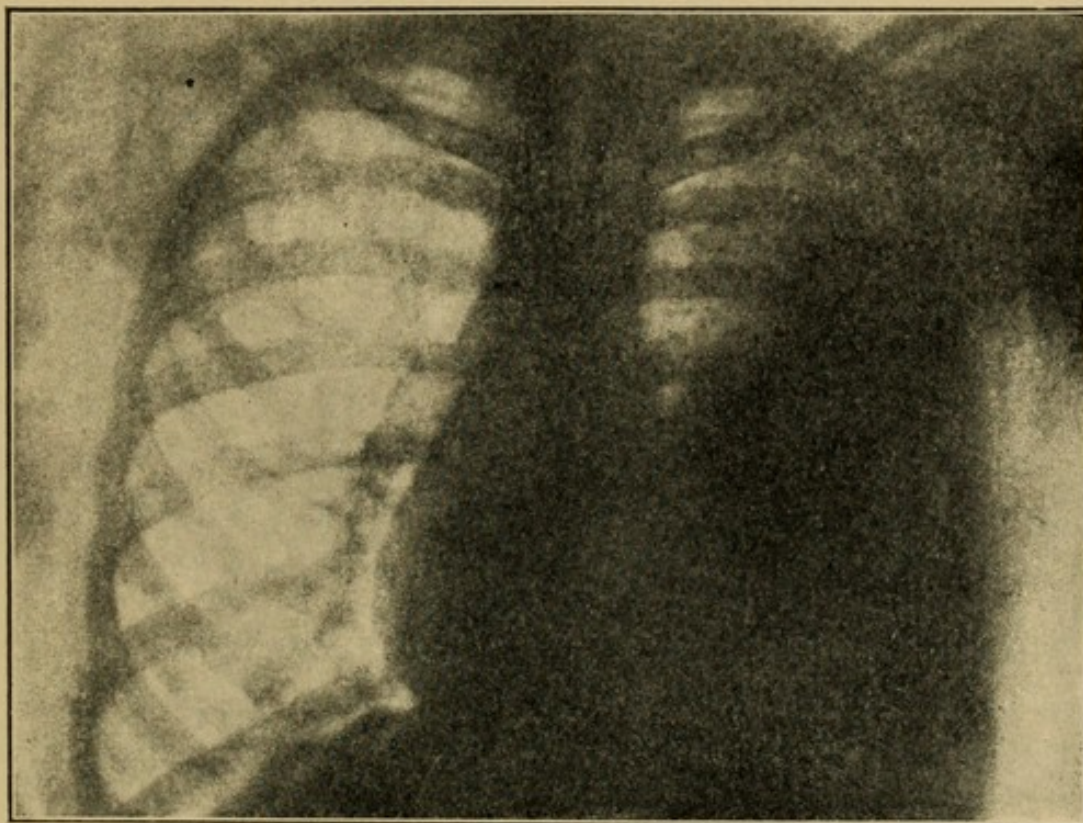


FIG. 141.—Left Pleural Effusion. Note that the surface of the fluid slopes outward and upward from the median line. (From v. Ziemssen's Atlas.)

The position of the effusion depends only in part upon the influence of gravity, and is greatly influenced by capillarity and the degree of retraction of the lungs. Consequently the surface of the fluid is hardly ever horizontal except in very large accumula-

tions. With the patient in an upright position it usually reaches a higher level in the axilla than in the back (see Fig. 141). Near the spine and near the sternum (in right-sided effusions) the line corresponding to the level of the fluid may rise sharply.

The S-curve of Ellis, as worked out so elaborately by Garland, varies still further the uneven line which corresponds to the sur-

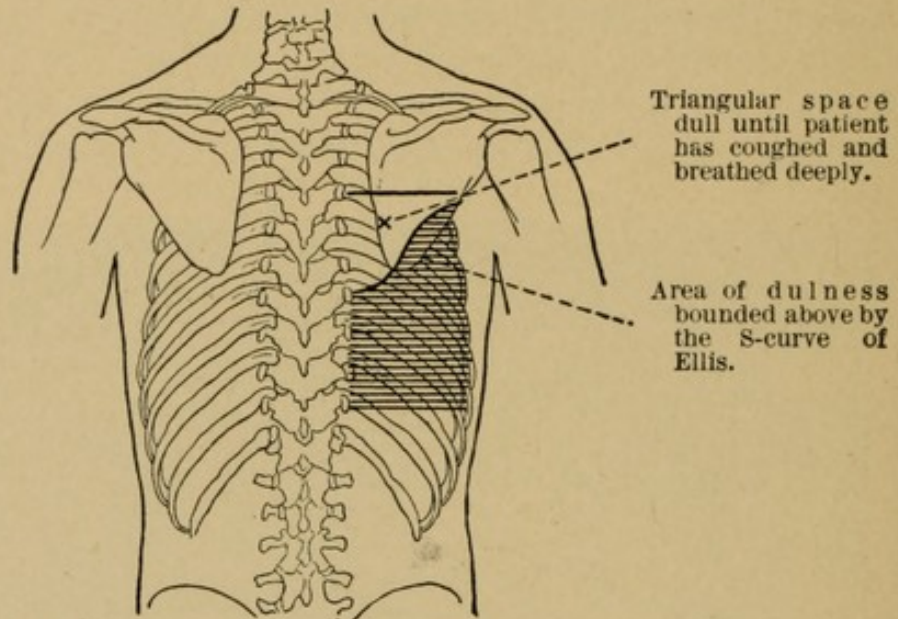


FIG. 142.—The S-Curve of Ellis.

face of the fluid (see Fig. 142). This curve can be obtained only after the patient has, by cough and forced breathing, expanded the lung as fully as possible.

All these curves are to be found with the patient in the upright position. None of them has any considerable diagnostic importance, and the chief point to be remembered is that the upper surface of the fluid, not being settled by gravity alone, is hardly ever horizontal.

With change in the position of the patient the level of the fluid sometimes changes very slowly and irregularly, and sometimes does not change at all. If, for purposes of thorough examination, we raise to a sitting posture a patient who has been for some days or weeks in bed, we should never begin the examination at once, since

it may take some minutes for the lungs and the fluid to accommodate themselves to the new position. It is well also to get the patient to cough and to take a number of full breaths before the examination is begun.

To test the mobility of the fluid with change of the patient's position, mark out the upper limit of the dulness in the back with the patient in the upright position. Then let the patient lie face downward upon a couch, and, after waiting a few minutes, percuss the previously dull area. It may be found to have become resonant.¹

When the fluid is absorbed or removed by tapping, one would expect an immediate return of the percussion resonance. But in fact the resonance returns very slowly and is wholly unreliable as a test of the amount of absorption which has occurred. Thickened pleura and atelectatic lung may abolish resonance long after the fluid is all gone. We depend here far more upon the evidence obtained by auscultation and palpation and on the general condition of the patient.

To determine the returning elasticity of the lung and the degree of movability of its lower border, percussion is very useful during the stage of absorption. After percussing out the lower border of pulmonary resonance in the back, the patient is directed to take a long breath and hold it. If the lung expands, the area of percussion resonance will increase downward.

Percussion aids us in determining whether neighboring organs are displaced by the pressure of the accumulated fluid. The liver is often pushed down, the spleen *very* rarely. *Dislocation of the heart* is one of the most important of all the signs of pleural effusion, and is often the crucial point in differential diagnosis. It is a very striking and at first surprising fact that a left-sided effusion displaces the heart far more than a right-sided effusion of the same

¹ This test, however, is somewhat fallacious and of very little diagnostic value, since the lungs tend to swing up toward the back when the patient lies prone, *even when no fluid is present*, and increase of resonance in the back with this change of position might, therefore, occur when the dulness was due to thickened pleura and not to fluid.

size. Small or moderate right-sided effusions often do not displace the heart at all.

With left-sided effusions, unless very small, we find the area of cardiac dulness shifted toward the right and often projecting beyond the right edge of the sternum (see Fig. 141). (Inspection and palpation often give us even more valuable information on this point. See below, p. 289.) We must be careful to distinguish such an area of dulness at the right sternal margin from that which may be produced in right-sided effusions by the fluid itself (see above).

As mentioned above, a right pleural effusion may very early show itself as an area of dulness along the right sternal margin. Light percussion will usually demonstrate that this dulness is continuous with a narrow strip of flatness at the base of the axilla (ninth and tenth ribs). Such an effusion is late in creeping up the axilla. It appears first and disappears first along the right margin of the sternum.

On the sound side the percussion resonance is often increased, owing to compensatory hypertrophy of the sound lung; the diaphragm is pushed down and the borders of the heart or of the liver may be encroached upon. When the hyper-resonance of the sound side is present, it should warn us to percuss lightly over the effusion, else we may bring out the resonance of the distended lung.

Summary of Percussion Signs.—(1) Flatness corresponding roughly to the position of the fluid.

(2) Tympany above the level of the fluid over the condensed lung.

(3) The level of the fluid is seldom quite horizontal.

(4) Shifting of the fluid with change of position is rare, slow, and has little or no importance in diagnosis.

Exceptions and Possible Errors.—(a) Great muscular pain and spasm may produce an area of dulness which simulates that of pleural effusions, especially as the auscultatory signs may be equally misleading. A hypodermic of morphine will dispel the dulness along with the pain if it is due to muscular cramp.

(b) If the lung on the affected side fails to retract (owing to

emphysema or adhesions to the chest wall), the area of dulness and its intensity will be much diminished.

(c) It must be remembered that dulness in Traube's space may be due to solidification of the lung, to *situs inversus*, to tumors, or to overfilling of the stomach and intestine with food, as well as to pleural effusion; also that the size of the tympanitic space varies greatly in health.

(d) Rarely percussion may be tympanitic over an effusion at the left base owing to distention of the stomach or colon.

(e) The diagnosis between fluid and thickened pleura will be considered later.

Auscultation.

The auscultatory phenomena vary greatly in different cases, and in the same case at different times, because the essential conditions are subject to similar variations. *Whatever sounds are produced in the lungs or in the bronchi may be heard over the fluid unless interfered with by inflammatory thickening of the costal pleura. Fluid transmits sounds well*, but there may be no breath sounds produced and hence none audible over the fluid. Or tubular sounds only may be produced because only the bronchi remain open, the rest of the lung being collapsed.

Or again, if râles or friction sounds are produced in the lung, they, too, may be transmitted to the fluid and may (alas!) deter the timid "observer" from tapping.

In about two-thirds of all large effusions *no* breathing at all is audible over the area of flatness on percussion. In the remaining third, and especially in children, tubular breathing, sometimes feeble, sometimes very intense, is to be heard.

In moderate effusions there are often three zones in the back. At the bottom we hear nothing, in the middle zone distant bronchial or broncho-vesicular breathing, while at the summit of the chest the breathing is normal.

The *voice sounds* correspond. When breath sounds are absent, the voice sounds are likewise absent. When the breathing is tubu-

lar, the voice, and especially the whisper, is also tubular and intensified. That is, *whenever the bronchi are open, the lung retracted, and the chest walls thin, the breathing, voice, and whisper will correspond to the tracheal and bronchial sounds.* Since children have especially thin chest walls, these bronchial sounds are especially frequent and intense in children.¹

Near the angle of the scapula and in a corresponding position in front, the sound of the spoken voice may have a peculiar high-pitched, nasal twang, to which the term egophony is applied. This sign has no importance in diagnosis, since it is not constant, and not peculiar to fluid accumulations.

Râles are rarely produced in the retracted lung, and so are rarely to be heard over the fluid.

All these sounds may be diminished or abolished if the costal pleura is greatly thickened.

The influence of cough upon the lung, and so upon the sounds produced in it and transmitted through the fluid, may be very great and very puzzling. Râles may appear or disappear, breathing change in quality or intensity, and in the differential diagnosis of difficult cases the patient should always be made to cough and then breathe deeply before the examination is completed.

In very large effusions, when only the primary bronchi are open, there may be signs like those of pulmonary cavity at the site of the bronchi in front or behind (amphoric breathing, large metallic râles, etc.). Over the sound lung the breathing is exaggerated and extends unusually far down in the back and axilla, owing to hypertrophy of the lung.

The heart sounds may be absent at the apex owing to dislocation of the heart. In left-sided effusions the apex sounds are often loudest near the ensiform cartilage or beyond the right margin of the sternum. Right-sided effusions have much less effect upon the heart, but occasionally we find the heart sounds loudest at the left of the nipple or in the axilla.

Since many cases of pleural effusion are due to tuberculosis, we

¹ Bacelli's theory—that the whispered voice is conducted through serum but not through pus—is not borne out by facts.

should never omit to search for evidences of this disease at the apex of the lung on the *sound* side, since experience has shown that phthisis is more apt to begin here than on the side of the effusion.

Summary of Auscultatory Signs.

(1) In most cases voice and breath sounds are absent or very feeble over the area occupied by the fluid.

(2) In a minority of the cases the breathing and voice sounds may be tubular and intensified, especially in children.

(3) Over the condensed lung at the summit of the chest the breathing is bronchial or broncho-vesicular, according to the degree of condensation. If the amount of fluid is small, the layer of condensed lung occupies the middle zone of the chest and the breathing is normal at the top of the chest.

(4) Râles and friction sounds are rarely heard over fluid.

(5) On the sound side the breathing is exaggerated.

(6) The heart sounds may be absent at the apex and present in the left axilla or to the right of the sternum owing to dislocation of the heart.

Inspection and Palpation.

The most important information given us by inspection and palpation relates to the displacement of various organs by the pressure of the accumulated fluid. In left-sided pleuritic effusions the heart is usually displaced considerably toward the right, even when the level of the fluid reaches no higher than the sixth rib in the nipple line. The apex impulse is to be seen and felt to the right of the sternum, somewhere between the third and the seventh rib, when a large amount of fluid is present. With smaller effusions one may find the apex beat lifting the sternum or close to its left border. The position of the heart may be confirmed by percussion.

The spleen is scarcely ever displaced.

Right-sided effusions are far less likely to displace the heart, and it is only when a large amount of fluid is present that the apex of the heart is pushed outward beyond the nipple. Moderate right-sided effusions often produce no dislocation of the heart whatever. The liver is often considerably pushed down by a right-sided pleu-

ritic effusion, and its edge may be palpable several inches below the costal margin. Its upper margin cannot be determined by percussion, as it merges into the flatness produced by the fluid accumulation above it.

Tactile fremitus is almost invariably absent or greatly diminished over the areas corresponding to the fluid; just above the level of the fluid it is often increased.

Occasionally a slight fulness of the affected side may be recognized by inspection, and the interspaces may be less readily visible than upon the sound side. Bulging of the interspaces I have never observed. When the accumulation of fluid is large the respiratory movements upon the affected side are somewhat diminished,¹ the shoulder is raised, and the spine curved toward the affected side. The diaphragm is depressed, and Litten's sign therefore absent.

There are no reliable means for distinguishing purulent from serous effusions. The whispered voice may be transmitted through either pus or serum. But we know that in children two-thirds of all effusions are purulent, while in adults three-fourths of them are serous.

Physical Signs During Absorption of Pleural Effusions.

When the fluid begins to disappear, either spontaneously or as a result of treatment, the dulness very gradually disappears and the breath sounds, voice sounds, and fremitus reappear. In case the heart has been dislocated, its return to its normal position is often much slower than one would anticipate, and indeed all the physical signs are disappointingly slow to clear up even after tapping. Pleural friction appears when the roughened pleural surfaces, which have been held apart by the fluid, are allowed by the disappearance of the latter to come into apposition again. Owing to pulmonary atelectasis and permanent thickening of the pleura, considerable dulness often remains for weeks after the fluid has been absorbed.

¹ I have purposely made but little of the changes in the shape of the chest produced by pleuritic effusions, as it has seemed to me that by far too much stress has usually been laid upon such signs.

(c) PLEURAL THICKENING.

In persons who have previously suffered from pleurisy with effusion, and in many who have never to their knowledge had any such trouble, a considerable thickening of the pleural membrane with adhesion of the costal and visceral layers may be manifested by the following signs:

- (1) Dulness on percussion, sometimes slight, sometimes marked.
- (2) Diminished vesicular respiration.
- (3) Diminished voice sounds and tactile fremitus.
- (4) Absence of Litten's phenomenon and diminution in the normal respiratory excursion of the chest.

These signs are most apt to be found at the base of the lung behind and in the axilla. Occasionally a similar thickening may be demonstrated throughout the whole extent of the pleura, and the lung failing to expand, the chest may fall in as a result of atmospheric pressure (see Fig. 20).

The ribs approximate and may overlap, the spine becomes curved, the shoulder lowered, the scapula prominent, and the whole side shrunk. The heart may be drawn over toward the affected side.

In the diagnosis of pleural thickening Rosenbach's "palpatory puncture" is sometimes our only resource. Under antiseptic precautions a hollow needle is pushed between the ribs and into the pleural cavity. As the needle forces its way through the tough fibrous, or perhaps calcified, pleura, the degree and kind of resistance are very enlightening. Again, the amount of mobility of the point after the chest wall has been pierced tells us whether the needle is free in a cavity, entangled in a nest of adhesions, or fixed in a solid "carnified" lung. There is no danger if the needle is sterile.

ENCAPSULATED PLEURAL EFFUSION.

Small accumulations of serum or pus may be walled off by adhesions so that the fluid does not gravitate to the lowest part of the pleural cavity or spread itself laterally as it would if free.

Such localized effusions are most apt to be found in the lower axillary regions or behind—sometimes between the base of the lung and the diaphragm, and more rarely between the lobes of one of the lungs or higher up. I have twice seen an encapsulated purulent effusion so close to the left margin of the heart that the diagnosis of pericardial effusion was made.

The diagnosis of encapsulated pleural effusion is a difficult one and oftentimes cannot be made except by puncture. The signs are those of fluid in the pleura, but anomalously placed. Even puncture may fail to clear up the difficulty, since the needle may pass entirely through the pouch of fluid and into some structure behind so that no fluid is obtained.

PULSATING PLEURISY (EMPHYEMA NECESSITATIS).

Under conditions not altogether understood the movements transmitted by the heart to a pleural effusion (usually purulent) may be visible externally as a circumscribed pulsating swelling near the precordial region, or as a diffuse undulation of a considerable portion of the chest wall. Sometimes this pulsation is visible because the fluid has worked its way out through the thoracic wall and is covered only by the skin and subcutaneous tissues, but occasionally pulsation in a pleural effusion becomes visible, although no such perforation of the chest wall has occurred.

The condition is a rare one, and is of importance only because it may be mistaken for an aneurism, from which, however, it should be readily distinguished by the absence of a palpable thrill or diastolic shock and by the evidence of fluid in the pleura.

DIFFERENTIAL DIAGNOSIS OF PLEURITIC EFFUSION.

The following conditions are not infrequently mistaken for pleuritic effusion:

- (1) Croupous pneumonia with occlusion of the bronchi.
- (2) Pleural thickening, with pulmonary atelectasis.
- (3) Subdiaphragmatic abscess or abscess of the liver.

In croupous pneumonia with plugging of the bronchi one may

have present all the physical signs of pleuritic effusion *except displacement of the neighboring organs*. The presence or absence of such displacement, together with the history, symptoms, and course of the case, is therefore our mainstay in distinguishing the two diseases.

From *ordinary* croupous pneumonia (without occlusion of the bronchi) pleuritic effusion differs in that it produces a greater degree of dulness and a diminution of the spoken voice sounds and tactile fremitus. Bronchial breathing and bronchial whisper may be heard either over solid lung or over fluid accumulation, although the bronchial sounds are usually feeble and distant in the latter condition. The displacement of the neighboring organs is of importance here as in all diagnoses in which pleuritic effusion is a possibility. In pleuritic effusion we can sometimes determine that the line marking the upper limit of dulness shifts with change of the patient's position. This is, of course, impossible in pneumonia. A few hard coughs may open up an occluded bronchus and so clear up the diagnosis at once. In doubtful cases the patient should always be made to cough and breathe deeply before the examination is finished.

It should always be remembered that one may have both pneumonia and pleuritic effusion at the same time, and that pneumonia is often followed by a purulent effusion. In children the bronchi are especially prone to become occluded even as a result of a simple bronchitis, and we must then differentiate between atelectasis and effusion—in the main by the use of the criteria just described.

(2) It is sometimes almost impossible to distinguish small fluid accumulations in the pleural cavity from pleural thickening with pulmonary atelectasis. In both conditions one finds dulness, diminution of the voice sounds, respiration, and tactile fremitus, and absence of Litten's phenomenon, but the tactile fremitus is usually more diminished when fluid is present than in simple pleural thickening and atelectasis. An area of dulness which shifts with change of position points to pleuritic effusion. The presence of friction sounds over the suspected area speaks strongly in favor of pleural thickening, but it is possible to hear friction sounds over fluid,

probably because they are conducted from a point higher up in the chest at which no fluid is present. In doubtful cases the diagnosis can and should be cleared up by *puncture*.

(3) In two cases I have known enlargement of the liver due to multiple abscesses to be mistaken for empyema. In both conditions, one finds in the right back dulness on percussion as high as mid-scapula, with absence of voice sounds, breath sounds, and fremitus. These conditions are due in one case to the presence of fluid between the lung and the chest wall, and in the other case to

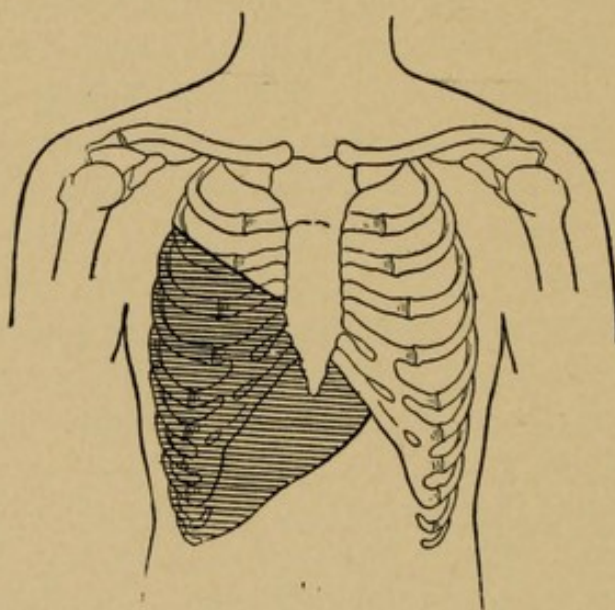


FIG. 143.—Area of Dulness in Solitary (tropical) Abscess of the Liver.

the liver which pushes up the lung together with the diaphragm. By physical signs alone I do not see how this diagnosis is possible, though Litten's sign may be of use, since the shadow is absent in empyema and sometimes present in moderate-sized subdiaphragmatic accumulations. Some of the symptoms, such as chills, sweating, and irregular fever, are common to both conditions. A careful consideration of the history and the associated signs and symptoms may help us to decide.

Large solitary abscess of the liver, occurring as it almost invariably does in the posterior portion of the right lobe, produces an area of flatness on percussion, which rises to a much higher level in

the axilla and back than in front or near the sternum (see Fig. 143), and may be in this way distinguished from empyema; but when the liver contains many small abscesses, as in suppurative cholangitis, this peculiar line of dulness is not present.

(*d*) Rare diseases, such as cancer or hydatid of the lung, may be mistaken for pleuritic effusion. The history of the case and the results of exploratory puncture usually clear up the difficulty.

CHAPTER XIV.

ABSCCESS, GANGRENE, AND CANCER OF THE LUNG, PULMONARY ATELECTASIS, ŒDEMA, AND HYPO- STATIC CONGESTION.

ABSCCESS AND GANGRENE OF THE LUNG.

I CONSIDER these two affections together because the physical signs, exclusive of the sputa, do not differ materially in the two affections. In some cases there may be no physical signs at all, and the diagnosis is made from the character of sputa and from a knowledge of the etiology and symptomatology of the case. In other cases we find nothing more than a patch of coarse râles or a small area of solidification, over which distant bronchial breathing, with increased voice sound and fremitus, may be appreciated. Rarely there may be slight dulness on percussion, but as a rule the area is not sufficiently large or sufficiently superficial to produce this. One may find the signs of cavity (amphoric breathing, cracked-pot resonance, and gurgling râles), but this is unusual.

Gangrene of the lung is not a common disease. The diagnosis usually rests altogether upon the smell and appearance of the sputa. In fetid bronchitis one may have sputa of equal foulness, but the odor is different. The finding of elastic tissue in the sputa proves the existence of something more than bronchitis.

Pulmonary abscess, which, like gangrene, is a rare affection, is often simulated by the breaking of an empyema into the lung and the emptying of the pus through a bronchus. Large quantities of pus are expectorated in such a condition, and abscess of the lung is suggested, but the other physical signs are those of empyema and should be easily recognized as such. The finding of *elastic fibres* is the crucial point in the diagnosis of intrapulmonary abscess,

whether due to the tubercle bacillus or to other organisms. Tuberculous abscess (cavity) is usually near the summit of the lung, and other varieties of abscess are near the base, but often there are no physical signs by which we can distinctly localize the process.

MALIGNANT DISEASE OF THE LUNG, PLEURA, OR CHEST WALL.

In its earlier stages this affection is often mistaken for empyema or serous effusion in the pleural cavity, and indeed the physical signs may be in part due to an accumulation of fluid secondary to the malignant growth within the lung. The rapid emaciation of the patient and the presence of a dark-brown bloody fluid in the pleural cavity, as determined by puncture, make us suspect malignant disease, but in sarcoma there is usually no emaciation until late in the course of the disease. The sputa rarely contain fragments of tissue whose structure can be recognized as characteristic of malignant disease. Secondary deposits in the supraclavicular glands may suggest the diagnosis.

The thorax is usually somewhat asymmetrical. The affected side may be either contracted or distended according to the nature of the malignant growth within; occasionally it is not deformed at all. When the growth attacks only the lung tissue itself, leaving the bronchi and mediastinum free, we get signs like those of pleural effusion (flatness, absent breathing, voice sounds, and tactile fremitus).

If the disease begins in the bronchi, we may have a noisy dyspnoea from stenosis of a bronchus, and a weakening of the respiratory sounds normally to be heard over the trachea in front has several times been noted. Percussion dullness, if present, is usually over the upper portions of the chest, and may disappear and reappear or skip from place to place in a very irregular and confusing way.

Signs and symptoms of pressure in the mediastinum due to secondary involvement of the peribronchial glands may be present and may simulate aneurism, or the growth may press directly upon the brachial plexus, producing pain in the arm.

ATELECTASIS.

(a) Areas of atelectasis or collapse of pulmonary tissue are often present in connection with various pathological processes in the lung (such as tuberculosis or lobular pneumonia), but are usually too small to give rise to any characteristic physical signs; nevertheless

(b) In most normal individuals a certain degree of atelectasis of the margins of the lungs may be demonstrated in the following way: The position of the margins of the lungs in the axillæ, in the back, or in the precordial region are marked out by percussion at the end of expiration. The patient is then directed to take ten full breaths, and the pulmonary outlines at the end of expiration are then percussed out a second time. The pulmonary resonance will now be found to extend nearly an inch beyond its former limits, owing to the distention of previously collapsed air vesicles.

If one auscults the suspected areas during the deep breaths which are used to dispel the atelectasis, very fine râles are often to be heard at the end of expiration, disappearing after a few breaths in most cases, but sometimes audible as long as we choose to listen to them. These sounds, to which Abrams has given the name of "atelectatic crepitation," are in my experience especially frequent at the base of either axilla. The same writer has noticed an opacity to the *x*-rays over such atelectatic areas.

Forceful percussion may be sufficient to distend small areas of collapsed lung, or at any rate to dispel the dulness previously present (see above, p. 82, the lung reflex).

(c) When one of the large bronchi is compressed (as by an aneurism) or occluded by a foreign body, collapse of the corresponding area of lung may be shown by diminished motion of the affected side, dulness on percussion, and absence of breathing, voice sounds, and tactile fremitus.

In new-born babies whose lungs do not fully expand at the time of birth, similar physical signs are present over the non-expanded lobes. The right lung is especially apt to be affected.

In the differential diagnosis of extensive pulmonary collapse,

the etiology, the suddenness of their onset, the absence of fever and of displacement of neighboring organs enable us to exclude pneumonia and pleuritic effusion. In distinguishing small areas of solidification from similar areas of atelectasis, Abrams finds the "lung-reflex" (see page 82) of value. Atelectatic areas expand if the skin overlying them is irritated. Solidified areas show no change.

ŒDEMA OF THE LUNGS.

In cardiac or renal disease one can often demonstrate that the lungs have been invaded by transuded serum as a part of the general dropsy. More rarely pulmonary œdema exists without much evidence of œdema in other organs or tissues.

The only physical sign characteristic of this condition is the presence of fine moist râles in the dependent portions of the lungs; that is, throughout their posterior surfaces when the patient has been for some time in a recumbent position; or over the lower portions of the axillæ and the back if the patient has not taken to his bed.

The râles are always bilateral (unless the patient has been lying for a long time on one side), and the individual bubbles appear to be all of the same size, or nearly so, differing in this respect from those to be heard in bronchitis. No squeaking or groaning sounds are to be heard. The respiratory murmur is usually somewhat diminished in intensity.

Dulness on percussion and modification of voice sounds are not present, unless hydrothorax or hypostatic pneumonia complicate the œdema.

HYPOSTATIC PNEUMONIA.

In long, debilitating illness, such as typhoid fever, the alveoli of the dependent portions of the lungs may become so engorged with blood and alveolar cells as to be practically solidified. Under these conditions examination of the posterior portions of the lungs shows usually:

(a) Slight dulness on percussion reaching usually from the

base to a point about one-third way up the scapula. At the very base the dulness is less marked and becomes mixed with a shade of tympany.

(b) Feeble or absent tactile fremitus.

(c) Diminished or suppressed breathing and voice sounds.

The right lung is apt to be more extensively affected than the left.

Occasionally the breathing is tubular and the voice sounds are increased, making the physical signs identical with those of croupous pneumonia, but as a rule the bronchi are as much engorged as the alveoli to which they lead, and hence no breath sounds are produced.

Râles of œdema or of bronchitis may be present in the adjacent parts of the lungs. The fact that the dulness is less marked at the base of the lung than higher up helps to distinguish the condition from hydrothorax.

The diagnosis is usually easy, owing to the presence of the underlying disease. Fever, pain, and cough such as characterize croupous pneumonia are usually absent.

APPENDICES.

APPENDIX A.

DISEASES OF THE MEDIASTINUM

I. MEDIASTINAL TUMORS.

NEW growths of the mediastinal glands¹ usually manifest their presence by the following symptoms and signs:

- (1) Cachexia and substernal pain.
- (2) Evidence of pressure against:—
 - (a) The *gullet*.
 - (b) The *windpipe* or primary *bronchi*.
 - (c) The large *venous trunks*.
 - (d) *Nerves* which pass through the mediastinum.
 - (e) The subclavian arteries.
 - (f) The heart.
 - (g) The ribs, clavicle, or sternum.
- (3) Secondary deposits in the cervical or axillary glands.

(a) By pressure on the gullet swallowing may be rendered difficult or impossible (dysphagia).

(b) By pressure on the windpipe may be produced displacement of the latter to one side, or fixation so that it cannot be moved in any direction. The larynx may be drawn down into a noticeably low position, and the laryngoscope may demonstrate that the tracheal wall is bulged inward by the pressure of the new growth upon it.

Dyspnœa, either inspiratory or expiratory, or both, and often

¹ Tuberculous glands not being here included.

of noisy strident type, may result from stenosis of the trachea or primary bronchi. Owing to pressure on one of the large bronchi, the resonance and breath sounds and fremitus may be diminished over the corresponding lung, in which finally abscess or gangrene may develop, owing to the retention and decomposition of the bronchial secretions.

(*c*) If the pulmonary veins are pressed upon, a systolic murmur may be audible in the left back, and congestion of the lungs may ensue.

Pressure on the innominate and subclavian veins produces cyanosis or œdema of the head, neck, shoulder, and arm, while the superficial veins of the chest may become enlarged and prominent owing to an attempt at collateral circulation, especially if the vena cava superior is pressed upon. Fluid may accumulate in one or both pleural cavities if the vena azygos or thoracic duct is involved.

(*d*) Aphonia or hoarseness points to pressure on the recurrent laryngeal nerve, and on laryngoscopic examination one vocal cord may be found in the cadaveric position. Inequality of the pupils, due to pressure on the sympathetic nerves, is not uncommon, and severe pain along the distribution of the intercostals or running down the arm indicates that the spinal ganglia or brachial plexus are pressed upon. Much rarer are symptoms of pressure on the vagus (slowing or quickening of the heart) and on the phrenic nerve (hiccup, unilateral spasm, or paralysis of the diaphragm).

(*e*) Weakening or delay in one radial pulse may be due to pressure on the subclavian artery.

(*f*) Occasionally the heart itself may be pushed out of place.

(*g*) Pressure of the new growth against the bones of the chest may give rise to an area of percussion dulness under or near the manubrium, which, however, is not likely to show itself until late in the course of the disease when the new growth has reached a considerable size. In many cases there is tympanitic resonance instead of dulness over the affected area. The ribs or sternum may be pushed forward, but this is not usually the case. Occasionally the new growth, if very vascular, may pulsate like an aneurism or

transmit the pulsations of the heart to the chest wall, and a systolic murmur may be heard over the pulsating area, so that the resemblance to aneurism is increased.

Differential Diagnosis.

Mediastinal tumors may be mistaken for

- (1) Aneurism of the aortic arch.
- (2) Syphilitic stenosis of a bronchus.
- (3) Phthisis.

Aneurism may be confounded with mediastinal new growths even by the most competent observers. Tactile thrill, diastolic shock, and tracheal tugging, if present, should suggest aneurism. If these signs are absent, aneurism may still be present but cannot be surely diagnosed. The degree of anæmia and emaciation is usually greater in malignant disease than in aneurism, but this is not always the case. The presence of secondary nodules in the neck or armpit speaks strongly in favor of new growth.

Stenosis of a bronchus, due to syphilis and giving rise to dyspnoea, cough, stridor, pulmonary atelectasis, may be very difficult to distinguish from mediastinal growth, but the degree of anæmia and emaciation is usually less in syphilis, and the beneficial results of antisiphilitic treatment may render the diagnosis possible, especially if there is evidence of syphilis elsewhere in the body or in the history of the case.

Phthisis may be suggested by the weakness, emaciation, and persistent cough produced by mediastinal growths, but should be easily excluded by the examination of the lungs and sputa.

II. MEDIASTITIS.

The acute suppurative forms of this rare disease do not give rise to any characteristic physical signs in the chest.

The evidences of chronic fibrous mediastinitis have been already sufficiently considered in connection with adhesive pericarditis.

III. TUBERCULOSIS OF THE MEDIASTINAL GLANDS.

Probably every case of pulmonary tuberculosis is preceded or accompanied by tuberculosis of the bronchial lymph glands, and in numberless cases the tuberculous process never gets beyond these glands but is choked off there. In post-mortem examinations of children, no matter what the cause of death, it is exceptional not to find the bronchial glands tuberculous.

Nevertheless the disease can but rarely be recognized during life. We may suspect it if, in a child showing tuberculous cervical glands or phthisis, we find evidence of pressure upon the right bronchus, increased tactile fremitus above the manubrium, lateral displacement of the trachea, or weakening of the pulse during inspiration. If a bronchus is compressed, the resonance, tactile fremitus, and breath sounds are diminished over the corresponding lung. Wiederhofer lays stress upon an increase in the intensity of the expiratory murmur over the situation of the left primary bronchus.

APPENDIX B.

ACUTE ENDOCARDITIS.

Whether the disease be of the benign or of the malignant (septic) type, the results of physical examination of the heart are usually very equivocal. We may guess that endocarditis is present owing to the presence of a cause (rheumatism), of a fever not otherwise explained, of a rapid irregular pulse of low tension, but the physical signs over the heart will not usually assist our guess materially.

Murmurs are often present but have usually the characteristics of "functional" murmurs (systolic, limited, soft, without accentuation of the pulmonic second sound or cardiac enlargement). If we can observe the advent of a *diastolic* murmur in such a case, we may fairly attribute it to a fresh endocarditis of the aortic (very rarely of the pulmonic) valve, but if we have not had the oppor-

tunity to examine the heart previous to the onset of the present attack it is impossible to exclude a long-standing valvular lesion as the cause of the murmur.

If murmurs come and go from day to day, or suddenly increase in intensity, we may suspect an acute endocarditis, especially if a musical murmur is present or if there be evidence of embolism.

Inspection, palpation, and percussion usually yield no signs of importance. There is no enlargement of the heart, no accentuation of the second sounds, and no evidence of stasis.

APPENDIX C.

PHYSICAL EXAMINATION OF THE CHEST IN INFANTS.

(1) Tactile fremitus and voice sounds can be investigated only in case the child cries or crows. The cry-sound is intensified over solidified areas and may or may not be lost over fluid accumulations.

(2) Percussion must be very delicately performed if we are to avoid setting the whole chest in vibration with every stroke. It is best to strike wholly with the finger, keeping the hand (as well as the wrist and arm) unmoved.

(3) In listening to an infant's lungs patience and concentration are essential. The child is apt to stop breathing when the examination begins, and we have to wait patiently to catch the long-delayed inspiration "on the wing," as it were, before the long expiratory wail begins. The inspiration, when it does come, is unusually intense owing to the thinness of the chest in infancy.

(4) Long flexible rubber tubes connecting the chest-piece of the stethoscope with the ear-pieces are very convenient when examining a wriggling child (see Fig. 51, p. 85), as they make it possible to hold the chest-piece in position despite the constant movements of the struggling sufferer.

(5) It is advisable to examine first the back while the child is held in the mother's arms with its back to the physician.

(6) Children almost always cry if made to lie down flat. If we wish to bring out the cry sound in order to test the vocal and tactile fremitus, this is a simple and humane method of producing it. If, on the other hand, peace is what we most desire, it is best to avoid putting the child in a recumbent position.

(7) There is no type of breathing peculiar to children or infants. Puerile breathing is simply vesicular breathing heard very distinctly on account of the thinness of the chest. If, in a healthy child, the expiratory murmur is prolonged and high-pitched, this is probably because the child blows out the breath forcibly in the effort to breathe deeply as it is told to do. A young infant never does this, and its breathing is like that of adults except that it is more rapid, more irregular, and better heard.

APPENDIX D.

RADIOSCOPY OF THE CHEST.

Radioscopy gives assistance in the diagnosis of diseases of the chest in two ways:

1. Through the use of the fluoroscopic screen.
2. Through the use of radiographs.

Those who are accustomed to the use of the fluoroscope gain far more information from it than from radiographs, but the record of the photographic plate is objective, permanent, and demonstrable, while the impressions gained from the fluoroscope are more apt to be modified by the personal equation.

For the present, therefore, we need both methods.

I shall not attempt to discuss the advantages of the various forms of apparatus used for producing Roentgen rays in a Crookes tube; the subject would carry me beyond my depth as well as beyond the limits of this book; but whatever form of instrument is used, the vacuum in the tube should be less perfect when we desire to use it for the chest than when searching for foreign bodies or studying fractures. We need a "low" or "soft" tube which gives

rays of a relatively slight degree of penetration. With high penetration rays the outlines of the solid organs are less distinct because the rays traverse the heart and liver almost as easily as they do the lungs. If the penetrating power is less, the rays are arrested by the solid organs, but not by the lungs, and hence the outlines of the former become visible.

I. The Use of the Fluoroscope.

1. It is advisable to remain in a dark room or to wear smoked glasses for a short time before attempting to use the fluoroscope. This applies especially to beginners. Skilled observers do not need such preparation of the retina, but many novices who complain at first that they can "see absolutely nothing" when they apply the fluoroscope to the chest, find their vision suddenly and permanently improved after fifteen minutes in a dark room. Practice increases our powers with the fluoroscope as much as it does with the microscope, and it is unreasonable to expect to see from the first all that an expert sees.

2. The patient should be placed at least two feet from the tube, else there is likely to be distortion and magnification of the shadows corresponding to the organs examined. The tube should be placed at such a height as to be opposite the most important object to be examined, and always in the median line.

3. Patients may be examined either in the upright position—the tube about two feet from the patient's back—the fluoroscope resting against the chest—or in the recumbent position, supported on a canvas cot with the tube underneath. I prefer the upright position. The patient's arms should always be extended forward so as to get the scapulæ out of the way.

4. To concentrate the light upon a spot of special interest, we may use a metal plate with a rectangular opening about two by three inches near one end. When this plate is held between the tube and the patient, so that the opening is opposite the spot to be examined, the rays pass through the opening, but are intercepted by the metal around it. The hand which holds this plate should be protected from the action of the rays.

5. To mark on the chest the outlines of the shadows seen with the fluoroscope, a pencil enclosed in a tube of brass is useful; the brass jacket makes the pencil visible and enables us to adjust its point to the outlines on the chest. An ordinary pencil is penetrated by the rays completely, and it is hard to draw with a pencil which we cannot see.

II. The Normal Fluoroscopic Picture (see Fig. 144).

The lungs appear as the lightest part of the field owing to the large amount of air they contain; at the end of full inspiration, they become still lighter. Against the light lung areas, the outlines of the ribs and of the vertebral column (with the sternum superimposed) are clearly visible. Less clear, but usually quite distinguishable, are the outlines of the heart and the upper border of the liver. A slight shadow (see Fig. 143) is often noticed just to the right and to the left of the heart in a position corresponding to the larger bronchi. The spleen is not usually to be made out clearly, but the upper surface of the diaphragm above it is generally visible. The contractions of the heart and the movements of the diaphragm are usually clear, and any restriction of the respiratory excursion on one side can be noted, though the fluoroscope has no advantages over the inspection of Litten's diaphragm shadow (see p. 23) for this purpose.

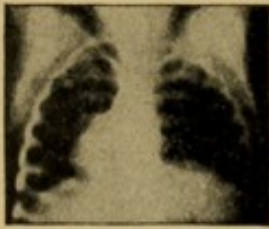
Abrams has noted that if the skin of the precordia is irritated by cold or pain, a reduction in the size of the heart occurs ("heart reflex") for a few seconds.

In children all these phenomena are especially clear, owing to the thinness of their chest walls and we note at once how much more horizontal the child's heart is than the adult's (see Fig. 144).

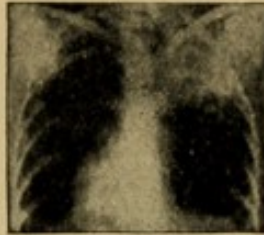
III. The Fluoroscope in Disease.

I shall mention first those diseases in which the fluoroscope furnishes us the most valuable information.

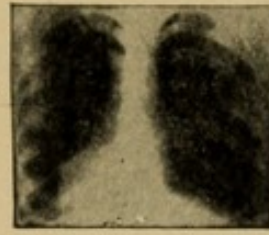
1. *Aneurism*.—Small aneurisms of the transverse or descending aorta may sometimes be recognized by the x -rays when no other



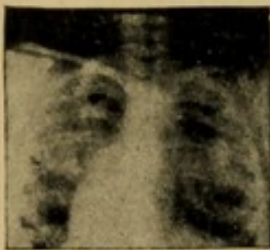
Chest of Healthy Boy aged nine years.



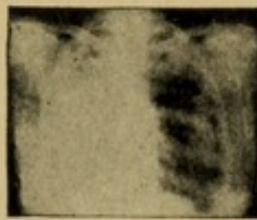
Incipient Phthisis at Right Apex.



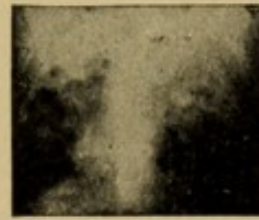Chest of Healthy Adult.



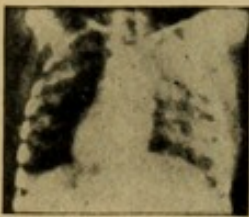
Advanced Phthisis (cavity?).



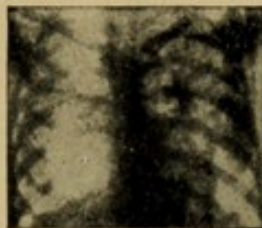Advanced Phthisis.



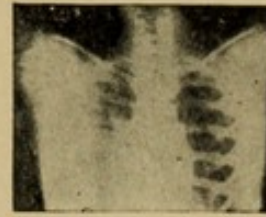
Bilateral Phthisis at Apices.



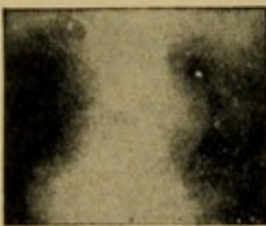Advanced Phthisis.



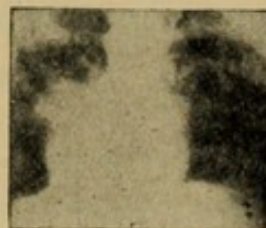
Advanced Phthisis.



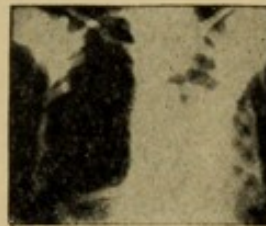Pulmonary Emphysema.



Aortic Aneurism.



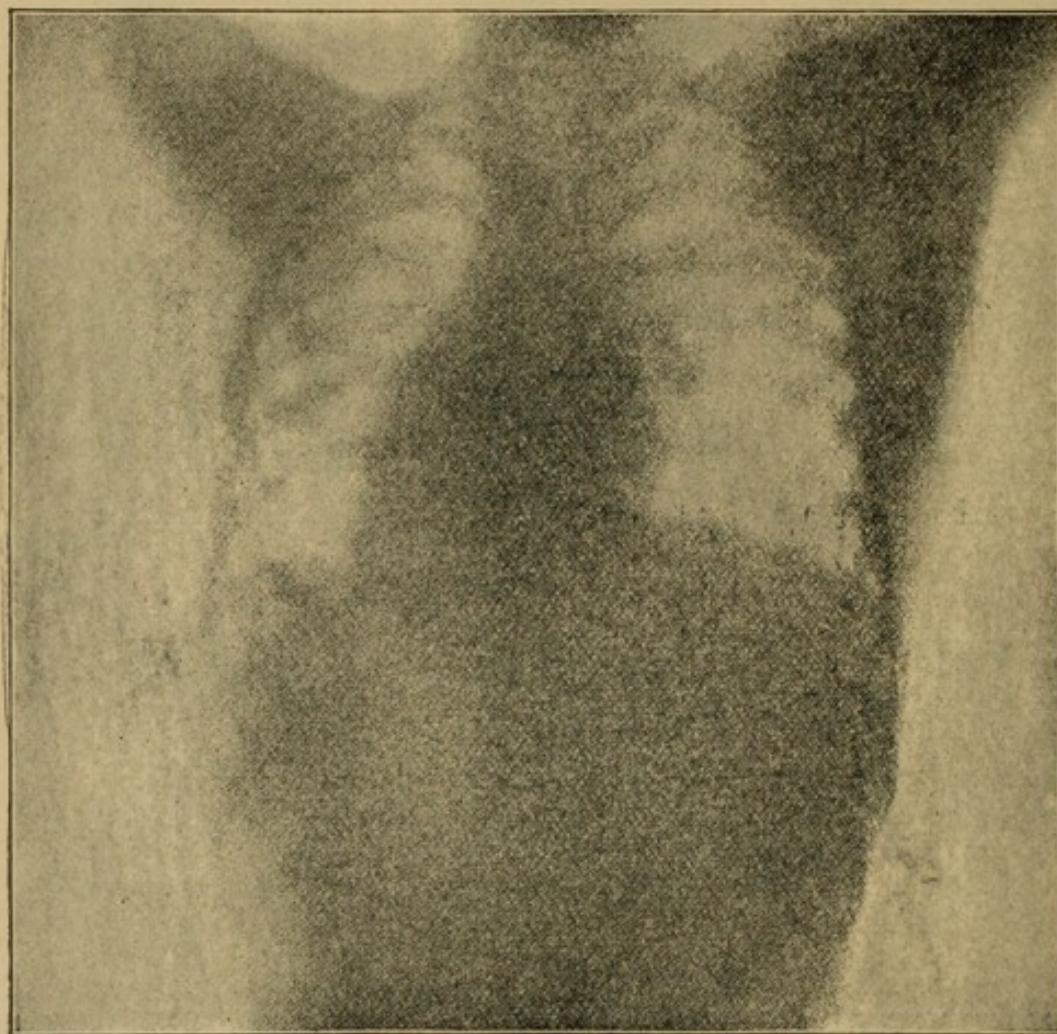
Aneurism of Left Auricle.



Fibroid Phthisis of Right Lung.
Heart drawn to the right.

FIG. 144.—Twelve Radiographs of the Chest, as Seen from Behind (after Walsham).

method of physical examination yields satisfactory evidence. An abnormal shadow appears at one side of the sternum (see Fig. 146) and may sometimes be seen to pulsate. In other cases the fluoroscopic evidence is not the only evidence, but tends to confirm or



Shadow corresponding to the position of primary bronchus (?).

FIG. 145.—Radiograph of a Case of Transposition of the Viscera. (After Gibson.)

dispel suspicions aroused by the ordinary methods of examination.

Aneurism of the heart itself is recognizable, according to F. H. Williams, by the fluoroscopic examination. No other method of examination gives us any evidence of such a lesion.

2. *Determination of the Cardiac Outlines in Patients with Emphysema and Fat Chest Walls.*—Emphysema spoils cardiac percus-

sion and interferes with inspection and palpation. But in fluoroscopic work emphysema is a boon and a blessing, for it renders the cardiac outlines more distinct than usual. Hence, for determining the size and position of the heart in such cases, the *x*-rays give genuine assistance, as they also do when mapping out the heart in women with large breasts and fat chest walls.

3. *Central Pneumonia*.—Williams and others have succeeded

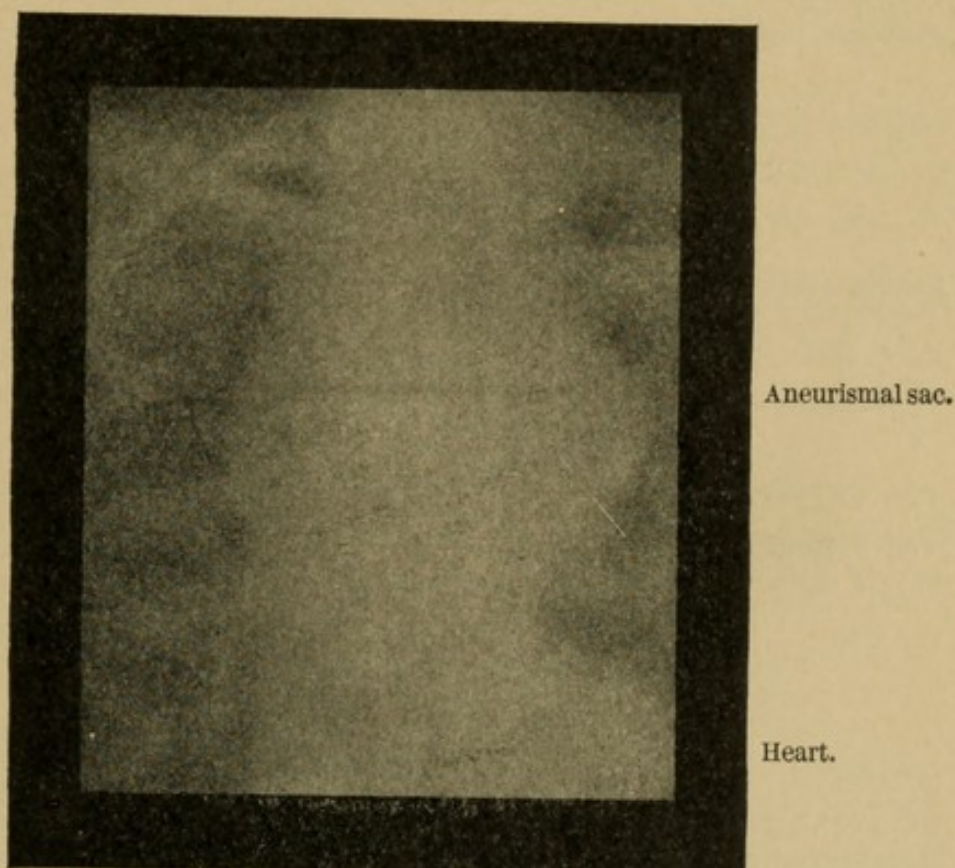


FIG. 146.—Front View of Thoracic Aneurism. The heart displaced downward.

in identifying foci of solidification beneath the surface of the lungs when no other physical signs could be obtained. It must be remembered, however, that congestion of the lung, oedema, atelectasis, and pleural thickening produce shadows similar to those of solidified lung.

4. *Tuberculosis*.—It is still a matter of doubt whether tuberculous foci can be recognized by the fluoroscope before the disease has

progressed sufficiently to produce localized râles, diminished breath sounds, or restriction of Litten's phrenic phenomenon.

Slight opacities have been noted in cases which later turned out to be tuberculosis, and which had not previously been diagnosed, but the shadows perceived by the fluoroscope are capable of many interpretations and correspond (as above said) to various pathological conditions. Old quiescent foci may appear like advancing le-

Aneurismal sac.

Heart.

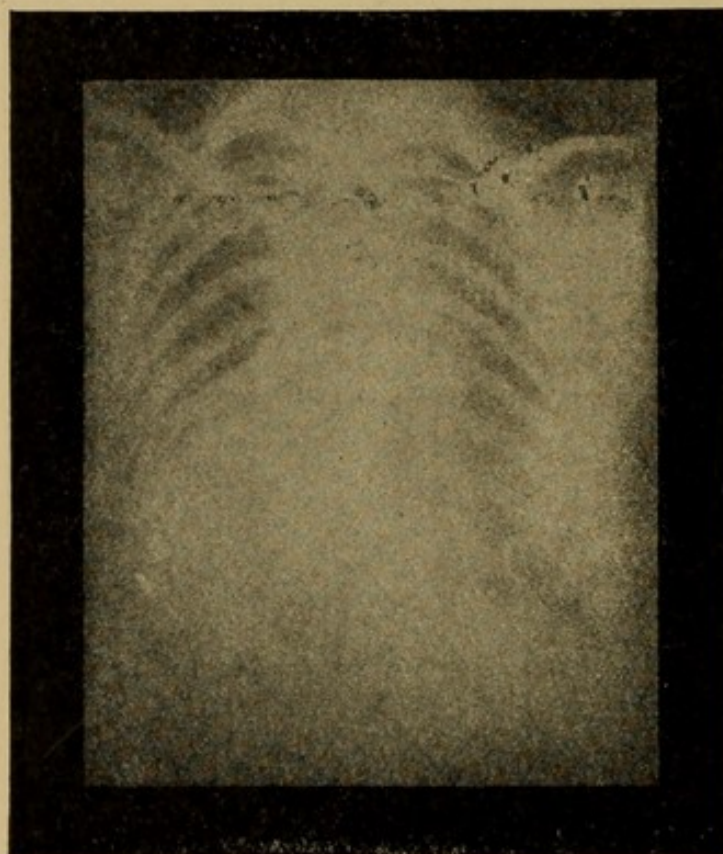

FIG. 147.—Aneurismal Sac Radiographed from Behind.

sions and thus lead to serious errors. We do not want to hurry a patient off to Colorado or Davos on account of the shadow thrown by a long-healed lesion. Further, in some cases of rheumatism, anæmia, debility, and convalescent typhoid, appearances very similar to those of tuberculosis may be found (Williams). Hence the interpretation of slight lung shadows in cases of suspected incipient phthisis is by no means easy.

Advanced phthisis renders the lungs relatively opaque to the Roentgen rays except where extensive excavation has occurred; here we see a light area in a dark background (see Fig. 144).

No satisfactory radiographs of cases of *incipient* phthisis have so far been published, so far as I am aware.

5. *Pleuritic Effusions*.—The displacement of the heart is sometimes better shown by the *x*-rays than by ordinary methods of examination, since the compensatory hypertrophy of the sound lung, which interferes with percussion and palpation of the heart, renders radioscopy easier.

The fluid exudate intercepts the rays perceptibly, and when the movements of the diaphragm are not abolished on the affected side, the line corresponding to the surface of the fluid can be seen to move up and down with respiration.

Small fluid accumulations flatten the normal curve of the upper surface of the diaphragm by filling up the chink between the inner surface of the chest in the axilla and the line of the diaphragm at that point.

6. *Emphysema*.—The lungs become unusually transparent and owing to the low position of the diaphragm the heart descends and assumes a very vertical position ("ptosis of the heart"); these points are very clearly seen with the fluoroscope.

Radiographs.

But little use has thus far been made of radiographs in studying diseases of the chest. The movements of the heart, of the chest walls, and of the diaphragm render all the outlines indistinct. For aneurisms, especially those containing a thick layer of clot, and for intrathoracic tumors, radiographs may be very useful, and bronchial lymph glands are sometimes rendered visible.

APPENDIX E.

THE SPHYGMOGRAPH.

This instrument consists of a system of levers by means of which the pulsations of the radial artery are transferred to a needle whose oscillations can be graphically recorded upon a piece of smoked paper. It is a very fascinating little toy, but in its present form is almost devoid of practical usefulness owing to the impossibility of eliminating the personal equation when using it. The size and, to a certain extent, the shape of the wave traced upon the smoked paper can be influenced at will by the amount of pressure with which the instrument is applied to the wrist. If an instrument is applied with a pressure of three ounces to the wrist of A, and then with the same pressure to the wrist of B, the force exerted upon the artery may be quite different in the two cases owing to the different shape of the wrist in the two individuals.

Almost any type of tracing can be obtained from a normal pulse by varying the pressure.

This objection is fatal to the use of the sphygmograph as an instrument of precision, and although it is capable of recording tiny secondary waves unpalpable by the fingers, it has yet to be shown that it reveals anything of practical diagnostic value which is not appreciated by skilled fingers. For these reasons I have given no account of the instrument in the body of this work.

INDEX.

- ABRAMS, 82
Abscess, pulmonary, 296
Adenitis, 41
Allbutt, 122, 182
Amphoric breathing, 107
Anatomy, regional, of the chest, 2
Aneurism, 226
 a cause of abnormal pulsations, 33
 thoracic, 33, 226
Aortic aneurism, 33, 226
 regurgitation, 175
 second sound, 125
 stenosis, 185
Apex beat, 26, 42
 beat, see also *Cardiac impulse*
 retraction, 31
Arrhythmia, 209
Arterial movements, 36
 murmurs, 143
 pressure, instruments for measuring, 57
 sounds, 128
Asthma, bronchial, 269
Asthmatic breathing, 21
Atelectasis, 298
 crepitant râles in, 109
Auscultation, 83
 mediate and immediate, 84
 of the heart, 117
 of the lungs, 95
 sources of error, 93
BARNARD, 60
Barrel chest, 9
Bowles, 86
Bradycardia, 208
Bramwell, 173
Breast, funnel, 7
 pigeon, 7
Breathing, amphoric, 107
 asthmatic, 21, 101
 bronchial, 96, 99, 106
 broncho-vesicular, 100, 106
 catchy, 22
 cavernous, 107
 Cheyne-Stokes, 21
 cogwheel, 102
 compensatory, 103
 diminished vesicular, 104
 emphysematous, 101
 exaggerated vesicular, 103
 interrupted, 102
 irregular, 22
 metamorphosing, 102
 restrained, 22
 rough, 99
 shallow, 22
 stridulous, 23
 tracheal, 96, 99, 106
 tubular, 96, 99, 106
 vesicular, 96
 see also *Respiration*
Bridge, Norman, 257
Broadbent, 174, 223

- Bronchial asthma, 269
 dilatation, 270
 Bronchiectasis, 270
 Bronchitis, acute, 239
 chronic, 242
 Broncho-pneumonia, 250
 Brush, 61

 CABOT, 141
 Cancer of the lung, pleura, or chest wall, 297
 Capillary pulse, 38, 178
 Cardiac impulse, character of, 29
 impulse, displaced, 29
 impulse, normal, 26
 murmurs, 130
 movements, 26
 see also *Heart*
 Chest, barrel, 9
 deformities of, 12
 flat, 8
 in infants, physical examination of, 305
 rachitic, 7
 radioscopy of, 306
 wall, cancer of, 297
 walls, nutrition of, 10
 see also *Thorax*
 Cheyne-Stokes breathing, 21
 Cirrhosis of the lung, 271
 Compensation, establishment and failure of, 148
 Cough, effects of, 111
 Creighton, Sarah R., 122
 Cyanosis, 39

 DEFORMITIES, 14
 Dextrocardia, 31
 Diaphragm, movements of, 23
 Dyspnœa, 18
 EGOPHONY, 115

 Ellis, 284
 Emphysema, 264
 complementary, 268
 interstitial, 268
 large-lunged, 264
 small-lunged, 264
 with asthma, 267
 with bronchitis, 267
 Empyema necessitatis, 292
 Endocarditis, acute, 304
 Epigastric pulsation, 32
 Eruptions, 41
 Examining the thoracic organs, methods of, 1, 305
 Expansion, 16
 diminished, 17
 increased, 18

 FLINT, AUSTIN, 173, 257
 Fluoroscope, use of the, 307
 Fremitus, tactile, 44
 Friction, pericardial, 46
 pleural, 46
 sounds, pleural, 111
 Friedreich, 222
 Funnel breast, 7

 GAERTNER's tonometer, 58
 Gairdner, 173
 Garland, 284
 Gibson, 122
 Glands, enlarged, 41

 HÆMODYNAMOMETER, Oliver's, 61
 Hæmopericardium, 218
 Harrison's groove, 7
 Heart, aortic regurgitation, 175
 aortic stenosis, 185
 arrhythmia, 209
 bradycardia, 208
 dilatation of, 154
 disease, congenital, 211

- Heart, diseases of, 145
 fatty degeneration of, 206
 fatty overgrowth of, 206
 hypertrophy of, 151
 mitral regurgitation, 156
 mitral stenosis, 166
 neuroses of, 207
 palpitation of, 210
 parietal disease of, 203
 pulmonary regurgitation, 197
 pulmonary stenosis, 198, 211
 rapid, 207
 situs inversus, 31
 slow, 208
 sounds, doubling of, 122, 127
 sounds, metallic, 128
 sounds, modifications of, 120
 sounds, muffled, 128
 sounds, normal, 118
 sounds, pathological, 124
 sounds, rhythm of, 127
 sounds, shortening of, 121
 sounds, weakening of, 121
 tachycardia, 207
 tricuspid regurgitation, 192
 tricuspid stenosis, 196
 valvular lesions, combined, 199
 valvular lesions of, 145
 weakened, 204
 see also *Cardiac*
- Henchen, 203
 Hill and Barnard sphygmometer, 60
 Hochsinger, 122
 Howell, 61
 Hutchinson, Woods, 9
 Hydropericardium, 218
 Hydrothorax, 104, 272
- INSPECTION, 5
 Instruments for measuring arterial pressure, 57
- JAUNDICE, 40
- LITTEN'S phenomenon, 23
 Locke, 141
 Lung, abscess of, 296
 cancer of, 297
 cirrhosis of, 271
 fistula sound, 116
 gangrene of, 296
 œdema of, 299
 reflex, 82
 syphilis of, 270
 tissue, collapse of, 298
 Lungs, diseases of, 239
 tuberculosis of, 251
- MEDIASTINAL glands, tuberculosis of, 304
 Mediastinitis, 303
 Mediastinum, diseases of, 301
 tumors of, 301
 Metallic tinkle, 116
 Methods of examining the thoracic organs, 1, 305
 Mitral regurgitation, 156
 stenosis, 166
 Movements, respiratory, 16
 Murmurs, arterial, 143
 cardiac, 130
 cardio-respiratory, 143
 functional or hæmic, 140
 venous, 143
 Muscle sounds, 92
 Myocarditis, acute, 203
 chronic, 204
- ŒDEMA, 40
 Oliver's hæmodynamometer, 61
 Osler, 171, 173, 210
- PALLOR, 40

- Palpitation of the heart, 210
 Percussion, 64
 auscultatory, 71
 immediate, 64
 mediate, 64
 palpatory, 73
 resonance, 73
 resonance, amphoric, 81
 resonance, cracked-pot, 80
 resonance, dull, 74
 resonance, flat, 74
 resonance, tympanitic, 76
 resonance, vesicular, 74
 technique, 64
 Pericardial friction, 46
 Pericarditis, 214
 dry, 214
 fibrinous, 214
 with effusion, 217
 Pericardium, adherent, 222
 diseases of, 214
 Phear, 174
 Phthisis, fibroid, 262
 Pigeon breast, 7
 Pleura, cancer of, 297
 Pleural effusion, encapsulated, 291
 friction, 46
 friction sounds, 111
 thickening, 291
 Pleurisy, 278
 dry, 278
 plastic, 278
 pulsating, 34, 292
 with effusion, 280
 Pneumonia, aspiration, 249
 broncho-, 250
 catarrhal, 250
 central, 243
 chronic interstitial, 271
 croupous, 243
 fibrinous, 243
 Pneumonia, hypostatic, 299
 inhalation, 249
 lobular, 250
 massive, 243
 wandering, 247
 Pneumopyothorax, 274
 Pneumothorax, 274
 Pneumothorax, 104, 272
 Pressure, arterial, instruments for
 measuring, 57
 Pulmonary regurgitation, 197
 stenosis, 198, 211
 tympanites, acute, 268
 Pulsating pleurisy, 34
 Pulsation, capillary, 38
 epigastric, 32
 venous, 35
 Pulsations, abnormal, 48
 due to aneurism, etc., 33
 due to retraction of the lung, 32
 Pulse, 49
 anacrotic, 53
 bounding, 53
 compressibility of, 52
 Corrigan, 179
 dicrotic, 53
 rate, 51
 rhythm, 51
 tension, 54
 water-hammer, 179
 wave, size and shape of, 52
 RACHITIS, effects on the thorax, 7
 Radioscopy of the chest, 306
 Râles, 107
 bubbling, 107
 crackling, 108
 crepitant, 108
 moist, 107
 musical, 110
 palpable, 47

- Recklinghausen, von, 60
Regurgitation, aortic, 175
 mitral, 156
 pulmonary, 197
 tricuspid, 192
Resistance, sense of, 82
Respiration, normal, 16
 types of, 96
 see also *Breathing*
Respiratory movements, 16
Rhythm, respiratory, changes in, 21
 Riva-Rocci sphygmometer, 59
Rosary, rachitic, 8
Rosenbach, 122, 138, 150, 174

SANSOM, 169
Scars, 41
Skoda, 256
Sphygmograph, 314
Sphygmometer, Hill and Barnard, 60
 Riva-Rocci, 59
Spinal curvatures and twists, 12
Stanton, 60, 62
Steel, Graham, 197
Stenosis, aortic, 185
 mitral, 166
 pulmonary, 198, 211
 tricuspid, 196
Stethoscope, Bowles, 86
 choice of, 84
 use of, 89
Succussion, 115
Syphilis of the lung, 270

TACHYCARDIA, 207
Tactile fremitus, 44
Thoracic aneurism, 226
 organs, methods of examining
 the, 1, 305
Thorax, paralytic, 8
 tender points upon, 48
Thrills, 43
Tonometer, Gaertner's, 58
Tracheitis, 239
Traube, 77
Tricuspid regurgitation, 192
 stenosis, 196
Tuberculosis of the mediastinal
 glands, 304
 pulmonary, 251
 pulmonary, advanced, 258
 pulmonary, incipient, 251
 pulmonary, moderately ad-
 vanced, 255
Tympanites, acute pulmonary, 268

VALVE areas, 117
Valvular lesions, combined, 199
Vascular phenomena, 34
Veins, inspection of, 35
Venous sounds, 129
Vierordt, 122
Voice sounds, spoken, 114
 sounds, whispered, 113

WILLIAMS, F. H., 26, 254





$$1 \overline{3} = 83 \text{ (drachms)}$$

$$1 \overline{3} = 3 \overline{\text{d}} \text{ (scruples)}$$

$$1 \overline{\text{d}} = 20 \text{ gr (grains)}$$

$$10 = 16 \overline{f3}$$

$$1 \overline{f3} = 8 \overline{f3}$$

$$1 \overline{f3} = 60 \text{ m (minims)}$$

Y.P. 1903.2

COUNTWAY LIBRARY OF MEDICINE

RC

76

C11

1903

RARE BOOKS DEPARTMENT

