

Cataract extraction : being a series of papers with discussion and comments read before the Ophthalmological section of the New York academy of medicine, 1907-1908 / edited by J. Herbert Claiborne.

Contributors

Claiborne, John Herbert, Jr., 1861-1922.
Francis A. Countway Library of Medicine

Publication/Creation

New York : Wood, 1908.

Persistent URL

<https://wellcomecollection.org/works/aessnckf>

License and attribution

This material has been provided by This material has been provided by the Francis A. Countway Library of Medicine, through the Medical Heritage Library. The original may be consulted at the Francis A. Countway Library of Medicine, Harvard Medical School. where the originals may be consulted. This work has been identified as being free of known restrictions under copyright law, including all related and neighbouring rights and is being made available under the Creative Commons, Public Domain Mark.

You can copy, modify, distribute and perform the work, even for commercial purposes, without asking permission.



Wellcome Collection
183 Euston Road
London NW1 2BE UK
T +44 (0)20 7611 8722
E library@wellcomecollection.org
<https://wellcomecollection.org>

CATARACT EXTRACTION.

JOHN ELMER WEEKS, M.D.

EDGAR S. THOMSON, M.D.

EDWARD B. COBURN, M.D.

J. H. WOODWARD, M.D.

PERCY FRIDENBERG, M.D.

J. HERBERT CLAIBORNE, M.D.

A. E. DAVIS, M.D.

RUDOLPH C. DENIG, M.D.


WILBUR B. MARPLE, M.D.

THOS. R. POOLEY, M.D.

WALTER EYRE LAMBERT, M.D.

HERBERT W. WOOTTEN, M.D.











CATARACT EXTRACTION

BEING A SERIES OF PAPERS WITH DISCUSSION AND COMMENTS READ BEFORE THE OPHTHALMOLOGICAL SECTION OF THE NEW YORK ACADEMY OF MEDICINE, 1907-1908.

EDITED BY


J. HERBERT CLAIBORNE, M.D.

Formerly Adjunct Professor of Ophthalmology New York Polyclinic; Instructor in Ophthalmology Cornell University Medical College; Surgeon New Amsterdam Eye and Ear Hospital.

NEW YORK
WILLIAM WOOD AND COMPANY
MDCCCXVIII

8616 Bi

COPYRIGHT, 1908,
By WILLIAM WOOD & COMPANY.

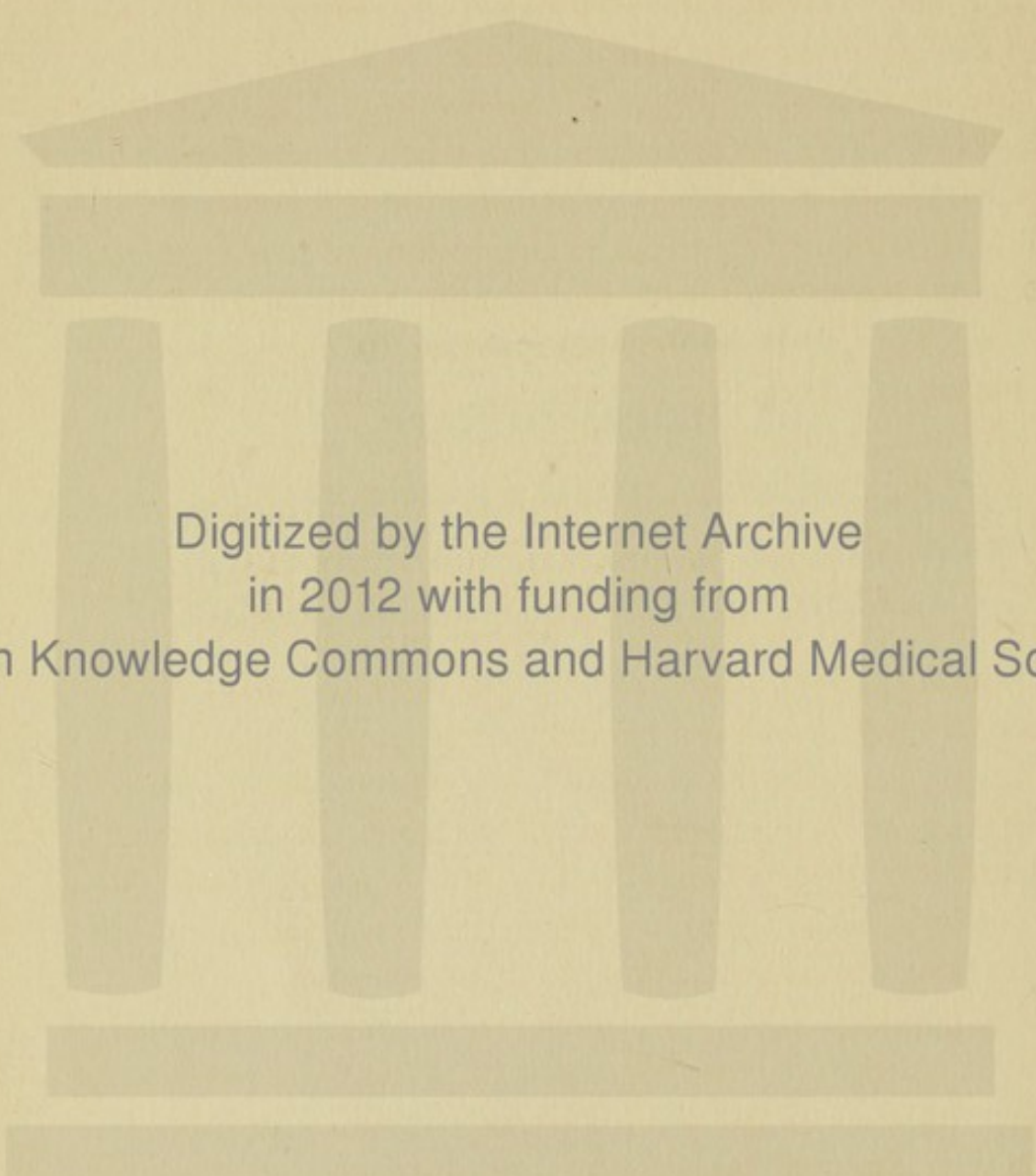


*Printed by
The Maple Press
York Pa.*

THIS BOOK IS DEDICATED TO

DR. HERMAN KNAPP

IN RECOGNITION OF HIS MONUMENTAL SERVICES TO
OPHTHALMOLOGY IN GENERAL AND PARTICULARLY
OF HIS SKILL IN THE EXTRACTION OF CATARACT



Digitized by the Internet Archive
in 2012 with funding from
Open Knowledge Commons and Harvard Medical School

INTRODUCTION.

THE editor, during his incumbency of the office of president of the Section of Ophthalmology, New York Academy of Medicine, 1907, instituted a symposium on cataract extraction. A different surgeon was selected to read a paper on each occasion, and that paper and the discussion which followed it constituted the main feature of the evening. It was attempted to select each essayist with a view to his peculiar aptness to present the part of the subject which, by reason of experience or training, he was best fitted to handle, and the sequence of the papers was arranged as far as possible in the order in which a surgeon would perform the operation.

After the chapter on the technic of the operation, the editor has taken the liberty of interpolating the description of a specially constructed lance-shaped keratome with which he has recently extracted cataract successfully.

It was deemed pertinent to the subject to introduce papers on artificial maturation of cataract, the extraction of artificially-matured lenses in highly myopic eyes, and the after-results, immediate and remote, of extraction.

The following pages are the result of that plan.

The majority of the surgeons have to a great extent presented their subjects from a personal stand-point, except in the chapters on the technic of the combined and simple extraction, and on discussion of the postoperative capsule, in which the essayists at the request of the editor have treated their themes in a more didactic way.

It has been the aim of the editor to have the subject so presented that it may be regarded as an expression of modern thought and practice in cataract extraction. He has made comments at the end of the discussion which follows each paper for the purpose of emphasizing certain views of the essayists, to add something which may have been omitted or to take sides on vexed questions of judgment or technic. The various steps of the operation and the elements of the technic in it are so interdependent and interwoven that it is not surprising to find one essayist occasionally encroaching on the ground of another. So far from this repetition being undesirable, it appears to the editor to be a distinct advantage, since by multiplying counsel, wisdom is more certainly attained.

The editor desires to express his thanks and appreciation to the gentlemen who by their able cooperation have rendered this achievement possible.

The papers of Drs. Weeks, Pooley, Claiborne and Marple were printed antecedently in the *New York Medical Journal*; that of Dr. Woodward in the *Vermont Medical Monthly*; that of Dr. Coburn in the *New York Medical Record*, and Dr. Fridenberg's in the *American Journal of Ophthalmology*.

The editor acknowledges his indebtedness to the editors of these journals for the privilege they have accorded him of incorporating these papers in this book.

23 WEST 36 STREET, NEW YORK CITY.
July 15, 1908,

CONTENTS

CHAPTER I.

What Stage in the Development of Cataract, Particularly Senile Cataract, is the Most Suitable for its Removal by Extraction?
Page 1.

BY

JOHN ELMER WEEKS, M. D.

Professor of Ophthalmology, University and Bellevue Hospital Medical College; Surgeon New York Eye and Ear Infirmary.

CHAPTER II.

The Preparation of the Patient and the Antiseptic Precautions to be Employed Preceding the Extraction of Cataract. Page 12.

BY

EDGAR S. THOMSON, M. D.

Surgeon and Pathologist, Manhattan Eye and Ear Hospital; Instructor in Ophthalmology, Manhattan Eye and Ear Hospital Post-graduate School.

CHAPTER III.

Simple Extraction *versus* Combined Extraction. Page 25.

BY

EDWARD B. COBURN, M. D.

Surgeon and Pathologist New Amsterdam Eye and Ear Hospital; Assistant Surgeon Department of Ophthalmology, Cornell University Medical College.

CHAPTER IV.

Combined Extraction *versus* Simple Extraction. Page 32.

BY

J. H. WOODWARD, M. D.

Formerly Professor of Ophthalmology, Vermont Medical College.

CHAPTER V.

The Technic of the Simple and of the Combined Operation for the Extraction of Mature Senile Cataract. Page 45.

BY

PERCY FRIDENBERG, M. D.

Assistant Adjunct Surgeon, Ophthalmic and Aural Department, Mt. Sinai Hospital; Junior Surgeon, New York Eye and Ear Infirmary.

CHAPTER VI.

Extraction of Cataract with a Lance-shaped Keratome. Page 80.

BY

J. HERBERT CLAIBORNE, M. D.

Instructor in Ophthalmology, Cornell University Medical College; Surgeon New Amsterdam Eye and Ear Hospital.

CHAPTER VII.

The After-treatment. Page 91.

BY

A. E. DAVIS, M. D.

Professor of Ophthalmology, New York Post-graduate College; Ophthalmic Surgeon, New York Post-graduate Hospital.

CHAPTER VIII.

Discussion after Cataract Extraction: Its Indications and Technic
Page 106.

BY

RUDOLPH C. DENIG, M. D.

Ophthalmic Surgeon to the German Hospital and Dispensary.

CHAPTER IX.

Extraction of Cataract in the Capsule. Page 117.

BY

WILBUR B. MARPLE, M. D.

Formerly Professor of Ophthalmology, New York Polyclinic; Surgeon, New York Eye and Ear Infirmary.

CHAPTER X.

The Operations for the Artificial Maturation of Cataract. Page 129.

BY

THOS. R. POOLEY, M. D.

Formerly Professor of Ophthalmology, New York Polyclinic; Executive Surgeon New Amsterdam Eye and Ear Hospital.

CHAPTER XI.

A New Procedure and Instrument for the Artificial Maturation of Cataract. Page 134.

BY

J. HERBERT CLAIBORNE, M. D.

Instructor in Ophthalmology, Cornell University Medical College; Surgeon New Amsterdam Eye and Ear Hospital.

CHAPTER XII.

The Extraction of the Artificially Cataractous Lens in High Myopia. Page 146.

BY

WALTER EYRE LAMBERT, M. D.

Formerly Professor of Ophthalmology, New York Polyclinic; Surgeon, New York Eye and Ear Infirmary.


CHAPTER XIII.


Final Results of Cataract Extraction. Page 158.

BY

HERBERT W. WOOTON, M. D.

Assistant Surgeon Manhattan Eye and Ear Hospital; Instructor in Ophthalmology, Manhattan Eye and Ear Hospital Post-graduate School.





CATARACT EXTRACTION.

CHAPTER I.

WHAT STAGE IN THE DEVELOPMENT OF CATARACT, PARTICULARLY SENILE CATARACT, IS THE MOST SUITABLE FOR ITS REMOVAL BY EXTRACTION?

JOHN ELMER WEEKS, M. D.,

IN considering this question I infer that we are agreed that the effort of the surgeon should always be in the best interest of the patient. In many cases extraction of cataract may be delayed until the surgeon is satisfied that the most favorable time for the operation has arrived. In many other cases the extraction is necessary for economic reasons at the earliest time possible compatible with good results.

I think that all ophthalmic surgeons agree that the most propitious time for the extraction of cataract is when the lens substance is readily detachable from the lens capsule. When the cataract has reached this stage it is really mature in an operative sense. The terms "mature cataract" and "complete opacification of the lens" are thought by many to be synonymous. This idea is erroneous so far as it applies to the most favorable time for the removal of cataract, as there are many exceptions.

In this connection it may be well to refer to and to briefly describe the types of senile cataract most frequently met with. These are:

1. Equatorial (cortical) cataract: (a) imbibition cataract; (b) cataract, always smaller than the normal lens.
2. Cortical (choroidal) cataract, anterior or posterior or both.
3. Nuclear cataract.

The equatorial cataract, the form most frequently met with, begins by the formation of opaque striæ near the equator of the lens. The shrinkage of the nuclear portion of the lens in this form plays an important part. The cortical lamellæ, as has been pointed out by Becker, do not shrink as rapidly as the nuclear lamellæ; as a consequence a process of cleavage between peripheral and nuclear lamellæ is set up. The fissures thus formed are filled with fluid, granular detritus, Morgagnian globules (myelin globules) and fat globules, the whole of which forms the liquor Morgagni. These spaces, filled as they are, produce white opaque striæ. This process is most marked in the equatorial region of the lens, probably because the traction of the suspensory ligament prevents the lens fibres from following the nucleus as readily as do those at the anterior and posterior poles of the lens.

As the process advances the lens fibres, among which the fissures form, take on a granular and fatty degeneration and become more or less disintegrated and broken. Morgagnian globules and albuminoid masses appear.

(a) In some cataracts, particularly in those forming rather early in life, an imbibition of intraocular fluids takes place, and the lens becomes considerably swollen, pushing the iris forward and causing a narrowing of the anterior chamber. The opacification of the lens progresses as the swelling increases, and the lens becomes almost opaque when the swelling has reached its maximum. The white soft cataract is the extreme example of this process. After having

reached the maximum swelling, the lens gradually loses in volume, and the anterior chamber becomes deeper until the lens becomes smaller than the normal transparent lens at the same period of life.

(b) In some cataracts which develop by the formation of fissures in the cortex a period of swelling, as pointed out by Priestly Smith, does not develop, the lens always remaining smaller than the normal lens of the same age.

Before maturity is reached these two forms of cataract present glistening or lustrous sectors, the so-called asbestos stripes. This appearance is produced by the granular contents of fissures and laminae of lens fibres undergoing granular and fatty degeneration and shining through transparent lens tissue and capsule, the liquor Morgagni not yet having found its way between capsule and cortical lamella of lens fibres. When the liquor Morgagni has found its way between capsule and cortical lamella, even in a very thin layer, the asbestos appearance is almost, if not entirely, lost although when the layer of liquor Morgagni is very thin the structure of the lens may be visible to some extent.

Cataracts which develop in the manner described can be readily removed when the development of liquor Morgagni between the lens capsule and the cortical lamina of lens fibres, in however thin a layer, has taken place. In not a few cases this occurs before the anterior chamber is fully restored to its normal depth. If extraction is attempted before this period the lens cortex will adhere more or less firmly to the capsule and some soft lens substance will remain in the capsule. If this form of cataract is permitted to become hypermature the capsule may become thickened by hyperplasia of the epithelial cells, the intracapsular fluid escapes, calcareous and cholestrin deposits form, the

degenerated lens fibres become attached to the anterior capsule, and difficulty in extraction is experienced.

Another form of cleavage cataract met with not very infrequently is the purely cortical cataract, sometimes referred to as chorioidal cataract. This is frequently preceded or accompanied in its early stage by a very mild uveitis or anterior chorioiditis. The process of cleavage begins in the posterior lamellæ of the lens, very near the capsule of the lens, sometimes near the equator, often at the posterior pole. It interferes very greatly with vision, advances very slowly, and may become almost, if not quite, stationary. Both eyes are usually involved, but it may be monocular. There may be vitreous opacities in some cases; in others the vitreous may be perfectly clear and the function of the retina may be unimpaired. The lens in these cases is, as a rule, smaller than the normal lens, but a stage in which the lens substance is readily separable from the capsule is reached, if ever, only after many years have elapsed. Reduction in the size of the lens by the process of sclerosis may continue until the lens becomes very thin (disciform).

The third form, which is second in frequency to the first form described, is that in which the opacification appears at the centre of the lens. The process is essentially one of sclerosis. In some cases numerous minute fissures are found between lamellæ in the nuclear portion of the lens, due to a process of cleavage, the process but slightly affecting the cortical part of the lens. In other cases of this type no cleavage can be seen. The substance of the lens becomes sclerosed, the nuclear portion taking on a deep amber color and becoming hazy. In these cases the lens is always smaller than the normal lens at a corresponding age; it tends to grow thinner (disciform) and smaller in its equatorial diameter. Such a lens when the opacification has advanced

sufficiently far to interfere with vision to an annoying degree, is not very closely adherent to its capsule. When extraction is attempted the cortical lamellæ are more adherent to the nuclear portion than to the capsule, and are removed almost completely with the nuclear portion even when the cortex is transparent to a considerable extent.

There is a fourth type of cataract which we are called upon to extract from time to time, namely, the zonular cataract, when the cataractous portion becomes so dense and is so large that vision is reduced below the point which enables the patient to follow the ordinary vocations of life; also there are cases in which calcareous deposits render dissipation of the cataract by needling imprudent or impossible.

Extraction of cataract in the types described, if done when most propitious for the welfare of the patient should be performed in the *first type* as soon as liquor Morgagni appears between the lens capsule and the lens substance; in the *second type*, at the convenience of the patient after vision is reduced below that necessary for the ordinary vocations of life; in the *third type*, when useful vision has been abolished and the lens is appreciably shrunken; in the *fourth type*, at the convenience of the patient after vision is reduced below that necessary for ordinary uses.

The degree of vision necessary to the individual in order that he may not be incapacitated differs with the vocation. It may be put at twenty fortieths to twenty two-hundredths.

In the foregoing pages we have considered the most propitious time for the removal of cataract. In the process of development of all forms of cataract there is a stage between the loss of useful vision and the condition in which the detachment of the lens fibres from the lens capsule is most easy; this may extend over a few months or a few years. This

stage is distressing to the patient and in not a few instances entails hardships on himself and his family.

During a long experience in the removal of the non-cataractous lenses in the dead house, conducted for self-instruction as well as for the instruction of students in the operative surgery of the eye, the writer has studied the behavior of the transparent lens. It was observed that in the lenses which were twenty-five or thirty years old, the nuclear portion was fairly firm, about two-thirds of the mass of the lens coming away with the nucleus. It was further observed that much of the detached cortex could be made to follow the nuclear portion. The firm "nuclear" portion becomes larger as the age of the lens increases. On the strength of these observations, in spite of the dictum "hands off" in reference to operations on immature cataract, I began to remove the cataractous lens soon after it had reached a degree of opaqueness sufficient to interfere with useful vision, whatever the form of the cataract might be, in all cases in which such removal was particularly urgent, those cases being excepted in which the lens was much swollen. If the lens is much swollen, the narrow anterior chamber makes the extraction much more difficult; it is much better then to wait until the lens has shrunk to some degree before attempting the operation.

Before this plan was followed, the operation of ripening advocated by Förster was tried in a number of cases. The lenses became rapidly opaque, but it was found that removal six weeks or two years later was complicated by adhesion of cortical substance to the capsule to probably the same extent as would have been the case had the extraction been performed at the time of the Förster operation. This experience was sufficient to cause the writer to abandon all ripening operations as not of sufficient value to com-

pensate for the extra liability to accidents and inflammatory changes consequent on them.

In almost all cases of the extraction of immature cataract some soft lens substance remains even after very careful irrigation of the anterior chamber. All that can be removed without too severe manipulation should be removed, but if a little cortex remains it is not a serious matter. Cortical lens substance which may remain in the eye after the removal of immature cataract does not give rise to serious inflammatory trouble.

Substances capable of producing irritation, such as tabular crystals of cholesterin or minute deposits of lime, do not exist in the cortex of the immature cataractous lens, but do appear in greater or less quantities in the cortex and deeper parts of the hypermature cataract, and their escape from the lens capsule and retention in the anterior or posterior chamber is not infrequently accompanied or followed by irritation to the eye of greater or less severity. The cortex of the immature cataract absorbs slowly if it lies in a capsule which has been opened near its periphery and in which the opening is small. If the capsule has been opened freely, absorption of the cortical substance advances more rapidly.

After the remaining cortical substance is absorbed the capsule of the lens may be dealt with as may be indicated by its condition. It may not be necessary to do anything with it.

At a meeting of the American Medical Association, held in Baltimore in 1895, the writer reported the results of twenty-five successive cases of immature and zonular cataract for the removal of which he had operated by extraction. There were no losses. The combined extraction was done in six cases; simple extraction in nineteen cases. One prolapse

of iris occurred. Discission was done in twenty cases. Ultimate vision was 20/20 or better in thirteen cases (52 per cent.). The lowest vision in any case was 20/70.

Since 1895 I have operated in many similar cases, proportionately more combined than simple operations being done. The visual results have not been less favorable than those reported in 1895.

I do not wish it understood that I operate for the removal of cataract by preference before the time of selection is reached. The difficulty of extracting immature cataract is greater than the difficulty of extracting mature cataract. When it is done, it should be done by expert operators. When so done the visual results are not much, if any, below those obtained after the removal of mature cataract.

DISCUSSION.

In the discussion on Dr. Weeks's paper, DR. E. GRUENING stated that many cataracts were sufficiently transparent to allow of serviceable distant vision, but not sufficiently transparent to permit the person to do useful near work, and that in many of these cases the lens was sclerosed and extraction could be safely performed. He did not operate in cataract that was really immature. If there was a large and transparent cortex, it was, as a rule, better to wait, but if the patient insisted upon operation it was usually better to perform a preliminary iridectomy. At times, however, the surgeon was compelled to perform extraction at one sitting, for sometimes the patient would not submit to a double operation. In zonular cataract, extraction could be performed without waiting for complete ripening of the lens. This could be preferably done by removing the nucleus and as much soft cortex as possible at one sitting, leaving the rest of the cortex to be absorbed. Removal of a cataract

in its capsule was, of course, the ideal operation, but on the average the results were less favorable than by the ordinary methods, for the loss of vitreous which might result was sometimes the cause of subsequent detachments of the retina and hemorrhage at the time of operation.

DR. T. R. POOLEY stated that in immature cataract he was opposed to operation as a general practice. Of course, when both eyes were about equally affected a patient was reduced to serious straits on account of the double loss of vision and the operation might be rendered necessary, but these cases were not very common. Nuclear cataract and sclerosed lenses could be removed before completely ripe without much danger. Zonular cataract was very difficult to deal with, for one could not be sure of removal of all the soft lens substance and, in these cases, a preliminary iridectomy was a good thing. In any case of cataract extraction, when it was known that the eye was highly myopic, a preliminary iridectomy ought to be performed.

DR. E. S. THOMSON made it a rule to operate as soon as the lack of vision in the better eye incapacitated the patient, except when the lens was much swollen or when much soft lens matter existed. How to distinguish clinically when these conditions are present is very difficult. When the lens is sclerosed the state of affairs is evident, but in the ordinary cases with striæ from the equator it is very hard to tell. He never performed extraction in the capsule unless he was compelled to. When there was much soft lens matter he preferred the simple operation and did not like to operate in two stages. The position he took upon the time to operate in cataract depended principally upon how far he could determine the presence or absence of soft lens matter.

DR. H. KNAPP stated that removal of the lens in the capsule was not difficult if the section was made below. He

does not like to operate on immature cataract, for some particles of soft lens matter are sure to be left behind. When much cortex was left behind, he irrigated with a special syringe. This syringe resembles an ordinary hypodermic with a short angular tip. It is made of glass, the piston working very tightly, and the whole syringe could be disinfected by boiling. He also used the syringe to inject salt solution when much vitreous had been lost, and also to syringe out the anterior chamber when it contained much blood.

DR. E. B. COBURN did not believe in inflicting much trauma in order to remove soft lens matter, and believed that too long a time should not elapse between the primary operation and the discission of the capsule, if this should be necessary, for a connective-tissue formation took place which made discission, with the increasing lapse of time, correspondingly difficult. With a swollen lens and a shallow anterior chamber, we should not operate, but if we found much sticky cortex during the operation we should carefully extract the soft lens matter without undue trauma.

DR. J. E. WEEKS, in closing, stated that, while the extraction of immature cataract was attended by many difficulties, the hardships often inflicted by waiting rendered early extraction in some cases perfectly justifiable.

[Within the last twelve months I have removed a perfectly clear lens from an eye in which there appeared to be a posterior cortical central cataract. This opacity interfered with the vision to such an extent that I concluded to attempt combined extraction. Artificial maturation was contraindicated by the existence of an old iritis and an indefinite history of choroiditis. A large incision was made, a T-shaped cystotomy was done, and the lens was delivered

entire with ease. Inspection of the lens showed that it was clear throughout; there was no opacity of the fibres even at the posterior pole. The opacity seen before the operation must, therefore, have been a posterior capsular one. I made a demonstration of the clearness and magnifying power of the lens by reading print through it. The eye healed quickly, but the patient unhappily injured her eye twice on the fourth night after the operation by striking at mosquitoes. The wound was opened, and a prolapse of one of the pillars of the coloboma was caused. Two weeks later she was again accidentally struck in the eye by her little grandson, and a more extensive opening of the wound, together with prolapse of the choroid, was produced. The visual result, of course, was bad, and an interesting feature of the case lay in a rolling up of the entire capsule into a scroll-shaped mass, which was finally attached to the site of the wound.

There were, apparently, no cortical remnants; perhaps the freedom with which the capsule separated from the lens, was due to the preceding iritis and choroidal disease.

This case, however, proves that a perfectly clear lens may be delivered without the capsule. Nevertheless, it is not a wise procedure to extract such lenses, and it should not be attempted except for stringent economic reasons.

If it is imperative to operate at once, the combined extraction or a preliminary iridectomy should be done.

Dr. Weeks's results are remarkable, in view of the fact that of twenty-five cases, simple extraction was performed in nineteen, and the combined operation in six. The results, however, in this small series of cases, should not form the basis of a rule of action. J. H. C.]

CHAPTER II.

THE PREPARATION OF THE PATIENT AND THE ANTISEPTIC PRECAUTIONS TO BE EMPLOYED PRECEDING THE EXTRACTION OF CATARACT.

EDGAR S. THOMSON, M. D.

THE important points to be considered in preparing for the operation of extraction of senile cataract are included under the following general headings:

- I. The general preparation of the patient.
- II. The preparation of the field of operation.
- III. The preparation of the operator and of the instruments to be used.

These questions have in the past led to great diversity of opinion, especially in regard to the methods used. It would be neither profitable nor interesting to attempt a statistical paper in this connection, and so I have simply set down what I believe to be the best usages and opinions of the leading American writers upon the subject, colored, of course, by my own preferences.

I. THE PREPARATION OF THE PATIENT.

It may be said in general that any patient undergoing an operation for cataract should be in his normal state of health, if circumstances permit, in order that we may secure resistance to bacterial invasion, prompt healing and the least possible post-operative inflammation. The following should be especially considered:

- (a) The cardio-vascular system.
- (b) The kidneys, particularly with reference to diabetes.

- (c) The respiratory apparatus.
- (d) The nervous system.
- (e) Toxic influences, especially syphilis and alcohol.
- (f) The digestive tract.

Assuming that the operation is performed under proper aseptic conditions, the state of the heart and vessels concerns us most, on account of the dreaded complication, choroidal hemorrhage, which destroys vision. Unless this follows some accident, as post-operative vomiting, loss of vitreous, compression of the eyeball by forcible attempts to close the lids, etc., it is hardly conceivable that the rupture of a choroidal vessel should occur unless some degree of degeneration of the vessel wall is present; therefore the evidences of arterio-sclerosis should be carefully noted, together with the degree of vascular tension present. The most reliable symptoms are, accentuation of the second sound of the heart, the persistent elimination of large amounts of urine poor in solids (of low specific gravity) and rigidity of the radials or other vessels. It is a well-known fact that vascular changes are not always symmetrical, and therefore it is not sufficient to feel the radials, but the brachials, facials, and all other accessible arteries, if suspicion arises. The history of the patient may lead us to suspect arterio-sclerosis, and the presence of an old chronic nephritis should cause us to look for it very carefully. The vascular tension may be judged by the degree of resistance to compression of the pulse at the wrist, by the heart sounds, or, best of all, by the sphygmomanometer. I believe we may almost always be forewarned, though we may not always be able to prevent the catastrophe of choroidal hemorrhage.

Where the arterial tension is high, especially if vascular degeneration is present in marked degree, hemorrhage

is more apt to occur, and the patient should be on careful diet and regimen for some days before the operation. Drugs to lower the arterial tension—*veratrum viride*, *aconite* or *nitroglycerin*—have been advised and are, in my opinion, indicated, though my personal experience with these remedies in this connection, fortunately, has been small. In such cases the circulatory system should be depleted by free catharsis, preferably with salines, before the operation; and, finally, the vessels should be subjected to no strain that can possibly be avoided after the first incision. It is better to operate on these patients in the bed in which they are to remain than to take them to the operating-room.

Urinalysis, which should always be done before cataract extraction, may give us important information. The presence of an acute or subacute nephritis would, of course, be an absolute contra-indication to the operation, for reasons which are obvious. Such patients should receive appropriate diet and treatment until a period more favorable for the extraction.

The respiratory system interests us chiefly on account of the risk of hemorrhage, or reopening of the wound, with its attendant dangers, in an attack of coughing during the first three or four days of convalescence. In acute bronchitis it is, of course, best to wait; but chronic bronchitis may be treated with codein or $\frac{1}{24}$ -grain doses of heroin every two or three hours for a day or two before the operation, giving sufficient to control the cough. Acute coryza with tendency to sneeze is, of course, an indication for the postponement of the operation. Asthma requires the same plan of treatment as chronic bronchitis, i. e., sedatives for two days or more before the operation to control the paroxysms.

The preparation of the nervous system is a difficult

matter and one much less under our control than those previously mentioned. Patients who fret or worry may be given bromids so as to sleep well for several nights before the operation. The remainder is a matter of personal encouragement, but even under favorable conditions nervous reaction, like delirium, is not always to be foreseen and must be treated according to the indications as they arise. I do not administer morphine in these cases, as I fear the stimulation in some instances and the nausea in others, but prefer to control a nervous patient largely by encouragement and moral suasion.

Toxic influences should be carefully investigated, with especial reference to syphilis or alcohol. Where a patient gives a history of severe outbreaks of syphilis, it is but the part of prudence to put such a patient under the influence of mercurials—preferably by inunctions—for several days prior to the operation, in order to avoid the severe secondary iritis that such patients are likely to have. The alcoholic habit is a severe handicap to the success of the operation, and when any tendencies in that line exist the patient should be treated with bromids, strychnin, etc., and the absolute withdrawal of all alcoholic beverages before the operation is attempted. It must be borne in mind that an alcoholic patient, seemingly in good condition, may develop delirium tremens following the operation, or at least post-operative delirium, and therefore treatment should be continued for several days after the patient seems fit for operation.

The digestive tract should be prepared by sensibly restricted diet for several days before operation and a cathartic administered the night before. If the case is an uncomplicated one, I am in the habit of allowing the patient to take whatever cathartic is preferred in a rather full

dose simply that the intestine may remain quiet for a few days following the operation. If depletion is desired, I give calomel and soda the night before with a saline the morning of the day I expect to operate.

Diabetes, while not a contra-indication, is certainly a disadvantage on account of the general nutritive disturbance of the system present in all true cases. There is also a tendency to secondary iritis which has been generally recognized. On account of these facts it is undoubtedly the best policy to be sure that the patient is on proper diet and proper medicinal treatment, so that conditions are at their best for that individual patient. In such cases, I always wait until the percentage of sugar in the urine is lowest, for I think it is generally conceded that the higher the glycosuria the poorer are the regenerative processes.

Of course, many cases come to us without the complications mentioned, and in these I merely give a cathartic the night before and have a bath administered with careful washing of the head and hair the day of the operation and, of course, have a urinalysis done.

II. THE PREPARATION OF THE FIELD OF OPERATION.

In considering this question it is well for us to realize at the start that all statistics and research work done tend to cast great doubt as to our power to sterilize the field of operation, as is done in other parts of the body. It may be said in general that it is impossible to completely sterilize the conjunctiva, at least without using so much violence or chemical irritation as to lower the resistance of the mucous membrane.

The anatomy of the conjunctiva, the communication through the canaliculi with the lachrymal canal to say nothing of the lashes and gland orifices, all make the problem

a difficult one. At present we have no germicides of proved power whose action is such that they will kill the germs present without irritating the conjunctiva. It is hardly necessary to cite authorities for this statement. At the same time, infection following cataract extraction is no longer a "burning question." It is very unusual with operators of good technic and careful methods of asepsis, and to my mind it is much better for us to give weight to the question of the patient's resistance and to increase that in every way than to take up complicated methods of preparation which may lower that resistance. This does not mean that I do not believe in careful asepsis nor that I shall not welcome the ideal "non-irritating germicide" when it comes.

In a normal case I have the brow and skin of the lids well washed with castile soap and well rubbed with a cotton pledget, after which they are flooded with a solution of bichlorid of mercury, 1-5000. I do not shave the brow nor do I trim the lashes, but wash them with especial care. After this the conjunctiva and cornea (cocainized, of course) are flooded with a 1-5000 bichlorid solution, and the cul-de-sac washed out with a pipette. All this is done by an assistant, unless the patient is nervous, when I use the pipette myself. I am inclined to think that the solution has more effect through mechanically carrying away whatever germs may be present than it has in killing them. Acting on the same mechanical principle, I next very carefully and gently wipe out the cul-de-sac with a cotton swab on an applicator. This removes any mucus that may be there and any bacteria that may be in it. I do this very carefully with a wet swab so as not to irritate the conjunctiva. Then the eye is closed and a pad of wet cotton is allowed to rest upon it for a few moments, while the other

eye is closed by a dressing. Sterile towels are placed upon the patient's chest and around the head, which has previously had a rubber cap put upon it; a dry towel is loosely arched over the patient's mouth, and I am ready to begin. For some years I have given up the habit of bandaging the eye for twenty-four hours previous to the operation, for I believe that not infrequently bandaging starts up secretion, probably by increasing the activity of the mucus formation and by dilating conjunctivæ vessels through the warmth of the dressing and also in another manner which is well explained by a statement in Fuchs (p. 74). He says: "Not that we are to think of the tears as having any bactericidal properties, their action being, on the contrary, purely a mechanical one in that they continually bathe the conjunctiva, and after washing it off drain into the nose." Now when the eyes are bandaged, this action of the tears is much lessened, and any bacteria which may be present have a chance to multiply. The clinical fact is that bandaging alone will start up a conjunctival secretion in many eyes. I do not see the wisdom in the eye-bath which some operators use for several days before operation, unless conjunctivitis is present, but always endeavor to interfere with the eye as little as possible, leaving it in what we may call its natural state. Of course, where there is blepharitis, conjunctivitis, or dacryocystitis, the question is a very different one, and treatment must be energetic and constant until the inflammation subsides.

This is hardly the place to discuss the means of getting rid of infective scales among the lashes or conjunctival discharge, but a word in connection with dacryocystitis may not be inappropriate. Any muco-pus in the sac, however slight, may be fatal to the success of the operation, as every one knows, but the dangers of clear mucus or a very

low grade of catarrhal secretion are perhaps not so well appreciated as they should be. I regard any abnormal secretion as dangerous, and my preference in cases that do not completely clear up under probing, irrigation, etc., is for sealing up the canaliculi with the actual cautery or complete extirpation of the sac before the extraction is attempted.

III. PREPARATION OF THE OPERATOR AND OF THE INSTRUMENTS.

Infection probably takes place more frequently from bacteria introduced by the operator than from the mild germs that we find so frequently in the normal cul-de-sac, so that it is here that we must be most careful. I immerse my ordinary instruments in boiling water for ten minutes, the cutting instruments being dipped in the boiling water by hand and then carefully wiped with sterilized cotton. They are then placed on a sterilized towel and covered with another towel until they are needed. All this should be done immediately before the operation, in order that they may not lie on the table any length of time. It seems almost superfluous, save for the sake of being thorough, to mention the necessity of the sterile operating gown. My own are long, with elbow sleeves. I scrub my hands and arms well with green soap, being especially careful of the nails, and immerse them to the elbow in a 1-5000 bi-chlorid solution, and then sterile water after the usual custom. The hair of the operator should always be protected by a towel, so that there may be no risk of any infective material falling upon the patient, and if I wore a beard I should certainly feel safer in having it bound up during the operation. As far as the mouth protector is concerned, its use seems to me somewhat extreme. The fact that bacteria may be projected by coughing is too well known

to need substantiation, but it seems self-evident that no operator is likely to cough into his patient's eye while operating. I try to avoid breathing directly upon the field of operation, and it seems to me that the danger of infection to my patients from this source is practically nil.

DISCUSSION.

In the discussion which followed, DR. J. E. WEEKS referred to the diabetic cases; he had recently seen one with 2.2 per cent. of sugar. The amount of acidosis had not been determined. The case was operated upon. On the fourth or fifth day there were drowsiness and some abdominal distension, and the patient died. The operation had been satisfactorily performed. In another case with 8.2 per cent. of sugar and some acetone in a patient seventy-three years of age, diet and bicarbonate of soda were resorted to and in a few days the amount of sugar was down to 1.5 per cent. and the acidosis much diminished. Operation was followed by good result. The patient had been kept upon bicarbonate of soda; he would not ordinarily operate with so much sugar, but the patient had been very anxious that the operation should be performed. The first case mentioned was the only bad result he had seen in operating on a diabetic patient, but the acidosis should always be determined. In regard to bacteria, the different varieties present in the conjunctiva might be determined before the operation. If the bacteria were pyogenic or pathogenic he tried to free the conjunctiva from them as much as possible before operating. A small number of pseudo-diphtheritic bacilli was not detrimental. If many were present he irrigated the eyes with 1-5000 bichlorid solution three or four times a day. Bandaging the eyes before operation was not good practice. Treatment for a few days, as described,

was all that was necessary. Dacryocystitis should be cured before extraction; he would not operate on a case which showed the diplobacillus of Morax-Axenfeld for fear of corneal ulceration. If only a little mucus could be squeezed out of the sac he applied a little bichlorid vaselin to the inner canthus immediately after operation.

DR. W. E. LAMBERT stated that in a case in which pseudodiphtheritic bacilli were found he had treated the case with argyrol, with an increase of this bacteria and of pus cells. Bichlorid of mercury was then used and the case recovered. He never had had occasion to extirpate the sac previous to a cataract extraction.

DR. M. L. FOSTER thought that argyrol was of no special value in these cases; bichlorid of mercury vaselin produced much better results.

DR. H. KNAPP stated that when a considerable quantity of sugar was present in the urine it was better to wait until the quantity had diminished.

DR. E. B. COBURN stated that he thought codein, combined with bicarbonate of soda, was beneficial in diabetes. Bichlorid of mercury in a solution of 1-5000 used in the conjunctival sac for a short period of time killed no germs. Argyrol, unless freshly made within the twenty-four hours preceding, was useless as a bactericide and was actually an irritant according to the genito-urinary surgeons. He sterilized the knives with pure lysol from six to twenty-four hours, removing the excess of lysol with absolute alcohol.

DR. E. L. OATMAN did not like to operate on diabetic cases as the operation was apt to cause cysts of the ciliary body, though these cysts possibly did no harm.

DR. F. N. LEWIS did not believe in giving a cathartic previous to the operation unless there was a history of constipation; he laid great stress upon the importance of

thoroughly cleansing the lid margins. He had used bi-chlorid of mercury for irrigation, but felt that boracic acid washed away superfluous secretion just as well and was not as irritating. He did not believe in bandaging the eye before operation.

DR. A. N. ALLING had never seen any ill effects from operating on a diabetic patient.

DR. H. KNAPP stated that, after cataract extraction, the infection came more from the conjunctiva than from the knife of the operator.

DR. J. E. GILES thought that infection rarely occurred nowadays from the instruments, but we should make sure that no dacryocystitis was present and should treat any cases of conjunctivitis.

DR. J. E. WEEKS thought that argyrol was of service in the conjunctiva. The clinical effects of drugs frequently differed from the results obtained in the laboratory.

DR. E. S. THOMSON, in closing, stated that, in his opinion, we could not, without long tedious culture experiments, learn much from the bacteriological examination previous to operation in cases that presented a normal appearance. Of course, if a smear was found full of germs the case was different. Argyrol *per se* was not a germicide, but its action upon germs of the conjunctiva was doubtless different from its action in the laboratory.

[Sugar in the urine, in high percentage, is, in my opinion, a marked contraindication for operation. The sugar should be reduced to the minimum by diet and medication before the operation is attempted. Even if suppuration does not occur in cases with a high percentage of sugar, delayed union of the wound usually results, and there is consequently danger of late infection. A high percentage of acetone I

consider an imperative contraindication to operation. I have seen delirium and death follow cataract extraction in a diabetic patient. Cataract extractions are frequently done without preceding examination of the urine, and it is safe to say there is none of us who has not been guilty of this neglect. To fail to do so is to invite misfortune and to be criminally negligent.

The character and the habits of the patient should be thoroughly studied, and an attempt should be made to establish a friendly *entente* between the patient and the surgeon, particularly when cocaine anesthesia is employed. To this end, an extraction should never be done on first acquaintance, and all appearance of haste should be avoided. We should remember that old people, as a rule, do not give their confidence and regard offhand, and are naturally skeptical and suspicious.

It is my opinion that the nose should be examined in all cases before operating. When circumstances demand it, the nasal passages should be put into a healthy condition before operating, and it is a safe and reasonable procedure to cleanse the nasal passages with antiseptic sprays for several days beforehand.

Both brows should be shaved in order to make the contiguous field as nearly sterile as possible, for one of the hands of the operator is apt to come in contact with the brow of the unoperated eye.

It would seem most reasonable to clip the lashes in all cases, but if that is done, injury and infection may easily result from the pricking of the conjunctiva by the short hairs in cases of spastic entropion. Some advise epilation of all the lashes, others cleanse them with benzine. Except in rare cases, it is perhaps best not to clip or epilate the lashes but to rely upon cleansing and disinfection. Ran-

dolph has pointed out that bacteria which may remain innocuous in the unirritated conjunctival sac may become factors of evil when the conjunctiva is irritated by strong solutions or injured during the operation. I lost a case once from suppuration which, I believe was due to the fact that I tore the conjunctiva slightly with the fixation forceps while operating. I had previously done a successful extraction upon the other eye without this accident. The man was strong and in good health and the eye was an ideal one for operation. In other respects, the technic was apparently without fault.

I think a surgeon should never operate when he has a cough, a coryza or is otherwise indisposed. He should wear a sterile cap and have his face from his eyes down covered by a sterile mask. This I consider absolutely obligatory for those who wear a beard. It is probable that all surgeons in the future will be clean-shaven. This is certainly the ideal condition for a surgeon who operates for cataract. Talking should be avoided. The assistants should be drilled by signs. When general anesthesia is given, the cone and the hands of the anesthetist should be sterile. When we reflect that it is not possible for us to sterilize the conjunctiva, we should render everything else as nearly sterile as possible. As to the hands, it is, of course, impossible to thoroughly sterilize them, but since the fingers do not touch the eye except in inserting and removing the speculum, the chances of infection from them are remote.

Since we can render everything appertaining to the operation sterile, except the fingers and the eye, it is our duty to achieve this to the minutest detail.

It is difficult to attain an ideal asepsis in this generation, owing to the persistence of the prejudices of the past, but the future generations will doubtless realize it. J. H. C.]

CHAPTER III.

SIMPLE EXTRACTION VERSUS COMBINED EXTRACTION.

EDWARD B. COBURN, M.D.

BEFORE discussing the advantages of the simple method of cataract extraction as opposed to the combined method, or extraction with iridectomy, it must be understood that the Pagenstecher and Indian method of extraction (i. e., in the capsule) is excluded from consideration. We shall assume that the patient is healthy, the field of operation normal as to bacterial content, the aseptic precautions are thorough and the patient is tractable.

In justice to the operation and the operator, certain cases should not be included in any statistical table. This refers to very old patients who are liable to pain and shock, hypostatic pneumonia, postoperative delirium, death from suicide or disease, dislocated lenses or fluid vitreous discovered after the operation is begun, collapsed eyeballs (frequent in elderly persons and when cocain has been too often instilled), and hemorrhage from the choroid or retina; nor should cases be included in which the patient is uncontrollable during operation and squeezes the lids, causing escape of vitreous.

The steps of the simple method of extraction are as follows: (1 Introduction of speculum; (2) section of cornea; (3) capsulotomy; (4) extrusion of lens; (5) toilet of wound, which includes the removal of cortical lens substance and replacement of the prolapsed iris (if it occurs); (6) removal of speculum.

Every step, including the use of a speculum, is debatable, and results may vary according to the judgment of the operator in performing the different steps of the operation. Thus the section of the cornea may be variously placed or include a flap of conjunctiva. The amount of effort made to remove cortical débris and replace the iris may be a potent factor in the result. The speculum may be removed after the capsule is opened or the lens is delivered, or it may be dispensed with entirely.

Having in mind all these variations, let us consider the advantages of simple extraction:

1. There is no unnecessary traumatism to the eye; i, e., only such procedures are employed as are absolutely necessary to remove the lens.

2. The minimum of traumatism means the minimum of danger of infection.

3. The number of instruments required for this operation for removal of the lens. Ordinarily only two instruments are introduced into the eye—the Graefe knife and the cystotome. This may be reduced to one if the capsule is incised during the passage of the knife through the anterior chamber. In some cases a spatula is necessary to reduce the primary prolapse of the iris.

4. The fewer the number of instruments introduced into the eye, the less is the liability to infection.

5. The anterior chamber is free from blood and the various steps of the operation are clearly visible.

6. The iris protects the wound from tags of capsule and particles of lens matter; hence these are less liable to get into the wound and cause delayed union or by their presence act as foreign bodies. Infection, glaucoma, sympathetic ophthalmia, iridocyclitis, and cystoid scar may result from their incarceration in the wound.

7. The iris serves as an obstruction to prevent prolapse of the vitreous.

8. Simple extraction requires the shortest possible time to remove the lens. Brevity in time means less exposure of the eye to pyogenic infection.

9. No assistants are required to perform simple extraction. The danger of infection is thereby diminished, and there is no fear of prolapse of the vitreous from undue pressure by unskillful assistants.

10. Convalescence is shorter by virtue of less traumatism.

11. The iris responds to stimulus and serves its purpose as a diaphragm in an optical sense.

12. Visual results are better. When the pupil is round, spherical aberration of the periphery of the cornea and of the correcting lens is cut off.

13. Some writers claim that the field of projection is better with a circular pupil.

14. Better vision and better projection mean less confusion, and together afford greater safety to the patient.

15. Cosmetic reasons. The result is ideal. The pupil is round and central and the eye presents a normal appearance. Sensitive persons do not, therefore, suffer by exciting attention and remark.

16. It is the easier method of extraction.

The following objections have been raised against simple extraction, and while some of these may be valid, I believe a majority of them are successfully combated.

1. The method is not adapted to all cases.

2. The corneal section must be more carefully placed to avoid secondary prolapse of the iris.

3. The corneal section must be larger to permit the exit of the lens as the iris is prolapsed into the opening and lessens the available space.

4. Capsulotomy is not so easily performed in a small pupil. If peripheric capsulotomy is attempted, the instrument must be out of sight during the opening of the capsule and, because it is unseen, undue pressure may cause dislocation of the lens and difficulty in its extraction, as well as prolapse of the vitreous. The point of the instrument may become entangled in the iris.

5. More pressure is required to tilt the lens and cause its extrusion through the pupil and corneal wound, hence greater liability to rupture of the zonular ligament and prolapse of the vitreous.

6. There is difficulty in delivering the lens through a small (and perhaps rigid) pupil and through the corneal section encumbered with iris.

Moderate pressure upon the advancing lens will cause the sphincter of the iris to relax, and if the operator's manipulations are deliberate the delivery of the capsule can be accomplished with ease.

7. The iris is bruised during the delivery of the lens, causing subsequent iritis and synechiæ.

8. The iris frequently becomes caught in the corneal section and must be replaced.

9. The toilet of the wound is difficult because cortical substance remains behind the iris.

It is probably true that thorough cleansing of the eye of cortical matter is more difficult, but the few small masses remaining do not get into the wound and cause irritation and delayed union; they are gradually absorbed.

10. Prolapse of the iris is a frequent complication and causes delayed union and necessity for another operation which is either painful or may require a general anesthetic for its abscission, results in anterior synechiæ or cystoid scar, and renders the eye liable to suppuration, glaucoma,

iridocyclitis, and sympathetic ophthalmia in the other eye.

Dr. Knapp calls iris prolapse the *bête noir* of simple extraction, and Gifford says "if it were not for prolapse of the iris, simple extraction would be employed."

Prolapse of the iris is usually traumatic in origin. The wound closes, and then some traumatism reopens it, causing a rapid escape of the vitreous which carries the iris with it.

Small prolapses frequently require no treatment, and even the large ones often flatten down and cause no subsequent disturbance. Certain it is that with all the danger of prolapsed iris the relative proportion of suppuration, iridocyclitis, glaucoma, and sympathetic ophthalmia, is not so large as that resulting from other methods of operating.

By careful exclusion of unmanageable patients, by making the corneal section rather well into the cornea, by keeping the eye quiet by a simple occlusive bandage without exercising undue pressure upon it, by avoiding excitement, by keeping the patient quiet and free from pain—if necessary, by the use of morphin—and by careful attention to the bowels to avoid straining at stool, the proportion of prolapse can be reduced to the minimum.

It may be objected that a corneal section means delayed union. Delayed union does not, however, mean prolapse, as may be readily proven by statistics.

11. The patient must be unusually quiet to avoid prolapse.

12. Early inspection is necessary to discover prolapsed iris.

The existence of prolapse may usually be diagnosed before the bandage is removed. The patient's statement of sudden pain with a gush of warm fluid from the eye is usually diagnostic. If such a history is not obtained, the

eye may remain bandaged. It is my preference, however, to examine every eye at the end of twenty-four hours. I have yet to learn of a prolapse or a suppuration directly attributable to early inspection of the eye.

13. Astigmatism is higher after iris prolapse.

14. The pupil is not always round and movable.

This is due to posterior synechiæ, the margins of the cut capsule becoming adherent to the iris. Careful performance of the capsulotomy in the periphery of the lens, together with the judicious use of atropin, will do much to prevent synechiæ.

15. Retroversion of the iris.

This occurs very exceptionally after prolapse of the vitreous, and affects only the cosmetic appearance of the eye.

16. Secondary cataract is not so easily treated.

With the pupil dilated with atropin, there is usually ample room to perform discission. If the pupil is small from posterior synechiæ, a sufficient opening may still be easily made if discission is performed within two to six weeks after the cataract extraction and before the capsule has become tough.

If now we consider the operation of simple extraction from the operator's view point, it is my opinion that the "personal equation" enters largely into the method which an operator adopts. Operators who are handicapped by inability to perform some step well or to handle certain instruments skillfully will naturally follow the method which does not expose their weakness. An operator will therefore select that method which gives him the best results according to his skill.

From the patient's standpoint the desiderata are: First, and most important, integrity of the eye and sight; second,

cosmetic result; and third, time. These, I believe, are best conserved by simple extraction.

To sum up, I quote Dr. Knapp's statement: "Simple extraction is not only the best but also the safest operation for senile cataract and many other cataracts."

CHAPTER IV.

COMBINED EXTRACTION VERSUS SIMPLE EXTRACTION.

J. H. WOODWARD, M. D.

IN discussing the question of choice between the operation of combined extraction and the operation of simple extraction, I may conveniently and practically group the arguments to be presented for consideration under four general headings, viz.:

I. Considerations pertaining to the technic of the operations.

II. Conditions observed during the period beginning with the completion of the operation and ending with the subsidence of all postoperative irritability.

III. The ultimate results of the operations.

IV. The range of their applicability.

I. TECHNIC.

The *simple operation* possesses the following advantages over the combined operation:

- (a) It is more easily performed.
- (b) It is more quickly performed.
- (c) It is less painful.
- (d) It inflicts a lesser traumatism on the eyeball.
- (e) It exposes the eye to a lesser danger of infection, by virtue of the employment of fewer instruments in its execution.

On the other hand the *combined operation* exposes the eye—

(a) To a lesser danger of prolapse of the vitreous.

(b) To a lesser danger of dislocation of the lens into the vitreous.

(c) To a lesser danger of revolution of the lens on its horizontal axis.

(d) To no danger from prolapse of the iris.

In the matter of technic, therefore, each operation presents notable advantages over its rival, and they are to this extent pretty evenly balanced.

Whatever others may think of the importance of *prolapse of the vitreous*, my opinion is fixed that it is an accident to be avoided with every care. For even though the loss of vitreous may amount to but a drop or two, and even though the wound may heal and the eye be useful again, in the greater number of cases in which vitreous has been lost the day will come when the baneful effects of that loss will be manifest in depreciation of vision or actual blindness. I do not contend that there may be no exceptions to this rule; but I do not hesitate to affirm that prolapse of vitreous is a disaster; and that whenever I choose to perform a simple extraction, I am conscious of exposing my patient to the risks of that accident to a greater degree than I would have done by choosing to perform upon him the combined operation.

Nothing can be more admirable than the skillful performance of the simple operation in the simplest way, namely, by the agency of a single instrument—the cataract knife. I have heard this operation ridiculed as a “play to the gallery.” But actual personal experience in a sufficiently large number of cases has convinced me that great security against prolapse of vitreous is obtained by eliminating the

speculum and the fixation forceps. Prompted to the undertaking by observation of the masterly work of Trousseau, some twelve or fourteen years ago, I proceeded immediately to dispense with the speculum and fixation forceps, not only in my simple extractions, but also in my combined operations. Thus the two operations were more closely approximated in simplicity, as well as in security from accident through involuntary contractions of the orbicularis and of the recti muscles in the critical moments of the operation. Practically, therefore, according to my experience since this modification of technic, vitreous is lost only through faulty manipulation in the delivery of the lens. It follows as a corollary that prolapse of the vitreous is more likely to occur in the simple operation, because the lens is less readily delivered through the round pupil than through the key-hole pupil. Preliminary atropinization does not modify this statement.

Prolapse of iris during simple extraction is not uncommon. The prolapse may be easily reduced, as a rule, leaving a round, central pupil. It may be queried, however, whether a large prolapse, although perfectly replaced, is not likely to be succeeded by a secondary prolapse in the early postoperative days. At any rate, it seems to me that that is the fact; and personally, I prefer to excise a large prolapse of the iris at once, rather than persist in a determination to complete a simple operation.

The *combined* operation, on the other hand, is much more difficult to perform well than is the *simple* operation and it consumes a longer time. Both of these considerations may be important, according to the temperament of the surgeon and the peculiarities of the patient.

II. CONDITIONS OBSERVED DURING THE PERIOD BEGINNING
WITH THE COMPLETION OF THE OPERATION AND END-
ING WITH THE SUBSIDENCE OF ALL POST-
OPERATIVE IRRITABILITY.

From the practical standpoint, there is no choice between the operations so far as the healing process is concerned. The chances of infection are intrinsically somewhat greater in combined extraction; but the operations may be equalized, in this respect, by sufficient attention to asepsis. I would not contend that iritis is more likely to occur in the one case than in the other; although it is true that when it does supervene after the simple operation, posterior synechia and occlusion of the pupil are more seriously threatened.

Every surgeon who performs the simple operation often enough will observe a condition that makes the crucial difference between the two methods of extraction. I refer, of course, to postoperative prolapse of the iris. Sometimes the causes of it are clearly defined; in other instances they are more or less theoretical and uncertain. We may have our fixed ideas on this subject, but often we are not able to demonstrate that they are true. After all is said, the fact remains that no operator is wise enough, no matter how many thousand simple extractions he may have completed, to say with authority that in one case there will be no prolapse of the iris while in another a prolapse will occur. No method yet devised will insure against occurrence of prolapse of the iris in an important percentage of simple extractions before the healing of the corneal wound can prevent it. Therefore, the contention will hold, that, so far as the prescience of the surgeon goes, the occurrence of prolapse of the iris after simple extraction is more or less a matter of chance.

It would be superfluous to dwell upon the baneful effects of the accident we are discussing. I suppose it is familiar to every one that the range of those effects may be from a comparatively harmless condition to a state that requires the greatest patience and skill to rescue the eye from total blindness. Its occurrence subjects the patient to one or more operations he was not prepared for; and, after it, the most brilliant ultimate result procured by the most skilled operator is very rarely, if ever, as good as would have been obtained with great certainty by a combined extraction.

III. THE ULTIMATE RESULTS OF THE OPERATIONS.

After either operation, I think a discission of the capsule should be made as a routine practice. For a certain length of time, in a certain number of cases, satisfactory vision may be obtained without a discission operation. But I prefer to perform it in practically every case of cataract extraction. This having been done, I may say that, so far as regards function, I have not been able to detect any essential difference between the results obtained by the two methods, either for distance seeing or for reading and writing. But, so far as regards the physical appearance of the operated eye, there is a wide difference between the effects of the two methods. The coloboma resulting from the iridectomy is disfiguring. The appearance of the eye after a successful simple extraction, however, leaves nothing to be desired; the cosmetic result is admirable. And I must confess that this argument in favor of simple extraction appeals to me very strongly. There are cases in which to obtain such perfection it were well worth while to take large risks. But, excepting a limited number of special cases, yielding to such temptation is done not really in behalf of the true

interests of the patient, but as a sacrifice to the enthusiasm of the operating surgeon.

IV. THE RANGE OF APPLICABILITY OF THE OPERATIONS.

Up to this point in the argument, we may consider that we have been assuming the case to be operated upon a mature senile cataract, in every particular suitable for an extraction operation of one sort or the other. Let us turn now to a brief examination of cases presenting other characteristics, and I shall refer only to cases of immature and hypermature uncomplicated senile cataract, for the time allotted me is too limited to permit any excursion into the field of traumatic, pathologic or complicated cataract.

The fundamental question that arises at this point is, at what stage of the development of senile cataract shall the extraction be performed? Must we wait until the cataract is matured before operating or shall we operate when function is so far impaired that the patient is not able to go about alone or to read or sew?

If we decide to wait until the maturity of the caratact is demonstrable, we shall frequently compel the patient to submit to months or years of helpless waiting, with all the attendant psychical and physical evil effects. I contend that such a decision is a condemnation both cruel and unjustifiable, destructive of the happiness of the victim and jeopardizing to his mental and physical wellbeing; and the moment I became conscious of the truth of these things, I began to operate upon cataracts before they were mature, as soon as the visual function had been sufficiently obscured to prevent the patient either from going about alone or from reading or sewing. The only regret I have in this regard is that I did not begin the practice earlier. This

manner of proceeding opens up a large field to which the simple method of extraction is not well adapted. It is not well adapted to the extraction of immature senile cataract, because, notwithstanding our assiduous efforts, we often fail to remove all of the cortex from the posterior chamber. The *débris* will swell under the action of the aqueous, and thus promote a prolapse of the iris or precipitate an attack of iritis. In this regard, like the pilot who knew the harbor because he had run a ship upon every sunken rock within its confines, I feel that I may speak as one who has had an enlightening experience. On the other hand, combined extraction is a satisfactory operation in this class of cases, and it may be safely performed without resort to any preliminary interference for ripening the cataract.

Finally, I would put one other restriction upon the applicability of the simple operation, and reject it whenever we are dealing with a hypermature senile cataract. The cortex of such lenses, as you know, is oftentimes as tenacious as glue, and after the delivery there remains in the posterior chamber a quantity of sticky *débris* that is removed with the greatest difficulty, even under the most favorable conditions. In other cases, the *débris* does not present such sticky properties, but it is also difficult to remove. In either case, it is very hazardous to leave any such substances in the posterior chamber, for they seem to possess extraordinary irritating properties. Massage, spooning and irrigation of the posterior chamber through the round pupil do not offer to my mind a sufficient guarantee against disaster from such cortical remains. Of all the cataracts that I have had occasion to operate upon, I look upon these as the most difficult to bring to a happy ending, and I am convinced that they are not at all suitable for the simple operation.

DISCUSSION.

DR. E. GRUENING thought that, when trained assistants could be obtained, the simple extraction was, as a rule, preferable. He had seen the operation with the Graefe knife alone performed in twelve cases; in three, prolapse of vitreous had resulted. As a method for all cases, he was not impressed with it, though of the final results he could not speak. Cases of hypermature cataract were especially suitable for the simple extraction. He was convinced that a patient was better with a round pupil and that healing was shorter by the simple method than by the combined. To avoid prolapse of the iris he instilled a 10 per cent. solution of cocain into the eye in order to produce a condition of hypotony which lasted several hours. In irritable or unruly patients he always performed an iridectomy.

DR. DAVID WEBSTER stated that an iris prolapse, occurring after the iris had once been replaced, usually necessitated iridectomy as soon as the prolapse was found, but these secondary iridectomies were very unpleasant for the patient and for the operator, and for this reason, during the past two years, he had performed more combined than simple operations. The secondary prolapses were due more often to the super-accumulation and subsequent expulsion of aqueous than to any act of the patient himself. He had recently performed some preliminary iridectomies, and had been very well satisfied with this method of operating. He did not think that the simple method gave any better vision than the combined.

DR. J. R. SHANNON preferred simple extraction, other things being equal. He thought that vision was just about as good by one method as by the other, and the rapidity of recovery in uncomplicated cases about the same.

DR. C. KOLLER thought that we were gradually doing more and more combined operations, and this might be due to the fact that more and more immature cataracts were operated upon than formerly. Prolapse of the capsule took place in many cases of combined extraction in spite of the most perfect toilet of the wound. As a result of this, the wound frequently remained red and injected for a long time, and many cases of insidious cyclitis thus originated, and he had even seen sympathetic ophthalmia follow.

DR. J. E. WEEKS thought that the combined method was becoming more and more the usual operation. The great desideratum in all cases was good vision; the cosmetic effect was a secondary consideration. This was especially the case in old people, and it was in old people that we were most frequently called upon to operate. The combined method left no anxiety as to prolapse and subsequent trouble to surgeon and patient. Cases for simple extraction should be very carefully selected. At present he performed the simple operation in about 30 per cent. of his patients.

DR. W. B. MARPLE spoke in favor of the preliminary iridectomy and said he performed the combined method more and more frequently.

DR. W. E. LAMBERT thought the combined method much safer and the visual results equally good. He spoke in favor of the preliminary iridectomy.

DR. F. VALK stated that in his experience the results of preliminary iridectomy had been the worst. In his cases of simple extraction prolapses had been few in number.

DR. C. B. MEDING thought it was exceedingly difficult, and in most cases impossible, to tell beforehand when prolapse

would take place and when it would not. He thought that most of us started out with the idea of doing the simple operation. We were frequently disappointed and had to abscise the resulting prolapse of the iris. He called attention to the fact that in many cases of simple extraction the resulting pupil was not central.

DR. PERCY FRIDENBERG thought that if hypnotics were more frequently given before and after operation, the results might be better. The speculum was a dangerous instrument. The lid retractor should be used instead whenever possible.

In concluding, Dr. Coburn remarked that a number of objections might be raised against the combined operation: iridectomy was an unnecessary traumatism; cosmetic results were not so pleasing; visual fields and visual acuity were impaired; the operation was more difficult to perform; it was a simple extraction together with an iridectomy; the cutting of the iris was frequently painful and caused the patient to become unruly; the iridectomy was often incorrectly done and the columns of the coloboma were not properly replaced; blood in the anterior chamber from the cut iris obscured the field of operation and necessitated immediate lavage with attendant risk of infection; tags of capsule and pieces of lens substance were apt to become entangled in the lips of the wound; prolapse of the vitreous was more frequent; iritis was more common; more instruments were required; hence more danger of infection; the operation was longer; an assistant was necessary.

He said that these objections to the combined operation were confirmed by the statistics of Dr. W. F. Ring (Medical Record, February 23, 1895) who collated the results of 1032 combined extractions made by operators of recognized ability in America and Europe.

	Simple.	Combined.
Prolapse of vitreous.....	4.27%	7.23%
Average vision after vitreous prolapse,	0.29..	0.23..
Incarceration of iris	4.00..	4.82..
Prolapse of iris	8.60..	None
Iritis	11.82..	13.15..
Suppuration.....	1.30..	1.91..
Discission.....	33.04..	27.61..
Perfect success	90.82..	88.08..
Partial success	6.30..	7.45..
Failure	2.88..	4.47..
Average vision.....	0.48..	0.34..

These figures showed that in spite of the dreaded iris prolapse, perfect success and average vision are greater in simple extraction; while iritis, prolapse of vitreous, suppuration, and total failure are more common in the combined method.

[It requires no great experience to have seen the pendulum swing back and forth with regard to the alternate popularity of the simple and the combined extraction. The probability is, some surgeons will continue to do one and some the other operation.

Everyone, however, admits that there are cases in which the simple operation is not indicated and should not be performed, and everyone likewise admits that there is no case in which the combined operation may not be performed. It is, therefore, a good rule of action, to perform the combined extraction in all cases.

When a patient comes to a surgeon to have a cataract extracted, he usually places himself unreservedly in his hands. He knows nothing about the merits and demerits of the simple and the combined extraction. Being old, as

a rule, he likewise has passed the age of vanity and cares little or nothing about cosmetic results. His one object and earnest prayer is that he may receive his sight. It therefore behooves the surgeon to give him every advantage and to run no risk in operating that is not necessary in the nature of things. Ring's table, as quoted by Coburn, shows that 8.60 per cent. of prolapse of the iris occurs after the simple extraction.

When prolapse occurs a second operation is necessary within twenty-four hours.

The economics of the situation, from the standpoint of the patient, is a factor which cannot be ignored in many cases. Furthermore, a second operation is undertaken after a trying and nerve-racking night; the morale of the patient has suffered considerably in consequence, and it is further weakened by the knowledge of the accident and of the necessity of another operation. These systemic and psychic effects are particularly important when the operation of abscission is attempted under cocain anesthesia. I once attempted abscission of the prolapsed iris, under cocain, on a woman who had behaved perfectly the day before at the simple extraction. When the iris was seized with forceps, she sat bolt upright, screamed and squeezed her lids together with all her might. The wound was opened, one-half of the vitreous was lost, and the eyeball filled with blood. The eye finally healed with an up-drawn iris and elimination of the pupil, though the projection of light through the tense iris was good. General anesthesia should have been employed in this case and should be employed in all these cases.

The prolapsed iris is exquisitely sensitive, the morale of the patients is weakened, and, under the circumstances, no reliance can be placed on their self-control.

Simple extraction is so simple and beautiful when skillfully done, and the results when they are good, are so pleasing to both patient and surgeon, that one can almost be excused for indulging his artistic sense to the risk or detriment of the eye.

But as good surgeons and faithful counsellors, it becomes us to sacrifice every consideration to the sole object—*sight!* It matters not one whit that the statistics quoted show that the percentage of failure after the combined is greater by 1.69 per cent. (4.47-2.88) than that after the simple extraction, for the fact remains that in 8.60 per cent. prolapse occurs in the simple, whereas it cannot occur in the combined operation.

Let us hear the conclusion of the whole matter:

Simple extraction necessitates a second operation in 8.60 per cent., and the second operation involves obvious additional risks; no secondary operation is required after the combined extraction. Therefore, the combined operation presents less risk, and consequently gives the patient better chances for sight. J. H. C.]

CHAPTER V.

THE TECHNIC OF THE SIMPLE AND OF THE COMBINED OPERATION FOR THE EXTRACTION OF MATURE SENILE CATARACT.

PERCY FRIDENBERG, M. D.

JUST two centuries have elapsed since Charles St. Yves first removed a lens from the eye by corneal section. For two centuries the technic of cataract extraction has claimed a large measure of the thought of ophthalmologists, and the history of its development forms one of the most attractive chapters in modern medicine. The modern operation for the extraction of cataract is, in its larger features, traditional, established, typical; while on the other hand, there is still divergence of opinion and practice in regard to minor details. It is scarcely an exaggeration to say that while we are in substantial agreement as to the aims of the operation, and in somewhat less a measure as to the procedures by which those aims are to be attained, no two surgeons carry out details exactly in the same order and in the same manner. Accordingly, this paper aims to present as briefly as possible an outline of the type operation, with somewhat closer attention to the more usual variations in the successive steps.

To describe a typical operation would be to present the method of a single operator, who alone would find this method a typical one and exclude all others, while to detail the consensus or preponderance of opinion and practice in

regard to each step would offer a composite portrait for which there is no single prototype. The procedure to be described is the extraction of senile cataract by peripheral flap section, without and with iridectomy, to which Wecker first applied the terms "simple" and "combined" operation respectively.

THE SIMPLE OPERATION

May be described in brief, as follows: The anterior chamber is opened with the Graefe knife by a large arched section upward in the margin of the cornea. The lense capsule is opened instrumentally, and the lens delivered by sliding pressure on the globe. Cortical remnants are removed from the anterior chamber, and the section is freed from all extraneous matter (toilet of the wound).

Each and every one of these steps has been variously modified, either in the manner of its performance, the instruments used or order of procedure. A more detailed consideration of each step is now in order.

RETRACTION OF THE LIDS AND FIXATION OF THE GLOBE.

The lids may be held open by the fingers of an assistant, by lid-holders or mechanically by an eye-speculum. The first is undoubtedly the least annoying for the patient, and when carefully performed the safest, but it requires an additional well-trained assistant, and on account of the space taken up by his hands renders certain maneuvers more difficult. There is always a possibility of the finger slipping or of pressure being made on the globe by a sudden closure of the lid by the patient or by carelessness of the assistant. This is complicated in deep-seated eyes by the difficulty of raising the upper lid sufficiently. Desmarre's

lid-holder acts much like the mechanical finger. The broad plate covers the entire lid margin and also keeps the lashes out of the way. In both cases the lids are lifted away from the surface of the globe, and no pressure can be made even with vigorous squeezing on the part of the patient and contraction of the peripheral portions of the lids. Extreme gentleness and care are required in the manipulation of the instrument to avoid excessive stretching of the lids and causation of pain, to avoid pressure on the globe, and at the same time to keep the eye well opened. If the handle of the lid-holder is held too flat the lid is apt to slip out; if raised too steeply, its edge is apt to catch under the orbital margin, causing pain and preventing complete opening of the lids in spite of all traction. A mechanical speculum replaces an assistant. Most models merely separate the lids but do not raise them from the globe, and none can effectually exclude pressure on the eye-ball in case of spasmodic contracture of the lids. This is particularly noticeable in prominent eyes and tight lids. It may be necessary to have the speculum held away from the globe by an assistant. This instrument is most valuable in small, deep-seated eyes. It should be easily introduced, rapidly removed and cause no pain when in situ.

FIXATION OF THE GLOBE.

For this purpose forceps with broad finely-toothed ends are generally employed. They should not press or draw upon the globe, but merely fix it in the position taken at the command of the operator. A catch is not necessary and may interfere with the rapid removal of the instrument. Fixation is generally applied near the corneal margin, as the conjunctiva in this region is less elastic and a better hold is afforded. A broad bite aids materially and is less apt to be

followed by tearing. The lower end of the horizontal meridian is usually chosen for the fixation point as the eye can be kept looking downward most easily and the forceps are least in the way. A point opposite the commencement of the corneal section and directly back of the intended counter-puncture is preferred by some for two reasons: Counter-pressure can be made more easily; the eye does not tend to roll before the knife, and the point of exit of this instrument is marked so that the section can be more exactly and surely carried out. A point near the corneal margin and half-way between those already mentioned, the so-called 45° position, is chosen by others who believe that it shares the advantages of the first two without their objectionable features. Fixation of the tendon of the superior rectus was advised to replace the speculum or lid-holder and to enable the operator to raise the globe at will and at all times to keep its movements under his control. Most forceps used for this purpose have the disadvantage that they are not sufficiently broad to prevent the lid in case of violent squeezing from closing around the fixation-forceps and pressing on the globe; that they do not open the lids wide enough, and that they do not keep the lashes out of the way. The last objection, naturally, does not apply in case the lashes have been cut or shaved off before operation. The advantages of this fixation are that no pressure is made on the globe, the section is made with ease on account of the eye being firmly fixed by counter-pressure of forceps and knife, and as the scleral margin of the section is slightly raised, the iris tends to return to the anterior chamber of its own accord. On the other hand, it has been claimed that this fixation is painful to the patient, causes marked spasm of the lids, and does not insure reliable fixation, as the globe may rotate before the knife.

OPENING OF THE ANTERIOR CHAMBER.

The section is made with the Graefe knife, held like a teaspoon (Haab). A fairly broad (2 mm.) knife is less apt to injure the iris, and in case the latter should touch the blade, a slight inclination of its axis will free the cutting edge. On the other hand, there is more apt to be escape of aqueous, and in case it should be necessary to alter the plane of the section, more danger of distortion of the wound, irregularity in its form, and traumatism of the tissues. The knife is applied to the eye, cutting edge upward (and it is well to assure oneself of this invariably), with the blade in the anterior basal plane of the cornea, its cutting edge directed vertically upward and very slightly forward, and the point in the corneal margin, or $\frac{1}{4}$ to $\frac{1}{2}$ mm. behind it, at or slightly above the temporal end of the horizontal meridian. Before actually making the section, the line from puncture to counter-puncture may be "addressed," to borrow a term from golf, by passing the knife over the cornea in the line of the section. This assists direction, and at the same time we may assure ourselves of the knife being right side up. The section is to take in from three-sevenths to one-half of the periphery, according to the size of the cornea and the probable dimensions of the nucleus. The knife is carried steadily but not too rapidly across the anterior chamber in a horizontal direction and caused to emerge directly opposite the puncture in the corneal margin. The advice is given to have the point engage the inner surface of the cornea when it appears to be 1 mm. from the margin. The point will then emerge exactly in the limbus. In case of a shallow anterior chamber it may be necessary to depress the handle of the knife so that the point rises out of the plane of the corneal base and passes nearer the posterior surface of that mem-

brane. After passing the pupil it must then be carried deeper so as to reach the intended counter-puncture. In this case the point of the knife describes an arc with its convexity forward. After piercing the cornea at the point of entrance the knife must under no circumstances be withdrawn. After emerging at the counter-puncture, the knife is carried forward and upward and the cornea cut through with a sawing motion, and little pressure on the cutting edge, care being taken that the section lies everywhere in the limbus. The blade of the knife may be turned backward slightly after the counter-puncture has been made. In this way the line of the section will encroach very slightly on the sclera, giving better conditions for prompt healing and facilitating the formation of a conjunctival flap which shall extend almost the entire length of the section instead of being limited to its summit. The back of the knife may be used to raise the cornea slightly and so prevent the iris falling over the cutting edge of the knife. In myopic eyes or others with a large cornea, the section may be a trifle within the corneal margin. An inclination of the edge is only necessary in case the section is not of the right size, in which case the blade may have to be turned slightly backward or forward to modify the extent of the section. It has been claimed that sawing motions are unnecessary and that with a sharp knife the cornea can be entirely divided with one forward and one backward stroke. If the knife is carried too far on the forward stroke there is danger of its striking the lid-angle and causing an involuntary movement of the patient. A slight inclination of the patient's head to non-operated side allows the globe to be rotated more into the temporal half of the lid-fissure.


As the end of the section is approached the stroke is made very gently, and the knife allowed, as the saying goes, to cut

its way out alone. The blade emerges in the limbus and raises a small bridge of conjunctiva. If a conjunctival flap is desired, the edge of the knife is turned directly upward, cutting a flap 2 to 3 mm. broad. If the conjunctiva is very lax the flap may be much broader than this. If, on cutting out of the cornea, the edge of the knife is turned directly forward, the conjunctiva is cut through close to the cornea and no flap is formed.

At this stage it is the custom of some operators to remove the speculum or to have it held away from the globe. The conjunctival flap is stroked back over the cornea and then lies only on the proximal lip of the section.

OPENING OF THE LENS CAPSULE.

This may be accomplished by incision with a cystitome or by exsection of a piece of the capsule with special forceps. The former procedure is the usual one. As the cystotome is generally introduced from the temporal side the shank of the instrument, which should not be rigid, may be bent about 6 to 7 mm. from its point. This is advisable in case the eye is deep set or the patient does not look well down. The cutting end can then be carried straight downward across the anterior chamber and more carefully controlled by the eye. The instrument is introduced into the eye and carried downward with the cutting edge parallel to the posterior surface of the cornea and turned through an angle of 90° as soon as the point has been reached where the capsule is to be incised. The cut is generally carried from below upward, and only sufficient pressure made to tear through the capsule. There is great diversity in the performance of this step, particularly as to the number of incisions and their position. The underlying principles are, however, the same, viz., to make a large opening for the

escape of the lens and of as much cortex as possible, leaving a space which would not be apt to be occluded in the course of healing, and to avoid random laceration producing capsule flaps which might become caught in the wound. In median capsulotomy, the attempt is made to circumscribe a square of the capsule which may be extruded or extracted with the lens, or folds back from the pupillary area like a curtain. Horizontal incisions, one above and one below, are considered sufficient for the delivery of the lens and, it is claimed, do not tend to become entangled in the section—an objection which has been raised against all vertical cuts. Crucial incision is often used, or the opening may have the form of a V, Y,  or inverted triangle.

The object of this modification was to avoid the entrance of capsule tags into the section, to prevent adhesion of the wound margins of the capsule with the iris or the edges of the coloboma, or of the anterior with the posterior capsule and consequent inclusion of cortical remnants with the formation of dense after-cataract. The incision is T-shaped or it may consist of a single cut in the upper equator of the lens equal in extent to the corneal section. This linear wound heals exactly in the same manner as the corneal section. There is no irritation of the iris, and no adhesion of the pupillary margin to the capsule. Blood or cortical remnants which have remained in the capsule sac may take somewhat longer to be absorbed than after median cystotomy. Discission of secondary cataract is generally necessary to clear the pupillary area. The capsule may adhere to the corneal wound, but this is infrequent.

EXCISION OF A PORTION OF THE CAPSULE.

This is performed with fine curved forceps armed with teeth on the posterior aspect of the point. They are intro-

duced into the anterior chamber while closed, opened in the middle of the pupil, and a fold 3 to 4 mm. broad pinched up. The advice is given to carry the forceps downward toward the opposite pupillary margin after grasping the capsule so that the portion grasped shall tear off from the lens at its upper attachment, thus avoiding a tongue-shaped flap which might be carried up into the corneal section. The procedure is especially adapted to tough capsules, but may fail entirely in the case of much thickened or tightly stretched capsule in swollen lenses or very soft or fluid cortex (Morgagnian cataract) as the forceps does not grasp in these cases or, again, the capsule bursts and the resulting opening is irregular. The excised piece is often 6 to 7 mm. in diameter and always larger than the portion actually grasped by the forceps, as the capsule tears more easily in the neighborhood of its equator, and the pupillary area is left completely free. There is practically no possibility of incarceration of capsule. Luxation of the lens is said to be less frequent than with the use of the cystotome, the sharp blade of which may penetrate too deep. In case the capsule does not tear through, the lens is brought forward toward the wound. This has been cited as an advantage, as the lens may then be extracted intact, or the capsule breaks during the delivery of the lens and may subsequently be extracted with forceps.

Opening the capsule with the knife during the corneal section has the single advantage of reducing the number of instruments to be introduced into the eye. Its disadvantages and dangers are so obvious and serious that they scarcely require to be detailed. The section is apt to be irregular or faulty on account of the repeated alterations of direction and plane. Cortical masses may fill the anterior chamber and obscure the field, rendering counter-puncture

inexact. The point of the knife may become wedged in the nucleus and require to be drawn back and out of the eye. The entire lens may be dislocated or pushed to one side in such a way as to crowd the iris before it and cause injury to that membrane. Capsule or cortex may be carried into the section and jeopardize prompt healing. The capsulotomy is rarely well placed or sufficiently large to allow easy delivery of the lens and to guarantee a free pupillary area.

DELIVERY OF THE LENS.

The procedure is mechanically an expulsion or expression rather than an extraction. It may be performed directly with instruments, notably the spatula, iris-repositor and spoon or finally with the ball of the finger, and indirectly through the medium of the lids. The last two forms are objectionable from the point of view of ideal asepsis, although the use of a sterile finger cot, in one case, and care against allowing the lids to rub against the wound margin, in the other, would minimize these disadvantages. The amount of pressure and its direction can be more easily applied and altered and gauged in this way than with any instrument. Some operators use the lid pressure for the expression of cortical remnants only after the lens has been delivered with instruments. Pressure is usually applied just above the scleral lip of the wound so as to cause slight gaping, the spatula or spoon lying parallel with the section. This aids in the passage of the upper lens margin past the pupillary edge of the iris and prevents the lens catching under the upper, i. e., peripheral scleral lip of the wound section. A second spoon is applied to the lower limbus and slight pressure made backward and the spoon slid upward. The lens turns on its frontal axis

reaching the pupillary margin and, rising, carries the latter with it. The necessary inclination of the lens is 30 to 40°. The corneal flap is raised and the wound gapes widely. Pressure on the upper lip may be continued until the largest diameter of the lens has passed through the wound. In case the iris tends to be drawn into the wound the spatula held flat may be used to hold it back or even to stroke the sphincter down along the posterior surface of the lens and so facilitate delivery. Toward the end of this process little pressure is required, sliding of the spoon being quite sufficient to carry the lens out of the wound and to lift it from the eye. If the section has been large enough, the lens is delivered with ease and very little cortex need be rubbed off in the passage of the lens through the wound. All these mechanical, external measures, no matter how gently carried out, tend to increase tension in the vitreous besides causing some local deformation, however temporary, as shown by the gaping of the wound and the production of inclined planes on the surface of the cornea. In case of actual or threatened loss of vitreous this must be carefully avoided, and it is practically in such cases only, e. g., subluxation of the lens or tearing of the zonule during the operation, that extraction in the restricted sense is practiced, and a spoon, loop, sharp hook or forceps passed into the anterior chamber to draw out the lens. Delivery of the lens may be rendered difficult by insufficient length or faulty position of the section, a rigid iris, incomplete laceration of the capsule or dislocation of the lens.

TOILET OF THE WOUND.

This step includes the removal of cortical remnants, blood and any other extraneous matter from the anterior chamber and from the corneal section, reposition or abscission of

displaced or incarcerated iris, capsule or prolapsed vitreous and, finally, the adaptation of the wound edges and of the conjunctival flap.

Cortical remnants may be expressed with spatula or spoon, the finger tip or the lid. The choice of procedure is the same as in the delivery of the lens. The introduction of instruments into the anterior chamber for this purpose has been almost completely abandoned. The use of irrigation for the removal of débris is considered inadvisable by so good an authority as Hess; and both this author, Czermak, and Snellen recommend the introduction of a spoon in preference. Irrigation of the anterior chamber is perhaps the most valuable of recent modifications in cataract technique. Sterile, normal, i. e., physiological salt solution is the safest, because least irritating, fluid for this purpose. A rubber bulb with glass pipette ending in a short, fine angular tip, has the advantage over all gravity apparatus and syringes of being easily disinfected, absolutely under control, requiring but one hand, and never getting out of order. In many cases it is not necessary to pass the tip into the anterior chamber, depression of the posterior wound lip and irrigation from this point being sufficient to clear the field completely, so that the possible objection against introducing another instrument into the eye carries little weight. Besides the mechanical removal of débris, irrigation is of value in that it tends to unfold and spread out the iris, thus acting as an aid in prevention of incarceration and prolapse. This agency is still further aided by stimulation of the sphincter by the stream of fluid, so that there is a tendency to contraction of the pupil. In case an iridectomy has been performed, the hemostatic action of the irrigation and its value in removing blood and so providing a clear field for the subsequent capsulotomy and extraction are

worthy of consideration. The mechanical removal of débris which serves as a nidus for infection, and the flushing out of any micro-organisms which have possibly been introduced into the eye up to this point, are indirect aids to asepsis and prompt healing whose importance cannot be overestimated. In case of collapse of the cornea the anterior chamber may be filled by means of irrigation and the normal curvature of the globe re-established. This materially aids in adaptation of the wound edges and so facilitates prompt healing.

Contraction of the sphincter of the iris may be stimulated by circular massage of the cornea. This was formerly used in case of limited prolapse of the iris, and is still employed to smooth out the iris when an irregular pupil warns us that there is a fold in some part of the membrane. Reposition of the iris should be attempted as soon as prolapse occurs, no matter at what stage of the operation this accident happens. The longer it remains in the wound, the more it is subjected to mechanical insult, the greater the danger of consecutive iritis. Reactive swelling and imbibition alone may make clean removal impossible, and when the bruised and swollen iris does not retract promptly or spread out evenly, it tends to prolapse again. The spatula is most generally used for the purpose of reposition; it should be passed from either angle of the wound diagonally downward toward the margin of the pupil or the angle of the coloboma. Excision of the prolapsed iris is the general practice. The reposition of the angles of the coloboma and the clearing of the angles of the wound are of great importance. Capsule shreds, blood coagula, etc., are removed with a fine clot forceps. A spatula is passed from end to end of the wound or a fine-toothed forceps carried through it and opened and closed several times. The conjunctival flap

is stroked back over the scleral lip of the section, and the spatula again stroked over the region of the wound, smoothing it in its entire extent. The conjunctival sac is then gently washed out, any débris which may remain being removed with clot forceps or wipes, and the eye is closed.

COMBINED EXTRACTION.

PERIPHERAL FLAP EXTRACTION WITH IRIDECTOMY.

The anterior chamber is opened with a section upward in the corneal margin which measures one-third to two-fifths of the periphery. A piece of iris is excised. Capsulotomy. Delivery of the lens. Removal of cortical remnants and toilet of the wound.

The section may be smaller than in simple extraction. The section lies in the limbus or $\frac{1}{4}$ to $\frac{1}{2}$ mm. behind it, and terminates in a conjunctival flap.

EXCISION OF THE IRIS.

One per cent. holocain dropped on the section wound and on the iris when drawn out renders this step almost painless. The speculum may be lifted or removed altogether. The fixation forceps may also be removed, but unless we can count on the patient remaining quiet there is danger of the iris being torn loose or of the iridectomy being irregular. The fixation may be entrusted to an assistant or the operator may continue to hold the forceps while a trained aid cuts off the iris. The former procedure is the general rule and by far the safer. The iris is drawn out of the anterior chamber with curved forceps. In case of prolapse, either this instrument or a straight forceps may be used. The forceps is closed, carried into the anterior chamber until it has nearly reached the pupillary margin, opened about 2 mm. and the

iris is grasped and drawn out of the wound. The iris is cut off as close as possible to the cornea by means of DeWecker's scissors or an ordinary curved iris scissors, slight pressure being made against the lips of the section with the scissors, and the iris cut through in two strokes. It is well to draw the iris a little away from the angles of the wound as the cuts are made, in order to free it as much as possible and to aid complete reposition. DeWecker's scissors may be held at right angles or parallel to the corneal section and the iridectomy done with one snip. In the former case the coloboma is narrow with parallel or slightly converging margins. When the scissors are held parallel to the corneal section, the iridectomy is broader and the margins diverge, the amount of this divergence depending on the amount of tissue cut away near the ciliary attachment. This varies directly and in proportion to the pressure on the wound with the scissors, i. e., the length of the cut, and with the amount of iris drawn out with the forceps.

In any case, the angles of the coloboma should lie in the anterior chamber and be at the same height. In case of incarceration, the corresponding sphincter angle stands higher than the other. If both margins are incarcerated, the pupil appears oval. Reposition is effected with the spatula. The instrument is carried flat into the angle of the section, its axis at a sharp angle with the vertical axis of the cornea so that it points toward the pupillary margin of the corresponding side at about the level of the middle of the pupil. The point is then stroked toward the middle of the pupil or the angle of the coloboma, unfolding the iris.

This reposition should take place immediately for the reasons mentioned in the description of the simple extraction. Hemorrhage from the conjunctival flap from the section or from the iris, may obscure the field. Before proceeding

with capsulotomy the blood should be removed as far as possible. Pressure with a moist cotton pledget or wipe on the posterior lip of the wound will often suck up the blood completely. Irrigation may have to be employed. In case the hemorrhage continues, the lids may have to be closed and an iced compress applied. The instillation of adrenalin usually prevents this accident except in the case of diseased iris or increased tension, complications which are not within the scope of this presentation.

OPENING OF THE CAPSULE.

The introduction of the cystitome and laceration of the capsule in adequate extent is greatly facilitated by the absence of the iris in the upper part of the field. On the other hand, there is greater danger of drawing capsule shreds into the section or of a flap of capsule rolling up of itself and becoming incarcerated in the wound.

DELIVERY OF THE LENS.

The procedure is substantially that already described. Expression is easily effected as the lens margin does not have to incline as far forward as it would have to do if it had to pass the iris. The edges of the coloboma may prolapse before the lens is expressed, requiring reposition or excision, or they may be carried out during delivery. This is apt to occur if the section is too small, in which case the margins of the coloboma rest like epaulets on the shoulders of the lens. In a large section there is wider gaping, the lens inclines forward and the margins of the coloboma slip off to either side. Even without pressure by the lens, the edges of a coloboma may prolapse at either angle of the wound, especially if the latter is small by reason of pressure made by the patient and consequent increase of intraocular

tension. During the excision of these incarcerated portions there is danger of further trouble in the form of a vitreous prolapse and of extrusion of the lens, or of its disappearance in the depths of the globe, so that the greatest care is necessary at this moment.

TOILET OF THE WOUND.

Removal of cortical remnants, particularly those in the upper part of the capsular sac, is greatly simplified. Free irrigation is possible without the necessity of passing the pipette into the anterior chamber, or at least without its being introduced very far. The details of the cleansing of the wound, the reposition of the flap, and the adaptation of the wound edges are identical with those described before.

PERIPHERAL IRIDECTOMY.

Button-hole.—The iris is grasped near the ciliary margin and a small piece excised, allowing the sphincter to remain uninjured. This may be combined with a radial cut through the iris connecting pupil and peripheral button-hole—the modified iridotomy of Verhoeff.

The button-hole procedure requires a perfectly quiet patient. It is difficult to determine the amount of iris tissue to be excised, so that the button-hole is often too large and only a thin strand of sphincter edge is left. Even this may be torn through when the lens is delivered. If the button-hole is too small it is of little value as a preventive of iris-prolapse, and may become entirely occluded. Removal of cortical debris is difficult unless the pipette be passed through the peripheral opening and the masses syringed out from behind. As the iris is grasped near its ciliary attachment, very slight restlessness of the patient may

suffice to cause iridodialysis. The button-hole, if large, may endanger delivery as the upper margin of the lens is apt to catch in it. If practiced after extraction, fixation must be applied or continued and there is danger of the patient pressing.

As to the time of performing iridectomy we must distinguish three possibilities:

Preliminary or preparatory iridectomy, after section with Graefe's knife or keratome, some days or weeks before the actual operation for extraction. The latter operation is modified to the extent that the corneal section, which is made exactly as in the combined operation, is immediately followed by capsulotomy. The advantages of the procedure are that there is no hemorrhage from the iris and generally none from the wound, so that capsulotomy and the removal of débris are rendered easier and more thorough. The operation is simplified to the extent of an extraction without iridectomy, and is probably even safer than the combined operation, as there is less danger of complications; the operation has been shortened by a step, the section is made with great ease and there is no danger of wounding the iris.

Primary iridectomy; i. e., during the operation for extraction. As already stated, this step follows the corneal section.

Secondary iridectomy. This term may be applied to the excision of the iris after laceration of the capsule and delivery of the lens.

It may be an after-thought, and rendered necessary by prolapse of the iris or other accident during operation. It is then not to be considered as an integral part of the operation; the procedure certainly is not to be designated as a combined extraction, as simple extraction through the typical corneal incision and through an undivided sphincter has

already taken place. The iridectomy in this instance is really a step in the toilet of the wound, a secondary measure, and may be termed consecutive iridectomy. In the combined operation, i. e., after the section usually performed in this modification, some operators choose to open the capsule and deliver the lens and make the iridectomy afterwards. The idea is to preserve the iris as long as possible as a protection against incarceration of capsule shreds and also to be able to operate without iridectomy in case it is found that all the cortex can be easily removed and that the iris does not tend to prolapse.

NECESSARY VARIATIONS IN TECHNIC. FAULTS AND ACCIDENTS.

Even in regard to the simplest details in the typical operation there is a lack of absolute unanimity. One standard author says the Graefe knife is to be carried through the chamber deliberately, and that flexion and extension of the wrist alone are to be employed in this manœuvre. Another, no less experienced and renowned, described the mechanism as an extension of the thumb and fingers only, and advises a rapid passage of the blade. We have good authority for "long, sawing motions" (Haab, Hess), and equally good authority for their careful avoidance.

Accidents due to faulty instruments can scarcely be considered in the limited time at our disposal. Attention has been called to the danger of the point of the knife breaking if the instrument is not sufficiently strong, especially if the plane of the blade is altered suddenly or if the point becomes caught between the corneal lamellæ—an accident which is liable to happen if the blade bends under pressure or if the point is blunt and the eye rotates before the knife. A speculum which does not loosen at the right moment, or

a Wecker scissors which binds after closing, a forceps which cannot be opened or which springs open of its own accord at the wrong time, may endanger the success of an operation. Each and all of these accidents are on record.

It is important to determine in advance of the operation or at least of the section, as far and as accurately as possible, the form, consistency, size, mode of origin, development and course of the cataract and, as a matter of course, any unusual abnormality in the condition of the patient.

The diagnosis of the intra-ocular conditions, the size and consistency of the lens, the condition of the iris may have been incomplete or inaccurate, the indications misunderstood, the procedures omitted, or a mistake made in the choice of a procedure. In all these points previous experience is a valuable guide so that, as Snellen puts it, the adage "*Sit chirurgus juvenis*" must be modified by the still more traditional and weighty maxim, "*Experientia docet.*"

Accidents may be due to restlessness, involuntary motion, lack of self-control or stubbornness on the part of the patient—and it is well to remember that such an attitude may be manifested in spite of previous docility and complete anesthesia—or to some shortcomings on the part of the operator. The preparation of the patient and of the field having been considered, we need only call attention again to the importance of careful instruction and of actual training of the patient previous to operation. If the operator himself personally attends to such details, as washing and disinfection of the eye, the instillation of the anesthetic and of any mydriatic which may be employed, the time is well spent in accustoming his patient to the part he is to play, and incidentally in familiarizing the surgeon with the reaction of the patient to local manipulations.

*Though we, exclude such abnormalities and complications of senile cataract, as markedly immature, hypermature, or dislocated lenses, markedly thickened capsule, synechiæ, glaucomatous tension, fluid vitreous, adherent iris, and serious intra-ocular disease or precedent hemorrhage, it must be borne in mind that unforeseen conditions may arise or be discovered during the procedure which must be met by appropriate change in technic. Such individualization is the rule rather than the exception if we consider the possible variations within normal limits in the size, prominence and tension of the globe, the depth of the anterior chamber, the elasticity of the iris, the degree of tension in the vitreous chamber, the amount of aqueous, the thickness and resistance of the cornea, the docility, intelligence, and fortitude of the patient, and last but not least the degree of experience, *sang froid*, and dexterity of the operator. Recognition of and allowance for these minor differences are the result of experience and special aptitude, the evidence of skill and the promise of a large measure of success. It is this factor of personality which combining art with science adds that magic touch which makes a diagrammatic, typical procedure an accomplishment of the individual.*

DURING FIXATION.

*The fixation forceps may fail to hold if superficially applied or, in case the conjunctiva is thin and brittle, it tears loose. A broad bite and avoidance of too much traction will generally obviate this accident, which moreover is not dangerous, but merely annoying on account of hemorrhage. If the application of the forceps at another point is followed by a repetition of this *contretemps*, it may be necessary to rotate the globe downward by means of a squint hook passed into*

the lower cul-de-sac, or the tendon of a rectus muscle may be grasped after fresh instillation of an anesthetic and the free use of adrenalin to check the bleeding. Marked restlessness of the patient during the art of introduction of the speculum and the application of the fixation forceps is always a danger signal, and should prepare us to be on our guard for complications. Just in such cases, however, when we cannot count on the patient keeping quiet, it is necessary to keep the lids separated and to hold the globe fast. The lid-holder may be employed or the speculum lifted up by an assistant.

Undue traction or pressure with the fixation forceps, especially the latter, may cause escape of aqueous, or, if tension has been lowered by the free use of cocain, so alter the curve of the cornea as to interfere with the regular shape and size of the section. In watching the section hand too closely, the fixation hand is apt to be overlooked, and instinctively pressure is made synchronously with the section. The fixing hand should therefore be well supported on the superior maxilla of the patient and the forceps grasped in such a way that after the globe is once fixed it is difficult to cause pressure.

DURING THE SECTION.

The knife may inadvertently be passed into the eye with its cutting edge downward. While it is possible to turn a narrow knife *in situ*, and this has actually been accomplished without untoward results (Knapp, Marple), there is necessarily much bruising of the wound lips and danger of escaping aqueous carrying the iris in front of the knife. The knife had better be withdrawn completely. If no aqueous has escaped, the knife may be reintroduced into the original point of entry or close to it. Otherwise the operation should

be deferred unless we are prepared to complete the section with a narrow probe-pointed Graefe knife, the secondary cataract knife (Desmarre's *couteau à pointe mousse*) formerly employed to enlarge the corneal incision and reintroduced of late by Black.

The section may be too large, either on account of the puncture and counter-puncture having been made too low down on the cornea or too far back, i. e., behind the limbus. If recognized early this may be corrected by inclining the edge of the blade more sharply forward as we cut upward through the chamber. In this way it may still be possible to avoid injuring the iris and to bring the plane of the section back into the corneal limbus. The section is almost unavoidably irregular and its summit may have to be laid in clear cornea. This is disadvantageous for an easy delivery of the lens, prevents the formation of a conjunctival flap, increases wound astigmatism, and the resulting section does not heal as quickly as one in the sclero-corneal margin. *Insufficient length of the section* is rare in the formation of a flap-section of semicircular form, and is easily corrected. Snellen claims that too small a wound is the commoner mistake, and both this author and Haab think it had better be too big than too small. If the section lies correctly, i. e., in the limbus, its ends may be lengthened by passing a small, curved strabismus scissors (Stevens) into either wound-angle and cutting through the cornea with a firm snip. As a rule, no harm is done. *If the section is made with the blade of the knife inclined too far forward*, so that it emerges in the clear cornea some distance from the corneal margin, the section, although actually not too short, is badly placed for all subsequent steps, particularly for the delivery of the lens which has to be capsized or tilted forward before it can engage. This requires more pressure

than usual and the danger of prolapse of iris and vitreous is greatly increased. There is more bruising of the iris, greater danger of incarceration of capsule, of adhesion of iris or of the margin of the coloboma to the wound. Pressure on the posterior wound lip cannot well be made as the wound now lies in front of instead of above and somewhat behind the equator of the lens, and tends to dislocate the lens backward. No correction of this section is possible.

INJURY OF THE IRIS.

The point of the knife may impinge upon the iris, and yet be made to free itself. Of course it is unwise to withdraw the knife, although that may be the instinctive tendency, as loss of aqueous would inevitably carry the iris down upon the blade and completely prevent correction. If, however, the handle of the knife is depressed, while it is advanced, so that the point rises as soon as it is seen to engage the iris, it will generally ride over that membrane and free itself. If this accident takes place when the point of the knife has nearly reached the counter-puncture, there is little or no danger in slightly withdrawing the knife, as the point of entrance will be occluded by the equal breadth of the blade of the knife. If the point of the knife is not freed by this manœuvre, the iris may be torn partially from its ciliary attachment or may fall in front of the blade. This accident is most liable to occur with a shallow chamber, a long section and a narrow knife. If inclination of the cutting edge forward does not cause the iris to slide back, and hemorrhage shows that it has been cut into, it is best to complete the section without any further effort to change the plane of the knife. Nothing can be done to save the iris, which would have to be excised in any event, and we merely risk a bad section in addition. Aside from the

mutilation of the iris, this accident is awkward, as a good deal of pain is caused by the slow cutting of the unanesthetized iris. There may be serious danger if the patient becomes restless at this point. The excised piece of iris may be removed with forceps before the capsule is opened, or if the iris is merely torn an iridectomy is performed.

After the section has been completed *lege artis*, a number of minor complications may occur.

COLLAPSE OF THE CORNEA.

This is observed in very feeble, aged patients, an unusually thin cornea, with small, deep-set eyes, sub-normal intra-ocular tension and, it is claimed, after too free use of strong solutions of cocain. As a rule, the curvature of the cornea is restored with the filling of the anterior chamber under the closed lids. It is more apt to happen after delivery of the lens, and if the anterior chamber is not promptly restored when the speculum is removed and the lids closed, a small amount of fluid injected into the anterior chamber in the course of irrigation will correct the deformity. A more serious form of this collapse has been observed in cases of annular synechia and tough cyclitic membranes, forming a rigid diaphragm in the plane of the pupil. There is no tendency for the lens system to press forward, and the external atmospheric pressure inverts the cornea.

ENTRANCE OF BLOOD OR AIR INTO THE ANTERIOR CHAMBER.

Hemorrhage from the sclera or conjunctiva at the upper part of the section may gravitate into the anterior chamber or be aspirated by negative pressure. Free bleeding is rare after adrenalin has been used, except in case of marked arteriosclerosis or other diathesis. It is usually removed by

pressure with a moist wipe which may actually aspirate the blood from the anterior chamber. Hemorrhage from the iris is generally seen only in case of wounding in the course of the section or in case of disease of this membrane. Iridectomy is usually a bloodless operation, as the cut vessels of a healthy iris immediately retract. Of course, this does not apply in case of plus tension or of adherent iris. Copious hemorrhage may, however, be caused by iridodialysis, and may require the operation to be brought to a sudden and premature close. While any hemorrhage from a normal iris stops promptly and is rapidly absorbed, a blood-clot may form causing dense occlusive membrane or secondary cataract when a coloboma is made in a diseased iris.

That *air bubbles in the anterior chamber are innocuous* was proven by Graefe's experiments on the eyes of animals, and it is generally claimed that it is not necessary to remove them as they escape spontaneously. While this is actually the usual result, it is by no means invariable, and at least one case has been seen in which a circumscribed opacity developed on the posterior surface of the cornea, corresponding exactly to the position of a bubble which had not been removed at operation. As a rule, irrigation will carry any air bubble out of the chamber, so there is no reason why they should be allowed to remain behind, unless, perhaps, some complication makes it advisable to terminate the operation abruptly.

Hemorrhage in the depths of the eye is always a serious complication. Small retinal hemorrhages are the rule after extraction in case of high tension. They are due to the sudden lowering of intra-ocular pressure, and, of course, more apt to happen in case of general or local disease of the vessels. Massive intra-ocular hemorrhage (*expulsive hemorrhage*, Terson) may occur during operation or immedi-

ately after it. There is always sudden and intense pain in the eye. Vomiting and even an epileptiform attack may occur. An insidious course during which the external wound opens and a large blood-clot with intra-ocular tissue is extruded is decidedly rare. The first sign of this accident may be the sudden advancement of the lens system, its dislocation into the anterior chamber or its sudden expulsion from the eye. If the cataract has already been extracted, the wound opens and vitreous prolapses without any evident cause, such as pressing on the part of the patient. Copious hemorrhage welling up from the depth may be the first sign of trouble. It may persist in spite of a pressure bandage, and is almost invariably followed by loss of the eye, through atrophy or secondary panophthalmitis and phthisis. The hemorrhage is retro-choroidal in origin, the vitreous prolapse is secondary, the entire semi-fluid contents of the eye being pressed forward by the massive blood-clot. High tension and obstruction in the system of the superior vena cava, such as embarrassment of respiration, spasmodic coughing, marked over-exertion, predispose to this accident; but while it is more frequent in glaucoma operation, its occurrence in other cases seems to have no bearing on or dependence upon increased tension. The accident cannot be foreseen or prevented, except, perhaps, in the unusual case of expulsive bleeding having already taken place in one eye.

PROLAPSE OF IRIS.

This may occur immediately after the section. For this reason it is advisable to have instruments at hand for an iridectomy in every operation in which the anterior chamber is opened by a section, however small. A small prolapse of uninjured iris may be replaced by means of the spatula

and subsequent irrigation, but as a rule it must be excised. In case of prolapse or incarceration of the margins of a coloboma after iridectomy, an attempt at reposition is not advisable. Excision at the time of operation has the advantage of effectually preventing a second prolapse. Excision of a post-operative prolapse is an emergency operation. The iris may be firmly incarcerated by the time an attempt is made to remove it and it may be impossible to free it completely. Add to this that after the subjection of the patient to this procedure we have, at the very best, accomplished what we would have secured without further complications, in all probability, by an excision of the prolapse at the time of the original operation; and in the latter case, the coloboma would inevitably have been smaller, more regular and less disfiguring.

Iridectomy during operation is indicated in case of the following complications: irregular or uneven section; injury of the iris by the knife, capsule forceps or cystotome; in case the iris does not lie smoothly in the anterior chamber, or cortical remnants behind the upper segment of iris cannot be removed; in case the lens cannot be delivered with gentle pressure or is displaced in the manipulation; in case of iris prolapsing during delivery and failing to be returned easily, or when the pupil shows a tendency to be drawn out toward the wound. In case of a rigid pupil, and when a thickened capsule has been extracted after delivery of the lens. Measures for the prevention of prolapse during the operation consist in the careful choice of cases to be taken, instruction and preparation of the patient, careful and complete anesthesia, early removal of speculum and fixation forceps, accurate performance of the section and sufficient size of the cut, the minimum of pressure during delivery of the lens, thorough irrigation for the removal of cortical remnants,

the avoidance of atropin where possible, and perhaps the instillation of pilocarpin or of very weak (1/10%) solutions of eserine immediately after the operation. To this we may add the injection of a small dose of morphin or of the administration of hypnotics some time before and soon after operation, suture of the wound, or its occlusion by a large flap of conjunctiva, peripheral iridectomy and sphincterectomy or radial incision of the sphincter.

PROLAPSE OF VITREOUS.

This may accompany a prolapse of the iris, in which case both are to be excised. In the simple operation prolapse of vitreous rarely takes place until after delivery of the lens. The speculum must be removed at once, if it is still *in situ* and the eye closed. In case of prolapse during expression of the cataract, or after iridectomy, no time is to be lost, as the lens almost immediately sinks backward or downward into the vitreous and is lost to sight. The rapid introduction of an extraction instrument, preferably the spoon, behind the lens may succeed in scooping it forward against the posterior surface of the cornea and in drawing it out of the eye, which is then immediately closed. In case we have to deal with a very quiet and sensible patient, it may be possible to abscise the prolapsed vitreous and so improve matters somewhat. If the corneal flap has been folded back by the prolapsing vitreous it may be stroked back into position with the spatula while the lower lid is held away from the eye. The flap is stroked upward under the upper lid and is thus prevented from opening further.

The iris may be unintentionally seized by the capsule forceps where this instrument is used to open the capsule. Catching of the teeth of the forceps in the iris may be due to introducing the forceps into the chamber along the iris,

instead of hugging the posterior surface of the cornea. The iris must be sharply watched during all manipulations with this instrument. If it shows any sign of traction, the forceps must be opened, the handle inclined more sharply and the point pressed somewhat more forward until it appears in the pupillary area. Inclusion of a fold of iris between the arms of the forceps is shown by an irregularity of the pupil when the forceps is withdrawn. Forceps of correct pattern are so constructed that the arms do not quite come into contact when the points are completely closed and the teeth are in apposition. It is advisable to excise a portion of iris after this accident as the bruised tissue generally tends to prolapse.

INCOMPLETE IRIDECTOMY.

The sphincter may not have been excised. This is apt to happen in case the iris was not drawn out of the wound sufficiently or the scissors were not held close to the wound. It may happen that the sphincter is not drawn out of the wound at all, particularly if the iris was grasped too near the ciliary attachment. If the bridge of iris tissue is very slender it may be torn through with a cystitome or hook. In any other case it is best to draw it out with iris forceps and make a clean excision with scissors.

DISLOCATION OF THE LENS.

This is an unusual accident, and one which presupposes anatomic abnormalities, such as fluid vitreous and lax zonule, exceedingly prominent eyes, great restlessness, with spasmodic squeezing on the part of the patient or unskillful manipulation by the operator. It not infrequently accompanies prolapse of the vitreous and requires prompt and energetic action in extracting the lens and

rapidly closing the wound. A badly constructed speculum which causes pain or presses on the eye, especially if the latter is prominent, may actually cause this accident. It may occur at any stage of the operation. During the cutting of the section, the knife may impinge on the lens and carry it out of its place. During capsulotomy, the cystitome may dislocate the lens backward, it may remain imbedded in the nucleus and draw the lens into the anterior chamber or cause it to wedge across the incision. Pressure with a capsule forceps may carry the lens back into the vitreous. During expression, the exertion of too much force may cause the lens to be torn from its attachment and disappear in the vitreous. This is more apt to occur if the section was too small or the laceration of the capsule not sufficiently extensive, as in any other event delivery is easily effected with the minimum of pressure, as stated above. Faulty situation of the section, particularly when its upper segment is too far forward in clear cornea, requires more manipulation and pressure in order to make the upper margin of the lens present and so may cause dislocation. Faulty technic during expulsion may also be the exciting cause, if pressure on the lower part of the cornea is made too energetically while the wound fails to gape, is made upward before the lens has tilted into the region of the section, or the spatula is pressed against the posterior lip of the wound too vigorously.

Slight displacement of the lens need not interfere with its delivery, and dislocation into the anterior chamber is not a serious matter, as the lens can usually be extracted without difficulty with a spoon or grasping instrument. Dislocation into the vitreous is much more ominous, particularly if accompanied by prolapse of vitreous. When the latter accident threatens or actually takes place, self-possession

and rapid action alone will save the day, by the instant introduction of the spoon behind the sinking lens, which should be pressed forward against the posterior surface of the cornea and pulled out along the anterior flap. A wire loop should not be used, as a small lens (or nucleus freed of cortex) may slip through it. Grasping instruments are much less reliable than the spoon, as there is no *vis a tergo* to help them catch in the lens capsule. If the lens has disappeared in the vitreous it is not advisable to thrust the spoon in after it, as all efforts are then made in the dark and at random. The results cannot be good. It is best to close the eye for a longer period. A day later, the lens may be found in the pupillary area, as was not infrequently the case after the couching operation, although the conditions are less favorable for such a spontaneous reposition on account of the generally complete tearing of the zonule. After extraction of a dislocated lens, the operation should be terminated as quickly as possible. If the speculum is still *in situ*, this must of course be removed at once. As the lens has come out in the capsule there is little danger of any extraneous matter remaining behind, and the prevention of vitreous prolapse or of further accident to this body is the prime consideration.

With the final closure of the patient's lids, the operation for the extraction of cataract has been concluded, and the after-treatment begins, a period which at least in its earlier stages is fraught with anxiety, and requires, if less skill and experience, at least as much conscientious attention to detail, as the original surgical procedure itself.

[There is one point in the technic of introducing the speculum to which especial attention should be paid, and that is, the absolute necessity of making tight the screw

which holds the branches of the speculum. Twice, in my life, once in my own experience and once in that of a colleague, I have seen misfortune follow the failure to make the screw tight and fast. As Fridenberg has pointed out, any patient by the exercise of all his power may so squeeze his lids together as to bend the branches of the speculum, though it is tightly screwed. Yet even slight pressure may do the same thing when the screw is not made tight and fast. The operator should assure himself absolutely of the certainty of this before he makes the section.

On one occasion, I thrust the knife into the anterior chamber, back foremost, and would have made the counter-puncture had not my assistant called my attention to the mistake. I withdrew the knife, covered the eye with a sterile pad and waited ten minutes. The anterior chamber having been restored, I made the section without difficulty and performed an otherwise normal combined extraction.

I cannot recommend turning the knife in the wound. If the blade is broad, the traumatism will be considerable. The knife should be withdrawn, the eye bandaged or covered with a sterile pad, and one should wait at least fifteen minutes. At the end of that time, the anterior chamber will usually have filled and the eye will be plump. The section can then be made without difficulty. If fifteen minutes does not suffice, one should wait longer or defer the extraction to another day. Just here haste or loss of one's head will precipitate disaster.

For various causes I have been compelled three times in my life to meet and combat this emergency. The plan of action which I have recommended enabled me on each occasion to snatch victory from the very jaws of defeat.

I have suggested to the instrument-maker that a small arrow be marked on the handle of the Graefe knife just

above the blade on each side, pointing in the direction of the cutting edge. The knife is therefore held correctly only when one sees the arrow, and the point of the arrow indicates the cutting edge.

I came near meeting calamity once, when after a faultless simple extraction I flushed the eye suddenly and with too much force. I had already flushed the eye preparatory to the section, so that it was not a new sensation to the patient, but I believe the shock largely arose from the contact of the water with the open wound and the iris. The patient squeezed her lids forcibly, causing the wound to gape and the vitreous prolapsed into the wound, but without pushing the iris before it. I removed the speculum with all the dispatch possible, and on looking at the eye several minutes later, I found the vitreous had returned. The eye healed slowly with inverted iris, but the final result was excellent.

The speculum ought to be removed, in my opinion, before the toilet of the wound is commenced, and the lid ought to be held back by the finger of the left hand or by some kind of lid-holder. I have seen some surgeons use a strabismus hook for this purpose.

In 1885, I saw Graefe, of Halle, perform sphincterectomy in a great number of extractions. He certainly performed the manœuvre most skillfully, and the resultant pupil was satisfactory in all the operations I saw done. It is, however, a most difficult procedure and implies perfect command of the hands and the instruments. I have tried it a number of times, but my attempts resulted in achieving a small iridectomy.

Incidentally, Graefe, of Halle, always used his right hand in making the section and operated with the eyeball swimming in a solution of bichlorid of mercury. I was with

him three months and followed his results at his elbow.
All the cases I saw healed red and angry.

Ambidexterity should be acquired by those who use the
Graefe knife in the extraction of cataract. J. H. C.]

CHAPTER VI.

EXTRACTION OF CATARACT WITH A LANCE SHAPED KNIFE.

J. HERBERT CLAIBORNE, M. D.

THE Graefe knife is now, and has been since its invention, the classical knife for the removal of senile cataract, and it would border almost on the impious to doubt its efficiency or proclaim that it does not completely fulfill the requirements. Nevertheless, there are a number of sound objections which may be raised against it.

In the first place, its use necessitates a counter-puncture which should relatively correspond with the puncture; in the second, a sawing motion is necessary to conclude the section—this causes an irregular and jagged wound, delays union, increases the risk of suppuration and the degree of postoperative astigmatism; in the third place, it necessitates the greatest precision in adjusting the size of the section.

These objections are valid, and I do not believe they can be successfully combated. If a knife can be invented with which the lens can be removed and which does not possess the disadvantages outlined above, I believe it should be preferred to the Graefe knife. I have long thought that if the lens could be removed by means of an irregular lance-shaped keratome of dimensions to make a wound large enough to allow the easy exit of the cataractous lens, the disadvantages of the Graefe section would be avoided.

We are all familiar with the rapidity and smoothness with which a wound caused by a lance-shaped keratome

heals. The difficulty, however, lay in constructing a knife of such dimensions as would make a wound large enough for the exit of the lens. To do that, it was necessary to know the dimensions of the cataractous lens without its capsule and the diameter of the anterior chamber. Investigation led me to believe that the cataractous lens, when measured just after its delivery, had in general a diameter of 9 mm. I accepted this as a fact, and attempted to find the diameter of the anterior chamber. I wished, of course, the diameter in the vertical meridian, and I experienced considerable difficulty in finding it. After investigation, I concluded that it was safe to assume it to be 11.6 mm. in diameter, at least in the vertical meridian, and I proceeded with this as a fixed quantity. It therefore became necessary to construct a lance-shaped knife which would make an opening in the anterior chamber large enough to allow the easy exit of a lens 9 mm. in diameter. In studying the dimensions of the anterior chamber by the double corneal magnifying lens, I could see very plainly that the anterior chamber extended back much further than the sclero-corneal margin, as apparent to the naked eye. But in using a knife it is quite impossible to avail one's self of the aid of the corneal magnifying glass at the same time, so I assumed that the cataract knife generally enters the anterior chamber about 2 mm. within its actual limit. I therefore concluded that I had to deal with a circle of 9.6 mm. in diameter, and I had a knife so constructed that when it was thrust into the anterior chamber and its apex had arrived in the inferior corneal angle, the chord which measures two-fifths of the diameter of the anterior chamber would correspond to a wound 9.2 mm. in length. (Fig. 1.)

Mr. H. S. Andrew, C. E., kindly made the mathematical calculation and drew the figures which are shown herewith.

As can be seen, the base of the knife was 12 mm. and the length 8.048 mm. Antecedent to having this knife constructed, I had another made, the base of which was 12 mm. and the length 6 mm. I tried this knife on a cadaver, but the experiment was unsatisfactory and non-conclusive on account of the time the cadaver had been in the dead house. The knife, however, was boiled and resharpened, and I used it in a case of soft cataract in a woman thirty years of

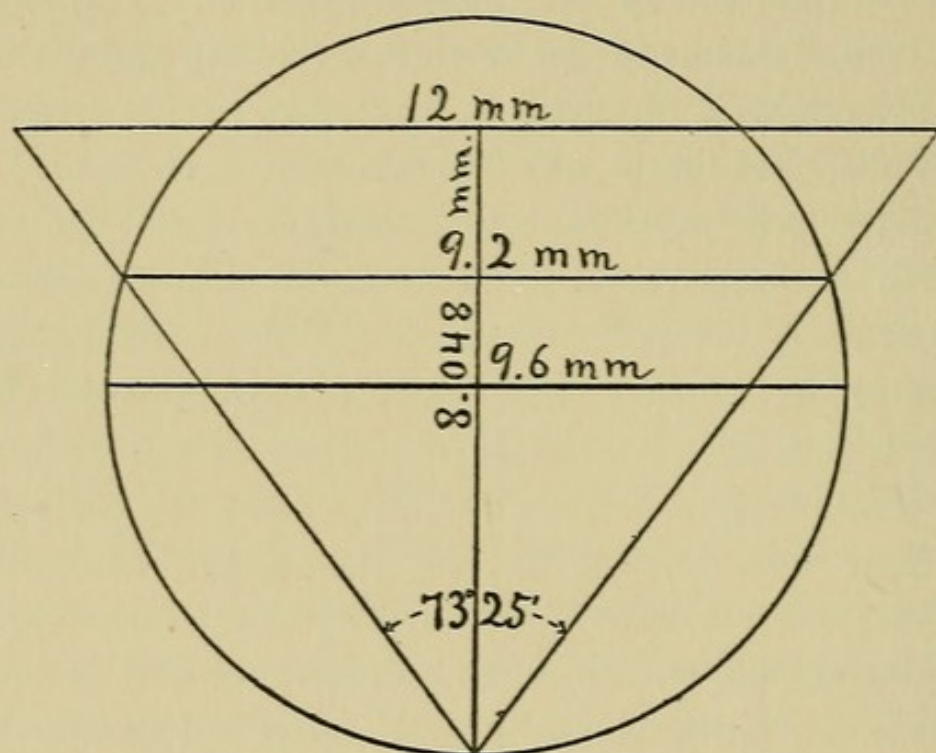


FIG. 1.

age. The angle caused by the above-stated dimensions was so obtuse (90°) that the knife entered the cornea only to one-half its length. Nevertheless, the cataract was delivered, but by an incision which really amounted to the old linear one. This experiment, therefore, proved nothing.

The knife mentioned above, as estimated by Mr. Andrew, to wit, with a base 12 mm. and length 8.048 mm., was constructed, and in two weeks a typical case for its exploitation was found. The cataract occurred in a woman of

forty, and had been completely ripe for several months. It was one of those dark-yellow sticky cataracts which are well known to eye surgeons and which are so difficult to extract from the capsule. The case, therefore, presented ideal conditions for testing the value of the knife.

The knife entered about 2 mm. behind the apparent sclero-corneal margin. The entrance was easy and the knife was shoved home, the apex of the blade apparently entering the lower iris angle. As the knife was withdrawn, a sideways cutting stroke was employed, in order to slightly enlarge the corneal section. This is a maneuver well known to those who use the lance-shaped keratome in performing iridectomy. A small iridectomy was done, and afterward a peripheral cystotomy. The wound gaped and the lens presented at the wound mouth as if anxious to come out, but when pressure was made by two spoons, one above and the other below the cornea, it failed to come. I then attempted to enlarge the nasal lip of the wound by De Wecker's scissors, but they failed to cut, and I at length repeated the cystotomy, making it more extensive and more thorough. Pressure below and counter-pressure above caused the lens to be delivered as easily as such sticky lenses usually are.

I am convinced, as well as were others who witnessed the operation, that the corneal wound was not enlarged at all by the scissors and that had I made a cystotomy more extensive and more thorough in the beginning the lens would have been delivered at the first attempt.

The wound closed in forty-eight hours, although there was some striped keratitis. This disappeared in a few days, and the patient left the hospital on the seventh day without having had an untoward symptom.

Up to this point it seemed to me that I had developed

an entirely new point in cataract extraction. But my colleague, Dr. Thomas R. Pooley, called my attention to a paper by Weber, of Darmstadt, published in 1867, in which he sets forth the idea of removing cataract by a keratome. After all is said and done, however, the idea is not original with Weber either, for the most cursory glance at the recent paper published by Hirschberg in the *Gaeffe-Saemisch Handbuch* shows that Daviel, in 1752, and les Frères Grandjean, Paris, 1766, removed cataracts with knives which more nearly resembled that of Weber than his resembles the one I have just described. I conclude, therefore, that the idea is not Weber's, but Daviel's; that the brothers Grandjean followed him, that Weber followed them, that I have in turn followed Weber, in a measure. All of these knives, however, differ, and each is entitled to its place in the archives of ophthalmology. Sattler also has extracted cataract with a keratome.

Weber, in his paper entitled "*Die normale Linsenentbindung der modificirten Linear Extraction gewidmet*," describes his knife. It is a bent knife of a heart shape, whose back is hollow-ground. It has on the handle a rough surface for better manipulation. It has a length of 10.25 mm., so that it may cross an anterior chamber of 12 mm. diameter to the opposite scleral limbus; 6.5 mm. from its point it has a breadth of 10 mm., and it increases in width 2 mm. more at its base. It then tapers off to the handle, as shown by the drawing. Fig. 2.

The curved character of the wound made by this knife is shown in Fig. 2. (b).

It will be seen, therefore, that the knife which Weber has described differs materially from the one I have devised. His knife is heart-shaped and has a hollow back. Mine is a triangle and has a flat back, so that the anterior and pos-

terior surfaces occupy parallel planes; it therefore makes a straight wound; it increases in thickness gradually from apex to base, and the handle rises from the base of the triangle exactly as in the regular lance-shaped keratome at present in use for iridectomy. The length of the Weber knife is 10.25 mm., whereas the one I have described is 8 mm. in length. The greatest breadth of his knife was 12 mm. at the base of the triangle; mine likewise was 12 mm. at the base. His knife was so constructed that at 6.5 mm. from the apex the breadth was 10 mm.; this would insure the safe passage of a lens of 9 mm. in diameter, but it is questionable whether with so obtuse an angle the knife could be thrust into the anterior chamber at all. In support of this suspicion is the statement that in regard to the cutting qualities of his knife he had some complaints to make, but that later he was completely satisfied with the work of his instrument-makers. My experience in that line leads me to doubt the efficiency of a heart-shaped knife which at 6.5 mm. from the point possesses a breadth of 10 mm. The angle is too obtuse for a stab wound to be made easily. The knife which I devised, however, entered the anterior chamber with as much ease as any of the lance-shaped keratomes I have ever used. The angle subtended by the point of the knife I have described was 73.5° , as shown by Mr. Andrew's drawing.

After performing the operation, I became convinced that I could use a knife with a broader base with greater certainty of success.

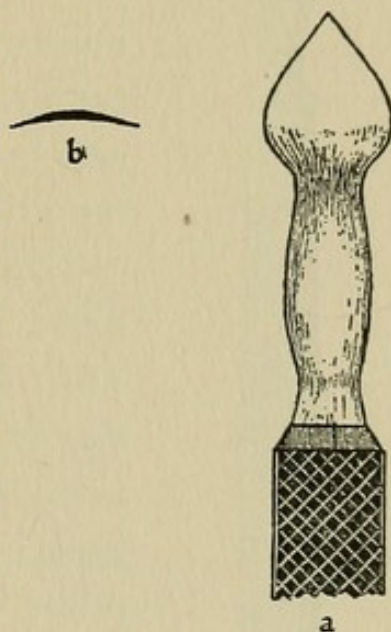


FIG. 2.

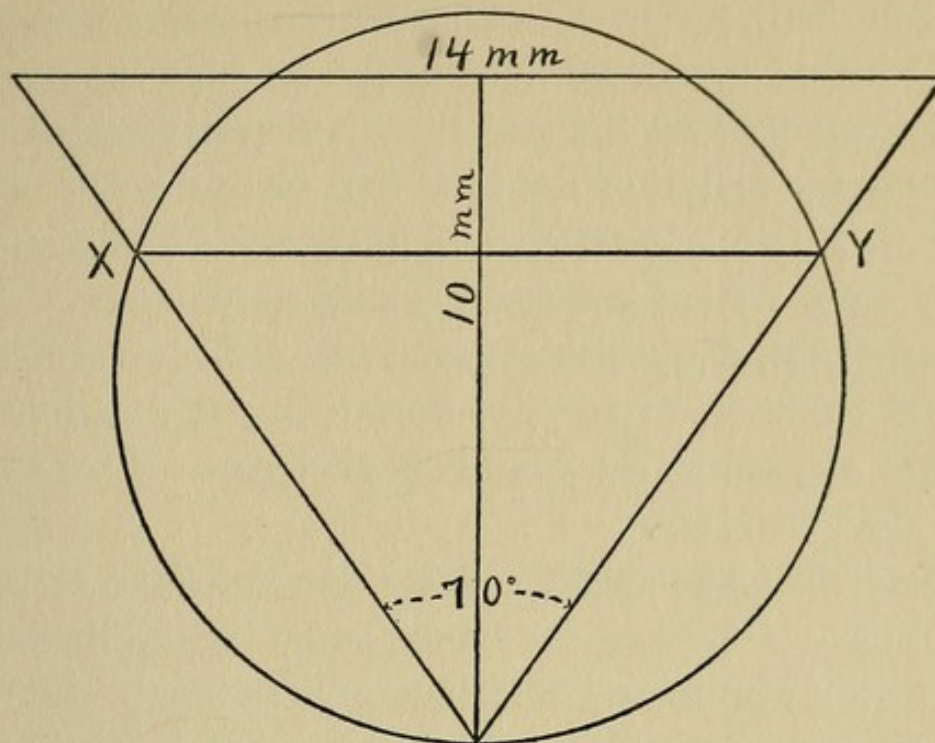


FIG. 3.

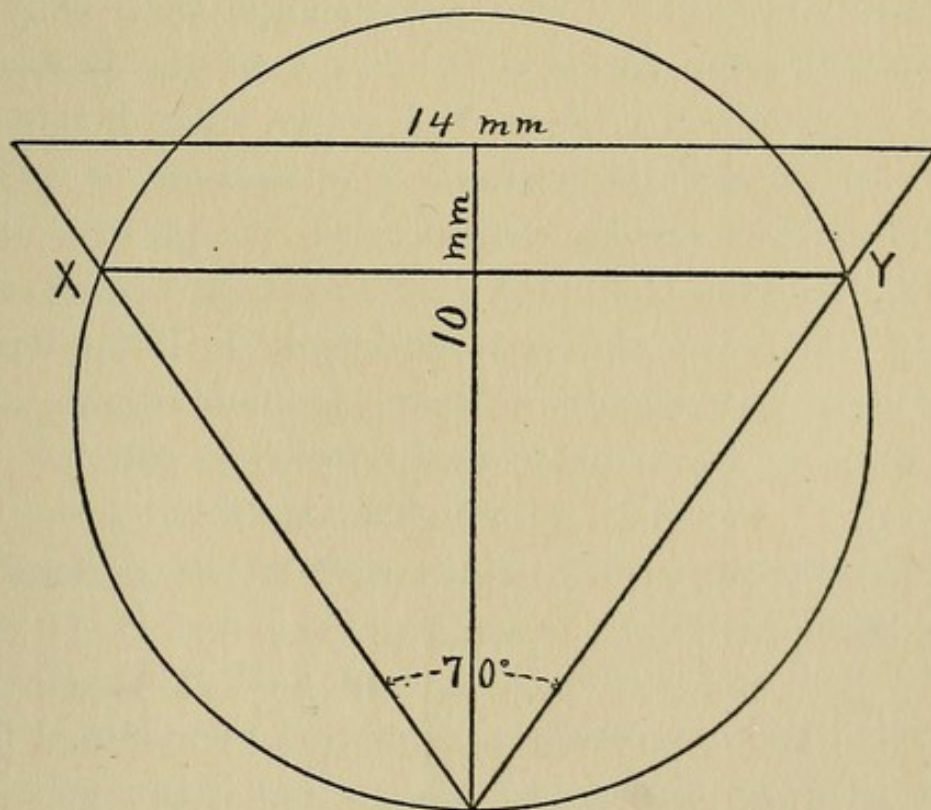
It will be observed that Weber estimated the depth of the anterior chamber at 12 mm., and I found it later estimated at 13 mm. (*Encyclopedia Française*, vol. I.) In view of these findings, I had Mr. Tieman make me a final knife with a base of 14 mm. and a length up to the base line of 10 mm. (Fig. 3.) But it will be observed that there are about 2 mm. of blade above and beyond the base line, after the manner of the ordinary lance-shaped keratome; this gives the knife 2 mm. more length and insures the entrance of the point well into the lower iritic angle.

The largest keratome made by Mr. Tieman has a base of 10 mm. and a length of 14 mm. This last knife, then, just reverses these measurements, and the angle subtended at the point is 70° (Fig. 4.) If now a knife with a base of 12 mm. and an angle of 73.25° at the point was sharp enough to enter the anterior chamber with ease, a knife which possesses a more acute angle (70°) will do the same thing beyond peradventure, and the value of this knife as a cutting instrument is established.

If we then allow that the knife will enter the anterior chamber 2 mm. within its actual limits, the diameter of the anterior chamber may be estimated at 11 mm. By referring to Fig. 4. (A), it will be seen that a knife of the above mentioned measurements, when it enters an anterior chamber 11 mm. in diameter and its point reaches the lower iritic angle, will make a wound at the chord XY, 10.337 mm.



A.—Circle 11 mm. diameter chord $XY = 10.337$ mm.



B.—Circle 12 mm. diameter chord $XY = 11.276$ mm.

FIG. 4.

in length. If, however, we allow that the knife enters 1 mm. within the actual limit of the anterior chamber, we have to reckon with a circle the diameter of which is 12 mm. and the length of the cord XY in this case is 11.276 mm. Fig. 4. (B). In either case there will be ample room for the easy exit of a lens of 9 mm. in diameter. These calculations also furnish a generous allowance for the personal equation of error in introducing the knife. The theorem, therefore, set at the beginning of this paper is amply demonstrated.

The method of using the knife which I have employed is as follows: The surgeon should stand behind the patient and a fixation forceps should be applied directly below the point of entrance of the knife; the eye being rotated downward, the point of the knife is entered about 2 mm. behind the sclero-corneal margin in the median plane of the vertical meridian. The knife should then be shoved straight across the anterior chamber until its apex arrives at the limit of the inferior iritic angle, when it should be withdrawn slowly. If the knife is withdrawn too quickly, aqueous escapes rapidly and the iris is apt to prolapse. The simple or the combined extraction may be performed. For my part, I prefer the combined, as it renders the exit easier. Care should be taken to maintain the point of the knife at the same plane in which it entered. The maneuver is executed within five seconds, forming a marked contrast to the time required to perform the Graefe section.

If we look for a moment at the modern Graefe knife with which the now classical operation of modified linear section is made, we see at a glance that it is a fac-simile, greatly reduced, of the Catlin knife for amputation at the hip. It is, in effect, an extremely delicate and finely-

tempered sharp-pointed scalpel, and yet no one denies Graefe the great credit which is his due.

I have already, in a measure, outlined the disadvantages of the Graefe knife, but I think they may be categorically stated in this wise:

1. The necessity of counter-puncture.
2. The difficulty of making counter-puncture correspond with puncture.
3. The necessity of a sawing movement to finish the section.
4. The difficulty of finishing the section at exactly the point intended.
5. The loss of æqueous and consequent exhaustion of anterior chamber after counter-puncture during the performance of the section.
6. The falling of the iris before the knife.
7. Imperfect apposition of lips of wound on account of its ragged and serrated character; increase of liability to suppuration by reason of raggedness of wound; tardy healing; increase of postoperative astigmatism.
8. Necessity of ambidexterity, in order to operate on each eye equally well.
9. Necessity of adjusting size of section.
10. Danger of prolapse of vitreous when section is too large or ends too far back of sclero-corneal margin.
11. Length of time required.

The advantages of a section made by a properly-constructed lance-shaped keratome are practically the corollary of the above. They are:

1. There is no counter-puncture.
2. The wound is a stab-wound, and by virtue of that fact is smooth; no sawing motion is employed.
3. The section is finished by shoving the knife home.

4. There is no loss of æqueous while the section is being made, because the knife increases in thickness from the apex to the base, and the further it is shoved in the tighter it stops the wound.

5. The iris is not so apt to prolapse on withdrawing the knife, because the broad back of the knife holds it in place.

6. The iris cannot fall before the knife from loss of æqueous, because no æqueous is lost during the section on account of the shape of the knife.

7. Perfect apposition of lips of wound by virtue of its smoothness; rapid healing; less liability to suppuration; less post-operative astigmatism.


8. Use of right hand for both eyes.

9. If the knife is entered properly and shoved home, the section is bound to be correct; it automatically commands success.

10. Less danger of prolapse of vitreous, because of the support furnished by the broad back of the knife.

11. Diminished time.

Since experience in the use of the knife is so limited, it may be argued that many of these points are academic; indeed, this may be held with justice, but the arguments set forth are at least backed by reason, and the fact remains that one of the most difficult of cataracts to extract has been successfully extracted by means of the knife herein described.



CHAPTER VII.

THE AFTER-TREATMENT.

A. E. DAVIS, M. D.

THE after treatment of extraction of senile cataract depends upon the nature of the operation performed, upon the condition of the patient, and I might also say to some extent upon the individuality of the surgeon.

After the simple and combined extraction of uncomplicated senile cataract both eyes should be covered, although but one is operated upon. Pads of cotton or cotton-wool, inclosed between two layers of gauze, are placed over the eyes, and these pads are held in position by narrow strips of adhesive zinc oxide plaster, extending from the brow above to the cheek below. Over this dressing most ophthalmic surgeons place a narrow bandage of flannel or gauze, one and one-half inches wide, to make the dressing more secure; the whole is covered with a shield to prevent the patient injuring the eye. Some surgeons use simply the cotton pads held in position with strips of adhesive plaster and over this a protective shield, while others have advised a strip of isinglass, one inch to an inch and a half wide, with which to close the eye, and use no other dressing. The objection to the bandage that it causes "dragging" on the dressing is overcome by the strips of adhesive plaster which hold the dressing in position.

With the dressings applied, the patient is placed in a moderately light room, in bed, on the back or on the side opposite to the eye operated upon.

Smarting of the eye lasts for five to six hours, as a rule, after the operation. If however, the patient remains restless and cannot sleep, and especially if an anodyne has not been given before the operation, one should be given at bed-time. The patient should stay in bed at least twenty-four hours, and it is better to remain in bed two or three days until the wound is firmly closed after which the patient may be allowed to sit up in an armchair for part of the day, or all day if he is more comfortable in a sitting position. Sometimes the patient is permitted to sit up from the first day, if there is any special reason, such as an emphysema accompanied by a cough; but these are exceptional cases. When confined to bed the urinal and bedpan should be used. If the bowels do not move on the third day after the operation a cathartic should be given. The patient should be cautioned not to strain at stool as great harm can result from this. The diet should be fluid for the first day and semi-solid for the next two or three, after which the usual diet may be given, care being exercised not to over-feed the patient. A nurse must feed the patient until one eye is left uncovered. Mild stimulants may be required in some cases, especially if the patient has been accustomed to them. Highly seasoned foods, fruits and pastries, except in limited quantities, are contraindicated.

If all goes well, the first dressing should be removed at the end of twenty-four hours after the operation. Some surgeons, however, wait two or three days before making a change. If the simple extraction is done the eye certainly should be examined at the end of twenty-four hours, to see if any prolapse or incarceration of the iris has occurred. The lower lid is pulled gently downward, a little warm sterile boric acid solution is squeezed from a pledget of cotton into the eye, and the lower lid and the face are

bathed with the same solution; then gently holding the lids open the pupil and corneal wound are inspected by the light of a candle. If the pupil is central and circular the dressings are reapplied. The dressings should be changed daily, under strictly antiseptic precautions, until the wound is healed. On the third day after the operation a drop of sterile atropin should be instilled into the eye, and this should be repeated daily until the eye is quiet and white. Both eyes are kept closed for five or six days when the operated eye is left uncovered. About the seventh or eighth day all dressings may be left off and the eye beprotected by a shade or smoked coquilles. From the tenth to the fourteenth day the patient may be allowed to take a little exercise out of doors. Usually at the end of two weeks the patient may go home. If the combined operation is performed the eyes should be inspected forty-eight hours following the operation, but earlier if there is any special indication, as pain, to demand investigation.

The above description applies to the normal uncomplicated course of healing following the extraction of senile cataract. Several complications both of a local and a general nature may occur to interrupt and retard the healing process or even jeopardize the success of the operation altogether.

LOCAL COMPLICATIONS.—(1) *Delayed union*.—This may result from improper apposition of the wound surfaces, especially when the incision has been made altogether in the clear cornea; or it may result from lack of nutrition in old or debilitated patients, at times without any apparent cause. In the cases due to lack of nutrition, tonics and concentrated food diet should be resorted to. The eye must be kept bandaged until the wound closes, even if it is as long as

two weeks, the dressing being changed infrequently, that is, at intervals of two or three days, so as not to disturb the wound any oftener than is absolutely necessary. There is no cause for alarm in such cases as they heal ultimately with good results.

(2) *Post-operative prolapse of the iris.*—After simple extraction this accident occurs occasionally, and exceptionally even after the combined extraction, a pillar of the iris coloboma prolapsing into the wound. Prolapse of the iris usually occurs within twenty-four hours after the extraction, before the edges of the wound have adhered. Occasionally it may take place as late as the third or fourth day from violent coughing, straining at stool, etc. In the great majority of cases a more or less sharp pain is the first sign of such complication. Later there is a feeling as if something were in the eye or on the under surface of the upper lid. After simple extraction I always examine the eye at the end of twenty-four hours' time and after the combined extraction at the end of forty-eight hours, as above stated. However, if pain of a decided nature persists after the usual five or six hours of smarting following extraction, I inspect the eye even earlier than twenty-four hours after the operation. If on inspecting the eye after the simple extraction, the pupil is seen not to be central and circular but is drawn upward and is oval in shape, the iris will be found either incarcerated or prolapsed into the corneal wound. In either condition my practice is to at once cocaine and adrenalize the eye, and excise the iris under thoroughly antiseptic precautions; care being taken to perform as clean an iridectomy as if it were done at the time of extraction; this can usually be done if the operation is performed within twenty-four to forty-eight hours after the extraction. In my experience the

corneal wound heals readily and smoothly. In nervous patients a general anesthetic should be used rather than a local one. No prolapse of the iris should be excised after forty-eight hours' duration, and for two reasons: the first and more important is that the eye is apt to be infected from inflammatory products present, if the wound is opened after this length of time; second, owing to adhesions it is impossible to make a clean iridectomy after this time.

All incarcerations of the iris should be considered and treated as prolapses from the beginning; for nine-tenths of them become prolapses finally. Moreover, when the iris is left in the wound it delays union and is a source of danger to the fellow-eye through the possibility of sympathetic inflammation. Furthermore, incarceration of the lens capsule following the combined extraction may cause sympathetic inflammation.

If prolapse or incarceration of the iris has been allowed to remain in the wound for more than forty-eight hours after extraction, no attempt should be made to excise it. The only operative measure justified at this stage, in my opinion, is either the actual or galvano-cautery. Under cocain anesthesia, except in very nervous patients when general anesthetics must be used, the procedure is a simple one. More than one séance may be necessary, however, before the protruding mass of iris tissue is completely removed. Some surgeons allow incarceration of the iris or even prolapse of the iris to remain in the wound, trusting in nature to smooth over the surface. I would remind my trusting confrères, however, of that old adage: "Nature is a very good physician, but a poor surgeon." And it is especially applicable in this condition, in which not only the operated eye, but even the fellow-eye may be endangered through sympathetic ophthalmia.

(3) *Iritis*.—Iritis following the extraction of senile cataract may be so mild as not to cause redness of the eye, discoloration of the iris or any pain whatsoever; yet when atropin is dropped into the eye on the second or third day after the operation synechiæ are shown to have formed between the pupillary margin and the lens capsule. These are considered to be non-inflammatory in nature, however, and are supposed to be simply “mechanical agglutinations” of the slightly wounded pupillary margin and the cut surface of the lens capsule (H. Knapp). The continued use of atropin for a few days usually suffices to break up such adhesions.

True iritis usually manifests itself on the third or fourth day after the operation by pain, which is more marked at night, redness and swelling of the ocular conjunctiva, discoloration of the iris, and later by plastic exudation which may block up the pupil entirely. The treatment is the same as in other cases of iritis; that is, leeches are to be applied to the temple, hot moist fomentations to the eye, atropin instilled four or five times a day and the bowels kept freely open with calomel and soda. As the eye has to be attended to frequently, the bandage should be left off and the pads should be held in position simply by adhesive strips.

(4) *Iridocyclitis*.—This is a most deplorable complication, but, fortunately, is of rather rare occurrence. There is great pain, marked circumcorneal infection, discoloration of the iris with a marked exudate into the anterior chamber, blocking the pupil, and later membranes form in the vitreous. The treatment is the same as in severe cases of iritis atropin, hot water and leeches should be used, and the bowels kept freely open with calomel. The disease may extend over a period of many weeks. It always leaves the pupil blocked and usually results in com-

plete loss of sight with shrinkage of the eyeball. In the chronic stages there are frequently exacerbations of the inflammation, not infrequently causing sympathetic inflammation in the fellow-eye. For this reason such shrunken eyes, if at all irritable and sensitive, should be enucleated.

(5) *Cyclitis*.—This complication generally does not develop until seven or eight days after extraction. The corneal wound may be healed smoothly, the pupil circular and central, the iris active and the eye quiet and white; when a pronounced circumcorneal infection with severe pain, more pronounced at night, appears. The inflammation lasts for weeks, leaving a more or less dense membrane in the pupil, and, what is more significant, is often followed by glaucoma. The treatment is practically the same as in iridocyclitis. In the milder cases after subsidence of the inflammation, needling of the membrane gives good vision; but in the cases which are associated with recurrent attacks of glaucoma the vision is often completely destroyed. In these latter, if simple extraction has been performed, an iridectomy should be performed at the first indication of plus tension, and if the combined operation has been performed, the colaboma of the iris should be enlarged or a sclerotomy performed. Myotics may be used.

(6) *Infection of the wound*.—In the milder cases of infection the following symptoms appear: a grayish infiltration into the edges of the wound, more or less redness of the eye, with lachrymation and later a slight mucopurulent discharge from the conjunctiva, redness and swelling of the eyelids and tenderness of the eye. Cauterization of the wound checks the infective process in a few cases.

In the severer cases of infection the infiltration extends still deeper into the upper half of the cornea, the iris becomes

involved, the discharge more profuse and the pain more intense. If the eyeball is saved at all in such cases it is usually with the upper half of the cornea opaque and with a retracted scar in which the upper half of the iris is implicated. There is rarely any useful vision after such an infection. In the worst cases the whole cornea becomes involved as well as the iris and deeper structure of the eye. Pan-ophthalmitis sets in and the eye is destroyed with subsequent shrinkage. Phthisis-bulbi following a severe suppurative infection, however, does not incite sympathetic inflammation as do shrunken eyes following a plastic irido-choroiditis.

Sometimes infection of the eye following extraction begins in the deeper structures, even after the corneal wound has healed. Purulent pan-ophthalmitis sets in and the eye is destroyed. As to the treatment in these infective and purulent cases, I am inclined to quote Knapp. (System of Diseases of the Eye, Norris and Oliver, page 808): "The treatment of all these suppurative processes in the great majority of cases is very unsatisfactory; it is only in the milder cases of partial suppuration of the flap that the eyeball may be saved; and if it is saved, so far as my experience goes, it is owing more to a mild degree of virulence of the infective material and to a strong vitality of the subject than to any one of the many remedies used and praised for this condition. I have not found that galvanocautery or disinfection of the wound are particularly beneficial. Opening of the wound and drainage of the anterior chamber, repeated every day, has had more effect than any other means I have tried."

(7) A minor complication following extraction is spastic entropion of the lower lid. This can be controlled by painting the outside of the lid and cheek with collodion

or, if this is ineffectual, a suture inserted in a vertical direction in the skin of the lid and cheek and tied tightly, will remedy the condition.

GENERAL COMPLICATIONS.—Shock, vomiting and delirium are the most important of the general complications which may follow extraction of senile cataract.

(1) *Shock* rarely occurs and only in patients very much debilitated. It is to be treated as after other operations, with stimulants internally and hot applications to the surfaces of the body, the patient, of course, being in bed.

(2) *Vomiting*.—This is, indeed, an unfortunate complication after extraction of cataract. The patient should be put to bed; should lie flat on the back and a mustard plaster should be placed over the stomach. Small pieces of ice may be placed in the patient's mouth, or teaspoonfuls doses of hot coffee or tea may be tried to relieve the vomiting. Any one of the numerous remedies prescribed for vomiting may be tried if the surgeon thinks fit. The nurse is to be constantly in attendance and should always support the patient's head during the vomiting. Fortunately, since the discovery of local anesthesia we rarely see this complication, for it is only exceptional now that we must resort to a general anesthetic,—the usual cause of vomiting following extraction.

(3) *Delirium*.—In nervous patients or patients in whom there is a tendency to insanity, delirium appears not infrequently within forty-eight to seventy-two hours after the operation. The mere fact of tying up both eyes in these patients seems to exert a bad influence on their nervous condition. Often the condition is completely relieved by removing the bandage from the eye not operated upon. Sedatives are to be given, the patient is to be kept as quiet as possible in bed and a nurse is to be in constant attend-

ance, one during the day and another during the night, to prevent the patient injuring himself or the eye. Sometimes, if the patient is allowed to go home, the familiar surroundings of home and friends serve to restore him to his normal mental condition.

DISCUSSION.

In the discussion which followed, DR. R. DENIG stated that in stupid and unmanageable patients general anesthesia was sometimes necessary. Affections of the heart and Bright's disease were contra-indications for its use. It was claimed that anesthesia induced congestion which might tend to promote hemorrhage. His cases had not given him this impression. As to hemorrhage in the anterior chamber, the absorption of the blood might be left to nature. Vomiting after general anesthesia was not to be feared. He mentioned that Gayet had employed general anesthesia in all his extractions and had studied this point by opening the lids of the patient while vomiting took place. He never saw any displacement of the lips of the wound or bulging of the vitreous. He always gave morphin hypodermically before the administration of the anesthetic.

As a rule, he employed the Angelucci fixation of the eyeball with a simultaneous use of Skeel's speculum; the fixation of the superior rectus was imperative in general anesthesia. During cataract extraction he directed the patient to keep his other eye open. He also had one or two drops of cocain instilled in the eye not to operated upon. He nearly always made a subconjunctival injection of cocain, following Koller's instructions, opposite the place where the section is to be made. In closing the fixation forceps, care should be taken to avoid folding up of the conjunctiva, as this may interfere with the section. He preferred not

to remove the speculum and fixation forceps before the operation is finished. The assistant should always hold the upper branch of the speculum slightly away from the eyeball during the operation. As to instruments, he agreed with Landolt who says: "Let us reduce the shank of all instruments in length, so that we can easily lay the little finger on the orbit of the patient while holding the instrument by the handle." He preferred an ivory-handled cataract knife. If the section is too small the wound should be enlarged, preferably by a sharp Graefe knife. After performing the iridectomy, he at once replaced the margin of the iris before proceeding any further. If there was some hemorrhage covering the field of operation, he syringed the anterior chamber with normal salt solution. Lately he had used the hook instead of the iris forceps, as it is claimed it causes less pain. In cases of prolapse of healthy vitreous, he removed the speculum and told the patient to close his eyes. He then syringed the lower cul-de-sac carefully with normal salt solution two or three times. On opening the eye he would find that the vitreous protruding between the wound lips had become liquefied and the wound closed. If we cut the vitreous with the scissors, there is danger of more vitreous bulging between the lips of the wound. In such cases he used the upper branch of Desmarre's speculum in finishing the operation. He always had a suture ready in every cataract extraction and, should expulsive hemorrhage occur, he would try to suture the wound. The majority of patients he kept in bed five or six days and covered both eyes for the first twenty-four hours with a light bandage consisting of a pad of gauze fastened by strips of adhesive plaster. In simple extraction he inspected the eye on the following day; in the combined, unless the patient complained of pain, he very often only changed

the pad, without permitting the patient to open his eye. On the third day, as a rule, the eye was generally allowed to go without any bandage. At night he always had the patient's hands tied during the entire term of his stay in the hospital. Slight displacements of the pupil, as are sometimes to be seen after simple extraction, should not be touched. The same holds more or less true of small incarcerations of the iris angle. Prolapses that are not localized to the angular portion of the iris, or imbedded in or surrounded by capsular shreds, thickened cortex, or both, near the angle of the iris, ought to be excised. Such incarcerations or small prolapses as are caused by escape of vitreous are, as a rule, harmless. Small prolapses that extend more or less along the whole section of the wound should be removed. As regards large prolapses, a clean iridectomy, after freeing the prolapse with the spatula from the wound lips, should be done. If a large prolapse is some weeks old, it may be let alone if it shows a tendency toward diminution; if not, it may be punctured with the Graefe knife and removed either with a pair of scissors or with the thermocautery. A flap of conjunctiva may be slid over the wound to prevent formation of a fistula. Old prolapses should not be touched. If there is tension, an iridectomy opposite the coloboma may be performed.

DR. F. VAN FLEET thought both eyes should be bandaged, and the bandage should not be removed for forty-eight hours. The patient could leave his bed at the end of a week. The secondary operation of discission should not be performed until the eye had become perfectly quiet.

DR. H. KNAPP described his method of peripheral capsulotomy in connection with the simple operation. This method left the pupil intact. By the simple operation, the method by which he almost invariably operated, he had

had scarcely any prolapses. He condemned the vertical incision of the capsule on account of the dense cicatrix it was apt to leave in front of the pupil and the fact that this cicatrix was very difficult to deal with. With the peripheral incision, subsequent discission was much easier and more satisfactory. Rupture of the zonule was an accident that might occur with a dull cystotome or too much pressure. A large secondary prolapse of the iris he abscised; smaller ones he let alone.

Dr. E. B. COBURN stated that in operating he preferred a speculum with a set-screw. He thought the practice of dropping holocain upon the iris just before cutting it was not very serviceable. He always examined the eye the following day. He suggested that nitrous oxide gas might be used in abscising a secondary iris prolapse. In a secondary iritis or iridocyclitis, in addition to the ordinary methods, he gave large doses of salicylate of soda. In infection he spoke highly of cauterization of the wound. Glaucoma was less frequent after the simple operation than after the combined.

Dr. J. H. CLAIBORNE stated that it was his common practice to cocainize both eyes. In this way an equal hypotony of both could be produced, and this he thought was very desirable.

Dr. PERCY FRIDENBERG stated that shaving or cutting off the eyelashes was very desirable in order to avoid the sticking together of the lids usually found at the first dressing. In order to avoid nervous symptoms, patients should not be operated upon the first day of arrival at the hospital. They should be allowed to accustom themselves to their surroundings. The cocainization of both eyes, mentioned by Dr. Claiborne, was very desirable.

Dr. A. E. DAVIS thought that the cautery, in cases of in-

fection, was not as efficacious as the method of opening and irrigating the anterior chamber.

[The question as to when to remove the first dressing after extraction is an important one. In case of combined extraction, I see no reason for removing it until forty-eight hours have elapsed, so long as the eye is not painful or uncomfortable. Wounds in other parts of the body when they do well, are best let alone—at least, that is the case in these days of aseptic surgery. But the case is somewhat different in simple extraction. As a rule, prolapse of the iris is indicated by some symptom of discomfort, yet this is not always the case. Stupid and sluggish patients will sometimes fail to tell you, even on being questioned, that the eye is uncomfortable or even painful, and the rule of action, in my opinion, in this matter of removing the bandage of the simple extraction, should, in a measure, be governed by the nature of the patient. In stupid and brutish people, it is the best policy to remove the bandage in twenty-four hours after simple extraction. When the patient is intelligent and sensitive, one can be governed, I believe with safety by his statements and sensations. As stated, there is no advantage, that I can see, in removing the bandage in twenty-four hours after combined extraction unless under exceptional circumstances. There certainly can be no prolapse, and if infection has taken place in that time, I believe it will, in a great majority of cases, make itself known by some untoward symptom. I have heard a surgeon say that he has known suppuration to take place in twenty-four hours after an extraction, without the patient experiencing any pain or discomfort. I have never seen this, and it is difficult for me to accept it as a fact.

Whenever a bandage is changed, risk is involved—the

risk of accident or the risk of infection. I have known an eye to be lost which I believe would have been saved, had I resisted the itching to look at the wound. The surgeon who insists on frequently looking at an eye that is doing well, reminds me of boys who plant corn and dig it up every day to see how it is growing.

Dr. Davis has pointed out the necessity of having a day and a night nurse for cataract cases. I think this should be an invariable rule, however docile the patient may appear to be, and an extraction should not be attempted unless this is possible. This is particularly true with regard to the first and second nights after operation, when the eye is tender and the patient still nervous. It is essential that the nurse be vigilant and attend to her duty.

In the case of alcoholics, it is important that they receive sufficient of their tippie to keep their nerves steady, unless the habit is completely broken before the operation.

I believe the postoperative excitement or the delirium which sometimes occurs after extraction may be modified or relieved by removing the bandage from the unoperated eye and leaving enough light in the room for the patient to recognize his surroundings. As a rule, patients can endure both eyes being bandaged the first night, but those that are excitable generally become worse the second day and night. It is good practice to remove the bandage from the unoperated eye the second day and keep it off in such cases. As Dr. Davis has pointed out, removal from the hospital to their home will sometimes restore mental equilibrium and save eyes which would otherwise be inevitably lost.

When infection has taken place, even in twenty-four hours, the cautery along the edges of the wound, followed by philosophic resignation on the part of both operator and patient, is the best treatment. J. H. C.]

CHAPTER VIII.

DISCISSION AFTER CATARACT EXTRACTION: ITS INDICATIONS AND TECHNIC.

RUDOLPH C. DENIG, M.D.

DISCISSION of a secondary cataract may be omitted if the sight is 20/40 or more, but even in such cases we may often be called upon to perform a secondary cataract operation; this depends a good deal upon the occupation of the patient and his age. A farmer will probably not need 20/20, while a city man, on an average, will insist on getting the full benefit of the operation.

Opacities of the cornea, of the vitreous and changes in the fundus are said to be among the contra-indications for the operation. I do not quite agree with this, as, for instance, in corneal opacities an iridectomy or an iridotomy may be performed opposite a transparent part of the cornea, and even in opacities of the vitreous or in changes of the fundus, partial atrophy of the optic nerve or partial detachment of the retina, some useful vision may sometimes be obtained by a secondary discission; it all depends upon the case and the circumstances. The following case may serve partly as an illustration:

Mr. M., forty-eight years, a clerk by occupation, presented himself in my office with a ripe cataract in his right and incipient cataract in his left eye. The candle-test showed projection toward the temporal side only, in his right eye, while with his left eye he counted fingers at a distance of nine feet. There was a detachment in both his eyes the one in

his left eye plainly to be seen with the ophthalmoscope. The detachment incident to high myopia had been present in both eyes for the last two years. The patient knew the condition of his eyes perfectly well himself and although told that the gain in vision to be expected by an extraction would be very little, he insisted on the operation, as in his opinion that little would help him to find his way. The operation was successfully performed, without any escape of vitreous. The patient counts fingers at a distance of two feet, and as there is some cortex left behind, I may be tempted to do a discission, especially as in this particular case the secondary cataract seems to consist of soft cortex, which may easily be divided by a fine knife-needle.

Secondary cataract imbedded in the vitreous does not present a contra-indication for the discission, for we have to remember that the *vis a tergo* in such cases is less if we have to deal with a liquified vitreous. The cataract may recede posteriorly as the knife advances, may shift with the needle or may even be partially dislodged. Another possibility is that the incisions may not gape. This may also happen in membranous, tough secondary cataracts, due to iridocyclitic processes with numerous and large adhesions to the iris. For such desperate cases and also for secondary cataracts imbedded in a completely liquefied vitreous I should employ the method recently recommended by Kugel.

In secondary cataract, imbedded in a normal vitreous and not complicated by iridocyclitic membranes, the incision may be made twice, first using the Graefe knife for cutting the cataract and then the knife-needle to push the edges of the incised membrane aside. Sometimes it may be advisable, to do the second incision a few days later.

A discission should never be performed before the eye

has entirely recovered from the cataract extraction i. e., about three weeks after. If the eyeball is entirely free from irritation we may safely operate, even in those cases in which an incarceration of the iris has taken place.

I am in favor of an early discission, because a secondary cataract is then more elastic, gapes better and offers less resistance to the knife-needle.

Only in those cases in which the extraction is followed by iridocyclitis or by some other complications, I wait from four to six weeks after the inflammatory processes have subsided.

One should not wait too long, because such iridocyclitic membranes get tougher and less elastic the longer one waits; at the same time it is wise to remember that unless such an eye is entirely free from inflammation, iridocyclitis may set in again.

Artificial light should be employed in performing the operation, and the field of operation should be illuminated sharply before the incision is made; only such parts of the membrane as promise to offer the least resistance to the knife needle should be attacked, although it is sometimes astonishing how easily apparently dense membranes can be divided; thin ones sometimes offer insurmountable difficulties.

We should never try to force the dividing of a tough membrane; at times we may be able to dislodge it after it has refused to be cut, or we may have to cut above and below in order to get useful vision. In cases in which we do not succeed with the knife-needle, we may have to use the Graefe knife instead. We should never force the operation, we should rather desist and chose another operative procedure some days later.

The Graefe knife is sometimes preferable to Knapp's,

especially if the cut is to be made through the limbus; with the Graefe knife, we can make a large, clean sweep, whereas Knapp's knife loses its keen edge when it is introduced through the rigid limbus.

The Graefe knife has the disadvantage that it can be used only for a single cut; it cannot be rotated while in the wound like the cutting needle. Care should be taken not to use the back of the blade for leverage, in order not to enlarge the puncture. If the Graefe knife is introduced through the cornea, there is also some danger of incarceration of vitreous substance.

Another instrument which we use occasionally is the de Wecker's scissors. For iridotomy and capsulotomy, to obtain an opening in the tough membranes left by iritis, de Wecker's instrument, introduced through a small peripheral corneal incision, is advisable. The instrument has its drawbacks: first, on account of the probability of escape of the vitreous and, secondly, because a tough, membranous secondary cataract cut by de Wecker's scissors, will, as a rule, refuse to gape.

All our instruments should be as sharp as possible, for we have to cut and not to tear.

Many operators nowadays prefer to introduce the knife through the conjunctiva or limbus. This method has its good and bad points. By making the wound sclerocorneal and subconjunctival the retention of aqueous and vitreous will be obtained. It is also claimed that it is a better safeguard against infection. Eight years ago, I had a case of infection after discission, which I am sure would not have happened if I had made the sclerocorneal incision. It was one of those cases in which on the day following the operation a little thread of vitreous could be observed attached to the wound. Although such an

occurrence is, as a rule, harmless, it proved to be disastrous in this case. The patient had some chronic eczematous condition of her lids, which apparently was aggravated by the operation and caused an infection. Since that time I always have the eyelashes pulled out in cataract complicated by blepharitis.

I make the sclerocorneal incision not only in these cases, but also in very thin uncomplicated secondary cataracts and in cases in which there is liquified vitreous. In all other cases I make the incision through the cornea. If dense bands are to be cut, it is advisable to start with that portion of the membrane, which is less dense and to finish in the denser part.

Kuhnt always cuts through the limbus, using an angular-shaped discission knife. He claims to have no difficulties in cutting even tough, unelastic bands with it.

The chances of retention of the aqueous are better when we puncture the cornea obliquely. It is also advisable to withdraw the knife slowly from the secondary cataract, but quickly from the cornea.

In uncomplicated, thin, secondary cataracts many operators prefer just one single incision of the membrane, taking care to injure the vitreous as little as possible. Kuhnt thinks that the injury done to the vitreous can be minimized by making a sclerocorneal incision, and he opens and splits the membrane side ways with one cut of his knife. He has seen very few cases of glaucoma after discission, and claims that the introduction of the knife through the cornea in a more or less vertical direction and the formation of a T-shaped or crucial incision produces a greater injury to the vitreous and consequently more secondary glaucoma.

In many cases the single incision about 7 to 9 mm. long, will not make an opening sufficiently wide and we have

to rely on the T-shaped or the crucial incision. But even then it may happen that the opening is not large enough; we may notice this immediately after the operation has been done. In such a case we may safely introduce the knife again at the same sitting. This occurrence is likely to happen in very thin, secondary cataract with no elastic bands, or in tough spongy membranous cataracts.

In some cases perhaps the mydriasis may be the cause, as I have seen cases in which the opening seemed to be sufficiently large and no aqueous was lost during the operation; whereas when the pupil became smaller, on the third or fourth day, the opening also became smaller, the contracting sphincter apparently pushing the incised capsule closer together. For this reason I mostly rely on homatropin for the dilatation of the pupil; in some cases of a naturally wide pupil, I use cocain only.

Loss of aqueous during operation also favors such an occurrence; the opening, which is made larger by the protruding and bulging vitreous, gets smaller as soon as the anterior chamber is restored. We should, therefore, bear in mind, in cases in which we lose aqueous during operation, to make the opening as large as possible.

Loss of aqueous, generally a harmless incident, may also sometimes favor the formation of threads of vitreous or even escape of vitreous, especially if the latter is liquefied. As I mentioned above, a worn-out knife-needle, perhaps faulty technic of the operator or unruly behavior of the patient may be responsible.

We should introduce the knife obliquely through the cornea; we should not move it too much forward or backward while in the anterior chamber; we should not rotate it too much and withdraw it slowly out of the pupillary region, but quickly through the cornea.

As regards the formation of threads of vitreous, to be seen on the second day after operation, I make it a practice in suspicious cases to seal up the wound by cautery. Some operators go even so far as to cauterize the wound in case of loss of aqueous. Sometimes we see on the day following the operation the corneal wound covered by what seems to be a little particle of mucous membrane. In such cases I take no chances and always cauterize the wound.

In withdrawing the knife a thread of the capsule may block the wound; by depressing the cornea we may manage to force the thread back into the pupillary region.

The operation should not be complicated by hemorrhage, unless the iris is cut by the knife or indirectly torn as in the presence of numerous posterior synechiæ. Such a hemorrhage may not be absorbed, may stay in the pupillary region and destroy the result of the operation.

I never bandage the eye after a simple, uncomplicated, discission; I only have the patient's hands tied during the night.

After operation the patient may complain of pain for a couple of hours, if the pain does not stop, the possibility of secondary glaucoma must be borne in mind.

While secondary glaucoma occurs more frequently after the combined extraction than after the simple, the opposite holds true for discission: We find more secondary glaucoma after the discission of a secondary cataract following a simple extraction than a combined one. In case of secondary glaucoma myotics have to be used or an iridectomy may have to be performed.

Amongst other complications iritis, cyclitis, iridocyclitis and the combination of glaucoma and iridocyclitis may be observed. Kuhnt described a case of secondary glaucoma and iridocyclitis after discission; he performed an iridectomy

but did not succeed in cutting the iris, as it could not be grasped even with the hook; immediately after the opening of the anterior chamber there was a great loss of vitreous, but although the operation had to be discontinued, the inflammation and the glaucoma subsided almost immediately and the final result was very good. Kuhnt thinks, that there existed an incarceration of the vitreous, which had produced an irritation of the ciliary body.

A faulty technic or blunt instruments may also cause a laceration of the vitreous, with subsequent vitreous opacities and even retinal detachment. I observed for the first time about a year ago a very peculiar formation of an opacity in the vitreous a few months after a perfectly smooth operation on a secondary cataract. I noticed attached to the upper edge of the divided membrane and a little behind it, swinging backward and forward with the movements of the eyeball, a very strange, cowweb-like opacity of the vitreous. In view of the uncomplicated simple discission I had done, I am at a loss to account for its presence; there were never any symptoms of cyclitis to be seen, although some irritation of the uveal tract, followed by proliferation of the capsule, was probably the cause of it.

Referring again to complicated secondary cataracts, such as are caused by iridocyclitis, the choice of the operative procedure is regulated by the amount of damage caused by the inflammation. If there are, for instance, one or two adhesions of the secondary cataract to the inferior edge of the pupil, the knife-needle may easily detach the membrane from the iris and provide a sufficiently wide opening.

If there are numerous posterior synechiæ present we may still try the knife-needle or the Graefe knife, but the incision may not remain open. We should then never force the operation but, as I said before, desist and a few days

later choose a different method. In some cases an iridectomy opposite the secondary cataract with subsequent discission may be performed or diverging cuts with de Wecker's scissors may be made. The risks may be lessened by making the wound sclero-corneal and subconjunctival.

In some cases we may have to open the anterior chamber with a keratome and remove a part of the membrane with forceps.

If we have to deal with occlusion of the pupil, where all our resources seem to be of no avail, Kugel's operation is indicated.

DISCUSSION.

DR. T. R. POOLEY stated that in practicing discission he nearly always employed a small Graefe knife, such as had been recommended by Dr. Wilson, of Bridgeport; he used it in all forms of secondary cataract and was better pleased with it than with any other instrument he had employed. He had observed secondary glaucoma several times after discission. Iridocyclitis was caused by too great traction upon the ciliary processes.

DR. W. E. LAMBERT thought that enough stress had not been laid upon the use of de Wecker's scissors, which were particularly serviceable when the membrane was tough. If a transverse incision was first made in the membrane with the keratome and then two vertical cuts downward with the scissors, gaping readily took place and a sufficient opening was usually obtained.

DR. H. KNAPP stated that in secondary glaucoma iridectomy was necessary. The iridectomy should not be too small.

DR. J. E. WEEKS stated that when incarceration of vitre-

ous took place in the wound the actual cautery seemed the best method of limiting its bad effects. He cauterized the wound in every case in which the aqueous was lost or when he thought the vitreous might be in the wound. Sometimes after operating on the membrane, the vitreous bulged forward through the opening in a large, tree-like mass, the surface of which not infrequently became covered with opacities. Cyclitis was usually the cause of these secondary deposits. With modern antiseptic method he did not think there was any excuse for infection following a capsulotomy. The time at which discission should be performed differed in different cases. The capsule cuts more easily before it is too old: at the end of three or four weeks discission could be more readily performed than at the end of six months. He was very much in the habit of using a Graefe knife and liked it very much, especially when there were tough bands to divide.

DR. D. W. HUNTER stated that glaucoma was often caused by tough bands and that, when these were severed, the tension was relieved.

DR. E. B. COBURN believed the discission should be done as soon as possible after the inflammatory symptoms caused by the primary operation had disappeared. Glaucoma was often caused by pieces of hyaloid or capsule drawn into the wound.

DR. D. W. HUNTER believed that the thick portions of the membrane rather than the thin should be attached.

DR. J. H. CLAIBORNE stated that the most unruly patient could be controlled if plenty of cocain were used and if the cocain were instilled into both eyes. He had seen thread-keratitis follow discission. He had formerly employed two needles, but of late had abandoned this method. We should cut through the thinnest portion of the membrane.

[Some years ago I had constructed a sickle-shaped knife for cutting the capsule of secondary cataract. The instrument resembled a Tyrell's hook, except that it was larger, and the concavity was ground to a fine cutting edge. An opening was made in the anterior chamber with a small keratome, the knife was pushed in convexity foremost, and turned at a right angle as soon as the capsule was reached; the membrane was then pierced by the sharp point and the blade drawn toward the wound.

In two cases excellent success followed—a clear and wide split was made in the capsule. This instrument was used only after the combined operation.

The “baby” Graefe knife of Wilson, referred to by Pooley, I have used and seen used a number of times. It does excellent service, and may be ranked with Knapp's stop-knife.

The operation of discission of the secondary cataract, appears to be so simple a procedure and occupies so little time that one is apt to become careless in performing it. As a matter of fact, the operation is difficult, is often unsuccessful, and has been known to be followed by suppuration and loss of the eye. Every precaution that is taken in the extraction should be taken in this operation; each case should be studied and the best method and the best instrument fitted to the case, should be employed. It seems best to keep the eye bandaged for at least, twenty-four hours. J. H. C.]

CHAPTER IX.

EXTRACTION OF CATARACT IN THE CAPSULE.

WILBUR B. MARPLE, M. D.

IF anyone supposes that the writer accepted the invitation of the chairman to present the following paper because he poses as an advocate of the extraction of cataract in the capsule as a routine practice, he wishes to correct the misapprehension at once. He never has done it, and doubts if he ever will, except in cases in which it is plainly indicated in the manner to be brought out below.

It is now thirty years since Pagenstecher advocated the extraction of cataract in the capsule in selected cases, and more recently Major Smith, of Jullunder, India, has done a similiar operation as a routine procedure.

The technic of Pagenstecher's operation is as follows: Strict attention to asepsis is given and cocain is employed. He syringes out the lachrymal canal with sublimate solution, 1 to 5000, before the operation and, being ambidextrous, operates on the right eye with the right hand and on the left eye with the left—standing at the head of the patient who is lying in bed. The section is made upwards in the sclero-corneal margin, so that it lies wholly in corneal tissue, with more or less of a conjunctival flap. The position of the section in the cornea favors rapid healing, and the conjunctival flap tends to bring about early closing of the wound. As Pagenstecher says, however, it is of more importance that the section be made with a steady hand and a sharp knife and that it shall not become infected than that its location be accurately adjusted.

The section should be large enough in each individual case to allow the easy extraction of the lens. When the lens is extracted in the capsule the section, above all, must not be too small, yet it should never be larger than one-third of the corneal circumference. (I generally make the section two-fifths of the corneal circumference.) Morgagnian cataracts, of course, slip out through smaller sections. Pagenstecher operates with a small knife, selecting one with the back not too thick. He thinks that a knife with too thick a back bruises the tissues at the points of puncture and counter-puncture, and that this may delay healing and predispose to infection. He uses a Weiss knife with double edge, but admits that it bends easily.

He always does an iridectomy, since the vision is practically the same whether or not there is a coloboma, and he would rather excise the iris than expose a single case to the danger of a prolapse. After freeing the pillars of the coloboma, an attempt is made to expel the lens by making pressure through the lower lid against the cornea below, while the scleral margin of the wound above is gently pressed backward with the spoon. Sometimes this manoeuvre succeeds in expelling the lens. If it does not, he introduces the spoon rather steeply behind the upper border of the lens; the handle is then depressed and the spoon is gently advanced, but not beyond the posterior pole of the lens. The assistant now makes gentle pressure upon the lower corneal margin with a specially constructed glass spoon or pusher, sliding this upward over the cornea with light continuous pressure, thereby pushing the lens upward into the wound. In this manner the spoon in the operator's hands serves more the purpose of an inclined plane upon which the lens is pushed out than of a traction instrument; at the same time it holds back the vitreous and prevents it

from escaping. Only when the zonula is pretty firm and when the lens by moderate pressure from without cannot be entirely delivered should the operator push the spoon further to the lower border of the lens, seize the latter from behind, and extract the cataract, while the assistant makes gentle pressure upon the cornea.

Pagenstecher thinks that when correctly done, in a proper case, it is a more conservative operation than when the capsule is opened and pressure is made upon the globe in expelling the nucleus and removing the cortex.

He flushes the conjunctival sac with a sublimate solution, 1 to 5000, before and after the operation, covers the eye with sublimate gauze, then with cotton wet in the sublimate solution, and finally with a bandage. When there is chronic conjunctivitis or a recently cured dacryocystitis, he employs a modified "open treatment." He covers the eye with a moist sublimate compress which is changed every two hours or three times a day; at the same time he washes the eye out with the above-mentioned solution.

He has been surprised at the very slight irritation which attends the healing in these cases.

When the eye is bandaged, he uses a form of coquille, as we do the mask, and as soon as the wound is closed he keeps on the coquille alone. (I myself have found in not a few cases that removal of the bandage within three or four days after the wound has closed, leaving the eye protected simply by the mask, has been followed by a more rapid clearing up of the redness of the eye.)

It may be instructive to bring out the indications for Pagenstecher's operation by briefly referring to one or two cases which have come under my observation.

Case I.—August 19, 1902, I operated at the New York Eye and Ear Infirmary on an old lady who had a hyperma-

ture cataract in the right eye. Careful examination previously showed that there was no sign of luxation of the lens. When an attempt was made to do a capsulotomy, the cystotome merely pulled the lens bodily after it, but did not lacerate the capsule. At the same time, vitreous presented in the wound. An iridectomy was made, the spoon was introduced, and a large brown lens was extracted with the loss of scarcely any vitreous. The result was excellent, and the patient was discharged in ten days. I thought at the time that the reason for the complication was a dull cystotome, but the same accident happened to me again after this when the cystotome was known to be in perfect order. It was evident that the lens was so hard, its capsule so adherent, and the zonula so atrophied, that the cystotome merely dug into the hard lens and pulled it along after it.

These lenses may not infrequently be removed without the introduction of a cystotome or spoon into the eye, and a cautious attempt to do this should generally be made. In several cases I have succeeded in extracting the lens in this manner.

Case II.—On June 23, 1905, I operated at the New York Eye and Ear Infirmary on the right eye of an adult male for shrunken cataract. After a small section, an unsuccessful attempt was made to express the cataract. I then endeavored to seize it with Dr. Gruening's forceps, but this attempt also failed. A small iridectomy was then done, and pressure and the forceps again failing I cut through the zonula with a Graefe knife. The spoon was then introduced and the cataract was extracted after one or two unsuccessful attempts, with the loss of a very little vitreous. The reaction was slight, and the patient was discharged in two weeks with a good result.

These two cases illustrate one of the indications for

Pagenstecher's operation, viz., hypermature cataracts. Under hypermature cataracts belong, of course, Morgagnian cataracts, and those that are shrunken and chalky.

Case III.—On June 30, 1904, I operated at the Infirmary on the left eye of a man. This patient had made several trips to Des Moines, Iowa, to consult a quack who cured cataracts without operation. This person had given him a "massage apparatus" to use, which was nothing more than an electric bell, without the bell. He would hold this up to his face so that the tapper would pound on his eye through the closed lids when the current from six cells was turned on. This was the "massage," and a brief experience demonstrated to me that it was quite painful. So far from curing the condition, it ripened both cataracts in a surprisingly short time, for ten days before he had been able to attend to his business, but then had to be led to my office. Both lenses were opaque and swollen; he saw fingers at five feet in one eye and at one foot in the other. In addition, the left lens was partially dislocated and there was a tremulous iris. It is easy to imagine the force with which this instrument "massaged" the eye.

Operation.—Left eye. After the section and iridectomy, vitreous presented. I introduced a wire loop back of the lens, and almost lifted it out, but it slipped back. This necessitated a second introduction of the loop, and this time the lens was extracted without the loss of vitreous. His vision with correction was finally 20/15, though on the fifth day I had to cauterize a portion of the wound. The anterior chamber was slow in closing.

This case illustrates another indication for Pagenstecher's operation, viz., dislocated cataracts with presentation of vitreous after section or iridectomy. A further indication for the operation, according to Pagenstecher, is furnished

by cataracts which have formed in eyes that have had chronic iridochoroiditis with occlusion of the pupil. I have recently, however, operated in such a case satisfactorily with capsulotomy and subsequent needling.

Contra-indications:

1. Even when from its character a cataract is suitable for this operation, it is contra-indicated if, after section and iridectomy, the tension of the vitreous is high or the patient is unruly.

2. In cataracts which have been ripened by Förster's method, it is best not to attempt to extract in the capsule, since the latter is very tightly stretched by the swelling of the lens masses and is apt to rupture if such an attempt is made.

3. Cataracts which have been ripe only a short time, and have ripened quickly, as in the course of a few months, should not be operated upon after this method, as the capsule has not attained sufficient strength compared to that of the zonula.

Pagenstecher says he regrets that he cannot operate upon all cataracts in this manner, and that the only reason he does not is on account of his conviction that the majority of cases are not suitable for it, inasmuch as the capsule is apt to rupture and part of it remain behind in the eye.

Advantages of the Operation.—The vision secured in this manner is permanent, for there is no capsule left behind to subsequently wrinkle and cause deterioration of sight. The pupil is clean, the best possible vision is secured, and a secondary operation is not necessary.

Disadvantages.—There can be no doubt that loss of vitreous occurs by this method far more frequently than when the capsule is left behind. Pagenstecher operated upon seventy-four cases in which the cataract in one eye was hyper-

mature and in the other eye simply mature. He extracted the first seventy-four with the capsule and the last seventy-four without the capsule. In passing, it might be noted that of these seventy-four cases Pagenstecher operated on both eyes in fifty-six at one sitting—a practice as to the wisdom of which opinions differ.

(I have never operated upon both eyes at one sitting, and it has always seemed to me that Dr. Knapp's position in reference to this was correct. If we operate on both eyes at the same time, the conditions are alike, and if there should happen to be a break in our chain of asepsis and infection should take place, both eyes would be lost—an appalling calamity. Moreover, during the treatment, we learn many peculiarities of the bodily and mental conditions of our patients, which it is of advantage to know at the second operation. If there are any particular circumstances making it desirable to have the two eyes operated on at about the same time, a good compromise is operate on the second eye a week or two after the operation on the first.)

Of the seventy-four cases extracted in the capsule there was loss of vitreous in thirty-nine, or in nearly 53 per cent.; while in the seventy-four cases extracted without the capsule this complication occurred in only five, or $6\frac{1}{2}$ per cent. While Pagenstecher prefers not to lose vitreous, his experience has led him to look upon such loss in extraction in the capsule as an unimportant complication, attended by no further danger to the eye so long as strict asepsis is observed. There are few observers, however, who agree with him, that this accident is of such trifling significance.

Ray, of Louisville, will read at Atlantic City, before the Section on Ophthalmology of the American Medical Association, a paper on "The Immediate and Remote Effect of Loss of Vitreous in the Operation for Extraction

of Cataract." In this paper he has collated the views of a number of operators of skill and experience upon the question whether loss of vitreous at the time of extraction increases the danger of infection. Most operators consider that the vitreous is a perfect culture for micro-organisms, and that the probability of infection is greater when the hyaloid is ruptured and vitreous is lost. Ray concludes that loss of vitreous at the time of extraction adds to the danger of primary infection, this danger being irrespective of the quantity of vitreous lost but dependent largely on the care used in the preparation of the field of operation.

With this opinion I agree in the main. I confess that I am much relieved when on changing the dressing I find everything in a satisfactory condition in a case in which I have lost vitreous.

While most operators consider that loss of vitreous predisposes to subsequent detachment of the retina, it must be confessed that Pagenstecher's results do not support such a view. Out of 600 extractions in the capsule, done by himself and his brother, he met with only *one* case of detachment of the retina, and this in a myopic eye with extensive choroiditis and fluid vitreous—surely a most excellent showing according to any method. Moreover, there is some force in what Pagenstecher says, viz., that, as so often happens, one here confuses cause and effect. If an operator happens to do an extraction with loss of vitreous in one or several ways in which subsequent detachment occurs, he immediately concludes that the loss of vitreous is the cause of the complication, whereas the real cause lies in certain pathological changes in the eye which predispose to retinal detachment, and this, together with the fluid vitreous or detachment of the vitreous present at the same time causes the loss of vitreous during the operation. Moreover, when this com-

plication occurs, the pillars of the coloboma are much displaced and the coloboma thereby is widened. This does not improve either the cosmetic or visual results.

Another disadvantage attending extraction in the capsule is that the resulting astigmatism is greater.

Rupture of the capsule very seldom happens in the ordinary method of operating or when the extraction in the capsule is limited to those cases in which Pagenstecher considers that it is indicated. In 117 cases operated on by him, rupture of the capsule occurred only four times.

Management of Prolapse or Loss of Vitreous.—If merely a bulging of the vitreous occurs without any actual loss, Pagenstecher says that this usually returns under the pressure of the lids. Until quite recently my own experience tallied with this observation. Some weeks ago, I extracted a hypermature cataract in the capsule with iridectomy. There was a small hernia of the vitreous, but no loss. I bandaged the eye, hoping that the vitreous would return, as I had seen it do before. On account of my subsequent illness I did not see the patient again for ten days. A condition had arisen which is well described by Czermak: "After the rupture of the zonula the hyaloid yields and the vitreous bulges forward and presses against the wound, causing it to gape. The iris is thus folded between the lips of the wound and incarcerated, whether or not there has been an iridectomy. The coloboma is thus made surprisingly broader and its pillars can be released only with the greatest difficulty, or not at all." This is exactly what had taken place in this case, and the condition was not at all satisfactory. The wound did not close for fully a month. So that if I had a similar case and still found bulging of the vitreous when I changed the dressing, I should excise it.

When there is actual loss of vitreous, Pagenstecher cuts it off close to the wound with scissors curved on the flat. My own observation has been that when vitreous is excised more follows, so that I have usually left the vitreous tags untouched, and generally at the first or second dressing I have found the wound closed.

Sometimes after the loss of fluid vitreous, sometimes when no vitreous has been lost, the eye collapses and presents what Knapp used to call a "squeezed-lemon" appearance. In these cases it is always well to gently inject sterile normal salt solution, so as to restore the shape of the globe and thus bring the edges of the wound into apposition. Knapp reported (in his *Archives*, 1899, page 308) cases treated in this manner, and Andrews also reported cases treated in a similar manner (Knapp's *Archives*) 1910, page 50).

The writer has a great deal of respect for the conservatism of Czermak, and agrees with his conclusions as to the value of Pagenstecher's work. Czermak says: "In these cases an accurate diagnosis is of the first importance, as Becker has already emphasized in his work on "The Pathology of the Lens System." But it is in just this direction that the untiring work of Pagenstecher has accomplished so much. Where he has succeeded in establishing the diagnosis as to the nature of the cataract and its appendages to such a degree of accuracy that of 117 cases extracted with the capsule, the latter ruptured only four times, he has attained as high a degree of accuracy as one could desire. This much we must admit unhesitatingly."

With the operation of Major Smith the writer has no personal experience, and therefore will refer to it in only a few words. It should be said, however, that the visual result in Major Smith's cases is almost an unknown quantity, for in many instances the patients are discharged in a few

days and lost sight of before any accurate visual tests are made. After doing ten of these operations, Cheney, of Boston, an exceptionally skillful operator and astute observer, concludes his report as follows: "While I am inclined to believe that a small per cent. of lenses may with advantage to the patient be extracted, I shall do very little more pioneer work in attempting to determine the cases best adapted to this operation. There is one sentiment of Major Smith's, in his article in the *Archives of Ophthalmology*, that expresses so admirably my feeling on this subject that although the application is a very different one I will take the liberty of quoting it in concluding this paper: "There is virtue in knowing when to quit and in letting 'well enough' alone."

DISCUSSION.

DR. E. GRUENING thought that Pagenstecher's operation should be limited to hypermature cataracts and cases in which, through accident, the vitreous presented before the lens was extracted and to cases of luxated lenses.

DR. T. R. POOLEY thought the operation should only be performed in exceptional cases.

DR. J. E. WEEKS thought that we should be forced to do it rather than do it by choice. The capsule was sometimes so tough that it could not be properly lacerated. As a matter of routine, the results of a Pagenstecher operation were generally poor. Loss of vitreous was not a desirable thing, and inclusion of vitreous in the wound was an unpleasant complication. Prolapse of vitreous, when it did occur, should be excised.

DR. A. N. STROUSE thought that the extraction of the lens in the capsule was the ideal operation and would be the method of the future. Loss of vitreous occurred after all

methods of extraction, and he did not believe that it was more serious occurring after Pagenstecher's than after the others.

[The removal of cataract in the capsule is undeniably the ideal one, but it is doubtful if its employment will ever be universal. Major Smith, however, has shown that it may be successfully performed in a large proportion of cases. Yet to operate on a Hindu, who only asks for enough sight to get about or go to his home and become lost among his inconsequential fellows, is one thing, and it is another to operate upon those whose sight is the source of their livelihood or the joy of their old age. Failure in the one case is hidden among the multitude which is naturally resigned or contented with little; in the other, it is heralded abroad, and the unhappy patient is a walking advertisement of misfortune or of the surgeon's incompetency. In the hands of the ordinary operator, the extraction in the capsule, I believe, is a hazardous undertaking, and would be followed by a much greater percentage of failure than either of the methods at present in vogue. Gruening has expressed the view of the majority of American surgeons, when he stated that the operation should be restricted to hypermature cataracts, to cases in which through accident, the vitreous presents before the lens is extracted and to cases of luxated lenses. J. H. C.]

CHAPTER X.

THE OPERATIONS FOR THE ARTIFICIAL MATURATION OF CATARACT.

THOMAS R. POOLEY, M. D.

The object of this paper is to present as succinctly as possible the various methods of operating in immature senile cataract to secure maturation; to give, from the writer's stand-point, the comparative merits and demerits of the same; and to bring out such discussion from the members of the section as will show the attitude of those present on this subject.

Before enumerating the different operations practiced and the dangers and complications liable to follow each one, I shall mention the forms of cataract in which the operation is contra-indicated. These are: Slowly sclerosing lenses with few striæ, posterior polar cataract, and slowly forming cataract in myopic eyes, as well as all those cases in which there is any indication of luxation of the lens, as shown by tremulousness of the iris.

Before any procedure is undertaken, however, we should be sure that the tension is normal and the pupil dilatable.

The methods which have been described, I will enumerate in tabular form:

1. Simple discission of the anterior capsule.
2. Discission combined with iridectomy (Mooren).
3. Discission and external massage.
4. Iridectomy and external massage (Förster).

5. Iridectomy and internal massage directly on anterior capsule (Bettman and Born).
6. Simple paracentesis with indirect massage (Pooley, White).
7. Paracentesis with direct massage.
8. Jocq's injection by the Pravaz syringe of aqueous beneath the anterior capsule.
9. A method recently practiced by the president of this section, which is in effect a modification of Mooren's, and of which he is to present a detailed account.

It would prolong this paper beyond proper limits and prove of no practical value to describe minutely the technic of each operation, especially as all this may be inferred from the definition given in the list, which is fairly familiar to every one.

Simple discission of the anterior capsule—which Knapp considers the most efficient of them all—falls short by ripening only the anterior cortex so that considerable portions of the posterior cortex are apt to be left behind. Others do not share in Knapp's opinion, but consider this method the most dangerous of them all on account of the inflammatory changes which may follow too rapid swelling of the lens, and consequent increase of tension. Iritis and even panophthalmitis have followed the operation. The opening in the capsule may be either too small or too large; in one instance it may become plugged by cortex which has been squeezed out of the capsular wound and subsequently closes; in the other, as stated, glaucoma or inflammatory reaction is threatened. These same objections hold good in Nos. 2 and 3 of the list.

As to the fourth method, Förster's operation, it is, perhaps, to be preferred, on the whole, to any other procedure. But to those who prefer the simple extraction the iridectomy

would be a serious objection. Some fibers of the iris are likely to be pressed between the lens and cornea and thus cause iritis. Mittendorf has reported the loss of an eye which followed this condition. The epithelial coat of the cornea may be rubbed off. Förster himself has called attention to injury of the cornea and iris, and dislocation of the lens. It may be well to add here that the latter danger should be included among the dangers in all operations for artificial ripening of cataract.

The operation of direct massage could be done with or without iridectomy.

So far as I know, Dr. Born, of this city, was the first to propose and practice this method, which he did after the accomplishment of the iridectomy, by making massage directly on the lens capsule with the knee of a squint hook.

To Dr. Bettman, of Cincinnati, is attributed the priority of this operation, as he published an account of the method. It is, however, somewhat different from that of Dr. Born, and will be described more in detail later. By many this is considered the best method, as it avoids the danger of injury to the cornea and iris. It would seem, however, that the danger of dislocating the lens is greater. The operation of indirect massage without iridectomy, so far as the writer knows, was first described by himself in the *Medical Record*, December 26, 1885, as a modification of Förster's method of artificially ripening cataract. Before him, Candon, in an article on the artificial maturation of cataract, *Revue générale d'ophtalmologie*, 1883, says at the conclusion of his paper that maturation of cataract, when we intend to extract without iridectomy, may be done by making paracentesis of the cornea and letting the aqueous humor escape, when the lens will fall forward upon the cornea, after which it can be triturated from without. He does not state,

however, that he had ever done this operation himself. Therefore, I think I may justly claim for myself the priority of the method.

My method was based upon the fact, well known to those who have used cocain in operations upon the eye, that the aqueous escapes very slowly after puncture or incision of the anterior chamber, and this led me to consider whether its use would not enable us to perform the operation suggested by Förster without iridectomy. The objection to such a procedure without iridectomy is obvious. The pupil will contract and both the lens and iris will fall forward against the cornea. Thus, the iris will be injured unless the pupil is kept widely dilated during the next step of the operation, which consists in rubbing the cornea over the exposed surface of the lens.

The operation thus suggested to me was performed upon a rabbit's eye by first rendering the lens partly opaque, and then maturing it by a second operation. Suffice it to say, the writer has since performed it upon patients with varying success in cases of immature cataract.

In Bettman's operation (the fifth in the list), the technic of which differs somewhat from that of Born's—the cornea is opened by a keratome, iridectomy is then done, and gentle massage is directly made on the anterior capsule of the lens with a spatula.

Jocq's method is new, and has not been sufficiently tested to permit an opinion of its value.

When one takes into consideration the uncertainty of obtaining success in bringing about a complete opacification of the lens, when we bear in mind the dangers and complications which may ensue upon the employment of any of them and when we recognize that a great many operators are no longer possessed of the fear which they so long

entertained of operating upon immature cataracts, we feel like falling in with the wise conclusion made by Knapp when he said: "Many operators, the writer included, prefer the risks of removing an immature cataract to any ripening operation."

CHAPTER XI.

A NEW PROCEDURE AND INSTRUMENT FOR THE ARTIFICIAL MATURATION OF CATARACT.

J. HERBERT CLAIBORNE, M. D.

THE preceding paper of Dr. Pooley has set forth in part if not in whole, the various methods which up to this date have been used to ripen cataracts artificially. The only method which he has mentioned which bears upon the one I shall now describe is the procedure of Mooren described in his paper entitled, *Die operative Behandlung der natürlich und der künstlich gereiften Staarformen*, published in Wiesbaden, 1894. He gives an account of his method on page 14. The following is a free translation:

“About eighteen to twenty-one days after an iridectomy has been done, the second step of the operation is undertaken. This consists in a widening of the iris coloboma by the use of a solution of atropin. The lens capsule is then opened about three quarters of its diameter with a discission needle. The iris should not be touched with the needle, in order not to cause iritis. In opening the capsule care should be taken that the lens substance is not injured, so that the subsequent swelling of the lens may not be uneven and bands may not be formed between the iris and the lens. The less the lens is touched in opening the capsule, the more even and the more perfect will be the transformation into a cataractous opacity. The whole idea of the operation is to bring the aqueous humor into contact with the lens substance, and so produce a rapid formation of cataract.”

It will be observed, from the foregoing, that Mooren's procedure consisted (1) in an iridectomy; (2) subsequent

dilation of the coloboma with atropin; (3) a discission of the lens capsule with the discission-needle at the end of eighteen to twenty-one days, and (4) extraction of the lens. The exact time at which he extracts the lens is not stated. Subsequently he used Graefe's cataract knife to cut the capsule instead of the discission-needle, and also combined Förster's trituration method with this procedure. He states that sometimes in children the cataract has ripened in three or four days, and usually in ten days in grown people.

His first attempts to ripen a cataract were made in the second year of his practice, and were done by discission with the needle, with a very small opening in the capsule. In his first attempts he did not do an iridectomy, and he states that as soon as he commenced to do an iridectomy the safety and certainty of his operations began. He performed at least as many as 220 operations successfully, and continued to ripen cataracts by his first and second methods for many years before his death. Mooren has, therefore, already demonstrated that the immature senile cataract can be successfully ripened, and subsequent extraction performed with good results. Notwithstanding his excellent results, and the long continuance of his methods, few surgeons have followed him and the procedure has practically fallen into innocuous desuetude. Mooren refers in particular to one case which it seems to me is of great interest. He operated upon a German colleague of his, Dr. Küster by name, who had a high grade of myopia and a posterior polar cataract which was about the size of and occupied the center of the pupil. This annoyed him so that he was unable to attend to his duties, and Mooren ripened and operated on both of his cataracts with success. As Mooren remarks, Dr. Küster not only rejoiced in the excellent sight which he had, but particularly in the fact that his near-sighted-

ness had been removed with the cataracts. Mooren does not state definitely whether he employed iridectomy in the operation upon Dr. Küster or not—in short, whether he operated by the first method or by the second. From the context it would appear that he operated with iridectomy.

The procedure which I bring before you tonight is similar in many respects to that of Mooren, but differs from it radically in other respects. I have employed my procedure upon one case only, and I present the patient and also the instrument with which the operation was done. Several times in my career I have attempted to artificially ripen cataracts, and have employed the method by which an iridectomy is done; the anterior capsule is stroked with a smooth instrument, or pressure made upon the capsule with a smooth instrument through the cornea. In all these cases the effect has been practically *nil*, and I fancy the majority of surgeons have had similar results with those methods. In one case I even gently scratched the anterior capsule with a cystotome; so far as ripening the cataract was concerned the result was negative, but when the eye healed, a streak could be plainly seen on the anterior capsule where the scratch had been made. After this case, it occurred to me that if an instrument was constructed by which a number of very fine incisions could be made with cambric needle points upon the capsule, the aqueous humor could be brought in contact with the lens substance without a protrusion of the latter through the capsule. Thus, an irregular swelling of the lens might be avoided and the cataract ripened in a reasonable length of time.

In pursuance of that idea I had an instrument made based upon the principle of the agricultural harrow. The instrument was constructed somewhat like a lance shaped keratome, and had on its under surface five very sharp

needle points—one at the apex of the blade, and the others arranged two on either side in a straight line. It will be understood, therefore, that in drawing this instrument across the face of the capsule three streaks would be cut in the capsule, the points in the rear finishing and complementing the work of the anterior ones. I determined to put this instrument into use in a case which was waiting for operation.

I had already done a successful simple extraction upon the right eye of a man of sixty years, with a resulting vision of 20/40 +, and a round pupil. He was a machine engineer and found that he could not employ his eyes in looking at his steam gauge, on account of the difference in vision of the two eyes; hence he requested that I should operate on the other eye at once. The vision of his left eye was "fingers" at five or six feet, and there was a very small central sclerosed opacity, with a few spiculæ of partially opaque lens-substance in the periphery which could be detected best by oblique illumination and transillumination. By the indirect method, the fundus of the eye could be clearly seen; the optic disc incidentally had a large physiological cupping. With the exception, therefore, of the central sclerosed opacity, which was very small, the lens was practically clear. Although the vision was greatly reduced, I did not feel that I had a right to attempt to extract the lens in the presence of so much clear lens-substance, and I proposed to him the operation of artificial maturation. He accepted, and the procedure was employed in the presence of Dr. E. B. Coburn and the house surgeon of the New Amsterdam Eye and Ear Hospital, Dr. Gaudineer. A broad iridectomy was done, the lance-shaped keratome being introduced about one millimetre behind the sclero-corneal margin and shoved in up to the hilt. As soon as the coloboma had parted the harrow was introduced. The point of the harrow was laid at a right angle to the curve of the sclera and the corneal lip of the wound slightly lifted, in order that the needle-point might not catch in the scleral lip. Hugging the posterior surface of the cornea, the blade was pushed into the anterior chamber until it was exhausted, and the corneal lip impinged upon the shank of the handle. It was found then that the blade was too short to scratch the lens over its central part. Nevertheless, it was determined to achieve as much as possible under the circum-

stances. The points were now pressed down upon the anterior capsule and drawn upward toward the wound, until the shoulders of the blade commenced to emerge, when the procedure was repeated. The instrument was withdrawn by tilting the handle upward and raising slightly the corneal lip, in order to avoid striking the scleral lip with the needle-points. One of them, possibly the forward one, caught slightly in the latter.

At the time of the operation the pupil was perfectly black to the observation of the naked eye. This was observed by my two colleagues also. I discussed the question of using atropin at once, but concluded, for fear of a glaucomatous reaction, not to do so. The eye was bandaged and the patient put to bed. For the first twenty-four hours there was a general throbbing of the head and of the eye operated on, but it was relieved by a hypodermatic injection of morphine. From that time to the dismissal of the patient from the hospital, about the ninth day, there was no pain. A severe catarrhal conjunctivitis developed in *both* eyes six hours after the operation, and both eyes were closely stuck together with matter. The lids having been thoroughly washed out with a salt solution, a bandage was renewed until the following day. The eye was opened again twenty-four hours after the operation. The wound was found closed, there was a mild iritis with slight posterior synechia on both pillars of the coloboma, and the conjunctival condition was about the same as before. The bandage was now removed, atropin being instilled every two hours, along with repeated flushings of the conjunctival cul-de-sac with normal salt solution. The lens was found to be opaque, almost completely; just below at the bottom of the pupil, however, it appeared to be slightly translucent; by candle-light the patient could count the fingers only at one foot. The anterior chamber was deep, and there was no reason to suspect the existence of glaucoma.

On the ninth day, as stated, the patient left the hospital, the eye almost perfectly white, the pupil dilated, with slight posterior synechia. The anterior chamber was still deep, and I would have operated for extraction then and there if there had not still been a mild conjunctivitis, with slight sticking of the lids in the morning. The patient went to his home and continued his treatment of atropin and mild applications of salt water. On the fourth night after his dismissal from the hospital he was wakened by a pain in his eye. In

the morning it became worse, and I saw him about 11 o'clock. There was a slight pinkness of the eyeball, and the pupil was considerably contracted. Nevertheless, the cornea was clear; likewise, the iris. I diagnosticated mild iritis, and instilled atropine several times within an hour. The pain was at once relieved, but the pinkness remained. The patient was then sent to the hospital, atropin was used every two hours and leeches were applied to the temple. The iris apparently disappeared completely, although the eye remained slightly pink. The coloboma was wide, and the patient was again dismissed from the hospital. Two days afterward he again had a slight conjunctival discharge, which was relieved under treatment in forty-eight hours. Three days afterward I extracted the cataract, the conjunctival cul-de-sac appearing to be practically normal. The extraction was done sixteen days after the maturation the vision at that time being reduced to "movements of the hand." Just before the iritis developed the lens swelled somewhat irregularly, so that the anterior chamber to the outer side was rendered very shallow, and the iris was attached almost at the apex of the swelling. The anterior chamber on the nasal side, however, was deep. Using a small Graefe knife, I made a small corneal section just past the iris, and thrusting my knife through a swollen area on the lens completed my section in a normal manner, making it entirely a corneal one. As soon as the section was finished the lens delivered itself on account of a slight pressure made by the patient with his eyelids. The nucleus of the lens was large and mushy, and some of the substance was gelatinuous and almost liquid. The anterior chamber was washed out thoroughly with a sterile salt solution, the coloboma was smoothed down with a spatula, atropine was instilled, and both eyes were bandaged.

The patient was comfortable until night time, when he complained of a throbbing in his eye. A hypodermatic injection of morphin was given by the house surgeon, and he was relieved until the following morning. Although he had no definite pain at that time, he complained of a slight moisture of his eyelids, and I concluded to remove the bandage and inspect the wound, in view of his preceding infection. I was surprised to find that there was an even more severe infection of the conjunctiva than after the first operation. Fortunately again, the wound had completely closed; the anterior chamber was deep, the eye was quite red, and there

was a mild iritis. From this time on the bandage was kept off on account of the discomfort which the pressure seemed to give the patient and in order to cleanse and drain the conjunctival cul-de-sac. The iritis continued in a mild way for two weeks while he was in the hospital, but the patient suffered practically no pain. Atropin was used three or four times a day, and the sterile salt solution continued.

The pupil presented an interesting state of affairs. Cortical substance of rather dense nature remained in the lower and inner portion of the pupil, while the upper part was perfectly black. The patient could see very clearly and in a few days was able to tell the time on a watch. There has never been any reason to suspect the existence of glaucomatous tension, although atropin was used lavishly from the very beginning.

The result in this case is not necessary to prove that artificial maturation of senile cataract can be successfully performed; as Mooren has demonstrated, it has been done through a long period of years and in several hundred instances.

Mooren states that the cases in which this procedure is to be employed should be selected, and that those should be avoided in which there is arterio-sclerosis, for it is well known that such cases are more apt to be attacked by glaucoma than others. Outside of this class of cases, it appears to me that there is none that may not be handled in this manner. I believe that the fear of postoperative glaucoma is exaggerated, for it will be seen that when an iridectomy has been done the remedy for glaucoma is already on the field before the condition arises, and it is not unreasonable to say that it will occur only in rare cases. It will be seen, then, that the procedure which I suggest differs in several respects from Mooren's. It is simpler, and in all likelihood will occupy much less time from incipency to completion. Mooren's operation is divided into four parts, whereas my procedure has but two parts, to wit: (1) iri-

dectomy coupled with simultaneous discission with a lance-shaped harrow, and (2) extraction at the propitious time.

I would suggest, however, the use of atropine several hours before the first procedure, in order that the iris may be dilated at the time of operation and a larger coloboma be made. In addition to this, the iris will then be already retracted to the periphery, and the central part of the capsule which is lacerated by the harrow will be separated from the edges of the coloboma at once.

I have had a second instrument made which seems to me to completely fill the requirements. The blade is 9 mm. long and 3 mm. wide. The nose of the instrument is slightly blunt, and on the under surface there are six cambric needle-points, one at the apex, two on each side in a series, and one in the centre between the two lateral series. These points are so sharp that they can readily lacerate the capsule by the gentlest pressure, and are not sufficiently long to enter deeply into the lens-substance and cause it to protrude through the lacerated area. The blade should be pushed in until the nose just touches the border of the sphincter below. Since the anterior needle point is 1 mm. from the apex, the danger of wounding the iris does not exist when the instrument is in skillful hands. I think it is wise to repeat the act of laceration twice, and more or less in the same planes, drawing the instrument up toward the wound until the shoulders of the blade commence to emerge. The purpose should be to lacerate the capsule in a gentle way from the lowest possible point to the periphery.

As stated, the operation of maturation has apparently



FIG. 5.

fallen into almost universal disuse, but there is really no reason for this, since there are numerous cases in which economic conditions demand the relief from slow growing, lenticular opacity. It is the common custom among a number of surgeons to operate when the vision has fallen but slightly from the normal, but it is reasonable to assume that large quantities of cortical substance are left behind after such operations, the process of recovery is slow, and the optical results are not so satisfactory as when the cataracts are ripe at operation. The recovery of this patient shown here tonight has been materially retarded by the unhappy surgical infection of his conjunctiva, at the time of operation. It is difficult for me to explain the first infection, particularly of both conjunctivæ, since the asepsis was of the most rigorous and painstaking character. I feel confident that the cataract could have been extracted under more favorable conditions within a week or ten days after the primary operation. The whole procedure, therefore, might have been accomplished within a week or ten days, and the patient fitted with glasses between three weeks and a month. The difference between the procedures of Mooren and myself justifies, I think, the statement that my method is a new procedure. The instrument which I present is entirely new.

The ease and the rapidity with which the senile cataract in the case detailed was ripened was so marked that the idea has occurred to me to suggest the employment of the same procedure in the surgical treatment of high myopia.

The methods of Mooren and Fukala consist in converting the normal lens or the highly myopic eye into a cataractous one by discission through a dilated pupil. The procedure which I herewith suggest consists in the performance of an iridectomy and the simultaneous discission of the capsule by

my instrument, after the pupil has been previously dilated with atropin—in short, the procedure which I have just described for the artificial maturation of immature senile cataract.

Mooren, in his brochure entitled *Die medicinische und operative Behandlung kurzsichtiger Störungen*, Wiesbaden, 1897, has described his method of discission on page 69. After the pupil has been dilated with atropin, three or four drops of a sterilized solution of cocain are instilled into the eye.

The first step, the opening of the capsule, is done with a Graefe knife in such a way that the capsule is split throughout its entire extent (*Ausdehnung*), with the knife held as nearly vertical as possible. The superficial incision into the lens he gave up after two and a half years, for he twice found that the lens moved under the pressure of the knife and the procedure had to be repeated. In order to avoid this he subsequently held the knife as vertical as possible and at the same time thrust it further into the lens so that it was incised to three-quarters of its thickness. Care should be taken that the aqueous flows off when the knife is withdrawn. Subsequent trituration is done with the finger or wad of wet borated cotton over the lid.

From this it will be seen that Mooren did not employ iridectomy in his procedure. If he ever employed it he did so when he operated upon Dr. Küster for artificial maturation of his cataracts, at which time he incidentally relieved the high-graded myopia. I repeat, it is not clear from the context whether he employed iridectomy or not on that occasion. If so, it was done as an element in the cataract extraction and not in the surgical treatment of the myopia.

As far as I am aware, therefore, the suggestion that iri-

dectomy be coupled with discission in the surgical treatment of myopia has not been heretofore made.

The advantages of this method are obvious and may be summed up in this way:

- (1) Greater ease in lacerating the capsule.
- (2) Greater area of laceration.
- (3) The less likelihood of iritic complications and the less extensive if they do occur.
- (4) The presence of a coloboma to forestall the occurrence of glaucoma or its relief in case it does occur.
- (5) The less likelihood of postoperative glaucoma.
- (6) Simplification of the final extraction.

DISCUSSION.

In the discussion which followed DR. W. B. MARPLE stated that he had ceased to employ artificial ripening, and that he found no special difficulty in extracting sclerosed lenses even when considerable cortex was still clear, and he preferred to operate on immature cataracts rather than to ripen artificially.

DR. W. C. LAMBERT stated that in regard to the maturation of senile cataracts, it was unnecessary. A preliminary iridectomy followed by extraction was sufficient. In high myopia the employment of Claiborne's instrument would be dangerous without an iridectomy, and he preferred Fukula's original method of discission.

DR. J. E. WEEKS thought that the cases could be dealt with just as well without maturation. Iritis frequently followed this treatment, and in the case presented by Dr. Claiborne, a mass of soft matter remained. If one did decide to ripen, he suggested that it would be better to remove a piece of capsule with the capsule forceps.

DR. T. R. POOLEY stated that ripening operations had rather justly gone into disrepute. The maturation was very slow at best, and he would prefer to take his chances without ripening. One could ripen the anterior portions of the cataract, but the process does not extend very deep, and disappointment was apt to be experienced from the amount of capsule left behind.

DR. MITTENDORF described a case in which a ripening operation had been followed by iridocyclitis with the loss of the eye. The lens was probably dislocated by trituration.

DR. F. N. LEWIS was not very favorably inclined toward ripening. The irritation caused was more than was desirable. There was not so much risk to be run in operating on immature cataracts after all.

CHAPTER XII.

THE EXTRACTION OF THE ARTIFICIALLY CATARACTOUS LENS IN HIGH MYOPIA.

WALTER EYRE LAMBERT, M. D.

As a part of the symposium on cataract, our chairman thought and very properly so, that the operative treatment of high myopia by the extraction of the lens might be considered, and has done me the honor to ask me to present this subject.

I shall endeavor briefly to consider the history of this operation and report the few cases which I have had the opportunity to deal with, and from my experience draw some conclusions as to the advisability of the operation and the best method to pursue.

As far back as 1708, Boerhaave observed the effect of the removal of cataract in high degrees of myopia. In 1776, Desmonceaux advised the extraction of the lens in high myopia in children and stated that he had several times seen the operation practiced with success. In 1817 it is reported that Beer suggested this operation. In 1858 Adolph Weber reported at the Heidelberg Ophthalmological Society that he had on several occasions removed the lens in high myopia, and Mooren reported several cases at the same meeting.

The advisability of the operation appears to have been strongly questioned by both Von Graefe and Donders and little was done along this line until 1887 when Fukala took up the operation and in 1890 published his first paper, reporting several cases. About the same time Vacher advocated

the operation before the French Ophthalmological Society and reported cases.

Since then the operation has been generally accepted and a great many cases reported by Pfluger, Schweigger, Thier, von Hippel, Vossius, Sattler, Wicherkiowitz, la Grange, Schroeder, Laquer, Widmark, Hoerstmann, Pergens, Eperon, Gergus, Lawson, Fröhlich, Adams-Frost, Hess, Mooren and others in Europe; and Bull, Callan, Barnes, Wulff, Wilmer, Kollack, Fridenberg, Bruns, myself and others in America.

Fukala, in a paper before the Moscow Congress collected over 2000 cases. From this large number of cases, it will be seen how generally the method has been practiced in Europe. In America, however, there are comparatively few cases reported. This might be explained in the first place by the fact that high degrees of myopia in which this operation is indicated are not met with so frequently in America as in European clinics, and that clinical patients here are not so ready so submit themselves to operative treatment as they are abroad. I am inclined also to think that American surgeons are much more conservative, or less radical, than their European confrères.

The indications for the operation are a high degree of myopia in which the visual acuity is unsatisfactory with correcting lens, and in which a progressive tendency is observed. The patients usually selected for operation are the young, although several successful cases have been reported in which the patient was of advanced age. Pfluger reports a successful case at the age of forty-eight; Sattler, one at sixty-four; Widmark, one at seventy, and Mooren several in old people.

Statistics prove that the results of operation vary greatly. The reports of Fukala, Mooren and Adams-Frost show

wonderfully successful results. Other experts, however, show that the operation is by no means devoid of risk, four absolute losses out of seventy-eight cases being reported from the Leipsic clinic; seven cases of detachment of the retina in fifty operations by Haedicke; five per cent. loss in 142 cases by Darier—three due to infection and four to detachment of the retina. Gelpe in fifty-nine operations saw glaucoma in thirty-eight per cent., they yielded, however, to myotics. Schnabel has never seen a case with the near vision as good after operation as before, either with or without glasses.

This is sufficient to show the widely diversified experience of different operators.

There is a great difference of opinion also as to the contra-indications. The generally considered contraindications are a known hemorrhagic tendency, choroidal degeneration in macula region, loss of one eye, advanced age, ability to see well with correcting glass, detachment of the retina and vitreous opacities.

The first contra-indication—known hemorrhagic tendency—is important and worthy of consideration. The eminently satisfactory result which was obtained in the two cases I am presenting tonight, in both of which choroidal degeneration existed, causes me to regard the second objection less seriously than the rest.

The preceding loss of one eye would also make one hesitate to perform any operation in which there was so much risk, unless the vision was so poor as to make the patient practically helpless. I see no reason why advanced age should contra-indicate this operation, other conditions being favorable. Detachment of the retina and vitreous opacities would naturally be very decided contra-indications.

The dangers of the operation are infection, secondary

glaucoma, intra-ocular hemorrhage and detachment of the retina. The first three are immediate complications; the fourth more or less remote. As to infection, this is a danger which we must face in all operative proceedings wherein the globe is entered, but with careful aseptic precautions, it should not be seriously considered. I am not aware of any case in which intraocular hemorrhage has occurred. Secondary glaucoma is very liable to occur, but if the patient is kept under careful observation and the condition is promptly dealt with by the evacuation of the swollen lens, it is not to be dreaded. Detachment of the retina is a danger greatly to be feared, but as it is liable to occur in all cases of myopia of high degree, it is, I think, impossible to determine whether it is produced by the operation or not, some authorities maintaining that this complication is not any more likely to take place in eyes in which the operation has been done, than in those not operated upon.

The different methods of operation are: direct linear extraction in the young; direct extraction, as in ordinary cataract extraction; repeated discissions, and discission with linear extraction commonly known as the operation of Fukala.

The first method is not advisable and, I think, seldom practiced, as there is great danger of loss of vitreous and the reaction is usually very severe. The second method is advisable in old people, especially when the lens is more or less hardened and already somewhat opaque.

Repeated discissions and discission with linear extraction are the two methods usually adopted. Repeated discissions, allowing the lens to absorb, is favored by a great many authorities, especially in America. The disadvantages of this operation to my mind are the prolonged period of treatment, the repeated danger of infection and the frequent

complication of secondary glaucoma which has to be relieved by linear extraction. Free discission with evacuation of the lens-matter as soon as possible is the method which is now most generally practiced, and in the light of my experience, I unhesitatingly indorse it.

The cases which I am showing tonight were treated in this way and the result has been, as you see, most successful. The first case has already been shown at this section and both of them were reported at the annual meeting of the Ophthalmological Society in Washington.

In the discussion of these cases at Washington, Dr. Risley brought out a point which I think is of some importance. This is that we should bear in mind the actual condition of the eye at the time of the operation. The eye with serious or extensive choroidal changes may be in a quiescent state, i. e., the uveal track for the time being comparatively healthy, whereas a diseased condition has previously existed. These highly myopic eyes are extremely prone to have exacerbations of choroiditis around the old scars left by former attacks of inflammation or by hemorrhages. If the eye happens to be in one of the quiescent stages of its history, the probabilities of favorable results from the operation are good; whereas, during the acute exacerbation any surgical interference would be perilous.

The first case, Miss L. F., aged 16, studying stenography and typewriting. For ten years she had been wearing O. D.—15; O. S.—13. She had, however, been suffering a great deal of discomfort with her glasses and found her vision extremely unsatisfactory—so unsatisfactory as to lead her to conclude that she would be unable to continue her studies.

She applied to the New York Eye and Ear Infirmary for

treatment May 2, 1907. The vision of her right eye was 5/200 and left eye 15/200. Under a mydriatic, skiascopy showed a myopia of 21 D, with a small amount of astigmatism in the right eye, and 18 D. in the left eye; vision with this correction was 20/70 in both eyes. The fundus in each eye, excepting large staphyloma, was in a very fair condition, although there were some choroidal changes.

She consented to have the operation performed and it was decided to do the needling with linear extraction—the Fukala method.

On May 3, the lens of the right eye was needled under cocain, a crucial incision being made in the capsule with Knapp's knife-needle, the lens-substance being but very slightly disturbed.

On May 4, there was a slight reaction, lens somewhat opaque, no great pain, anterior chamber but partially restored. Hot bathing and atropin.

On May 5 she complained of considerable pain in the eye. There was great circumcorneal injection, plus tension, anterior chamber shallow, lens swollen. The afternoon of the same day a linear extraction was made, soft lens-matter removed, the anterior chamber irrigated freely with normal salt solution, atropin instilled and the eye bandaged.

The anterior chamber was restored, eye was comparatively quiet, tension normal and no pain. The patient made an uninterrupted recovery without any untoward symptoms, the remaining soft lens-matter being gradually absorbed; the capsule alone remained.

On May 15 (twelve days after the first needling) a discission of the capsule was made and a clear black pupil obtained. The vision with + 1.50 cyl. 90 degrees was 20/30 +.

The left eye of the same patient was operated on June 12.

The experience with that eye was practically the same as with the right, with the exception that there was little or no pain following the first needling, and but slight increase in tension.

The lens-matter was removed by a linear extraction as in the first eye forty-eight hours after the first needling, and on the seventeenth day after the first needling, a discision of the capsule was made, resulting in a clear pupil with a vision of 20/30 +, with + 1.50 + 1.50 cyl., axis 90 degrees. The patient soon overcame the diplopia which followed the operation, became accustomed to her glasses and has been able to use her eyes for near work by wearing a + 3 S. in addition to the correction above mentioned. The vision has improved somewhat and was tested by me on November 13, showing practically 20/20 with both eyes and Jaeger No. 1 at fifteen inches.

The second patient, a young woman thirty-one years old, had been near-sighted from birth. Fifteen years ago, she was seen by one of the most eminent ophthalmologists of New York, who described her case as hopeless and told her nothing could be done.

I saw her in October, 1904. She was then wearing —10 D. in each eye. The vision with this correction was O. D. 6/200; O. S. 12/200. With a — 20 O. D., she then had 20/200 vision; O. S. with —16, 20/100 vision. There was a large posterior staphyloma in both eyes, as well as most extensive changes. There was also a small central opacity in the capsule of each lens. She was kept under observation until the spring of 1906, when an operation was advised, which, however, was deferred until the fall of 1906. A consultation was then held with Dr. Bull, of New York, who agreed that an operation was justifiable, at any rate in the poorer eye to start with.

It seemed to me that the fundus conditions had progressed, and also that the opacities on the lens had increased, although the vision was about the same.

Under homatropin the vision of the right eye on October 21, 1906, was 20/200 with —22 D.; left eye, 20/100 + with —20 D.

The patient was taken to the New York Eye and Ear Infirmary on December 4, and on December 5 a discission of the lens of the right eye was made, a crucial incision being made in the anterior capsule. There was practically no reaction and little or no effect produced. On December 7, a second discission was made a little more boldly. The result of this was equally unsatisfactory. On December 9, two days later, a third discission was made, the capsule being thoroughly opened and the lens stirred up. The result of this was most satisfactory.

On the following day, the lens was quite swollen and opaque, the tension remained normal and very slight reaction.

December 11, a linear extraction was made, soft lens-matter being removed by free irrigation with normal salt solution. Atropin and hot bathing was used, the eye rapidly quieting down. The patient remained in the hospital until December 20. The eye was then perfectly quiet. All lens soft matter had disappeared.

She then went to her home in Pennsylvania to return later for the needling of the capsule. She was instructed to use daily a weak solution of atropin and hot bathing during the interim. She came back January 10, 1907, when a free discission of the capsule was made with a Knapp's knife-needle, a satisfactory opening being obtained. She was kept in the hospital, and atropin and hot bathing continued for several days.

The vision even at that early date was 20/50 with a —2 cyl. axis 90.

The success with this eye, the poorer one, encouraged us to proceed without delay with the other eye.

On January 29, the first needling was made. The reaction was very slight and little or no effect was produced. A second needling was made two days later. The result of this also was unsatisfactory. A third needling was made February 2. This produced some slight reaction but little or no opacity in the lens, except in the immediate line of incision.

On February 7, five days after the third needling, a fourth was made, the lens-matter being thoroughly stirred up. The following day the lens was quite swollen and opaque. The eye, however, was quiet and there was little or no pain.

February 10, three days later, a linear extraction was made and the soft lens-matter washed out by free irrigation with a normal salt solution. She complained of considerable pain during the night which was relieved with trional.

The following day the anterior chamber was restored, the pupil was well dilated, there were no adhesions, some soft lens-matter remained; treatment was hot bathing and atropin.

The improvement in the general condition of the eye was uninterrupted, and on the twenty-second of February, the patient left the hospital to return later for the discission of the capsule. The capsule in this eye was much more dense than that in the other eye, and the vision was consequently very poor at that time. She returned and on the twenty-first of March an opening was made in the capsule with a knife-needle. The result was not satisfactory and a

second discission was made on March 26, a good opening resulting.

The patient was kept under observation for some time, atropin and hot bathing being used moderately. In about three weeks all of the capsule had been absorbed, leaving a clear black, almost circular pupil.

The resulting vision was O. D. 20/30 + with -2 cyl., axis 90; O. S. 20/30 + with $-1\frac{1}{2}$ S. + $2\frac{1}{2}$ cyl., axis 165. With + 3 S. added to the above, she reads Jaeger No.1.

Should one be guided by the result of the cases here presented and the great number of very successful ones reported by such men as Mooren, Fukala and Adams-Frost, one would naturally be most enthusiastic about this method of treatment and be inclined to adopt it in all cases of myopia of high degree.

I do not desire to encourage such an idea. We must appreciate its risks and recall the failures recorded by men of wide experience and undoubted skill, and give every consideration to a case before advising and resorting to such radical treatment.

When a patient presents himself with a high degree of myopia, we should first make a careful correction with glasses and for some time watch him. Should useful vision not be obtainable or maintained by the correcting glass, or should they not be tolerated, the operation seems to me to be entirely justifiable unless some very decided contra-indication is present.

As I have said before, the method I would decidedly advocate is free discission, well into the lens substance, avoiding cutting the posterior capsule and extracting the lens-matter as soon as possible thereafter.

This method is certainly much more expeditious than

repeated discissions, and I am of the opinion that it is a much safer proceeding.

It is most important that the patient should be kept under constant and careful observation during the entire period of treatment, so that any untoward complications may be promptly dealt with.

DISCUSSION.

In the discussion which followed, DR. M. L. FOSTER stated that he had operated by discission alone, but thought the method of Dr. Lambert was much better. He also thought we could not always tell whether the processes in the fundus would be checked or not. In some cases the fundus changes progressed in the same way as if no operation had been performed. Still, he thought operation was indicated to give the patient the benefit of better vision for as long a period as possible. The chances of detachment of the retina in high myopia were very great anyway.

DR. LAMBERT thought that he could not yet say whether or not the fundus changes were retarded by the operation. In persons of advanced years he would do a preliminary iridectomy.

[The probability is that the removal of the artificially cataractous lens in high-graded myopia will never be generally employed in this country, and there are several sound reasons for it.

First the proportion of myopia here is less than in Europe in general, and in Germany in particular; consequently the high-graded myopia is still less frequent.

Secondly, it is never likely to be so great, unless the percentage is raised by immigration, for our lower classes

among whom myopia is more frequent, have better hygienic surroundings, better light, by day and by night in their dwellings, and the text which is used in our school books is the Latin.

Moreover, patients do not submit themselves so readily to the advice of surgical counsellors here as abroad; their individuality is more pronounced and they have an abounding faith that all wisdom is not centred in any one man.

Inspection of the reports of any eye hospital or clinic in this country will disclose the fact that the excess of hyperopic over myopic refractive error is about 3 to 1.

The procedure necessitates at least two operations—dissection and subsequent extraction—with the risks attendant upon both. Even when success is attained, the patient is annoyed by the loss of accommodation and the necessity of wearing both reading and distance glasses.

It is questionable whether the last state of such patients is not worse than the first.

The excellent result obtained by Lambert in his two cases is exceptional. J. H. C.]

CHAPTER XIII.

FINAL RESULTS OF CATARACT EXTRACTION.

H. W. WOOTON, M. D.

THE results obtained in the extraction of senile cataract are materially influenced by many circumstances, which may be considered under five headings:

I. The condition of the eye previous to the operation.

II. Accidents connected with the operation itself.

III. Reactive processes occurring during the healing of the wound.

IV. The optical changes produced by the operation.

V. Conditions which may supervene more remotely.

I. In the consideration of the previous state of the eye, it is not the intention of the writer to enumerate all the abnormalities that may exist in eyes from which the extraction of cataract may be necessitated, but merely to mention three conditions which may greatly influence the result in eyes, the external appearance of which may be normal. These are senile degenerative changes in the choroid, fluidity of the vitreous with weakened zonula, and disease of the retinal and choroidal vessels. The senile changes in the choroid, so common in the ages and which are so frequently situated in the macular region, are capable of recognition more or less by the well-known tests of perception and projection, but it must be observed that minutely circumscribed macular defects are not exactly determinable by these methods and that, after a successful extraction, their existence may cause disappointment in the degree of

visual acuity obtained. Fluidity of the vitreous accompanied by a weakened zonula conduces to premature expulsion of the lens and to loss of vitreous with its unfortunate consequences. Disease of the choroidal vessels may lead to choroidal hemorrhage and, necessarily, to the loss of the eye. Happily, hemorrhage from the choroid rarely occurs, even in cases in which disease of the superficial vessels is very marked.

II. The accidents or untoward circumstances which may occur during the operation and which may essentially influence the result are:

1. An irregular and misplaced section. The section which does not lie evenly in the limbus causes delayed healing in the majority of cases. By the uneven coaptation of the edges of the wound, tardy restoration of the anterior chamber is favored and, with this, the ingrowth of corneal epithelium. When the apex of the section extends too far posteriorly, inclusion of the iris is apt to occur; the eye is likely to remain irritable for an unusually long period, thus delaying discission, and the increased astigmatism which sometimes results may influence unfavorably the degree of visual acuity finally obtained.

2. An insufficient section is stated by Knapp to be the worst mistake that the operator can make. If it is not enlarged with scissors before extraction is completed, bruising of the edges of the wound results, and the evacuation of the lens may be rendered incomplete. The occurrence of either of these circumstances is unfortunate. Bruising of the edges of the wound increases the inflammatory reaction and the retention of much soft lens-matter conduces to iridocyclitis and is apt to increase the density of the secondary cataract.

3. Prolapse of the vitreous is perhaps the most common

accident of importance that occurs during the operation. It is said to be more common with the "combined" than the "simple" method, and is most common when the lens is extracted within its capsule. With perfect technic it ought not to occur in either "simple" or "combined" extraction, if the eye is normal and the patient tractable, but, unfortunately, either or both of these conditions are frequently wanting. If the patient is intractable and insists upon forcibly closing the lids, the pressure thus exerted by the speculum upon the globe may cause prolapse of even normal vitreous and, with a weakened zonula and fluid vitreous, large quantities of the latter may be lost in spite of the most careful management. Loss of vitreous was more common before the advent of cocain than it is at present, on account of the greater restlessness of the patient. The older operators believed that if not more than one-third of the vitreous was lost, the result need not necessarily be unfavorable, and, indeed, the loss of a small amount may be of small moment, more particularly if it takes place after the extraction of the lens. Still, the inclusion of vitreous in the wound delays healing, the opening of the vitreous cavity invites infection, and the possibility of subsequent detachment of the retina must be taken into consideration. Hess regards prolapse of vitreous as a probable cause of opacities of this medium, but it must be remembered that the very cases in which prolapse is most apt to take place are those in which the vitreous is fluid and probably contains opacities before the operation is undertaken. Certainly, after all has been said on this subject, there are few of us who have not had occasion to be agreeably surprised at the result in cases in which considerable quantities of vitreous have been lost, cases in which the dreaded suppuration has not supervened, in which inflam-

matory reaction has been remarkably slight and in which the vision has continued excellent so long at least as the patient has remained under observation.

4. Incomplete removal of the lens with the retention of considerable quantities of soft lens-matter is apt to influence the result unfavorably by the production of iritis and the occlusion of the pupil to a greater or less degree. This accident is more frequent with the simple than with the combined method. In the opinion of the writer it is least deleterious in cases operated upon by the method of preliminary iridectomy. In these, the cut edges of the iris have healed before extraction is undertaken and they do not present so ready a surface to infection or to the mechanical irritation of swollen lens fragments as does the freshly cut iris of the combined method or as do the fresh ruptures of the iris sphincter which are so apt to occur when extraction is performed without iridectomy. Whether this explanation be correct or not, so far as the writer's observation goes, iritis and iridocyclitis are least frequent when preliminary iridectomy is performed and, as these conditions are the cause of most of our losses and bad results, it seems to him that a reasonable plea may be made for the reintroduction and more general employment of this method of extraction.

5. Choroidal hemorrhage may occur during the operation, although it is more frequent a few hours later, and it has been exceptionally observed on the second or third day after the operation. The cases in which it occurs are to be numbered among our losses. The frequency of its occurrence seems to have varied so greatly in the experience of different operators that Dimmer, writing in 1901, was almost tempted to believe that its frequency might vary with difference of locality. Thus, Golowin gives 1 in 300 to 500 extrac-

tions; Mooren only 1 in 1000; Schliess $1\frac{1}{10}$ per cent. before the use of cocain and $4\frac{47}{100}$ per cent. since its employment, in 630 cases. Knapp had but one case in 2300 extractions and Dimmer 4 in 385. Sattler concludes that hemorrhage has been more frequent since the employment of cocain than before. Previous to 1886, in 1250 extractions, he had no case of hemorrhage; after 1886, he lost six eyes from this cause in 1869 extractions. Hess, in 1000 extractions, had no case of hemorrhage. The wide differences in these figures, given by the ablest operators, not only illustrate the general mutability of medical statistics, but may well be considered by those who would argue the superiority of some particular method from statistical tables. In regard to the anatomical findings in cases of choroidal hemorrhage, it is also interesting to note that, while disease of the choroidal vessels has frequently been observed (S. Blum), in two cases examined by Fromaget and Bordier, the entire choroidal system, including the ruptured vessels, was found to be normal.

6. Detachment of the ciliary body and anterior portion of the choroid was first described by Knapp in 1886 and was observed by him in an eye which he had been compelled to enucleate. Only eleven cases were reported as late as 1900. This accident may immediately follow extraction or it may not occur until some time later. Recently Fuchs has investigated the subject and states that this detachment is not so rare as is commonly supposed. In eight months he saw it five times. It has occurred during otherwise undisturbed healing and, up to the present time, has been observed only with the "combined" method, if we except Cartwright's case (1902) in which the detachment took place two years after an extraction without iridectomy. Fortunately, the prognosis is usually good, the detachment

gradually recedes, and the eye recovers with good vision, although, as in Knapp's original case, blindness may result.

III. The more important occurrences and reactive processes which may influence the result, during healing are the following:

1. Tardy closure of the wound. This is usually a matter of comparatively small moment and does not seem to increase the liability to infection and suppuration, but the longer the wound remains open, the more likely is epithelial ingrowth to take place, and as this condition is exceedingly serious, long-continued non-closure cannot be regarded as altogether harmless.

2. Iritis and iridocyclitis may occur in several forms. Slight iritis with a few posterior synechiæ is exceedingly common. Iritis and iridocyclitis more severe and plastic in character may appear about the third or fourth day after extraction and, according to its severity and extent, may result in but slightly deleterious consequences, may lead to complete loss of the eye, or may even be followed by sympathetic ophthalmia. In a certain number of cases, a cyclitis slow in its development and persevering in its nature commences from about the fourth to the eighth day after extraction, or even later. In the milder cases only a few adhesions are present which yield readily to atropin, but in the more severe, the entire pupillary area is gradually covered with dense thick exudates and the visual acuity is greatly lowered. Through involvement of the deeper structures or by the development of glaucoma this form may lead to complete blindness and may be followed by sympathetic ophthalmia. On the other hand, the process may cease in its earlier stages and after the division of the resulting adhesions good vision may result. The etiology of this variety of cyclitis is still unknown. Hess thinks that

its clinical picture is that of an infectious process and Schirmer also regards it as infectious in nature. Knapp (1899) on the contrary believes it to be mechanical irritation of swollen lens fragments. In regard to the frequency of iritis after extraction, Ring's table shows it to be slightly more common after the "combined" than after the "simple" method. Dimmer's statistics, which will again be referred to, give losses from iridocyclitis as decidedly more common after the "simple" than after the "combined." The writer, as already intimated, believes that iritis and iridocyclitis will be found to be less frequent after extraction with preliminary iridectomy than after either of the other methods.

3. Sympathetic ophthalmia occasionally follows the extraction of senile cataract. The frequency of its occurrence varies greatly in the figures given by different writers. Steffan in 300 extractions had 28 losses and, in six of the cases in which the eye was lost (2 per cent. of those operated upon) sympathetic ophthalmia developed. Eversbusch states that in 1420 cases operated upon in the Munich Clinic there were 154 losses and that sympathetic ophthalmia followed in two cases. Buerlein had 44 losses in 860 cases, but no case of sympathetic ophthalmia. Knapp saw four cases in about 3000 extractions. The writer is compelled, unfortunately, to add one case of his own to those already reported. The patient, in Drs. Pomeroy and Hepburn's service at the Manhattan Eye and Ear Hospital, was operated upon in June, 1902. Extraction with iridectomy was performed. The cataract was immature and was incompletely evacuated. Iridocyclitis followed, and on the fourteenth day after the operation the pupillary reaction of the other eye became sluggish, with a typical picture of iridocyclitis, the sympathizing eye became

painlessly blind and underwent atrophy in about a year. There was no history of syphilis or rheumatism, and although the rather early occurrence of the cyclitis in the unoperated eye may throw some doubt upon the nature of the case, it is difficult to assign to it any other origin than a sympathetic one.

4. Glaucoma is not a very unusual development in eyes from which the lens has been removed. It may occur with a short or longer period after extraction or it may follow discission. In about one-half the cases, causes connected with the operation can be cited to account for its development, viz., iridocyclitis with posterior synechiæ, the complete separation of the posterior from the anterior chamber by an excessively developed secondary cataract, the blocking of the filtration angle by inclusion of iris or capsule, or by prolapse of vitreous. In other cases, in which these causes do not exist, the glaucoma must be regarded as primary; that is, as occurring only accidentally in an eye previously disposed to increased tension, the operation being, perhaps, the exciting cause. In regard to the frequency of its occurrence, Treacher Collins reported (1896) 1405 extractions in the Moorfields Clinic with .64 per cent. of loss from subsequent glaucoma. In regard to its frequency after discission Knapp (1895) states that in nine years he observed in 2 per cent. of all discission severe glaucoma requiring iridectomy and, in addition, one per cent. of milder cases which yielded to myotics. Fortunately, the prognosis in most cases following discission is good. Dalen considers glaucoma more frequent after "combined" than after "simple" extraction; other writers hold the contrary opinion.

Glaucoma caused by growth of the corneal epithelium into the anterior chamber, although of infrequent occurrence,

is extremely interesting and has of late received a good deal of attention. Originally noted by Guaita (1888), the condition has been very fully described by Cross, Miller (1901) and Elsching (1903) and, recently, Oatman (1906) has illustrated before this Section the method of its occurrence. The corneal epithelium invades the wound and occludes the filtration angle; it covers the posterior surface of the cornea, may cover the anterior surface of the iris, invades the pupillary area and appears on the posterior surface of the iris. Hess attributes the cause of this complication to any circumstances that may occasion delay in the healing of the wound or the restoration of the anterior chamber. He also quotes Cross as authority for the statement that the condition may follow dissection of secondary cataract.

5. Suppuration of the wound which may be followed by panophthalmitis, or panophthalmitis following suppuration of the iris and vitreous, is the most serious complication of the healing process. Fortunately, panophthalmitis is much less common at the present day than before the introduction of antiseptic methods. In the pre-antiseptic period, the average loss from suppuration was as high as from six per cent. to twelve per cent. by the corneal section and even equalled two per cent. by Graefe's method. At present, many series of hundreds of extractions are reported without a single loss from this cause.

In estimating the relative importance of the conditions enumerated in the determination of our losses, the first place is given by most modern operators to iridocyclitis. Thus Dimmer (1901) states that with the "combined" method, he experienced .98 per cent. and with the "simple" method 1.89 per cent. of losses from this cause. Losses from suppuration are at the present day unusual. Dimmer given 77 per cent. If to the losses from irido-

cyclitis and suppuration we add those which must always occasionally occur from glaucoma and hemorrhage, we may state that the total loss from cataract extraction varies from 1.01 per cent. given by Knapp as the result of 300 simple extractions, to 6 per cent. given by Wilson in 1895, as the result of 10,000 extractions performed by various operators between 1879 and 1893. Hess thinks that Wilson's percentage is really too high for the present day, for he believes that it was only considerably later than 1879 that certain operators adopted antiseptic methods.

IV. We have to consider the optical condition of the eye resulting from the operation. The degree of visual acuity obtained after cataract extraction is stated to vary from 20/200 to 20/20 or better in cases which may be regarded as successful. Vision usually improves materially for a short period following the operation, and then generally diminishes on account of wrinkling and increasing opacity of the capsule. About 70 per cent. of all cases require discission before the result can be considered as final. As first pointed out by Donders (1864), astigmatism is a necessary sequence of extraction. It is for the most part inverse and of sufficient regularity to admit of marked improvement of vision by the use of cylinders. Its degree and quality are materially influenced by the relation of the principal meridians before operation, also by the character of healing and the presence or absence of foreign substances in the wound. The size of the section seems also to exercise considerable influence; the larger the section and the more nearly it approaches to the central portions of the cornea, the greater the astigmatism will be. The astigmatism is greatest immediately after the operation and gradually diminishes, but does not, as a rule, entirely disappear. In most cases there remains not only a flattening

of the vertical curvature, but also an increase of the horizontal, and a permanent inverse astigmatism of about 3 D. represents, perhaps, the most usual. The result is usually considered final in about two months but exceptionally, it is not until four months that the permanent status is established. Although the astigmatism is generally inverse, this rule has its exceptions. Thus, Treutler in 1900 reviewing the records of forty-nine eyes in which the astigmatism had been determined both before and after extraction, found that in 88 per cent, the vertical curvature was lessened, unchanged in two per cent, and increased in twelve per cent. while the horizontal curvature was increased in 88 per cent., unchanged in 2 per cent. and lessened in 12 per cent. In one of the writer's cases, the astigmatism which equalled 3 D. with the rule before extraction was also 3 D. with the rule some months after. The degree of astigmatism remaining may influence very materially the result, for the higher degrees do not admit of complete correction and the importance of avoiding conditions that may lead to an excessive amount is very great. In this connection may be mentioned the obtaining of smooth healing by an even section and the avoidance of the inclusion of foreign structures between the edges of the wound. Still, with all our care, the resulting astigmatism will sometimes be excessive. Hess reports a case in which it equalled 6 D. although healing had been perfectly smooth.

V. Among the conditions that may remotely follow extraction and exercise a deleterious influence upon the result, glaucoma has already been mentioned. Knapp states that iridochoroiditis may occur after many years and impair vision. Detachment of the retina may occur in cases in which vitreous has been lost, and doubtless loss of

vitreous does predispose to subsequent detachment but it must be remembered that in a certain, perhaps the greater number of these cases, the vitreous was probably fluid before extraction was performed and that detachment might have taken place ultimately even had no operative procedure been attempted.

[The operation for cataract without a doubt requires more skill, more nerve, more judgment and greater readiness to cope with unexpected disaster and accident than any other surgical procedure possible on the human body. But even when the lens has been removed by simple extraction and a round nimble pupil is obtained, the result is at best a failure by virtue of the lack of accommodation and the necessity of wearing thick and unsightly lenses.

Since there are many very old people who never have opacities of the lens, it would be incorrect to say that cataract is a necessary concomitant of old age. And when we reflect that the majority of cataracts occur in those in the lower walks of life, whose lives have not been regulated on hygienic principles, particularly with reference to the care of the eyes, it is safe to predict that the treatment of cataract in the future will be prophylactic, and consequently it is not unreasonable to predict that it will cease to occur and that all men may at some time in the future go down to their graves preserving to the last the noblest of their faculties. This result will probably be gained not by the brilliant achievement of one man, but by that slow and painstaking process by which all lasting results in science are attained. J. H. C.]

FINIS.











