

A manual of diseases of the nose and throat / by Cornelius Godfrey Coakley.

Contributors

Coakley, Cornelius Godfrey, 1862-1934.
Francis A. Countway Library of Medicine

Publication/Creation

New York and Philadelphia : Lea & Febiger, 1908.

Persistent URL

<https://wellcomecollection.org/works/m6je6u68>

License and attribution

This material has been provided by This material has been provided by the Francis A. Countway Library of Medicine, through the Medical Heritage Library. The original may be consulted at the Francis A. Countway Library of Medicine, Harvard Medical School. where the originals may be consulted. This work has been identified as being free of known restrictions under copyright law, including all related and neighbouring rights and is being made available under the Creative Commons, Public Domain Mark.

You can copy, modify, distribute and perform the work, even for commercial purposes, without asking permission.



Wellcome Collection
183 Euston Road
London NW1 2BE UK
T +44 (0)20 7611 8722
E library@wellcomecollection.org
<https://wellcomecollection.org>



*J. Victor Greenbaum
Harvard Medical School.*

HARVARD MEDICAL
LIBRARY




RÖNTGEN


THE LLOYD E. HAWES
COLLECTION IN THE
HISTORY OF RADIOLOGY

☞ Harvard Medical Library
in the Francis A. Countway
Library of Medicine ~ Boston


VERITATEM PER MEDICINAM QUÆRAMUS












Digitized by the Internet Archive
in 2012 with funding from
Open Knowledge Commons and Harvard Medical School

PLATE V



Right.


Left.

Transillumination of the Antra. Right healthy;
left diseased.

A
MANUAL OF DISEASES
OF THE
NOSE AND THROAT.

BY
CORNELIUS GODFREY COAKLEY, A.M., M.D.,
PROFESSOR OF LARYNGOLOGY IN THE UNIVERSITY AND BELLEVUE HOSPITAL
MEDICAL COLLEGE, NEW YORK CITY; LARYNGOLOGIST TO COLUMBUS HOS-
PITAL, THE UNIVERSITY AND BELLEVUE HOSPITAL MEDICAL COLLEGE
CLINIC; CONSULTING LARYNGOLOGIST TO THE NEW YORK BOARD
OF HEALTH; MEMBER OF THE NEW YORK ACADEMY OF MED-
ICINE, SOCIETY OF THE ALUMNI OF BELLEVUE HOSPITAL,
MEDICAL SOCIETY OF THE COUNTY OF NEW YORK, MED-
ICAL SOCIETY OF THE STATE OF NEW YORK,
AMERICAN LARYNGOLOGICAL, RHINOLOGICAL,
AND OTOLOGICAL SOCIETY, ETC., ETC.

FOURTH EDITION, REVISED AND ENLARGED,
ILLUSTRATED WITH 126 ENGRAVINGS AND 7 COLORED PLATES.



LEA & FEBIGER,
NEW YORK AND PHILADELPHIA.

Entered according to Act of Congress, in the year 1908, by

LEA & FEBIGER.

In the Office of the Librarian of Congress. All rights reserved

PREFACE TO THE FOURTH EDITION.

THE author desires again to thank the many friends whose kindly interest in this work has brought the opportunity of another revision.

Each article has been carefully considered and changes made to conform to the advances in diagnosis and treatment. The former articles on Spurs and Deflections of the Septum have been considered under a single head, Deformities of the Septum, which will, we hope, simplify the subject considerably. The technique of the radical operations for Chronic Diseases of the Accessory Sinuses has been more fully described than in previous editions.

It may not be amiss to point out that the purpose of this work, in its successive editions, has been to provide a compact manual answering the needs of both students and practitioners. Special attention has, therefore, been devoted to the more practical sections—namely, those on Examinations, Diagnosis, and Treatment. It is of the first importance that the appearances found on examination of a patient should be thoroughly appreciated, and that microscopical and bacteriological investigations should be made where the nature of the morbid process is in doubt. Sufficient guidance in these directions will be found in the work.

A departure has been made from usual methods of dealing with the subject of treatment. The author has selected from among the multiplicity of medicinal and operative measures those which, in his judgment, are the best, and full details are given for the benefit of

those who have not had the advantage of personal clinical instruction.

For convenience, a special chapter, devoted to Therapeutics, has been added, wherein will be found a classification of drugs according to their local actions, and a number of useful prescriptions, together with indications for their employment. In order to make the work of greater value to those who have acquired some practical knowledge of diseases of the nose and throat, references to these additional remedies have been indicated by heavier type in the index under the *treatment* of each disease.

I have freely consulted all the larger treatises, monographs, and journals pertaining to the subject, and desire to express my indebtedness to the authors thereof for much valuable information. In order to keep the book in as compact a form as possible, individual references are omitted.

I desire also to express my appreciation to Messrs. Lea & Febiger for the care they have taken with the illustrations and printing, and to extend my thanks for many valuable suggestions received during the course of preparation of the book.

To the publishers great credit is due for the excellent reproduction of the new cuts.

C. G. C.

CONTENTS.

CHAPTER I.

	PAGE
ANATOMY OF THE UPPER RESPIRATORY TRACT	17-32

CHAPTER II.

PHYSIOLOGY OF THE UPPER RESPIRATORY TRACT . .	33-38
---	-------

CHAPTER III.

EXAMINATION OF THE UPPER RESPIRATORY TRACT . .	39-68
--	-------

CHAPTER IV.

ANTISEPSIS IN OPERATIONS UPON THE UPPER RESPI- RATORY TRACT	69-72
--	-------

CHAPTER V.

NASAL OBSTRUCTION	73-77
-----------------------------	-------

CHAPTER VI.

DISEASES OF THE NOSE	78-197
--------------------------------	--------

CHAPTER VII.

DISEASES OF THE ACCESSORY SINUSES OF THE NOSE . .	198-251
---	---------

CHAPTER VIII.

DISEASES OF THE NASOPHARYNX	252-279
---------------------------------------	---------

CHAPTER IX.

	PAGE
DISEASES OF THE OROPHARYNX, TONSILS, AND TONGUE .	280-410

CHAPTER X.

DISEASES OF THE LARYNX	411-535
----------------------------------	---------

CHAPTER XI.

AFFECTIONS OF THE UPPER RESPIRATORY TRACT OCCUR- RING IN THE INFECTIOUS DISEASES	536-550
---	---------

CHAPTER XII.

THERAPEUTICS. REMEDIES FOR THE LOCAL TREATMENT OF THE NOSE, PHARYNX, AND LARYNX	551-573
--	---------

DISEASES OF THE NOSE AND THROAT.

CHAPTER I.

ANATOMY OF THE UPPER RESPIRATORY TRACT.

ANATOMY OF THE NOSE.¹

The External Nose.

THE external nose varies considerably in shape from the long, narrow, aquiline to the short, broad, pug-nose. It is seldom perfectly symmetrical.

It consists of a bony and cartilaginous framework covered with muscles and skin.

The bones are the two nasal bones and the nasal processes of the two superior maxillary bones.

The cartilages—five in number—are the two upper lateral, the two lower lateral (also called alar cartilages), and the triangular cartilage of the septum. Between the upper and the lower lateral are usually found one or more sesamoid cartilages. The cartilaginous portion of the nose is slightly movable in all directions. Sometimes during difficult breathing there can be noticed a widening and narrowing of the orifices at the anterior end of the nose.

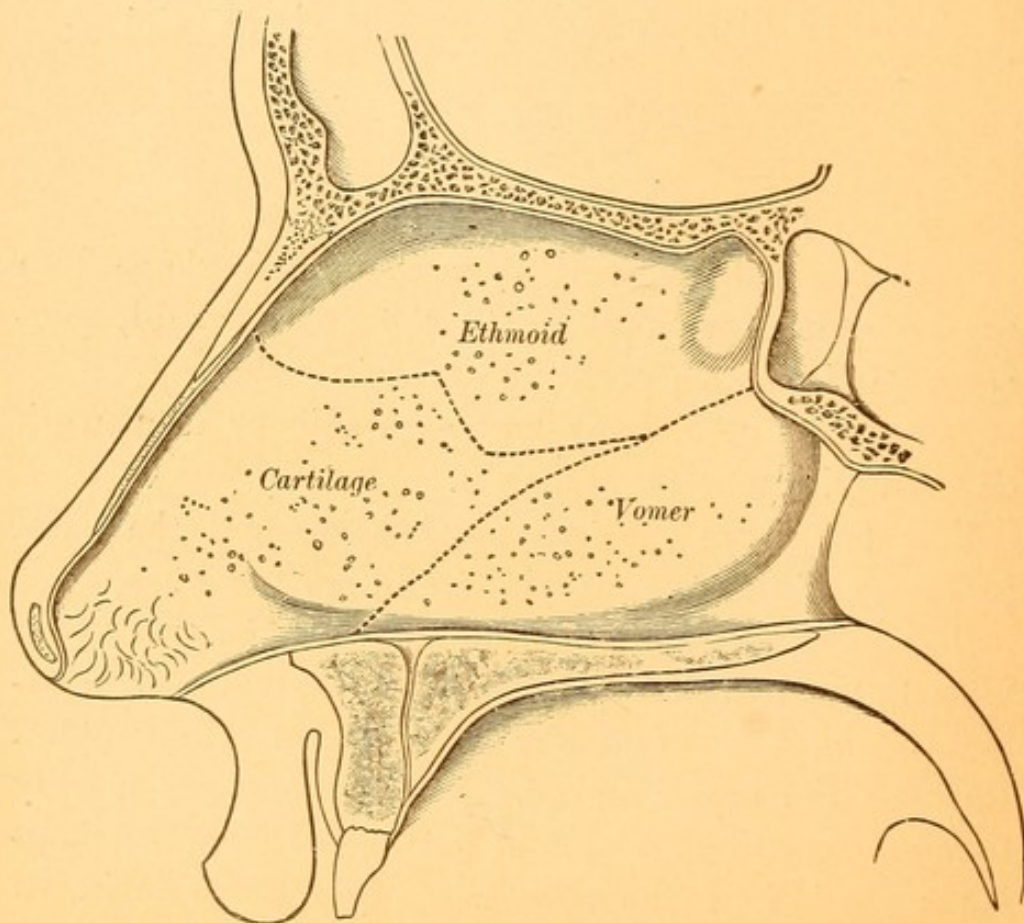
¹ The details of the anatomy of the upper respiratory tract will not be given. It is intended to refresh the reader's memory in regard to only the more important points.

The Interior of the Nose.

THE FRAMEWORK. The interior of the nose consists of two wedge-shaped cavities extending from the nostrils in front to the nasopharynx behind. The boundaries of these cavities are as follows:

The **FLOOR** consists of the palate process of the superior maxillary bones and the palate process of the palate bones posteriorly.

FIG. 1.



Antero-posterior section of the nose, showing the septum. (MERKEL.)
 The lines of junction of the several pieces are indicated by the dotted lines.
 The vestibule and the vibrissæ are also pictured.

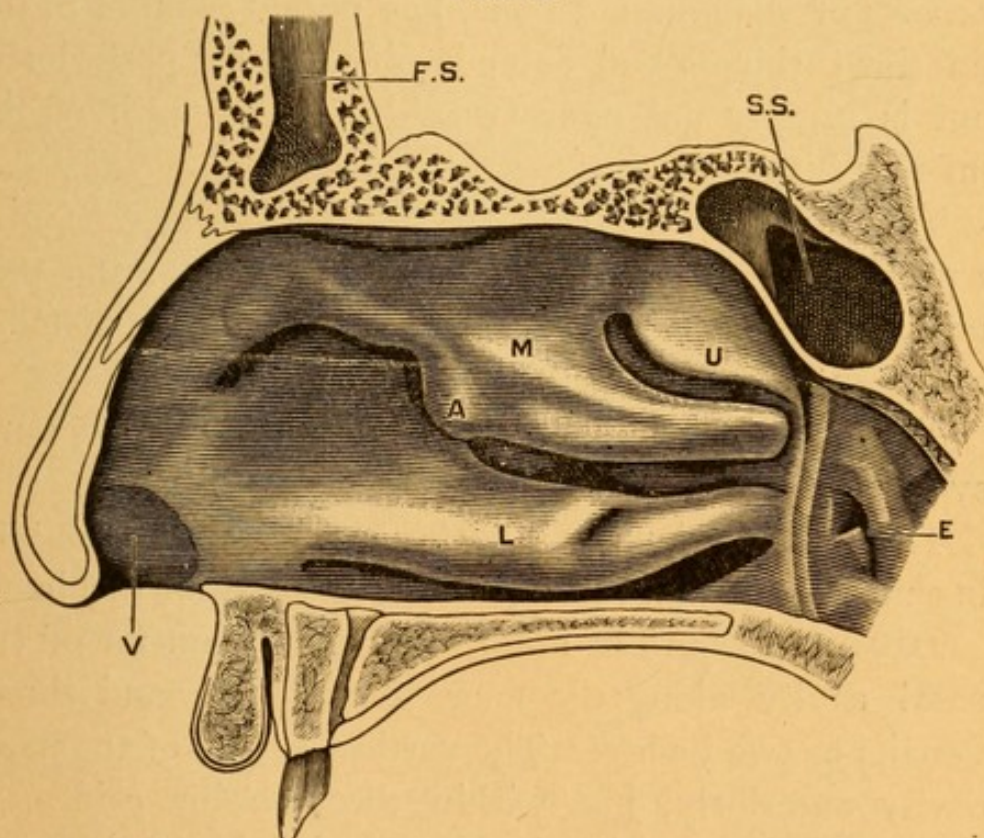
The **ROOF** is composed from before backward of the nasal bones, the cribriform plate of the ethmoid, and the body of the sphenoid,

The OUTER WALL is composed of the superior maxillary, lachrymal, palate, and sphenoid bones.

The INNER WALL, called the septum, and separating one cavity from the other, is composed of the perpendicular plate of the ethmoid, the vomer, and the triangular cartilage of the septum (Fig. 1).

The septum is seldom perfectly straight, but usually presents slight deviations from the median line, and is

FIG. 2.



Antero-posterior section of the nose, showing the outer wall of the right nasal cavity. (ZUCKERKANDL.)

L. Inferior turbinate. M. Middle turbinate. A. Anterior end of middle turbinate. U. Superior turbinate. F. S. Frontal sinus. S. S. Sphenoidal sinus. E. Eustachian orifice. V. Vestibule.

also the seat of small thickenings on one or the other side. These thickenings or ridges most commonly follow the lines of junction of the three pieces composing the septum.

The outer wall is traversed from before backward by three scroll-shaped bones, known as the inferior, middle, and superior turbinated bones. When covered with the mucous membrane and underlying tissues we shall speak of them as the turbinates.

The inferior turbinate (Fig. 2, L, and Fig. 3) extends about three-fourths of the entire length of the outer wall of the nose.

The middle turbinate (Fig. 2, M, and Fig. 3, *b*), a process of the ethmoid bone, lies nearly parallel to the inferior turbinate and extends about as far posteriorly, but is usually not over two-thirds the length of the inferior turbinate.

The superior turbinate (Fig. 2, U, and Fig. 3), also a process of the ethmoid bone, extends from the posterior margin of the nose and one-third of the distance to the anterior portion of the nose.

The size and shape of the superior turbinate, however, vary considerably in different skulls.

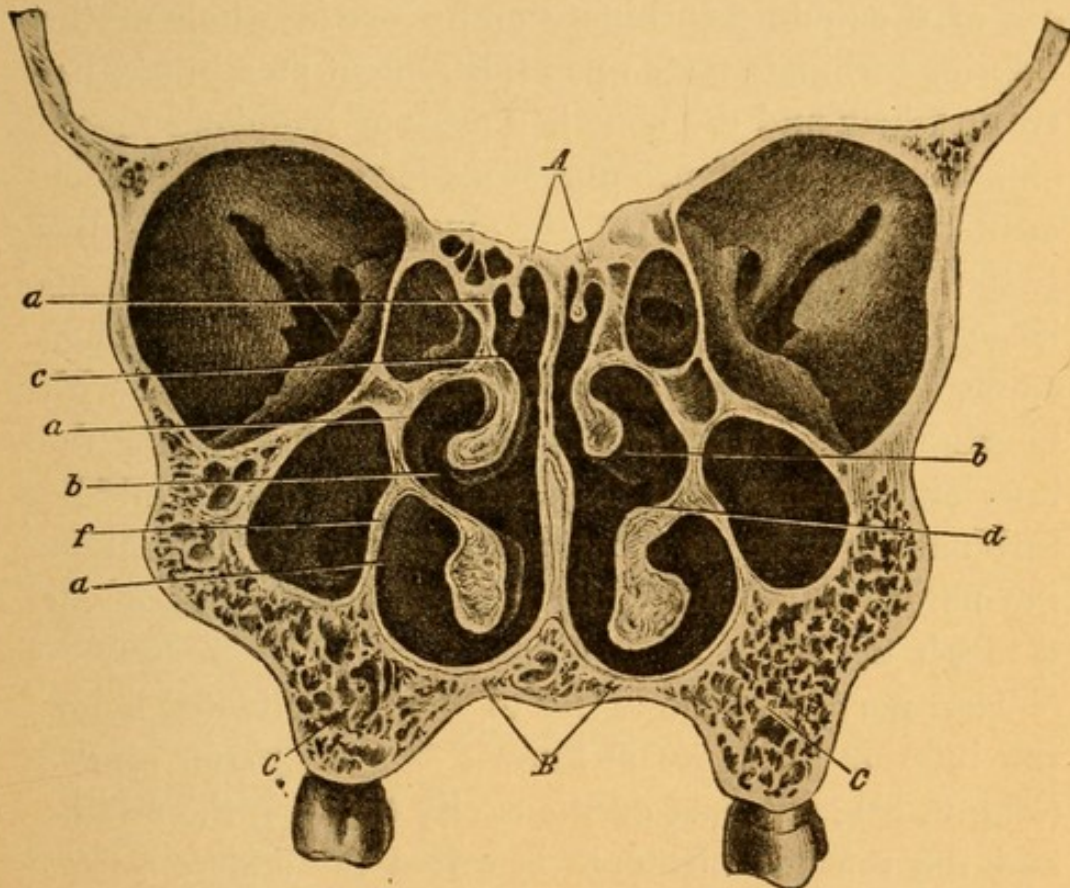
There is occasionally a fourth turbinate, rudimentary in character, parallel to and above the superior turbinate.

DIMENSIONS. The antero-posterior diameter of the nasal cavity along the floor is from one and three-fourths to two inches. The vertical height of the nasal cavity anteriorly, just within the anterior orifice, is about five-eighths of an inch. The height of the nasal cavity at the posterior extremity is from one to one and one-fourth inches.

The lining membrane of the outer wall of the nose, for a distance of about one-half inch, is composed of stratified epithelium, through which pass a number of hairs, called vibrissæ. This portion of the cavity of the nose is called the vestibule (Fig. 2, V). The re-

maining portion of the cavity is lined with a mucous membrane, which varies in character in the upper and lower portions of the cavity. The upper part, known as the olfactory region (Fig. 3, *c*), consists of the upper

FIG. 3.



Transverse section of the head, showing the relation of the structures within the nasal cavities. (ZUCKERKANDL.)

A. Roof of nose. *B.* Floor of nose. *f.* Outer wall. *C.* Superior maxilla. *a*¹. Superior meatus. *a*². Middle meatus. *a*³. Inferior meatus. *b.* Middle turbinate. *c.* Olfactory region. *d.* Respiratory region.

third of the septum, the mucous membrane over the superior turbinate, and the upper half of the middle turbinate. It is covered with columnar epithelium, and contains the endings of the olfactory nerve. Situated in this region is a considerable amount of yellow-

ish-brown pigment, giving to this part of the mucous membrane a yellowish instead of a pinkish tinge. This pigment probably is connected with the sense of smell.

The rest of the nasal cavity, known as the respiratory region (Fig. 3, *d*), is lined with ciliated columnar epithelium. The mucous membrane over the lower border of the middle turbinate and over the whole of the inferior turbinate rests upon a basement membrane, between which and the bone is a mass of lymphoid tissue, embedded in which are numerous mucous glands which open upon the surface of the mucous membrane. Between the lymphoid tissue and the bone are numerous large thin-walled venous channels, collapsing when empty or capable of being enormously distended with blood. When so distended the soft parts covering the inferior turbinate and the lower border of the middle turbinate may be so enlarged as completely to occlude the nares and mechanically prevent the passage of air through the nose.

That portion of the cavity of the nose situated below the inferior turbinate is known as the *inferior meatus* (Fig. 3, *a*³); the part of the cavity between the middle and the inferior turbinate is called the *middle meatus* (Fig. 3, *a*²); and the cavity between the superior and the middle turbinate is known as the *superior meatus* of the nose (Fig. 3, *a*¹).

Blood Supply of the Nose.

The arterial supply of the olfactory region of the nose is derived in part from the ethmoidal branches of the ophthalmic artery. The rest of the mucous membrane gets its blood supply from the branches of the internal maxillary.

The venous blood returns by three distinct channels :

1. The blood from the upper olfactory region enters the ethmoidal veins, whose blood passes into the superior longitudinal sinus.

The lesson to be drawn from this is that operations in this region are not to be undertaken lightly, owing to the danger of infection being carried from these veins to the superior longitudinal sinus, causing thrombosis and meningitis.

2. The bulk of the blood passes into the veins accompanying the arteries, and thus into the internal maxillary vein.

3. Some of the veins on the floor of the nasal cavity and of the anterior portion of the septum anastomose with the veins of the skin at the exterior of the nose, and the blood from these regions returns by way of the facial vein. The result of this is frequently seen in the redness and congestion of the tip of the nose during certain inflammatory conditions within.

Lymphatics.

The lymphatics of the nose run posteriorly, and terminate in lymphatic glands situated at the vault and at the upper lateral wall of the pharynx.

The Accessory Sinuses of the Nose.

The accessory sinuses of the nose are :

1. The antrum of Highmore, known also as the maxillary sinus, or simply as the antrum.
2. The frontal sinus.
3. The anterior ethmoidal cells.
4. The posterior ethmoidal cells.
5. The sphenoidal sinus.

The ANTRUM, or MAXILLARY SINUS (Fig. 3), is a large pyramidal-shaped cavity, hollowed out of the body of the superior maxillary bone. Its floor is usually on a level with the floor of the nasal cavity. It may, however, be at a somewhat lower or even at a considerably higher level. Its upper boundary is the floor of the orbit, from which it is separated by a thin layer of bone. Its walls vary considerably in thickness.

The inner wall of the antrum is usually thin and easily punctured at a point immediately below the middle of the ridge marking the attachment of the inferior turbinated bone to the outer wall of the nose.

The antrum is also very thin on its anterior surface, in that horizontal groove that runs above the first molar tooth.

The cavity of the antrum communicates with the nose by a small opening in the middle meatus, situated about half-way between the anterior and the posterior portion of that meatus. The boundaries of this opening are frequently membranes instead of bone. This would be the ideal place for a probe or aspirating-needle to enter the cavity of the antrum, were it not that the middle turbinate is frequently so curved that it is difficult to find the natural opening.

The mucous membrane of the antrum is continuous with that lining the nose, and differs from it only in the pleated, folded condition in which it is often found.

Occasionally a root or roots of one of the back teeth (bicuspid or one of the molars) project into the cavity of the antrum.

The FRONTAL SINUSES (Fig. 2, F. S.) vary considerably in size. Each sinus extends horizontally outward

from one and a half to two inches from the median line, and has a vertical height of about one inch in the median line. The two sinuses are usually completely separated from each other by a median partition. Each has an outlet, the infundibulum, into the nasal cavity, opening into the middle meatus along the outer wall, usually just anterior to that of the maxillary sinus. One or both sinuses may be absent.

The ANTERIOR ETHMOIDAL CELLS vary in number, and communicate with the nasal cavity in the middle meatus. One of these cells projects from the outer wall of the nasal cavity, and is known as the bulla ethmoidalis. This marks the lower boundary of a groove into which the infundibulum from the frontal sinus empties.

The POSTERIOR ETHMOIDAL CELLS also vary considerably in number and communicate with the cavity of the nose in the superior meatus.

The SPHENOIDAL SINUS (Fig. 2, S.S.) is a large cavity hollowed out of the body of the sphenoid bone. It varies considerably in size, and is occasionally absent. It is partitioned in the median line similarly to the frontal sinus, and each cavity then communicates with the superior meatus along the outer wall of the nose.

The distance of this sinus from the anterior portion of the nose varies somewhat, but it is usually from two and seven-eighths to three and one-fourth inches.

ANATOMY OF THE PHARYNX.

The pharynx extends from the under part of the basilar portion of the sphenoid bone to the level of the cricoid cartilage of the larynx. It is conveniently divided into (1) the nasopharynx, extending from the sphenoid bone to the lower border of the soft palate;

(2) the oropharynx, continuous above with the nasopharynx, the lower limit being at the upper level of the epiglottis; (3) the laryngopharynx, the portion behind the larynx.

1. The nasopharynx is the broadest of these portions. Its anterior wall is deficient, being the openings (choanæ) into the posterior part of the nasal cavity. Behind, it is bounded by the occipital bone, atlas, and part of the axis. Laterally it contains the openings of the Eustachian tubes, which are slightly above the level of the hard palate. A distinct ridge, the Eustachian eminence, marks the posterior border of the pharyngeal opening of these tubes; behind them, extending laterally, is a deep groove, Rosenmüller's fossa. The mucous membrane of the nasopharynx is lined with ciliated columnar epithelium. In the submucous tissue are found numerous lymphatic glands. These are bunched at the upper and posterior wall, forming the pharyngeal, Luschka's, or the third tonsil. Many mucous and some serous glands are found beneath the mucous membrane. The lymphatic channels pass into the lymphatic glands situated at the angle of the jaw, and this accounts for the enlargement of the glands here in certain affections of the nasopharynx.

2. In connection with the description of the oropharynx we shall describe also the soft palate, tonsils, and tongue. The posterior wall of the oropharynx is formed almost entirely by the body of the axis. This should be nearly flat, but in a child that has suffered from rickets or caries of the cervical vertebræ the body of the axis is often abnormally convex, projecting into the cavity of the nasopharynx so markedly as to make a decided obstruction at the point of junction of

the nasopharynx and oropharynx. The anterior wall of this cavity is absent, being the channel of communication between the mouth and the pharynx. The lateral wall is composed of loose connective tissue and the constrictor muscles of the pharynx, which separate it from the great bloodvessels of the neck. The mucous membrane is similar to that found in the nasopharynx, except that it is covered with stratified epithelium. The lymphoid tissue is in scattered nodules, except on the lateral walls just behind the posterior pillars of the fauces, where a chain of lymph nodules runs vertically, connecting with the lymphoid tissue along the lateral walls of the nasopharynx.

The soft palate, or velum, consists of two layers of mucous membrane, including between them muscles. The upper border is attached to the posterior margin of the hard palate. The lower border is doubly concave, with a prolongation in the median line, called the uvula. It is to the uvula alone that the laity usually refer when they speak of their palate being long, etc. In the median line can be seen the raphé, or line of junction of the two halves of the soft palate that existed in the embryonic state. Laterally the palate above consists of a single layer, but half-way down in its course it separates into two folds. One contains the palatoglossus muscle, and, passing forward, becomes attached to the posterior lateral margin of the tongue. This is called the anterior pillar of the fauces. The other fold passes downward and backward, and contains the palatopharyngeus muscle, which is inserted into the lateral and posterior wall of the oropharynx. This constitutes the posterior pillar of the fauces.

Between the two pillars of the fauces lie the ton-

sils, or, more properly, the faucial tonsils. These consist of large masses of lymphoid tissue held together by a varying amount of connective tissue and covered on their free surface with stratified epithelium. Externally they are separated from the ramus of the inferior maxilla and the bloodvessels of the neck by a layer of fat and loose connective tissue. Starting from the free surface and penetrating into the substance of the tonsil are several (eight to twenty) canals, called lacunæ or crypts. In the normal tonsil (one which does not project beyond the pillar of the fauces) these are not very deep; but in the greatly enlarged tonsils they may penetrate the substance of the tonsil for a distance of half an inch. After leaving the surface these lacunæ often branch like an inverted Y. The canal of the lacunæ normally contains some of the lymphoid cells such as compose the bulk of the tonsil. At the bottom of the canal these cells are in a fair state of preservation, but as they are forced on toward the outlet they are found to have undergone fatty degeneration—to have disintegrated and broken down into a fatty granular mass teeming with bacteria. The bacteria are usually non-pathogenic, but occasionally Klebs-Loeffler bacilli and pneumococci are found in normal tonsils.

The points on the tongue that are of interest to the laryngologist are the mass of veins, often greatly distended and varicose, situated at the posterior portion behind the circumvallate papillæ. The presence of lymphoid tissue in this same region, at times excessively hypertrophied, constitutes the so-called lingual tonsil.

3. The laryngopharynx is a membranous canal, the anterior part of which is deficient, being the opening

into the larynx. It is funnel-shaped, broader above than below. Its point of junction with the esophagus is the narrowest part of the digestive tract, and the place where large foreign bodies and masses of food, too large to be swallowed, lodge. Should a foreign body be large enough to cover the entrance to the larynx, death from asphyxia quickly ensues.

ANATOMY OF THE LARYNX.

The larynx is a cartilaginous box composed of the thyroid, cricoid, the two arytenoid cartilages, and the epiglottis. There are four other cartilages—two cartilages of Santorini superimposed upon the arytenoid, and two cartilages of Wrisberg external to those of Santorini. The thyroid cartilage is the largest, and shields, as its name indicates, the structures within. A strong fibrous membrane (thyrohyoid) connects it with the hyoid bone above, and a similar membrane (cricothyroid) connects it with the cricoid cartilage below. The cricoid cartilage is the support of all the other cartilages of the larynx. Upon it rest the movable arytenoid cartilages, to which the vocal cords are attached. The epiglottis is a leaf-like cartilage, the apex directed downward and attached to the thyroid cartilage, the base being uppermost. It is connected to the root of the tongue by three ligaments—one in the median line and two laterally. These ligaments form, with the tongue and epiglottis, two fossæ, the glosso-epiglottic, in which foreign bodies, such as fish-bones, often lodge. The arytenoid cartilages are two small cartilages, triangular in cross-section, resting upon the upper and posterior part of the cricoid. They are freely movable about a

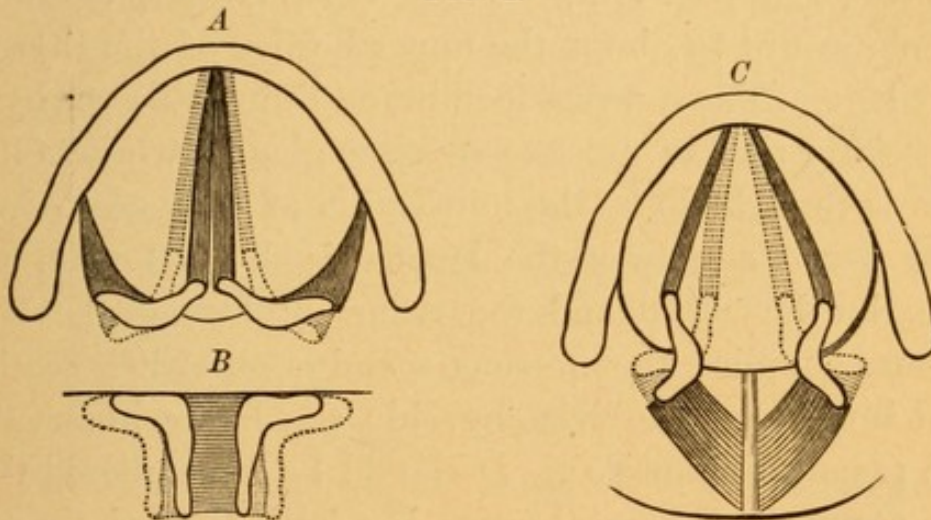
vertical axis, and also slide laterally over the upper surface of the cricoid. The varying positions of the arytenoid cartilages cause the movements of the vocal cords, whereby these are approximated or drawn apart. The cartilaginous framework of the larynx acts as a protection to the delicate structures within, at the same time affording sufficiently firm and resistant points of attachment for the vocal cords and the muscles necessary to regulate the position and tension of these.

The vocal cords are two bands of yellow elastic tissue attached anteriorly to the nearly immovable thyroid cartilage and posteriorly to the very movable arytenoid cartilages. Their length in the male is about three-quarters of an inch; in the female they are about half an inch long. They are covered with a thin layer of mucous membrane, the epithelium over which is squamous. Their normal color is white (see Plate II., Figs. 1 and 2, *c*). The space between the vocal cords is called the glottis, or the *rima glottidis*. The cavity of the larynx above the vocal cords is known as the supraglottic region. The portion of the larynx below the vocal cords is known as the subglottic region. The muscles of the larynx may be classed, according to their effect upon the glottis, into those which narrow and those which widen the glottis. The former approximate the vocal cords, the latter separate them. The narrowers of the glottis are the thyro-arytenoidei externi, the thyro-arytenoidei interni, and the arytenoideus. The muscles which widen the glottis are the crico-arytenoidei postici.

In Fig. 4 the lightly shaded dotted portions show the position of the uncontracted muscles and arytenoid cartilages, while the heavily shaded parts show the

same as the result of the contraction of the muscles. *A* shows the action of the thyro-arytenoidei externi. They rotate the arytenoid cartilages, and approximate and render tense the vocal cords. *B* shows the action of the arytenoideus. It approximates the vocal cords without necessarily increasing their tension. *C* shows the action of the crico-arytenoidei postici. They separate and relax the vocal cords. In addition to these muscles the two cricothyroids increase the tension of the vocal cords without usually affecting their positions.

FIG. 4.



Diagrammatic representation of the action of the laryngeal muscles upon the arytenoid cartilages and vocal cords. (SCHROETTER.)

A. Action of thyro-arytenoidei externi. *B.* Action of arytenoideus.
C. Action of crico-arytenoidei postici.

The thyro-arytenoidei interni relax the cords; and the ary-epiglottici, when contracted, markedly narrow the entrance into the larynx. It must be remembered that this is not the glottis, for the entrance to the larynx is from a quarter to half an inch above the vocal cords. The mucous membrane of the larynx, except that over the vocal cords, is covered with ciliated columnar epithelium. The submucosa is made up of connective and

elastic tissue, and contains mucous glands and some lymphatic tissue. The mucosa is very loose over the arytenoids and the ventricular bands, thus accounting for the ease with which it becomes edematous at these places. A thick fold of mucous membrane, the ventricular band (see Plate VII., Figs. 1 and 2, *b*), often improperly called the false vocal cord, extends from the thyroid cartilage to the arytenoid, above and parallel to each vocal cord. Between the vocal cord and the ventricular band on either side is a cavity called the ventricle of the larynx, or the ventricle of Morgagni (see Plate VII., Fig. 1, *k*). These extend, first, laterally, then upward to about the upper border of the thyroid cartilage. The mucous membrane lining this cavity is especially rich in mucus-secreting glands, whose function is thought to be the lubrication of the vocal cords. The nerve supply of the larynx is derived from the superior laryngeal and the recurrent laryngeal. The former supplies the mucous membrane with sensation and innervates the cricothyroid; the latter innervates the remaining muscles. It should be remembered that the recurrent laryngeal nerve is a branch of the pneumogastric, and that on the left side it winds around the arch of the aorta, while on the right side it passes behind the subclavian artery.

CHAPTER II.

PHYSIOLOGY OF THE UPPER RESPIRATORY TRACT.

PHYSIOLOGY OF THE NOSE.

THE functions of the nose may be classed as :

1. Respiratory.
2. Olfactory.
3. Auditory.
4. Vocal.

1. RESPIRATORY. The respiratory functions of the nose may be divided into :

- (a) The filtering of dust and germs from the inspired air.
- (b) The warming of the air.
- (c) The moistening of the air.
- (d) The destruction of some of the disease-producing bacteria.

(a) The hairs, or vibrissæ, at the vestibule of the nose prevent the entrance of large particles of foreign matter, and upon them, as upon a filter, are deposited many of the particles of dust and bacteria. Those which escape the vibrissæ are most of them entrapped by the mucus covering the surface of the mucous membrane lining the nose.

The shape of the nasal cavity, partitioned as it is by the turbinated tissues, breaks up the column of entering air, causing eddies within the nose, so that almost all of the inspired air comes in contact with some part

of the nasal mucous membrane, thus facilitating the deposit of foreign particles upon it.

The inspired air in passing through the nose takes a somewhat curved direction, the bulk of it passing through the middle meatus. This can be easily demonstrated by placing a small plug of cotton along the floor of the nose in the inferior meatus and noting the amount of obstruction that such cotton produces; remove this piece of cotton and place an equally large piece in the middle meatus, and it will be found that the amount of obstruction caused by this second piece of cotton is much greater.

(b) Physiology teaches that the temperature of the expired air is usually about $98\frac{1}{2}^{\circ}$ F. The temperature of the inspired air is, in this climate, with the exception of a few days in summer, lower than that of the expired air. The increased warmth of the expired air is almost exclusively derived during the passage of the inspired air through the nose. Aschenbrandt, by an ingenious device, determined the fact that the inspired air on reaching the nasopharynx had been warmed almost to the full extent that it would have acquired on expiration.

(c) Expired air invariably contains more moisture than that which is inspired, and is saturated with moisture at the temperature at which it is expired. This increase in moisture is for the most part added to the air that passes through the nose during inspiration, the peculiar arrangement of bloodvessels in the mucous membrane of the inferior and middle turbinates being the principal source of the watery secretion. It is estimated that the total amount of water secreted by the nose and necessary to moisten the inspired air is

from twelve to eighteen ounces daily, varying with the temperature of and the amount of moisture in the inspired air.

(d) It is claimed by some bacteriologists that the secretions found on the nasal mucous membrane retard the growth of some bacteria and prevent the development of others. While these observations lack confirmation, the scarcity of bacteria found well within the nasal cavities beyond the vestibule makes it seem highly probable that the mucus of the nose may have a bactericidal influence.

2. OLFACTORY. The mucous membrane of the nose contains the peripheral organs for the sense of smell. These are distributed along the upper half of the septum over the superior turbinate and the upper half of the middle turbinated body. In order that the sense of smell may be perfect it is necessary, first, that there shall be no obstruction to air reaching these portions of the nasal cavity; second, that the peripheral endings of the olfactory nerve in the mucous membrane shall not have been destroyed by any local disease; third, that the pathway from the periphery to the cortical centre for the sense of smell must be intact.

3. AUDITORY. The Eustachian tube, which enters the nasopharynx, serves the purpose of ventilating the middle ear, thus equalizing the atmospheric pressure on the external and internal surfaces of the membrana tympani. Whenever there is partial or complete obstruction to nasal respiration mouth-breathing is indulged in; the current of air entering the mouth and passing just below the nasopharynx aspirates some of the air from the nasopharynx, Eusta-

chian tube, and the cavity of the middle ear, thus diminishing slightly the atmospheric pressure within the middle ear. The effect of this is to cause a sinking in of the membrana tympani and to blunt somewhat the acuteness of perception of sound.

4. VOCAL. While sound is produced within the larynx by vibration of the vocal cords, certain of the sounds receive many added characteristics from the vibrations of the air in its passage through the nasopharynx and nasal cavities. Whenever the nose or nasopharynx is obstructed these vibrations are rendered abnormal or impossible, and hence that part of the sound derived from the nasal cavity is absent, and the individual is said to be talking through his nose. As a matter of fact, the individual is not talking through the nose, but it is the absence of that vibration which is necessary for proper resonance that gives the peculiar character which, from the prevailing catarrhal conditions in this country, has given rise to the peculiar nasal twang ascribed to Yankee speech.

Of the four functions of the nose, that which is vitally the most important to the individual is the respiratory. The functions of warming, moistening, and filtering the air can only imperfectly be accomplished by the pharynx and larynx, as there is no adequate provision in these tissues for carrying on this function. The result of mouth-breathing, therefore, is a sensation of dryness in the throat. The dust-laden air striking the delicate mucous membrane of the pharynx and larynx is a common cause of attacks of inflammation in these parts.

PHYSIOLOGY OF THE PHARYNX.

The nasopharynx serves as a resonating chamber in the production of certain tones of the voice. It should be a continuation of the tract through which inspired air enters the oropharynx. It also serves as a source of ventilation of the middle ear. The wise provision of placing the opening of this canal here can be seen when it is remembered that air passing through the nose is warmed to nearly body temperature by the time it reaches the nasopharynx, thus preventing the ill effects of cold air on the delicate mucous membrane of the middle ear. The functions of the oropharynx and laryngopharynx comprise those of digestion, respiration, and phonation. These form a common tract for the passage of food and the respired air. The soft palate is drawn backward by the action of its muscles during swallowing, so as to prevent the food entering the nasopharynx and passing out of the nose. Where the soft palate is absent or its muscles paralyzed patients find difficulty in swallowing liquids without allowing a portion to be discharged through the nose. The soft palate in its different positions aids in the production of the voice.

PHYSIOLOGY OF THE LARYNX.

The functions of the larynx may be divided into those of respiration, sound-production, and deglutition. The respiratory functions of the larynx consist in keeping an open, unobstructed pathway for the entrance and exit of air. During inspiration the glottis is widened somewhat, to be narrowed again during expiration. These movements of the vocal cords can easily be seen

in most individuals during respiration while the larynx is being observed through the laryngeal mirror. Sound is produced by vibration of the vocal cords when proper tension has been made by the muscles described. This vibration is normally produced only by the current of expired air. The sound produced varies with the size and shape of the larynx, with the length, thickness, and tension of the vocal cords, and with the force with which the expired air can be thrown against them. In cases in which the vocal cords are destroyed by disease the ventricular bands may vibrate sufficiently to make a sound. Sound alone is made by the larynx. Speech is the result of the modification of this sound by the various movements made by the soft palate, tongue, lips, and teeth. In cases in which the entire larynx has been excised patients have learned to speak so as to be distinctly heard at a distance of many feet. In such cases the blast of expired air has set in motion some folds or projections of mucous membrane along the respiratory tract, and the sounds so made are modified in the normal way. The voice in such cases is seldom better than a loud whisper. The function of the larynx in deglutition lies mainly in its being drawn up under the base of the tongue, out of the way of the bolus of food. At the same time, owing to contraction of the ary-epiglottic muscle, the entrance to the larynx is markedly diminished. The epiglottis is folded down so as partially to shield the entrance to the larynx. It does not prevent the entrance of food into this canal, as once believed, for it has been completely destroyed by disease without any greater tendency of the food to enter the larynx than before.

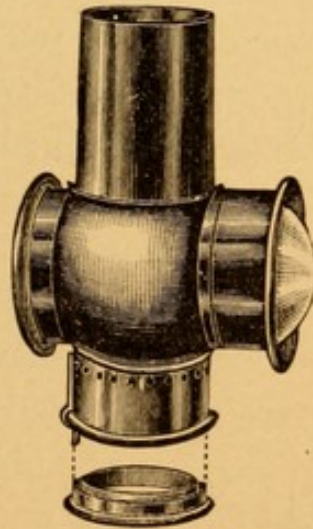
CHAPTER III.

EXAMINATION OF THE UPPER RESPIRATORY TRACT.

WITH the exception of the mouth, which may be examined by means of direct illumination, the examination of the upper respiratory tract must be made by means of light reflected from a mirror.

The source of illumination may be sunlight or some form of artificial illumination. As sunlight is not always available, artificial light is usually employed.

FIG. 5.




Mackenzie condenser.

The naked flame of an Argand burner, using either gas or oil, or, better, an Argand burner provided with a Mackenzie condenser (Fig. 5), is the most common source of illumination. The Welsbach hood with a

Mackenzie condenser affixed gives a much more brilliant light than that of the ordinary gas-jet, but it is of a greenish-white color.

FIG. 6.



Coakley lamp and stand.

a Mackenzie condenser. The light from this 20 candle-

One who is accustomed to inspecting the air-passages with an ordinary gas or oil light will not readily discern with the Welsbach light the slight differences in color that he has been in the habit of noting with either of the other forms of illumination.

Electricity is the best source of illumination. It gives a very brilliant light, but the reflection of the carbon filament in an unfrosted bulb unequally illuminates the different portions of the examined area. This defect may be remedied by using a frosted lamp, although the light from which is not quite as brilliant as that from an unfrosted one.

The author has devised a lamp mounted on a stand (Fig. 6) in which a frosted bulb containing a spiral filament may be accurately centered opposite the proper focal distance of the lens in

power lamp is very brilliant and sufficient to thoroughly illuminate the deepest portions of the nasal cavities, larynx, and trachea during operations. Its portability, easy adjustment in height, and the simple mechanism for changing the direction of the illuminating rays are valuable features.

In emergency cases, when called to the house of a patient to make a bedside examination, a candle, or, better still, three candles bound together, may be used. The author has recently employed under such circumstances a small, dry-cell electric lamp, similar to that used on bicycles.

In whatever form artificial illumination be employed, there should be some mechanism by which the light may be raised or lowered in order to accommodate it to the varying heights of different patients. The source of illumination should be placed to the right of the patient, on a level with the patient's ear and just behind the transverse axis uniting the ears.

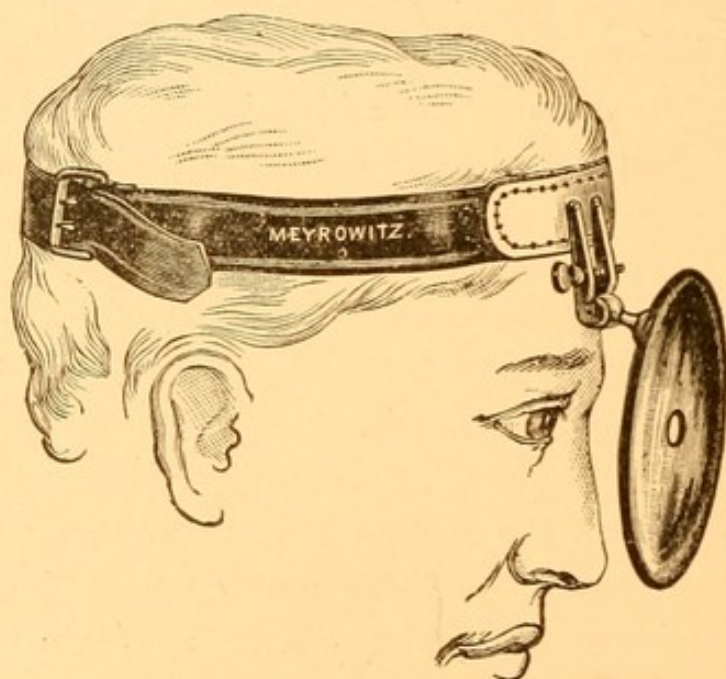
A concave mirror (Fig. 7) is employed to reflect the rays of light into the regions that are to be examined. This mirror should be three and one-half inches in diameter, with a five-sixteenths of an inch circular opening in its centre, and have a focal distance of about eight inches. It should be attached to a head band by a single ball-and-socket joint.

Some head bands are provided with a nose rest, but the author believes that this only adds weight to the mirror without increasing the stability of the instrument.

To illuminate properly any part of the respiratory tract the patient should be seated in a high-backed

chair, with the head resting against the back of the chair. The examiner should be seated upon a stool, similar to a piano stool, capable of being raised or lowered, in order that he may accommodate his height to that of the patient. He should then arrange his own head and the light so that both may be on a level with the patient's ear. The head mirror should be so adjusted that the opening in the centre of the mirror will be opposite the pupil of his left eye (Fig. 7). The

FIG. 7.



Head mirror and band, with its proper adjustment over the left eye.

mirror should then be rotated to the right, to the left, up or down, as the case may be, so that the light may be reflected upon the face of the patient. The examiner's head must then be moved forward or backward until in such a position as to give the greatest illumination of the part to be inspected. The distance of the mirror (practically that of the examiner's head)

from the part to be inspected is the same as the focal distance of the mirror.

The difficulty that every *beginner* experiences in attempting to make this adjustment is that instead of keeping *his* own head fixed and moving the mirror to illuminate different portions, *he* attempts to keep the mirror fixed and moves his head in order to change the direction of the illuminating rays. The head is thus placed in strained and unnatural positions. He is unable to look at the illuminated part with more than one eye, and he finds it impossible in this strained position to use properly the other instruments necessary for thorough examination of the parts. He should always be able to see any illuminated part with both eyes. The test for this is easily made by closing the right eye and noting whether he can with the left eye look through the opening in the mirror and see the desired illuminated portion.

Binocular vision is very necessary in using the throat mirror and other examining instruments, in order that we may note just how far within any cavity the instrument may be placed. An individual who has the sight of but one eye has learned to judge distance from long experience, but he who has the sight of both eyes has more difficulty in appreciating distances with the use of but one eye.

The examination of the nasal cavities should be made from in front, which is called anterior rhinoscopy, and also from behind, posterior rhinoscopy.

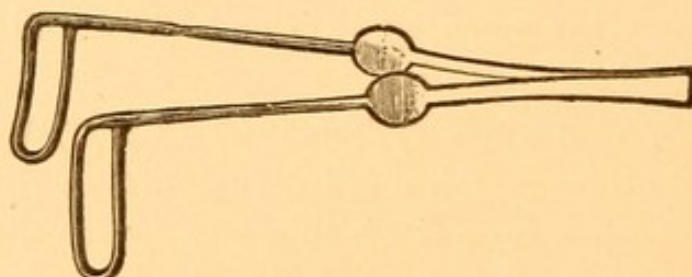
ANTERIOR RHINOSCOPY.

Although one cannot inspect the structures deep within the nasal cavities without dilating the nostril with some sort of nasal speculum, yet very valuable information can be gained as to the position, shape, and width of the nasal orifices, columnar cartilage, deviations of the septum, and spurs situated anteriorly without the use of a speculum, either by simple inspection or by tilting upward the tip of the nose.

SPECULUM.

There are many forms of specula used to dilate the anterior nasal orifice, and it becomes a matter of habit

FIG. 8.



Bosworth's nasal speculum.

with each individual examiner as to the kind of speculum that he will use. The small wire speculum of Bosworth (Fig. 8) is a very convenient form, and serves admirably the purpose of dilating the nostrils of children. It is not a formidable looking instrument, and does not frighten them as much as some of the larger instruments. It has one drawback. In the examination of the nares of adults, where the vestibule is thickly studded with hairs, these are not adequately pushed

aside, and the view of the deeper structures may be somewhat obscured by their lying in the line of vision.

This speculum should be held with the thumb and forefinger placed upon the two enlargements found about half-way along the handle, the blades brought into apposition and inserted within the nostril, one blade looking toward the septum and the other toward the outer wall of the nose. The instrument should be held so as to make an angle of about thirty degrees to the median line of the face. The pressure of the thumb and finger upon the sides of the handle should be gradually diminished, thus allowing the blades to separate, and when the maximum dilatation of the nostril is obtained the thumb and finger should hold the blades in this position. If no pressure at all is made upon the sides of the handle, the force of the spring may be so great, when exerted entirely upon the nasal orifice, as to cause discomfort to the patient.

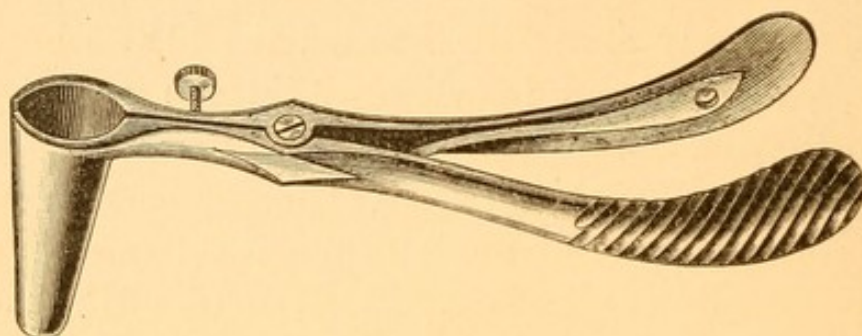
Where the vestibule contains many hairs the speculum which the author is in the habit of using is his modification of the Chiari speculum (Fig. 9). The blades, being solid, push the hairs aside, and the view of the nares is no longer obstructed.

It should be held in the hand, the blades being closed when inserted; pressure upon the handles forces the blades apart, thus dilating the orifice. The blades should rest as when using the Bosworth speculum, and it should be held at about the same angle.

In examining with either of these instruments the speculum should be held in the left hand when the right nasal cavity is being inspected, and in the right hand when inspecting the left.

There are many other forms of specula, one of which, the Myles speculum (Fig. 10), is self-retaining. This

FIG. 9.

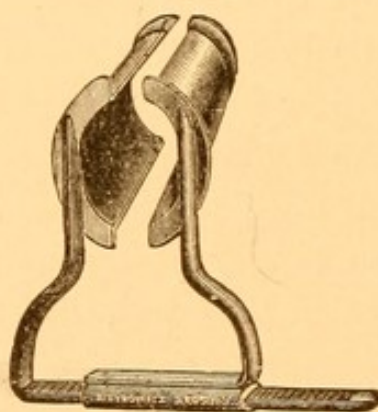


Coakley's nasal speculum.

may be an advantage occasionally when one desires to have both hands free for operative work.

The Myles speculum should be inserted with the blades closed and with the cross-bar up toward the

FIG. 10.



Myles' nasal speculum.

roof of the nose, and then the blades slid apart until the desired dilatation of the orifice is obtained.

With the nostril well dilated one proceeds to examine the structures within the nose.

If the patient's head is held in a natural position, we

see within the cavity along the outer wall a ridge covered with mucous membrane, the inferior turbinate. Usually there can be seen a space below this, the inferior meatus, and a space above it, the middle meatus. The lower part of the septum will also be brought into view. The middle turbinate and the structures in the upper portion of the cavity will probably not be visible. In order to see the middle turbinate it is usually necessary to tilt the head backward, possibly to an angle of forty-five degrees. In order to make a thorough examination through the anterior nares the head should always be tilted backward and forward one or more times, in order to get a good view of all the structures at the different levels of the nasal cavity. The head should also be turned slightly from side to side.

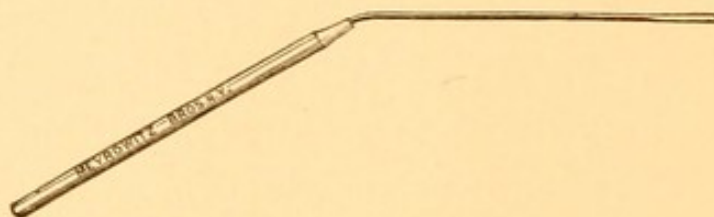
In examining the right nasal cavity, if the patient turns his head slightly to the right the outer wall and the structures found on it will be brought into better view than when the head is held directly forward. By turning the head slightly to the left the septum in its middle and posterior portions can be seen better than when looking straight into the nasal cavity.

From anterior inspection of the normal nose it is very seldom possible to see the superior turbinated body. The inspection of the nose may be rendered somewhat obscure by the presence in it of more or less mucus. If the patient blows his nose, it will often be sufficient to free the cavities from most of this. Sometimes it may be necessary to wipe away mucus or other secretions in order to get the best view of the structures. For this purpose a small metallic applicator wound with absorbent cotton is employed. One that is bent as shown in

Fig. 11 is to be preferred. The tip of the shaft should be triangular and slightly roughened, to facilitate the winding and retention of the cotton.

To wind an applicator properly, one should take a small piece of absorbent cotton and tease it out so that it forms a very thin layer about an inch square. The cotton should then be placed near the tip of the forefinger of the left hand. The applicator should be placed upon the cotton close to the proximal edge, and yet so that only about three-quarters of an inch of the applicator is in contact with the cotton.

FIG. 11.



Nasal applicator.

The cotton should be turned over by the thumb on to the applicator and held tightly between the thumb and finger while the applicator is rotated a number of times with the right hand. This winds the cotton tightly at a point three-quarters of an inch from the tip of the applicator, but leaves the distal part of it fluffy. The point of the applicator is buried in the cotton one-quarter of an inch from its tip. This covers the point and prevents injury to the tissues.

In order to determine the consistency of various tissues that may obstruct the nasal cavity it is necessary to palpate them with some rigid instrument. One may use for this purpose a silver probe, preferably about double the length of that usually found in a pocket-

case. We frequently, however, use for this purpose the naked applicator above described. The probe which accompanies Grünwald's set (Fig. 49) is best adapted to palpate the tissues within the nose.

The nasal mucous membrane is very sensitive, and the introduction of any substance within the cavity is painful and usually produces sneezing.

In order to obviate these conditions, and also to reduce the swelling in tissues which may obstruct the view of the deeper parts of the nasal cavity, it may be advisable to cocainize the nose. The formula that we employ is :

R.—Cocaine hydrochlorate	gr. x.
Antipyrine	gr. xl.
Solution of thymol (alcoholic)	℥ij.
Aquæ	℥j.—M.

(The thymol is used simply to prevent the growth of bacteria in the solution, thereby preserving it practically indefinitely.)

This solution is best sprayed into the nostrils through one of the many forms of hand atomizers found in the market. Two or three compressions of the bulb of the syringe suffice.

POSTERIOR RHINOSCOPY.

The examination of the posterior nares is usually made by means of light reflected from a mirror held at the back portion of the pharynx.

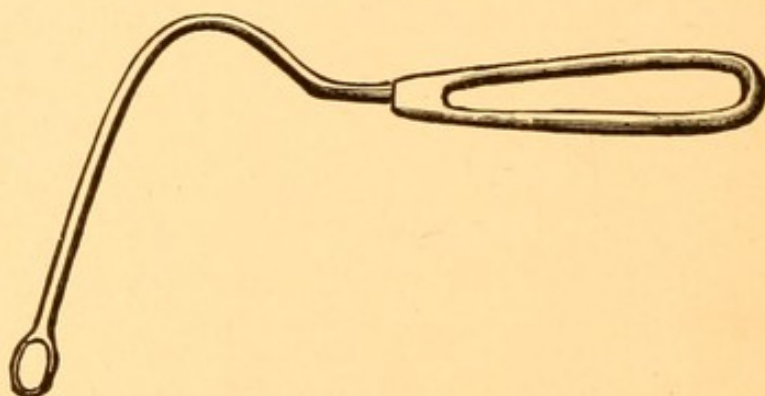
It is seldom that one finds a patient having sufficient control over the tongue to keep this organ well down on the floor of the mouth, so as to permit the use of

the mirror. We employ, therefore, a depressor to keep this organ from obstructing the view.

There are many forms of tongue depressors, but the one which we prefer for this work is Fraenkel's (Fig. 12). Its advantages are:

1. Being of metal and in one piece, with a surface free from depressions in which bacteria can lodge, the instrument is readily sterilized after use in infected cases.

FIG. 12.



Fraenkel's tongue depressor.

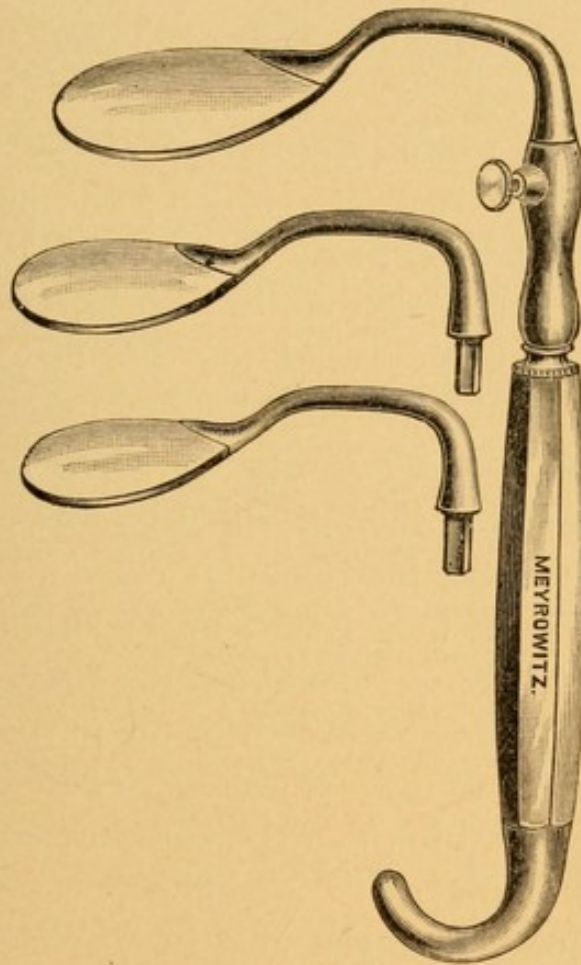
2. The blade being narrow depresses the central more than the lateral portions of the tongue, and thus leaves in the median line more room for the introduction of the mirror than where a broader tongue depressor is used, which cannot depress the tongue to so great an extent.

Occasionally, however, one meets with a very rigid tongue, whose upper surface is markedly convex, and then we find it difficult to employ this narrow-bladed depressor, on account of the tendency of the instrument to slip from the tongue to one side or the other. In such cases, if one cannot gain the confidence of the patient sufficiently to have him relax the peculiar

contraction of the muscles, it will be found necessary to use a depressor whose blade is considerably broader than that of Fraenkel's depressor.

Turek's depressor (Fig. 13) answers well for this purpose, for the blade being somewhat smoothly ser-

FIG. 13.



Turek's tongue depressor.

rated is easily held in place upon such an obstreperous tongue, and if pressure be made with it steadily, yet not too forcibly, usually it will be found that the spasmodic contraction of the tongue muscles gives way. This tongue depressor is an exceedingly valuable instrument, especially in operative procedures

on the posterior nares and nasopharynx, in which the physician needs both hands for the manipulation of the instruments. The blades are made in three sizes and can be clamped in one handle.

The peculiar angle at which the blade is set upon the handle allows the patient to grasp the handle of the tongue depressor and to depress his own tongue, at the same time keeping his hand out of the way of the hands of the operator.

We must earnestly protest against the use of any tongue depressor having a hinge joint, however convenient this instrument may be for being carried about in the pocket. The ease with which infected secretions gain access to the joint and the difficulty of properly sterilizing it render its employment exceedingly dangerous. We know of two cases in which infection (one of diphtheria, the other of syphilis) was conveyed by the use of such an instrument.

The New York City Board of Health has recently provided its inspectors of contagious diseases with thin strips of plain sterilized wood for the purpose of examining the throats of infected cases. These serve admirably the purpose for which they are intended, and similar ones are employed in our office practice for examining the mouth and pharynx in suspicious cases of syphilis and diphtheria. These tongue depressors when once used are burned.

Being straight they do not make very suitable depressors for examining the posterior nares, because the hand of the examiner, when holding the depressor, is apt either to cut off some of the light reflected from the head mirror or to get in the line of vision.

The knack of employing a tongue depressor is not easily acquired. By observing carefully the following points many of the difficulties may be overcome.

1. The mouth should be opened nearly to the full extent.

2. The patient should be told to allow the tongue to rest within the mouth. (Many patients as soon as they open their mouths protrude the tongue.) Attempts at depression with the tongue protruded result in injury to the tongue and spasm of the organ, with insufficient depression.

3. If one carefully observes the tongue while lying quietly within the opened mouth, he will see that it is arched from before backward.

If the end of the tongue depressor be placed in front of the highest point in the arch of the tongue, only the anterior portion will be depressed. The parts behind the tip of the tongue depressor will rise and obscure the field of vision more than if no depressor were used. On the other hand, if the tip of the tongue depressor passes much beyond the highest point of the arch, then the tongue, instead of being depressed directly downward, will be pushed backward as well as downward.

The tongue cannot be pushed backward to any extent without producing gagging. Gagging once excited, it is more difficult for proper depression of the tongue to be made without producing the same result, so sensitive are the tissues of the pharynx.

The proper procedure, then, is to pass the depressor into the mouth carefully, avoiding touching any of the tissues, particularly the upper surface of the tongue, until the tip of the tongue depressor passes about one-eighth of an inch beyond the highest point in the arch

of the tongue, then gradually lower the depressor and make gentle, steady pressure upon the organ. Do not slide the tongue depressor over the surface of the tongue; that of itself is often sufficient irritation to cause reflex gagging.

4. Keep the tongue depressor in the median line. Pressure to one side or the other crowds the tongue so much to the opposite side as often to cause gagging.

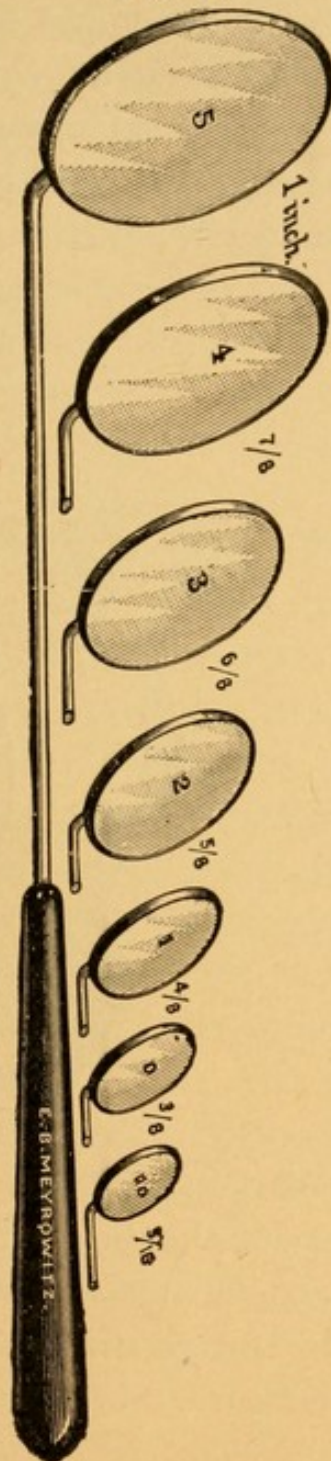
5. Avoid using too great pressure, for in so doing there is insufficient space along the floor of the mouth for the depressed tongue, and it is again forced backward with the inevitable gag.

Having properly depressed the tongue, we next proceed to introduce into the mouth a small throat mirror, in order that the light may be reflected up into the nasopharynx and the tissues there observed. The mirror should first be warmed by passing it over the flame of the light or through that of an alcohol lamp where the electric light is employed. Care must be taken not to have the mirror so hot as to burn the patient. Its temperature should be ascertained by touching the back of the mirror to the palm of the hand.

Throat mirrors are found in varying sizes, usually numbering from 00 to 5. The diameters of these mirrors may be seen by referring to Fig. 14.

The mirror is attached to a long, slender shank, the latter being either inserted into a fixed handle (Fig. 14) or into a movable one, the shank being rendered immovable by a binding screw. The latter arrangement is the more economical, for with the best of care a mirror will last but a short time, while the handle may be used indefinitely with new mirrors.

FIG. 14.



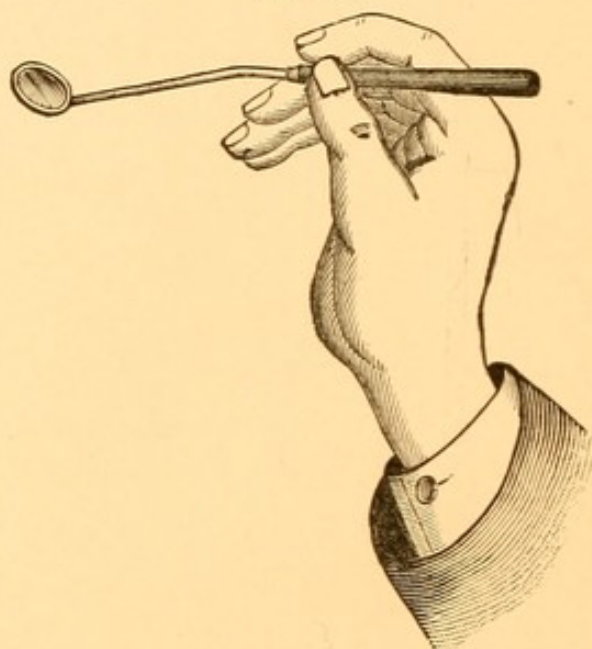
Set of laryngeal mirrors.

We advise each person to provide himself with at least three of the seven sizes of mirrors here shown—viz., Nos. 1, 3, 5.

No. 1 is the size that is ordinarily employed when examining the posterior nares and nasopharynx. If, however, the distance between the soft palate and the posterior pharyngeal wall is sufficient, and the tongue can be depressed enough to permit of the use of a larger sized mirror, better illumination will be obtained.

To introduce the mirror properly, it should be held in the hand as one is taught to hold a pen, the handle

FIG. 15.



resting upon the tip of the middle finger, the forefinger on top of the handle, and the thumb holding the handle against the metacarpophalangeal articulation of the forefinger (Fig. 15). If the shank of the mirror be bent as shown in the figure, a better view of the vault will be obtained.

The mirror should be introduced into the mouth with the reflecting surface looking upward, and about one-quarter of an inch above the tongue. By resting the little finger upon the left side of the patient's chin the

hand may be steadied, so as to prevent trembling, and the mirror kept from touching any portion of the mucous membrane within the buccal cavity.

When the mirror has reached the back part of the throat one obstacle to the introduction will usually be found to be the uvula. Avoid touching this by passing the mirror to one side or the other—where possible to the left side of the uvula (that is, to the right of the uvula as it appears to the observer). The mirror will now be at the back part of the throat, behind the uvula, with its reflecting surface looking upward. The light from the head mirror should be focussed constantly upon the back part of the pharynx.

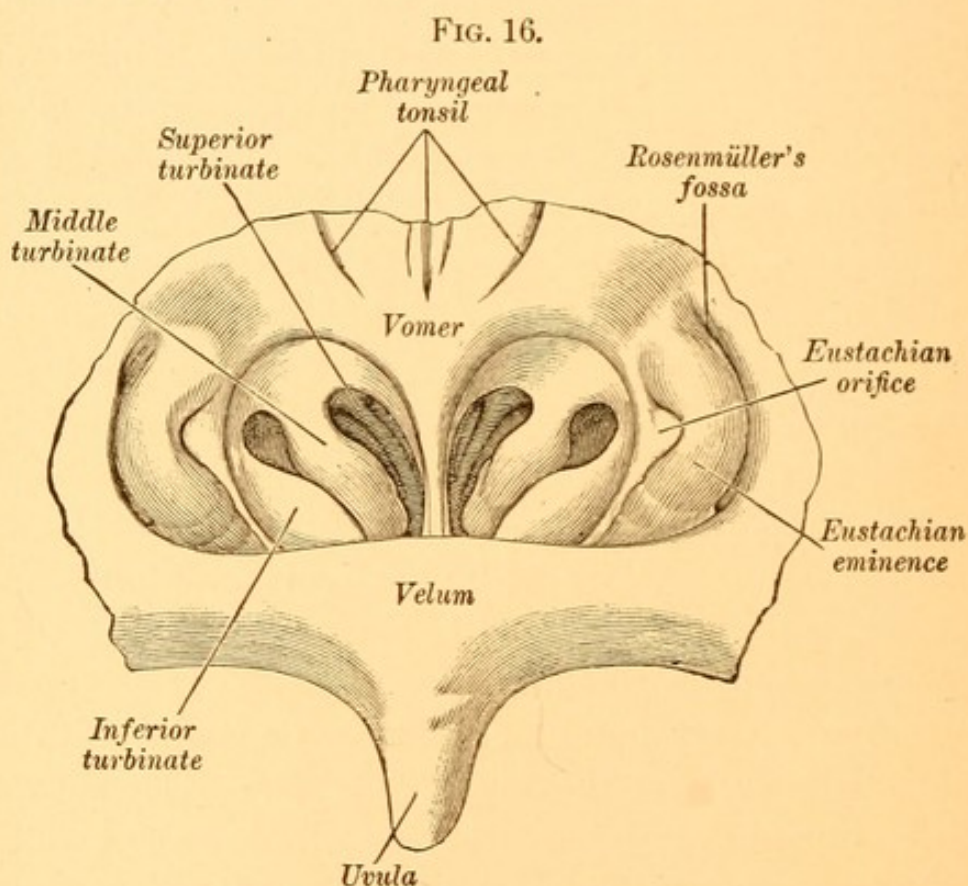
It may be found that the part visible in the mirror is only the posterior or upper wall of the nasopharynx. To bring into view the upper part of the posterior nares, and successively the posterior ends of the middle and inferior turbinated bodies, it will be found necessary usually to depress slightly the handle of the mirror, thereby reflecting the surface somewhat more anteriorly, and allowing one to observe structures that are nearer the floor of the nose.

By rotating the handle of the mirror slightly to the right the tissues on the left side of the nasopharynx will be brought into view, whereas rotating the handle to the left brings into view the tissues on the right side.

It is necessary for the examiner to learn to adjust his mirror so that different portions of the posterior nares and nasopharynx may be successively brought into view. No mirror, however large, if held in one position, can show all the structures. This is not the fault of the mirror, but is due to the cubical shape of the nasopharynx.

For a complete inspection one needs to examine the anterior portion (the choanæ), the two lateral walls, the vault, and the upper part of the posterior wall.

It is scarcely necessary to say that in all the slight movements, rotating and changing the angle of the mirror, no part of the posterior pharyngeal wall, uvula, soft palate, or tongue should be touched, or gagging will be produced.



The objects that will be seen when the mirror is properly held are the posterior border of the septum, usually observed as a thin line situated vertically in the centre of the mirror (Fig. 16). It will be observed that the upper part of this line gradually broadens and finally merges into the upper wall of the naso-

pharynx. At either side of the septum will be found three little projections, pale pink in color, and separated from the septum by a greater or less space. When all three are seen the upper of the three in the mirror is the posterior end of the superior turbinated body. The middle is the posterior end of the middle turbinated body, and the lower the posterior end of the inferior turbinated body. It is seldom that all three of these will be brought into view in a single position of the No. 1 mirror. If the upper and middle are seen, none or only a part of the lower will be visible. If the mirror shows the two lower, then the upper is usually invisible.

Very frequently there will be seen on either side of the septum, about opposite the space between the middle and inferior turbinated bodies, a slight thickening of the mucous membrane of the septum, denoting the presence of erectile tissue. By tilting the mirror to one side we get a view of the lateral wall of the pharynx, upon which can be seen a pear-shaped swelling whose posterior border is a well-defined ridge and whose anterior border is less distinct. In the centre of this swelling can be seen a marked depression, usually grayish in color—the pharyngeal opening of the Eustachian tube.

Behind the more distinct posterior border a vertical groove or depression can be noticed—Rosenmüller's fossa. Not infrequently a little bridge of tissue is seen crossing Rosenmüller's fossa, running from the posterior border of the Eustachian eminence to the angle of junction of the lateral and posterior walls of the nasopharynx. Tilting the mirror so that its reflecting surface looks upward, one can inspect the vault

of the nasopharynx. We there observe a surface that may be nearly smooth, but more frequently we see slight elevations and depressions, and often in the median line a well-marked groove or circular opening. The elevations and depressions are due to an increase in the lymphoid tissue; the groove or opening is the remnant of what probably in earlier life was a fair-sized cavity—the pharyngeal bursa.

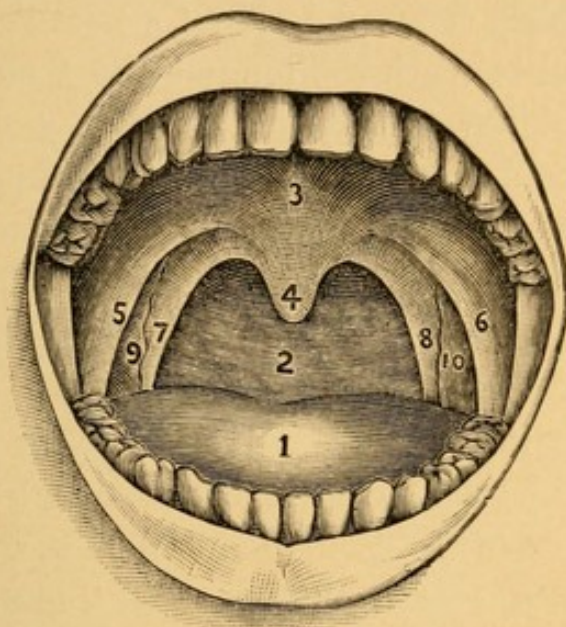
By inclining the mirror so that its surface is more nearly directly upward we get a view of the posterior pharyngeal wall, on which may be seen also, at its upper part, slight elevations and depressions, evidences of hypertrophied lymphoid tissue.

EXAMINATION OF THE MOUTH.

The examination of the mouth and oropharynx is to be conducted with the aid of light reflected from the head mirror. The tongue depressor employed as above described is usually necessary for the full inspection of the structures in this region. The condition of the teeth and gums must first be noticed. The former may give evidence of inherited syphilis or be decayed and the source of bad breath and other conditions. The latter may be inflamed, indicating metallic poisoning, or be the seat of secondary syphilitic manifestations and other inflammatory conditions. The tongue (Fig. 17, 1) should next be observed, and the character and position of its coating, thickenings, and ulceration noted. The sides and under surface as well as the dorsum of the tongue should be examined. If now the tongue depressor be employed, the region of the posterior pharyngeal wall (Fig. 17, 2), soft palate (Fig. 17, 3), uvula

(Fig. 17, 4), pillars of the fauces (Fig. 17, 5, 6, 7, 8), and tonsils (Fig. 17, 9, 10) will be brought into view. The

FIG. 17.



Structures within the mouth as seen when it is opened and the tongue depressed.

1. The tongue. 2. The posterior pharyngeal wall (the oropharynx). 3. The soft palate. 4. The uvula. 5. Right anterior pillar of the fauces. 6. Left anterior pillar of the fauces. 7. Right posterior pillar of the fauces. 8. Left posterior pillar of the fauces. 9. Right tonsil (faucial tonsil). 10. Left tonsil (faucial tonsil).

head should next be tilted well back, so as to get a view of the hard palate—that is, the roof of the mouth.

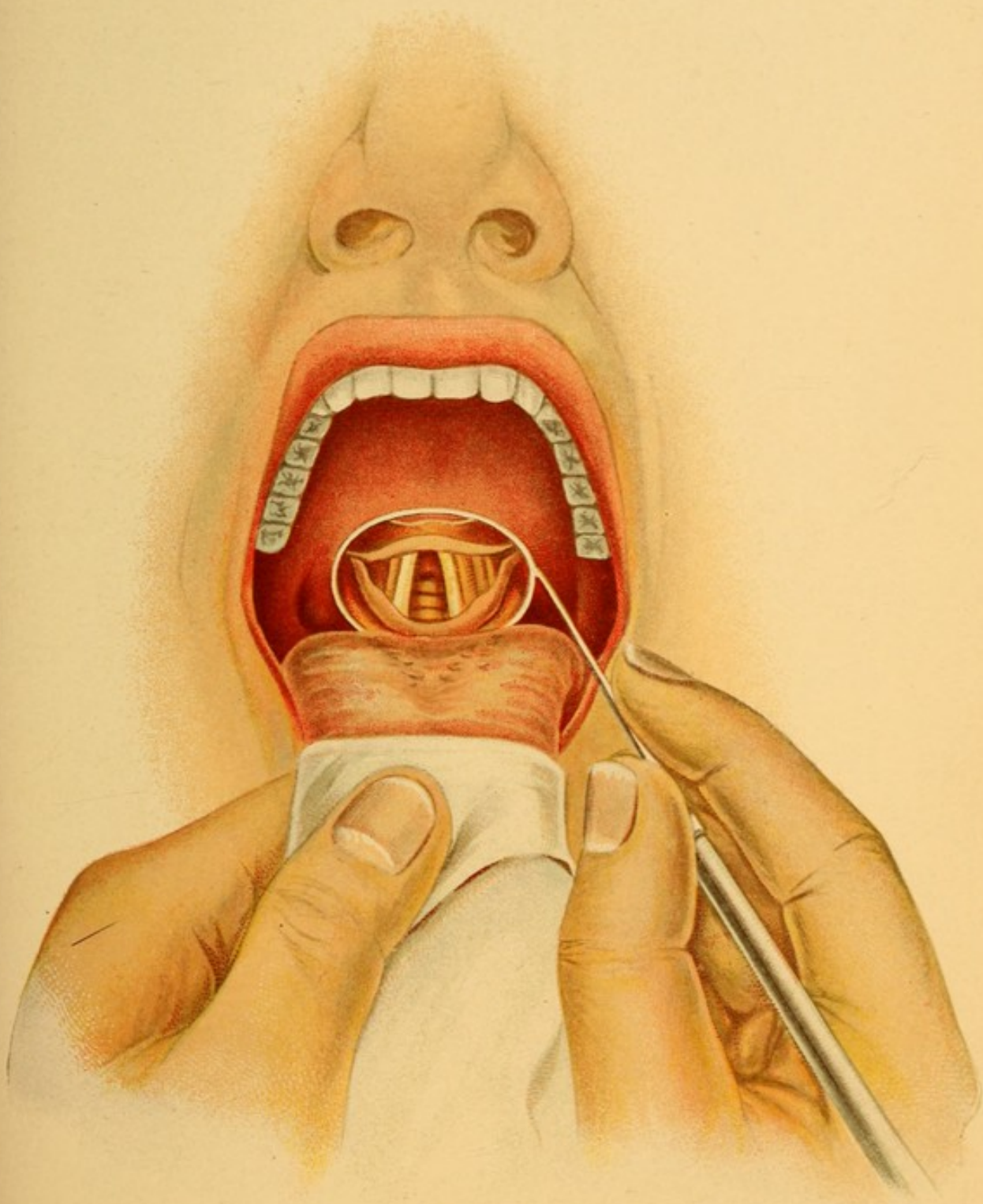
EXAMINATION OF THE ROOT OF THE TONGUE AND LARYNX.

The examination of the laryngopharynx can usually be accomplished only with the aid of reflected light and a laryngeal mirror. To examine the base of the tongue a large-sized mirror, No. 3 or No. 5 (Fig. 14), should be employed, and the mirror warmed as for posterior rhinoscopy. The patient is requested to protrude the

tongue. The examiner then takes in his left hand a piece of cheesecloth or a napkin the size of those used by dentists, and folds it through the middle. The cloth is then laid upon the protruded tongue, the folded edge being posteriorly (Plate I.). Next work the cloth around the sides and beneath the tongue, the forefinger of the left hand holding it in place beneath, and the thumb of the left hand holding it on top, and thus make firm, steady traction on the organ. The tongue is too slippery to be held by the fingers alone. The cloth prevents the slipping. Care must be taken not to make too much traction on the tongue, or the frænum will be pulled against the edge of the lower incisors and wounded. The traction must be made in a line at right angles to the teeth. If made in a downward direction, the under surface of the tongue will be pressed against the incisor teeth and cause great pain or result in wounding the tongue. The handle of the mirror should be held as for posterior rhinoscopy, except that the reflecting surface of the mirror is to be directed *downward*. The mirror should be passed into the mouth, being held so that the reflecting surface is parallel to the tongue. Care should be taken that the mirror does not touch it, or gagging will be produced. The mirror should finally rest against the soft palate at its junction with the uvula. It is often desirable to steady the hand by resting the fingers on the side of the cheek (Plate I.). If the patient's head is held horizontally, and the handle and shank of the mirror are also horizontal, the back of the tongue and epiglottis will be seen in the mirror.

To examine the larynx the mirror is to be warmed and the tongue protruded and grasped as above described,

PLATE I



Examination of the Larynx.

but the patient's head must be thrown back almost as far as possible. In performing this act the tendency of most patients is to throw the whole body back as well. This would make the examiner's distance from the patient too great, and force him either to bend forward in an awkward, cramped position or to hold the mirror at arm's length—a thing very difficult to do without a trembling of the hand which holds the mirror. This procedure will almost invariably cause the patient to gag. The mirror is to be passed back into the mouth and brought to rest at the junction of the soft palate and the uvula. At first only the epiglottis may be seen. This may be due to several causes—namely, insufficient traction on the tongue, the mirror not placed far enough back in the mouth, the wrong angle of the reflecting surface, or the patient's head allowed to come forward with the traction on the tongue. All these must be carefully guarded against while making the first few examinations. After a little practice they are unconsciously corrected. A single examination should not last over twenty or thirty seconds, as the patient becomes tired, the irritability of the pharynx is increased, and gagging results. In rare cases we find a very long epiglottis, or one where the glosso-epiglottic ligaments are very long and loose. In these cases traction on the tongue does not lift the epiglottis sufficiently to uncover the entrance to the larynx. To examine such cases the physician should be seated at least a head higher than the patient, the mirror should be held against the posterior pharyngeal wall below the uvula, and the reflecting surface of the mirror tilted a little more forward. Where the pharynx is very sensitive and gagging results a small amount of a 2 per cent. solu-

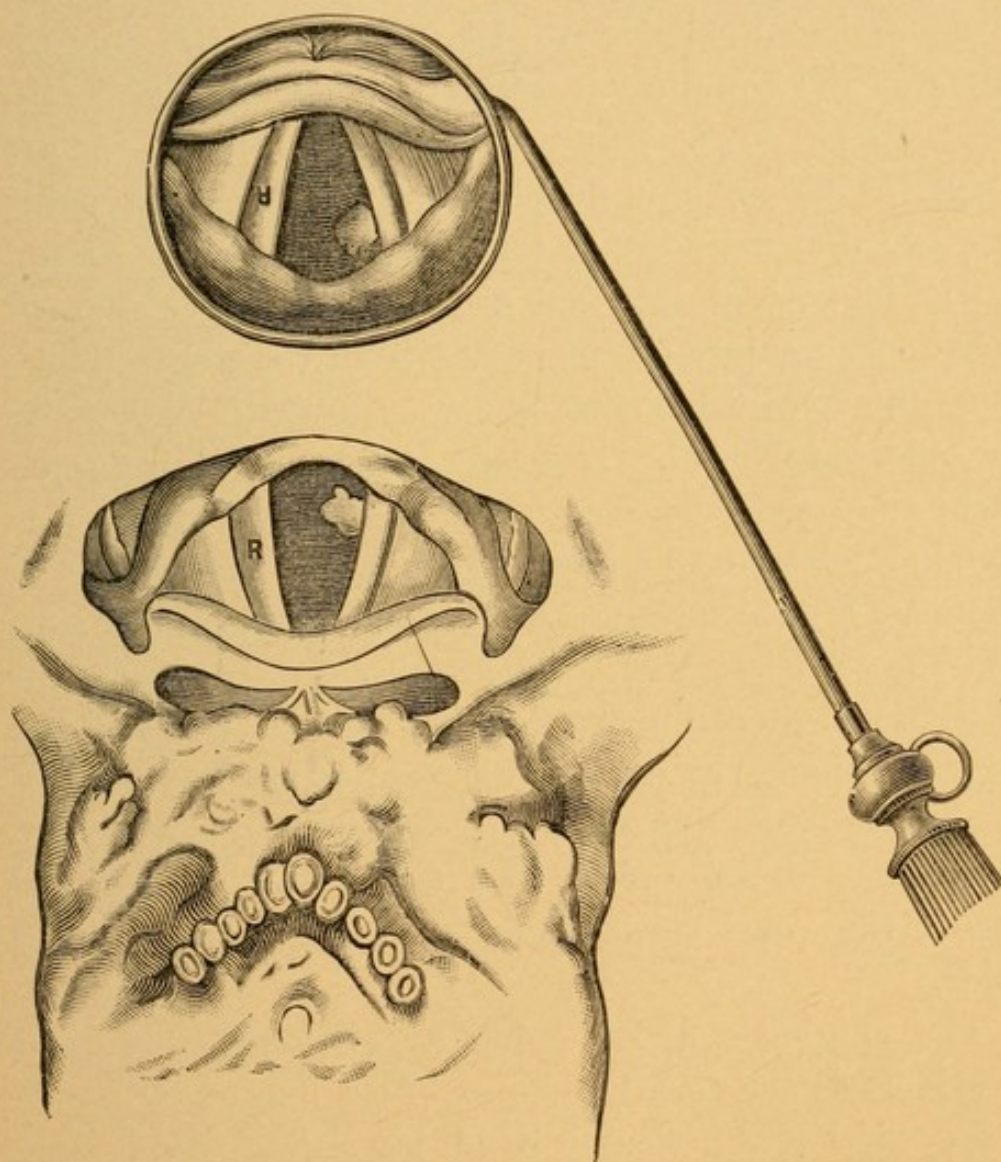
tion of cocaine sprayed upon the soft palate, uvula, and posterior pharyngeal wall usually anesthetizes in three or four minutes these structures sufficiently to permit of examination. As the view of the larynx is often only momentary, it is very necessary that the beginner should become perfectly familiar with the laryngeal image.

In order to make a complete examination of the larynx the appearances of this organ should be noted during quiet respiration (Plate VII., Fig. 1), and during phonation (Plate VII., Fig. 2). During respiration the vocal cords will be seen to be separated as in Plate VII., Fig. 1. With each inspiration the vocal cords will be observed to move slightly toward the median line, while with each expiration they separate slightly. To get a view of the larynx during phonation the patient is instructed to say *e* or *he* while the mirror is *in situ*. The sounding of *a* as in *are* or saying *ha* may give a good view of the cords provided the patient can at the same time control the arching of the tongue. During phonation (Plate VII., Fig. 2) the vocal cords will be seen to be parallel or nearly so; a slight concavity toward the median line frequently leaves the merest chink between their inner margins. The vibration of the cords is often manifested by a flickering of the light reflected from their superior surfaces. We earnestly recommend every beginner to get a larynx from a dead-house, set it up in a box or bottle in the position of the larynx of a person sitting opposite, as one who is to be examined, and then with head-light and laryngeal mirror study the image as seen reflected in the mirror and compare this with the specimen. The relative positions of the structures to each other, and the depth of these within the larynx, can be ascertained in this way better than in

any other. A careful study of Fig. 18 and of Figs. 1 and 2 of Plate VII., will aid materially in interpreting the laryngeal image.

Fig. 18 is intended to represent the back of the tongue, the larynx, and the laryngeal image as seen in a post-

FIG. 18.



Comparison of laryngeal image with specimen. (SCHROETTER.)

mortem specimen. Near the posterior part of the *left* vocal cord is a small tumor. The letter R is written on the *right* vocal cord, so as to appear in the proper

position to one standing in front of the specimen. When the mirror is held so as to get a view of the larynx, it will be noted that the epiglottis which is nearest the observer is highest in the mirror, and that all structures at the *anterior* part of the larynx appear at the *upper* part of the mirror. The structures at the *posterior* part of the larynx appear at the *lower* part of the mirror. In the mirror the anterior parts of the vocal cords seem to touch the epiglottis. If we look down into the specimen larynx, we are surprised to see how deeply situated the vocal cords are, and that they do not touch the epiglottis. Again, it will be noticed that the growth which is on the *left* vocal cord appears on the *right* side in the mirror. The R on the *right* vocal cord appears on the *left* of the mirror, and is inverted. It usually takes a beginner some little time to become accustomed to this inversion as seen in the laryngeal mirror. If now we examine Fig. 1, Plate VII. (which shows the larynx during respiration), and Fig. 2, Plate VII. (which shows the larynx during phonation), we can point out the various parts of the laryngeal image as seen during respiration and phonation while examining a patient. The mucous membrane should be a delicate pink, like that of the inside of the cheek, the vocal cords alone having a shining white color.

The epiglottis, *a*, often has a yellowish tinge, and bloodvessels are usually seen as in the diagrams.

b is the left ventricular band, less being visible during respiration than during phonation.

c is the left vocal cord. During respiration a slight enlargement is often seen near the posterior end, interrupting the slightly concave inner border. In phona-

tion the two cords are almost in apposition, the red line between being the mucous membrane of the trachea.

d shows the elevation marking the site of the cartilages of Wrisberg in the ary-epiglottic folds. These will be observed further from the median line in respiration than in phonation.

e shows the elevation over the cartilage of Santorini situated on top of the arytenoid cartilage. It will also be noted that the position of this elevation is further from the median line in respiration than in phonation.

f is the interarytenoid space—wide during respiration, narrowed almost to obliteration in phonation. With the head thrown well back and the mirror properly tilted, one usually sees some of the posterior wall of the larynx at this place. Fig. 5, Plate VII., shows a tubercular infiltration on the posterior wall above the vocal cords.

g shows the transverse cartilaginous rings of the trachea. The rings normally have a yellowish tinge, while the membranous portions between them are bright or dark red. The number of rings visible will depend on the shape and position of the trachea, the position of the patient's head, and the tilt of the laryngeal mirror. These may be so adjusted as frequently to see the bifurcation of the trachea. The rings in the *lower* part of the image are those furthest down the trachea. During phonation the approximation of the vocal cords prevents a view of the trachea.

h shows the pyriform fossa—a groove running external to the larynx and leading into the laryngopharynx. It is important as being the lodging place of foreign bodies.

k shows the position of the right ventricle of the

larynx. It is seen usually much better during respiration than in phonation. A better view may be obtained if the head be tilted laterally to the side on which we wish to view the ventricle.

In treating patients suffering from diseases of the upper respiratory tract it will be found very convenient to keep a record of the history, examination, and treatment. The history should be taken first, and then a systematic examination of all parts of the tract made. While the order of making this examination differs with various physicians, that which we recommend is as follows:

1. Examination of the exterior of the nose.
2. Anterior rhinoscopy of each nasal cavity.
3. Examination of the teeth, gums, tongue, oropharynx, and tonsils.
4. Examination of the base of the tongue, then tilting the head backward and examination of the larynx and laryngopharynx.
5. Posterior rhinoscopy.

The posterior nares are usually the most difficult to be examined, and if examined before the larynx gagging may be induced. This always produces a congestion of the laryngeal mucous membrane, and may mislead one if he examines the larynx after gagging has taken place.

CHAPTER IV.

ANTISEPSIS IN OPERATIONS UPON THE UPPER RESPIRATORY TRACT.

A. THE PASSAGES.

WE do not possess at the present time any antiseptic that can safely be employed to sterilize the nasal passages or the nasopharynx. Solutions of bichloride of mercury, or of carbolic acid, of sufficient strength to kill bacteria, would excite a local inflammation of the mucous membrane of these regions. It is always desirable, however, to diminish the number of bacteria found in these regions by thoroughly douching or spraying the nose and nasopharynx with some bland, non-irritating solution.

One of the best for this purpose is that made by dissolving one normal saline infusion tablet (formula¹ of Dr. G. R. Fowler) in a pint of water that has been sterilized by a half-hour's boiling.

Another excellent preparation is Dobell's solution :

R.—Ac. carbolic	gr. iv.
Sod. bicarb.,						
Sod. borat.	āā	gr. xl.
Glycerini	℥j.
Aquæ	q. s. ad	℥ iv.—M.

¹ Each tablet contains :

R.—Sodii chloridi	1 $\frac{2}{3}$ gr.
Sodii sulphatis	1 "
Sodii carbonatis	$\frac{2}{3}$ "
Sodii phosphatis	$\frac{1}{3}$ "
Magnesii phosphatis	1 $\frac{2}{3}$ "

Where it is desired to cleanse the nose, either of these solutions should be employed in the douche bottle (Fig. 31), or sprayed into first one and then the other cavity with an atomizer, such as the Century (Fig. 125), giving a generous stream. For his own use the author prefers a syringe for cleansing the nares. The aseptic syringe (Fig. 19), holding about two ounces, should be sterilized by boiling before using. If the precautions of contracting the nasal mucosa with a 1 per cent. solution of cocain before irrigating the nares, or irrigating first through the more obstructed naris, that the fluid may return freely through the opposite unobstructed side, and of never using more force than necessary to barely cause a gentle stream to return, the danger of aural complications is practically eliminated.

The cleansing of the nasopharynx is best accomplished by means of the hard rubber post-nasal syringe (Fig. 73). Where operations are to be done in the mouth this cavity may be sprayed with a solution of bichloride of mercury (1 : 3000), provided the patient is careful to expectorate the excess of fluid. The mucous membrane of the mouth is far more tolerant of mercurial solutions than is that of the nose or nasopharynx.

The cleansing of the larynx is a tedious process, and can only be accomplished by means of the compressed air apparatus, using a spray with a down-curved tip—either the Davidson form (Fig. 113) or that of Sass.

The normal saline tablet solution or that of Dobell should be used.

B. THE INSTRUMENTS.

All instruments used, either for examining the air passages or for operations in these regions, should be rendered as sterile as those used in an operation upon any other part of the body.

Those which are of metal should be made aseptic by boiling.

Laryngeal mirrors, if boiled, are soon destroyed. When one has been used on a syphilitic or tuberculous patient it should be boiled before being used on another patient. A far better plan is to have each patient who has a primary or secondary syphilitic lesion, or one suffering from tuberculosis, furnish his own mirrors, which are to be kept separate in jars containing a solution of carbolic acid (1 : 20). A special set of tongue depressors, nasal specula, and applicators should be kept in a separate compartment for use in cases of syphilis, and another set for tubercular patients.

The examining physician should have a small bowl containing a solution of carbolic acid (1 : 100), into which all instruments should be dipped and wiped dry on a clean towel before being employed in examination. After using an instrument it should be placed in a *second* bowl containing a solution of carbolic acid (1 : 20).

It will not do to use the instrument again until it has been rinsed in the carbolic solution (1 : 100), as some of the stronger solution may not be wiped off and thus burn the patient.

Fresh solutions must be prepared for each patient examined. Should the ordinary examining instruments be employed on a syphilitic or a tubercular patient, then the mirrors must be placed with those of the infected

class, and the metal instruments sterilized by boiling before again being used.

The safest plan is to lay aside all instruments that have been used each day, and sterilize them before beginning the following day's work.

All instruments which are expected to be employed in any cutting operation on the upper respiratory tract must be sterilized just prior to their use.

CHAPTER V.

NASAL OBSTRUCTION.

As the conditions producing obstruction to nasal respiration are quite numerous, and the symptoms resulting from all forms so similar, it is deemed advisable under this heading to enumerate the various causes of nasal obstruction and to mention the symptoms that may result.

Etiology. Nasal obstruction may be due to pathological processes (*a*) in the nose, (*b*) in the nasopharynx, and (*c*) in the oropharynx.

(*a*) The pathological processes in the nose causing it are :

Acute rhinitis.

Purulent rhinitis.

Chronic hypertrophic rhinitis.

Atrophic rhinitis (where there is a thick crust formation).

Membranous rhinitis.

Nasal diphtheria.

Vasomotor rhinitis (hay fever).

Deviations of the septum.

Large spurs on the septum.

Atresia (post-operative or congenital).

Hematoma of the septum.

Abscess of the septum.

Syphilis.

Tuberculosis.

Foreign bodies in the nose.

Rhinoliths.

Non-malignant growths of all kinds.

Malignant growths.

(b) The pathological processes in the nasopharynx producing it are :

Adenoids.

Non-malignant growths.

Malignant growths.

Adhesions of the soft palate to the posterior pharyngeal wall.

Foreign bodies.

(c) It is very seldom that diseases of the oropharynx alone cause nasal obstruction. It may, however, be produced by :

Retropharyngeal abscess.

Double peritonsillar abscess (quinsy).

Enormously hypertrophied tonsils.

Of these conditions some are acute, come on suddenly, the obstruction and other symptoms lasting but a short time, and may disappear without treatment; others begin gradually, almost imperceptibly, are steadily progressive, and have no tendency to spontaneous cure. The latter are remedied only by proper treatment, medical and surgical.

Symptoms. The symptoms of this condition may be classified as those referable to the nose proper and those affecting the other portions of the body. The nasal symptoms are a feeling of fulness, sometimes accompanied by a sense of pain across the bridge of the nose. This is more apt to be the case when the obstruction is in the region of the middle and superior meatus. If obstruction is complete, there is

absence of the sense of smell; if partial, this sense may be diminished. Redness and swelling of the tip of the nose, such as are seen in alcoholic subjects, cause these patients great annoyance, especially if they are total abstainers from alcoholic beverages. Mucus collects within the nasal cavity and cannot be blown out, owing to the insufficient blast of air. Bacteria gain access to this mucus and produce fermentative changes that result in an odor slight or fetid, according to the variety of the bacteria. In some cases the mucus becomes very irritating, and excoriates the skin around the nostril and on the upper lip. Of the symptoms referable to other portions of the body, mouth-breathing, with its attendant ill effects, is one of the most prominent. In mild cases the mouth-breathing may occur only at night, owing to the greater engorgement of the tissues and consequently increased obstruction while lying down. During the day, except while exercising freely, as in going up stairs, walking, running, bicycle riding, etc., these patients breathe in a normal manner through the nose. In marked obstruction mouth-breathing persists day and night. The effects of mouth-breathing are a dry, parched condition of the mouth, tongue, and lips, most marked on awakening in the morning, snoring at night, restless sleep, frequent attacks of sore throat, laryngitis, bronchitis, a hacking cough, thick, coated tongue, bad taste in the mouth, and some impairment of the sense of taste. The voice is more or less hoarse, and has a peculiar nasal twang. There is greater or less difficulty in properly pronouncing "m" and "n." The pharyngeal and laryngeal mucus becomes dry and tenacious, having been robbed of its moisture by the inspired air, and prolonged efforts

at coughing frequently result in gagging and vomiting before the mucus can be dislodged. In children the shape of the face is altered, becoming long and narrow, the palate is very much arched, the permanent teeth come in irregularly, often overlapping each other, and the upper incisors and canines frequently extend much in front of the lower ones. The tossing of the children at night prevents their obtaining the rest so necessary for their growth and development, and they are consequently often undersized and seldom robust. The ear complications with nasal obstruction are tinnitus, impairment of hearing, earache, and acute or chronic otitis media. The eye conditions met with are lachrymation, due to obstruction to the nasal duct, dacryocystitis, conjunctivitis, keratitis, and glaucoma. Certain symptoms are observed, called by the general term *aproxia*—namely, mental depression, disinclination to work, and loss of energy. These effects are more marked in children, and they are usually considered dull and stupid. In school they are one or more classes below the average child of their age. Adults in whom there is a slight odor to the discharge have a tendency to be melancholic and disinclined to share in the social enjoyments of life. Various reflex neuroses, among which may be mentioned sneezing, hay fever, asthma, stammering, stuttering, chorea, epilepsy, and nocturnal incontinence of urine, are found when nasal obstruction is present.

It is not to be understood that all of these numerous symptoms occur in every case. Some cases show many of these symptoms, others only a few. They are placed together here to prevent repetition in the description of many of the diseases of the nose.

Examination. A careful examination of the nose and nasopharynx should *always* be made before any treatment for this condition is advised. It is only by accurately determining the cause of the stenosis that one can expect to remedy the condition.

Treatment. The treatment of the different varieties of nasal obstruction will be found under the articles devoted to each of the diseases producing obstruction.

CHAPTER VI.

DISEASES OF THE NOSE.

ACUTE RHINITIS.

AN acute inflammation of the mucous membrane of the nose. A cold in the head.

Etiology. Exposure to cold and dampness, and especially getting the feet wet while the system is run down or debilitated from other diseases, are the commonest causes of this condition. At times the disease is so prevalent as to lead us to believe that there is some infection in the atmosphere producing it. It is apparently at times even contagious. It frequently ushers in an attack of bronchitis, laryngitis, and the acute infectious diseases, such as influenza, measles, typhoid fever, small-pox, and whooping-cough. The inhalation of irritating chemical fumes, such as those of iodine, chlorine, bromine, or hydrochloric acid, will produce it. Where persistent and frequent colds in the head are seen in children one should always investigate the nasopharynx, with the probability of finding there hypertrophy of the lymphoid tissue (adenoids).

Pathology. There are an increase in the size of the bloodvessels and an infiltration of lymphocytes in the surrounding tissues. At times the congestion is so great as to cause rupture of the capillaries.

Symptoms. These usually begin with an attack of sneezing, feeling of stuffiness in the head, and a pecu-

liar dry and irritable condition of the mucous membrane of the nose. In a few hours there is a profuse watery discharge. This at times may be irritating, and with the frequent use of the handkerchief produces a redness and even an excoriation at the entrance of the nose and the adjacent portions of the lips. Frontal headache is quite common. There is usually more or less abolition of the senses of smell and taste; there may be loss of appetite and a slight rise in temperature. If the inflammation persists for many days, there may be a feeling of stuffiness in the ears. The voice has a peculiar nasal twang. During the first few days the nose is often so completely occluded as to necessitate breathing entirely through the mouth. This results in a very dry condition of the throat, and frequently leads to secondary pharyngitis and laryngitis. After four or five days the discharge becomes less watery and thicker, like the white of an egg, and later mucopurulent. In nursing children, where the nose is completely blocked there is considerable difficulty in their being able to take nourishment properly, having to stop and catch their breath frequently during this act. The disease lasts from five or six days to three weeks.

Complications. The common complications of this affection are extension of inflammation to the frontal, maxillary, and ethmoidal sinuses, extension through the Eustachian tubes to the middle ear, and extension into the pharynx, larynx, trachea, and bronchi. These complications are more apt to take place in those forms of acute rhinitis that are associated with influenza, although they may occur with any attack.

Examination. Examining the nose, it will be found to be nearly if not quite occluded, the red, swollen turbinal tissues touching the floor and the septum as

well. In the meati will be found more or less secretion of a character depending upon the stage of the disease. Not infrequently small hemorrhagic extravasations can be seen on or under the epithelium.

Treatment. Many people do nothing for a cold in the head, the disease being ordinarily self-limiting. Other and more severe cases may demand treatment at the hands of a physician. If seen early, a hot mustard foot bath, followed by hot lemonade and ten grains of Dover's powder, the patient being put to bed, and well covered up so as to induce free perspiration, will often ameliorate the symptoms very markedly. If seen on the second or third day, the above treatment is not so efficacious. We would then advise administering an eighth of a grain of extract of belladonna, or one one-hundred and twentieth of a grain of atropia every two hours until the coryza subsides, after which the drug should be given every five hours for two days. To counteract the irritating effects of the mucus upon the skin of the nose and lips, these should be protected by some bland ointment, such as either simple vaseline or the officinal ointment of the yellow oxide of mercury diluted with three parts of vaseline. At one time a weak solution of cocaine was used to contract the swollen and congested turbinal tissues. This, however, is not to be advised—first, because of the danger of forming the cocaine habit, and, secondly, because we have other and safer remedies that will do the work of cocaine.

Frye's atomizer is the one we employ for this purpose, as it ejects a fine spray that reaches the more remotely diseased areas. The effect of this solution is to contract the tissues as much if not more than cocaine would. The spraying may have to be repeated as often as every two or three hours. The various preparations,

such as adrenalin, suprarenalin, and adrephrin, containing the active principle of the suprarenal gland, are extensively used to contract the blood-vessels and, in consequence, to temporarily diminish secretion. The stock solution 1 to 1000 is unnecessarily strong. When diluted with nine or more parts of normal saline solution, the effect is apparently equally as good. The color of the solution when thus diluted and exposed to light and air may become pink, but the therapeutic action is still retained. When it turns brown, its specific action is lost. Either from personal idiosyncrasy or on account of the peculiar effect produced by the decomposed drug, some patients cannot use these preparations without developing symptoms analogous to hay-fever, which may last from a few hours to a week. For such patients the use of these preparations is contraindicated. We frequently prescribe an oily spray, containing menthol, camphor, and eucalyptol, varying somewhat the strength of the menthol according to the severity of the case—the greater the congestion, the more menthol. The following prescription may be taken as a sample, and the ingredients increased or diminished slightly to suit the case in hand:

R.—Menthol	gr. xxx.
Camphor	gr. xx.
Eucalyptol	℥ xx.
Ol. rosæ	℥ ij.
Benzoinol	q. s.	ad	℥ ij.

M. et sig.—Use in albolene atomizer.

This spray, if used immediately after using that of the suprarenal extract, will tend to keep the nose free and lessen the discharge. We are not in favor of using a watery spray for acute rhinitis, unless it may be at the very last of the attack, at which time the secretion

is very thick or mucopurulent; even then it should always be followed with the menthol albolene spray.

Many people who are subject to frequent attacks of colds in the head may overcome this tendency by proper hygienic measures. We earnestly advocate that these individuals become accustomed to cold bathing each morning on rising. At first it will be difficult for these persons to jump into a cold bath, and for such we advocate the sponging of a portion of the body at a time, beginning with the face, neck, and chest, then drying this portion, then sponging the abdomen and thighs, drying, and finally the legs and feet. It is quite necessary that a coarse towel be employed and considerable friction used to stimulate the capillary circulation of the skin. The water should be used as cold as possible, yet not so cold but that after the rubbing a healthy glow is felt. If after the bath the patient feels exhausted, and reaction does not take place, the water should not be used quite so cold at first. Attention also to the character and thickness of the underwear is important. These patients should wear flannel undergarments which should not be of the heaviest grade. On going out-of-doors they should put on a sufficiently heavy coat to keep them warm, and this should be removed at once upon entering a heated room. If the undergarments are too heavy, profuse perspiration will ensue, and on slight exposure to a draught they will be very apt to take cold. Persons whose occupations are of a sedentary character are more frequently afflicted with colds. To such people it is quite as necessary to prescribe the regular and systematic taking of exercise in order to prevent catching cold, as it is to prescribe medicine after they have taken it. With a little tact one can readily find out what form of exercise is likely

to be most pleasing to each patient, and prescribe that. Bicycling, golf, gymnasium work, fencing, and tennis are some of the modes of exercise most apt to be acceptable, and where the patient's circumstances will not admit of these, good, brisk walking may be as good as any.

PURULENT RHINITIS.

A chronic inflammation of the mucous membrane of the nose accompanied by the discharge of pus.

Etiology. The disease occurs usually in young children soon after birth; the common cause is infection of the nasal mucosa by the vaginal secretions, especially where the mother has suffered from recent gonorrhœa. Children born of syphilitic parents frequently suffer from snuffles and purulent rhinitis. In glanders the discharge is purulent. In the adult there is often a purulent discharge from the nose; if gonorrhœa and glanders can be excluded, the cause should be searched for in syphilitic necroses, tuberculosis, rhinoliths, malignant growths, or diseases of the accessory sinuses.


Pathology. There are an intense hyperemia of the nasal mucous membrane and a rapid proliferation and exfoliation of cells.

Symptoms. The symptoms are those of nasal obstruction (*q. v.*), with a profuse, thick, purulent discharge. A child is able to nurse only with difficulty, and emaciation is common.

Examination. This in children is difficult on account of the small size of the nasal cavity, and in doubtful cases the child should be given a whiff or two of chloroform, in order to quiet it and allow the proper examination. The pus should always be examined bacteriologically.

Differential Diagnosis. In children after the administration of chloroform the presence of a foreign body

FIG. 19.



Aseptic syringe.

can easily be eliminated. If gonococci are found, the diagnosis is plain. In doubtful syphilitic cases the history and other manifestations of this disease assist in making a diagnosis. Adenoids frequently produce a mucopurulent discharge. These may be eliminated by examining the nasopharynx. In adults a purulent discharge should lead to a thorough investigation for the diseases mentioned in the etiology.

Prognosis. The disease runs a protracted course, and may result in atrophy of the mucous membrane.

Treatment. The nose should be kept scrupulously clean by syringing with normal saline solution from two to four times daily, according to the amount of the discharge. The aseptic syringe (Fig. 19), of a capacity of two ounces, best serves the purpose. Very little force should be used. Care should be taken that the child is kept well nourished. If syphilis is suspected, one or two grains of gray powder should be given three times a day.

HYPERTROPHIC RHINITIS.

A chronic inflammation affecting the mucous membrane of the nose accompanied by an increase in the tissues.

Etiology. Frequent attacks of acute rhinitis, occupations requiring living or working in a dusty atmosphere, the presence of spurs or deviations of the septum, narrowing of the nostrils, with consequent difficulty of respiration, are the more common causes. It also occurs more frequently in anemic patients, and not infrequently in those having a rheumatic or gouty diathesis.

Pathology. The microscopical changes vary with the length of time the process has existed. At first there is usually only the dilatation of the bloodvessels with a round-cell infiltration into the connective tissue. Later the bloodvessels are markedly dilated, their walls thickened, and the interstitial tissue considerably increased. In some forms the glandular tissue is also increased. Occasionally we find the connective tissue increase more marked in certain areas than in others; the posterior end of the inferior turbinate is very liable to show this condition. If the contraction is more marked in some places than in others, then the mucous membrane has an uneven, rugous appearance.

Symptoms. The three most common symptoms are nasal obstruction, increased secretion, and a slight odor to the breath, which, for lack of a better name, may be called a catarrhal odor. The nasal obstruction, where an accurate history can be obtained, will be found to have gradually increased in amount, at first involving only one side of the nose at a time, and usually being more marked at night and upon that side of the head upon which the patient is lying.

As the disease extends the nasal obstruction becomes greater in amount, and in severe cases patients are never free from it. Then mouth-breathing is the rule, especially at night, the mouth being very dry in the morn-

ing. The voice has a nasal twang, smell and taste are impaired, and the appetite is often capricious. The effect of the nasal obstruction is to produce a congestion in the nasopharynx, and an extension of inflammation along the Eustachian tube, and often the first symptom which causes the patient to consult a physician is the fact that he is somewhat hard of hearing. If the obstruction happens to be in the region of the middle turbinate, frontal headache and inability to keep one's attention upon work—aproxia—are common symptoms. Redness and swelling of the tip of the nose are often seen. The increased secretion is usually removed with some difficulty, being of a thick and tenacious character. The irregular outline of the mucous membrane, and the insufficient blast of air during the act of blowing the nose, contribute to make the use of the handkerchief unsatisfactory. The presence of bacteria induces fermentation in the thickened secretion, thus producing the catarrhal odor. Certain irritating substances are also developed by the fermentation of the mucus, which are factors in the further increase of the hypertrophy. If the hypertrophy is of such an extent that any two mucous surfaces of the nose come in contact, sneezing and other reflex neuroses are frequently very annoying symptoms.

Examination. On examining the nose in a suspected case of hypertrophic rhinitis we should always proceed with the anterior nares first. On account of the swelling we often find that our view of the tissues is limited. Those which are within view should be carefully examined with a probe. We should next proceed to examine the nasopharynx to determine the condition of the posterior portion of the turbinal

tissues. Having done this, spray the nose with a 2 per cent. solution of cocaine (see page 49), and after waiting three minutes again observe the parts both anteriorly and posteriorly. As a result of pathological processes the examinations will reveal various conditions which for sake of rational treatment may be indicated as follows:

I. A bright pinkish mucous membrane, which, when touched with the probe, is found to be very spongy, but the impression made by the probe disappears almost immediately upon withdrawing the latter. After the use of cocaine the nasal cavity is seen to be very roomy, the swelling having entirely disappeared, and with it relief from the nasal obstruction. This is usually an early stage of the hypertrophy before very much tissue increase has taken place.

II. A rather pale pink mucous membrane, which, before cocainization, has a firmer feel to the probe; pitting takes place, which may last from several seconds to as many minutes before the rounded form of the tissues is regained. Only partial contraction results from the use of the cocaine spray, and more or less nasal obstruction still remains.

III. After cocainization the lower border of the inferior turbinate may be found touching the floor of the nose. Examined with a probe, this lower border may be moved laterally very freely. Mucus is usually found entrapped between this pendulous border and the outer wall of the nose. The mucus is apt to remain there in spite of very vigorous blowing of the nose.

IV. Posterior rhinoscopy frequently shows a large rounded mass (Fig. 20), with a surface pale, uneven,

Rx
1 cleansing
alkaline
muc
spray
2 Cocainization.

1 Cocainization
2 Cold
Snare

1 Cold
Snare

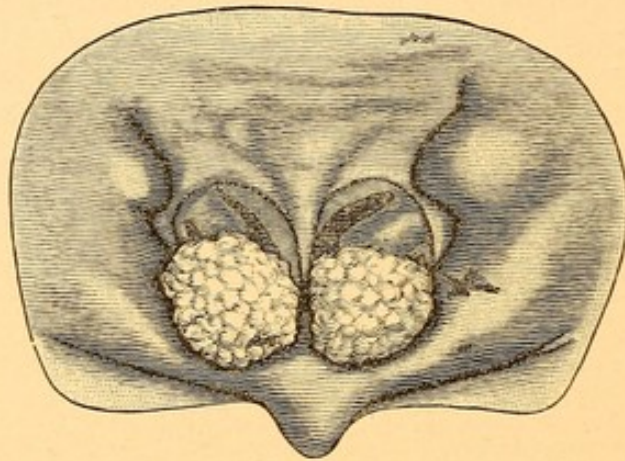
*1 Cold Snare
or
Galvano-
Caustic
Snare*

and mulberry-like, occupying the position of the posterior end of the inferior turbinate. Occasionally, instead of being pale and uneven, this mass is reddish and perfectly smooth when the vessels are very much distended with blood.

1 Cold Snare

V. A thickened, pendulous mucous membrane on the under surface of the middle turbinate. The probe will show this to be movable, but with a very broad

FIG. 20.



Hypertrophy of the posterior ends of the inferior turbinates.

attachment running antero-posteriorly, so that it should not be mistaken for a polyp.

*1 Cold Snare
or
Caustic
ization.*

VI. A spongy thickening of the septum at the junction of the cartilaginous portion with the vomer (see Fig. 1), and nearly opposite the anterior end of the middle turbinate, with which it is often in contact.

*1 Caustic
ization*

VII. An oval pale swelling on either side of the posterior margin of the septum, usually seen best by posterior rhinoscopy. This swelling causes a bulging of the otherwise almost straight contour of the septum as seen posteriorly, and is situated about midway between the top and bottom of the septum.

It not infrequently happens that two or more of

these conditions are found in the same patient, or that the condition in the nares of one side is quite different from that in the other.

Differential Diagnosis. After the use of the cocaine spray and a careful examination of the various structures in the nose with a probe there should be no difficulty in distinguishing these various manifestations of hypertrophic rhinitis from such conditions as deviations of the septum, spurs, foreign bodies, polypi, and other benign or malignant tumors. *The cause of most mistakes in diagnosis is the failure to use the probe.*

Prognosis. Most cases of hypertrophic rhinitis respond well to treatment. It is not always easy to change the patient's environment and his occupation. Those factors which originally contributed to the disease, if still active, may cause a return of the condition in a few months or years.

Treatment. We wish to caution the inexperienced against too active surgical interference. Many think that if a little cauterization or snaring gives a moderate amount of relief, more might be better. The result is a destruction of too much of the mucous membrane, thus leaving the patient with a condition of freedom so far as breathing is concerned, but with a dryness of the nose and throat very distressing and extremely difficult if not impossible to overcome. When seen in the early stage, presenting the appearances as described under variety I., page 87, cleansing sprays are first to be resorted to. The spray should be slightly alkaline, and contain sodium chloride of about the strength of a normal saline solution (0.6 per cent.). Most saline sprays contain too large proportions of sodium chloride. A very good cleansing solution is :

R.—Sodii bicarbonatis gr. vj.
 Sodii chloridi gr. iij.
 Aquæ $\bar{\text{z}}$ j.

M. Sig.—Use as spray in atomizer.

Where patients prefer to have a pleasant odor to the spray a teaspoonful of listerine, borolyptol, or any of the other numerous preparations found in the market may be added. In prescribing any watery spray one should always caution the patient as to the necessity of remaining in-doors for at least half an hour after using it. The effect of the spray is to wash the mucus from the membrane, and until a sufficient amount of mucus, which is nature's protection to the delicate epithelium, can be re-formed, exposure to cold and dust is very apt to produce sufficient irritation to cause vasomotor dilatation, and the swelling of the mucous membrane will be more marked than before the use of the spray. If the watery spray be followed by an oily one, the patient may then go out-of-doors immediately. As an oily spray for this purpose we would prescribe :

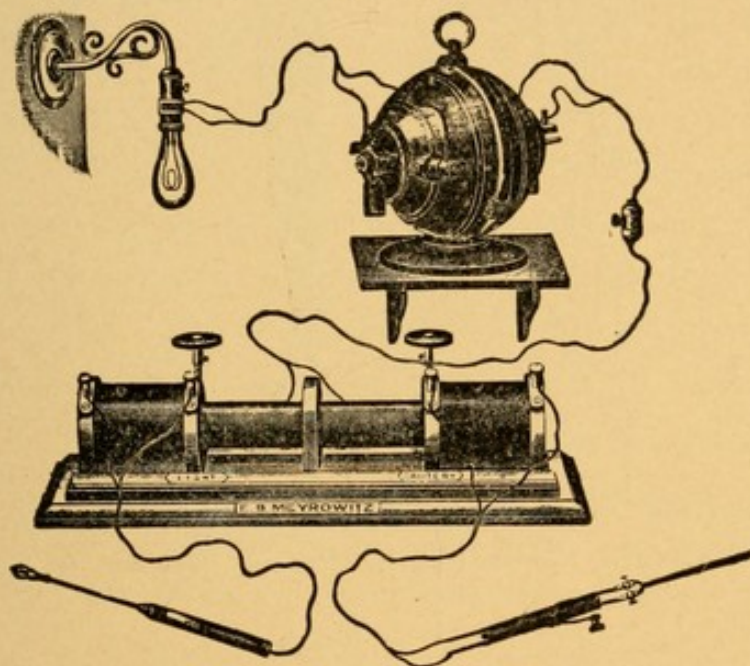
R.—Menthol gr. xl.
 Camphor gr. xv.
 Eucalyptol m xxx.
 Ol. pini pumilionis m xv.
 Benzoinol q. s. ad $\bar{\text{z}}$ ij.

M. Sig.—Use in albolene atomizer.

Where these, after thorough trial, do not seem completely to relieve the swelling, we advise light cauterization along the middle of the internal surface of the inferior turbinate with one of the following cauterants—the galvano-cautery, trichloracetic acid, or chromic acid. We value them in the order mentioned. The

source of electricity for galvano-cauterization may be a storage battery, cells of the Leclanché type, or, preferably, where street current is obtainable in the office, one of the several forms of adapters by which the street current may be utilized for light, cautery, and motor purposes. Fig. 21 illustrates an adapter by

FIG. 21.



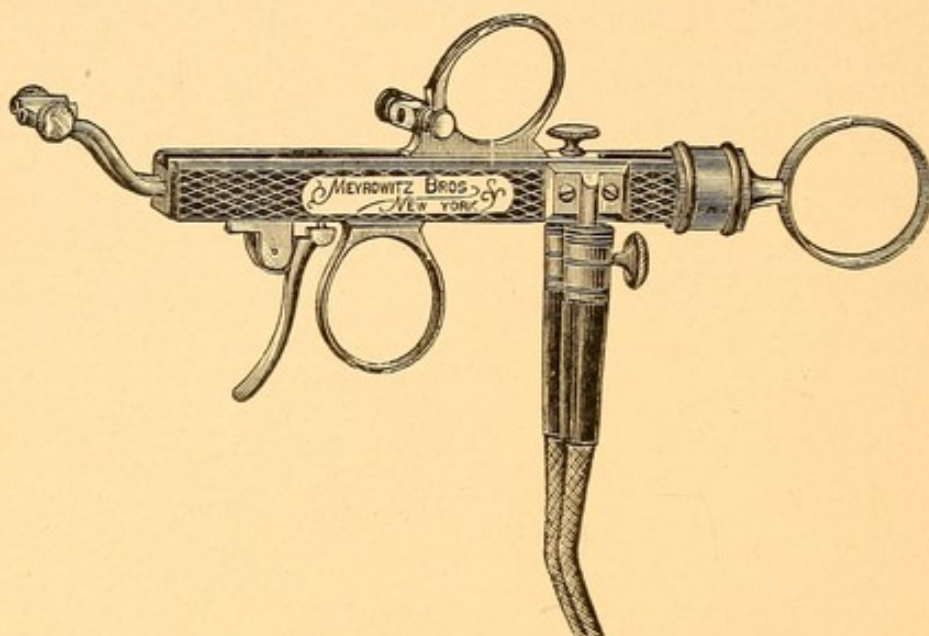
Transformer for adapting the street current (constant) for both cautery and transilluminating work.

means of which the constant current may be employed both for cauterization and heating small lamp for examining the air-passages and ear, or transilluminating the accessory sinuses of the nose. The same instrument without the attachment of the motor may be employed with the alternating street current. The Schech cautery handle (Fig. 22) is the most practical and convenient one for holding the electrodes. It is considerably more expensive, however, than the smaller handle shown in Fig. 23.

In selecting an electrode (Fig. 24) for this purpose

the points should be made of platinum-iridium, and should be so rigid that considerable pressure can be

FIG. 22.



Schech cautery handle.

made against the tissues without bending the point of the electrode. Platinum alone, unless very thick,

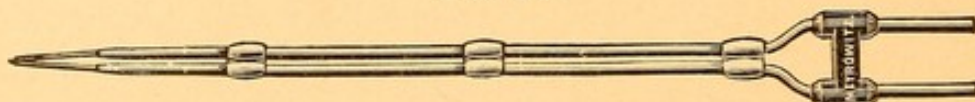
FIG. 23.



Cautery handle and electrode.

which is undesirable, does not give a sufficiently rigid point. When the current is turned on it should be regu-

FIG. 24.



Electrode.

lated so as to heat the electrode not more than a cherry-red color. The method of cauterization is as follows :

Spray the nose with a 2 per cent. solution of cocaine. After waiting three minutes for this to take effect, tease out a small piece of cotton so that it will form an extremely thin layer, the breadth of which shall be that of the inferior turbinate, and the length that of the surface to be cauterized. Dip it in a 10 per cent. solution of cocaine and squeeze it between the thumb and finger until the cotton is so pressed that the solution will not drip. Carry this into the nose on a cotton applicator (Fig. 11), so that it will rest against the inferior turbinate. After waiting five minutes the surface will be found to be thoroughly insensitive to the pain that otherwise would result from the cauterization. Wipe the surface dry with a pledget of cotton and proceed to use the galvano-cautery, *burning only in one straight line antero-posteriorly*. The cauterized surface will have a grayish-white appearance, and its width, if the electrode is of the proper size, and used so that but *one blade* of the electrode touches the tissue at one time, will not be more than that of the head of a small-sized pin. Some advocate smearing the cauterized surface with vaseline carried on a cotton-wound applicator.

To cauterize with trichloroacetic acid: This acid should be in crystallized form and be kept in a glass-stoppered bottle, as the acid is very prone to deliquesce. A piece of copper wire, six inches long, the diameter of a pin's head, should be slightly flattened for about an inch at one end. A small crystal of trichloroacetic acid (half the size of a grain of rice) is placed upon the flattened end of the copper probe. The probe is then passed through the flame of an alcohol lamp once or twice until the crystal is only *partially* melted. If

then allowed to cool, the acid will recrystallize and become firmly adherent to the copper. Any of the acid not recrystallizing should be carefully wiped off with a piece of absorbent cotton, and in so doing one can find whether the crystal is adherent to the copper or not; if not, it must be again melted until it becomes adherent. If heated too much, the entire crystal becomes liquefied and recrystallization may not take place. The tissues are to be cocainized, as for the galvano-cautery, and carefully wiped dry. One should have a small glass containing a strong solution of bicarbonate of sodium, in which should be placed a cotton-wound applicator. The copper wire, with the crystal surface toward the turbinal tissue, should then be introduced into the nose, the nostril being dilated with the nasal speculum, and a linear mark made along the turbinal tissue, as in the case of galvano-cauterization. Wherever the acid touches the tissue a white eschar results. If there is any moisture upon the turbinal tissue, the acid will spread over a greater surface than may be desirable, and to avoid this spreading the nasal cavity should be immediately swabbed out with the cotton applicator, which had been placed in the solution of sodium bicarbonate. Cauterization with trichloroacetic acid, while it will give excellent results if properly applied, is very apt to cauterize a greater surface than may be desirable through its tendency to spread and its inability to be controlled as accurately as the galvano-cautery.

To use chromic acid as a cauterant the following method will be found very convenient: An ordinary nasal applicator is heated in the flame of an alcohol lamp until nearly red hot. It should then be dipped

into a bottle containing crystals of chromic acid. (This bottle should be well stoppered, as the salt is also deliquescent.) A few crystals will be found to adhere and be fused upon it. To insure a well-rounded bead, again pass the applicator once or twice through the alcohol flame until the crystals are melted; then allow the mass to cool. Having prepared the surface as for cauterization with trichloroacetic acid, proceed as with that acid, being careful to wash off the excess with the bicarbonate of sodium solution. In my experience the use of chromic acid has been followed more often by reflex neuralgias extending to the teeth, the eye, temporal region, and even to the ear, than either of the other two forms of cauterization.

The after-treatment in these cases is merely one of cleanliness. If seen the day after cauterization, a thick, grayish-white eschar will be found on the cauterized area; the turbinal tissues may be swollen considerably, even to a greater degree than before cauterization.

If care has been taken not to touch any portion of the opposite nasal mucous membrane with the cautery, the slough will come away in from six to ten days. In a few days more the cicatricial tissue resulting will have so contracted as to leave the nose free. Should the cautery have touched the mucous membrane of the septum as well as that of the inferior turbinate adjacent, then, unless great care is taken during the week or ten days during which healing is going on, an adhesion or synechia is apt to occur between the two. To prevent such adhesions a small pledget of cotton should be inserted between the two cauterized surfaces and renewed daily, after cleansing the parts by spraying the nose with the salt and soda solution.

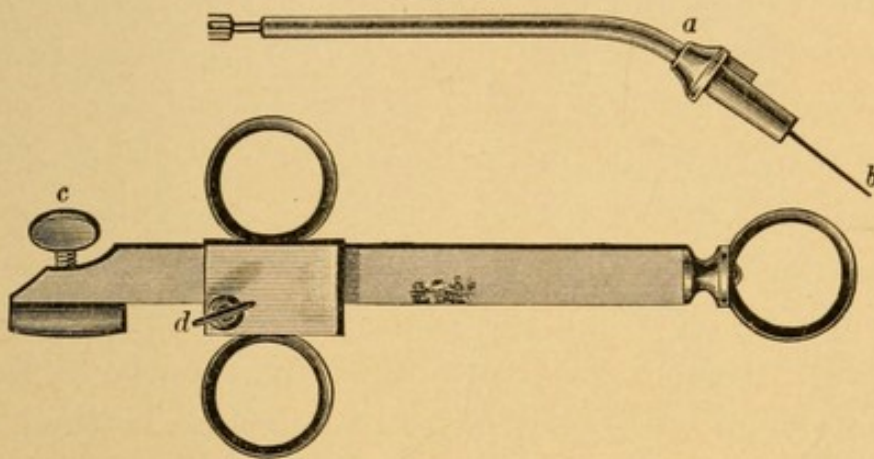
Where the condition is such as described under variety II., cauterization alone with any of the methods described is sometimes disappointing in its results unless the cauterization is made very deep. This can be done only with the galvano-cautery at one sitting, in which the groove that may be made is often an eighth of an inch in depth. The cauterization in these cases, to be effective, should involve the entire substance of the mucous membrane down to the bone. Where either acid is used a single cauterization seldom involves such a depth of the mucous membrane, and after healing has taken place a second application may be necessary, following accurately in the line of the first cauterization. Parts that project very prominently in spite of cauterization, and still produce nasal obstruction, are best removed by means of the cold snare.

The instrument we prefer for this purpose is that of Schroetter, shown in Fig. 25. It consists of a canula, *a*, into which slides a stylet, *b*, having two perforations at one end, through which the wire may be threaded. The canula with the contained stylet is clamped at *c*, the stylet, *b*, being clamped with the set-screw, *d*. As the sliding bar is pulled toward the ring at the end of the handle the stylet is drawn into the canula and the loop of wire made smaller until it disappears entirely within.

To use the instrument, the canula and stylet are placed in the handle and clamped so that the two openings for the wire project just beyond the end of the canula. The wire best suited for this purpose is that which is known as No. 5 piano wire. A small piece is cut off, the length varying from three and a half to

four inches. A longer length of wire will not, when double, pass entirely within the canula; a shorter length is desirable only when a very small portion of tissue is to be removed. The threading of the wire is a matter of no little importance. If it is desirable to

FIG. 25.



Schroetter snare.

a. Canula. b. Stylet. c. Binding screw for canula. d. Binding screw for stylet.

have the wire loop in a vertical position when introduced into the nostril, the wire should be threaded as shown in Fig. 26—that is, both ends of the wire loop are inserted from the same side of the stylet. After

FIG. 26.



Wire threaded for a vertical loop.

passing one-eighth of an inch through the hole in the stylet the wire is bent sharply toward the loop—that is, away from the handle of the snare. The stylet is then drawn within the canula until the small projecting bent ends are concealed.

In threading the instrument it will be observed that if both ends of the wire are inserted on the left side of the stylet, then, when the ends are properly guarded by being drawn inside the canula, the loop, in addition to being vertically placed, will have a natural bend toward the right, whereas if inserted on the right-hand side of the canula the loop will have a natural bend toward the left. This is very advantageous, because the wire is always stiffer and will engage an object more readily where advantage is taken of this natural bend than where artificial bending of the wire loop has to be resorted to. If the ends of the wire be inserted into the stylet from the opposite sides (Fig. 27), and the stylet then drawn into the canula, it will be found that the loop will be horizontal instead of vertical.

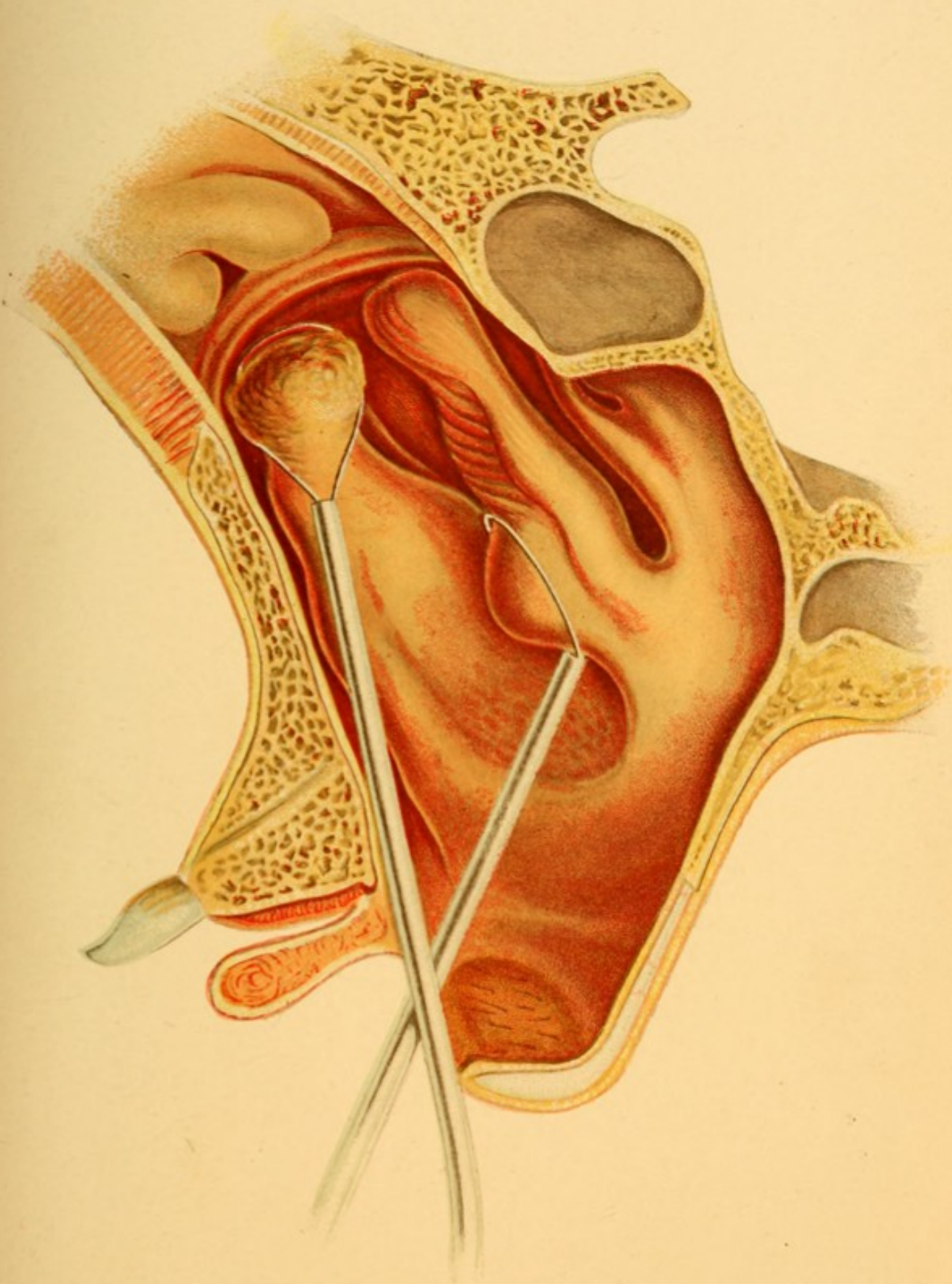
FIG. 27.




Wire threaded for a horizontal loop.

To employ the snare for the removal of hypertrophies the nose should first be thoroughly sprayed with a 2 per cent. solution of cocaine, and then, after waiting two or three minutes, cotton soaked in a 10 per cent. solution of cocaine, as described above, should be placed over the portion it is desirable to remove. If this portion is on the inner surface of the inferior turbinate or on its posterior end, or is a projection from the thickened mucous membrane of the septum, it will be found more convenient to employ the loop in the vertical position, threaded as shown in Fig. 26, also in Plate II. If, however, the projection to be removed is on the under,

PLATE II



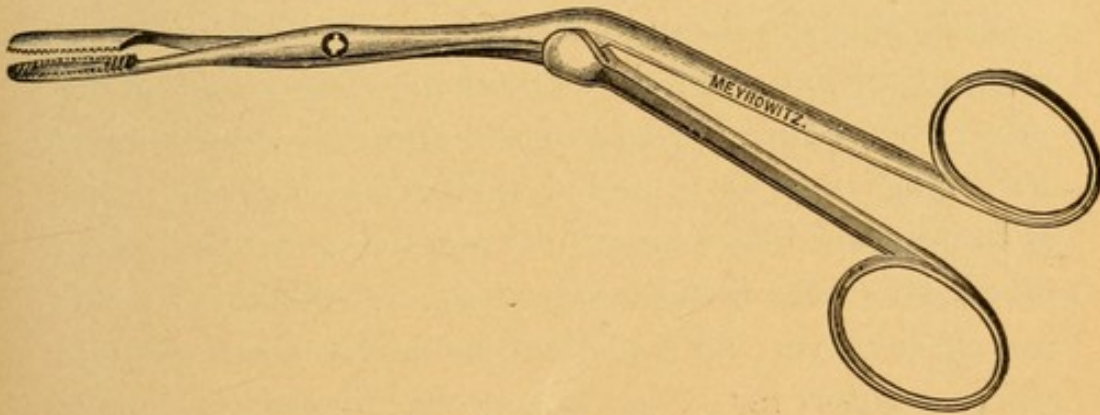
Hypertrophy of the Posterior End of the Inferior Turbinate and of the Anterior End of the Middle Turbinate. The Vertical and Horizontal Adjustment of the Wire Loop for removing such Hypertrophied Mucous Membrane is shown.



pendulous edge of the inferior turbinate, or the under portion of the middle turbinate, it will be found more convenient to have the loop horizontally placed and the snare threaded as shown in Fig. 27, also in Plate II.

The loop having been inserted into the nostril so that the furthestmost portion of the loop is posterior to the part to be removed, firm lateral pressure should be made with the canula against the outer wall of the nose and just in front of the projecting portion which it is desired to remove; the two fingers placed in the rings of the sliding bar are then drawn with a quick movement toward the thumb, which is placed in the ring at the end. The included mucous membrane will thus be caught in the loop of the snare and cleanly excised.

FIG. 28.



Angular forceps.

The excised portion will usually be found to remain within the nostril, and it may then be removed with a pair of angular forceps (Fig. 28), or the patient may forcibly blow through the nostril, the opposite one being held closed with the finger. This latter method, however, sometimes causes an unnecessary amount of hemorrhage, the nose being considerably congested and hemorrhage increased by this act.

Should sharp hemorrhage follow the removal of turbinal tissue, it may be controlled in one of the following ways, which we should advise being employed in the order given :

1. About 10 grains of powdered suprarenal extract should be blown into the nose, and a pledget of cotton inserted into the nostril to keep the blood from flowing out. The active principle will be dissolved by the blood, and coming in contact with the bloodvessels so contract them as to stop the bleeding.

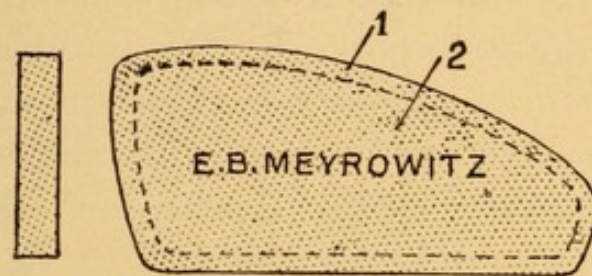
2. Syringing (Fig. 19) the nose with very hot normal saline solution. The temperature of the solution should not be lower than 125° F. Unless the solution employed is of this temperature, or a little higher, the washing is apt to aggravate the hemorrhage rather than control it.

3. If this should not succeed, syringing the nose with peroxide of hydrogen may be tried. This causes a considerable amount of frothing in the nose, and is apt to leave both nostrils plugged with froth, and the patient is thereby forced to breathe through his mouth—an exceedingly uncomfortable sensation. Peroxide of hydrogen is, however, an excellent hemostatic, and some of the discomfort may be overcome by *carefully* but gently syringing the nasal cavities with hot normal saline solution ten to fifteen minutes after it has been found that hemorrhage has been controlled by the peroxide of hydrogen.

4. Plugging the nose with cotton. One of the best methods of accomplishing this is to take a form of compressed cotton known as Bernay's sponges, made in two sizes and shaped to fit the nasal cavities (Fig. 29). These, as now made, are too thick for the average

nose. We are in the habit of splitting them, using only about one-half or one-third of the thickness of the original sponge. The nostril having been rapidly cleansed of blood-clots by means of a cotton-wound applicator, the Bernay sponge is introduced into the nose with the aid of the angular forceps and adjusted

FIG. 29.



Bernay's sponges, actual size. The smaller one, 2, is indicated by the dotted line; 1 is the larger size. The thickness of each is shown on the left.

so that the centre of the sponge lies opposite the cut surface. These sponges swell rapidly with the serum of the blood, and the pressure thus produced is usually very effective in controlling hemorrhage.

5. Where none of the above methods has controlled the hemorrhage we should recommend taking a strip of sterile gauze, an inch in width and not less than a yard in length, and with a blunt-pointed heavy laryngeal applicator pack the nasal cavity. The first portion of the gauze should be introduced well back to the posterior portion of the cavity, packing from above downward, until the entire nasal cavity is completely filled with the strip of gauze. If properly accomplished, it will take nearly if not quite all of the yard of gauze to fill the average nasal cavity.

The post-operative treatment in cases in which the snare has been employed lies mainly in keeping, as far as possible, a healthy condition of the wound until

healing shall have taken place. This is best accomplished by twice or thrice daily syringing the nasal cavity with normal saline solution without the use of undue force.

When plugging has been resorted to for control of the hemorrhage by either the Bernay sponge or the strip of gauze, this should be removed at the end of twenty-four hours. If left longer, it is very apt to become septic and foul smelling, and occasionally a septic tonsillitis may ensue. On removing the plug there is usually a little hemorrhage, which is generally easily controlled by syringing with hot saline solution. If, as rarely happens, the hemorrhage is still considerable, the nose may have to be plugged again for another twenty-four hours.

III. The treatment of the third variety of hypertrophic rhinitis is best accomplished by removing the lower portion of the inferior turbinate by means of the cold snare. The loop should be horizontal.

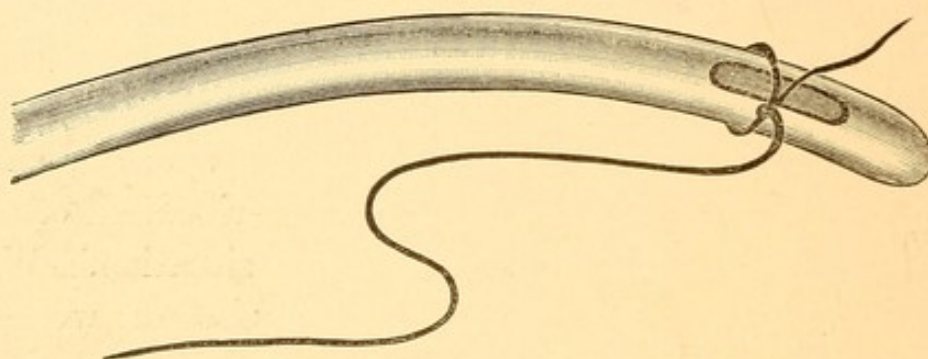
IV. The treatment of the fourth variety—hypertrophy of the posterior end of the inferior turbinate—should be either its removal with the cold snare (Plate II.) or with the galvano-cautery snare, the wire being used at a red heat. The galvano-cautery snare—the wire being threaded through a hollow canula and fastened into the Schech handle—is the better method where electricity can be obtained, as the hemorrhage in such cases will be much less. If the cold snare be used, one always has to bear in mind the fact that the tissue here is very vascular, and that from its position the blood drops into the large cavity of the nasopharynx, and that there is not usually the same opportunity for the blood to clot upon the surface as when the

tissue removed lies within the cavity of the nose proper. Cocaine contracts these tissues, and very often a patient will leave the office with very little hemorrhage, and, as soon as the effects of the cocaine have passed off, the extra heart action from walking causes a secondary hemorrhage, and one is frequently annoyed in the course of an hour or so either by having the patient re-enter his office or by being sent for to control a rather severe hemorrhage from the site of the wound. Hot water and peroxide of hydrogen, the insufflation of powdered suprarenal glands, Bernay's sponges, and even packing with gauze, as above described, all often fail to control the hemorrhage in this situation. We have found that a nasopharyngeal applicator, wound with cotton and dipped in a thick, syrupy-like solution of tannic acid and water, and accurately applied through the mouth and up behind the soft palate to the bleeding surface, often suffices to control this very annoying hemorrhage. When all of these methods fail the only satisfactory means of controlling the hemorrhage is to plug the posterior nares with absorbent cotton.

This may be readily accomplished by means of an ordinary male gum-elastic catheter, around the eyelet end of which a piece of floss silk or sufficiently strong, small twine may be tied, as shown in Fig. 30. One end of the string should be cut short and the other should be about three feet long. The eyelet end of the catheter, with the string attached, should be inserted into the nostril on the side that has been operated upon, and then pushed back into the nasopharynx until the end is seen below the lower border of the soft palate. The catheter may then be grasped with a pair

of forceps introduced into the mouth, and the catheter and string drawn out, care, of course, being taken to leave some of the string still in the nose. The string is next cut close to the point where it is tied to the catheter. We now have a piece of string passing through the nose and nasopharynx and coming out of

FIG. 30.



Catheter with cord attached for plugging the posterior nares.

the mouth. To the mouth end tie a piece of cotton about the size of a walnut. Traction should next be made upon the end of the string protruding from the nostril, the finger being placed upon the wad of cotton so as to guide the plug that it may pass behind the soft palate, thereby preventing it from catching, and so inverting the soft palate into the nasopharynx.

It is sometimes necessary to plug also the anterior nares, as well as the posterior, to control hemorrhage. Plugging the posterior nares is not to be regarded lightly, for it occasionally happens that a large plug will press upon the Eustachian orifice. The readiness with which plugs become infected with pyogenic bacteria renders infection of the middle ear through the Eustachian tube highly probable in such cases. This may result in abscess of the middle ear, and even suppurative mastoiditis. A post-nasal plug

should never be allowed to remain *in situ* more than twenty-four hours.

V. The fifth variety should be treated by the removal of the pendulous portion with the cold snare. Cauterization with acids, the use of the galvano-cautery, or the employment of the galvano-cautery snare, has each been found to be somewhat dangerous in this region, owing to the fact that some of the veins here communicate through the dura with the sinuses of the brain, and septic meningitis has occasionally resulted from this method of treatment. Care should be taken to remove only that portion of the mucous membrane which is actually pendulous. The removal of more than this and the removal of the middle turbinated bone often leave the nose in a very dry condition after healing has taken place.

VI. The sixth variety, in which the mucous membrane projects enough to be included in the loop of the cold snare, may be removed by means of it. When the hypertrophied membrane cannot be caught by the loop of the snare we should advise linear cauterization of the thickened area with the galvano-cautery, or, not having this, trichloracetic acid may be employed.

VII. The seventh variety should be remedied by the employment of trichloracetic acid. Where the nasal structures are sufficiently open, enabling one to see the exact situation of the swelling, it may be cauterized by the galvano-cautery. In using trichloracetic acid in this region, however, we must remember that the situation of the tissues is well back, and we should advise first measuring the exact distance from the anterior nares at which the swelling is situated, and marking, with a small pledget of cotton wound about the appli-

cator, the distance into the nose to which the applicator has to be inserted in order accurately to reach the diseased area. Care must be taken, also, in introducing the applicator, that the acid does not touch any other point of the mucous membrane than that which it is desired to cauterize.

Where there is a general but slight thickening of the nasal mucous membrane remaining after operation painting the nasal cavity with

R.—Iodini	gr. v.
Potass. iodidi	gr. x.
Glycerini	℥j.—M.

once or twice a week, is often very beneficial. Where the patients are anemic, rheumatic, gouty, or are subjects of indigestion, disordered circulation, etc., the appropriate remedies for these conditions must also be given.

Fowler's solution, administered in doses of gtt. v-x, three times a day, we have often found beneficial in correcting slighter forms of hypertrophy.

ATROPHIC RHINITIS.

A chronic inflammation, involving the mucous membrane of the nose, resulting in atrophy of this as well as of the turbinal bones.

Etiology. The cause of this disease is as yet unknown. Many theories have been advanced to account for it, such as secondary to hypertrophic rhinitis, the result of the action of specific bacteria, the result of chronic suppurative processes involving the accessory sinuses of the nose, and as being one of the manifestations of inherited syphilis; but each of these in turn has been

discarded as producing the lesion in every case. Undoubtedly there are cases of atrophic rhinitis which have been produced in each of these several ways, but the number of cases of this disease which may be accounted for by all of the above named causes, taken together, forms, perhaps, only a small part of the total.

It has been noticed that the disease begins most frequently in early childhood, about the twelfth year, although it may occur much earlier. It seldom begins after the twenty-fifth year. It is more common in females than in males, and it is seen very frequently in those who are pale and anemic, and in those living in unhygienic surroundings. It may also be observed in more than one member of a family, and is seen in the children of those who suffer from atrophic rhinitis.

Pathology. In well-marked cases the mucous membrane of the nose is almost completely atrophied, the normal epithelium being replaced by the stratified variety. The underlying tissues of the mucous membrane are replaced by a dense connective tissue. The atrophy extends to the scroll-like turbinal bones, so that not infrequently no trace of the inferior turbinate can be found. The middle turbinate may persist only as a small stump toward its posterior end. The secretion from the nose in these cases has a very foul odor, and shows many desquamated epithelial cells in various stages of fatty degeneration. Bacteria swarm in the secretion, and a bacillus, which in culture develops a very fetid odor, was at one time thought to have been the cause of the disease. Inoculation experiments, however, have failed to establish this.

Symptoms. The nasal symptoms of this disease consist in a blocking of the nose by the extensive forma-

tion of crusts, which, when they are removed, as frequently happens once in two or three days, leaves the nose for a time quite clear. The odor from these crusts is very fetid (hence the term ozena so frequently applied to this disease), and is so objectionable to those with whom the patient comes in contact that he is frequently reminded of the bad odor of his breath. The patient himself is seldom aware of the odor, as the atrophy involves the terminal filaments of the olfactory nerve, thus depriving him of the sense of smell. The dry crusts, when partially loosened within the nose, are vibrated by the ingoing and outcoming air during respiration, producing an uncomfortable tickling sensation. To obviate this the patient resorts to the practice of removing these crusts with the finger, with the usual result that either the finger or the sharp edge of a crust inflicts slight wounds upon the nasal mucous membrane. If the crusts tend to form on the cartilaginous portion of the septum, a constant picking frequently produces at first a deep ulcer, and then, finally, a perforation of this portion of the septum. It is often, however, not until atrophic rhinitis produces a dryness of the nasopharynx, and, later on, of the larynx, that these patients will, of their own accord, offer themselves for treatment complaining only of these latter affections. The cause of the dryness of the pharynx and larynx lies in the fact that the air in passing through the nose is not properly moistened, and hence an undue amount of moisture is taken up from the mucous membrane of the pharynx and larynx. The cool and dust-laden air, not being sufficiently warmed in its passage through the nose, passes over the pharynx and larynx, and, irritating the sensitive mucous membrane in this latter region,

produces a condition of chronic congestion of these organs. The mucus secreted from the pharynx and larynx, robbed of its moisture, remains upon the mucous membrane as a dry and very adherent film. It is most marked and annoying in the morning, and excites a great deal of coughing and hawking before it is expelled.

It is not uncommon to find in these patients a sclerotic process in the mucous membrane of the middle ear, thickened and retracted membrana tympani, and marked diminution in the sense of hearing.

Examination. Anterior rhinoscopy reveals the nasal cavity pretty thoroughly lined with thick greenish or blackish crusts, adherent to the mucous membrane of the turbinates and septum. Here and there, if the crusts have been recently removed, may be seen ulcerated areas. At times, in addition to the crusts, a thick purulent or mucopurulent secretion is also found in the nasal cavities. Examination of the posterior pharyngeal wall shows the mucous membrane dry, glistening, and parchment-like in appearance.

Posterior rhinoscopy reveals similar dry crusts, with thick, tenacious mucus spread over the posterior and superior walls of the nasopharynx. The mucous membrane of the larynx is dry, reddened, swollen, and glistening in appearance, often accompanied by the formation of crusts in the interarytenoid spaces on the posterior laryngeal wall. The vocal cords, in addition to being dry and slightly congested, have their surfaces finely wrinkled in appearance.

Differential Diagnosis. The condition is to be differentiated from syphilitic and tubercular ulcerations of the nose, empyema of the accessory sinuses, and the

ulcerative processes accompanying foreign bodies within the nasal cavity. Tertiary syphilis of the nose produces an odor very much like that of atrophic rhinitis, but the history of a primary sore some years before, the presence of necrosed bone, as detected with a probe, and perforations of the bony portions of the septum, with probable tertiary manifestations in other portions of the body, will differentiate syphilis from atrophic rhinitis.

In tuberculosis of the nose (a rare condition) the presence of granulation tissue and the thick purulent discharge, without much tendency to crust formation; the site of the lesion, involving, as it does, mainly the cartilaginous portion of the septum and the region of the inferior turbinate; and, lastly, the microscopical examination of the excised granulation tissue, showing the presence of tubercle, are sufficient to make the diagnosis. It is not easy to detect tubercle bacilli in the purulent discharge in these cases.

To differentiate atrophic rhinitis from empyema of any of the accessory sinuses one should employ the methods of examination of these sinuses as given in the article on those diseases. It must not be forgotten that empyema of the accessory sinuses not infrequently accompanies an atrophic rhinitis, and that where the history shows that, in addition to the crust formation, there is a discharge of pus or muco-pus, empyema of the accessory sinuses should always be suspected as a complication.

The odor due to a foreign body in a nasal cavity may also simulate that of atrophic rhinitis. Careful examination of the cavities with a probe should enable one to determine if a foreign body be present.

Prognosis. The prognosis in atrophic rhinitis is bad so far as ability to effect a cure is concerned. Most of the disagreeable symptoms may be markedly relieved providing the patient will faithfully carry out the directions of his physician. There is, however, no way of restoring to normal condition the atrophied mucosa. After middle life the disease is rarely so troublesome, and the crust formation has a tendency to diminish and even disappear.

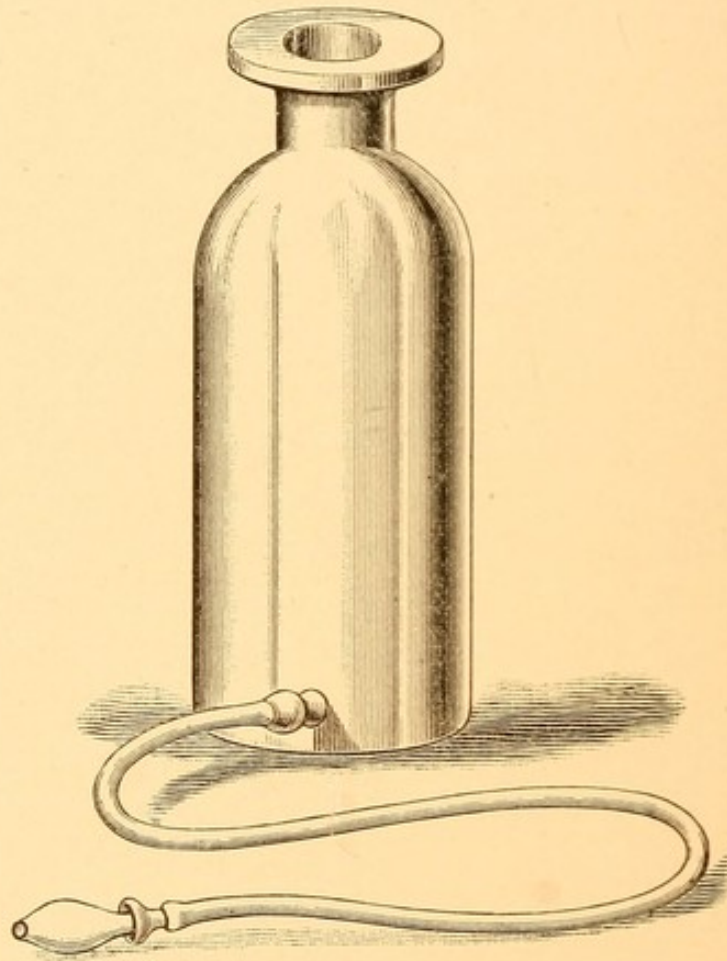
Treatment. The first indication in the treatment of this disease is to cleanse thoroughly the nose and to take such measures as will tend to prevent, as far as possible, the crust formation. For the purpose of cleansing the nose the ordinary hand atomizer is of but little use, as the amount of liquid that can be sprayed into the nostril is insufficient properly to moisten and wash off the hard crusts.

*nasal
douche*

For this purpose we are in the habit of employing the Whitall-Tatum nasal douche (pint size) (Fig. 31). The ordinary douche bag, fitted with the proper nasal nozzle, may be employed equally well. As the amount of liquid to be used is considerable—at first two or three bottlefuls may be necessary to accomplish the purpose—it becomes necessary to prescribe a fluid that is inexpensive. For this reason we advise patients to take four tablespoonfuls of baking soda (sodium bicarbonate) and two tablespoonfuls of salt (sodium chloride), mix them thoroughly, and preserve dry in a suitable receptacle. The bottle is then filled three-quarters full of lukewarm water, to which is added two-thirds of a teaspoonful of the soda and salt mixture, and the bottle shaken until the powder is dissolved. With a towel wrapped around the neck the patient stands before a

sink or wash-bowl, bending slightly forward. The bottle is grasped with the left hand, and the nozzle of the tube, held between the thumb and forefinger of the right hand, is inserted into the right nostril sufficiently tight to prevent escape of fluid from the nostril. The bottle is then elevated until the fluid is noticed running

FIG. 31.



Nasal douche.

from the left nostril. If the mouth is kept open and the patient breathes through it, he will find no difficulty in allowing the fluid to run for some time through the right nostril, back into the nasopharynx, and out of the left nostril. He must be cautioned not to elevate the bottle too high, or the pressure of the fluid in the

nasopharynx will force some of it into the Eustachian orifices, and the disagreeable sensation as of water in the ears will result. The bottle should be elevated only high enough (usually not more than two or three inches above the level of the nose) to cause the fluid to flow in a very gentle stream from the nose. After allowing about half of the fluid to run through in this manner, lower the bottle, remove the nozzle from the right nostril, and proceed to wash through the left, holding the nozzle now in the left hand and the bottle in the right. It will be found that as a result of washing in this way most of the crusts have been softened and washed out of the nose. If one bottleful does not suffice, use a second, and, if necessary, a third. The nose should be washed at first three times each day—morning, noon, and night. Patients must be cautioned not to blow the nose for three or four minutes after the washing, the danger being that by this act some fluid may be forced into the Eustachian orifices and aggravate any inflammatory process that may be going on in the middle ear. They must also be cautioned not to go out-of-doors for at least half an hour after the washing. By so doing they will avoid taking cold. Each patient should report to his physician at first twice a week, in order that he may observe the effects of the washing, that it is properly and thoroughly carried out. It often happens that some of the crusts which are situated high up above the middle turbinate may not be washed out of the nose, although they are well softened. In such an event a small pledget of cotton wound about an applicator may be employed to remove the crusts remaining after the washing. It is surprising how much odor may come from even a small amount of

crusts left in the nose. If the odor is exceedingly foul and not allayed by thorough washing with the above solution, two grains of permanganate of potassium dissolved in a pint of lukewarm water may be employed instead of the soda and salt solution for the first week. After washing and cleansing the nares it will be found advantageous to swab the entire mucous membrane of the nose with a cotton-wound applicator that has been dipped in the following solution :

R.—Iodini gr. x.
 Potassii iodidi gr. xx.
 Glycerini ℥j.—M.

The alterative action of this solution tends to increase the flow of mucus, thereby lessening the sensation of dryness in the nose accompanying this disease.

Where there are many ulcerations resulting from picking of the nose the patient should be cautioned against putting the finger into the nose. He should be given the following spray, to be used after each washing :

R.—Menthol gr. xx.
 Aristol gr. xxx.
 Benzoinol ℥j.
 M. Sig.—Use in oil atomizer.

After the crust formation has been pretty well controlled it is advantageous to swab the nasal mucous membrane once a week with the following :

R.—Acidi carbolic,
 Glycerini āā ℥ss.—M.

This may be a little painful, and it is better to spray the nose with a 2 per cent. solution of cocaine before swabbing.

The great difficulty with these patients is that once they get comparatively free from crust formation and feel much better, they fail to see the necessity of once or twice daily washing their nose, and consequently stop all treatment. The crust formation, odor, and other symptoms quickly return.

In order to be sure that these patients are carrying out the instructions of the physician they should, after the symptoms are well ameliorated, report at least once a month for inspection.

The general health of these patients should be looked after. They are frequently anemic, and although iron tonics, arsenic, and cod-liver oil are to be administered, patients do not show the good effects of their use as quickly as in most other diseases.

VASOMOTOR RHINITIS, OR HAY FEVER.

A condition of intense engorgement of the nasal mucous membrane, with paroxysmal sneezing, suffusion of the eyes, and a watery discharge from the nose.

Etiology. It is commonly believed that there are three factors necessary for the production of this disease: (1) A neurotic condition of the system. (2) A special susceptibility and a very irritable condition of the nerve-endings in the mucous membrane of the nose and of the conjunctivæ. (3) Some irritating substance which is the exciting cause. Dunbar has proved that the pollen of many plants contains a substance which, if sprayed into the nose, dropped into the eyes, injected into the rectum or hypodermatically, will produce in those susceptible to hay fever a typical attack. The first and second factors may be regarded as predisposing causes. Sufferers from this affection are usually of that class of people who may be said to have a nervous

temperament. It is more commonly seen in the highly educated, overworked people in cities than among the inhabitants of country districts. It is somewhat more common in men than in women and in adults than in children, and it very frequently runs in families. As to the condition of the nasal mucous membrane which renders one susceptible to the exciting cause, it is difficult to say just what lesion most frequently predisposes to it.

The following are some of the pathological conditions found in those who suffer from hay fever: hypertrophic rhinitis; thickening of the septal mucous membrane at the juncture of the cartilaginous and bony portions; marked deviation of the septum; spurs (sometimes large enough to touch the turbinal tissues opposite); adhesions between the mucous membrane of the septum and that covering the turbinal bones; nasal polypi; and adenoids in the nasopharynx.

One occasionally sees a sufferer from this disease in whom it is difficult to detect a pathological process at any portion of the nasal mucous membrane, with the exception of here and there specially sensitive areas, which, when touched with a probe, cause paroxysmal sneezing.

As to the exciting causes, cases of hay fever may be divided into two classes: those which begin early in the season, the latter part of May and June, and the more common variety, which begins from the 15th to the 25th of August. There are some that begin between these periods.

The first class of cases is commonly known as rose fever, and is usually attacked about the time that roses are in full bloom, the pollen from which is usually the exciting cause. The August form of hay fever is generally most marked during the time that the common rag-

weed is in bloom, the pollen from this being accredited as the irritating substance. These, however, are not the only irritating substances which excite the disease in those predisposed to it, as the odors from stables, dust, and irritating chemicals may act in individual cases as excitants.

Pathology. In the etiology we have mentioned the more common chronic pathological processes of the nose which may predispose to hay fever. During the acute attack the bloodvessels are dilated and the mucous membrane enormously distended, so as practically to occlude the nares. Its color is a bright red, and the glands are stimulated to great activity.

Symptoms. The attack is usually ushered in by a sense of great burning and dryness of the nose, which may be accompanied by a similar condition of the conjunctivæ. In a few hours the nasal mucous membrane may be so swollen as to make nasal breathing impossible. About this time sneezing and a watery discharge from the nose and eyes make their appearance. At first there may be but a single sneeze, which is repeated in the course of several minutes. Later the sneezing recurs in paroxysms, a dozen or more sneezes following each other in rapid succession. The discharge from the nose may be so profuse as completely to saturate a handkerchief in the course of a few minutes, and at such times the frequent use of the handkerchief produces a redness and soreness of the nostrils. Frontal headache, usually due to the congested condition of the mucous membrane of the frontal sinuses, is often severe. The patient frequently complains of a feeling of stuffiness in the ears. When the sneezing is severe and prolonged, exhaustion is often a prominent symptom. Fortunately, there are usually periods in the

day, often of quite long duration, when the patient is free from these paroxysms and can get a much-needed rest. After retiring at night the sneezing and nasal discharge quickly cease, but the swelling of the nasal mucous membrane usually persists. In aggravated cases, on awaking, and even before getting out of bed, the paroxysms return. A peculiarity of this disease is that the patients often predict months in advance the very day upon which they expect the attack to begin. Those who have suffered from hay fever several years in succession frequently manifest symptoms of bronchial asthma after from five to ten years. The asthma may persist through the winter months, and not infrequently with the onset of the asthma the attacks of hay fever diminish in severity or disappear.

Examination. Examination of the nose shows an almost total occlusion of the nasal cavity, the mucous membrane of the inferior and middle turbinates touching that of the septum. Ecchymotic spots are frequently seen on the mucous membrane. The conjunctivæ are reddened and the bloodvessels injected. The use of the cocaine spray may in a few minutes reduce the swelling of the mucous membrane, so that a better inspection of the nasal cavity can be obtained, and then the chronic pathological processes described in the etiology will be brought into view if they exist.

Differential Diagnosis. The disease can scarcely be confounded with any other condition, as the patients usually come to the physician for treatment, having made their own diagnosis of the condition.

Prognosis. The prognosis in hay fever should be a guarded one. If, during the time of the year when a patient is subject to the attack, he can leave and go to

those places where the particular irritant in his case is not found, the attack will usually be warded off for that year. If any pathological process is detected within the nose and remedied, one of the factors causing the disease will have been removed; and it is possible that under such conditions he may remain at his usual residence and be free from the attack, although there is no certainty that such will be the case. If, also, the neurotic condition can be removed by suitable medication and proper hygienic surroundings, including freedom from business worries, much will have been accomplished to render the patient less susceptible to hay fever.

Treatment. The treatment may be divided into that during the attack and that in the interval.

During the attack the patient should, if possible, be removed from his usual place of dwelling to one that is free from the source of irritation. Some of the notable places to which patients suffering from this disease are sent are: the White Mountains, the Lake Region in Maine, parts of the Adirondacks, and the Lake Region in Canada. Pollantin, a preparation prepared on the principles of an antitoxin derived from the pollen of hay-fever-producing plants, has been advised for prophylactic purposes. In a few cases it has worked well.

An ocean voyage begun two or three days before the expected attack, taking one of the slower steamers, may prevent it. If a patient having the disease sails, the attack usually ceases the second or third day out. If unable to get away, then such remedies must be employed at home as will tend to render the mucous membrane less sensitive to the irritant. For this purpose we recommend the following prescription:

- R.—Menthol gr. xl.
 Camphor gr. xx.
 Eucalyptol ℥j.
 Ol. pini pulmillionis ℥xxx.
 Benzoinol q. s. ad ℥ij.
- M. Sig.—Use in oil atomizer every two hours if necessary.

This prescription, when first employed, will cause a smarting of the very sensitive nasal mucous membrane, but the anesthetic action of the menthol and the coating of the entire mucous membrane with the oil lessen the irritating effect of the pollen or dust.

A remedy, which we have employed in many cases (in most with excellent results), is a solution of suprarenal extract in a half-saturated solution of boric acid, or solutions of adrenalin 1 to 10,000. This solution should be sprayed into the nose five minutes before using the menthol preparation above given. In very aggravated cases ten grains of cocaine may be added to the above menthol solution, but we would again caution physicians about the use of cocaine in any spray that is given into the hands of the patient to use at his pleasure. The practice is fraught with great danger to the patient so far as becoming an *habitué* in the use of this drug.

In case extensive pathological conditions are found in patients suffering from hay fever the question of operating upon these during an attack is to be considered. Unless these conditions are of such a nature as to produce very marked nasal obstruction independent of the attack of hay fever, it seems to me better to defer the correction of these chronic conditions until after the hay fever has subsided.

Constitutional treatment during an attack of hay fever should be directed toward remedying the nervous

condition of the patient. Valerianate of zinc in full doses has been highly recommended, and in some cases it apparently does good. Fowler's solution, in five- to ten-drop doses three times a day, and the administration of the iodide of potassium, ten grains thrice daily, also apparently are beneficial in some cases. Pollantin has diminished the severity of the attack in some cases and in others completely arrested it.

The treatment of these patients in the interval between the attacks should consist in first searching for any pathological condition within the nasal cavity and remedying it, in the hope that by so doing specially sensitive portions of the mucous membrane may be eradicated. Failing to find any pathological conditions, should any portion of the nasal mucous membrane be found to be hypersensitive, as indicated by paroxysmal sneezing when touched with a probe, such areas should be cauterized with the galvano-cautery or trichloroacetic acid, observing the directions as given for applying these in hypertrophic rhinitis.

Careful inquiry should be made to detect any neurotic condition, and appropriate remedies and proper regulation of diet and exercise should be ordered.

It has been my custom, for at least six weeks prior to the expected attack, to give the following :

R.—Potassii iodidi ℥iv.
 Ext. grindeliæ robustæ fl. ℥vj.
 Elixir simplicis,
 Spt. vini rectificati āā q. s. ad ℥iv.
 M. Sig.—One drachm in water t. i. d.

MEMBRANOUS RHINITIS.

An acute inflammation of the nasal mucous membrane, accompanied by the formation of a membrane involving the epithelial and occasionally the subepithelial tissues.

Etiology. The disease occurs more frequently in children who are poorly nourished and live amid damp, unhygienic surroundings.

It occurs also as a result of traumatism to the mucous membrane, whether in children or in adults. This traumatism may be either the result of any of the varieties of cauterants employed in treating diseases of the nose or from the irritating effect of inhaling hot steam. Occasionally after the removal of a foreign body, such as may be frequently introduced into the nose by a child, a membrane may be seen for a few days.

Pathology. This disease is not to be confounded with nasal diphtheria, although it is sometimes difficult to distinguish between the two. The membrane is usually grayish white in appearance, and when first formed is removed with difficulty, leaving a raw and slightly bleeding surface. Later on the membrane may be quite loose and readily removed.

Excluding those forms the result of traumatism, bacteriological examination of the secretions has, according to various observers, given quite different results. Some have found the Klebs-Loeffler bacillus. Such cases, although not having any of the other symptoms of nasal diphtheria, should be regarded as such. Other observers have found a bacillus resembling the Klebs-Loeffler bacillus, but when this has been cultivated and animals inoculated therewith the results have

shown that the cultures were not virulent. Staphylococci have also been found in these membranes. Microscopically the membrane consists of a meshwork of fibrin enclosing epithelial cells in various stages of degeneration, leucocytes, and the micro-organisms above described.

Symptoms. The attack is usually ushered in by marked nasal obstruction, the mother observing that the child suddenly has become a mouth-breather, with the accompanying snoring, and is restless at night.

If the child happens to be of a nursing age, it will be observed that it is able to retain the nipple for only a few seconds at a time, letting go in order to breathe through the mouth, and again nursing for a few seconds. There may be a thick whitish or slightly yellowish-white discharge from the nose, which is usually not very irritating to the skin about the nostrils. There is very little, if any, enlargement of the glands of the neck, and the temperature is usually not much if any above normal.

Examination. Examination will show one or both nostrils almost completely occluded with a tenacious mucus and a grayish-white membrane. It is often difficult to make a proper examination of the nares of a young child without the administration of a small amount of chloroform. This is best done by dropping fifteen or twenty drops of chloroform upon a handkerchief or a piece of sheet lint, and holding the same a couple of inches in front of the nose and mouth. It is always advisable to smear vaseline, sweet oil, or some other oily substance over the face, as the skin of a child is quite tender, and may otherwise be blistered by the vapor from the drug. The anæsthesia should not be profound, the primary stage usually sufficing

to keep the child quiet long enough for a thorough examination of the nasal cavities. With the nostril dilated by a nasal speculum, cotton wound about an applicator should be used to free the nasal cavities from the mucus; the exact extent and position of the membrane may then be seen. A blunt probe should be introduced into the nose to assure the examiner that the membrane may not be the result of a foreign body within the cavity. A pair of angular forceps should be employed, without any great amount of force, to test the tenacity with which the membrane adheres to the underlying tissues. The membrane will usually be found to be situated upon the inferior turbinate. It may also be found upon the septum and middle turbinate.

Differential Diagnosis. The patient's history, in case the membrane is the result of the use of cauterants, usually suffices to differentiate this form of membrane from the non-traumatic variety. The use of the probe should detect a foreign body if present. The principal disease that it should be differentiated from is nasal diphtheria. In nasal diphtheria the discharge from the nostrils is usually blood-tinged, and varies in color from a light pink to a distinct red, according to the amount of blood. The secretion is also ichorous, and excoriates the nasal orifices and the upper lip. In membranous rhinitis the secretion is not blood-tinged unless undue violence has been used in attempting to remove the membrane, and the secretions are bland and unirritating. In nasal diphtheria the glands of the neck are very much enlarged, which is not the case in membranous rhinitis. In nasal diphtheria the temperature may be from 101° to 103° F. or higher. In membranous rhinitis the temperature is usually normal or but very slightly elevated. Nasal

diphtheria is usually accompanied by evidences of a diphtheritic exudation on the tonsils, pillars of the fauces, or in the nasopharynx, or accompanied by the symptoms of croup. These are not present in membranous rhinitis. Cultures should invariably be made from every case of membranous rhinitis, and the presence of the Klebs-Loeffler bacillus should be the criterion of nasal diphtheria. The case should be regarded as diphtheria where these are found.

Prognosis. The prognosis of non-diphtheritic membranous rhinitis is invariably good. The cases frequently run a somewhat lengthy course, lasting from one to four weeks, the membrane often forming several times after having been removed. Young children, from the difficulty they have in nursing, frequently emaciate considerably.

Treatment. The nose should be carefully syringed three or four times a day with a non-irritating fluid, such as that described on page 88 (hypertrophic rhinitis). We have also employed the officinal liquor calcis, in the strength of one part to four of water, with apparently beneficial results. Should the membrane produce so much nasal obstruction as to prevent the child from nursing, it may become necessary to remove the membrane with a pair of forceps. This should be done, however, with as little violence to the tissues as possible, as the membrane will re-form in a few hours and be more extensive than before if undue violence is used. The administration of the diphtheria antitoxin is often followed by excellent results.

DEFORMITIES OF THE SEPTUM.

Theoretically, the septum should be of nearly uniform thickness from roof to floor and from the anterior to the posterior portion, and it should be vertically placed, dividing each nasal cavity into two equal and symmetrical halves. As a matter of fact, such a septum is never seen. Slight thickenings are found in the cartilaginous and bony portions of the septum, usually most marked along the lines of the union of the sutures. These thickenings, when not very extensive, are commonly called ridges, but when excessive are given the name of spurs. The septum, moreover, is frequently twisted or bent, sometimes in the vertical direction and at others in the horizontal direction, and not infrequently a combined bending in both directions in different proportions of its extent. So great is the variety and combination of these deformities that it is impossible to adequately picture them.

Etiology. There are two main causes for deformities of the septum: traumatism and malformation in the development of the head. The trauma may occur at birth as a result of extreme flattening of the nose and consequent displacement of the as yet not fully developed component parts of the septum. In childhood the frequent falls while learning to walk and the later falls and blows upon the nose frequently result in displacements and injuries, the effect of which is most marked at the junctions of the several parts forming the septum. During childhood these accidents are equally common to boys and girls, but in later years the athletic sports among boys and men account for the greater number of deformed septa seen in adult males as compared with

adult females. Malformation due to improper development of the head may be best understood by realizing that the septum is placed between the cranium above and the hard palate below. We need but look at the arch of the palate in a series of cases to realize the great variation in its shape. In some it is a flat bone and very wide; in others it is Λ -shaped and exceedingly narrow. Unquestionably, there is also some difference in the downward development of the cranial cavities, so that the floor of the cranium is in some lower than in others. Whenever the vertical height between the floor of the cranium and the floor of the nose is diminished, the septum is compressed between these two and is bound to bend to accommodate the diminished height. At times the bending is all in one direction, to the right or left, while at other times it is doubly bent, first to the right and then to the left. The ultimate factors in the imperfect development of the head are not as yet well understood. Rickets probably accounts for a certain number. Unequal development and eruption of the incisor teeth for others. Mouth-breathing as a result of adenoids and large tonsils, has been thought to give rise to sufficient tension upon the buccinator muscles to produce lateral compression upon the superior maxilla and cause a high arch-palate.

Pathology. The thickenings found upon the septum are usually the result of partial dislocations or greenstick fractures. At the time of the injury some exudate is thrown out along the lines of suture and this callous undergoes organization into cartilage or bone, according to the character of the tissue over which it lies. In consequence the deformities in the anterior portion of the nose are much more apt to be composed of cartilage,

while those in the posterior portion, of bone. The more recent the injury the less firm and dense is the deposit, while those of long standing are oftentimes of extreme hardness.

Symptoms. The symptoms produced by deformities of the septum are of two varieties: First, obstruction to nasal respiration. Second, pain and neuralgia and reflex neuroses. The obstruction is apt to be nearly constant. There may be slight variations when the mucous membrane of the turbinates is swollen or collapsed.

Those whose nasal cavities are naturally narrow will complain of obstruction with a less degree of deformity and with a slighter involvement of the turbinal tissues than those whose nares are wider and more capacious. The obstruction may not be sufficient to be noticeable during the day, but is sufficient to cause mouth-breathing at night, owing to the increase in the size of the turbinates at that time. The deformity may not be great enough to interfere with nasal breathing during ordinary quiet respiration, but interfere greatly with nasal breathing during exercise. Nasal deformities not infrequently are of such a nature as to interfere with the proper ventilation of the nasopharynx and are a factor in the production of chronic inflammatory processes in the Eustachian tube and tympanum, resulting in diminished hearing and tinnitus. They also frequently interfere with the proper catheterization of the Eustachian tube.

Examination. Examination of the anterior nares will give an idea of the variety of the deformity. The septum may be seen to be convex on one side with a corresponding concavity on the other. Ridges or spurs may project laterally and be in contact with the tissues on

the outer wall. They may appear to be adherent to the inferior or middle turbinate, but they seldom are unless some previous cauterizations or operations have been attempted. By means of a probe one can usually determine quite satisfactorily the distance backward a deflection or thickening extends and also whether any adhesions exist. Examination of the posterior nares usually shows the posterior part of the septum of normal thickness and straight—that is, the deflection or spur seldom extends to the posterior part of the septum. It is not uncommon to have considerable asymmetry of the external nose associated with septal deformities, especially when the latter involves the anterior third of the septum.

Prognosis. Proper operative procedures may be relied upon to restore adequate nasal respiration in most cases, except when the nares are congenitally very narrow. In the latter great improvement is obtained. The intranasal operation will not often materially improve the external nasal deformity if it exists.

Treatment. A great many operations have been devised for the correction of septal deformities; each has marked a step in advance in nasal surgery and has sufficed for the correction of a certain class of cases.

Until the development of the submucous resection, none of the previous operations corrected that type of deflection which existed in the upper portion of the nasal cavity, whereby one side of the septum was practically in contact with the outer wall of the nasal cavity close to and parallel with the dorsum of the nose.

The older operations depended upon the use of the saw for removing thickenings of the septum. In that

operation the removal of a spur by means of the saw left a greater or less area of the septum, varying with the size of the spur, denuded of its mucous membrane. The process of healing was slow and by means of granulations, the organization of which not infrequently left a mass of thickenings, almost if not quite equal to the original thickness of the spur. Scabbing and crust formation added to the thickening not infrequently left the patient no better off so far as respiratory space was concerned, and far more uncomfortable from the annoyance of the crusts.

The moderate thickenings in cartilages and bone in the upper portion of the nose, producing considerable obstruction to respiration, could never be corrected by the older methods of treatment.

The principle of the submucous resection is a sound surgical one: namely, through a linear incision made on one side of the septum in its anterior portion the muco-perichondrium and muco-periosteum is elevated from that side of the septum. An incision is then made through the cartilage down to the muco-perichondrium of the opposite side and the muco-periosteum is elevated from the opposite side of the septum. The entire septum, or so much of it as is deemed necessary for the correction of the deformity, be it thickening or deviation, is then cut away with suitable forceps. The two mucous membranes are then held in apposition in the median line with gauze tampons. The result is a membranous septum, at first flexible, but later, owing to the organization of a certain amount of blood-clot which forms between the two layers, the septum becomes fairly ridged, so much so that in some cases at the end of a few months it is difficult to believe that the car-

tilage or bone has been removed. The details of the operation are as follows :

Both sides of the septum are thoroughly cocainized by rubbing them with a cotton-wound applicator that has been dipped in a 10 per cent. solution of cocain. This procedure should be repeated every five minutes for about a half hour. By this time the patient will probably experience a sense of numbness in the incisor and the canine teeth of the upper jaw. The mucous membrane on each side of the septum should next be treated with a solution of adrenalin (1 : 1000). This blanches the mucous membrane and greatly lessens the tendency to bleeding during the operation.

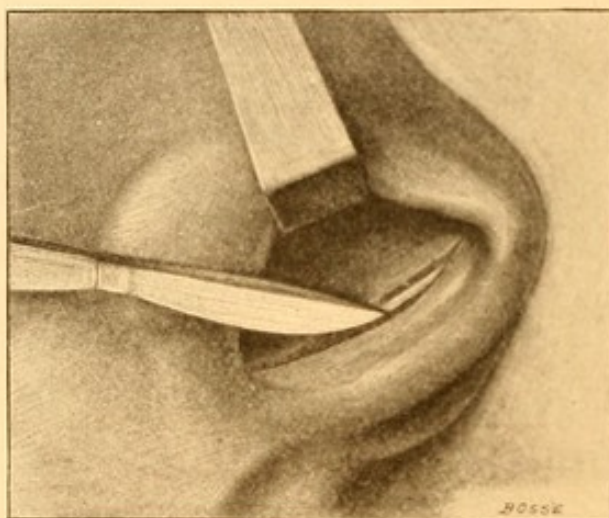
During the cocainization the instruments should be thoroughly sterilized by boiling, and the skin of the face, with which the operator's hands are likely to come in contact, should be cleansed with soap-water, alcohol, and bichloride solution (1 : 5000). The operator's hands should be sterilized and the vestibule of the nose cleansed with hydrogen dioxide.

An excellent light is necessary in order that the posterior portion of the nasal cavities may be well illuminated. Those who are ambidextrous will find it most convenient to make the primary incision in that nasal cavity to which the convexity is directed—that is, if the convexity is directed into the right nasal cavity, the incision should be on the right side of the septum and *vice versa*. Those who are right-handed will find it more convenient to make the primary incision on the left side of the septum.

The incision should be made with a narrow-bladed, very sharp knife ; it is best begun at the junction of the mucous membrane and epithelium surfaces of the

septum at the floor of the nasal cavity and carried upward, following the line of junction of the mucous membrane and skin surfaces of the septum; in other words, about an eighth of an inch within the vestibule of the nose and terminating near the upper portion of the septum. (See Fig. 32.)

FIG. 32.




Head tilted to left, retractor holding back ala. Line of primary incision on right side of septum.

The incision should be deep enough to penetrate the layers of the mucous membrane and just enter the cartilage of the septum. Care must be taken that the incision be not carried through the whole extent of cartilage and mucous membrane into the other nasal cavity. If the incision is made nearer the anterior portion of the nose than indicated, it will be through the portion of the line of stratified epithelium by which cocain is not absorbed, and be very painful. A Killian sharp elevator (Fig. 33) is next introduced and the mucous membrane lifted up from the cartilage in the upper portion. At this place it is least adherent and most easily lifted. After lifting up the membrane posteriorly for a distance

of a quarter of an inch the sharp elevator may be replaced by a blunt one (Fig. 34), and it will be found comparatively easy to dissect the membrane from the underlying septum, provided the direction be parallel to the dorsum of the nose. If a sharp bend exists in


FIG. 33.



Killian sharp elevator.

the septum, it is advisable not to attempt to lift the membrane beyond the angular deflection at this time for fear of perforating the mucous membrane. The dissector may then be used to strip up the membrane over the cartilage down to the point of attachment with the voma. At this point the mucous membrane is usually very firmly adherent, and if much pressure is used at

FIG. 34.



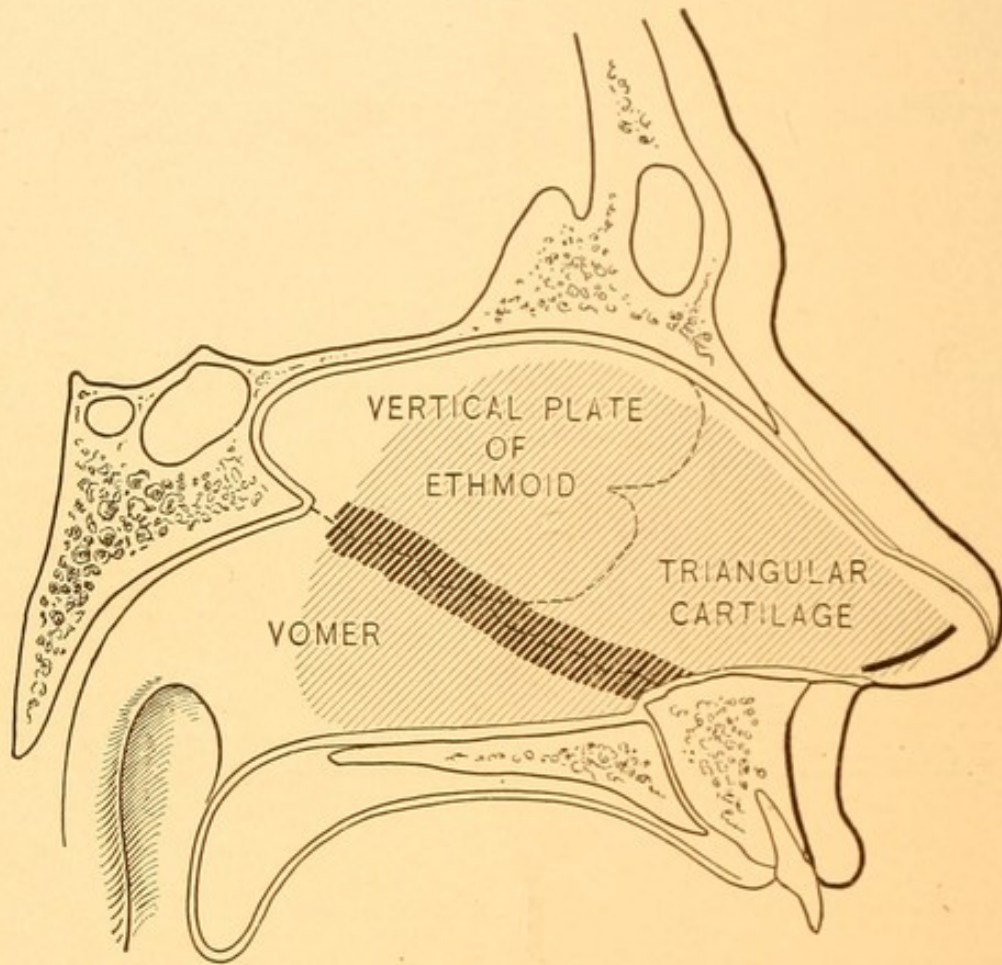
Killian blunt elevator.

this time the mucous membrane is again apt to be perforated. If the sharp elevator is then introduced at the lower portion of the incision and made to hug closely the septum, it will usually be found very easy to run this separator backward along the septum at its junction with the floor and the nasal cavity. From there the mucous membrane can also easily be dissected up to the ridge marking the point of union of the cartilage and voma, where it is again adherent. This leaves now practically the whole of the mucous membrane lifted up from this side of the septum with the

exception of a narrow strip (the darkly shaded part of Fig. 35) which remains attached.

By careful use of the sharp dissector, beginning anteriorly, it is comparatively easy, working alternatively

FIG. 35.

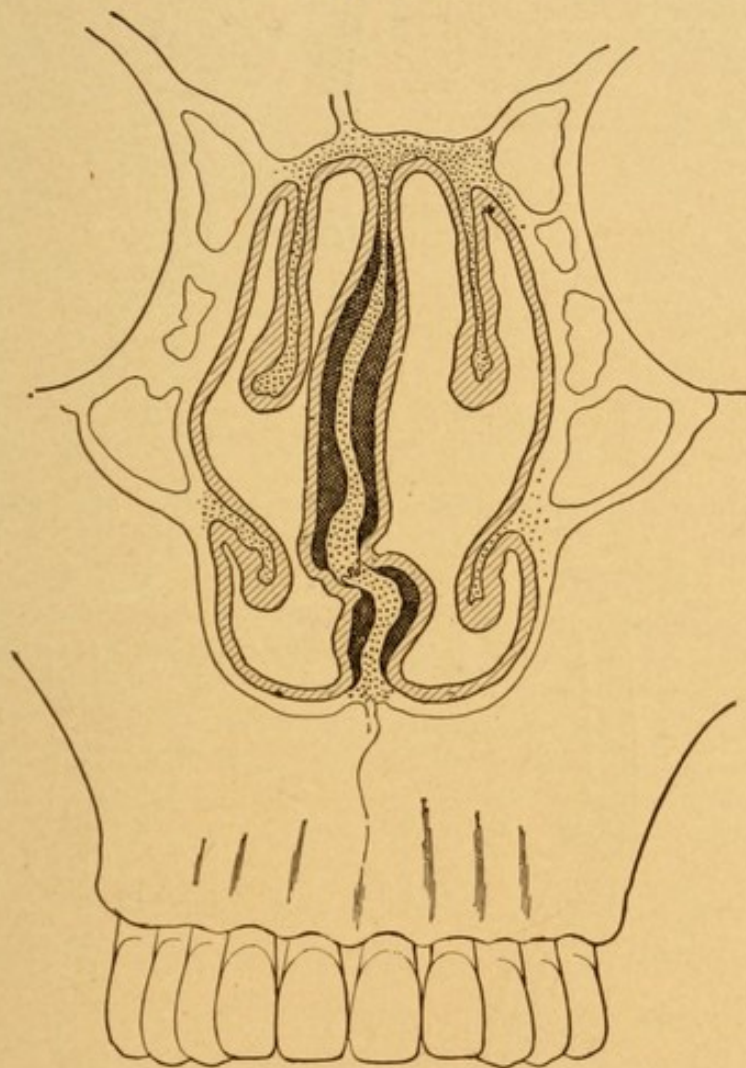


Semi-diagrammatic lateral view of septum. Slightly curved line in front is the line of the mucous membrane incision. The shaded area, the portion of the septum which may be removed if necessary. The darkly shaded area, the part of the muco-periosteum usually very adherent to the bone, consequently easily torn and buttonholed.

from above and below, to lift the membrane along this narrow strip, provided the sharp point of the instrument be invariably kept toward the ridge and away from the mucous membrane. With the index-finger of the left hand placed in the right nasal cavity opposite the line

of the original incision through the mucous membrane and the thumb of the left hand grasping the columna and bending it sharply over, the knife is used to cut through the cartilage down to the perichondrium of the

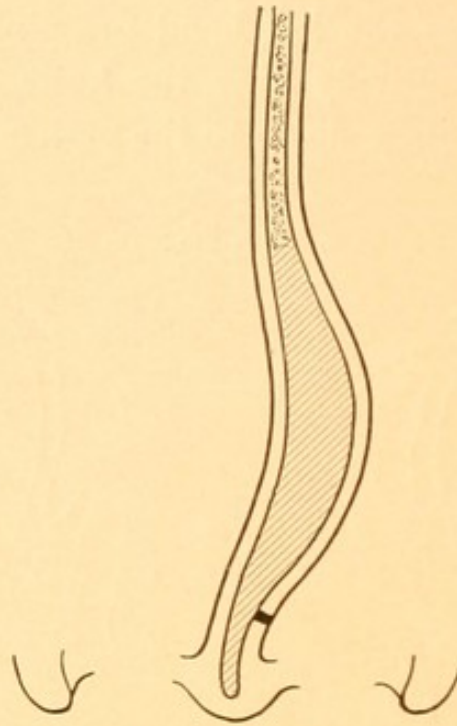
FIG. 36.



Semi-diagrammatic transverse section of nares, indicating the muco-periosteum separated from each side of the septum, above and below the superior border of the vomer, to which it is still attached.

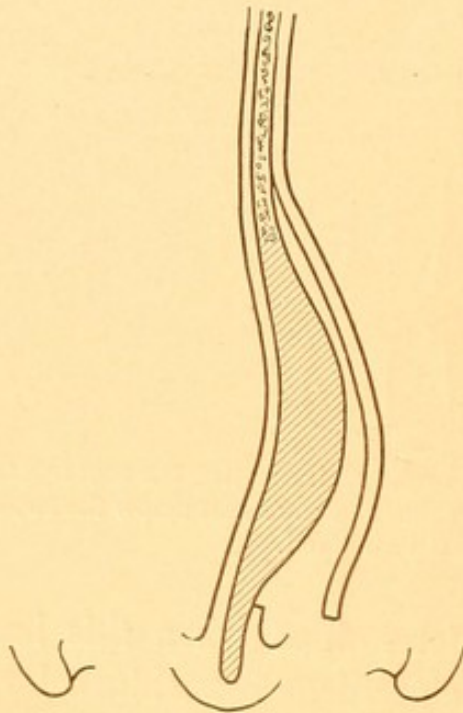
opposite side. It is easily determined when this has been accomplished because the cartilage is a white color, whereas the perichondrium in the opposite nasal cavity is pink in color.

FIG. 37.



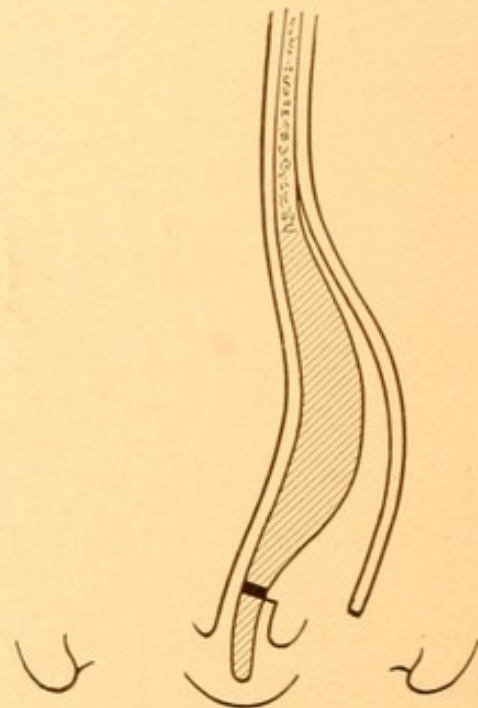
Diagrammatic scheme of submucous resection of septum ; first step, incision on the left side.

FIG. 38.



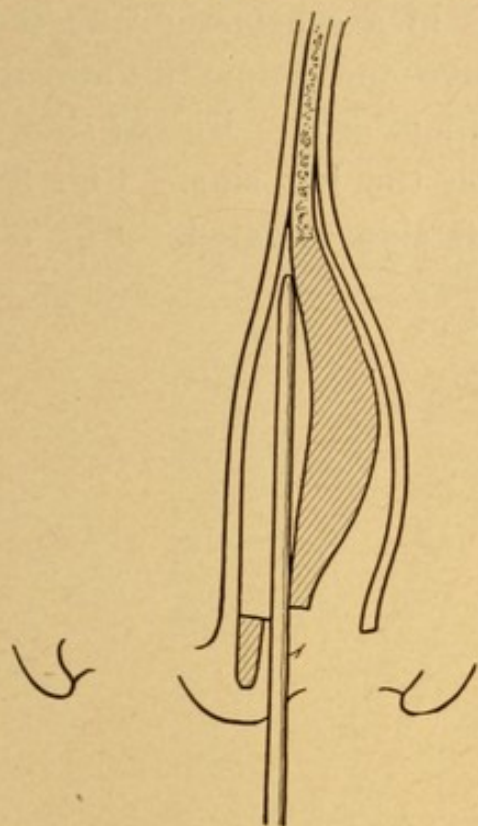
Diagrammatic scheme of submucous resection of septum ; second step, elevation of muco-periosteum.

FIG. 39.



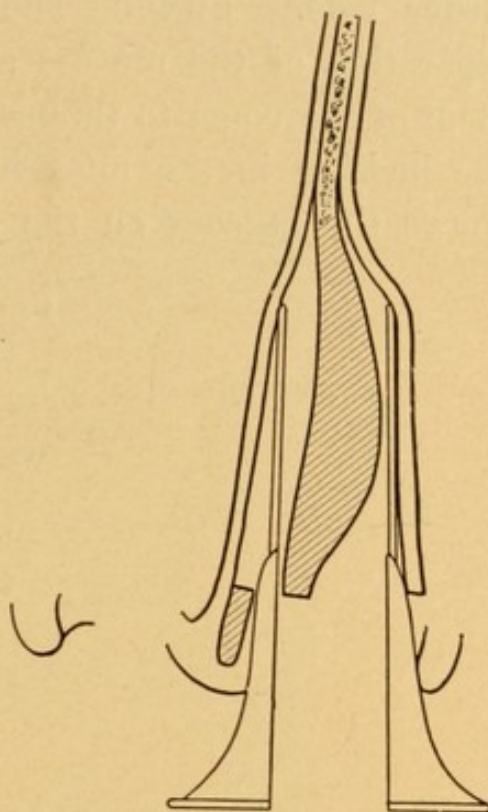
Diagrammatic scheme of submucous resection of septum ; third step, incision through cartilage.

FIG. 40.



Diagrammatic scheme of submucous resection of septum; fourth step: Periosteal elevator passed through incision in cartilage and separating muco-periosteum of opposite side.

FIG. 41.

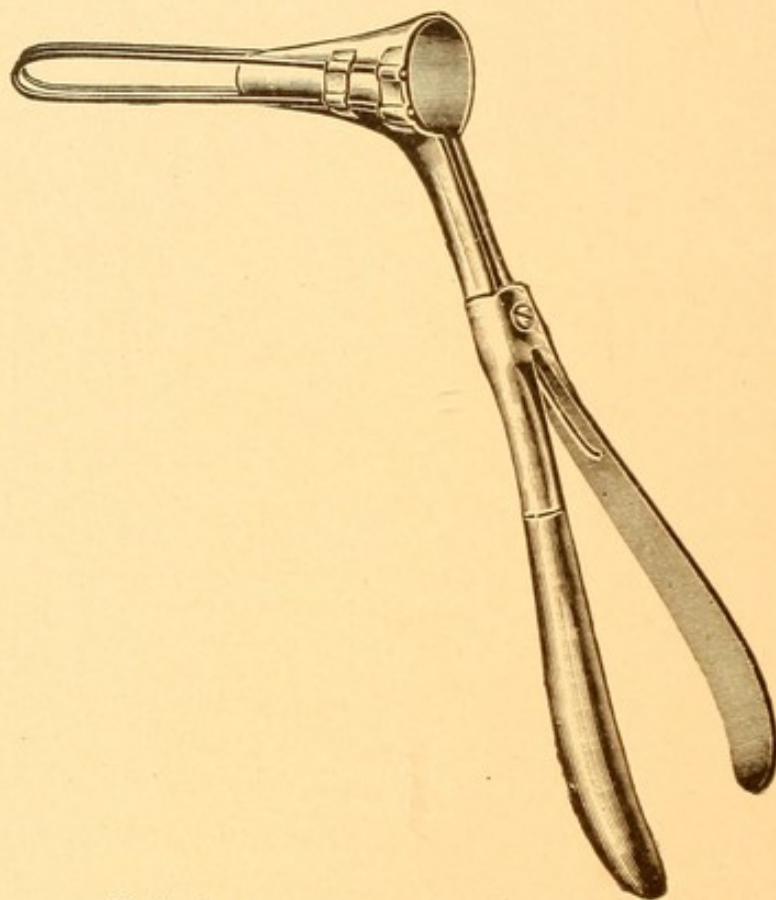


Diagrammatic scheme of submucous resection; fifth step: Blades of Moshier's speculum inserted, one on each side, between the muco-periosteum and cartilage to facilitate removal of cartilage and bone without injury to the muco-periosteum.

The sharp elevator of Killian, the flat edge of which is passed through the incision in the cartilage and lies against the right side of the cartilage, may be easily used to dissect up the perichondrium and cartilage in the right nasal cavity. After this has been done to a slight extent, the dull elevator is utilized as in the other cavity, and the mucous membrane removed from so much of the septum as is desired, beginning first in the upper portion, then in the lower portion along the voma, and finally freeing the portion attached at the junction of the cartilage and the voma. At this stage of the

operation we have a septum free of its membrane on either side. Fig. 36 shows in a schematic way the separation of the mucosa above and below the attachment of the vomer to the maxillary crest. Fig. 37 shows the incision in the mucosa on the left side. Fig. 38 shows the mucosa on the left side elevated. Fig. 39

FIG. 42.

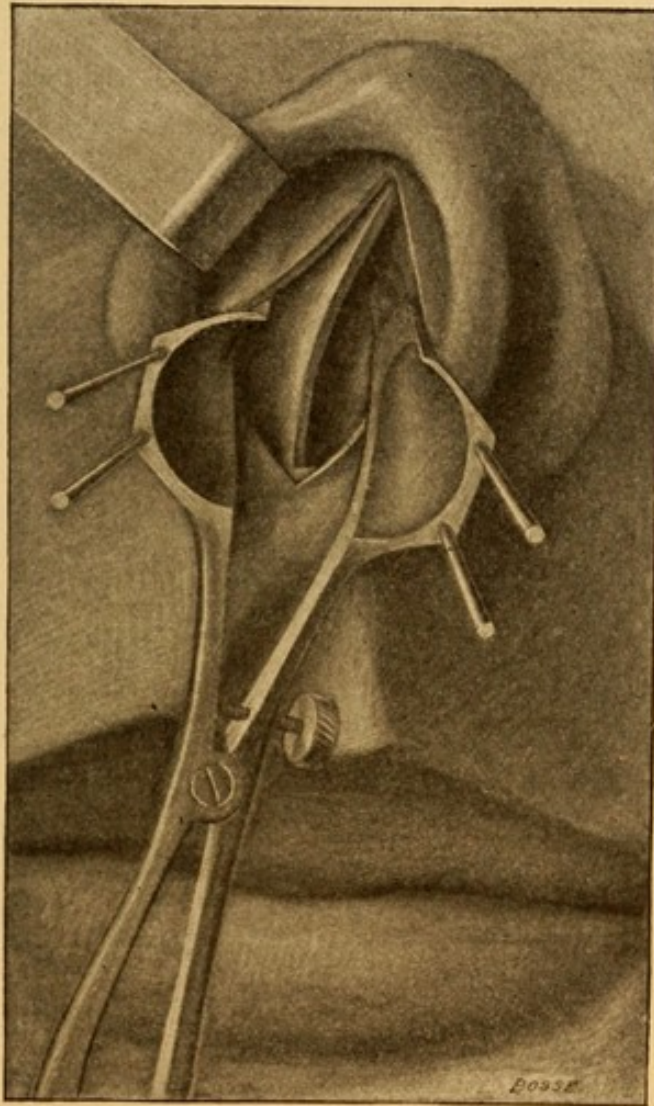


Mosher's submucous operating speculum.

shows the incision through the cartilage down to the opposite mucosa. Fig. 40 shows the elevator lifting the mucosa on the left side. Mosher's submucous speculum (Fig. 42) is then inserted through the incision in the mucous membrane, one blade of the speculum passing between the mucous membrane and the cartilage of one side, and the other passing between the mucous mem-

brane and the cartilage on the other side. Fig. 41 shows the position in horizontal section, while Fig. 43 shows the vertical appearance of the same. When the

FIG. 43.



Moshé's speculum in position.

blades of the speculum are opened the mucous membrane is held at an appreciable distance away from the cartilage.

With the Ballinger swivel-knife (Fig. 44) inserted into the cartilage at the upper portion, and pushed

upward and backward as far as it will go, or in the case of a very marked angular deflection as far as the dissection has thus far gone, then downward and forward, practically the whole of the cartilaginous septum is separated from its attachments. With forceps this portion of the cartilage is easily withdrawn from the incision. It is usually found that some of the cartilage at the upper posterior and lower portions is not removed with the knife

FIG. 44.

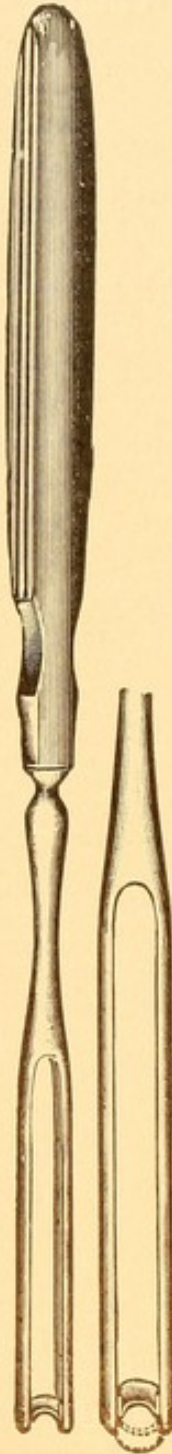
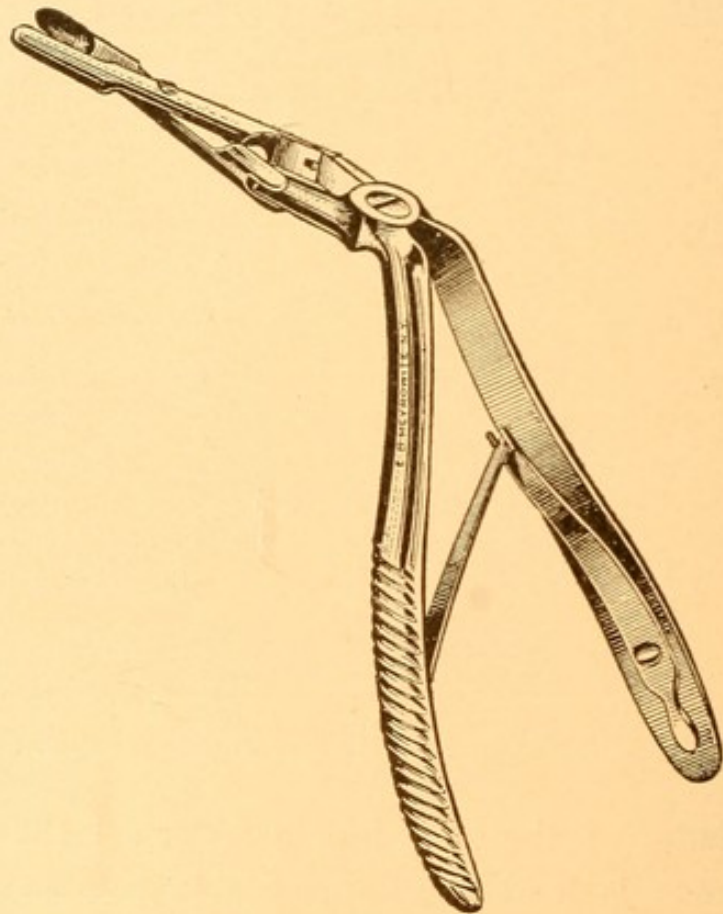
Ballinger
swivel-knife.

FIG. 45.

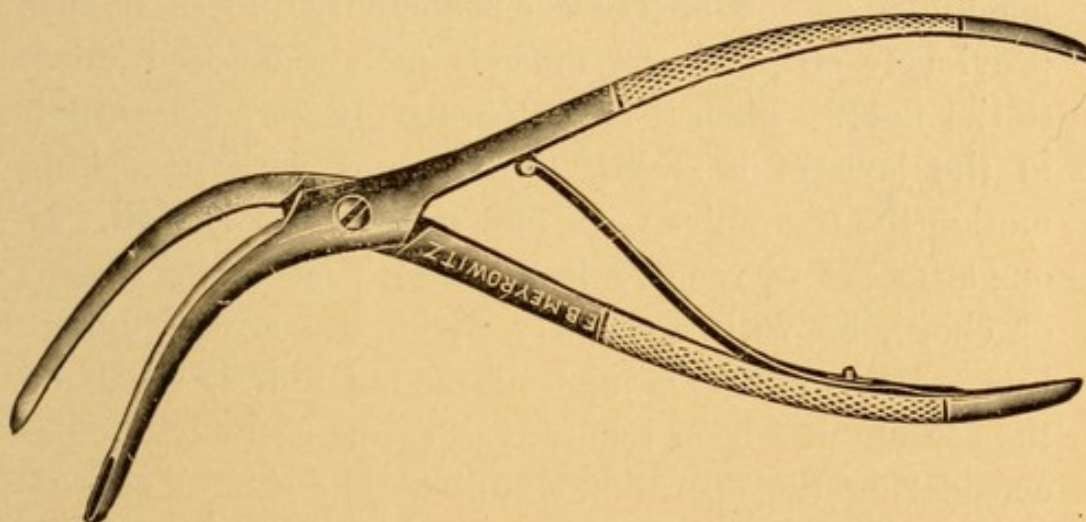


Jansen-Middleton forceps.

and will have to be cut away piecemeal with a suit-

able forceps. The ones which I prefer for this purpose are the Jansen-Middleton (Fig. 45). In those cases where extreme angular deformity exists and only a portion of the membrane has been lifted on either side, it will usually be found to be comparatively easy to introduce a flat elevator, such as the Killian blunt elevator, and straighten out the bend in the septum as soon as the cartilage anterior to the angle has been removed. It is then easy to proceed with the elevation of the remainder of the membrane on each side of the

FIG. 46.



White's bone forceps for cutting away septum.

septum. The removal of the bony portion of the septum in the upper half is usually quite easily accomplished by means of the Jansen-Middleton forceps. It is only occasionally that one meets with thick, dense bone in this region requiring the use of a chisel. When large ridges or spurs appear on the septum in addition to the deflections, it requires no little ingenuity on the part of the operator to separate the membrane from around these. Once, however, the membrane has been freed, a pair of long bone forceps (Fig. 46) may be used

with a twisting movement, breaking them off and removing them. It is never, however, safe to attempt to twist or break any portion of the septum unless the membrane has been thoroughly lifted from it. The portion which is usually most difficult to remove is the thick ridge found at the lower portion of the septum, beginning anteriorly at the anterior end of the voma and extending backward for a distance of one-half to one and one-half inches. Unless this portion of the septum is considerably thickened, I ordinarily do not remove it. But when greatly thickened it oftentimes taxes the ingenuity of the operator considerably unless he has previously stripped the mucous membrane well down to the floor. Then it is comparatively easy to grasp it in the jaws of a strong forceps, and with a rocking motion lift the entire voma and ridge out of its bed. If one attempts to remove it piecemeal, either by forceps or chisel, he will frequently find quite a task before him. When in the opinion of the operator so much of the septum has been removed as seems necessary before considering the operation completed, he should remove the speculum from between the flaps of the mucous membrane, bringing them in apposition, then with the nasal speculum placed in the ordinary manner in the nose he should inspect the cavity and see whether all of the deformity has been corrected. Very frequently I find that the central portion and floor has been well taken care of, but a considerable deformity to one or the other side exists at the upper portion of the septum. This, if allowed to remain, spoils much of the good effect that should and would be obtained if more of the upper portion of the septum were removed. One should invariably leave a thin ridge of cartilage, from one-six-

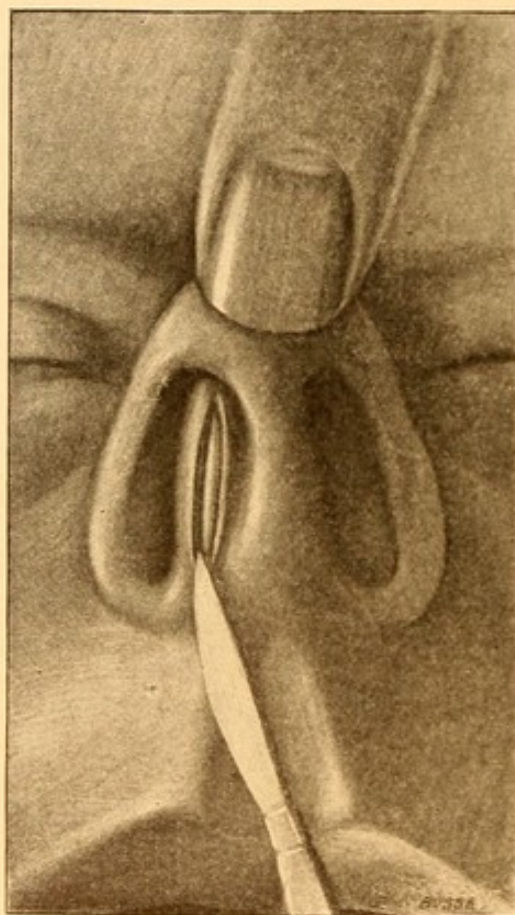
teenth to one-eighth of an inch in height, as a support for the dorsum of the nose, for if all of the cartilage is removed a slight tendency to saddle-back nose may develop. The cartilage and bone having been removed, the space between the flaps should be examined to see that no small particle of bone or cartilage is lying loose between them. The blood-clots should be wiped clean and the two surfaces of the membrane placed in apposition.

Each nasal cavity should then be packed with strips of sterile gauze, into the meshes of which have been rubbed powdered bismuth subnitrate. These strips should be two and one-half inches long and one inch wide. My method of packing is to insert these strips into the nasal cavities alternately, beginning first on the side that the incision is made and then the opposite side. The strip is carried backward the whole length of the nasal cavity and pressed down to the floor, and the septum built up in this way and supported from floor to roof. In my opinion it is as necessary to take the greatest care in the packing of the nose as in the operation, for unless the two surfaces of the septum are kept in even apposition throughout their entire extent from floor to roof, from front to back, and, moreover, unless the packing is so placed as to keep the septum in the median line, one will be greatly disappointed in the result obtained. If the pressure is not equal on the two sides throughout its entire extent, blood-clots will form in the parts that are subject to the least pressure, and it will be found that that portion will be subsequently thicker than the rest of the septum. It will also be found that if the nares are packed unequally so as to deflect the septum, that that deflection will be a

permanent one, and may counterbalance the good effects expected to be derived.

If the anterior part of the septal cartilage is dislocated as shown in Fig. 47, this deformity can be corrected by

FIG. 47.



Dislocation of anterior end of septum to the right and the line of incision most convenient for correcting this type of deformity.

removing the whole of the anterior end of the cartilage, which is not usually done where deviations do not begin so far forward. To do this I find it most convenient to tilt the end of the nose toward the unobstructed side, which leaves the end of the cartilage showing as a white ridge in the vestibule of the obstructed side. The primary incision is made directly on this whitish ridge

and the mucous membrane elevated on either side of the cartilage through this incision. There is no necessity to sew up the incision ; the edges come in close apposition and primary union results.

The packing may be removed at the end of twenty-four hours or, if desired, may be left as long as three to four days. There is usually considerable headache and some oozing from the nose for the first ten or twelve hours after the operation. On removing the packing there is apt to be a little bleeding from the edges of the wound. For two or three hours the nose is comparatively free, but the traumatism resulting from the pressure of the packing and that occurring in its removal, usually results in more or less occlusion of the nose for two or three days. Unless there is considerable secretion in the nasal cavities, I favor leaving this swelling alone, as it gradually subsides. In the event of there being considerable secretion I spray both nasal cavities with a 2 per cent. solution of cocain, and at the end of five minutes syringe the nares with warm normal saline solution.

The submucous resection is a safe and scientific operation ; in simple cases it is easily and comparatively quickly performed. In badly deformed septa and in those which have previously been operated upon with caustics, the saw, or one of the older methods of procedure, the ingenuity and patience of operator and patients are considerably strained. There is seldom any pain during the operation, and the bleeding is seldom enough to obscure the field. Should it do so the operation must be halted while an application of adrenalin on cotton is employed to check the hemorrhage. The time required for the operation is its

greatest drawback ; from an hour to an hour and one-half is no unusual time for a difficult, complicated case.

For the intense headache which begins in a few hours after the completion of the operation, I have found nothing better than cold applications to the forehead and nose and the internal administration of one-half grain of codein. For the slight crusting within the nares, which is often very annoying for a week or so after removing the packing, the most serviceable remedy is white vaselin projected into the nares night and morning from a tube such as dental pastes are put in.

A rare complication is the formation of a hematoma or abscess between the layers of the mucosa. This should be treated in the manner as described for hematoma or abscess of the septum (*q. v.*).

HEMATOMA OF THE SEPTUM.

By this is meant a collection of blood between the mucous membrane of the nose and the septum, usually found at the anterior portion, in the region of the septal cartilage.

Etiology. The one cause of this condition is traumatism, such as blows or falling upon the nose.

Pathology. Hematoma may undergo organization, leaving a thickened condition of the septum at the site of the hematoma, or, if pathogenic germs gain access, suppuration will ensue and an abscess of the septum result.

Symptoms. The symptoms of hematoma depend upon its size. Usually one, sometimes both nostrils, are occluded, and the symptoms of nasal obstruction result.

Pain in the anterior portion of the nasal cavity is frequently experienced. It rarely happens that there is any hemorrhage from the nose as the result of the traumatism, unless some of the tissues in the more posterior portion of the nose are lacerated at the same time. The history is then apt to be that at first there was some bleeding from the nose, but as the hematoma increased in size, by blocking the nose, the blood flowed back into the nasopharynx and was expectorated.

Examination. Examination shows a large swelling of the septum, dark reddish in color, situated anteriorly. The swelling may be prominent enough to be seen without the use of the speculum. Touched with a probe the swelling is found to be soft, and at first fluctuating. After coagulation of the blood has taken place the mucous membrane has a "boggy" feeling, pitting easily on pressure.

Differential Diagnosis. History of traumatism, rapid swelling, and examination with a probe will suffice to make a diagnosis if seen during the first forty-eight hours. After this time it may become a question as to whether it is a simple hematoma or an abscess as a result of infection. In the latter case the temperature of the nose is apt to be higher than that of the other portions of the face. There may even be a rise in body temperature of from one to three degrees, and the patient may complain of a sensation of throbbing in the part.

Prognosis. The prognosis in hematoma of the septum is usually good unless infection takes place. There is almost always some thickening of the septum, which may form a slight impediment to respiration in one or both nostrils.

Treatment. If the hematoma be small, it is better to leave it alone and let nature take its course. If, on the other hand, it be large, completely obstructing one or both nostrils, we deem it advisable to cocaineize the mucous membrane over the hematoma, make a free incision into the most prominent part of it, turn out the clot, and wash the cavity with 1 : 40 carbolic acid solution. The anterior portion of the nasal cavity should then be plugged with antiseptic gauze, either bichloride or iodoform, which serves the double purpose of making slight pressure against the site of the hematoma and preventing the entrance of germs. The gauze should be renewed each twenty-four hours. Healing is usually complete in from three to five days.

ABSCESS OF THE SEPTUM.

A collection of pus in the mucous membrane and the underlying structures of the septum.

Etiology. Like hematoma of the septum, which it usually follows, this condition is due to traumatism. It may occur as a result of the access of germs beneath the mucous membrane, from an ulcer or operation, but such a condition is rare.

Pathology. The existence of pus between the mucous membrane and the septum, if allowed to remain a great while, deprives the underlying structures of their nourishment, which is derived through the blood-vessels of the mucous membrane, and consequently necrosis of the cartilage or bone may result. When the abscess discharges spontaneously, or as a result of operative interference, it is not infrequent to find perforation of the septum as a result of the necrosis.

Symptoms. The symptoms of abscess of the septum are usually those of hematoma, with the addition of an increase in the local temperature, possible elevation of body temperature of from one to three degrees, and considerable pain of a throbbing, pulsating character.

Examination. Examination in a case of abscess of the septum reveals a fluctuating swelling, which may be visible in one or both nasal cavities. The color may vary from a reddish to a yellowish, according to the amount of pus in the tumor and the thickness of the mucous membrane.

Differential Diagnosis. It may be difficult to determine in a given case whether the soft fluctuating swelling is merely a hematoma or an abscess, except by the symptoms or after an incision has been made in the swelling.

Prognosis. The prognosis depends upon the length of time the abscess has existed. If seen early and evacuated, healing takes place promptly. If it has been of long standing, there is great danger of perforation of the septum, and it is well to state this fact to the patient, in order that the physician may protect himself in these cases. Where total destruction of the cartilaginous portion of the septum has taken place the nose is apt to fall in, producing the deformity known as the "saddle-back nose."

Treatment. The only treatment for this condition lies in incising the abscess, cocaine anesthesia usually sufficing, evacuating the pus, washing out the cavity with 1 : 40 carbolic acid or 1 : 3000 bichloride of mercury solution, and packing the nostril as described for hematoma. Pus may re-accumulate under the mucous

membrane of the septum, and if it does it should be evacuated. If the abscess cavity is very large, it is best to insert a Bernay's splint (Fig. 29) in each nostril. It holds the two surfaces of mucous membrane in apposition and prevents the subsequent deformity of the nose. The splints must be renewed daily and the nose irrigated with normal saline to prevent sepsis.

PERFORATION OF THE SEPTUM.

Etiology and Pathology. From an etiological standpoint perforations of the septum may be divided into those which are in the cartilaginous and those which involve the bony portion. The more common form is the rounded perforation situated in the cartilaginous portion. It varies in size from a very small hole to one large enough to allow the passage of the end of the forefinger. This form does not involve the bony portion, although its posterior border may be formed by the anterior portion of the bony septum. It may be due to a necrosis of cartilage as described in the article on abscess of the septum, but it more frequently results from the ulceration produced by attempts at removing thickened and dried mucus resting upon this portion of the septum. The finger-nail produces at first a slight ulcer, upon which a scab forms. Constant picking at these scabs finally causes a deepening of the ulcer until perforation results. Scab formation on the site of a spur that has been removed, if continually picked at, will also end in the production of a perforating ulcer. Perforations of the septum are sometimes accidentally made by an operator in using a saw, trephine, or other instrument for the removal of spurs, where, in addition

*Cartilag-
inous
Perforation
1. Abscess
septum
2. Picking
of scab =
ulcer
3. Operations*

to removal of the spur, too much of the septal tissue is removed. Perforations involving the bony portion of the septum are almost invariably the result of necrosis of the bone, as seen in syphilis and very rarely in tuberculosis of the nose.

Bony Perforation
1 Syphilis
2 T.B.

Symptoms. The symptoms produced by an ulcer limited to the cartilaginous portion of the septum are usually those resulting from the deposit of crust-like scabs upon the margins of the ulcer, and the itching, tickling, and irresistible desire to remove the same. At times these may be thick enough to give rise to some obstruction, which may add to the patient's desire to remove them. The picking may be followed by hemorrhage, usually slight but occasionally severe. Enough of the septum at the upper and anterior portion usually remains to act as a support to the soft tissues of the nose, so that no deformity is visible externally. Where, however, the entire cartilaginous portion of the septum is destroyed, as it may be in syphilis, a sinking in of the nose takes place at the lower end of the nasal bone, and the deformity known as "saddle-back nose" is seen. During the time that the necrosis of the bony portion of the nose is active the patient will have a purulent discharge, accompanied by a very fetid odor. Pain is often a prominent symptom in these cases.

Examination. Perforation of the cartilaginous portion is readily detected when the nostril is dilated. The margins of the perforation have a dull-white, shiny appearance, owing to the presence of new connective tissue. The edges of the perforation frequently are the sites of dried mucus, or, where this has been recently removed, an ulcerating, perhaps bleeding, area may be seen. Where the bony portion of the septum

is involved, if the process of exudation is going on, large, thick, greenish-black crusts cover the edges of the perforation, and when these have been softened and removed by washing examination may show pieces of bone freely movable when touched with a probe. It is very common to find in these cases syphilitic necrosis of the turbinal bones as well.

Differential Diagnosis. The existence of a perforation of the septum was once thought to be an evidence of syphilis. It is now known that perforations of the cartilaginous portion of the septum alone are seldom, if ever, syphilitic in their origin. It is only when the bony portion of the septum is involved that this disease is to be suspected, although here we should bear in mind that tuberculosis and lupus also may destroy the bony portion of the septum.

Prognosis. A septum once perforated always remains in that condition.

Treatment. The treatment in this disease should be directed to the prevention of the annoying symptoms accompanying the perforation—that is, during the irritation of the scab formation patients must be cautioned that under no circumstances should they remove these scabs by picking. Thorough softening of the scabs by the use of the wash bottle, as described in the article on atrophic rhinitis, and subsequent blowing of the nose, will allow the larger ones to be easily blown out. The margin of the perforation should then be pencilled with some antiseptic healing ointment. This will tend to prevent the re-formation of the very thick scabs and heal the ulcerating surface upon which they form. Five per cent. ichthyol ointment, ointment of the yellow oxide of mercury, and 10 per cent. aristol ointment are all useful for this purpose. When the margins of

the ulcer are covered with exuberant or unhealthy granulation tissue they should be cauterized every fifth day with nitrate of silver fused upon the end of an applicator. In addition to the local treatment, where perforation exists in the bony portion of the septum, constitutional treatment for syphilis or tuberculosis, depending upon which of these is causing the necrosis, should be employed.

When the perforation is not too large, a plastic operation for the closure of the opening may be undertaken with fair prospect of success.

The mucous membrane in the centre of the margin of the perforation is split with a knife. With the sharp dissector of Killian (Fig. 33) the mucoperiosteum is dissected up on *one* side for a distance posteriorly of a little more than the diameter of the perforation. A vertical cut is then made in the mucosa at the posterior part of the elevated membrane. By means of sutures the freshened edges of the perforation are brought into apposition, thus leaving a portion of the cartilage and bone posterior to the former perforation denuded of covering, which fills by granulations. The perforation is covered by a single layer of mucous membrane, provided the tension on the sutures is not so great as to cause them to cut through.

TUBERCULOSIS OF THE NOSE.

A chronic inflammation of the mucous membrane of the nose due to the action of the tubercle bacilli.

Etiology. A few instances of primary tuberculosis of the nose have been reported, but the majority of cases

of this disease are secondary to tuberculosis elsewhere in the body, usually of the lungs. The most common mode of infection appears to be through picking at the nose, the fingers being infected with tubercle bacilli. Any inflammatory process resulting in ulceration and consequent scab formation in a patient suffering from pulmonary tuberculosis predisposes him to tubercular rhinitis. The nose is the least frequent seat of tuberculosis of any of the divisions of the respiratory tract.

*1 Tumor
2 ulcer.* **Pathology.** Two forms of tubercular process are observed—one a tubercular infiltration resulting in a well-defined tumor, usually found on the inferior turbinate, floor of the nose, or very rarely on the septum; the other an ulceration involving the septum at its anterior portion, the floor of the nose, or rarely the turbinal tissues. In the former variety there are a round-cell infiltration and a giant-cell formation in a circumscribed area, producing a tumor that may vary in size from a match-head to a pea. The surface is frequently lobulated and papillomatous in appearance.

The ulcer is usually shallow, its edges irregular and not surrounded by a zone of inflammatory swelling. A white or slightly yellow secretion, in which a few tubercle bacilli may be found, often bathes the ulcer.

In rare cases, when the ulcer involves the turbinal tissues, the turbinated bone may be the seat of necrosis.

Symptoms. The symptoms of tuberculosis of the nose are either those due to obstruction from the presence of the tubercular tumor, or, in case of an ulcer, a thick, purulent discharge, with occasional hemorrhage from the ulcerated area. The secretion is often very

tenacious and is blown out with difficulty. When it is allowed to accumulate in the nares it may produce obstruction to respiration and have a slightly fetid odor.

Examination. Examination of the nose will show one of the two forms described under pathology. It is usual to find the ulcer in only one nasal cavity, and on the cartilaginous part of the septum just within the nostril. A few grayish-white tubercles may occasionally be seen beneath the mucous membrane in the immediate neighborhood of the ulcer. The rest of the mucosa is very pale, almost bloodless. One should always carefully examine for tubercle bacilli the secretions from any ulcers in the nose in a tubercular subject. Repeated examinations may have to be made before they are found. A more certain method of determining the character of such a process is to cocaineize some of the tissue at the circumference of the ulcer and excise a small portion of it. When hardened and thin sections are stained by Gram's method their tubercular nature is more evident.

Differential Diagnosis. Tubercular infiltration may be mistaken for papilloma of the nose. It is advisable to examine microscopically every papillomatous tumor taken from the nose of a tubercular subject, for in no other way can the true nature of the growth be determined.

Tubercular ulcers may be mistaken for syphilitic ulcers. The former are much slower in their growth; but rarely involve the bone; are accompanied by less pain, discharge, and odor to the secretions; their margins are more irregular, less elevated, and scarcely, if at all, congested.

The finding of tubercle bacilli in the secretion or in the tissue taken from the ulcer will determine the character of the ulcerative process. The presence of pulmonary tuberculosis may assist in the diagnosis, but it must be remembered that a tubercular patient may also suffer from syphilis, and that a syphilitic ulcer of the nose may become infected with tubercle bacilli.

Prognosis. The process may exist for a long time, resisting treatment, but seldom is accompanied by the grave symptoms met with in pharyngeal and laryngeal tuberculosis. There is a possibility of the disease being arrested and the ulcer healing.

Treatment. The ulcer should be cleansed twice daily of all secretion by means of a simple saline solution, using the anterior nasal syringe (Fig. 19). The surface of the ulcer should be painted with a 10 per cent. solution of cocaine. After waiting ten minutes for anesthesia to be produced the diseased area should be thoroughly curetted with the Grünwald curette (Fig. 49). Any small areas found to be diseased at a subsequent examination may be cauterized with the galvanocautery point under cocaine anesthesia. Iodoform, or, if this is very disagreeable to the patient, then aristol, should be insufflated daily. The general health of the patient must be built up with tonics, and a pulmonary lesion, if existing, must be given appropriate treatment.

clean
anesthe
aristol.
general
treatment.

SYPHILIS OF THE NOSE.

The lesions found in syphilis of the nose are conveniently divided into two forms: A. Acquired. B. Congenital.

A. Acquired Syphilis of the Nose.

This may manifest itself as : 1. The primary sore or hard chancre. 2. Secondary syphilis, the erythema and the mucous patch. 3. Tertiary syphilis, the gumma or the ulceration consequent upon its necrosis.

1. Primary Syphilis of the Nose. Chancre.

Etiology. The nose is very rarely the seat of a primary chancre. A few cases of chancre of the septum just within the nostril at the muco-cutaneous juncture of the nose are recorded in literature. Infection may be carried to these parts, especially where there are abrasions of the mucous membrane, by articles that have become infected by contact with a chancre.

Symptoms. The symptoms of chancre of the nose are a hard, indurated mass, with slight ulceration of the surface and with but little discharge from the ulcer. There is little or no pain complained of at the site of the chancre. The glands of the neck, especially those under the jaw of the affected side, are greatly enlarged and very hard to the touch. If allowed to take its course without treatment, other than that of cleanliness, the chancre usually heals in from four to ten weeks.

Differential Diagnosis. A chancre of the nose may for a few days be mistaken for any form of slight ulceration or for malignant disease. If, however, the other manifestations of syphilis be carefully watched for, they will usually be observed in a few weeks. The glandular enlargement may be mistaken for malignant disease, but malignant disease of the nose is seldom accompanied in its early stage by the marked glandular enlargement

found in chancre. The ulceration in malignant disease may gradually extend until it involves a considerable area. A chancre is seldom larger than a silver three-cent piece.

Prognosis. A chancre usually disappears in the course of a few weeks, and leaves no scar or but a slight one.

Treatment. If there is doubt as to whether any particular ulcer of the nose is a chancre or not, it is better simply to treat the ulcer with cleanliness and an antiseptic powder, such as aristol, nosophen, or europhen, until such time as one can be certain as to whether the ulcer is or is not syphilitic. The object of this is to ascertain positively the nature of the lesion. If a small ulcer heals after the internal administration of antisypilitic treatment, we may do our patient a great injustice in thinking that he had syphilis. He would go through life with the idea that he had this disease, and probably would suffer unnecessarily from the depression of spirits to which so many syphilitics are subject. As soon as the diagnosis is *positive*, treatment in this stage is to be the same as that for chancre in any other part of the body—namely, the internal administration of mercury. The form which we prefer is that of the protoiodide. One-quarter grain pills of this drug should be prescribed.

We are in the habit of beginning with one pill three times a day, and every other day increasing this dose by one pill until unfavorable symptoms, such as diarrhea or tenderness of the gums, are complained of. This full dose varies usually from eight to fifteen pills per day.

When the maximum dose is found the patient should continue to take this for six months, at the end of

which time he may stop for a couple of weeks and then resume the maximum dose for three months. Similar periods of rest and medication should be continued throughout the first two years after the initial lesion. If the patient is very anemic, cod-liver oil and iron should also be administered.

The quickest and most reliable, though more painful, method of antisyphilitic treatment is the hypodermic one. Deep injections into the buttocks once a week of some of the soluble salts of mercury enables the physician to regulate the dosage according to the severity of the infection.

2. *Secondary Syphilis of the Nose. The Erythema and the Mucous Patch.*

Etiology. Secondary manifestations in the nose are not as common as those in the pharynx. They may appear at any time between the disappearance of the chancre and two years thereafter. They are found usually from three to nine months after the chancre has disappeared, whatever its position on the body may have been.

Pathology. The syphilitic erythema is characterized by a deep-red injection of the mucous membrane, which is often mottled in appearance.

The mucous patch is the result of a necrosis of the superficial epithelium, whereby these cells have a grayish-white appearance. The aspect is very much like that which is produced by lightly touching a mucous membrane with a strong solution of nitrate of silver. The exudate is not perceptibly elevated above the surrounding mucous membrane, in this respect differing from other exudates. The remaining mucosa has the erythe-

matous appearance described above, and often a very narrow zone of active hyperemia surrounds the patch.

Symptoms. The symptoms of secondary syphilis in the nose are almost identical with those of acute rhinitis, except that they persist for a much longer time. There is a profuse watery discharge, with a sense of burning and smarting in the mucous membrane. Sneezing is also frequent. Patients usually complain of a sore-throat as well, and it is for the latter that they more frequently apply for treatment, the nasal lesion only being discovered during the examination of the patient. Nocturnal headaches, pains in the joints, and falling out of the hair should lead one to regard with suspicion an accompanying rhinitis.

Examination. The condition either of erythema or mucous patch, described under pathology, will be found. The patches are usually observed on the septum, inferior turbinate, and at the junction of the alæ of the nose and upper lip. Other evidences of syphilis will usually be present, such as mucous patches on the pillars of the fauces, soft palate, tonsils, tongue, or lips; enlarged glands in the sub-occipital, femoral, and epitrochlear regions, and macular or papular syphilides of the skin. A history of a chancre some weeks before can usually be obtained.

Differential Diagnosis. It is difficult to mistake secondary syphilis of the nose for any other disease when a careful history is taken and a thorough examination is made. The nose is rarely the only organ affected, and should the first manifestation of secondary syphilis appear here it is quickly followed by other evidences of this stage of the disease.

Prognosis. A mucous patch in the nose usually disappears in from two to six weeks when appropriate

treatment is given. No trace is usually left of the site of the mucous patch. The erythema may persist for from two to four months. Should these patients fail to follow the instructions as to internal medication, the condition may reappear at any time within two years following the disappearance of the chancre.

Treatment. The treatment of the secondary lesions must be general and local. The general treatment is the same as that described for the primary sore. Where patients do not bear mercury well by the mouth, or where it is difficult for them to become quickly saturated, inunction of blue ointment or the oleate of mercury, 5 or 10 per cent., should be employed in combination with the internal medication. A mass the size of a pea should be rubbed into the skin of the thigh or back night and morning. Where for any reason it is desired to bring a patient under the influence of mercury quickly we are in the habit of directing him to some establishment where mercurial baths are given. Care must be taken that salivation is not produced.

The local treatment consists in touching the mucous patches every third day with nitrate of silver fused upon a probe. If there is much secretion from the mucous patches, it is best to prescribe a cleansing spray, such as Dobell's solution or an alkaline spray.

3. *Tertiary Syphilis of the Nose. The Gumma and the Syphilitic Ulcer.*

Etiology. Gummata and syphilitic ulcers may appear at any time after two years from the date of the chancre. They are seldom seen before the fifth year, and often as late as the twentieth.

Pathology. The gumma consists of a mass of round cells, with here and there a giant-cell. When the cell proliferation is rapid their mutual pressure induces necrosis, and ulceration is apt to ensue. Gummata are found on the septum and turbinal tissues. They occasionally involve the nasal bones and the alæ of the nose.

Syphilitic ulcers are deep, usually involving the cartilage and bone of the affected parts. Their margins are elevated and surrounded by a broad zone of hyperemia. There is an abundant secretion of pus from their surfaces. When the cartilage or bone is involved the secretions have a very foul odor.

Extensive necrosis of the septum, nasal bones, or alæ of the nose gives rise to great deformity, producing in the first case the deformity known as "saddle-back nose," in the other cases often leaving but a small portion of the organ.

Symptoms. In the early stage a gumma often gives rise to no symptoms unless it be of large size, when more or less obstruction to nasal respiration will be complained of. As necrosis begins pain of a throbbing character may be experienced. In a few days this will be followed by a discharge of muco-pus having a very foul odor, perceptible to the patient as well as to those with whom he comes in contact. The secretions frequently become dried within the nose and are blown out as thick crusts, which may take the form of casts of the nasal cavities. Occasionally pieces of necrosed bone or cartilage will be found in the secretion. Slight and even severe hemorrhages may occur.

Examination. The examination in the stage of gumma will reveal a tumor which is bright red and of an even or slightly lobulated contour. It may be firm in

consistency, or softened in the centre if necrosis is beginning. The gumma, however, owing to the few symptoms to which it gives rise, is not often seen until softening and ulceration have begun. The ulcer presents the appearance given in the pathology. The probe not infrequently detects bare and loose bone.

Differential Diagnosis. A gumma may be mistaken for a spur, an hypertrophy of the turbinal tissues, or a malignant growth.

It will sometimes be difficult to differentiate between a spur and a gumma when seen for the first time, but spurs are usually paler in color and more firm in consistency. Their growth, too, is much slower than that of a gumma. The softening and ulceration which are found in a gumma will reveal the true character. Large doses of potassium iodide cause the gumma to disappear but do not affect spurs.

From an hypertrophied turbinate a gumma may be differentiated by the local swelling and greater hardness. Potassium iodide causes a gumma to disappear, while it does not affect an hypertrophied turbinate.

A malignant growth of the nose may for a time be confounded with a gumma. In the former case the slower growth, the greater pain, and the tendency to bleed when touched with a probe are quite characteristic. A malignant growth will ulcerate, but it never leaves the deep, excoriated ulcer seen in syphilis. The administration of large doses of potassium iodide and the excision of a piece of the growth, which should be examined microscopically, suffice for differentiating between them.

Prognosis. The gumma, if seen early and proper antisyphilitic treatment given, may be absorbed without undergoing necrosis. If necrosis takes place, destruc-

tion of the tissues of the nose, with permanent loss of substance, invariably results. If a considerable portion of the septum is destroyed, falling in of the bridge of the nose will ensue.

HI

Treatment. In the constitutional treatment of tertiary syphilis the iodide of potassium should be the drug relied upon. It should be given in doses of fifteen grains three times daily, and rapidly increased in amount until the patient is taking from thirty to sixty grains three times a day. In some cases the administration of a small amount of mercury, one-thirtieth of a grain of the bichloride in combination with the potassium iodide, may be advantageous.

clean

The local treatment of the ulcerating gumma should consist in keeping the parts as thoroughly cleansed as possible with a disinfecting fluid. The wash bottle, as described for the treatment of atrophic rhinitis, is the best means of cleansing the nose in these cases, and the fluid that will most quickly control the fetor is the solution of permanganate of potassium there recommended. Any loose dead bone detected by the probe in the nasal cavity should be extracted with a pair of forceps, as the mere presence of this bone acts as an irritant, increasing the ulceration and discharge. After cleansing the ulcer insufflations of aristol or nosophen assist in the healing.

B. Congenital or Inherited Syphilis of the Nose.

This form of syphilis may appear in two stages, giving rise to (1) secondary manifestations and (2) tertiary manifestations.

1. *Secondary Manifestations of Congenital Syphilis of the Nose.*

Etiology. These usually appear between the first and sixth week after birth. Children are occasionally born with them, or the symptoms may be delayed until the third month.

Pathology. The pathological processes are identical with those of secondary syphilis of the acquired form—viz., the erythema and the mucous patch (*q. v.*). Owing to the small size of the nasal cavities in the child, the congestion of its nasal mucous membranes usually produces complete occlusion of the nose.

Symptoms. The symptoms which attract the greatest attention in these infants are difficult respiration, snoring, and inability to take the breast or bottle for more than a second or two without letting go to breathe through the mouth. These, with an almost continual discharge from the nose of yellowish-white mucus or muco-pus, which can be removed only with difficulty, make up the condition to which the name “snuffles” is ordinarily applied. Any severe acute rhinitis in a child will give rise to the same symptoms, but the peculiarity of those of a syphilitic origin is the chronicity of the attack, which often persists for weeks, while those of simple acute rhinitis may last only a day or two. Children usually emaciate rapidly, and their skin has a wrinkled appearance, making them look very old.

Examination. The examination of the interior of the nose in such a young child is well nigh impossible. The mucous patches may be observed at the junction of the alæ of the nose and upper lip, and at the corners of the mouth and on the fauces. These, together with the enlarged glands found in the neck, axillæ.

Snuffles.

and groin, and the eruptions on the skin, should leave no doubt as to the character of the process in the nose.

Differential Diagnosis. It is possible that for a few days secondary syphilis may be mistaken for "snuffles" due to an acute cold in the head. Should the symptoms persist careful search for the manifestations of syphilis in other regions rarely fails to find other evidences sufficient to enable a correct diagnosis to be made.

Prognosis. With the best of treatment it will be several weeks and perhaps three or four months before the children recover. Owing to the effects of the other manifestations of syphilis very many of them succumb to the disease.

Hag. **Treatment.** This should be both constitutional and local. The constitutional treatment consists in administering mercury by the mouth, by inunction, or by both of these methods combined.

The best form of mercury for administration by the mouth is hydrarg. cum creta. This may be given in doses varying from one-quarter of a grain to one grain three times a day. The powder is best suspended in a teaspoonful of milk and thus administered.

For inunction the oleate of mercury (2 per cent.) is perhaps the best. A mass the size of a pea should be rubbed over the abdomen after the daily bath and a flannel binder loosely applied. The wriggling of the child assists greatly in the absorption, owing to the friction of the bandage upon the skin.

Cleanse The local treatment consists in syringing (Fig. 19) the nose three times each day with a solution made from normal saline tablets, page 69. After this has been accomplished the child should be placed on its back, with the head slightly lower than the body, and

with a medicine dropper five drops of the following solution are slowly dropped into each nostril :

R.—Aristol	gr. xxv.
Menthol	gr. xx.
Ol. olivæ	℥j.—M.

2. *Tertiary Manifestations of Congenital Syphilis of the Nose.*

These occur at any time after the third and up to the twentieth year. They are most commonly seen between the seventh and fourteenth years. They appear as the gumma and the subsequent ulcer, and require no special description beyond that which has been given for tertiary syphilis in the acquired form. The hard palate is often involved, and an opening through it between the mouth and the nose frequently results, giving rise to the peculiar voice met with in cleft palate.

FOREIGN BODIES IN THE NOSE.

Etiology. Foreign bodies in the nose are most frequently met with in early childhood, from the time the infant begins to creep. Articles found upon the floor are frequently inserted into the nostril. These substances vary from a shoe-button, pieces of wood, to, in fact, almost any substance small enough to be inserted into the nostril. It occasionally happens that articles held in the mouth pass part of the way down the digestive tract in the act of swallowing, and are vomited and lodged in the posterior nares.

Pathology. Foreign bodies act as sources of irritation, producing hyperemia and subsequently ulceration of the mucous membrane. In this stage the discharge may be fetid and excoriate the nostrils and upper lip.

Cases have been reported in which foreign bodies remaining in the nose for some years have become encysted.

Symptoms. The pain produced by the presence of a foreign body, and the sense of discomfort, may be sufficient, when the child is old enough to talk, to cause it to call the parents' attention to the nose. Sneezing and a watery discharge from one nostril often occur soon after the introduction. After two or three days the discharge becomes thicker, mucopurulent, possibly fetid, with a tendency to excoriate the tissues over which it flows. Mouth-breathing, especially at night, and snoring are usually observed. In older children there may be headache, suffusion of the eyes, and earache on the side on which the foreign body lies.

Examination. Examination of the nasal cavities of young children, owing to the fear that they have of physicians and the tenderness of the nostril on the affected side, can seldom be thoroughly made without the administration of an anesthetic. A few whiffs of chloroform, administered upon a handkerchief, will suffice to render the child quiet, so that a thorough examination of the nasal cavities can be made. It is not necessary to carry the anesthesia beyond the primary stage. If the foreign body has only recently been inserted, it will usually be found situated along the floor of the nose just within the vestibule, impacted between the inferior turbinate and the septum. If several days have elapsed since its introduction, muco-pus or even a distinct membrane may hide the foreign body. Gentle manipulation with a probe, after wiping away the secretion, will detect the presence of the foreign body. One should take care in introducing the probe that the foreign body is not pushed further back in the nasal cavity.

Differential Diagnosis. A unilateral discharge from the nose in a child should always make the physician suspicious of a foreign body in it. The character of the discharge may resemble that seen in nasal diphtheria, but in the latter disease the discharge is usually bilateral and accompanied by other evidences of diphtheria, as in the pharynx, and a gradual enlargement of the cervical lymphatic glands. In older persons the character of the discharge is often like that found in rhinoliths, syphilitic necrosis, or empyema of one of the accessory sinuses. Thorough cocainization and subsequent examination of the nose with a probe should detect a foreign body if present.

Treatment. If the foreign body is hard or rounded, it is best removed by taking an ordinary silver probe and bending it one-eighth of an inch from the tip, so as to form a right angle. The probe is now carried into the nose, so that the bent portion lies flat against the septum, and is pushed on until it is estimated that the bend is beyond the posterior portion of the foreign body. The probe is then rotated through an angle of ninety degrees, so that the tip of the probe points toward the outer wall of the nasal cavity. A sudden forward movement of the probe will then remove the foreign body. It sometimes happens that the probe, in the first attempt, passes either above or below the foreign body. If this occurs, it will be an indication that the operator should depress or elevate the shaft of the probe, so as to bring the bent portion opposite the middle of the foreign body.

If the foreign body be soft in character, then it may be easily grasped and removed with a pair of forceps. If the foreign body is lodged well in the posterior portion of the nasal cavity, it is sometimes easier to push

it back into the nasopharynx with a cotton-wound applicator, than to extract it through the anterior nares. If the child is under a general anesthetic, it should be held by an assistant with the head down, for fear of the foreign body dropping into the larynx. In the absence of any other instrument, a hair-pin, bent as above described, may be used. Recently introduced foreign bodies may also be removed by placing a piece of cheesecloth across the open mouth of the patient, the free nostril being closed with the finger, and forcibly blowing into the child's mouth. The blast of air forced through the obstructed nostril may expel the foreign body.

RHINOLITHS (Nasal Calculi).

Etiology. Rhinoliths are found more frequently in women than in men, and are due to an excess in and a deposit of salts from the nasal secretions. They are usually unilateral, but may be found in both nasal cavities. As in the formation of calculi elsewhere, there is usually a nucleus around which the salts are deposited. This may be some small foreign body introduced years before, or a clot of blood or inspissated mucus. Rhinoliths are commonly seen in individuals suffering from the various diseases of the nose accompanied by excessive secretion. The chemical composition of rhinoliths varies. Phosphate of calcium is the most abundant mineral constituent, although phosphate of magnesium, carbonate of calcium, magnesium, and sodium, and the chloride of sodium are also found. Organic substances, such as mucin and proteid material, are usually present in small quantities.

Symptoms. Rhinoliths may exist a long time, giving rise to only a slight discharge which the patient as-

cribes to catarrh, and for which he may be treated by his physician without examination or benefit. As the calculi grow and the nose becomes obstructed the symptoms of nasal obstruction and the discharge of a more abundant mucopurulent, sometimes fetid secretion, may lead to a more thorough examination, and the detection of the cause. There may be pain on the affected side, which radiates to the forehead or involves any of the branches of the fifth cranial nerve.

Examination. After cocainization, examination of the anterior nares will show an obstruction in the cavity, the situation depending upon the site of the rhinolith. It is commonly found wedged in the middle or superior meatus, although it may lie on the floor of the nose. While wiping away the secretion it may be noticed that the cotton catches on some rough substance, which tends to fray it out. Touched with a probe the sensation is that derived from touching a stony substance. A distinct click may be heard. The rhinolith may be partially imbedded in and surrounded by a pyogenic membrane, and only a small part of its surface be bare and give rise to the sensation described.

Differential Diagnosis. Rhinoliths may be mistaken for other foreign bodies, necrosed bone, spurs, atrophic rhinitis, deviations of the septum, or any new growth in the nose. The exact nature of the foreign body, whether one accidentally introduced, a rhinolith, or necrosed bone, may not be determined until after its removal. Rhinoliths are distinguished from new growths by their not being attached to the nasal structures, but imbedded or wedged in the nasal cavity. Bony new growths, as osteomata, are hard, while all other neoplasms are soft. In cases of bilateral calculi the discharge may resemble that of atrophic rhinitis. When the

crusts are removed the open nasal passages seen in atrophic rhinitis eliminate the presence of calculi. The purulent secretion may simulate the discharge in diseases of the accessory sinuses. If proper care be taken in all cases to examine the structures within the nose, the rhinolith should be detected. A rhinolith may cause empyema of the maxillary sinus, and this complication must be borne in mind.

Prognosis. When removed rhinoliths rarely re-form.

Treatment. The nose having been thoroughly cocainized, the calculus can usually be seized with a forceps and removed. If firmly imbedded, a stiff probe should be used to pry the stone from its resting place, after which it may be grasped and removed with the forceps. If too large to pass through the anterior nares, pieces may be chipped off the borders until it is diminished in size sufficiently to be withdrawn.

RHINOSCLEROMA.

A chronic inflammation of the nose produced by a specific bacillus.

Etiology. This disease is exceedingly rare in this country. It is found in Hungary, Austria, and, to a lesser extent, in the other southern European countries.

Pathology. The tissue consists of an infiltration of round and spindle-cells, with a tendency to nest-formation of these. The cells are very densely packed together, and in places have the characteristic appearance of giant-cell formation. When stained by Gram's method a bacillus like the pneumococcus can be found in the cells and in the interstices between them.

Symptoms. The symptoms of this disease are local, and depend upon the amount of interference with the

functions of the nose. It not infrequently happens that after existing two or three years the growth will completely occlude the nose. When the mucous membrane of the nose is involved occasional hemorrhages result. The growth is not usually accompanied by pain.

Examination. The condition found upon examination will depend upon the site of the disease. The nasal mucous membrane alone is seldom involved, the skin of the nostrils also being usually invaded. In such cases the nose is thickened, its surface slightly reddened, and a scaly desquamation is seen at times. There is no tendency whatever to breaking down or ulceration of this growth. When handled the tissue has the consistency and feel of dense cartilage.

Differential Diagnosis. This disease has to be differentiated from those diseases which produce an increase in the tissues of the nose, such as syphilis, various malignant diseases, tuberculosis, and lupus. These latter diseases are rapid in their growth and have a tendency to ulceration. Rhinoscleroma is slow in its growth and does not ulcerate. In syphilis, tuberculosis, and lupus there will probably be found evidence of these diseases in other parts of the body. Rhinoscleroma may also be found in other places than the nose, but wherever found it has the same peculiarities that it has in the nose. In malignant disease age is an important factor. Malignant disease occurs most frequently in persons over forty, whereas rhinoscleroma occurs in young adults. Malignant disease is accompanied by a great deal of pain; rhinoscleroma is free from pain. Enlargement of the lymphatic glands is frequent in malignant disease, and absent in rhinoscleroma.

Prognosis. Rhinoscleroma of the nose alone rarely

produces death. Invasion of other portions of the respiratory tract, especially of the larynx, may result fatally from dyspnea and asphyxia. When removed the growth is almost sure to recur.

*Recurring
growth.*

Treatment. The treatment consists in removing the growth. Where possible the tissue may be cocaineized and removed with the snare. This is often difficult, on account of the intense hardness of the tissue and the inability to catch the growth in the snare. General anesthesia will frequently be necessary in order to excise the growth with the scalpel.

NON-MALIGNANT GROWTHS IN THE NOSE.

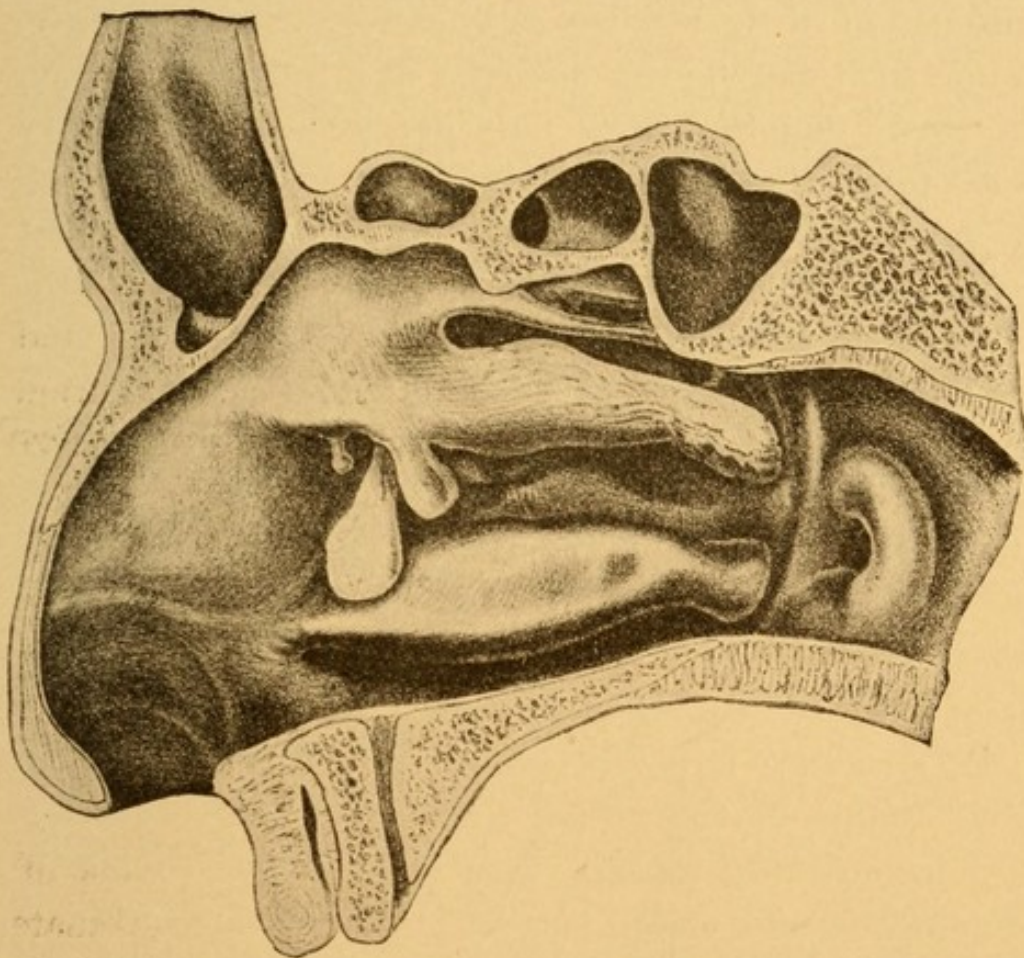
The new growths found in the nose which are non-malignant in character, and which do not usually have a tendency to become such as the result of operative interference or degenerative processes taking place in them, may be classified as (1) polypi, (2) papillomata, (3) fibromata, (4) lymphomata, (5) adenomata, (6) angiomas, (7) osteomas. By far the most common of these are the nasal polypi; the others are exceedingly rare.

(1) Nasal Polypi.

Etiology. The causes of nasal polypi are not well understood. They are seen more frequently in men than in women, in about the proportion of two to one. They also occur more frequently after the twentieth year. They are rarely seen in children. They are met with so commonly in suppurative diseases of the accessory sinuses and in chronic necrosing ethmoiditis that some observers have gone so far as to state that nasal polypi are invariably associated with suppurative and

necrosing processes. While recognizing the frequency with which nasal polypi follow necrosis, we believe that polypi may occasionally occur independently of necrosis and suppuration of the accessory sinuses. Nasal polypi usually spring from the outer wall of the nose, in the middle meatus, and in the region near the bulla ethmoidalis.

FIG. 48.



Outer wall of the right nasal cavity, exhibiting three polypi.
(ZUCKERKANDL.)

In Fig. 48 the outer wall of the right nasal cavity is shown with three nasal polypi. The smallest (anterior one) springs from the bulla ethmoidalis; the largest (middle one) springs from beneath the middle turbinate,

and the medium-sized (posterior one) springs from the anterior end of the middle turbinate.

Vasomotor disturbances in the blood-supply of the nose may also account for nasal polypi. They are usually multiple, and frequently involve both nasal cavities.

Pathology. Nasal polypi were formerly considered to be types of myxomata—that is, a low form of connective tissue, containing large, branched, stellate cells, holding in their meshes a mucin-bearing substance. While such may be the character of a few nasal polypi, the great majority show only the presence of a very loose form of connective tissue, the meshes of which are infiltrated with round cells and a clear fluid. Most polypi contain mucus-secreting glands. The mouths of some of these glands may become obstructed and the retained secretions cause the gradual accumulation of fluid within the gland, so as to produce a cyst within the polyp. We sometimes find a polyp that is almost entirely cystic in character. A few bloodvessels are seen within the polyp. On the surface the polyp consists of stratified or columnar epithelium resting upon a delicate basement membrane.

In structure a polyp can scarcely be differentiated from edematous connective tissue of a loose character. Not infrequently we see cases of extensive edema of the anterior and under portion of the middle turbinate which have the appearances—gross and microscopical—possessed by a polyp. For this reason it is now believed that the production of polypi results from some derangement in the vasomotor system by which an abnormal amount of the fluid portions of the blood transudes through the bloodvessels, producing an edema

of the surrounding tissues. If this vasomotor dilatation be local, the increasing weight of the tissue causes the growth to sag more and more, to become elongated, and finally pendulous, a well-defined tumor, a polyp.

Symptoms. The symptoms of nasal polypi depend partly upon the nasal obstruction which they produce and partly upon the reflex disturbances which they excite. Symptoms of obstruction will vary with the size, number, and situation of the polypi. If one or both nares are completely occluded, mouth-breathing, with all its uncomfortable symptoms, will result. Small polypi often produce a sense of fulness at the root of the nose, giving rise to occasional headaches. Where they press upon the outlet of the infundibulum unilateral headache, situated just above the eyebrow of the affected side, is a common symptom. Polypi are accompanied by more or less discharge of a thick, glairy, white-of-egg-like mucus. Where the nose is filled with polypi there is a nasal twang, so characteristic that when once heard the diagnosis of polypi can frequently be made by the peculiarity in the sound of the patient's voice. In damp weather, and when the humidity is high, polypi seem to be increased in size. Whether this is due to their absorption of moisture from the atmosphere, or whether this atmospheric condition favors transudation of fluid from the bloodvessels of the polypi, it is difficult to say. In dry weather with low humidity polypi are smaller and the symptoms are lessened. Among the reflex symptoms observed with polypi are hay fever, asthma, coughing, sneezing, and occasionally chorea and epilepsy.

Examination. Nasal polypi are frequently of such size that they may be seen protruding from the nostril

or detected without the use of the speculum. When the speculum is introduced into the nose large polypi are seen wedged between the septum and outer wall of the nose. When the polypi are small a mass is seen between the middle turbinate and the outer wall of the nose, or attached to this wall in the region of the bulla ethmoidalis. Their color resembles that of an oyster. When touched with a probe these masses are freely movable and insensitive, in contrast to the rest of the mucous membrane of the nose, which is very sensitive when touched. Where irritating snuffs have been used or unsuccessful attempts at removal have been made the surface of the polyp may have a reddish granular appearance. The probe can be passed beneath the polyp up between it and the septum. It can also be passed from under the polyp up between it and the outer wall of the nose. Posterior rhinoscopy may show a similar mass either filling the choanæ or even projecting down into the nasopharynx.

Differential Diagnosis. Polypi are to be differentiated from papillomata, fibromata, lymphomata, malignant tumors, hypertrophies of the turbinal tissues, and deviation of and spurs upon the septum. The tumors above mentioned are firmer and harder in their consistency than polypi. Papillomata are warty-like in appearance, their surface being corrugated, while the surface of a polyp is full, rounded, and smooth. Fibromata are bright red in appearance and very hard in consistency. Lymphomata are usually like fibromata, from which they are seldom differentiated until after removal.

Malignant growths give a history of very rapid obstruction of the nasal cavity, while the growth of

polypi is slower. Malignant growths are accompanied by sharp, lancinating pain, nasal polypi by a sense only of fulness and discomfort. Malignant growths have a tendency to ulcerate early in their course, and hemorrhage, slight or severe, is frequent. Polypi rarely ulcerate unless as a result of unsuccessful attempts at removal, and spontaneous hemorrhage practically never occurs. Malignant growths bleed easily when touched with a probe, and are firmly attached to the surrounding tissue. Nasal polypi do not bleed, and are very freely movable.

Deviations of the septum and spurs have a firm, resistant feel, are immovable, and when a proper observation of the structures of the nose is made ought not to be mistaken for soft, movable polypi.

Turbinal hypertrophies are very commonly mistaken for polypi by beginners. Their bright-red color, inability to be surrounded by the probe, as above described, broad base of attachment, their occupying the position of normal structures within the nose, and not filling up *the space between these structures*, should be sufficient for diagnosis.

Prognosis. A single, moderate-sized polyp may be removed with fair probability of its never returning. If, however, we have to deal with multiple polypi, the large visible ones may be removed, but the small invisible ones beneath the middle turbinate will enlarge and demand removal at a subsequent time. It is never safe to promise a cure in a case of multiple polypi, unless the complicating chronic suppuration in the ethmoid cells and other accessory sinuses is relieved. It is better to state that if they do recur, which is probable, they can be removed when symptoms demand it. If the radical operation described below is

performed, the chances of their return are somewhat lessened. When polypi are associated with asthma, hay fever, and other reflex neuroses their removal may result in cure of these conditions. The removal of these polypi should be advised solely on the ground of restoring nasal respiration. Patients should be candidly told there is a possibility that the operation may cure the asthma, hay fever, or other reflex neuroses. Any more positive statement than this is apt to lead to great disappointment both to patient and physician.

Treatment. The removal of nasal polypi is best accomplished by means of the cold wire snare. The snare, wire, and methods of threading the wire are described in the article on Hypertrophic Rhinitis. It will be found more convenient to thread the snare so that the wire loop is vertical. The loop should be made but little larger than the estimated size of the polyp. The nose should be sprayed with a 2 per cent. solution of cocaine, followed by a spray of adrenalin, 1 to 10,000. The nostrils should be widely dilated with a nasal speculum, and the loop inserted so as to pass between the polyp and the septum. So adjust the loop that the lower part of it lies one-sixteenth of an inch lower than the lower border of the polyp, and the distal end of the loop about the same distance back of its posterior border. The handle of the snare is now to be rotated toward the outer wall of the nose, so that the lower border of the loop is made to pass underneath the polyp. Care must be taken in this movement that the snare is not withdrawn however little from the nasal cavity. If the proper sized loop has been made, the lower part of the polyp will now lie within the loop. If traction were to be made at this time, the polyp would probably be

cut in two. To prevent this a gentle rocking motion is to be made, so as to carry the loop high up into the nasal cavity, directing it toward the middle meatus, at the point from which nasal polypi usually spring on the outer wall of the nose. Slight traction should now be made upon the loop, and pressure in an upward direction is also to be made, so that the loop will follow up to the point of the attachment of the polyp and finally cut it off at that point. With the withdrawal of the snare the polyp frequently falls from the nose. If it remains within the nasal cavity, it should be grasped with a pair of forceps and extracted.

If the loop has been properly adjusted, so as to cut through the polyp at or near its point of attachment, hemorrhage is usually very slight, amounting only to one or two drops. If, on wiping this away, other polypi are seen, they should be similarly removed. It is usually better to thread the stylet with a new wire for each polyp, although the same wire, with a little adjustment, may be used several times. If polypi exist in both nasal cavities, it is not advisable to operate on both sides at one sitting. The amount of cocaine necessary to produce insensibility in the two cavities may be sufficient to produce symptoms of cocaine-poisoning. Should hemorrhage be sharp, a small pledget of cotton inserted into the nasal cavity against the site of the stump of the polyp will quickly control it. In severe cases as many as twenty-five or thirty polypi have been removed from one nasal cavity at a single sitting; but, as a usual thing, by the time five or six have been removed the slight bleeding from each obscures the field of vision so much as to render the accurate snaring of any more somewhat difficult. After four or five days the stumps have sufficiently healed to allow the oper-

ator a good field of vision, and any remaining polypi may be removed.

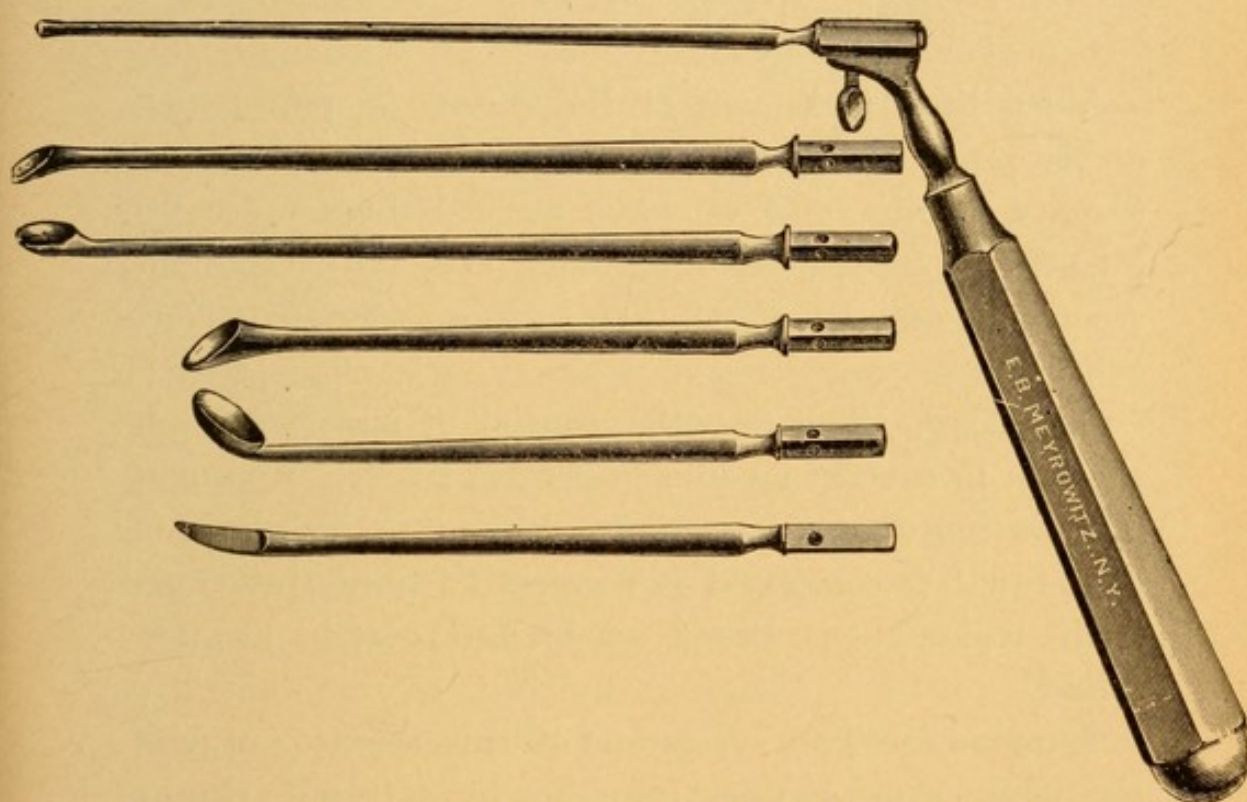
During the first three or four days after the removal of polypi slight bleeding occurs if too violent efforts are made at blowing the nose, and patients should be cautioned against this. The nose should be sprayed night and morning with a solution of Seiler's tablets or normal saline solution.

Some physicians recommend touching the base of an excised polyp with chromic acid, others with trichloroacetic acid, and still others the employment of the galvano-cautery wire heated to a red heat. It has always seemed to me that if the polypi be properly removed by the snare these cauterants are unnecessary. In the region where they are applied, unless great care is taken to touch the stump only, considerable damage may be done in the way of exciting undue inflammation. The danger of applying cauterants in this region lies in the fact of the anastomoses of the middle turbinal veins with those of the dura, and the possibility of septic meningitis resulting from the inflammation.

Where polypi return after the removal of those which are visible, one should suspect necrosing ethmoiditis or suppuration in the accessory sinuses, especially that of the antrum of Highmore. This should be sought for, and, if found, appropriate remedies thereto employed. Failing to find any of these conditions, the patient should be told that a thorough curetting of the mucous membrane in the region from which the polypi spring will afford a better means of ridding him of the troublesome condition than any other procedure. The curetting is, however, in spite of the use of cocaine, quite painful. We have, therefore, sometimes employed gen-

eral anesthesia when it has been found necessary to adopt this measure. It has the disadvantage, however, that hemorrhage is quite profuse and quickly obscures the field of operation in spite of the constant wiping away of the blood with pledgets of cotton on an applicator. The instruments preferred for this operation are Grünwald's curettes (Fig. 49).

FIG. 49.



Grünwald set, consisting of a probe, four curettes and a curved, sharp-pointed bistoury, each of which can be inserted into a common handle.

In a set four differently shaped curettes are found, which fit in a universal handle, and usually suffice to enable one to get at all the diseased area of the mucous membrane. The operation is somewhat difficult, and we would not advise its performance except a thorough knowledge of the anatomy of the parts has been gained, for the curette may easily be pushed

through into the accessory sinuses, into the cavity of the orbit, or, if the proper direction is not observed, even through the cribriform plate of the ethmoid into the cranial cavity. Curetting does not always succeed in preventing the return of nasal polypi, as some portions of the diseased area may not have been reached in the operation, and from these polypi may grow.

(2) Papillomata.

Very little is known of the causes of papillomata of the nose. They are seen in connection with hypertrophic rhinitis, and we have noticed them more frequently in foreign-born patients, especially Germans, Austrians, and Russians, than in those who are American-born.

Pathology. The growths consist of superficial epithelium in several layers arranged in a corrugated manner, resting upon a basement epithelium. The body of the growth is composed of connective tissue infiltrated with leukocytes. Bloodvessels and glands are also found.

Symptoms. The symptoms of this disease are practically the same as those of either hypertrophic rhinitis or nasal polypi (*q. v.*).

Examination. These growths are usually seen in connection with the inferior turbinate, springing either from the inner surface or the under border. They may spring from the septum; sometimes also from the posterior end of the inferior turbinate. They are bright red in color, corrugated, freely movable, sometimes with a very small pedicle, at other times having a rather broad base of attachment.

Prognosis. Papillomata, when completely removed, do not usually return. If the patient is beyond forty-five years of age and recurrence takes place, one should always bear in mind the possibility of degenerative processes of a malignant character going on in the growth, and careful microscopical examination of the excised tissues should be made.

Treatment. These growths are to be removed with the cold wire snare, as described for polypi. Where accessible the base of the growth may be touched with a cauterant, such as the galvano-cautery, trichloracetic acid, or chromic acid.

(3) **Fibromata.**

The etiology is unknown.

Pathology. The growths consist of very dense fibrous tissue containing bloodvessels. Mucous glands are not present in the structures.

Symptoms. The symptoms are those of nasal obstruction, coming on slowly and increasingly.

Examination. Fibromata are seen as pinkish or pale-red tumors. The surface is usually smooth, although it may sometimes be granular in appearance. They spring from the septum, floor of the nose, and, more rarely, from the turbinal tissue. Examined with a probe they have a firm, dense feeling, not so hard as that of cartilage, and yet firmer than the normal tissue of the nose. If attached by a small pedicle, they are readily movable. They often, however, have rather a broad base of attachment, in which case the mobility is not very great. If large, ulcerations may appear on the surface from pressure and contact with the opposed structures in the nose. Adhesions of the growth to

other portions of the nose than that from which it springs occasionally result.

Prognosis. When removed completely recurrence does not take place.

Treatment. Small fibromata are best removed by means of the cold snare or the galvano-cautery snare. When very large, completely blocking the nasal cavity, it is difficult to surround the growth with a snare. In such cases enough of the growth may be removed piece-meal with a pair of cutting forceps (Fig. 58) to allow the wire being passed around the growth. If exceedingly large, fibromata may have to be removed under ether by a surgical operation involving resection of the superior maxilla.

(4) Lymphomata.

Lymphomata present very much the symptoms and appearance of fibromata, with the exception that they are not so dense in structure.

Treatment. The treatment of lymphomata is the same as that given for fibromata (*q. v.*).

(5) Adenomata.

Adenomata usually spring from the septum by a broad base, but may also arise from the ethmoid region. They grow rapidly and soon fill the naris, giving rise to the symptoms of nasal obstruction.

On examining the nose a reddish mass can be seen filling the space. It bleeds so easily on being touched with a probe that one usually suspects he is dealing with a malignant growth, until, after a portion is removed, its true nature is revealed by the microscope. The growths rapidly recur unless thoroughly removed,

and, like adenomata in other regions of the body, have a tendency to malignant degeneration.

Treatment. Same as for polypi, and, in addition, the base of the growth should be thoroughly curetted so as to remove all trace of the mass. Hemorrhage is usually easily controlled by plugging the naris with aseptic gauze.

(6) Angiomata.

These are soft, reddish to reddish-black, mulberry-like growths springing from the septum or turbinal tissues. They consist of a dense plexus of bloodvessels with a thin, epithelial covering.

Their special characteristics, as far as the symptoms are concerned, are the tendency to frequent and severe hemorrhages, either spontaneous or when touched lightly with a probe, and the obstruction to respiration. When removed, as they should be, with the galvano-cautery loop, they seldom return. Other methods of removal often result in very severe hemorrhage.

(7) Osteomata.

Osteomata spring from the septum, floor of the nose, and outer wall of the nasal cavity. They often protrude into the nasal cavity from the antrum. They are dense, ivory-like in character, and very slow in their growth. The symptoms produced are those of nasal obstruction. They may be seen as evidence of inherited syphilis. Their removal is usually very difficult, and had better be accomplished under general anesthesia. The chisel, gouge, and trephine may all have to be employed for their removal. They sometimes recur.

MALIGNANT GROWTHS OF THE NOSE.

These are not very common if we except the epitheliomata that involve the skin covering the nose. Of the etiology of malignant disease very little is known. Sarcomata, including osteosarcomata, are found in the young as well as in the old; carcinomata and epitheliomata usually only in people past middle life. Sarcomatous degeneration is occasionally met with in cases of nasal polypi and other benign tumors after they have been removed a number of times. Sarcomata of the nose may be the first evidence of an existing sarcoma in the antrum of Highmore from extension of the disease into the nasal cavity.

Symptoms. Malignant tumors usually grow quite rapidly, occluding one or both nasal cavities. The condition thus produced will be a rapidly increasing nasal obstruction, with all its attendant symptoms. These growths tend to ulcerate early, and a history of recurrent bleedings, which at first may be slight and subsequently severe in character, is common. At this time also there is a mucopurulent discharge, very frequently fetid in character. Pain at first is not very marked; but in the later stages, especially where the growth involves the nasopharynx, lancinating pain, shooting up to the ear on the affected side, is common.

Examination. Examination by anterior rhinoscopy will show in the cavities an obstruction, which varies from a bright red to a purplish color. The surface of the growth is often uneven and mulberry-like. Ulcerations, covered with a thick, grayish-yellow or greenish slough, may be seen. When touched with a probe these growths bleed freely, have a hard feel, as of solid

tissue, and are not usually very movable even when of considerable size.

Examination of the nasopharynx often shows thickening of the soft palate at its point of attachment to the hard palate, and a swollen, reddened, infiltrated appearance of one or both lateral walls of the pharynx. The posterior portion of one or both choanæ may be seen filled with a growth similar to that which is observed in the anterior nares, and in such cases the lateral wall of the pharynx is very likely to be involved.

Where the malignant growth is limited to the nasal cavity alone, secondary involvement of the lymphatic glands at the angle of the jaw is not very great; but as soon as the growth involves the tissues of the nasopharynx, then immediately the lymphatic glands of the neck become progressively enlarged and feel dense, firm, and resistant.

Differential Diagnosis. Malignant growths are to be differentiated from the various non-malignant growths, foreign bodies in the nasal cavity, and from syphilitic and tubercular ulcers. It is not always easy at the first examination to state positively whether a suspicious growth in the nasal cavity is malignant or non-malignant. In all doubtful cases a portion of the tumor should be excised and a careful microscopical examination made to determine the character of the growth. Malignant growths differ from non-malignant ones in their greater rapidity of growth, their tendency to ulceration with a fetid discharge, the frequent hemorrhages, the great pain that accompanies them, their tendency to involve the glands and the adjacent tissues, and their hardness and immobility within the nasal cavity.

Foreign bodies may give rise to pain, ulceration,

sloughing, fetid discharge, and hemorrhage ; but thorough examination of the nasal cavities with a probe will lead to their detection. In tertiary syphilis a gumma may for a time by its rapid growth, and its subsequent breaking down, with hemorrhage and discharge, simulate a malignant growth, especially where no history of a primary lesion can be elicited. Microscopical examination of pieces of excised tissue, the administration of large doses of potassium iodide, and time will decide the character of the growth.

Tubercular ulcerations are usually seen in common with other evidences of tuberculosis, especially pulmonary ; in addition, staining of a section of the tissues by Gram's method and microscopical examination will show the presence of tubercle bacilli.

Rhinoscleroma is so rare in this country, and so different in its character of growth and feeling, that it should readily be differentiated from a malignant growth.

Prognosis. The prognosis in all forms of malignant growth depends upon the variety of the growth and the stage in which it is seen. Sarcomata, especially the osteosarcomata that occur in childhood, if seen early and radically removed, may not recur. The prognosis in these cases, however, should always be guarded, as it frequently happens that in a case in which one has the best reasons to expect a favorable outcome we are greatly disappointed to find a recurrence, and finally death takes place from the disease. Carcinomata and epitheliomata are almost invariably fatal. Where the mucous membrane of the nose is involved the course of the disease is quite rapid, and it terminates fatally, with symptoms of sepsis or meningitis, in from three to twelve months. Epithelioma involving the skin of the nose usually runs a course of from one to five years.

Treatment. Soft sarcomata may be removed, if small, at one sitting with the galvano-cautery snare, cocaine anesthesia being employed. If large, several partial operations may be required to eradicate the growth. The base of the growth should be thoroughly cauterized with the galvano-cautery, and the patient should report at least once a week for several months, in order that the first evidences of reappearance of the growth may be detected. Osteosarcoma should only be removed under general anesthesia, by means of the knife, the chisel, and the gouge. Epitheliomata and carcinomata, when detected early and before extranasal tissues have become involved, should be removed under ether, by a radical operation, removing not only the tissues involved, but also an area sufficiently wide of this to insure, as far as possible, non-recurrence of the growth. Should the tissues of the nasopharynx or the lymphatic glands of the neck be secondarily involved in an epithelioma or a carcinoma, there is practically no hope that a radical operation can so eradicate the growth as to offer any chance of cure. In these cases it is better to keep the patient as free from pain as possible by the use of morphine, and after keeping the parts cleansed with an antiseptic wash—one of the best being two grains of permanganate of potassium to a pint of lukewarm water—let nature take its course.

ANOSMIA (Loss of the Sense of Smell).

Etiology. The sense of smell is dependent upon two factors: (1) a healthy state of the olfactory nerve and of the tract; thence to the cortex of the brain; (2) a patent condition of the nasal cavities, by which the odorous particles emanating from various substances

may reach the endings of the olfactory nerve in the upper part of the nasal cavity.

Under the first heading, any cause which destroys the olfactory nerve, olfactory tract, or cortex of the brain in the region of the uncinate gyrus permanently destroys the sense of smell. Syphilitic or other forms of ulceration of the nose and tumors by pressure may destroy all the nerve-endings, as may also the sclerosis in atrophic rhinitis. Tumors at the base of the brain or pressure upon the cortex may destroy the conducting and perceptive organs. The nerve-endings may also become fatigued by the too long perception of any one odor, and fail to be stimulated by this odor, although responding to all others. This is a matter of daily observance by the physician, who may fail to detect the odor of carbolic acid or iodoform in his office that is very noticeable to a patient.

Under the second heading, any cause of nasal obstruction by which air is prevented from reaching the middle meatus results in loss of the sense of smell.

Symptoms. If the sense of smell be lost on one side of the nose, it may only accidentally be discovered by the patient, as the other side enables him to detect odors. In addition to the loss of the sense of smell that of taste is also impaired, as these two sensations are very closely allied, and the inability properly to taste food may be the first knowledge the patient has of impairment of the sense of smell.

Examination. To test this sense the perfumes or the essential oils should be used. Ammonia stimulates the fifth nerve, producing pain and lachrymation, which the patient often mistakes for the sense of smell. An instrument called an olfactometer is sometimes em-

ployed to estimate the acuteness of this sense, but the results are not accurate.

Prognosis. Anosmia, if due to destruction of the nerve or pathway to the brain, is rarely recovered from. If due to nasal obstruction, and this can be relieved, the sense of smell is restored, unless lost for a long time, in which case there is apt to be only partial restoration.

Treatment. For the first group, potassium iodide and strychnine may be tried, but without much hope of relief unless syphilis is the cause. For the second group of cases removal of the obstruction is demanded.

HYPEROSMIA.

A condition in which the acuteness of the sense of smell is increased. This condition is seen in extremely nervous individuals, especially those subject to hysteria. Little can be done except to treat the constitutional condition.

PAROSMIA.

A condition of perversion of the sense of smell in which the patient is constantly or periodically perceiving foul odors.

Etiology. This condition is often seen in the insane, and may be one of the earliest hallucinations experienced by them. It sometimes follows influenza, and is often present in those who have a slight degree of hypertrophic rhinitis, with a small amount of discharge that to other people is odorless. Like hyperosmia, it is probably due to increased sensitiveness of the nerve-endings.

Symptoms. The patients complain of various sorts of foul odors, such as emanations from a privy, burnt hair, rags, etc. It often happens that these sensations prey

upon them to such an extent that they shun society, fearing that the odors which they perceive must also be very disagreeable to those with whom they come in contact.

Treatment. The treatment of this condition consists in curing any pathological process existing in the nose, and, when this is remedied, assuring the patient that his condition is such as to be absolutely inoffensive to others. Tonics and the internal administration of valerian and asafetida are often useful.

EPISTAXIS (Nose-bleed).

Etiology. The causes of epistaxis are numerous, and may be divided into, first, those which are due to local conditions within the nose, and, secondly, those dependent upon constitutional diseases or conditions.

Local

Under the first heading are to be placed traumatism, such as blows or falls upon the nose; the hemorrhage from this source may be slight or severe. Frequent attacks of nose-bleed are usually due to the presence of a small group of thin-walled veins, situated on the cartilaginous part of the septum, just within the anterior nares and about a quarter of an inch above the floor of the nose. Following efforts to blow the nose, picking at this part of the septum with the finger, or even without any apparent cause, these veins burst, giving rise to a profuse flow of blood. A slight amount of hemorrhage occurs in acute rhinitis, sometimes in hypertrophic rhinitis. When ulcers exist in atrophic rhinitis slight hemorrhage is often seen. Ulcers of the nose from whatever cause, whether due to continual picking, foreign bodies, syphilis, tuberculosis, or to malignant growths, frequently give rise to hemorrhage. The non-malignant growths, with the exception of angiomata,

are not very apt to bleed. Angiomata frequently give rise to very profuse hemorrhage. Hemorrhage occurs as the result of operations upon the nose, and may often persist for several days in a severe form.

Under the second heading (constitutional causes of ^{constitutional} nose-bleed) may be placed that form which is seen at the onset of some of the infectious diseases, such as typhoid fever, pneumonia, influenza, measles, scarlet fever, whooping-cough, erysipelas, and diphtheria, even in those cases in which the nasal mucous membrane is not the seat of the diphtheritic exudation. Epistaxis may occur in those cardiac conditions in which there is an increase in arterial tension, as in cardiac hypertrophy, or those conditions in which there is obstruction to the return flow of blood, as in tricuspid regurgitation. In cirrhosis of the liver and cirrhotic kidney it is a common symptom. Diseases accompanied by altered composition of the blood, such as anemia, chlorosis, leucocythemia, malaria, pernicious anemia, purpura, scurvy, and hemophilia, have epistaxis as a frequent symptom. It also occurs in females as a form of vicarious menstruation. Epistaxis in the aged is often an indication of weak bloodvessels and may be a precursor of cerebral hemorrhage.

Symptoms. Usually the blood flows from the anterior nares, but when the hemorrhage occurs while the patient is lying down, and in cases in which the hemorrhage is very profuse, the blood may flow back into the nasopharynx and be expectorated. The amount of blood varies from the merest trace to a quart or more, although the patient is always prone to exaggerate the amount. If two or three pints of blood be lost in an adult or a proportionate amount in a child, the patient will show evidences of anemia. The face may be pale from fright

when only an ounce or two of blood are lost. Syncope is common after the loss of a large amount, and this often results in so lowering the heart's action as to allow of clotting, thus bringing about a cessation of the hemorrhage.

Examination. If there is no history of traumatism causing the hemorrhage, it is best to examine carefully the septum in the region described as being the seat of the venous plexus. On wiping away the blood it will often be seen that the blood is oozing from this point. If the hemorrhage has recently ceased, this part of the septum may be found covered with a clot of blood. If examined a few days later, a dry, brownish or blackish crust may be found. Should this crust be removed, hemorrhage is very apt to recur. If the hemorrhage does not arise from this region, it is usually difficult to locate the site from which it takes place.

Prognosis. Unless due to hemophilia, epistaxis usually ceases spontaneously. A severe anemia may result if the loss of blood is great, but ordinary epistaxis is followed by no symptoms.

Treatment. Slight hemorrhage will cease spontaneously or after the use of such familiar household remedies as cold applications over the nose and at the back of the neck, upon placing the feet in hot water, or after plugging the anterior nares with absorbent cotton. In an aged patient with cardiac hypertrophy and hard arteries it is usually best not to check the hemorrhage unless it is excessive. The flow of blood may relieve vascular tension and prevent possible hemorrhage in other undesirable situation, especially in the brain. If called to a patient and the hemorrhage continues, dilate the nostril and carefully examine for the source of bleeding. If found to be on the septum (the

usual place), thoroughly cocainize this area and touch the bleeding spot with a stick of nitrate of silver, or, better, with the point of a galvano-cautery. The bleeding may be so profuse that this will be difficult, in which case tannic acid should be mixed with water until the solution is of the consistency of syrup. A pledget of cotton dipped in this solution and inserted into the nasal cavity opposite the bleeding point will usually quickly control the hemorrhage. It is sometimes advisable to have the patient press the cotton against the septum by making pressure against the ala of the nose in the direction of the septum. Perchloride of iron is recommended by some, but we have found the tannic acid solution nearly as efficient, without possessing the irritating qualities of the iron. In case the venous plexus cannot be destroyed at the time of the hemorrhage, it should be destroyed a day or two later. Vaseline should be applied to the eschar night and morning until healing takes place. When the seat of the hemorrhage cannot be located, the bleeding should be controlled in one of the ways described in the article on Hypertrophic Rhinitis (page 100) or by plugging the posterior nares (page 103).

If the bleeding has been so profuse that the patient shows the constitutional effects of the loss of a large amount of blood, such as extreme pallor, a small, rapid, thready pulse, frequent attacks of syncope, and convulsive twitching of the muscles, then subcutaneous injections of warm normal saline solution are to be given in quantities varying from eight ounces to two pints. Such patients are to be kept in bed, the restlessness controlled by morphine, and be given a light fluid diet. As recovery takes place tonics containing iron are to be given.

*Find spot
ag. 2 or 3 or
galv. caut.*

*Tannic acid
+ H₂O.*

*Superficial
+ caut.*

*Hot normal
saline sol.*

H₂O₂.

*Plug cotton
Packer's gauge
Plug post.
nares.*

CHAPTER VII.

DISEASES OF THE ACCESSORY SINUSES OF THE NOSE.

WE shall classify these diseases as acute and chronic.

As the former seldom involve one group of sinuses alone, except when the antrum is infected from a diseased tooth, it will be most convenient to discuss the etiology and pathology of all acute inflammation of the sinuses together.

ACUTE SUPPURATIVE INFLAMMATION OF THE ACCESSORY SINUSES OF THE NOSE.

Etiology. Acute inflammation of the mucous membrane lining the accessory sinuses of the nose is an exceedingly common occurrence, complicating an acute rhinitis from any cause. Influenza, pneumonia, scarlet fever, measles, diphtheria, typhoid fever, and the other infective diseases are most frequently accompanied by suppurative inflammation in the accessory cavities. Any deformity in the nose which during an attack of acute rhinitis interferes with drainage may so dam up the secretion as to cause an overflow into the antrum and infect also the ethmoidal cells. Common conditions causing this are nasal polypi, deviations of the septum, cystic conditions of the middle turbinate, congenitally narrow nasal cavities, and marked hypertrophies of the nasal mucous membrane. Where the frontal sinus and ethmoidal cells are early involved, the antrum may become a reservoir for the accumulated secretion from

above without its mucous membrane becoming markedly inflamed. The antrum is frequently infected from the extension of caries and suppuration around the roots of the bicuspid and molar teeth of the upper jaw. A diseased canine tooth occasionally induces suppuration in this cavity. Traumatism, such as fractures of the outer table of the frontal bone or of the anterior wall of the antrum, especially when accompanied by puncture from infected foreign bodies, may cause acute suppuration. Necrosis, syphilitic or the result of malignant disease of the superior maxilla, occasionally induces an acute empyema.

Pathology. The mucous membrane lining the accessory cavities, nominally $\frac{1}{25}$ of an inch in thickness, becomes enormously œdematous and swollen, so that in the case of the antrum we have seen it $\frac{3}{8}$ of an inch thick. Examined under the microscope, it shows small round-cell infiltration with considerable œdema, presenting very much the appearance that is noted in polypi where there is a small amount of round-cell infiltration. On the disappearance of the inflammatory process the mucous membrane returns to its normal condition, only rarely exhibiting a slight amount of thickening.

In the earlier stages the secretion in these cavities is thick, gelatinous, whitish, or slightly yellowish in color. It is exactly like the thick, gelatinous mucus that is blown from the nose in the later stages of a cold in the head. In fact, some of such secretion from the nose undoubtedly comes from the accessory sinuses. Examined microscopically, it is composed of masses of mucus in which are imbedded numerous well-preserved leucocytes. When the process has existed several days the secretion from the cavities becomes thinner. The

mucus and pus-cells are disintegrated by the action of putrefactive bacteria. In such cases there may be an offensive odor to the discharge, if some of the varieties of the *Bacillus fœtidus* have gained access to the cavities. The fetid secretion is more frequently observed in the antrum, secondary to infection from a diseased tooth, than in any of the other accessory cavities. When the normal orifices of any of these accessory sinuses become completely occluded, then the secretion under tension produces a bulging of the weakest portion of the walls of the containing cavity. In such cases there is swelling and œdema of the tissues overlying these cavities, and eventually, unless relief is speedily obtained, a fistulous opening is formed for the outlet of the secretion. In the antrum fistulous openings have been noted underneath the lip, above the first and second molar teeth; also large openings have been formed in the nose by the gradual absorption of the bone of the outer wall, in which case fluctuating tumors, which consisted of the thickened membrane, have been observed in the region of the middle meatus. Retention of the contents in a frontal sinus results in œdema and redness of the upper eyelid, and eventually a fistulous formation at the thinnest portion of the wall of the sinus, namely, about $\frac{1}{4}$ to $\frac{1}{2}$ inch above the inner canthus of the eye. The posterior wall of the frontal sinus has also been absorbed, the contents passing into the cranial cavity, infecting the meninges or brain. Retention in the ethmoidal cells may result in the formation of a globular swelling slightly above and occasionally below the inner canthus of the eye. The cribriform plate of the ethmoidal has also been perforated and the contents of the ethmoidal cells evacuated into the cranial cavity. A few cases

have been reported in which the roof of the sphenoidal sinus has become necrosed, with irruption of the contents into the base of the cranial cavity. In diseases of the antrum caused by caries or a suppuration around the teeth, there is first an inflammation about the roots of the teeth, which eventually terminates in a small abscess forming at this point. If there is no obstruction to the outflow of pus along the roots into the mouth, there is but little danger of infecting the antrum; but when the pus is under considerable tension, the lower outlet being obstructed, it burrows through the normally thin layer of bone existing between the roots of the teeth and the cavity of the antrum. It occasionally happens that one or more roots of the second bicuspid or the first molar may have in their growth penetrated the floor of the antrum and be there covered only by the normal mucous membrane; if such teeth become the seat of caries, unless seen very early and properly treated, infection of the antrum will almost certainly follow.

Symptoms. The symptoms of acute sinus inflammation are two—*pain* and *discharge*—either from the nose ^{*Pain*} anteriorly or back into the nasopharynx. ^{*Discharge*}

It may be taken for granted that a very large percentage of persons suffering from cold in the head accompanied by *neuralgia* are suffering from an acute inflammation in some or all of the accessory sinuses of the nose with retention of secretion in the accessory sinuses.

PAIN. The pain varies from a dull ache, most commonly referred to the supra-orbital region of the forehead, to a persistent, exceedingly painful throbbing. It may be limited to the area over the sinus in which the secretion is under greatest tension, but it often radiates

to remote regions of the head, such as the vertex, the canal of the ear, the mastoid, or the occipital region. In acute suppuration of the antrum there is often a feeling of soreness over the anterior portion of the superior maxilla, most marked in the malar region. The teeth on the affected side often ache even though they may be perfectly sound. The second bicuspid and first molar are the ones most often complained of. When a diseased tooth is the cause of antrum suppuration, not only the infected tooth, but the ones on either side are so tender on percussion that it is often difficult, without the aid of a dentist, to determine which tooth is at fault. Supra-orbital pain is very frequently complained of in antrum disease, often when there is no inflammation of the frontal sinus.

The pain in acute suppuration of the frontal sinus is nearly always most intense just above the inner portion of the eyebrow. Percussion over the frontal bone in this region is painful, and where but one frontal sinus is involved, percussion on the same area over the healthy side elicits no pain. Pressure on the orbital plate of a diseased frontal sinus internal to the course of the supra-orbital nerve causes far greater pain than percussion over the thicker vertical portion of the frontal sinus.

It is not uncommon to have the pain in frontal sinus suppuration referred to the ear, side of the head, or the mastoid region. Pathognomonic of acute disease of the frontal sinus is the increase of frontal pain on blowing the nose. It is often so intense that patients fear to properly rid the nasal cavities of the secretion by blowing, on account of the pain produced.

In acute suppurative ethmoiditis the pain is referred to the lower portion of the forehead and the back of the eye, and often radiates throughout the entire head.

The pain in acute sphenoidal suppuration is often spoken of as a deep-seated pain in the head back of the eye and sometimes to the occipital and frontal regions. In severe cases, where several of these sinuses are involved, patients most frequently complain of general headache, referring the maximum of pain one hour to one region of the head, and later to other regions.

DISCHARGE. The discharge accompanying acute sinus disease varies in amount with the sinus involved, and the character varies with the length of time the disease has persisted. The greatest amount of discharge is that which accompanies suppuration in the largest cavity, namely, the antrum. The secretion in the earlier stages is thick, whitish, gelatinous mucopus, usually blown from the nose in teaspoonful or larger masses once or more in the course of an hour. If the patient is confined to bed the secretion passes posteriorly into the nasopharynx, and is drawn down and expectorated or swallowed. In the morning patients will spend some time before they are able to remove all of the thickened, sometimes semi-dried, mucopus from the nasopharynx. Occasionally, when an obstruction in the anterior portion of the nasal cavity exists, the discharge from the antrum will, even though the patient be in an upright position, flow back into the nasopharynx and none be blown out anteriorly. In the later stages of acute suppurative sinusitis the discharge becomes thinner, less mucoid, more purulent, and especially, if a diseased tooth is the source of the infection, is apt to


have the foul odor of rotten eggs, noticeable not only to the patient, but also to others. The discharge from a frontal sinus is identical in appearance with that from an antrum and follows the same routes in its exit, depending upon the position of the patient and the conformation of the interior of the nose. The discharge is usually most abundant in the morning, a couple of hours after awaking, and then is intermittent during the remainder of the day. The discharge from the anterior group of ethmoidal cells follows the same course as that from the antrum and frontal sinus. The discharge from the posterior ethmoidal cells and sphenoidal sinus is mostly directed backward into the nasopharynx, where it is drawn down and expectorated. It is only when the head is bent well forward that discharge from these cavities is blown out through the anterior nares.

The temperature in acute sinusitis may be slightly elevated or considerably so, depending on the type of infection and the disease which it complicates.

Examination. Examination of the anterior nares shows the mucous membrane reddened and swollen. The latter condition is often so marked, owing to contact of the mucous membrane of the inferior and middle turbinates with the septum, as to prevent any extensive view of the cavity. The other nasal cavity, if less or not at all involved, may show only a slight hyperæmia of the mucous membrane. A thick, yellowish-white, ropy discharge is usually observed in the naris of the affected side. Postnasal examination is apt to reveal the posterior ends of the inferior and middle turbinates greatly swollen, and the presence of the same mucopus issuing from the choana and over the upper surface of

the soft palate. The next step is to spray into the anterior nares a 2 per cent. solution of cocaine, followed in a couple of minutes by a spray of a 1 : 10,000 solution of adrenalin. While waiting for these to act, it is my invariable custom to take the patient into an absolutely dark room and transilluminate the frontal sinuses and antra. In order that transillumination shall give the most satisfactory results, it is necessary to have a rheostat (Fig. 50), by which the amount of light may be regulated to the thickness of the structures in each individual case. The rheostat is connected with the street

FIG. 50.



Coakley rheostat.

current, either constant or alternating, and is graduated so that the voltage used may be recorded for reference at a future visit.

Much criticism has been directed against transillumination as an aid in the diagnosis of acute and

chronic suppuration in the accessory sinuses. If the above directions are carried out in all cases, we feel sure that transillumination will be found to be a very valuable aid, although not infallible, in most cases.

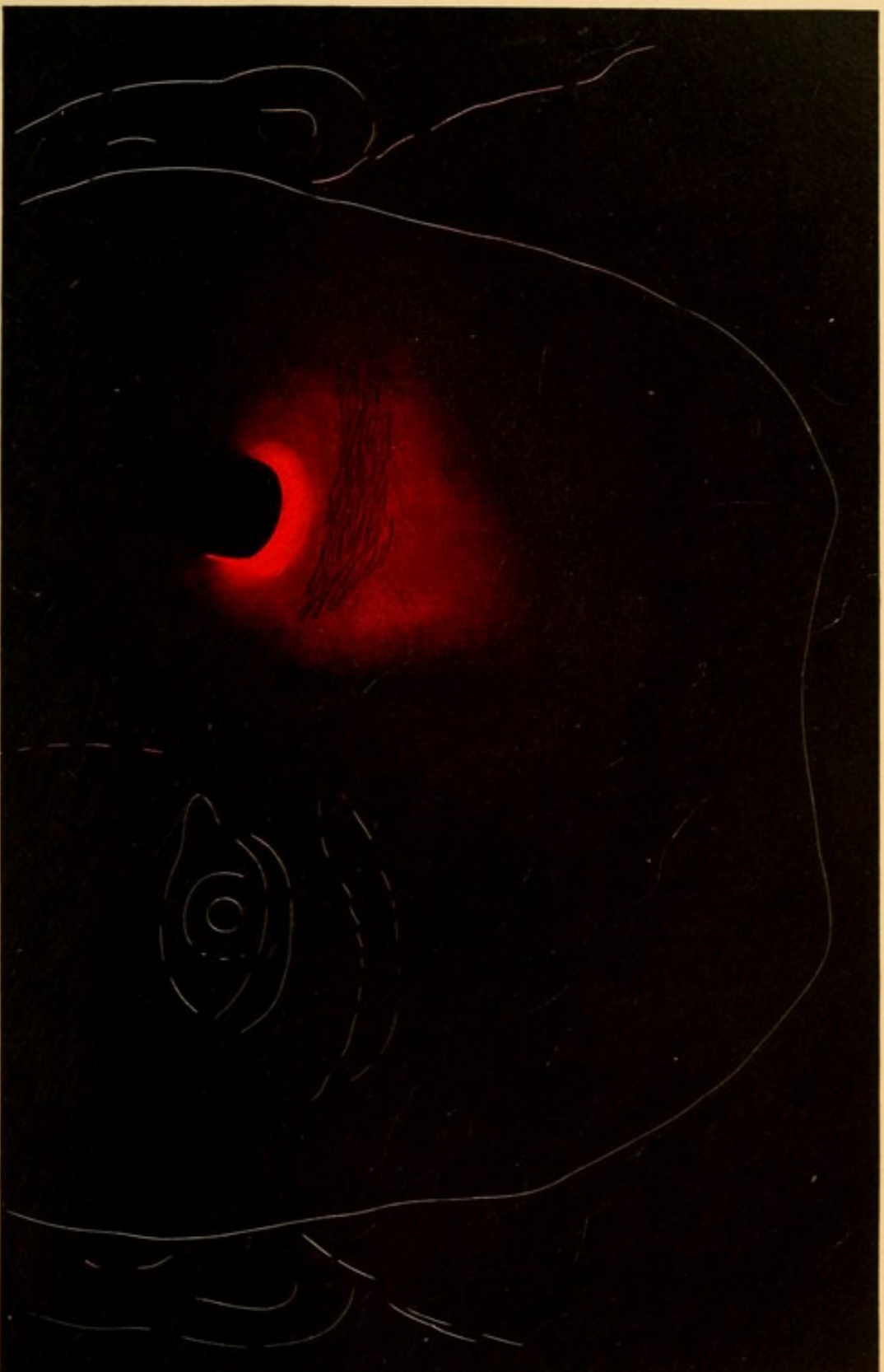
Transillumination of the frontal sinus is not so valuable an aid in diagnosis as is antral transillumination. The great variation in the size of the frontal sinuses and in the thickness of the bony walls often makes it impossible for one to determine whether the smaller area of illumination and the more poorly illuminated frontal region is due to the differences in size of normal sinuses or to differences due to disease.

Plate III. shows the area illuminated and the average color of a medium-sized right frontal sinus. Plate IV., the area and color in a diseased left frontal sinus of the same size as that in Plate III. Comparing these two plates, it will be readily seen that not only is there a considerable difference in the area illuminated in Plate III. as compared with Plate IV., but that the brilliancy of the color is much greater in Plate III.

Since the employment of the *x*-rays to determine the size of the frontal sinuses the value of frontal transillumination is greatly increased. When the two frontal sinuses are approximately of the same size, as shown by a radiograph, any great difference in transillumination is probably due to thickened mucosa or inflammatory products within the cavity.

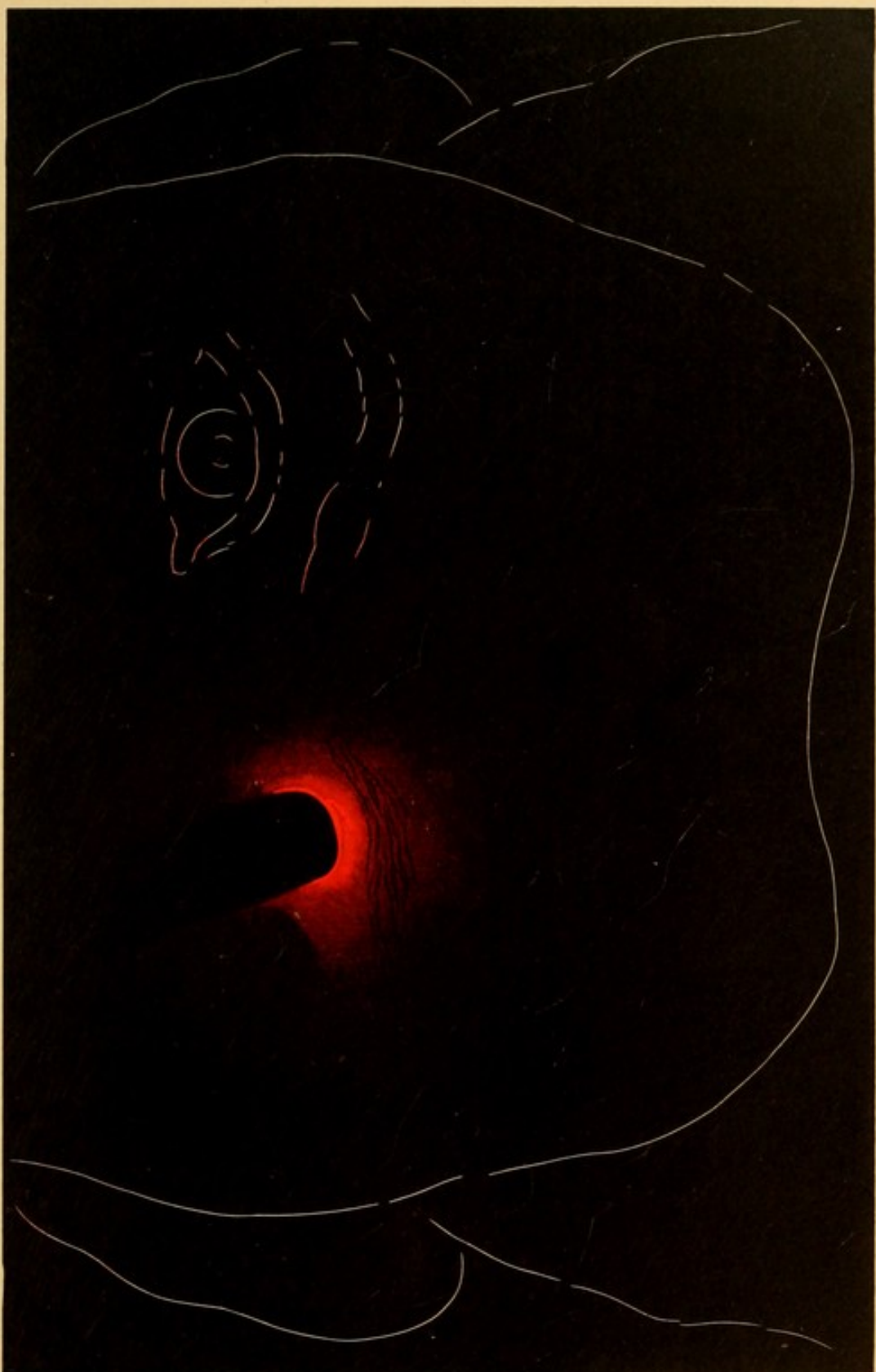
Figure 51 illustrates the author's transillumination lamp, with frontal sinus hood and the glass protectors for placing over the lamp when illuminating the antra. These tubes are readily sterilized by boiling after having

PLATE III



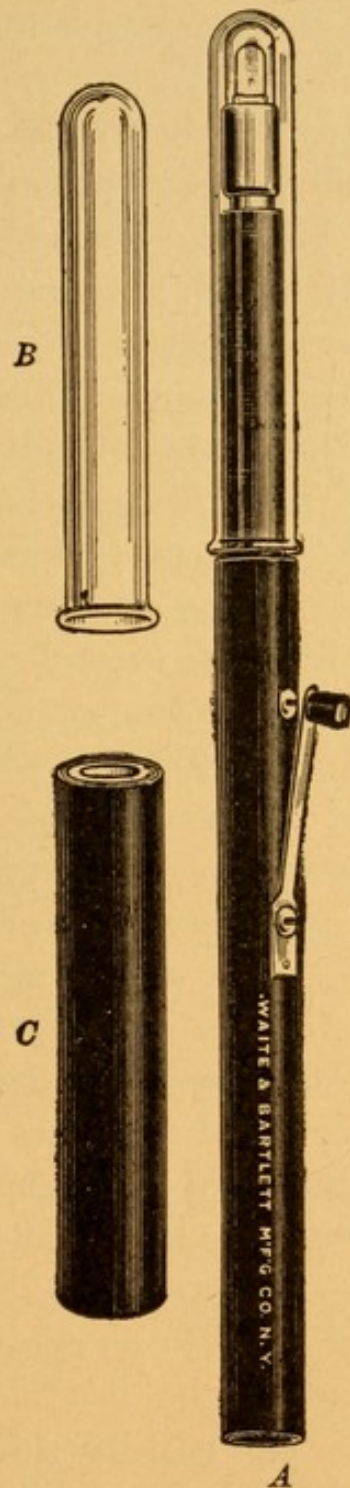
Transillumination of Medium-sized Normal Right Frontal Sinus.

PLATE IV



Transillumination of Medium-sized Diseased Left Frontal Sinus.

FIG. 51.



Coakley transilluminating set.

A. Handle containing lamp and hood for transilluminating the antrum of Highmore. B. Antrum hood detached. C. Hood for use in transilluminating the frontal sinus.

been used. By transilluminating the frontal sinuses first, the heat from the lamp is not so great as to be unbearable.

After transilluminating the frontal sinuses the black hood is removed, and the glass protector for the mouth is slipped over the lamp and inserted into the mouth, the lips being tightly closed. In transilluminating the antra it will be observed that in normal cases there is a considerable difference in the illumination of the face. Thick, square-jawed, heavy-boned individuals illuminate much less brilliantly than thinner-boned subjects. The lower portion of the cheek, up to the level of the *alæ nasi*, is almost invariably well illuminated, even in a diseased antrum. Plate V. illustrates well the difference in transillumination between the right (healthy) antrum and the left (diseased) sinus. It will be observed that the lower eyelid and malar region on the healthy side illuminate brightly, and the pupil shows a reddish glow. On the left, or diseased, side, on the other hand, the malar region and lower eyelid are in shadow and invisible, and no illumination of the pupil can be detected. Any great difference in the illumination of two frontal sinuses or of the two antra should invariably arouse a strong suspicion of infection in these cavities, and cause the examiner to investigate the subject most carefully.

Transillumination is apt to be misleading in cases of bilateral involvement of the frontal sinuses or antra. One has no contrasting healthy side for comparison, and must judge as to the probability of the sinuses being involved by the amount of illumination in a given case. If the conformation of the face is such


as to lead one to suspect a fairly brilliant illumination, whereas only poor illumination is observed, a strong suspicion of sinusitis should be entertained.

The transillumination having been completed and the results noted, the patient returns to the examining chair and the cocainized nasal cavities are again inspected, both anteriorly and posteriorly. In case of sinusitis, secretion may be seen in the middle meatus and along the floor by anterior inspection.

The nasal cavities should next be washed out with normal saline solution through a syringe which is capable of being thoroughly sterilized. The accompanying illustration (Fig. 52) is that of a metal syringe with an asbestos packing, which may be boiled each time it is used.

The nasal cavities are again inspected, and if pus is seen between the middle turbinate and the septum it is an evidence that either the antrum, frontal sinus, or anterior group of ethmoidal cells, or some combination of these, is involved. If secretion is seen between the middle turbinate and the septum, this indicates involvement of

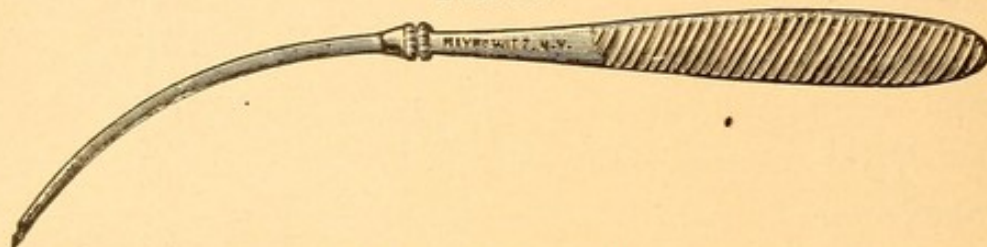
FIG. 52.



Aseptic syringe.

the posterior ethmoidal cells or sphenoidal sinus, or both together.


FIG. 53.



Myles' trocar and canula.

Antrum. Transillumination of the antrum having shown a darkness on one side, with secretion between the middle turbinate and the outer wall, one is justified

FIG. 54.

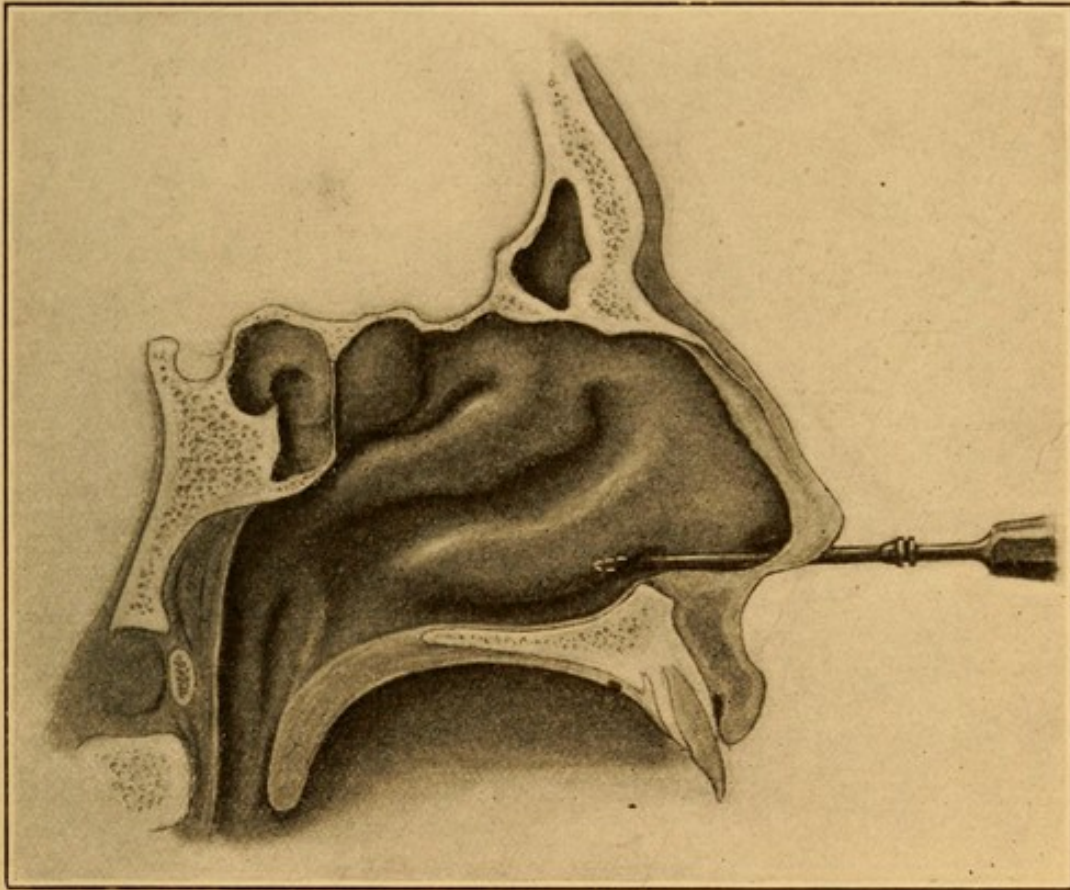


Myles' canula and tube for washing out the antrum of Highmore.

in washing out the antrum. This procedure is performed by first placing a pledget of cotton, moistened with a 10 per cent. solution of cocaine, beneath the inferior turbinate, where the trocar is shown in Fig. 55. It is allowed to remain there for ten minutes. After removal, a Myles trochar and canula (Fig. 53), having been previously sterilized by boiling, is passed into the nose, underneath the inferior turbinate, and at a distance of one inch from the nostril; its point is directed upward and outward, and there pushed through the outer wall of the nasal cavity into the antrum.

Fig. 55 illustrates the distance within the nose that the trochar is inserted, and Fig. 56, the trochar as it has passed through the bony wall of the antrum,

FIG. 55.

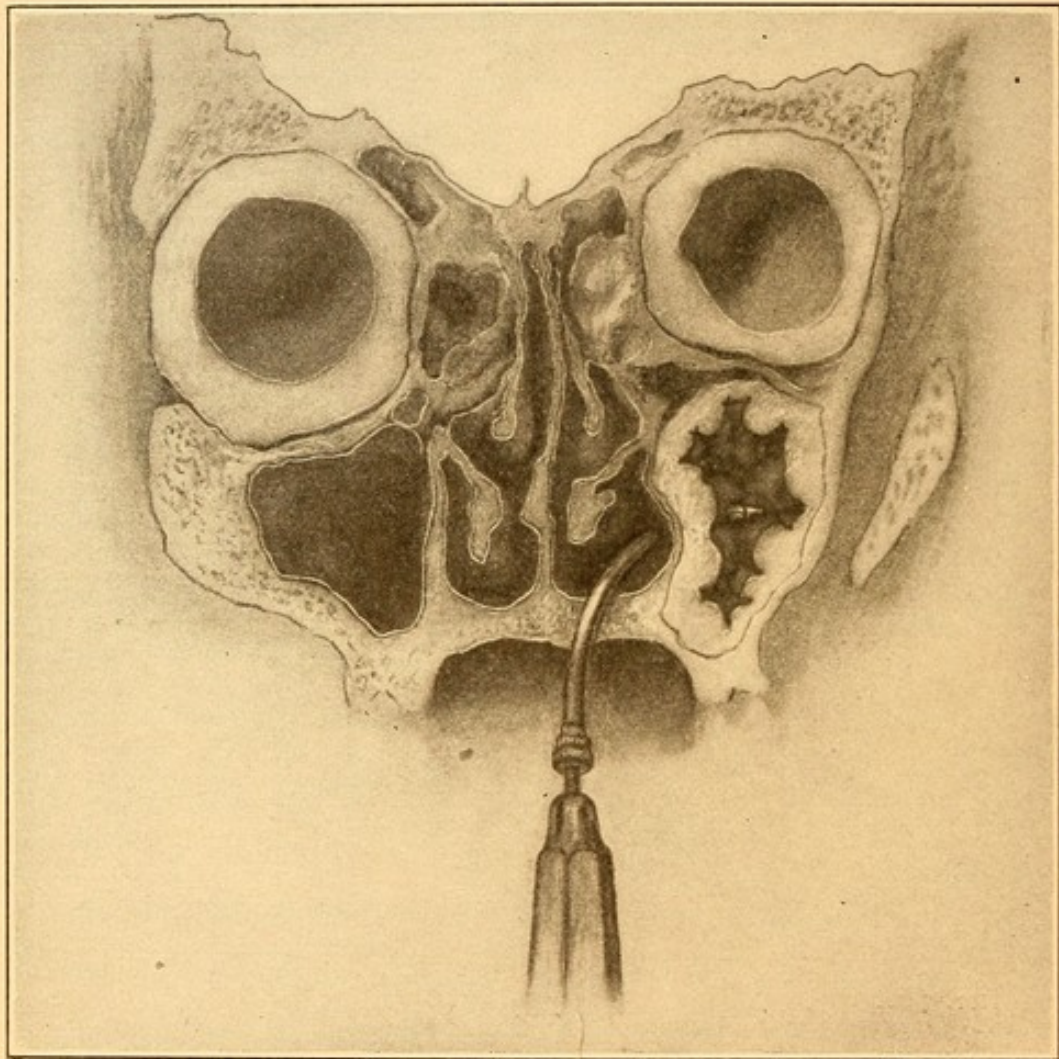


Antero-posterior section of a head with trocar in position for puncturing the antrum. (Author's specimen.)

through the thickened mucous membrane, and the point lying free in the cavity of the antrum. The trochar is next removed, and the irrigating tube (Fig. 54) is inserted into the canula. The aseptic syringe, filled with sterile normal saline solution, forces the latter through the canula into the antrum, and out of the antrum through the normal orifice. If the head is inclined downward, it flows forward through the nose into a pus-basin held below the chin. Any secretion

which may be in the antrum is carried out in the process of syringing. Of course, the nose having been

FIG. 56.



Cross-section of head, showing healthy membrane lining right antrum and thickened polypoid membrane lining left antrum. The point of the trochar is shown piercing the membrane and free in the cavity. (Author's specimen.)

irrigated and inspected, to see that it is free from secretion, any discharge that falls into the basin must have come from the antrum. It occasionally happens that the first or second syringe-full comes away clear or slightly bloody, and that only the third or fourth syringing will bring away a thick, ropy, gelatinous secre-

tion. Oftentimes the first syringeful brings away only mucopus, the succeeding syringeful being clear. Again, the discharge, instead of coming in one thick, ropy mass, will come away disintegrated and flocculent. The latter condition has usually been the case with us when the disease has existed for some time, or when putrefactive bacteria have gained access to the antrum. The importance of this is considerable, for, in the first case, one or two irrigations usually suffice for a cure, whereas, in the disintegrated secretions, a longer-standing process has to be dealt with, and one from which the patient does not so quickly recover. After satisfying one's self that the irrigating fluid has removed all the contents from the antrum, the barrel of the syringe is filled with air, and the latter is forced through the canula, thus blowing out any water that remained in the antrum, so as to leave the cavity dry. In case the antrum is healthy, we have never seen any infection result from this method of puncturing and irrigating an antrum, where one has carefully sterilized the instruments and solutions used.

The nose is again examined, and if pus is still visible between the middle turbinate and the outer wall, in spite of the irrigation of the antrum, it is an indication that the frontal sinus or ethmoidal cells, one or both, are also involved.

Frontal Sinus. Frontal sinus suppuration may be diagnosed with certainty if there exist the pain described above under Symptoms of Frontal Sinus Involvement, and transillumination shows a darkness on that side, and if, after irrigating the antrum, pus is present between the middle turbinate and the outer wall. The

mucous membrane of the middle turbinate is usually so swollen, and approximates so closely the outer wall of the nose, that it is very rarely possible to so contract this membrane with cocaine and adrenalin that one can pass a probe or canula into the frontal sinus for purposes of diagnosis. We have, therefore, to be content with a somewhat less certain diagnosis, unless we proceed to the removal of the anterior third of the middle turbinate, which is unadvisable, except for purposes of drainage. (See *Treatment*.)

Ethmoiditis. It is seldom that the anterior ethmoidal cells are alone acutely involved. The discharge will appear between the middle turbinate and the outer wall, and, being shut in by the middle turbinate, would be very apt to be dammed back into the antrum, thus infecting this cavity, the symptoms of which would overshadow those of the ethmoiditis.

Sphenoidal Sinus. When pus is seen between the middle turbinate and septum, and again, on posterior rhinoscopy, high up in the choana, it is presumptive evidence of sphenoidal sinus suppuration and posterior ethmoiditis. The region between the middle turbinate and septum should be wiped free from secretion with cotton wrapped about an applicator, and then this region contracted with cocaine and adrenalin, on a cotton-wound applicator. After waiting five minutes a sphenoidal probe (Fig. 57) should be passed between the middle turbinate and septum, slightly above the lower border of the middle turbinate, until it reaches the anterior wall of the body of the sphenoid. There it is moved about, upward and downward, slightly to the right or the left, until the tip of the probe is found to

pass through an opening—oftentimes somewhat constricted—into a larger cavity. This will be the cavity of the sphenoid. It can readily be ascertained that the probe is not in the nasopharynx from the fact that all upward, downward, or lateral movements of the probe are restricted by the very narrow opening through which the probe is passed. The mucous membrane lining the cavity when diseased is soft, velvet-like, in contrast with the firm, dense, bony field of a normal mucous membrane. The opening once found by the probe can often be seen anteriorly, and the discharge observed as it is forced out by the probe.

Prognosis. The prognosis in acute sinusitis is good if seen early and efficient drainage be established. The great danger lies in the condition not being recognized, when the severer cases are liable to infect the meninges, terminating fatally or becoming chronic. The milder cases often recover without any special treatment. The average case lasts about ten days.

Treatment. The treatment of acute sinus disease may be divided into constitutional and local. The constitutional treatment should be that which would ordinarily be directed to the disease which this complicates; that is, the constitutional treatment for grip, pneumonia, and so forth.

The local treatment should be directed toward contracting the nasal mucous mem-

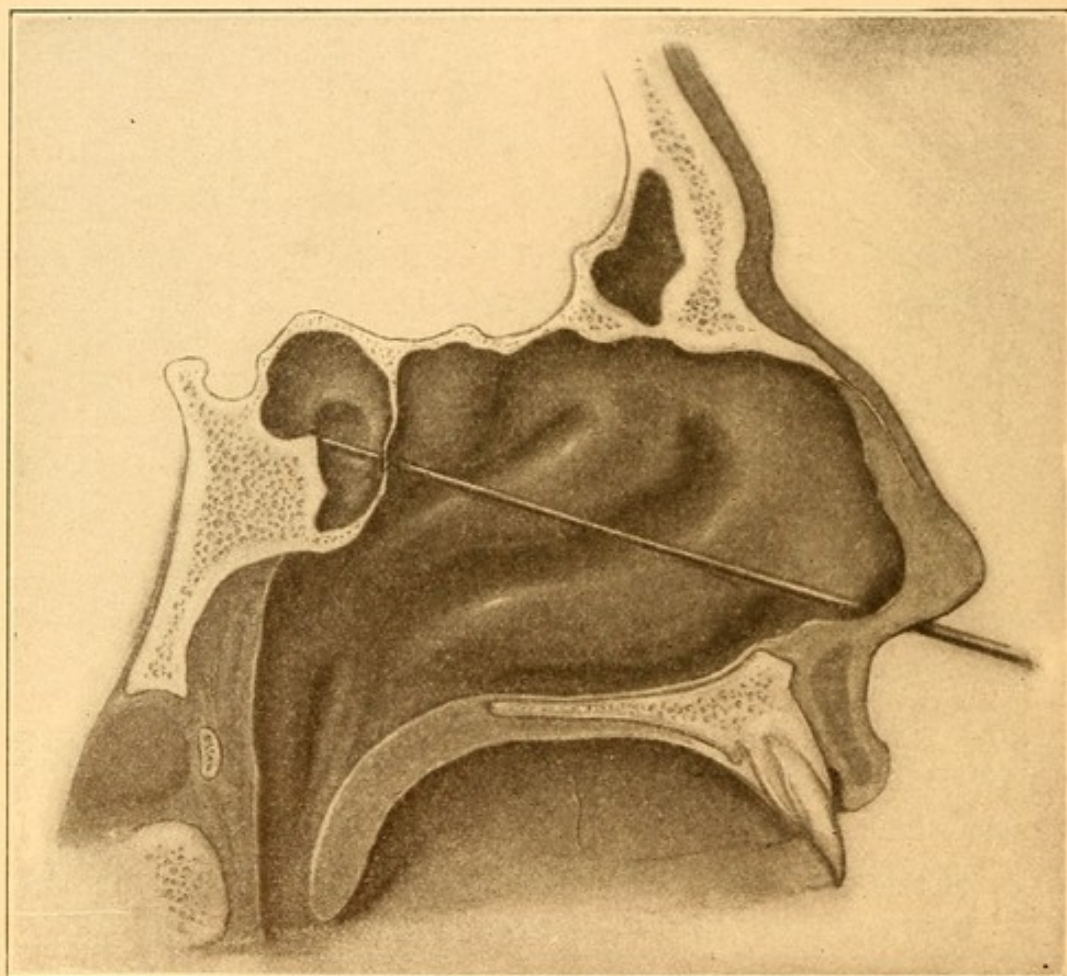
FIG. 57.



Sphenoidal probes, three sizes.

brane and keeping it in this condition. As the swelling of the nasal mucous membrane interferes with the drainage from the accessory cavities, this indication must always be borne in mind, and every effort made to establish drainage. Sprays of adrenalin (1 : 10,000) every two hours usually suffice for this purpose. Syringing the nose with

FIG. 58.

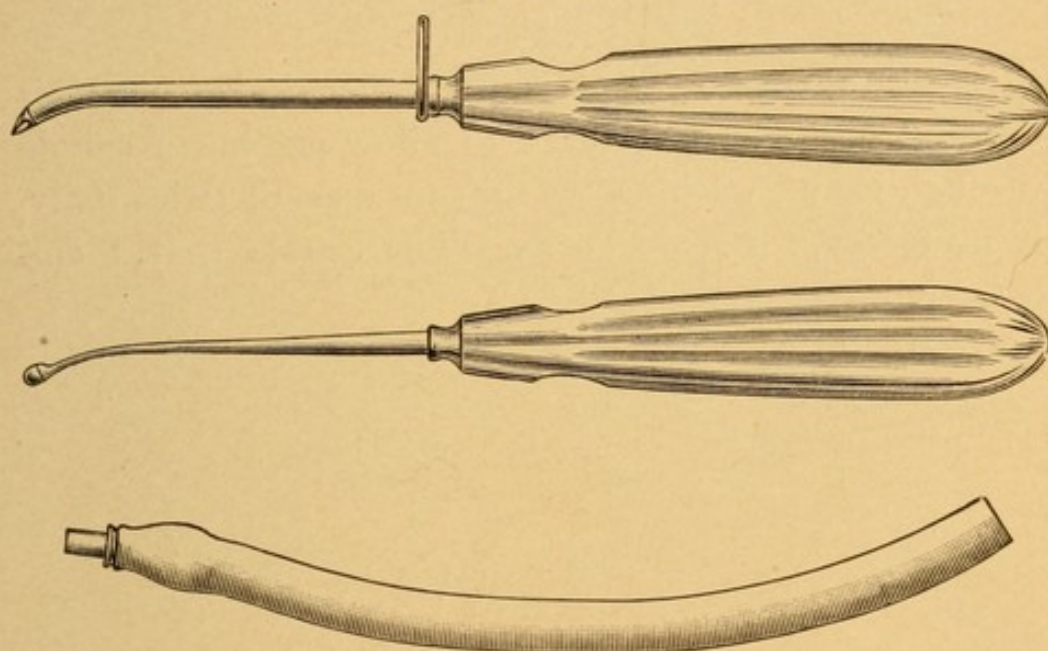


Probe in sphenoidal sinus. (Author's specimen.)

hot normal saline solution often removes the discharge far better than by using the handkerchief, and assists in keeping the nasal mucosa contracted. Steam inhalations occasionally are of value for the same purpose. Sometimes, when these means have failed, a 1 per cent.

solution of cocaine may be placed in the hands of a trained nurse or assistant, to be used in spraying the nose, for purposes of contracting the mucous membrane. It is, however, a very dangerous plan to give a prescription for cocaine which shall be placed in the hands of the patient, to be used indiscriminately, on account of the danger of contracting the cocaine habit.

FIG. 59.




Halle's trochar and canula.

SPECIAL LOCAL TREATMENT—ANTRUM. Whenever the antrum is filled with secretion, puncturing and washing it out, as mentioned under the head of *Diagnosis*, should be performed. If the cavity refills, as it may in the course of from twenty-four to forty-eight hours, as evidenced by the large amount of discharge from the nose, again, at the end of this time, a second paracentesis and irrigation is indicated. In the severer types of acute cases the procedure may have to be repeated daily for a couple of weeks. Where such a

condition is to be apprehended I prefer making a larger opening in the inferior meatus by means of a Halle trochar (Fig. 59), which has the double advantage of affording an outlet for the secretion near the floor of

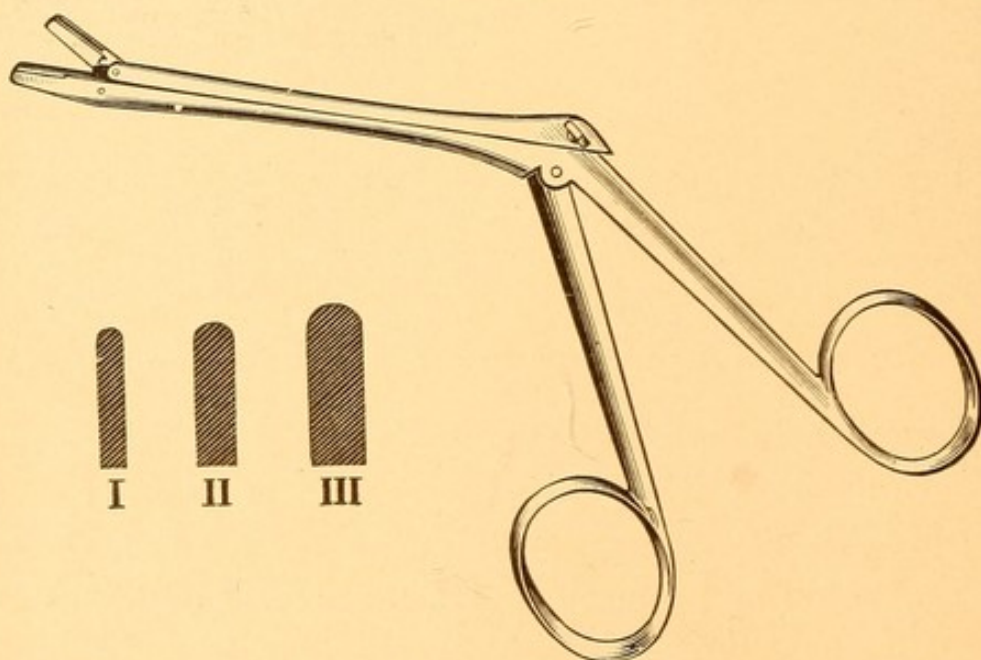
FIG. 60.



Eustachian catheter for irrigating an antrum after puncturing with Halle's trochar.

the antrum, thereby establishing better drainage. This opening is sufficiently large to allow passing a canula through it and washing the antrum once or twice daily, if necessary, for some weeks. The canula that I em-

FIG. 61.



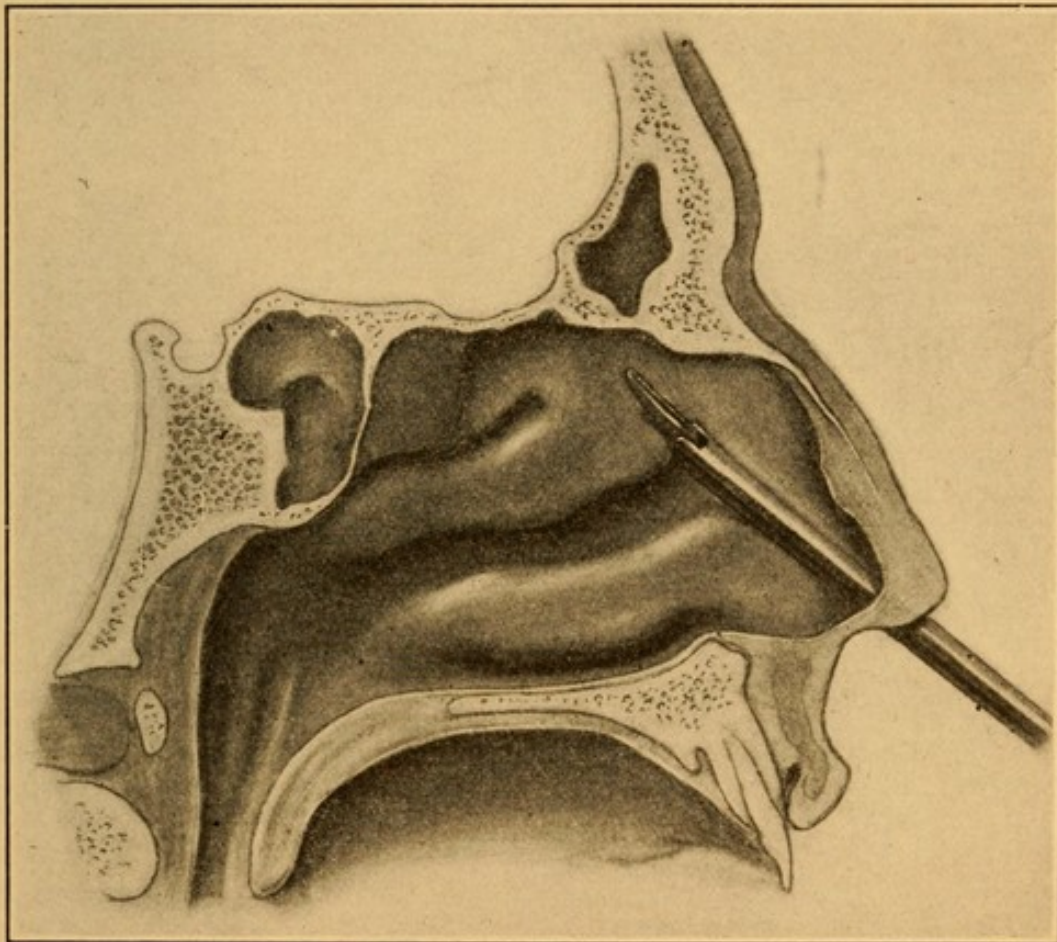
Myles' nasal punch, three sizes. The smallest is the most useful.

ploy for this purpose is a Eustachian catheter (Fig. 54), the tip of which has been sealed over to facilitate introduction, and the fenestra placed on the convexity near the tip. We have never found any advantage, but

oftentimes great harm has come, from irrigating an antrum with any antiseptic or astringent solution.

If the disease is secondary to a carious tooth, the latter should be extracted, and the antrum drained through the alveolus. The trephines and burrs (Fig. 65) are useful for this purpose.

FIG. 62.

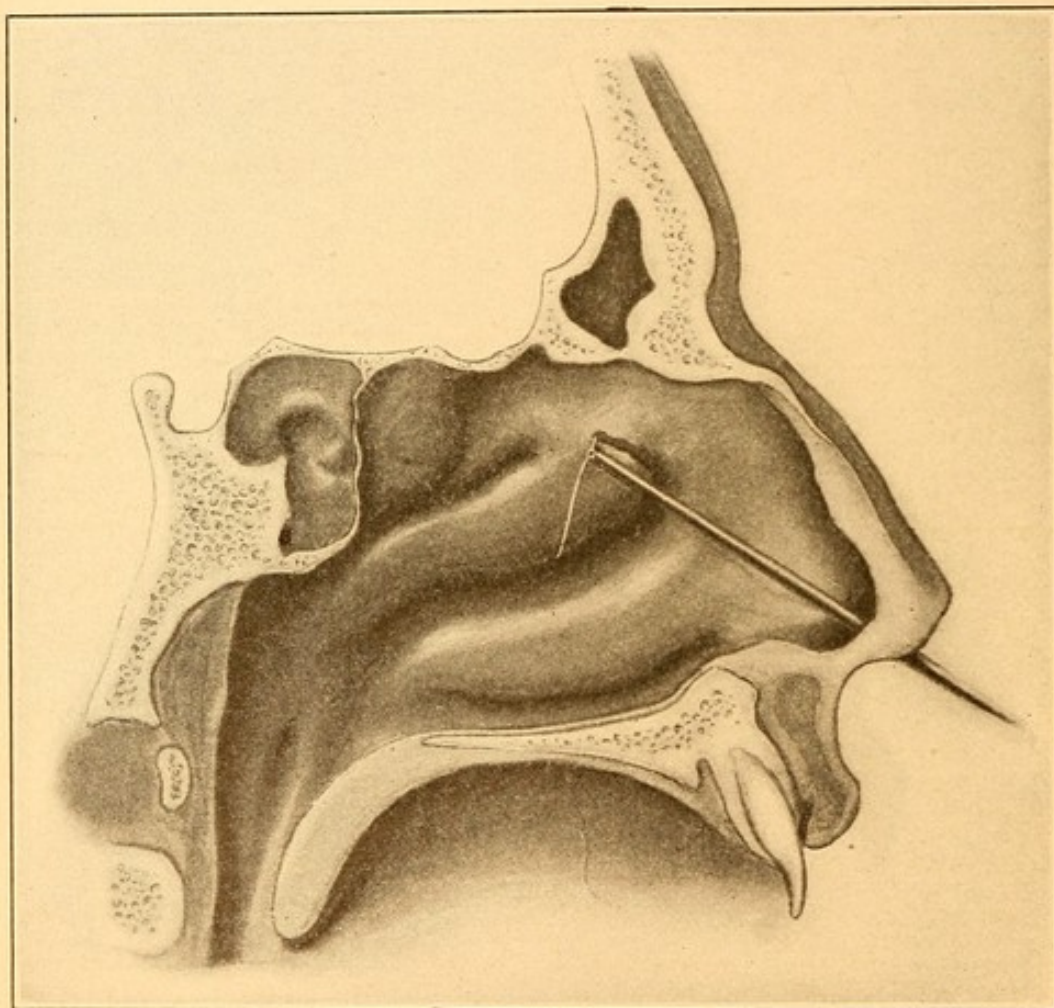


Myles' forceps in position for severing anterior portion of attachment of the middle turbinate.

FRONTAL SINUS. If the use of adrenalin, cocaine, and other general means does not suffice for drainage from the frontal sinus, as evidenced by the pain and discharge from the sinus, then we must infer that the drainage is unsatisfactory, and it becomes necessary first to remove the portion of the middle turbinate which is

anterior to the lower opening of the nasofrontal duct. Both sides of the anterior portion of the middle turbinate should be cocainized thoroughly, and painted with a 1:1000 solution of adrenalin. A small-sized Myles nasal cutting-forceps (Fig. 61) should be passed into the

FIG. 63.



Attachment of middle turbinate severed and wire in position for excising anterior end of middle turbinate.

nose, with the blades partially open, so that they may straddle the anterior portion of the attachment of the middle turbinate to the lateral wall of the nose (Fig. 62). The forceps is then closed, so that a piece is bitten out, as in Fig. 63. The wire loop of the snare is then

passed into the nose, so as to cut off the anterior portion of the middle turbinate, as shown in Fig. 63. The portion removed is shown in Fig. 71. By this means we remove the middle turbinate, together with the swollen membrane on the external surface of it, which usually is the offending member in preventing drainage. Sometimes a small polyp, heretofore undetected, is found blocking the outlet of the nasofrontal duct, and if so, it is removed by snare or forceps. In a very large percentage of cases—in fact, in all but one case in the writer's experience—this means has established excellent drainage, with the rapid subsidence of the suppuration in the frontal sinus. Should, however, drainage be insufficient, pain and symptoms of tension in the frontal sinus persist, especially if there is œdema and redness of the upper eyelid, then it is necessary to open the frontal sinus by an incision through the eyebrow, peel up the periosteum over the anterior surface of the frontal bone, chisel through the bony wall, and proceed in the manner described for the radical treatment of chronic frontal sinusitis, *q. v.*

ETHMOIDITIS. The local treatment of acute ethmoiditis demands a means of affording an outlet for the discharge from the ethmoidal cells. As the middle turbinate usually greatly interferes with drainage, its anterior portion must be removed in the same manner as described in the article on *Acute frontal sinusitis*. It is only rarely that it is necessary, in an acute case, to open the ethmoidal cells, as described in the article on *Chronic ethmoiditis*.

SPHENOIDAL SINUS. In acute sphenoidal sinusitis it is necessary to cocaineize the space between the middle turbinate and the septum, and locate with the probe, as

above described, the normal opening of the sphenoidal cavity. A sphenoidal canula (Fig. 64) should then be passed into the sinus and the cavity irrigated with

FIG. 64.



Sphenoidal canula.

normal saline solution. A few irrigations, at intervals of twenty-four hours, usually suffice for the cure of this condition.

CHRONIC DISEASES OF THE MAXILLARY SINUS.

These may be divided into chronic suppuration or empyema, polypi, cysts, osteomata, and malignant growths.

Chronic Suppuration of the Antrum.

Etiology. Chronic empyema of the antrum is invariably secondary to acute suppuration. When an acute attack is not recognized, and it has been of such severity as not to undergo spontaneous cure, the disease becomes "chronic."

Pathology. The early pathological changes are the same as those met with in acute sinusitis, *q. v.* Later, the round-cell infiltration into the subepithelial and periosteal layer undergoes organization, with the result of a greatly thickened, polypoid-like mucous membrane. It is not uncommon to find the mucous membrane half an inch thick in places. Not infrequently contraction of

the organizing connective tissue produces a great unevenness in the contour of the membrane, so that it appears very rugous (Fig. 56). Oftentimes well-formed polypi are found projecting from various portions of the membrane.

Symptoms. The principal complaint of patients suffering from chronic suppuration in the antrum is a discharge from the nose. This may be very abundant at all times, usually more copious in the morning than during the remainder of the day. Post-nasal discharge, when in the recumbent posture, is frequently observed. The amount of the discharge often varies considerably, being much greater at times than at others, and the patients frequently state that they are very subject to colds in the head. At such times the discharge is very profuse, and with the subsidence of the acute exacerbation the amount of the discharge diminishes to such an extent that they complain but little of it during the interval. In many of the long-standing cases there is considerable fetor to the discharge. There is seldom any pain associated with these chronic cases, and almost never any rise in temperature, as is usually the case in a suppurative process.

Examination. Any patient who gives a history of considerable discharge from one or both nasal cavities should be carefully examined for suppuration in some of the accessory cavities. It not infrequently happens that upon the first visit of the patient to the physician's office no secretion is visible in the nose, when examined either anteriorly or posteriorly, to direct one's attention to the accessory cavities. This is often due to the fact that patients spray their noses just before coming to visit a specialist or, on entering the office, blow the nose,

thereby freeing it from every trace of discharge. In such cases transillumination has many times directed my attention to an antrum where the history or examination of the nose did not lead me to suspect a chronic suppuration in the antrum. In the large percentage of cases, however, inspection of the anterior nares shows the presence of pus in the middle meatus, often flowing down the middle of the inferior turbinate to the floor of the nasal cavity. Posteriorly the secretion may be seen in a streak over the upper portion of the inferior turbinate, and so down along the upper surface of the soft palate. Transillumination, if one antrum only is involved, as described under *Acute Sinusitis*, almost invariably shows the shadow produced by the greater obstruction to light on the diseased side, as compared with the healthy side. If both antra are involved, the great darkness, on transillumination, in the region of the malar bone and lower eyelid on each side, and the lack of illumination of the pupil, even when a strong light is used, should invariably cause one to puncture the antrum for the purpose of ascertaining whether or not it is the seat of disease.

The method of puncturing the antrum is the same as that which is described under the head of *Acute Sinusitis*. If some doubt exists in one's mind as to whether or not the antrum is involved, I am in the habit of using the small Myles trochar and canula (Fig. 53). If, however, the history of the case, the presence of pus in the middle meatus, and transillumination all indicate chronic suppuration in an antrum, I use the largest-sized Halle trochar, in order that the opening thus made may remain patent, and be readily found for subsequent daily irrigations.

The teeth should also always be inspected to determine whether any one of these may not have been the cause of suppuration.

Prognosis. The prognosis in a chronic suppuration of the antrum depends upon the treatment that is instituted. In some even long-standing cases irrigations through an artificial opening made in the nasal wall of an antrum will result in a cure, in from three weeks to three months. In other cases, when the disease has been apparently cured in this manner, the first cold starts the trouble up again, and nothing short of a radical operation suffices for a cure. The time necessary for the latter varies from two to six months.

FIG. 65.



Trephine.



Burr.

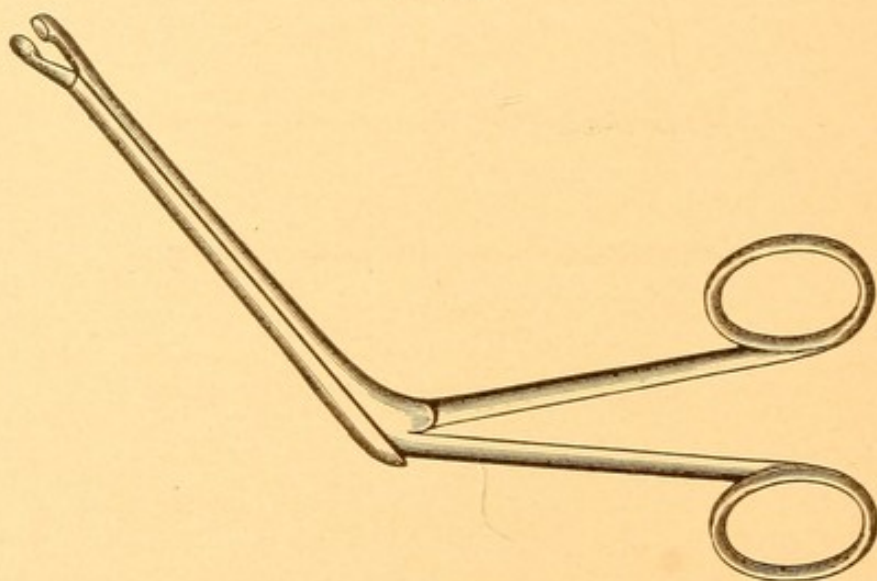


Burr.

Treatment. The first step to be undertaken before treating a chronic empyema of the antrum is to determine whether any existing teeth are decayed and likely to continue as a source of infection to the individual. If so, they must be treated by a dentist or extracted. If the patient is willing to undergo a long course of irrigations, then it is my custom to open the nasal wall of the antrum beneath the anterior third of the inferior turbinate, first with a large Halle trochar, and then enlarge this opening with either trephines or burrs

(Fig. 65). This may be inserted into a hand-piece such as dentists employ. The power for rotating the drills may be derived from an electric motor or from the ordinary foot-engine used by dentists. I more frequently employ a Grünwald punch-forceps (Fig. 66). The opening is thus enlarged to half an inch in diameter. Owing to the swelling and inflammation around the margin of this opening, the physician himself should irrigate the antrum for the first ten days; after this time the patient may be given a canula and instructed how to wash the antrum himself, night and morning, with normal saline solution. The patient should report

FIG. 66.



Grünwald punch-forceps.

once or twice a week for examination as to the condition of the cavity. In spite of this large opening there is considerable tendency for its closure by granulation tissue formed from its margins, and usually once a month or thereabouts it will be necessary to cocaine the area and again enlarge the opening. Transillumination is a valuable guide as to the progress of healing.

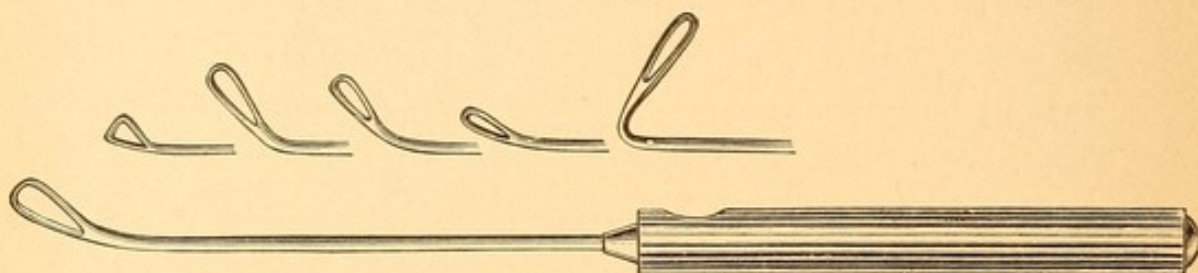
Where the case is progressing favorably, transillumination will show a gradual increase in brilliancy on the diseased side, and when the mucous membrane has undergone retrograde metamorphosis the illumination of the diseased side will be nearly as good as that of the healthy side.

If it happens that the patient lives at some distance from one's office, and cannot spare the time to experiment with treatment by irrigation, then the radical operation is advised immediately, as this procedure is necessary in all chronic cases not healing by irrigation.)

RADICAL OPERATION. Many varieties of radical operation have been advocated, but the one which has given the author the most satisfactory results is the following: The patient is anæsthetized, the skin of the face sterilized, and an incision made in the gingivobuccal fold, on the affected side, beginning posteriorly, a quarter of an inch above the gum of the last molar tooth, and extending forward parallel with the line of the gums, and a quarter of an inch above it, to the lateral incisor tooth, the incision to be carried through the mucous membrane and periosteum, down to the bone. No bloodvessels requiring ligation will be encountered. With a periosteal elevator lift up the periosteum and overlying tissues over the entire anterolateral surface of the antrum as far as the infra-orbital foramen. A medium-sized straight chisel cuts through the outer wall of the antrum in the canine fossa, care being taken to disturb the underlying mucous membrane as little as possible. This opening is then enlarged with bone-scoops and forceps until the entire anterolateral wall of the antrum is removed, from the floor upward, as high as the infra-orbital foramen, anteriorly to the

junction of the anterior with the nasal wall, and posteriorly to a point above the first molar tooth. With variously shaped curettes (Fig. 67) the mucous mem-

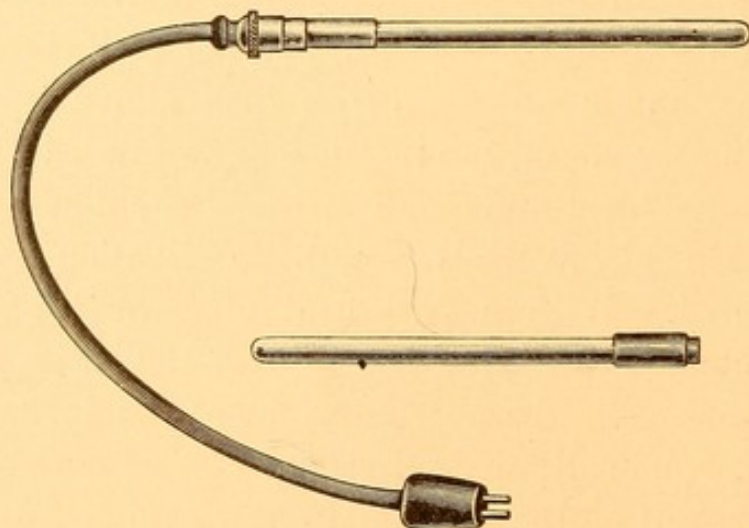
FIG. 67.



Coakley sinus curettes.

brane of the antrum is completely removed from every nook and corner. In order to facilitate this removal a small electric lamp (Fig. 68) is inserted in the antrum, so that the cavity may be most carefully inspected.

FIG. 68.



Author's lamps for illuminating the antrum and frontal sinus while operating.

Any small shred of mucous membrane that is left will invariably result in failure to secure healing. The cavity is then packed with 5 per cent. iodoform gauze, care

being taken to separate widely the upper and lower margins of the incision in the wound under the cheek, to facilitate the removal of the gauze, and future inspection of the cavity and dressings. The gauze is removed on the sixth to the eighth day, according to the amount of secretion. The cavity is not irrigated, but is immediately repacked with the same kind of gauze, and thereafter the renewals of gauze should be made at intervals of four or five days. Usually at the end of two weeks' time the entire inner surface of the antrum is lined with healthy granulations. These continue to grow and gradually fill the cavity of the antrum. The packings are discontinued at the end of about a month, provided the granulations are healthy in appearance. The wound in the cheek is simply protected by a small piece of gauze, held in place at meal-times. At the end of a month it will only be necessary for the patient to report once in two or three weeks for inspection of the cavity. Should any œdematous, polypoid, and easily bleeding areas appear during the course of healing, it is almost invariable evidence that some of the mucous membrane lining the cavity was left in place at the time of the operation, and usually necessitates pretty thorough scraping, under cocaine anæsthesia, in order to remove it. The complete filling up and obliteration of the antrum is accomplished in from three to six months, sometimes a little longer. No deformity of the face follows this operation.

POLYPI OF THE ANTRUM.

Polypoid degeneration of the mucous membrane of the antrum is often seen in long-standing cases of

empyema. The causes of this form of degeneration are probably the same as those of nasal polypi, *q. v.*

Symptoms. Accompanying, as it does, empyema of the antrum, the symptoms are practically the same, and it is usually only after the antrum has been opened by one of the operative procedures described under the *treatment of empyema of the antrum* that polypi are detected. A polyp in the middle meatus occasionally has its point of attachment just within the antrum, near the normal opening. It may develop saddle-bag like, part in the nose and part in the antrum. If a tenaculum is used, the hidden part of the polyp within the antrum may be drawn out into the nasal cavity.

Treatment. Where polypi are found in the antrum they should be removed by the curette most thoroughly, under general anæsthesia, as in the radical operation for the cure of chronic antrum suppuration.

CYSTS OF THE ANTRUM.

Cysts of the antrum are of two varieties—those which develop within the mucous membrane proper, and those which develop external to the antrum around the roots of teeth, and usually only invaginate the antrum.

*cyst within
M. M. proper.* **Symptoms.** The first variety of cyst may be suspected where an intermittent, watery discharge occurs from one nostril. Examination of the nose usually shows a bulging of the outer wall on the affected side. The bulging may affect also the other walls of the antrum, so that the face may appear asymmetrical, being swollen on the affected side. Puncture of the antrum, as described in the article on *Acute Antrum Disease*, invaria-

bly results in a portion of the fluid coming out through the canula.

Treatment. The antrum should be freely opened, as in *Chronic suppuration*, the cavity thoroughly explored, and the thickened diseased membrane treated in the same manner as described in that article.

THE SECOND VARIETY. Dentigerous cysts develop from cystic degeneration of the wall of the tooth-sac. The development begins usually by enlarging the bone of the superior maxilla until it has eroded the bony wall of the antrum, when the enlargement continues, pushing before it the mucous membrane of the antrum. From this time on the development of the cyst is quite rapid, often completely filling the cavity of the antrum and producing bulging of the anterior and nasal wall. There is frequently bulging of the hard palate as viewed from the mouth, so that this region is convex instead of the normally concave condition. It differs from the former variety in that there is never any discharge into the nasal cavities. A quite characteristic condition is the parchment-like, crackling sensation that is observed on palpating the outer wall of the antrum. The fluid contained in a cyst is thick, gelatinous, usually greenish in color, devoid of odor, and frequently contains cholesterol crystals. If spontaneous rupture occurs the cavity may become infected by the pus-producing germs, in which case there are developed all the symptoms of a localized abscess with foul-smelling discharge.

Treatment. The cyst is best treated by an incision in the gingivo-buccal fold, the cavity irrigated with a weak (1 : 100) carbolic solution, and packed with iodoform gauze. Contraction of the cyst wall takes place

*cyst extends
to antrum*

fairly rapidly, and agglutination of the walls obliterates the cyst. Occasionally this is not accomplished, reaccumulation of fluid ensues, when the cyst has again to be opened and its lining wall excised.

OSTEOMATA OF THE ANTRUM.

Osteomata of the antrum occur rarely, and are usually seen as a manifestation of tertiary syphilis.

Symptoms. The symptoms produced by osteomata are never marked so long as the growth is confined to the cavity of the antrum. It is only when the outer wall of the nose is pushed into the nasal cavity or back into the nasopharynx that symptoms are produced. They are then those of nasal obstruction.

Examination. Examination of the nasal cavity shows a bulging of the outer wall of the nose, with a hard, ivory-like resistance to the probe. Transillumination shows the face on the affected side very dark as compared with the healthy side. Attempts made to puncture the antral cavity with the trochar and canula result in failure to penetrate the dense bone. The nose is usually found free from any abnormal secretion, unless complicating diseases coexist.

Differential Diagnosis. Osteoma of the antrum is to be differentiated from malignant diseases of the antrum. In malignant disease the growth is very rapid, while in osteoma it is very slow. In malignant disease there is usually pain, while osteoma is devoid of pain until the tumor becomes large. Malignant disease tends to burst through the outer wall of the nose and to appear within the nasal cavity as a reddish mass, which bleeds easily and gives rise to an abundant secretion. An osteoma pushes out the external wall of the nose rather than

breaks through it, is pale in color, does not bleed freely, and gives rise to no secretion. Osteomata are often multiple, involving the bones of the cranium as well as those of the antrum.

Prognosis. Osteomata, when removed, seldom recur.

Treatment. If small, these growths had better be treated by the internal administration of potassium iodide and the iodide of iron, which may check their growth. If sufficiently large to produce marked nasal obstruction, they should be removed with the chisel and gouge under general anæsthesia, the antral cavity being thoroughly exposed by dissecting up the face and entering the antrum through the anterior wall.

MALIGNANT DISEASE OF THE ANTRUM.

Sarcoma of the antrum and osteosarcoma of the antrum are the two most common forms of malignant growths invading this cavity. A few cases of epithelioma have been reported. These growths may originate in the antrum or be secondary to similar growths in the nasal cavity.

Symptoms. The symptoms of malignant growths in the antrum are those of a rapidly growing tumor, which fills the antrum and breaks through the wall of the antrum into the nose or nasopharynx. At this stage nasal obstruction becomes marked; a mucopurulent, perhaps fetid, discharge is seen; pain of a lancinating and boring character is experienced, and when the mucous membrane of the nasopharynx is invaded enlargement of the glands at the angle of the jaw may be distinctly felt.

Prognosis. Prognosis in sarcoma of the antrum occurring in childhood, where the growth can be thoroughly

removed, is fair. There seems to be less tendency for these growths to return than for the other forms of malignant disease.

Treatment. Where malignant growths of the antrum are diagnosed, it is best to remove the entire superior maxilla by one of the methods given in text-books on general surgery.

CHRONIC DISEASES OF THE FRONTAL SINUS.

These are chronic suppuration or empyema, cysts, osteomata, and malignant growths.

Chronic Suppuration of the Frontal Sinus.

Etiology. Chronic suppuration in this sinus is caused in the same manner as the similar infection of the antrum. Unquestionably, a chronic ethmoiditis is a frequent source of inducing suppuration in the frontal sinus, as many of the anterior ethmoidal cells are found around the lower portion of the nasofrontal duct, and as the result of the imperfect drainage and retention of secretion, rupture of the ethmoidal cells, with their infective contents, passes into the frontal sinus. We have records of several cases of suppuration, starting originally in the antrum, that have subsequently infected the ethmoidal cells and frontal sinus.

Pathology. The pathological changes in the mucous membrane of the frontal sinus are the same as those in chronic suppuration of the antrum.

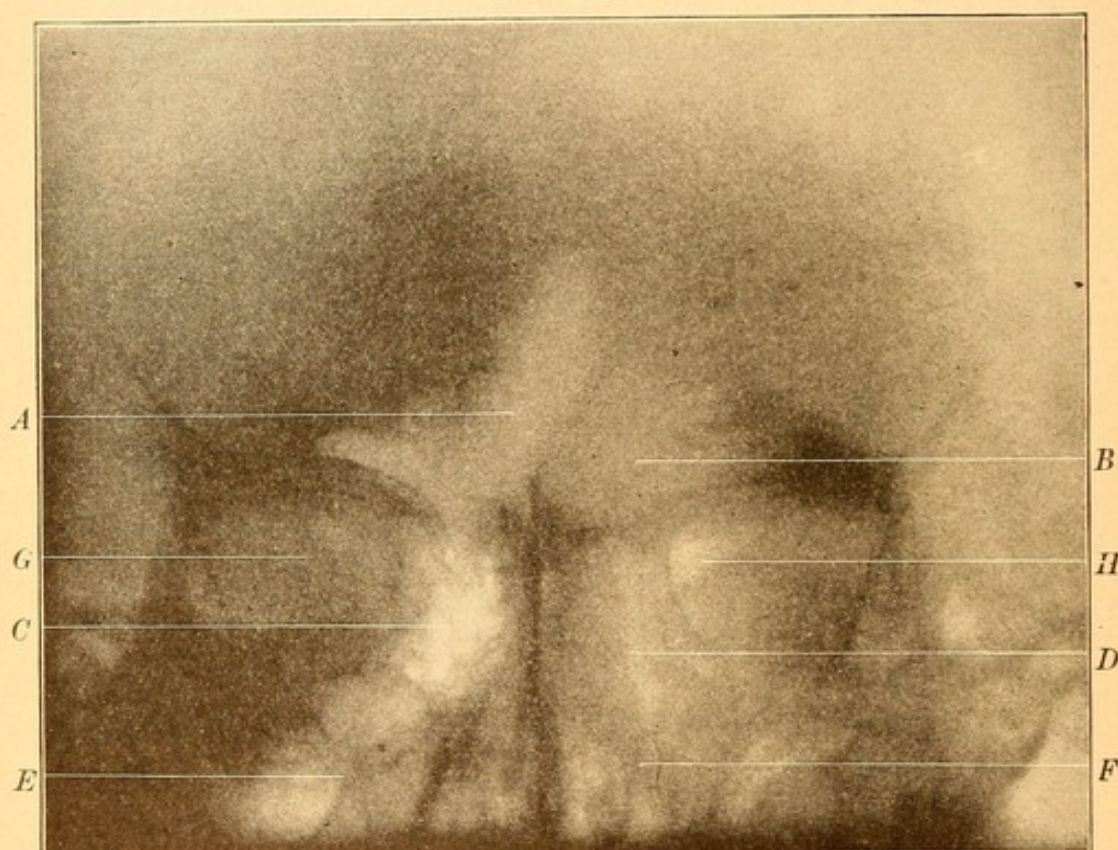
Symptoms. Two principal symptoms characterize this disease : 1. Discharge of pus into the nose, which is usually blown from the anterior nares, the victim complaining of catarrh. Occasionally, on account of some obstruction in the anterior portion of the middle meatus, the flow of pus is directed backward, and is complained

of as a dropping from the posterior nares. 2. There is rarely acute pain, which is such a prominent symptom in acute frontal sinusitis. Very frequently there is a feeling of fulness in the head, a "sense of pressure," as they explain it. Sometimes this amounts to moderate pain during colds in the head, at which times the discharge is greater and the lower portion of the nasofrontal duct more or less blocked. Polypi, with the accompanying nasal obstruction, is a source of discomfort, for which patients very frequently seek relief. Fistula formation, as described under *Acute frontal sinusitis*, occasionally occurs. Meningitis, either from rupture of the posterior wall of the frontal sinus, with infection of the meninges, or as a result of infection through the bloodvessels and lymphatics leading from the mucous membrane, has occasionally developed.

Examination. The presence of pus in the middle meatus, between the middle turbinate and the outer wall, should at once excite one's suspicions as to the possibility of frontal sinusitis. This region should be cocainized and sprayed with a 1 : 10,000 adrenalin solution, in order that the tissues may be well contracted. The presence of polypi in this region also should cause most thorough examination of the frontal sinus, as often in these cases this particular region will be found to be diseased. Transillumination of the frontal sinus may show considerable darkness on the diseased side. This, of itself, is quite suspicious, but the difference in illumination may be due to the very unequal development in the size of the two sinuses. This is far more common in frontal sinuses than in the antra. Where facilities exist, a skiagraph (Fig. 63) should be taken of the patient's head. This will show very accurately the height and breadth of the frontal sinuses, the position

of the septum between the two, and oftentimes the subsidiary, incomplete septa in each cavity, if they exist. The value of a skiagraph in connection with transillumination is very great. If a skiagraph shows two frontal sinuses of practically the same extent, and yet transillumination shows a far smaller area, and poorer illumination on one side than the other, very strong suspicions

FIG. 69.

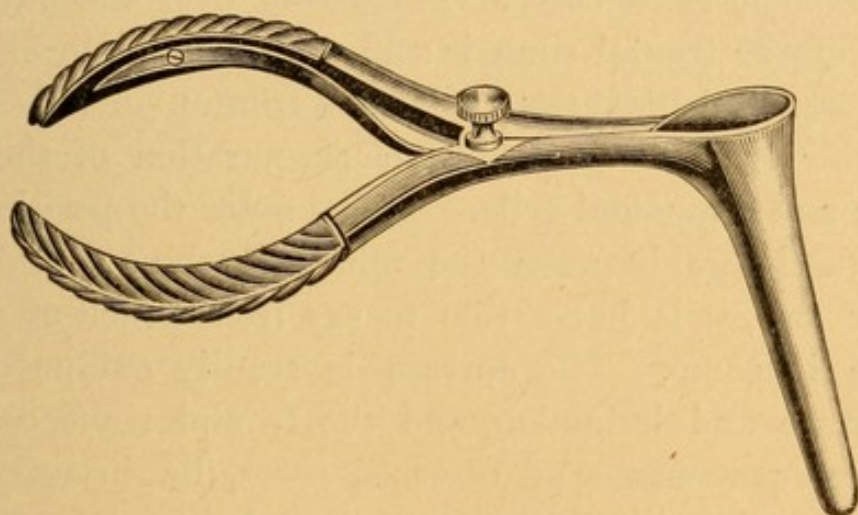


Skiagraph of patient's head. *A*, healthy right frontal sinus; *B*, diseased left frontal sinus; *C*, healthy, *D*, diseased ethmoids; *E*, healthy, *F*, diseased antrum; *G*, *H*, orbital cavities.

of chronic frontal sinusitis should be entertained. The middle turbinate, in cases where polyp formation exists between the middle turbinate and the outer wall, is usually pressed toward the median line to such an extent that there is little difficulty in passing a suitably curved probe up through the nasofrontal duct into the frontal

sinus. The proper curvature is that which is shown in Fig. 71. In case the middle turbinate hangs too closely to the outer wall of the nose, a Killian rhinoscopic speculum (Fig. 70) may often be passed, with its blades closed, between the turbinate and the outer wall. When the blades are separated, the turbinate can be forced toward the septum far enough to afford room for the passage of the probe. If this does not suffice, recourse must then be had to excising the anterior portion of the middle turbinate with forceps and snare, as shown in Figs. 62 and 63. The hemorrhage is usually slight, and can be

FIG. 70.



Killian rhinoscopic speculum.

controlled by the insufflation into the nasal cavity of powdered suprarenal gland. In a large percentage of cases, by having employed one of the means above described, the probe can be passed into the frontal sinus. If the mucous membrane is healthy, the tip of the probe gives one a sensation of encountering hard bone with but a very thin covering; if the mucous membrane of the cavity be thickened, as it always is in chronic suppuration, then the tip of the probe gives one the same sensation as that obtained on pressing against

a piece of velvet. Usually some pus flows along the side of the probe as it passes up the nasofrontal duct. A suitably curved canula (Fig. 72) may be passed upward through the nasofrontal duct into the sinus, and the cavity irrigated with normal saline solution. As a usual thing only a few drops of secretion may be expected from this procedure, as, no matter how large the frontal sinus may be, the actual space within the cavity is but small, owing to the encroachment made by the greatly thickened mucous membrane. Pressure on the orbital plate of the frontal sinus, as in the case of acute sinusitis, is painful, but rarely to the extent observed in acute cases. Percussion over the anterior wall of the frontal sinus is seldom painful.

Differential Diagnosis. Chronic frontal sinusitis is to be differentiated from chronic suppuration of the antrum and ethmoidal cells. If one notes the position of the discharge between the middle turbinate and the outer wall, it is impossible to say from which of these three it came. The antrum is readily excluded by puncture and irrigation, and the frontal sinus can, in a large percentage of diseased cases, be investigated with a probe, either at once or after the operative measures indicated, so that there ought to be little doubt as to the diagnosis. It is possible that the probe may enter an anterior ethmoidal cell which extends upward toward the root of the nose; but if one take the precaution to measure the length of the probe, and compare it with the conformity of the head by placing it outside on the face, parallel with its position when in the nose, there ought to be little doubt in the examiner's mind as to how high upward the end of the point was while examining the patient through the nose.

Prognosis. The prognosis in chronic suppuration of

the frontal sinus depends upon the amount of change that has taken place in the mucous membrane, and upon the size of the cavity and the number of septa within it. A small frontal sinus without septa can usually be treated intranasally with good prospects of cure. A large frontal sinus, with many septa and a recess that extends backward over the orbit, containing badly thickened mucous membrane, can seldom be more than relieved of its worst symptoms by any intranasal treatment. The radical operation only can in such cases effect a cure. Unquestionably, a chronic suppurative frontal sinusitis is a menace to the life of the patient, on account of the sudden blocking of the lower portion of the nasofrontal duct, and the consequent danger of secretion breaking through into the cranial cavity and setting up a fatal meningitis.

Treatment. The treatment of chronic empyema of the frontal sinus may be considered under two heads :

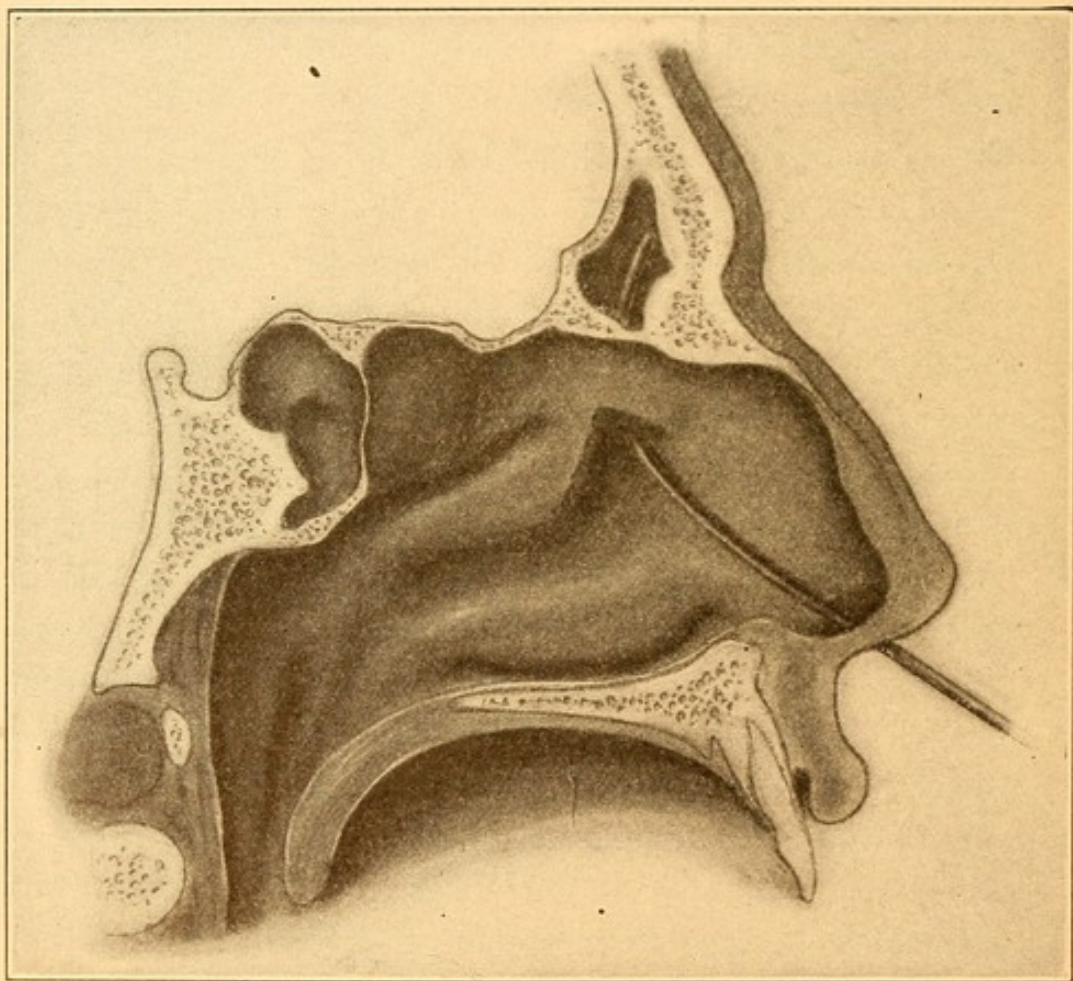
1. Intranasal treatment.
2. External operative treatment.

The INTRANASAL TREATMENT consists in removing so much of the anterior portion of the middle turbinate as may be necessary in order to readily get at the nasofrontal duct. This is done by the use of the forceps and snare, as shown in Figs. 62 and 63. A frontal sinus canula (Fig. 72) is then introduced through the nasofrontal duct and the cavity irrigated once or twice daily with hot normal saline solution. As many of the ethmoidal cells bordering anteriorly upon the lower portion of the nasofrontal duct are also invaded, in these cases they will have to be opened, as described under *Ethmoiditis*. Gentle curettage of the nasofrontal duct, pressure being made mostly anteriorly, may be employed to dilate the canal. The patients may fre-

*irrigate
+ drain
dilute
nasofrontal
duct.*

quently be taught how to pass a canula, so that they may themselves irrigate the sinus as often as is necessary. In a small sinus, with a not too badly diseased membrane, this method has proved very serviceable. One difficulty is that, not infrequently, the first cold in the head excites anew a suppuration in the sinus, months

FIG. 71.



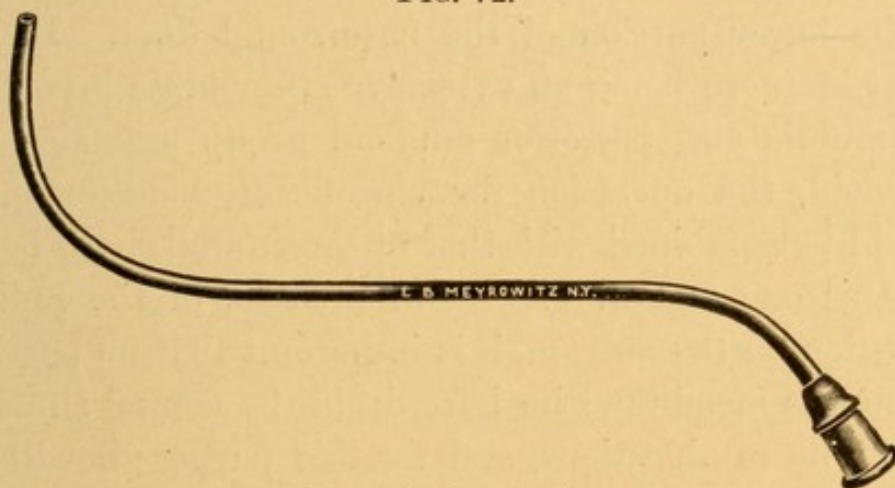
Section of head, showing resection of anterior third of middle turbinate, and a frontal sinus canula with proper curve *in situ*. (Author's specimen.) Two-thirds normal size.

after a cure has been thought to be complete. In enlarged sinuses, with multiple septa, orbital recesses, and badly thickened mucous membrane, the above method of treatment may afford temporary relief, but is apt to necessitate continual treatment on the part of the

patient or the physician. In such cases the radical operation about to be described is the one that the author has used with practically unfailing success.

RADICAL OPERATION. The patient is anæsthetized, and the skin of the forehead, eyebrows, and upper portion of the face sterilized. An incision is then made through the middle of the unshaved eyebrow, beginning at the nasal end and extending outward to the external angular process of the orbit. The incision should be made through the skin and muscular tissue down to the

FIG. 72.



Frontal sinus canula.

periosteum. The periosteum is then incised a quarter of an inch above and parallel to the supra-orbital arch. The periosteum is pushed upward as far as may be necessary, and downward to the edge of the orbital arch. All bloodvessels, frequently quite numerous, are caught, tied, and the clamps removed before proceeding further. With a Killian -shaped chisel a groove is cut in the anterior wall of the frontal sinus, a sixteenth of an inch above and parallel to the orbital arch. With a gouge the anterior wall of the frontal sinus is now removed down to the groove just mentioned. Every particle of the anterior wall of the frontal sinus should be removed above this line, so as to expose the

entire cavity with all its recesses. The mucous membrane lining the cavity is removed with the author's curettes (Fig. 67), the mucous membrane of the nasofrontal duct being removed last. All the ethmoidal cells bordering upon the nasofrontal duct are broken into and, if diseased, are thoroughly curetted, so as to form one large opening between the frontal sinus and the nose. Through this a probe, threaded with iodoform gauze, is passed and brought out at the anterior nares. This is see-sawed up and down, so as to very thoroughly remove all traces of the mucous membrane at the lower portion of the nasofrontal duct. In the event of there being an extensive ethmoiditis involving the middle and posterior ethmoid group and also the sphenoid, the operation for chronic ethmoiditis (*q. v.*) should be combined with that of the frontal, both being done as one operation. As in the case of the radical operation on the antrum, it is important that no particle of mucous membrane be left within the frontal sinus or any of its ramifications, and for this purpose it will be found that the lamps (Fig. 68) afford an excellent means of illuminating the cavity. A cigarette drain is passed from the frontal sinus through the nasofrontal canal and naris of that side and cut off flush with the vestibule of the nose. The skin incision is united with five or six interrupted horsehair sutures. Sterile vaseline is smeared along the line of sutures, and over this small gauze tampons wet with a saturated solution of boric acid are so placed that they press the skin and underlying tissues firmly against the posterior wall of the frontal sinus. A bandage around the forehead retains the dressing in place. At the expiration of twenty-four hours the cigarette drain is extracted

through the anterior nares. The sutures may be removed after forty-eight or seventy-two hours, at the option of the surgeon. The special dressing for keeping the tissues in apposition with the posterior wall must be continued until firm union is established, viz., in about three weeks. Any evidence of cellulitis in the wound should cause the surgeon to at once remove the sutures, reopen the incision, irrigate the frontal sinus with a solution of chinosol (1 : 500), and apply a compress wet with that solution until the cellulitis subsides, after which secondary sutures may be inserted.

This operation, modified after that of Killian, results in an obliteration of the frontal sinus above the arch. The portion behind the arch gradually fills in with granulations, and after some weeks all discharge and crust formation in the nose ceases. The deformity resulting is in the nature of a depression or flattening. In small sinuses it may not be noticeable, but in broad, high, and deep cavities the depression may be considerable.

The scar from the incision in the eyebrow is not noticeable six months after the operation.

OSTEOMATA OF THE FRONTAL SINUS.

Osteomata are rarely found in the frontal sinus.

Symptoms. About the only symptom which these patients complain of is neuralgia unaccompanied by any discharge into the nose. Transillumination shows the affected sinus dark. A skiagraph would undoubtedly show the presence of the bony growth in this region.

Treatment. The only treatment of any value is exposing the frontal sinus and enucleating the growth.

MALIGNANT DISEASE OF THE FRONTAL SINUS.

Epitheliomata, adenomata, and sarcomata have been reported.

Symptoms. The symptoms are practically the same as those of acute or chronic frontal sinusitis. As the disease progresses distention of the walls of the sinus occur with the formation of a tumor in the region of the upper eyelid. Discharge from the nose is sometimes slightly bloody, and the nose itself is often the seat of the same growth.

Treatment. As a usual thing by the time the disease is recognized it is past operation, except as a relief for the headache resulting from tension on the bony walls.

CYSTS OF THE FRONTAL SINUS.

A few cases of cysts in the frontal sinus have been reported.

Symptoms. The symptoms are a gradual swelling appearing in the region of the forehead to one or the other side of the glabella. They are seldom accompanied by pain, merely gradual distention of the bony walls. Palpation often produces a crackling, parchment-like feeling. Occasionally rupture evacuates a thick, mucigenous, greenish fluid.

Treatment. Incision should be made over the most prominent portion of the cyst and the thickened wall excised with curettes, the cavity packed, and allowed to fill up by granulation.

DISEASE OF THE ETHMOID CELLS (ETHMOIDITIS).

A common condition found involving these cells is that of caries with suppuration.

Etiology. This condition is most frequently seen in

connection with nasal polypi. It is doubtful whether the caries causes the polypi or *vice versa*. It is also met with in syphilis, and is associated with empyema of the antrum and of the frontal sinus.

Symptoms. Pain referred to the root of the nose, the occipital region, or to the orbit is one of the most aggravating symptoms. There is usually some nasal obstruction, most marked in those cases in which polypi exist at the same time. A purulent discharge having an offensive odor is often present. Exophthalmos occasionally is produced, either by the distention of the posterior group of cells with the accumulated secretion or by infection of the orbital contents, producing an orbital cellulitis. With the latter condition edema of the eyelids is common. A distended posterior ethmoid cell may so press upon the optic nerve as to cause interference with vision or blindness.

Examination. Inspection shows an enlarged middle turbinate, the mucous membrane over which is often red and of a granular appearance. Polypi are frequently present. A thick, not very abundant, purulent secretion may be seen bathing the anterior end of the middle turbinate if the anterior cells are involved. If the posterior ethmoidal cells are involved, pus can be seen, on posterior rhinoscopy, in the middle meatus or in the region just above the middle turbinate. Occasionally no trace of pus and only a slightly enlarged middle turbinate may be seen, which is apparently otherwise healthy. Touched with a probe, the mucous membrane is often found to be thickened and the bone crumbly, so as to allow of the easy entrance of a probe into the cells.

Differential Diagnosis. The differential diagnosis be-

tween this disease and empyema of the maxillary and frontal sinuses has been given.

Prognosis. Until all of the carious bone has been removed the disease is likely to progress and involve, if it has not already done so, the maxillary, frontal, and sphenoidal sinuses. Removal of the diseased bone by intranasal methods is often tedious, and it may be several months before the patient fully recovers. The most satisfactory method of treating the severe cases, especially those with orbital complications, is by the external radical operation. In extensive caries patients frequently complain of dryness in the nose and nasopharynx after healing has taken place.

Treatment. *Intranasal.* A pledget of cotton soaked in a 10 per cent. solution of cocaine renders the part anæsthetic, and a solution of suprarenal extract sprayed into the nose diminishes very much the hemorrhage during operation and permits a better view of the area to be operated on. All of the diseased bone must be removed. The cold snare can often be employed to advantage to remove large masses of the diseased tissue and the polypi so frequently met with. The remaining cells should be freely opened up with curettes, Grünwald's (Fig. 49) or the author's (Fig. 67), so that perfect drainage is obtained.

The probe in this stage is very valuable in detecting the diseased carious bone, and may often be used to break down the thin partitions between the cells. Grünwald's punch-forceps (Fig. 52) is an admirable instrument for excising small spiculæ of bone when these cannot be removed with the curette or snare. Hemorrhage is often severe, but usually may be controlled by the Bernay sponge or by packing the middle

meatus with sterile gauze. The nose should be syringed with normal saline solution made from Seiler's tablets twice or three times daily. Insufflation of aristol, euphphen, or nosophen, after the cleansing, assists in the healing.

External Radical Operation.

The patient is anæsthetized, preferably with chloroform vapor pumped into the mouth. The anterior and posterior nares should be tamponized to prevent the blood from entering the larynx. Having sterilized the operative field, a curved incision is begun at one-quarter of an inch posterior to the supra-orbital notch and carried downward along the side of the nose, midway between the dorsum of the nose and the inner canthus of the eye, and terminating below at the lower border of the nasal bone. The periosteum is peeled forward and backward, thus baring the whole of the nasal process of the superior maxilla and the lower inner portion of the frontal bone. Cut away the nasal process of the superior maxilla with chisel and immediately some of the anterior ethmoidal cells are opened. By means of bone scoops and the Jansen-Middleton forceps (Fig. 45), the entire ethmoid labyrinth may be removed and the sphenoid entered and its anterior and inferior wall cut away. Great caution must be exercised during the operation to work parallel with the cribriform plate, as the bone is very thin, easily perforated, the dura wounded and infected, resulting in meningitis and, usually, death of the patient. Ethmoid or frontal cells extending over the roof of the orbit may be reached in this operation more readily and thoroughly than by any other route. The anterior nasal tampon should be

removed and the cavity of the ethmoid lightly packed with iodoform gauze, the proximal end being brought out of the vestibule of the nose.

The skin incision is closed with five or six interrupted horsehair sutures. Sterile vaseline is squeezed from a tube over the line of incision and over the cornea and along the edges of the eyelids and a wet boric-acid dressing is held in place by a bandage. At the end of twenty-four hours the postnasal and anterior nasal plugs are removed and the outer dressing renewed. At the end of another twenty-four hours the dressing is taken down, the sutures removed, and a cotton colloid dressing applied over the line of the incision. After a couple of weeks there will usually be found some loose edematous fragments of membrane in the ethmoidal or sphenoidal regions that will need to be cocainized and cut away with forceps. There is absolutely no deformity following this operation, the line of incision being scarcely visible a few months after the operation. Should cellulitis develop, the wound should be opened and treated as described in the radical frontal operation.

CYSTS OF THE MIDDLE TURBINATE.

The anterior end of the middle turbinate is sometimes found to be very large and rounded, so as to fill the cavity of the nose and prevent nasal respiration on that side. A bilateral enlargement is sometimes found.

Etiology and Pathology. The cause is rarefying osteitis, but what induces this is not always clear. The cavity of the cyst may contain air, a thin, watery fluid, a thick, gelatinous fluid, and occasionally pus.

Symptoms. The patient suffers from obstruction to nasal respiration and headache. If the cyst is large,

completely occluding the nares, the sense of smell may be lost.

Examination. This reveals a large, reddish, rounded mass in the middle meatus. It may be in contact with the septum on one side and with the outer wall of the nose on the other. It often projects so far downward and forward as to invade the vestibule of the nose. Touched with a probe the mucous membrane is found to be thin and covering a bony mass that is immovable.

Differential Diagnosis. It may be mistaken for polypi or other new growths. Its immobility and hardness ought to differentiate it from the former. Its connection with the middle turbinate, slow growth, hardness, and failure to bleed when touched with a probe differentiate it from other growths.

Treatment. The cyst should be cocainized, included in a loop of the snare, and excised when the symptoms are of sufficient gravity to warrant it. It is often impossible to remove it all at one sitting. Grünwald's punch-forceps (Fig. 58) may be employed for trimming off the edges, which are apt to be crushed by the snare and left ragged.

INFLAMMATION OF THE SPHENOID SINUS.

Etiology. Inflammation of the sphenoid sinus is caused by the same factors that produce inflammation of the other accessory sinuses of the nose.

Symptoms. Pain in the back of the head, with a purulent discharge that flows into the nasopharynx or at times from the anterior nares, are the two most common symptoms. If the pus does not find a ready outlet, it may break through the base of the cranium, causing a meningitis or an abscess at the base of the brain.

Examination. Unless the other sinuses are involved no abnormal conditions may be observed on anterior rhinoscopy. Posterior rhinoscopy will usually show pus in the nasopharynx. After removing this with a post-nasal syringe (Fig. 59) the point of exit of the pus can usually be detected high up in the choana above the superior or middle turbinate.

Differential Diagnosis. After excluding suppuration of the other accessory sinuses, a discharge of pus into the nasopharynx and a continuance of the pain should lead one to suspect empyema of the sphenoidal sinus.

Treatment. When pus has been diagnosed in the sphenoidal sinus a free opening should be made to allow proper drainage. The opening may be made by enlarging the normal opening in the superior meatus where this is possible. Grünwald's small-sized curette (Fig. 49) serves well for this purpose. The nasal cavity should be thoroughly cocainized by spraying with a 10 per cent. solution of cocaine. The curette is to be passed into the nose along the septum until it reaches the roof of the nose near the posterior part of the middle turbinate. The direction of the curette should be upward and backward, at an angle of 45 degrees to the floor of the nose. Firm pressure on the handle usually suffices to break through the anterior wall of the sinus. The opening thus made can be enlarged to any desired extent. Puncture in this situation is not devoid of danger, for unless the operator is perfectly familiar with the anatomy of the nose it is possible for him to push the curette through the cribriform plate of the ethmoid into the cranial cavity. Meningitis or abscess of the brain will follow. A long, thin canula, to which is attached a rubber tube, is to be inserted

and the cavity washed out two or three times daily. With a little instruction the patient can learn to wash out the cavity himself. The sinus may be punctured through the nasopharynx by a long, grooved trocar. Puncture should be made just back of the choana. It is usually more difficult to wash out the sphenoidal sinus punctured in this way than in the first method. As the drainage is apt to be imperfect at best, these cases usually run a very protracted course.

As the sphenoid is usually involved in severe ethmoidal disease, the most satisfactory opening is that done at the time of performing the radical ethmoid operation (*q. v.*).

CHAPTER VIII.

DISEASES OF THE NASOPHARYNX.

THE nasopharynx may be acutely inflamed. It may be the seat of hypertrophy or atrophy of the mucous membrane. There is frequently an hypertrophy of the lymphoid tissue. Tertiary syphilitic ulcers and foreign bodies are occasionally found. It may also be the site of new growths, non-malignant or malignant.

ACUTE NASOPHARYNGITIS.

Acute nasopharyngitis is an acute inflammation of the mucous membrane lining the nasopharynx.

Etiology. Its causes are the same as those of acute rhinitis, which it very frequently complicates, beginning simultaneously with or a day or two after the onset of acute rhinitis. Occasionally the nasopharyngitis precedes the acute rhinitis.

Pathology. The mucous membrane is thickened and reddened. At first the secretion may be diminished; subsequently the glands secrete a thick mucus containing many desquamated epithelial cells.

Symptoms. The symptoms of this disease consist in a feeling of rawness back of the nose as the respired air passes through this region, and an increase in the amount of mucus, which drops down or is brought down in the act of hawking, and thus expectorated. At night it accumulates in considerable quantities, and

in the morning there is a feeling as of a foreign body in the nasopharynx. Hawking is persistent until this thickened, tenacious mucus is removed. The mucus sometimes adheres so firmly to the membrane that repeated attempts at hawking finally produce gagging, and possibly vomiting, before it can be loosened and finally expectorated. When the orifices of the Eustachian tubes are congested, tinnitus, a feeling of fulness in the ears, and diminished hearing are complained of.

Prognosis. Acute nasopharyngitis lasts from one to four weeks, and subsides at about the same time as the accompanying rhinitis.

Treatment. The treatment of acute nasopharyngitis is identical with that of acute rhinitis.

HYPERTROPHY OF THE NASOPHARYNGEAL MUCOUS MEMBRANE.

By this is meant a chronic inflammation producing an infiltration into and a thickening of the mucous membrane of the nasopharynx.

Etiology. This disease is secondary to hypertrophic rhinitis and to the various other obstructive conditions found in the nose. Those who work amid unhygienic surroundings, who are badly nourished, and whose occupations are such as to cause them continually to inhale large quantities of dust, as employés of tobacco factories, machinists, clothing-cutters, stone-cutters, etc., are especially prone to this disease.

Pathology. The mucous membrane is swollen, and usually reddened; there is increase in the connective tissue, and often in the glandular and lymphatic tissues of this region as well,

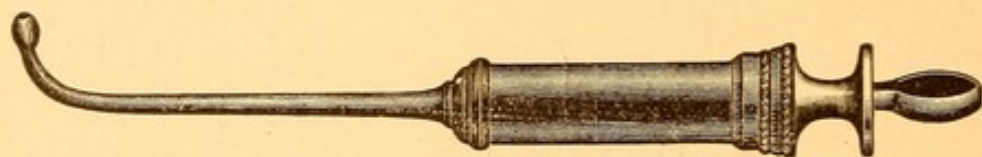
Symptoms. The symptoms of this disease are nearly the same as those of acute nasopharyngitis. The mucus is usually more tenacious, and the patient is continually hawking and making ineffectual attempts to rid himself of it. The symptoms differ from those of acute nasopharyngitis in that they are more or less constant.

Examination. Examination of the nasopharynx shows the mucous membrane to be reddened and thickened, with tenacious mucus clinging to the vault and posterior wall. This mucus may have lost much of its moisture, and it often has a dry, brownish or blackish appearance, according to the kind of dust that is intermingled with it.

Prognosis. These cases are apt to be obstinate, especially when the occupation of the individual is a prominent factor in producing the condition.

Treatment. Before treatment is begun for this affection the nasal cavity should be carefully examined, and any pathological conditions found there should

FIG. 73.



Post-nasal syringe.

be remedied. Unless this is done very little benefit will be derived from treating the nasopharynx alone. The best method of softening and removing the tenacious, adherent mucus accompanying this disease is by means of the wash-bottle described in the article on Atrophic Rhinitis, using the solution of salt and soda there recommended. The hard-rubber nasal syringe

(Fig. 73) may also be employed for this purpose, using the salt and soda solution.

If the mucus is firmly adherent to the vault of the nasopharynx, this method may be the only effectual means of removing it. The syringe should be filled with the lukewarm solution, a tongue depressor employed to depress the tongue, and the curved tip of the syringe passed behind the soft palate. The irritation of the pharyngeal wall thus produced usually causes the soft palate to be drawn back tightly against the posterior pharyngeal wall, thus shutting off the cavity of the nasopharynx from that of the mouth. If now the piston of the syringe be gently pushed into the barrel, the fluid will be ejected into the nasopharynx, and if at the same time the head be slightly inclined forward the fluid will run out of the anterior nares into a pus-basin. If the injection be made before the soft palate is drawn back to the posterior pharyngeal wall, some of the injection fluid is apt to fall into the larynx, producing coughing. After having removed the mucus the nasopharynx should be swabbed out with a cotton-wound applicator that has been dipped in the following solution :

R.—Iodini	gr. xij.
Potassii iodidi	gr. xxiv.
Glycerini	℥j.—M.

The applicator should be of rigid material (Fig. 102), and bent almost to a right angle one and three-eighths inches from its end.

The alterative action of this solution, which should be applied twice a week, gradually diminishes the congestion of and secretion from the mucous membrane.

At the end of three or four weeks it is often advisable to swab the nasopharynx with a 10 per cent. solution of nitrate of silver instead of the iodine mixture. Great care must be taken that the swab is not too moist, or some of the nitrate of silver solution will trickle down the posterior pharyngeal wall and enter the larynx, causing most violent dyspnea and coughing, and probably induce an acute laryngitis.

ATROPHIC NASOPHARYNGITIS (Nasopharyngitis Sicca).

A chronic inflammation of the nasopharyngeal mucous membrane characterized by an atrophy of the same.

Etiology. This condition is usually associated with atrophic rhinitis and with the other diseases of the nose, such as syphilis and tuberculosis, which result in extensive destruction of the nasal mucous membrane. It is also seen in anemic patients who have a very patent nasal cavity, whereby the volume of air entering the nose is too large to be sufficiently moistened and warmed. It is sometimes secondary to hypertrophic nasopharyngitis.

Pathology. The nasopharyngeal mucous membrane is atrophied, the normal tissues being replaced in great part by connective tissue. The normal ciliated epithelium is replaced by a squamous variety.

Symptoms. The symptoms of atrophic nasopharyngitis resemble very much those of the hypertrophic variety except so far as the character of the mucus is concerned. In this condition the mucus is almost entirely robbed of its moisture, and is deposited upon the walls of the nasopharynx as thick, dry, hard crusts, greenish, brownish, or blackish in color. Their pres-

ence gives rise to the feeling of a foreign body in the nasopharynx, and when partially loosened they cause a disagreeable sensation. Once a day, or once in two or three days, a large, dry crust, often taking the form of a complete cast of the nasopharynx, will be expectorated, and for a short time the patient will be very markedly relieved. So annoying are these crusts, and with such difficulty are they gotten rid of by hawking, that it is not unusual to find patients who have acquired the habit of introducing the finger behind the soft palate to remove them. Slight excoriations of the mucous membrane usually result and some hemorrhage may follow their removal. Many of these patients also suffer from atrophic processes in the mucous membrane of the middle ear, with the attendant difficulty in hearing.

Examination. Examination of the nasopharynx shows the thick crusts as above described covering almost the entire surface. Where the mucous membrane can be seen it will be found to be pale, and superficial ulcerations are often observed.

Differential Diagnosis. The only disease this condition is likely to be mistaken for is that of a partially healed gumma in this region. When the crusts are removed in gumma a deep ulcer with an elevated margin is visible. A history of syphilis and the evidence of this disease in other portions of the body assist materially in making the diagnosis.

Prognosis. Like atrophic rhinitis, this disease is very obstinate, and all we can promise the patient is that by carefully carrying out the directions of the physician he can be kept in comparative comfort so far as the crust formation is concerned.

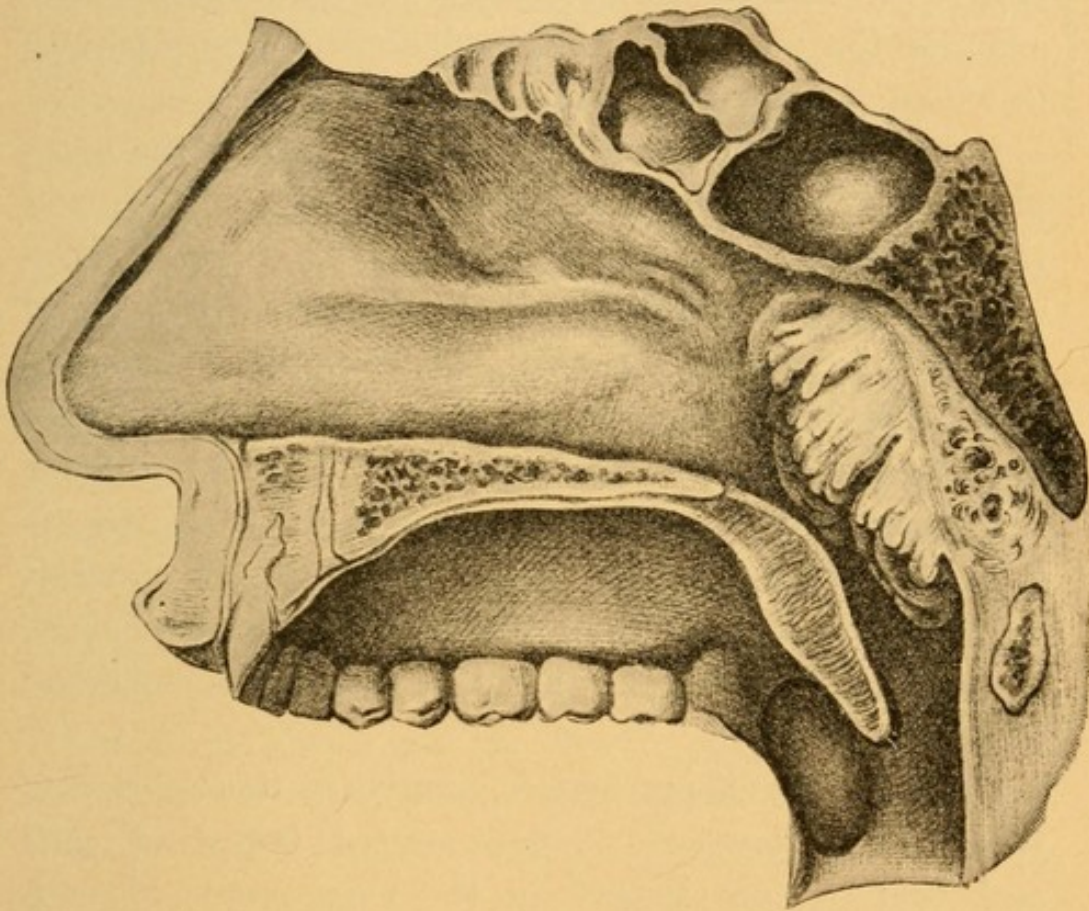
Treatment. As the disease so commonly is associated with atrophic rhinitis, the wash-bottle, used as described for that condition, may be sufficient to soften and remove the crusts. If it does not do so, then the patient must be taught how to use the post-nasal syringe himself, and be given directions to use the salt and soda solution, at first three times a day, and, as the crust formation lessens, to syringe the nasopharynx night and morning. When superficial ulcers are found on the mucous membrane the blowing into the nasopharynx of an antiseptic powder, such as aristol or nosophen, mixed with 10 per cent. stearate of zinc, is advisable. The nasopharynx should be swabbed once a day with boroglyceride or the patient himself be taught how to make this application. The object of the boroglyceride is to increase the amount of secretion from the glands of the nasopharynx and diminish the tendency to crust formation.

ADENOIDS (Hypertrophy of the Lymphoid Tissue of the Nasopharynx. Enlargement of the Third Tonsil. Hypertrophy of Luschka's Tonsil).

Etiology. Why hypertrophy of the lymphoid tissue at the vault of the nasopharynx should occur in some individuals and not in others is a problem to be solved. It is seen most often in children between the third and twelfth years. We have seen it occur as early as the third month. It occasionally occurs also in adults. It is seen in all classes—the rich as well as the poor. In the former class it has been ascribed to faulty nutrition due to pampered feeding; in the latter class it is often ascribed to malnutrition. We have noticed digestive disturbances very frequently in chil-

dren having adenoids. How far indigestion is a causative factor and how far the result of the adenoids it is difficult to say. It is often seen in the condition to which the name "scrofula" has been given. Heredity plays some unknown factor in its production, as

FIG. 74.



Antero-posterior section of the head of an adult, showing the situation and gross structure of hypertrophy of the lymphoid tissue of the nasopharynx. (ZUCKERKANDL.)

we frequently see several children of a family affected with adenoids. Adenoids are somewhat more common in males than in females. Hypertrophic rhinitis in childhood, deviations of the septum, spurs, and those conditions which produce nasal obstruction seem to favor the growth of lymphoid tissue in the nasopharynx.

It is claimed that this tendency to adenoids is not so marked in warm, dry climates as in cold, damp, and changeable ones. The lymphoid tissue often markedly increases in size during and after the acute infectious diseases, such as measles, scarlet fever, diphtheria, and whooping-cough. Adenoids are so frequently associated with enlarged tonsils that one should carefully examine the nasopharynx for adenoids in every patient in whom there is hypertrophy of the tonsils.

Pathology. The upper and posterior wall of the nasopharynx is normally the seat of a mass of lymphoid tissue. Like the pharyngeal tonsil, this tissue is composed of masses of round-cells held together by a small amount of connective tissue. The amount of connective tissue found in adenoids is usually much less than that seen in tonsillar tissue. The lymphoid tissue is frequently so redundant as to be folded or plaited, as is well shown in Fig. 74. (This cut shows in an adult the usual position of the growth, occupying, as it does, the vault of the nasopharynx and extending down along its posterior wall.)

Occasionally cheesy masses, similar to those found in the tonsil, composed of degenerated lymphoid cells and bacteria, are lodged in these recesses. Mucous glands are found in varying numbers in the deeper portions of the lymphoid tissue.

Symptoms. The symptoms of adenoids are usually so well marked that when one has once seen a case it is difficult to see how he should fail to recognize the condition again from the symptoms alone. The dull expression of the face, the open mouth, thick lips, pinched nose, absence of the groove over the *alæ nasi*, the enlarged transverse vein at the root of the nose,

inability of the patient to blow the nose, and, therefore, usually a thick, tenacious mucus obstructing the nasal cavity, and the nasal twang to the voice, are such as enable the observer to recognize the condition at a glance.

From the mother the history of snoring at night, great restlessness, continual kicking off of the bed-clothes, and *frequent attacks of cold in the head*, the child scarcely ever being free from a cold, add to the certainty of the diagnosis. The children are seldom robust, and are usually of a stature far below that of the average child of their age. If of a school age, they will usually be found to be mentally deficient as well. Indigestion is the rule in these children. Various reflex neuroses are present in children suffering from adenoids. Among these may be noted nocturnal enuresis, spasms and twitchings of the muscles during sleep, convulsions, chorea, laryngismus stridulus, coughing, hawking, stammering, and stuttering. These children also suffer from frequent attacks of nose-bleed. The lymphatic glands at the angle of the jaw are usually enlarged. Earache and suppurative affections of the middle ear are more frequent in these children than in others, and marked diminution in hearing frequently leads the teacher to call the attention of the mother to the fact that the child is very inattentive at school.

Examination. It will be noticed that the hard palate is very much arched, and that the secondary teeth, if erupted, have come in irregularly, overlapping each other and projecting forward more than normal. As the child's tongue is depressed a mass of white-of-egg-like mucus is often seen coming down from the nasopharynx along the posterior pharyngeal wall. It is

difficult to make an examination of the nasopharynx with a mirror in a child under six years of age. In older children posterior rhinoscopy will show a mass in the vault of the nasopharynx in such a situation as to hide the upper part of the septum. In extensive hypertrophies the entire septum may be invisible.

In younger children the examination of the nasopharynx with the finger will confirm the diagnosis as made from the history. To examine the nasopharynx with the finger the physician should stand behind and slightly to the right side of the child, who should be seated in a chair or held on the mother's right knee. The examiner's left hand should encircle the head and neck of the child, thus holding it firmly, the right side of the head being pressed against the physician's left side. The mother or an assistant should hold the child's hands. The child is now told to open the mouth, and the left side of the cheek is to be pushed in between the teeth by the thumb of the left hand. The physician should now rapidly insert the forefinger of his right hand into the mouth, carrying it back until the posterior wall of the pharynx is felt. If the finger is now turned up toward the nasopharynx, it can be pushed behind the soft palate into the nasopharyngeal cavity. Here, instead of the thin mucous membrane covering the bony structures, there will be found a soft mass, more or less completely filling the nasopharynx, the feel of which is not unlike that of a bundle of worms. The finger, when withdrawn, will be coated with thick white-of-egg-like mucus and *blood*. No blood will be found on the examining finger if the nasopharynx is normal.

Differential Diagnosis. An adenoid may be mistaken

for a polypus projecting into the nasopharynx, a fibroid tumor of the nasopharynx, or a malignant growth. The mobility of a polyp and the presence of polypi in the nasal cavity should not lead one to mistake this condition for adenoids. A fibroid tumor is much harder, does not bleed, and is freely movable. Malignant growths are of rapid formation, and accompanied by pain, spontaneous hemorrhage, fetid discharge, cachexia, and progressive emaciation.

Prognosis. The operation for the removal of adenoids is attended with so little danger when properly performed, and the consequences of allowing them to remain are so injurious to the patient, especially their tendency to cause impairment of hearing, that even moderate adenoid hypertrophies should be operated upon. When thoroughly removed statistics prove that they do not tend to return in 90 per cent. of the cases. Where an imperfect or partial operation is done the chances of their recurring are much greater. When a child has recently had an attack of acute otitis media there is always a possibility that removal of the adenoids may be followed by a second attack of suppurative otitis media. This should not deter one from operating as soon as the acute symptoms referable to the ear have subsided, for if the growth be allowed to remain it is pretty certain that, sooner or later, the child will have a second attack of otitis media. If adenoids exist in connection with chronic suppurative otitis media, no time should be lost in removing them.

There is a tendency for these growths in many cases to decrease in size after the fifteenth year. This, together with the great enlargement that takes place in the nasopharynx at about this time, may suffice to restore

partially or completely nasal respiration. It is not safe to advise waiting for this change to take place, as the child's general health, hearing, and development may be everlastingly impaired in the meantime.

Treatment. Where adenoid growths are of sufficient size to produce many of the symptoms described we have found very little benefit to be derived from the internal administration of remedies, such as cod-liver oil, syrup of the iodide of iron, Fowler's solution, or potassium iodide.

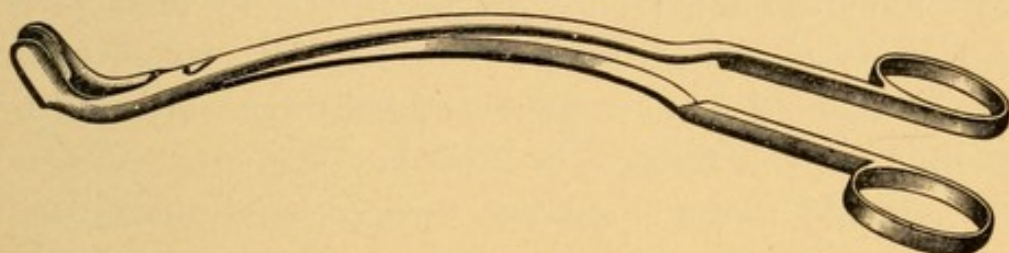The removal of the lymphoid tissue by surgical means is the only rational treatment. We do not approve of the method advocated by some—namely, that of introducing the finger into the nasopharynx, breaking up the tissue, and *partially* removing it in this way. It is so crude a method of operating, and the growths return so frequently, that we are forced to condemn it.

The instruments devised for the removal of adenoid growths are many. Operators have their individual preferences. Those which we are in the habit of employing are the Loewenberg forceps, the Gottstein curette, and the Chappell curette (Figs. 75, 76, and 77).

The patient is to be placed under general anesthesia. We employ ether where the patient is over six years and chloroform when under that age. The hemorrhage is usually more profuse where ether is employed than where chloroform is used. The anesthetic is given with the child in the ordinary recumbent posture. As soon as full anesthesia is obtained the child's body is moved so that the head falls sharply backward over the end of the table. The instruments should be previously ster-


ilized by boiling and then placed in Thiersch's solution, or in a solution of carbolic acid (1 : 100). A mouth-gag (Fig. 95) is then inserted between the molar teeth, so as widely to open the mouth. The forefinger of the right hand is now introduced into the nasopharynx, to ascertain the situation and extent of the hypertrophied lymphoid tissue. When this has been done the Loew-

FIG. 75.



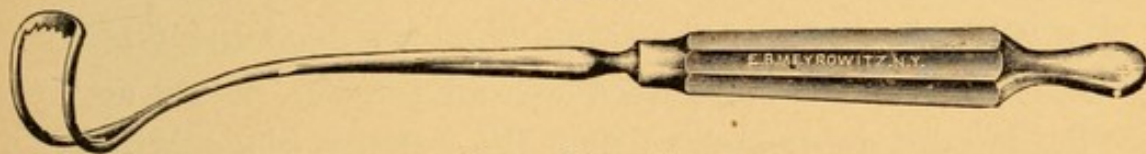
Loewenberg forceps.

FIG. 76.



Gottstein curette.

FIG. 77.



Chappell curette.

enberg forceps are inserted (closed) behind the soft palate and into the nasopharynx. The forefinger of the left hand or a tongue depressor is used to depress the tongue if necessary. Care must be taken as to the direction in which the handles of the forceps lie. If they are too near the inferior maxilla, the blades of the forceps in the nasopharynx will probably be in such a position as to seize the posterior portion of the septum.

If the handles of the forceps be too near to the upper teeth, then only the lower portion of the hypertrophied mass will be grasped. Care should also be taken that the forceps are *not rotated* either to the right or to the left, *for fear of grasping the tissues on the lateral wall where the Eustachian eminences project*. The forceps should now be opened widely and pushed into the soft, doughy mass. Closure of the handles of the forceps will include a large mass of the tissues in their jaws. A *rocking* motion, from side to side, will tear off some of the adenoid tissue. If a straight downward pull be made upon the forceps, it often happens that some of the adenoid tissue is not cut through, and that a strip of the attached mucous membrane will be torn from the nasopharynx and peel off some of that in the oropharynx as well. After the removal of this piece of tissue the examining finger should again be inserted into the nasopharynx to ascertain the situation of any remaining lymphoid tissue. If any be found, the forceps should again be introduced, so as to include this, and removal effected as before.

With the bulk of the tissue thus removed the Gottstein curette is to be passed behind the soft palate and the handle depressed, so that the cutting blade, which is on the posterior surface, reaches the upper *anterior portion* of the roof of the nasopharynx. Firm pressure is to be made upon the handle, which is now to be elevated so that the cutting edge shall sweep in the arc of a circle across the upper and posterior wall of the nasopharynx. The first sweep of the Gottstein curette should be *absolutely in the median line*. A second sweep should be made with the curette carried up to the point as before, and in the downward sweep lateral pressure

should be made, so that the side of the curette is pushed outward into Rosenmüller's fossa, *behind* the Eustachian eminence on one side. The small sized Chappell curette we have found to be more suitable for removing the adenoid tissue in Rosenmüller's fossæ. A similar sweep should be made on the opposite side. In making these movements care should be taken that the course of this sweep is *parallel* with that of the first, but external to it. Having made these two lateral sweeps, the curette is to be removed and the finger passed into the nasopharynx, to ascertain whether there are any small portions remaining; and, if so, the curette is to be introduced, so as to scrape these away. Where proper skill has been acquired the forceps will remove the bulk of the growth in one or two applications, and three sweeps of the curette, one in the median line and two laterally (one to the right and the other to the left), suffice for the removal of the remaining adenoid tissue. Hemorrhage is very brisk, but much of this flows out through the nose. If during the operation the mouth fills with blood, as is usual, the head should be turned to one side, so as to allow the blood to run out, and the operation resumed. The entire operation usually consumes two or three minutes. When finished, it will usually be found that the patient has lost from two to eight ounces of blood. The child should then be drawn back upon the table, when it will be found that the hemorrhage usually quickly ceases. A few moments later the child will vomit, and a considerable amount of dark, clotted blood will be found in the vomited material.

The after-treatment consists in the patient being put to bed and kept there until all danger of hemorrhage is passed, which is usually in about twenty-four hours.

During the winter months it is not advisable to allow these patients to go out-of-doors inside of a week, as they catch cold very easily, and the congested condition of the nasopharynx predisposes them to acute inflammation of the middle ear. They may be allowed to be up and about in their rooms, provided they can be kept free from draughts. Their diet should be fluid until deglutition becomes easy, which it frequently does on the second or third day.

We are opposed to syringing the nose or nasopharynx after this operation, *unless there is some positive indication for it*, such as sepsis, which is characterized by a rise in temperature of two or three degrees, foul odor of the breath, purulent discharge from the nose or nasopharynx, and an increase in the swelling of the glands at the angle of the jaw. We have seen more cases of abscess of the middle ear follow adenoid operations where syringing had been practised than where it had been omitted. If it becomes necessary to syringe the nose, we employ an anterior nasal syringe, using a solution made from Seiler's tablets.

Severe hemorrhage has in rare cases followed the removal of adenoids. To control this the nasopharynx is to be plugged with absorbent cotton or a sponge that has been immersed in a strong solution of tannic acid in water. Should the amount of the hemorrhage be such that constitutional symptoms result from the loss of blood, then subcutaneous injections of warm normal saline solution or intravenous injections of the same are to be employed. The limbs are to be elevated and bandaged, so as to keep the blood as much as possible in the internal organs.

Cod-liver oil and iron are to be administered after

the first week. It often happens that mouth-breathing continues after the removal of adenoids. When it is ascertained that the child can breathe through the nose perfectly well while being watched, this mouth-breathing is then only a matter of habit on the part of the patient, and it is to be overcome by the parents calling the attention of the child to the open mouth whenever they observe it, and at night tying a handkerchief under the child's chin and over its head, so as to prevent dropping of the lower jaw.

SYPHILIS OF THE NASOPHARYNX.

The nasopharynx may be the seat of secondary syphilis appearing in the form of mucous patches, or the site of a gumma, or the ulcer left as the result of the breaking down of the latter.

Symptoms. Where extensive mucous patches are found in the mouth and oropharynx they will usually be found also on the posterior wall of the nasopharynx. The symptoms produced are mainly those of acute nasopharyngitis. The patches are recognized only on examination of the cavity by posterior rhinoscopy.

Tertiary syphilitic gummata are occasionally met with on the posterior wall of the nasopharynx. They may be the size of a hickory-nut, and give rise to considerable pain referred to the back part of the throat and the occipital region of the head. They may be large enough to bulge forward the soft palate and mechanically prevent the proper occlusion of this cavity during deglutition. In such cases there is usually a regurgitation of liquids into the nasopharynx and out through the nose during the process of swallowing.

When the gummata break down ulcers result. These usually cause considerable pain during deglutition and a discharge of pus into the oropharynx. If a large ulcer exists in the lower portion of the nasopharynx, there is always a possibility of the irritating discharge producing a necrosis of the epithelium on the posterior surface of the soft palate. Granulation tissue formed on the soft palate may unite with similar tissue on the ulcerated surface of the posterior wall of the nasopharynx and adhesion take place between the soft palate and the posterior pharyngeal wall.

Examination. Posterior rhinoscopy will reveal a tumor or ulcer according to the stage of the disease. A history of syphilis some years previously, and other manifestations of tertiary syphilis, will assist in making a correct diagnosis.

Treatment. The constitutional treatment in both the secondary and tertiary forms of syphilis has been described in the article on Syphilis of the Nose.

The local treatment of an ulcer lies in keeping the surface clean by syringing the nasopharynx with the salt and soda solution, using the post-nasal syringe twice daily. It is also advisable to cauterize the surface of the ulcer every other day with nitrate of silver fused on a post-nasal applicator (Fig. 65). Care should be taken not to touch the posterior wall of the soft palate, for fear of producing a raw surface there, which may cause a union of the soft palate with the posterior pharyngeal wall.

FOREIGN BODIES IN THE NASOPHARYNX.

These are usually particles of food that have lodged there during the act of vomiting. Occasionally metallic

or other substances held in the mouth are partially swallowed and regurgitated into the nasopharynx. This is more common in those suffering from paralysis of the muscles of the soft palate.

Symptoms. They produce an uncomfortable feeling at the back of the nose and upper part of the throat. If large enough, they produce sudden obstruction to nasal respiration. The patient is usually aware of the presence of a foreign body, and quickly applies to his physician for relief.

Examination. Owing to the reflex irritation the muscles of the soft palate are apt to be spasmodically contracted and the velum drawn back to the posterior pharyngeal wall, thus preventing a view of the nasopharyngeal cavity. Where the mass is very large it may not only be felt in the nasopharyngeal cavity, but it may project below the soft palate into the oropharynx and be visible when the mouth is opened.

Treatment. A pair of curved forceps should be passed into the mouth and behind the velum, grasping and extracting the foreign body. The Loewenberg forceps (Fig. 75) described for the removal of adenoids, may be used for this purpose.

NON-MALIGNANT GROWTHS OF THE NASOPHARYNX.

The tumors of a benign character most frequently found in the nasopharynx are polypi and fibromata. Papillomata, adenomata, and chondromata also have been found.

Nasopharyngeal Polypi.

Etiology. Nasopharyngeal polypi are probably caused in the same way as polypi in the nasal cavity. They

are frequently found at a much earlier period of life than nasal polypi, occurring as they do between the fifth and twenty-fifth year. They are also frequently associated with polypi in the nasal cavity, and are somewhat more common in males than in females.

Pathology. These growths usually spring from the lateral walls of the nasopharynx. Their structure differs from that of nasal polypi in that they contain a firmer, denser connective tissue, and are not so edematous. Polypi which originate in the posterior portion of the nasal cavity often enlarge posteriorly and finally project into the nasopharynx. Here, meeting with no counter-pressure, they increase rapidly in size, often completely filling the cavity, and protrude below the lower margin of the soft palate. Such polypi are very often cystic in character, being scarcely more than a thin shell of connective tissue enclosing a large amount of fluid. Their size frequently prevents the examiner from accurately determining their point of origin, whether from the mucous membrane of the nasopharynx or that of the nose.

Symptoms. The most marked symptom produced by these tumors is obstruction to nasal respiration. The patients are mouth-breathers. Where the tumors do not completely fill the nasopharynx it is frequently noticed that some air can be inspired through the nose during forcible inspiration, but the moment any attempt at expiration is made the movable tumor is pushed forward, so as to fill up the choanæ, and serves as an effectual plug to prevent the expired air passing out through the nose. Snoring and restlessness at night are complained of, and the patients awake in the morning but little benefited by their sleep. When the growths press

upon the Eustachian orifices impairment of hearing is commonly observed. The voice has a peculiar nasal twang, and epistaxis or expectoration of blood is occasionally seen.

Examination. Posterior rhinoscopy reveals a growth which, according to its size, more or less completely fills the nasopharynx. Its surface is smooth, pale, and semi-translucent, having very much the appearance of a nasal polyp. On examining the anterior nares the growth may be visible in the posterior portion of the nasal cavity, having pressed itself into the choanæ. Where the seat of attachment is not visible in the rhinoscopic mirror the finger should be introduced into the nasopharynx. The growth will be felt to be soft, yielding, freely movable, and its pharyngeal or nasal attachment, which is usually by a small pedicle, can readily be ascertained.

Differential Diagnosis. The mass is to be differentiated from the other non-malignant growths, from hypertrophy of the posterior ends of the inferior turbinates, and from malignant growths in this region.

The other non-malignant growths are brighter red in appearance when viewed through the mirror, and are more irregular in outline. Hemorrhage is much more common and more severe in the other non-malignant growths than in polypi. When felt with the finger the other growths are found to be of much firmer consistency, and lack the elastic feel that polypi have.

Hypertrophy of the posterior ends of the inferior turbinates may be so extensive as to project well into the nasopharynx, simulating nasopharyngeal tumors. If, however, care be taken to observe the position of

these growths—namely, at the anterior portion of the nasopharyngeal cavity, and occupying the position that the normal inferior turbinates should have—they should not be mistaken for new growths. The finger introduced into the nasopharyngeal cavity should be sufficient to ascertain the sites from which they spring—namely, the posterior ends of the inferior turbinates.

Malignant growths may be mistaken for post-nasal polypi. In their early stage the diagnosis may be in doubt, but after a few weeks the very rapid increase in size of malignant growths, their tendency to profuse bleeding, the pain and cachexia that accompany them, together with the age of the patient, enlargement of the cervical glands, and a fetid, mucopurulent discharge from the nasopharynx, reveal the character of the growth.

Prognosis. The prognosis, as far as life is concerned, is good. The growths have, like nasal polypi, a marked tendency to return, or at least are followed by the appearance of other polypi.

Treatment. In the vast majority of cases the cold-wire snare may be advantageously employed to remove these growths. The galvano-cautery snare may also be used for this purpose. The nose and the nasopharynx should be thoroughly sprayed with a 10 per cent. solution of cocaine and the seat of the pedicle accurately determined by inspection in the mirror and palpation with the finger. If the patient be a child, or one whose nasopharynx is exceedingly sensitive, it is advisable to remove these growths under general anesthesia rather than with cocaine. The Schroetter snare (Fig. 25) should be threaded with the loop in the horizontal position, as shown in Fig. 27, and passed into

that nasal cavity which is on the same side of the head as that from which the growth springs. The forefinger of the left hand should be passed behind the soft palate up into the nasopharynx, and as the wire loop reaches the nasopharynx the forefinger should adjust the loop around the growth, pushing the wire well up to the base of the pedicle. Traction should now be made upon the handle of the snare until it is found that the wire begins to engage the growth. If the subsequent traction be made intermittently, so as to take half a minute or a minute to cut through the pedicle, much less hemorrhage will result than when the tumor is cut off quickly. The site of the stump should be examined with the mirror and with the finger, and if it is found that some of the pedicle still remains the Loewenberg forceps (Fig. 75), may be advantageously employed to remove it.

The after-treatment simply consists in keeping the nasopharynx clean by syringing the nose with normal saline solution.

Fibroid Tumors of the Nasopharynx.

Etiology. The causes producing fibroid tumors in the nasopharynx are not known. It has been observed that they occur more frequently in males than in females, and most commonly between the ages of fifteen and twenty-five. Noting the large number of cases recorded in German and French literature, these growths appear to be more common in those countries than in this.

Pathology. Fibromata consist of very dense, firm connective tissue containing bloodvessels. Their contour is apt to be uneven and often lobulated. They usually spring from the vault of the nasopharynx, al-

though they may arise from the posterior or lateral walls of this cavity. When very large their size causes them to press upon the mucous membrane of the nasopharynx, producing atrophy of the parts with which they come in contact. They have been known to exert such firm pressure upon the sphenoid bone and the posterior wall of the antrum of Highmore as to cause absorption of the bone at these points, and to project in the one case into the cranial cavity, and in the other into the antrum. They are usually attached by a small base, but may have a broad seat of attachment.

Symptoms. The symptoms produced by fibromata are very much the same as those of polypi in this region. They have, however, a greater tendency to bleed, and, owing to the pressure of the growth upon the mucous membrane, erosions occur. Pain, especially where ulcers exist, may be complained of. There is usually a mucous or mucopurulent discharge, which runs down the posterior pharyngeal wall and is expectorated or swallowed. Where the tumor is large it pushes the soft palate forward, and there are usually some difficulty in swallowing and a sensation as if a foreign body were lodged in the throat.

Examination. Posterior rhinoscopy reveals a reddish or pale irregularly shaped tumor in the nasopharynx. Examined by the finger these growths are found to be dense, firm, freely movable, and with a point of attachment high up in the vault of the nasopharynx.

Differential Diagnosis. The differential diagnosis between nasopharyngeal polypi and these growths has already been given. Malignant growths may be mistaken for fibroid tumors. Where any doubt exists as

to the character of the growth it should be cocainized, and a piece removed with the forceps submitted to a microscopical examination to ascertain its character. Papillomata and adenomata are of such rare occurrence, and their symptoms so resemble those of fibromata, that we shall do no more than mention the existence of these growths. Chondromata are also exceedingly rare, and differ from fibromata in that, when examined by the finger, they are dense, hard, and cartilaginous to the touch.

Prognosis. The prognosis in these growths depends upon their size. If small, they are usually readily removed. Severe hemorrhage is to be expected. If very large, they may demand a capital operation for their removal, the dangers of which are considerable. They not infrequently return after removal.

Treatment. The method of removing small nasopharyngeal fibromata is identical with that advised for the removal of nasopharyngeal polypi. Where the growth is very large, completely filling the nasopharynx, it may be impossible to pass a snare around it. In such cases electrolysis has been employed with fair results. The process is long and tedious. If this does not suffice, then an extensive surgical operation, involving resection of the superior maxilla or splitting the soft and hard palates, may have to be resorted to. These operations, on account of the sepsis that is likely to follow and the danger of septic pneumonia, are not to be undertaken without advising the patient of the risk. The treatment following the operation is the same as that advised for nasopharyngeal polypi.

MALIGNANT GROWTHS OF THE NASOPHARYNX.

These may involve the nasopharynx primarily, and as such be either sarcomata or carcinomata. The former are seen in children as well as in adults. Carcinomata rarely occur before the fortieth year. Secondary involvement of the nasopharynx occurs from the extension of malignant growths of the nose, antrum, orbit, mouth, tongue, and especially in cases of malignant disease of the tonsils.

Symptoms. In their early period of development the only symptoms produced by these growths are the presence of a more or less rapidly increasing obstruction to nasal respiration and a nasal twang to the voice. Later, pain of a lancinating character, shooting up to the ear on the affected side, will be complained of. Hemorrhage, either in the form of epistaxis or the expectoration of blood from the mouth, is usually seen in these cases. A fetid, mucopurulent, often slightly blood-tinged discharge from the nose and into the oropharynx accompanies this condition when ulceration takes place. Enlargement of the glands at the angle of the jaw on one side if the growth is limited, or on both sides if extensive, is the first symptom for which patients may come for treatment. Cachexia and emaciation are late manifestations of the disease.

Examination. Posterior rhinoscopy reveals a dark reddish, perhaps purplish mass, whose surface is often seen to be ulcerated and covered with a yellowish or greenish secretion. Examined with the finger, the growth is found to be firm or else friable, and firmly attached to the surrounding tissue, the examining finger usually causing some hemorrhage. A small amount of

the tissue removed and examined microscopically will confirm the diagnosis.

Prognosis. Sarcomata of the nasopharynx have been successfully removed. They usually, however, return and run a fatal course. Carcinomata are invariably fatal. The disease usually terminates life either from sepsis or erosion of the bloodvessels in the neck, when death from hemorrhage takes place. The course of the disease is very rapid, the patient succumbing in from three to twelve months.

Treatment. Where the growth is found, on microscopical examination, to be sarcomatous, a radical operation for its removal is to be advised, providing there is a fair chance of removing all of the growth.

When the structures in the neck are also found to be infiltrated there is little hope of relief, and it is better to keep the patient comfortable with anodynes and let the disease take its course.

CHAPTER IX.

DISEASES OF THE OROPHARYNX, TONSILS, AND TONGUE.

ACUTE PHARYNGITIS.

AN acute inflammation of the mucous membrane of the pharynx.

Etiology. The causes of acute pharyngitis may be classified as predisposing and exciting.

The conditions predisposing a person to attacks of this disease are debilitated states of the body in those whose occupations are of a sedentary character and who take insufficient exercise. Improper clothing, as often in those who are over-clothed as in those who are insufficiently clothed, also predisposes to this disease. The attacks are most prevalent during the winter, and somewhat more frequent in the spring and autumn than in the summer months. Gout, rheumatism, alcoholism, and the excessive use of tobacco also predispose to this disease. The menstrual epoch in women often leaves the system in such a condition as to make these patients susceptible at such times to acute pharyngitis.

Among the exciting causes, first and foremost are a sudden chilling of the body surface while perspiring, exposure to draughts that strike upon the back of the neck, and getting the feet wet. The disease is very frequently secondary to acute rhinitis, nasopharyngitis,

and laryngitis. At times the disease is so prevalent that it would seem as if some as yet unknown epidemic influences were at work to cause it. Many of the acute infectious diseases, such as influenza, scarlet fever, measles, German measles, smallpox, typhoid fever, and erysipelas, are accompanied by acute pharyngitis. The earliest manifestations of secondary syphilis of the pharynx have most of the appearances of an acute pharyngitis.

Symptoms. The disease is ushered in usually by a sense of dryness in the throat. Within a few hours pain at the back part of the pharynx is experienced. A peculiarity of acute pharyngitis in patients having a rheumatic diathesis is the varying location of the seat of the pain. One day it will be located upon one side of the pharynx, and in a few hours or the next day the point of greatest pain may be situated at some other portion of the pharynx. There is often a sensation as of a lump at the back of the throat, which causes continual attempts at swallowing, in order to rid one's self of this disagreeable feeling. Early in the disease the patient may have a distinct chill, more often a chilly feeling extending up and down the back. The temperature is usually slightly elevated, varying from 100° to 102° F. Headache and a sense of lassitude are frequently complained of. As the disease progresses difficulty in swallowing becomes quite marked, so that the patient may be disinclined to take food. Associated very frequently with acute pharyngitis are acute rhinitis and acute laryngitis. Cough accompanied by expectoration of mucus is frequently seen independently of acute laryngitis. The uvula is often edematous, and the patient will then complain of the sensation as

of a foreign body in the throat, tickling, and coughing, which are more marked when lying down at night. These may be so annoying that the patient's sleep is much disturbed.

Examination. Examination of the oropharynx shows the mucous membrane upon the posterior wall bright red, swollen, and coated with thick, tenacious mucus. The uvula is usually reddened, swollen, perhaps edematous, and the pillars of the fauces and tonsils are very frequently inflamed. Examination of the nose and of the larynx usually shows an acute inflammation involving these cavities as well.

Differential Diagnosis. Ordinarily there is no difficulty in diagnosing an acute pharyngitis. It may not always be easy at the first visit to recognize the difference between a simple acute pharyngitis and one that is to usher in an attack of one of the acute infectious diseases mentioned in the etiology. Two or three days usually suffice to distinguish between simple pharyngitis and that accompanying an infectious disease. It may, however, be a week or ten days before the acute pharyngitis of syphilis so develops that mucous patches and the true character of the disease can be diagnosed.

Prognosis. The prognosis in simple acute pharyngitis is good. The disease usually lasts from three or four days to two weeks.

Treatment. The treatment of this disease should be both general and local. It is better to begin the treatment of an attack with the administration of a mercurial laxative, such as tablet triturations of hydrargyrum chloridum mite, one-quarter grain being administered in the evening, every half-hour, until eight are taken.

This should be followed in the morning by a Seidlitz powder or a dose of Rochelle salt. One should also carefully ascertain the diathesis of the patient. Where a rheumatic history is obtained the following may be given :

R.—Phenacetin gr. xxxvj.

Salol ʒj.

M. et ft. in chart No. 12.

Sig.—One every two hours until pain is relieved.

We are also in the habit of prescribing for these patients, every three hours, one-half teaspoonful of bicarbonate of sodium and one-half teaspoonful of Rochelle salt dissolved in a tumblerful of water, until the urine becomes alkaline, after which these should be administered three times a day, one-half hour before meals.

Those who have a gouty diathesis are to be given one-half grain of the acetic extract of colchicum three times a day. At the onset of the disease aconite, if given one drop every fifteen minutes until profuse perspiration is induced, often seems markedly to cut short the duration of the disease, and may even abort an attack. Where there is much restlessness at night a ten-grain Dover's powder will give the needed sleep. Quinine in large doses is frequently given in the early stages, but we are often disappointed in the results obtained from the use of this drug.

The local treatment should consist in prescribing an alkaline spray, the object of which is merely to soften the thick, tenacious mucus and render its expectoration more easy. Sodium bicarbonate, 20 grains, and water, 1 ounce, serve this purpose very nicely. As the dis-

ease begins to subside a mildly stimulating spray, such as bromide of sodium, 15 grains, and water, 1 ounce, often greatly assists in hastening recovery.

Gargles, which are so frequently prescribed for this condition, are practically useless. Very few patients learn to gargle their throats in such a way that the fluid comes in contact with any of the structures other than the dorsum of the tongue, anterior pillars of the fauces, and the anterior surface of the soft palate. The real seat of the trouble—the posterior pharyngeal wall—is not reached by the fluid during the process of gargling. The act itself is usually somewhat painful, so that little or no benefit is derived.

Cold in the form of a cold compress or a cold coil, applied to the neck, is usually very grateful to the patient, diminishing the pain and reducing the swelling and congestion of the pharyngeal tissues.

CHRONIC HYPERTROPHIC PHARYNGITIS.

A chronic inflammation of the mucous membrane of the pharynx characterized by hyperplasia.

Etiology. This disease is seen in those who are debilitated and anemic, or who present the opposite condition of plethora. Individuals subject to frequent attacks of acute pharyngitis may finally be left with the hypertrophic form. The disease is secondary to the various lesions of the nose which result in obstruction to nasal respiration. Those whose occupations cause them to inhale large quantities of dust, such as stone-cutters, cloth-cutters, operatives in tobacco factories, etc., frequently suffer from this disease. The improper or excessive use of the voice by public speakers, auctioneers, and peddlers will produce it. The constitutional condi-

tions with which this disease is frequently associated are rheumatism, gout, disorders of digestion, congestion and cirrhosis of the liver, cardiac hypertrophy, valvular lesions of the heart that produce obstruction to the return circulation, and those diseases of the lungs, such as chronic bronchitis, emphysema, asthma, and tuberculosis, in which prolonged and excessive coughing is a common symptom.

Pathology. There are a passive hyperemia of the bloodvessels and an increase in the connective-tissue cells of the submucosa. The mucus-secreting glands are perverted in their functions, and secrete a thick, tenacious mucus. There is usually some increase in the lymphatic tissue found in the submucosa.

Symptoms. The symptoms of a chronic hypertrophic pharyngitis are a sensation of fulness in the throat and the presence of a thick, tenacious secretion. This accumulates on the posterior wall of the pharynx at night, and in the morning is found to adhere so firmly that the efforts of hawking often result in vomiting before the mucus can be dislodged. These patients complain of various disorders of digestion. The tongue is coated, the appetite poor, and the acuteness of the sense of taste greatly diminished. Chronic laryngitis is almost invariably associated with this condition. The speaking voice is hoarse, and the patient usually finds he is unable to sing. Owing to the disease extending into the nasopharynx and through the Eustachian tubes to the middle ear, impairment of hearing is very common in this disease.

Examination. Some difficulty is usually experienced in making an examination of the pharynx in these cases, on account of the gagging due to the excessive sensi-

bility of the tongue and mucous membrane of the pharynx. The mucosa is red, swollen, and has a velvety appearance, and the bloodvessels, especially the veins, are distended and tortuous. On the mucous membrane, either over the entire surface or in small areas, thick, whitish mucus can be seen.

Differential Diagnosis. When a careful history of the case is taken and an inspection of the pharynx is made there can be no doubt as to the nature of the diseased conditions found.

Prognosis. The disease is apt to run a rather protracted course, owing to the inability to correct the constitutional conditions and the mode of life, so frequently important etiological factors in this disease.

Treatment. Before attempting local treatment of the pharynx the nose and nasopharynx should be examined and any diseased conditions found should be remedied. The physician should also inquire into the diathesis of the patient and seek to correct any of the conditions that have been mentioned in the etiology. Unless these two important factors are appreciated and appropriate treatment directed to correct them, little benefit will result from local treatment alone. Constipation and congestive disease of the liver are so frequently the cause of chronic hypertrophic pharyngitis that we advise the thorough evacuation of the bowels every morning with a dose of Epsom salt.

The local treatment consists in prescribing a spray to remove the viscid mucus. Twenty to thirty grains of bicarbonate of sodium to the ounce of water, to which may be added a small amount of listerine or borolyptol, in order that the solution may be more agreeable to the patient, answer this purpose. The

patient should be instructed to paint the posterior pharyngeal wall every day with

R.—Iodini	gr. x.
Potassii iodidi	gr. xx.
Glycerini	℥j.—M.

The alterative action of this assists in the absorption of the hyperplastic tissue. Once a week the physician should apply a 10 per cent. solution of nitrate of silver to the thickened mucosa with a cotton-wound applicator. This solution should be made fresh each time.

CHRONIC GRANULAR PHARYNGITIS (Clergyman's Sore Throat).

A form of chronic inflammation of the pharyngeal mucous membrane, accompanied by an increase in the size of the lymph-follicles. It is usually associated with hypertrophic pharyngitis.

Etiology. The causes of this disease are practically the same as those of chronic hypertrophic pharyngitis. Its special factor seems to be an improper or excessive use of the voice, especially in those who address large audiences or speak in the open air.

Pathology. The granules are found to be masses of lymphoid cells, varying in size from a pin's head to a pea. On the posterior pharyngeal wall they may vary in number from two or three to cases in which they are so thickly studded as almost to touch each other. They are usually isolated, but often three or four may be found bunched, the rest of the mucous membrane being free from them. Dilated veins can usually be seen radiating from these masses.

One of the commonest situations in which to find this

increase of lymphoid tissue is on the lateral wall of the oropharynx, just behind the posterior pillar of the fauces. When so situated the condition is known as pharyngitis hypertrophica lateralis.

This chain extends into the nasopharynx, and is intimately connected with hypertrophy of the lymphoid tissue in this region.

Symptoms. The most distressing symptoms that these patients complain of are cough and a tickling sensation as of a hair in the throat. This is most marked while lying down at night, so that the patient's rest is considerably broken. The continued coughing produces a hoarseness of the voice, and tends to keep up a chronic congestion of the pharyngeal mucous membrane that eventually results in hypertrophy.

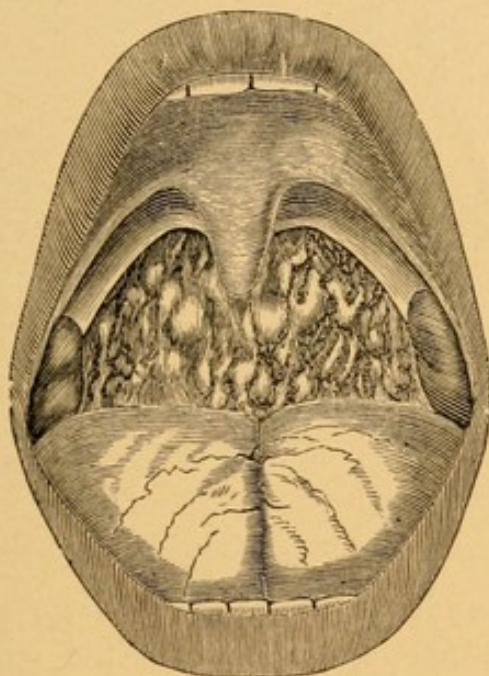
Where lateral hypertrophy behind the posterior pillars of the fauces exists mechanical interference with the functions of the posterior pillars of the fauces results. Deglutition then becomes difficult, and efforts at speaking tire the throat greatly. Singers find great difficulty in controlling the flexibility of the voice, false tones are produced, and the sufferers become very much discouraged and disheartened. The hearing in these cases is very apt to be impaired.

Examination. Examination of the pharynx reveals the rounded bodies with their dilated veins, as shown in Fig. 78. If recent, these masses are bright red in color; if of long standing, they may be paler than the surrounding mucous membrane. The lateral hypertrophy may not at first sight be very marked, but if the patient should gag as a result of depressing the tongue, then a thick, rounded projection can be seen on the lateral wall, internal to and behind each posterior pillar

of the fauces. The thickening may exist to the same degree on each side, but it is quite common to find it more extensive on one side.

Prognosis. The hypertrophies that exist at the time a patient consults a physician can usually be removed with little difficulty. Other masses of lymphoid tissue frequently increase in size when the original cause of the hypertrophy cannot be remedied.

FIG. 78.

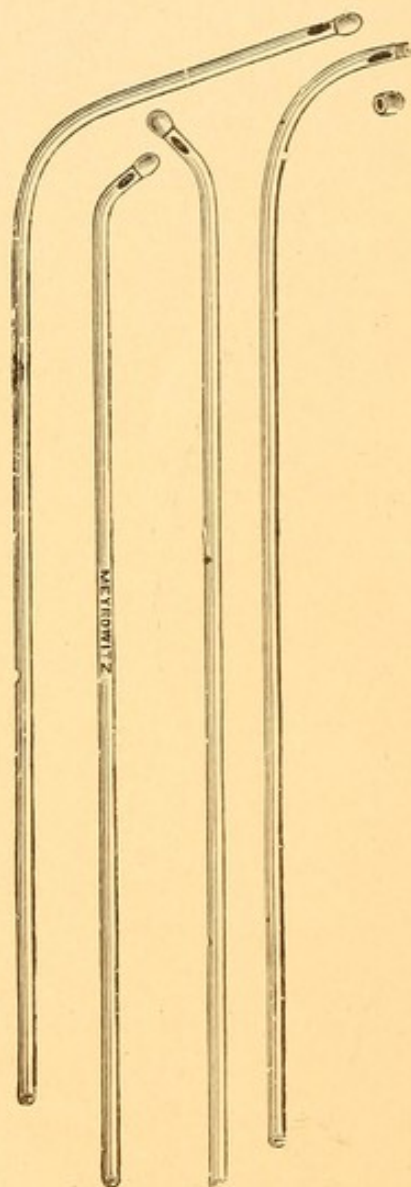


Granular pharyngitis.

Treatment. The constitutional treatment of these cases should be directed to ascertaining the diathesis of the individual, as in hypertrophic pharyngitis, and correcting it. Patients should also receive instruction from a vocalist or elocutionist, to enable them properly to use the voice. The administration of ten grains of potassium iodide internally, and Fowler's solution, five drops, three times a day, may be beneficial in preventing return of these growths.

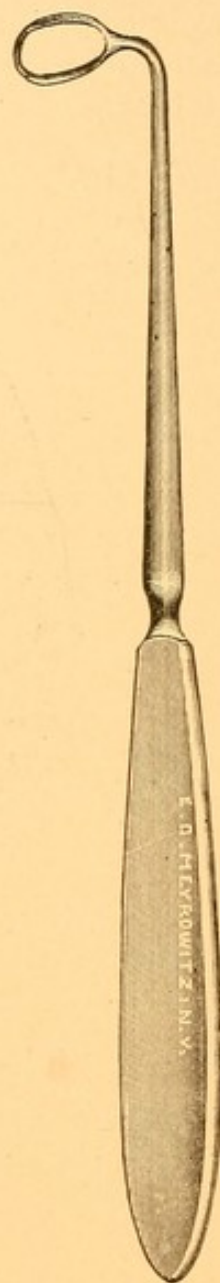
The local treatment consists in first spraying the pharynx with a 4 per cent. solution of cocaine. At the

FIG. 79.



Aluminum applicators for applying caustics.

FIG. 80.



Hartman's lateral cutting curette.

end of six minutes the posterior pharyngeal wall will be found to be anesthetic. Each elevation should be

touched with the point of a galvano-cautery electrode heated to a red heat. As the dilated bloodvessels carry increased nutrition to the hypertrophic areas, it is very necessary, in order to prevent the hypertrophy re-forming, that each of the small vessels radiating from the elevation should be lightly touched with a galvano-cautery electrode at about the middle point of its course. This occludes the bloodvessel and prevents hypernutrition and consequent increase of the lymphoid cells. Where the number of granulations is very great it is usually advisable to destroy only a part (six or eight) at one sitting. After healing has taken place—in from six to ten days—more should be destroyed in the same way until all are eradicated. Where a galvano-cautery is not accessible crystals of nitrate of silver should be fused upon the end of a probe or upon an applicator, such as is shown in Fig. 65 (one of the short, curved ones), and the granulations cauterized in this way. To remove the chain of lymphoid follicles on the lateral wall the cautery point may also be employed where the tissue is not too excessive. If very thick, the Grünwald punch forceps, or a lateral cutting curette (Fig. 80), used in a manner similar to that of the Gottstein curette (see Treatment of Adenoids), should be employed.

This operation, in spite of cocaine, is quite painful, and in nervous patients a general anesthetic is preferable. The treatment after cauterizing is the same as that for chronic hypertrophic pharyngitis—namely, cleanliness.

CHRONIC ATROPHIC PHARYNGITIS (Pharyngitis Sicca).

A chronic inflammation resulting in atrophy of the mucous membrane of the pharynx.

Etiology. This disease is sometimes secondary to chronic hypertrophic pharyngitis. It more commonly is associated with atrophic rhinitis and atrophic nasopharyngitis. The same causes which produce these diseases are consequently factors in the production of atrophic pharyngitis. It may occur in persons who are extremely anemic, without any previous history either of hypertrophy of the pharyngeal mucous membrane or atrophy of the nasal mucous membrane. Two constitutional diseases—diabetes mellitus and cirrhosis of the kidney—are frequently complicated by atrophic pharyngitis.

Pathology. The normal subepithelial tissues are replaced by connective tissue. Many of the glands are so pressed upon as gradually to atrophy and disappear. Those which persist have their functions altered, so that they secrete a scanty but thick and tenacious mucus. The inspired air robs this of what little moisture it contains and leaves it deposited upon the mucous membrane of the pharynx in the form of hard, dry crusts.

Symptoms. The condition is most distressing to patients, suffering as they do from an intense dryness and burning in the throat. The irritation of this dried mucus produces considerable reflex coughing in order to clear the throat. This is always more marked in the morning, and often before the crusts can be removed gagging and even vomiting are produced.

Owing to the laryngitis which almost invariably accompanies this disease the voice is husky and at times aphonic. Not infrequently the decomposition going on in these crusts gives rise to an odor which imparts itself to the breath.

Examination. The posterior pharyngeal wall will be found pale, dry, and covered either with a thin, scale-like mucus or thick, dry, dark brown or blackish crusts. The glistening appearance of the mucous membrane is not unlike the sheen of parchment. When the posterior pillars of the fauces contract, instead of the elastic tissue in the mucous membrane taking up the slack the inelastic connective tissue wrinkles. Small areas of superficial ulceration may occasionally be seen. Where no cause for the condition can be found in the nose, such as atrophic rhinitis or the results of syphilitic necrosis, it is always advisable to examine carefully the urine for evidences of either diabetes or chronic cirrhotic lesions in the kidney.

Differential Diagnosis. The cicatricial tissue left by an old syphilitic, tubercular, or lupoid ulcer may be mistaken for that of atrophic pharyngitis. These ulcerations are invariably deep, and leave a scar that binds the mucous membrane firmly to the cervical vertebræ. The cicatricial bands have a white, puckered appearance when the pharynx is at rest, quite at variance with the pale, smooth condition of the mucosa found in atrophic pharyngitis. The puckering in the latter condition occurs only with contraction of the muscles. The history of an ulcer at some previous date, with its pain and discharge, is very different from that of atrophic pharyngitis.

Prognosis. Atrophic pharyngitis is practically never

recovered from. All that can be done is to make the symptoms less annoying by lessening the crust formation.

*12 Cl 13
10 gts 3/1.
boroglyceride*
Treatment. The treatment recommended is to prescribe a spray to soften and loosen the thick mucus, and subsequently to paint the pharynx with such substances as will stimulate the glands to greater activity.

For the first purpose a spray of chlorate of potassium (ten grains to the ounce of water) serves very well. For the second purpose the medication must be varied from time to time, as the glands fail to respond to any one stimulus for any length of time. The patient should be given boroglyceride, and instructed how to paint the posterior pharyngeal wall with this night and morning. At the end of two or three weeks this remedy loses some of its efficacy, and then the following may be used in an oil atomizer:

R.—Menthol	gr. xx.
Eucalyptol	3j.
Benzoinol	q. s. ad	3j.—M.	

These two preparations may be employed alternately, each being used for a period of two weeks.

Pilocarpin, one-tenth grain, three times a day, often serves admirably to increase the secretion from the mucous membrane, and relieves the disagreeable sensation of intense dryness in the pharynx.

If atrophic processes are present in the nose or nasopharynx, they should be treated as already described.

Where diabetes or cirrhotic kidney is the etiological factor appropriate treatment for the condition should be directed.

RETROPHARYNGEAL ABSCESS.

A collection of pus in the connective tissue beneath the mucous membrane of the pharynx.

Etiology. In the majority of cases it is very difficult to determine the exciting cause. The disease occurs most frequently in infancy or in very early childhood, before the third year. A few cases have been reported as occurring in adults. Tuberculosis, rickets, and inherited syphilis in children predispose to this disease. It is often seen following the acute infectious diseases of childhood. Foreign bodies have been known to lacerate the posterior pharyngeal wall, through which pus-producing germs gained access to the submucous areolar tissue, and abscess resulted. Caries of the cervical vertebræ is sometimes an etiological factor.

Pathology. In infancy a few lymph-glands are found beneath the mucous membrane of the pharynx, opposite the second and third cervical vertebræ. It is believed that the suppuration originates in these glands. They have been observed to be greatly enlarged, hard, and indurated. Later a retropharyngeal abscess is found in place of the hard mass. It is probable that the early stage—the enlargement of these glands—owing to the age of the child and its inability to complain of the symptoms produced at this time, is overlooked, and only the objective symptoms of a large abscess call attention to the pharynx. These glands usually atrophy before the fifth year. Cases dependent upon caries of the spine are seen more frequently by the orthopedic surgeon as one of the complications of tuberculosis of the spine (Pott's disease of the spine). The collection of pus may be sufficiently

large to burrow behind the mucous membrane not only of the entire oropharynx, but to dissect upward or downward, involving, on the one hand, the mucous membrane of the nasopharynx, and, on the other, that of the laryngopharynx.

Symptoms. The fact that the disease occurs so often in very young children who are unable to talk makes a complete history very difficult to obtain. The child is taken sick, has fever, and cries considerably. When the abscess has reached a large size the cry is very peculiar, and has been likened to that of the "quacking of a duck." It is probable that the child suffers considerable pain. For a few days the physician is often at a loss to determine the cause of the child's sickness. Soon swallowing becomes difficult, and it is noticed that the child refuses the breast or the bottle. Dyspnea supervenes, with great restlessness and coughing, and, finally, symptoms similar to those of croup when the abscess has extended down so as to press upon the entrance to the larynx. At such time, if not sooner, it occurs to the physician to examine the throat, when he readily finds a cause for these symptoms. Stiffness of the muscles of the neck and torticollis are seen, especially in those cases which result from caries of the cervical vertebræ. Mouth-breathing and in older children a nasal twang to the voice are usually observed. The child, owing to its inability to take food and the high temperature, rapidly emaciates. Enlargement of the lymphatic glands at the angle of the jaw may take place early, and indicate to the physician the probability of a septic process arising from the throat.

Examination. As soon as the child's mouth is opened and the tongue depressed there will be observed a

bulging forward of the posterior pharyngeal wall, pushing ahead of it oftentimes the soft palate and uvula. These may be pushed so far forward as to appear almost in the middle of the cavity of the mouth. When the finger is introduced fluctuation can readily be detected in the bulging mass.

Differential Diagnosis. The symptoms may resemble somewhat those of croup, for which it has been mistaken. Inspection of the fauces fails to detect a membrane. The peculiar fluctuation and bulging should not deceive the physician as to the nature of the disease.

Prognosis. When seen early and the pus evacuated these cases make a good recovery. The cavity not infrequently fills up partially once or twice with pus before it finally is obliterated. Where the cause is caries of the cervical vertebræ the prognosis is not so good. Cases of retropharyngeal abscess have produced death, the cause of which was only detected on the autopsy table.

Treatment. The abscess should be evacuated. The method of doing this depends upon the cause. Where one has reason to suspect that the cause is due to caries of the vertebræ it is better to make an external incision along the anterior border of the sterno-cleido-mastoid, dissect up the great vessels of the neck at the level of the upper border of the thyroid cartilage, and push a pair of scissors through the lateral wall of the pharynx into the abscess cavity. These should then be widely opened, so as to increase the opening into the abscess cavity, which should then be washed out with Thiersch's or carbolic acid (1:100) solution. The finger should next be introduced, the cavity explored, and any dis-

eased bone found removed with a Volkmann spoon. The abscess cavity should be lightly packed with gauze, a piece of which should be allowed to protrude from the wound to serve as drainage. The after-treatment is the same as that of any abscess.

The majority of cases can be opened through the mouth with perfect safety. The child should be held upon the lap of an assistant, with the head considerably lower than the rest of the body. A sharp-pointed curved bistoury is held against the forefinger, so that the point is guarded until such time as the finger can be introduced into the mouth, and placed at what, in the upright position of the child, is the most dependent point of the abscess. This is usually just above the entrance into the larynx. If the finger now be slipped to one side, the bistoury can readily be pushed through the thin mucous membrane into the abscess cavity and a long, free incision toward the nasopharynx made. Inexperienced operators are apt to make a slight puncture instead of a free incision. The pus will flow out of the mouth and nose. The finger should be introduced into the mouth, and any pus remaining in the cavity should be gently pressed out. The child should be carefully watched, and the pharynx examined the next day with the finger to see whether pus has re-accumulated or not; if so, it must be evacuated.

The after-treatment consists in building up the child by the administration of cod-liver oil and iron.

ACUTE INFLAMMATION OF THE UVULA (Acute Uvulitis).

Etiology. The loose areolar tissue composing the bulk of the uvula beneath the mucous membrane, and

its dependent position, suspended as it is from the lower border of the soft palate, render this organ peculiarly liable to congestion and edema in all acute inflammatory conditions which involve the soft palate. In acute pharyngitis and in acute tonsillitis the uvula is very frequently found to be acutely inflamed. The infectious diseases of childhood, in which there is inflammation of the pharyngeal mucous membrane, are complicated usually by acute uvulitis. Foreign bodies, such as fish-bones, frequently penetrate the uvula, producing acute inflammation, which may result in abscess formation. The uvula may be the seat of diphtheritic and syphilitic exudations; the description of these is given under the headings of these diseases.

Symptoms. The symptoms of acute uvulitis are usually complicated by those of the disease which it accompanies. Those symptoms referable to the uvula are mainly dependent upon the increased size of the organ and the irritation this produces to the pharynx, base of the tongue, and epiglottis, with which it is often in contact. There is a sense of tickling in the throat, accompanied by an irritating cough. These are apt to be more marked at night or when the patient is in the recumbent position. The uvula may be so greatly elongated that its lower border hangs over the entrance into the larynx. In such cases, dyspnea, with a sense of impending suffocation, is the symptom complained of.

Examination. Examination of the mouth shows the uvula elongated, and in extreme cases so much so that the inferior border of it may not be visible with ordinary depression of the tongue. The uvula may be bright red; more frequently, only portions are bright red, other portions being pale and semi-translucent in

the parts that are markedly edematous. The diameter of the uvula is often twice or three times that of the normal organ.

Treatment. In moderate elongation of the uvula the use of an astrigent spray, such as glycerite of tannin, 1 drachm; water, 1 ounce, suffices to reduce the organ nearly to its normal size. The sucking of pieces of ice, about the size of a hickory-nut, is also beneficial in these cases. Where the uvula is very thick and edematous it is better to apply a 10 per cent. solution of cocaine by means of a cotton-wound applicator, and, at the end of five minutes, scarify with a sharp-pointed bistoury the uvula over the parts that appear to be most swollen and edematous. In very aggravated cases the uvula may be excised, as described in the next article.

CHRONIC ELONGATION OF THE UVULA.

Etiology. This disease is very frequently seen in those who are subject to attacks of acute pharyngitis and in those who have a chronic pharyngitis.

Symptoms. The symptoms produced are the sensation of a foreign body or a tickling in the throat and an irritating cough, most marked at night.

Examination. Examination will show the uvula elongated, often resting upon the base of the tongue even when this organ has been depressed. At times it may be so long that the lower border of the uvula can only be brought into view by passing a hook behind it and dragging it forward into the mouth. The lower extremity is apt to be enlarged and bulbous.

Treatment. Palliative treatment, such as the use of astrigent sprays, is of little use in chronic elonga-

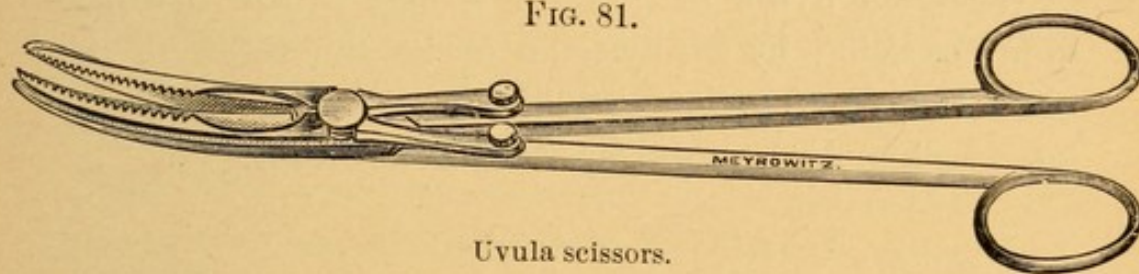
1 *astrigent spray*

2 *scarified*

3 *excised*

tion. The uvula should be excised. It should first be painted with a 10 per cent. solution of cocaine, and at the end of five minutes the uvulotome or uvula scissors (Fig. 81) should be inserted into the mouth, the tongue being depressed, and the uvula grasped about three-eighths of an inch from its attachment to the lower border of the soft palate. The scissors are curved, and should be so applied that the cut through the substance of the uvula is made in a slanting direction, the anterior part of the incision being at a much lower level than the posterior portion. The uvula is thus cut, not straight across, but on the bias, from below upward and

FIG. 81.



backward. This brings the cut in such a position that during deglutition the raw surface is pushed back against the posterior pharyngeal wall, and is not scraped by the food in the act of swallowing. If one does not possess a uvulotome, a pair of ordinary curved scissors may be used. The tendency is for the uvula to slip from between the blades of such a pair of scissors. To prevent this the uvula may be grasped with a tenaculum forceps. The cut surface in these cases is not apt to be left as above described, and the subsequent pain during the healing process is consequently greater, owing to the irritation of the bolus of food during deglutition. Hemorrhage is frequently persistent after excision of the uvula, but it is always controlled

either by light cauterization of the stump with the galvano-cautery, or, where this is not obtainable, by the use of a thick, syrupy solution of tannic acid in water, applied to the part with a cotton-wound applicator.

DEFORMITIES OF THE UVULA.

The uvula is often bifid, the two portions being quite separate in their origin from the soft palate. This is frequently seen in connection with congenital cleft palate. Two distinct uvulæ may be seen where the soft palate is otherwise normal. The end of the uvula is sometimes bifid, like an inverted Y.

When the uvula is absent this may be due to a previous excision by a physician or be the result of the ulceration from tertiary syphilis in the organ. Usually no symptoms are caused by these deformities.

ACUTE TONSILLITIS.

An acute inflammation of the parenchyma of the tonsil and of the lacunæ or crypts in those organs. The two structures may be equally involved, or one or the other may predominate. This has led to the subdivision of acute inflammation of the tonsil by some clinicians into acute parenchymatous and acute lacunar tonsillitis. We shall include both forms under the head of acute tonsillitis.

Etiology. The etiology may be divided into predisposing and exciting causes.

The most important predisposing cause is the rheumatic diathesis. In about 60 per cent. of the cases a history of acute rheumatism, either in the patient himself or in other members of his family, can be obtained. Heredity also plays a very important part. The fathers

or mothers will very frequently be found to have suffered from acute tonsillitis at some time in their lives. Acute tonsillitis most frequently occurs between the tenth and the thirtieth year. It may occur somewhat earlier, and it has occurred at a considerably later period in life. The disease is more common in the fall, winter, and spring months, and at such times when sudden atmospheric changes occur. The living in damp dwellings and unhygienic surroundings also predispose to this disease. It is more common in those who have enlarged tonsils than in those whose tonsils are normal in size. A person who has had one attack is very likely to have another, and it not infrequently happens that at or about the same time each year an attack is experienced. Lowered vitality from overwork, worry, or mental anxiety predisposes to it.

The most common exciting cause is getting the feet wet. Nearly as frequent a cause is sitting in a cold draught, especially where the air strikes the back of the neck, while the body is overheated. At times the disease is so prevalent that it would seem that some infective germ was in the atmosphere capable of exciting this disease. Where one member of a family has acute tonsillitis other members are subsequently often attacked, so that the disease is at times rightly considered contagious. Exposure to certain of the contagious diseases, especially scarlet fever and diphtheria, frequently is followed by an attack of acute tonsillitis.

Pathology. In acute tonsillitis there is an enlargement of, and a rapid increase in, the lymph-cells, so that the size of the tonsil is often doubled or trebled. In the parenchymatous form this is more marked than in the lacunar variety. In the latter form a prolifera-

tion of cells along the lacunæ and a migration of lymphoid cells from the parenchyma take place. Owing to the presence of bacteria these cells degenerate into a fatty, granular mass of the consistency of soft cheese. These masses, of a white or yellowish color, may often be seen protruding from the mouths of the lacunæ. At other times they are smeared over the free surface of the tonsil, resembling an exudation. The bacteria most commonly found in the exudation are staphylococci, streptococci, and pseudodiphtheria bacilli. The mucous membrane of the pharynx is usually inflamed and has the appearance described in the article on Acute Pharyngitis.

Symptoms. An attack of acute tonsillitis is often ushered in by a chill, followed by a rise in temperature from 103° to 105° F.; the pulse is rapid, from 100 to 120. The patient complains of headache and pain in the back and limbs. There is a sense of fulness in the throat, which quickly is followed by sharp pain on the side of the affected tonsil. Where both tonsils are affected, as occasionally happens, this pain is bilateral. The pain sometimes radiates to the ear on the affected side. Dysphagia and a constant desire to swallow, the latter act being exceedingly painful, are usually complained of. The tongue is coated, the breath foul, and the bowels constipated. The urine is scanty and high colored, and often voided with a burning sensation. Albumin is not usually found in the urine unless the temperature be very high—105° F. or thereabout. The solids, especially the urates, are greatly increased. Cough is an occasional symptom, and there is a nasal twang to the voice. Sleep is usually restless, the breathing labored and often stertorous. The severity of

the symptoms usually, but not always, keeps pace with the swelling of the tonsils. In the parenchymatous form the symptoms are more severe than in the lacunar variety. Only one tonsil is usually involved; both, however, may be, and in such cases the lacunar type is more common. As one tonsil gets better the other tonsil may be inflamed, and thus the symptoms be prolonged. There is no slight affection that can make a patient feel more miserable in so short a time as acute tonsillitis. The symptoms last from three to seven days, gradually subside, and leave the patient feeling weak, owing to the high temperature and inability to take proper nourishment.

Examination. The examination of the throat in a person suffering from acute tonsillitis is often difficult, owing to the excessive sensibility of the mucous membrane. The tonsil is observed to be swollen, projecting beyond the pillars of the fauces more or less, according to the type of the inflammation, whether parenchymatous or lacunar. The crypts are usually distended, and a white or yellowish secretion may be seen filling their mouths. A cheesy material is often spread over the surface of the tonsil, and may resemble a membrane. If attempts are made to remove this with a cotton-wound applicator, this material can very readily be wiped away, leaving an unbroken, merely red and inflamed mucous membrane underneath. The pillars of the fauces and the soft palate are bright red; the blood-vessels are often injected. The uvula is swollen, red, edematous, elongated, and where one tonsil alone is greatly enlarged usually curved so as to lie against the free surface of that tonsil. The posterior pharyngeal wall has the appearance described in the article on Acute Pharyngitis. There is usually a considerable amount of

thick, tenacious mucus covering its surface. The lymphatic glands in the neck, below the angle of the jaw, are usually enlarged on the side of the affected tonsil.

Differential Diagnosis. Acute tonsillitis may be mistaken for mycosis of the tonsil and for diphtheria.

The differential diagnosis between tonsillitis and diphtheria is as follows:

TONSILLITIS.

1. Sudden onset.
2. Chill.
3. Temperature 103° to 105° F.
4. Vomiting is occasional.
5. Albuminous urine rare.

DIPHTHERIA.

1. More gradual onset.
2. Chill is rare.
3. Temperature 101° to 103° F.
4. Vomiting is common.
5. Albuminous urine common.

Examination.

- | | |
|--|--|
| 1. Tonsils considerably enlarged. | 1. Tonsils not much enlarged unless chronic hypertrophy of the tonsils previously existed. |
| 2. Exudation in spots or a "pseudo-membrane." | 2. Exudation, a thick membrane. |
| 3. Pseudomembrane margins are the same color as the rest of the mucous membrane of the tonsil. | 3. Diphtheritic membrane margins are dark red or purplish in color for a distance of a quarter of an inch. |
| 4. Pseudomembrane not adherent; easily wiped away with cotton. | 4. Membrane very adherent; removed with difficulty, and only with forceps. |
| 5. Leaves no bleeding surface. | 5. Denuded surface bleeds. |
| 6. Pseudomembrane does not re-form. | 6. Membrane re-forms in a few hours. |
| 7. Pseudomembrane limited to the tonsil. | 7. Membrane also found on the pillars of the fauces, the soft palate, and posterior pharyngeal wall. |
| 8. Intense active hyperemia of the soft palate. | 8. Soft palate almost normal in appearance. |

Bacteriological Examination.

- | | |
|---|----------------------------|
| 1. Staphylococci, streptococci, and pseudodiphtheria bacilli. | 1. Klebs-Loeffler bacilli. |
|---|----------------------------|

There are slight forms of these two diseases in which only a bacteriological examination can determine the true nature. Without it these cases would be classed by one observer as tonsillitis and by another as diphtheria. Statistics, therefore, are apt to be unreliable.

Prognosis. The disease usually terminates favorably in from three to seven days. In rheumatic subjects an attack of rheumatism may follow. If these patients are allowed to leave the house before thoroughly recovered, re-infection may take place; the other tonsil or the same tonsil again inflaming, or a peritonsillar abscess frequently occurs.

Treatment. The patient should be kept in bed in a room the temperature of which is about 70° F. What little nourishment these patients are willing to take should be fluid; cold milk and Vichy, or very hot milk and lime-water, are apt to be most acceptable.

The constitutional treatment is to be begun by administering calomel, as in acute pharyngitis. Ten grains of salol, given every two hours until there is ringing in the ears or until the urine becomes dark and smoky, usually quickly relieve the patient. Ten to fifteen grains of phenacetin, every two hours until three doses are taken, greatly diminish the pain from which these patients suffer. Alkalies given internally are very advantageous. Half a teaspoonful of bicarbonate of sodium and half a teaspoonful of Rochelle salt should be administered every three hours until the urine becomes alkaline, after which these should be given morning, noon, and night. When the patient is restless at night, ten grains of Dover's powder usually control this. At the very beginning of the disease, if the temperature is high, one drop of aconite, adminis-

tered every fifteen minutes until free perspiration is induced, often markedly cuts short the duration of the disease. It is of little value to administer aconite after the first twenty-four hours.

The local treatment consists in applying cold to the throat externally. This may be done either by a cold compress, ice-bags, or, best of all, a cold coil. The relief of the swelling, congestion, and pain from the application of cold is often very marked. "Gargles," which are so frequently prescribed for this condition, are useless. The mere act of gargling induces great pain, and the liquid does not reach the seat of the disease. Those of us who have suffered from acute tonsillitis and have attempted to use a gargle will, I think, never prescribe it for another. To cleanse the throat from the thick, tenacious mucus, twenty grains of bicarbonate of sodium, dissolved in an ounce of water and sprayed into the throat, will reach the seat of the trouble and remove the mucus. Peroxide of hydrogen, either in full strength or diluted with equal parts of water, is also very efficacious in cleansing the throat. A 30 per cent. solution of argyrol acts well both as an antiseptic and astringent. It is best sprayed over the tonsil every four hours.

As the disease subsides an astringent will hasten the retrograde process. We are in the habit of prescribing:

R.—Tr. ferri. chlor.	℥iss.
Potass. chlor.	℥j.
Glycerini	℥iij.
Aquæ	q. s. ad.	℥iij.

M. et Sig.—One drachm, t. i. d., in one-third tumblerful of water; swallow.

When frequent attacks of acute tonsillitis occur in an individual, and in the intervals the tonsils are found

to be not increased in size, it is well to advise such a patient to submit to thorough cauterization of the tonsils with the galvano-cautery in the interval between the attacks, as described in the article on chronic hypertrophy of the tonsils.

Treatment during convalescence and for a time after should be a general tonic one, cod-liver oil and iron being the drugs most serviceable.

PERITONSILLAR ABSCESS (Quinsy Sore Throat).

Etiology. The causes of peritonsillar abscess are practically the same as those of acute tonsillitis. The former seldom occurs in epidemics, as does the latter, and it is not contagious. The period of life at which it is most common is from the eighteenth to the thirtieth years. It has even occurred in children, and we have seen it in a patient of sixty-five. It is very rare, however, at the extremes of life. It is probably due to the passage of pus-producing bacilli through the tonsillar substance or between the pillars of the fauces and the tonsils, invading the loose connective tissue external to the tonsils. It frequently follows an attack of acute tonsillitis where the individual has exposed himself, getting his feet wet, or contracting a fresh cold before having fully recovered from the previous tonsillitis. When a person has once had an attack of peritonsillitis, each subsequent inflammation of the tonsil is very likely to result in an extension of the disease to the peritonsillar tissue, and abscess results.

Pathology. The pus is found external to the tonsil in the loose connective tissue existing there. In about 90 per cent. of the cases the tendency of this pus is to burrow in an upward direction into the soft palate, markedly distending the tissues here, but limited to one side

of the soft palate by the dense connective tissue in the median raphe. In the remaining cases the pus passes down in the posterior pillar of the fauces on the lateral wall of the oropharynx; very rarely the pus burrows into the tonsillar substance. The point of exit of the pus often occurs through a spontaneous opening, the result of the dissection, on the one hand, of the anterior pillar of the fauces from the tonsil, and, on the other hand, of the posterior pillar of the fauces from the tonsil. In these cases the pus appears to pass through the tonsillar substance, whereas in reality it does not. The bacteria most frequently found in the pus are streptococci and staphylococci.

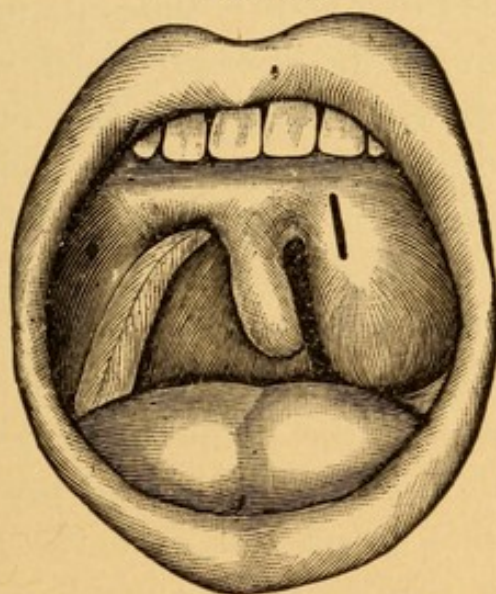
Symptoms resemble acute tonsillitis but more severe.

Symptoms. The symptoms of peritonsillar abscess resemble those found in acute tonsillitis. The chill, rise in temperature, and symptoms at the onset are, however, more severe. The pain is intense, and almost invariably extends up to the ear on the affected side when the pus burrows in an upward direction. At the end of forty-eight hours it is often impossible for the patient to separate the jaws more than a quarter of an inch. Where the pus burrows downward into the posterior pillar of the fauces there is usually not so much difficulty in opening the mouth. Deglutition is so excessively painful in peritonsillar abscess that it is impossible for these patients to take any nourishment whatever by the mouth. Thick, tenacious mucus collects in the posterior portion of the pharynx and distresses the patient very markedly, owing to his inability either to swallow or to expectorate it. Saliva frequently can be seen dribbling from the partially opened mouth. The high temperature and inability to take any nourishment, often for three or four days, produce great weakness and emaciation in the patient. There are

snoring at night, mouth-breathing, dyspnea, and a full, thick, guttural voice so characteristic that the diagnosis may often be made from this alone. The neck is usually stiff, the head being turned toward the affected side. The glands of the neck are usually greatly enlarged on the affected side.

Examination. Owing to the inability to open the mouth widely the examination of the throat in peritonsillar abscess is accomplished in many cases with great

FIG. 82.



Peritonsillar abscess on the left side.

difficulty. The moment the tongue depressor is introduced gagging is apt to result. Where the pus burrows in a downward direction into the posterior pillars of the fauces the mouth usually can be widely opened and a better inspection of the parts obtained. Where a view of the posterior portion of the throat can be obtained through the partially opened jaws the appearance is somewhat like that shown in Fig. 82. The anterior pillar of the fauces and the soft palate will be seen to be intensely red, often of a

purplish hue, swollen, and projecting far more anteriorly than the anterior pillar of the fauces and the soft palate on the opposite side. The tonsil itself is somewhat enlarged, but as a usual thing does not project very markedly beyond the swollen anterior pillar of the fauces. The mouths of the lacunæ usually are filled with yellowish, cheesy material. The bulging is often most prominent at a point just external to the base of the uvula, indicated in the figure by a heavy, dark line. The uvula is very much elongated, swollen perhaps three or four times its normal size, and often curved toward the diseased tonsil, with which it is in contact, as shown in Fig. 82. Where the pus burrows downward a swelling can be seen below and behind the tonsil, projecting into the lumen of the oropharynx. It is frequently difficult to depress the tongue sufficiently to enable one to see the lower limit of the swelling. The finger should always be introduced into the mouth to detect, if possible, the point of greatest softening or fluctuation. It is often difficult to say in any given case whether pus be present or not. The connective tissue in these regions is of such loose texture that swelling and edema may give one the sensation of fluid before pus has formed.

Differential Diagnosis. Peritonsillar abscess has been mistaken for malignant disease of the tonsil. The latter disease is characterized by a slower onset, absence of fever, hard, firmer character of the growth, and absence of pus when an incision is made. Examination of a portion of excised tissue will, in doubtful cases, show the character of the growth.

Prognosis. The prognosis is usually good. A few cases have been recorded in which the abscess burst

during sleep, and pus entered the larynx and produced death by strangulation. Edema of the larynx may occur in that variety in which pus burrowing downward along the lateral wall of the pharynx is found.

Treatment. As soon as peritonsillar infiltration is discovered we deem it advisable to make an incision into the most prominent portion of the swelling, even though pus has not yet formed. The usual site, not only of greatest swelling, but that at which pus can be detected, is shown in the region of the heavy, vertical line (Fig. 82). To make this incision the small knife shown in the Grünwald set (Fig. 49), or an ordinary curved, sharp-pointed bistoury whose blade is wound with a thin layer of absorbent cotton, so as to leave bare only half an inch at the point, is to be employed. A 10 per cent. solution of cocaine sprayed over the soft palate may diminish slightly the pain from this operation. The mouth is to be opened as widely as possible, the tongue depressed, and the knife carried back to the soft palate. The incision should be made from above downward, beginning at a point a little above the junction of the uvula and soft palate and about three-eighths of an inch external to the inner margin of the anterior pillar of the fauces; the knife is to be plunged into the soft palate the full depth of the *exposed* surface of the blade and the incision carried downward in the direction and to the extent shown in the illustration. Care must be taken that the incision is nearly vertical—a transverse incision may wound the large bloodvessels of the neck, especially the ascending pharyngeal artery. Care must also be taken, in withdrawing the bistoury, that the tongue be not cut. If the peritonsillar swelling has existed for three days,

pus will usually follow the incision. Failure to get pus may result from not making the incision deep enough into the tissues. With the first prick of the knife the patient is apt to draw his head back : a mere scratch in the mucous membrane results. To prevent this the head should either rest against the back of a chair or be steadied by an assistant. When pus is found its odor is often very offensive. In these cases we advise syringing the abscess cavity with a solution of carbolic acid, 1 : 100. A small strip of iodoform gauze should be tucked into the abscess cavity, leaving an eighth of an inch projecting through the wound in the soft palate, to serve as drainage and to prevent the too rapid closure of the wound and re-accumulation of pus. This gauze should be removed at the end of twenty-four hours and the cavity again washed out. If more pus or swelling be found, it is usually advisable to drain for another twenty-four hours ; ordinarily this is not necessary. Should pus not be detected at the time of the incision, the hemorrhage resulting depletes the congested tissue, and the path of the incision serves as a place of least resistance through which the pus may escape in the course of the next day or two. We would like to caution against the making of incisions into the substance of the tonsil itself. These do no good, as the pus, it should be remembered, is not in the tonsil, but external to it. Where pus is found burrowing downward in the posterior pillar of the fauces an incision should be made there, at the point of greatest swelling, with a knife guarded as above described. Great care must be taken that the point of the knife does not extend too far laterally for fear of wounding the ascending pharyngeal artery. Cleansing sprays, as in

acute tonsillitis, are to be prescribed. Most patients find relief from the application of a hot poultice to the neck on the affected side; these should be renewed at least once an hour. A few derive more benefit from cold applications. During convalescence tonics should be administered.

When the patient has completely recovered from his attack he should be carefully examined for any diseased condition of the tonsil, and if found it should be treated as described in the article on Chronic Hypertrophic Tonsillitis. Thorough eradication of the tonsillar tissue often renders these painful attacks of peritonsillar abscess much less frequent, even doing away with them entirely.

CHRONIC HYPERTROPHIC TONSILLITIS.

A chronic inflammation of the tonsil characterized by increase in the size of the organ.

Etiology. The majority of cases cannot be attributed to any assignable cause. They occur more frequently between the second and thirtieth years. There are some persons in whom an increase in the lymphoid tissue throughout the entire upper respiratory tract is found. This condition has been designated the "lymphatic diathesis." The underlying factors producing such a diathesis are not understood. Some cases of chronic enlargement of the tonsil give a history of repeated attacks of acute tonsillitis, but many have a chronic enlargement without any history of such acute attacks. The disease has been noticed to follow the acute fevers in childhood, such as scarlet fever, measles, diphtheria, and whooping-cough. It is very

commonly associated with pharyngitis and disorders of nutrition. It frequently occurs in the children of those who have been subject to enlarged tonsils, and it is seen very frequently in several or all the children in a family. There seems to be a tendency of this lymphoid tissue to undergo partial, sometimes complete, atrophy after the thirtieth year.

Pathology. Microscopical examination of an enlarged tonsil shows it usually to be composed of the same sort of tissues—viz., lymphoid and connective—that exist in the normal tonsil. In some cases the amount of connective tissue and its character may be in the same proportion as that found in the normal organ. Where the tonsil has been enlarged for a long time the amount of connective tissue is usually increased and its consistency much firmer and more dense. We can thus microscopically and clinically divide enlarged tonsils into, first, those which are characterized by an increase in the parenchyma and connective tissue in about the normal proportion. These tonsils are red or bright pink in color, irregular in outline, soft to the touch, the crypts distended and partially filled with a cheesy material. The second variety is that in which the connective tissue is greatly increased and dense in character. These tonsils are pale, often rounded in appearance, and very firm and hard, almost cartilaginous when felt with the finger. As a result of successive attacks of acute tonsillitis, adhesions frequently take place between the tonsils and the anterior and posterior pillars of the fauces. The mouths of the lacunæ are sometimes obstructed, as the result of adhesions near the surface of the tonsils. The ducts then become distended with secretions, which, if they remain fluid,

leave a small cyst within the tonsil. The organic constituents of these cysts may be absorbed, leaving the salts deposited either as a gritty, granular mass, or sometimes in the form of a dense, hard calculus. The lymphoid follicles on the posterior pharyngeal wall, and the lateral band behind the posterior pillar of the fauces, are often hypertrophied. Adenoid hypertrophy in the nasopharynx is seen in the great majority of cases of enlarged tonsils occurring in children.

Symptoms. The symptoms of this disease are rarely those resulting from tonsillar hypertrophy alone, but are due to the combined symptoms of this and the associated adenoids. The more common symptoms are mouth-breathing, snoring at night, restless sleep, screaming or crying out in the sleep, a peculiar, expressionless face, with lips swollen and everted; aprosexia, inability to blow the nose, recurrent attacks of earache, with discharge of pus from the ears. The voice is usually thick, the person talking as if he had a mouthful of something in the buccal cavity. The children are seldom robust; the complexion is often sallow, and they are frequently pigeon-chested. Perhaps the symptom which is most frequently dependent upon the enlarged tonsils is that of an irritable, hacking cough. Disorders of digestion and loss of appetite are common. The breath is often foul, and these patients expectorate, every few days, little, roundish, yellowish pearls of cheesy material, which smell not unlike Limburger cheese. These protrude frequently from the tonsil before breaking off, and are a source of great irritation in the pharynx, and attempts are made by patients to rid themselves of these by constantly clearing the throat. Persons with hypertrophied ton-

sils are undoubtedly more susceptible to the factors that excite attacks of acute tonsillitis and peritonsillar abscess than those whose tonsils are not enlarged. It is usually considered that hypertrophied tonsils in an individual predispose him to the action of germs of the acute infective fevers, especially diphtheria.

Examination. Examination of the throat usually shows both tonsils enlarged, although one may be so to a greater extent than the other. The tonsils are apt to be irregular and ragged in their outlines; the lacunæ are plainly visible, their mouths frequently distended with secretion. The size of the enlarged tonsils varies from that of a hickory-nut to an English walnut. Unless adhesions exist between the tonsils and the pillars of the fauces the enlarged tonsils can be seen projecting markedly beyond the pillars. Where adhesions exist the pillars of the fauces tend to draw the tonsils outward, so that at first glance the tonsils may not seem to be increased much, if at all, in size. If the tongue depressor happens to be inserted a little too far into the mouth, so as to produce gagging, then the tonsils can be seen to meet in the median line, and their enlargement is better appreciated. Granulations (spoken of in the pathology) are usually found on the posterior pharyngeal wall. *One should never consider the examination complete in a patient who has enlarged tonsils unless at the same time careful examination of the nasopharynx for adenoid hypertrophy be made with the mirror or with the finger, or both.*

Differential Diagnosis. There is usually very little likelihood of mistaking hypertrophy of the tonsils for any other condition. In adults it may be mistaken for malignant disease of the tonsils. In the latter a progres-

sive enlargement, usually of one tonsil, is found, accompanied by pain in the throat and radiating to the ear. In malignant disease the tonsils are much firmer to the touch than ordinary hypertrophied tonsils. There is a tendency to ulceration and hemorrhage, and the disease shows a marked tendency to infiltrate the pillars of the fauces, extending below to the tongue and posterior pharyngeal wall and upward into the soft palate. The cervical lymphatic glands are enlarged and very hard. Where any doubt exists as to the character of an enlarged tonsil a piece should be excised, thin sections prepared, and microscopical examination made.

Prognosis. The danger in removing tonsils in children is very slight. Occasionally one meets with a patient in whom bleeding is more severe than usual, but it seldom causes great anxiety. A few cases of hemorrhage following excision of the tonsils have been reported, but when compared with the vast number of tonsils that have been removed the percentage of deaths from this cause must be very low. It is not safe, of course, to excise the tonsils of children belonging to a family of bleeders (hemophilia). In adults in whom the tonsil is very hard hemorrhage is often profuse. Singers and public speakers often hesitate to have the tonsils removed for fear of impairing their voices. We have never seen anything but improvement in the voice—clearer tones both in singing and speaking—as a result of excising enlarged tonsils. Parents frequently object to having their children's enlarged tonsils removed, on the ground that they had theirs removed when young and that no benefit was derived. Our reply is that they probably had adenoids as well as enlarged tonsils, and at that time the operation for the removal of adenoids

was not thought of, and hence the failure to get relief. Another cause of repeated attacks of tonsillitis after removal lies in the fact that in many cases amputation left behind a diseased stump. Enucleation of the entire gland by careful dissection is the only remedy in such cases. Rapidly recurring enlargements of the tonsils should always make one suspect malignant disease of the tonsils.

Treatment. The treatment of enlarged tonsils consists in removing as much of the tonsillar tissue as is possible. This may be accomplished in several ways: first, by the tonsillotome; second, by the galvano-cautery snare; third, by cauterization with the galvano-cautery electrode; fourth, by enucleation. The indications for the employment of these different methods may be stated as follows:

1. The tonsillotome may be employed in all cases of hypertrophied tonsils in children where there are no adhesions to the pillars or a history of hemophilia. In the latter case it is better to let the tonsils alone, trusting to atrophy later in life. If the symptoms *absolutely* demand their excision, then the galvano-cautery snare or galvano-cautery electrode should be employed.

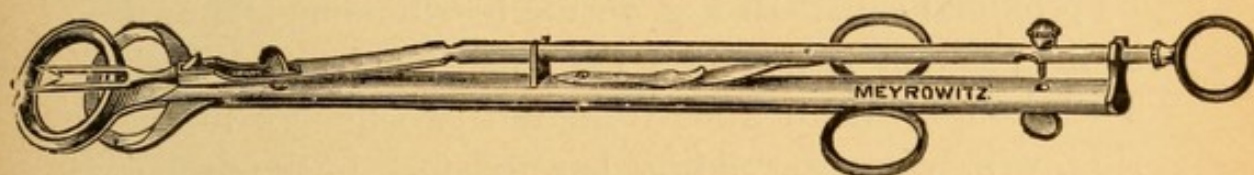
2. In adults in whom the tonsil is soft and non-adherent to the pillars, without too great an increase in the connective tissue, the tonsillotome should also be employed. Where, however, the tonsil is the pale, hard, fibrous variety, one can save himself considerable annoyance from hemorrhage by employing the snare.

3. A slight form of tonsillar hypertrophy is observed in adults in which the special symptom is distention of the lacunæ, with the cheesy masses, foul breath, pharyngeal irritation, and frequent attacks of acute tonsillitis

or peritonsillar abscess, for which the galvano-cautery electrode is to be employed.

When one has decided to use the tonsillotome the next point to be considered is the question of the anesthetic to be employed. In children under ten years of age in whom adenoid hypertrophy is so frequently found associated with hypertrophied tonsils, the administration of a general anesthetic—ether—is to be advised. Both operations are to be done after full anesthetization; the tonsils first being removed, the adenoids immediately afterward. In older children, unless they are exceedingly nervous, and unless adenoids coexist, a 10 per cent. solution of cocaine applied to the tonsils on a cotton-

FIG. 83.



Mathieu tonsillotome.

wound applicator deadens the pain sufficiently to allow excision. Nervous children will have to be given ether. Where the galvano-cautery snare or electrode is employed cocaine anesthesia suffices. The patient should always be anesthetized in the recumbent position when ether is employed, a mouth-gag inserted, and the Mathieu tonsillotome (Fig. 83), previously sterilized, placed in warm Thiersch or carbolic acid (1 : 100) solution. The Mathieu tonsillotome is made in a number of sizes, and one who expects to excise properly many tonsils should provide himself with at least three sizes—a small, a medium, and a large one. The suitable-sized tonsillotome should be selected. The proper size is one that will just slip over the enlarged tonsil. If the

ring of the instrument be too small, the tonsil cannot be crowded through the rings, and only a small part will be excised. If too large a tonsillotome is employed, the blades press upon the anterior and posterior pillars of the fauces and push these and the tonsil laterally, so that very little of the tonsil projects into the blade and is cut off. The tonsil is also apt to wobble around and be only partly excised if too large a tonsillotome is used. Any adhesions between the pillars of the fauces and the tonsils should be broken up. The Asch elevator serves well for this purpose. The forefinger and middle finger of the right hand should now be inserted into the two rings on the shank of the tonsillotome, and the thumb into the ring at its proximal end. In Fig. 83 the tonsillotome is shown in the position it has after the tonsil has been excised. The thumb, drawn away from the two fingers in the ring, will bring the sliding bar and fork in the proper position for beginning the operation. The spear-points must always be directed toward the *median* line. The swivel on the thumb ring enables one to turn the instrument so as to accomplish this. The tonsillotome should now be introduced into the mouth and the ring pressed over the tonsil, being careful to hold the rings so that they lie in an antero-posterior vertical plane. If allowed to be rotated so that the upper end is more external than the lower, or *vice versa*, the tonsil will be cut off obliquely and only partially excised. When the tonsil is found to protrude well through the ring the sliding bar should be pushed sharply away from the operator. The fork will then spear the tonsil, drag it still further through the ring of the tonsillotome, and the knife cutting-blade excise the protruding portion. Quickly remove

the tonsillotome, make a half-turn on the swivel, so as to bring the spear-points in the proper position, reinsert in the mouth, and proceed as above with the other tonsil. If the tonsils be unequally enlarged, different-sized instruments may have to be employed in removing them. The larger, more round a tonsil is the easier its removal, as a general thing. We therefore advise the removal of the harder tonsil first, as time can be taken to insert the ring over this. A hemorrhage from the first excised tonsil usually partially obscures the field of operation, which is the reason for leaving the easier tonsil to be operated on last. The hemorrhage in children seldom amounts to more than two or three ounces, and ceases within three or four moments after the operation. Some blood is usually swallowed, and may be vomited subsequently. Where hemorrhage is excessive a syrupy solution of tannic acid and water applied on a cotton-wound applicator quickly controls it. Ten grains of powdered suprarenal gland applied to the bleeding surface by means of a powder blower have frequently been used with satisfactory results to control the capillary hemorrhage. The local treatment following excision of the tonsils is the same as that given for acute tonsillitis (*q. v.*). When the patient is visited the next day the excised surface will be found to have upon it a dark grayish membrane. This usually disappears before the end of a week. The diet should be fluid. We have found ice-cream to be very grateful to these children, the cold benumbing the pharynx, so as to make deglutition less painful.

In removing an enlarged tonsil with the galvano-cautery snare the wire and ring shown in Fig. 84 are to

be used in the Schech cautery handle (Fig. 22), the ends of the wire being clamped by the two screws on the upper, sliding ring. The wire loop is to be fastened to the ring by a piece of cotton thread, as shown in the diagram. The object of this is to keep the loop in contact with the ring and to facilitate its proper adjustment over the tonsil. The wire, however, is to be pushed through, so as to make the size of the loop the same as that of the ring, and not smaller, as shown in the diagram. The ring and loop are now to be adjusted over the projecting tonsil, any adhesions between which and the pillars of the fauces having

FIG. 84.



Knight's tonsil galvano-cautery snare.

been broken up, as above described. The current of electricity is now to be turned on and gentle traction made upon the handle of the cautery snare, so as to diminish the size of the loop as the tonsil is cut through. Three or four minutes elapse usually before the wire burns its way through the enlarged tonsil. If too much current is turned on, so that the wire is at a white heat, the danger of hemorrhage is as great from this source as when the tonsillotome is employed.

In adults with a slight amount of tonsillar hypertrophy, or in whom the crypts are continually filled with the cheesy material, or in whom we find frequent attacks of acute tonsillitis, the employment of a galvano-cautery electrode (Fig. 85) is an admirable pro-

cedure for reducing these slight hypertrophies, obliterating the lacunæ, and thereby preventing the formation of secretion and tendency to acute tonsillitis. A tonsil having been cocainized with a 10 per cent. solution of cocaine, the electrode is heated to a red heat and pushed into the tonsillar substance one-half or two-thirds the depth of the bent

FIG. 85.



Galvano-cautery electrode.

portion of the electrode. Four or five such insertions are to be made in each tonsil at one sitting. When healing has taken place, usually in about eight or ten days a second application should be similarly made.

FIG. 86.



Douglas' tonsil knife.

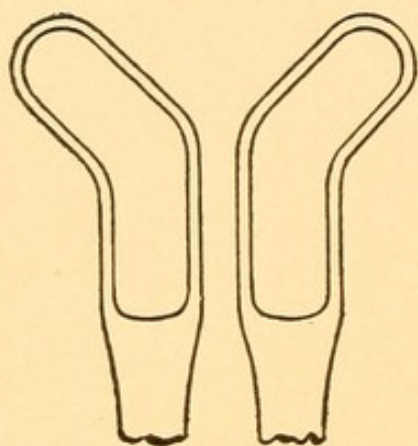
This may have to be repeated as many as half a dozen or more times before all of the hypertrophied tonsil is removed.

In place of the galvano-cautery knife being employed in this class of cases, the Douglas tonsil knife (Fig. 86) may be introduced deeply into each lacuna and then

withdrawn, cutting up or down so as to enlarge greatly the outlet of the lacunæ and thus favor drainage and the escape of the hitherto pent-up and decomposing secretions.

When it is desired to remove small portions of tonsil tissue that cannot be included

FIG. 87.



Myles' angular punch-forceps.

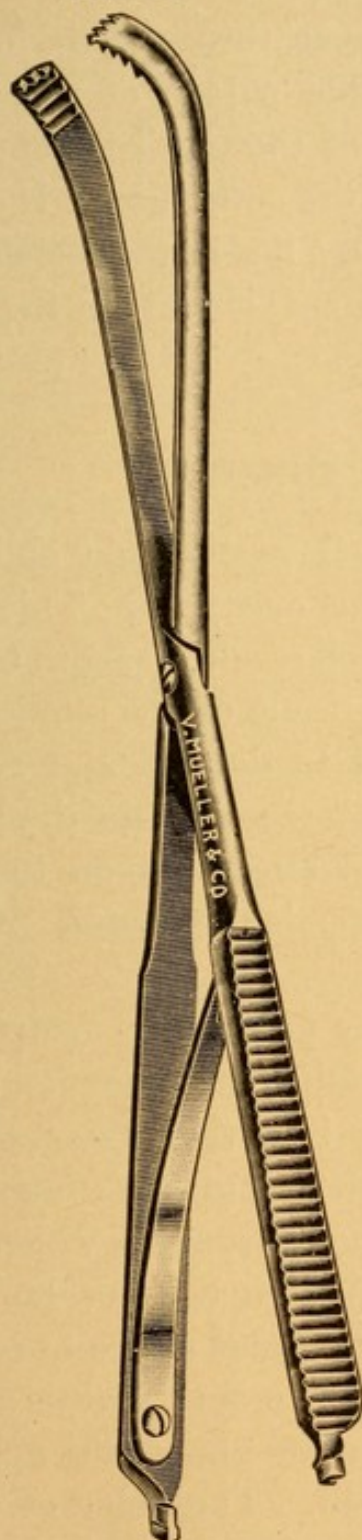
in a tonsillotome the Myles angular punch-forceps will be found very efficient. They are shown in Fig. 87, full size, right and left. If 1 drop of a 1 to 1000 solution of adrenalin is added to 10 minims of a one-fourth of 1 per cent. solution of cocaine and a few drops of this mixture injected into the tonsil with a hypodermic syringe

it will be found to make the operation nearly painless and bloodless.

When properly performed the most satisfactory method of removing diseased tonsils is that of enucleation or tonsillectomy. For adults, cocaine anæsthesia, produced by injecting a 1 per cent. solution into the pillars and substance of the organ, greatly diminishing the pain, suffices, but for children a general anæsthetic is necessary. The tonsil is grasped near its centre with a good forceps having a catch. That of Richards (Figs. 88 and 89) answers very well.

Traction is made on the forceps so as to draw the tonsil toward the median line. The adhesions of the tonsil to the pillars anteriorly, posteriorly, and superiorly may then be distinctly seen. These adhesions

FIG. 88.



Richards' tonsil forceps, open.

FIG. 89.



Richards' tonsil forceps, closed.

are next severed with a pair of long-handled, curved scissors or knife, at the option of the operator. The

forefinger passed above the tonsil into the supratonsillar fossa readily shells out the upper three-fourths of the gland from its bed. By passing a loop of wire in a strong snare over the handle of the tonsil-forceps and around the base of the tonsil, the entire gland is easily removed. The greatest difficulty lies in the oozing that occurs after the adhesions are cut, obscuring the field for properly adjusting the snare.

CYSTS OF THE TONSIL.

Etiology. Cysts of the tonsil result from obliteration of the mouths of the lacunæ or crypts. This may be brought about either as the result of acute tonsillitis or very frequently as the result of the application of caustics or cauterants used to destroy and reduce the tonsillar hypertrophy. The secretion in the lower portion of the crypt cannot find an exit upon the free surface of the tonsil, and it distends the lacunæ. Cysts may be single or multiple.

Symptoms. When small they produce no symptoms, and are usually only accidentally discovered. They may be quite large, projecting into the cavity of the mouth, resting against the surface of the tongue or touching the posterior wall of the pharynx, in which case there will be a sensation of a foreign body or lump in the throat, with possible irritation and desire to cough.

Examination. Inspection of the mouth reveals a portion of the tonsillar surface having almost the appearance as if it had been blistered. The color of these blebs is usually gray or slightly yellow.

Treatment. The surface of the cyst should be anesthetized with a 10 per cent. solution of cocaine, and a

knife plunged into the cyst so as to open it very freely. The contents, which are usually thin, readily flow out; but if thick, cheesy in character, some of it may remain and have to be forced out with the blade of a tongue depressor. If left in this condition, cicatrization is very apt to take place in the wall of the cyst, and the fluid re-accumulates in a few days or weeks. The galvano-cautery should, therefore, be employed to sear thoroughly the entire inner surface of the cyst. Adhesive inflammation results, and the cyst will be obliterated. The tonsil is often considerably hypertrophied, and, if so, it should be excised. /

CALCULUS OF THE TONSIL (Tonsillith).

Etiology. Where there is slight narrowing of the mouths of the lacunæ the secretion in the crypts may be retained and the organic matter partially absorbed, leaving a deposit in the form of small, sand-like concretions. These are frequently seen in hypertrophied tonsils that have been excised. It often happens that there is a continual addition to these particles, so that a well-defined stone or calculus develops. These are composed principally of phosphate and carbonate of calcium, with a greater or less amount of organic material. The *leptothrix buccalis* is frequently found in these concretions, and it has been supposed by some to be the exciting cause. This we doubt, because the *leptothrix buccalis* is very commonly found in the throats of healthy persons, and very frequently in the secretions found in the crypts of tonsils in which no calculi or gritty deposits are found.

Symptoms. Small gritty-like masses usually give rise to no symptoms. They probably act as one source of irritation, which may be a factor in the production of the hypertrophy of the tonsil in which they are found. Calculi the size of a pea, which had given rise to no symptoms, have been discovered accidentally. When very large they frequently produce ulceration in the surrounding tissue of the tonsil, giving rise to pain localized in the tonsil. The pain is more marked during deglutition. A purulent discharge and foul odor of the breath have been observed.

Examination. Examination frequently shows a bulging of the tonsil, which, when felt by the finger or touched with a probe, elicits the stony hardness of a calculus.

Treatment. Under cocainization an incision should be made into the tonsillar substance down to the calculus, which can readily be extracted with a pair of forceps. The cavity should be syringed out with an antiseptic solution (carbolic acid, 1 : 100) for a few days, until healing takes place.

LINGUAL VARIX.

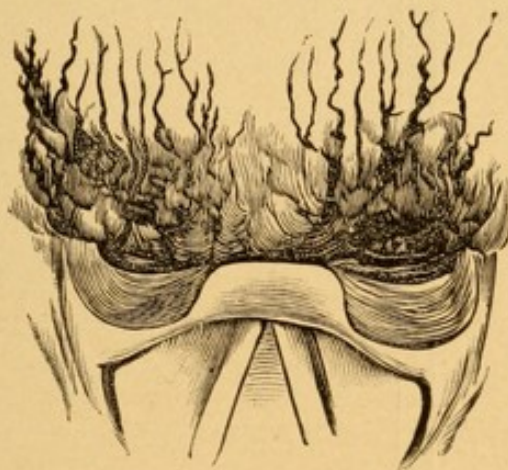
A dilated, varicose condition of the veins at the base of the tongue, in the region behind the circumvallate papillæ.

Etiology. This condition is often found in those in whom there is an obstruction to the return circulation of the blood, due to valvular lesions in the heart. It is very commonly one of the manifestations of chronic alcoholism, and is associated with congestion

and cirrhosis of the liver, so frequently found in those who are intemperate in the use of alcohol. It is seen in those who are subject to chronic rheumatism and gout. It occurs also in women at about the period of the menopause.

Symptoms. The symptoms complained of in this condition are a sense of fulness or of a lump in the throat, which patients continually try, but ineffectually, to get

FIG. 90.



Lingual varix.

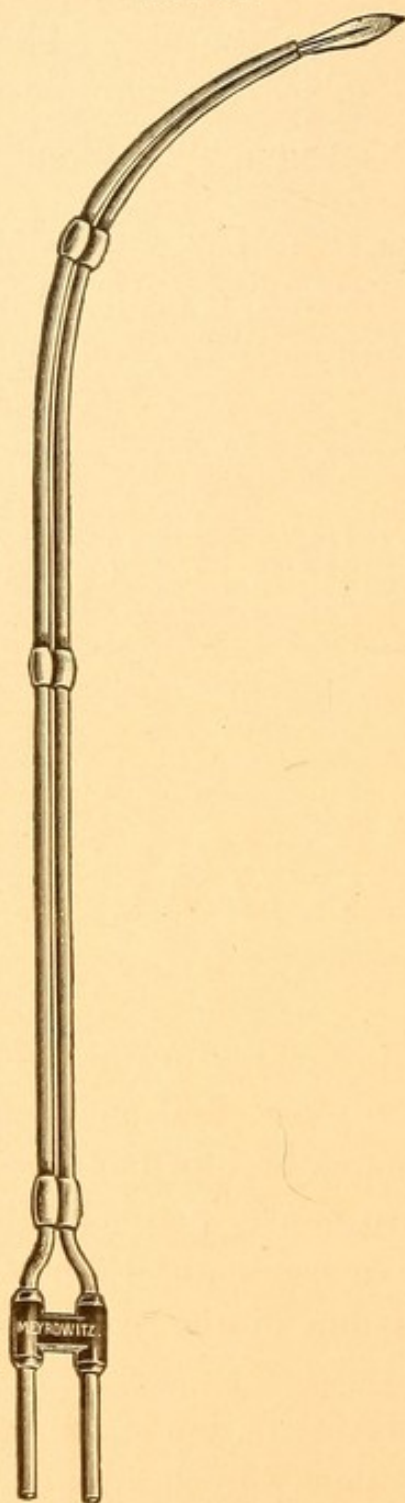
rid of by swallowing or try to raise by coughing. The veins frequently rupture, and the individual expectorates a slight amount of blood or blood-stained mucus. Patients are apt to consider this an indication of consumption, having a cough, and knowing, as they do, that hemorrhage is one of the symptoms of pulmonary tuberculosis.

Examination. Examination of the base of the tongue shows plainly the dark bluish, dilated, distended veins (Fig. 90). They run anteroposteriorly at the base of the tongue, spreading out, fan-shaped, from the epiglottis.

Treatment. These veins are best obliterated with the

Gabano-Cantley

FIG. 91.



Curved electrode for the base of the tongue.

galvano-cautery. The surface of the tongue in this region should be thoroughly cocainized by *two* applica-

tions of a 10 per cent. solution of cocaine, at intervals of five minutes. At the end of ten minutes the electrode (Fig. 91), heated to a red heat, should be applied transversely to the direction in which these veins run. It is better not to cauterize more than two or three veins at one sitting. If the galvano-cautery be employed at a white heat, severe hemorrhage will result.

HYPERTROPHY OF THE LINGUAL TONSIL.

An increase in the amount of the lymphoid tissue found at the root of the tongue behind the circumvallate papillæ, just in front of the epiglottis.

Etiology. Very little is known of the etiology of this disease other than that it occurs more frequently in adults than in children. In this respect it differs very markedly from the lymphoid tissue found in other regions of the upper respiratory tract, where tendency to hypertrophy is so much more marked in childhood. It is about three times as common in females as in males. It is frequently associated with a varicose condition of the veins at the base of the tongue. Hypernutrition resulting from these enlarged veins may be an etiological factor in the production of the hypertrophy, or the lymphoid hypertrophy, by interfering with the return circulation, may produce the varix.

Pathology. Microscopically the tissue is almost identical with that found in the tonsils and adenoids, but the amount of connective tissue intermingled with the lymphoid tissue is usually far greater than that found in hypertrophied tonsils or adenoids.

Symptoms. The symptoms complained of are a sense of fulness in the throat, often of a lump in the throat,

tinual cough and partly to the congestion of the mucous membrane about the entrance to the larynx in the ary-epiglottic region.

Examination. Examination with the laryngeal mirror will show a large lobulated, mulberry-like mass, situated on either side of the median glosso-epiglottic ligament, at the base of the tongue (see Fig. 92). The growth sometimes is so large that these two masses meet in the median line and appear as one large mass covering this entire region. The tip of the epiglottis is often invisible, being buried in the lobulations of the lymphoid tissue. One can readily ascertain that the hypertrophy of tissue in this region is the cause of the irritable cough and other symptoms of which the patient complains when these nodules are touched with the point of a laryngeal probe. They often exclaim, "That is the spot where the trouble is."

Prognosis. These cases may be very much relieved or cured for the time being, but the lymphoid hypertrophy frequently returns, and with it the symptoms.

Treatment. Thorough cocainization of this region should be made as described under lingual varix, and with a similarly curved galvano-cautery electrode (Fig. 91) the growth should be cauterized. It is impossible to reduce much of the swelling in this way at one sitting. When healing has taken place following the first cauterization (usually a week or ten days) a second application is to be made. From six to ten cauterizations at similar periods are often required before the growth is reduced to such an extent that symptoms are no longer present.

These growths may sometimes be removed by the cold wire snare, using a canula that is curved in the

same way that the electrode is. The amount of connective tissue here, however, is so great that if a very large piece of the growth is included in the snare it may be impossible to cut through the mass, or the wire will break before it cuts through the tissue.

The after-treatment in either case consists in spraying the throat with

R.—Menthol gr. xv.
 Eucalyptol ℥ss.
 Benzoinol q. s. ad. ℥ij.

M. et Sig.—Use in oil atomizer and inhale while spraying into the mouth.

The cauterization or snaring often causes considerable pain during deglutition for the first two or three days. The above prescription usually diminishes the pain. While a 2 per cent. solution of cocaine will relieve it, one should be very careful to prescribe it only in the most urgent cases.

DIPHTHERIA.

An acute constitutional disease, of an infectious and contagious nature, produced by the Klebs-Loeffler bacillus, and characterized locally by the presence of a fibrinous exudate upon the mucous membrane of the pharynx, and less frequently upon that of the nose, larynx, conjunctivæ, or any mucous surface of or wound on the body.

Etiology. This may be conveniently divided into the predisposing and the exciting causes. In the former class the age of the patient is a very important factor. Diphtheria occurs most frequently between the second and the fifteenth years. It may occur before the second year, or even in adults. The period from the

second to the fifth year is that in which the largest number of cases is found. The disease is more common in cities than in country districts. The overcrowded portions of a city devoted to the tenement-house population, and where the sewage, drainage, and sanitary conditions are poor, are the situations in which the germ finds a continual lurking-place.

While the disease often attacks those who are apparently in perfect health at the time of the onset, a weak or feeble condition, such as that brought about by any of the acute infectious diseases, makes these persons more susceptible than the healthy.

Any diseased condition of the mucous membrane of the mouth, and especially the presence of an enlarged or diseased tonsil, affords a better place for entrance of the Klebs-Loeffler bacilli than where the mucous membrane is healthy. The disease occurs more frequently between the months of October and March than at any other time of the year. Nurses, physicians, and those who care for patients suffering from diphtheria are exceedingly liable to contract the disease. Very few physicians or nurses who spend any length of time in their official capacity at a contagious hospital in which diphtheria is treated fail at some time to contract the disease. The condition of the throat produced by scarlet fever seems to leave the patient very susceptible to the diphtheria bacilli, and diphtheria more frequently complicates this exanthem than any of the others.

The exciting cause of diphtheria is the Klebs-Loeffler bacillus. This germ is exceedingly tenacious of life, existing outside of the body many weeks and even months. It is often impossible, therefore, to trace the source of infection. In many cases the source can be determined as due to direct contagion, as in the

act of a mother kissing a child ill with this disease. During the examination of a patient coughing may project particles of membrane or infected saliva into the face of the physician or attendant, and the disease be thus produced. The usual method of infection is, perhaps, that in which infected articles of clothing, bedding, dishes, and so on, which have been in contact with a diphtheritic patient, have been put away unclean—that is, improperly disinfected—and those who handle these subsequently become infected. The germs also remain in the mouth, and frequently in the nose, of patients long after they have made a complete recovery. The expectoration of these persons has been found to contain virulent germs, which may be scattered broadcast, and thus be likely to infect any susceptible person. It is also common to find Klebs-Loeffler bacilli in the mouth and expectorated secretions of those who have been in attendance upon a patient suffering from diphtheria. Owing to some peculiar resistance that such a person has to the diphtheria bacillus, resulting in immunity from the disease for that person, he does not suffer from the disease, but may convey it to others. The Klebs-Loeffler bacilli have been found in milk, and this may be one source of infection in children, with whom milk plays so important a part as an article of diet. Infection has in some instances been traced to domestic animals (cats and dogs) that have been the playmates of children during the stage of recovery.

It seems more probable that the germ enters the system through the mouth and through articles that infect the food than through the dust and inspired air. The period of incubation varies according to the mode of contagion or infection. Where particles of membrane

have been coughed into the mouth of the physician or nurse the period of incubation has been as short as twenty-four hours. The usual period of incubation is three to four days; incubation, may, however, be as long as one week. If, therefore, a person exposed to infection from diphtheria does not manifest any symptoms within a week following the last exposure to infection, there is little probability of an attack of diphtheria from that source.

Pathology. The pathological processes found in diphtheria are both local and general. It is a question which of these two processes is the primary. We believe it is generally conceded at the present time that the bacilli find a suitable nidus on some mucous membrane or on a wound in which they develop, and that the toxins produced in the life-history of the bacillus are absorbed into the circulation, giving rise to the constitutional symptoms of the disease and producing pathological changes in distant tissues and organs of the body. It is not common to find the Klebs-Loeffler bacilli circulating in the blood or in any other tissue or organ of the body than that in which the local membrane formation is found.

Locally, the Klebs-Loeffler bacilli produce, first, a hyperemia of the bloodvessels supplying the mucous membrane and the submucous tissues. Next, a round-cell infiltration and transudation of lymph occur in this area. The lymph coagulates, and this, together with the toxins developed by the bacilli, produces a coagulation necrosis of the cells in the epithelial layer of the mucous membrane, giving rise to the diphtheritic exudate or membrane. This necrosis gradually extends to the submucous tissue and the round-cell infiltration existing in this region. In mild cases the amount of

infiltration and coagulation necrosis in the submucous tissue is not very great, while in severe cases it may extend from the submucous into the underlying tissues. When the lymph, which was early transuded from the bloodvessels, coagulates, it forms fibrin, which binds all the tissues into a firm mass. It is because of the presence of this fibrin that it is so difficult to remove a diphtheritic exudate, the filaments of the fibrin extending into and binding the exudate firmly to the underlying tissues. The exudate, depending on its thickness, is more or less elevated above the surrounding mucous membrane. The color of the exudate is usually a dirty gray; but where the process extends so deeply into the underlying tissues as to cut off the blood-supply in the larger-sized bloodvessels the exudation may become gangrenous, and the color be dark green or even black. In from four to six days a line of demarcation forms between the exudate and the underlying tissues, the fibrin becomes broken up or granular, the epithelial cells disintegrate, and the membrane either gradually melts away or the edges of it become loosened and curled up on themselves, this process gradually spreading underneath the entire exudate, which may be cast off as a large mass. In the latter case an ulcer, more or less deep, is left, according to the original involvement of the tissues underlying the mucous membrane.

The most common places in which a diphtheritic exudate is found are the free surfaces of the tonsils, the anterior and posterior pillars of the fauces, posterior pharyngeal wall, the nasopharynx, and the nose, where it is found upon the mucous membrane of the septum and turbinates. In severe cases, in which the nasal mucous membrane is infected, the conjunctivæ may

become involved from the passage of the germs to them through the nasal ducts. When the larynx is involved the under surface of the epiglottis, the ary-epiglottic folds, the ventricular bands, and the vocal cords are the seats of the membrane. The membrane may also be found in the trachea and bronchi.

The general pathological processes consist in, first, an adenitis of the cervical lymphatic glands. The heart is usually the seat of myocarditis. There is rarely an endocarditis. The kidneys show the changes found in acute parenchymatous nephritis.

Where death has resulted from diphtheria the commonest lesion found is that of a bronchopneumonia, usually due to the presence of streptococci.

Symptoms. The symptoms of diphtheria are both constitutional and local.

The constitutional symptoms are the result of absorption of the toxins and the effects that these have in the perversion of the functions of the various organs.

The local symptoms are those which are due, first, to the inflammation of the various parts of the upper respiratory tract in which the exudate is found, and, secondly, in some of these regions, as in the nose and in the larynx, to the mechanical obstruction produced by the exudate.

PHARYNGEAL TYPE. In a case of diphtheria of ordinary severity the child for a day is listless, has loss of appetite, and often vomits whatever food it eats. At the end of this time sore throat will usually be complained of. The child's temperature will now vary from 101° to 103° F.; its pulse will be accelerated, ranging from 100 to 120; the urine is scanty and high colored; slight albuminuria is very common. Epis-

taxis at this stage frequently occurs, even where there is no exudation upon the nasal mucous membrane. The glands at an angle of the jaw are usually slightly enlarged. When the child is old enough, headache and pain in the back and limbs may be complained of. The face may sometimes be flushed, and a rash, similar to that of scarlet fever, at other times somewhat resembling that of measles, is occasionally seen on the body. These symptoms occurring in a child generally suffice to call the physician's attention to the throat, and an examination of it is made.

In the severe form the child is suddenly prostrated. The temperature is usually about the same as that in the milder form, but the pulse is more rapid, from 140 to 160 or more. The skin has a dusky, dingy hue; the child may pass into a semi-comatose condition, from which it is aroused with great difficulty; there is a foul odor to the breath, which is recognized almost immediately on entering the room. The urine is scanty or may be entirely suppressed. Death usually takes place in from two to four days.

Examination. If seen early, an examination of the throat reveals a thin, grayish membrane situated upon the tonsil, uvula, soft palate, or posterior pharyngeal wall. At first the membrane on the tonsil may be in spots, resembling somewhat the appearance of lacunar tonsillitis; but later the membrane spreads, covering nearly, if not quite, all the free surface of the tonsil, and extends to the pillars of the fauces. The exudate is elevated above the surrounding mucous membrane, and is bordered by a narrow zone of deeply congested mucous membrane, the color of which is a dark maroon or purple. (See Plate VI., Fig. 2.) If attempts are

made to remove this membrane with a cotton-wound applicator, it will be found impossible to do so without very vigorous rubbing. The membrane can be torn away with a pair of forceps, leaving a bleeding surface; but this should never be done. If removed, the membrane re-forms within a few hours. In severe cases the margins of the membrane are blackish and have a gangrenous appearance. As examinations are made from day to day the membrane at the end of from the fourth to the tenth day can be seen either gradually to melt away, or, as more frequently happens, the edges become loosened and curled up toward the end; the gagging produced by the examination frequently results in casting off this curled-up membrane. No examination should be considered complete in doubtful cases of diphtheria unless a culture be made from the secretions of the throat and this examined bacteriologically.

NASAL TYPE. The constitutional symptoms in the nasal type are practically the same as those of the pharyngeal type, for it is uncommon to have nasal diphtheria without pharyngeal implication at the same time. The symptoms peculiar to the nose are recurrent attacks of severe epistaxis and a discharge of mucus that is blood-tinged and excoriates the nostrils and lip over which it flows. Mouth-breathing, stertor, and a very offensive odor to the breath are observed. The temperature in the nasal type is usually somewhat higher—may be 105° F.—than that found in the simple pharyngeal type. The glands of the neck are enormously enlarged on one or both sides, according to whether the membrane is unilateral or bilateral. Earache and abscess of the middle ear very often accompany nasal diphtheria.

Examination. On examining the nasal cavity it

will be found completely occluded with a thick, grayish membrane situated upon the inferior turbinate and septum. Bacteriological examination of the secretion will show the presence of Klebs-Loeffler bacilli. It is not unusual to find, as recovery is taking place, a complete cast of the nasal cavity blown out during an attack of sneezing. These casts may be an inch or more in length, nearly half an inch in thickness, and three-quarters of an inch wide. They frequently leave an ulcerated surface in the nose which will be two or three weeks in healing.

LARYNGEAL TYPE. Laryngeal diphtheria is usually secondary to the pharyngeal type. It sometimes accompanies a nasal diphtheria in which there may be no involvement of the pharynx. The membrane has been found in the larynx without evidence of any portion of the respiratory tract above the larynx having been infected. One of the first symptoms noticed in the laryngeal type is a cough. A reflex cough is not uncommonly found in the pharyngeal type. The cough in such cases is clear, distinct, and hacking in character. The moment a dry cough, accompanied by hoarseness of the voice, makes its appearance, one should be suspicious that the larynx is being involved and an exudation forming. In these cases the cough gradually becomes tighter and tighter, until finally it assumes that peculiar type known as the "croupy" cough. At first this may disappear or be less marked during the day, only to return with greater intensity the next night. Dyspnea at this time becomes a prominent symptom, and unless relieved or the membrane formation is but slight, cyanosis soon develops. Now the patient is aphonic. The sterno-cleido-mastoids will stand out as distinct cords. A sinking in above

and below the clavicles will be noticed during inspiration. The child becomes exceedingly restless, frequently clutching with its fingers at its mouth and larynx, as if trying to rid itself of the obstruction that exists. Convulsions and spasms are common, the child gradually sinks into a coma, becomes cyanotic, pulse exceedingly rapid, respiration finally gasping, and the child dies. It occasionally happens that in one of the convulsions a membranous cast of the larynx may be expelled, the child's color clear up, and recovery take place.

Examination. The examination of the larynx in a child suffering from laryngeal diphtheria can seldom be made with any degree of satisfaction to the physician. It is usual, however, to find the evidences of diphtheria in the pharynx or the nose. While the bacteriological examination may be important to confirm the diagnosis, the urgency of the case is such that treatment should not be delayed until the diagnosis shall have been confirmed bacteriologically.

Sequelæ. The common sequelæ of diphtheria are the diphtheritic paralyses, otitis media, acute nephritis, and suppuration of the glands in the neck.

The diphtheritic paralyses usually appear during the period of convalescence. They may occasionally be noticed before the disappearance of the membrane, in which case the prognosis, so far as concerns the recovery of the child from the original disease—diphtheria—is bad. The paralysis usually first affects the soft palate. It may be noticed that in taking liquids some regurgitates and comes from the nose during the act of swallowing. The voice also becomes changed, and has a peculiar nasal twang. The muscles of deglutition may next be

involved. This interferes greatly with the patients' ability to swallow food, and during such time they may have to be fed through a stomach tube. The muscles of the upper extremity are sometimes involved, as are also those of the lower extremity, to such an extent that the patient walks only with difficulty, dragging the paralyzed limb. These paralyses last a varying length of time—from a few weeks to six months or more—but are usually entirely recovered from. They are supposed to be due to the effects of the toxins upon the nerve centres.

Otitis media is very frequently seen during the convalescence from diphtheria, and the Klebs-Loeffler bacilli are sometimes found, associated with streptococci, in the purulent discharge.

Acute nephritis is an occasional sequela of diphtheria, also coming on during convalescence or within the first few weeks thereafter.

Suppuration of the glands of the neck is seen in the severe forms of pharyngeal diphtheria, but more commonly where the nose and nasopharynx are infected. It is found more often in children who were very much run down in health and debilitated before the onset of the diphtheria. The complication is usually unfavorable, as septicemia and death frequently result.

Differential Diagnosis. The diseases most likely to be confounded with diphtheria are acute tonsillitis, streptococcus sore throat, mucous patches of secondary syphilis, and mycosis of the pharynx.

The differential diagnosis between acute tonsillitis and diphtheria has been given in the article on the former disease.

A streptococcus infection of the tonsil and pharynx




PLATE VI

FIG. 1

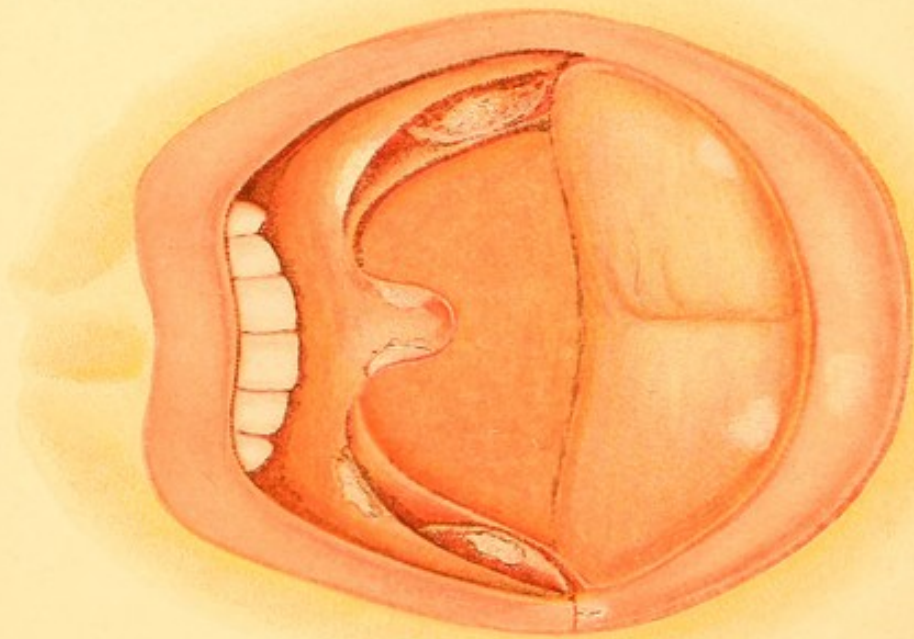


FIG. 2

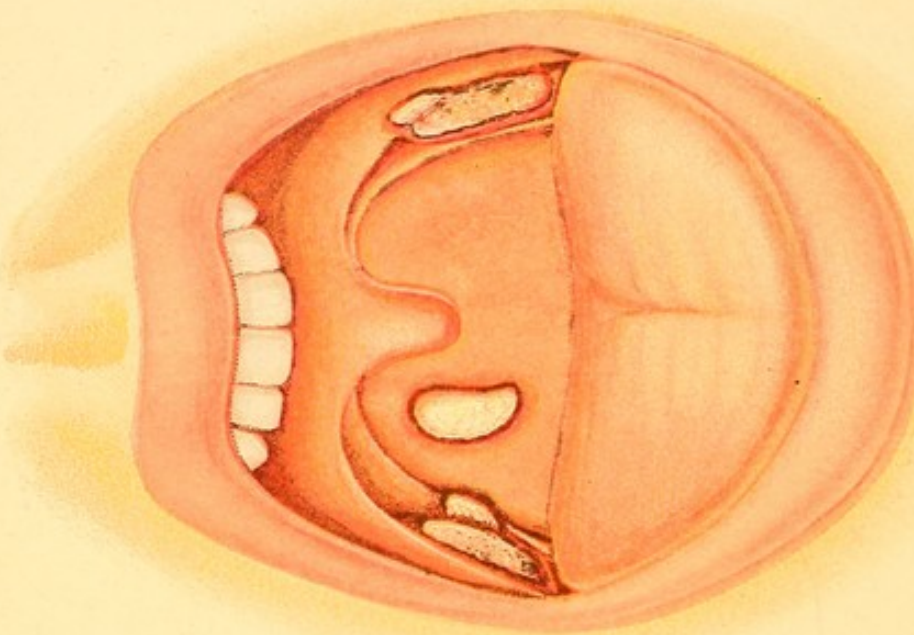


Fig. 1.—Secondary Syphilis (Mucous Patches) of the Lips, Tongue, Tonsils, Pillars of the Fauces and Uvula.

Fig. 2.—Diphtheritic Exudate on the Right Tonsil and Posterior Pillar of the Fauces, on the Left Tonsil and Anterior Pillars of the Fauces, and on the Right Side of the Posterior Pharyngeal Wall.

occurs frequently in scarlet fever, measles, and the other infectious diseases of childhood, as well as in adults. The membrane formation is almost identical with that of diphtheria in that it is firmly adherent to the mucosa. The symptoms of streptococcus infection are often more severe than those found in diphtheria, the temperature running as high as 105° or 106° F. It may even be followed by paralysis of the soft palate, as in diphtheria. Bacteriological examination alone is the only possible way of differentiating between these two conditions.

The mucous patches of syphilis have more than once been mistaken for a diphtheritic exudation. The symmetrical situation of the patches (see Plate VI., Fig. 1), and their thin, filmy character, the long time that the sore throat has existed (often for several weeks), the enlargement of the suboccipital cervical glands, as well as those beneath the angle of the jaw and those in the femoral region, the presence of macular or papular syphilides on the skin, and the falling out of the hair are sufficient to differentiate the two conditions. Where doubt still exists a bacteriological examination will settle the question.

In mycotic disease of the pharynx careful observation will show the whitish elevations studding the mucous membrane, each as a separate elevation, and not confluent, as found in the diphtheritic exudate. There is seldom any rise in temperature or any constitutional symptoms. Bacteriological examination fails to detect the Klebs-Loeffler bacilli, and microscopical examination shows the *mycelium leptothrix buccalis*.

Prognosis. The prognosis in diphtheria should always be a guarded one. A case that at the onset of the dis-

ease has very mild symptoms and a moderate amount of exudation may suddenly assume a virulent type, or laryngeal diphtheria may intervene and death take place. On the other hand, we have seen the most severe forms of diphtheria, in which there was apparently no hope for the child, suddenly markedly improve and finally get well. The character of the epidemic and the prevailing type of the disease should always be taken into consideration in giving a prognosis. In some years the types of diphtheria are very mild, and the death-rate may not be more than 5 per cent. In other epidemics the death-rate may rise as high as 35 per cent. The death-rate is usually lower in the families of the moderately well-to-do than in those of the poor in the tenement-house districts and in those who apply to the contagious disease hospitals for treatment. The important factor in this is that the children in the former cases receive attention in the first stages of the disease earlier than those in the latter conditions. There is no disease in which early, prompt, and efficient treatment so favorably affects the prognosis as in diphtheria.

The prognosis in laryngeal diphtheria is always more grave than that in the pharyngeal type, the death-rate in these cases varying from 30 to 80 per cent.

Age is a very important factor in the prognosis. Diphtheria is a much more serious condition in children under three years of age than in those who are older. Children who are debilitated, or who have recently recovered from any prolonged disease, such as the exanthemata, usually stand diphtheria poorly.

Some of the conditions which render the prognosis bad are the presence of laryngeal or nasal diphtheria; great enlargement of the glands of the neck; a slow, ir-

regular pulse or one that is excessively rapid and feeble; severe epistaxis; gangrenous odor of the breath, and a dusky color of the skin. The commonest causes of death are heart-failure and bronchopneumonia. These two complications should always be carefully watched for and guarded against.

Treatment. We shall divide the treatment of diphtheria into, first, *prophylactic*; second, *hygienic*; third, *constitutional*; and fourth, *local treatment* of the *pharyngeal*, *nasal*, and *laryngeal types* of the disease.

PROPHYLACTIC TREATMENT. No form of treatment should be given more care and attention than that of the prevention of the spread of the disease. One of the greatest advances that bacteriology has made in a practical way is that of convincing us of the long time that virulent germs remain in the mouth, nose, and upper air-passages of individuals who have had diphtheria and who have completely recovered from the outward manifestations of the disease. Isolation, absolute and complete, should be insisted upon, not only during the time that the individual is actually ill with diphtheria, but during all the period, however long—and it is often several weeks—in which the Klebs-Loeffler bacilli are found in the upper air-passages. In no other way can we be sure that a recent convalescent from diphtheria may not scatter broadcast the germs of this disease.

Immunity against the disease is claimed to be produced by the injection of the diphtheria antitoxin in doses varying from 200 to 1000 units, according to the age of the patient. While this renders the individual immune in the great majority of cases, it does not always do so, for we have known of supposedly immunized children becoming infected about a

week after the antitoxin injection. Antitoxin immunization does not last indefinitely, but, apparently, only for a few weeks or months at the most; and when a person is later exposed to the germs of diphtheria immunizing doses of antitoxin should again be administered.

A very important prophylactic measure consists in remedying any diseased conditions that may exist in the throats of children. It is pretty definitely decided that the enlarged tonsils and adenoid hypertrophies found in children predispose them markedly to the contagion of diphtheria. These, therefore, should be appropriately treated.

It is common for physicians to prescribe an antiseptic gargle for the nurses and others in close attendance upon diphtheritic patients. We believe that a spray will reach the parts much more accurately, and serve the purpose, therefore, better than any gargle. The throats of these individuals are to be sprayed every three hours with a 1 : 5000 bichloride of mercury solution. Care must be taken not to swallow too much of the solution, or diarrhea and symptoms of mercurial poisoning may ensue. It is not advisable to use the bichloride of mercury spray to disinfect the nasal cavities, as the mucous membrane in this region is very sensitive to the action of mercury, and acute rhinitis will probably be produced. The spray for the nose that we advise in these cases is a solution made from Seiler's tablets.

HYGIENIC TREATMENT. Patients suffering from diphtheria should be placed in a well-ventilated room; all unnecessary furniture, carpets, pictures, and other movable articles must be removed. Where the circumstances of the patient permit, an iron bedstead,

spring mattress covered with a blanket, a wooden chair or two for the nurse and attendant, and a cheap wooden table for medicines, are all the articles that should be in the room. The room should be kept rather warm—namely, about 72° F. All sources of draught that may strike the patient should be carefully examined for and corrected. It is advisable to keep a kettle of water boiling, so that the air of the room may be moderately moist.

The diet should be a fluid one—milk and lime-water, peptonized milk, kumyss, and buttermilk being those articles which are usually most easily digested and assimilated.

Pieces of old cloth, which after use must be burnt, are to be employed in wiping away secretions from the nose and mouth. After convalescence, should a bacteriological examination show the air-passages to be free from the Klebs-Loeffler bacilli, or in the event of the death of the patient, the bedding, furniture, and all articles which have been in contact with the patient are to be disinfected with a 1 : 2000 bichloride of mercury solution or by steam heat in special disinfectors. The floors, walls, and ceilings are to be washed with 1 : 1000 solution of bichloride of mercury, the room well aired, and subsequently repainted, papered, and decorated before being occupied again.

CONSTITUTIONAL TREATMENT. At the present time the use of diphtheria antitoxin is so universal that we need do no more than call attention to the fact that to be of the greatest value it must be administered early in the disease. While it may be given no matter how late the physician is called in, its administration before the third day gives the best results. The dose should

*give while
effect
produced.*

be from 2000 to 3000 units, administered hypodermatically with a special syringe. In severe cases half of the maximum dose may be repeated twenty-four hours after giving the first injection. A rash not unlike that of urticaria often follows the use of the antitoxin. It usually disappears in a few days, but is annoying while it lasts. A few cases of death quickly following the injection of antitoxin have been reported.

In connection with the antitoxin treatment we advocate the employment of those remedies which were so esteemed before antitoxin was discovered. We invariably begin internal medication by the administration of quarter-grain triturated tablets of calomel every half hour until the bowels are moved. The internal administration of tr. ferri chlor., 1 part; glycerin, 4 parts; fifteen drops of which are to be given in water, every two hours, to a child one year old, and thirty drops administered to a child over two years of age, is an old and valuable remedy.

The condition of the heart should be carefully looked after. When the pulse is very rapid or shows signs of irregularity, either in force or rhythm, whiskey and strychnine should be administered, the former in doses from thirty drops to a teaspoonful and a half, varying with the age of the patient, and the latter in doses from $\frac{1}{200}$ to $\frac{1}{40}$ of a grain, also according to the age of the patient. Digitalis, strophanthus, and other cardiac stimulants are to be borne in mind where the two previously mentioned do not give all needed relief.

One of the most important points to be remembered in connection with diphtheria is the fact that heart-failure makes its appearance often early; at other times late, when convalescence is almost established.

Nothing seems to us to increase so markedly the liability to this as fussing with the child, attempting to do something for it all the time, allowing it to sit up in bed or to be carried about in the arms in the upright position. The child should be kept on its back and quiet, so as to give the heart as little work as possible.

The treatment of the sequelæ of diphtheria consists in giving small doses of strychnine for the diphtheritic paralyses. This may hasten the return of the functions of the part. If an abscess of the neck occurs, it should be opened and treated antiseptically. For otitis media with a purulent discharge from the ear, frequent douching with a saturated solution of boric acid in warm water should be prescribed. The pus must not be allowed to accumulate in the external auditory canal, for fear of damming back that which is in the middle ear, and thus cause mastoiditis. When acute nephritis occurs it is to be treated the same as that arising from any other cause.

LOCAL TREATMENT. *Pharyngeal Type.* No attempt should be made to remove the diphtheritic membrane from the pharyngeal mucosa. In mild cases in which there is not much secretion at the posterior portion of the throat *no local medication is necessary.* In the more severe cases, in which the parts are considerably swollen, and thick, tenacious secretion is present in the back of the throat, we have found Loeffler's solution, used in a spray or applied on a cotton-wound applicator, to be very advantageous in diminishing the swelling and congestion and in hastening the exfoliation of the membrane. The solution is made as follows: 10 parts of menthol are dissolved in toluol, so that the mixture represents 36 parts; to this are

added 4 parts of liquor ferri sesquichloridi and 60 parts of alcohol. Peroxide of hydrogen, diluted with an equal volume of water, may also be advantageously sprayed into the throat to remove the mucus. Many young children greatly object to the use of sprays and swabs, and struggle violently while these are being employed. It seems to us that in such case the exhaustion produced and the extra taxation of the heart more than counterbalance any good accomplished with the spray.

Nasal Type. Where diphtheritic exudation is found in the nose and nasopharynx the frequent association of streptococci with the Klebs-Loeffler bacilli usually makes it necessary to free the nose from exudation, in order that the toxins produced by the streptococci may not be absorbed and thus add to the constitutional symptoms of the patient. The mouth-breathing caused by nasal obstruction can be lessened when the nose is kept comparatively free from membrane. To wash the nasal cavity properly the child should be wrapped from neck to foot in a flannel blanket, and this pinned about it in such a way as to fasten the arms to the sides of the body and to enclose the feet, so that struggling cannot take place. The child should be laid on its side on a table covered with a rubber sheet, which should overhang its edge, so as to guide the solution into a metal receptacle on the floor. A large-sized douche-bag, with a long rubber tube attached, is to be filled with normal saline solution (temperature 115° F.). A glass nozzle, similar to that shown attached to the douche in Fig. 32, is to be connected with the rubber tube and inserted into the uppermost nostril of the child. The douche-bag is now to be

elevated to a height varying from one to five feet above the child's head, until the solution distends the nasal cavity, and flows back into the nasopharynx and out through the opposite nostril. Considerable pressure is often necessary to loosen and dislodge the membrane, which comes away with the outflowing stream. When the membrane from the inferior nostril has been discharged the tube should be inserted into the lower nostril and irrigation resumed, so that the membrane in the upper nostril can be washed away. The child may struggle at first, but, wrapped in the manner mentioned, it is much easier to control it than in any other way. The washing of the nose and nasopharynx may be accomplished by means of a large-size hard-rubber syringe, but unless great care is taken the movements of the head frequently result in injury to the structures within the nasal cavity. Once the nasal cavity has been freed from membrane the douche should be employed at intervals of twelve hours, in order to remove the secretions and keep the passages as clean as possible.

Laryngeal Type. As soon as symptoms of laryngeal diphtheria appear a tent improvised from a sheet or blanket should be rigged over the cot upon which the patient lies. A steam-kettle with a rubber hose attached to the spout should be kept at boiling-point continually, the hose being situated a few inches from the mouth of the patient, just far enough so that the steam will not *scald* the patient. The moist air thus inspired frequently tends to limit the amount of congestion and to assist in exfoliation of the membrane. If the child's strength will permit, an emetic dose of syrup of ipecac or sulphate of copper may be administered. If the child is weak and exhausted, it is usually ad-

visible not to administer emetics. Ten grains of calomel fumigated under the tent in which the child is placed may retard the development of the membrane.

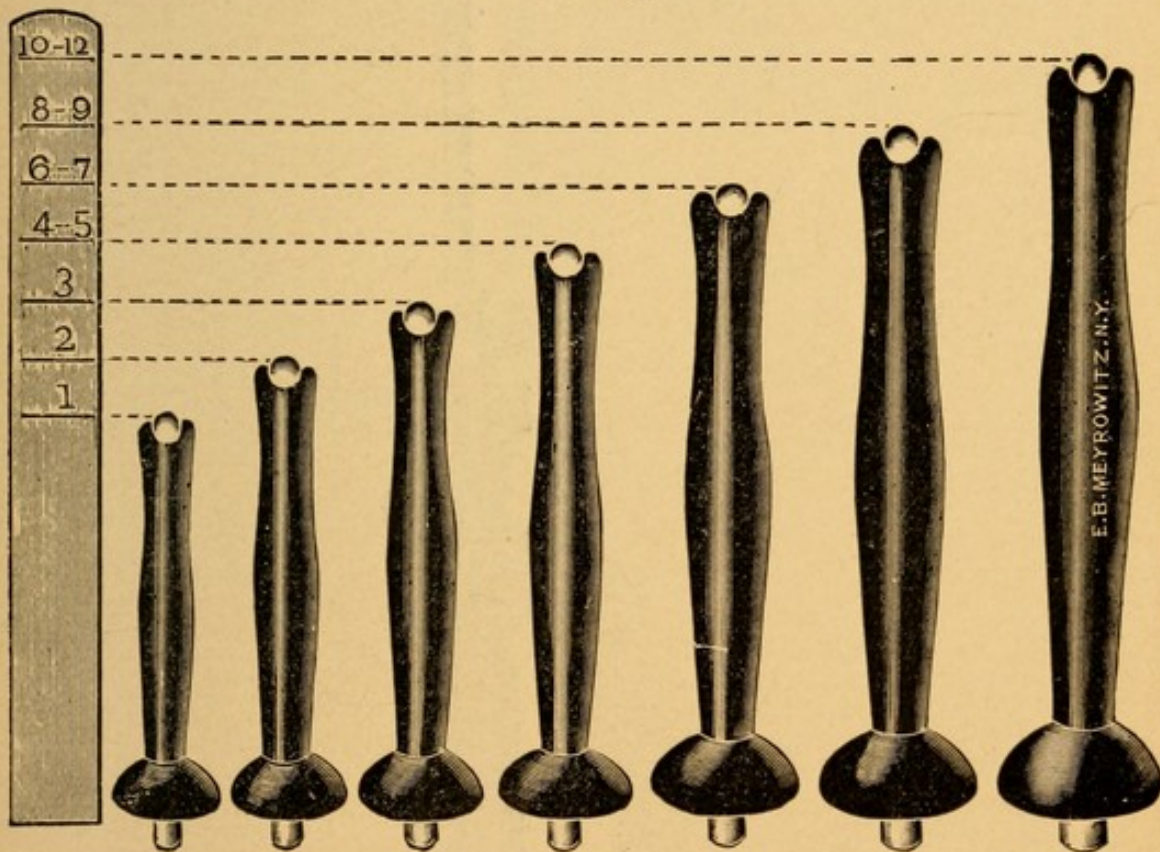
The above remedies are to be considered as of use in only the very mild forms of laryngeal diphtheria or to be employed while waiting for the arrival of instruments for intubation or tracheotomy.

The diphtheritic membrane in laryngeal diphtheria, in the majority of cases, produces so much mechanical obstruction to respiration that some means has to be devised by which the child may be permitted to breathe until such time as the membrane can be exfoliated and respiration becomes normal. The first means devised for this purpose was that of tracheotomy, and the insertion of a tube into the trachea, so that the wound might be kept open and the patient respire through this. The wound itself frequently became infected with the Klebs-Loeffler bacilli, and the membrane extended from this into the trachea and bronchi, producing obstruction in the lower portions of the respiratory tract that could not be overcome. The objection on the part of the parents to the mutilation of the child necessary in this operation, and the fact that death so often followed in spite of the temporary relief, made it difficult oftentimes to obtain the consent of parents to have this operation performed. At the present time intubation has in this country almost superseded tracheotomy as a means of relieving the dyspnea due to laryngeal diphtheria.

INTUBATION.—The late Joseph O'Dwyer, of New York City, after painstaking experiments, devised a set of tubes for insertion into the larynx by which the normal respiratory channel may be kept sufficiently

open to allow of respiration until such time as the membrane becomes exfoliated and the obstruction to respiration removed. These are known as *intubation* instruments. As now made they consist of a set of seven hard-rubber (Fig. 93) or gold-plated metal tubes, varying in length and diameter according to the size of the larynx into which they are to be inserted. A scale

FIG. 93.

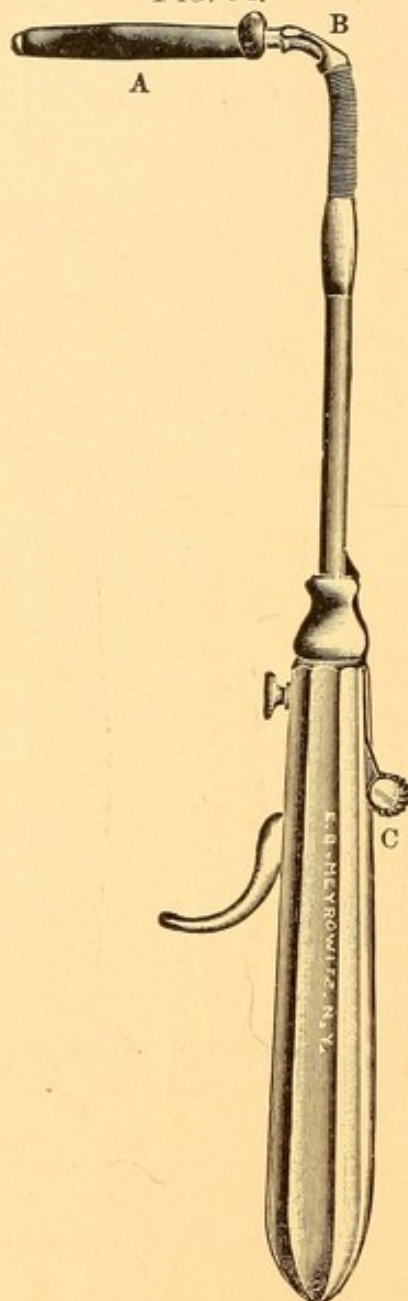


O'Dwyer intubation tubes.

accompanies these tubes, upon which figures representing the ages of children are placed. For example, if a child be two years old, that tube is to be selected whose length is equal to that part of the scale extending from the line 2 to the bottom of the scale. Each tube is fitted with a metal obturator, the lower end of which projects slightly below the lower end of

the tube, to facilitate introduction into the larynx. The upper end of the obturator is hollowed out and

FIG. 94.



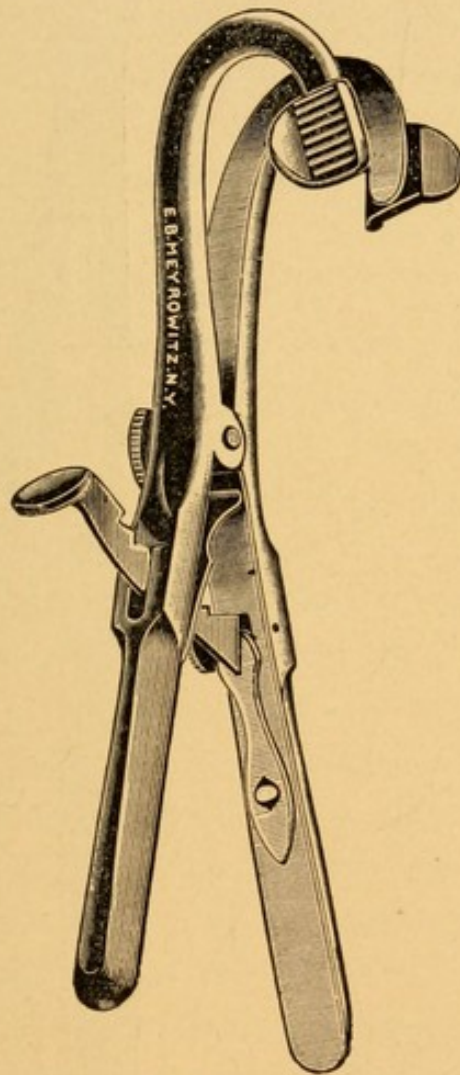
Intubator with a tube in the proper position for insertion into the larynx.

A. Intubation tube. B. Fork pushing tube away from obturator. C. Knob which, when pushed forward, causes the fork to strike the head of the intubation tube.

threaded, so as to be screwed upon the intubator (Fig. 94). A tube (Fig. 94) is shown attached to the

intubator, in the proper position for insertion into the larynx. It will be noticed that the head of the tube is flanged, so that it projects beyond the edge of the tube at one place and is flush with the edge of the tube on the opposite side. This projecting edge of the tube

FIG. 95.

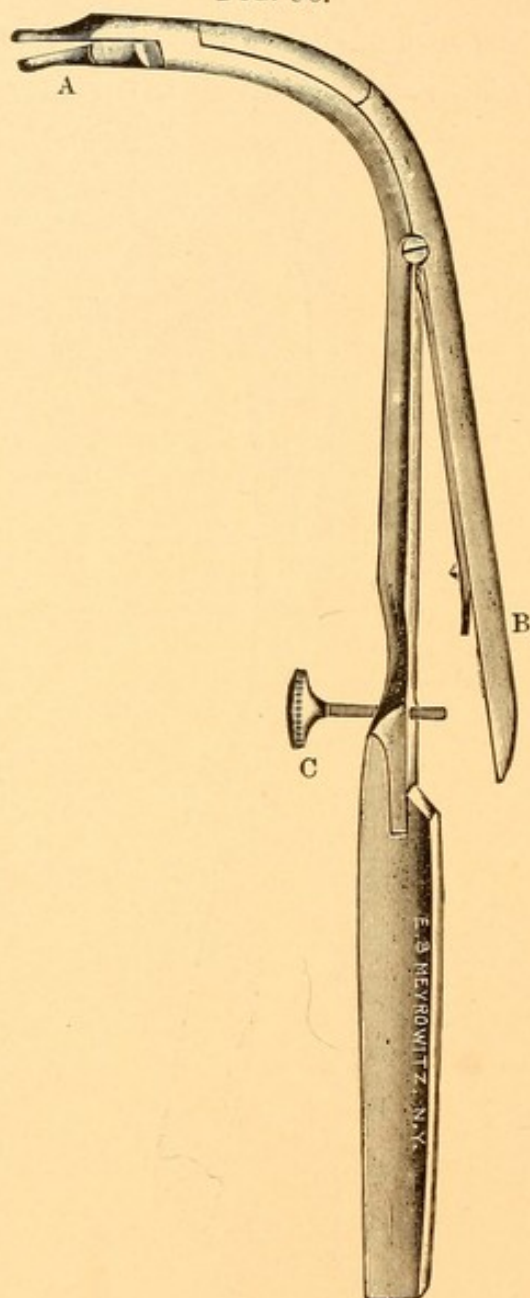


Mouth-gag.

should be *away* from the operator when the tube is properly attached to the intubator. If, after screwing on a tube, it is found that the projecting edge is *toward* the operator, then it is necessary to pull the obturator out from the tube, turn the tube around at an angle of

180 degrees, and reinsert the obturator, when the tube will be found in the proper position for insertion into the

FIG. 96.



Extubator.

A. The jaws partly open. B. Lever, pressure on which in a downward direction opens the jaws. C. Screw which regulates the extent to which the lever may be depressed and the jaws opened.

larynx. On the right-hand side of the head of the tube will be found a small hole, through which a piece of floss

silk, three feet long, is to be threaded and the ends tied together, to prevent the silk being pulled out. At C on the intubator (Fig. 94) will be found a little knob, which can be pushed forward in a groove on the upper side of the handle of the instrument. When this is done it will be noticed that a jointed fork, B, slides down over the solid rod to which the obturator is attached, so as to strike the head of the tube and loosen it from the obturator. A mouth-gag (Fig. 95) accompanies a set of the instruments, for the purpose of keeping the jaws opened while the tubes are being inserted. The set is completed by an extubator (Fig. 96). The jaws, A, of the extubator are kept closed (shown open in the diagram) by a spring. By pushing down at B on the handle of the instrument the jaws are opened—the amount of which is regulated by the thumb-screw at C. The jaws, A, of the extubator fit into the lumen of the tube, and pressure on the lever at B opens the jaws anteroposteriorly, so as to cause them to engage upon the inner wall of the lumen of the tube with sufficient force that the tube may be lifted out of the larynx.

The indications for performing intubation are: dyspnea of such a character as to produce either beginning cyanosis and exhaustion of the patient or marked sinking in above and below the clavicles during inspiration.

The method of performing intubation is as follows: The child should be wrapped in a sheet from the neck to its feet, so as to pin *down* the arms to the side and to keep the feet closely approximated. An assistant should hold the child on his lap, so that the wrapped-up feet can be held between his legs, the back of the child's head resting upon his left shoulder. The mouth-gag is to be inserted into the left corner of the

mouth and the gag opened as widely as possible. A second assistant should be instructed to hold the mouth-gag to prevent its falling out, and at the same time to steady the head of the child, which should be extended backward as far as possible. He should also lift the child's head, for by so doing the space between the root of the tongue and the entrance into the larynx is increased and the operation made less difficult.

The operator, while the child is being prepared for the operation, should select the proper-sized tube for the age of the child, thread it with a piece of floss silk, knot the two ends, and attach the tube to the intubator so that its head is in the proper position for intubation. The child having been properly placed in position, the operator grasps the handle of the intubator with his right hand and winds the doubled end of the floss silk two or three times about the little finger of this hand. The knot should be in the part wound about the finger. He then inserts his left forefinger into the child's mouth, feels for the epiglottis, lifts it to a vertical position, and feels for the little eminences that mark the sites of the arytenoid cartilages at the posterior portion of the entrance into the larynx. This usually takes only a second or two, but where the operator is unfamiliar with the parts, or they are much swollen, several seconds may be necessary to locate accurately the entrance to the larynx. In such a case it is better to remove the finger and wait for a respiration or two, for the finger in this region usually interferes for the time being with respiration, and cyanosis deepens. Again introduce the left forefinger, lift up the epiglottis, and place the pulpy portion of its tip so that it rests upon the top of the arytenoid cartilages. The intubator in

the right hand should now be held so that its handle is parallel with the child's chest and the intubation tube opposite the entrance to the mouth. The tube should now be passed into the mouth parallel with the tongue and *kept absolutely in the median line*. When the distal end of the tube reaches the back part of the tongue the handle of the intubator is to be elevated through an arc of a circle, care being taken that while this is being done the handle is kept continuously in the median line. The elevation of the handle depresses the end of the tube, which should now be in contact with the palmar surface of the forefinger. Continued elevation of the handle will cause the tube to descend along this surface of the forefinger, the tip of which, being at the posterior portion of the entrance to the larynx, the tube is guided thereby into the cavity of the larynx. One of the greatest difficulties that beginners experience in performing this operation is that of allowing the right hand, holding the intubator, to deviate from the median line of the child's body. If such deviation takes place, the tube almost invariably passes down the pyriform fossa, *alongside of instead of in front of* the forefinger of the left hand, and passes into the esophagus. No force whatever should be employed, for none is needed, to insert the tube into the larynx in a case of diphtheria. When the head of the tube has come down to the level of the tip of the forefinger the latter should be moved forward so as to rest upon the head of the tube and push it well down into the cavity of the larynx. The button, C, on the intubator (Fig. 94) should be pressed forward with the thumb of the right hand, thereby releasing the obturator from the tube, and the intubator, with the attached obtura-

tor, is to be withdrawn from the mouth, the forefinger still resting on the head of the intubation tube to prevent its withdrawal. The string is to be unwound from the little finger, allowing the end to hang out of the mouth for ten minutes, to observe the effects of the intubation. When the tube is properly in the larynx one or two coughs will be given; the child's respiration, which was before croupy, becomes quiet; the cyanosis clears up, and the child, who has usually been exhausted by its efforts to breathe, falls into a quiet sleep.

The operation, which has taken so long to describe, occupies really not more than three or four seconds. If any difficulty be experienced in introducing the tube, no single effort to introduce it should last more than fifteen seconds. The finger and the tube in position for intubation obstruct respiration, and the child should be given a rest for half a minute in order to recover.

It may happen that when the tube is thought to be in the larynx it in reality has passed into the esophagus. If this be the case, coughing will not be produced; respiration does not change from its original character; the cyanosis does not clear up, and the string which hangs from the mouth can be seen gradually but slowly receding, owing to the peristaltic action of the muscles of the esophagus. Seize the string and pull out the tube, place it again on the obturator, try to ascertain the cause of failure to insert the tube, correct it, and try again.

When the tube is found to be in the larynx, at the end of ten minutes the string should be cut, so as to remove completely the knot that had been tied in it, the mouth-gag reinserted, the forefinger of the left hand placed upon the head of the tube, and traction upon one

end of the string made until it is pulled out from the little hole in the head of the tube.

Great care must be taken in feeding children while wearing an intubation tube. Liquid food may pass through the tube into the trachea and produce coughing, which may be violent enough to expel the tube. If the physician be not within ready calling distance, the child may die of asphyxia before he can return to the case. The child is best fed through a small gum-elastic catheter passed through the nose, nasopharynx, and esophagus into the stomach, and fluid food given through the catheter. Care should be taken that the catheter passes into the stomach, and not into the intubation tube in the larynx. Where a trained nurse cannot be obtained to feed the child in this manner, the giving of liquids in spoonful doses, the child being held with the head much lower than the body, should be resorted to. In case this produces coughing and permits entrance of liquid into the larynx, rectal alimentation must be resorted to so long as the tube is *in situ*.

The question as to how long to leave an intubation tube in the larynx is one that may be difficult to decide. It should be remembered that absorption or exfoliation of the membrane occurs in from six to ten days, and that the larynx has usually been involved in the membrane formation several days (three or four, sometimes) before the symptoms demanding intubation appear of sufficient gravity to warrant this operation. The tube, therefore, will have to remain in the larynx from two to seven days, varying with the rapidity of absorption or exfoliation of the membrane. We are not frequently called upon to decide how long a tube shall remain, as with the disappearance of the membrane and the sub-

sidence of the swelling the tube is often expelled during a fit of coughing. We deem it best, unless the obstruction to respiration is still great, to remove the tube at the end of the fifth day. After removing it, it is always necessary for the physician to wait at least an hour before taking his departure, for swelling of the mucous membrane sometimes comes on as late as this after extubation, which may necessitate reintroduction of the tube.

To extubate a tube the child is to be wrapped and held as before, the mouth-gag inserted, and the forefinger of the left hand passed into the mouth and down to the larynx, so as to touch the posterior border of the intubation tube. The extubator is held in the right hand, no pressure being made upon the lever, B (Fig. 96), so that the jaws at A are closed. The extubator is to be inserted in the same manner that the intubator was, great care being taken to hold it in the *median line*, elevating the handle as the jaws strike the palmar surface of the finger that is placed on the tube, and the jaws, closed, are to be passed down along the palmar surface of the forefinger. If kept in the *median line*, they will enter the opening at the upper end of the tube. Pressure with the forefinger of the right hand on the lever, B, will open the jaws, cause them to catch finally into the tube, and with steady pressure on the lever the extubator should be lifted vertically upward for an inch, when the handle should be depressed toward the sternum, the tube being brought into the mouth and so out.

TRACHEOTOMY. When intubation does not relieve dyspnea in laryngeal diphtheria tracheotomy must be resorted to as a means of preventing asphyxia and saving the life of the patient.

Before describing the method of performing tracheotomy we deem it advisable in this place to name all the conditions which may demand this operation, and thus avoid repetition. Any disease that is likely to narrow markedly the lumen of the larynx, either above the vocal cords in the supraglottic region, or below them in the infraglottic region, may, if the narrowing is sufficient, demand relief from the dyspnea. The most common diseases producing laryngeal obstruction are laryngeal diphtheria (croup); malignant diseases of the larynx; syphilis; benign tumors, such as papillomata; foreign bodies in the larynx; paralysis of the abductors of the vocal cords; Bright's disease; and some forms of laryngeal tuberculosis. Any of the causes that will produce edema of the larynx (*q. v.*) may demand tracheotomy.

Operation. In slowly on-coming asphyxia the urgency of the dyspnea may not be so great but that the operator can take all the time required for slow dissection of the tissues lying in front of the trachea prior to the insertion of the tube; but where the onset of asphyxia is rapid, and the patient, as is frequently the case, is almost moribund when the physician reaches the bedside, then no time should be lost in opening the trachea; instances are recorded in which life has been saved by using a penknife and keeping the wound in the trachea open by means of sutures inserted through the skin at the tracheal opening, thus giving a passage for air until a suitable tracheotomy tube could be obtained.

The operation for tracheotomy may be divided into the high and the low operation. In the high operation an opening is made into the trachea above the isthmus

of the thyroid gland, which usually extends across the trachea at about the level of the second or third tracheal ring. In the low operation the trachea is opened below the isthmus of the thyroid gland and above the level of the episternal notch.

The instruments necessary to perform tracheotomy are a scalpel, two thumb forceps, a grooved director, two sharp tenacula (Fig. 97), half a dozen artery

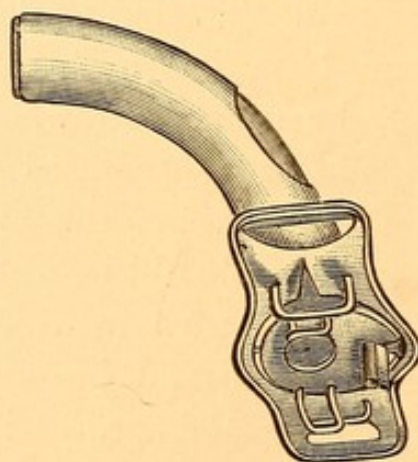
FIG. 97.



Tenaculum.

clamps, two retractors, needles, catgut and silk for ligatures and sutures, sterile gauze, and tracheotomy tubes, preferably of silver (Fig. 98). Of the latter

FIG. 98.



Tracheotomy tube.

there should be several sizes and of different curvatures as to the part that is inserted into the trachea, in order that the largest size may be used compatible with the size of the trachea, and one whose curvature will con-

form to the depth and curvature of the trachea. A piece of tape long enough to pass twice around the neck should be passed through one side of the flange of the tracheotomy tube. All the instruments should be sterilized prior to their employment.

The patient should be placed on a table with a hard pillow or block under the back of the neck, so that the head is sharply extended backward. The skin of the neck should be sterilized by scrubbing with green soap, afterward washing it off with 1 : 3000 bichloride solution and drying. Absolute alcohol should be rubbed over the line of incision. As to the use of an anesthetic, in severe cases of asphyxia the patient may be so thoroughly narcotized by carbon dioxide poisoning as not to require the administration of an anesthetic. Where tracheotomy is done for slowly oncoming dyspnea a subcutaneous injection along the line of the incision of a 4 per cent. solution of cocaine is all the anesthesia required. In extremely nervous and hysterical patients it is well to have chloroform and a chloroform inhaler at hand in case the cocaine does not sufficiently anesthetize the tissues. Chloroform we prefer to ether on account of the irritation by the latter of the mucous membrane of the upper respiratory tract.

As to whether one should perform the high or the low operation, it may be said that, as a general rule, the high operation is to be preferred in all cases excepting those in which one expects to remove the entire larynx at a later operation.

The operator stands at the right side of the patient, the assistant opposite him. An incision is made in the median line from the lower level of the thyroid cartilage, which can always be felt just below the Adam's

apple, to half an inch above the episternal notch. The incision should be through the skin and superficial fascia. The hemorrhage may be severe, owing to the congested state of the bloodvessels. At this stage one should be careful about the two anterior jugular veins, which are likely to be injured, especially if one of them takes a course obliquely across the neck, as it sometimes does. The muscles in front of the trachea should be separated with the handle of the scalpel, rather than by incising them, and pushed to either side. On reaching the trachea the isthmus of the thyroid gland, which may be abnormally large, may extend above the second ring, and prove an obstacle to the insertion of the tracheotomy tube above it. If this is the case, two silk ligatures, one on either side the median line, should be passed around the isthmus and tied tightly, after which the isthmus may be cut without hemorrhage. The *arteria thyroidea ima* may be cut at this time ; and if cut, the hemorrhage is likely to be profuse, but is easily controlled by artery clamps and ligature. All hemorrhage must be stopped before attempting to open the trachea, although in cases of great dyspnea combined with cyanosis capillary oozing is not usually to be avoided until relief of the congestion after opening the trachea. Such capillary oozing need not be feared provided all the large arteries and veins have been clamped, as the hemorrhage will cease as soon as the trachea is opened.

Having exposed the trachea—all the tissues being well pulled aside by means of retractors—the operator should make sure that the centre of the convexity of its surface is in the centre of the wound, and with a sharp tenaculum inserted into the rings on either side, an incision three-quarters of an inch long should be

made in the median line of the trachea at right angles to its course. At this time spasmodic coughing will take place, with sudden rising and falling of the trachea, so that care must be taken not to let the knife pass through the posterior wall of the trachea. The handle of the scalpel, if inserted into the wound and turned at right angles, usually opens the trachea sufficiently wide to allow insertion of the tracheotomy tube. Should this not be the case, then an artery clamp, inserted above or below the handle of the knife and the blades opened, will sufficiently extend the tracheal opening to admit the tube. The tube with its canula inserted should be tied in the trachea by passing the tape, which had been placed in one of the openings on the flange, around back of the neck, threading it through the opposite opening, and tying it to the other end behind the neck. The upper and lower edges of the incision should next be brought together with catgut sutures, and a piece of thin sterile gauze should be placed beneath the shoulder of the tracheotomy tube and the skin around the margin of the wound.

The inner tube should then be removed and a bit of cotton wound round an applicator, properly bent for insertion into the canula, should be passed down it to wipe away any blood or mucus that may be in the trachea or tracheal tube. The inner tube is then reinserted and a light aseptic dressing placed over the wound.

The patient should be kept in a room the temperature of which is at least 80° F., and in which the atmosphere is kept moistened by steam from a kettle. A nurse should be in constant attendance with small pieces of sterile gauze to wipe away secretion from the mouth of the tube as often as any is coughed up.

The dangers of the operation are that in cases of diphtheria extension of the diphtheritic process to the wound and further down into the trachea and bronchi frequently causes bronchopneumonia, from which the patient usually succumbs. Bronchopneumonia, even in cases which are not diphtheritic, is not an uncommon complication following tracheotomy. Infection of the wound may take place, and the infected pus may gain access to the trachea by being inhaled and carried down to the trachea and bronchi, producing a septic pneumonia which is usually fatal.

Abscesses in the neck which have a tendency to burrow beneath the deep fascia into the thorax are always to be guarded against by opening and drainage when they occur. Emphysema of the thorax and the tissues of the neck has followed tracheotomy, especially when the lateral or posterior wall of the trachea has been incised during the operation.

SYPHILIS OF THE MOUTH AND OROPHARYNX.

The manifestations of syphilis in this region may be those of the acquired or the congenital form. Acquired syphilis is found here in its several stages—primary, secondary, and tertiary. *Congenital—usually tertiary gumma and deep ulceration.*

Acquired Syphilis.

PRIMARY OR INITIAL LESION, CHANCRE.

Etiology. The initial lesion, or hard chancre, is occasionally seen on the lips, tongue, tonsils, pillars of the fauces, and, more rarely, on the posterior pharyngeal wall. This mode of infection may be the result of perversion of the sexual appetite or the result of various

infected articles coming in contact with the broken or diseased membrane in this region. The contagion may be conveyed through kissing, using knives, forks, cups, etc., that have been used by a syphilitic, smoking an infected pipe, and through dentists' or physicians' unclean instruments. Infection is often conveyed in obscure and untraceable ways, especially where the mucous membrane of the lips is chapped or where there are diseased conditions of the mucous membrane of the cavity of the mouth.

Symptoms. A chancre of the lip presents itself as a hard, indurated mass about the size of one's thumb-nail. Its free surface may be covered with a small amount of secretion. The lip in the immediate neighborhood of the chancre is considerably swollen, as are also the lymphatic glands beneath the inferior maxilla on the same side. When the chancre is situated near the median line the glands on both sides are enormously swollen, hard, and indurated, often mechanically interfering with mastication. Pain is referred to the site of the chancre. The chancre usually disappears in from five to nine weeks, leaving no scar.

Chancre of the tongue is characterized by symptoms almost identical with those of chancre of the lips.

Chancre of the tonsil is characterized by an excessive enlargement of the tonsil, which feels very firm and dense to the finger. The amount of secretion found on the tonsil in these cases is usually greater than that seen in chancre of the lip and of the tongue. The glands of the neck are enlarged, those at the angle of the jaw on the affected side being enlarged to a greater extent than those under the anterior portion of the inferior maxilla. Pain in deglutition is severe.

Differential Diagnosis. On seeing a patient for the first time who is suspected of having a chancre in this region it may be difficult to make a positive diagnosis. The physician should never state to the patient his suspicions as to the nature of the case until he is certain as to whether or not the lesion is a chancre. It may be several days, or not until secondary symptoms appear, before the true character of the lesion is ascertained.

Chancre of the lip may be mistaken for epithelioma. The rapid increase in size, the age of the patient (which is usually much less than that at which epithelioma is found), and the appearance in a few weeks of secondary manifestations in the mouth and on the skin, and the enlargement of the lymphatic glands in other regions of the body, enable one in a short time to make the diagnosis. Where doubt exists a microscopical examination of a piece of excised tissue permits one to make a positive diagnosis.

Chancre of the tongue may also be mistaken for malignant disease or for gumma. The differential diagnosis between chancre of the tongue and malignant disease is practically the same as that given between chancre and epithelioma of the lip. A gumma of the tongue is usually bright red, very painful, and with a tendency to early ulceration and sloughing. The latter is not present in chancre. A history of syphilis some years previously can usually be obtained, and the administration of large doses of iodide of potassium effects a rapid cure of a gumma, but does not affect a chancre. Secondary manifestations of syphilis are soon observed in a case of chancre.

Chancre of the tonsil may be mistaken for malignant

disease of the tonsil. The rapid increase in the size of the tonsil, early and excessive enlargement of the lymphatic glands of the neck, the absence of hemorrhages so common in malignant disease, and the appearance of secondary manifestations in other places will settle the diagnosis. In doubtful cases a microscopical examination of a piece of the tonsil will show the true nature of the disease.

Treatment. The treatment of the primary lesion, as soon as its character has been diagnosed beyond doubt, should be the administration of mercury. Pills containing one-quarter of a grain of the protoiodide should be ordered, three to be given the first day, four the second, five the third, and so on until the limit for that patient has been reached, as described in the article on Syphilis of the Nose. H g.

SECONDARY MANIFESTATIONS OF SYPHILIS.

Etiology. Secondary syphilis in the mouth occurs not only consecutively to the primary lesion in this region, but also follows the appearance of the chancre in any other part of the body.

Symptoms. The symptom most frequently complained of in secondary syphilis of the throat is that of pain. The patient will usually give a history of having had a very severe sore throat lasting for several weeks. One should always be suspicious of the character of a sore throat when he hears such a history. Ordinarily, simple sore throats do not last anywhere near so long. The pain is most acute during deglutition. Patients also frequently complain of sore and chapped lips that have existed for some time. Hot fluids and spices aggravate the pain.

Examination. The usual condition found is that of mucous patches (see Plate VI., Fig. 1). These are faint, whitish areas, irregular in outline, situated upon the uvula, pillars of the fauces, tonsils, lips, and margin of the tongue where it comes in contact with the teeth. It is not to be understood that mucous patches are found in every patient at all of these places. The uvula, pillars of the fauces, and tonsils are most frequently affected. The peculiarities of mucous patches, in addition to those mentioned, are that they are not elevated above the mucous membrane; that they are commonly bordered by an extremely narrow zone of hyperemia, like a faint penciling with vermilion, and that they are usually symmetrically situated—that is, if a patch be situated on one side of the uvula, a patch almost identical in size and shape will be found upon the opposite side; the same arrangement applies to the patches on the pillars of the fauces, tonsils, etc. The entire mucous membrane of the pharynx is usually reddened and mottled, giving rise to the appearance known as syphilitic erythema. A rare secondary manifestation of syphilis is a thickened, wart-like excrescence upon the tongue and occasionally upon the tonsils. This may or may not be ulcerated. Mucous patches frequently accompany this condition. Where doubt exists as to the character of any exudation seen in the throat search should be made for evidences of secondary syphilis on other portions of the body. It is rare not to find a syphilitic erythema or papillide of the skin. The examination should be conducted in a bright light, the patient being stripped. Enlargement of the suboccipital glands and of those in the femoral region is almost

invariably present. The epitrochlear glands are usually enlarged. *glandular enlargement* Rheumatic-like pains at night and a slight rise in temperature are usually complained of. Persistent headache is also a marked symptom. The hair, eyebrows, and beard may fall out in patches. Some or all of these conditions accompany a mucous patch.

Differential Diagnosis. The secondary manifestations of syphilis in this region are so pathognomonic that a competent observer, on looking into the mouth, should be able to recognize the condition at once.

Prognosis. Mucous patches, when properly treated, heal in from two to six weeks. The patient must be cautioned, however, to take his pills regularly during all the period, and in the manner prescribed in the article on Syphilis of the Nose. When patients do not follow this treatment mucous patches may reappear at any time within two years from the date of infection. *Specific precautions* These patients should be cautioned in regard to the use and care of knives, forks, cups, towels, etc. Each should have his own special utensils, which should not be used by another person, and which should be washed separately, so as not to endanger others with infection. The physician should be extremely careful while examining one of these patients that he does not cough in his face, as there is great danger of becoming infected in this way. He should be especially careful in regard to the instruments employed, and it is advisable to have a set that are used only with patients suffering from primary and secondary syphilis, and these should be disinfected by boiling and immersion in a solution of carbolic acid (1 : 20). This, of course, tarnishes the nickel and quickly destroys the mirrors, but it is the only sure way to prevent infection of other patients.

Treatment. The treatment of mucous patches is the same as that advised for secondary syphilis of the nose (see p. 161). In treating the rarer form—warty excrescences—potassium iodide should be given in doses of from 10 to 30 grains three times a day. Each excrescence should be touched every third day with nitrate of silver fused on an applicator.

TERTIARY MANIFESTATIONS OF SYPHILIS.

2-20 years
7-8 average
The tertiary manifestations of syphilis appear some years after the primary sore. They may occur as early as the second or third year, but they are not usually seen until after a lapse of seven or eight years. We have seen them as late as twenty years after the initial lesion. The form which the process first takes is that of the gumma. This, if seen early and properly treated, may become absorbed and leave no trace of its former existence. It is very common, however, for the gumma stage to be overlooked, or the symptoms may be of such a mild character that the patient does not offer himself for treatment until necrosis and ulceration of the gumma have taken place. As a result of the ulceration cicatricial tissue is formed, and the appearance of this is usually so characteristic that one can be positive in diagnosing tertiary syphilis from the appearance of these cicatrices.

The Gumma.

Symptoms. The usual places in which gummata are found are the posterior pharyngeal wall, soft palate, hard palate, pillars of the fauces, tongue, and tonsils. Gummata usually give rise to pain, especially if they happen to be situated where the bolus of food passes

over their surfaces in swallowing. There may be a sense of fulness and often a sensation as of a lump in some part of the throat, depending upon the situation of the gumma. Where the gumma is large and on the posterior wall of the pharynx obstruction to nasal breathing is usually experienced and the voice has a nasal twang.

Examination. A gumma presents itself as a more or less regularly rounded mass, elevated above the surface of the part on which it is situated. It is usually redder than the surrounding mucosa. When felt with the finger it is found to be firm and dense and about the consistency of an enlarged lymph-gland. Its size varies from that of a pea to that of a small lime.

Differential Diagnosis. A gumma may be mistaken for a fibroid tumor or a malignant growth. It is often difficult, unless a history of syphilis is obtained, to be positive as to the nature of such a growth when first seen. In all doubtful new growths about the pharynx tertiary syphilis is to be kept in mind, and it is well to place the patient at once upon large doses of potassium iodide, beginning with 15 grains three times a day, and increasing this amount by 3 grains each day until from 40 to 60 grains are taken three times a day. If the growth be a gumma, ten days or two weeks will show a marked diminution in its size. Occasionally a malignant growth will slightly diminish for a short time from the use of the iodides, but it will subsequently increase in size. Non-malignant growths are not affected by the iodides. Where doubt still exists as to the character of any growth an invariable practice should be to excise under cocaine a small piece

RT.

of tissue, and to examine thin sections of this under the microscope. Its character will then be revealed.

Prognosis. If gummata be seen before ulceration begins, and large doses of the iodides are given, they are usually absorbed and disappear completely. If very large and softening or ulceration has begun, then cicatrization follows and a permanent scar will be left.

RT.

Treatment. The treatment consists in the administration of potassium iodide, as indicated in the differential diagnosis.

The Ulcer.

Tertiary ulcers are found on the sites occupied by the gummata.

Symptoms. These ulcers give rise to pain, which will be variously located according to the seat of the ulceration. When the ulcer is on the posterior pharyngeal wall, soft palate, or tonsils, pain frequently radiates to the ear on the affected side. Deglutition is often so painful that patients abstain from eating the usual amount of food rather than suffer the excruciating pain experienced in swallowing. Pus, which bathes the surfaces of the ulcers, may be expectorated. It is not uncommon for slight or even severe hemorrhages to result from erosion of the bloodvessels of the part.

Examination. The ulcers usually take one of two forms : a round variety, looking almost as if the mucous membrane had been cut out with a punch ; or an irregular, serpiginous form, the margins of which are considerably elevated above the healthy mucous membrane, but the centre of the ulcer excavated. The first variety is more frequently seen upon the pillars of the fauces, soft palate, and hard palate. The serpiginous form is met with on the tongue, posterior pharyngeal wall, and

sometimes on the soft palate. The ulcer is covered with a thick slough, and pus bathes its surface and often the adjacent mucous membrane.

Differential Diagnosis. Syphilitic ulcers are to be differentiated from tubercular ulcers. Tubercular ulcers of the pharynx seldom occur primarily, but are found in those who suffer from pulmonary tuberculosis. Tubercular ulcerations are usually more painful than those of syphilis. Their outline is apt to be more irregular, their margins less elevated and congested, and their centre less excavated than a syphilitic ulcer. Large doses of potassium iodide cause rapid healing of a syphilitic ulcer, while they do not affect (unless it be to aggravate) a tubercular ulcer. Finally, excise a portion of the margin of the ulcer and submit it to microscopical examination. Sections stained by Gram's method show the tubercle bacilli. A syphilitic ulcer in a tubercular patient may become infected through the sputum, so that a mixed form of ulceration results.

Prognosis. A syphilitic ulcer usually heals kindly, but leaves a scar which plainly tells the tale. Where the ulcer is on the soft palate or hard palate perforation or destruction of the palate may result, and the voice subsequently has the peculiar tone heard in those who have a cleft palate. Where the ulcer is situated on the posterior pharyngeal wall, at about the junction of the oropharynx and nasopharynx, there is likelihood of adhesion taking place between the posterior surface of the soft palate and the posterior pharyngeal wall. This may be partial or complete. When partial the voice is impaired and respiration through the nose impeded; when complete the naso-

pharynx will be entirely shut off from the mouth and nasal respiration made impossible.

Treatment. The treatment of syphilitic ulcers is to be directed toward causing them to heal and to prevent the formation of perforations and adhesions. The treatment should be both constitutional and local. The former consists in administering large doses of potassium iodide (40 to 60 grains three times a day). In some cases $\frac{1}{30}$ grain of bichloride, administered three times a day, will assist in the healing. The main reliance, however, should be placed on potassium iodide. The mixed treatment as ordinarily prescribed—mercury and iodide in one prescription—contains enough mercury, but seldom a large enough quantity of potassium iodide. We, therefore, prefer administering these drugs separately.

The local treatment consists in first cleansing the surface of the ulcer with a spray of 15 grains of sodium bicarbonate to the ounce of water. With a cotton-wound applicator a 10 per cent. solution of cocaine should be applied to the surface of the ulcer. At the end of five minutes a second cotton-wound applicator is to be dipped in a solution of acid nitrate of mercury, 1 part; water, 2 parts, the excess of fluid shaken off, and the whole surface of the ulcer painted with this solution. In spite of the cocaine the application is quite painful. We prefer it, however, to cauterizing the ulcer with nitrate of silver, for we believe that in the latter case the albuminate of silver formed on the surface does not allow the cauterant to penetrate as deeply into the necrosed area as does the acid nitrate of mercury. The object of this cauterization is to remove rapidly the necrosed cells, and thus

R.I.
40-60 gr
T.I.D.

clean
cauterize =
paint
acid nitrate
of Hg. after
cocaine.

obtain a healthy granulating surface. On the soft and the hard palate it is especially necessary for this cleaning process to take place quickly, in order to prevent perforation and great loss of tissue in these regions. The patient should be directed to use the bicarbonate of sodium solution freely in a spray four or five times a day to cleanse the surface of the ulcer. Cauterization should be made every second or third day until a healthy granulating surface is obtained, after which the nitrate of mercury is no longer to be used. The surface of the ulcer is then to be dusted with an antiseptic powder, such as aristol or euophen, applied by means of a powder blower. Healing takes place in from two to five weeks, depending upon the size of the ulcer.

The Cicatrix.

The cicatrix left by a syphilitic ulcer is usually characteristic. Dense white bands of connective tissue radiate from the centre of the ulcerated area. On the tongue the cicatrix has a depressed area in the centre, and a peculiar star-shaped, folded, or pleated arrangement of the mucous membrane and underlying tissue. On the posterior pharyngeal wall the ulcer usually has been so deep as to bind down the submucous and connective tissues to the anterior portions of the cervical vertebræ. The finger introduced into the back part of the pharynx feels firm, hard bone and an immovable scar. Adhesions frequently bind the posterior pillars of the fauces and the soft palate to the posterior pharyngeal wall. These greatly alter the voice and produce greater or less obstruction to nasal respiration. Mouth-breathing with its at-

tendant ill effects is then present. It often becomes necessary to free the soft palate. A simple incision through the portion uniting the soft palate to the pharyngeal wall is seldom sufficient, as the raw surfaces resulting from this incision, the one on the posterior part of the soft palate and the other on the posterior pharyngeal wall, usually reunite, and the patient is not benefited by the operation. It is necessary to devise some means of keeping these two granulating surfaces apart until cicatrization takes place. This may frequently be accomplished by passing a tape through the nose, down through the nasopharynx and out through the mouth, and tying the two ends, thus drawing the soft palate forward and holding it there until cicatrization has taken place.

Congenital Syphilis.

The manifestations of congenital or inherited syphilis appear either quite early in infancy, from a few weeks after the birth of the child up to the second year, or again about the time of puberty. A few cases appear in the interval between these two periods, and rarely the lesions are seen as late as the twentieth year. When occurring at this late date congenital may easily be mistaken for acquired syphilis. The form found is usually that of tertiary gumma and deep ulceration. Mucous patches have been observed. The regions involved are the soft palate, the hard palate, posterior pharyngeal wall, nasopharynx, tongue, and nasal cavity, in which the septum and turbinates are most frequently affected. The larynx is rarely involved.

Symptoms. In young children the presence of snuffles, a purulent discharge from the nose, mouth-breathing,

great difficulty in nursing, continual crying, emaciation, an old-looking, wizened face, wrinkled skin, with frequent association of syphilitic lesions of the skin, make the diagnosis easy.

At the time of puberty the child complains of pain, especially on deglutition, and has an accumulation of muco-pus in the throat, and deafness or great impairment of hearing. The voice has a nasal twang, and where perforation of either the hard or the soft palate has resulted the voice is like that heard in cleft palate.

Examination. This reveals an ulcerated area, usually situated on the median line. If on the posterior pharyngeal wall or hard palate, bare and necrosed bone can usually be detected. The ulcer is covered with a gray slough. Ulcerations, or the puckered scars left by these, are commonly seen at the angles of the mouth. Pigmented, serpiginous ulcers on the body are common.

Prognosis. Inherited syphilis usually is very destructive to the tissues of the upper respiratory tract, which it involves. Destruction of the entire soft palate, or the adhesion of this to the posterior pharyngeal wall, perforation of the hard palate, necrosis of parts of the bodies of the cervical vertebræ, destruction of the entire bony and cartilaginous septum, with falling in of the nose, and destruction of the soft parts around the alæ of the nose are some of the common sequelæ. The disease frequently reappears unless thorough constitutional treatment is carried out. Many of the children die as a result of combined lesions here and in the other organs in the body.

Treatment. The constitutional treatment of congenital syphilis is given in the article on Syphilis of the Nose (page 166). In the ulcerative stage large doses of potas-

sium iodide should also be administered. The administration of tonics, such as cod-liver oil and iron, assists in the nutrition of the child.

Locally, cleansing solutions in the anterior nasal syringe and sprays for the throat are to be used.

The parts are to be kept as clean as possible. Any necrosed bone is to be removed with forceps. If healing is slow, curetting the diseased bone is often beneficial.

Plastic operations to correct deformities may later be undertaken, but not until all ulcerations have healed and the patient's general health has been re-established.

TUBERCULOSIS OF THE PHARYNX.

Etiology. Pharyngeal tuberculosis may be primary or secondary. Primary infection of the pharynx with tubercle bacilli is exceedingly rare—so rare in fact that until within the past few years it was thought never to exist. The infection is probably due to the existence of some wound or abrasion of the mucous membrane of the pharynx or tonsil whereby tubercle bacilli gain access to the submucous tissues. It is possible that primary tuberculosis may be thought to exist in some cases, in which it is really secondary to pulmonary tuberculosis, in such an early stage that the symptoms and physical signs fail to detect any involvement of the lungs. Pharyngeal tuberculosis is usually secondary to pulmonary tuberculosis, and is more frequently associated with the acute miliary form of this disease than with any other variety. Infection probably reaches the pharynx through the bloodvessels, as we know of no connection existing between the lymphatics of the pharynx and those of the lungs. Where ulceration,

especially that of syphilis, occurs in a patient suffering from chronic pulmonary tuberculosis, the sputum containing the tubercle bacilli may infect the ulcer, and thus pharyngeal tuberculosis be produced.

Pathology. The early stage consists in a deposit of miliary tubercles in the submucous tissue. This stage often passes unnoticed by the physician. There is a round-cell infiltration, with the subsequent formation of giant-cells followed by necrosis and ulceration in the infiltrated areas. Round-cell infiltration and giant-cell formation also occur in other slow-growing inflammatory processes, such as is seen sometimes in gummata, in glanders, and in actinomycosis. The only positive evidence that such a formation is tubercular in origin is obtained when the tissues are stained by Gram's method and tubercle bacilli are found in the giant-cells. The ulcerations produced are irregular in outline, at first usually small and discrete, and separated by areas of infiltrated tissues. These intervening portions rapidly break down and ulcerate, leaving the now enlarged ulcers with a very irregular outline, having the appearance that has been described as "mouse-nibbled." The margins of the ulcer are seldom elevated above the surrounding mucous membrane, and there is no marked line of congestion or inflammation surrounding a tubercular ulcer, as is so frequently seen in the other forms of ulceration in the pharynx. The mucous membrane, on the contrary, is apt to be pale pink and anemic in appearance. A small amount of muco-pus covers the site of the ulcer, which is not excavated, as are syphilitic ulcers. The common situations in which these ulcers are found are the posterior pharyngeal wall, soft palate, uvula, tonsils, and occa-

sionally the tongue. The lymph-glands in the neck are enlarged, and occasionally are broken down, cheesy, or fluctuating.

Symptoms. The symptoms of a tubercular ulcer in the pharynx are partly masked by those of the pulmonary affection with which it is so frequently associated. Those referable to the ulcer proper are: Pain in the back of the throat, in the region of the tonsil or tongue, according to the situation of the ulcer; when on the posterior pharyngeal wall this pain frequently radiates to the ear. Deglutition is usually so painful that these patients abstain from taking the necessary quantity of food rather than suffer the severe, lancinating pain caused by swallowing. Emaciation is consequently rapid. Reflex cough, the result of the pharyngeal irritation, is often observed. The temperature in these patients is that of the hectic variety; often subnormal in the morning, and rising to 100° to 102° F. in the afternoon, preceded occasionally by a slight chilly feeling or rigor. Where the soft palate is involved the action of all the muscles in this region becomes impaired, and attempts at swallowing liquids usually result in some of the fluid passing into the nasopharynx and out through the nose. The muco-pus collecting on the site of the ulcer annoys the patient; but attempts to free himself of this by coughing and hawking are so painful that he frequently allows it to accumulate, so that a rattling sound in the pharynx is heard during respiration.

Examination. In the early stage, that of miliary tubercles, the affected portions are studded with grayish, translucent spots about the size of the head of a small pin. These project above the mucous membrane,

which is almost bloodless in appearance. The tubercles are sometimes uniformly scattered over the affected parts, at others bunched in small areas. Their general appearance is not unlike that sometimes seen in the sudamina that occur on the skin. In a few days it will be noticed that these miliary tubercles have undergone ulceration. Small ulcerated areas can be seen, and the coalescence of these areas, with the gradual breaking down of other miliary tubercles, will be observed from day to day. Thick, tenacious mucus, with admixture of pus, bathes the ulcerated surface. Examination of this secretion may not at first show tubercle bacilli, as the number of these found in the ulcerated areas is not great. Repeated examinations should be made, or scrapings from the margins of the ulcer are to be stained, with greater probability of finding the bacilli.

Differential Diagnosis. The differential diagnosis is between syphilitic ulcer, diphtheria, and lupus of the throat. The differential diagnosis between tubercular and syphilitic ulcers is given in the article on Syphilis. In diphtheria there is a membrane formation which is elevated above the surface of the mucosa, and the membrane cannot be readily removed. There is no membrane formation in tuberculosis, and the secretion covering the ulcer can readily be wiped away. The margins of the diphtheritic membrane are deeply congested; those of the tubercular ulcer are pale. The Klebs-Loeffler bacilli are found on bacteriological examination in diphtheria; tubercle bacilli may be found in tuberculosis. A diphtheritic membrane disappears in a few days; the tubercular ulcer gradually extends until death ensues. Evidences of pulmonary tuber-

culosis are usually found with a pharyngeal tuberculosis; diphtheritic membrane is found only where a consumptive has contracted diphtheria.

The differential diagnosis between lupus and tuberculosis lies, first, in the slow, gradual onset of lupus; the rapid ulcerative process in tuberculosis. There is no elevation of temperature in lupus; an evening rise occurs in tuberculosis. Lupus is a painless disease; tuberculosis, an exceedingly painful one. Nodular deposits are found in the ulcerated areas in lupus, whereas none is seen in tuberculosis. Cicatrices are usually found showing healed areas that have been involved in lupus; these are exceedingly rare in tuberculosis. The soft palate and the uvula are the commonest sites for lupus, whereas the posterior pharyngeal wall is more commonly affected in tuberculosis.

Prognosis. The prognosis in pharyngeal tuberculosis is bad. A few cases of healed tuberculosis have been reported, but the great majority succumb in from a few days to a few weeks at most.

Treatment. The treatment should be both constitutional and local.

The constitutional treatment is directed to maintaining the nutrition at the highest possible point. The diet should be composed chiefly of liquids, and where these cannot be swallowed they should be introduced by means of the stomach-tube or by rectal alimentation. Cod-liver oil, hypophosphites, and beechwood creosote in large doses are to be administered. The patient should live in the open air as much as possible.

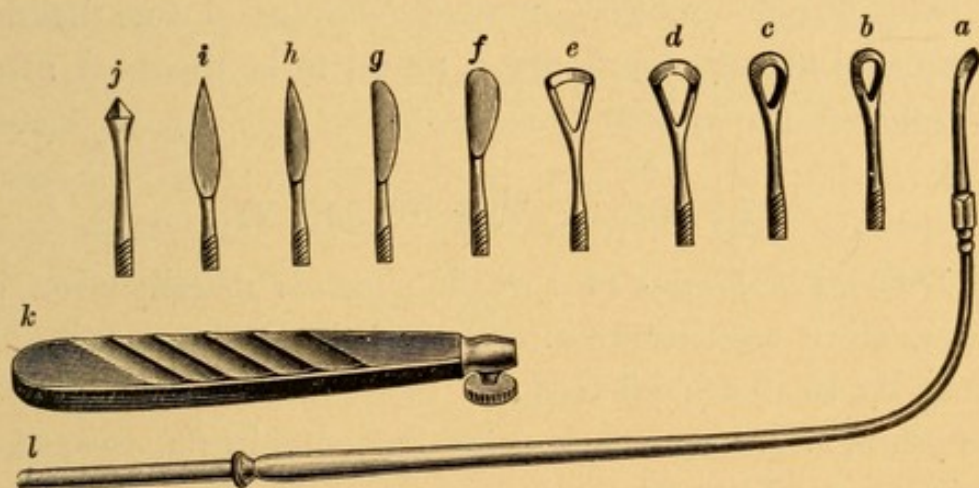
The local treatment consists in prescribing a spray, by which the tenacious secretion can readily be removed from the ulcerated areas :

R.—Sodii bicarb.	gr. xv.
Sodii chloridi	gr. iij.
Listerine	3 j.
Aquæ	q. s. ad.	3 j.

M. et Sig.—Use in atomizer.

The ulcer should then be painted twice with a 20 per cent. solution of cocaine, allowing an interval of five minutes between the applications. Its surface should be curetted. Heryng's curettes (Fig. 99, *a*, *b*, and *c*) are

FIG. 99.



Set of Heryng's knives and curettes.

well adapted to this purpose. If these are not obtainable, the Grünwald curettes (Fig. 72, *a*) may be employed. The operation is usually attended with great pain, notwithstanding the use of the strong solution of cocaine. After curetting the blood should be wiped away with a cotton-wound applicator, and a 40 per cent. solution of lactic acid in water be applied to the raw surface with a cotton-wound applicator. An application of lactic acid should be made every three days, the strength of the acid being increased 5 or 10 per cent. each time, according to the reaction, until finally the full strength of the acid is employed. Gelatin tablets, containing $\frac{1}{4}$ grain

of cocaine, should be prescribed half an hour before taking food, with directions to hold one in the mouth until it has dissolved. This somewhat diminishes the pain of deglutition, so as to enable the patient to take nourishment.

Orthoform has been highly recommended to be applied to the raw surface of the ulcer (after cleansing it from mucus), to diminish the pain and make deglutition more easy. It has not been very satisfactory in our hands.

The galvano-cautery may be employed for the destruction of any small areas found to be diseased after the use of the curette.

LUPUS OF THE PHARYNX.

Etiology. Lupus of the pharynx is usually seen in connection with lupus in other portions of the body, especially in the facial region. It occurs most commonly in young adults, and is more frequent in females than in males. It is often seen in those in whom there is a family history of tuberculosis.

Pathology. There is infiltration of the mucous membrane and submucous tissues with small round-cells. These cells have a tendency to be bunched, so as to form nodules on the surface; and tend to undergo slight ulceration without much accompanying secretion. The lupus formation is peculiar in that some of these nodules appear in the ulcerated stage; other portions of the tissue show healed cicatrices, the result of the ulceration; while neighboring areas show the nodule formation prior to that of ulceration. Tubercle bacilli are found but very sparsely in the nodules. Lupus is considered to be a form of tuberculosis in which the

attenuated bacillus is not very virulent. The parts most commonly affected are the soft palate and the uvula. The posterior pharyngeal wall is rarely affected. Lupus of the pharynx is usually sooner or later complicated by laryngeal lupus.

Symptoms. The symptoms of pharyngeal lupus are mainly due to the stiffness and inflexibility of the soft palate and the mechanical interference with its functions. Deglutition may be slightly impaired, owing to the rigidity of the soft palate. Liquid food is commonly regurgitated through the nose. The voice frequently has a nasal twang. Pain is rarely present, the parts being usually anesthetic rather than hyperesthetic. The lymphatic glands in the neck are usually not enlarged. When the larynx becomes involved, as it usually does, the additional symptoms will be those mentioned in the article on Laryngeal Lupus.

Differential Diagnosis. This disease is to be differentiated from syphilis, tuberculosis, and malignant disease of the soft palate. In syphilis the onset of the disease is sudden; in lupus it is gradual. Deep ulcers, with mucopurulent discharge, are found in syphilis; nodule formation, slight ulceration, little or no discharge, in lupus. There is usually pain in syphilitic ulcer; none in lupus. Large doses of potassium iodide very favorably affect syphilitic ulcers, but have no influence upon lupus. The differential diagnosis between a tubercular ulcer and lupus is given in the article on Tuberculosis of the Pharynx.

Malignant disease of the soft palate is distinguished from lupus by a very rapid course, the accompanying pain, the enlargement of the lymphatic glands of the neck, the greater age of the patient, and, lastly, by

microscopical examination of a portion of the excised growth.

Treatment. The constitutional treatment of lupus should aim to maintain nutrition at the highest possible point. For this purpose a change of air and residence if possible in a climate where patients can be out of doors the greater part of the time, as in Southern California and New Mexico, are to be advised. Cod-liver oil, syrup of the iodide of iron, and arsenic, all seem to have a favorable influence on these patients.

The local treatment consists in applying the galvano-cautery to the nodules, thus destroying them, following with the application of lactic acid, as described in the article on Pharyngeal Tuberculosis. Curetting may also be used for the removal of infiltrated areas.

Tuberculin hypodermatically has been employed. The reaction from it is often very severe, and great care should be exercised in its use.

MYCOSIS OF THE PHARYNX (Pharyngomycosis).

A parasitic disease of the tonsil, tongue, and pharyngeal mucous membrane, due to the presence of fungi of the class mycosis. The *leptothrix buccalis* is the fungus most commonly found.

Etiology. The *leptothrix buccalis* is almost invariably found in the secretions of the mouth, especially where the teeth are decayed. It is frequently present in the cheesy masses in the lacunæ of hypertrophied tonsils. Why these persons are not invariably affected with the peculiar growth of the *leptothrix* as seen in mycosis is not understood. The disease occurs most frequently between the ages of twenty and thirty-five, although it has been noticed in infants and in the aged.

Pathology. The leptothrix penetrates the glands found in the mouth at the base of the tongue, on the posterior pharyngeal wall, the lacunæ of the tonsils, and the glands of the nasopharynx. Active multiplication of the threads takes place, which grow through the epithelial cells and appear on the free surface of the mucous membrane. Here they present as whitish, grayish, or slightly yellowish conical elevations, the base attached to the mucous membrane, and the apex, sometimes forked, projecting into the cavity of the pharynx. Their size varies from a mere speck to that of a grain of rice. The mucous membrane surrounding these masses is usually normal in appearance. Examined microscopically they are seen to consist of granular material, in which a few epithelial cells of the part and numerous small, rod-like masses may be found. These, when weak Lugol's solution is applied to them, stain blue, and are seen to be jointed and to contain spores. The saliva in mycosis is often acid in reaction.

Symptoms. Where few in number no symptoms may result from the presence of the mycotic masses. They are often accidentally discovered while examining the throat of a patient. At other times patients complain of irritation and a tickling or pricking sensation in the throat, which may be aggravated during swallowing. An irritating cough may be present.

Examination. Examination of the throat shows white conical masses in the regions described. At first they may be mistaken for the cheesy material that is found in the lacunæ of the tonsil. When attempts are made to wipe them away with a cotton-wound applicator it is found that they are firmly attached to the mucous membrane. If grasped with a forceps, it will

be found that they are so firmly attached that the mucous membrane of the pharynx can frequently be pulled up, cone-like, before they break away.

Prognosis. It is usually a tedious matter to eradicate these mycotic masses, months often elapsing before they are all destroyed. Unless the portions deep down in the mucous membrane are destroyed, they quickly re-form.

It occasionally happens that these growths disappear spontaneously in a short time without treatment.

Treatment. The best method of ridding the parts of these masses is by the use of the galvano-cautery electrode. The point of the electrode should be small and inserted deeply into the root of the mass, penetrating the mucous membrane at least one-eighth of an inch. As the number of these masses is great, and it is impossible to cauterize many at one sitting, their removal is usually slow. A spray containing bichloride of mercury (1 : 3000) may be employed to disinfect the pharynx. This frequently checks the growth. Care must be taken that the solution is not swallowed. Pyoktanin blue, rubbed into the affected parts, may be tried where the number of growths is large. It is sometimes efficacious.

FOREIGN BODIES IN THE PHARYNX.

Foreign bodies may be lodged in almost any part of the pharynx. The places in which they are most commonly found are the tonsils if these be enlarged, the glosso-epiglottic fossæ, pyriform fossæ, pillars of the fauces, uvula, and the junction of the laryngopharynx with the esophagus. The foreign substances are most frequently fish-bones, sharp pieces of chicken-bone, etc.,

which are accidentally taken in with the food. Pins, needles, pieces of straw, and other sharp particles held in the mouth may, during the act of swallowing, lodge in these places. Demented and insane patients occasionally attempt to swallow a very large bolus of unchewed food, which lodges in the narrowest part of the digestive tract, at the entrance into the esophagus. False teeth have been known to become displaced during sleep and lodge in the pharynx.

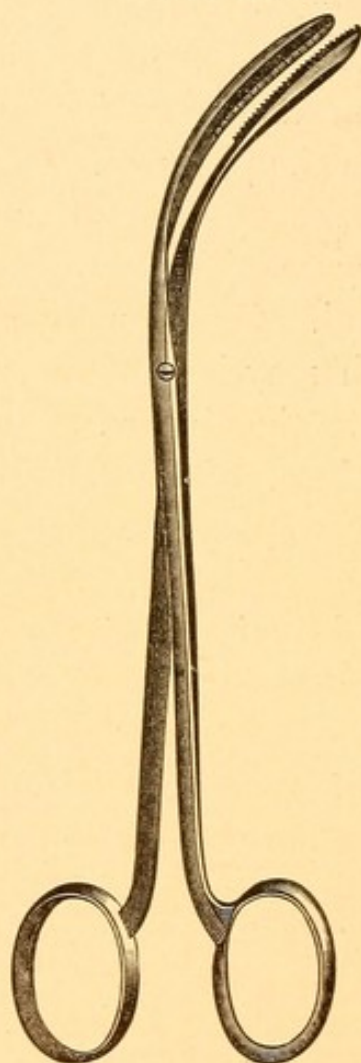
Pathology. Where foreign bodies are found and quickly removed only a slight degree of inflammation is found at the site of the wound. Occasionally an abscess results, the pus from which may burrow downward along the esophagus and into the thorax. Pins and needles have been known to become encysted and gradually, years after, work their way out at distant portions of the body.

Symptoms. Small, sharp-pointed foreign bodies usually cause pain, most severe during deglutition. The pain is not always referred to the spot at which the foreign body is situated, owing to the peculiar distribution of the sensory nerves in the pharynx. The pain is usually referred to just behind the larynx, although the foreign body may be situated at the base of the tongue or at some other portion of the pharynx. Pain often persists for a day or two after removal of the foreign body. When the object is large and lodges in the lower part of the laryngopharynx it is very apt to block the entrance into the larynx, and, unless quickly removed, produce severe dyspnea, asphyxia, and death. An abscess occasionally results from the entrance of pus-producing germs along with the foreign body. With the discharge of pus the foreign

body is frequently either passed on into the stomach or coughed up.


Examination. The parts should be thoroughly cocainized, and with the best illumination possible the region

FIG. 100.



Forceps of Buck, opening antero-posteriorly.

FIG. 101.



Forceps of Fauvel, opening laterally.

in which foreign bodies are especially likely to lodge should be examined with the aid of a mirror. Care should be taken to search for any area of localized inflammation. In this way the foreign body will usually be found. When the parts are too sensitive to allow of

examination with a mirror the forefinger should be inserted and the offending particle felt for. Fish-bones not infrequently bury themselves in the substance of an enlarged tonsil, so that only a very small portion of the bone remains visible. *are often decalcified.*

Treatment. When located the best method of removing foreign bodies is with a pair of curved forceps, used so as to grasp the foreign body, the region in which it lies being well illuminated with the laryngeal mirror. The operator should have the choice of two forms of forceps for the removal of foreign bodies—one, a forceps opening antero-posteriorly (Fig. 100), and the other opening laterally (Fig. 101). Whichever form can be made to grasp the substance the more readily should be employed.

The umbrella-like probang which is so frequently employed for the removal of foreign bodies is seldom of any use. It merely scratches and inflames the mucous membrane without removing the body. Where induration or abscess formation is discovered it is to be incised, so as to evacuate the pus and prevent its burrowing into dangerous regions. If this cannot be done fully through the mouth, an external opening down to the abscess should be made.

NON-MALIGNANT TUMORS OF THE PHARYNX.

Benign growths of almost every variety have been found springing from the various portions of the pharyngeal mucous membrane. Papilloma is by far the most common, perhaps equalling in number that of all the other varieties combined. We shall enumerate the several varieties of tumors that have been found on the various portions of the pharyngeal mucous mem-

brane and give the symptoms most commonly complained of:

Uvula and Pillars of the Fauces. Papilloma, angioma, fibroma, adenoma, polyp, and dermoid cyst.

Soft Palate. Papilloma, adenoma, angioma, fibroma.

Posterior and Lateral Pharyngeal Wall. Papilloma, adenoma, fibroma, polyp, chondroma, osteoma, and dermoid cyst.

Tonsil. Adenoma, fibroma, polyp, and chondroma.

Tongue—Posterior Portion. Adenoma, papilloma, angioma, fibroma, and dermoid cyst.

Symptoms. Small tumors, especially of the papillomatous variety, may exist in these regions without producing symptoms, and only be discovered accidentally by a physician while examining the patient for other diseases. Movable tumors, when of moderate size, produce, first, a sensation as of a foreign body in the throat, and, secondly, a tickling, with probably a cough as the result. Large-sized tumors, in addition to these symptoms, may cause difficulty in swallowing and impairment of the normal vocal sounds, so that the patient either talks as if his mouth were full or with a nasal twang to the voice. Pain is seldom complained of.

Examination. Examination of the pharynx reveals a tumor varying in size and appearance according to the variety.

A papilloma is usually a small, wart-like growth, whose point of attachment is by an extremely small pedicle. Papillomata on the uvula and anterior surface of the soft palate may have a broad base of attachment. Their color is usually paler than that of the surrounding mucous membrane. When they are pen-

dulous and hang well down in the buccal cavity their inferior portion may be reddened and slightly edematous.

Angiomata are usually readily distinguished by their dark-red or purple color, and by the dilated, often pulsating vessels. They may be small or large, and have either a small or a broad point of attachment to the mucous membrane.

Fibromata are irregularly rounded, pale in color, varying in size from that of a pea to that of a walnut, usually attached by a very small pedicle, and firm and hard when felt with the finger.

Adenomata are sometimes pedunculated and at other times are partially buried in the tissue from which they spring. They are usually firm and dense, but not to the same degree as the fibromata. Their surfaces are apt to be more regular than those of the fibromata. It is often difficult to distinguish between these two varieties of tumors before they have been removed.

Polypi may be small or large, are pear-shaped, and are attached by a small pedicle. Their color is grayish, resembling somewhat that of nasal polypi. If large, so that they are freely moved about in the buccal cavity during deglutition, their surfaces may be red, but smooth, unlike that of a fibroma. They are much softer in consistency than any of the other tumors excepting the dermoid cysts found in this region.

Dermoid cysts appear as large or small, rounded, pale or reddish-colored elevations, according to whether their surfaces are inflamed or not. When felt with the finger they give a distinct sense of fluctuation.

Chondromata are usually rounded in appearance, attached by a broad base, pale in color, and very firm when touched with a probe and finger.

Osteomata resemble chondromata, but their bony character can usually be determined by palpation.

Differential Diagnosis. The differential diagnosis between a malignant and a non-malignant growth can usually be made quite readily. The main features of a non-malignant tumor are the slow growth, the circumscribed character of its point of attachment, the extreme mobility, and the absence of pain or tendency to ulceration or enlargement of the lymphatic glands of the neck. When doubt exists, a microscopical examination should be made of thin sections of the tumor, which usually suffices to show its character.

Prognosis. Non-malignant growths, when small, are easily removed and do not return. Some patients seem to have a papillomatous diathesis, and other papillomata may subsequently appear. The larger and harder growths, as the chondromata and osteomata, may demand a capital operation for their removal, which is attended with some danger to the life of the patient.

Treatment. The pedunculated, non-vascular growths, papillomatous or otherwise, may be removed under cocaine with the cold wire snare, the stump being subsequently cauterized with the galvano-cautery point. Angiomata or other very vascular growths, if pedunculated, are best removed with the galvano-cautery snare. If attached by a broad base, it is better to cauterize, with the galvano-cautery point, small portions of the growth at one sitting, and repeat the process once a week until the entire growth is eradicated. A tumor that has a broad attachment can usually be removed, under cocaine, by making an incision over the most prominent part of it, peeling back the mucous membrane, and shelling out the growth. Where, however, the growths

are very large, or chondromatous or osteomatous in nature, a general anesthetic may have to be employed, and an extensive operation with a knife, chisel, and gouge be undertaken.

MALIGNANT GROWTHS OF THE PHARYNX AND TONSIL.

These growths are usually of the varieties known as sarcoma, lymphosarcoma, epithelioma, or scirrhus-carcinoma.

Etiology. The factors tending to produce malignant growths in these regions are not known. They have been ascribed to excessive smoking or irritation from other causes, but how far these really go toward producing this disease is very doubtful.

Sarcomata appear at all ages, in the young as well as in the old.

The varieties of carcinomata are seldom seen before the fortieth year, and become more frequent as age advances. They are found on the posterior and lateral walls of the pharynx, at the base of the tongue, and in the tonsil.

Epitheliomata may appear upon the uvula and soft palate.

Symptoms. The symptoms depend upon the character of the growth. Sarcomata grow rapidly, usually are not accompanied by much pain, but interfere with deglutition, and, where the growth presses upon the larynx, cause considerable dyspnea. The cervical lymphatic glands are not enlarged until ulceration in the growth is observed.

Epitheliomata grow very rapidly, and are accompanied by considerable pain, which, if the growth in-

volves the lateral walls of the pharynx or the tonsils, usually radiates to the region of the ears. Deglutition and respiration are markedly interfered with. The glands of the neck are involved early, usually even before ulceration. The tendency of this variety of growth is to ulcerate early and to be accompanied by a bloody, mucopurulent discharge. Hemorrhage may be severe. A peculiar sallow cachexia of the skin is observed. Emaciation, owing to the inability to swallow food, is very marked.

The scirrhus variety, which is not common in this region, grows much more slowly, and is accompanied by pain and slight, but progressive, enlargement of the cervical lymphatic glands, ulceration occurring very late in the disease. Cachexia is present.

Examination. Where the growth involves the tonsil, this will be seen to be enlarged, reddish in color, and irregular in outline. On the more exposed surface of the growth ulcerations may be seen, and these, when touched with a probe, bleed readily. There is a marked tendency for the infiltration to involve the anterior pillar of the fauces and to extend down this and involve the tongue at its postero-lateral border, or to extend upward and cause thickening and induration of the soft palate above the tonsil. When the posterior pillar of the fauces becomes involved the growth rapidly infiltrates the tissues in this region, extending up into the nasopharynx and down into the oropharynx. Felt with the finger, the growth is found to be firm and hard, not very movable, and usually painful to the touch. Where the growth involves the postero-lateral wall of the oropharynx it may only be seen with the aid of a laryngoscopic mirror. Its color is a deep red, deep maroon, or

purple; ulcerations may be visible, and the larynx is usually displaced either forward or laterally according to the situation of the greatest mass of the growth. The finger when introduced into the pharynx encounters a firm, dense mass filling the normal channel in this region, and when the finger is withdrawn it is very frequently found blood-stained. No examination of a suspicious growth in any of these regions should be considered complete without having cocainized a portion of the surface of the growth, and with a pair of punch forceps, such as those shown in Fig. 72, *a*, excising a piece of tissue, which should be examined microscopically.

Prognosis. The prognosis in sarcoma is better than that in other varieties of malignant growth. If small and encapsulated, the growth often does not return after removal. Adenosarcomata, epitheliomata, and scirrhus can seldom be eradicated so completely that they will not return, and eventually end the life of the patient.

Treatment. In cases of sarcoma the growth should be removed under a general anesthetic by a surgeon. Where it returns after such an operation the galvano-cautery snare, used as described for the removal of hypertrophied tonsils, may be employed to diminish the size of the growth, and thus lessen interference with deglutition and respiration.

The treatment of the other varieties should, we think, depend upon the amount of involvement at the time a patient is first examined. When the growth is diagnosed early, before very much involvement of the cervical lymphatic glands has taken place, the growth and the glands should be thoroughly removed by a surgeon. This operation is usually a serious one for the patient,

as the disease not infrequently is found by the operator to be more advanced than was at first suspected. The chances are that the growth will return, but the operation, if successful, generally prolongs life for several months. Where the growth has extended beyond the tonsil into the soft palate to the lateral nasopharyngeal wall, and has involved the tongue and implicated the cervical lymphatic glands to a great extent, it is impossible to eradicate it from all these regions, and no general operation is to be advised. All that can be done then is to remove by the galvano-cautery snare the large pieces of tissue that project into the pharynx, so that deglutition and respiration may be less difficult. When the malignant growth is situated at the lower part of the oropharynx, or involves the laryngopharynx, there is little prospect of any radical operation being done that will relieve the patient. When deglutition becomes markedly interfered with, gastrostomy should be performed and the patient fed through a canula. When the growth overrides the entrance into the larynx, producing great dyspnea and danger of death from asphyxia, then tracheotomy must be resorted to. The patient should be kept free from pain by the use of morphine. Cleansing sprays are to be used to keep the parts clean.

NEUROSES OF THE PHARYNX.

The neuroses of the pharynx may involve (1) the motor and (2) the sensory nerves.

(1) Neuroses Involving the Motor Nerves.

Spasms. Spasmodic action of the motor nerves of the pharynx causes a sensation as of a lump in the

throat, producing the condition known as globus hys-
tericus. This spasmodic condition may be caused by excessive irritability in the central nervous system, such as results from hysteria, in which globus hystericus is a common symptom. It may be produced reflexly by slight inflammatory conditions in the mucous membrane of the pharynx, and is very commonly associated with two conditions at the base of the tongue, already described—namely, lingual varix and hypertrophy of the lingual tonsil. In the latter condition there is, of course, an actual increase of the tissue at the base of the tongue, which may in part account for the sensation of a lump in the throat. Spasmodic contractions of the pharyngeal muscles are occasionally seen in severe cases of chorea. The origin of the spasm in these cases is central. Associated with the spasm that is seen in globus hystericus there is occasionally a spasm of the muscles of deglutition, including those of the esophagus, whereby air contained in the pharyngeal cavity is swallowed, and enormous distention of the stomach and intestines, simulating peritonitis, may be produced. Eructations of large quantities of the swallowed air may subsequently be observed.

Treatment. Before beginning the treatment of globus hystericus a careful examination should be made to determine the presence of any local inflammatory condition in the throat, paying special attention to the region at the posterior portion of the tongue. Relief of any diseased conditions detected in this region assists greatly in controlling the spasm. The effect of this treatment may be partially psychic. Constitutional treatment directed toward the nervous temperament of the patient should also be given. Sedatives, such as valerian,

globus hystericus
hysteria
lingual
varix
hypertrophy
lingual tonsil
chorea

asafetida, and the bromides, are among the most valuable. The choreic spasm can only be corrected by appropriate medication directed to the disease of which this is a part. The swallowing of the air is usually purely a hysterical act, the remedy for which is the administration of the above-mentioned drugs.

Paralysis. Paralysis of the pharyngeal muscles is usually the result of diseased conditions affecting the nerve cells in the brain. One of the commonest forms of paralysis is that which has been described as a sequela of diphtheria and streptococcus infection of the throat. Paralysis of the muscles on one side of the pharynx sometimes accompanies cerebral apoplexy, and affects the muscles of the same side of the pharynx as that on which the facial muscles are paralyzed. Examination of the throat in these cases shows the uvula curved and drawn over to the non-paralyzed side. If gagging be excited while the tongue depressor is in the mouth, the non-paralyzed side of the soft palate can be observed to approximate itself in the normal way to the posterior pharyngeal wall, while the paralyzed side is only partially drawn back and may not come in accurate contact with the posterior pharyngeal wall, thus producing an alteration in the voice, which has a nasal twang, and allowing liquids during deglutition to pass into the nasopharynx and out through the nose. This form of paralysis is frequently recovered from as the other facial muscles regain their functional activity.

Paralysis of the pharyngeal muscles is seen in glosso-labio-lingual paralysis (bulbar paralysis). Paralysis of this nature is rarely recovered from, as the disease is progressive, usually resulting in death.

Basilar meningitis sometimes produces a paralysis of

the pharyngeal muscles. Deglutition in these cases is exceedingly difficult—so much so that the patient may have to be fed by means of a stomach tube.

It occasionally happens that acute inflammations of the mucous membrane involve the muscles of the pharynx to such an extent as temporarily to cause a paresis or paralysis in them. With subsidence of the inflammation these muscles usually regain their function.

Treatment. The application of the faradic current has been advised, one electrode being placed in the mouth and the other at the back of the neck, stimulating these muscles until such time as the central lesion can be cured. Strychnine, gr. $\frac{1}{30}$ three times a day, may be given with beneficial results.

(2) Sensory Neuroses of the Pharynx.

Anesthesia. Anesthesia of the pharyngeal mucous membrane frequently accompanies the motor paralyses of the pharynx. It is occasionally observed in hysterical patients, and is often seen in the insane.

Hyperesthesia. Hyperesthesia of the pharyngeal mucous membrane accompanies most of the acute and many of the chronic inflammatory conditions of the mucous membrane. It is commonly met with in hysterical and neurotic individuals.

Paresthesia (perverted sensibility) manifests itself as a sense of suffocation, a tickling or an itching in the throat, or a feeling that there is a foreign body situated there. These conditions are frequently seen in neurotic patients, and may occur reflexly where obstructive lesions in the nose are found.

Treatment. The treatment of the above conditions

should be directed to the state of the general health. Tonics, as iron and cod-liver oil, and sedatives, as asafetida, valerian, and bromide of potassium, give the best results. Change of scene and interesting the patients in pursuits that will divert their mind from their condition very materially assist in the cure.

CHAPTER X.

DISEASES OF THE LARYNX.

ACUTE LARYNGITIS.

AN acute inflammation of the mucous membrane of the larynx.

Etiology. PREDISPOSING CAUSES. Acute laryngitis is predisposed to in all chronic affections of the upper respiratory tract, and especially in those that produce obstruction to nasal respiration. When mouth-breathing is indulged in, the dry, cold, and dust-laden air robs the larynx of its moisture and acts as a source of irritation. Acute inflammation of the larynx is frequently thereby produced. Individuals who live a sedentary life and who take an insufficient amount of out-door exercise are particularly subject to attacks of acute laryngitis. Those who wrap the throat with a muffler or turn up the coat collar the moment they go out of doors are more subject to throat affections than those who allow the skin of the neck to become toughened by exposure in the same manner as that of the face.

The disease is met with at all ages, but owing to the lowered vitality in the aged it is more commonly seen in them. It is more frequent in men than in women. Impairment of health from any cause predisposes to this disease. It is most common in the winter months, and is particularly prevalent in the month of March.

EXCITING CAUSES. Exposure to cold draughts which strike the back of the head or the neck, and getting the feet wet, are usually the most common exciting causes of acute laryngitis. Sudden climatic changes, especially where the change is from warm to cold, with excessive dampness of the atmosphere, frequently cause an outbreak of acute laryngitis in so many individuals as to make it appear as though at such times there was an infection in the atmosphere capable of exciting inflammation in the upper respiratory tract. Inhalation of dust, as occurs in metal-workers, stone-cutters, tobacco operatives, millers, etc., often induces an acute inflammation of the larynx. The vapors of chlorine, bromine, iodine, and some of the mineral acids, as sulphuric or nitric, will cause it, and those employed where these substances are used often suffer from attacks of acute laryngitis. The introduction of foreign bodies or the application of caustics to the larynx frequently excites an acute laryngitis. Mention has been made of the fact that in applying caustic to the pharynx an excess of the material may trickle down the posterior pharyngeal wall, enter the larynx, and produce acute inflammation. Improper use of the voice, as is frequently seen in those who become hilarious and indulge in prolonged shouting during athletic contests, often induces acute laryngitis. This latter factor is more likely to excite inflammation if at the same time the individual imbibes freely of alcoholic stimulants.

Acute laryngitis is a frequent concomitant of many of the acute infectious diseases—notably influenza, measles, whooping-cough, typhoid fever, smallpox, and occasionally scarlet fever.

Pathology. There is hyperemia of the bloodvessels supplying the mucous membrane of the larynx, with a slight amount of edema and round-cell infiltration. These conditions are more marked in those regions of the larynx where the connective tissue is of a loose texture, as in the ary-epiglottic folds and ventricular bands.

Symptoms. There is first a feeling of fulness and discomfort in the throat, soon followed by a sense of tickling and a dry, irritating cough. The cough, after the first day, is apt to be accompanied by a feeling of rawness in the larynx, extending downward in the median line often as far as the middle of the sternum. In the latter case the pain is due to extension of the inflammation to the trachea. At the end of forty-eight hours there is an expectoration of thick, white-of-egg-like mucus, which later may become more cloudy, owing to increase in the number of cell elements. At first the voice is rough and hoarse, especially in the morning; subsequently, as the congestion, edema, and infiltration become more marked there may be aphonia. This may be the result of mechanical interference with the function of the vocal cords owing to swelling in the interarytenoid region of the larynx, or it may be due to inflammation of the muscles interfering with their proper contraction and the consequent imperfect approximation of the vocal cords. There is usually little difficulty in respiration experienced by persons suffering from acute laryngitis. When the edema and infiltration are excessive, as in the severer forms, and in that variety which accompanies influenza, a feeling of tightness in the larynx, with difficulty in breathing sometimes amounting to dyspnea, may be observed.

CONSTITUTIONAL SYMPTOMS. The disease is often ushered in by a chilly sensation, occasionally even by a distinct chill; the temperature may be elevated two or three degrees above normal, the pulse keeping pace with the temperature range. The bowels are constipated, the tongue coated, and there is malaise. The constitutional and local symptoms of acute rhinitis and pharyngitis, which so frequently accompany this affection, may also be present.

Examination. Examination of the larynx usually shows the mucous membrane of the epiglottis (Fig. 3, Plate VII.) reddened, and the vessels coursing over its surface plainly visible and distended with blood. In mild forms of acute laryngitis the redness and swelling of the mucous membrane may be limited to the epiglottis, ventricular bands, and the ary-epiglottic folds. The tracheal mucous membrane is usually inflamed. The vocal cords may be normal in appearance. A better view of the vocal cords is obtained in the phonatory than in the respiratory position. In the more severe cases these may be light pink in color, with here and there a dilated bloodvessel. In the severest forms the vocal cords may be so reddened as to be scarcely distinguishable from the ventricular bands. In these latter cases the ventricular bands and the ary-epiglottic folds are usually intensely congested and edematous, the ventricular bands being swollen to such an extent as to leave very little of the vocal cords visible, even during phonation. The nose, nasopharynx, and pharynx will generally be found to present the appearances peculiar to acute inflammation of these regions.

Differential Diagnosis. The sudden onset and the

laryngoscopic appearances usually leave no room for doubt as to the character of the inflammatory process.

Prognosis. The prognosis is good, the affection usually lasting from three to ten days. In the weak and debilitated it may continue somewhat longer.

Treatment. The treatment of acute laryngitis may be divided into constitutional and local.

CONSTITUTIONAL TREATMENT. It should be remembered that acute laryngitis is frequently associated with acute rhinitis and pharyngitis, and that the constitutional treatment appropriate for any one of these affections is suitable for all three. At the onset of the disease, tincture of aconite, administered in drop doses every fifteen minutes until perspiration is induced, often seems to mitigate the severity of the malady. The patient should remain in-doors, in a warm room, and in severe cases remain in bed. Free evacuation from the bowels should be produced by administering calomel at night, followed by a saline aperient in the morning. After the second day, if thick, tenacious mucus accumulates in the larynx over night, it may be loosened, so that cough and expectoration are made free, by prescribing a glass of very hot milk, to be sipped slowly as soon as the patient awakens. This stimulates the glands to increased activity and makes expectoration of the mucus easier. At this stage the cough often becomes very annoying, and the two drugs which seem to be most valuable in allaying this, without interfering with the secretion of the glands, are codein, administered every four hours, in doses of half a grain, or one-twelfth of a grain of heroin every four hours. The latter drug sometimes causes severe headache and occasionally nausea. A stimulating expectorant is also valuable.

Bed.

Bowels

Hot drink

Codein

Stimulant

Expectant

PLATE VII.

MODIFIED FROM SCHNITZLER'S ATLAS.

Fig. 1. The normal larynx as it appears during inspiration.

Fig. 2. The normal larynx as it appears during phonation.

- a. Epiglottis.
- b. Left ventricular band.
- c. Left vocal cord.
- d. Eminence marking the site of the left cartilage of Wrisberg in the ary-epiglottic fold.
- e. Eminence marking the site of the left cartilage of Santorini and practically also that of the arytenoid cartilage in the ary-epiglottic fold.
- f. Interarytenoid space, with a slight amount of the upper portion of the posterior wall of the larynx visible.
- g. Trachea with its rings.
- h. Right ventricle of the larynx.

Fig. 3. The larynx in a moderate attack of acute laryngitis.

Fig. 4. Early stage of tubercular laryngitis. Localized hyperemia and thickening on the posterior portions of the vocal cords. Infiltration of the posterior wall of the larynx with tubercle formation. Pale, edematous swelling of both ary-epiglottic folds obliterating the eminences of Wrisberg. Anemia of the laryngeal mucous membrane.

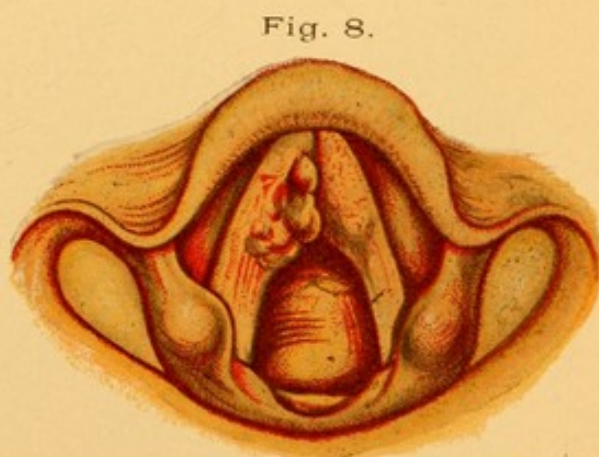
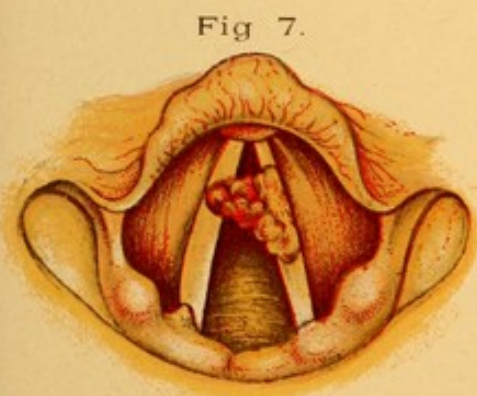
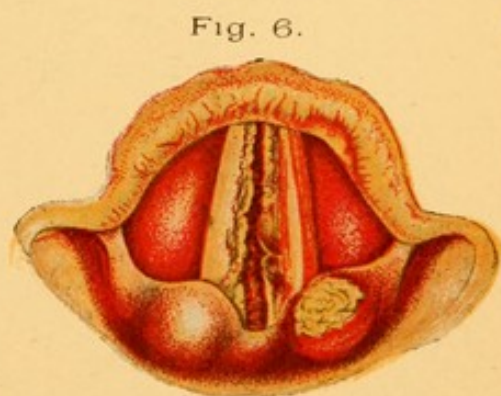
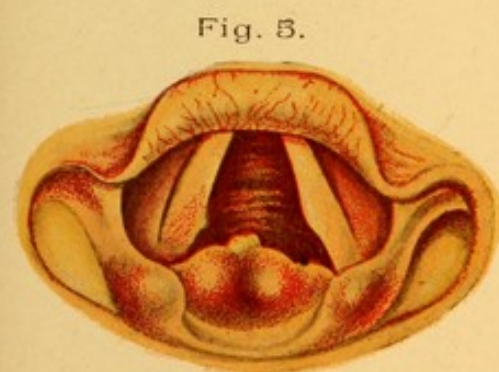
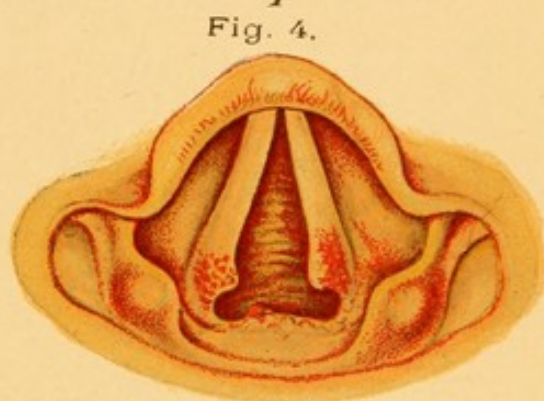
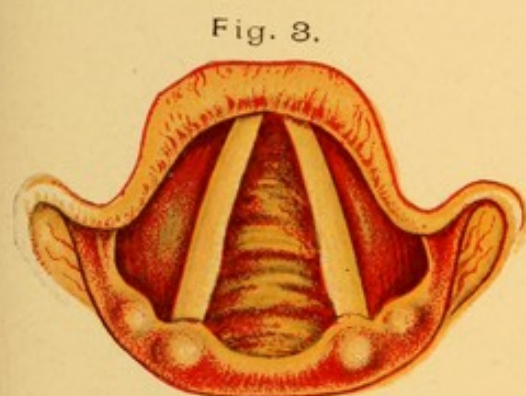
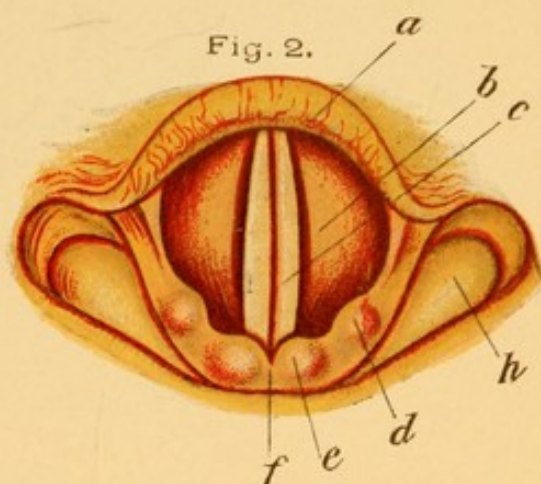
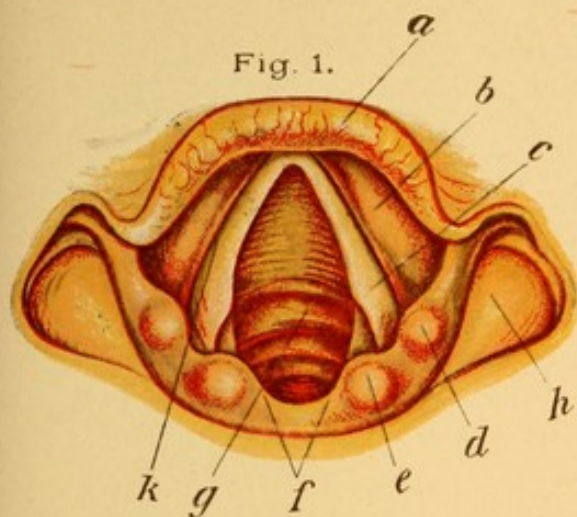
Fig. 5. Large, lobulated, tubercular infiltration on the posterior wall of the larynx. Commencing ulceration at the most prominent part of the growth.


Fig. 6. Tertiary syphilitic ulcer of the left ary-epiglottic fold and margins of the vocal cords. The right ary-epiglottic fold is the seat of a gumma that has begun to soften. The under portion of the epiglottis on the left side is superficially ulcerated from contact with the secretions of the ulcer on the ary-epiglottic folds.

Fig. 7. A papilloma attached by a broad base to the left vocal cord. It extends across the glottis and rests upon the right vocal cord. Owing to the weight of the tumor the action of the left crico-arytenoideus posticus is impaired and the left vocal cord is straighter and abducted less than the right one.

Fig. 8. An epithelioma involving both vocal cords. The left is merely infiltrated, while the right is ulcerated slightly. The deep red or purplish color of the passive hyperemia should be contrasted with the appearance of the mucous membrane in other inflammatory conditions.

PLATE VII





After the first forty-eight hours we frequently prescribe for this purpose:

R.—Ammonii chloridi ʒij.
 Syr. scillæ,
 Syr. toluani āā ʒj.
 Spts. ætheris nitrosi ʒss.
 Elix. simplicis q. s. ad. ʒiv.
 M. et Sig.—A teaspoonful in water every four hours.

Codein may be combined with this prescription if thought desirable. We usually administer them separately, for the codein may be dispensed with while the expectorant mixture is still required.

Those whose vocations necessitate the use of their voices in singing or public speaking should be enjoined not to use them as long as the acute laryngitis continues. There is great danger of straining the weakened muscles, increasing the congestion and inflammation, and permanently injuring the voice should one attempt to follow his vocation at such a time.

LOCAL TREATMENT. Local treatment consists in absolute rest for the voice, the person speaking as little as possible, and then only in whispers. Counter-irritation over the larynx and upper portion of the chest—employing turpentine, either in full strength or mixed with an equal part of sweet oil—gives great relief. This mixture should be rubbed in each night until redness and smarting of the skin are produced. The application of cold to the larynx, either in the form of cold compresses, or, preferably, the cold coil, often diminishes the swelling and favors quick return to normal conditions. We do not believe that local astringent applications to the larynx with a cotton-wound applicator or laryngeal brush are beneficial, but, on the con-

Rest
Counter-
irritation
cold
Spray
(oil ad.)

trary, we are of the opinion that they frequently aggravate the condition.

The best method of applying drugs to the interior of the larynx in acute diseases is in solution in an oily substance used in an oil atomizer. Each time the bulb is compressed the patient should take a deep inspiration. The fine spray is then drawn into the larynx and trachea with the inspired air.

The formulæ given in the articles on Acute Rhinitis and Pharyngitis may be employed in this disease. They facilitate expectoration of the thick, tenacious mucus, and diminish the congestion of the mucous membrane.

Acute Laryngitis in Children.

Acute laryngitis in children may be of the simple variety, in which the symptoms do not markedly differ from those described in the preceding article; but severer forms, in which special symptoms occur, call for a separate description.

Etiology. The etiology of acute laryngitis in children is similar to that for the affection in adults.

Pathology. The structure of the mucous membrane of the larynx of a child differs from that of the adult in that the connective tissue in the region of the ary-epiglottic folds and ventricular bands, and that immediately below the vocal cords, in what is known as the *subglottic* region, is very loose in texture, and when infiltrated becomes more edematous than that found in the corresponding regions in the adult. In the small larynges of children this edema causes relatively a greater obstruction to respiration than is seen in the case of adults.

Symptoms. In addition to the cough and hoarse

voice, or aphonia, as previously described, dyspnea is a marked symptom in severe cases of acute laryngitis in children. The cough is often of the character known as croupy. This is usually more marked at night-time, and disappears or is not so severe during the day, only to reappear the succeeding night. In aggravated cases the croupy cough and dyspnea may be as severe as those observed in membranous laryngitis, or which have been described in the article on Laryngeal Diphtheria.

Examination. It is seldom possible to examine the larynx of a child, but where such examinations can be made the ary-epiglottic region will be found to be very edematous, the swollen mucous membrane often making it impossible to get a view of the posterior portions of the vocal cords. The subglottic mucous membrane may also be observed to be swollen, appearing as a bright-red band situated below the vocal cords, and convex toward the median line. The appearance is that of three bands, the upper being the ventricular band, the middle the vocal cord, and the lower the edematous subglottic tissue.

Differential Diagnosis. This form of laryngitis is to be distinguished from membranous laryngitis or diphtheritic laryngitis.

From slight membranous laryngitis it can seldom be differentiated, owing to the inability to get a view of the larynx to ascertain the presence or absence of a membrane. Diphtheritic laryngitis is usually accompanied by the presence of a membrane in the pharynx, in the larynx, or in both. The depression from which the child suffers in diphtheria is more marked than that seen in acute laryngitis. While there may be a

slight amelioration in the symptoms of membranous laryngitis during the day, this is not so marked as in acute laryngitis. Albuminuria usually accompanies diphtheritic laryngitis, but is rarely seen in simple laryngitis. In diphtheritic laryngitis bacteriological examination of the secretions from the throat reveals the Klebs-Loeffler bacilli, while these are not present in simple laryngitis.

Prognosis. The prognosis is usually good, although occasionally one meets with a very severe form of acute laryngitis, especially of the subglottic variety, in which it becomes necessary quickly to perform intubation or tracheotomy to prevent the child dying of asphyxia.

Treatment. The constitutional treatment in a child should consist in giving at the outset a quarter of a drop of tincture of aconite until free perspiration is induced, and following this up with inhalations of steam from a croup-kettle. It is often advisable to add a teaspoonful of the compound tincture of benzoin to the water in the croup-kettle. Hot milk, fed in teaspoonful doses at frequent intervals, seems to loosen the mucus and allow of its being coughed up more readily. Where the mucus is very tenacious and obstructs respiration by being lodged in the larynx, an emetic dose of the wine of ipecac will give temporary relief. This should not be administered to one who is weak and exhausted from the effects of dyspnea. As an expectorant—

R.—Ol. ricini,
 Syr. acaciæ,
 Syr. ipecacuanhæ āā ʒj.
 M. et Sig.—One drachm every three hours.

is very valuable in those forms accompanied by bronchitis of the large tubes. It should not be administered when bronchopneumonia is present. If the dyspnea be such that the symptoms of asphyxia—namely, cyanosis, great restlessness, and a sinking in above and below the clavicle during inspiration—are seen, then intubation or tracheotomy should be performed.

MEMBRANOUS LARYNGITIS.

An acute inflammation of the mucous membrane of the larynx, accompanied by the formation of a membrane involving the epithelial and often the subepithelial tissues.

Etiology. Membranous laryngitis is a rare disease, resulting from the application of caustics to the mucous membrane, and has been known to follow the inhalation of hot steam and smoke. It has followed injury, such as severe blows on the larynx, with or without fracture of the cartilages, and the introduction of foreign substances into the larynx. It occurs most frequently in early childhood, and may complicate a severe, acute laryngitis at this age.

Pathology. The mode of formation of the membrane and its gross pathological appearances are identical with those seen in diphtheritic laryngitis. It is not, however, to be confounded with this disease, as the Klebs-Loeffler bacilli are not present in the membrane, nor are they a pathological factor in its production. No membrane formation is observed in the pharynx or in the nose, as is usually the case in diphtheritic laryngitis.

Symptoms. The symptoms of membranous laryngitis are, first, a hoarseness of the voice followed by a

*transcendent
croupy cough
Dyspnoea
cyanosis etc.*

croupy cough. Dyspnea appears very early ; the respirations become labored and a sense of impending suffocation quickly manifests itself. The sterno-cleido-mastoids stand out prominently ; there is a sinking in above and below the clavicles during inspiration ; where the membrane is extensive, cyanosis, great restlessness, and convulsions are observed. Constitutional symptoms in this disease are rarely marked. There may be a slight rise in temperature and some acceleration of the pulse. There is seldom the grave depression in this condition met with in diphtheritic laryngitis.

Examination. When a view of the larynx can be had a grayish-white membrane is observed on the ventricular bands, ary-epiglottic folds, and occasionally on the vocal cords. If the larynx be sprayed with a 20 per cent. solution of cocaine, it is found that this membrane is firmly adherent and cannot readily be removed with a cotton-wound laryngeal applicator.

Differential Diagnosis. It is difficult to distinguish between membranous laryngitis that is non-diphtheritic from that which is diphtheritic in character. Diphtheritic laryngitis is almost invariably accompanied by the presence of a membrane in the pharynx or nose. Bacteriological examination may assist in the diagnosis. Where doubt exists as to the character of the membrane it is the safest plan to consider it diphtheritic and to treat it as such.

Prognosis. As in diphtheria, the prognosis is grave when cyanosis and evidences of imperfect aëration of the blood are observed.

Treatment. The treatment of membranous laryngitis up to the point where the membrane is sufficiently ex-

tensive to interfere markedly with respiration should be the same as that given for acute laryngitis. There is no specific, and diphtheria antitoxin is without effect in these cases. When dyspnea and cyanosis appear intubation or tracheotomy should be performed.

LARYNGEAL HEMORRHAGE.

Etiology. Hemorrhage from the laryngeal mucous membrane is of rare occurrence. It may be met with in severe attacks of acute laryngitis. It sometimes occurs when no inflammatory condition in the mucous membrane is present. It may be an early evidence of that peculiar weakened condition of the bloodvessels antedating tubercular manifestations. It has been observed in severe cases of whooping-cough, owing to the congestion of the bloodvessels of the head and neck that accompanies the paroxysms of coughing. Diseases of the heart or lungs in which there is interference with the return of the venous blood are sometimes complicated by laryngeal hemorrhage. It is occasionally seen in women as an evidence of vicarious menstruation. Laryngeal hemorrhage has been observed in those diseases of the blood in which there is marked alteration in its constituents, as in malaria, leucocythemia, chlorosis, purpura, and scurvy. Hemorrhage may accompany any form of ulceration in the larynx, especially in connection with the ulcerative stage of malignant disease.

Symptoms. Unless inflammation of the larynx exists, the only symptom observed is a tickling in the larynx, followed by cough and expectoration of blood. The amount of blood expectorated is seldom large, often not more than sufficient merely to streak the expectoration.

In acute laryngitis or ulcers the further symptoms will be those common to those conditions.

Examination. Examination of the larynx usually shows one or more hemorrhagic areas, upon which either freshly exuded, uncoagulated blood can be seen during the attack, or, more commonly, dark, clotted blood will be found upon the ventricular bands, vocal cords, or in the interarytenoid space on the posterior wall of the larynx after hemorrhage has ceased. When no inflammatory process or ulcerative disease is observed in the larynx, careful examination of the patient should be made to determine which of the other constitutional etiological factors causes the hemorrhage.

Prognosis. The prognosis in laryngeal hemorrhage depends upon the exciting cause. The amount of blood lost is rarely sufficient to produce constitutional disturbance. The blood may ooze in sufficient quantities to trickle into the trachea, bronchi, and alveoli of the lungs, and so produce symptoms of lobular pneumonia.

Treatment. The hemorrhage, if slight, usually ceases without treatment; when profuse, the patient should be kept in bed, and the coughing, which prevents clotting, should be controlled by a hypodermatic injection of one-quarter grain of morphine. The application of an ice-bag over the larynx will contract the bloodvessels and so diminish hemorrhage. The use of an astringent spray containing perchloride of iron, 10 minims; water, 1 ounce, has been recommended as a means of coagulating the blood. We have never had recourse to this measure, and we doubt whether a sufficient amount of the spray can be made to enter the larynx to be of material benefit.

EDEMA OF THE LARYNX (*Œdema Glottidis*).

Etiology. The causes of edema of the larynx may be classed as local and constitutional.

Among the local causes may be placed the edema that results from the injudicious application of caustics, as the galvano-cautery, and the injections of creosote that are sometimes used in treating tubercular infiltrations of the larynx. It also results from the lodging of foreign bodies in the supraglottic region of the larynx, and the swallowing of hot liquids or the introduction into the larynx of strong spirituous liquors. Inhalation of steam and irritating smoke has produced edema of the larynx. Prolonged and excessive use of the voice, as in shouting, may cause it. The inflammation of the larynx that accompanies erysipelas, diphtheria, influenza, measles, scarlet fever, and whooping-cough, or any other cause exciting a severe acute laryngitis, may be accompanied by edema of the tissues. The ulcerative conditions of the laryngeal mucous membrane seen in tuberculosis, syphilis, and malignant growths are frequently accompanied by edematous infiltration. Inflammations of the tissues about the larynx, especially when accompanied by abscess-formation, are very likely to produce edema. These diseases are perichondritis of the larynx, abscess of the larynx, and peritonsillar abscess.

The constitutional causes that produce edema of the larynx are Bright's disease, diabetes, those cardiac lesions accompanied by general anasarca, and the peculiar neurotic condition in which dilatation of the blood-vessels of the neck is noted, as in Ludwig's angina. The administration of large doses of potassium iodide,

and even of small doses in those peculiarly susceptible to the action of this drug, has been known to produce edema of the larynx.

Pathology. The loose areolar tissue in the ary-epiglottic folds, on the ventricular bands, that of the epiglottis, and occasionally that immediately beneath the vocal cords, in the subglottic region, is infiltrated with a pale, colorless transudation from the bloodvessels of these regions. At times, where the edema accompanies ulcerative processes, the infiltrating fluid may be turbid and seropurulent in character.

Symptoms. Edema of the larynx usually occurs quite suddenly, and is either moderate or severe in amount. The severity of the symptoms depends entirely upon the amount of the swelling and the mechanical interference with the functions of the larynx thus produced. Dyspnea of a moderate, but often of a most severe, character will be observed. The voice is usually aphonic, and there is frequently great difficulty in deglutition, owing to the projection of the edematous tissue in the ary-epiglottic folds obstructing the laryngopharynx. Dyspnea may be so marked that cyanosis develops in the course of two or three hours, and unless the mechanical obstruction be immediately relieved death from asphyxia quickly ensues.

Examination. Examination of the larynx will show large, pale, usually gray swellings completely distending the ary-epiglottic folds, so as often to preclude a view of the interior of the larynx. The elevations marking the positions of the cartilages of Santorini and Wrisberg are effaced. Occasionally the edematous infiltration is more marked in the subglottic region, in

which two large, oval, pale-colored swellings can be seen beneath the vocal cords.


Differential Diagnosis. Where a view of the larynx can be obtained, the enormous swelling of the tissues, the extreme pallor and semi-translucent appearance of the mucous membrane leave no doubt as to the nature of the condition. Where laryngeal examination is impossible an abscess or new growth of the larynx may simulate edema. Abscess of the larynx is characterized by localized pain in the organ, with elevation of body temperature, both of which are absent in edema. New growths obstruct the larynx very gradually, and may or may not be accompanied by pain according to their nature. Edema comes on suddenly, often within a few hours.

Prognosis. The prognosis in this condition depends partly upon the cause of the edema and partly upon the promptness with which efficient aid is rendered the patient. Coming on late in tuberculosis or in malignant disease, death frequently takes place before relief can be obtained.

Treatment. If of moderate severity—that is, where dyspnea is not accompanied by cyanosis—sucking and swallowing small pieces of cracked ice, and the application of ice-bags to the neck, often afford great relief. When the dyspnea is severe no time should be lost in scarifying the edematous tissue. This should be done by first spraying the back of the throat freely with a 20 per cent. solution of cocaine, and instructing the patient to swallow any excess of the fluid, so that some of the solution may bathe the edematous tissue in the ary-epiglottic folds. A cotton-wound laryngeal applicator (Fig. 102) should be dipped in a 20 per cent. solution

*Sucking
Ice,
Ice to neck
Scarify tissue
+ tracheotomy*


FIG. 102.



Laryngeal applicator.

of cocaine and the swollen region of the larynx brushed with the solution, the tongue being protruded and the laryngeal mirror employed in order to paint accurately the swollen areas. Sometimes the edema will be markedly diminished owing to the constricting action that this drug has upon the mucous membrane. It is not safe to rely upon this entirely, for in an hour or so, when the effects of the cocaine have passed off, the edema usually reappears in a more aggravated form. Five minutes after the cocainization the parts

FIG. 103.



Tobold concealed laryngeal lancet.

should be well illuminated with a laryngeal mirror, and a curved, concealed laryngeal knife (Fig. 103) should be introduced, the knife being concealed during the introduction, and only pushed forward to scarify the tissues when it has reached the areas of greatest swelling. Hemorrhage and transudation of serum follow, the swelling diminishes, and respiration becomes easier. If this procedure does not diminish the edema and cyanosis deepens, then tracheotomy should be promptly performed.

CHRONIC HYPERTROPHIC LARYNGITIS (Chronic Laryngeal Catarrh).

Chronic inflammation of the mucous membrane and submucous tissues of the larynx, accompanied by congestion of and increase in the tissues. Three varieties of this disease will be described. Each may occur separately, or two or all of them may be present in the same individual:

1. *Diffuse hypertrophic laryngitis.* A form in which there is diffuse infiltration pretty evenly distributed throughout the larynx.

2. *Subglottic hypertrophic laryngitis.* A variety in which the tissues immediately beneath the vocal cords are inflamed to a greater extent than is the rest of the mucous membrane.

3. *Chorditis nodosa, or trachoma of the vocal cords.* This variety is characterized by the appearance of small nodules on the inner borders and upper surfaces of the vocal cords.

1. Diffuse Hypertrophic Laryngitis.

Etiology. Diffuse hypertrophic laryngitis may follow recurring attacks of acute laryngitis. It most frequently results from persistent mouth-breathing and the consequent respiration of cold, dry, and dust-laden air made necessary by those conditions of the nose which produce obstruction to respiration through this organ. It is, therefore, more common in the winter months, and in cold, damp climates, than in the warmer summer months or in those regions where a more equable climate is found. The disease is frequently associated with those chronic pulmonary affec-

tions, such as asthma, emphysema, chronic bronchitis, and tuberculosis, of which coughing is a constant symptom. It is also met with in the cardiac diseases characterized by impeded return circulation of the blood. A gouty and rheumatic diathesis is frequently accompanied by a chronic laryngitis. Patients in whom congestive diseases of the liver are found frequently suffer from chronic laryngitis. All chronic lesions of the larynx, such as are seen in syphilis, tuberculosis, and lupus, and the new growths, benign or malignant, are often complicated by it. Tumors of the neck and upper part of the thorax, such as goitre, aneurism, and enlarged lower cervical or thoracic lymphatic glands, produce a passive hyperemia of the larynx which eventually leads to chronic hypertrophic laryngitis. Those whose occupations compel them to inhale large quantities of dust, as is the case with stone-cutters, metal-workers, bakers, tobacconists, etc., often suffer from an aggravated form of this disease, on account of the tendency these patients have to hypertrophic rhinitis and the consequent necessity for breathing through the mouth. Public speakers and those who make protracted use of the voice in loud tones, especially in the open air, are very liable to it. Those who indulge in smoking to excess, particularly in-doors, so that the air in the room is saturated with tobacco smoke, are prone to this disease. Chronic alcoholism predisposes one to it. Any impairment of the general health renders the individual more susceptible to the above-mentioned causes. The disease is more common in men than in women, and elderly people are particularly susceptible.

Pathology. The bloodvessels of the larynx are con-

gested; there is a round-cell infiltration into the sub-mucous tissues, and the secretion from the mucous glands is profuse and thicker and more tenacious than normal.

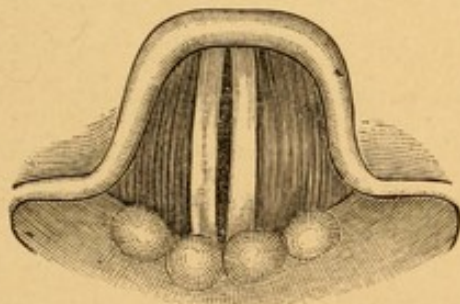
Symptoms. The two symptoms that are most marked in chronic laryngitis are change in the voice and frequent attempts at clearing the throat. The voice at first is hoarse, and this is often most marked early in the morning shortly after rising. At this time the voice may be almost, if not quite, aphonic. Later in the day the voice frequently clears, so as to be nearly normal. Speaking is often an effort for these patients, and while a moderate amount of it may be accomplished with ease, any prolonged tax upon the voice results in hoarseness. The singing voice can rarely be depended on, and an effort at singing quickly produces a strained, aching feeling in the larynx.

The clearing of the throat is for the purpose of ridding it of the thick, tenacious mucus. These efforts are sometimes made at intervals of only a few minutes. The expectoration is usually scanty, thick, and gelatinous, and often contains little pearls of grayish mucus. Blackish particles of dust are seen in the expectoration of immoderate smokers and of those whose occupations compel their living or working in a dust-laden atmosphere. Where the expectoration is profuse the trachea, bronchi, and lungs should be examined for accompanying diseased conditions. Excessive smoking or a short stay in a room filled with tobacco smoke increases both the hoarseness and the laryngeal secretion.

Examination. Examination of the larynx reveals the mucous membrane red, swollen, and congested,

with usually secretion deposited here and there on the surface of the ventricular bands, or in the interarytenoid region on the posterior laryngeal wall. The vocal cords vary in color and appearance according to the intensity of the inflammatory process. At times they are only slightly inflamed; at other times they are deep red in color, approaching that of the rest of the laryngeal mucous membrane. This is especially seen in those given to alcoholic excesses. In severe and long-standing cases the even contour of the inner edge of the vocal cords may be lost, and they appear slightly irregular and uneven, owing to thickening of the epithelium. The vocal cords themselves are often sluggish in action, which may be due to either infiltration of the muscles, especially the *thyro-arytenoidei interni*, or to the thickened, indurated tissues on the posterior wall of the larynx, in the interarytenoid space. The vocal cords, instead of approximating by

FIG. 104.



Faulty approximation of the vocal cords as often observed in chronic hypertrophic laryngitis.

their internal edges during vocalization, as shown in Fig. 2, Plate VI., frequently leave an oval slit between their internal edges, as shown in Fig. 104.

Differential Diagnosis. Usually there is little difficulty in diagnosing chronic hypertrophic laryngitis.

It is only in those cases in which the hypertrophy is not evenly distributed, or is more marked in some portions of the larynx than in others, that one may be in doubt as to whether the process is a manifestation of tuberculosis or syphilis, or the beginning of a malignant growth, when the age of the patient is such as to make this supposition possible. Whenever such uneven hypertrophies are discovered a careful examination of the lungs and sputum for evidences of tuberculosis should be made. Potassium iodide should be administered to eliminate a syphilitic growth, and the patient should be carefully watched for a rapid increase in the size of the thickened area, in which case a portion of the growth should be excised and examined microscopically.

Prognosis. The prognosis in chronic hypertrophic laryngitis depends upon the causative factor. If this can be remedied, there is every prospect of relief, and even cure.

Treatment. Before beginning local treatment for chronic hypertrophic laryngitis thorough search should be made in each case to determine the factors which have predisposed to the disease. Obstructive lesions in the nose are to be remedied; cardiac and pulmonary diseases cured or ameliorated as far as possible; a gouty or rheumatic diathesis should receive appropriate treatment; smoking in-doors should be prohibited and the excessive use of alcohol abandoned. The internal administration of saline laxatives is often of the greatest assistance in depleting the congested state of the bloodvessels so frequently found in this disease. A teaspoonful of Carlsbad salts in a tumblerful of hot water, half an hour before breakfast each morning, for

two or three weeks, is usually followed by excellent results.

LOCAL TREATMENT. Watery sprays containing astringents, prescribed for the patient's use at home, are, we believe, of very little service in this disease. The spray is seldom fine enough to be carried into the larynx in sufficient quantity to be useful. Substances soluble in oil can be made into a sufficiently fine spray to be carried into the larynx during each inspiration, and so reach the diseased areas. The patient may be given :

R.—Menthol gr. xxv.
 Eucalyptol ʒj.
 Ol. pini pumilionis ℥xx.
 Benzoinol q. s. ad. ʒij.

M. et Sig.—Use in oil atomizer every four hours.

Applications to the laryngeal mucous membrane should be made with a laryngeal applicator (Fig. 102) by the physician. This instrument has a threaded tip, and should be wound with cotton in the manner described for winding a nasal applicator. Care must be taken that the cotton is wound firmly, so that there will be no danger of its becoming detached while in use. The curve of the applicator (Fig. 102) is that suitable for reaching the posterior portion of the larynx. Where applications are to be made to the anterior portion of the larynx as well, the curve has to be more nearly at right angles than that shown. The larynx should first be sprayed, or, better, swabbed with a 10 per cent. solution of cocaine on a cotton-wound laryngeal applicator. At the end of five minutes a solution of chloride of zinc (10 grains to the ounce of water) is to be applied to the laryngeal mucous membrane by

only sprays.

*Applications
 cocaine
 2. Zinc chloride
 10 to 30 gr.
 increase.*

means of the cotton-wound applicator. Care must be taken that any excess of the solution is shaken from the cotton, as when the cotton is too moist some of the fluid may be squeezed out, pass into the trachea, and excite inflammation in that region. The application at first should be made each day, the strength of the solution being gradually increased until, at the end of two weeks, it contains a drachm of chloride of zinc to the ounce of water. Spasm of the larynx often results when stronger solutions are used. These spasms usually disappear quickly, and it is advisable to tell patients that they are in no danger of suffocating, and direct them to breathe rapidly in a panting manner, when the spasm will pass away in one or two minutes. When the larynx fails to react to the chloride of zinc solutions, as it may after three or four weeks, solutions of nitrate of silver, used in the same strength as the zinc chloride, will be found efficacious.

Elderly people who are, each winter, subject to attacks of chronic laryngitis, which disappear in this climate with the advent of warm weather in the latter part of May, only to return the following October or November, can rid themselves entirely of this susceptibility by a residence in the warmer, dryer climates found in New Mexico, Southern California, along the Riviera, or in Egypt.

2. Chronic Subglottic Laryngitis.

This variety of laryngitis is characterized by infiltration of the tissues beneath the vocal cords.

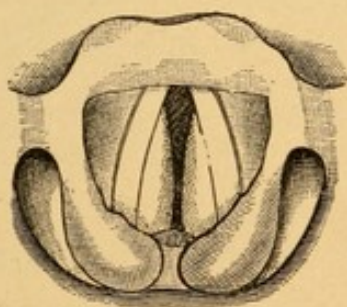
Etiology. The causes which produce this form of chronic laryngitis are similar to those which have been given for the diffuse form.

Symptoms. In addition to the symptoms observed

in diffuse hypertrophic laryngitis, those which specially characterize this variety are the intense dyspnea; the great impairment of the voice, which is usually aphonic; and a peculiar cough, resembling very much the tight, "brassy" cough found in compression of the trachea from aneurism and other tumors. The dyspnea is so marked that patients frequently feel as if they were about to suffocate.

Examination. Examination of the larynx reveals two oval, usually pale masses, parallel to and immediately below the vocal cords (Fig. 105). The normal glottis, therefore, is markedly encroached upon; hence the dyspnea. This figure also shows marked swelling and edema of the ary-epiglottic folds. (These may or may

FIG. 105.



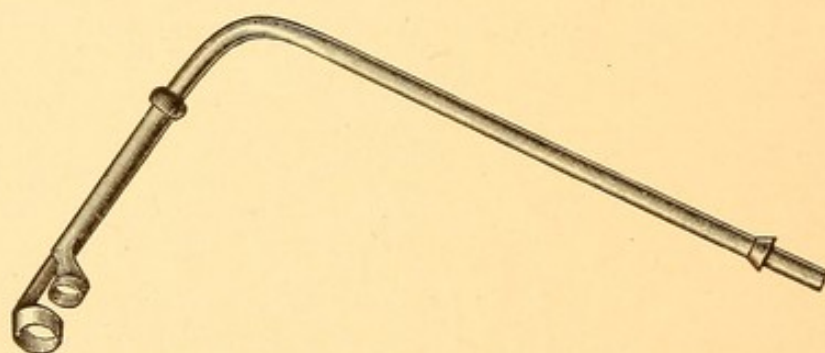
Subglottic infiltration. Edema of the ary-epiglottic folds.

not be present.) When the larynx is viewed during vocalization it will be noticed that the vocal cords do not move with their accustomed freedom, and very frequently the bulging subglottic tissue projects between the edges of the vocal cords, thereby making it impossible for proper approximation and vibration in the production of sound.

Differential Diagnosis. This disease is to be differentiated from rhinoscleroma of the larynx, in which the appearance may be very similar to that just described.

Rhinoscleroma, however, is a very rare disease in this country, and is almost invariably accompanied by rhinoscleroma of the nose, where the characteristics of the disease can well be determined. If the larynx be cocainized and the swelling touched with a laryngeal probe, that of subglottic laryngitis will be found comparatively soft and easily indented, while that of rhinoscleroma will be hard, cartilaginous, and scarcely if at all indented. Where doubt still exists remove a portion of the growth by means of the punch forceps (Fig. 106), which is used with the Schroetter handle

FIG. 106.



Punch forceps for removing laryngeal growths.

(Fig. 25). Sections made and stained by Gram's method will determine not only the character of the growth, but will reveal also the presence of the bacilli of rhinoscleroma.

Prognosis. The prognosis in this disease is far more grave than in diffuse hypertrophic laryngitis. Where the swelling is of large size the voice seldom returns to normal and on account of the dyspnea the patient may have to be tracheotomized and wear a canula for the rest of his life.

Treatment. The internal administration of 10 grains of potassium iodide, three times a day, may assist in

R.I.

the retrograde changes and absorption of the newly formed tissue. Caustics, such as nitrate of silver and trichloroacetic acid, and even the galvano-cautery, have been employed to reduce the size of this tissue. The introduction of caustics into the larynx to remove an overgrowth of tissue in this region has to be made with the greatest nicety. There is danger that the caustic will be applied not only to the diseased tissues, but also to the vocal cords, thus destroying them or binding them down to the lateral walls of the larynx, so that their mobility and usefulness in voice-production are greatly impaired. The larynx should, of course, be thoroughly cocaineized with a 20 per cent. solution of cocaine, and it is better at the first sitting or two to introduce a laryngeal probe and touch the various portions of the larynx, so that the patient will be accustomed to the introduction of instruments into the larynx, before any attempt is made to use a caustic. The caustic is best applied by means of the concealed applicator (Fig. 109), fitted into a Tuerck handle (Fig. 109). Nitrate of silver is probably the safest cauterant to employ. It should be fused upon an applicator. Chromic acid similarly fused is preferred by some laryngologists. The caustic carrier should be kept within the shield until it is opposite the part it is desired to cauterize. It should then be protruded, cauterization made, and again withdrawn into its sheath before being removed from the larynx.

The introduction of a large-sized intubation tube into the larynx has in some cases been of value in reducing the swelling, as the pressure from the tube aids in absorption of the growth. Where the stenosis of the larynx is of such a degree that severe dyspnea,

*Caustic
ag 203
cocaine*

*Intubation
tube.*

Tracheotomy. cyanosis, and asphyxia are impending, then the introduction of a large-sized intubation tube, such as is used for adults, or the performance of tracheotomy, becomes necessary. If the latter procedure be adopted, there is little likelihood that the patient will ever be able to dispense with the tube.

3. Chorditis Nodosa (Trachoma of the Vocal Cords).

Etiology. Chorditis nodosa accompanies chronic hypertrophic laryngitis in those who use their voices in a faulty manner. The condition is more frequently seen in females than in males. It occurs in singers and public speakers and in those whose occupations demand the use of their voices for long periods of time, especially in large buildings or in the open air.

Pathology. The nodes are found sometimes on one vocal cord, often on both, and may be situated anywhere along the inner border and the adjacent portion of the upper surface. They are more commonly found somewhat nearer the posterior than the anterior portion of the vocal cords. They consist of layer upon layer of stratified squamous epithelial cells.

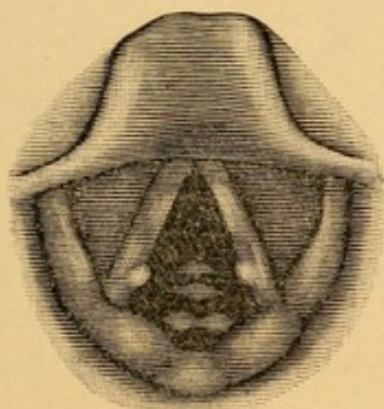
Symptoms. The most important symptom complained of by those having chorditis nodosa is impairment of the voice. Singers find difficulty in striking the right note, and in holding it when once obtained. Public speakers find their voices "crack" in the midst of talking. The other symptoms depend upon the amount of the associated hypertrophic laryngitis, which not infrequently is very slight.

Examination. Examination of the larynx reveals a slight whitish, grayish, or very light pink elevation on the vocal cords near their internal margins (Fig. 92).

These frequently project almost straight inward from the thin, inner margins of the vocal cords, thus making little lumps or nodes plainly visible, interrupting the otherwise slightly curved edge of the normal cords. The mucous membrane in the immediate neighborhood of these nodes is apt to be slightly reddened when compared with the other regions of the cord.

Prognosis. When patients can be induced to follow implicitly the directions of the physician, especially in regard to giving the voice a needed rest, and

FIG. 107.



Nodes on the vocal cords; that on the right cord is somewhat the larger.

where they subsequently correct faults in speaking or singing, these growths usually disappear and do not return. If, however, instructions are disobeyed, the growths, if removed, are apt to return.

Treatment. The first and most important point in the treatment is to give the voice absolute rest. In slight nodule formation this alone is sufficient, after a period of from three to six months, to allow of absorption of the thickened epithelium and a return to the normal condition. Zinc chloride, applied in the manner described in the treatment of chronic diffuse hypertrophic laryngitis, usually materially assists in

Rest.

zinc chloride.

Remove.
+ touch
base with
zinc chloride.

the absorption of these growths. Where the nodules are large it is often necessary to remove the greater portion of them by means of the punch forceps (Fig. 106). The larynx should be thoroughly cocainized with a 20 per cent. solution of cocaine. Great care must be taken so to adjust the jaws of the forceps that only the growth shall be included in them, and that *none* of the other tissues of the vocal cord be grasped. In the latter event it will be found that the cicatricial contraction following removal of a portion of the vocal cord impairs the mobility of it as much, if not more, than the previous presence of the node.

The treatment after this operation consists in touching the base of the growth with the zinc chloride solution.

CHRONIC ATROPHIC LARYNGITIS (*Laryngitis Sicca*).

A chronic inflammation of the larynx resulting in atrophy of the mucous membrane and of some of the submucous tissues.

Etiology. This disease is usually secondary to atrophic rhinitis and pharyngitis. It may be, though rarely, the result of atrophy following hypertrophic rhinitis. It is occasionally seen in mouth-breathers in whom there is obstruction to nasal respiration.

Pathology. The normal tissues of the larynx are replaced by a rather dense connective tissue. Many of the mucous glands are destroyed, and those which remain secrete a thick mucus, the moisture of which is absorbed by the dry, inspired air, leaving a residue in the form of thick, brown, green, or black crusts on the vocal cords and in the interarytenoid region. On

the posterior wall of the larynx areas of superficial ulceration may occasionally be found.

Symptoms. The voice is usually aphonic in the morning and until such time as the crusts are loosened by coughing and expectorated. When this happens, varying from half an hour to two or three hours after rising, the voice becomes more resonant, but usually remains husky. Prolonged paroxysms of coughing are necessary to dislodge the crusts, which often have a very disagreeable odor. These crusts, if large, produce dyspnea, which disappears when they are dislodged. Occasionally slight hemorrhage follows their removal. An offensive odor of the breath is almost always present in this disease.

Examination. The mucous membrane of the larynx is dry and pale, and the vocal cords often present a finely wrinkled, shiny appearance. Crusts, small or large, may be found on the vocal cords, ventricular bands, and covering the posterior wall of the larynx. They are frequently visible in the trachea as well. Upon removal of the crusts it is not uncommon to find small, ulcerated areas on the sites where they were located.

Prognosis. Chronic atrophic laryngitis can seldom be cured. The disagreeable symptoms can only be ameliorated.

Treatment. In treating atrophic laryngitis it should never be forgotten that the condition is usually associated with a similar process in the nose and pharynx, and that until these conditions can be considerably bettered, so far as crust formation is concerned, very little progress can be made in the local treatment of the larynx. The menthol spray prescribed for diffuse *menthol spray.*

hypertrophic laryngitis should be put into the hands of these patients, with instructions that they employ it very frequently—every two hours, if necessary—in order that the mucous glands may be stimulated to increased activity and the crusts softened, so that they can be more readily loosened and expectorated. One-tenth of a grain of pilocarpine, administered three times a day, often increases the glandular activity to such an extent that patients will be relieved from the distressing dryness and irritation complained of. Ulcerated areas in the larynx should be painted with a 4 per cent. solution of nitrate of silver every third day until healing takes place.

PROLAPSE OF THE VENTRICLE.

A condition in which the mucous membrane of the sacculus laryngis becomes everted or prolapsed, so as to pass into the cavity of the larynx between the ventricular band above and the vocal cords below.

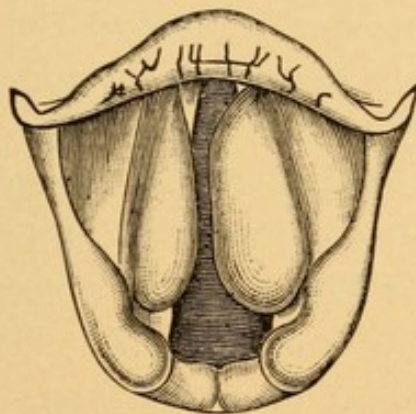
Etiology. The conditions which predispose to this disease are an acute or chronic laryngitis, and plethora or anemia, in which there is a relaxed condition of the mucous membrane. Such conditions are found in tubercular and syphilitic patients. A new growth, benign or malignant, originating in the mucous membrane of the larynx, may by its weight cause prolapse of the ventricle. As exciting causes, severe blows upon the exterior of the larynx and paroxysmal coughing have been known to produce it. The prolapse may be unilateral or bilateral.

Symptoms. The two symptoms which are most marked, in addition to those of the diseases which it is apt to complicate, are aphonia and dyspnea.

The aphonia is caused either by the prolapsed mucous membrane getting in between the two vocal cords and thus mechanically preventing their approximation, or by the membrane resting upon the vocal cord and thus interfering with the vibration necessary to vocalization. The dyspnea is attributed to narrowing of the glottis and interference with the entrance and exit of air in the larynx.

Examination. Examination of the larynx reveals a red swelling (Fig. 108) on one or both sides, which,

FIG. 108.



Prolapse of the ventricles of the larynx.

according to its size, partially or completely hides the vocal cords. The accompanying cut shows prolapse of both ventricles, that of the left being the larger, leaving only a small portion of the posterior part of the left vocal cord visible, while that of the right obscures the middle two-thirds of the right cord, leaving the anterior and posterior portions plainly discernible. When the larynx has been cocainized and a probe introduced the mass is found to be soft, and it is often possible to tuck this prolapsed mucous membrane between the ventricular band and the vocal cord,

whence it came. If the patient coughs, the prolapse immediately returns.

Differential Diagnosis. Prolapse may be mistaken for gumma of the larynx. A gumma is usually unilateral, firm in consistency, and not capable of being pushed laterally into the ventricle of the larynx. New growths, benign or malignant, may be mistaken for prolapse of the ventricle. These are always firmer in their consistency and usually irregular in outline; benign growths are attached by a small pedicle and easily movable, while malignant growths are attached by a broad base and bleed freely when palpated.

Prognosis. Prolapse of the ventricle is often difficult to cure unless it be seen early.

Treatment. Where the prolapse is small in size, replacing the prolapsed tissue with a probe and the application of caustics, such as nitrate of silver, to bind the detached mucous membrane to the surrounding tissues, may prevent its return. The patient should be cautioned against coughing, and, if necessary anodynes to check this may be administered until cicatrization takes place. In severe cases interfering with respiration and producing dyspnea the prolapsed mucous membrane may have to be excised with a double curette (Fig. 97). Where this is impossible, or the urgency of the case demands it, tracheotomy should be performed to save the life of the patient. At the end of a week thyrotomy may be performed, the prolapsed membrane excised, and the thyrotomy wound closed. When the latter has healed the tracheotomy tube should be removed and the wound allowed to close.

*Small
Replare
+
caustic
check coughing*

*Severe
excise
or
double curette
+ tracheotomy
+ thyrotomy*

PACHYDERMIA LARYNGIS.

A rare disease, accompanied by replacement of the normal epithelium on the cords in limited areas by nodules composed of stratified epithelial cells. There is also infiltration of the substance of the cord with round-cells and newly formed connective tissue, and in this respect the condition differs from chorditis nodosa.

Etiology. This disease is usually associated with chronic hypertrophic laryngitis, and in those in whom there is a history of either chronic alcoholism or excessive smoking. It has been observed more frequently in males than in females, and occurs usually between the thirtieth and sixtieth years.

Symptoms. The symptoms are usually those present in chronic laryngitis, except as to the changes in the voice, which are seldom very marked. Dyspnea is usually more intense than in diffuse hypertrophic laryngitis.

Examination. In addition to the conditions found in hypertrophic laryngitis, a conical node, considerably larger than that shown in Fig. 107, will be observed on one vocal cord. On the other vocal cord, at a point directly opposite to the node, a concavity will be seen, into which, during phonation, the node opposite accurately fits. The approximation of the vocal cords is, consequently, not much interfered with, hence the slight alteration in voice production. If the head be tilted to one side, so as to obtain a partial view of the under surface of the vocal cord during respiration, it can be seen that the node and concavity extend to this portion of the cord as well.

Differential Diagnosis. This disease is to be differen-

tiated from chorditis nodosa, which is usually possible from the characteristic appearance of the node on one cord, and a thickening, with a *depression in the centre*, on the opposite cord; by the fact that it occurs more commonly in males, while chorditis nodosa occurs more frequently in females, and that it occurs usually at a much later period in life than that in which chorditis nodosa is usually found. A history of chronic alcoholism and excessive smoking may assist in the diagnosis.

Prognosis. The condition is usually a very chronic one, and unless the habits of life of the patient can be materially improved little permanent benefit is to be expected from treatment.

Treatment. The treatment of this condition is the same as that given for chorditis nodosa, with the addition that the patients must be restrained from the excessive use of alcohol and tobacco.

PERICHONDritis OF THE LARYNX.

An acute inflammation of the perichondrium and the laryngeal cartilages, resulting in destruction of the cartilage in the affected area.

Etiology. This condition may follow severe blows on the larynx. Stab wounds and attempts at self-destruction by cutting the throat may lead to it. The disease is usually secondary to syphilitic, tubercular, or malignant disease of the larynx. It is one of the rare sequelæ of the acute infectious diseases, such as typhoid fever and diphtheria, or where an intubation tube of too large size has been employed. Instances of perichondritis of the cricoid cartilage have been observed in patients long confined to bed as the result of fract-

ures or dislocation of the vertebræ. The constant pressure of the cricoid cartilage against the bodies of the cervical vertebræ has been thought so to interfere with the circulation in the perichondrium as to induce this inflammation. In many cases it is impossible to account for its origin.

Pathology. Pus-producing bacteria gain entrance to the perichondrium either through an external wound or through a wound or ulceration within the cavity of the larynx. The germs induce a suppurative inflammation, with the formation of pus, which strips the perichondrium from the underlying cartilage and so deprives the latter of its means of nutrition. Necrosis and death of the cartilage result. This is followed by either gradual disintegration or sloughing of a large piece of the necrosed cartilage through the sinus that is made during the exit of the pus. The pus may either open through the mucous membrane of the larynx or burrow in the tissues external to the larynx, infiltrating the neck beneath the deep fascia, in which case there is a tendency for the spontaneous opening to be at some distance from the larynx; or it may even burrow into the thorax. The cartilage that is most frequently affected is the cricoid, involving with it usually the arytenoid cartilages, and occasionally the thyroid cartilages as well. Following extrusion of the laryngeal cartilages and the subsequent cicatrization, great deformity of the larynx results.

Symptoms. The symptom first complained of is pain of a throbbing character, referred to some portion of the larynx, depending upon the starting-point of the inflammatory process. Where the pus tends to burrow toward the laryngeal cavity dyspnea, rapidly increas-

ing in intensity, will be complained of. Where the pus burrows in the tissues surrounding the larynx the esophagus will be compressed and difficult and painful deglutition experienced. The temperature is usually of that variety found in suppurations elsewhere: higher in the evening—may be 102° to 104° F.—and lower in the morning. The pulse is considerably accelerated. At the end of a few days a sinus may form. If it opens into the larynx, the patient will expectorate pus slightly admixed with blood. Where the tendency is to burrow into the tissues of the neck a large fluctuating swelling will be found in the region of the larynx or lower down in the neck.

Examination. Examination of the larynx will reveal a localized swelling in some part of this organ, depending upon the seat of the perichondritis. Before the abscess has discharged fluctuation may be detected in this area by means of a laryngeal probe. When a sinus has formed pus may be seen oozing from it, and a laryngeal probe may detect loose cartilage underneath the mucous membrane. Localized pain on slight pressure over the affected portion of the larynx will be complained of. The arytenoid cartilage on the affected side will usually, owing to the inflammation in the crico-arytenoid articulation, be immovable, and consequently the vocal cord of that side will not change its position during respiration or phonation.

Differential Diagnosis. The diagnosis of perichondritis of the larynx, when seen early, may be difficult to make. The throbbing pain, and the increase in this when pressure is made upon the exterior of the larynx; the elevation in both local and body temperature; the appearance of a fluctuating swelling, either within the

larynx or exteriorly in its immediate neighborhood, should always arouse suspicion of a perichondritis. The laryngeal appearance of a gumma may simulate that of a perichondritis, but a gumma is seldom painful, even on pressure over the larynx; there is no elevation in temperature, and the history of syphilis in earlier life and the absorption of the growth under the administration of large doses of potassium iodide render the diagnosis easy.

Malignant disease may be mistaken for perichondritis; but the pain in the former case is not often as acute as that in perichondritis, and usually radiates to the ear on the affected side, and there is a history of slow and more gradual development. Excision of a portion of the swelling and its examination under the microscope will show the malignant character of the growth. It must not be forgotten, however, that perichondritis of the larynx occasionally complicates epithelioma, gumma, and tubercular affections of the larynx in their ulcerative stages.

Prognosis. The prognosis in perichondritis of the larynx depends upon the condition existing at the time the patient is first seen. Where perichondritis is seen early, and efficient surgical means are taken to evacuate the pus and prevent further destruction of the laryngeal cartilages, the patient may recover with comparatively slight deformity of the larynx. Where, however, the pus has burrowed so as to strip the perichondrium from most of the cartilages of the larynx extensive and prolonged suppuration, involving the tissues of the neck, will very likely be found, and if healing finally takes place the larynx is practically useless as an organ either of respiration or phonation.

The patient is often obliged to wear a tracheotomy tube the rest of his life.

Treatment. Perichondritis, once recognized, should be treated surgically with promptness. We believe that the best results will be obtained if the patient be tracheotomized and subsequently a free incision made through the skin of the neck down to the larynx, and the perichondrium freely incised, so as to evacuate the pus. Any necrosed cartilage must be removed and the wound packed and treated as an abscess in any other region. If a considerable area of the laryngeal cartilages be found necrosed, it may be advisable to insert an intubation tube into the larynx, as a support to the relaxed tissues and as a means of preserving the shape of the laryngeal cavity during healing. Where patients will not submit to this operation they should be candidly told of the dangers that confront them; of the likelihood of a tracheotomy becoming necessary at any moment to prevent asphyxiation, and of the great danger that results from destruction of the cartilages of the larynx and the subsequent deformities that will be produced.

ABSCESS OF THE LARYNX.

Etiology. Abscesses of the larynx are not common, and may be the result of perichondritis or the breaking down of a syphilitic gumma, or follow the introduction of foreign bodies into the larynx. Erysipelas of the larynx has been followed by abscess formation.

Symptoms. The symptoms are practically the same as those of edema of the larynx, with the addition of a throbbing pain referred to the larynx. The body temperature may be elevated one to three degrees.

Tracheotomy
+ then
incise - abscess
has occurred
necrosed
cartilage
intubate.

Examination. In the earlier stage of abscess formation the mucous membrane of the larynx is red and enormously swollen; later, some point of the swelling may appear slightly yellow, indicating the presence of pus beneath the mucous membrane.

Diagnosis. Abscess of the larynx is often accidentally mistaken for edema of the larynx, and its character only determined upon incision being made into the mass.

Treatment. Where possible the larynx should be cocainized and the abscess cavity evacuated by means of the curved laryngeal lancet (Fig. 103). The knives in Heryng's set (Fig. 99) are very serviceable for this purpose. The concealed knife (Fig. 109) used in the Tuerck handle may be employed with less danger of wounding the healthy tissues during the introduction or withdrawal of the instrument. Where dyspnea is marked, tracheotomy may have to be performed before any attempts are made to open the abscess. When the abscess is opened after tracheotomy is performed care must be exercised to see that the patient's head is lowered, so that the pus may not travel down beside the tracheotomy tube into the bronchi and lungs and induce a septic pneumonia.

FOREIGN BODIES IN THE LARYNX.

A great variety of substances, such as buttons, beans, particles of food, pieces of wood, pins, needles, coins, etc., have been found in the larynx.

Etiology. The usual method by which these foreign bodies enter the larynx is as follows: The substances are placed in the mouth, and during a sudden inspiration, such as that which precedes coughing or sneezing

or laughing, attention is distracted from the foreign substance, and it is drawn into the larynx with the inspired air. Conditions in which the sensibility of the pharyngeal and laryngeal mucous membrane is blunted, as is frequently seen in intoxicated persons or in those suffering from paralysis of the throat, and the anesthesia of this region often present in the insane, predispose to the entrance of foreign bodies into the larynx. Where a patient has recently partaken of a hearty meal there is great danger of particles of food entering the larynx during the vomiting that occurs during or after the administration of a general anesthetic, such as ether or chloroform. The vomited material may be regurgitated only as far as the back of the pharynx, lodging there, a portion passing into the laryngeal cavity. Large foreign bodies are usually impacted in the laryngopharynx and project into the cavity of the larynx at its upper opening. Somewhat smaller bodies may pass into the cavity proper and lodge above the ventricular bands. Small substances, especially if flat, may find their way between the ventricular bands and vocal cords, and thus enter the ventricles of the larynx. Very small bodies may lodge for a time in the larynx, being held either by the approximated vocal cords or ventricular bands; and subsequently, when the spasm in these passes away, or through injudicious attempts at removal, the foreign bodies may fall or be pushed through the larynx into the trachea and lodge in the bronchi. Needles and pins have been known to penetrate the mucous membrane of the larynx, become encysted for a time, and later work their way out through the larynx and skin of the neck.

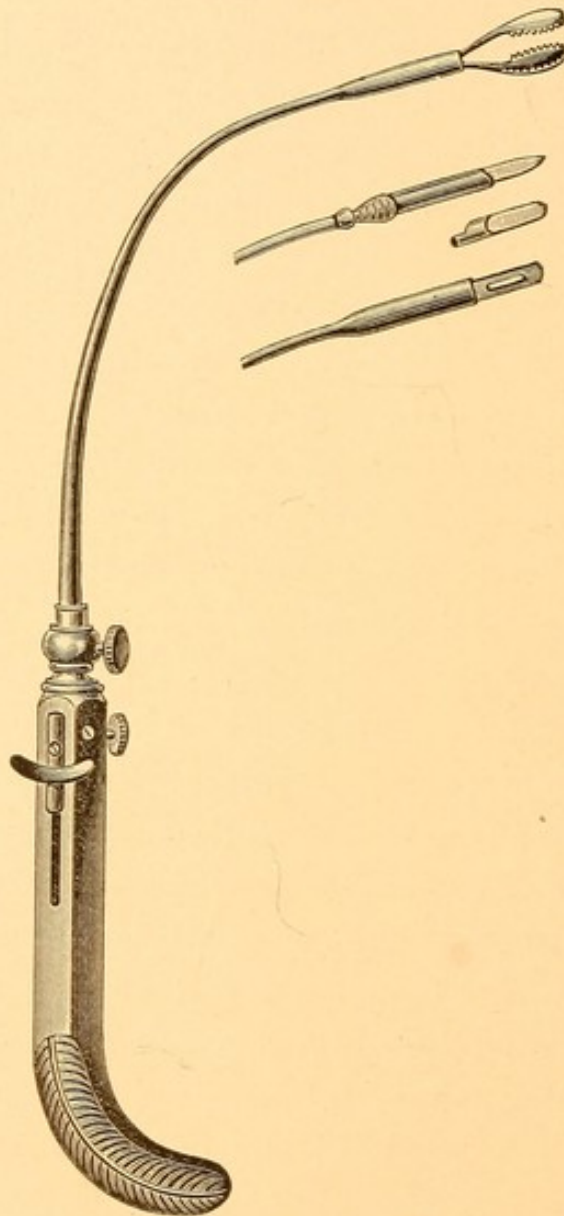
Symptoms. Large particles of food and foreign bodies that completely block the inlet to the larynx produce asphyxiation, and unless the substances can be quickly removed death of the patient follows in from two to five minutes. The somewhat smaller bodies which enter the cavity proper of the larynx and lodge in the supraglottic region produce inspiratory dyspnea, the intensity of which depends upon the size of the obstruction. The voice is hoarse or aphonic according to the amount of interference with the function of the vocal cords. Pain is not a frequent accompaniment unless the body be rough and produce ulceration or abscess in the larynx. Cough is often very annoying, being spasmodic in character and sometimes persisting for a considerable period after removal of the foreign body. Everyone has experienced the sensation produced by a small crumb or a drop or two of liquid entering the upper portion of his larynx, and is aware of the length of time that the irritation and cough last after removal of the offending particles. Owing to reflex cough, patients frequently insist for two or three days that there is something remaining in the larynx.

Examination. Where a good view of the larynx is obtained the foreign body can usually be detected. When the offending particle has been expelled the mucous membrane is frequently found reddened and congested as a result of the irritation and persistent coughing.

Treatment. Some foreign bodies may be gotten rid of by inverting the patients and slapping them upon the back, in which case, as soon as the spasm of the larynx ceases, the foreign body will drop into the pharynx and be expectorated. Where the foreign

body can be plainly seen it should be grasped with a pair of forceps, such as those shown in Fig. 100 or 101, the choice depending upon which will grasp it the more

FIG. 109.



Tuerc handle, containing serrated forceps. Two sheathed knives and a sheathed caustic applicator are also shown.

readily. The serrated forceps shown in Fig. 109, fitted into the Tuerc handle, may be employed for this purpose. It has the advantage of being on a flexible shaft, which can be bent so as to reach the offending particle,

and the blades of the forceps are capable of being turned in any direction, and can thus readily seize the object and remove it. Foreign bodies in the larynx may be extracted with Killian or Jackson tubes (see p. 502). When dyspnea is so marked as to threaten the life of the patient no time is to be lost in performing tracheotomy. After this has been done it may be possible to introduce a pair of forceps through the tracheal wound into the larynx and remove the offending body. If this can be done without too much injury to the laryngeal tissues, it is advisable to close the tracheotomy wound at once. Should much trauma to the larynx result, either from the foreign body or during attempts at its removal, it is advisable to allow the tracheotomy tube to remain in place until such time as the laryngeal swelling subsides, after which the tube should be removed. It should be our endeavor to remove the tracheotomy tube at the earliest time that it is safe to do so. Retention of the tube is usually followed by sclerosis of the trachea, the amount of which varies with the length of time the tube is worn. When the foreign body cannot be grasped through the tracheotomy wound or through the mouth with the aid of a laryngeal mirror, then thyrotomy must also be performed, in order to remove the foreign substance. This wound may be closed immediately, leaving the tracheotomy tube for a time *in situ*.

TUBERCULOSIS OF THE LARYNX (Laryngeal Phthisis).

An acute or chronic laryngitis, due to deposit of tubercle and the subsequent changes that occur in it.

Etiology. Laryngeal tuberculosis is usually secondary to pulmonary tuberculosis. The disease is most com-

monly met with in adults between the ages of twenty and forty-five years. It may occur both at a later and at an earlier period of life.

Statistics vary considerably as to the frequency with which the larynx is involved in cases of pulmonary tuberculosis. Most statistics are the results of observations made in dead-houses, and come from the general hospitals in the larger cities of Germany, where autopsies are made upon nearly all patients who die in those institutions. Thus, Schroetter, in Vienna, found the larynx involved in only 6 per cent. of the cases ; while Heinze, in Liepsic, found laryngeal involvement in 51 per cent. of the cases of pulmonary tuberculosis. The laryngologist usually sees only the cases of tuberculosis in which there is implication of the larynx. He is very likely, therefore, to consider involvement of the larynx as far more frequent than is the general practitioner, to whom the pulmonary condition is the all-important lesion. We have carefully examined the larynges of a large number of cases of pulmonary tuberculosis, and found only 20 per cent. presenting evidences of laryngeal affection. Most writers state that laryngeal tuberculosis occurs in about 33 per cent. of the cases of pulmonary tuberculosis.

The laryngeal involvement may be unilateral or bilateral. In the latter case the two sides may be unequally affected. Tubercular disease of the larynx usually begins and is more marked on the same side as that on which the pulmonary lesion originated or is the more extensive.

Tubercle bacilli gain access to the laryngeal tissues in three ways :

1. Through the lymphatics. This is probably the

most usual method of infection. When occurring in this manner one can readily understand how it is that the pulmonary and laryngeal involvement should occur on the same side of the median line.

2. Through the entrance of tubercle bacilli into the blood-stream, and their deposition in the tissues of the larynx.

3. Should slight abrasion of the epithelium of the mucous membrane occur in a patient suffering from pulmonary tuberculosis the tubercle bacilli of the sputa, which necessarily pass over the abraded surface, may infect the larynx. Any acute inflammatory condition of the larynx, or even a chronic laryngitis in tubercular patients, renders them more liable to infection, on account of the slight abrasions of the epithelium often met with in these conditions. In a syphilitic patient the ulcerations frequently present in the larynx in that disease afford a favorable point of entrance for the tubercle bacilli, and a mixed infection—namely, tuberculosis engrafted upon a syphilitic ulcer—will result.

A few cases of well-authenticated primary tuberculosis of the larynx have been observed, but the majority of supposed primary tubercular infections of the larynx show within a few weeks marked evidences of pulmonary involvement. It is always a matter of doubt in these cases whether the condition of the lungs is secondary to that in the larynx, or whether, as we believe to be the more common, the evidences of pulmonary tuberculosis were at first so slight as not to be detected on physical examination. There is no special peculiarity of the larynx or germicidal influence in its secretions that will prevent the larynx becoming primarily infected. Probably the principal reason

why the larynx is not more frequently affected primarily is that tubercle bacilli present in the respired air are deposited upon the mucous membrane of the nose and nasopharynx, and few or none are in the air that passes through the larynx.

Pathology. Whether involved secondarily or primarily, the pathological processes in the larynx are the same. The first effect of the introduction of tubercle bacilli beneath the mucous membrane of the larynx is to produce a round-cell infiltration and the formation of "the tubercle" and the giant-cell. Where the proliferation of these cells is very rapid they crowd each other, so as to interfere with their nutrition, and, assisted by the toxins of the tubercle bacilli, cloudy swelling and cheesy degeneration of the cells in the centre of the tubercle take place. The tubercles may be scattered pretty evenly beneath the mucous membrane, or they may be piled one on top of the other, so as to form a well-defined tumor. When pus-producing bacteria gain access to the degenerated cells necrosis and suppuration quickly ensue, and the second stage, or that of ulceration, will be found. The first stage frequently passes unnoticed, as there may be no symptoms referable to the larynx, and the physician who is treating the pulmonary lesion fails to examine the larynx. Laryngeal ulcers are usually superficial in character and irregular in outline, having a "mouse-nibbled" appearance, and their margins, which are not elevated, seldom exhibit a boundary zone of passive hyperemia. Edema of the ary-epiglottic folds is frequently observed. The situations in which the ulcers are commonly found are the ary-epiglottic folds, the epiglottis, vocal cords, posterior wall of the larynx in the inter-

arytenoid region, and the ventricular bands. Occasionally an ulcer in the interarytenoid region involves the perichondrium of the cricoid cartilage, necrosis of this cartilage resulting.

Symptoms. The symptoms of tubercular laryngitis depend upon the stage of the involvement, whether that of tubercle or that of ulcer.

STAGE OF TUBERCLE. In the stage of tubercle the most noticeable symptom is presented by the voice. In the early stages the voice is hoarse and very changeable. The individual may speak clearly for a little while, suddenly become hoarse, and after uttering three or four words, or with a slight clearing of the throat, the voice may again become perfectly clear. Where considerable infiltration of the tissues is found the voice may be aphonic and whisper-like. The changes in the voice may be due to one or more of the following conditions :

*Voice
hoarse &
changeable.*

1. Mechanical interference with the action of the vocal cords ; the presence of a tumor in the interarytenoid region, as shown in Fig. 5, Plate VII. ; or the difficulty of properly approximating the vocal cords, owing to the edema in the ary-epiglottic folds, as shown in Fig. 110.

2. Tubercle may be found on the vocal cords, causing unevenness in their contour and thereby interfering with their proper approximation during vocalization.

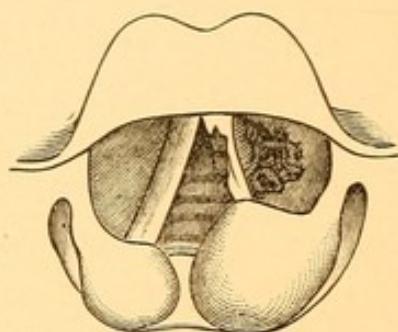
3. Thick, tenacious muco-pus brought up from the lungs or derived from an ulcer in the larynx may temporarily be deposited upon the vocal cords, thus interfering with their action, and when the throat is cleared the removal of this permits of proper vocalization.

4. The muscles of the larynx may become infiltrated

by the tubercle, so that their contraction is interfered with, and they thus fail to approximate properly the vocal cords.

5. The recurrent laryngeal nerve on one side—more frequently on the right side—becomes imbedded in the pleuritic exudate at the apices of the lungs, and compression neuritis develops, which interferes with innervation of the laryngeal muscles, and paresis or paralysis, as a result of this, prevents proper approximation of the vocal cords.

FIG. 110.



A tubercular ulcer on the left ventricular band and left vocal cord. Pear-shaped edematous swelling of ary-epiglottic folds, more intense on the side of the ulceration. (COHEN.)

6. In advanced lesions of the lungs the volume of air contained in the thorax may be so much less than normal that, with the weakened condition of the muscular system generally, the blast of expired air is insufficient to cause the vocal cords to vibrate properly, and the voice as a result is weak.

Unless the tumefaction or growth of the tubercle is extensive, respiration is seldom interfered with, and any dyspnea complained of is a result of the pulmonary rather than of the laryngeal lesion. Cough is always present in tuberculosis, and is due rather to involvement of the pleuræ than to the laryngeal disease.

Where the tubercle formation is heaped up tumor-like, as shown in Fig. 5, Plate VII., a hacking, irritating cough, due to the presence of the tubercle, is often observed. The expectoration that may accompany the cough is not to be attributed to the laryngeal involvement, but to that of the lung. Only those patients in whom the infiltration of the epiglottis or the ary-epiglottic fold is marked complain of dysphagia or sense of fulness or lump in the throat. Pain on swallowing will not otherwise be complained of.

STAGE OF ULCERATION When ulcers follow the tubercle the following symptoms will be complained of in addition to those above mentioned: An increased amount of secretion and a greater tendency to clear the throat, owing to the mucopurulent secretion arising from the ulcer. It is not uncommon to find a small amount of blood streaking the sputa of these patients. Deglutition becomes exceedingly painful where the ulcers are found on the epiglottis or in the ary-epiglottic folds. This act is then so painful that these patients often go twenty-four to thirty-six hours without food rather than suffer the excruciating pain accompanying deglutition. Liquids usually cause less pain than solids. Should the ulcer be limited to the vocal cords or ventricular bands, deglutition may be normal. The voice is usually more interfered with in cases of ulcer involving the interior of the larynx than in the stage of tubercle.

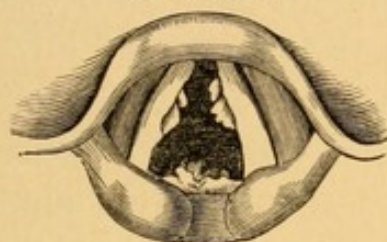
In addition to these local symptoms, the constitutional manifestations of tuberculosis—namely, emaciation, night-sweats, hectic temperature, and anemia—will be found.

Examination STAGE OF TUBERCLE. In the stage

of tubercle the mucous membrane of the larynx will be found very pale in color, with here and there areas in which the bloodvessels are slightly dilated, as is seen at the posterior portion of the vocal cords in Fig. 4, Plate VII. This extreme pallor, with the small areas of congestion, should always make one suspicious of tuberculosis, especially where the patient gives a history of having a cough and perhaps a slight expectoration for some weeks. The sputa of these patients should always be carefully examined for tubercle bacilli. It is best to advise patients to bring the sputum that is expectorated on rising in the morning, and to be careful to bring that which they raise by coughing, not that which they draw from the nose or which comes from the pharynx, for these patients frequently have an associated nasopharyngitis, the secretions from which will not contain tubercle bacilli. Very rarely one meets with a case of acute laryngeal tuberculosis associated with acute pulmonary tuberculosis (hasty consumption), in which the mucous membrane of the larynx is swollen and bright red in appearance. Very characteristic of the tubercular stage is a pale, pear-shaped, edematous swelling found in the ary-epiglottic folds, obliterating the little nodule which indicates the position of the cartilage of Wrisberg. This characteristic pear-shaped swelling is shown as being larger on the left than on the right in Fig. 110, and of equal size on both sides in Fig. 111. Where the tubercles are small and situated just beneath the mucous membrane they appear as grayish elevations the size of the head of a pin. These are frequently seen on the epiglottis, ary-epiglottic folds, and ventricular bands. The tubercles are frequently massed

so as to form a distinct tumor, which may be small and uneven, as shown in the interarytenoid space (Fig. 4, Plate VII.), or as forming a large, lobulated tumor in the same region (Fig. 5, Plate VII.). They are occasionally wart-like, as in Fig. 111. Slight ulceration

FIG. 111.



Tubercular infiltration of the interarytenoid space with tubercular papillomata of both vocal cords. Characteristic edematous infiltration of the ary-epiglottic folds. (COHEN.)

and crust formation may be seen covering the surfaces of these tumors. Small ulcers are frequently found when these crusts are removed. *The appearance of any thickening in the interarytenoid region of the larynx in a patient who has pulmonary tuberculosis is almost certain evidence that this portion of the larynx is involved by tubercle.*

STAGE OF ULCERATION. Examination of the larynx in the ulcerated stage invariably shows edematous involvement of the ary-epiglottic folds. If an ulcer is situated on the epiglottis, the accompanying edema will cause it to be thickened, swollen, pale, and turban-shaped, so as often to make it impossible to view the interior of the larynx. When the ulcer is situated within the larynx, on the ventricular bands, as shown in Fig. 110 on the left ventricular band, it will usually be seen to be irregular in outline, covered with a thin gray or yellow exudation, and the edema of the ary-epiglottic region will be more marked on the side

of the ulcer than that on the opposite side of the larynx. The vocal cords when ulcerated are irregular in outline, often having a serrated appearance. It will frequently be noticed that during attempts at phonation the vocal cords do not approximate in the median line, but that there is a considerable space between them. One vocal cord may lag behind the other in this movement or scarcely move at all. The interference with the movement of the vocal cords may be due to one or more of the following causes: (1) edema in the ary-epiglottic region, or interarytenoid infiltration, mechanically preventing approximation of the arytenoid cartilages; (2) involvement of the muscles of the larynx, whereby their functions are destroyed; (3) loss of substance in the vocal cords through ulceration, (4) paralysis of the recurrent laryngeal nerve, as described above. Tubercle bacilli can be detected in the secretion from these ulcers, and should any doubt as to the character of the ulcer still remain, a small portion of the tissue may be removed, a section of which cut and stained by Gram's method will be found to contain tubercle bacilli.

Differential Diagnosis. Tubercular laryngitis is to be differentiated from syphilitic and lupoid affections of the larynx, and from new growths, whether benign or malignant. Syphilitic ulcerations are distinguished from those found in tuberculosis by their more rapid formation, the deeper excavation of the ulcer, the elevated and more regular boundary zone of congestion encircling them, the greater amount of secretion, and the failure to find tubercle bacilli in the sputum or the physical signs of tuberculosis when the lungs are examined.

Lupus of the larynx can be distinguished from an ordinary tubercular process by the nodule formation in some parts, slight superficial ulceration in others, and the visible cicatrices which are found in still other parts of the larynx. Cicatrization as the result of tubercular laryngitis is not common. The larynx alone is seldom involved in lupus, for the peculiar characteristics of lupus in the pharynx or on the face almost invariably accompany the laryngeal infection, which renders the latter much more easy of diagnosis.

The tubercular infiltration occurring in the interarytenoid space or the posterior wall of the larynx might be mistaken for inflammatory thickening accompanying chronic hypertrophic laryngitis, for a non-malignant growth, such as a papilloma, or for commencing malignant growth. Papillomata, however, are usually more warty and cauliflower-like in appearance than are tubercular growths, and are not accompanied by the peculiar pear-shaped, edematous swelling of the aryepiglottic folds that is so pathognomonic of a tubercular laryngitis. Examination both of the sputum and of the lungs will detect tubercle bacilli on the one hand and the physical signs of pulmonary tuberculosis on the other. While it is possible for a papilloma of the larynx to exist at the same time with pulmonary tuberculosis, the majority of laryngeal growths occurring in patients suffering from pulmonary tuberculosis will be found tubercular in nature.

Malignant growths may be mistaken for tuberculosis of the larynx. In the early stage malignant growths have a dark-red or purplish, congested appearance which is in marked contrast to the pale appearance of tubercular infiltration. The mucous mem-

brane of the larynx in the non-involved portion in malignant disease is also deeply congested, while in tuberculosis it is usually exceedingly pale. Malignant growths are rare before the forty-fifth year, while the majority of cases of tubercular laryngitis occur at an earlier period in the patient's life. The pain in malignant growths is usually severe, even before ulcerations appear, and frequently radiates to the ear on the affected side. Enlarged cervical lymphatic glands are usually present in malignant diseases of the larynx when the tissue breaks down. When ulceration takes place in a malignant growth the expectoration of blood is more common and more profuse than that which occurs in tubercular disease. Lastly, examination of the lungs, of the sputum, and of an excised portion of the growth usually suffices to distinguish between the two conditions.

Prognosis. The prognosis in laryngeal tuberculosis depends (1) upon the character of the tubercular process existing in the lungs and (2) upon the form in which the tubercular involvement of the larynx manifests itself.

(1) Where acute pulmonary tuberculosis is complicated by any form of laryngeal tuberculosis the prognosis is always grave. These cases seldom live more than a few weeks. Another class of cases is met with in which the tendency to cicatrization is not marked, and gradual melting away of large areas in one or both lungs is found. Such patients, when the larynx becomes involved, usually die in a short time in spite of treatment. There is, however, a type of pulmonary involvement in which only portions of the lung are implicated, usually the apices, and in which connective-

tissue formation of a dense character surrounds the involved areas. The disease extends very slowly, and oftentimes the process may be arrested entirely. It is in this class of cases, in which the general health can be improved, that the greatest benefit, and even cure, may be expected as the result of local treatment of the laryngeal disease.

(2) In those rare cases in which the mucous membrane of the larynx is deeply congested and miliary tubercles are scattered through this reddened area, the disease rapidly passes on to the stage of ulceration, and the patient succumbs in a few weeks. In other cases, in which the tubercular infiltration is heaped up into a well-defined tumor in the interarytenoid space, as shown in Fig. 5, Plate VII., and in Fig. 111, the tendency to ulceration may be slight; and when the pulmonary condition admits of improvement years may pass before ulceration takes place. Should ulceration occur in such a growth, active surgical treatment, provided the general health of the patient is such as to admit of it, often results in healing of the ulcer. Where extensive ulceration of the larynx is observed little hope of cure may be entertained. On the whole, laryngeal tuberculosis is at best an exceedingly grave complication in the course of pulmonary disease. While a few cases recover, the majority, owing to extension of the process in the lungs and the discomfort and interference with nutrition resulting from the lesion in the larynx, are in a few weeks, or at most a few months, relieved of their sufferings through death.

Treatment. The treatment of laryngeal tuberculosis should be hygienic, constitutional, and local.

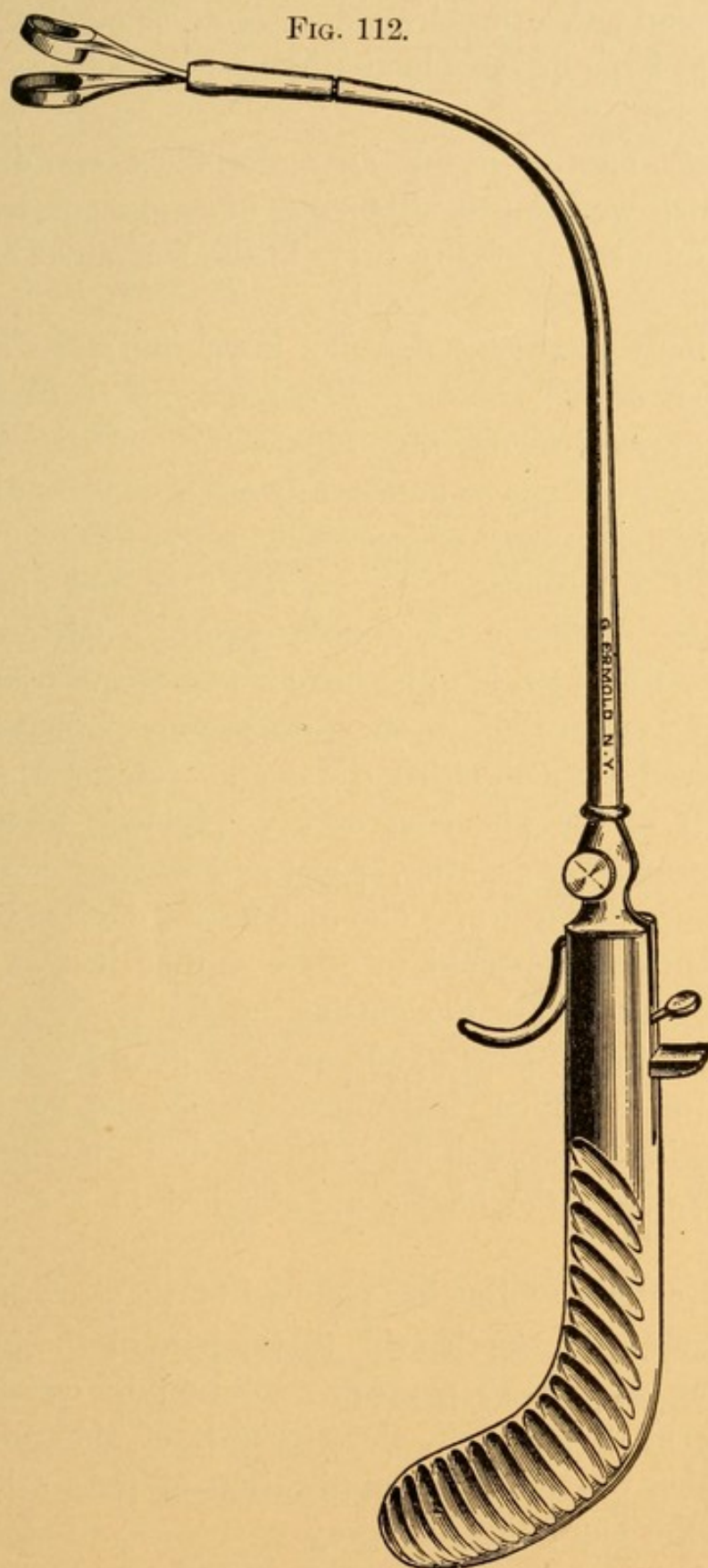
The hygienic treatment consists in placing the patient in such surroundings that the general health may be kept at the highest point possible. Cities are, consequently, unsuitable places for tubercular patients to reside in. They should, if possible, be sent to a warm, dry climate, where they can lead an out-of-door life as much as possible. We have not found that the colder climates, such as are met with in the Adirondacks in the winter and in the mountainous regions of Colorado, agree so well with patients who have laryngeal tuberculosis as the warmer climates found in New Mexico, Southern California, along the Riviera, or in Egypt. The question as to the place most suitable for a given patient is a difficult one to answer, for it has been our experience that what is suitable for one is not for another.

The diet of these individuals should be the most nutritious possible. Milk, either plain or peptonized, according to the patient's taste, buttermilk, and kumyss are all easily digested and assimilated, and should form an important part of the patient's diet.

The patient should be warned in regard to the disposition of his sputum. The best method of disinfecting this is to keep in his room the small cardboard boxes made for this purpose, and once or twice daily to burn them and their contents. Promiscuous expectoration, especially about the house, is rigidly to be cautioned against. There is great danger that other members of the family may thus contract the disease.

The constitutional treatment should be the same as that given for pulmonary tuberculosis—namely, the administration of cod-liver oil, hypophosphites, phos-

FIG. 112.



Author's handle and double curette for removing intralaryngeal growths.

phorus, and either beechwood creosote or guaiacol carbonate in large doses, whichever agrees the better with the patient.

As yet no antitoxin for tuberculosis has been discovered which we think is either safe to employ, or, having been employed, is of any value in the treatment of this disease.

The local treatment depends upon the stage of involvement of the larynx. Tubercular infiltrations, if small and not growing very rapidly, are best left alone. When large enough to produce dyspnea they should be thoroughly cocainized with a 20 per cent. solution of this drug, and after waiting five minutes a second application is to be made. A double curette, such as that shown in Fig. 112, is to be introduced into the larynx, care being taken that in this procedure the blades are not allowed to touch either the tongue, epiglottis, posterior wall of the pharynx, or ary-epiglottic folds, for fear of producing gagging, spasm and contraction of the muscles of the larynx. The instrument devised by the author is to be preferred to other similar instruments, for the reason that the cutting blades remain at the same level in the larynx, and are not drawn up by the stilette, as in other instruments. One is, therefore, able to seize the growth more accurately than is usually the case where the blades are attached to a movable stilette.

The treatment following removal of the growth consists of applying lactic acid to the base of the tumor, beginning with a 25 per cent. solution in water, increasing by 5 per cent. the strength of the solution every other day until the application of pure acid can be borne. The following spray

R.—Menthol	gr. xx.
Ol. eucalypti	℥ss.
Ol. pini pumilionis	℥xv.
Benzoinol	q. s. ad. ℥ij.

M. et Sig.—Use in oil atomizer.

is to given to the patient, with directions to inspire every time that the bulb of the spray apparatus is compressed.


Ulcers in the larynx should be freed from secretion with an alkaline spray, such as:

R.—Sodii bicarbonatis	gr. x.
Aquæ	℥j.—M.

(To this half a teaspoonful of listerine may be added.)

This is best accomplished by means of the Davidson spray tube and Graefe pump for compressing the air. The apparatus (Fig. 113) is very useful, in that it can be

FIG. 113.



Davidson spray tubes and Graefe pump for compressing air.

easily carried to the house of the patient and used in those later stages of the disease which preclude the patient visiting the office of the physician. The parts should then be anesthetized with a 20 per cent. solution of cocaine and the ulcers thoroughly curetted with a

Heryng curette (Fig. 99), the curette A, B, C, D, or E being used, according to which is best adapted to the portion of the larynx in which the ulcer is situated. Lactic acid should then be applied to the base of the curetted ulcer. The process is exceedingly painful at the first curetting, notwithstanding the cocainization, and it is advisable to curette only lightly, for the already edematous condition of the larynx is sometimes so markedly increased that great interference with respiration results. Iodoform insufflated into the larynx by means of the powder blower often assists in healing these ulcers.

In the later stages of ulceration, when deglutition is very painful and the weak condition of the patient precludes operative interference, the sole object of the physician should be to make the remaining days of the patient's life as comfortable as possible. For this purpose the following prescription may be employed :

R.—Morphine gr. x.
 Comp. stearate of zinc gr. xx.—M.

Insufflate a mass the size of a pea, night and morning, by means of the powder blower. Where compound stearate of zinc cannot be obtained, five grains of morphine should be mixed with a drachm of starch and used in the same manner. Orthoform has recently been advocated as an analgesic in painful ulcers in laryngeal tuberculosis. We have employed it a number of times, and while in some cases we think it has afforded relief, in most it has failed. A 10 per cent. solution of cocaine, sprayed into the larynx ten or fifteen minutes before food is taken may diminish the pain of deglutition. There can be no objection to ad-

ministering cocaine to these patients as often as is necessary to relieve pain, for they usually do not live many days. Should sudden edema appear in cases of laryngeal tuberculosis, the propriety of performing tracheotomy must be considered. Many authors recommend this procedure merely for the purpose of making the last hours of the patient's life more comfortable. We never feel justified in performing tracheotomy in a tubercular subject where the pulmonary and laryngeal involvement is so extensive as to make it certain that death must take place in a few days.

The feeding of patients in the ulcerative stage of tuberculosis demands separate attention. Liquids are usually the only substances that can be swallowed, and ice-cold liquids sometimes are more grateful than those which are very warm. Sucking small pieces of ice after cocainization of the parts, as above described, may also help to diminish the swelling and pain, and thereby make deglutition more easy. Patients sometimes can take food by sucking it through a glass tube, with the head hanging over the side of the bed, when they cannot swallow from a glass lying on their back. In extreme cases a small stomach tube may be passed into the stomach and nourishment administered through it. Rectal alimentation is usually the last method to be employed.

LUPUS OF THE LARYNX.

Etiology. Primary lupus of the larynx is exceedingly rare. The disease is usually secondary to lupus of the pharynx or of the face. The condition is due to the action of an attenuated tubercle bacillus upon the submucous tissues in this region. No involvement of

the lungs may be found in this peculiar form of tubercular infection of the larynx.

Pathology. The pathological processes in lupus of the larynx are identical with those which have been described in pharyngeal lupus.

Symptoms. The symptoms that are most marked in laryngeal lupus are change in the voice and difficulty in respiration. The voice is hoarse in the early stages, while later on, when the vocal cords and ventricular bands are involved, the patient can seldom speak above a whisper. Difficulty in respiration is at first slight, but increases gradually until marked dyspnea is experienced. The dyspnea progresses in this disease very differently from that in any other laryngeal affection, owing to the slow but progressive involvement of the laryngeal tissues with nodule formation and cicatrization. Cough is usually of a hacking, irritating character, and the amount of secretion is very slight. Tubercle bacilli are seldom found in the expectoration. No pain is experienced. When the epiglottis and ary-epiglottic folds are very much infiltrated slight interference with deglutition and a sensation as of a foreign body in the throat may be complained of.

Examination. Examination of the larynx will usually show three separate and distinct processes going on at one time: 1. A nodule formation in which these are pale, varying in size from a pin-head to that of the head of a match. 2. Small areas of ulceration over which a thin, grayish, sometimes yellowish secretion may be seen. 3. Areas where the ulcerations have healed, as evidenced by the white, puckered scars, producing great deformity in the laryngeal structures. It

is to these cicatricial contractions, and the consequent narrowing of the respiratory passages in the larynx, that the dyspnea is due. The portions of the larynx most commonly involved are the epiglottis, from which the disease extends to the ary-epiglottic folds, and thence to the ventricular bands. The vocal cords are rarely involved. The epiglottis may be completely destroyed by the ulcerative process.

Differential Diagnosis. The only disease for which this is likely to be mistaken is tertiary syphilis of the larynx. In tertiary syphilis the history will be that of a gumma which rapidly breaks down and gives rise to an ulcer from which the secretion and consequent expectoration are profuse. The whole course of syphilitic disease is much more rapid than the slow, often interrupted, progress of lupus. Laryngeal syphilis is often accompanied by manifestations of tertiary syphilis in other regions of the body, while lupus of the larynx will be secondary to lupus of the pharynx or the face. Removal of a lupoid nodule and examination of this under the microscope will show the presence of giant-cells, in which may be found the tubercle bacillus.

Prognosis. Laryngeal lupus is practically never cured. Its progress may be arrested for a time, but it will eventually break out anew, and finally terminate the patient's life.

Treatment. The constitutional treatment of lupus should be the same as that advised for this disease when it affects the pharynx. The local treatment should consist in removal of the lupoid nodules under cocaine anesthesia, by means of some suitable forceps. The double curette of the author (Fig. 112) is well

adapted to this purpose. Following removal of the nodule the surface should be painted with a 50 per cent. aqueous solution of lactic acid by means of a cotton-wound applicator. This application should be made every third day until cicatrization is obtained. Where such stenosis following cicatrization greatly impedes respiration tracheotomy should be performed. The intubation tube usually is of no value in these cases, because (1) it is difficult to introduce one of sufficient size, and (2) the pressure from the tube excites the laryngeal disease to renewed activity.

SYPHILIS OF THE LARYNX.

Syphilis of the larynx may be either (*a*) acquired or (*b*) inherited.

(a) Acquired Syphilis of the Larynx.

Acquired syphilis may present as (1) primary, (2) secondary, and (3) tertiary manifestations.

(1) PRIMARY SYPHILIS OF THE LARYNX.

Infection of the larynx with a chancre is an exceedingly rare occurrence. The epiglottis is the only site upon which a chancre has been observed. The diagnosis of a chancre in this region will be a matter of more or less doubt until secondary manifestations appear. Mercury should not be given until there is absolute certainty that the infiltration is due to chancre, for should an ulcer heal while the patient is taking mercury the physician and the patient might easily be misled as to its character.

(2) SECONDARY MANIFESTATIONS OF SYPHILIS IN THE LARYNX.

These are either an erythema or the mucous patch.

Etiology. Secondary manifestations of syphilis in the larynx may follow the appearance of a chancre upon any portion of the body. It apparently does not occur more frequently in cases in which the primary sore is situated on the lips, tongue, or tonsil than in those in which it is situated elsewhere on the body. Secondary manifestations may be noted before complete healing of the primary sore has occurred, or may be observed as late as the second year after infection. The usual period during which secondary lesions are observed is from the third to the ninth month following the chancre. Patients subject to acute or chronic inflammations of the larynx are more prone to the secondary manifestations of syphilis in this region. It is rare to find evidences of secondary syphilis in the larynx without similar conditions in the pharynx. The larynx, however, is not involved nearly so frequently as is the pharynx.

Pathology. The erythematous stage is characterized by a hyperemia of the larynx of a mottled character, differing somewhat from the even and brighter red appearance of the mucous membrane in simple acute laryngitis. The mucous patches are produced in a manner similar to their production elsewhere in the body, namely, round-cell infiltration into the epithelial and, to a moderate extent, the subepithelial tissues, with a coagulation necrosis involving usually only the superficial epithelium. Should the coagulation necrosis involve the subepithelial tissues, a slight ulcer may result, but this condition is very uncommon. The

necrotic area presents the appearance of a faint, milk-white, non-elevated exudation, which may either blend into the surrounding erythematous mucosa, so that its boundary lines are indistinct, or, as more frequently happens, a narrow, reddened zone of inflammation borders the mucous patch. In the larynx patches are seldom so symmetrically situated as in the pharynx. Mucous patches may be found on the epiglottis, vocal cords, ary-epiglottic folds, and ventricular bands, or on the posterior wall of the larynx between the arytenoid cartilages.

Symptoms. The symptoms of secondary syphilis of the larynx are practically those of a mild, but rather chronic, laryngitis. The voice is apt to be somewhat hoarse, and there is a slight secretion which annoys patients and causes them repeatedly to clear the throat. Respiration is seldom interfered with, and deglutition is painful only when the patches are on the epiglottis and ary-epiglottic folds, when it will be noticed that hot or cold articles of food and those which are highly seasoned cause a smarting or burning sensation referred to the back of the throat.

Examination. Examination of the larynx will show either the erythema or the patches, having the appearances and in the situations described in the pathology.

Differential Diagnosis. It is possible that the erythema may be mistaken for acute laryngitis, or even chronic laryngitis. The mottled appearance of the mucous membrane should always arouse suspicion as to the nature of the inflammation and cause the physician to seek for other evidences of syphilis, such as eruptions on the skin, enlarged lymphatic glands in the suboccipital, femoral, and epitrochlear regions; falling out of

the hair; nocturnal headache; mucous patches in the pharynx and around the genitals and anus. It is possible that a mucous patch might be mistaken for a diphtheritic exudation, but the thin character of the exudate in the presence of some or all of the above-mentioned evidences of secondary syphilis usually suffices to differentiate these conditions.

Prognosis. Secondary syphilis of the larynx usually heals kindly. The physician should always be exceedingly careful in examining the throats of patients with secondary manifestations of syphilis in the larynx. As the pharynx is often exceedingly irritable, gagging and coughing are frequently induced, either during the examination or while applying remedies to the larynx, and there is the greatest danger that some of the secretions may be coughed into the face of the examiner, who may thus become inoculated. It is my custom always to direct these patients to turn their heads a little to one side, usually toward the patient's left, while my head is held a little to the right of the patient. By this means we are out of the direct line of any mucus that may be ejected during coughing. The patient is instructed to turn his head still further to the left with the first evidence of gagging, while we unconsciously move ours in the opposite direction, so as to be still further away from the line of the ejected material. It is the custom of some laryngologists to have a glass plate suspended from the ceiling or from a wall-bracket, between the face of the patient and that of the examiner, so as to intercept any material expectorated by these patients.

Treatment. The erythematous condition of the mucous membrane is usually remedied by the admin-

Hg.

Snal.
Ag₂O₃

istration of protoiodide of mercury, which should be given in the doses and in the manner described in the article on Syphilis of the Nose. For the mucous patches the same internal medication is to be employed and the patches touched with a cotton-wound applicator that has been dipped in a solution of nitrate of silver, 30 grains to the ounce. Care must be taken that the cotton does not contain an excess of the solution, for fear that some of the liquid may pass into the trachea and produce severe coughing and inflammation.

(3) TERTIARY SYPHILIS OF THE LARYNX.

Tertiary syphilis of the larynx may present in two stages: (a) the gumma, and (b) the ulcer, which results from necrotic changes taking place in the gumma.

(a) *The Gumma.*

Pathology. This consists of a mass of round-cells, which infiltrate the submucous and occasionally the deeper structures of the larynx. A gumma is usually round or ovoid in shape, varying in size from a match-head to a hickory-nut. Where several gummata are found close together the surface, instead of being rounded and smooth, is often lobulated, showing elevations and depressions. The common places on which they are found are the epiglottis, the ary-epiglottic folds, ventricular bands, and posterior wall of the larynx over the cricoid cartilage. Proliferation of cells in a gumma of the larynx is usually rapid, although we occasionally meet with slow-growing gummata. In the former variety necrosis and ulceration usually quickly ensue; in the latter variety the tendency to ulceration is not so great as in the former.

Under appropriate treatment the gumma may entirely disappear. Without it ulceration, with the subsequent changes later described, will ensue.

Symptoms. The symptoms of a gumma of the larynx depend upon the situation of the mass. Where the epiglottis is involved the more prominent symptoms are difficulty in swallowing, sensation as of a lump in the throat, and slight pain during deglutition. When the ary-epiglottic folds are involved, in addition there will be difficulty in respiration, depending upon the size of the tumor, and the voice will be hoarse or aphonic, depending upon the amount of interference with the movements of the vocal cords. Where the gumma is situated on the ventricular bands or the posterior wall of the larynx dyspnea is more marked, and there is hoarseness or aphonia as well. Deglutition is usually not interfered with where the gumma is situated in either of the two latter positions.

Examination. Examination of the larynx will reveal the presence of a swelling that is bright or dusky red in color, and the mucous membrane unbroken. When the larynx is cocainized and this mass touched with a probe it is found to be moderately firm in consistency.

Differential Diagnosis. In appearance a gumma may closely resemble early invasion of the larynx by a malignant growth. The latter, however, grows more slowly than do gummata, is accompanied by a greater amount of pain, and its consistency is usually firmer than that of gummata. It is often very difficult to decide, when seeing a patient for the first time, as to the exact nature of any such growth in the larynx. Even when a history of syphilis in former years is denied it is advisable to place these patients upon a

thorough course of treatment with potassium iodide, which should be administered in large doses, and the effect upon the growth observed. If it be a gumma, retrograde processes cause a rapid and steady diminution in size, and finally disappearance of the mass. In malignant growths a slight diminution in size may take place for two or three weeks, after which the growth increases in size even while the iodides are being taken in large doses. It is always well in these cases to remove a portion of any growth whose character is suspicious, and to make a microscopical examination to determine its nature.

Prognosis. Gummata, when seen early, before softening has taken place, usually subside in from three to six weeks, the time varying with their size. If softening has begun, it usually continues, and an ulcer develops.

Treatment. As has been inferred, the treatment consists in the administration of large doses (20 to 60 grains) of potassium iodide three times a day.

KI.

(b) *The Ulcer.*

Pathology. Tertiary syphilitic ulcers result invariably from the breaking down of gummatus infiltrations. It often happens that these infiltrations are of a diffuse character, and produce so little discomfort while in this stage that the patient does not apply for treatment until necrosis and ulceration have occurred. This is, perhaps, observed more frequently in the larynx than in any other portion of the respiratory tract. The changes which accompany a syphilitic ulcer in the larynx depend in part upon the position in which the ulcer is found and in part upon the depth of the tissues involved. When situated upon the epiglottis it is not

at all uncommon to find partial or even total destruction of this organ, and even the base of the tongue may be implicated in the ulcerative process. Where the ulcer is upon the ary-epiglottic folds these may be involved to such an extent that when healing takes place the epiglottis may be twisted from its symmetrical shape by the contraction of the cicatrix. The entrance into the larynx will usually be asymmetrical and narrowed. The arytenoid cartilages are very apt to be involved in the ulcerative process in this region, being either necrosed or extruded, resulting in ankylosis of the crico-arytenoid articulation. Ulcerations involving the ventricular bands very frequently implicate also the vocal cords, which may result in destruction of the latter to a greater or less extent. Should the ulceration implicate the adjacent margins of both ventricular bands or both vocal cords, union of the granulation tissue along the edges of these frequently takes place, producing a marked narrowing or stenosis of the larynx. When the ulcer is situated on the posterior laryngeal wall in the interarytenoid space the perichondrium of the cricoid cartilage is frequently implicated, and a perichondritis, with subsequent death of the cricoid cartilage, prolonged suppuration, and marked deformity of the larynx, as described in the article on Perichondritis, result.

Symptoms. The symptoms are dependent somewhat upon the situation of the ulcer. Where the epiglottis and ary-epiglottic folds are involved great difficulty of respiration and pain during deglutition will be experienced. The patient may so dread this pain that it becomes difficult for him to take sufficient nourishment, and emaciation is marked. Where the interior of the

larynx is involved dyspnea is a marked symptom. At any stage in the ulceration there may be a sudden edema of the larynx, which markedly increases the dyspnea, so that the patient is in great danger of asphyxia unless quickly relieved by tracheotomy. There is almost always expectoration of a mucopurulent character, which may occasionally be blood-tinged. Where the cartilages are involved as a result of the perichondritis a fetid odor of the breath and of the expectorated material will be noticed.

Examination. Examination of the larynx shows very different appearances according to the situation of the growth and the processes accompanying the ulceration, as have been noted in the pathology. The ulcers appear as deeply, excavated areas, covered with a dirty yellowish slough, with a considerable amount of secretion in the immediate neighborhood of the ulcers. Surrounding an ulcer is an elevated, indurated zone, in which the bloodvessels are in a state of passive hyperemia. Fig. 6, Plate VII., gives a very fair idea of a syphilitic ulcer on the ary-epiglottic fold over the left arytenoid cartilage, while the arytenoid region on the right side shows tumefaction and abscess formation just antedating the appearance of the ulcer. The vocal cords in this figure also show the irregular, ulcerated margins frequently seen in syphilitic laryngitis. Im-mobility of a vocal cord will be observed if the ary-tenoid cartilage be involved in the ulceration.

Differential Diagnosis. The two diseases for which this condition is most likely to be mistaken are malignant growths and tuberculosis of the larynx. In malignant disease there is usually more pain; less secretion; hemorrhage is greater and more profuse;

the glands of the neck are apt to be implicated. The administration of potassium iodide and mercury has little or no effect upon a malignant growth, while markedly benefiting a syphilitic ulcer; and, finally, microscopical examination of an excised portion of the growth reveals its nature.

The diagnosis between tubercular and syphilitic ulcers has been given in the article on Tuberculosis of the Larynx.

Prognosis. The prognosis in a syphilitic ulcer of the larynx should always be a guarded one. Where there is any tendency to edema this may suddenly markedly increase, and the patient may become asphyxiated and die unless quickly operated upon. When the ulcerations heal there is great danger that such deformity and stenosis of the larynx may be produced that intubation or tracheotomy may be necessary in order to save the patient from asphyxiation. Where the vocal cords are implicated, or where ankylosis or destruction of the arytenoid cartilages follows the ulcerative process, the voice is markedly impaired and usually aphonic.

Treatment. The constitutional treatment in these cases should be the administration of large doses of potassium iodide. Mercury, as directed for the tertiary lesions of the pharynx (*q. v.*), may sometimes be advantageously given with the iodide. Cod-liver oil and tonics assist in maintaining the general health.

The local treatment consists in first removing the thickened secretions from the ulcers by spraying with an alkaline solution, and subsequently applying nitrate of silver (60 grains to the ounce of water) to the ulcer-

KI
Hg.
tonics

Spray
20 gr. NO_3

ated surface by means of a cotton-wound laryngeal applicator. If any tendency to edema of the larynx be observed, the patient should be carefully watched lest this increases, and preparations should be made to perform tracheotomy at a moment's notice. Where intubation can be employed this may be attempted, but the parts are often so swollen as to make this procedure difficult or impossible. With the first evidence of perichondritis the treatment as advocated in the article on that disease should be carried out. To diminish the tendency to edema the patient should be kept in bed in a warm, moist room, and should be instructed to breathe the steam from a croup-kettle in which a teaspoonful of compound tincture of benzoin and one-half a teaspoonful of turpentine to each quart of water have been placed.

The treatment of the stenosis resulting from tertiary ulcers of the larynx will be given in the article on Laryngeal Stenosis.

(b) Inherited Syphilis of the Larynx.

CONGENITAL LARYNGEAL SYPHILIS.

The majority of cases of congenital laryngeal syphilis are observed during the first eighteen months of child life. Occasionally the disease does not manifest itself until about the time of puberty.

Pathology. The pathological processes are practically the same as those occurring in acquired syphilis. The disease manifests itself in the form of either superficial or deep ulcers.

Symptoms. One of the earliest symptoms noticed is the peculiar bleating, almost voiceless, cry of the child.

A cough lacking in tone is frequently observed. Respiration is usually impeded, the child breathing quickly and with evident distress. Laryngismus stridulus often occurs. Edema of the larynx may occur, necessitating tracheotomy to prolong the child's life. Where the ulcers involve the epiglottis and ary-epiglottic folds difficulty in deglutition, so marked that the child nurses or takes the bottle with great difficulty, will be observed. Emaciation and a wrinkled condition of the skin almost invariably result. Other evidences of syphilis are usually to be detected either in the pharynx, in the characteristic eruptions of the skin, or in the fissures at the angles of the mouth and around the anus. In children who have passed through the second dentition characteristic Hutchinson's teeth can be recognized.

Examination. It is usually impossible to get a view of the larynx in so young a child. The other evidences of syphilis that have been described, together with the symptoms noted by the mother and observed by the physician, suffice for diagnosis.

Prognosis. The prognosis in the cases of children under two years of age is exceedingly grave. Very few of them recover from the disease. The causes of death are either asphyxia, marasmus from inability to take food, or bronchopneumonia from passage of the purulent secretions of the larynx into the bronchi and alveoli of the lungs. Older children may recover, in which case deformity and stenosis of the larynx often result.

Treatment. The local treatment is the same as for acquired tertiary syphilis (for the constitutional treatment, see page 166).

LARYNGEAL STENOSIS.

Laryngeal stenosis may be congenital or acquired. Congenital webs have been observed to pass from one vocal cord to the other, so as to leave but a small opening, usually near the posterior portion of the larynx, through which the respired air may pass. These webs are usually considered evidences of congenital syphilis, resulting from ulcerative processes involving the larynx during fetal life.

The acquired stenoses may be divided into those which are acute and those which are chronic. Acute laryngeal stenosis comes on quickly, is slight or severe, demands immediate operative treatment for relief of the dyspnea, and usually subsides with the disease of which it is a part. The chronic forms of stenosis come on more gradually and are often steadily progressive, and it is not until late in their course that there is urgent demand for operative interference. It is surprising how little air enters the larynx in this form of stenosis when the patient has gradually become accustomed to the condition.

Etiology. The causes of acute stenosis are those diseases in which a membranous exudation is formed in the larynx, such as laryngeal diphtheria and membranous laryngitis. Any disease accompanied by edema of the larynx (*q. v.*) will produce an acute stenosis. A small amount of edema in the subglottic region of the larynx produces more grave symptoms than a similar amount in any other portion of the upper respiratory tract. Bilateral paralysis of the abductors of the vocal cords, when sudden in its onset, will produce intense dyspnea. The chronic forms of laryngeal steno-

sis are most frequently associated with the cicatrization following tertiary syphilitic ulcers of the larynx. It may be produced by tuberculosis, malignant growths, and also by lupus and rhinoscleroma. The contraction following perichondritis often results in severe stenosis of the larynx. Laryngeal stenosis may be produced by ankylosis in the crico-arytenoid articulation, especially where fixation of the vocal cords near the median line occurs.

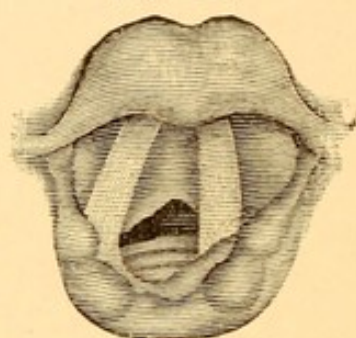
Pathology. The pathology of laryngeal stenosis has been given in the articles treating of the several diseases liable to cause stenosis. It remains only to explain the formation of a web extending across the larynx. This is due to the formation of an ulcer which leaves two opposing granulating surfaces, usually on adjacent edges of the vocal cords, although sometimes on the internal edges of the ventricular bands. As the vocal cords at their anterior ends come in close proximity to each other, and are but slightly movable during respiration and phonation, the two granulating surfaces are united by the organization of the granulation tissue. The contraction of this cicatricial tissue brings the edges of the vocal cords or ventricular bands posterior to the web closer than normal, and any slight ulceration is apt to result in extension of the web from before backward, until finally it may involve one-half to two-thirds or more of the length of the vocal cords or ventricular bands (Fig. 114).

Symptoms. The symptoms of acute stenosis have been given several times—namely, in the articles on Laryngeal Diphtheria and Edema of the Larynx. The symptoms of the chronic forms of stenosis are two—namely, change in the character of the voice (which is

often aphonic or whisper-like), and dyspnea. The latter is often only moderate in amount, providing the patient remains at rest; but on attempted exertion dyspnea is very much intensified, so that cyanosis becomes marked.

Examination. Examination of the larynx in the acute form of stenosis will reveal a membranous exudate, edema, abscess, foreign body, or whatever form the obstruction may take. In the chronic

FIG. 114.



Laryngeal stenosis due to web between the vocal cords.

forms the presence of a deformed larynx, with bands of adhesions between the vocal cords, as described in the pathology, or the presence of a tumor, or paralysis and fixation of the vocal cords, will be observed.

Prognosis. In acute laryngeal stenosis, unless it be of the diphtheritic variety, the prognosis is fair. In the chronic forms of stenosis all that can be done is to dilate the constriction, and trust that contraction may not recur, as it often does. Where the stenosis is due to malignant disease the prognosis is grave, and the relief offered by tracheotomy is only temporary.

Treatment. Acute laryngeal stenosis demands immediate intervention either by intubation or by tracheotomy. If tracheotomy is performed, the tube should be removed at the earliest possible date, as prolonged

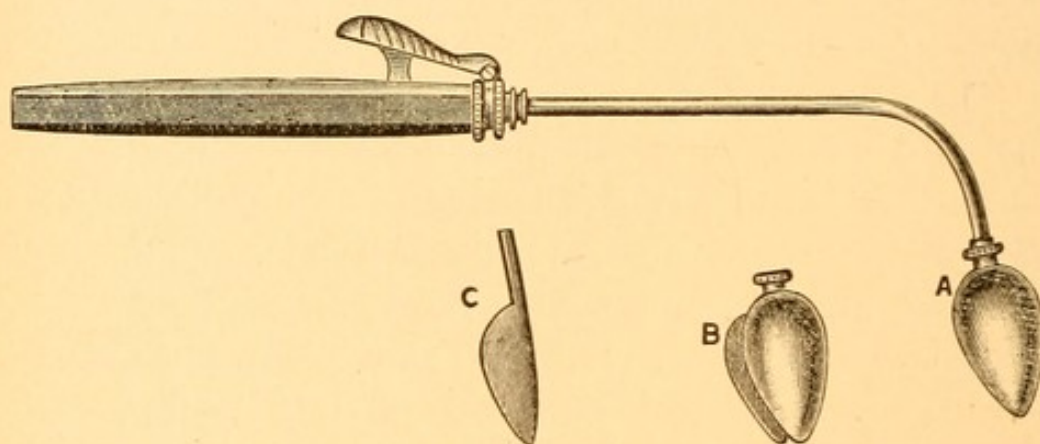
retention of the tube produces paresis or paralysis of the abductor muscles in the larynx, in which event it is often impossible to dispense with the tracheotomy tube, owing to the obstruction that the vocal cords in the adducted position offer to the entrance of air. The trachea also in the immediate neighborhood of the tracheotomy tube is apt to become filled with granulation tissue, and this, after removal of the tube, may so narrow the lumen of the trachea at this point as to cause intense dyspnea, and often necessitates reintroduction of the tube.

The treatment of chronic stenosis, especially that form due to cicatrization and contraction resulting from ulcerations in the larynx, demands special notice. The first procedure that may be adopted is that of dilating the small opening in the larynx by means of Schroetter's laryngeal tubes. These act in very much the same way as sounds in dilating a urethral stricture. The tubes are made of hard rubber, are hollow, of various sizes, and are properly curved for introduction into the larynx. The larynx should first be cocainized, a small-sized tube warmed, coated with vaseline, and then passed into the larynx, the forefinger of the left hand being inserted into the mouth to lift up the epiglottis. The tube should be left *in situ* two or three minutes, the patient breathing through the lumen of the tube. A second and slightly larger tube should then be introduced and allowed to remain the same length of time. At the first sitting these two tubes may be all that can be employed. At the end of forty-eight hours dilatation should again be practised, using larger-sized tubes, until finally by dilating at intervals of two or three days the largest-sized tubes may be introduced into the larynx and left there for ten or fifteen minutes. This

merely stretches the cicatricial tissue, as is the case in the introduction of sounds into the urethra for similar purposes. The cicatricial tissue may contract after weeks or months, and leave the stenosis nearly if not quite as marked as before, unless the tubes are inserted at intervals of one, two, or three weeks.

Another method, where a web exists between the vocal cords, is the employment of Whistler's cutting

FIG. 115.



Whistler's cutting dilator.

dilator (Fig. 115). The knife (*C*) is concealed during the introduction of the bulb dilator (*A*), and is only released (*B*) so as to incise the web when the dilator is pushed well down in the strictured portion of the larynx. The edges of the cut so made quickly reunite unless the dilator is introduced daily to break up adhesions until cicatrization of the margins of the cut takes place.

In this country the method that is given the preference for dilating stenoses is the introduction of a large-sized O'Dwyer intubation tube by means of the same sort of instruments that are employed in laryngeal diphtheria. This may be done under cocaine, or, if neces-

sary, after the administration of ether. Several sizes of tubes should be at hand. At first it may be necessary to introduce a small tube, allowing it to remain a few minutes, and then to insert a large tube, which is to remain in the larynx. These tubes should be worn from one to four weeks; they should then be removed, and the respiration carefully noted. It may be several months before the patient can dispense with the tube. The tube should never be inserted into the larynx of a syphilitic patient so long as ulceration exists. The ulcers should be treated locally and constitutionally until they are healed, after which intubation is to be attempted.

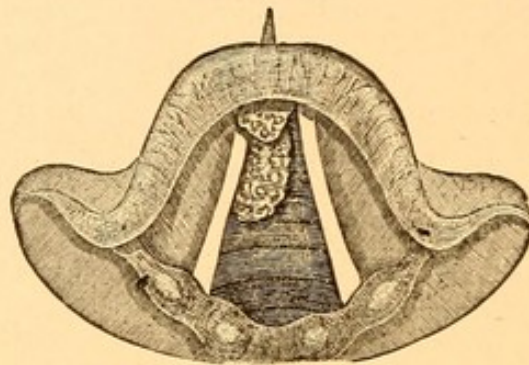
Where it is impossible to introduce the intubation tube, or where its retention causes great pain, as sometimes, happens, tracheotomy is the only other resource. This is the operation that will have to be performed in the chronic stenoses met with in malignant growths of the larynx. In cicatricial contractions it may be possible to introduce a dilator through the tracheotomy wound into the larynx from below, and so dilate the stricture that subsequently the tracheotomy tube may be removed.

NON-MALIGNANT GROWTHS OF THE LARYNX.

Etiology. The exciting cause of these growths is unknown. There is occasionally a history of irritation of the laryngeal mucous membrane, such as may be seen in chronic laryngitis, but in the majority of cases no such history can be obtained. These growths appear at all ages, but are more common in adult life. They are more frequently observed in males than in females. A few cases of congenital new growths have been reported. Judging from the number of cases reported in French

and German literature, benign tumors of the larynx are met with more frequently in the inhabitants of those countries than in the United States. The varieties of tumors found are: papillomata, fibromata, cysts, polypi, lipomata, angiomata, chondromata, adenomata, and mixed forms of tumors. Papillomata are met with more frequently than all the other varieties combined.

FIG. 116.



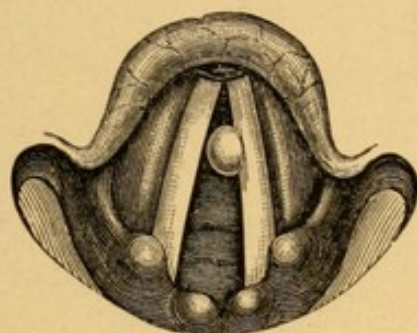
A small papilloma springing from the anterior commissure and resting on the right vocal cord. A papilloma also is shown arising in the subglottic region of the larynx beneath the right vocal cord.

Pathology. 1. Papillomata consist of connective tissue in various stages of organization, in the meshes of which is found round-cell infiltration. They are covered with an exceedingly thick layer of stratified epithelium. Their surfaces are warty or cauliflower-like in appearance. They are usually attached by a somewhat broad base, but are also found as pedunculated masses having a small point of attachment. They may be either single or multiple. Their color is usually a pale pink, although their free portion, if movable, may be a somewhat brighter red, as shown in Fig. 7, Plate VII., where a broadly attached papilloma is situated at the junction of the anterior and middle third of the left vocal cord, projecting across the glottis, with the free edge resting upon the right vocal cord. The more common situations from which papillo-

mata of the larynx spring are the vocal cords, ventricular bands, subglottic region of the larynx (as shown in Fig. 116), the ary-epiglottic folds, and the epiglottis.

2. Fibromata consist of dense connective tissue, usually covered only with a thin layer of stratified or columnar epithelium. In shape they are rounded or

FIG. 117.



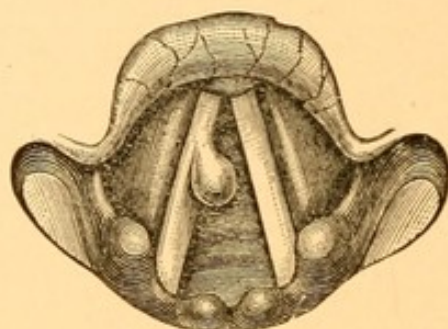
Fibroma on the left vocal cord.

oval, smooth in contour, and pale in color. They are almost always attached by a rather broad base (as shown in Fig. 117, in which a fibroma of the left vocal cord is depicted). Fibromata vary in size from a pin's head to a pea.

3. Cysts are usually due to the sealing up of the mouths of mucus-secreting glands, and to the retention in and distention of the ducts of the glands by the secretions. Cysts may be small or quite large, and are usually attached by a broad base. Attention has been called recently to the fact that the walls of these cysts are in some cases observed to contain giant-cell formation and tubercle bacilli. There may be no other evidences of tuberculosis in an individual having such a cyst. The positions in which cysts are most commonly found are the ventricular bands, ary-epiglottic folds, epiglottic, protruding from the ventricles of the larynx, and, rarely, from the vocal cords.

4. Polypi are usually semitranslucent bulbous masses. Their structure resembles very much that of nasal polypi, although the amount of connective tissue in a laryngeal polyp may be greater and more dense than that observed in polypi arising from the nasal mucous membrane. Their most common situation is on the

FIG. 118.



A polyp on the right vocal cord.

vocal cords (Fig. 118, in which a polyp is depicted as springing from the anterior third of the right vocal cord). They are sometimes found springing from the laryngeal surface of the epiglottis.

5. Lipomata are fatty, lobulated, pale or yellowish growths attached by a broad base, and usually springing from the ary-epiglottic folds. Their tendency is to enlarge in a lateral and downward direction into the pyriform fossa.

6. Angiomata consist of a mass of dilated bloodvessels. They are irregular in outline and usually attached by a broad base. Their color is a deep red or purple; their size varies from a pin's head to a small marble. They are found most frequently on the vocal cords, ventricular bands, and epiglottis.

7. Chondromata are firm, dense masses, somewhat irregular in their general outline, and pale in color. They are invariably attached by a broad base, and

microscopically are seen to consist of hyaline cartilage. They spring most frequently from the cricoid or thyroid cartilage, but have been observed on the epiglottis and arytenoid cartilages.

8. Adenomata are broad-based, irregularly outlined tumors springing from the laryngeal surface of the epiglottis. Histologically they are composed of masses of glands held together by loose connective tissue.

Symptoms. The symptoms produced by benign tumors depend partly upon their situation and partly upon the size of the growths. When situated within the larynx proper, as on the vocal cords, ventricular bands, in the interarytenoid space, or on the posterior laryngeal wall, they interfere with vocalization and respiration. The voice is first observed to be hoarse, and subsequently, as the growths increase in size and interfere further with the action of the vocal cords, the voice becomes aphonic. Pedunculated growths springing from the vocal cords or the ventricular bands may drop down between the vocal cords and interfere with their approximation, producing hoarseness or aphonia. An expiratory blast of air may force them up to the supraglottic region of the larynx, when the voice may suddenly become perfectly clear. This changeability in the character of the voice is more marked in the pedunculated tumors. Respiration will be interfered with when the growth markedly narrows the lumen of the glottis. Ordinarily the interference with respiration is a slow, gradual process, and the patient complains of dyspnea only upon exertion. Papillomata in the subglottic region produce more dyspnea than supraglottic growths of an equal size. Large supraglottic growths have occasionally become caught between the vocal cords, producing sudden and extreme dyspnea

and cyanosis. The benign tumors are usually slow in development, and may exist in the larynx for several months before attaining such a size as to produce symptoms. Pain is practically never complained of, and the growths rarely evince any tendency to ulceration. Cough of a reflex character is often observed, but there is usually no expectoration, or only that of a little thick, tenacious mucus, such as accompanies hypertrophic laryngitis. Unless the growth is large and springs from the ary-epiglottic region, difficulty in deglutition will not be experienced.

Examination. Examination of the larynx will show a tumor, usually pale in color, and having one of the appearances described in the pathology, according to the nature of the growth.

Differential Diagnosis. Benign tumors are to be differentiated from malignant growths. In the latter the growth is more rapid, accompanied by pain, with a tendency to ulceration and expectoration of muco-pus and blood. The lymphatics of the neck may be enlarged, and cachexia is present late in the disease. Malignant growths are usually more deeply congested and purplish in color, as shown in Fig. 8, Plate VII., in contrast to the pale, non-congested appearance, not only of the tumor, but of the surrounding mucous membrane as well in benign growths. It may be difficult to differentiate between malignant growths and benign ones in their very early development, and no examination should be considered complete in doubtful cases without first having removed a portion of the mass for microscopical examination.

Prognosis. Prognosis, so far as life is concerned, in benign tumors of the larynx is good unless these growths be of a very large size and have a tendency

Malignant

suddenly to drop and fill the glottis, in which case sudden death may occur from asphyxia. The most common variety—papillomata—have a great tendency to return, owing to the difficulty of completely eradicating the growth or of knowing when this has been accomplished. Where the growths are attached by a broad base it not infrequently happens that as a result of operation for their removal, whether intralaryngeal or extralaryngeal, a portion of the vocal cord may also be removed or the cicatricial contraction so interferes with the functions of the cords that slight or marked hoarseness or even aphonia may remain permanently after the removal of the growths. Spontaneous cures of benign tumors of the larynx have frequently been recorded.

Treatment. Benign tumors should be removed in whatever manner seems most likely to effect a cure with the least danger to the patient, so far as life and the subsequent use of the voice are concerned. There are three general methods for removing these growths. One is known as the intralaryngeal method, by which suitable instruments are inserted through the mouth and so into the larynx, guided accurately by the aid of the laryngeal mirror, and the growths removed either piecemeal or entirely at one sitting. This method may be employed for removing small growths, whether pedunculated or attached by a broad base, provided they are situated above the vocal cords. It may also be employed for the papillomatous variety of broad-based tumors. Only those skilled in the use of laryngeal instruments should undertake the removal of growths by this method, as there is great danger of catching and removing healthy portions of the vocal cords, with consequent impairment of the voice.

Extralaryngeal methods consist in reaching the

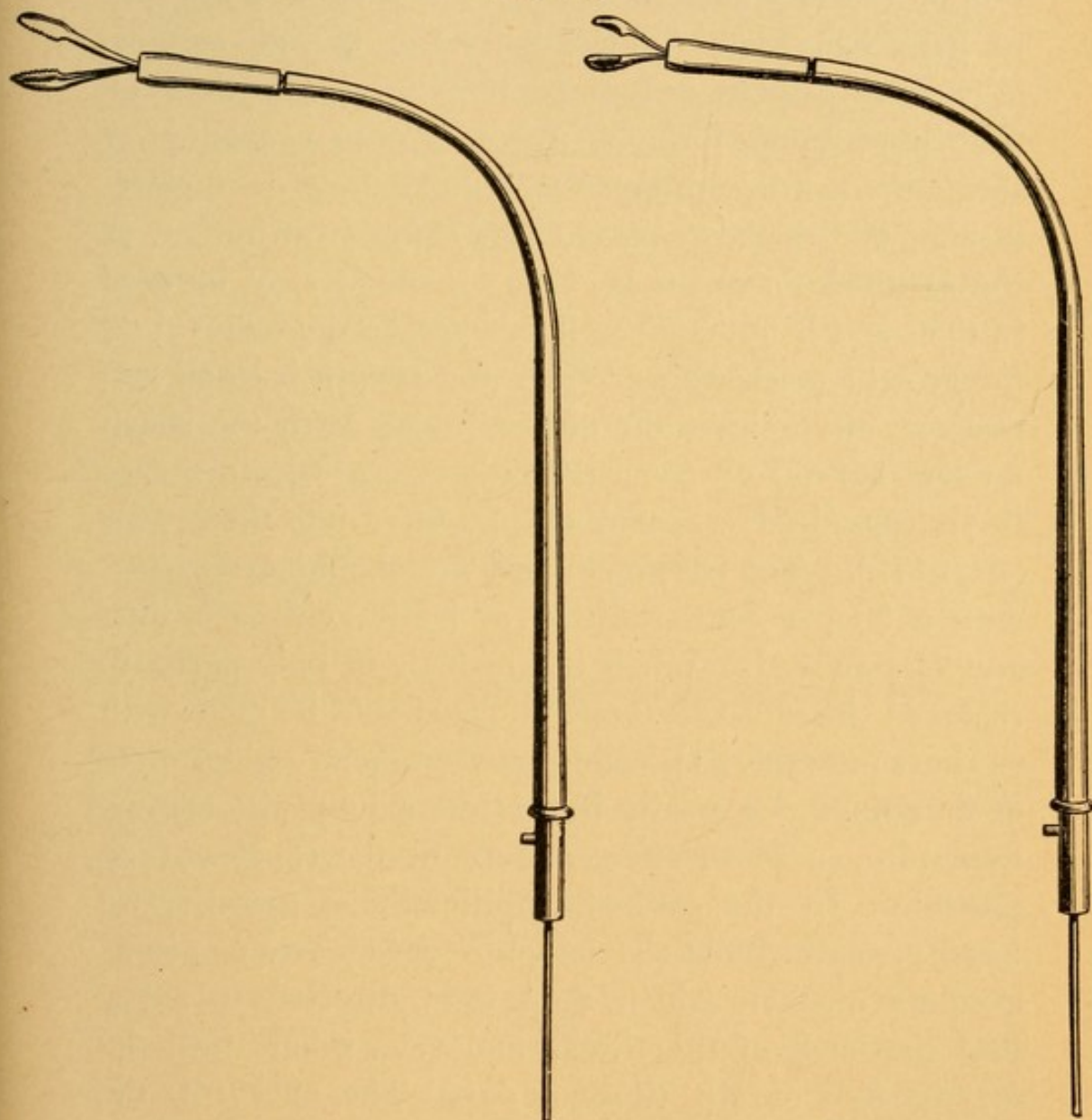
growth through thyrotomy, tracheotomy, or an incision through the thyrohyoid membrane, and are to be employed in the removal of subglottic growths, or those which are of a firm, dense consistency and attached by a broad base, and oftentimes for those rapidly recurring papillomata that nearly, if not quite, fill the supraglottic portion of the larynx, and in which intense dyspnea and danger of asphyxiation occur.

The third method is that of direct laryngoscopy with the aid of either the Killian or Jackson tubes. For this method the pharynx and larynx are thoroughly cocainized, and, if necessary, a general anæsthetic may also be employed. With the neck bent backward, a straight tube is passed through the mouth and pharynx into the larynx. Straight cutting or punching forceps of suitable size and shape are passed through the tube to the seat of the growth. In the Killian set the source of illumination is an electric light projected from a Kerstein lamp on the forehead, or a Brüning's lamp attached to the handle of the instrument. In the Jackson set there is a small electric lamp at the distal end of the tube.

Intralaryngeal operations for the removal of new growths are to be done with the aid of cocaine. A 20 per cent. solution should be applied to the interior of the larynx with a cotton-wound laryngeal applicator, and at the end of five minutes a second application usually suffices to deaden the sensibility of the larynx so that suitable instruments may be inserted and the growth seized and removed. Few patients have both the knack of protruding their tongues and sufficient control over the muscles of the pharynx to allow one to remove the growth at the first visit. It is advisable in nervous patients to cocainize the larynx and simply introduce a probe at the first one, two, or three visits, until the

confidence of the patient and his aid can be secured before any attempt at removal of the growth is undertaken. Pedunculated growths may be included

FIG. 119.



A
Author's serrated laryngeal forceps.

B
Author's lateral cutting laryngeal forceps.

in the wire of a snare and removed in the same way that polypi are removed from the nose. The canula and stylet made for this purpose are curved for entrance

into the larynx, and fit into the Schroetter handle (Fig. 25). All instruments should be warmed before being introduced into the larynx, as the cold steel coming in contact with the mucous membrane produces contraction of the laryngeal muscles, even though sensibility to pain has been deadened by the use of cocaine. When the growth cannot be included in the loop of the snare some form of forceps, either cutting or serrated, must be employed to remove the growth piecemeal. The double curette (Fig. 112) of the author, or the serrated forceps (Fig. 119, A), which may be used in the same handle, are well adapted to the removal of the growth piecemeal. Where the growth is small and situated on the margin of the vocal cord, the sharp forceps, cutting on one edge only (Fig. 119, B), serves the purpose best. It may also be fitted into the handle (Fig. 112). The base of the growth should be touched with a 50 per cent. solution of lactic acid each time any is removed. When the growth is only partially removed the subsequent operations should be made with as short intervals as possible between them—every three or four days—especially if the tumor be papillomatous in nature, so as to effect a cure in the shortest time possible. In the case of papillomatous growths we have prescribed for the patients' use on two occasions absolute alcohol, which they were directed to spray into the back of the throat, and thus inhale into the larynx five or six times a day. The effect of the alcohol seems to be that of contracting the blood-vessels, thus diminishing the nutrition of the growth, in which atrophy and finally disappearance of the tumor resulted. Other observers have spoken well of this alcohol treatment, which was first suggested by Dr. D. B. Delevan. The galvano-cautery, which is advised by some for the

removal of intralaryngeal growths, is, we think, an exceedingly unsafe method of procedure, owing to the great danger of cauterizing healthy portions of the larynx and producing undesirable cicatrices.

Extralaryngeal operations for the removal of laryngeal growths are the performance of tracheotomy, by which means subglottic tumors can easily be removed and their bases cauterized with lactic acid or the galvanocautery. The supraglottic intralaryngeal growths can be removed either by median thyrotomy or through an incision in the thyrohyoid membrane. The former gives better access to the site of the growth than does the latter, but it has the disadvantage that occasionally the vocal cords are injured in the incision, and hoarseness of the voice or aphonia persists for the rest of life. For the methods of performing these operations reference should be made to works on general surgery.

MALIGNANT GROWTHS OF THE LARYNX.

Etiology. Malignant growths may either originate primarily within the laryngeal cavity or be secondary to malignant disease of the tongue, tonsil, and pharynx. The ages at which malignant growths are the most common are from the fortieth to the sixtieth year. Sarcomata may be found at a considerably earlier period than this, and the epitheliomata even at a much later time of life. The growths are found more frequently in men than in women, in about the proportion of $3\frac{1}{2}$ to 1. In a few cases a history of hereditary malignant disease may be obtained. Any person in middle life in whom there is a family history of cancer will be more apt to develop a malignant growth if he be subject to chronic inflammation of the larynx. Excessive

smoking produces a chronic laryngitis, and it is possible in this way to account in part for the origin of cancer in those who smoke to excess.

Pathology. Malignant growths of the larynx are rarely found in any other varieties than those of epithelioma and sarcoma. The former occurs about five times as frequently as does the latter. The primary forms of cancer originate within the larynx either on the ventricular bands, vocal cords, or on the posterior wall of the larynx. In this situation the tumor is apt to be slow growing, and the involvement of the lymphatic glands of the neck external to the larynx is usually a late occurrence. Where the larynx is involved secondarily to malignant disease of the tongue, tonsil, or pharynx, the extension of the growth, involving, as it does, the epiglottis, ary-epiglottic folds, and the tissues of the laryngopharynx, is much more rapid than in the primary form. The cervical lymphatic glands are infected early in this form of the disease. There seems thus to be a much more intimate connection with the lymphatic channels around the entrance to the larynx and those of the neck than exists between the mucous membrane of the interior of the larynx and the cervical lymph-glands.

Symptoms. The symptoms of a malignant growth of the larynx depend upon whether it is primary and intralaryngeal, or secondary, involving the region of the epiglottis and ary-epiglottic folds. In the primary variety a moderate amount of hoarseness is usually the first symptom that the patient complains of. This hoarseness steadily progresses, until finally the voice of the patient becomes aphonic in the course of a few weeks. Respiration will be observed to become more and more difficult, until finally pronounced dyspnea

and symptoms of laryngeal stenosis appear. Pain is also a common complaint of these patients, and, like the pain of other ulcerative lesions in the larynx, it may be referred to the ear on the affected side. At first, cough may not be a very prominent symptom, but as the growth enlarges an irritating cough is usually observed. In the early stages of invasion there may be little or no expectoration, except that of a small amount of mucus, such as is seen in chronic hypertrophic laryngitis. When ulceration occurs in a malignant growth the cough becomes more pronounced, the expectoration mucopurulent and often contains blood. In the primary form difficult or painful deglutition is only a late symptom in the disease, when it extends to the ary-epiglottic folds or induces a perichondritis of the laryngeal cartilages. Cachexia is usually seen much later in malignant disease of the larynx than where other portions of the body are involved. Where the malignant growth is found on the posterior wall of the larynx perichondritis of the cricoid cartilage, with its painful symptoms, may be observed. Where the disease occurs secondarily from extension of a similar growth in the pharynx, involving the epiglottis and ary-epiglottic folds, ulceration is early observed; the expectoration of blood is sometimes profuse; dyspnea, owing to the extensive edema that accompanies the disease process, is marked; and dysphagia and painful deglutition cause rapid emaciation in the patient. In this variety the glands of the neck are enlarged, participating in the malignant process.

Examination. Examination of the larynx will show a dark-red or purplish growth (Fig. 8, Plate VII.),

uneven in its contour, involving the vocal cords, ventricular bands, or interarytenoid space on the posterior laryngeal wall. The vocal cord on the affected side will usually be found to move less freely than the unaffected one. Where ulceration has taken place it is covered with a gray, green, or black slough, dependent upon the amount of blood that is mixed with the secretion. On cocainizing the larynx and touching the growth it will be found to be firm, hard, and to bleed readily. Should the growth be secondary to malignant disease in the tonsil or tongue, the epiglottis will be enormously enlarged, probably eroded, and the ary-epiglottic folds edematous; but the edema is characterized by a marked hyperemia, in contradistinction to the pallor that usually accompanies the edema due to other inflammatory conditions.

Differential Diagnosis. The differential diagnosis between malignant growths in their early stage of development and indurations due to simple inflammations is often made with difficulty, and only by the aid of microscopic examination of a small piece of the growth removed with a forceps. To the practised eye, however, the irregularity of the growth, the peculiar deep purplish congestion and fixation or lack of freedom in the movements of the vocal cords, the result of a far deeper infiltration of the laryngeal tissues by the growth than is apparent to the naked eye, make a picture that is very different from simple inflammatory induration. The differential diagnosis between non-malignant growths, syphilis, and tuberculosis has been given in the articles treating of those diseases.

Prognosis. The prognosis in this disease depends upon whether the growth be primary and intralaryngeal,

or secondary, involving the epiglottis and ary-epiglottic folds. In the primary variety the prognosis depends upon the amount of involvement at the time the growth is first seen and operated upon. When seen early, and the involvement is on one side of the larynx alone, and ulceration has not taken place, the prognosis is better than that of similar growths in other portions of the body. It is for this reason that when a patient beyond middle life complains of hoarseness his larynx should be carefully examined and not prescribed for by the general practitioner without his having made a careful inspection of this organ. When the time arrives that a general practitioner will employ the laryngeal mirror to investigate the causes of hoarseness, and refer all suspicious cases to those whose experience is wider than his, as he would in a growth of doubtful character in any other part of the body, then will these cases fall into the surgeon's hands early and patients have a fair chance of recovery. There is almost no chance of cure where an intralaryngeal cancer has involved the extralaryngeal tissues.

Secondary involvement of the larynx is invariably fatal. Primary cancer of the larynx, if allowed to take its course, usually proves fatal in from one to three years. Secondary cancer of the larynx extends more rapidly, and terminates the patient's life by septic pneumonia, marasmus, septicemia, or as the result of hemorrhage from erosion of the large bloodvessels of the neck.

Treatment. Primary laryngeal cancer should be treated by surgical removal of the growth. As this at first usually involves but one-half of the larynx, the removal of the involved half usually suffices to

eradicate the disease. Owing to the poor connection existing between the intralaryngeal lymphatics and those of the neck surrounding the larynx the chances of completely removing the growth by such an operation are far better than in other portions of the body. Within the last few years the most brilliant results have been obtained by this operation. If only a small part of one side of the larynx is involved, as part of one vocal cord, thyrotomy and excision of the mass together with the healthy tissue for one-quarter of an inch adjoining the growth has given excellent results in the hands of Butlin, Semon, and others. There is far less impairment of the voice as a result of this operation than in hemi-laryngectomy, and recurrences are infrequent. Where the growth has involved both sides complete extirpation of the larynx is the only procedure. This operation is of itself a very serious one, the danger of sepsis and septic pneumonia is very great, and few patients survive the operation. We think in such cases it is better to state the great danger of the operation to the patient, on the one hand, and, on the other, tell him the certain outcome of the disease if allowed to run its course, and let him choose between the two.

The method of operation that has given the greatest percentage of cures in total extirpation of the larynx is that of Solis-Cohen. The reader is referred to textbooks on surgery for a description of the operation.

Where the extralaryngeal tissues are involved no surgical operation can extirpate the entire growth. In these cases it is advisable to keep the patient comfortable by means of sprays, to facilitate the expectoration of the secretion, and, when the laryngeal stenosis becomes distressing, to perform tracheotomy and keep the patient free from pain by morphine until death relieves him.

THE NEUROSES OF THE LARYNX.

The neuroses of the larynx may be divided into those affecting (A) the motor nerves and (B) the sensory nerves of the larynx.

(A) Motor Neuroses.

The motor nerves may (1) have their irritability heightened either reflexly or through excessive discharge from the central cells in the brain, and produce *spasm* of some or all of the laryngeal muscles. (2) Incoördination in the action of the muscles may result from irregular and untimely impulses sent out from the higher centres. (3) Paralysis may affect a single muscle, a group of muscles, or all the intrinsic muscles of the larynx as the result of the interference with the passage of the nerve influence to one or a few or all of the muscles.

(1) SPASM OF THE LARYNGEAL MUSCLES.

Spasm of the laryngeal muscles appears in three forms: (a) adductor spasm; (b) spasm of the tensors of the vocal cords; (c) spasmodic laryngeal cough.

(a) *Adductor Spasm* (*Laryngismus Stridulus*,
False Croup).

Etiology. The spasm involves the crico-arytenoidei externi and the arytenoideus. It is usually observed in children between the ages of three months and two years. It has been observed in adults. Rhachitic children and those born of neurotic parents are very prone to attacks of laryngismus stridulus. There is frequently the history to be derived from the mother

that all her children have a "croupy tendency." It is not infrequent to find some diseased conditions of the nose, nasopharynx, or tonsils which render the nerve-endings more irritable, and in the neurotic condition of the patient are sufficient to cause reflex spasm of the adductors. Of the conditions mentioned, adenoids take first rank, followed by enlarged tonsils and hypertrophy of the turbinal tissues. The irritation produced by dentition often excites an attack of false croup. It is also frequently associated with disorders of digestion and the presence of intestinal worms.

Tabes

In adults the entrance of a small particle of food, as a crumb of cracker, often produces a condition quite analogous to laryngismus stridulus, especially in those of a hysterical or neurotic temperament. In the first stage of locomotor ataxia there is occasionally seen a spasm of the laryngeal muscles very much resembling laryngismus stridulus. Such a symptom in an adult should, in the absence of a history of a foreign body gaining access to the larynx, always make one seek for other symptoms of that disease.

Symptoms. The usual history of an attack of laryngismus stridulus in a child is as follows: At the time of going to bed the child was apparently well; later in the evening the mother may have observed that it was breathing with a little difficulty; but more frequently the parents are awakened by the crowing, croupy character of the child's breathing. The child may be tossing about, its hands waving in the air or clutching at its throat; the muscles of forced inspiration may be in a state of rigid contraction, but the glottis, being closed by the adductor muscles, no air can enter the thorax. Opisthotonos is seen in severe cases. The child gradually becomes red in the face, and then as the spasm

continues a cyanotic hue of the skin is seen. A slight relaxation of the spasm ensues, and the air rushes in through the narrow chink, making a long, shrill, croupy sound. Expiration is usually not impeded. The next few inspirations are apt to be less croupy in character, to be soon followed by another severe spasm. Involuntary evacuation of urine and feces during the height of the spasm frequently occurs. When the spasm ceases the child usually falls asleep, but the respiration may still be slightly labored. The following day the child is apparently perfectly well; there may be even no hoarseness. A second attack often appears the succeeding night.

Examination. No examination of the larynx can be made during the attack, nor, as a usual thing, in the interval, owing to the age of the patient.

Differential Diagnosis. Laryngismus stridulus has to be differentiated from membranous laryngitis, either simple or diphtheritic. In membranous laryngitis there is a history of hoarseness and cough, with more or less dyspnea, one or more days before the attack of croup supervenes. The child is more prostrated, has some elevation in temperature, and usually evidences of a membrane in the pharynx in diphtheritic laryngitis. A family history of laryngismus stridulus and the ready response to simple antispasmodic treatment make the diagnosis usually easy.

Prognosis. The prognosis is good. The spasm is rarely so severe that death from asphyxiation ensues.

Treatment. The treatment should be directed, first, to relieving the spasm during the attack, and, second, to ascertaining the reflex or constitutional causes, and remedying them. During the attack the child should be placed in a hot mustard bath, from which it should

*Rectal
warm*

be taken and carefully wrapped in a warm woolen blanket. In case the attacks are very severe, rectal injections of

*Rectal
Injections*

R.—Chloralis hydratis gr. vj.
Potass. bromidi gr. x.
Aquæ ʒj.—M.
(For a child six months old.)

chloroform

may be given every two hours. Should the attack still persist, a few drops of chloroform placed on a handkerchief and held over the child's face, which should be coated with vaseline or sweet oil, quickly give relief.

In the interval between the attacks all sources of irritation should be searched for and removed. Disorders of digestion must be corrected and eating heartily at night prohibited. Adenoids, enlarged tonsils, or nasal obstruction, if found, should be appropriately treated. Cod-liver oil, syrup of the iodide of iron, and in very nervous children bromide of potassium, are to be administered. In nervous, hysterical adults, in addition to the sedatives, potassium bromide and strontium bromide, the administration of valerian and asafetida is advisable. The use of a galvanic or faradic current to the larynx often lessens the tendency to spasm.

(b) *Spasm of the Tensors of the Vocal Cords (Aphonia Spastica, Phonatory Spasm).*

A rare form of spasm of the tensors of the vocal cords, seen in neurotic persons and in those whose occupations demand considerable use of the voice, as in singers, public speakers, and auctioneers. The disease is considered to be an affection of the laryngeal muscles analogous to that observed in the muscles of the hand in writers' or telegraphers' cramp.

Symptoms. The important symptom is sudden loss of voice. This may happen in the middle of a sentence, the person being unable to complete it for several seconds, after which, in mild cases, speech may be normal for several sentences. As a usual thing, the greater effort the individual makes, either to sing or to speak, the longer the spasm continues. The speech in this disease is not unlike that of stammering.

Examination. The vocal cords have been observed to be approximated in the median line, as in the phonatory position.

Treatment. Absolute rest to the voice is necessary in these cases. This can best be obtained either by camping out in the woods or a long sea-voyage. Tonics, such as iron, strychnine, and arsenic, must be given.

(c) *Spasmodic Laryngeal Cough (Laryngeal Chorea).*

The condition is described under this heading; but although there is a rhythmical contraction or spasm of the laryngeal muscles, the other muscles of respiration are also involved in the spasm in order to produce the expiratory blasts necessary to the cough. The name laryngeal chorea might mislead one into believing that the disease was associated with chorea, whereas it is not. It occurs more frequently in females than in males, and almost always in those of a neurotic or hysterical tendency. The period from the twelfth to the twenty-fifth year is that in which it is usually seen.

Symptoms. The only symptom is a peculiar barking cough, consisting of from four to ten barks in rapid succession. These are hollow in character, usually deep-toned, like the barking of a hound. A case recently seen gave a most perfect representation of a sea-lion's bark. These spasms occur at intervals varying

from three to ten minutes. They cease during sleep. The voice is seldom hoarse.

Examination. Examination of the larynx usually shows no abnormality. The beginning of the spasm may be observed while the larynx is being examined. The vocal cords are approximated with great rapidity.

Treatment. This should be directed first toward correcting the nervous condition by means of the bromides, hyoscyamus, or cannabis indica. Cod-liver oil and iron are usually beneficial. No great fuss should be made over the condition, as these patients are often delighted at the attention they receive and make no attempt to restrain the cough. Electricity over the larynx may be employed, more, however, for its psychical effect than for any influence upon the muscles or nerves.

(2) LARYNGEAL VERTIGO (*Laryngeal Epilepsy*).

A rare condition, due to incoördination in the respiratory centres, and implicating the nerves of the larynx, producing a contraction of the muscles closing the glottis.

Etiology. The condition occurs in adults of a neurotic disposition, and is more common in men than in women.

Symptoms. The attack begins with a tickling sensation in the larynx, followed by an attack of coughing. A full, deep inspiration is taken when the glottis closes, and the air is confined in the thorax. Dizziness, perhaps cyanosis, and partial or complete loss of consciousness follow. In a few moments the attack passes off and the patient recovers. The paroxysms may be repeated at intervals of a few days or weeks.

Examination. The larynx is usually found normal,

although evidences of slight laryngitis have been observed. Diseased conditions in the nose, nasopharynx, and pharynx are frequently observed.

Prognosis. The prognosis as to life is good. The attacks may recur at intervals for a long time.

Treatment. As in the other neuroses, the general health should be looked after and tonics and antispasmodics administered. Diseased conditions in the upper respiratory tract should be carefully searched for, and if any are found appropriate treatment should be directed toward remedying them.

(3) PARALYSES.

(a) *Unilateral Abductor Paralysis.*

Paralysis of the crico-arytenoideus posticus on one side.

Etiology. The crico-arytenoideus posticus is innervated by the recurrent laryngeal branch of the pneumogastric nerve. The most common source of interference with the nerve-supply of this muscle is that of some tumor which presses either upon the recurrent laryngeal nerve or the pneumogastric after its exit from the brain. Cancer of the esophagus, goitre, enlarged bronchial glands, and enlarged glands in the neck are the conditions which may affect either nerve. An aneurism of the innominate artery or of the right subclavian, or a thickened pleura at the apex of the right lung, may cause paralysis on the right side of the larynx. An aneurism of the arch of the aorta may cause paralysis of the left muscle. Central lesions may produce a unilateral affection, but usually produce a bilateral one. These lesions are locomotor ataxia and bulbar paralysis. The muscle itself may be infiltrated

and its action thus interfered with, resulting in paresis or paralysis. The nerve of the right side is involved more frequently than that of the left. An abductor paralysis may be the precursor of a complete paralysis of the recurrent laryngeal nerve involving all of the muscles on one side of the larynx.

*Slight
or none*

Symptoms. The symptoms of abductor paralysis are often of such a slight nature that the condition is only detected upon laryngological examination. The voice may be slightly hoarse, but it usually is normal. Dyspnea is rarely complained of.

Examination. Examination of the larynx will show the vocal cord on the paralyzed side to be stationary during respiration and somewhat more closely approximated to the median line than is the non-paralyzed cord during this act. If Fig. 4, A, is referred to, the lightly shaded lines on one side will show the position of the paralyzed vocal cord during respiration, while the dark, heavily shaded lines (Fig. 4, C) of the opposite side will show the position of the other vocal cord at this time. During phonation the adductors will be able to approximate the vocal cords, so that voice production may be normal. When phonation ceases the non-paralyzed vocal cord will be seen to separate widely from the median line, while the paralyzed cord recedes but slightly from its phonatory position. The internal edge of the paralyzed vocal cord is nearly if not quite straight.

Differential Diagnosis. Unilateral abductor paralysis is to be differentiated from complete paralysis of the recurrent laryngeal nerve. In the latter condition the paralyzed vocal cord during respiration lies considerably further from the median line than it does in abduc-

tor paralysis, and in what is known as the cadaveric position—that is, only about half-way between the position of the vocal cord during phonation and during respiration. In complete recurrent paralysis the vocal cord will not approach the median line as it does in simple abductor paralysis, and the outline of the vocal cord is concave, with the concavity looking toward the median line of the larynx.

Prognosis. Unless the paralysis be due to infiltration of the muscle, which subsequently disappears, or due to the pressure of a tumor, which can be either removed or absorbed, as in the case of a syphilitic gumma, by the use of potassium iodide, the paralysis remains permanently, and is very apt to be followed by complete recurrent laryngeal paralysis, as the pressure of the growth or the diseased condition in the medulla increases.

Treatment. The treatment of this condition consists in first determining, if possible, the cause. If the local tumor be of such a nature and in such a position that it may be removed, an operation for its removal is indicated. Inoperable aneurisms may be benefited by the internal administration of potassium iodide. Syphilitic gummata are usually absorbed when this drug is administered, and the paralysis, if not of too long standing, disappears. An enlarged thyroid may be benefited by the administration of the thyroid extract. Subcutaneous injections of strychnine, beginning with one-fortieth of a grain three times a day, and gradually increasing the dose until twitching of the muscles of the face is observed, may be of advantage in these cases. The galvanic and faradic currents may be employed to prevent atrophy of the muscle in those cases in which there is a

prospect of removing the cause either by surgical or medical means.

(b) *Unilateral Adductor Paralysis.*

This condition has been met with but very few times, and some of those reported were doubtful cases. The muscle involved is the crico-arytenoideus lateralis. The voice in these cases is hoarse, sometimes aphonic. No interference with respiration will occur.

Examination. Owing to the unopposed action of the crico-arytenoideus posticus the vocal cord on the affected side will be widely separated from the median line, in about the position it would occupy in a forced expiratory effort. Efforts at phonation result in the arytenoideus dragging the arytenoid cartilage of the affected side somewhat nearer to the median line, but will not rotate the arytenoid cartilage so as to cause the vocal cord on the paralyzed side to come into the normal position.

Treatment. The treatment is the same as that for unilateral abductor paralysis.

(c) *Paralysis of the Arytenoideus.*

The function of the arytenoideus is to approximate the arytenoid cartilages and the posterior ends of the vocal cords during phonation.

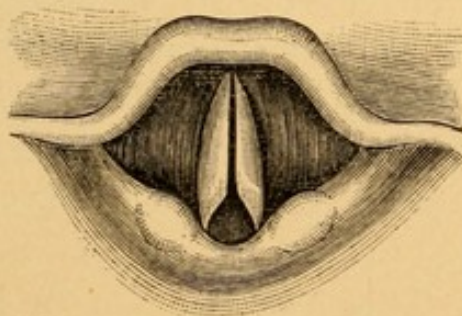
Etiology. The principal cause of paralysis of the arytenoideus is hysteria. The position of the arytenoideus, lying, as it does, at the posterior portion of the larynx, forming the anterior boundary of the laryngopharynx, is one that makes it liable to become bruised by a large bolus of food during the act of swallowing. Inflammation of the muscles may also result

from severe inflammatory diseases of the pharynx, in which there is considerable infiltration of the submucous tissues. Tubercular and syphilitic infiltrations in the interarytenoid space frequently involve the muscle or mechanically interfere with its action.

Symptoms. The symptoms most complained of in this condition are hoarseness of the voice and fatigue in talking. The hoarseness is due to the imperfect approximation of the posterior ends of the vocal cords, and the fatigue is due to the escape of a considerable volume of expired air, so that the force of the column of air is insufficient to cause the vocal cords to vibrate properly. When this fatigued condition is marked the voice in consequence is often aphonic. Respiration is not interfered with.

Examination. Examination of the larynx reveals a triangular opening at the posterior portion of the vocal cords, the apex of the triangle being directed toward the epiglottis (Fig. 120).

FIG. 120.



Paralysis of the arytenoideus.

Treatment. The treatment is the same as that given for unilateral abductor paralysis, with the exception of those cases which are due to hysteria, in which tonics and nerve sedatives are to be administered.

(d) *Unilateral Paralysis of One Internal Tensor of the Vocal Cords.*

The internal tensors of the vocal cords are the thyroarytenoidei, which run parallel to, external, and beneath the vocal cords.

Etiology. One of these muscles may be involved in an inflammatory thickening or infiltration of the vocal cord and the tissues external to it. It is seen in chronic subglottic laryngitis, occasionally in chronic diffuse hypertrophic laryngitis, in malignant and non-malignant growths of the larynx, and in tuberculosis and syphilis. The disease often results from prolonged use of the cords, especially when the general health of the patient is not in the best condition. It is occasionally observed as a manifestation of hysteria.

Symptoms. The voice is usually somewhat hoarse, and becomes easily fatigued when used.

Examination. Examination of the larynx will show the affected vocal cord usually somewhat thickened and congested, and on attempts at phonation the straight chink between the cords will be replaced by one that is wider than normal. The internal edge of the unaffected vocal cord can be seen to be straight during phonation, whereas that of the paralyzed vocal cord will be seen to be concave toward the median line and slightly distant from it. This accounts for the increased space between the two during phonation.

Treatment. Local treatment of the laryngeal inflammatory condition, according to the pathological process present, must be given as recommended for those diseases. The general health should be looked after and the voice given *absolute* rest. Strychnine and elec-

tricity, as described in the article treating of abductor paralysis, are beneficial.

(e) *Unilateral Paralysis of One External Tensor of the Vocal Cords.*

The external tensors of the vocal cords are the cricothyroidei muscles.

Etiology. Unilateral paralysis of the external tensors of the vocal cords is uncommon. It may result from blows on or wounds of one side of the larynx, or as the result of the action of the diphtheritic toxins upon the superior laryngeal nerve, which innervates this muscle as well as supplies the mucous membrane of the larynx with sensation.

Symptoms. The principal symptom in paralysis of one of the cricothyroid muscles is slight hoarseness of the voice, together with the inability so to regulate the tension of the vocal cords as to produce the higher notes. Where the disease is due to diphtheria the anesthesia of the pharynx as well as of the larynx makes the likelihood of food or foreign particles entering the larynx and exciting inflammation very great.

Examination. Examination of the vocal cords will show the identical conditions described when considering unilateral involvement of an internal tensor, with the exception of the local thickening and induration often found in that condition.

Treatment. When due to local conditions, such as blows and wounds, these should be treated as are like conditions elsewhere in the body. When due to diphtheria, strychnine administered internally and faradization or galvanization of the muscles should be resorted to.

(f) Bilateral Abductor Paralysis.

Paralysis of both crico-arytenoidei postici.

Etiology. The causes of bilateral abductor paralysis are practically the same as those which have been given for unilateral abductor paralysis, but with the difference that the growth or tumor involves both recurrent laryngeal nerves instead of but one. The disease may also result from the too long wearing of a tracheotomy tube and the consequent atrophy of the muscles from disuse. The affection also follows lead-poisoning. As in unilateral abductor paralysis, this condition often precedes a paralysis of the other muscles supplied by the recurrent laryngeal nerve.

*Inspiratory
dyspnea.*

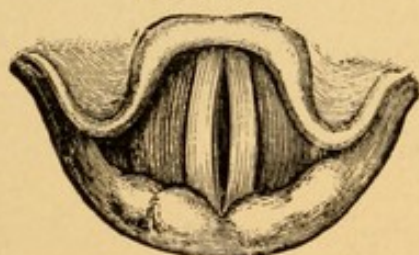Symptoms. It will be remembered that during normal inspiration the vocal cords separate so as to allow the freer entrance of air into the larynx and trachea. This is accomplished through the action of the abductor muscles of the vocal cords. When these are paralyzed marked difficulty in inspiration produces intense dyspnea. Expiration is normal in character. The dyspnea is always greater whenever slight exertion is undertaken. Accompanying inspiration there is frequently a stridor, owing to vibration of the relaxed vocal cords. This is often most marked at night. There is usually no interference with the production of the voice other than that which would be observed in any dyspneic person, the words being spoken at short intervals, between which the patient stops to catch his breath.

Examination. Examination of the larynx will show the vocal cords as in Fig. 121, or in nearly the position that they are made to assume in the heavy lines in Fig. 4, A. Owing to the fact that the crico-arytenoidei

lateralis are unopposed in their action by the paralyzed muscles, the two vocal cords are nearly parallel to each other, and but a slight chink is observed between them during respiration. A fluttering of the cords may be seen during inspiration, but no separation of them such as takes place normally. On the contrary, the cords may even be crowded closer together during inspiration, owing to the increased pressure of the column of air on the ventricular bands and the cords, thus forcing the former down and the cords toward the median line.

Differential Diagnosis. The only condition which is likely to be mistaken for bilateral paralysis of the abductors is that of spasm of the adductor muscles.

FIG. 121.



Position of the vocal cords in respiration in bilateral abductor paralysis.

The latter, however, is sudden in its onset, in contrast to the slower and more gradual onset of the abductor paralysis. The former condition is seen in children, and is most marked at night; whereas the latter condition is found in adults, and dyspnea is more marked on exertion and less at night. The former condition is accompanied by a croupy cough; the latter, only by the peculiar stridor heard in this condition.

Prognosis. Unless due to a tumor that can be removed, this condition is never recovered from. It may lead to sudden death unless the patient is where immediate operative interference can be had in the event of

any severe inflammatory condition of the vocal cords narrowing still further the glottis and producing asphyxia.

Treatment. The medical treatment of bilateral abductor paralysis is the same as that recommended for unilateral abductor paralysis. Should the dyspnea become so marked that the patient is in danger of suffocating, then either intubation or tracheotomy must be performed. In the former case a large-sized adult intubation tube must be introduced, and where this is of hard rubber it had better be removed at the end of every month or six weeks and cleansed of the calcareous secretions that are very apt to be deposited on it. A second tube should be at hand for immediate introduction in case the dyspnea is so marked that there is not time to cleanse and re-insert the tube that has been removed. Should tracheotomy be performed, there is very little prospect of the patient ever being able to dispense with the canula.

(g) *Bilateral Adductor Paralysis.*

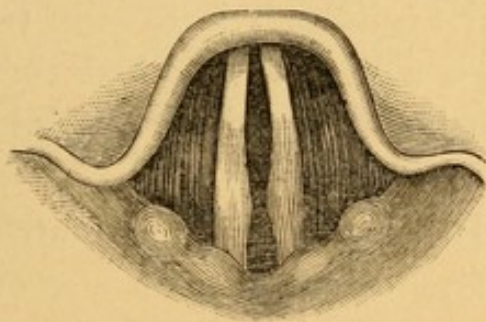
Bilateral paralysis of the crico-arytenoidei laterali, and usually of the arytenoideus as well.

Etiology. This is the condition that is usually observed in patients suffering from sudden and hysterical aphonia. It occurs, therefore, more commonly in women than in men, and especially in those of a nervous, high-strung, and emotional temperament. It is very frequently associated with hystero-epilepsy and diseases of the female genital organs. The loss of voice that is so common in pregnancy from the third to the ninth months results from functional paralysis of these muscles. These patients are frequently anemic

or chlorotic, but the affection may be seen in those who are apparently robust. A very slight exciting cause may be sufficient to produce the condition in those who are predisposed to it. Among such causes may be a slight pharyngitis or laryngitis, sudden fright or joy, or the infliction of a slight wound, such as the mere pricking of the finger.

Symptoms. The one symptom present in this condition is aphonia. It often comes on suddenly, and may disappear as quickly as it came. As a usual thing patients are able to cough and laugh in a perfectly

FIG. 122.



Bilateral paralysis of the adductors.

normal manner, and if taken unawares or startled, it is not uncommon for them to cry out and speak with a perfectly clear voice, only to relapse into an aphonic condition.

Examination. Examination of the larynx may reveal various conditions as regards the position and mobility of the vocal cords. The usual picture is that shown in Fig. 122, in which the vocal cords do not approximate in the median line when attempts at phonation are made, although they move considerably from the position they had during inspiration. The respiratory movements of the vocal cords may be perfectly normal—that is, during inspiration the vocal cords separate, and during

expiration they approach each other. One occasionally observes in these cases that during phonation the vocal cords come together in nearly, if not quite, a normal way, and yet no sound will be made. No inflammation of the larynx is usually present.

Differential Diagnosis. The history of a sudden onset of aphonia; the mobility of the vocal cords during respiration; the partial approximation of the cords during phonation, and often a history of previous attacks of a similar character, stamp the disease as one that is functional and not due to organic change in the nerves.

Prognosis. The condition is usually recovered from, although we have a patient who had the condition for eighteen months before speaking a word louder than a whisper.

Treatment. In treating these patients every attempt should be made to discover the cause of the neurotic condition, and to ascertain whether menstrual irregularities or other diseased condition of the genital organs exist, and if such be found they should be treated. The general health should be looked after, and cod-liver oil, iron, and nerve sedatives administered. The physician should in all these cases impress himself upon the patients, sympathize with them until he gets their confidence, and, when this has been gained, state that in a few days he will be able to effect a cure. In the meantime such placebos as Dobell's solution, or a weak menthol-albolene spray (5 grains to the ounce), may be prescribed, with a view of making the patients think something is being done for the relief of their condition. When the time stated for the expected cure has arrived the introduction into the larynx of a cotton-

wound applicator that has been dipped in a weak solution of nitrate of silver or chloride of zinc (5 grains to the ounce), just sufficient to smart the patient a little, and then telling him that you know he can now speak a little better, will probably result in his talking in a hoarse voice. A second application the next day will probably complete the cure. In more obstinate cases it is better to take some friend of the patient into your confidence, explain the functional nature of the aphonia to him, and the fact that any sudden pain, such as would be produced by the passage of a strong faradic current through the larynx, would probably cause the patient to cry out and talk, and proceed to treat the patient with a strong battery current.

(h) *Bilateral Paralysis of the Internal Tensor of the Vocal Cords.*

A bilateral paralysis of the thyro-arytenoidei muscles.

Etiology. The etiology and symptomatology of this disease are the same as those given for unilateral paralysis (*q. v.*). The condition more commonly affects both nerves than a single one.

Examination. Examination of the vocal cords shows a small oval slit between the two during vocalization. The inner margins of both cords are concave toward the median line.

Treatment. The treatment is the same as that advocated for the paralysis of one internal tensor.

(i) *Bilateral Paralysis of the External Tensors of the Vocal Cords.*

Etiology. This disease is almost invariably associated with a neuritis of the superior laryngeal nerve, such as is seen in diphtheria.

Symptoms. The symptoms of this disease are the same as those given for unilateral paralysis of the external tensor of the vocal cord.

Examination. Examination of the larynx shows a condition identical with that found in bilateral paralysis of the internal tensors, except that the mucous membrane of the larynx is anesthetic, which it is not invariably in the former disease.

Treatment. The treatment is the same as that given for unilateral paralysis of the external tensor of the vocal cord.

(j) Complete Paralysis of the Recurrent Laryngeal Nerves.

Etiology. In this disease the paralysis involves both the abductors and the adductors of the vocal cords. Usually one nerve is paralyzed, but both nerves may be. Unilateral paralysis is more commonly found on the left side, owing to the passage of the nerve around the arch of the aorta and the frequent involvement of this as a result of aneurism in this situation. On the right side the nerve may be implicated in an aneurism of the innominate or subclavian artery, or be included in a pleuritic exudate at the apex of that lung, the subsequent organization of the exudate producing a compression neuritis in the right recurrent nerve. Any tumor in the course of either of these nerves, such as cancer of the esophagus, enlarged lymphatic glands of the neck, abscesses of the neck, mediastinal tumors, goitre, or gummata may press upon one or the other of the recurrent laryngeal nerves. Should these tumors press upon both nerves, then a bilateral paralysis will occur. The central causes of this disease are locomotor ataxia,

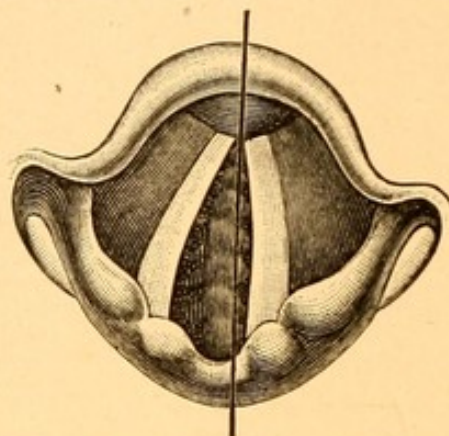
syphilitic tumors at the base of the brain, bulbar paralysis, tabes, and the effects of diphtheria toxin and lead upon the cells in the medulla.

Symptoms. The symptoms of unilateral paralysis of the recurrent laryngeal nerve are those due to the laryngeal condition and very frequently those due to the pressure of a tumor on the trachea. About the only symptom found where one nerve alone is involved is a slight hoarseness of the voice. There is usually no dyspnea from this cause alone. The change in the voice is not as marked as that observed in unilateral adductor paralysis, because the vocal cord lies in the cadaveric position, which is midway between that which it has in phonation and that which it has in ordinary quiet respiration. The non-paralyzed vocal cord is frequently drawn beyond the median line toward the paralyzed cord, so as to come in pretty close apposition with the latter during vocalization (Fig. 124). This is attended with an overriding of the arytenoid cartilage on the non-paralyzed side, either passing in front or behind the arytenoid on the paralyzed side. A tumor, which frequently presses upon the recurrent laryngeal nerve and causes paralysis, also frequently compresses the trachea, and the irritation from this produces a cough, which is brassy in character, such as is heard in aneurism of the arch of the aorta. Should the lumen of the trachea be very much narrowed, dyspnea from this source, especially on exertion, will be complained of.

In bilateral paralysis the voice is nearly aphonic and very weak, and there is usually some dyspnea, owing to the interference that the cords in the cadaveric position make to the entrance of air into the trachea. The

dyspnea, however, is never so great as that seen in bilateral paralysis of the abductors.

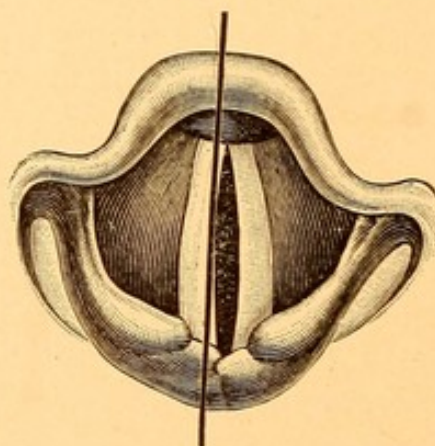
FIG. 123.



Paralysis of the left recurrent laryngeal nerve. Appearance of the vocal cords during respiration.

Examination. Examination of the larynx in cases in which unilateral paralysis of the recurrent laryngeal nerve exists will reveal one vocal cord in the cadaveric position (Figs. 123 and 124). The cord does not move

FIG. 124.



Paralysis of the left recurrent laryngeal nerve. Appearance of the vocal cords during phonation.

either in phonation or respiration. Its inner margin is curved, with the concavity toward the median line. The

non-paralyzed cord will be observed to move during both respiration and attempts at phonation. When the latter is attempted the sliding of the arytenoid cartilage on the non-paralyzed side, carrying with it its vocal cord, can be observed, passing either in front (Fig. 124) or behind the arytenoid cartilage of the paralyzed side. This gives to the glottis, or opening between the vocal cords, an obliquely directed position instead of the normal opening in the antero-posterior line of the pharynx. The obliquity from before backward is directed *toward* the paralyzed side. Where both recurrent laryngeal nerves are paralyzed the vocal cords are both in the cadaveric position, and move neither during respiration nor during attempts at phonation.

Differential Diagnosis. The condition is to be differentiated from bilateral abductor paralysis. The fact that the vocal cords in bilateral abductor paralysis are able to be adducted in a normal way during phonation, while no movement of the vocal cords will be observed in bilateral recurrent laryngeal paralysis, suffices to differentiate the two conditions.

Prognosis. The prognosis in this disease is usually bad, because of the conditions which interfere with the functions of the nerves. When due to syphilitic gum-mata administration of the iodides may cause absorption of the tumor and restoration of the functions of the nerves.

Treatment. The treatment is the same as that for unilateral abductor paralysis.

(B) Sensory Neuroses.

These may be (1) anesthesia, (2) hyperesthesia, and (3) paresthesia.

(1) ANESTHESIA OF THE LARYNX.

Etiology. Anesthesia of the larynx is frequently observed in hysterical patients. It is also observed as a result of the action of toxins, especially those of diphtheria and the streptococci, upon the central cells in the medulla. It is one of the symptoms met with in glosso-labio-lingual paralysis. It is occasionally seen in epilepsy. Severe ulcerative processes, such as are met with in syphilis and lupus of the larynx, are frequently followed by anesthesia, owing to destruction of the terminal filaments of the superior laryngeal nerve. Any long-continued chronic inflammation of the mucous membrane may also produce it in the same way. It is frequently seen in dementia.

Symptoms. The normal mucous membrane is very intolerant of the presence of foreign substances, which, if small, are immediately expelled by coughing. In anesthesia they may not only lodge in the larynx, but even pass into the trachea and bronchi and produce abscesses of the lungs or pneumonia (septic).

Treatment. In cases of central origin strychnine (one-thirtieth to one-tenth grain, three times a day) may be of great benefit. Tonics—cod-liver oil and iron—are useful in hysterical cases. Faradization or galvanization of the larynx may assist in restoring the function of the nerves.

(2) HYPERESTHESIA OF THE LARYNX.

Hyperesthesia is frequently observed in nervous patients who have some disease of the nose or pharynx. The enlarged, dilated veins at the base of the tongue frequently produce a reflex hyperesthetic condition of

the larynx. Disorders of digestion, especially those met with in chronic alcoholism, frequently produce it.

Symptoms. The most common complaint of these patients is a hacking cough, usually unaccompanied by expectoration.

Treatment. The main point in the treatment of these cases lies in ascertaining whether any diseased condition exists to account for the symptoms, and, if so, correcting it. Bromide of potassium, heroin, codein, and hyoscyamus may be given to allay the nervous irritability.

(3) PARESTHESIA OF THE LARYNX.

By this is meant the sensation as of a foreign body, or hair, or a pricking in the larynx. We have before referred to the fact that diseased conditions in the pharynx, such as granular pharyngitis or hypertrophied lingual tonsil, lingual varix, etc., all produce the same feeling. The sensation is seldom referred to the larynx, but often to a point in the median line just below the larynx. The larynx is seldom the offending organ, and if this be remembered and search made elsewhere for pathological processes the patient will be cured when these conditions are removed.

CHAPTER XI.

AFFECTIONS OF THE UPPER RESPIRATORY TRACT OCCURRING IN THE INFECTIOUS DISEASES.

THE pathological changes met with in diphtheria, tuberculosis, lupus, and syphilis in the upper respiratory tract have been described under their appropriate headings in preceding chapters.

SCARLET FEVER.

Nasal Condition. The nose is not usually implicated to any great extent in the mild forms of scarlet fever. There is, however, frequently a slight form of acute rhinitis manifested by coryza and occasionally epistaxis. In the severer types of the disease extensive ulceration of the turbinates and septum has been observed, with involvement of the accessory sinuses—the maxillary sinus, frontal sinus, and ethmoid cells—with the attendant symptoms of pain, elevation of temperature, enlargement of the cervical lymphatics, nasal obstruction, and profuse purulent, sometimes fetid discharge from the nose. As a sequel to the ulcers adhesions between the turbinates and septum may occur.

Pharyngeal Condition. In all cases of scarlet fever the pharynx shows more or less involvement. In the milder cases there will be only an erythema of the mucous membrane of the hard and soft palate and the posterior pharyngeal wall. The tonsils will be slightly

swollen and present the appearances seen in lacunar tonsillitis.

In the more severe cases (*scarlatina anginosa*) the mucous membrane is a deep, dusky red, the tonsils and pillars of the fauces are covered with a thick, fibrinous, pseudo-membranous exudate, and the uvula is very much elongated and edematous. The patient complains of dysphagia and the breath is very fetid. Bacteriological examination of the exudate in these cases almost invariably reveals the presence of the *Streptococcus pyogenes*, with which are associated frequently the *Staphylococcus pyogenes* and *Staphylococcus aureus*, and occasionally the Klebs-Loeffler bacilli. When the last-named bacteria are found the patient should be considered to have diphtheria complicating the scarlet fever.

Sloughing of the tonsils and portions of the pillars of the fauces and soft palate, also peritonsillar abscesses, have been known to occur.

The lymphoid tissue of the nasopharynx (adenoids) is almost always acutely inflamed, and an exudate similar to that of the oropharynx is frequently found in the nasopharynx. The lymphatic glands of the neck are in such cases greatly enlarged, and one of the principal dangers to be feared is suppuration of the cervical lymphatic glands, followed by pyemic symptoms and usually death.

When the nasopharynx is implicated a common complication is acute suppurative otitis media, not infrequently complicated by mastoiditis, and the patient often is left either with hearing markedly impaired or totally deaf.

Laryngeal Conditions. The larynx is usually less in-

volved than the pharynx and presents more or less evidence of acute laryngitis. In the severe (anginose) types of the disease there may be edema of the larynx. The epiglottis may be swollen, and ulcers, usually superficial, but occasionally deep, involving the cartilages, have been observed.

Treatment. In the milder forms of the disease cleansing sprays, such as

R.—Sodii chlor.	gr. vj.
Sodii bicarb.	gr. x.
Aquæ dest.	℥ ij.—M.

to be sprayed with an atomizer into the nose and pharynx, keeping the parts free from secretion and lessening thus the dangers from the absorption of toxins produced by the bacteria, will be all that is required.

In the severe, or anginose, types great care should be taken to keep the parts as clean as possible, and this can perhaps best be done by spraying the pharynx and the nose, in order to reach the nasopharynx, with

R.—Pyrozone	1 part
Aquæ dest.	4 parts.

and afterward spraying with an alkaline solution as recommended above.

Acute otitis media should be treated early by incision of the membrana tympani; mastoiditis by early operation upon the mastoid cells; and suppurating glands of the neck by incision and free drainage. Cold applications to the neck in the form of the cold coil or cold pack often greatly alleviate the inflammatory processes in the pharynx and larynx. Intubation or tracheotomy may be necessary to overcome dyspnea from edema of the larynx.

Sequelæ. Paralysis of the soft palate and of the pharyngeal muscles and the consequent nasal twang of the voice and regurgitation of liquid food through the nose may occur as sequelæ during convalescence. Paresis or paralysis of the laryngeal muscles may leave the patient hoarse or aphonic for several months after convalescence.

MEASLES.

In measles antedating the appearance of the eruption upon the skin, and with the first onset of the sneezing and coryza, Koplik's spots may be observed on the mucous membrane on the inside of the cheeks. These are only visible when the patient is examined in bright daylight. They are "small, irregular rose-colored spots with a very minute bluish speck just large enough to be visible, in the centre of the rose area."

Nasal Condition. The nose is invariably the seat of an acute rhinitis, which is characterized by a profuse, almost colorless watery discharge for the first day or two; later the discharge becomes seropurulent or possibly mucopurulent in the more severe types. Epistaxis, often severe, is not an uncommon occurrence. The accessory sinuses, especially the frontal sinus and antrum of Highmore, are usually acutely inflamed, giving rise to headache. Occasionally suppurative involvement of the accessory sinuses occurs. Ulcerative processes involving the septum and turbinal tissues, and, later, adhesions between the ulcerative surfaces, may take place.

Pharyngeal Condition. The pharynx in this disease is usually hyperemic, the hard and soft palate often showing small areas of deep, purplish-red blotches

separated by areas of less intense hyperemia, similar to the eruption found upon the skin. Hemorrhages into these congested areas may be seen in the severe, hemorrhagic types of the disease. Lacunar tonsillitis is not uncommonly found, and the thick pseudo-membrane formation so frequently seen in scarlet fever is only rarely met with in measles.

The lymphatic tissue (adenoids) of the nasopharynx may be considerably swollen, as will also in these cases be the lymphatic glands of the neck. Acute suppurative otitis media and mastoiditis are commonly found, although perhaps not to such an extent as in scarlet fever.

Laryngeal Condition. The larynx is acutely inflamed, but usually only to a slight extent; although in the severe cases edema of the larynx, spasmodic laryngitis with croupy symptoms, and rarely ulcers have been reported.

Treatment. The treatment of throat affections in measles should be carried out on precisely the same lines as those given for scarlet fever. Acute rhinitis, where the nose is completely occluded, may be controlled by the remedies given in the article on Acute Rhinitis, page 80.

ROTHELN (German Measles).

The upper respiratory tract is usually but slightly involved in this disease. A mild form of acute rhinitis frequently accompanies it.

In the pharynx the soft palate is hyperemic and a slight, blotchy eruption may be observed. In severe cases the tonsils are slightly swollen and there may be lacunar tonsillitis.

The larynx is often the seat of a mild acute laryngitis.

Treatment. The treatment is the same as that given for these affections under their respective headings in the body of the work.

PERTUSSIS.

Nasal Condition.—Epistaxis is often an early symptom of this disease, and when the paroxysms have reached their greatest degree of intensity, about the middle of the course of the disease, epistaxis may be a troublesome complication, which, on account of its frequent recurrence, may materially weaken the patient. It will usually be found that the bleeding arises from the group of dilated veins on the cartilaginous portion of the septum just within the nostril. Accompanying the disease there is often acute rhinitis of a mild type.

Pharyngeal Condition.—The pharynx gives evidence of acute pharyngitis, the membrane being hyperemic when the paroxysms of coughing are frequent and severe. Granular pharyngitis is of common occurrence. Small hemorrhages beneath the mucous membrane of the soft palate, hard palate, tonsil, and pharyngeal wall are not infrequent. The lymphoid tissue (adenoids) of the nasopharynx is considerably swollen, Eustachian congestion is common, and otitis media frequently occurs.

Laryngeal Condition.—The larynx is markedly congested and submucous hemorrhages are occasionally found. A thick, viscid, pearl-like mucus may be seen on the trachea in nearly all cases which admit of laryngeal examination.

Treatment. In addition to the constitutional treat-

ment and the administration of antispasmodic and sedative cough mixtures for the severe paroxysms of coughing, the nose and pharynx may be sprayed with the suprarenal extract solution (p. 81), to lessen the hyperemia in those parts.

SMALLPOX.

Nasal Condition.—A mild type of acute rhinitis may be present. Ulcers of the septum have been reported.

Pharyngeal Condition.—The eruption of smallpox may be found on the hard and soft palate, tonsil, pharyngeal wall, and occasionally on the mucous membrane of the cheeks and tongue, twenty-four hours before it occurs on the skin. The number of lesions is usually small, from six to twelve, except in the hemorrhagic type of the disease, in which cases they are very numerous and are purpuric in character. In severe cases the tonsils may be enlarged and covered with a fibrinous exudate, streptococcic in origin; in these cases the cervical lymphatic glands are greatly enlarged and frequently break down into abscesses. Otitis media in severe cases is not uncommon.

Laryngeal Condition.—The larynx is usually but slightly involved, but in the severe types of the disease the pocks may exist on the epiglottis and even within the larynx, in which event edema of the larynx is apt to occur, as is also ulceration, which may involve the cartilage and result in sloughing and abscess of the neck. False membranes may form where two ulcerated surfaces are in contact.

Treatment. The ulcers resulting from the pocks should be kept cleaned with Dobell's solution. When the ulceration is extensive or healing slow each should

be painted every other day with a solution of nitrate of silver sixty grains to the ounce of water.

CHICKENPOX.

The pharynx, inside of the cheeks, and the tongue may show the typical lesions as found on the skin. They are, however, few in number, and are by no means present in all cases.

TYPHOID FEVER.

Nasal Condition.—This disease is frequently ushered in with attacks of epistaxis, and later in the course—about the third week—the epistaxis may recur and be quite profuse. Ulcers of the septum and turbinates, giving rise to a purulent discharge with crust formation occurring in one or both nares, are occasionally observed. Deep ulcerative processes, resulting in destruction of the cartilaginous portion of the septum and adhesions between the septum and turbinates, are also met with.

Pharyngeal Condition.—The tongue is always dry and covered with a thick coating; cracks and deep fissures, which may bleed, are not uncommon. The pharynx is dry, glazed, and usually hyperemic, hemorrhage sometimes occurring over portions of the mucous membrane.

As sequels to the disease, paresis and occasionally paralysis of the muscles of the soft palate and pharynx have been noted, allowing regurgitation of liquids through the nose.

Laryngeal Condition.—The larynx is nearly always the seat of an acute laryngitis. The lymphoid tissue is hypertrophied, and ulcers of the laryngeal surface of the epiglottis, ary-epiglottic folds, vocal bands, and

posterior wall of the larynx occasionally occur. In some cases these ulcers are deep, involving the perichondrium and cartilage, as a result of which destruction of these tissues, with abscess formation and excessive edema of the larynx, has been noted.

During convalescence, as a result of inflammation involving the adductor muscles of the vocal cords paralysis of these muscles has been known to occur, leaving the voice hoarse or aphonic.

Treatment. The dry, parched tongue and lips should be frequently moistened with glycerine (1 part) and rose water (4 parts). The sluggish granulations following the fissures are best stimulated to healthy healing by daily applications of a solution of nitrate of silver 1 to 8.

MALARIA.

In this disease the upper respiratory tract, more especially the pharynx, may be intensely congested and the lymphoid tissue hypertrophied. Hemorrhages in the more severe cases may occur from the nasal, pharyngeal, and occasionally the laryngeal mucous membrane.

Neuroses of the pharynx, producing dysphagia, have been reported; and cases have also been noted of neuroses of the larynx resulting in spasmodic coughing of a croupy character.

GLANDERS.

Glanders is a disease which is occasionally met with in stablemen and in those working around horses which are afflicted with the disease.

Nasal Condition. The nose is the organ usually affected, the disease being ushered in with the symptoms of a severe acute rhinitis; the discharge, however,

quickly becomes thick, yellow, and fetid, and later is blood-stained. The lymphatic glands of the neck are usually enormously swollen, tense, and hard; later they break down and suppurate. The accessory sinuses of the nose, especially the maxillary and frontal sinuses, may be involved.

Examination of the nose in the early stages shows small, firm, colorless, nodular elevations on the septum and turbinal bodies. The nodules later become red and, in a few days, yellow. They then break down and discharge the pus to which the yellow color is due. When examined microscopically the pus shows the presence of the specific *Bacillus malleus*.

Glanders may also affect the pharynx, lips, and tongue, the tonsils being frequently the site of the disease. The same nodular conditions, undergoing the identical transformations described in the nose, have been observed.

The disease is exceedingly fatal, usually causing death in from two to ten days.

Treatment. Treatment is of little avail in this disease. The parts should, of course, be kept cleansed with alkaline sprays as described in the treatment of hypertrophic rhinitis. Large doses of potassium iodide have been advocated, and in some cases they seem to exert a beneficial influence. The antitoxin, mallein, may be given; but the number of cases of this disease is so small that treatment with this remedy is yet in the experimental stage.

INFLUENZA (*La Grippe*).

The entire upper respiratory tract is involved in an intense acute inflammation in this disease. In some

epidemics, however, the inflammatory processes are more severe than in others ; it is also noted that in some epidemics the nasal, in others the pharyngeal, and in still others the laryngeal implications are most severe.

Nasal Condition. The nose is the seat of an intense, acute rhinitis, in which the mucous membrane is often dusky red in appearance, with ecchymotic spots beneath the membrane ; there is also a slight blood-stained discharge. The inflammation is very apt to extend to the frontal, ethmoidal, and maxillary sinuses, producing acute sinusitis in one or all of these cavities. Frontal headache is usually more marked in the rhinitis of influenza than in that of non-specific origin.

Pharyngeal Condition. The pharynx is intensely congested, the lymphoid tissue of the posterior wall and behind the posterior pillars of the fauces is nearly always hypertrophied, and the lymphoid tissue of the nasopharynx is much swollen. Extension of inflammation along the Eustachian tubes to the middle ear and acute suppurative otitis media, often complicated with mastoiditis, are observed in many epidemics in which the nasopharynx is markedly implicated.

Laryngeal Condition. Laryngitis, sometimes slight, but often severe, is a constant lesion in this disease. When severe the coughing may be paroxysmal in nature and accompanied by profuse expectoration of a thick, glairy mucus, which is occasionally blood-stained. The laryngitis often persists for several weeks.

Treatment.—It is very necessary in the nasal type of this disease to contract thoroughly the swollen and congested mucous membrane so as to allow free drainage from the accessory sinuses of the nose, especially of the frontal sinus, and prevent retention of secretions

in these cavities. Suprarenal extract spray, as recommended in the article on Acute Rhinitis, answers this purpose best.

In the pharyngeal type cleansing alkaline sprays, such as are recommended in acute pharyngitis, should be employed to diminish congestion of the mucous membrane and to lessen the liability of the extension of the inflammation through the Eustachian tubes to the ears.

The acute laryngitis should be treated as recommended in the article on that subject, and we have found that dionin, gr. $\frac{1}{6}$ administered every four hours, is very useful as a sedative in diminishing spasmodic cough.

ERYSIPELAS.

Nose.

Erysipelas of the nose is rarely a primary affection, but is usually secondary to erysipelas of the face involving the skin around the nose. Occasionally primary erysipelas, beginning on the nasal mucous membrane at the junction of the mucous membrane and the skin at the nostril, occurs. Both nasal cavities are usually involved, the nose being completely obstructed; the intensely swollen mucous membrane is colored a dusky red, and the portion of mucous membrane visible in the anterior portion of the nose frequently shows ecchymotic spots. The glands of the neck are usually very much swollen, hard, and may suppurate.

The accessory sinuses are very apt to be implicated, and suppuration of the antrum and frontal sinus, and necrosis of the ethmoid cells, supervene.

Erysipelas of the nose may terminate fatally from extension of the inflammation to the meninges, when meningitis and death occur. The prognosis, however, in the nasal form of erysipelas is not so unfavorable as in erysipelas of either the pharynx or larynx.

Pharynx.

Erysipelas of the pharynx begins with a sensation of pricking in the throat, quickly followed by great difficulty in swallowing. The mucous membrane is intensely red, dry, and glistening; small vesicles and large blebs appear upon the soft palate, interior of the cheeks, tonsils, and pharyngeal wall; the uvula is elongated and edematous, and a fibrinous exudate is occasionally found on the tonsils. The inflammation is very apt to involve the nasopharynx and to extend along the Eustachian tubes to the middle ear, resulting in suppurative otitis media, often involving the mastoid as well. The glands of the neck are greatly swollen, hard and brawny in feel. Temperature is usually very much elevated, 105° – 107° F.; the patient is delirious; the urine scanty and albuminous.

The **Prognosis** in pharyngeal erysipelas is exceedingly grave.

Treatment.—The treatment is the general supporting treatment given for erysipelas in other portions of the body, and should be supplemented by painting the mucous membrane affected with the following ointment:

R.—Ichthyol	grs. 100.
Vaseline	℥j.
Oil of bergamot	℥ 5—M.

Larynx.

Erysipelas of the larynx begins with an acute swelling of the mucous membrane, which is shiny in appearance, quickly followed by hoarseness and great dysphagia and dyspnea. The dyspnea is due to the enormous swelling which takes place in the ary-epiglottic folds and ventricular bands. In a few hours the patient becomes very dyspneic, and tracheotomy is necessary to avert death from suffocation.

The constitutional symptoms are grave, and in spite of tracheotomy, the wound of which is apt to become infected, the patient frequently succumbs.

The prognosis in erysipelas of the larynx is exceedingly grave. Tracheotomy should be performed early and with the most careful antiseptic precautions, and the patient should be stimulated in the hopes of tiding him over the crisis of the disease.

ACTINOMYCOSIS.

Actinomycosis has occurred in the antrum ; its symptoms have not differed materially from those of ordinary empyema of the antrum. It was only after evacuation of the pus and examination of this microscopically that the characteristic ray fungus was discovered in the lumpy pus.

Actinomycosis of the lips, tongue, and tonsils presents the appearance of a somewhat irregular and nodular swelling. The growth is usually quite rapid, more so than that of any of the non-malignant tumors found in this region, and not infrequently is as rapid as that of malignant growths, such as sarcoma and epithelioma, for which it is in its early stage easily mistaken. There

is little or no pain accompanying the growth. In a few weeks the tissue shows signs of softening, and later breaks down in one or several places, leaving the growth riddled with sinuses. In addition to the pus that is discharged from these sinuses, small yellowish lumps are observed, which if examined microscopically will be found to be almost pure cultures of the ray fungus.

The prognosis in this disease depends upon the part implicated and the stage at which the disease is diagnosed. If on the lips and in such a position that the discharge is not swallowed, thereby favoring involvement of the gastro-intestinal tract, or by the fungus entering the larynx and invading it, the bronchi, lungs, and pleuræ, the prognosis is good. In such cases the growth may be completely excised without recurrence.

Where the tongue or tonsil is involved the infection of the lower parts of the digestive and respiratory tracts is almost sure to take place before a diagnosis can be made, and it may be impossible on account of the situation of the growth to enucleate all of the diseased tissue; in such cases the prognosis is exceedingly grave.

Treatment. The only treatment of value is the complete surgical removal of the diseased tissue.

CHAPTER XII.

THERAPEUTICS.

REMEDIES FOR THE LOCAL TREATMENT OF DISEASES OF THE NOSE, PHARYNX, AND LARYNX.

IN this chapter we shall give a number of additional remedies¹ that may be employed in the local treatment of the diseases already described. We shall attempt to classify these so that the reader may understand more clearly the indications for their use.

A. AQUEOUS SOLUTIONS FOR THE NOSE AND PHARYNX.

The uses of aqueous solutions are :

- I. For cleansing the passages from accumulated secretions.
- II. As mild antiseptics.
- III. As astringents, lessening secretion.
- IV. For stimulating the glands to increased activity.
- V. For deodorizing foul-smelling discharges.

As they are all fluid, the first indication is carried out whatever their further action may be under the other four heads.

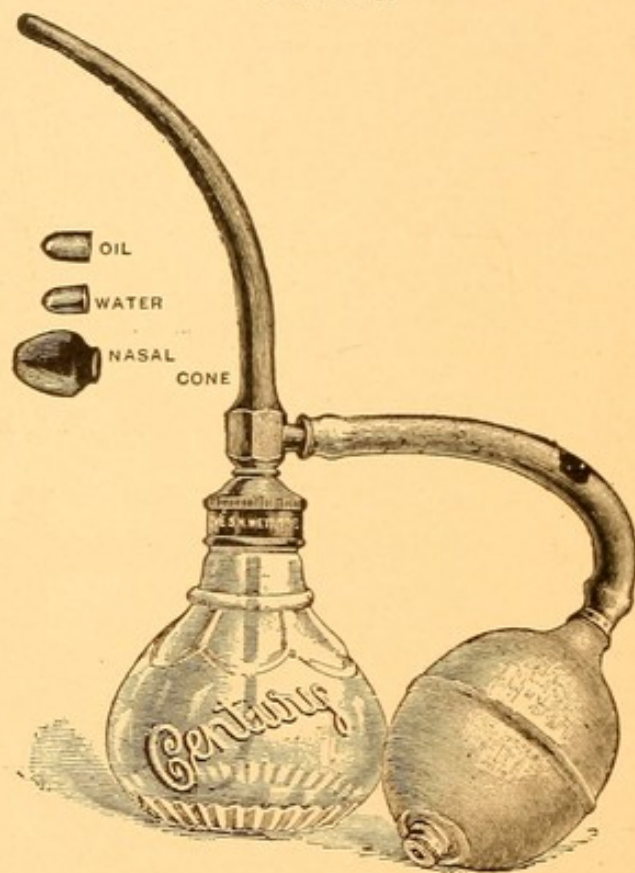
Aqueous solution may be employed in the nasal douche (Fig. 31), provided the nasal passages are clear,

¹ Only those which we have used with good results will be included. Where the source from which they are derived is known mention of it will be made.

so that no marked obstruction to the return circulation exists.

When nasal obstruction is marked it is better to use the hard-rubber nasal syringe (Fig. 19), *syringing through the obstructed side*. The solutions may also be used in a hand atomizer. In prescribing such an instru-

FIG. 125.



Century atomizer.

ment, one that gives a generous stream, as the Century atomizer (Fig. 125), is to be preferred. This instrument has the advantages that it is provided with a large nasal bulb which prevents its introduction too far within the nose, thus avoiding injury to the septum, and, also, that it has two tips, through one of which watery and through the other oily solutions may be used.

All liquids should be warmed to a temperature of 100° F., and should not cause more than momentary smarting. If they prove decidedly painful, they should be diluted.

For cleansing the posterior nares the syringe (Fig. 73) gives the best results.

I. Simple Cleansing Solutions.

1. R.—Sod. bicarbonatis,
Sod. boratis,
Sod. chloridi āā 3j.
(Demilt Dispensary formulary.)

M. Sig.—A small teaspoonful to a pint of lukewarm water.

A very useful preparation where large quantities of fluid are needed and cost has to be taken into consideration.

2. R.—Sod. bicarb.,
Sod. biborat. āā gr. xxxij.
Aquæ dest. 3iv.—M.
(L. Browne.)

An alkaline spray for softening thick, tenacious mucus.

II. Mild Antiseptic Solutions.

3. R.—Resorcini gr. v-xx.
Aquæ dest. 3j.—M.

Often useful in hay fever and *chronic* cases in which there is a watery discharge from the nose.

4. R.—Creolini ℥j-iv.
Aquæ dest. 3j.—M.

Antiseptic and deodorant. Useful in atrophic rhinitis, syphilitic and other ulcerations, and in diseases of the accessory sinuses.

5. R.—Thymol gr. vj.
Alcohol,
Glycerini āā 3vj.
Aquæ dest. q. s. ad. 3iv.—M.

(Demilt Dispensary formulary.)

Antiseptic and stimulant. Useful where there is a feeling of dryness in the nose not due to atrophic rhinitis.

III. Astringents Lessening Secretion.

6. R.—Zinci sulpho-carbolatis . . . gr. v-x.
Aquæ dest. ʒj.—M.
7. R.—Zinci sulphatis . . . gr. v-x.
Aquæ dest. ʒj.—M.
8. R.—Ferri perchloridi . . . gr. ij-vj.
Aquæ dest. ʒj.—M.
9. R.—Cupri sulphatis . . . gr. v-x.
Aquæ dest. ʒj.—M.
10. R.—Aluminis . . . gr. v-xv.
Aquæ dest. ʒj.—M.
11. R.—Ac. tannici . . . gr. iij—v.
Aquæ dest. ʒj.—M.

Each of the above is useful for a time in hypertrophic rhinitis and pharyngitis with increased secretion. The effect of each is usually lessened at the end of two weeks, and a different one should then be used.

12. R.—Antipyrini . . . gr. x.
Zinci sulphatis . . . gr. ij.
Ext. hamamelidis . . . ʒj.
Aquæ dest. . . q. s. ad. ʒj.—M.
(Ingals.)

A very agreeable astringent, slightly antiseptic. Uses as in No. 11.

13. R.—Ac. borici . . . ʒj.
Glyceriti ac. tannici . . . ʒss.
Ol. gaultheriæ . . . ℥x.
Aquæ dest. . . q. s. ad. ʒiv.—M.
(O. D. P. Bellevue Hospital.)

Astringent and antiseptic. Uses as in No. 11.

IV. Stimulating the Glands to Increased Activity.

14. R.—Potass. chlor. . . gr. x-xx.
Aquæ dest. ʒj.—M.

This alone, or frequently combined with No. 2, is very serviceable in anemic females whose nasal and pharyngeal mucous membranes are pale, dry, and glistening.

15. R.—Thymol,
 Menthol āā gr. ij.
 Glycerini 3vj.
 Sol. ac. borici (sat.) 3jss.
 Aquæ dest. q. s. ad. 3iv.—M.
 (Demilt Dispensary formulary.)

For the same condition as No. 14.

V. Deodorants.

16. R.—Sodii chloridi gr. iij.
 Potassii permanganatis gr. j—v.
 Aquæ dest. 3j.—M.

Very useful in cases of diseases of the accessory sinuses, syphilitic necrosis, atrophic rhinitis, or other conditions in which there is much fetor to the discharge. No. 4 is also useful for the same purpose.

In addition to the above formulæ mention may be made of a number of pharmaceutical preparations which are useful as cleansing and antiseptic solutions.

Listerine may be added to any of the antiseptic solutions given. It should not be used in greater proportion than a teaspoonful to each ounce of the prescription. It often makes the odor of the preparation more pleasing to the patient. In the same category may be placed borolyptol, boroformalin, glycothymolin, and alphasol.

B. OILY SOLUTIONS FOR THE NOSE AND PHARYNX.

These act as follows :

- I. Protectives.
- II. Sedatives.
- III. Stimulants and depletives.
- IV. Astringents and antiseptics.

I. Protectives.

They coat the mucous membrane with a thin layer of oil, which may remain in contact with it half an hour or longer. They are seldom, however, used for their protective action alone, as drugs are combined with them for some of the other indications. They are of little or no use in cleansing the passages, but very valuable as protectives for use immediately after employing aqueous solutions.

Oily solutions should not be used continuously for more than three or four weeks, as they deplete the mucous membrane of so much moisture as often to leave a dry feeling in the air passages. The Century atomizer, or the well-known albolene atomizer of Codman & Shurtleff, may be used to spray them into the air passages. Frye's atomizer is very handy, especially when the patient is travelling and has to carry his apparatus with him.

The protective fluids are :

Benzoinol.

Albolene.

Liquid vaseline.

The heavy white vaseline may be used in a DeVilbiss atomizer, which, being of metal, allows the mass to be warmed sufficiently to become liquid. We have failed to get any better results with the heavy vaseline than with the oily liquids.

The addition of two minims of oil of rose or extract of violets to any of the oil solutions gives a pleasant odor to the mixture that is very acceptable to many patients.

II. Sedatives.

17. R.—Ac. carbolic gr. iij.
 Menthol gr. v.
 Benzoinol $\bar{3}$ j.—M.

Excellent for use after watery solutions, to prevent a patient catching cold on immediately going out.

18. R.—Eucalyptol \mathfrak{m} x.
 Menthol gr. v.
 Camphoræ gr. v.
 Benzoinol q. s. ad. $\bar{3}$ j.—M.

Used for the same purpose, but often found to be more agreeable.

19. R.—Ext. pini Canadensis dest. $\bar{3}$ ss.
 Olei geranii \mathfrak{m} iv.
 Albolene q. s. ad. $\bar{3}$ j.—M.
(Ingals.)

Used for the same purpose as the two preceding.

III. Stimulants and Depletives.

Useful in acute and subacute inflammations of the nose and pharynx.

20. R.—Menthol gr. xxx.
 Camphoræ gr. x.
 Ol. rosæ \mathfrak{m} ij.
 Benzoinol $\bar{3}$ ij.—M.

21. R.—Menthol gr. xl.
 Thymol gr. xv.
 Camphoræ gr. xx.
 Ol. rosæ \mathfrak{m} ij.
 Benzoinol $\bar{3}$ ij.—M.

A more powerful depletor than the above.

22. \mathfrak{m} .—Ac. carbolic gr. xxx.
 Ext. pini Canadensis dest. \mathfrak{m} xx.
 Albolene $\bar{3}$ j.—M.
(Ingals.)

Stimulating and astringent. Useful in hay fever on account of the anesthetic effect of the carbolic acid.

IV. Astringents and Antiseptics.

23. R.—Eucalyptol	℥xv.
Menthol	gr. xv.
Camphoræ	gr. x.
Ol. pini pumilionis	℥ss.
Ol. rosæ	℥ij.
Benzoinol q. s. ad.	℥ij.—M.

Good in mild cases of chronic hypertrophic rhinitis.

24. R.—Aristol	gr. xx.
Ol. olivæ	℥jss.
Menthol	gr. xx.
Ol. pini pumilionis	℥x.
Eucalyptol	℥ss.
Benzoinol q. s. ad.	℥j.—M.

(The aristol should first be dissolved in the olive oil, heating if necessary to 115° F. ; a higher temperature may liberate the iodine.) An excellent formula for use in atrophic rhinitis after freeing the nose from crusts ; also good in some cases of hay fever.

25. R.—Nosophen	gr. xx.
Menthol	gr. xx.
Camphoræ	gr. x.
Ol. gaultheriæ	℥xv.
Benzoinol q. s. ad.	℥j.—M.

(In this formula the nosophen is only held in suspension. It is best used in Frye's atomizer ; to be shaken before spraying.) May be used in atrophic rhinitis and for ulcerations in the nose and pharynx, alternating with No. 24.

26. In connection with the oily solutions oleo-stearate of zinc is an excellent base for applying the various drugs to the nasopharynx and floor of the nose. This preparation is manufactured by McKesson & Robbins, and is combined with iodoform, menthol, aristol, camphor, boric acid, etc. Its advantage lies in the fact of its clinging to the surface of the mucous membrane longer than most other liquid substances. Its disadvantage lies in its thickness and the consequent inability to be used in an ordinary atomizer. A special pipette

comes for use with the preparation, which is poured into the nose and allowed to run over the floor, inferior turbinate, and so into the nasopharynx.

C. MEDICAMENTS TO BE LOCALLY APPLIED TO THE NOSE, NASOPHARYNX, AND MOUTH ON COTTON-WOUND APPLICATORS.

The action of these applications may be classed as

- I. Alteratives.
- II. Astringents.
- III. Stimulants.
- IV. Caustics and escharotics.

I. Alteratives.

These are indicated where local thickenings are found beneath the mucous membrane, as in hypertrophic inflammation. They should be applied every three or four days for a considerable period.

- | | | | | | | | |
|-----|-----------------|---|---|---|---|---|----------|
| 27. | R.—Iodini | . | . | . | . | . | gr. v. |
| | Potassii iodidi | . | . | . | . | . | gr. x. |
| | Ol. gaultheriæ | . | . | . | . | . | ℥v. |
| | Glycerini | . | . | . | . | . | ℥j.—M. |
| 28. | R.—Iodini | . | . | . | . | . | gr. x. |
| | Potassii iodidi | . | . | . | . | . | gr. xx. |
| | Ol. menth. pip. | . | . | . | . | . | ℥v. |
| | Glycerini | . | . | . | . | . | ℥j.—M. |
| 29. | R.—Iodini | . | . | . | . | . | gr. xv. |
| | Potassii iodidi | . | . | . | . | . | gr. xxx. |
| | Ol. gaultheriæ | . | . | . | . | . | ℥v. |
| | Glycerini | . | . | . | . | . | ℥j.—M. |
| 30. | R.—Iodini | . | . | . | . | . | gr. xx. |
| | Potassii iodidi | . | . | . | . | . | gr. xl. |
| | Ol. menth. pip. | . | . | . | . | . | ℥v. |
| | Glycerini | . | . | . | . | . | ℥j.—M. |

These four solutions increase gradually in strength. After the third or fourth application with No. 27, employ No. 28 a few times, and then use No. 29. For the nasopharynx it is usually possible to begin treatment with No. 28.

The addition of the *ol. gaultheriæ*, $\mathfrak{M}\text{v}$, or *ol. menthæ piperitæ*, $\mathfrak{M}\text{v}$, to each of the above renders them more agreeable to the patient. These are used so frequently that it is well to have a double set—one flavored with wintergreen the other with peppermint, for the patient to choose from.

II. Astringents.

Used to diminish excessive secretion.

- | | | | |
|-----|------------------------|-----------|------------------------|
| 31. | R.—Alumnol | | gr. v-x. |
| | Aquæ dest. | | $\bar{3}\text{j.}$ —M. |
| 32. | R.—Zinci sulphatis | | gr. x-xx. |
| | Aquæ dest. | | $\bar{3}\text{j.}$ —M. |
| 33. | R.—Zinci chloridi | | gr. v-xv. |
| | Aquæ dest. | | $\bar{3}\text{j.}$ —M. |
| 34. | R.—Liq. ferri chloridi | | \mathfrak{M}_{xxx} . |
| | Aquæ dest. | | $\bar{3}\text{j.}$ —M. |

III. Stimulants.

Used to increase secretion from the tissues. Useful in atrophic pharyngitis and rhinitis.

35. R.—Glyceriti ac. tannici.

36. R.—Boroglyceride.

Each of these is used in full strength.

37. R.—Tr. iodini,
Tr. catechu,
Glycerini $\bar{a}\bar{a}$ $\bar{3}\text{j.}$ —M.
(Hall.)

38. R.—Argenti nitratis gr. xx-lx.
Aquæ dest. $\bar{3}\text{j.}$ —M.

(All solutions of nitrate of silver should be kept in dark bottles, and made fresh every three or four days.)

IV. Caustics and Escharotics.

These are useful for applications to ulcerations.

39. R.—Liq. hydrargyri nitratis . . . ʒj-ʒiv.
Aquæ . . . q. s. ad. ʒj.

One of the very best for cleaning up a sloughing tertiary syphilitic ulcer. The application is very painful, so that cocaine must first be employed. Great care must be taken that the applicator is not too moist, or neighboring parts will be cauterized by the fluid running over them.

40. R.—Argenti nitratis . . . ʒij.
Aquæ dest. . . ʒj.—M.

Excellent for secondary mucous patches of syphilis.

41. R.—Zinci chloridi . . . gr. xxx-ʒj.
Aquæ dest. . . ʒj.—M.

For cauterizing the ulcers of malignant growths.

42. R.—Ferri perchloridi . . . gr. xxx-ʒj.
Aquæ dest. . . ʒj.—M.

For checking capillary oozing from malignant growths.

D. OINTMENTS FOR USE IN THE NOSE AND ABOUT THE FACE IN CONNECTION WITH DISEASES OF THE NOSE AND PHARYNX.

The principal use for ointments lies in their protecting the skin of the nostrils and lips from being excoriated by irritating discharges from the nose. They may also be used to protect the margins of a perforating ulcer of the septum and to stimulate granulation-tissue to a more healthy action, with consequent cicatrization.

43. R.—Vaselini carbolati . . . ʒj.
Apply with a camel's-hair brush; protective to skin.

44. R.—Olei eucalypti . . . ʒss.
Vaselini . . . q. s. ad. ʒj.—M.
Protective.

45. R.—Ung. hydrarg. nitratis . . . ʒj.
 Vaselini . . . q. s. ad. ʒj.—M.

Useful where there are cracks or fissures about the vestibule or in the angles of the mouth. Also useful in cases in which there are ulcerations around a perforated septum.

46. R.—Ichthyol . . . ʒj.
 Ung. zinci oxidi . . . ʒvij.
 Ol. bergamot. . . ℥v.—M.

Useful where the tissues are thick and indurated.

47. R.—Dermatol . . . ʒss.
 Vaselini . . . ʒj.—M.

Nearly as efficacious as No. 46, and does not possess the disagreeable odor. One may have to use this on account of the patient's dislike to No. 46.

48. R.—Iodol . . . ʒss.
 Vaselini . . . ʒj.—M.

Used like No. 47.

E. POWDERS FOR INSUFFLATION INTO THE NOSE OR PHARYNX.

The only use we make of powders in the nose or pharynx is for the purpose of dusting over a raw surface after operations, such as snaring a portion of the turbinate or removing a spur with the saw, and in treating ulcers. They act as antiseptics and promote healing. They are best applied by means of a powder blower. The powders most frequently employed are

49. R.—Aristol.
 50. R.—Europhen.
 51. R.—Nosophen.
 52. R.—Iodol.
 53. R.—Iodoform.

In empyema of the accessory sinuses.

These powders may be used alone, filling the little cup of the powder-blower about one-third full, or they may be mixed with—

54. Compound stearate of zinc, using about 2 parts by volume of the stearate to 1 part of the powder. In such cases the cup of the powder blower should be filled with the mixture. The advantage of the stearate is that it adheres to the raw surfaces more tenaciously than do the plain powders.

55. R.—Soziodol-zinc 1 part.
Talcum 9 parts.—M.
(Schmidt.)

For use in atrophic rhinitis with ulcerations after cleansing the nose from crusts.

F. DRY INHALATIONS. (SMELLING SALTS.)

These are occasionally of use in the congested condition of the nasal mucous membrane, accompanied by a feeling of stuffiness in the head, to which some people are subject on slight exposure.

56. R.—Acidi carbolici gr. xxx.
Ammonii carbonatis ʒj.
Pulveris carbonis ligni ʒj.
Olei lavendulæ ℥xx.
Tr. benzoini comp. ʒss.—M.
(L. Browne.)

Keep in well-stoppered bottles and only remove the cork when inhaling.

57. R.—Acidi carbolici liq. ʒj.
Ammonii carbonatis ʒij.
Pulveris carbonis ligni ʒij.
Tr. benzoini comp. ʒj.
Ol. lavendulæ ℥vj.
Aq. ammoniæ fort. q. s.—M.
(Hall.)

Somewhat stronger than the preceding.

58. Chloride of ammonium inhalers are found on the market in variety, and are sometimes useful in the early stages of acute rhinitis. Their use may abort a mild attack.

G. TABLETS.

These are useful as a means of allowing the medicines contained in them to become slowly dissolved in the secretions of the mouth and thus act upon the mucous membrane of that cavity, as well as on the oropharynx and laryngopharynx. When it is not convenient to use sprays this is a far better way of administering remedies than is that of gargling. Unfortunately, only a few remedies can be employed in the form of tablets, as the drugs, if swallowed, interfere seriously with the functions of the stomach and intestines.

These tablets may be used as

- I. Astringents and antiseptics.
- II. Sedatives.
- III. Stimulants.

I. Astringents and Antiseptics.

These are indicated in acute inflammation of the fauces, tonsils, and pharynx.

59. R.—Tr. ferri chloridi ℥iij.
 Hydrarg. chlor. *corrosivi* gr. $\frac{1}{100}$.
 Tr. aconiti ℥ $\frac{1}{2}$.
 Sacch. lactis q. s.—M.

One such tablet dissolved in the mouth every hour for four hours, after which one every three hours.

Useful in acute pharyngitis and tonsillitis, to replace the iron and chlorate of potassium gargle so frequently prescribed.

60. R.—Hydrarg. chlor. *corrosivi* gr. $\frac{1}{100}$.
 Tr. belladonnæ ℥j.
 Pulv. ipecacuanhæ gr. $\frac{1}{10}$.
 Sacch. lactis q. s.—M.
(Rankin.)

One every hour until six are taken, then one every three hours.

Used for same condition as No. 59.

61. R.—Res. guaiaci gr. $1\frac{1}{2}$.
 Ext. glycyrrhizæ gr. $\frac{1}{2}$.—M.
 (Smith.)

62. R.—Res. guaiaci gr. $1\frac{2}{3}$.
 Ammonii chloridi gr. $1\frac{2}{3}$.
 Ext. glycyrrhizæ gr. $\frac{1}{2}$.—M.

No. 60 and No. 61 are almost specifics for some patients with lacunar tonsillitis. Many patients are intensely nauseated by the guaiac, and cannot take it in any form.

63. R.—Ac. benzoici gr. $\frac{1}{5}$.
 Pulv. opii gr. $\frac{1}{30}$.
 Pulv. catechu gr. $\frac{1}{4}$.
 Pulv. camphoris gr. $\frac{1}{20}$.
 Ext. yerbæ santæ gr. $\frac{1}{4}$.
 Sacch. lactis q. s.
 Aromatics q. s.—M.

One every two hours as an astringent in subacute pharyngitis with congestion of the bloodvessels.

64. R.—Red gum lozenges are useful where a slight astringent action is desired in mild acute pharyngitis.

II. Sedatives.

These are indicated in acute and chronic inflammations of the mucous membrane, accompanied by a sensation of rawness or tickling in the pharynx. A persistent cough frequently accompanies these conditions and tends to aggravate the inflammation. Sedatives should only be used to give temporary relief while the diseased condition is being treated.

65. R.—Terpini hydratis gr. ij.
 Ammon. chloridi gr. j.
 Ext. glycyrrhizæ gr. $\frac{1}{2}$.
 Pulv. ipecacuanhæ gr. $\frac{1}{10}$.
 Codeinæ gr. $\frac{1}{10}$.—M.

One every hour or two until tickling and cough cease.

66. R.—Ammon. chloridi gr. ij.
 Pulv. ipecacuanhæ gr. $\frac{1}{4}$.
 Ext. scillæ aceteci gr. $\frac{1}{4}$.
 Ext. senegæ fl. ℥j.—M.
 (Brewer.)

Dose and indications same as for No. 64.

67. R.—Ac. carbolicæ gr. $\frac{1}{40}$.
 Menthol gr. $\frac{1}{30}$.
 Ol. sassafras ℥j.
 Pulv. acaciæ q. s.
 Sacch. lactis q. s.—M.

A good lozenge for the foul breath associated with syphilitic and atrophic diseases of the pharynx and larynx.

III. Stimulants.

These increase the activity of the glands of both the pharynx and larynx, and are indicated in cases in which a feeling of dryness in the parts and hoarseness are complained of.

68. R.—Potassii chloratis gr. j.
 Pulv. ipecacuanhæ gr. $\frac{1}{20}$.—M.
 (McEwen.)

One every hour, if necessary, for dry throat.

69. R.—Potassii chloratis gr. ij.
 Ext. eucalypti rostratæ gr. j.
 Pulv. cubebæ gr. $\frac{1}{4}$.
 Sacch. lactis q. s.—M.
 (L. Browne.)

One every hour or two for dry throat and hoarseness.

70. R.—Menthol gr. $\frac{1}{35}$.
 Ol. anisæ ℥ $\frac{1}{80}$.
 Ac. benzoici gr. $\frac{1}{12}$.
 Eucalyptol ℥ $\frac{1}{15}$.
 Sacch. lactis q. s.—M.

As in No. 69.

H. AQUEOUS SPRAYS FOR USE IN THE LARYNX.

The situation of the larynx renders it very difficult for most patients to insert the down tip of an atomizer far enough back into the pharynx to spray any appreciable amount of fluid into the laryngeal cavity. These sprays are therefore, practically only employed by the physician. The compressed air apparatus, or that described in Fig. 113, is to be employed.

The indications for the use of watery sprays for the larynx are the same as those given for the nose.

I. Simple Cleansing Solution.

71.	R.—Sod. chloridi	gr. v.
	Sod. bicarbonatis	gr. x.
	Listerine	℥ss.
	Aquæ dest.	.	.	.	q. s. ad.	℥j.—M.

II. Antiseptic Solutions.

Nos. 3 and 4 are useful in cases of tubercular, syphilitic, and malignant ulcers as a means of softening the pus and facilitating its expectoration prior to local applications to the diseased areas.

III. Astringent Solutions

are indicated in hypertrophic laryngitis. The solutions Nos. 6, 7, 8, 9, 10 are employed for the purpose of cleansing the larynx and for their subsequent astringent action.

IV. Stimulating Solution.

Formula No. 15 may be employed, but the oily solutions are usually better.

V. Deodorant Solution.

This may be employed in syphilitic or malignant ulcerations and in atrophic laryngitis with fetor.

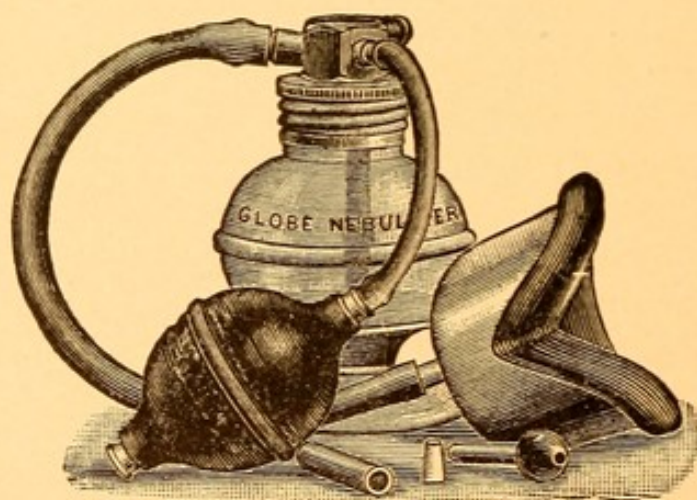
72. R.—Sod. chloridi gr. iij.
Potassii permanganatis gr. ss.
Aque dest. $\bar{3}$ j.—M.

I. OILY SPRAYS FOR THE LARYNX.

The actions of these are the same as those given for such solutions in the nose.

In order to reach the parts they must be used by the patient in an oil atomizer, and he should be instructed

FIG. 126.



Globe nebulizer.

to take a full, deep inspiration just as the bulb of the atomizer is compressed. The current of air will carry some of the finely comminuted spray into the larynx, and often beyond it to the trachea and possibly to the bronchi. Some of the solution will be deposited on the pharyngeal mucosa ; but as this is also frequently diseased, only benefit will result. The physician may use

the compressed air atomizers, employing the down tip. The tongue should be protruded and the spray tube passed into the mouth parallel to the tongue until it is within a quarter of an inch of the posterior pharyngeal wall. The spraying gives the most satisfactory results if the cut-off is released at the commencement of a deep inspiration. A patient occasionally finds difficulty in acquiring the knack of inspiring and thus drawing the oily solutions into the larynx.

The globe nebulizer, with the mask (Fig. 126), serves as a means of applying volatile ingredients soluble in oil to the mucous membrane not only of the larynx, but to the trachea and bronchi as well.

I. Sedatives.

Useful in acute laryngitis.

Formulae Nos. 17, 18, and 19 are well adapted to this purpose.

II. Stimulants and Depletives.

For increasing the secretion from the glands and mucous membrane, thus diminishing the congestion.

Useful in the early stages of acute laryngitis and in the exacerbations of a chronic hypertrophic laryngitis.

Formulae Nos. 20 and 21 are the most serviceable.

III. Astringents and Antiseptics.

For relieving the dyspnea due to slight edema of the tissues, formula No. 23.

Formulae Nos. 24 and 25 are valuable in tubercular ulcerations of the larynx.

J. MEDICATED STEAM INHALATIONS.

These are of service in cases of marked congestion and edema of the larynx and in membranous laryngitis. They are also serviceable in softening the thick, tenacious secretions found in some cases of chronic laryngitis, and especially in atrophic laryngitis. When employed great care has to be taken to protect the patients from draughts, and they should not be allowed to go outdoors for several hours, as the relaxation of the mucous membrane makes them very susceptible to a renewed and more severe inflammation. These preparations may be used in a steam atomizer, or they may be placed in an ordinary teakettle, and a cone made of cardboard used to direct the steam toward the mouth. Care must be taken that the steam does not scald the face, especially if the patient be unconscious.

73. R.—Tr. benzoini comp. ʒj.
Aquæ Oj.—M.

Heat to 150° F. For acute laryngitis of children with a croupy cough.

74. R.—Olei pini pumilionis ʒij.
Tr. benzoini comp. . . q. s. ad. ʒij.—M.

A teaspoonful of this mixture in a pint of water, temperature 150° F. Somewhat more stimulating than the preceding.

75. R.—Creosoti ʒss.
Magnesiæ carb. levis gr. xc.
Aquæ dest. q. s. ad. ʒij.—M.

(L. Browne.)

A teaspoonful in a pint of hot water (150° F.), for softening the crusts in laryngitis sicca.

76. R.—Ol. eucalypti ʒij.
Terebinthinæ ʒj.
Magnesiæ carb. levis ʒij.
Aquæ dest. q. s. ad. ʒij.—M.

A teaspoonful in a pint of hot water (150° F.), for loosening the secretion and allaying the cough in tubercular laryngitis.

K. MEDICAMENTS TO BE LOCALLY APPLIED TO THE LARYNX BY MEANS OF COTTON-WOUND APPLICATORS.

These topical applications should be limited to those remedies which it is necessary to apply only to the laryngeal mucous membrane or to small portions of it.

When the mild effects of stimulation or astringent action are desired, the object will best be accomplished by the use of oil or water sprays. The improper introduction of a swab or brush often does great harm by the traumatism produced, thus counteracting the good effect of the medicaments.

The larynx should always be cocainized by the introduction of a cotton-wound laryngeal applicator that has been dipped in a 10 per cent. solution of cocaine.

I. Alteratives.

Those given in Nos. 27 and 28 may be employed to assist in the absorption of the thickened mucosa in chronic hypertrophic laryngitis. It may be possible to use No. 29 in some cases, but the reaction is apt to be too great.

II. Stimulants.

77. R.—Argenti nitratis gr. x.-xx.
Aquæ dest. ʒj.—M.

This may be employed to stimulate the mucous membrane to increased activity in chronic laryngitis. Formula No. 36 may be employed for the same purpose.

III. Caustics.

If it is decided to apply these on a swab (they are best applied fused on a concealed laryngeal caustic applicator, Fig. 94), great care must be taken not to have

the cotton too moist, for fear that some of the caustic will enter the trachea and produce *intense* spasm and dyspnea.

Formulæ Nos. 40 and 41 may be used on a cotton-wound laryngeal applicator for the local treatment of ulcers of the larynx.

L. INSUFFLATION OF POWDERS INTO THE LARYNX.

The only condition which, in our opinion, warrants the insufflation of powders into the larynx is the presence of ulcers. These may be due to syphilis, tuberculosis, malignant growths, or lupus.

The powders are to be used in a powder blower, and may often be advantageously mixed with stearate of zinc, as described for powders for the nose.

The substances to be insufflated are the same as those already given, Nos. 49 to 53 inclusive.

78. R.—Soziodol-mercury 1 part.
Talcum 9 parts.—M.

This is of special service in syphilitic ulceration.

79. R.—Alumnol by volume 1 part.
Stearate of zinc “ 2 parts.—M.

Also useful in syphilitic and malignant ulcers.

In tubercular and malignant ulcers of the larynx it is permissible to use cocaine and morphine with the antiseptic powders, as the patient's prospect for living very long is small, and there is no danger of acquiring any drug-habit.

80. R.—Cocainæ gr. xx.
Iodoformi ʒij.
Stearate of zinc ʒj.

For relief of the pain in tubercular or malignant ulcers.

81. R.—Bismuthi subnit.,

Pulv. acaciæ āā ʒij.
 Iodoformi ʒss.
 Morphinae sulph. gr. xx.
 Ac. tannici ʒss.—M.

(Demilt Dispensary formulary.)

This is a very good powder for insufflation into the larynx, half an hour before taking food, in cases of painful deglutition in tuberculosis and malignant disease.

82. R.—Cocainæ gr. x.

Bismuthi oxychloridi ʒj.—M.

(L. Browne.)

For relief of pain in tubercular and malignant ulcers of larynx.


83. R.—Cocainæ,

Morphinae sulph. āā gr. xx.

Nosophen ʒjss.

Stearate of zinc ʒj.—M.

Used as Nos. 80 and 81, where the smell and taste of iodoform are disagreeable to the patient. Either the cocaine or morphine may be omitted in mild cases.



INDEX.

NOTE.—Figures in ordinary type refer to the pages of the book. Heavy-type numbers in parentheses refer to the formulæ in Chapter XII., pages 551 to 571.

A.

ABSCCESS of larynx, 452. *See*
Larynx, abscess of
of septum, 148. *See* Septum,
abscess of
peritonsillar, 309. *See* Peri-
tonsillar abscess
retropharyngeal, 295. *See*
Retropharyngeal abscess
Accessory sinuses, acute suppu-
rative inflammation of,
198
diseases of, 198
involvement of, in erysipe-
las, 547
Acid, chromic, cauterization,
method of employing, 94
trichloracetic, cauterization,
method of employing, 93
Actinomycosis, 549
appearance of, 549
of antrum of Highmore, 549
of lips, 549
prognosis of, 550
of tongue, 549
of tonsils, 549
treatment of, 550
Acute laryngitis, 411. *See*
Laryngitis, acute
in children, 418
nasopharyngitis, 252. *See*
Nasopharyngitis, acute
pharyngitis, 280. *See* Pha-
ryngitis, acute

Acute rhinitis, 78. *See* Rhinitis,
acute
suppurative inflammation of
the accessory sinuses of
nose, 198. *See* Sinuses,
accessory, of nose, acute
suppurative inflammation
of
tonsillitis, 302. *See* Tonsilli-
tis, acute
Adenoids, 258
differential diagnosis of, 262
etiology of, 258
examination of, 261
in influenza, 546
in measles, 540
pathology of, 260
in pertussis, 541
prognosis of, 263
in acute otitis media, 263
in chronic otitis media, 263
recurrence after operation,
263
in scarlet fever, 537
symptoms of, 260
treatment of, 264
constitutional, 264, 268
operative, 264
post-operative, 267
hemorrhage, 268
Adenomata of larynx, 499
of nose, 186. *See* Nose, adeno-
mata of
of pharynx, 401
Adhesions in nose, 95. *See* Syne-
chia

- Air, direction of current of, in nose, 34
- Alkaline cleansing solution, 89, 90
- Anesthesia of larynx, 534
of pharynx, 409
- Angiomata of larynx, 498
of pharynx, 401
of nose, 187. *See* Nose, angiomata of
- Anosmia, 191. *See* Nose, smell, loss of sense of
- Anterior rhinoscopy, 44
- Antisepsis in operations on upper respiratory tract, 69
- Antiseptic solutions, aqueous, for larynx, 567
for nose, 553
for pharynx, 553
oily, for larynx, 569
for nose, 558
for pharynx, 558
- Antrum of Highmore, actinomycosis of, 549
acute suppurative inflammation of, 198
diagnosis of, 210
etiology of, 198, 199
examination of, 204
puncture in, 210
transillumination in, 206, 208
pathology of, 199
prognosis of, 215
symptoms of, 201
treatment of, 215
constitutional, 215
local, 217
chronic suppuration of, 222. *See* Antrum of Highmore, empyema of
cyst of, 230
dentigerous, 231
symptoms of, 230
treatment of, 231
varieties of, 230
empyema of, 222. *See* also Antrum of Highmore, acute suppurative inflammation of
after-treatment of, 229
- Antrum of Highmore, empyema of, etiology of, 222
examination of, 223
puncture in, 224
transillumination in, 206, 208, 224
pathology of, 222
prognosis of, 225
symptoms of, 223
treatment of, 215, 217, 225, 229 (1, 2, 4, 6, 7, 9, 10, 16, 31, 32, 33, 40, 41, 49, 53, 55)
radical operation, 227
through nasal wall, 225
malignant disease of, 233
etiology of, 233
prognosis of, 233
symptoms of, 233
treatment of, 234
osteomata of, 232
differential diagnosis of, 232
etiology of, 232
examination of, 232
prognosis of, 233
symptoms of, 232
treatment of, 233
polypi of, 229
etiology of, 229
symptoms of, 230
treatment of, 230
maxillary, anatomy of, 24
mucous membrane of, 24
opening of, normal, 24
thinnest parts of, 24
- Aphonia spastica, 514
- Applicator, nasal, winding cotton on, 48
- Aprosexia, 76, 86
- Aryepiglottic fold, normal appearance of, 67
- Arytenoid cartilage, 29
- Arytenoideus, action of, 31
- Astringent solutions, aqueous, for larynx, 567
for nose, 554
for pharynx, 554
oily, for larynx, 569

- Astringent solutions, oily, for
 nose, 558
 for pharynx, 558
 Atrophic laryngitis, 442. *See*
 Laryngitis, atrophic
 nasopharyngitis, 256. *See*
 Nasopharyngitis, atrophic
 pharyngitis, 292. *See* Pharyn-
 gitis, atrophic
 rhinitis, 106. *See* Rhinitis,
 atrophic
 Auditory function of nose, 35
- B.**
- BERNAY'S sponges for control-
 ling hemorrhage, 101
 Bursa, pharyngeal, appearance
 of, in mirror, 60
- C.**
- CALCULI, nasal, 170. *See* Rhino-
 liths
 Calculus of tonsil, 329. *See* Ton-
 sils, calculus of
 Cartilage, arytenoid, 29
 of Santorini, normal appear-
 ance of, 67
 position of, 29
 of Wrisberg, normal appear-
 ance of, 67
 position of, 29
 Caustic solutions for larynx, 571
 for nose, 561
 for pharynx, 561
 Cauterization, chromic acid,
 method of employing, 94
 galvano-, method of, 93
 of middle turbinate, dangers
 of, 105
 trichloroacetic acid, method of
 employing, 93
 Cells, ethmoidal, anterior, anat-
 omy of, 25
 openings of, 25
 posterior, anatomy of, 25
 openings of, 25
 Chancre of nose, 157. *See* Nose,
 syphilis of, primary
- Chickenpox, 543
 lesions in pharynx in, 543
 Chondromata of larynx, 499
 of pharynx, 401
 Chorditis nodosa, 430, 440
 etiology of, 440
 examination of, 440
 pathology of, 440
 prognosis of, 441
 symptoms of, 440
 treatment of, 441 (6, 9, 20,
 21, 23, 27, 28, 40, 41)
 Chorea, laryngeal, 515. *See*
 Spasmodic laryngeal cough
 Chronic acid cauterization,
 method of employing, 94
 Cleansing larynx, method of, 70
 mouth, method of, 70
 nasopharynx, method of, 70
 nose, method of, 70
 solution, alkaline, 90
 for larynx, 567
 for nose and pharynx, 553
 Clergyman's sore-throat, 287.
 See Pharyngitis, granular,
 chronic
 Coakley's lamp and stand, 40
 Cocaine spray for diagnostic
 purposes, 49
 Cords, vocal, anatomy of, 30
 nodes on, 430, 440. *See*
 Chorditis nodosa
 normal appearance of, 65
 trachoma of, 430, 440.
 See Chorditis nodosa
 Cough, spasmodic laryngeal,
 515. *See* Spasmodic laryn-
 geal cough
 Crico-arytenoideus posticus, ac-
 tion of, 31
 Croup, false, 511
 Cyst of antrum of Highmore,
 230. *See* Antrum of High-
 more, cyst of
 of frontal sinus, 244. *See*
 Sinus, frontal, cysts of
 of larynx, 497
 of maxillary sinus, 230
 of middle turbinate, 248.
 See Middle turbinate, cysts
 of

Cyst of tonsil, 328. *See* Tonsil, cyst of
 Cysts, dentigerous, of antrum, 231
 dermoid, of pharynx, 401

D.

DEFORMITIES of septum, 126
 of uvula, 302
 Dentigerous cysts of antrum, 231
 Deodorant solutions for larynx, 568
 for nose, 555
 for pharynx, 555
 Depressors of tongue, 50
 Dermoid cysts of pharynx, 401
 Diphtheria, 336
 differential diagnosis of, 346
 etiology of, 336
 examination of laryngeal type, 345
 of nasal type, 343
 of pharyngeal type, 342
 exudation in, situations of, 340
 incubation period of, 338
 pathology of, 339
 prognosis of, 347
 sequelæ of, 345
 symptoms of, 341
 laryngeal type, 344
 nasal type, 343
 pharyngeal type, 341
 treatment of, 349
 constitutional, 351
 hygienic, 350
 local, 353 (1, 6, 16, 43, 44, 48, 59, 60)
 laryngeal type, 355. *See* also Intubation
 nasal type, 354
 pharyngeal type, 353
 prophylactic, 349
 Dobell's solution, 69
 Douche, nasal, 111
 method of using, 111
 precautionary measures in using, 113

E.

EDEMA of glottis, 425. *See* Larynx, edema of
 of larynx, 425. *See* Larynx, edema of
 in measles, 540
 in scarlet fever, 538
 in smallpox, 542
 Electrode for tonsil, 325
 Empyema of antrum of Highmore, 198, 222. *See* Antrum of Highmore, empyema of
 of frontal sinus, 198, 234. *See* Sinus, frontal, empyema of
 Epiglottis, anatomy of, 29
 function of, 38
 normal appearance of, 66
 Epilepsy, laryngeal, 516. *See* Laryngeal vertigo
 Epistaxis, 194. *See* Nose, hemorrhage from
 in pertussis, 541
 in typhoid fever, 543
 Erysipelas, 547
 of larynx, 549
 prognosis of, 549
 symptoms of, 549
 treatment of, 549
 of nose, 547
 accessory sinus inflammation in, 547
 examination of, 547
 prognosis of, 548
 treatment of, 548
 of pharynx, 548
 examination of, 548
 otitis media in, 548
 symptoms of, 548
 treatment of, 548
 Ethmoidal cells, anterior, anatomy of, 25
 openings of, 25
 posterior, anatomy of, 25
 openings of, 25
 suppuration of, acute, 198
 diagnosis of, 214
 etiology of, 198
 examination of, 204

- Ethmoidal cells, suppuration of,
 acute, examination
 of, transillumination
 in, 205
 pathology of, 199
 prognosis of, 215
 symptoms of, 201
 pain, 201, 202
 temperature, 204
 treatment, 215
 constitutional, 215
 local, 221
 chronic, 244
 differential diagnosis
 of, 245
 etiology of, 244
 examination of, 245
 prognosis of, 246
 symptoms of, 245
 treatment of, 246 (1,
 2, 4, 6, 16, 21, 22)
 Ethmoiditis, 198, 244. *See* Eth-
 moidal cells, suppuration
 of
 external radical operation,
 247
 intranasal operation, 246
 Eustachian tube, functions of,
 35
 posterior rhinoscopic ap-
 pearance of, 59
 Examination of hard palate, 61
 of laryngopharynx, position
 of head in, 61
 of mirror in, 62
 of larynx, 62
 during phonation, 64
 position of head in, 63
 of mouth, 60
 of posterior nares, 56
 pharyngeal wall, 60
 of soft palate, 60
 of teeth, 60
 of tongue, 60
 of upper respiratory tract,
 39
 order of making, 68
 of uvula, 60
 Extirpation of larynx, voice
 after, 38
 Extubation, method of, 366
- F.**
- FALSE croup, 511
 Fauces, anatomy of anterior
 pillar, 27
 of posterior pillar, 27
 Fibroid tumors of nasopharynx,
 275. *See* Nasopharynx, fibroid
 tumors of
 Fibromata of larynx, 497
 of nose, 185. *See* Nose, fibro-
 mata of
 of pharynx, 401
 Foreign bodies in larynx, 453.
See Larynx, foreign
 bodies in
 in nasopharynx, 270. *See*
 Nasopharynx, foreign
 bodies in
 in nose, 167. *See* Nose,
 foreign bodies in
 in pharynx, 396. *See* Phar-
 ynx, foreign bodies in
 Fossa, glosso-epiglottic, 29
 pyriform, normal appearance
 of, 67
 Rosenmüller's, anatomy of, 26
 posterior, rhinoscopic ap-
 pearance of, 59
 Fourth turbinate, anatomy of,
 20
 Frontal sinus, absence of, 25
 anatomy of, 24
 cysts of, 244. *See* Sinus,
 frontal, cysts of
 empyema of, 234. *See*
 Sinus, frontal, empyema
 of
 Killian operation for, 242
 malignant disease of, 244.
See Sinus, frontal, ma-
 lignant disease of
 obliteration of, 242
 deformity after, 243
 openings of, 25
 osteomata of, 243. *See*
 Sinus, frontal, osteomata
 of
 polypi of, 235
 radical operation for cure
 of, 242

Frontal sinus, suppuration of,
acute, 198. *See* Sinus,
frontal, suppuration of,
acute
transillumination of, 206
x-rays in, 206

G.

GALVANO-CAUTERIZATION,
method of, 93
Galvano-cautery snare in hyper-
trophic rhinitis, 102
in hypertrophic tonsillitis,
324
German measles, 540. *See*
Rötheln
Glanders, 544
buccal condition in, 545
nasal condition in, 544
prognosis of, 545
treatment of, 545
Globus hystericus, 407
Glosso-epiglottic fossa, 29
Glottis, action of, during expira-
tion, 37
during inspiration, 37
definition of, 30
edema of, 425. *See* Larynx,
edema of
Granular pharyngitis, chronic,
287. *See* Pharyngitis, gran-
ular, chronic
Gumma of larynx, 482
of nasopharynx, 269
of nose, 161
of pharynx, 376

H.

HARD palate, examination of,
61
Hay fever, 115. *See* Rhinitis,
vasomotor
Head, position of, for examining
larynx, 63
when using nasal speculum,
47

Hematoma of septum, 146. *See*
Septum, hematoma of
Hemorrhage from nose, 194. *See*
Nose, hemorrhage from
laryngeal, 423. *See* Laryn-
geal hemorrhage
in malaria, 544
nasal, control of, by Bernay's
sponges, 100
by gauze packing, 101
by hot water, 100
by hydrogen peroxide,
100
by plugging posterior
nares, 103
by suprarenal extract,
100
by tannic-acid solution,
103
Highmore, antrum of, anatomy
of, 24
Hydrogen peroxide for control-
ling epistaxis, 100
Hyperesthesia of larynx, 534
of pharynx, 409
Hyperosmia, 193. *See* Nose,
smell, increase in sense of
Hypertrophic laryngitis, chrcn-
ic, 430. *See* Laryngitis, hy-
pertrophic, chronic
nasopharyngitis, 253. *See*
Nasopharyngitis, hypertro-
phic
pharyngitis, chronic, 284.
(*See* Pharyngitis, hyper-
trophic, chronic
rhinitis, 84. *See* Rhinitis,
hypertrophic
hemorrhage in, control of,
100, 101, 102, 103
use of snare in, 96, 97, 98,
99, 102, 105
Hypertrophy of inferior turbi-
nate, posterior end of, 87
of lingual tonsil, 333
of lymphoid tissue of naso-
pharynx, 258. *See* Ade-
noids
of nasopharyngeal mucous
membrane, 253. *See* Naso-
pharyngitis, hypertrophic

I.

- ILLUMINATION, artificial, source
of, 39
of upper respiratory tract,
difficulties of, 43
technique of, 42
- Image, laryngeal, inversion of,
in mirror, 64, 65
in mirror, 63-66
of posterior nares, 57, 58, 59
- Infectious diseases, affections of
upper respiratory tract
in, 536
care of instruments in, 71
- Inferior meatus of nose, 22
turbinate, anatomy of, 20
hypertrophy of posterior
end of, 87, 88, 102
removal of, 102
treatment of, 102
- Influenza, 545
accessory sinus involvement
in, 546
laryngeal condition in, 546
nasal condition in, 546
otitis media in, 546
pharyngeal condition in, 546
treatment of, 546
- Inhalations, dry, 563
steam, 570
- Instruments, care of, in infec-
tious cases, 71
sterilization of, 71
- Interarytenoid space, normal
appearance of, 67
- Intubation, 356
diet after, 365
indications for, 361
instruments for, 357
method of performing, 361
tube, length of time to be
worn, 365
removal of, method of, 366

L.

- LA GRIPPE, 545. *See* Influenza
- Laryngeal chorea, 515. *See* Spas-
modic laryngeal cough
- epilepsy, 516. *See* Laryngeal
vertigo

- Laryngeal hemorrhage, 423
etiology of, 423
examination of, 424
prognosis of, 424
symptoms of, 423
treatment of, 424
- image, inversion of, in mirror,
64, 65
description of, 63-66
- mirrors, 55
- nerve, recurrent, 32
superior, 32
- vertigo, 516
etiology of, 516
examination of, 516
prognosis of, 517
symptoms of, 516
treatment of, 517
- Laryngismus stridulus, 511
- Laryngitis, acute, 411
in adults, 411
differential diagnosis of,
414
etiology of, 411
examination of, 414
pathology of, 413
prognosis of, 415
symptoms of, 413
treatment of, 415
constitutional, 415
local, 417 (17, 18, 19,
20, 21, 23, 73, 74)
- in children, 418
differential diagnosis of,
419
etiology of, 418
examination of, 419
pathology of, 418
prognosis of, 420
symptoms of, 418
treatment of, 420 (20,
21, 73, 74)
- atrophic, chronic, 444
etiology of, 442
examination of, 443
pathology of, 442
prognosis of, 443
symptoms of, 443
treatment of, 443 (1, 2,
24, 25, 71, 72, 75, 77)
- hypertrophic, chronic, 430

- Laryngitis, hypertrophic, diffuse, 430
 differential diagnosis of, 433
 etiology of, 430
 examination of, 432
 pathology of, 431
 prognosis of, 434
 symptoms of, 432
 treatment of, 434
 climatic, 436
 constitutional, 434
 local, 435 (1, 2, 6, 8, 10, 20, 21, 23, 27, 28, 71, 77)
 membranous, 421
 differential diagnosis of, 422
 etiology of, 421
 examination of, 422
 pathology of, 421
 prognosis of, 422
 symptoms of, 421
 treatment of, 422 (17, 18, 19, 20, 21, 23, 73, 74)
 sicca, 442
 subglottic, chronic, 430, 436
 differential diagnosis of, 437
 etiology of, 436
 examination of, 437
 prognosis of, 438
 symptoms of, 436
 treatment of, 438 (1, 2, 6, 8, 10, 20, 21, 23, 27, 28, 71, 77)
 Laryngopharynx, anatomy of, 28
 examination of, position of
 head in, 62
 of mirror in, 62
 Laryngoscopy, direct, 502
 Larynx, abscess of, 452
 diagnosis of, 453
 etiology of, 452
 examination of, 453
 symptoms of, 452
 treatment of, 453 (1, 2, 24, 25, 40, 41, 71, 72, 81, 83)
 adenomata of, 499
 anatomy of, 29
 Larynx, anesthesia of, 534
 angiomata of, 498
 chondromata of, 499
 condition of, in influenza, 546
 in measles, 540
 in pertussis, 541
 in Rötheln, 541
 in scarlet fever, 537
 in smallpox, 542
 in typhoid fever, 543
 cysts of, 497
 diseases of, 411
 edema of, 425
 differential diagnosis of, 427
 etiology of, 425
 examination of, 426
 in smallpox, 542
 pathology of, 426
 prognosis of, 427
 symptoms of, 426
 treatment of, 427 (20, 21, 23, 74, 75)
 effect of mouth-breathing on, 36
 erysipelas of, 549
 prognosis of, 549
 symptoms of, 549
 treatment of, 549
 examination of, 63
 difficulties in, 63, 64
 during phonation, 64
 position of head in, 63
 fibromata of, 497
 foreign bodies in, 453
 etiology of, 453
 examination of, 455
 symptoms of, 455
 treatment of, 455
 by direct laryngoscopy, 457
 gumma of, 482
 hyperesthesia of, 534
 image of, in mirror, 64, 66
 lipomata of, 498
 lupus of, 475
 differential diagnosis of, 477
 etiology of, 475
 examination of, 476
 pathology of, 476

- Larynx, lupus of, prognosis of, 477
 symptoms of, 476
 treatment of, 477
 constitutional, 477
 local, 477 (3, 4, 24, 25, 40, 41, 76)
 malignant growths of, 505
 differential diagnosis of, 508
 etiology of, 505
 examination of, 507
 pathology of, 506
 prognosis of, 508
 symptoms of, 506
 treatment of, 509 (3, 4, 24, 25, 40, 41, 72, 76, 79, 80, 81, 82, 83)
 method of cleansing, 70
 mucous membrane of, 31
 normal appearance of, 66
 patches of, 79
 muscles of, 30
 nerves of, 32
 neuroses of, 511
 motor, 511
 inco-ordination, 516
 laryngeal vertigo, 516
 etiology of, 516
 examination of, 516
 prognosis of, 517
 symptoms of, 516
 treatment of, 517
 paralyses, 511, 517
 abductor, bilateral, 524
 differential diagnosis of, 525
 etiology of, 524
 examination of, 524
 prognosis of, 525
 symptoms of, 524
 treatment of, 526
 unilateral, 517
 differential diagnosis of, 518
 etiology of, 517
 examination of, 518
 prognosis of, 519
 symptoms of, 518
- Larynx, neuroses of, motor paralyses, abductor, unilateral, treatment of, 519
 adductor, bilateral, 526
 differential diagnosis of, 528
 etiology of, 526
 examination of, 527
 prognosis of, 528
 symptoms of, 527
 treatment of, 528
 unilateral, 520
 examination of, 520
 symptoms of, 520
 treatment of, 520
 arytenoideus, 520
 etiology of, 520
 examination of, 521
 symptoms of, 521
 treatment of, 521
 external tensor, bilateral, 529
 etiology of, 529
 examination of, 530
 symptoms of, 530
 treatment of, 530
 unilateral, 523
 etiology of, 523
 examination of, 523
 symptoms of, 523
 treatment of, 523
 internal tensor, bilateral, 529
 etiology of, 529
 examination of, 529
 treatment of, 529
 unilateral, 522
 etiology of, 522

- Larynx, neuroses of, motor pa-
ralyses, in-
ternal tensor,
unilateral, ex-
amination of,
522
symptoms of,
522
treatment of,
522
recurrent, complete,
530
differential diag-
nosis of, 533
etiology of, 530
examination of,
532
prognosis of, 533
symptoms of, 531
treatment of, 533
spasms, 511
adductor, 511
differential diagno-
sis of, 513
etiology of, 511
examination of, 513
prognosis of, 513
symptoms of, 512
treatment of, 513
spasmodic laryngeal
cough, 515
etiology of, 515
examination of,
516
symptoms of,
515
treatment of,
516
tensors of vocal cords,
514
etiology of, 514
examination of,
515
symptoms of,
515
treatment of,
515
sensory, 533
anesthesia, 534
etiology of, 534
symptoms of, 534
- Larynx, neuroses of, sensory,
anesthesia, treatment
of, 534
hyperesthesia, 534
etiology of, 534
symptoms of, 535
treatment of, 535
paresthesia, 535
etiology of, 535
treatment of, 535
non-malignant growths of,
495
differential diagnosis of,
500
etiology of, 495
examination of, 500
pathology of, 496
adenomata, 499
angiomata, 498
chondromata, 499
cysts, 497
fibromata, 497
lipomata, 498
papillomata, 496
polypi, 498
prognosis of, 501
symptoms of, 499
treatment of, 501
extralaryngeal, 502, 505
intralaryngeal, 502
pachydermia of, 447
differential diagnosis of,
447
etiology of, 447
examination of, 447
prognosis of, 448
symptoms of, 447
treatment of, 448 (6, 9, 20,
21, 23, 27, 28, 40, 41)
papillomata of, 496
paralysis of, abductor, bilat-
eral, 524
unilateral, 517
adductor, bilateral, 526
unilateral, 520
arytenoideus, 520
external tensor, bilateral,
529
unilateral, 523
internal tensor, bilateral,
529

- Larynx, paralysis of, internal
 tensor, unilateral, 522
 recurrent nerve, complete,
 530
 paresthesia of, 535
 perichondritis of, 448
 differential diagnosis of,
 450
 etiology of, 448
 examination of, 450
 pathology of, 449
 prognosis of, 451
 symptoms of, 449
 treatment of, 452 (1, 2, 24,
 25, 40, 41, 71, 72, 81, 83)
 physiology of, 37
 polypi of, 498
 rhinoscleroma of, 437
 stenosis of, 490
 etiology of, 490
 examination of, 492
 pathology of, 491
 prognosis of, 492
 symptoms of, 491
 treatment of, 492
 subglottic region of, 30
 submucous tissue of, 31
 supraglottic region of, 30
 syphilis of, 478
 acquired, 478
 primary (chancre), 478
 situation, 478
 treatment, 478
 secondary, 479
 differential diagnosis
 of, 480
 etiology of, 479
 examination of, 480
 pathology of, 479
 prognosis of, 483
 symptoms of, 480
 treatment of, 481
 constitutional, 481
 local, 482 (3, 4, 24,
 25, 40, 41, 77, 78,
 79)
 tertiary, 482
 gumma, 482
 differential diagno-
 sis of, 483
 examination of, 483
- Larynx, syphilis of, acquired
 tertiary, gumma,
 pathology of, 482
 prognosis of, 484
 symptoms of, 483
 treatment of, 484
 ulcer, 484
 differential diagno-
 sis of, 486
 examination of, 486
 pathology of, 484
 prognosis of, 487
 symptoms of, 485
 treatment of, 487
 constitutional, 487
 local, 487 (3, 4, 6,
 9, 24, 25, 40,
 41, 72, 75, 77,
 78, 79, 80, 81,
 82, 83)
 inherited, 488
 examination of, 489
 pathology of, 488
 prognosis of, 489
 symptoms of, 488
 treatment of, 489
 tuberculosis of, 457
 changes in voice in, causes
 of, 461
 differential diagnosis of,
 466
 etiology of, 457
 examination of, 463
 pathology of, 460
 prognosis of, 468
 symptoms of, 461
 treatment of, 469
 constitutional, 470
 dietetic, 470, 475
 hygienic, 470
 local, 472
 stage of tubercle, 472
 of ulcer, 473 (3, 4,
 24, 25, 71, 76, 80,
 81, 82, 83)
 ulcers of, in smallpox, 542
 ventricle of, 32
 normal appearance of, 67
 prolapse of, 444
 differential diagnosis of,
 446

- Larynx, ventricle of, prolapse of, etiology of, 444
 examination of, 445
 prognosis of, 446
 symptoms of, 444
 treatment of, 446 (6, 9, 23, 40, 41, 77)
 ventricular band of, 32
 Light, relation of, to patient and examiner, 42
 Lingual tonsil, hypertrophy of, 333
 position of, 28
 varix, 330
 etiology of, 330
 examination of, 331
 symptoms of, 331
 treatment of, 331
 Lipomata of larynx, 498
 Lips, actinomycosis of, 549
 Lupus of larynx, 475. *See* Larynx, lupus of
 of pharynx, 392. *See* Pharynx, lupus of
 Luschka's tonsil, 26
 Lymphatics of nasopharynx, 26
 Lymphoid hypertrophy in malaria, 544
 tissue of nasopharynx, appearance of, in rhinoscopic mirror, 60
 hypertrophy of, 258. *See* Adenoids
 of oropharynx, 27
 of tongue, 28
 Lymphomata of nose, 186. *See* Nose, lymphomata of
- M.**
- MALARIA, 544
 hemorrhages in, 544
 lymphoid hypertrophy in, 544
 neuroses in, 544
 spasmodic coughing in, 544
 Malignant growths of antrum of Highmore, 233. *See* Antrum of Highmore, malignant disease of
 Malignant growths of frontal sinus, 244. *See* Sinus, frontal, malignant disease of
 larynx, 505. *See* Larynx, malignant growths of
 of nasopharynx, 278. *See* Nasopharynx, malignant growths of
 of nose, 188. *See* Nose, malignant growths of
 of pharynx and tonsil, 403. *See* Pharynx, malignant growths of; and Tonsils, malignant growths of
 Maxillary antrum, anatomy of, 24
 mucous membrane of, 24
 opening of, normal, 24
 thinnest parts of, 24
 sinus, diseases of, 198, 222. *See* Sinuses, accessory, of nose, acute suppurative inflammation of; and Sinus, maxillary, chronic diseases of
 Measles, 539
 accessory sinus involvement in, 539
 adenoids in, 540
 edema of larynx in, 540
 epistaxis in, 539
 German, 540. *See* Rötheln
 Koplik spots in, 539
 laryngeal condition in, 540
 nasal condition in, 539
 nose, ulceration of, in, 539
 otitis media in, 540
 pharyngeal condition in, 539
 tonsillitis in, 540
 treatment of, 540
 Meatus, inferior, of nose, 22
 middle, of nose, 22
 superior, of nose, 22
 Membranous laryngitis, 421. *See* Laryngitis, membranous
 rhinitis, 122. *See* Rhinitis, membranous
 Middle meatus of nose, 22
 turbinate, anatomy of, 20

- Middle turbinate, cysts of, 248
 differential diagnosis of, 249
 etiology of, 248
 examination of, 249
 pathology of, 248
 symptoms of, 248
 treatment of, 249 (1, 2, 4, 12, 13)
 dangers of cauterization of, 105
 removal of, in suppurative inflammation of frontal sinus, 220
- Mirrors, laryngeal, 55
 post-nasal, 56
 warming of, 54
- Morgagni, ventricle of, 32
- Mouth, examination of, 60
 method of cleansing, 70
 mucous patches of, 376
 syphilis of, 372. *See* Syphilis of mouth
- Mouth-breathing, effects of, 36, 75
- Mucous membrane of larynx, normal appearance of, 66
 patches of larynx, 479
 of mouth, 376
 of nose, 159
 of pharynx, 376
- Muscles of larynx, 30
- Mycosis of pharynx, 394. *See* Pharynx, mycosis of
- N.**
- NARES, posterior, examination of, 56
 image of, 57, 58, 59
 plugging, dangers of, 104
 method of, 103
- Nasal applicator, winding cotton on, 48
 calculi, 170. *See* Rhinoliths cavity, plugging, dangers of, 102
 douche, 111
 method of using, 111
 precautionary measures, 112
- Nasal obstruction, 73
 effect of, on hearing, 35
 on voice, 36
 etiology of, 73
 examination of, 77
 symptoms of, 74
 aprosexia, 76
 ear, 76
 eye, 76
 face, shape of, 76
 mouth-breathing, effects of, 75
 nasal, 74
 reflex neuroses, 76
 voice, 75
 treatment of, 77
- polypi, 174. *See* Nose, polypi in
- probe, use of, 48
- speculum, holding of, 45, 46, 47
 position of head when using, 47
- Nasopharyngitis, acute, 252
 etiology of, 252
 pathology of, 252
 prognosis of, 253
 symptoms of, 252
 treatment of, 253 (20, 21, 24, 44, 56, 57)
- atrophic, 256
 differential diagnosis of, 257
 etiology of, 256
 examination of, 257
 pathology of, 256
 prognosis of, 257
 symptoms of, 256
 treatment of, 258 (1, 2, 5, 14, 15, 22, 27-30, 35, 37)
- hypertrophic, 253
 etiology of, 253
 examination of, 254
 pathology of, 253
 prognosis of, 254
 symptoms of, 254
 treatment of, 254 (1, 2, 5, 6, 12, 13, 21, 24, 25, 27-30, 31, 33)
- sicca, 256. *See* Naso-pharyngitis, atrophic

- Nasopharynx, anatomy of, 26
 diseases of, 252
 examination of, by finger,
 method of, 262
 fibroid tumors of, 275
 differential diagnosis of,
 276
 etiology of, 275
 examination of, 276
 pathology of, 275
 prognosis of, 277
 symptoms of, 276
 treatment of, 277
 foreign bodies in, 270
 etiology of, 270
 examination of, 271
 symptoms of, 271
 treatment of, 271
 gumma of, 269
 hypertrophy of lymphoid tis-
 sue of, 258. *See* Adenoids
 lymphatics of, 26
 lymphoid tissue of, appear-
 ance of, in rhinoscopic
 mirror, 60
 hypertrophy of, 258. *See*
 Adenoids
 malignant growths of, 278
 examination of, 278
 prognosis of, 279
 symptoms of, 278
 treatment of, 279 (1, 2,
 4, 6, 16, 25, 26, 41,
 42)
 method of cleansing, 70
 non-malignant growths of,
 271
 polypi of, 271
 differential diagnosis of,
 273
 etiology of, 271
 examination of, 273
 pathology of, 272
 prognosis of, 274
 symptoms of, 272
 treatment of, 274
 after operation, 275 (1,
 2, 6, 12, 13)
 syphilis of, 269
 examination of, 270
 symptoms of, 269
- Nasopharynx, syphilis of, treat-
 ment of, 270
 constitutional, 270
 local, 270 (1, 2, 4, 6, 7,
 10, 16, 39, 40, 41, 49-
 55)
 vault of, appearance of, in
 rhinoscopic mirror, 59
 Nerves of larynx, 32
 Neuroses of larynx, 511
 in malaria, 544
 motor, 511
 paralysis, 517
 spasms, 511
 sensory, 533
 anesthesia, 534
 hyperesthesia, 534
 paresthesia, 535
 of pharynx, 406
 motor, 406
 paralysis, 408
 spasms, 406
 sensory, 409
 anesthesia, 409
 hyperesthesia, 409
 paresthesia, 409
 Nodes on vocal cords, 430, 440.
See Chorditis nodosa
 Non-malignant growths of the
 larynx, 495. *See* Larynx,
 non-malignant growths
 of
 of nasopharynx, 271
 of nose, 174
 of pharynx, 399. *See*
 Pharynx, non-malignant
 growths of
 Normal saline tablet, 68
 tonsils, 28
 Nose, accessory sinuses of, 23
 affections of, in scarlet
 fever, 536
 diseases of, 198
 adenomata of, 186
 etiology of, 186
 examination of, 186
 pathology of, 186
 prognosis of, 187
 symptoms of, 186
 treatment of, 187
 adhesions in, 95. *See* Synechia

- Nose, anatomy of, 17
 of cartilages of, 17
 of inner wall of, 19
 of outer wall of, 19
 of septum of, 19
 angiomata of, 187
 pathology of, 187
 symptoms of, 187
 treatment of, 187
 auditory function of, 35
 blood-supply of, arterial, 22
 venous, 23
 calculi in, 170. *See* Rhinoliths
 chancre of, 157. *See* Nose,
 syphilis of, primary
 condition of, in influenza, 546
 in measles, 539
 in pertussis, 541
 in R  theln, 540
 in scarlet fever, 536
 in smallpox, 542
 in typhoid fever, 543
 daily excretion of water from,
 34
 deformity of, in abscess of
 septum, 149
 in hematoma of septum,
 147
 in perforation of septum,
 151
 dimensions of interior, 20
 direct inspection of, 43
 direction of current of air in,
 34
 diseases of, 78
 erysipelas of, 547
 fibromata of, 185
 etiology of, 185
 examination of, 185
 pathology of, 185
 prognosis of, 186
 symptoms of, 185
 treatment of, 186
 foreign bodies in, 167
 differential diagnosis of,
 169
 etiology of, 167
 examination of, 168
 pathology of, 167
 symptoms of, 168
 treatment of, 169
- Nose, glanders of, 544
 gumma of, 161
 hemorrhage from, 194
 etiology of, 194
 examination of, 196
 prognosis of, 196
 symptoms of, 195
 treatment of, 196
 constitutional, 197
 local, 196 (40, 41, 42)
 inferior meatus of, 22
 lymphatics of, 23
 lymphomata of, 186
 symptoms of, 186
 treatment of, 186
 malignant growths of, 188
 differential diagnosis of,
 189
 etiology of, 188
 examination of, 188
 prognosis of, 190
 symptoms of, 188
 treatment of, 191 (1, 3,
 4, 6, 16, 24, 25, 31, 32,
 41, 42, 44, 48, 49-53,
 55)
 method of cleansing, 70
 middle meatus of, 22
 mucous membrane, patches
 on, 159
 structure of, 21
 non-malignant growths in, 174
 olfactory function of, 35
 region of, 21
 osteomata of, 187
 pathology of, 187
 symptoms of, 187
 treatment of, 187
 papillomata of, 184
 etiology of, 184
 examination of, 184
 pathology of, 184
 prognosis of, 185
 symptoms of, 184
 treatment of, 185 (1, 2, 5)
 physiology of, 33
 pigment of, 22
 plugging of, dangers of, 102
 polypi in, 174
 differential diagnosis of,
 178

- Nose, polypi in, etiology of, 174
 examination of, 177
 pathology of, 176
 prognosis of, 179
 symptoms of, 177
 treatment of, 180 (1, 2, 5)
 respiratory functions of, 33
 region of, 22
 rhinoscleroma of, 172
 differential diagnosis of, 173
 etiology of, 172
 examination of, 173
 pathology of, 172
 prognosis of, 173
 symptoms of, 172
 treatment of, 174
 smell, increase in sense of, 193
 etiology of, 193
 treatment of, 193
 loss of sense of, 191
 etiology of, 191
 examination of, 192
 prognosis of, 193
 symptoms of, 192
 treatment of, 193
 perversion of sense of, 193
 etiology of, 193
 symptoms of, 193
 treatment of, 194
 superior meatus of, 22
 synechia in, prevention of, 95
 syphilis of, 156
 acquired, 157
 primary, 157
 secondary, 159
 tertiary, 161
 congenital, 164
 secondary, 165
 differential diagnosis of, 166
 etiology of, 165
 examination of, 165
 pathology of, 165
 prognosis of, 166
 symptoms of, 165
 treatment of, 166
 constitutional, 166
 local, 166 (4, 5, 12, 25)
- Nose, syphilis of, congenital, tertiary, 167
 inherited, 164. *See* Nose, syphilis of, congenital
 primary, 157
 differential diagnosis of, 157
 etiology of, 157
 prognosis of, 158
 symptoms of, 157
 treatment of, 158
 constitutional, 158
 local, 158 (1, 2, 12, 17, 38, 48)
 secondary, acquired, 159
 differential diagnosis of, 160
 etiology of, 159
 examination of, 160
 pathology of, 159
 prognosis of, 160
 symptoms of, 160
 treatment of, 161
 constitutional, 161
 local, 161 (1, 2, 6, 12, 13, 24, 25)
 tertiary, acquired, 161
 differential diagnosis of, 163
 etiology of, 161
 examination of, 162
 pathology of, 162
 prognosis of, 163
 symptoms of, 162
 treatment of, 164
 constitutional, 164
 local, 164 (4, 5, 12, 13, 16, 24, 25, 39, 40, 55)
 syphilitic erythema of, 159
 ulcer of, 161
 tuberculosis of, 153
 differential diagnosis of, 155
 etiology of, 153
 examination of, 155
 pathology of, 154
 prognosis of, 156
 symptoms of, 154
 treatment of, 156
 constitutional, 156

Nose, tuberculosis of, treatment
 of, local, 156 (1, 2, 4, 16,
 23, 24, 25, 31, 32, 33, 39,
 40, 41, 47, 50, 52, 55)
 ulcer of, syphilitic, 161
 tubercular, 154
 in typhoid fever, 543
 venous channels of, 23
 vestibule of, 20
 vocal function of, 36
 Nose-bleed, 194. *See* Nose,
 hemorrhage from

O.

OBSTRUCTION, nasal, 73
 etiology of, 73
 examination of, 77
 symptoms of, 74
 aprosexia, 76
 ear, 76
 eye, 76
 face, shape of, 76
 mouth-breathing, effects
 of, 75
 nasal, 74
 reflex neuroses, 76
 voice, 75
 treatment of, 77
 Ointments for nose and
 pharynx, 561
 Oleo-stearate of zinc, 558
 Olfactory function of nose, 35
 Operations, antiseptics in, 69
 antrum of Highmore, punc-
 ture of, 210, 224
 cauterization, chromic acid,
 of nose, 94
 galvano-, of nose, 93
 trichloroacetic acid, of nose,
 93
 for nasal polypi by cau-
 terants, 182
 by cold wire snare, 180
 by curetting, 182
 Oropharynx, anatomy of, 26
 lymphoid tissue of, 27
 Osteomata of antrum of High-
 more, 232.
 of frontal sinus, 243.
 of nose, 187.

Osteomata of pharynx, 402
 Otitis media in erysipelas, 548
 in influenza, 546

P.

PACHYDERMIA laryngis, 447
 Palate, soft, anatomy of, 27
 Papillomata of larynx, 496
 of nose, 184.
 of pharynx, 400
 Paresthesia of larynx, 535
 of pharynx, 409
 Parosmia, 193. *See* Nose,
 smell, perversion of sense of
 Perforation of septum, 150.
See Septum, perforation of
 Perichondritis of larynx, 448.
See Larynx, perichondritis of
 Peritonsillar abscess, 309
 differential diagnosis of,
 312
 etiology of, 309
 examination of, 311
 pathology of, 309
 prognosis of, 312
 symptoms of, 310
 treatment of, 313
 between attacks, 315
 medicinal, 315 (1, 2, 6,
 9, 10, 59-62)
 operative, 313
 Peroxide of hydrogen for con-
 trolling epistaxis, 100
 Pertussis, 541
 adenoids in, 541
 epistaxis in, 541
 granular pharyngitis in, 541
 laryngeal condition in, 541
 nasal condition in, 541
 pharyngeal condition in, 541
 suprarenal extract in, 542
 treatment of, 541
 Pharyngeal bursa, appearance
 of, in mirror, 60
 tonsil, 26
 wall, posterior, examination
 of, 60
 Pharyngitis, acute, 280
 differential diagnosis of, 282
 etiology of, 280

- Pharyngitis, acute, examination of, 282
 prognosis of, 282
 symptoms of, 281
 treatment of, 282
 constitutional, 282
 local, 283 (1, 2, 6, 7, 10, 20, 21, 31, 32, 33, 59, 60, 65)
 atrophic, 292
 differential diagnosis of, 293
 etiology of, 292
 examination of, 293
 pathology of, 292
 prognosis of, 293
 symptoms of, 292
 treatment of, 294 (1, 2, 5, 14, 15, 27-30, 35, 37, 63-70)
 granular, chronic, 287
 etiology of, 287
 examination of, 288
 pathology of, 287
 in pertussis, 541
 prognosis of, 289
 symptoms of, 288
 treatment of, 289
 constitutional, 289
 local, 290 (1, 2, 6, 7, 10, 14, 15, 23, 31, 32, 33, 63, 64, 65)
 hypertrophic, chronic, 284
 differential diagnosis of, 286
 etiology of, 284
 examination of, 285
 pathology of, 285
 prognosis of, 286
 symptoms of, 285
 treatment of, 286
 constitutional, 286
 local, 286 (1, 2, 6, 7, 10, 14, 15, 23, 31, 32, 33, 63, 64, 65)
 hypertrophica lateralis, 288
 examination of, 288
 symptoms of, 288
 treatment of, 289 (1, 2, 6, 7, 10, 14, 15, 23, 31, 32, 33, 63, 64, 65)
 sicca, 292
- Pharyngomycosis, 394
 Pharynx, adenomata of, 401
 anatomy of, 25
 anesthesia of, 409
 angiomata of, 401
 chondromata of, 401
 condition of, in influenza, 546
 in measles, 539
 in pertussis, 541
 in R  theln, 540
 in scarlet fever, 536
 in smallpox, 542
 in typhoid fever, 543
 dermoid cysts of, 401
 effect of mouth-breathing on, 36
 erysipelas of, 548
 examination of, 548
 otitis media in, 548
 symptoms of, 548
 treatment of, 548
 fibromata of, 401
 foreign bodies in, 396
 etiology of, 396
 examination of, 398
 pathology of, 397
 symptoms of, 397
 treatment of, 399
 glanders of, 545
 gumma of, 378
 hyperthesia of, 409
 lupus of, 392
 differential diagnosis of, 393
 etiology of, 392
 pathology of, 392
 symptoms of, 393
 treatment of, 394
 constitutional, 394
 local, 394 (1, 2, 6, 24, 25)
 malignant growths of, 403
 etiology of, 403
 examination of, 404
 prognosis of, 405
 symptoms of, 403
 treatment of, 405 (1, 2, 4, 6, 7, 9, 10, 16, 24, 25, 26, 41, 42, 49-55, 60, 67, 80, 82, 83)
 varieties of, 403

- Pharynx, mucous patches of, 376
 mycosis of, 394
 etiology of, 394
 examination of, 395
 pathology of, 395
 prognosis of, 396
 symptoms of, 395
 treatment of, 396
 neuroses of, 406
 motor, 406
 paralysis, 408
 etiology of, 408
 symptoms of, 408
 treatment of, 409
 spasms, 406
 etiology of, 407
 symptoms of, 407
 treatment of, 407
 sensory, 409
 anesthesia, 409
 hyperesthesia, 409
 paresthesia, 409
 treatment, 409
 non-malignant growths of, 399
 differential diagnosis of, 402
 examination of, 400
 adenomata, 401
 angiomata, 401
 chondromata, 401
 dermoid cysts, 401
 fibromata, 401
 osteomata, 402
 papillomata, 400
 polypi, 401
 prognosis of, 402
 symptoms of, 400
 treatment of, 402
 varieties of, 400
 osteomata of, 402
 papillomata of, 400
 paralysis of, 408
 paresis of, in typhoid fever, 543
 paresthesia of, 409
 physiology of, 37
 polypi of, 401
 spasm of, 406
 syphilis of, 372
 Pharynx, tuberculosis of, 386
 differential diagnosis of, 389
 etiology of, 386
 examination of, 388
 pathology of, 387
 prognosis of, 390
 symptoms of, 388
 treatment of, 390
 constitutional, 390
 local, 390 (1, 2, 4, 6, 7, 10, 25, 26, 54, 63, 65, 80, 82, 83)
 ulcers of, in chickenpox, 543
 Phonatory spasm, 514
 Plugging of posterior nares, dangers of, 104
 method of, 103
 Pollantin, use of, in hay fever, 119
 Polypi of antrum of Highmore, 229
 of frontal sinus, 235
 of larynx, 498
 nasopharyngeal, 271
 in nose, 174
 of pharynx, 401
 Posterior nares, examination of, 56
 image of, 57, 58, 59
 plugging of, dangers of, 104
 method of, 103
 rhinoscopy, 43, 49
 Post-nasal mirrors, 55, 56
 syringe, method of using, 255
 Powders for larynx, 572
 for nose and pharynx, 562
 Probe, nasal, use of, 48
 Prolapse of ventricle of larynx, 444. *See* Larynx, ventricle, prolapse of
 Purulent rhinitis, 83. *See* Rhinitis, purulent
 Pyriform fossa, normal appearance of, 67
- Q.**
- QUINSY sore throat, 309. *See* Peritonsillar abscess

R.

- RECURRENT laryngeal nerve, 32
 Reflex neuroses in nasal obstruction, 76
 Respiratory functions of nose, 33
 Retropharyngeal abscess, 295
 differential diagnosis of, 297
 etiology of, 295
 examination of, 296
 pathology of, 295
 prognosis of, 297
 symptoms of, 296
 treatment of, 297
 Rhinitis, acute, 78
 complications of, 79
 etiology of, 78
 examination of, 79
 pathology of, 78
 symptoms of, 78
 treatment of, 80
 constitutional, 80
 local, 80 (20, 21, 24, 44, 56, 57)
 prophylactic, 82
 atrophic, 106
 differential diagnosis of, 109
 etiology of, 106
 examination of, 109
 pathology of, 107
 prognosis of, 111
 symptoms of, 107
 treatment of, 111
 constitutional, 115
 local, 111 (1, 2, 4, 5, 14-16)
 ulcerations, 114 (24, 25, 55)
 hypertrophic, 84
 differential diagnosis of, 89
 etiology of, 85
 examination of, 86
 hemorrhage in, control of, 100, 101, 102, 103
 pathology of, 85
 prognosis of, 89
 symptoms of, 85
 Rhinitis, hypertrophic, treatment of, 89
 constitutional, 106
 local, 89 (6-13, 23, 27-34)
 use of snare in, 96, 98, 102, 105
 membranous, 122
 differential diagnosis of, 124
 etiology of, 122
 examination of, 123
 pathology of, 122
 prognosis of, 125
 symptoms of, 123
 treatment of, 125 (1, 2, 4)
 purulent, 83
 differential diagnosis of, 84
 etiology of, 83
 examination of, 83
 pathology of, 83
 prognosis of, 84
 symptoms of, 83
 treatment of, 84 (1, 2, 4, 6, 7, 10)
 vasomotor, 115
 differential diagnosis of, 118
 etiology of, 115
 examination of, 118
 pathology of, 117
 prognosis of, 118
 symptoms of, 117
 treatment of, during
 attack, 119
 constitutional, 121
 hygienic, 119
 local, 120 (3, 22, 24, 25, 27)
 in the interval, 121
 constitutional, 121
 local, 121
 Rhinoliths, 170
 composition of, 170
 differential diagnosis of, 171
 etiology of, 170
 examination of, 171
 prognosis of, 172
 symptoms of, 170
 treatment of, 172 (1, 2, 4)

- Rhinoscleroma of larynx, 437
 of nose, 172
 Rhinoscopy, anterior, 44
 posterior, 43, 49
 Rima glottidis, definition of, 30
 Rings of trachea, normal
 appearance of, in laryngeal
 mirror, 67
 Rose fever, 116
 Rosenmüller's fossa, posterior
 rhinoscopic appearance of, 59
 Rötheln, 540
 laryngeal condition in, 541
 nasal condition in, 540
 pharyngeal condition in, 540
 treatment of, 541
- S.**
- "SADDLE-BACK NOSE," 149, 151
 Saline normal tablet, 69
 Santorini, cartilage of, normal
 appearance of, 67
 position of, 29
 Scarlet fever, 536
 accessory sinus involve-
 ment in, 536
 adenoids in, 537
 bacilli in throat in, 537
 edema of larynx in, 538
 laryngeal condition in, 537
 nasal condition in, 536
 otitis media in, 537
 pharyngeal condition in,
 536
 sequelæ of, 539
 tonsillitis in, 537
 treatment of, 538
 Schroetter's snare, description
 of, 96
 Sedative powders for larynx,
 572
 solutions, oily, for larynx, 569
 for nose, 557
 for pharynx, 557
 tablets, 565
 Septum, abscess of, 148
 differential diagnosis of,
 149
 etiology of, 148
 examination of, 149
 Septum, abscess of, pathology
 of, 148
 prognosis of, 149
 symptoms of, 149
 treatment of, 149 (4, 12, 13)
 deformities of, 126
 etiology, 126
 deflections, 127
 thickenings, 127
 examination, 128
 pathology, 127
 prognosis, 129
 symptoms, 128
 treatment, 129
 hematoma of, 146
 differential diagnosis of,
 147
 etiology of, 146
 examination of, 147
 pathology of, 146
 prognosis of, 147
 symptoms of, 146
 treatment of, 148 (4, 12,
 13)
 perforation of, 150
 differential diagnosis of,
 152
 etiology of, 150
 examination of, 151
 pathology of, 150
 prognosis of, 152
 symptoms of, 151
 treatment of, 152 (1, 5, 13,
 15, 23, 24, 25, 39, 43,
 44, 47, 48)
 submucous, resection of, 129
 Sinus, frontal, absence of, 25
 anatomy of, 24
 chronic diseases of, 234
 cysts of, 244
 symptoms of, 244
 treatment of, 244
 empyema of, 234. *See*
 also Sinus, frontal,
 suppuration of, acute.
 differential diagnosis of,
 238
 etiology of, 234
 examination of, 235
 pathology of, 234
 prognosis of, 238

- Sinus, frontal, empyema of,
 symptoms of, 234
 transillumination of, 206
 treatment of, 239 (1, 2, 4,
 6, 16, 21, 22, 49-55)
 external, operative, 241
 intranasal, 239
 malignant disease of, 244
 symptoms of, 244
 treatment of, 244
 openings of, 25
 osteomata of, 243
 symptoms of, 243
 treatment of, 243
 polypi of, 235
 suppuration of, 234. *See*
 Sinus, frontal, empy-
 ema of
 acute, 198
 diagnosis of, 213
 etiology of, 198
 examination of, 204
 pathology of, 199
 prognosis of, 215
 symptoms of, 201
 treatment of, 215
 constitutional,
 215
 local, 219
 chronic, 234. *See* Sinus,
 frontal, empyema of
 transillumination of, 206,
 208, 235
 maxillary, anatomy of, 24
 cysts of, 230
 chronic diseases of, 222
 empyema of, 222
 malignant growths in, 233
 osteomata of, 232
 polypi of, 229
 sphenoidal, anatomy of, 25
 chronic inflammation of,
 249
 differential diagnosis of,
 250
 etiology of, 249
 examination of, 250
 symptoms of, 249
 treatment of, 250 (1, 2,
 4, 12, 13, 16, 24, 25)
 openings of, 25
- Sinus, sphenoidal, suppurative
 inflammation of, 198
 diagnosis of, 213
 etiology of, 198
 examination of, 204
 pathology of, 199
 prognosis of, 215
 symptoms of, 201
 treatment of, 215
 constitutional, 215
 local, 221
- Sinuses, accessory, of nose,
 acute suppurative
 inflammation of, 198
 diagnosis of, 209
 etiology of, 198
 examination of,
 204
 pathology of, 199
 prognosis of, 215
 symptoms of, 201
 transillumination
 in, 205
 treatment of, 215
 constitutional,
 215
 local, 215
 diseases of, 198
 acute, 198
 chronic, 222
- Sinusitis, acute suppurative,
 198. *See* Sinuses, accessory,
 of nose, acute suppurative
 inflammation of
- Smallpox, 542
 laryngeal condition in, 542
 larynx, edema of, in, 542
 ulceration of, in, 542
 nasal condition in, 542
 otitis media in, 542
 pharynx in, 542
 eruption in, 542
 tonsils in, 542
 treatment of, 542
- Smell, sense of, increase of, 193
 loss of, 191
 perversion of, 193
- Smelling-salts, 563
- Snare, cold wire, hemorrhage
 after, 100

- Snare, galvano-cautery, for excising tonsils, 323
in hypertrophic rhinitis, 102
Schroetter's, description of, 96
use of, in hypertrophic rhinitis, 96, 98, 102, 105
wire, methods of threading, 97, 98
Snaring, post-operative treatment of, 101
Soft palate, anatomy of, 27
examination of, 60
function of, 37
Solution, Dobell's, 69
Solutions, aqueous, for larynx, 567
antiseptic, 567
astringent, 567
cleansing, 567
dedorant, 568
stimulating, 567
for nose and pharynx, 551
method of employing, 551
uses of, 551
antiseptic, 553
astringent, 554
cleansing, 553
deodorant, 555
stimulating, 554
for local application to nose and pharynx, 559
alterative, 559
astringent, 560
caustic, 561
escharotic, 561
stimulant, 560
locally applied on applicator to larynx, 571
alterative, 571
caustic, 571
stimulant, 571
uses of, 571
oily, for larynx, 568
antiseptic, 569
astringent, 569
depletive, 569
Solutions, oily, for larynx, method of using, 568
sedative, 569
stimulating, 569
for nose and pharynx, 555
method of employing, 555
uses of, 555
antiseptic, 558
astringent, 558
depletive, 557
protective, 556
sedative, 557
stimulating, 557
suprarenal extract, method of making, 81
Sore-throat, clergyman's, 287
quinsy, 309
Spasmodic laryngeal cough, 515
etiology of, 515
examination of, 516
symptoms of, 515
treatment of, 516
Speculum, nasal, holding of, 45, 46, 47
position of head when using, 46
Sphenoidal sinus, anatomy of, 25
inflammation of, 198, 249.
See Sinus, sphenoidal,
chronic inflammation of,
and suppurative inflammation of
openings of, 25
Sphenoiditis, external radical operation, 251
intranasal operation, 250
Spray, cocaine, for diagnostic purposes, 49
Spurs of septum, 125. *See Septum,* spurs of
Steam inhalations, 570
Stearate, oleo-, of zinc, 558
Stenosis of larynx, 490. *See Larynx,* stenosis of
Sterilization of instruments, 71
Stimulating solutions, aqueous, for larynx, 567
for nose, 554
for pharynx, 554

- Stimulating solutions, oily, for
 larynx, 568
 for nose, 557
 for pharynx, 557
- Submucous resection of septum,
 129
 complications, 146
 headache after, 146
 incision in, 131
 packing, 143
- Superior laryngeal nerve, 32
 meatus of nose, 22
 turbinate, anatomy of, 20
- Suprarenal extract in pertussis,
 542
 solution of, method of
 making, 81
- Synechia in nose, prevention of,
 95
- Syphilis of larynx, 478. *See*
 Larynx, syphilis of
 of mouth, 372
 acquired form, 372
 primary lesion of, 372
 differential diagnosis
 of, 374
 etiology of, 372
 symptoms of, 373
 on lip, 373
 on tongue, 373
 on tonsil, 373
 treatment of, 375 (1,
 2, 6, 24, 25, 59, 60)
 secondary lesions of, 375
 differential diagnosis
 of, 377
 etiology of, 375
 examination of, 376
 prognosis of, 377
 symptoms of, 375
 treatment of, 378 (1,
 2, 6, 8, 10, 24, 25,
 39, 40, 59, 60)
 tertiary lesions of, 378
 cicatrix, 383
 gumma, 378
 differential diagno-
 sis of, 379
 examination of, 379
 prognosis of, 380
 symptoms of, 378
- Syphilis of mouth, acquired,
 tertiary lesions of,
 treatment of, 380
 ulcer, 380
 differential diagno-
 sis of, 381
 examination of, 380
 prognosis of, 381
 symptoms of, 380
 treatment of, 382
 constitutional, 382
 local, 382 (1, 2, 4,
 6, 7, 16, 24, 25,
 39-41, 49-55,
 59, 60, 65, 67)
 congenital form, 384
 examination of, 385
 prognosis of, 385
 symptoms of, 384
 treatment of, 385
 constitutional, 385
 local, 386 (1, 2, 6, 16,
 43, 44, 48)
 of nasopharynx, 269. *See*
 Nasopharynx, syphilis of
 of nose, 156. *See* Nose, syph-
 ilis of
 congenital, 165. *See* Nose,
 syphilis of, congenital
 tertiary, 167
 inherited, 165
 primary, 157. *See* Nose,
 syphilis of, primary
 secondary, acquired, 159.
See Nose, syphilis of,
 secondary, acquired
 tertiary, acquired, 161.
See Nose, syphilis of,
 tertiary, acquired
 of pharynx, 372
- Syphilitic erythema of nose,
 159
 ulcer of nose, 161
- Syringe, post-nasal, use of,
 255
- T.**
- TABLETS, 564
 antiseptic, 564
 astringent, 564

- Tablets, normal saline, 69
 sedative, 565
 stimulant, 566
- Teeth, examination of, 60
- Thyro-arytenoideus externus,
 action of, 31
- Tongue, actinomycosis of, 549
 condition of, in typhoid fever,
 543
 depressors, 50
 examination of, 60
 lymphoid tissue of, 28
 method of depressing, 53
 of holding, when pro-
 truded, 62
 position of, for examining
 larynx, 62
 varicose veins of, 28, 330
- Tonsillectomy, 326
- Tonsils, actinomycosis of, 549
 anatomy of, 28
 calculus of, 329
 etiology of, 329
 examination of, 330
 symptoms of, 330
 treatment of, 330
 cysts of, 328
 etiology of, 328
 examination of, 328
 symptoms of, 328
 treatment of, 328
 enlargement of, chronic, 315.
 See Tonsillitis, hypertro-
 phic
 enucleation of, 326
 glanders of, 545
 lacunæ of, 28
 bacteria in, 28
 lingual, hypertrophy of, 333
 etiology of, 333
 examination of, 335
 pathology of, 333
 position of, 28
 prognosis of, 335
 symptoms of, 333
 treatment of, 335 (24, 25,
 28, 30, 41)
 Luschka's, 26
 hypertrophy of, 258. *See*
 Adenoids
 malignant growths of, 403
- Tonsils, malignant growths of,
 etiology of, 403
 examination of, 404
 prognosis of, 405
 symptoms of, 403
 treatment of, 405
 normal, 28
 pharyngeal, 26
 third, enlargement of, 258.
 See Adenoids
- Tonsillith, 329. *See* Tonsils, cal-
 culus of
- Tonsillitis, acute, 302
 differential diagnosis of,
 306
 etiology of, 302
 examination of, 305
 pathology of, 303
 prognosis of, 307
 symptoms of, 304
 treatment of, 307
 between attacks, 308
 constitutional, 307
 hygienic, 307
 local, 308 (1, 2, 6, 9, 10,
 59-62)
 hypertrophic, chronic, 315
 differential diagnosis of,
 318
 etiology of, 315
 examination of, 318
 pathology of, 316
 prognosis of, 319
 symptoms of, 317
 treatment of, 320 (6, 7,
 29, 30, 34)
 by galvano-cautery
 electrode, 324
 snare, 323
 by punch-forceps, 326
 by tonsillotome, 321
 hemorrhage after,
 323
 in measles, 540
 in scarlet fever, 537
- Trachea, rings of, normal
 appearance of, in laryngeal
 mirror, 67
- Tracheotomy, 366
 anesthesia in, 369
 complications following, 372

- Tracheotomy, dangers of, 372
 hemorrhage in, 370
 indications for, 367
 instruments for, 368
 operation, 367, 369
 treatment after, 371
 tubes, 368
- Trachoma of vocal cords, 430, 440. *See* Chorditis nodosa
- Transillumination of accessory sinuses of nose, 205
 of antrum of Highmore, 206, 208, 224
 of ethmoidal cells, 205
 of frontal sinus, 206, 208, 235
- Treatment of abductor paralysis of larynx, bilateral, 526
 unilateral, 519
 of abscess of larynx, 453 (1, 2, 24, 25, 40, 41, 71, 72, 81, 83)
 of septum, 149
 of actinomycosis, 550
 of acute laryngitis, 415 (17, 18, 19, 20, 21, 23, 73, 74)
 in children 420 (20, 21, 73, 74)
 nasopharyngitis, 253 (20, 21, 24, 44, 56, 57)
 pharyngitis, 282 (1, 2, 6, 7, 10, 20, 21, 31-33, 59, 60, 65)
 rhinitis, 80 (20, 21, 24, 44, 56, 57)
 suppuration of ethmoidal cells, 215
 of frontal sinus, 215
 suppurative inflammation
 of accessory sinuses
 of nose, 215
 of antrum of Highmore, 215
 of sphenoidal sinus, 215
 tonsillitis, 307 (1, 2, 6, 9, 10, 59-62)
 uvulitis, 300 (6-10, 21, 22, 59, 60, 65)
- Treatment of adductor paralysis of larynx, bilateral, 528
 unilateral, 520
 spasm of larynx, 513
 of tensors of larynx, 515
 of adenoids, 264
 of adenomata of nose, 186
 of anesthesia of larynx, 534
 of angiomata of nose, 187
 of anosmia, 193
 of arytenoideus paralysis of larynx, 521
 of atrophic nasopharyngitis, 258 (1, 2, 5, 14, 15, 22, 27-30, 35, 37)
 pharyngitis, 294 (1, 2, 5, 14, 15, 27-30, 35, 37, 68, 70)
 rhinitis, 111 (1, 2, 4, 5, 14-16)
 of calculus of tonsil, 330
 of chancre of mouth, 375 (1, 2, 6, 24, 25, 56, 60)
 of chorditis nodosa, 441 (6, 9, 20, 21, 23, 27, 28, 40, 41)
 of chronic elongation of uvula, 300
 hypertrophic pharyngitis, 286 (1, 2, 6, 7, 10, 14, 15, 23, 31-33, 63-65)
 tonsillitis, 320 (6, 7, 29, 30, 34)
 laryngitis sicca, 442 (1, 2, 24, 25, 71, 72, 75, 77)
 pharyngitis, 289 (1, 2, 6, 7, 10, 14, 15, 23, 31-33, 63-65)
 subglottic laryngitis, 438 (1, 2, 6, 8, 10, 20, 21, 26, 27, 28, 71, 77)
 suppuration of ethmoidal cells, 246 (1, 2, 4, 6, 16, 21, 22)
 of congenital syphilis of mouth, 385 (1, 2, 6, 16, 43, 44, 48)
 of cyst of antrum of Highmore, 231
 of frontal sinus, 244

- Treatment of cyst of middle turbinate, 249 (1, 2, 4, 12, 13)
 of tonsil, 328
 of diffuse hypertrophic laryngitis, 434 (1, 2, 6, 8, 10, 20, 21, 23, 27, 28, 71, 77)
 of diphtheria, 349 (1, 6, 16, 43, 44, 48, 59, 60)
 of edema of larynx, 427 (20, 21, 23, 74, 75)
 of empyema of antrum of Highmore, 215, 217, 225, 229 (1, 2, 4, 6, 7, 9, 10, 16, 31-33, 40, 41, 49-53, 55)
 of frontal sinus, 215, 239 (1, 2, 4, 6, 16, 21, 22, 49-55)
 of epistaxis, 196 (40, 41, 42)
 of erysipelas of larynx, 549
 of nose, 548
 of pharynx, 548
 of ethmoiditis, 215, 246 (1, 2, 4, 6, 16, 21, 22)
 of external tensor of larynx, paralysis of, bilateral, 530
 unilateral, 523
 of fibroid tumors of nasopharynx, 277
 of fibromata of nose, 186
 of foreign bodies in larynx, 455
 in nasopharynx, 271
 in nose, 169
 in pharynx, 399
 of glanders, 545
 of globus hystericus, 407
 of hematoma of septum, 148
 of hyperesthesia of larynx, 535
 of hyperosmia, 193
 of hypertrophic nasopharyngitis, 254 (1, 2, 5, 6, 12, 13, 21, 24, 25, 27-30, 33)
 rhinitis, 89 (6-13, 23, 27-34)
 tonsillitis, 320 (6, 7, 29, 30, 34)
- Treatment of hypertrophy of lingual tonsil, 335 (24, 25, 28-30, 41)
 of posterior end of inferior turbinate, 102
 of inflammation of sphenoidal sinus, 198, 250 (1, 2, 4, 12, 13, 16, 24, 25)
 of influenza, 546
 of internal tensor of larynx, paralysis of, bilateral, 529
 unilateral, 522
 of laryngeal hemorrhage, 414
 vertigo, 517
 of laryngitis, acute, 415 (17-21, 23, 73, 74)
 in children, 420 (20, 21, 73, 74)
 atrophic, 443 (1, 2, 24, 25, 71, 72, 75, 77)
 chronic subglottic, 438 (1, 2, 6, 8, 10, 20, 21, 23, 28, 71, 77)
 diffuse hypertrophic, 434 (1, 2, 6, 8, 10, 20, 21, 23, 27, 28, 71, 77)
 membranous diphtheritic, 355
 non-diphtheritic, 422 (17-21, 23, 73, 74)
 sicca, 442 (1, 2, 24, 25, 71, 72, 75, 77)
 of lingual varix, 331
 of lupus of larynx, 477 (3, 4, 24, 25, 40, 41, 76)
 of pharynx, 394 (1, 2, 6, 24, 25)
 of lymphomata of nose, 186
 of malignant disease of antrum of Highmore, 234
 of frontal sinus, 244
 of pharynx, 405 (1, 2, 4, 6, 7, 9, 10, 16, 24-26, 41, 42, 49-55, 60, 67, 80, 82, 83)
 of tonsil, 405 (1, 2, 4, 6, 7, 9, 10, 16, 24-26, 41, 42, 49-55, 60, 67, 80, 82, 83)

- Treatment of malignant growths
 of larynx, 509 (3, 4, 24, 25, 40, 41, 72, 76, 79-83)
 of nasopharynx, 279 (1, 2, 4, 6, 16, 25, 26, 41, 42)
 of nose, 191 (1, 3, 4, 6, 16, 24, 25, 31, 32, 41, 42, 44, 48-53, 55)
 of measles, 540
 of membranous laryngitis, 422 (17-21, 23, 73, 74)
 rhinitis, 125 (1, 2, 4)
 of motor paralysis, abductor, bilateral, of larynx, 526
 unilateral, of larynx, 519
 adductor bilateral, of larynx, 528
 unilateral, of larynx, 520
 arytenoideus, of larynx, 521
 external tensor, bilateral, of larynx, 530
 unilateral, of larynx, 523
 internal tensor, bilateral, of larynx, 529
 unilateral, of larynx, 522
 recurrent, complete, 533
 of pharynx, 408
 spasms, adductor, of larynx, 513
 of pharynx, 407
 tensors of vocal cords, 515
 of mycosis of pharynx, 396
 of nasal obstruction, 77
 of nasopharyngeal polypi, 274 (1, 2, 6, 12, 13)
 of nasopharyngitis, atrophic, 258 (1, 2, 5, 14, 15, 22, 27-30, 35, 37)
 hypertrophic, 254 (1, 2, 5, 6, 12, 13, 21, 24, 25, 27-31, 33)
 of non-malignant growths of larynx, 501
 of pharynx, 402
- Treatment of osteomata of antrum of Highmore, 233
 of frontal sinus, 243
 of nose, 187
 of pachydermia of larynx, 448 (6, 7, 20, 21, 23, 27, 28, 40, 41)
 of papillomata of nose, 185 (1, 2, 5)
 of paralysis of pharynx, 409
 of paresthesia of larynx, 535
 of parosmia, 194
 of perforation of septum, 152 (1, 5, 13, 15, 23, 24, 25, 39, 43, 44, 47, 48)
 of perichondritis of larynx, 452 (1, 2, 24, 25, 40, 41, 71, 72, 81, 83)
 of peritonsillar abscess, 313
 of pertussis, 541
 of pharyngitis, atrophic, 294 (1, 2, 5, 14, 15, 27-30, 35, 37, 68, 70)
 hypertrophica lateralis, 289 (1, 2, 6, 7, 10, 14, 15, 23, 31-33, 63-65)
 of polypi of antrum of Highmore, 230
 of nasopharynx, 274
 in nose, 180 (1, 2, 5)
 of primary syphilis of nose 158 (1, 2, 12, 17, 38, 48)
 of prolapse of ventricle of larynx, 446 (6, 7, 23, 40, 41, 77)
 of purulent rhinitis, 84 (1, 2, 4, 6, 7, 10)
 of retropharyngeal abscess, 306
 of rhinitis, acute, 80
 constitutional, 80
 local, 80 (20, 21, 24, 44, 56, 57)
 prophylactic, 82
 atrophic, 111 (1, 2, 4, 5, 14-16, 24, 25, 55)
 hypertrophic, 89 (6-13, 23, 27-34)
 membranous, 125 (1, 2, 4)
 purulent, 84 (1, 2, 4, 6, 7, 10)

- Treatment of rhinitis, vaso-
motor, 119 (3, 22, 24, 25,
57)
of rhinoliths, 172 (1, 2, 4)
of rhinoscleroma of nose,
174
of R  theln, 541
of scarlet fever, 538
of sensory neuroses of larynx,
 anesthesia, 534
 hyperesthesia, 535
 paresthesia, 535
of pharynx, 409
of smallpox, 542
of spasmodic laryngeal cough,
516
of spasms of pharynx,
407
of stenosis of larynx, 492
of suppuration of frontal
sinus, 215
of suppurative inflammation
of accessory sinuses of
nose, 215
of sphenoidal sinus, 215
of syphilis of larynx, primary,
478
 secondary, 481 (3, 4, 24,
 25, 40, 41, 77-79)
 tertiary, gumma, 484
 inherited, 489
 ulcer, 487 (3, 4, 6, 9,
 24, 25, 40, 41, 72,
 75, 77-79, 80-83)
of mouth, 375, 378 (1, 2,
6, 8, 10, 24, 25, 39, 40,
59, 60)
of nasopharynx, 270 (1, 2,
4, 6, 7, 10, 16, 39, 40,
41, 49-55)
of nose, primary, 157
 secondary, 161
 acquired, 161 (1, 2, 6,
 12, 13, 24, 25)
 congenital, 166 (4, 5,
 12, 25)
 tertiary, acquired, 164
 (4, 5, 12, 13, 16, 24,
 25, 40, 55)
of tertiary syphilis of mouth,
 cicatrix, 383
- Treatment of tertiary syphilis
of mouth, gumma,
380
ulcer, 382 (1, 2, 4, 6,
7, 16, 24, 25, 39-41,
49-55, 59, 60, 65,
66, 67)
of tuberculosis of larynx, 469
 (3, 4, 24, 25, 71, 76, 80,
 81, 82, 83)
of nose, 156 (1, 2, 4, 16, 23-
25, 31-33, 39-41, 47,
50, 52, 55)
of pharynx, 390 (1, 2, 4,
6, 7, 10, 25, 27, 54, 63,
65, 80, 82, 83)
of typhoid fever, 544
of vasomotor rhinitis, 119
 (3, 22, 24, 25, 57)
of vertigo of larynx, 517
Trichloracetic acid cauteriza-
tion, method of employing,
93
Tubercular ulcer of nose, 154
Tuberculosis of larynx, 457
 of nose, 153
 of pharynx, 386
Tubes, intubation, 357
tracheotomy, 368
Tumors of pharynx, non-malig-
nant, 399
Turbinate, fourth, anatomy of,
20
 inferior, anatomy of, 20
 middle, anatomy of, 20
 dangers of cauterizing, 105
 superior, anatomy of, 20
Typhoid fever, 543
 epistaxis in, 543
 laryngeal condition in, 543
 larynx, ulcers of, in, 543
 nasal condition in, 543
 nose, ulcers of, in, 543
 pharyngeal condition in,
 543
 pharynx, paresis of, in, 543
 tongue in, 543
 treatment of, 544
 voice after, 544

U.

- ULCER of larynx in smallpox, 542
 in typhoid fever, 543
 of pharynx in chickenpox, 543
 syphilitic, of larynx, 484
 of mouth, 380
 of nose, 161
 tubercular, of nose, 154
- Upper respiratory tract, anatomy of, 17
 examination of, 39
 illumination of, difficulties of, 43
 technique of, 42
 operations on, antiseptics in, 69
 order of making examination of, 68
 physiology of, 33
- Uvula, deformities of, 302
 elongation of, chronic, 300
 etiology of, 300
 examination of, 300
 symptoms of, 300
 treatment of, 300
 examination of, 60
 inflammation of, acute, 298
- Uvulitis, acute, 298
 etiology of, 298
 examination of, 299
 symptoms of, 299
 treatment of, 300 (6-10, 21, 22, 59, 60, 65)
 chronic, 300

V.

- VARICOSE veins of tongue, 28, 330
 Varix, lingual, 330
 Vasomotor rhinitis, 115
 Veins of tongue, varicose, 28, 330

- Velum, anatomy of, 27
 Ventricle of larynx, 32
 normal appearance of, 67
 prolapse of, 444. *See* Larynx, ventricle; prolapse of of Morgagni, 32
 Ventricular band, 32
 normal appearance of, 66
 Vertigo, laryngeal, 516. *See* Laryngeal vertigo
 Vibrissæ, 20
 function of, 33
 Vocal cord, anatomy of, 30
 female, length of, 30
 male, length of, 30
 normal appearance of, 66
 nodes on, 430, 440. *See* Chorditis nodosa
 trachoma of, 430, 440. *See* Chorditis nodosa
 vibration of, 38
 function of nose, 36
 Voice after extirpation of larynx, 38
 after typhoid fever, 544
 effect of nasal obstruction on, 36

W.


- WATER, amount of, excreted from nose daily, 34
 Whooping-cough, 541. *See* Pertussis
 Wrisberg, cartilage of, normal appearance of, 67
 position of, 29


X.

- X-RAYS in frontal sinus disease, 206

Z.

- ZINC, oleo-stearate of, 558





COUNTWAY LIBRARY OF MEDICINE

RF
46
C63
1908

RARE BOOKS DEPARTMENT



COUNTWAY LIBRARY OF MEDICINE

RF

46

C63

1908

