

Hydatid disease in its clinical aspects / by James Graham.

Contributors

Graham, James.
Francis A. Countway Library of Medicine

Publication/Creation

Edinburgh and London : Young J. Pentland, 1891.

Persistent URL

<https://wellcomecollection.org/works/p8zkrc8y>

License and attribution

This material has been provided by This material has been provided by the Francis A. Countway Library of Medicine, through the Medical Heritage Library. The original may be consulted at the Francis A. Countway Library of Medicine, Harvard Medical School. where the originals may be consulted. This work has been identified as being free of known restrictions under copyright law, including all related and neighbouring rights and is being made available under the Creative Commons, Public Domain Mark.

You can copy, modify, distribute and perform the work, even for commercial purposes, without asking permission.



Wellcome Collection
183 Euston Road
London NW1 2BE UK
T +44 (0)20 7611 8722
E library@wellcomecollection.org
<https://wellcomecollection.org>



10 G. 17
No.

~~20~~ 15


BOSTON
MEDICAL LIBRARY
ASSOCIATION,
19 BOYLSTON PLACE,

Received

May 13. 1892


By Gift of

G. B. Shattuck, M.D.



10.6.14

HYDATID DISEASE.



HYDATID DISEASE

IN ITS CLINICAL ASPECTS

BY

JAMES GRAHAM, M.A., M.D. (EDINR.)

LATE DEMONSTRATOR OF ANATOMY, SYDNEY UNIVERSITY; MEDICAL
SUPERINTENDENT, PRINCE ALFRED HOSPITAL, SYDNEY.

ILLUSTRATED WITH THIRTY-FOUR COLOURED PLATES.

EDINBURGH & LONDON:
YOUNG J. PENTLAND.

1891.

1119



PRINTED FOR YOUNG J. PENTLAND, EDINBURGH, 11 TEVIOT PLACE;
LONDON: 38 WEST SMITHFIELD, E.C.



P R E F A C E.


THIS work was originally undertaken as a Thesis for the degree of Doctor of Medicine. I have been induced to publish it in a somewhat more extended form in the hope that it may prove of service to those interested in the subject of Hydatid disease and its treatment.

The plates given are faithful copies of the morbid organs, and were drawn from the specimens before any active changes of decomposition had affected them.

I am indebted to Dr. G. Sims Woodhead, of London, for his kindness in revising the proofs of the illustrations, and to Dr. R. S. Aitchison for looking over the text as the work was passing through the Press.

JAMES GRAHAM.

183 LIVERPOOL STREET, HYDE PARK,
SYDNEY, N.S.W., *August* 1891.



CONTENTS.

	PAGE
INTRODUCTION,	1
The sources of Hydatid Disease and methods of prevention, .	22
The Tænia Echinococcus,	34
The Hydatid Cyst,	42
The Echinococcus Multilocularis,	52
General Symptoms of Hydatid Disease,	66
Diagnosis of Hydatid Disease,	70
The Hydatid Fluid,	74
The Hydatid Rash,	77
Multiple Hydatids,	85
Hydatids in the various organs—	
Liver,	90
Lung,	94
Peritoneum,	107
Brain,	110
Spinal Cord,	122
Kidney and Supra-renal Capsule,	124
Spleen and Pancreas,	127
Bone,	130
Heart,	134
Uterus and its Appendages,	136


	PAGE
Hydatids in the various organs (<i>continued</i>)—	
Breast and Axilla,	138
Eye and Orbit,	140
Treatment of Hydatids—	
Medicinal,	142
Operative,	145
By direct incision and evacuation of their contents,	161
By electricity,	169
By medicated injections,	171
Cases illustrating the results of different methods of treatment,	173


LIST OF ILLUSTRATIONS.

1. Hydatid Cyst eight weeks old, showing also scolex and brood-capsules.
2. The *Tænia Echinococcus*, showing also the appearance of hooks and ovum, with scolex and brood-capsule becoming transformed into daughter-cysts.
3. Hydatid Tumour in the small omentum, with daughter cysts *in situ*.
4. Hydatid Cyst destroying almost the whole of the right lobe of the liver.
5. Hydatid Cyst growing from the serous surface of the liver.
6. Hydatid Tumour growing from the upper surface of the liver, showing hypertrophy of the remaining portion of the right lobe.
7. Hydatid Tumour growing from the upper and outer surface of the right lobe of the liver.
8. Multiple Hydatid Cysts of the Liver. The liver is uniformly enlarged, and the cysts deeply embedded in its substance.
9. Multiple Hydatid Tumours on the upper surface of the liver.
10. Multiple Hydatid Tumours on the lower surface of the liver.
11. Small Hydatid Cyst embedded in the interior of the right lobe of the liver tissue.
12. Small Hydatid Cyst in the Liver undergoing caseous degeneration.
13. Showing the outline of a large Hydatid Cyst growing from the under surface of the liver, without producing any apparent bulging.
14. Large Hydatid Cyst of the Abdomen, showing the mottled rash after an exploratory puncture.

15. Hydatid Tumour of the Abdomen, showing outline of cyst and the mottled rash after puncture.
16. Large Hydatid Cyst in the Great Omentum.
17. Hydatid Tumour growing from the under surface of the liver.
18. Hydatid Tumour in the Mesentery.
19. Multiple Hydatid Cysts of the Large Omentum.
20. Multiple Minute Hydatids in the Great Omentum.
21. Minute Hydatid Cysts in front and behind the Uterus.
22. Microscopic appearances of one of the Minute Cysts in previous plate.
23. Pedunculated Hydatid Cyst in the Mesentery.
24. Hydatid of Rectum, Kidney, and Suprarenal Capsule.
25. Small Hydatid Tumours in the Lung.
26. Large Hydatid Tumours in the Lung.
27. Hydatid Tumour in the Right Occipital Lobe of the Cerebrum.
28. Hydatid Cyst in the Frontal and Parietal Lobes of the Brain.
29. Hydatid in the Brain : the Patient before operation.
30. Hydatid of the Spleen ; daughter cysts *in situ*.
31. Hydatid Tumour in the Wall of the Left Auricle of the Heart.
32. Hydatid of Humerus.
33. Hydatid Tumour of the Right Breast.
34. Hydatids in the Broad Ligament and the upper surface of Uterus.

HYDATID DISEASE.





HYDATID DISEASE.

INTRODUCTION.

ALMOST every living creature is preyed upon by some carnivorous foe, and in not a few cases the parasite itself is liable to be attacked by other parasites.

Though there is great variation in the manner and degree in which the different animals are attacked, yet neither the size nor the mode of life of the animal gives immunity from the attack of these foes.

Man himself, placed as he is at the head of the animal kingdom, would appear to be the host of a greater number of parasitic forms of life than any other animal, although it is admitted that new genera and species are constantly being added to the list, and that time may deprive him of the doubtful distinction of being the most liberal entertainer of these "unbidden guests."

Much attention has been given to the subject of the parasites of man, and, so far, about sixty different forms have been described. They vary greatly in their importance from a medical point of view, some indeed appearing to cause little disturbance of the

well-being of their host, while others may seriously impair health, and even destroy life.

It is only within recent years that a rational theory of parasitic diseases has been fairly established. From the earliest times, however, many diseases were traced directly to the influence of parasitic forms of life. Parasites were dreaded for the effects they produced; but their life history, and the manner by which they produced diseased conditions, were unknown.

During the seventeenth and eighteenth centuries nearly every serious malady was attributed to the influence of an animal parasite. They took the place that the modern Bacillus or Germ "Theory" does now in the estimated production of disease, even the best representatives of the pathology of the time giving their adherence to such a view.

The passage of a worm from the intestine of a patient was a proof to the early observers that the exciting cause had been removed, and the recovery of a patient after such an event was further regarded as an unanswerable proof of the correctness of their view.

As the sciences of Physiology and Pathology began to expand, these crude notions of disease began to be dispelled. The so-called worms of blood vessels, for example, were shown to be only blood-clot, and many of the supposed parasitic causes of morbid conditions were found to be equally incorrect.

The systematic observations of helminthologists subsequently began to sway professional opinion regarding the causation of disease in quite an opposite direction, and many denied that intestinal worms

had any hurtful effect on the host, and their specific relations to disease were even discredited.

Such naturalists as Göze and Abildgaard gave as their opinion that, instead of being a menace to life and health, parasites aided digestion by absorbing mucus and exciting peristaltic contraction; and Jördens called them "the good angels and unfailing helpers of children." They denied the existence of any specific form of worm disease, and maintained that it was exceptional for the presence of parasites to give rise to any disturbance to health.

The older physicians still clung to the theory and practice of worm diseases, and the terms "worm fever" and "worm irritation" were commonly applied by them to those numerous febrile and nervous conditions which their limited knowledge of exact pathology prevented from referring to their true cause. They also held the view that the vital condition of the patient favoured the development of the parasite, and they spoke and wrote of a "diathesis verminosa." Their knowledge of the origin of human parasites and of the affections produced by them is best expressed in Bremser's own words.

"By a worm disease I mean any disturbance or interruption in the functions of the primary or secondary digestive or nutritive organs, whereby substances are formed and collected in the alimentary canal, which under favourable circumstances may, but do not necessarily produce worms; I mean, in short, the material factors of worm production. So that worms in the alimentary canal are not an

original disease, and, indeed, can only rarely be regarded as a disease at all, but are much more frequently the sign of a diseased state of the organs in question, or of some interruption in the co-operation of these organs, from which state many results may ensue without the presence of worms."

Numerous experiments have furnished us with a solid foundation of fact as to the exact origin of all parasitic diseases. The parasites originate from germs intruded or introduced, and they develop wherever they find the conditions of their development fulfilled. The number of parasites will increase in each individual case, according to the number of germs introduced, and according to the adaptability of their environments. Their presence in the human subject is certainly not in consequence of any known diseased condition which could favour their existence and development, for their introduction into the body as germinating ova is wholly a matter of accident, and in many cases where numerous parasitic forms are found, no possible effect on the health of the host can be attributed to their presence.

It is hardly to be wondered at that the nature and origin of many forms of parasitic affections were long a cause of mystery, from a medical as well as a zoological point of view. As long as the infesting animals confined themselves to the alimentary canal, or to the outer surface of the body, their presence could easily enough be explained, but when they were found deep in the interior of what appeared to be inaccessible organs, such as the brain, kidneys, lungs,

spleen, etc., the explanation became all the more perplexing.

The theory of spontaneous generation was a very convenient way of solving all the difficulties in regard to the existence of parasites in different parts of the body; the only point at all likely to give rise to difference of opinion among those who accepted this view was the particular formative elements out of which the organism arose.

Swammerdam and Redi in the beginning of the eighteenth century were among the first to contradict the earlier view that sexual generation was confined to the higher animals. They clearly demonstrated sexual development as applied to insect forms of life. Redi, for example, proved that maggots were really the larvæ of flies, and that they could only develop after the mature insect had deposited its eggs. It is not quite clear whether they claimed for the intestinal parasites a similar mode of development, although they did not deny the possibility of worms originating from ova of species that had already existed in other animals.

The application of the microscope to biological work subsequently revealed the existence of myriads of minute forms of life that had hitherto escaped observation, and the theory arose that the animalculæ so abundant in food, water, earth, and air, became transformed in the alimentary canal, under the influence of warmth and moisture, into fully formed worms. Such naturalists as Boerhaave and Hoffmann believed that the progenitors of the Entozoa were in

some cases worms which had a free existence, and which resembled in appearance the parasitic forms. The discovery by Linné of a tapeworm in fresh water seemed to give weight to this view. It was not known, however, by this naturalist that the *Bothriocephalus* or *Schistocephalus solidus* inhabits the body cavity of the stickleback, but leaves it at a certain stage of its development, and after passing some time in the water is eventually swallowed by a waterfowl. Linné regarded this free form as an incomplete specimen of the *Bothriocephalus latus* so common in the human subject, and inferred that it was swallowed by man. He also claimed to have found living in a free state the liver fluke of the sheep and the *Oxyuris* of the human subject. It was, however, shown later that he had mistaken a Planarian and one of the free-living *Anguillulidæ* for these parasites.

Linné's hypothesis seemed very feasible, and was commonly accepted, as it offered an easy explanation of the origin of human parasites; but the researches of several helminthologists so increased the number of parasitic species, and, as all attempts to find them in a free state failed, the theory of free existence had to be abandoned, especially when it was shown that Linné was wrong in supposing that certain worms which he found in water were identical with some found in the human subject, whereas they were only similar in appearance in some respects, but of entirely different species.

It was Pallas who subsequently put forth the theory that the Entozoa resembled other animals

in originating from eggs that are carried from one animal to another. In his own words—

“The eggs of the Entozoa are scattered abroad and undergo various changes without loss of vitality, and immediately they reach the body of a suitable animal, through the medium of its food or drink, they grow into worms.”

To account for the presence of parasites in various organs Pallas believed that the eggs were carried by the bloodstream to distant parts of the body, occasionally reaching the body of the embryo before birth. This was the basis of his theory of the “inheritance of Entozoa,” by which he maintained that intestinal worms could be inherited by one host from another.

In 1831 Mehlis discovered that the eggs of some Distomidæ contained an embryo. Von Siebold also observed that in the tapeworm the egg, before it was laid, contained an embryo. In each case the embryo was totally different from the parent; it was a simple spherical mass, characterised by the possession of six hooks arranged in pairs.

It was left to Eschricht to show the great value of this discovery, who, in a masterly paper published in 1841, after reviewing all that had been said and done to elucidate the theory of the origin of parasites, approached the true condition by pointing out that change of place and form were the most important facts in the life history of parasites.

Shortly after the researches of Eschricht were published, Steenstrup issued his classic work on the “Alternation of Generations,” which at once threw

great light on the whole question of the development of parasites. By direct observation he proved his case conclusively, and showed that there were certain animals whose offspring in the second or third generation returned to the original form of the sexual animal, and that numerous intestinal worms belonged to this class.

Kuchenmeister in 1852 described the conclusions which he had arrived at by actual experiment, and which showed that bladder-worms, the exact nature of which had so long puzzled helminthologists, became developed into true tapeworms in the alimentary canal of a suitable animal. A year later he succeeded in obtaining bladder-worms in animals that he had fed with ova of tapeworms, and thus he completely established the cycle of their life history.

None of the typical intestinal worms pass their whole life cycle in one locality. As a rule, the eggs are deposited in the locality where the parent lives. There is considerable variety in the stage of development the eggs have reached at the time of their leaving the parasite. Every stage of development is represented, from the newly fertilised egg to the fully formed embryo. The ova of the *Trichina Spiralis* are hatched while in the body of the mother. The subsequent history of the ova also varies much in different cases. As a rule, as soon as they are laid they pass from the body of the host together with the excreta.

The passing of ova in this way is not confined to intestinal parasites. The eggs of the *Distomum*

Hepaticum come down the bile duct before reaching the outer world by the intestine, and similarly the ova of *Filaria Bancrofti* and *Strongylus Gigas* are voided with the urine.

The after history of the ova of parasites depends on many circumstances, both of distribution and environment. Considering the countless ova that are constantly being distributed over the face of the earth, it is evident that the greater number perish from lack of opportunity to complete their developmental cycle. As a general rule, "A moist environment is necessary for the further development of the eggs of Entozoa." Some ova are possessed of a thick outer covering or shell that serves to protect the enclosed embryo from injury for a long time. Leuckart's experiments with the ova of the *Ascaris* showed that they could even remain a long time in such fluids as chromic acid, spirit, turpentine, and other liquids, without the embryo being destroyed. This is all the more remarkable as the fully developed worms are readily destroyed under such circumstances. In many cases the eggs lose their power of development completely in dry localities, while in moist places and in water they are capable of retaining their vitality for a considerable time. Leuckart, who experimented with the ova of certain Nematodes, by subjecting them to conditions of alternate drying and moistening, found that they retained their power of development for months.

The eggs of intestinal parasites, after being extruded into the outer world, follow one of two courses,—either

they leave the eggshell that envelops them and live for a longer or shorter period a free life, or else they remain within the capsule and are not liberated until swallowed by another host. It is obvious that the character of the shell is an important factor in determining the captivity or liberation of the embryo after it is set free from the original host. The shell of the ovum, when thick and resisting, is acted on by the gastric juice on reaching the stomach of the animal that has swallowed it. The influence of the gastric juice on these eggshells is demonstrated by the fact that when they are swallowed by cold-blooded animals, such as the frog, in whom the digestive activity is very feeble, they pass unaltered through the alimentary tract.

In some cases, where the ovum has reached the stage of the embryo and is liberated outside the original host (as is the case with the *Bothriocephalus latus*) the eggshell is provided with a lid which can be raised by the embryo, and allows it to assume a free mode of existence.

The embryos thus liberated pass this stage in water, and are usually provided with means of movement, as, for example, a covering of cilia. As soon as they meet with a proper host they lose this special power of movement and undergo their definite form of development by metamorphosis. These larval forms may find their way into the body of their host by means of water that is drunk; many animals feed on the ova passed by Entozoa, or they are introduced into the body in various passive ways with the food.

The ova of some species of Entozoa pass directly from the stomach of the animals that have swallowed them, into the intestine, and there arrive at sexual maturity; among human parasites this is the case with the *Oxyuris*. The usual path, however, is much more complicated.

The rule is, that after they have found their way into the body of some host, they wander in various directions among the tissues and organs. They are assisted in their course and distribution by getting into blood-vessels and being carried into the remotest parts of the organism. In some cases the presence of embryos of *Tæniæ* in the blood have been actually demonstrated, and in the case of *Trichina Spiralis* the connective tissue has been noticed to form passages of communication from one part of the body to another. The embryo seems to be adapted for making its way through the tissues of the body of its host without damaging the structures through which it pierces. Its wanderings finally become arrested, and then, if the circumstances of its environment are favourable, it undergoes further development by growth and metamorphosis. In some cases the embryo may find these special conditions for development in only one particular organ or host; on the other hand, it may be able to develop in almost every tissue of several different hosts. The *Tænia Echinococcus* is a good example of the latter, the parasite being found in every conceivable region of the human body, and also in sheep, oxen, pigs, horses, &c., while the *Tænia Cœnurus*, which seems to find its suitable environment

only in the brain of the sheep, may be cited as an example of the former.

This quiescent stage following the wanderings of the embryo does not conclude the life history of the parasite, which requires a second migration before the life cycle is complete. Further development is accomplished by an asexual brood produced from the quiescent form, or bladder stage. The most common course is for these larval elements to be passed from one animal to another, usually accomplished by their being devoured along with part of their host by some other animal. When the immature parasite has been transferred to the body of its right host it arrives at sexual maturity, otherwise it dies.

The digestive juice exercises an influence on the parasites in this stage, just as it does on the walls of the ova from the worm. They remain longer in contact with the juice than the ova do, on account of their larger size and greater extent of surface exposed. The outer covering that encloses them is dissolved, and the heads or scolices are carried to the intestine, where they develop into the mature parasite. That the digestive juice of each animal should be suited only for those embryos that are known to find in them a suitable habitat for further development is an interesting and striking fact. It destroys the embryos that have, so to speak, no right there.

The life history of intestinal parasites is of a complicated character, and the nature of their growth must serve to check their too rapid increase, for in consequence of it myriads of ova must perish.

The presence of parasites in any animal organism is calculated to affect the health of the host in various ways. This will depend partly on the particular region or organ where the embryo finds a suitable nidus in which to develop, and partly, also, on the size to which the parasite can attain. The first obvious disturbance is that of pressure. The parts in immediate relation with the growing parasite yield to the gradual pressure of the small bladder. The cellular elements of the structure immediately adjacent to the foreign body begin to disappear, and the connective tissue, from the irritation of the new growth, begins to increase and hypertrophy. The increase in the connective tissue is often very remarkable, and at an early period in the development of the cystic stage of some parasites, it serves the purpose of an outer covering to the cyst, many times thicker than the animal wall to which it is in close relationship, receiving the name of ectocyst. It is obvious that the constitutional disturbances which the host experiences will depend on the relative vital importance of the particular organ attacked. Thus, when situated in the brain, where the structure, function, and relation of parts admit of little or no morbid disturbance, the symptoms will be of a pronounced character, and the risk to life imminent; on the other hand the organ or region attacked may be more tolerant of the pressure of a foreign organism, and even in such an organ as the liver the destruction of the cell elements is wrought so insidiously by the slow growth of the cyst, that compensation by hyper-

trophy is brought about, and the requirements of the body provided for before the health of the victim has seriously suffered. Many other circumstances may result from the presence of a parasite in the body of an animal organism that may bring about disturbance to the health of the host. Blood-vessels may be pressed upon, and the blood-supply shut off from various parts of the body, and branches of nerves may become involved, causing motor or sensory disturbance. Serious results may also follow even when the parasites are minute in size. The embryos of the *Trichina Spiralis* very speedily cause destruction of the sarcous elements of muscle fibre. Acute constitutional symptoms rapidly supervene, fever, lassitude, nausea, and great pain and stiffness of the muscles of the body. The victims often die four or five weeks after infection, death being due to exhaustion or some inflammatory attack, as pneumonia, which the condition of the patient induces.

The ova of *Distomum Hæmatobium* may lead to marked renal trouble, showing itself by attacks of hæmaturia; similarly the parasitism of the *Echinococcus* and *Strongylus* may lead to suppression of urine. The disturbance to health, or even the death of the host, may not always be directly caused by the presence of the parasite; but it is easy to understand how its presence may give rise to a long series of chronic ailments that undermine the constitution of the patient. In some cases the wanderings of the embryos give rise to marked constitutional disturbance in the host. Leuckart ascertained this from experiment, by feeding

rabbits with large quantities of the eggs of the tapeworm. In some of these cases the animals died in a few days without any apparent external cause. On examination he found the capillaries of the viscera injected, especially in the lungs and liver. Leisering also experimented with the lamb by feeding it on the ova of the *Tænia Marginata*. The changes he observed after death were in the liver, which was congested throughout its whole extent. There was icterus present, and extravasation of blood in the lungs. In the case of those animals who survived the experiment, an effect was produced resembling the symptoms of miliary tuberculosis, which Mosler termed "Acute Cestodic tuberculosis." Poisonous properties have also been attributed to the ova, which give rise, in their passage through the tissues and organs of the host, to these acute symptoms; but the cause is more probably to be found in the inflammatory condition set up by the mechanical disturbance resulting from their wanderings in the body. These phenomena do not occur in every case, at least most animals would seem to survive the effects of such an ordeal, and frequently do not even exhibit any unusual symptoms.

It is surprising to what extent an animal may harbour numbers of actively growing parasites without suffering any apparent loss of nutrition. Leuckart remarks that "there must be unusual influences at work if the loss caused by the abstraction of nutritive material by the parasite for its metabolism, growth, and propagation, is at all appreciative to the host, provided that he belong to the larger animals, and

much exceed his parasites in size and nutritive requirements."

That a severe marasmus may occur in some cases is not an uncommon belief among physicians of the present day. In such supposed cases "it is quite possible that the relation between disease and parasite is of an indirect nature, and brought about by the state of the infected organ." Leuckart, further quoting the observations of Eschricht in regard to the *Bothriocephalus latus*, as related to the health of its host, says:—"It throws off yearly a number of pieces, which measure altogether about 15 or 20 metres, and may represent a weight of about 140 grains. Even on the supposition that the animal—which, of course, undergoes continuous metabolism—abstracts three or four times that quantity from its host, and that the nutritive material consumed by all the parasites amounts to several pounds yearly, it is easy to see that so moderate a quantity is of hardly any account compared with the yearly consumption of the host. It is much the same in the case of the *Tæniæ*, and even of the *Tænia Saginata*, which throws off, let us say, eleven proglottides daily, with an average weight of 1.5 grains, and thus loses in the course of a year about 550 grains of organic matter. If the number of parasites be greater the association is, of course, more unfavourable. A female thread-worm produces 42 grains of egg substance yearly, and, taking into account what it requires for metabolism, must deprive its host during this time of at least 100 grains. Thus if, as sometimes occurs, there were 100 of them (there have been cases

in which 1000 have been found at the same time in the intestine) they would cause a loss of 833 grains monthly, which, under some circumstances, and especially in childhood, must have a very appreciable effect. Similarly the 100,000 specimens of *Rhabditis Stercoralis* (1 mm. long, 0.4 mm. in diameter), which are often evacuated daily by patients suffering from Cochin China diarrhoea, represent by their mass alone, without taking into account material used in metabolism, a weight of 200 grains. And if it be considered, further, that the number of the evacuated worms may increase tenfold, it becomes easy to understand how a severe marasmus may ensue, even after a severe illness."

In considering the presence of parasites in man from an etiological point of view, it may be stated that, as a general rule, by far the largest proportion are derived from other animals. They transmit them to the human subject in various stages, and by different means. The domestic animals furnish man with the eggs of their parasites, and they develop in them their larval stage. Chief among these household animals that thus transmit their parasites is the dog. *Pentastomum denticulaturus*, *Cysticercus tenuicollis*, and the *Tænia Echinococcus* are the most common of the parasites that he harbours, the eggs of which in one way or another are transmitted to the human being.

We also derive some parasites from animals that are used as food material. The common tapeworm and the *Trichina* (measly pork) reach us in this way. They reach us through the food as adult forms, though they correspond to the larval stage of the

parasites from the circumstances of their position and relation. In these cases man becomes self-infected. The embryos of the *Trichina* are born free in the intestinal cavity, and wander thence into the muscles of the body and become encapsuled. Man may also infect himself with the ova of the *Tænia Solium* by transferring the ripe joints or eggs into the stomach. Kuchenmeister supposed that the ova of the common tapeworm could develop into the bladder stage by their passing direct from the intestine. Leuckart, however, maintained that the liberation of the embryo presupposed removal of the capsule, which could only take place by means of the gastric juice, and he strengthened his view by direct experiment, by transferring the ova of the *Tænia Serrata* direct into the intestine of a young rabbit, through an opening in the abdominal wall, by means of a hypodermic syringe, and found that the animal remained free from the bladder worms.

Parasites are developed in man mainly by the accidental introduction of ova with his food and drink. In cases where flesh is eaten raw this is easily understood, but among civilised people this is, of course, not a very common mode of introducing parasitic ova into the stomach, though the butcher and the cook may often be tempted to test the savoury condition of such articles as sausage, mince, and the like in their raw state. A much more common and dangerous source is meat that has been imperfectly cooked, where the central portion is much less acted on by heat than the outer surface. Even boiling or roasting

meat is not always sufficient to ensure freedom from the risk of parasitic infection, although in the great majority of cases the parasites are destroyed by the ordinary processes of cooking. Leuckart's experiments in 1860 proved that trichinous flesh is by no means rendered innocuous by the usual process of cooking or boiling. The same thing applies to such articles of common use as ham, pork, smoked sausage, &c. It has also been clearly shown that some kinds of fish may convey parasitic infection to those who eat them. Braun proved that the pike may convey the *Bothriocephalus latus* in its young stages to human beings; similarly, the *Bothriocephalus cordatus* of Greenland is probably derived from fish that harbour its young stage. This tapeworm is found commonly among the Esquimaux and their dogs, who partake liberally of raw or dried fish.

Parasites may also reach man by means of the water he drinks; this is more likely to be the case when the water is obtained from open reservoirs or exposed tanks or cisterns. In country districts where the water supply is not very abundant, and where men, dogs, sheep, and cattle drink alike from the same source, it is easy to understand how parasitic embryos may readily gain access to an animal suited to their further development.

Similarly, raw vegetables, such as are commonly used in salads, which have been imperfectly washed, may serve as media for the transference of parasitic eggs to man. Though such a mode of infection has not been actually demonstrated, it nevertheless seems

highly probable that they are as liable to the accidental association with parasitic embryos as the flesh of animals used as food by man.

The occurrence and distribution of parasites in man is found to occur irrespective of age, sex, or race. Their occurrence is primarily determined by the opportunities that exist for the transmission of the embryos. Custom, habit, mode of life, and occupation are the chief factors that determine their distribution. The fact that certain parasites occur more commonly in children, and in some races more than others, can be explained by the fact that the various surroundings which influence their habits and customs render them more liable to be infected. Thus children are generally known to harbour the threadworm more commonly than adults, and this is no doubt to be explained by the fact that they are apt to eat and suck all kinds of food stuffs without being able to choose or distinguish. Vix pointed out the interesting fact that those afflicted with mental diseases, and whose appetite could be described as voracious, are commonly the hosts of numerous parasites. This is to be explained in the same way as the common presence of threadworms in children.

In like manner one can explain the presence of parasites in man as apparently related to time and space. In European countries persons with the common tapeworm (*Tænia Solium*) come under treatment more commonly in summer than in winter. During the winter meat is more generally consumed, and allowing several months for the development

of the parasite, its presence in the summer would naturally be more often observed. In the same way, *Trichina Spiralis*, which requires but a very short time for its development, is observed more frequently in the human subject during the winter months.

Leuckart, in referring to the local and endemic occurrence of parasites, specially points out their constant relation to cause and effect, as exemplified by their occurrence among savage races—

“Nowhere are intestinal worms more frequent than among savage peoples, especially in the tropics, as has been long ago sufficiently established and lately confirmed by travellers and physicians, especially in the case of Africa. In Abyssinia, for example, every inhabitant, male or female, is infested with intestinal worms from his fourth or fifth year. Similar accounts might be given in regard to the American slaves, the Esquimaux, and the Burätis among the lower class populations of the East Indies. Of course the same parasites do not prevail throughout. The negroes of the West Indies are specially plagued with *Ascaris*; the Abyssinians most commonly harbour *Tænia*, due, as has been supposed since the time of Bruce, to their general use of raw meat. Since the flesh of swine is avoided by the Abyssinians, it is, of course, not *Tænia Solium*, but *Tænia Saginata* which occurs. The latter is associated with the ox almost throughout the world, while the former, like the *Trichina*, is specially prevalent in those lands where swine are generally bred.”

HYDATID DISEASE.

The term "Hydatid" is usually applied to the larval or bladder stage of the *Tænia Echinococcus*, a small tapeworm that is found sexually mature chiefly in the intestine of the dog. The term is also applied in a more or less vague way to the bladder stage of several other animal parasites, so that it has been suggested to apply only the name of "Echinococcus" disease to this special form, in order that stricter accuracy may be ensured. However, as the term "Hydatid" is so commonly used, and as the "Echinococcus" bladder worm, is the parasite to which it is chiefly applied, it will be found convenient to retain it for the present.

The name of "Echinococcus" was originally invented by Rudolphi ($\acute{\epsilon}\chi\acute{\iota}\nu\omicron\varsigma$ = hedgehog, $\kappa\acute{\omicron}\kappa\kappa\omicron\varsigma$ = berry), and describes the appearance presented by the scolices or heads that are developed from the wall of the cyst.

German writers make use of it to include the bladder with its contained daughter-cysts, brood-capsules, and scolices, while English writers, on the other hand, apply it usually only to the scolex.

The cycle of the life history of this parasite may be briefly stated as follows:—The fertilised eggs are passed from the dog along with the excreta. The eggs are contained in the last segments or proglottides of the *Tæniæ*, and it is in these segments that the eggs

are conveyed into the outer world. The segments soften and disintegrate, and enable the ova to get free, so that they have a chance of becoming dispersed in various directions. The segments when newly voided by the dog seem to possess some power of peristaltic movement; they are also covered with glairy mucus, and by this means may adhere to various substances that different herbivora find suitable as food material. The ova of the Echinococcus may thus reach the stomach of different animals, either in clusters enclosed in the proglottides, or they may be swallowed with the food or drink as separate eggs. When thus swallowed they have reached the embryonic stage, having a slight amount of differentiation, and possessed of six hooks arranged in pairs. Each embryo is enclosed in a thick fibrous capsule, which serves to protect it from injury, and enables it to retain its vitality for a considerable length of time.

The gastric juice of these animals that are known to harbour the cyst, digests the fibrous membrane of the eggs, and by this means the embryos are liberated. After their liberation they are able to bore through the walls of the stomach, apparently without any difficulty, and without causing any serious local injury to the tissues which are pierced.

They are carried by the blood to different parts of the body, their course being commonly stopped by the liver, which they reach through the portal stream. They thus arrive at a stationary position, and begin to develop by a process of growth and metamorphosis into the characteristic bladder cysts.

Different animals besides man are capable of acting as intermediary hosts, by affording these special conditions of environment which the Echinococcus bladder requires for its growth and development. It is found in sheep, cattle, pigs, horses, kangaroos, the camel, ass, zebra, monkey, &c.

The Echinococcus bladder consists of a thick homogeneous pellucid membrane, filled with clear saline fluid, and it attains its developmental completeness by the formation from its inner surface of small vesicles, called "brood-capsules," which may be regarded as repetitions of the parent cyst.

From the brood-capsules are developed the characteristic heads or scolices. The brood-capsules and their scolices remain attached to the cyst, or they may undergo retrograde changes by becoming transformed into bladders,—the so-called daughter-cysts. The daughter-cysts have also for their function the formation of brood-capsules and scolices.

There is great variety both as to the number and size of hydatid cysts found in different animals. The organ in which they are most commonly found is the liver, but no portion of the body is free from the ravages of their attack.

The bladder stage is not capable of any further development, until it is swallowed by the dog, which it commonly reaches in the raw offal that these animals easily procure. The heads or scolices which thus reach the dog readily become retransformed into the sexually mature tapeworm, thus completing their life cycle.

The dog may be regarded as practically the only

source of hydatid disease, and since this animal has long been privileged to live in close personal contact with man and domestic herbivora, the opportunities for becoming infected with the ova are more or less constant.

The extent to which the disease prevails in any particular country will depend on the number of dogs and herbivora in the country, and on the opportunities that exist for enabling the ova to reach their intermediary hosts. It is easy to understand how readily the *Echinococcus* eggs are able to reach the stomach of cattle and other animals that commonly harbour hydatid cysts. The segments come in contact with various kinds of food material, or the eggs are washed or blown into the open reservoirs or pools of water which the cattle drink from. In all probability they reach man most commonly in the water he drinks. In some cases he may be compelled to drink the water from exposed places, to which the eggs could easily find access; they may also be conveyed to him in certain articles of diet, as, for example, raw vegetables. Dr. Bird, of Melbourne, is of opinion that they sometimes reach the human subject through the atmosphere. He cites his observations as to the prevalence of pulmonary hydatids among all classes in Melbourne, and gives it as his view that the water which is used for allaying the dust on the streets is taken from an open stream, which is, he believes, often impregnated with *Echinococcus* ova. Dr. Bird would seem to imply that the eggs might reach the lungs direct in this way, and undergo the development of the bladder stage. It

seems quite possible to conceive of the ova being swallowed with the dust that is blown about, but for them in some cases to pass direct into the respiratory passages, and there to develop, presupposes that the egg capsules can be dissolved by the warmth and moisture of the pulmonary alveoli. Demonstrated proof of their reaching man in this way would be a point of great interest and practical importance. Meanwhile it stands as a doubtful conjecture until further evidence is forthcoming, the gastric juice being, so far as is actually known, necessary for dissolving the proteid character of the capsule. It is of importance to remember that the dog, besides actually harbouring the mature worm, may serve as an intermediary host in conveying the ova to man; the eggs may be attached about the hair of the dog's face, or even on the mouth or tongue, reaching this part of the body in the course of picking up different articles of diet with which the ova have come in contact; thus, in the act of licking his master's hand, the eggs under such circumstances might easily find a lodgment on the hand, and from there be transferred to the mouth, and in this way swallowed. Some persons indiscreetly allow the dog to lick the face, or to partake of some dainty morsels from off their own plates, thus thoughtlessly exposing themselves to the risk of a terrible disease.

Hydatid disease prevails more extensively in Iceland and Australia than in any other parts of the world. "Given a country," says Dr. Davies Thomas, "with many sheep, &c., the organs of which are often

eaten raw by the dogs, if the water supply be scanty and procured from bogs, swamps, waterholes, and dams, on the banks of which dogs may deposit the eggs to be blown in by the winds or washed in by the rains, and there be dogs in abundance, we have all the conditions necessary for the spread of the disease." In both countries the dogs are widely distributed and the number of herbivora very large. Thomas gives the number of domestic herbivora in Australia as 2689, and in Iceland as 524 per hundred inhabitants. The number of dogs in Iceland he states as one to every eleven inhabitants. In Australia the number cannot even approximately be given. In 1880, the number of registered dogs in the Colony of Victoria, according to Thomas, was one to every 23 inhabitants. In Australia by far the larger number of dogs are not registered, and, judging from the number that one sees prowling about the streets of the large cities and inland towns, the registered number must form but a fractional portion. I lately counted in one short street in the city of Sydney 26 dogs running about, in some cases the children innocently making playmates of them. In 1882, in the same city, during one of the spasmodic attempts of the officials to abate the dog nuisance, thirteen hundred dogs were destroyed. During the last six years, to my knowledge, nothing has been done in a systematic way to check this growing evil in Sydney. In the country districts of Australia in some cases a price is put on the head of the native dingo, entirely on the ground of the danger to sheep and other stock

from his ravaging propensities, but the danger by their presence of the spread of hydatid disease in the human subject is a matter which has never been seriously taken up by the responsible officials.

The indifference which prevails among the people as to the danger of this terrible scourge is indeed surprising; it is rare that one finds that patients with hydatid disease have any knowledge either as to its nature or the way by which infection generally takes place.

In some parts of Australia it is the rule to find the sheep and oxen that are slaughtered infected with hydatid tumours, and though the cysts do not usually attain in these animals the large size that they do in the human subject, yet, as a rule, the disease occurs in them as multiple cysts, thus affording many opportunities for re-infecting the dog.

It is obviously a difficult matter to form even an approximate idea as to the extent to which the disease prevails in man. We must judge of the extent more from the opportunities that are known to exist in any given country for developing and disseminating the eggs of the *Tænia Echinococcus*. The presence of hydatid tumours in persons whose deaths are attributed to other causes is, I believe, large, and there are many cases of patients who have been treated for hydatid disease, and whose deaths subsequently have been attributed to other causes, but which actually were brought about by the presence of the parasite. Cobbold, referring to the death rate from hydatids in England, says that:—

“As regards hydatids, I believe the returns to be excessively deficient. In place of an average of thirty-four deaths annually from this cause in the United Kingdom, I am of opinion that at least 400 deaths are due to hydatids. This opinion, and the data on which it was founded, were communicated by me twelve years ago to the Linnean Society, and I have since become acquainted with facts which lead me to conclude that my original estimate was very much below the mark. The *post mortem* registrar of one of our large hospitals has told me that of late years as many as ten deaths might be reckoned as annually due to hydatids in their institution alone. At a smaller hospital I ascertained that the average was about four. Obviously, if these estimates are correct, the Registrar-General's returns for the United Kingdom do not record a tithe of the annual mortality due to hydatids.”

In Iceland, where hydatid disease is known as the “liver plague,” it was estimated that as many as ten to fifteen per cent. of the population at one time suffered from it, and though this estimate is considered too high by more recent observers, yet it is obvious that it constitutes the most serious malady among the people of that country. The people there are mainly engaged in the rearing of cattle, and the lack of cleanliness in their habits, aided by the stern conditions of climate, induce many of them to crowd together beneath the same roof, along with their dogs and cattle. “The carelessness with which the Icelanders carry on their intercourse with these animals

must also frequently lead to infection, for they even go so far as to allow their wooden dishes to be licked clean by the latter instead of washing them."

As regards Australia, it appears to me that the disease is increasing as the districts in the country are becoming more and more populated.

It may be that the opening up of the interior of the country by the railways has had the effect of bringing more hydatid patients within easy reach of the hospitals in the various cities. At the present day, in frequency and importance, it claims the distinction of being a national disease, and it bids fair to deprive Iceland of the unenviable distinction of being the most hydatid stricken country in the world.

During the last six years alone over two hundred patients have been treated for this malady in Prince Alfred Hospital, Sydney.

We must look to the eradication of hydatid disease by the removal and prevention of those causes that are known to favour its increase, and no effort should be spared to destroy or minimise the causes of this menace to health and life. There is no more terrible or distressing condition that can affect the human subject, for while the resources of the surgical art can often cure or alleviate those who are the victims of such an affection, yet many, otherwise strong and healthy, end their days with a tragic suddenness, or drag out a painful existence from some organic trouble directly induced by the presence of the parasite.

It is the duty of those in authority to see that the laws relating to the dog nuisance are strictly

and stringently carried into effect. Natural history, as applied to human parasites, and the diseases which they cause in man, should form part of every school curriculum, and every opportunity should be taken to remind the inhabitants of those countries where this disease specially prevails what a terrible calamity may befall them by disregarding those precautions which require to be taken in order to avoid the risks of infection. "We must," writes Leuckart, "prevent dogs from licking us, banish them from room and kitchen, keep them clean, and see that their excreta is, as far as possible, removed. Further, suitable precautions should be taken to prevent an infection with embryos of *Echinococcus*, the dogs should be kept away from places where the bladders are thrown carelessly away, or even given to dogs as 'tit bits.' The careless disposal of these 'water bladders,' and the unnecessarily large number of dogs, have most to do in perpetuating and propagating one of the most severe and dangerous forms of helminthiasis."

The Central Board of Health of Victoria have caused to be distributed throughout that colony the following circular, which gives a brief and excellent description of the means by which infection can best be avoided:—

CIRCULAR.]

CENTRAL BOARD OF HEALTH, 19th May 1885.

SIR,—The question of impure water supplies has been latterly, on more than one occasion, carefully considered by this Board, and it is believed that a

large quantity of water in daily use is unfit for human consumption unless precautions are taken.

It is known that hydatid disease is on the increase in Victoria, and that many valuable lives are annually lost from want of a little knowledge and care.

In Quain's *Dictionary of Medicine*, it is stated that in Iceland, which is more infected with hydatid disease than any other country in the world, twenty-eight per cent. of the dogs are affected by it, and of the human subject one-sixth of the annual deaths are from hydatids. It is further stated that probably Victoria is already the second most infected territory.

The Central Board desires to point out that in drinking open natural waters or eating vegetables to which dogs have access, all persons—but especially children—run a great risk of incurring hydatid disease, with all its consequent dangers.

The Board strongly recommends that all such water be first thoroughly *boiled*; and persons living in the country, or travellers, should avoid drinking from waterholes or swampy water of any kind without such precaution, and in all cases the water supply for domestic use should be guarded against the invasion of dogs. Dogs should not be allowed to swim in reservoirs, or, where possible to prevent it, to drink from the same supply as man, sheep, cattle, or pigs.

It is highly important to remember that the purest-looking water may contain numerous hydatid germs; hence the importance of boiling the water where there is any risk.

It is desirable to bury or throw boiling water over the exposed fæces of dogs, and chained dogs should have their kennels and the ground for some distance round purified frequently with boiling water. Dogs should never be fed with, or allowed the opportunity of eating, the offal of slaughter-houses, nor should pigs be kept there. The laws against unregistered dogs should be strictly enforced.

It should be known that hydatid disease can be communicated to the human subject by impure salads or vegetables (uncooked), and care should be taken to wash and thoroughly cleanse everything of the kind before it is eaten. Water-cress from drains should never be eaten. Fluke in sheep is another source of danger, and such mutton should be carefully avoided.

Further, it should be known that there is risk of contracting the disease in allowing dogs to lick the hands or faces of children or adults, and in permitting them to lick plates and dishes.

In all this, as in many other cases, "cleanliness is one of the most important preventives against infection."

I have the honour to be, sir, your most obedient servant,

J. W. COLVILLE, *Secretary.*

The Secretary, Local Board of Health.

THE TÆNIA ECHINOCOCCUS.

THE adult tapeworm is found in large numbers in the upper portion of the small intestine of the dog. Panceri has also observed it in the Egyptian jackal, and Cobbold in the Russian wolf. Kuchenmeister has advanced the hypothesis that man himself might be the presumptive host of the Tænia; he also held the view that the human Echinococcus was specifically distinct, and might be found "in the intestines of those individuals who suffer, or have suffered, from the corresponding species of Echinococcus in any part of their body, and in whom one of these Echinococci has opened into the intestine."

Kuchenmeister's hypothesis has received no actual confirmation, and Leuckart adds that "we may confidently leave it to the future to discover whether the Tænia Echinococcus is found in the intestines of Australian shepherds, or of the inhabitants of any district where the Echinococcus disease is epidemic."

The opportunities that occur for their development in the human subject are not rare, as, for example, when hydatid cysts, from ulceration through pressure, rupture and discharge their contents into the alimentary canal, or in the case of pieces of pulmonary hydatid, which are often swallowed in imperfect expectoration.

It is hardly conceivable that such a pathological

condition as the presence of innumerable Tæniæ Echinococci in the human intestine should have escaped observation. I have frequently examined scrapings from the mucous membrane of the intestine in cases where a hydatid cyst had burst into the alimentary canal some considerable time before death, but without result.

Davaine cites forty cases of hydatids which had opened into the intestine, and in none of these could he discover traces of the tapeworm. The same author refers to forty-five cases that opened into the bronchi, where the contents had been expectorated, thus affording ample opportunity for innumerable scolices to be swallowed. There was no evidence of the Tænia.

The Tænia Echinococcus, when sexually mature, never exceeds a quarter of an inch in length. It consists of three to four segments, of which the last exceeds all the rest of the body in size. The head is extremely small and possesses a prominent crown which surrounds the bulging rostellum. The rostellum bears two rows of hooks, numbering from fourteen to twenty-five each, which are rarely found in a perfect condition. The hooks may differ considerably in appearance even in the same worm. They are distinguished by the thick and solid character of their root processes. The hooks of the inner series are the larger, the claw is slender and strongly curved. The outer series are not only smaller in the claw, but the root processes are much thinner, and altogether less powerful.

These hooks have very considerable strength, owing to the stout and broad character of the root processes, and the deposition of carbonate of lime in their substance. In the scolex the hooklets have the same shape and appearance as those of the *Tænia*, but the root processes in the former are but slightly developed.

The head of the tapeworm is furnished with four suckers, below which is the constricted neck, which passes without any visible boundary into the unsegmented anterior part of the body.

The first segment is only very slightly marked off, and is about the same breadth as the anterior portion of the body adjacent to it; its length is about equal to its breadth. In the second segment the breadth is doubled, and the length is increased four times; in it the male and female reproductive organs can be distinguished. The third and last segment contains the ripe ova, from which hydatid tumours are developed. One segment may contain ova to the number of 500 and upwards.

Before the last segment containing the ova is voided another segment appears, so that for a time four segments or proglottides are to be observed.

The peculiarities of the sexual organs of this parasite are so marked as compared with those of other tapeworms that Leuckart maintained that this special character alone justifies the independent position claimed for it. His minute description of the generative system is given as follows:—

“*The Male Organs* strike one by the unusual size of the cirrus pouch, which measures almost 0·5 mm.,

and, by its club-shaped, thickened posterior end, reaches to the middle of the newly fertilised joints. The cirrus itself has apparently a greater independence than is the case in the other cystic tapeworms. It lies in the anterior portion of the cirrus-like pouch, like the glans in the præputium, and is not unfrequently protruded. Sometimes it is found in the act of copulation. The sexual cloaca is destitute of a proper papilla, the penis itself is bent into a sort of hook shape, and is sunk into the anterior end of the adjacent vagina.

“ Before its entrance into the posterior end of the cirrus pouch the vas deferens makes several irregular coils, which are mostly distended with spermatozoa. In the testes, too, the spermatozoa are readily recognisable, since they possess an unusual length and thickness. They are usually seen rolled up in coils, and can sometimes be observed passing into the thin efferent canals of the testes. The size of the testes is quite appreciable, averaging about 0·07 mm., and their number is proportionately reduced to about sixty.

“ *The Female Organs.*—The vagina is characterised by a longitudinal enlargement (with a transverse diameter of 0·05 mm.) in the middle of its course. In this there can be seen a yellow chitinous lamella, with numerous points directed outwards. . . . Its posterior end leads to a distinct bladder (0·014 mm.), whose contents consist of spermatozoa—in other words, a receptaculum seminis. Opposite the opening of the vagina there rises from this receptaculum a fertilising canal of appreciable width, and distinguished by the double contour

of its walls. After a short course this divides into two narrower ducts, of which the one trends forwards, while the other continues the original course backwards. The former of these two canals is the oviduct, whose upper end is connected as usual with the two ovaries.

“The cæcal tubules which form the glands are short and wide, and so slightly separated that the ovaries look more like lobulated sacs than acuniform glands. Internally the eggs may be recognised as sharply defined balls, about 0·01 mm., in size. The second canal divides further down into two ducts, one of which enters the simple sacular yolk gland, while the other is probably in connection with the uterus. The latter appears from the first as a wide cavity. It is sometimes late before it is distinguishable, namely, after the ovaries have liberated their contents, and, like the yolk glands, have disappeared.”

The *Tænia Echinococcus* attaches itself between the intestinal villi of the dog, where it is sometimes present to the number of many thousands. The milk-white proglottides are visible to the naked eye, and in warm intestine they exhibit elongating and shortening movements after the manner of the leech.

The length of time that the worm lives is not quite determined. Von Siebold thought that it did not survive two months, but his opinion is rejected on the ground that it is against all analogy to suppose that the productivity of the worm is exhausted after throwing off one or two proglottides, besides the thick character of the roots of the hooks suggests a greater

age. The fact that this parasite is found much more frequently in the older animals would seem to point to the probability that the *Tænia* lives much longer than Von Siebold believed.

The scolices, or brood-capsules, taken from a hydatid cyst in man, or in any of the lower animals that harbour them, readily develop into the mature worm when swallowed by the dog. This has been often demonstrated by experiment, and, of course, constitutes the chief source by which dogs become infected. According to Von Siebold's experiments the metamorphosis from the head or scolex into the tapeworm takes place with great rapidity. "Fifteen or twenty days after feeding dogs with hydatid material he found in most of the heads a two-jointed body, while others were still without segmentation. Thereafter three joints appeared, and some days later (on the twenty-seventh after feeding) some hard-shelled eggs with embryos were found in the last joint.

"Van Beneden also saw ripe *Tæniæ* developed from the *Echinococcus* heads within four weeks after feeding, while Kuchenmeister, who experimented at the same time as Von Siebold, discovered no ripe forms for eight to nine weeks. In my experiments I did not find mature worms till the seventh week. Zenker, even eleven weeks after feeding, found them perfectly developed as regards size, but still without eggs. In the feeding experiments of Naunyn, Pagenstecher, and Nettleship, seven weeks were also required for the attainment of maturity." ¹

¹ Leuckart, *Parasites of Man*. Translated by Hoyle, 1886.

Numerous animals have been experimented on with a view to ascertaining whether any besides the dog can readily harbour this *Tænia*. With the exception of the jackal and wolf, already referred to, I am not aware of its having been found in any other animal. Leuckart experimented in vain with rabbits, Von Siebold with a like result on the fox, which also belongs to the genus *canis*; nor has the domestic cat been found to be adapted for the rearing of the parasite.

Scolices from hydatid cysts of man produce in the dog's intestine exactly the same species of *Tænia* as is developed from the scolices of hydatids of the lower animals, although Kuchenmeister—holding the view that hydatid tumours in man, as distinguished from those of animals, were different species, to which were applied the names of *Echinococcus hominis* and *Echinococcus veterinorum*—was of opinion that the *Tænia* was different. His feeding experiments, together with those of Zenker and Levison, seemed at first to favour this particular view, as the scolices from human hydatids yielded negative results when given to the dog. It has been pointed out, however, that the fallacy probably arose from the nature of the material used, for when obtained from the human subject it is hardly likely to be as fresh as when obtained from the recently killed ox or pig; besides it is not every dog that is suitable for the rearing of the parasite.

Positive results, however, have been obtained by Naunyn, Krabbe, and others. In one dog to which

Naunyn gave hydatid fluid, obtained from a human liver by tapping, he found Tæniæ thirty-five days afterwards measuring from 3 to 5 mm., in length, and with eggs in their terminal joints. Krabbe thrice obtained positive results in his experiments. In each case the animals were young, and had lived under conditions which excluded the possibility of their having been previously infected.

It is stated by Leisering that the Tænia Echinococcus, if occurring abundantly in the intestine of the dog, sometimes occasions external symptoms like those of hydrophobia. In Australia, where hydrophobia is, fortunately, as yet unknown, I am not able to confirm this statement, nor am I aware of anything peculiar in the behaviour of the dogs that are known to harbour large numbers of the parasite.

THE HYDATID CYST.

THE hydatid cyst, in its early stage, has been fully described by Leuckart from his experiment on the pig, an animal readily infected with hydatid disease. He found, four weeks after the feeding with ripe proglottides, some small points resembling tubercle in various places under the serous covering of the liver. They had a thick homogeneous, transparent capsule, with coarse granular contents. The lamination of the wall was indistinct, though their physical nature was identical with that of the more mature forms. They were expansile and elastic, so that their diameter could be increased on pressure to twice their real size. The connective tissue enclosing the young hydatid was everywhere in direct continuity with the connective tissue of the liver. In all cases the interlobular tissue contained the parasites. In the case of a pig killed eight weeks after the feeding with proglottides, he found the liver studded with cysts double the size of the first; the hydatids were distributed on both surfaces of the organ under the serous covering. The average diameter measured 1.5 mm., and they shone like clear drops. This greater transparency, as compared with those of four weeks' growth, was due to the commencing liquefaction of the contents. At this age they were really

bladders, which collapsed on being pricked, and voided transparent fluid. The cuticle was distinctly lamellated, though the lamellæ were not completely defined. An inner membrane adjoining the cuticle had some cellular structures visible throughout its granular substance, and in some the cells had a definite arrangement, the larger of them, lying most internal, having a clear nucleus and a stellate ramification. Cysts were next examined at the age of nineteen weeks; they measured from 10 to 12 mm., in diameter. In this case they were also situated beneath the serous covering of the liver, some pushing the covering before them, so that they were only partially embedded in the liver substance. The capsular wall of the parasite was thick and firm, contracting powerfully when cut, and it was also separable from the liver. When the hydatid was removed from its outer covering, it appeared as a round and transparent bladder of fluid, which flattened on being placed on a firm surface, proving that its walls were yielding and of an elastic nature. The outer surface of the bladder was broken at different places by rents and fissures, as though the external layers had yielded from overstretching. On cutting the bladder wall the edges curled in upon themselves, thus showing that the inner layers were more contractile and elastic than the outer. The lamination was evidently due to the successive deposition of layers, the lamellæ being more marked from within outwards. At this age the cysts were still without brood-capsules and scolices.

The granular structure which lies under the cuticle

is known as the parenchyma or the endocyst of Huxley, and constitutes the essential vital part of the animal. From a side view, in fresh specimens, it is seen to consist of two layers, an outer and inner. The inner layer shows the presence of some cellular structures, some of which are clear and sharply defined, and having a distinct lustre. The outer layer is much more granular in its character. The refractile corpuscles of the inner layer are found of varying sizes. According to Huxley, "these corpuscles appear to be solid, but by the action of dilute acetic acid the interior generally clears up very rapidly, and a hollow vesicle is left of the same size as the original corpuscle. No gas is developed during this process, and sometimes the corpuscles are not acted upon at all by the acid, appearing then to be of a fatty nature. A strong solution of caustic ammonia produces a concentrically laminated or fissured appearance in them. Under pressure, and with commencing putrefaction, a number of them sometimes flow together into an irregular or rounded mass." These corpuscles are supposed by some authorities to take a share in the future development of daughter-cysts.

The presence of a vascular system has not been shown to exist in the hydatid. The cellular layer of the parenchyma, in some cases, seems to have a system of anastomosing cords, which Naunyn considered to be probably of the nature of vessels. However, further examination showed them to be solid homogeneous bands, and are not present in all cases. Their exact physiological significance is not known.

The cuticle of the hydatid has great capacity of imbibition; if the bladder be placed in a coloured fluid, the space between the cuticle and the parenchyma is immediately coloured, while the fluid of the interior remains clear for some time.

As the cyst increases in size, the cuticle would seem to share in the increased growth more than the parenchyma; the lamellæ also increase in thickness, and become more sharply defined. The fibrous covering of the hydatid likewise increases in thickness with the growth of the cuticle; it is often found of a thick, tough, firm nature, five to ten times as thick as the bladder wall, and is freely supplied with blood vessels, which, in some cases, are large and tortuous. The inner surface of the fibrous Ectocyst is generally smooth, and has a thin granular layer, which, after the removal of the cyst, is only seen in patches. This granular layer is as firmly attached to the wall of the cuticle as it is to the Ectocyst, and probably serves as a means of attachment between the two.

The hydatid cyst attains its full development by the formation on its inner surface of small vesicles called brood-capsules, which give origin to the characteristic heads or Scolices.

The brood-capsules are developed from the parenchymal layer of the cyst wall, and the bladders have attained a diameter of about 15 to 20 mm., before the heads are found, and from actual experiment it has been observed that the cyst takes at least five months before it reaches this size.

The limits to the growth of a hydatid cyst have not yet been determined. It may attain to such a size that it is alone arrested by the death of its host ; on the other hand, it may retain its vitality for many years, even when its growth apparently remains stationary.

Hilton Fagge quotes the case of Reynal and Dr. Budd, the former of whom met with a tumour of the neck, which had existed for forty years, and when punctured gave issue to an immense number of hydatid cysts, all apparently living ; and the latter met with the case of a lady, who died at the age of seventy-three, who was believed to have had two hydatids since she was the age of twenty-eight years. Another case is referred to by the same author of a large hydatid tumour, the first symptoms of which had been observed thirty years before. Velpeau had under his observation a case of hydatid in the axilla of a young girl, and which had only attained the size of a small nut six months from the time she first noticed it.

Barrier collected twenty-four cases with good data to test their duration from the first symptoms. He found that it was less than two years in three cases, four years in eight cases, six years in four, eight years in five, and thirty years in one.

It is difficult, however, from mere clinical observation to state even approximately the rate of growth of hydatid cysts, or to judge of their age from the size they have reached. It is no uncommon answer to the question which patients give when asked how long

they have noticed the hydatid swelling, for the treatment of which they have sought advice, for them to reply that the tumour had not increased, as far as they could judge, for several years, or that it had increased but very slightly. It has to be borne in mind that the increase in size may be so insidious, and its development cause no appreciable disturbance to the health of its host, that the size may have considerably increased without the patient actually being aware of any altered condition.

The growth of a hydatid cyst is not only slow, but its increase in size varies with the nature and position of the organ attacked. It will be found often of a large size in those parts of the body that can offer it the greatest space for its growth, and where the surroundings are soft and yielding. Thus they often do attain a very large size when growing from the under surface of the liver, where the yielding character of the abdominal wall and the easily displaced intestine make room, as it were, for the growing cyst. In such a region as the medullary cavity of a long bone, the hard, dense surroundings and limited space, must greatly retard its growth, while, on the other hand, when it develops in the brain it will bring about the death of its host before it has attained to any great size.

The experiments already quoted, where the hydatid in a pig reached the size of a hazel nut in five months after the ingestion of the embryo, do not afford us sufficient data from which to calculate the age of hydatids in the human subject with anything like

mathematical precision, for in the herbivora hydatids do not reach the large size that they so commonly do in the human subject.

The hydatid cyst may be found dead at all stages of its development. It is not always easy to determine the cause that arrests its growth and brings about its death.

The cyst and its contents may be found degenerated into a solid caseous mass, showing only amorphous *debris* and hooklets under the microscope. Some cysts filled with daughter bladders may be found, presenting an appearance similar to dried figs packed in a box. The contents of a dead cyst is often found to be thick, tenacious, colloid material, which cannot be made to flow through a large-sized canula. The hydatid may become converted practically into a circumscribed abscess.

Berthold found in the case of a hydatid situated in the lung of a dromedary, a calcareous shell with two distinct layers, the outer composed of phosphate, and the inner of carbonate of lime. In the case of a *post-mortem* examination made on the body of a young man who met with a sudden death from an accident, there were found in the under surface of the liver four cysts undergoing degeneration; the largest of the cysts was the size of an orange, and wholly embedded in the liver substance, its wall was impregnated with lime salts, and the contents were of a greyish thick jelly-like material. The other cysts were smaller, and situated in the serous surface of the liver, and filled with white pultaceous matter.

The hooklets in each case were quite distinctly seen under the microscope, and had not lost any of their characteristic appearance.

These forms of degeneration constitute a process of cure which render the parasite perfectly inert. I have noticed complete calcareous degeneration in small hydatids in the lung, which had given rise to no pulmonary symptoms during the patient's life.

The hydatid cyst will generally be found to have undergone degenerative changes when bile is present in the cyst contents, and the frequency with which this has been noticed has led to ox bile being injected into the hydatid with a view of causing its death. Such a method of treatment has not met with much favour, neither can any special advantage be claimed for it. It is liable to result in suppuration of the cyst contents, and to necessitate more radical measures, when the condition of the patient is not so favourable as it otherwise would have been if suppuration had not been set up.

The cause of degenerative changes met with in some cysts is not known. It probably is to be found in the condition of the organ in which the hydatids are situated. It has been noticed in the case of cattle that where the cysts were found degenerated, the cellular tissue immediately underlying the bladder wall was in a state of cloudy degeneration.

The process of decay and subsequent quiescence may result from overcrowding of the daughter-cysts, although the mutual pressure and resistance that they are capable of, is very remarkable. This can be often

observed in cases of large hydatid cysts which contain a great many secondary bladders, when an incision is made into the parent hydatid the contained progeny come bounding out of the opening with great force. Degeneration of the parent cyst wall, caused by the pressure of the daughter-cysts, is not so frequent as is generally supposed. The real explanation is probably to be found in the structural changes of the fibrous ectocyst, which affect the coverings of the vessel and the nutrition of the cyst wall and its contained progeny.

Pressure of the daughter-cysts does certainly sometimes lead to destruction of the parent cyst wall, for cases are often met with where the daughter-bladders are healthy, but where the original cyst wall has partially or completely disappeared, and where the hydatid fluid contains evidence of the granular *debris* resulting from degeneration of the parent wall.

Sir Thomas Watson (*Practice of Physic*), referring to the degeneration of hydatids from the pressure effects of the contained progeny, says that—"Sometimes the colony perishes while yet hid in its dwelling cave, all the enclosed hydatids losing their vitality, and shrinking up as their fluids are absorbed. It may be that they increase in number and in size, till the crowding and pressure prove fatal to them, their former domicile now becomes their tomb, and effectually precludes any contamination of the fluids of the body, or irritation of surrounding textures by their remains."

Dr. Kelly, in an article on the spontaneous cure of hydatid cysts, published in the *British and Foreign Medico-Chirurgical Review* for 1869, describes at

length some of the causes that lead to the death and degeneration of hydatids. He thinks that in some cases the fibrous ectocyst becomes so tense and thick as to be unyielding, and the walls of the parasite, growing out of all proportion to its coverings, fall back in folds into the space which contains the fluid. Nutrition in this way becomes seriously altered, from the vessels in the ectocyst becoming partially or wholly obliterated by the contracting of the fibrous tissue. Chemical and physical changes then take place in the cyst wall, fatty degeneration, with the deposition of cholesterine and lime salts. The increase of the fibrous tissue of the ectocyst, which brings about these degenerative changes in the hydatid wall, may result from inflammatory irritation adjacent to it. I have noticed in the case of small degenerated cysts in the lung, where the ectocysts as a rule are not very thick, and may even be wanting, that the lung substance around them was indurated, as if it had been the seat of inflammatory trouble.

The idea among some of the early investigators that there were several distinct species of hydatids, led to the introduction of different names, which are now occasionally made use of. Thus, Rudolphi accepted two species, — *Echinococcus hominis* and *Echinococcus veterinorum*, the former containing daughter-cysts and found in man, while the latter were only supposed to occur in the herbivora, and did not contain any progeny. Kuchenmeister supported this view, but changed the names into *Echinococcus altricipariens* and *Echinococcus scolecipariens*.

This distinctive classification, however, has now been abandoned, for not only have the various forms been proved to be one and the same species, but both are commonly found together in the same subject. The fact that scolices or brood-capsules are found in some cases and not in others, simply means that different circumstances of environment have affected their special character and development.

The term *Acephalocyst* was first used by Laennec. In some cases which he examined, he could find no traces of the presence of scolices; for this reason, he considered that this form also was the representative of a distinct species. Cysts in the acephalocystic condition are, however, far from being rare, and when situated in the brain, they are nearly always acephalic; the bladder wall shows no difference in structure or appearance from those which are fruitful, and the sterility, which is their only point of difference, is to be accounted for either in the inherited debility of the embryo, or in the surrounding tissues, which probably do not furnish the suitable nourishment.

The scolices or heads are developed from within special minute vesicles, called brood-capsules, which are developed from the inner surface of the bladder wall. The length of a scolex, when fully extended, never exceeds 0·3 mm. It is of a solid consistence, and cylindrical in form. The egg-shaped posterior portion is furnished with a muscular stalk, which attaches it to the wall of the brood-capsule; the depression, which shows the position of the stalk, is marked even when the scolex is separated from its basis. The anterior

portion bears the armed rostellum and the four suckers, and is usually separated from the posterior part by a narrow constriction. There is little differentiation in the parenchyma of the body. In the posterior portion specially there may be noticed numerous calcareous bodies, which effervesce on the addition of acids, and in favourable specimens four longitudinal coiled vessels can be noticed, which anastomose below the hooks. The anterior portion of the scolex, with the crown of hooks and suckers, is generally seen under the microscope to be invaginated into the posterior part.

The brood-capsules, from which the scolices develop, originate from the bladder wall of the hydatid cyst. The membrane of the brood-capsule, though extremely thin, has a distinct histological structure. The capsules are regarded as invaginations of the bladder wall, this view being supported from the fact that their layers have an exactly opposite relation to those of the hydatid. The cavity is lined with a clearly defined cuticle, the outside being a thin layer of granular cells. Though apparently devoid of muscular fibres, they may exhibit peristaltic movements, which originate from the point of attachment. Certain portions of the cyst wall often develop more brood-capsules than others. The capsule increases in size in proportion to the number of the budding heads, and fifteen to twenty scolices may be contained in one brood-capsule.

It was Von Siebold who first discovered that the scolices were contained in special capsules, and he also

held the view that there were other scolices in the same cyst which developed directly from the hydatid wall. It was further held by many authorities that the attachment of the scolices to the cyst wall or brood-capsules was only temporary, and that they finally separated and burst through the wall of the capsule, or left their fixed points on the parent cyst, and wandered freely for a time in the hydatid fluid, still retaining their vitality. Leuckart's view seems to me to be the correct one, that "all the parts of the echinococcus (mother, brood-capsule, and head) are throughout life in direct continuity with each other. I do not deny," he adds, "that one may often observe burst brood-capsules and isolated heads, but I have only observed these conditions in encysted worms which were investigated some time after the death of their host. If the worms were fresh, I found without exception the condition I have described; the heads all within their brood-capsules, and all of these attached to the inner wall by means of a small stalk. But if the worm were exposed to the influence of external agents, or the parenchyma brought into contact with water or any other diffusible fluid, the appearance altered, inasmuch as the brood-capsules burst and the heads contained in them became free. The latter were either detached at once or remained for a time in connection with the shrivelled and rolled up wall of the capsule, and were united in groups, which were attached to the parenchymal layer by the stalk of the capsule."

Naunyn and Rasmussen maintain that the scolices

originate from the inner surface of the brood-capsule, being from the first solid processes. Leuckart, on the contrary, considers that they make their appearance from the outer surface, and in their rudimentary form are hollow. Huxley maintained that both surfaces were equally well adapted for the development of brood-capsules.

The development of the scolex is first noticed as a discoidal thickening, quickly becoming club-shaped, its long axis being perforated with a hollow process of the brood-capsule. In its rudimentary stage the scolex has great power of contractility, being capable of shortening itself to half its real length. It may be seen swinging to and fro from right to left like a pendulum. The hooks appear first as a thick fringe of prickles, at the distal or cephalic end; as the head develops they all disappear, except the foremost row, which increase in size. They are subsequently retracted along with the sucker portion into the posterior part of the head. The hooks resemble in appearance those found in the tapeworm, the only difference being in the slender character of the root process. The brood-capsules when fully developed may attain the size of 1.5 mm., in diameter. They are sometimes to be seen by the naked eye as minute white specks floating in the clear fluid removed from a hydatid cyst.

They are first noticed developing as minute elevations in the cellular layer of the parenchyma. According to Naunyn, they are possessed of cilia, which often persist even when the capsule has reached

maturity. A small cavity is soon recognised in the interior, which is lined with a cuticular layer. The first scolex to appear is usually found opposite the point of insertion of the capsule. In a brood-capsule filled with scolices one or more of the heads are often found separated from their vital attachments to the capsule; these dead scolices are easily recognised by the dark brown colour which they assume when lying free for any length of time in the capsule.

Daughter-cysts are usually found in the interior of a parent hydatid, and often in very large numbers. The sizes to which they attain, even in the same cyst, are very variable. They may be found from the size of a pea up to that of an orange, and even larger. The presence of cysts within daughter-cysts—the so-called granddaughter-cysts—is occasionally to be met with, although this condition is not common. The number of daughter-cysts met with in a parent hydatid is also very variable. Frequently I have noticed only two or three in very large cysts, and very often they could be counted by thousands. Some writers seem disposed to discredit the presence of as many as thousands of daughter-bladders being found in one cyst; but such a large number in one hydatid in the human subject is by no means a rare occurrence. In the specimen represented in Plate III., I counted as many as eight hundred, and I have seen cysts in the abdomen ten times as large and equally as densely packed.

There is no authentic case of a hydatid smaller than a walnut containing daughter-cysts. Plate XXV.,

represents two small hydatids in the lung, packed with daughter-cysts all dried up, where the whole tumour did not exceed an inch in diameter.

In shape and structure daughter-cysts correspond to the parent hydatid. Continual pressure in some cases, where they are numerous and closely packed, may give them a slightly flattened appearance, or from the same cause they are sometimes found furnished with facets, which indicate the spots where two or three have become adherent. In cases of great crowding many are often found collapsed; the walls of the cysts which have burst in this way break down into fine granular *debris*, or they are found in their collapsed state to be soft and friable, having lost their pearly white colour.

The daughter-cysts are developed in different ways, either direct from the parent cyst or from the brood-capsules and scolices which undergo changes by metamorphosis. They may be found lying sometimes outside the parent cyst. Hydatids which develop their progeny so as to enable them to lie outside the cavity, and in some cases to be apparently free, were thought by Kuhn to represent a distinct species, which he named "Echinococcus Exogena," in contra-distinction to those which contain the daughters within the parent cavity, "Echinococcus Endogena." The term Echinococcus Granulosus has also been applied to this form. The so-called exogenous cysts are found occurring commonly in the domestic herbivora. Occasionally they are met with in the human subject, specially in such regions as the medullary cavities of bone, and under

the peritoneal covering of the abdominal wall. They have also been found in the liver, lungs, and spleen. Daughter-cysts forming in this exogenous way are seen to develop as bud-like out-growths from the parenchyma of the parent cyst-wall, which push the adjacent layers apart, and enlarge by the repeated deposition of the cuticular layers. They pass through the same changes as have been noticed in connection with the growth of the parent hydatid. The more the daughter-cysts grow the more does the attachment become attenuated, until it is set free. It may lie at first in the lateral pouch of the parent cyst, but in course of time it acquires a distinct partition separating the parent from the daughter. It is sometimes difficult to distinguish which is parent and which is daughter, their size and appearance being the same. One essential difference is that daughter-cysts develop brood-capsules at an earlier date than the parent hydatid.

The *Echinococcus Endogena* is the most common form met with in the human subject, and it usually attains a size very much larger than the exogenous hydatid. Daughter-cysts which lie within the parent cavity are developed in different ways. Bremser, Von Siebold, and Wagener were the first to assert that these daughter-cysts arose from changes that took place in the scolices, and Naunyn and Rasmussen first furnished a detailed description of the changes by metamorphosis, which resulted in the transference of heads and brood-capsules into cysts. Rasmussen was of opinion that the brood-capsules and not the scolices

were capable of becoming transformed into the typical endogenous cysts, while Naunyn and Leuckart showed that the scolices also took their share in this special work.

There are hydatid cysts filled with daughter-bladders occasionally met with, in which no trace of heads can be found, and Helm, who specially investigated this point, sufficiently demonstrated the occurrence of such a form as to leave no doubt as to its being occasionally met with. Leuckart accounted for the presence of this form of hydatid by supposing that the cyst was either unable to develop the scolices, or that the brood-capsules had passed into the cystic stage before the heads had had time to appear.

In the endogenous form, Naunyn proved that the daughter-cysts sometimes originated directly from the cyst-wall, apart altogether from the other constituent portions of the hydatid from which they are known to arise. This process consists essentially in the sacculation of the parent wall: the hydatid loses part of the fluid, and folds of the membrane come together so that the surfaces coalesce. "When this contact, as often happens, leads to coalescence, a portion of the parenchymal sheath separates like a fold from the covering of the echinococcus bladder, and the portion of the parenchyma thus separated forms the starting point of the new formation. First of all, it is changed by flattening and disappearance of the internal cavity into a band, which in its turn generally breaks up after a short time into a number of pieces. These become surrounded by a system of

concentric cuticular lamellæ, and, becoming hollow inside, form so many new hydatids."

I have noticed on several occasions what Eschricht and Leuckart have pointed out as sometimes occurring in connection with this mode of cyst formation, namely, cauliflower-like excrescences containing hollow spaces situated in the wall of the parent hydatid. These are cysts formed by this mode, which have become arrested in their development.

The scolices, which undergo the change by metamorphosis into cysts, may sometimes be found before these changes are complete, lying either free in the parent cyst cavity or in the centre of a brood-capsule, before they burst through its walls. They are more transparent in their appearance than the unaltered heads, and show in the posterior part of the body a cavity containing clear fluid; fibrous bands enclosing vessels are also seen running through it towards the head. On the inner surface of the body there are seen fine thread-like bands, in the form of a network, proceeding from the anterior end. Some of the thicker fibres enclose clear drop-like bodies. The outer covering is formed of a cuticle, which becomes laminated as the body increases in size.

The internal cavity passes from the posterior to the anterior part of the body, the suckers disappear, and the fine network spreads itself over the wall of the body as a delicate layer. The hooks gradually disappear, and when the cyst has attained the size of a millet seed, the former head is indistinguishable from a young hydatid.

The transformation of the brood-capsules begins in the hyaline membrane. When this has become laminated it is set free from the parent wall, the superficial parenchyma disappears, and a new one is developed from the substance of the heads, which are seen attached to the cuticle, and, losing their form, become distributed over the inner surface. The hooklets gradually disappear, and the former brood-capsule becomes a perfectly formed hydatid.

THE ECHINOCOCCUS MULTILOCULARIS.

THE special form of hydatid tumour which is known by the name of *Echinococcus Multilocularis* has not yet been observed in Australia.

It was first described in Europe by Buhl in 1852, and shortly after by Zeller and Professor Luschka. In its physical characters it appeared to resemble a malignant or other neoplastic growth, and nothing suggested at first that it was of the nature of a hydatid tumour. Virchow, in 1855, was the first to describe its real pathological nature, and subsequent observers, as Carrière and Marie Prougeansky, of Zurich, confirmed Virchow's opinion from a series of cases which came under their own care.

This form is found chiefly in man. Huber, in 1861, described a case occurring in the ox, which was growing along with some other ordinary hydatid cysts.

It is found of different sizes, from a pea up to that of a fist or child's head, and is usually situated in the liver. In consistence it is hard and firm, and on making a section through the tumour-mass a well-marked fibrous stroma is seen enclosing spaces filled with clear, gelatinous contents.

The liver tissue entirely disappears in the part where the tumour has developed, but round the periphery of

the *Echinococcus Multilocularis* the liver substance is usually clearly defined.

Sometimes white bands are seen passing from the tumour into the adjacent liver tissue, and these become new foci of this special form of hydatid. It has a peculiar tendency to ulceration, the degenerative changes taking place in the stroma. This ulcerated appearance gave rise to the belief among the early observers that these tumours were of the nature of colloid growths, and the term of alveolar colloids was applied to them. Before the correct description of this form appeared the presence of hydatid elements which were noticed in them were not regarded as of any special importance.

Virchow explained the special mode of development in the multilocular form by supposing that it resulted from repeated external proliferation, the cyst in the first instance developing in a lymphatic vessel. Subsequent observers have shown that they do not always select the lymphatics for their seat of growth, but are to be found originating in other parts of the liver. The spaces lying in the stroma vary in size, the largest measuring from 3 to 4 mm. They are filled with soft, gelatinous material, which the microscope shows to consist of hydatid membrane, with the usual laminated structure. In some cases the cuticle is very thick, but in others it exhibits the usual variations common to young *Echinococci*.

There is usually an absence of scolices in this form of hydatid; but in one case investigated by Marie Prougeansky the various cysts found in the spaces

enclosed by the stroma were remarkably fertile. "The smallest bladders usually contained only one head, which almost filled the whole interior, but others contained several, which were sometimes of normal structure, and at other times had lost their hooks, and had become calcified. Besides the heads there were in the alveoli laminated calcareous corpuscles and red hæmatoidin crystals, and occasionally also accumulations of yellowish-brown bile pigment."

The bladders found in the loculi are rarely of a regular and spherical shape; some are found to be indented and folded, while others are constricted in the middle, or have protrusions of varying sizes, which give them a racemose appearance.

Kuhn described a racemose form of hydatid which he found in cattle where the protrusions attained an average size of 1 mm. A similar form is described by Leuckart, where he states that "the protrusions together enclosed a single individual hollow space, although the communication was, in many cases, effected only by means of a narrow canal. If," he adds, "one thinks of this *Echinococcus racemosus* as enclosed in a common thick stroma, in which the individual protrusions have each their own alveolus, it is seen that the only difference between it and the *E. Multilocularis* is in regard to the size of the separate parts."

The resemblance of the racemose to the Multilocular form strengthens the supposition that the latter originate primarily from single bladders, and not from a number of isolated *Echinococci*. The separated

bladders in the *Echinococcus Multilocularis* do not appear to be connected with each other, although Virchow and Leuckart are both clear on the point that upon the surface of the bladders small sprouts or appendages were noticed, which proved to be continuations of the parenchyma and the cuticle of the mother. The terminal portions of these sprouts become developed into daughter-cysts, subsequently becoming constricted, and acquiring a free existence. The new bladders thus formed were soon enclosed in a separate space, causing it to appear as if they had originated within it.

The *Echinococci Multilocularis* sooner or later cause the death of their hosts.

GENERAL SYMPTOMS OF HYDATID DISEASE.

A HYDATID tumour in itself is a painless affection, and may develop to a considerable size before the patient's attention is drawn to it. Plate XIV., is a diagram of a patient who had never sought medical advice till the tumour had assumed enormous proportions.

It is surprising how large the cyst may grow without producing any appreciable disturbance in the condition of the host. In the abdomen, for example, the cyst may extend from liver to pubes without any pressure symptoms arising; in fact the hydatid cyst of the abdominal cavity is noticed so often to avoid pressing the large vessels that I look upon the presence of dilated veins in the abdominal wall as weakening rather than strengthening the diagnosis of hydatids.

The symptoms indicating their presence must be naturally very manifold, and their symptoms and prognosis must depend entirely on the organ and seat of their growth.

The larger they grow the greater the risk to the surrounding tissues of the organ in which they are embedded, so that the symptoms arising from the pressure effects may be the first indication of the presence of the parasite.

Thus, pressure on the bile ducts, and the jaundice resulting, is not uncommonly the first sign that tracks their presence in the liver; and a short hacking cough and an attack of hæmoptysis may first lead to their discovery in the lung. In the eye they are early detected from the loss of sight they produce.

They are free from pain in themselves, unless they involve by their presence some branch of nerve; pain, however, may be the only symptom in some cases that leads to the discovery of their existence. A young woman came under my care for a persistent pain under the free margin of the ribs on the left side. The part was extremely tender to the touch, and the condition had been more or less constant for over a year. There was no apparent bulging, but on putting my hand under the ribs and making her take a deep inspiration I felt a cystic tumour descend. On inserting the aspirating needle I drew off one pint of clear fluid containing scolices and brood-capsules; her pain quite disappeared. In another case a man, aged 35, sought relief for severe intestinal hæmorrhage; he succumbed to the exhaustion which followed. The *post-mortem* examination showed the hæmorrhage to be the result of continued pressure of a hydatid tumour on the portal vessels.

Patients as a rule are quite ignorant of the nature of the swelling from which they suffer, and being free from any degree of pain, and their general health often not in the least affected, they are content to leave well alone until some complication arises. Recently a

patient informed me that for several months past he had found a swelling over the region of the right kidney appear and disappear, followed each time by copious micturition of a brownish colour, with long, shreddy strings of white material. The microscope showed that he was passing hydatid *debris* from a cyst in his kidney, which kept re-filling from time to time, the contents passing *per urethram*.

Occasionally there is developed a condition of cachexia, even when the cysts are found quite healthy at the operation. The patient loses flesh and strength, has some pyrexia and loss of appetite, and a moist, clammy skin. The condition is specially noticeable in cases where the abdominal cavity is crowded with daughter-cysts.

Where suppuration has followed some inflammatory action there may be rigors, fever, and great exhaustion. The hydatid may even practically destroy a whole organ in those cases where its function can be relegated to another, as, for example, the kidney and the lung, without the patient's being aware of anything unusual. Plate IV., represents a case where the whole of the right lobe of the liver was replaced by a single cyst, and the left lobe hypertrophied to twice its normal size. When the hydatid is situated in a vital organ, as the heart or brain, the patient may die suddenly, without any previous symptoms. A dull, heavy feeling is sometimes experienced by patients in whom a hydatid of the liver is not distinguishable by its size. In the case of a patient, aged 30, who came

under treatment for hæmorrhoids, he complained of a feeling of fulness, with pain in his right shoulder, and a dull aching over the liver. A small aspirating exploratory needle drew off several ounces of hydatid fluid.

DIAGNOSIS OF HYDATID DISEASE.

THE diagnosis of hydatid disease is only positively established by an exploratory puncture. The presence of a tumour with a globular and cystic feel, slowly growing, without general constitutional disturbance or pain, would point to the probable existence of a hydatid, but they so often do not exhibit even these symptoms that one must be careful in committing himself without some actual proof.

A patient, aged 28, complained of a swelling in Scarpa's triangle of the right leg. It was about the size of a goose's egg, immoveable, and hard to the touch. No result was obtained from several exploratory punctures, and a sarcoma being suspected, an incision was made down to it, but a prick from the knife caused the tumour to collapse and to reveal its real nature, which was a solitary hydatid, with a very tough ectocyst growing from the deep fascia of the thigh.

I had under observation two female patients, each of whom had a swelling in the abdominal wall, a little below the umbilicus. The smaller tumour was the size of a hen's egg, and the other twice that size. They felt equally hard, and neither the history nor the exploratory needle aided the diagnosis.

On cutting down, the smaller of the two was found

to be a hydatid cyst, and the larger a sarcomatous mass. They were both growing from the sheath of the rectus muscle.

A male patient, aged 50, had a swelling between the posterior border of the right scapula and spinous process of the vertebræ, measuring from above downwards 5 in., and transversely 3 in. It was soft, with a distinct lobulated feel. No results were obtained from the exploratory needle. The superficial muscle could be traced over it. An exploratory incision showed it to be a hydatid, full of collapsed and dried daughter-cysts. The cyst itself took origin from the deep portions of the Spinalis dorsi. The ectocyst was thick and tough, and there was an entire absence of parent cyst-wall, as if it had become absorbed by the presence of the progeny.

When the cyst is obstructed in its development at one part it may grow in the form of a diverticulum in a direction where resistance is removed, as in the case represented in Plate XVII.

The hydatid tremor, or thrill, or purring, first described by Briançon, is an aid of some value in the diagnosis of hydatid. It is, however, very inconstant, but is most distinct in those cases where daughter-cysts are present. The cysts, when made to strike against each other produce a tremor similar to that noticed when shaking a mass of calves' feet jelly.

Often, however, one fails to get this tremor, especially when the parent cyst is tightly packed. A similar sensation is sometimes experienced in large and tense single cysts, and is then not to be dis-

tinguished from an ordinary ascitic wave, or from the feeling produced in percussing a cyst of the broad ligament.

The age of the patient cannot be relied on as a point in the diagnosis. Hydatids are most frequently observed at from 20 to 40 years, but no age seems to be exempt.

From the slow growth of the parasite and from the greater risks of infection that are encountered in the pursuits of adult life, this is just what one would naturally expect.

Neisser and Finsen drew attention to the preponderance of female subjects affected with the parasites. The former giving his proportion as 210 : 148, and the latter as 255 : 181.

It is evident, however, that in Iceland and Germany, where the disease is said to attack the females most, their avocations must bring them into closer contact with hydatid ova. Especially is this the case among the Icelandic women, who are occupied in cleaning the places where the dogs are quartered.

In Australia, the men are most commonly affected, for the reason that their habits and pursuits are such as to render them more liable.

Leuckart states that it is rare for the hydatid to occur in early childhood, for the reason of its slow growth, and he cites the cases of Finsen and Thorstensen, who operated on two children of six and four years respectively, as the youngest cases on record.

Dr. Davies Thomas operated on a boy aged two years and one month for hydatid of the liver.

If children are in the way of becoming infected their age is certainly no immunity. Within a period of a year I observed hydatids in ten children, their ages varying from five to eight years. They usually make a good recovery. The organs in which the cysts are situated are less likely to be so completely affected as is the case in the adult subject, where the pressure changes are more permanent.

THE HYDATID FLUID.

WHEN healthy, hydatid fluid is limpid and transparent, with a faintly sweet, pleasant odour and saltish taste.

It is neutral or alkaline in its reaction, with a specific gravity ranging from 1004 to 1015. It contains an excess of chlorides in the form of chloride of sodium, 6 parts per 1000 and over, and it is free from albumen. If the fluid be placed in a transparent glass vessel, small whitish specks are frequently seen floating in it; these are scolices or brood-capsules and shreds of cyst-wall.

It readily undergoes decomposition, emitting an offensive odour, and these scolices or brood-capsules, examined microscopically several hours after the fluid has been withdrawn from the cyst, are seen to be broken up, and their constituent portions to have parted from each other.

A single exploratory puncture may alter the character of the fluid in a cyst by its becoming commingled with transuded serum, and the fluid may thus contain albumen, in which case the microscope alone can make the diagnosis clear.

It contains abundance of leucin and tyrosin.

Heintz showed that it contained succinic acid, and Naunyn confirmed his discovery, and also found the presence of inosites. Minute quantities of grape sugar

may also be found in cysts in the region of the liver, and also cholesterin crystals and crystals of hæmatoidin.

The fact that Barker (*Cystic Entozoa of the Human Kidney*, p. 9) found in a case of hydatid of the kidney, uric acid, oxalic acid, triple phosphates, and the other solid constituents of the urine, points to the presence of these contents as a means of diagnosing the organ from which they grow.

Ascitic fluid, in persons who are hydræmic, as the result of amyloid degeneration, occasionally presents some of the chief characteristics of hydatid fluid, especially its clear character and freedom from albumen. So also does the fluid of some cysts in the broad ligament, but the microscope and the presence of grape sugar or succinic acid should render the diagnosis unequivocal. In one case the fluid of a large parovarian cyst, removed from a young woman, which I carefully examined, was indistinguishable in its physical characters from hydatid fluid. It was perfectly transparent, alkaline in reaction, specific gravity 1007, no albumen, and had excess of chloride. The microscope gave negative results.

In cysts which are undergoing a process of decay, the contained fluid may sometimes be found of different colours, even when it has not suppurated.

From a large cyst, situated on the under and posterior part of the liver of a male patient, aged 40, the exploratory needle drew off dark green fluid. It was only after a long microscopic search that I found the presence of hooklets. On opening into the cyst three pints of this fluid were removed; the cyst

wall proper was quite separated from its capsule and broken up into pieces, which looked and felt like steeped leather. The peculiar colour was doubtless due to the action of bile, which had found its way into the cyst. In the same way, blood-stained fluid may be obtained, its colour depending on the age of extravasation.

There are many sources of hæmorrhage into the cyst cavity, either from the vascular condition of the ectocyst, or from some vessel of importance which may become involved by the growth and pressure of the tumour. The fluid may be replaced by gas, pus, thick glairy colloid matter, simple caseous *debris*, or a deposit of pure lime salts.

CONSTITUENTS OF NORMAL HYDATID FLUID.

(*Davies Thomas*).

Percentage of	Hayem.	Jacobson.	Munk.	Wyss.	Heintz.	Scherer.
Water	97· 9	—	98·426	98· 59	98·675	93·476
Solid constituents, .	2· 3	—	1·574	1·410	1·324	6·523
<i>Consisting of—</i>						
Organic matter, .	—	—	—	—	—	—
Sugar,	—	0·060	0·606	0·546	—	—
Leucin,	—	{ considerable }	—	—	—	—
		{ amount }				
Succinic acid, . . .	—	0·700	uncertain	—	0·341	—
Inosite,	—	—	0·041	—	—	—
Urea,	—	—	{ uncertain }	—	—	—
Creatin,	—	—	{ amount }	—	—	—
Mucus,	0·18	—	—	—	—	—
Albumen,	0· 4	—	—	—	traces	—
Inorganic matter, .	—	—	0·968	0·864	—	1·061
Sodium Chloride, .	0·53	0·6140	0· 61	0·482	0·385	—
„ Phosphate, }	0· 7	{	traces	—	}0·90	—
„ Sulphate, }			—	—		—
„ Carbonate, }			0·230	—		—

THE HYDATID RASH.

THE urticaria-like eruption which sometimes follows the tapping of hydatid cysts, more especially those situated in the abdominal cavity, is spoken of as the Hydatid Rash. It is only noticed in a small proportion of cases by those who have had large opportunities of observing and treating this disease.

It usually makes its appearance shortly after the puncture, and lasts from two to three days. It is said sometimes to appear prior to, and independent of any operative interference. Dr. Verco mentions a case (*Australian Medical Gazette*, 1882) where the rash appeared before the patient was operated on; it attended an attack of giddiness and vomiting which suddenly developed.

Plate XIV., shows the rash on a patient the day after an exploratory puncture was made. It covered the abdomen, the chest, and arms, was intensely itchy, and was accompanied by an aggravated condition of cutis anserina.

It persisted for two days; the patient had never seen nor experienced anything of the kind before, although her tumour had been growing for at least five years. It accompanied a high temperature, and a considerable amount of abdominal pain. These conditions generally accompany it.

• Dr Macgillivray, Sandhurst, Victoria (*Hydatid Disease*), relates that, in one of his cases which ruptured into the abdominal cavity, intense urticaria followed, which lasted for three days. In the *Lancet* of 15th January 1887, a case is recorded where the patient nearly succumbed from the effects of a simple puncture of a cyst in the liver, and where the rash was most profuse on the abdomen and legs and extensor surface of arms, but did not appear on the chest and face. Vidal (*Annales de Dermatologie et de Syphiligraphie*) mentions that he has twice seen it follow capillary puncture of liver hydatid, lasting on each occasion for 48 hours.

Dr. Davies Thomas records a case where a fatal issue nearly followed the tapping of a hydatid of the spleen, and where the rash was distributed only on the face, neck, and arms.

On one occasion I observed the rash, after tapping, distributed only over the region of the liver. In this case the capillary injection persisted for several weeks.

The rash may appear in the typical form of urticaria, or it may present itself as a diffuse erythema. In one case that I had occasion to tap six times for a hydatid of the liver, which kept persistently filling and refilling, the diffuse redness on the face and chest was quite noticeable, but unattended by any itchy condition.

In a case of Dr. Morrison's, Melbourne (*Australian Medical Journal*, 1883) the urticaria was accompanied by marked injection of the capillaries, which persisted long after the wheals had disappeared.

It has been attempted to explain the occasional

existence of this cutaneous appearance on grounds other than reflex action, and an explanation has been sought for in the nature of the hydatid fluid itself.

Professor Roy, of Cambridge, in the *Lancet* of 15th January 1887, gives the results of some experiments with hydatid fluid, carried out with a view of ascertaining the nature of the cause of the alarming phenomena, which, from time to time, are observed to follow the sudden passage of this fluid into the blood stream or the abdominal cavity.

He injected 6 cc., of hydatid fluid into the jugular vein of a guinea pig, which caused an increased frequency in the respiration, and made the heart to beat irregularly; an additional quantity of 6 cc., caused no further noticeable result. He next opened the peritoneal cavity of two more guinea pigs and injected 6 cc., but during the time they were watched the results were negative. He took a large dog (a cross from a collie) and fastened a canula to the vein and carotid, which was connected with a kymograph. While the blood pressure was marked at 140 mm., mercury, the pulse 68, and the respiration 24, 12 cc., of the fluid was slowly injected into the vein.

Five minutes afterwards the blood pressure was estimated at 135 mm., mercury, the pulse 70, and the respiration 37. Ten minutes later 14 cc., were injected into the jugular vein, with no further marked change. Twenty minutes afterwards 20 cc., caused the blood pressure to sink gradually—the first five minutes from 137 mm., to 63, the pulse to 33, and the respiration to 17. As the animal seemed dying small doses of

atropine were injected into the vein, when the blood pressure rose to 125 m., at which point it remained, notwithstanding that a further quantity of 40 cc., was injected at intervals of five minutes during the period of rise. The pulse rose to 72, and the respiration to 28. He summarised his experiments thus:—"In hydatid fluid there is a substance which has a powerful effect on both the heart and the respiratory mechanism. From the first two doses little effect was produced, but a larger dose resulted in a slowing of the heart from 70 to 30 per minute, which was very striking. The acceleration of respiration by the first dose, and its great slowing after a further dose of 20 cc., is also very remarkable. The great fall in the blood pressure after the third dose, shows that the fluid contains some substance which can affect the blood pressure in the systemic arteries to a very serious extent."

He also pointed out that the marked change which took place in the heart's beat, the respiration, and the blood pressure after the injection of atropine, seemed to point to its practical importance in such cases, as well as to its great interest.

Professor Roy's experiments are, of course, too limited to lead one to conclude definitely that the fluid contains some specific principle capable of affecting the cardiac and respiratory mechanisms through the nervous system, and my own observations, so far as they have gone, have afforded me no further conclusive proof.

I took a male retriever dog, weighing $12\frac{1}{4}$ lb., and noted the normal pulse, respiration, and condition of

his pupils. I injected hypodermically 25 minims of freshly drawn hydatid fluid. For the first fifteen minutes, beyond a slight increase in the pulse and respiration, which I attributed to the shock or pain from the puncture, no noticeable feature was developed. At the second fifteen minutes 25 minims more were injected into the tissues of the abdominal wall, with no further result. At the third and fourth fifteen minutes similar doses gave negative results. I then doubled the dose for the next two quarters of an hour, and lastly injected 100 minims, which the animal took very kindly, exhibiting no symptoms of distress whatever.

Three days afterwards a hydatid cyst in a boy of nine years came under my notice. I drew off the fluid by an aspirator, and, opening the peritoneal cavity of the same dog, injected 2 drachms; the wound was stitched up with fine catgut, and covered with a coating of collodion, and the dog recovered without a noticeable symptom. Three weeks afterwards the dog was killed, and no trace was found in his abdominal cavity of peritonitis; the areas which marked the seat of the hypodermic injections were distinguished by a little inflammatory thickening.

Again, I opened the peritoneal cavity of a male Scotch terrier, weighing $12\frac{1}{2}$ lb., and injected 2 oz. of freshly drawn hydatid fluid. The animal during its recovery never seemed any the worse.

It is difficult to explain the appearance of the rash from the specific nature of the fluid itself, and more especially as such eruptions are observed so often to arise where no such cause is possible. Dr. McCall

Anderson records a case (*Diseases of the Skin*) where urticaria appeared every time a sound was introduced into the uterus of a patient, and another case where the mere mention of nettle-rash would cause it to appear.

An urticaria-like rash is also occasionally noticed to follow the simple act of tapping in cases of pleurisy with effusion.

Alarming symptoms, however, have been frequently observed to follow when there was reason to believe that the fluid had gained entrance into the blood stream. There is Bryant's fatal case (*Clinical Society's Transactions*, Vol. XI.), where he found that, inside the hydatid capsule, the trocar had transfixed a large vein, and where he attributed the fatal issue to the fact that on the withdrawal of the instrument hydatid fluid had escaped into the portal vein.

In the *Lancet*, 15th January 1887, there is a case mentioned where the patient, a few minutes after being tapped for a cyst in the liver, was seized with faintness, dyspnoea, and vomiting, the extremities became cold, the radial pulse almost imperceptible, and the heart sounds almost inaudible.

Thomas (*Hydatid Disease*) had a case where, a few minutes after tapping a cyst of the spleen, the face became dusky, hands and feet cold, the radial pulse imperceptible, and the respiration laboured and hurried.

Dr. Humphry, Addenbrooke's Hospital, *Lancet* for 1887, records his opinion, based on cases that have

come under his observation, that hydatid fluid may enter a wounded vein at the time of puncture, or escape into the peritoneal cavity and be absorbed, as indicated by the urgency of symptoms and rapidity of their onset.

Hilton Fagge's hypothesis (*Practice of Medicine*, Vol. II.) is, that after the withdrawal of the trocar hydatid fluid may be sucked into the portal vein and act as a direct and fatal poison. The veins on the surface of the Ectocyst are occasionally observed to be dilated and varicose, so that there is ample opportunity for them to be pierced by the passage of a trocar, and thus afford a means of entrance for the hydatid fluid.

I once witnessed the case of a strong, powerfully-built man, aged 28, who was found lying in a public park in Sydney apparently dead. He had been seen to sit down quietly on the grass, on a summer afternoon, half an hour previously. When I examined him he was livid, flaccid, and cold, the radial pulse was imperceptible, the breathing very shallow and irregular. He died a few minutes after admission into the hospital. The *post-mortem* showed that there were two hydatid cysts on the under surface of the liver. The smaller one was filled with dark fluid blood, and was attached to the portal vein at its sinus, where and into which it had ruptured. There was nothing worthy of note about the other organs. A careful examination failed to discover any other cause to which death could be attributed. It is surmised that, after the patient had lit his pipe, he stretched

himself full length, and rolled from back to front, the strain causing the curious accident that brought about his death.

The cases where a fatal issue has resulted from a simple puncture have nearly always been confined to the abdominal cavity, unless in those cases of pulmonary hydatids, where the obvious cause of death was the flooding which followed the rupture of the cyst.

Dr Martineau (*Lancet*, August 1875) had a patient who, after being punctured with a fine trocar for a cyst in the liver, became sick and faint and died. In *Bartholomew's Hospital Reports*, Vol. XVI., there is a record of a case where a patient died suddenly after the trocar had penetrated a small cyst in the right lobe of the liver.

In the absence of any direct proof that hydatid fluid is in itself a poison, the majority of the fatal cases may be attributed to shock.

In the *International Encyclopædia of Surgery* (p. 361) is an account of symptoms following an exploratory puncture of the liver, which seem almost identical with those attributed to the absorption of hydatid fluid, and Dr Thomas has suggested that the symptoms might be explained by a sudden inhibitory influence on the heart, exerted in a reflex manner through the sympathetic supplying the liver or spleen, as the case may be.

MULTIPLE HYDATIDS.

IN most cases of multiple hydatids one of the cysts is found in the liver. In a case that came under my notice of multiple hydatids in the peritoneum the one in the liver was only about the size of a walnut, and quite degenerated, while all the others, to the number of over twenty, were actively growing, and some of them of a large size.

It is difficult to decide whether multiple cysts are the result of numerous infections by ova, or of a single infection, or the result of an ovum, which, in its turn, has given rise to a numerous progeny.

The mode of exogenous multiplication of cysts is fully established by Leuckart, Küchenmeister, and other authorities. To account for multiple hydatids by this process one would expect to find them lying close to each other, which is far from being the case; on the contrary they are often wide apart, and present great differences in size and appearance.

Naunyn and Rasmussen's theory, that they arise from the scolices and brood-capsules of the parent cyst involves the difficulty of supposing that the primary hydatid has opened into a blood-vessel, and allowed its brood-capsules to travel all over the body.

Leuckart regards it as most probable that multiple hydatids result in most cases from a single infection,

which furnishes not one, but many embryos. He found the same differences developed from one feeding as are nearly always found where there are multiple cysts, so that in cases of multiple hydatids in the human subject it may be that many have originated from an infection of numerous embryos.

He cites the case of the *Cœnurus*, which is most commonly found solitary, but is not always so from the first, and from analogy it appears not improbable there may be numerous ova introduced at one time, and as the developmental result does not necessarily depend upon any given number but on the sum total of different vital circumstances, one ovum might proceed to develop to a large size while all the others remained sterile.

No direct evidence has hitherto been published that the brood-capsules or heads liberated from the parent cyst may develop into multiple hydatids at some distant part where they may find a lodgment. Plate XXI., is from a specimen taken from a patient who died of exhaustion, following a suppurating hydatid of the liver. A cyst growing from the under surface of the right lobe had been tapped three months previously. At the *post-mortem* examination I found the large omentum simply studded with minute tubercle-like specks of a white pearly appearance; some were the size of a small pea. There was a similar appearance on the upper surface of the spleen, on the kidney, and mesentery. The most wonderful condition, however, was in the peritoneum, where it is reflected to form the pouch of Douglas and the

utero-vesical pouch ; it had a rough papillomatous-like feel. There were hundreds of small cysts on the serous surface of the bladder, on both aspects of the uterus, and in the anterior and posterior pouches. The great mass of these elevations were about the size of sago grains. A section taken from the omentum, and from the peritoneum in Douglas' pouch gave the characteristic appearance under the microscope of young hydatids (Plate XXII.). They showed the lamination of the cuticle, and the young actively growing connective tissue cells of the ectocyst. In some, numerous hooklets were found. From the difficulty of cutting a section of the true cyst-wall most of them appeared under the microscope as if the cyst-wall were wanting, but in others it was seen shrivelled up, with the hooklets embedded in its substance.

This case goes far to strengthen the view that scolices and brood-capsules, when they escape from the parent hydatid, find the peritoneum suitable ground for their further development into cysts. It seems the most feasible way to explain their presence in the case in point. They were in greatest numbers at the most dependent parts, just where the fluid would gravitate to after its escape from the liver cyst. Whether they generally become aborted in their development from this mode of origin cannot be positively affirmed, but the fact that hydatid cysts are very commonly found in large numbers in the abdominal cavity, varying from the size of a pea to that of a bean, would seem to favour such a hypothesis.

In some cases the large omentum is found to be literally one mass of hydatids of this size.

A young man, aged 20, came under my notice with hydatid of liver. The exploratory needle drew off a few drops of hydatid fluid and shreds of hydatid membrane. No further operative treatment was carried out at that time.

Two years later he again presented himself for advice. In addition to his liver cyst, which had increased in size, the region of the great omentum was felt to have on its surface a number of round bodies about the size of a horse bean, evidently small hydatid tumours.

In every case that I am aware of, where the peritoneum at different parts was found to be studded with numerous small hydatids, there was a previous history of either exploratory puncture or aspiration of a liver cyst.

The evidence is distinctly in favour of multiple secondary cysts, arising from liberated scolices, so that leakage from a parent cyst, such as often happens after exploratory puncture, should be guarded against.

The hydatid cyst has a wide distribution in the human body.

The young embryos, after they are liberated from their capsules, bore their way through the walls of the stomach, and may be carried by the blood-stream to any part of the body. Thus they are found growing in the liver, respiratory organs, peritoneum, circulatory apparatus, brain and spinal cord, spleen, kidneys, and suprarenal capsules; in the substance of

muscle and subcutaneous tissues, the medullary cavity of bone and joints, in the orbit and eye, in the breast, axilla, scrotum, testes, ovaries, and uterus.

Like other parasites it has its favourite position, and in more than half the cases recorded the liver is found to be its seat of growth. Finsen, from his observations, states that in Iceland he found it occurring in the liver in 69 per cent. In Neisser's statistics, based on the records of 1000 cases, about one half are described as occurring in the liver. Its occurrence in the lung is much less, 11·3 per cent., according to Thomas, from the statistics of 2000 cases.

In 200 cases under my own observation, the liver was attacked in 60 per cent., whereas the lung cases amounted to 9 per cent. The peritoneum comes next in frequency, and the other organs in more or less varying proportions.

HYDATIDS IN THE LIVER.

IT is the liver that the parasite most frequently attacks, owing to the ease with which the ova can reach it through the portal stream.

A single cyst is the most common form that is met with, although the presence of two, three, or more in the same organ is by no means rare.

In the liver of animals who readily harbour the hydatid, as for example the pig, cysts will be found pervading the whole organ to the number of hundreds. In the case of multiple hydatids, one will generally be found in the liver, while the other organs, especially the peritoneum, omentum, spleen, and kidney, may contain several dozen.

Wunderlich mentions a case where the cyst in the liver was the size of a child's head; in the spleen, omentum, behind the cæcum, and Douglas' pouch there were twelve other cysts, varying from the size of an apple to that of a fist; while under the mesenteric coat of the small intestine there were about fifty, varying from the size of a poppy-seed to that of a bean.

In one case, where the patient died from the effects of a large suppurating hydatid of the liver, I found innumerable cysts in the peritoneum, ranging from the size of a bean to that of a pin's point.

In the experimental cases of Leuckart he found the hydatid cysts in the liver of the pig, lying beneath the serous covering, and in some cases they had grown mostly out of the organ, involving but little of the liver tissue.

In man they may be found of considerable size without affecting to any extent the substance of the liver.

They seem to take their growth very commonly from the upper or under surface, judging from the large size they sometimes attain to, without hollowing out the substance of the liver.

They may excavate the whole of our lobe while the other correspondingly hypertrophies (Plate IV.).

In *post-mortem* examinations I have found them not larger than a walnut, embedded in the very centre of the liver substance (Plate XI.). In a case mentioned in Ziemssen (Vol. III.), a hydatid was found free in the abdominal cavity, lying alongside the liver, and had probably escaped from it.

The parts adjacent to the cysts show the usual atrophic changes in the cell elements due to pressure.

The various organs, as the lungs, heart, and abdominal viscera, may be considerably displaced owing to the size and growth of the tumour.

In one case of a large hydatid growing from the liver, the great mass of the intestines was pushed towards the left side, so closely as to cause intestinal obstruction.

They may sometimes extend below the umbilicus without producing any marked bulging or deformity ;

on the other hand, when growing from the upper surface of the liver, they may produce marked deformity from bulging out the ribs.

The area of liver dulness may not be increased to any extent, and yet a cystic bulging of three or four pints' capacity may be occasionally met with. It has usually a tense elastic feel, and the tension of it may be so great that a slight amount of external violence may occasion its rupture.

Cobbold mentions a case where a lad, aged twelve years, received a slight blow from a playmate, and death speedily followed. The *post-mortem* showed that a solitary hydatid in the liver had been ruptured.

Hydatids are not usually found developing in cavities lined with mucous membrane, although such a condition is not unknown.

Thus Ziemssen, Vol. III., refers to cases where small hydatid cysts have been found in the gall-bladder without any trace of a liver hydatid having been discharged into it. By the same authority a case has been referred to where a cyst actually developed in the interior of the vermiform appendix. Hydatid cysts in the liver may develop to an enormous size without producing jaundice or ascites, but in some cases of small cyst the jaundice may be very distressing.

A favourable mode of termination is when the contents of the tumour pass into the intestine along the common bile duct. Whole cysts may thus be voided *per anum*, as in a case recorded by Davaine, where it was supposed that the patient, a woman, was

actually laying eggs. Daughter-cysts have been known to pass *per anum* intact with a diameter of two inches.

In Ziemssen there is a case recorded where, in the course of several years, a tumour appeared repeatedly and disappeared again in a short time with severe pain. During the last attack, jaundice occurred and cysts were evacuated from the bowel; about 400 were actually counted.

A cyst growing from the upper surface of the liver may be found sometimes to bulge up as high as the second rib, and in such a case the diagnosis between this condition and intra-thoracic affections is usually very difficult. Frerichs and Bartels state that in hydatids growing from the upper surface of the liver the line of dulness at the back descends as it approaches the spine. This rule does not hold good in many cases.

HYDATIDS IN THE LUNG.

IN the capital of Victoria, according to Bird, hydatid disease is equally common in rich and poor, and of as frequent occurrence among the inhabitants of the city as among the shepherds of the west or the workers in the Bendigo gold fields.

He ventures the opinion that the ova of the *Tænia*, tenacious of life as they are, find their way into the streets with the water laid on to allay the dust; and by the great heat and frequent strong winds are dried and blown about in the very air which the people breathe.

The probable cause of its common occurrence is most likely to be the water itself, which the people so often drink without the precaution of seeing to its being filtered; otherwise, it is difficult to account for the embryo being liberated from its capsule without such an aid as the digestive juice. Besides their development in the bronchi would be more common than is actually the case, and the irritation which the presence of a growing hydatid would set up in such a region would naturally lead to its early discovery.

As in cysts in the liver, it is surprising to what a size they sometimes attain without causing any serious inconvenience to the patient.

In the case of a patient who first came under treatment for dyspnœa, which he had felt for several months, but which did not prevent his following his usual employment as a bullock driver, I found after his death, which suddenly followed the introduction of an exploratory needle, that the whole of the right lung was converted into a single cyst (Plate XXVI.)

I have found at the *post-mortem* of a girl aged 16, who died from a non-hydatid tumour in the brain, two hydatid cysts on the right lung, each about the size of a walnut, filled with daughter-cysts, and undergoing caseous degeneration. She had no chest symptoms whatever, and, after repeated examination, there seemed nothing unusual in the physical signs.

Andral (*Clinique médicale*) relates the case of a woman, aged 45, who died from uterine cancer. In the centre of the lower lobe of the right lung he found a hydatid the size of a walnut, containing numerous daughter-cysts, which had given rise to no pulmonary symptoms during life.

Geoffrey and Dupuytren (*Bulletin de l'École de médecine*) record a case of a voluminous cyst in each lung, extending on both sides from the apex of the chest to the diaphragm. Each contained an enormous solitary hydatid filled with about $5\frac{1}{2}$ pints of fluid. The patient had died from pure loss of breathing space.

M. Limpéropoulo showed a specimen of hydatid on the lung at the Paris Anatomical Society (*Lancet*, 1887). It was about the size of a walnut, and undergoing degeneration. There was no symptom of its existence in the lung during the life of the patient.

Hydatids in the lung, containing numerous daughter-cysts, though by no means rare, are exceptional. In many cases apparent daughter-cysts noticed in the expectoration of patients suffering from this affection are no doubt pieces of the parent cyst-wall; while, on the other hand, the pleural cavity has been found full of daughter-cysts, which had passed through the diaphragm from the parent hydatid in the liver.

A large hydatid, tenanted by a few daughter-cysts, is sometimes met with.

In one of Macgillivray's cases (*Hydatid Disease*) an Indian had a hydatid of the lung tapped and 52 ozs. of fluid drawn off. The patient died rather suddenly, and the *post-mortem* showed that the parent cyst contained the sacs of a few moderate-sized daughter-cysts and a few very small.

Hydatid cysts are found in either lung, but more frequently in the right, and are commonly situated in the lower lobe. They are also sometimes found at the apex.

There may be very marked bulging of the thoracic wall of the affected side.

In the case of a young child, aged eight, the bulging of the right side was very pronounced, and was especially so in the antero-posterior direction. The cyst seemed to extend throughout the whole area of the lung, and was removed by incision through the thoracic wall. The child made a good recovery.

In the case of a boy, aged five years, with a hydatid in his right apex, the bulging was distinctly visible only over the area of dulness, which extended to the

nipple from the first rib. There was no lateral bulging whatever, the cyst was of $\frac{1}{2}$ -pint capacity, unbroken, and gave rise to little constitutional disturbance.

In the fatal case already referred to, where the whole lung was practically converted into a single cyst, except $1\frac{1}{2}$ in. of healthy tissue at the apex, there was no deformity of the chest wall whatever.

Plate XXVI., is drawn from a patient who had a hydatid of the left lung, the size of a foetal head, where there was no deformity in the chest wall.

Hydatids in both lungs are met with occasionally, also multiple hydatids in the same lung.

Dr. Wilson, Cheltenham (*British Medical Journal*, 1880), records the case of a girl, six years old, where, at the *post-mortem* examination, he found the apex and middle lobe of the right lung healthy, and a large hydatid at the lower lobe. Another cyst occupied the whole of the upper lobe of the left lung.

Bird (*Hydatid of the Lung*) refers to the case of a woman, aged 36, who had unmistakable evidence of two hydatids in the same lung, one of which had burst, the other was quite entire.

I had under observation a woman, aged 40, with a large hydatid in the right lobe of the liver, growing downwards into the abdominal cavity. There was a cyst in the lower lobe of the right lung and one in the left apex.

In the *Transactions of the Pathological Society*, Vol. XV., Peacock and Hicks record the case of a boy, aged 18, whose lungs both contained numerous hydatid

cysts, about the size of a horse-chesnut, embedded in the pulmonary tissue.

The cyst-wall in pulmonary hydatid is, as a rule, but slightly adherent to the surrounding tissue; so much is this the case, that in the radical operation for hydatid of the lung the cyst is forced out by respiratory efforts, or is easily removed by gentle traction with a pair of forceps.

Bird states that he has seen old lung-cysts with as thick an ectocyst as any in the liver, while in some cases, where the cysts were not larger than an apple, they lay immediately in contact with the lung tissue.

In my own experience, when I found the ectocyst tough and thick the hydatids were usually small and undergoing calcareous degeneration.

Bouvier mentions that at the *post-mortem* on a patient who died of meningitis, a large hydatid was found in the lower lobe of the left lung, the fibrous capsule of which was formed by a cellular membrane, along which vascular branches projected, denuded, and, as it were, dissected in a part of their course.

The diagnosis may be made almost certain if the cyst has reached to the capacity of a pint or more. It has frequently attained to this size before the patient comes under treatment, as, before this, the cyst, slow growing and painless as it is, generally escapes the attention of the patient, and casual examination of the chest may fail to reveal the presence of anything unusual.

In some cases, where the bulging of the chest wall is well marked, it is surprising how slightly incon-

veniened the patient is; the deformity, indeed, may be the first sign that directs attention to his condition. This was the case of a young girl, aged eight; the parents noticed her getting rather anæmic, and the arched appearance of the upper portion of the chest wall led them to seek advice about her.

The Physical Signs of Hydatid of the Lung, when the cyst is still unbroken, are usually easily defined.

Inspection shows a deficiency in the expansion of the affected side, and the *Mensuration* is usually increased, but not necessarily so.

Palpation reveals an absence of fremitus over a well-defined area, but it may be increased at a corresponding level posteriorly; according to the amount of lung tissue involved or compressed.

Percussion gives an absolutely dull note to the exact limits of the cyst, and it remains unaltered by position. According to Bird, peripheric fluctuation is sometimes obtained on percussing over the intercostal spaces in thin subjects.

Auscultation reveals an entire absence of breath sounds, if the cyst has developed sufficiently to approach the chest wall. If, however, some thickness of lung tissue intervene between the cyst and the chest wall, the breathing may be tubular in its character. The breath sounds beyond the line of the cyst may be perfectly normal, or the breathing may be simply puerile.

The *Temperature* is usually quite normal. The lung itself may be in such a condition as to quite alter the typical signs of hydatid in that organ.

Pressure on some large bronchi may give rise to a constant irritable cough, or there may be present a low form of pneumonia, and I have also experienced the difficulty in diagnosis which the presence of pleurisy with effusion gives rise to, when it exists as a complication of hydatid.

A careful differential diagnosis has always to be made between pleurisy, localised empyema, pulmonary abscess, phthisis, and mediastinal tumours; but the history and condition of the patient will generally lead us to a correct conclusion.

In the ruptured cyst the diagnosis is rendered clear by the character of the sputa. The patient usually has some pyrexia, and the physical signs are very much those of a phthisical vomica.

Even in cases of unruptured cysts there is often noticed a pinched and anæmic appearance of the patient. Bird speaks of it as a phthisical-like cachexia, and it is often noticed to co-exist with clubbing of the fingers and incurvature of the nails. It has been seen in cases where there was no evidence of tubercle, and often, when the patient had entirely got rid of the parasite, he made a robust and strong recovery.

A variable degree of hæmoptysis is generally present in hydatid of the lung, before and after the rupture of the cyst.

I have noticed several cases run their course without this symptom. According to Hearn (*Kystes hydatiques du poumon et de la plèvre*, p. 24), only one-fifth of the cases collected by him were unaccompanied by this symptom.

A cough may exist for a considerable time, either of a short dry character, or of a paroxysmal kind.

Gairdner (*Edinburgh Medical Journal*, 1857) and Thomas (*Hydatid of Lung*) have both referred to the marked croupy clang which accompanies the cough in hydatid of the right lung, situated in the right apex. This, however, is so variable and uncertain a symptom that little value can be attached to it in the diagnosis.

Hydatids in the pleura are indistinguishable from those embedded in the lung tissue, and are treated in the same manner. They are usually devoid of an ectocyst, the serous membrane itself acting as such.

The following brief clinical notes of some cases may serve to illustrate the symptoms commonly met with in pulmonary hydatids:—

C. L., male, aged 32. The patient complained of shortness of breath, and a dry, hacking cough, which had troubled him at intervals for twelve months. One day, while driving in his cart, he spat up some mouthfuls of bright blood, followed by gushes of clear fluid. There was no attack of coughing before the blood appeared. After three days' rest he went about his work as usual, not having had in the meantime any medical attention. He found his breathing easier, he thought, after this attack of hæmoptysis, and he was able to attend to his work for some months, when he had another attack of hæmoptysis, accompanied with a large amount of frothy expectoration.

On admission into hospital, he looked pale and thin.

He had lost 1 stone and 11 lbs. since his first attack of bleeding.

On examining his chest from the front, the right side bulged forwards in a marked manner. The vocal fremitus was hardly perceptible over the right side, except at the apex, where it was very marked. The percussion note was dull and the breath sounds faint and distant. Posteriorly, the fremitus was marked throughout its whole extent, the percussion note was dull, and the breath sounds approached the character of tubular breathing. In the supra-spinous region there was a patch where the breathing was accompanied with coarse crepitations. The left lung was quite normal.

Two days after admission, and while his chest was again being percussed, he was seized with a sudden fit of coughing accompanied with gulping of mouthfuls of blood and fluid. This attack of coughing lasted for over an hour; he had expectorated and coughed up a quart of hydatid fluid mixed with blood, frothy mucus, and pieces of hydatid cyst membrane.

The patient was kept under observation for four months, during which time no operative interference was resorted to. The expectoration was copious for several weeks, and latterly became thin and purulent; but as he suffered from little constitutional disturbance, it was considered a suitable case for expectant treatment.

When discharged from hospital, he had greatly improved. Examination of the chest showed that the vocal fremitus had become equal on both sides.

The breathing in the right axilla, and over the spine of the scapula, was amphoric; but there were no signs of active change going on in the lung. It was difficult to realise that a large cyst had occupied the lung so short a time before.

W. W., male, aged seven years. The patient's father stated that he had noticed the boy getting thin and pale for some months; he had been gradually losing his appetite, and had become apathetic and dull. He complained of no pain, but had a short, dry, irritable cough. There had been no hæmoptysis.

On admission into hospital, the temperature was normal, pulse small and rapid, and the respiration 30 per minute. His face was pinched and drawn, but the body generally was well nourished.

Examination of the chest showed a distinct bulging over the right mammary and infra-clavicular region. The dulness was absolute over the right side of the chest anteriorly, as far down as the nipple line. The vocal fremitus seemed but slightly altered, and the breath sounds puerile. There were no accompaniments. At the lower portion of the bulging the breathing was loud and harsh. Posteriorly, the dulness was not so well marked, the fremitus was impaired, and the breathing tubular. At the base of the lung, the physical signs were normal. The cyst was treated by aspiration, 18 ounces of clear fluid being removed.

S. A., male, aged 28. The patient complained of pains in the right side of his chest, a troublesome cough, and spitting of blood. He looked emaciated, and had a clammy, moist skin. He had experienced

his pain and cough for two years, and previous to then had enjoyed good health.

On inspection, no bulging of either side of the chest wall was noticeable. When viewed from the front, the respiratory movements of the right side were very feeble. Posteriorly, the respiratory movements were much more apparent. The fremitus was absent in front on the right side, but posteriorly it was even more marked than on the left. There was slight dulness in percussion down to the level of the fifth rib in front, and from there, outwards and backwards, it became absolute. The breath sounds on the left side were normal; on the right side they were very faint, except from the lower angle of the scapula, and upwards they were loud and bronchial. The hydatid cyst ruptured spontaneously during a severe fit of coughing. The patient expectorated 24 ounces of fluid and blood, and for two months afterwards kept bringing up pieces of hydatid membrane. He eventually made a good recovery, and regained almost perfect use of his lung.

G. P., female, aged 11 years. The patient was brought to me from the country. Her mother stated that six months previously the girl had a severe attack of hæmorrhage from the lungs, which left her in a very exhausted and weak condition. The medical man called in told her that the bleeding was from the right lung, and due probably to some inherited pulmonary weakness.

Eight weeks before I saw her she had another attack of hæmoptysis, the blood coming up in mouth-

fuls, and filling a bowl of about one and a half pints capacity. While in the act of retching during the last attack she suddenly showed signs of choking, becoming black in the face and insensible. Her mother had the presence of mind to shake and slap her between the shoulders, when, after doing so, she noticed that the patient vomited something which looked like curdled milk. This was followed by relief and return to consciousness of the patient. Fortunately, the vomited matter was preserved and brought to me. It was a large piece of hydatid cyst membrane, curled up on itself, and, when spread out, measured eight inches by four.

Examination of the chest showed that the cyst had been situated at the apex of the right lung. There were distinct signs of a large cavity. The breathing was cavernous and accompanied with coarse crepitations.

This patient eventually made a perfect recovery. When I last saw her, she had become a stout, sturdy, rosy-faced girl. There was still dulness over the apex of her right lung, but the breathing seemed quiet and normal.

B. S., female, aged 40 years. The patient complained of a stitch-like pain under her right nipple, which she had felt for a month; previous to then her health had been very good.

Inspection showed no bulging, but there was a noticeable deficiency in the respiratory movements of the right side. The fremitus was well marked at the upper portion of the lung, back and front. The

dulness at the right base posteriorly commenced at a line drawn horizontally on a level with the inferior angle of the scapula, and extended downwards to the tenth rib. Over this part the breath sounds were tubular. The dulness in the axilla commenced at the right nipple line, and extended downwards to the lower margin of the ribs. The breath sounds over the area of dulness in front were faint, but, posteriorly, they were loud and harsh. The cyst was treated by aspiration, 30 ounces of clear fluid being removed.

HYDATIDS OF THE PERITONEUM.

IN the peritoneum, hydatids generally occur as multiple cysts; the large and small omenta especially are favourite seats for their development. Unlike hydatids in the serous membrane of the lungs and brain, they are characterised by a tough fibrous ectocyst. Plate III., represents a specimen where the whole gastro-hepatic omentum was converted into one large cyst, with numerous daughter-cysts.

The large omentum may be studded with Echinococci of different sizes (Plate XX.).

Frequently they are found not larger than a walnut or small orange, and may number several dozens (Plate XIX.).

In the mesentery a cyst may form for itself an attenuated and twisted pedicle (Plate XXIII.).

The recto-vesical pouch is a common site for them. There are many such cases on record. Plate XXIV_A., shows one *in situ* from a patient who died from exhaustion after operation for a cyst in the liver.

Verco (*Australian Medical Gazette*, 1886) mentions a case where he found one between the rectum and the bladder, and extending down into the perineum. It had stripped the peritoneum completely off the bladder. The patient could only retain urine a short

time. The catheter could not pass beyond a small cavity just within the prostate gland.

In a case reported by Bright (*Memoirs of Abdominal Tumours*), the *post-mortem* showed that the catheter passed by an opening from the urethra behind the bladder into a large hydatid cyst, attached to the posterior part and fundus of the bladder, and preventing it entirely from filling with urine.

In the case of a young woman who was operated on for a hydatid which greatly distended the abdominal wall, the incision through the linea alba, two inches below the umbilicus, passed into the bladder, which had become adherent to the abdominal wall, being pressed upwards by a large cyst growing from the front of the uterus. The patient, for weeks after she was able to go about, had a fistulous opening in the abdominal wall, through which urine trickled.

Dr. Macgillivray records an interesting case (*Hydatid Disease*) of a patient who died from pneumonia, where the *post-mortem* showed a swelling in the scrotum, which was due to a herniated hydatid cyst, developing in a process of the omentum, and preventing its return. In all probability the parasite was trifling in size when it descended with the hernia, and had enlarged in the scrotal region.

Dr. Muskett (*Australian Medical Gazette*, 1886) found a hydatid cyst in the scrotum, simulating a hydrocele, and about the size of an emu's egg; after tapping with a large trocar, the cyst-wall protruded itself through the aperture.

Hydatids sometimes distend the abdomen to an

enormous extent. Plate XIV., is that of a woman, aged 34, with a large moveable tumour, which was growing, so far as one could judge, from the great omentum. It was mono-cystic, and fourteen pints of clear hydatid fluid were aspirated from it. The cyst was tapped again on two subsequent occasions, and was eventually incised.

In three cases—(1) a man aged 45; (2) a young woman of 19; (3) a girl of 11—I was unable to get any tympanitic note from the liver margin to the pubes. There was great distension in each case. A free incision in the linea alba gave exit to hundreds of daughter-cysts, and the great cavity of the mother-cyst seemed to shut off entirely the abdominal viscera.

Plate XXIV_A., is that of a cyst situated at the junction of the large and small intestines, containing four daughter-cysts.

HYDATIDS OF THE BRAIN.

THE hydatid cyst is found in the brain in all its parts ; it is also found in the membranes.

It does not usually attain to any great size on account of the fatal issue that it speedily brings about. In some cases, however, it is surprising how much brain tissue such a tumour may displace without causing any marked symptoms or impairment of intellect. It has been known to absorb part of the bones of the cranium, and to continue its growth beneath the scalp. It may also find an exit through the orbit or base of the skull. Davies Thomas found it occurring in the brain in four per cent. out of 2000 cases recorded of hydatid disease in the body generally.

Out of 100 cases of brain tumours collected by Hale White in Guy's Hospital, one only was a hydatid.

The largest number of cases have been found occurring in the cerebrum, and about twice as often in the right hemisphere as the left. It is, relatively, less frequent in the cerebellum, even when the normal proportions of these two parts of the brain are taken into account.

It most frequently occurs as a single cyst, sterile, and without an external membranous covering. Cases of multiple hydatids, however, have occasionally been

found, and single cysts with a distinct membrane, and with daughter-cysts numbering from one to two hundred.

They have also been found undergoing spontaneous cure by a process of calcification.

The co-existence of the same disease may be found in other organs, especially the liver and lungs. In two cases, where the patients had died from the effects of cerebral hydatids, I found multiple hydatids of a small size in the lungs which had given rise to no chest symptoms.

One hydatid cyst found in the brain is recorded by Rendorf as weighing $2\frac{1}{2}$ lbs. They are most frequently spherical or ovoid in shape, and when single are commonly found ranging from the size of a hen's egg to that of an orange.

The recorded cases of hydatid tumours of the brain show that the largest number have been found in patients in the second or third decade of life; though no age seems exempt, the majority have occurred in patients between the ages of 15 and 25. They have been found in patients as young as four and five years, and in one as old as 75.

The symptoms must vary with the size and position of the tumour. The usual symptoms are headache, vomiting, vertigo, blindness, and hemiplegia. Frontal headache is the most frequent symptom. It is usually very intense in its character, and may be persistent or paroxysmal. In a case recorded by Dr. Gee, it was the only symptom complained of by the patient, even when the cyst was the size of a turkey's

egg, and situated in the middle lobe of the left hemisphere.

The pain is sometimes referred to the region of the cyst.

Blindness is nearly always present, no matter what be the situation of the cyst. Patients often state that they lost their sight suddenly, or that they have had periods of blindness. The pupils are usually widely dilated and insensible to light. When blindness has been unilateral the affected eye has been on the side where the tumour was found.

Convulsions are frequently observed, varying in their intensity and character, and in some cases taking the form of epileptic seizures or clonic spasms of face, arms, and legs.

Hemiplegia is the most commonly recorded form of paralysis, but it is obvious that any form may result according to the position and size of the cyst.

The diagnosis is often a matter of great difficulty.

In all suspected cases the scalp should be shaved and the cranial walls carefully felt for thinning of the bones at any part.

Sometimes there is a bulging of the bones at the affected side, and in some cases the bone has been felt to be as thin as paper, or even to have been perforated.

The age of the patient may also be taken into account, and the fact that the hydatid cyst has rarely been found in the cerebellum, while tubercular growths, especially in children, are common in that region, is a point of some diagnostic value. Westphal

makes a special point of the intermittence of the symptoms, with now and then an intensified recurrence.

The treatment consists in removing a button of bone by the trephine, drawing off the fluid with a fine trocar and cannula, and removing the collapsed cyst-wall, which usually comes away without any difficulty.

Hydatid disease in this region may be best illustrated by the following clinical cases.

C. G., aged 16, born in Ireland, but has lived with his parents in the suburbs of Sydney for the last twelve years. His father states that the boy was easily brought up, and that he was unusually sturdy, bright, and active. Beyond receiving an injury to his head by falling over a rock when he was ten years of age, he has always enjoyed good health.

For some weeks before his admission to the hospital his employer had occasion to complain of his forgetting messages entrusted to him, but beyond this symptom his behaviour showed nothing unusual.

His occupation was that of a van driver, but he had previously worked with his father at market gardening.

Three weeks before I saw him he woke one morning with intense frontal headache, and on getting up felt giddy and sick, and everything seemed misty before him.

For about a week he lost all use of his legs, his headaches persisted, he vomited at intervals, and his sight almost disappeared, only having perception of light. For some days afterwards he seemed to improve, he could see more clearly with his right eye, but was almost blind in the left. He also

regained the power of walking, but felt weak in the legs.

He was admitted into hospital under my care January 20th, 1890. His condition then was that of a well-developed and strong-looking lad. He walked with a staggering gait, and like one trying to steady a load on his head. He was unable to stand with his eyes shut. The upper limbs were equally strong; the superficial and deep reflexes normal.

Taste, hearing, and smell were normal. Eyes were somewhat prominent, pupils widely dilated and insensible to light, the left eyelid slightly drooped.

Ophthalmoscopic examination showed both discs to be in a condition of post-neuritic atrophy. The veins of the fundus were large, the arteries considerably contracted, pointing to contraction of the exudation in the nerves. In the left eye the exudation was more widespread than in the right; in the right it was confined to the disc and its immediate vicinity, in the left it extended for some distance, obscuring the vessels at different places. He was able to give an intelligent account of his trouble, and generally seemed to take an interest in things about him.

Three weeks after admission the nurse reported that he had had a fit during the night, and that the convulsive movements were most marked on the right side. For some days subsequently his mental hebetude became marked, he had no perception of light, there was a general weakness in his right side, and in walking the right leg was dragged with difficulty. The face was slightly drawn to the left side.

A careful examination after the scalp was shaved showed no unusual form of bulging nor softening of the bones at any particular part. The lungs, liver, and abdominal organs generally were healthy.

As it was evident that the pressure was mainly in the left motor area my colleague, Mr. Clubbe, trephined over the parietal eminence. On ascertaining the depth to which the trephine had reached, the quill at one spot suddenly entered the cranial cavity, and its withdrawal was followed by pulsating jets of clear fluid. On removing the button of bone the dura mater was thickened, and beneath it was found a hydatid cyst, which had become collapsed during the operation. This was easily removed by a pair of forceps; it measured 4 inches in diameter, with a fluid capacity of 19 ounces. It appeared to be growing from the arachnoid membrane. The bone over the region of the cyst was thinned out to about one-sixth of an inch, and the part of the brain exposed was seen by a reflected light to be dimpled and the "sulci" obliterated.

After a month's convalescence the patient completely regained his power of movement and the use of all his limbs, his mental condition improved, but though his pupils reacted to light there were no symptoms of returning vision.

Plate XXVII., was drawn from the brain of a patient who was under the care of Dr. Watson Munro in Sydney Hospital.

He was 17 years of age, a jockey by occupation. He complained of having suddenly lost his sight after a fit of shivering, accompanied by an attack of vomit-

ing and severe headache three months before his admission into hospital.

The patient attributed his illness to the effects of a fall which he had from a horse six months before.

When he came under Dr. Munro's care he complained chiefly of intense constant pain at the back of his head shooting down his neck and back. He had the expression of *Risus Sardonius*, but no distinct form of paralysis of motion or sensation.

The eyes slightly protruded, the pupils were widely dilated and insensible to light. There was double optic neuritis, and paralysis of the internal rectus of the left eye.

The patient, while under observation, had a troublesome cough, but nothing unusual was revealed by a careful examination of the lungs. The liver and abdominal organs were normal.

He had three convulsive seizures in rapid succession, and died in a state of coma.

The *post-mortem* examination showed a hydatid cyst, the size of a hen's egg, embedded in the occipital lobe of the cerebrum on the right side. The adjacent part of the bone was unaffected by pressure. The cyst was entirely covered with brain tissue. At its upper part the pellucid membrane of the hydatid could be seen through an attenuated portion of brain substance.

In the right lung of this patient two small hydatids the size of a walnut were found, which probably accounted for his cough. They were not sufficiently large to be diagnosed during life. There was also one of a similar size in the left lung.

In a case recorded by Mr. Hawkins in the *Australian Medical Gazette*, 1882, the patient was supposed to be the subject of epileptic attacks. For some time previous to his death he complained of a severe pain at the back of his head and a fulness at the back of his throat. He seems to have been an intelligent lad of 18 years, with no other symptoms than his seizures and headaches. He died in one of his fits. The *post-mortem* showed that a portion of the parietal bone on the right side was very thin and almost transparent. At the back of the right posterior lobe the nerve tissue had given way, and from it was seen protruding the white cyst-wall of a hydatid. It was egg-shaped, and measured three inches in its largest diameter and two inches in its shortest.

Dr. Allen, Melbourne, has recorded notes of an interesting case, which is quoted in Cobbold's *Parasites of Man*.

The patient, a lad aged 15, began to lose power in his left arm and leg for eight weeks before death. During this time he had every week an attack of severe headache, and once he lost sight completely for over half an hour. The day before his death he could walk with help.

At the *post-mortem* a large cyst about four inches in diameter was found in the mid-convexity of the right hemisphere of the cerebrum, slightly towards its anterior part. It formed a marked prominence in the anterior surface of the brain. The brain tissue around presented hardly any induration.

In the case of a girl, aged 17 years, who had the

symptoms of a tumour in the cerebellum, I fully expected to find it of the nature of a hydatid cyst. She resided in a district where the disease was common, and the history of her symptoms reasonably supported my opinion. Her death took place suddenly, and at the *post-mortem* examination I found a small solid tumour, about the size of a walnut, of the nature of a glioma, situated in the left side of the cerebellum.

In each lung there was a small hydatid, filled with daughter-cysts, undergoing calcareous degeneration, which had given rise to no chest symptoms.

This patient had complained of severe attacks of headache, with vomiting, for over a year. She lost her sight suddenly two months before her death, but retained sensation and complete power of movement.

Plate XXVIII., and its accompanying photograph, are taken from the brain of a girl, aged seven years, who was under the care of Dr. Jenkins, in the Sick Children's Hospital, Sydney. Eighteen months before admission the mother noticed that the child, who was previously right-handed, began to use her left hand, and soon after the right arm became quite powerless. The right leg was next noticed to become affected, causing the patient to walk with a limp. For over a year she remained under treatment for what was supposed to be spinal disease, until she began to suffer from headache and vomiting. On her admission into hospital, she was found to be a well-nourished, bright, and active child. The right arm hung helplessly by the side, but could be raised by voluntary effort to

the level of the shoulder joint. The right hand was flexed at the wrist, and the elbow joint was distinctly rigid; there was also great rigidity of the right knee joint and increase of the knee jerk; there was no ankle clonus, no wasting of the muscles, and no alteration of sensation. Hearing, taste, and smell were normal, and the sight seemed good. The mouth was drawn to the side on laughing, but the tongue, when protruded, was straight, and the uvula and soft palate were in no way affected. There was no paralysis of ocular muscles. Examination with the ophthalmoscope showed that there was double optic neuritis, slightly more marked on the left side.

The head seemed unduly large, but symmetrical. It measured $22\frac{1}{2}$ inches in circumference above the ears. On the right side of the head, at the coronal suture, the bones seemed to be slightly separated. Percussion gave a peculiar hollow note over the left parietal eminence. There was no indication of organic disease in any other part of the body.

The diagnosis of hydatid disease was arrived at by exclusion. The points that aided the diagnosis were the absence of a tubercular history, of syphilis, injury, or ear trouble, the strong and healthy condition of the patient, the enlargement of the head, and the presence of intracranial pressure, as evidenced by the widening of the coronal suture, and the fact that hydatids were common in the district where the patient had resided.

Dr. Chisholm removed a button of bone over the upper portion of the fissure of Rolando on the left

cerebral hemisphere, corresponding to the arm area, as mapped out by Reid's lines. The bone was thinned to about one-eighth of an inch. When the portion of bone was removed the cyst bulged up into space, and pulsated strongly. The dura mater was thickened, a fine exploratory needle was introduced, and clear hydatid fluid drawn off. On making an opening in the dura mater, there was a sudden gush of clear fluid, and an opening was seen through the cortical substance of the brain leading into a large cavity. The hydatid cyst was seen lying collapsed at the bottom of this cavity. It was easily removed by gentle traction. There were no daughter-cysts, and it lay in immediate contact with the brain substance. It measured four and a quarter inches in diameter. After the operation the head was dressed with every antiseptic precaution.

The patient quickly recovered from the effects of the anæsthetic, and recognised and named some of the people about her, but she died very suddenly six hours after the operation, the temperature rising to 104° shortly before death.

The *post-mortem* examination showed that the cyst occupied a large part of the medullary centre of the left hemisphere.

Its cortical relations were as follows:—

Its opening on the surface occupied an area immediately in front of the ascending frontal convolution, just on the site of the prefrontal sulcus, and hinder parts of the superior and middle frontal convolutions, the centre of the opening being about one and a

quarter inches from the great longitudinal fissure. The ascending frontal convolution was greatly thinned, and spread out over the posterior bulging part of the tumour, and so also were the posterior halves of the superior and middle frontal convolutions. The upper part of the ascending frontal, though undermined and partly thinned, still retained considerable thickness, and the same might be said of the whole of the ascending parietal behind the Rolandic fissure; the para-central lobule was comparatively intact in its cortical portion, and the inferior frontal convolution was also rather pushed aside and flattened out than actually destroyed.

The main mass of the cyst was in front of the Rolandic area, *i.e.*, in the hinder part; the frontal lobe, and thus the motor area, though no doubt greatly impaired, especially in its anterior portions, was not so completely destroyed as appeared at first sight. The middle and lower parts of the ascending frontal convolution were the parts of the motor area proper which had suffered most profound alteration.

HYDATID OF SPINAL CORD.

IN this region the parasite is comparatively rare, and, unlike hydatid of the brain it generally develops outside the membranes. It may force its way from without into the vertebral canal by widening the inter-vertebral foramina, or it finds an entrance into the canal by absorption of the vertebræ.

Dr. Pedkoff, in the *Lancet* for 1887, reports a case of myelitis, where the patient first noticed a tumour in the back to the left side of the vertebral column. There was loss of motion in the lower extremities, pain in the joints simulating articular rheumatism, loss of sensation followed by retention of urine and constipation. The patient gradually sank and died, when there was found developing in the muscles of the back a hydatid tumour, with about a hundred daughter-cysts, and a quantity of fluid opening into the canal and compressing the cord.

Guy's Hospital Reports for 1875 contains the notes of a case where the hydatid had crowded out the vertebral canal, and made its way into the pleural cavity on both sides, and also by numerous ramifications into the muscles of the back. The diagnosis from other tumours is very difficult,

and the cases, so far as recorded, have terminated fatally.

Cobbold refers to a case of Dr. Annand's, of Melbourne, where the whole length of the vertebral canal was occupied by a hydatid cyst.

HYDATID OF THE KIDNEY AND SUPRA-RENAL CAPSULE.

HYDATIDS of the kidney are by no means rare, and they are sometimes met with in this organ when the rest of the body is entirely free.

It is the most common parasite that attacks the kidney, and it may have attained considerable size before the patient suffers any inconvenience. When it develops in the medullary tissue it seldom reaches a large size, and has a tendency to rupture into the renal pelvis. Its slow growth in one kidney gradually accustoms the other to accommodate itself to the needs of the economy.

Plate XXIVB., was drawn from a case of multiple hydatids, where one had developed on the serous surface of the kidney.

Hydatids are rarely found between the capsule and the gland, most commonly they are situated in the renal tissue, and may grow to such a size as finally to destroy all the kidney substance. They attain to their greatest size when they develop from the substance of the cortex.

There is usually a thick, firm capsule, as is generally the case in hydatids of the abdomen. The ectocyst may be highly vascular.

The hydatids may be simple, or contain numerous

daughter-bladders. They sometimes reach down into the iliac fossa, and up to the diaphragm, and may in consequence be difficult to distinguish from a cyst of the liver. They may also be confounded with ovarian tumours.

The diagnosis is only made certain when the contents are found to be voided with the urine.

They may also rupture into the chest cavity, and be expelled through the bronchi, in which case a urinous odour has been noticed with the expectoration.

Two-thirds of the recorded cases opened into the pelvis of the kidney, and the symptoms were generally similar to those experienced in renal colic; pain of a sudden excruciating character, darting down the hip and thigh, vomiting, retraction of the testicle, with some blood in the urine. In these cases the swelling has disappeared gradually, and often spasmodically.

Whole daughter-cysts may be passed by the urethra. In a case recorded by Ziemssen, the patient (a woman), who was suffering from retention, extracted with her own fingers a cyst which was blocking up the urethra.

Daughter-cysts may, perchance, rupture into the bladder from hydatids of the abdominal cavity, but such a termination would seem to be very rare.

When they rupture into the pelvis, and the contents become expelled per urethram, the termination is generally a very favourable one, but the complication of pyelitis may supervene after the expulsion of the parasite, and retard the recovery.

Hydatids in the suprarenal capsule are rare. There is a case of Huber's (referred to in Ziemssen, vol. IV.)

of a patient, aged 63, who had a severe attack of pain in the right hypochondriac region. Six years previously he had been taken ill with loss of appetite, severe pain in the right hypochondrium, and great weakness. He died from extreme exhaustion. The *post-mortem* showed that the right suprarenal capsule had been transformed into a tumour the size of a walnut. This had a fibrous capsule and a central ulcerated cavity. The tumour was evidently of the multilocular form.

Plate XXIVc., is that of a hydatid replacing the suprarenal capsule. In shape it very much resembled a cocked hat. It contained no daughter-cysts.

The patient was a man, aged 35 years. His skin was of a tawny yellow colour. There were none of the other characteristic symptoms of jaundice. The palms of the hands and the soles of the feet were much lighter than the skin of the body. The tawny colouration was uniform, and did not occur in other patients.

He was in a very feeble, asthenic condition, and died a few hours after I saw him. There was a small hydatid cyst in the liver, which did not encroach on the common bile duct; there were also numerous hydatid cysts in the peritoneum. Some days before his death he passed a large quantity of blood per rectum.

HYDATIDS OF THE SPLEEN AND PANCREAS.

HYDATIDS of the spleen are not infrequent; in some cases they may be confined to this organ alone, but most commonly the liver and peritoneum are infected at the same time.

They are usually felt readily through the abdominal wall. The symptoms they produce are those of a feeling of fullness and weight over the splenic area, or of mechanical pressure on the stomach. They may give rise to symptoms of gastric irritation.

In most cases there is comparatively slight disturbance to the general health. The differential diagnosis between such a condition and the other forms of enlargement of the spleen is usually easily established.

In the case of a woman, aged 42, who died from exhaustion from a large suppurating hydatid on the liver, I found nearly the whole spleen replaced by a hydatid containing daughter-bladders.

Dr. W. Paget (*British Medical Journal*, 1880) mentions the case of a patient, aged 39, whose death took place suddenly in attempting to clear his throat of a piece of hydatid membrane from a cyst in the lung. At the *post-mortem*, he found the spleen replaced by a hydatid tumour, measuring 9 inches long, 6 inches broad, and 4 inches thick, filled with

daughter-cysts of different sizes. In this case the liver was unaffected.

Plate XXX., was drawn from the spleen of a male patient, aged 38, who died from valvular disease of the heart. The cyst was deeply embedded in the substance of the organ, and contained several hydatid cysts. There was an absence of hydatids in all the other organs.

In two cases, one in a boy, aged 11 years, and another in a woman, aged 25, where I drew off $2\frac{1}{2}$ pints and 1 pint of hydatid fluid respectively, from cysts in the spleen, alarming symptoms of collapse followed. Other writers have recorded a similar experience in tapping cysts of the spleen. In the case of a lad with a large hydatid in this region, I performed aspiration while the patient was under chloroform, and the result seemed to me to be much more satisfactory in avoiding the collapse which I formerly witnessed when the anæsthetic was not employed.

The hydatid is sometimes met with in the pancreas. I have observed it as a cyst about 3 inches in diameter, replacing the head of this organ. The patient had also a suppurating hydatid of the liver, causing obstructive jaundice. The hydatid in the pancreas was not diagnosed during the life of the patient. The liver-cyst had suppurated, and caused the death of its host.

The diagnosis of a hydatid cyst in the pancreas will depend on the size it has attained and on its position in relation to the organ, and whether the pancreas

has become sufficiently involved so as to have its function completely interfered with.

The presence of other cysts in the peritoneal cavity is commonly met with in those cases where hydatids in the pancreas have been found.

HYDATIDS IN BONE.

HYDATIDS are sometimes found developing in the medullary cavity of large bones.

From mere pressure they are occasionally found to force their way through the bones of the skull, chest, and vertebral column, but their presence in the shafts of large bones may only be detected from a fracture, either spontaneous or resulting from a slight injury, or in the operative treatment for long-standing necrosis.

Leuckart mentions a case of Dupuytren's where a patient had a hydatid in the medullary cavity of the humerus, and where the shaft of the bone broke while the patient was in the act of throwing a stone. The hydatid may break through at one part, and, spreading among the surrounding muscular tissue, complicate the diagnosis.

Dr. Coppinger, Belfast (*British Medical Journal*, 1887), had a patient under observation for three years for necrosis of the femur; he made an incision over the trochanter, and scraped and washed out the sinus in the necrosed bone. In the contents he found granular debris and numerous scolices.

Dr. Leacock, of Camden, N.S.W., reports a case (*Australian Medical Gazette*, November 1887) of a boy, aged 12, who could only give a history of having

received a kick over his left knee-joint. For seven years he had been unable to straighten the limb properly. The joint was painful and enlarged. There were no signs of suppuration, and but little effusion. There was often severe pain at night, and the patient's health was giving way.

An operation with a view to resection or amputation was undertaken. The cartilages were found slightly eroded, and there was a perforation large enough to admit the tip of the finger into the femur, otherwise there seemed nothing amiss with the joint. In sawing through above the condyles the bone was found to be a mere shell, in some parts scarcely thicker than paper, and the cavity crowded with hydatid cysts, from the size of a small pea to nearly an inch in diameter.

Landau (*Archiv fur Gynäkologie*) records a case of a hydatid of the right side of the chest, where there was complete destruction of the ribs in the parasternal line over a considerable area.

Dr. John Ogle (*Transactions of the Pathological Society*, vol. IX., p. 299) records a case where the hydatid originated in the spinous process of the seventh cervical vertebra, and projected into the spinal canal.

Dr. Davies Thomas (*British Medical Journal*, September 1886) refers to a case where the primary seat of the hydatid was in the right os ilium.

Cobbold refers to the collection of hydatids in bone in St. Thomas' Hospital Museum, and especially to that of a humerus, taken from a man, aged 34 years, where the shaft was occupied throughout by small

hydatids that had destroyed almost all the cancellous structure ; in some places there was little more than periosteum left.

There are also two preparations by Mr. Travers, from a man, aged 38 years, in whom numerous small hydatids occupied both the head of the tibia and the lower end of the femur. They freely communicated with the knee-joint, necessitating amputation of the limb. I have also had a case reported to me where a hydatid cyst was found in the distal phalanx of the index finger of the left hand of a patient, giving the end of the finger a curious clubbed appearance, and destroying the whole of the bone.

Plate XXXII., represents a humerus of the left side removed from a female patient, aged 35 years. There was a diffuse tense swelling in the tissues of the lower portion of the arm, which, on being incised, allowed a quantity of pus and small hydatid cysts to escape. On examining with the finger it was found that the cavity of the bone had become much distended, and filled with minute daughter-cysts throughout its entire length. At the upper and lower portions of the shaft the bony substance of the walls had in part disappeared. At the lower portion of the bone the shaft was converted into a fusiform sac, in which were a large number of cysts, most of them entire and healthy.

The arm was amputated at the shoulder, as it was considered that the bone was practically useless. The shaft had lost almost the whole of its bony walls, the head and lower extremities alone being

free from the encroachments of the parasite. There was no trace of a parent cyst. It is probable that the growth of the cyst took place exogenously, as so commonly occurs when the hydatid develops in this region.

HYDATIDS IN THE HEART.

HYDATIDS are sometimes found in the heart and the pericardium. Plate XXXI., was drawn from the heart of a strong, powerful man, who, in the act of breaking stones, dropped down dead. Beyond a feeling of tightness in the chest he had complained of nothing amiss in his health. The wall of the left auricle contained a hydatid with numerous daughter-cysts, the left ventricle was hypertrophied. The cyst had ruptured into the pericardium.

Dr. Bird (*Medical Times and Gazette*, August 1873) found a hydatid filled with daughter-cysts occupying the whole of the outer surface of the heart, extending from the upper surface of the auricles, and surrounding the large vessels. Some of the daughter-cysts were the size of small oranges.

It seemed to have arisen in the visceral layer of the pericardium, not encroaching much into the muscular substance. The cavities of the heart were untouched by the parasite.

Brodribb (*Lancet*, 1837-38, p. 628) records the case of a lad, the right ventricle of whose heart was so occupied by a hydatid cyst as to cause fatal interference with the passage of blood into the pulmonary artery. Death took place after a sudden attack of dyspnoea and cardiac oppression.

Peacock and Hicks (*St. Thomas' Hospital Reports*, 1864) record a case of a lad, aged 18 years, where there was a partially collapsed cyst with thickened walls on the surface of the right ventricle, partly embedded in the muscular structure, but not projecting into the cavity of the ventricle.

In the *Australian Medical Gazette*, 1879, Sterling and Allen record a case of hydatid in the substance of the right ventricle at its apex. It was the size of a hen's egg, and full of daughter-cysts.

In the Sydney University Pathological Museum there is a preparation of a hydatid cyst occupying the interventricular septum. The cyst seemed to occupy about three-fourths of the original space of the left ventricle, and encroached also on the cavity of the right ventricle. Thomas has collected numerous cases where hydatid cysts were found in various branches of the pulmonary artery.

The diagnosis in cases of hydatids in the heart is very difficult. They usually result in the sudden death of the patient.

HYDATIDS IN THE UTERUS AND ITS APPENDAGES.

Dr. J. J. HILL records a case of uterine hydatids in the *New South Wales Medical Gazette*, for January 1872, where the patient, aged 41 years, sought relief for menorrhagia and bearing down pains. The uterus was much enlarged, extending up to the umbilicus. The "os" was soft, flaccid, and open. After a few days' observation and medicinal treatment the patient sent for him hurriedly, when he found the vagina full of small cysts, varying in size from a pea to that of a grape.

The notes of this case do not make it quite clear that the cysts removed were not portions of the ordinary hydatiform mole, a pathological condition resulting from the dropsical swelling of the chorionic villi. The symptoms, the size of the so-called cysts, and the rapid recovery of the patient, would seem to point to the case not being one of Echinococcus disease.

There is no doubt that many of the cases recorded as hydatids in the uterus were of the nature of degenerated villi of the chorion.

Hydatid cysts are occasionally found developing in the serous covering of the uterus, also in the anterior and posterior pouches, and in the broad ligaments.

I witnessed an operation by Martin at his private hospital in Berlin, for the removal of two tumours attached to the serous surface of the uterus; they were freely moveable, having each a long constricted pedicle. The diagnosis of subserous fibroids was made before abdominal section showed their true nature. On lifting them out of the abdominal cavity to ligature their pedicles they burst in the operator's hands. They were hydatid cysts the size of a man's fist, and enclosed in a serous covering, with a long constricted pedicle.

Plate XXXIV., was drawn from a specimen taken from a patient who died after an operation for the removal of a large hydatid cyst in the liver.

There were two large cysts situated in the broad ligament of the right side.

Two other cysts, filled with purulent contents, were found growing from the upper surface of the fundus of the uterus.

There are some cases recorded of hydatid cysts growing from the ovary, but the records of these cases do not make it quite clear whether they were actually situated in that organ, or only destroyed it by pressure, while their actual seat of growth was some adjacent structure.

HYDATIDS IN THE BREAST AND AXILLA.

PLATE XXXIII., was drawn from a patient who was admitted into the hospital for treatment, under the care of Dr. Clubbe.

She had been married thirteen years, and had nine children. After the birth of her fifth child, seven years ago, she noticed a lump on the right breast, on the outer side of the nipple, and nearly the size of a hen's egg. Since then the breast had gradually increased in size, and the patient considered that it had made most progress during the last three lactations, remaining comparatively quiescent in the intervals. She had only felt pain in it for a few days before admission, and this she attributed to the effects of a knock she received while at her housework. On examining the breast it was found to be occupied by a tense, rounded tumour, extending more to the outer than to the inner side of the nipple. A distinct wave impulse could be made out on tapping with one finger, while two fingers of the other hand steadied it in an opposite direction. There was a glandular enlargement in the axilla. On the right side of the breast the skin was oedematous and a little tender. This had only been present, the patient thought, for a few days. A fine needle was inserted, and clear fluid withdrawn. Hooklets were seen under the microscope.

The breast was laid freely open ; the cyst-wall was found firmly adherent, and could not be pulled off without causing bleeding. It, however, came away afterwards in pieces with the discharge.

Hydatid tumours may be met with in the breast occasionally, and their size and appearance may baffle the most careful attempt at diagnosis.

Macgillivray (*Hydatid Disease*) mentions two cases of women, one of whom had a tumour in the right breast about the size of a hen's egg. The patient had felt it for four years ; when it was first noticed it was the size of a hazel nut. The exploratory needle gave no positive result. On cutting down on the swelling it was found to be a hydatid cyst, containing putty-like material of a hydatid nature. The other woman had a deep-seated lobulated swelling, of a hard feel, in the right breast. The skin over the most superficial part of the swelling was retracted and adherent. There was considerable pain at times, but no affection of the axillary glands. On incision the swelling was found to consist of a hydatid with eight daughter-cysts, the largest the size of a pigeon's egg. Macgillivray has also recorded a case where the tumour was situated in the axilla, and led to sloughing of the axillary artery, and consequent fatal hæmorrhage.

A similar case is referred to in a paper read by Dr. Muskett, Sydney, N.S.W. (*Australian Medical Gazette*, 1886), where the patient was a young child.

HYDATIDS OF THE EYE AND ORBIT.

THE hydatid has been observed in the interior of the eye, and associated with complete loss of sight.

More frequently it is found in the orbit.

Macgillivray records a case (*Hydatid Disease*) of a patient, aged 40, who, for six years, had felt the power of vision of his right eye gradually becoming impaired. At the time of his seeking advice the eye was noticed to protrude a little and turn up. The sight was limited to the perception of light. A tense, fluctuating tumour could be felt beneath the lower lid. Nine daughter-cysts were evacuated, the largest weighed half an ounce.

Dr. Gosse, Adelaide, records the case of a lad, aged 17 (*Australian Medical Gazette*, 1885), where the eye was prominent, and pressed downwards and outwards to the temporal side by a hydatid. The patient's sight was only partially affected. The ophthalmoscopic examination showed that the veins were dilated, the arteries small and pale, the optic discs hazy, and their outline indistinct. On opening the cyst a few daughter-cysts the size of filberts escaped.

The majority of the cases recorded have resulted in the destruction of the eye.

In two cases, one a boy, aged 14, the other a man, aged 25, both of whom had lost an eye from injury some years previously, I removed hydatid tumours, each containing daughter-cysts; they were growing from the tissues of the stump. There was no trace of the parasite in any other organ. Pain was present in both cases.

TREATMENT.

THE growing Echinococcus of internal organs is a constantly threatening danger to its host, and whenever its true nature is revealed no time should be lost in attacking it in the most thorough manner.

The expectant treatment can only be followed in a very limited number of cases, where the cyst has burst before advice has been sought, and the contents have found a means of easy exit by one of the natural channels of the body without seriously affecting the condition of the patient. Such may be the case with cysts that burst into the ureter, when the contents pass per urethram or by the bowel, or in the case of hydatids of the lung that burst into a bronchus and are expectorated; but even in some such cases the safety of the patient is best insured after the cavity has been drained by free incision.

From time to time certain medicinal remedies have been advocated by some medical men who have had considerable experience in the treatment of hydatid disease. In 1867 Dr. Hjaltelin brought under the notice of the profession the use of Kamala in this disease (*Edinburgh Medical Journal*, August 1867). He believed he had obtained some satisfactory results that he attributed to the influence of the drug.

Dr. Macgillivray published his experience of the

efficacy of kamala in this disease (*Australian Medical Journal*, July 1872). In his cases it had no effect whatever, beyond producing intestinal irritation, to which action probably the drug owes its reputation as an anthelmintic. Dr. Bird, Melbourne (*Hydatid of Lung*), believes that medicinal remedies are of some avail, and he records some cases of the disappearance of the cysts under drachm doses of tincture of kamala, combined with bromide of potash. In his wide experience he has also found benefit from the employment of turpentine internally, which he ascribes to its anthelmintic powers and ready diffusibility.

Dr. Thomas (*Hydatid of Lung*) is of opinion that, beyond relieving intercurrent symptoms, medicine is of no avail, and simply adds to the distress of the patient.

In some of Dr. Bird's cases, where he attributes a favourable result to medicinal measures, the cysts had been tapped twice or thrice, and had refilled; these cases are, therefore, unreliable as a test, though the cysts did disappear during the regimen of turpentine or kamala. Mere tapping is in itself a remedy which occasionally leads to recovery; even when the cyst refills the nature of the fluid is altered, and the vitality of the parasite is affected to such a degree that the exploratory puncture may lead to its death.

Dr. Heckford (*British Medical Journal*, 1868) observed in the case of a woman, aged 22 years, that a hydatid in the left lobe of the liver disappeared in five weeks under the use of 27 grains of iodide of potash daily.

Davaine thought that he had obtained some good results from the salts of mercury. I have frequently employed kamala and turpentine in large doses, without being able to record any special action in their favour. I am of opinion that the practice is absolutely without any benefit, and only serves to disturb the alimentary canal of the patient, thereby increasing the risk of rupture of a tense cyst from the vomiting and tenesmus, which sometimes result from their administration.

In some cases where kamala and iodide of potash had been given in large doses, with the view of causing the death of the parasite, there was no evidence of any degenerative change having taken place when the cyst contents were removed some weeks afterwards, and only in one case could faint traces of iodine be found. In three cases of hydatid of the brain, where the diagnosis for a time was not clear, I observed that the patients got marked relief from the severe headache which they complained of, by the administration of large doses of bromide of potash.

In each of these cases a considerable part of the brain substance was encroached on by the growth of the cyst. The temporary benefit was to be attributed to the reputed sedative action of the drug on the brain centres generally.

OPERATIVE TREATMENT.

THE various methods of operative treatment in hydatid disease have been exhaustively reviewed by Davies Thomas, in his papers published in the *Transactions of the Inter-Colonial Congress* for 1889, and in the *Australian Medical Journal* for 1888. To the same *Transactions* Dr. Gardner, Adelaide, contributes a concise and able account of the surgical treatment of this disease, and records his own views in a very definite manner, strengthened by statistics of cases from his own experience. The opinions of some of the principal surgeons in Australia regarding the methods of operative interference in this disease are also recorded in the same *Transactions*.

The methods of treatment now are practically limited to (1) tapping, and (2) free incisions, with entire removal of the cyst contents. The other modes of operative procedure which have at various times been employed, while they aim at the same result, have so many objectionable features as to lead to their being practically relegated to the past history of the subject. Successful results have been claimed for each of the various methods, either by the originators themselves, or by others whose experience is based on a small group of cases; but while it is abundantly evident that cures have been recorded from all of

them, it is not so clear that the processes of cure have been brought about by any specific result of the special principle of the operation.

The various modes of treatment employed have been :—

- (1.) Simple tapping, with or without the aid of the aspirator.
- (2.) The injection of various kinds of fluid, such as bile, iodine, perchloride of mercury, carbolic, Condy, alcohol, extract of the male fern, &c.
- (3.) Electricity.
- (4.) Introduction and retention of a large trocar and cannula.
- (5.) Free incision and drainage.

Nos. 4 and 5 of these methods have been carried out in different ways.

The trocar and cannula may be directly introduced and retained, or a circle of needles or hare-lip pins may first be inserted for a period of 8 to 12 hours, with the view of promoting adhesions between the visceral parietal layers of the peritoneum, or an opening is made down to the peritoneum with the knife, or by means of potassa fusa or the actual cautery.

The methods of incision and drainage comprise the direct opening into the cyst, and the immediate stitching of its wall to that of the external opening, allowing the contents to be expelled spontaneously; or it may be performed in two stages, the preliminary operation consisting of a dissection down to the parietal layer of the serous membrane, then packing the incision thus made with some aseptic gauze, the

opening of the cyst itself being postponed for some days, in order to ensure the presence of adhesions.

The same methods of procedure are followed in the operation which certainly has given the best results, namely, where the whole bulk of the cyst contents are removed at the time of the operation, and the cavity freely irrigated with some mild antiseptic lotion.

Tapping with a fine trocar and cannula, with or without the addition of the aspirator, has long been the means most commonly employed in the treatment of hydatid tumours of internal organs. This method has many ardent supporters at the present day, though the recent observations of some authorities go to show that the method is more frequently ineffectual than is generally supposed.

It is claimed for aspiration that it frequently results in a cure, that it is simple and easy in its application, and that the patient much more readily submits to this form of operation than to the bolder method of free incision. It is applicable only in those cases where the cyst contents have not suppurated, and where there is an absence of daughter progeny.

Some authorities look with disfavour upon the additional use of the aspirator to the trocar and cannula. Fitzgerald, of Melbourne, speaks of it as involving the risk of exhausting the receiver to such an extent that the dilated vessels of the adventitia may be ruptured, and a dangerous and even fatal hæmorrhage follow. Dr. Bird (*Hydatid of the Lung*) has found no special advantage to be derived from its use, and Macgillivray

speaks of the simple trocar and cannula as the safest and most satisfactory.

It is important to remember that the puncture of an internal hydatid, simple as it may seem, may be followed by very serious results, so that it should never be undertaken without the surgeon having everything ready for the major operation, as the necessity for such a course may arise suddenly.

In a consulting room, for example, the medical man is often pressed to give a definite opinion as to the nature of a tumour in his patient, and an awkward casualty might arise, which, to the public, would at least seem less terrible if it happened in the patient's own house, and the risk were carefully explained beforehand.

I lately sent a patient from the outdoor department into the hospital ward for the purpose of inserting a fine exploratory needle, with the view of verifying the diagnosis in a case of abdominal hydatid. As soon as the needle was inserted the patient became faint, and collapsed, the face became dusky, and the pulse small and uncountable. In spite of every effort that was made the patient died ten hours after the needle was inserted. The *post-mortem* showed the presence of three large hydatid cysts in the liver, and two small ones in the left lung. There was no evidence of extravasation into the general peritoneal cavity, and beyond a slight extravasation of blood along the track of the needle, the needle puncture in the cyst had become obliterated.

I had as serious an occurrence in the case of a

patient who presented himself at the hospital, complaining of dyspnoea which he had felt for six months. The right side of his chest was absolutely dull from base to apex, and by way of clearing up the nature of the dulness I inserted a hypodermic needle in the sixth intercostal space. The patient gave a sudden cough, then gulped up some mouthfuls of clear fluid, and, after a few convulsive sobs, died.

The *post-mortem* showed that the whole lung was practically converted into a hydatid cyst, and that the sudden cough on the introduction of the needle had led to its becoming ruptured and flooding the healthy lung.

In the cases of two patients, one of whom, an aboriginal Australian, had a hydatid the size of a foetal head in the base of the left lung, and the other one in a corresponding place in the right lung, the symptoms of suffocation and distress became so alarming after insertion of the needle that an immediate incision through the chest wall had to be made, and the cyst and its contents removed. In both cases instant relief followed, and the patients perfectly recovered.

I have frequently noticed, after puncturing an abdominal hydatid, troublesome and anxious symptoms persist for several days—vomiting, severe pain, high temperature, and rapid pulse; it is in such cases that the rash often makes its appearance. It is not easy to explain the cause of these symptoms from the shock of the operation, neither can they be explained by any inflammatory attacks resulting from extravasation of fluid. The symptoms are generally too rapid in their

onset, often appearing immediately after the withdrawal of the needle.

I have never been able to detect a true attack of peritonitis resulting from fresh hydatid fluid extravasated into the abdominal cavity, and it has yet to be determined whether the cause of these distressing symptoms so often to be found is the absorption of the fluid itself, or whether they are reflex in their character, or whether these causes are combined.

It is difficult to test the value from statistics of aspiration as a means of cure in hydatid disease. In the majority of such cases, the patients being satisfied with some actual and visible proof of the removal of their disease, are lost sight of, and many, discontented at the reappearance of the swelling, are apt to seek other advice, so that it is a matter of great difficulty to get a true return of the percentage of cures. Besides, the swelling may reappear after years of an interval, so that the patient may be out of the reach of communication or observation.

There is no doubt that treatment by aspiration does occasionally result in a cure. Fitzgerald makes reference in the *Inter-Colonial Medical Transactions* to a case where he had tapped a liver cyst, and withdrawn four or five pints of hydatid fluid. The patient died three years afterwards from apoplexy. At the *post-mortem* examination he found the sac dense, leathery, and shrivelled, without a trace of fluid in it. He also refers to other cases where, years after tapping, he had found in the patient,

who had died from other causes, the cyst-wall lying folded up within the adventitia, and perfectly dry.

Macgillivray (*Hydatid Disease*) cites the case of a young woman, aged 23, with a cyst in the liver, which partially refilled after he had withdrawn eleven ounces of clear fluid, with numerous scolices. Nine months afterwards there was no trace whatever of the swelling.

Dr. Verco, South Australia, mentions a case where he drew off a gallon of hydatid fluid from the liver of a patient; a year afterwards there was no trace of the tumour. He also gives it as his opinion that cure from a single tapping is more common than is usually supposed, and that the reappearance of the swelling may, in some cases, be due to the growth of a second cyst, small and insignificant at the time of tapping the first.

The slow growth of hydatid tumours is against such a view, so is the altered nature of the fluid usually found in all subsequent tapplings.

Plate XIV., was drawn from a woman who had a very large hydatid tumour in the abdomen. I drew off by aspiration $14\frac{1}{2}$ pints of clear fluid containing scolices. Three weeks afterwards the cyst had refilled to about half its original size; I again drew off $6\frac{1}{2}$ pints of dark fluid, containing numerous pus cells. During the subsequent four weeks her temperature remained persistently high, and the swelling became gradually hard and firm. She promised to return if her tumour gave her any further incon-

venience, but has not yet done so, although it is over three years since.

Success in some cases may be claimed after several tapplings of the same cyst.

In one case of a liver hydatid I drew off three pints of fluid, slightly bile-stained, containing scolices and hooklets. Ten days afterwards the cyst seemed to be as large as ever, and I drew off two pints four ounces. The fluid contained numerous pus cells, which, however, seemed to make little difference to its fluidity.

On the twenty-second day from the first tapping I drew off one pint, one-fourth of which was pus; on the thirtieth day a pint and a half, very similar in its character to the last was withdrawn, and on the thirty-fifth day 12 ounces of pus. The cyst made no further attempt to fill. Six months after the patient had left the hospital he communicated with me, to the effect that there was no appearance of the swelling.

Dr. Morrison records a case in the *Australian Medical Journal* for 1883, where at the first tapping he drew off 130 ozs. of heavy, yellowish-green liquid. A few days afterwards the tumour regained its former shape. He tapped on six different occasions afterwards, and drew off quantities of fluid, varying from 177 ozs. to 43 ozs. His last tapping was almost dry. The cyst remained quiescent for four months until after a violent attack of sea sickness the swelling reappeared, the contents were so thick when the patient again came under treatment that it had to be treated by incision.

Dr. Morrison recommends the application of pressure

over the position of the tumour, in the form of a pad adjusted with a bandage, as soon as the cyst is emptied by the aspirator, maintaining that it helps to approximate the walls of the ectocyst, and to diminish the effusion which generally takes place after tapping.

The suggestion is of some value in those cases where the position of the tumour permits of such pressure, but as a rule it will be found to be inapplicable and inefficient.

The rationale of tapping is that after the withdrawal of the fluid the true cyst-wall collapses, and falls away from the adventitia, and that soon after an exudation of serum takes place from the vessels of the ectocyst, which become dilated in consequence of the removal of the intra-cystic pressure. I have observed in some cases which had been treated by incision that when the cyst-wall was not removed at the time of the operation it readily broke down into a fine granular *debris*, and passed off with the discharge from the cavity. The same fate, in most cases, probably befalls the cyst-wall after tapping. Disturbed from its vital relations it readily becomes a suppurating mass, and breaks down into amorphous *debris*.

Hilton Fagge (*Practice of Medicine*) recommends that a period of one year should elapse after a cyst has been tapped before it is interfered with again, as by that time it will have been shown whether the hydatid has any tendency to disappear.

The cyst cavity will, in many cases, be found to have refilled in a few days, and as the contents are apt to suppurate it is not safe to let the patient go out

of one's care before a thorough cure has been effected.

It is alleged that in some cases the mere withdrawal of a small quantity of fluid from the cyst may so disturb the vitality of the hydatid as to lead to its ultimate disappearance without any further interference.

Dr. Wilton Hind (*British Medical Journal*, 1886) reports a case of hydatid in the liver of a woman, aged 40. The dulness extended 2 inches below, and 3 inches to the left of the umbilicus, shading off into the stomach resonance. There was great bulging over the area of dulness. He could only draw off 6 ozs. of clear hydatid fluid, no more would flow through the cannula.

For a few days the patient had a slight rise of temperature, but it soon disappeared. He noticed that the swelling was getting less about a week after the tapping, and in a month's time there was very little enlargement to be seen. He saw the patient two years afterwards, and she was quite free from her old trouble.

Such a fortunate result from this means, however, is in no way to be relied on, as it is neither the rule nor even a common occurrence; besides, the cyst contents in such a case may have partly passed into the general peritoneal cavity, or the configuration of the cyst may have so altered as to give the appearance of having shrunken, or its contained daughter-cysts may have gradually collapsed, and the mother cyst become contracted, converting the

tumour into a solid, caseous mass, a mode of cure which nature sometimes brings about, but which cannot be induced.

Treatment of hydatid cysts by aspiration is a means of cure which I believe to be unsatisfactory, and except as an aid to diagnosis its use should be limited.

In some cases of multiple hydatids the surgeon may have no alternative left him but to use the aspirator as a palliative measure. Plate VIII., was drawn from a case in which the liver was enormously hypertrophied. In its substance were three large separate hydatid cysts, all containing clear fluid and free from daughter-cysts. They were all three covered on their surface by a thick layer of liver substance, and growing apart from one another. The exact condition could only have been ascertained after an exploratory excision, and a radical cure would have necessitated three abdominal incisions wide apart from each other. The patient had several hydatids in other regions of the body, so that aspiration in his case would have been an appropriate means of relieving the distress which the liver cysts were causing.

In using the aspirator for exploratory purposes in the case of some liver cysts one may occasionally fail to strike the fluid over the anterior surface of the liver, even though the bulging seems localised and prominent. The cyst in such cases may be growing from the under surface of the liver and pushing the mass of liver substance before it against the abdominal wall.

Plate VI., shows a case in which the cyst was growing from the upper and posterior part of the liver, causing the mass of the liver substance to be pushed downwards and to the front. In such a case there is nearly always bulging of the ribs over the seat of the tumour.

The following tabulated statistics by Dr. Davies Thomas, showing the results of tapping operations upon hydatids in various parts of the body, is an interesting and valuable contribution to the treatment of the subject.

Situation of Cyst.	Deaths.	Not Relieved.	Failure of Puncture (other operation).	Relieved.	Reputed Cures.	Result Un-known.	Total.
Liver	73	5	92	68	168	10	411
Lung	14	—	20	1	14	4	53
Spleen	2	—	7	4	6	1	20
Kidney	—	—	4	—	2	—	6
Omentum, mesentery, &c.	1	—	3	—	3	—	7
Abdomen	1	—	1	5	1	2	10
Male pelvis	4	—	4	—	5	—	13
Total	95	5	131	78	199	17	520

The summary of results he gives as follows :—

Deaths 18·88 per cent.
Not relieved 0·99 „
Unsuccessful puncture followed by other operation 26·04 „
TOTAL FAILURE OF PUNCTURE	. 45·91 „
Relieved 14·51 „
Reputed Cures 39·56 „
TOTAL SUCCESS OF PUNCTURE	. 54·07 „

He also draws attention to the fact that though the total success of puncture is stated as 54 per cent., the majority of patients had not been under the observation of the operators sufficiently long to justify the conclusion that a permanent cure had been effected.

In seventy-five cases of hydatid cysts, including eight in the lungs and sixty-seven in the liver, where I closely observed the effects of aspiration, I found that twenty-seven returned again at periods from two weeks to five years, and had to be further treated by incision.

Six died from the effects of tapping, three of these from the direct and immediate result of the tapping, and three from attacks of pleurisy which followed the operation.

Of the twenty-seven cases which had to be treated by incision, and where aspiration had previously been tried and failed, ten died.

Of thirteen cases treated by direct incision, without any previous treatment, eleven recovered and two died.

Of the cases treated by aspiration, one was discharged as unrelieved, the cyst refilled, and the patient was unwilling to submit to any further operation; the others were under observation from three days to six weeks. Two of these cases were aspirated twice, four three times, two four times, and one seven times. I recently saw one of the patients, a boy, in whom I had aspirated a hydatid of the spleen ten months previously. There was still a fullness over the site of the cyst, and the boy was not in good health, being

pale and thin, and complaining of pain over the region operated on. I have also seen a patient who had a cyst in the liver aspirated three years previously, and in whom there was no evidence of the hydatid having refilled.

Treatment by aspiration is limited to hydatids which do not contain daughter bladders, and even in single cysts it frequently fails to cure, and is sometimes attended with serious consequences. Moreover, in a large number of these cases, where this method has been applied, and failed, the patients are left in a less favourable condition to withstand the strain of further operative procedure.

In an able paper (Inter-Colonial Medical Congress, 1889) by Dr. Gardner, of Adelaide, on the operative treatment of hydatid disease, he writes of aspiration as being "decidedly unreliable," and states, further, that his experience has led him to give it up, "except as a diagnostic aid at the time of performing a radical operation." Dr. Davies Thomas, in a paper read at the same Congress, says that "until quite recently in Australia, puncture has been the recognised regular mode of treatment for all cases of internal hydatids." This fact alone should be proof that sometimes cure results from tapping operations; but, on the other hand, it is certain that in a large proportion of cases it fails to rescue the patient from death.

It must also be conceded that the treatment by puncture is attractive from its simplicity, and its apparent freedom from risk. Moreover, if we accept

without criticism the statements of many of its advocates, it might be concluded that failure to cure by it is exceptional. But a closer scrutiny brings with it much scepticism, for the statistical data, based upon the number of reputed "cures" by tapping operations, are to the last degree unsatisfactory, inasmuch as it is certain that in many of them the cyst refills, and becomes a source of peril to the patients. Such an occurrence has been known to take place even as long as ten years after the patient was believed to have been cured; indeed, it is almost impossible to fix a time at which a hydatid cyst, treated by puncture, may safely be said to be cured. It follows, therefore, that in statistics bearing upon this question the number of reputed cures must be accepted with very large reservation.

Simple and harmless as puncture with a trocar generally is, yet it not unfrequently happens that alarming symptoms follow it, and in a few cases death has even taken place. I have elsewhere (*Australian Medical Journal*, 1888) referred to three cases in which death occurred immediately after the puncture of hydatid cysts in the liver, apparently from shock. I have also seen a patient in imminent danger for hours from shock after a puncture of a hydatid cyst of the spleen, although a very fine needle was used.

Jonathan Hutchinson, in his *Archives of Surgery* for April 1890, records a case of an abdominal hydatid cyst, which is interesting from the point of view of treatment. The patient had been tapped by him twelve years before, when about a pint of clear

fluid was drawn off. After the tapping the boy returned to the country, and was occasionally heard of, always with the statement that he was quite well. Eleven years later he was brought to him again, his abdomen having been steadily increasing in size. He opened the abdomen by incision, and removed a large number of daughter-cysts. The fluid in which they were was opaque and whey-like. He remarks that in his opinion the case "illustrates the fact that in some cases what appear to be cures of hydatid tumours by simple paracentesis are not always such. In this instance the tumour did not begin to refill after the first tapping for several years, and we thought the patient cured."

"Its increase was afterwards very slow and insidious. I have published many years ago," he adds, "several cases in which I believed that cures had resulted from simple drawing off the fluid from hydatid cysts. With the light thrown upon the disease by this case, however, I cannot but admit that it is very possible that in some of these the disease may have relapsed."

TREATMENT OF HYDATID CYSTS BY DIRECT INCISION AND EVACUATION OF THEIR CONTENTS.

TREATMENT of hydatid cysts by direct incision and stitching the cyst-wall to the parietes is the method which has decidedly given the best results in the hands of surgeons experienced in the treatment of this disease.

Lindemann first performed the operation in 1871 in the case of a liver hydatid in a woman. The opening in the cyst was attached to the abdominal wall by deep stitches, and the patient made a rapid recovery.

Lawson Tait published in 1881 a series of cases where, after making the abdominal incision, he aspirated the fluid, and then opened the cyst and stitched its edges to the external wound.

The operation which bears the name of Simons was described some years previous to Lindemann's. The author's aim was to avoid the dangerous effects of tapping, and to improve on the painful and tedious method of Recamier.

He first inserted a fine trocar and cannula, and, withdrawing the trocar to verify the diagnosis, inserted a second and larger instrument, about an inch from the first. Having allowed some of the contained

fluid to escape he plugged both cannulæ with carbolised wax, and applied an antiseptic dressing.

The patient was kept in bed, and the dressing and plugs moved from time to time, at intervals of a few days, to ascertain whether the cyst contents had begun to suppurate.

The presence of pus he regarded as a sufficient proof that inflammatory adhesion had resulted, and he completed his operation by making an incision down into the cyst between the cannulæ.

He practised his operation of radical cure only in cases where the tumours had attained a considerable size, or in cases where they had already suppurated.

In a case recorded by Boinet, where the patient was being treated by the introduction and retention of a large trocar and cannula, and where septic symptoms of a dangerous character developed, he passed a curved trocar through the track of the original wound, and made a counter opening, through which he transmitted a drainage tube, and allowed a few days for the formation of adhesions; he then incised between the two wounds.

Simons' operation may be regarded as a developmental stage in the surgical treatment of hydatid tumours which has become perfected in the method of Lindemann, which accords with the true spirit of scientific surgery of the present day, and which has proved its value by its results.

The objectionable features of Simons' method are that it is tedious and uncertain as a means of procuring adhesions (which is one of its chief objects), that

suppuration of the cyst contents usually results, and that in the method of performing the operation certain structures may be transfixed which should be avoided.

Davies Thomas gives the mortality from this treatment as high as 48 per cent.

The steps of the operation by the method of direct incision may be briefly stated as follows:—

When the cyst is situated in the abdomen, the most prominent part is selected, and an oblique incision, about two inches long, is carefully made down on to the surface of the peritoneum.

All bleeding points are picked up and ligatured, and then the peritoneum, to a corresponding extent is opened.

The assistant presses carefully on the abdominal wall so as to allow the exposed part of the cyst to come closely to the wound. Two large sponges are kept closely applied to the opening to readily absorb any fluid which may escape when the cyst is entered, and prevent its passing into the abdominal cavity. Then with a handled curved needle, armed with carbolised silk, four stitches are passed attaching the cyst to the edges of the abdominal incision. The cyst is then opened with the knife, and the finger immediately inserted. It is further secured by additional stitches, to ensure its complete and safe adaptation to the external wound. The contents are thoroughly evacuated, the daughter-cysts extricated when necessary by means of a pair of suitable forceps. Great care is taken to completely empty the cyst, as retained

pieces of membrane readily suppurate. This is best ensured by irrigating the cavity with some mild antiseptic lotion, such as boro-glyceride or boric lotion, until all the original contents are brought away with the return flow.

The parent cyst-wall will, in many cases, be found to collapse as soon as the fluid contents are removed, when it can be easily caught hold of by the forceps and extracted. If it still remain *in situ* gentle traction should be made with the view of separating it from the ectocyst, but anything like force must be carefully avoided, as the vessels in the connective tissue of the outer covering, in some cases, are numerous, and might easily bleed if forcible separation were attempted.

In the cases where I have noticed the cyst-wall retained it speedily broke down in amorphous *debris*, and passed with the fluid with which the cavity was irrigated. The operation is completed by inserting a large perforated rubber drainage tube, and the wound dressed with firm pads of suitable material such as tenax covered with iodoform, or serum-gauze. The dressing will have to be changed frequently for the first twenty-four hours, as the discharge is usually considerable.

The method of direct incision has also been performed in two stages, with the object of more safely providing against the passage of any of the cyst contents into the peritoneal cavity.

The first step consists in incising down to the peritoneum, or even through it, and plugging the wound with serum-gauze, until inflammatory adhesions are

formed. About a week afterwards the cyst is boldly opened with the knife, the subsequent treatment being the same as in Lindemann's operation.

This operation is usually known as Volkmann's, and was strongly advocated in England by Barwell.

I have occasionally seen, after an interval of eight days, no attempt at the formation of adhesions with such preliminary precautions, and even in some cases where adhesions had formed one could not with safety trust to them alone to withstand the strain of a heavy dragging cyst. This method possesses no special advantage over the other mode of operation, it necessitates the shock of two operations, it is not always to be depended on as a sure means of procuring adhesions, and it has the great drawback of requiring a certain amount of local peritonitis to ensure its success. The mortality from it is given by Thomas as 19 per cent.

In the case of cysts growing from the upper surface of the liver, as depicted in Plate VI., they usually show bulging of the lower portion of the thoracic wall on the affected side, and are best reached by removing portions of two or more ribs at the most dependent part, and securing the cyst by stout ligatures to the edge of the wound before the contents are evacuated. Every care should be taken to prevent any of the contents passing into the pleural cavity. When the cyst is emptied of its contents the diaphragm readily descends, pushing the flaccid walls of the empty cyst before it. As drainage is apt to be rendered imperfect, a counter opening requires to be made at a suitable

and selected spot. This is usually conveniently done by passing a large-sized Lister's sound into the original wound, and cutting down on it at the most dependent part.

The cyst cavity should be frequently syringed with some mild antiseptic lotion, tincture of iodine, five minims to a pint of tepid water, I have found very well suited for this purpose. In one case where I employed perchloride of mercury solution, 1 in 4000, the patient became salivated, and its use had to be discontinued.

In washing out the cavity care should be taken to avoid anything like forcible injection of the fluid, as the fibrous surface of the ectocyst readily tends to contract and adhere by plastic union.

Verco records a case in the *Australian Medical Gazette*, 1886, where a cyst had excavated the whole of the right lobe of the liver. The patient died five days after abdominal section, and it was found that over a considerable area in the cyst cavity its walls had come together by plastic adhesion.

The drainage tube should be kept in the wound until the discharge has practically ceased to flow. Its too early removal permits of the closing of the external wound too rapidly, and subsequent bagging of the sinus may necessitate its re-opening.

The surgeon may have to deal with the radical treatment of a hydatid tumour in the lung, even after it has shown signs of spontaneous rupture, and part of its contents have been expectorated.

While many such cases have a favourable termina-

tion there is the constant danger of suffocation from obstruction of the glottis by pieces of the cyst-wall, besides which the seat of the tumour may readily become converted into an abscess cavity, and the patient's life be endangered by suppurative exhaustion.

In the case of a girl, aged eighteen years, who was admitted to the hospital in a dying state, supposed to be in the last stage of phthisis, there was evidence of a large cavity in the right lung, and coarse crepitant râles were heard from base to apex. The left lung was healthy. In the history it appeared that the cyst had ruptured six months before, but, the patient living beyond the reach of skilled advice, her true condition had not been recognised. She died the day after I saw her. At the *post mortem* I found a large cavity in the centre of the right lung, with a piece of hydatid membrane corresponding to about a fourth of the size of the cyst. The substance of the lung was in a state of catarrhal pneumonia, and the walls of the cavity in a sloughy condition.

When a hydatid in the lung is sufficiently large to be diagnosed and mapped out, its immediate removal should be undertaken. An incision is made in the usual way and a portion of the rib removed. With care, a piece of one of the ribs can be resected before the pleural cavity is opened by guarding it with an elevator, which can be inserted perpendicularly between the inner layer of periosteum and the bone. After the bleeding points have been seized and the wound cleaned up, the pellucid surface of

the cyst can often be seen through the serous lining, altering its position slightly with the movements of respiration.

Two or more stitches of carbolised silk on a curved handled needle are passed into the exposed surface of the cyst. The ligatures are left some inches long, so that the surgeon can drag on them while he inserts a trocar and cannula and allows the contents of the cyst to flow out. If the hydatid is found to be furnished with a fibrous ectocyst, the fibrous capsule is fixed to the thoracic wall, the finger of the operator being placed as a director in the opening made by the cannula.

It will frequently be found that the hydatid membrane expels itself spontaneously, being devoid of any ectocyst, when there will be no need to secure the cavity to the chest wall. In such cases it is a good precaution to make a counter opening at the most dependent part to provide for efficient drainage.

The usual practice of subsequent irrigation should be carried out with great caution. The injection of fluids often occasions an attack of severe and distressing coughing. I have on two occasions seen patients pass into an alarming asphyxiated state during this part of the after treatment.

In those cases where a liver hydatid has burst through the diaphragm into the pleural cavity, the chest wall should be opened immediately, and the cavity drained. The original hydatid should, at the same time, be operated on, unless it can conveniently be reached from the thoracic incision.

TREATMENT BY ELECTRICITY.

THE treatment of hydatid tumours by means of electricity in its different forms has never become very popular. Several cures have been claimed for it, though it is difficult to support Fagge's and Durham's contentions that the treatment of hydatid tumours by means of electrolysis has the advantages of being—

- (1) Altogether free from danger.
- (2) Not liable to set up suppuration within the cyst.

They record a series of six cases in the Medico-Chirurgical Society's *Transactions* for 1871. The cases so treated were subsequently examined at periods varying from seven months to three years, and in all except one a complete cure was claimed.

The mode of procedure is given as follows:—Two electro-gilt needles were used, which were introduced into the cyst at a distance of 1 or 2 inches from each other. Care was taken to observe that they had entered the same cavity, and could be made to touch one another. They were then attached to wires connected with the negative pole of a galvanic battery of ten cells, while the positive pole was made to terminate on a moistened sponge, placed over the tumour at a little distance from the points of entry of the needles. The current was allowed to pass for ten minutes, after which the needles were withdrawn.

It was thought that the saline fluid of the hydatid decomposed, and that the parasite in consequence lost its vitality, but in several of the cases it was observed that symptoms similar to those which often follow the passage of cyst contents into the abdominal cavity resulted during the course of the treatment, so that it is probable that the disappearance of the tumour may have been due to the rupture of the parent cyst itself.

Apostoli also claimed success in a case treated by him.

Davies Thomas refers to five other cases which he has collected, in two of which the treatment seems to have failed, but successes were recorded for the other three.

Faradism and Galvanism have both been tried, but no special benefit has been known to follow their use.

TREATMENT BY MEDICATED INJECTIONS.

DR. DAVIES THOMAS gives statistics of eighteen cases in which various injections were employed with a view to causing the death of the parasite.

In nine iodine was used, which in some cases produced iodism. In one of these cases death resulted, and in none was any advantage obtained over simple tapping.

Carbolic acid was used in three cases, two of which proved fatal.

In two cases the injection of bile through a trocar was followed by fatal results.

Pavy, in one case, injected a mixture of half a drachm each of extract of male fern and liquor potassæ, added to 6 ozs. of water. The patient recovered.

In two cases Professor Bacelli, of Rome, replaced 10 centigrammes of fluid by a corresponding quantity of a 2 per 1000 solution of corrosive sublimate. In both cases the tumours gradually diminished until they almost entirely disappeared.

Dr. Whitcombe, in a paper read before the Medical Congress at Melbourne, claimed a successful result from the injection of permanganate of potash into a hydatid filled with daughter-cysts.

He attributed a solvent action to the permanganate from the readiness with which the contents of a hydatid

cyst flowed through a retained cannula after some Condry's fluid had been injected into it.

I think the same result could be obtained by the injection of any other bland fluid, although possibly the permanganate of potash was of some benefit in correcting the presence of decomposition.

Recamier's method, or the opening into hydatid cysts by caustics, has for its object the forming of adhesions between the cyst-wall and the parietes. The agents used are caustic, potash, and zinc chloride. I have also seen the thermo-cautery employed.

The cauterisation is applied at intervals until the sac is reached, the cyst itself may be opened by it. The method is a tedious and painful one. Bouchet (*Gazette Méd. de Paris*, 1865) reported a case where the time from the first application of the cautery to the opening of the cyst was twenty-one days.

Attempts have been made to shorten the process by incising to a certain depth, then using the caustic or applying the cautery, and then emptying the cyst by aspiration or the use of the trocar and cannula.

This method of treatment has no special advantage to commend it; on the contrary, besides the extreme pain which it generally produces, it often fails to procure adhesions.

It is only applicable for liver cysts, and the mortality which has attended its use is, according to Thomas, about 34 per cent.

The method of introduction and retention of a large-sized trocar and cannula—canule à demeure—aims at procuring adhesions, and establishing a free

opening to enable the contents of the cyst to be evacuated.

In some cases, after the cannula has remained in for a few days, a drainage tube is passed through and the cannula withdrawn. The process of cure by this method is usually a slow one, and has the great drawback of not affording sufficient drainage to a cyst the contents of which readily decompose, and which are not easily made to flow through a narrow channel.

There is always uncertainty about the structures which the trocar and cannula are made to transfix. The cyst in some cases, when partially emptied, is in danger of collapsing and falling away from the cannula, permitting the contents to find their way into the abdominal cavity.

While it seems to have given better results than Recamier's method (mortality, 27 per cent., Thomas) it is much less satisfactory and more fatal than the method of free incision.

The following notes of some cases of hydatid disease show the results of different methods of treatment.

(1.) W. C. N., female, aged 11 years. Hydatid of the liver.

The patient, on admission into hospital, looked hectic and emaciated; temperature, 101° F. She complained of uneasiness in her breathing, and pain over the region of the liver.

There was a prominent bulging of the lower portion of the thoracic wall on the right side. Dulness extended from the third rib to 1½ inches below the

umbilicus. A distinct fluctuating feeling could be discerned through the abdominal parietes, over the region of the swelling, some yellowish fluid, showing pus cells and hooklets under the microscope, was drawn off with a fine exploratory needle.

An incision was made 3 inches long, in an oblique direction, down on to the serous covering of the cyst, at a part where the tension appeared to be greatest, and the cyst-wall secured to the abdominal parietes by means of stout silk ligatures. The hydatid was then opened and six pints of fluid removed. The parent cyst-wall was only partially removed, as it seemed somewhat adherent to the ectocyst; the cavity was freely irrigated with a weak carbolised solution, and a large-sized drainage tube inserted.

On examining the patient's chest a week afterwards, it was found that there were signs of fluid in the right pleural cavity, extending up to the second rib. The patient had not exhibited meanwhile any symptoms of an inflammatory attack in the chest. The exploratory needle drew off some fluid of the same appearance as that obtained from the cyst when it was incised. An incision was made over the tenth rib posteriorly, and a piece of it resected, and about four pints of fluid removed. It is probable that the fluid found its way into the pleural cavity at the time of the original operation through some portion of the diaphragm.

The patient made a good recovery, and was discharged as cured after four months' convalescence.

On one occasion, while irrigating the chest cavity with weak iodine fluid, the patient was suddenly seized

with a fit of coughing, then fell back in bed in an unconscious state. This condition lasted ten minutes, and during that time there was squinting and rigidity of the limbs. I have had a similar experience in irrigating the chest cavity in a case of empyema.

D. D., male, aged 17 years. Hydatid of the liver.

The hydatid cyst in the liver of this patient had been aspirated six months previously, and he had been discharged from the hospital as "cured." On that occasion, after the tapping, he had a rigor, severe abdominal pain, distressing vomiting, and a temperature of 104° , which persisted for several days. On readmission it was noticed that the dulness and bulging had attained to their original extent.

An oblique incision was made one inch below the costal margin, and the tumour could be seen and felt to be freely moveable. The incision was carried down on to the peritoneum, and the wound packed with antiseptic gauze. Eight days afterwards the cyst was incised. About three pints of whey-like fluid, with numerous daughter-cysts, were removed. Some of the daughter-cysts had collapsed, and their walls were undergoing degenerative softening. The parent-cyst had separated from the ectocyst, and was removed in pieces. The cyst was further secured to the abdominal wall by means of silk sutures, as it seemed heavy and dragging. The cavity was irrigated with a weak iodine solution. The patient made a good recovery, and returned to his home six weeks after the operation.

J. H., male, aged 43 years. Hydatid of the abdomen.

The patient complained chiefly of getting very easily out of breath, weakness, and loss of appetite. He had been able to carry on his work as a "bush carpenter" up to a few days before admission into hospital.

The abdomen looked prominent, and felt very tense. It was dull over its whole extent, except in the left flank. The liver dulness beginning at the level of the fourth rib, became indistinguishable with the general dulness of the abdomen. The greatest part of the girth measured 37 inches. The veins on the right side of the abdominal wall were dilated and tortuous. The feet and legs were not swollen, and there was no evidence of free fluid in the abdominal cavity. There was a distinct thrill felt on percussion. A fine exploratory needle drew off clear hydatid fluid. An abdominal incision was made in the linea alba, the peritoneum was indistinguishable from the tissues of the ectocyst. Thirty pints of fluid, containing numerous daughter-cysts, were removed. The daughter-cysts all seemed healthy. There was no trace of the parent cyst-wall. A large-sized drainage tube was inserted, and the cavity gently irrigated several times daily. The patient was able to return to his home, a distance of three hundred miles, eight weeks after the operation.

A. D., female, aged 29. Hydatid of liver.

The patient had noticed a swelling in the region of the liver for twelve months.

It had caused some pain and uneasiness, but had not prevented her from carrying on her household work.

On inspection there was noticed a distinct bulging on the right side, extending from the nipple to the costal margin.

The lower edge of the liver was easily felt and was not in any way displaced. The bulging was also marked in the lateral portion of the chest wall, and the dulness was absolute from the level of the fifth rib. Posteriorly the breath sounds could be heard at the base of the lung, but they were loud and harsh. In the upper part of the chest the breath sounds were of the same loud harsh character, as if the lung itself was compressed.

The exploratory needle drew off some clear hydatid fluid. An incision was made in the axillary line, over the ninth rib, and a portion of the bone removed; the cyst was stitched to the edges of the incision before any of its contents were allowed to escape. There were numerous daughter-cysts removed.

Two days after the operation the patient developed an attack of acute pleurisy, to which she succumbed.

The hydatid in this case had developed in the upper surface of the liver, and its growth was mainly in an upward direction. The left lobe was hypertrophied to compensate for the destruction of the right lobe.

Some of the cyst contents had found their way into the pleural cavity, and set up the attack of pleurisy which unfortunately proved fatal.

P. W., male, aged nine years. Hydatid of lung.

The mother of the patient stated that the boy seemed quite well up to eight weeks before admission. She first noticed that there was something unusual in

his breathing after the boy had sustained a fall, from which time his breathing became short and rapid. He also complained of pain over the region of the right scapula at its inferior angle.

On admission, the temperature was normal, the respiration 32, and the pulse 114 per minute.

There was an entire absence of movement on the right side of the chest; there was distinct bulging on the anterior and lateral aspects. The physical signs were those of the condition of hydro-pneumothorax. The splashing sound was well marked.

Having first of all drawn off some of the fluid with an exploratory syringe, and detected the presence of hydatid, I resected a portion of the ninth rib posteriorly, and opened into the pleural cavity. Fully a pint of greyish fluid was removed. On inserting my finger into the opening, I felt the hydatid membrane lying curled up in itself. This was easily withdrawn with a pair of cyst forceps.

The patient left for his home twenty-one days afterwards, having made a good recovery.

J. G., male, aged 26. Hydatid of liver.

The hydatid cyst had been aspirated five months previous to admission into hospital, and $2\frac{1}{2}$ pints of clear fluid had been withdrawn.

The cyst showed itself as a bulging, most prominent over the right hypochondriac region. There was some slight pain and tenderness over the swelling, but his general constitutional condition was good.

I drew off with the aspirator $1\frac{1}{2}$ pints of bile-stained fluid, containing numerous pus cells. Nine days after

this tapping the swelling seemed to be as large as ever. I again aspirated and drew off 1 pint of fluid very similar in its appearance to the last. Two weeks later the cyst had again refilled, and being anxious to test the limits of the aspirator in the treatment of this affection, I again drew off 3 pints of fluid, about one-eighth of which was pus. I subsequently tapped the cyst three times, at intervals of ten days. After the last tapping the patient remained under observation for four weeks, and during that time there were no signs of the cyst refilling. He returned to his home in the country, feeling, as he said, all right, and has not since reported himself, though a period of three years has passed.

K. G., female, aged 32 years. Hydatid of liver.

The cyst had been tapped twelve months before admission, and the tapping had been repeated four times since, at the patient's home.

There was bulging of the lower portion of the thoracic wall on the right side, and the dulness extended from the fourth rib down to the umbilicus. She complained chiefly of dyspnoea, and a feeling of weight in the right side. Her temperature on admission was normal, pulse and respiration somewhat rapid; she looked slightly emaciated and jaundiced.

An incision was made on the axillary line, over the ninth rib, and 2 inches of bone resected; the cyst was stitched to the walls of the incision, and then freely opened. The contents were purulent fluid and numerous daughter-cysts. Two days after the patient

developed an attack of pneumonia in the right lung, which proved fatal.

A. C., female, aged 32. Hydatid of liver.

The cyst appeared as a large globular swelling in the abdomen, which the patient had noticed for five years.

It had not occasioned her any pain beyond a feeling of dragging weight, and she had never had any medical advice about her condition until she came to the hospital. The dulness extended from the third interspace downwards to the level of the crest of the ilium. Its lower pear-shaped extremity could easily be felt passing into the pelvis.

There was some free fluid in the peritoneal cavity. There was a slight trace of albumen in the urine.

Clear hydatid fluid was got with the exploratory needle. The aspirator was then applied, and when two and a half pints of fluid were withdrawn, the patient became faint and collapsed, and further treatment was immediately deferred.

A well-marked urticaria rash appeared on the abdomen, chest, and arms a few hours after the cannula was withdrawn. The rash persisted for three days.

There was abdominal pain, vomiting, and rise of temperature at the same time as the rash appeared. The temperature varied between 103.6° and 101° for fourteen days subsequently.

When the temperature had again become normal, another attempt was made to empty the cyst by aspiration, and twelve and a half pints of fluid were removed.

No troublesome symptoms followed the second operation.

Three weeks later the cyst had refilled though not quite to its original bulk, and ten and a half pints of fluid were withdrawn. Its colour was a light green. Under the microscope were hooklets, pus cells, amorphous *debris*, and crystals of hæmaloidin. The usual tests gave the reaction of bile.

She was tapped again twice within the following two months, and nineteen and a half pints of fluid removed. Forty-five pints of fluid in all had been removed from the cyst cavity.

She remained under observation during the following three months, and at the end of that time the cyst cavity had shrunk to the size of a foetal head, and her general condition had very much improved.

She was discharged as "cured."

Four months afterwards she again returned, complaining of pain over the abdomen.

The cyst had refilled, though its walls were flaccid. She looked thin and haggard, and her temperature was 101° F.

Two and a half pints of fluid, about one-fourth of which was pus, were removed with the aspirator. A few days later, as she seemed to be losing ground, the cyst was incised and drained. The contents then were found to be greenish yellow fluid, containing pus and pieces of hydatid membrane. She gradually got into a weak hectic condition, and died seven weeks later.

The *post-mortem* examination showed the cyst was

growing from the under surface of the liver, the large ectocyst was of great thickness, and parts of its surface had become adherent, thus converting the original cyst cavity into loculi.

M. J. T., female, aged 27. Hydatid of the liver.

The cyst had been aspirated on three different occasions at the patient's home, the first time three years ago, the second fully one year ago, and the third time six months before admission into hospital.

The tumour seemed to her to be about the same size as when she first noticed it. It had not occasioned her any serious inconvenience, except that latterly she had been getting weak and losing her appetite.

The cyst was opened, and the cavity drained. Two pints of purulent fluid, with a few daughter-cysts, were removed. The parent cyst-wall was found lying coiled up among the fluid contents. The patient made a good and rapid recovery.

M. F., female, aged 36. Hydatid of the liver.

The hydatid had been tapped five years previously, and had slowly refilled. She had felt in good health up to a few months before coming into hospital. Her symptoms on admission were, feverishness, loss of appetite, and weakness. The temperature was 100·4°. There was no local pain. There was bulging over the surface of the liver on the right side. The cyst was treated by incision and drainage with a good result. The contents removed were bile-stained fluid, one-eighth of which was pus. No daughter-cysts were present in the cavity. The hydatid membrane had

partially disappeared, the portion that remained was suppurating and friable.

S. S., female, aged 58 years. Hydatid of liver.

On admission the hydatid was aspirated, and three pints of clear fluid removed.

The patient soon after complained of great pain and tenderness, and was very sick. The temperature the same evening was 102° F. These symptoms persisted for several days after the tapping.

At the end of five weeks the cyst had quite refilled, apparently to its original size. It was again aspirated, the fluid on this occasion being of an opaque grey character. Two weeks later the cyst had again refilled, the fluid removed being bile-stained, and containing pus cells.

The patient, a few days after the last tapping, showed symptoms of septic absorption, when the cyst was incised and drained. There were no daughter-cysts, the parent cyst-wall was soft and friable, and was removed in pieces by gentle traction with a pair of forceps.

The patient had a tedious convalescence, but eventually got quite well.

A. S., male, aged 38. Hydatid of liver and lung.

The patient had felt a dull aching pain behind the free ribs on the right side for fully eighteen months. In the right hypochondrium a rounded cystic swelling could be easily felt, which was moveable with respiration. Examination of the chest showed that, posteriorly from the spine of the scapula to the base of the right lung, the dulness was absolute and the breath sounds inaudible.

The liver swelling was aspirated, and 24 ounces of fluid were removed. This made no change on the extent of the dulness in the chest. After the patient had quite recovered from the shock of the tapping of the liver cyst, a fine aspirating needle was inserted into the base of the right lung.

While some hydatid fluid was flowing into the bottle receiver, the patient developed an alarming and distressing cough, which necessitated the immediate withdrawal of the needle. The coughing was shortly accompanied with profuse expectoration, containing hydatid fluid and membrane. It was calculated that two pints of fluid must have been expectorated.

The following day there were coarse friction rubs heard all over the posterior part of the lung. The temperature was 103.4° , and there was much constitutional disturbance. The expectoration was profuse for the three following weeks, and then it gradually became small in quantity, and the constitutional symptoms abated.

The liver-cyst refilled, and was again treated by aspiration. The patient remained ten weeks under observation. At the end of that time the dulness in the chest was still marked, but no more fluid could be obtained by the exploratory needle, the breath sounds had become much more audible.

The liver-cyst had not again refilled, and his condition generally had greatly improved.

W. A., male, aged 36. Hydatid of liver.

The patient had experienced pain for more than a

year over the region of the liver, and in the right shoulder blade.

The liver dulness extended from the level of the fourth rib, downwards for eight inches. The spleen was also distinctly enlarged, being uniformly hard, and its notches easily felt. The liver bulged markedly over the costal margin, and it felt tense and cystic.

After an exploratory puncture in the liver-cyst, the patient became faint and sick.

The same evening he had a typical attack of ague. He had lived in India for some years, where he had contracted malarial fever. After the symptoms of fever had subsided, the liver-cyst was treated by aspiration, and three pints of clear hydatid fluid removed. Exploratory puncture of the spleen gave negative results, so that the enlargement of that organ was probably due to the hypertrophy common to the ague constitution.

The patient was only three weeks under observation, and the cyst had not refilled during that time.

M. I. K., female, aged 27 years. Hydatid of liver.

The cyst had been aspirated nine months previously, and two and a half pints of clear hydatid fluid removed. On re-admission, the swelling seemed to have attained the same size as formerly, but had meantime given rise to no constitutional disturbance. Two pints of fluid were withdrawn with the aspirator. It contained bile, and a few pus cells. The patient returned to her home fifteen days afterwards, and has not again reported herself.

W. B., male, aged 32. Hydatid of liver.

The patient sought advice for bleeding hæmorrhoids and troublesome constipation. He also complained of a dull, aching pain over his liver. There was no bulging and no increase of hepatic dulness. The hæmorrhoids were removed by surgical means. Three weeks afterwards, the liver pain still persisting, I again carefully examined the hepatic area.

This time I thought I got a feeling of fluctuation on the upper surface of the right lobe. On inserting an exploratory needle some clear fluid was obtained, and in using the aspirator about ten ounces more were removed. Four days afterwards the same deep seated fluctuation was obtained. There was great pain and tenderness over the cyst area. Half a pint of yellowish fluid was again drawn off, which, on boiling, became solid from the contained albumen.

I have seen this patient frequently during the three years subsequent to his last operation. He seems in perfect health, and I can detect no return of the swelling.

B. S., female, aged 40. Hydatid of lung.

The symptoms complained of were cough and occasional slight attacks of hæmoptysis. She had also some dyspnœa, and pain on taking a deep breath. The physical signs pointed to a hydatid at the base of the right lung. Thirty ounces of hydatid fluid were drawn off with the aspirator. She felt greatly relieved after the operation. Ten days later her breathlessness had returned, accompanied with considerable pain. Examination showed that there was fluid up to the level of the nipple line. Two pints of serous fluid were drawn off with the aspirator.

She remained under observation for five weeks, and was allowed to return home at her own request. There was still some fluid in the pleural cavity, but her general condition had improved.

D. S., male, aged 32. Hydatid of liver.

The patient sought advice for an attack of jaundice, which first appeared seven weeks previously. He felt nauseated and feverish, but had no special local pain.

There was bulging over the region of the liver. It had not attracted his attention until it was pointed out to him. The exploratory needle drew off some bile-stained fluid containing pus. An incision was made three inches long below the costal margin, at the outer border of the rectus margin, and the cyst stitched to the edges of the external opening. On incising the hydatid, it was found to contain a quantity of purulent fluid, with cyst membrane, deeply bile-stained. The cyst cavity was irrigated with a solution of perchloride of mercury, 1 in 2000.

The patient showed signs of salivation three days after using this fluid, so that a weak iodine solution was used instead. At the end of ten weeks the patient was able to return home, having completely recovered from his jaundice, and feeling well and strong.

G. S., male, aged 50. Hydatid of the liver.

The patient had noticed a swelling in his abdomen for over two years, but attributed it to the effects of a fall, which he had sustained about that time. Six weeks before admission he began to have attacks of

vomiting. His food returned shortly after swallowing it. A few days before coming into hospital, he had become deeply jaundiced. The abdomen felt tense, and there was some tenderness on pressure. Dulness extended from the fifth rib in the nipple line, the seventh rib in the axillary line, and the ninth in the scapular line, downwards to two inches below the umbilicus. An exploratory needle drew off some drops of gelatinous fluid.

Twelve hare-lip pins were inserted in a circular manner at the most prominent part of the swelling; they were allowed to remain in for eight and a half hours. After they were removed there was some febrile disturbance, and the abdomen seemed more distended and tender. An incision was made through the area twenty-four hours after it had been needled. The cyst was found firmly adherent to the parietes, but was further secured by stout silk ligatures. A large quantity of hydatid *debris*, with numerous daughter-cysts, was removed. The patient was able to return to his usual work ten weeks after the operation.

E. H., female, aged 47 years. Hydatid of liver.

The chief symptoms that were complained of were, swelling of both feet and legs, and a feeling of weight and oppression about the epigastrium. A marked swelling was noticed below the xiphoid cartilage. On percussing it there was a distinct thrill felt. The exploratory needle confirmed the same diagnosis of hydatid, and the aspirator drew off four pints of clear fluid. Six weeks later the original cyst could be felt as a hard globular mass about the size of a fist. The

patient returned to her home two months later, feeling quite well.

F. O. D., female, aged 17 years. Hydatid of liver.

The patient sought advice for a small rounded swelling on the upper surface of the right lobe of the liver. It had given rise to no pain, but its presence made her feel somewhat uncomfortable. An exploratory needle drew off some clear hydatid fluid. Ten and a half ounces were subsequently drawn off by the aspirator. Three hours after aspiration, a well marked attack of urticaria appeared. The rash was distributed over the abdomen, and both arms and legs. It was accompanied with rise of temperature and tenderness over the region tapped, and two days afterwards it quite disappeared, leaving the skin very itching.

The patient returned to her home eight days after the operation, the cyst then showed no signs of refilling.

M. M., female, aged 19. Hydatid of abdomen.

The patient on admission was in an emaciated and enfeebled state. She complained of loss of appetite, dyspnœa, and abdominal pain. Temperature 99° F. The lungs were apparently healthy; the heart's action feeble, but organically sound. Urine normal.

The abdomen was very tense and much distended. Around its greatest girth it measured thirty-four and a half inches. The percussion note was dull throughout its whole extent; the dulness was not in any way altered by the change of position. The enlargement of the abdomen seemed uniform.

Examination *per vaginam* showed that the uterus as a whole was pushed down, and a doughy cystic swelling could be felt through the fornices. A well marked tremor could be made out. A fine exploratory needle drew off clear hydatid fluid. Some hours after the exploratory puncture was made, the patient was seized with great abdominal pain, accompanied by an attack of vomiting. The vomited matter had a fæcal odour, so that an operation was resorted to without delay.

An incision was made through the linea alba. The glistening surface of the peritoneum could not be distinguished from the other structures. On opening the abdomen a very large number of daughter-bladders were removed; there was no trace whatever of the parent hydatid wall. On passing the hand into the cavity, nothing could be felt but the walls of a very large cyst. None of the viscera could be directly touched. It seemed remarkable how the stomach and intestines could have carried on their functions when subjected to such great pressure. It was difficult to say where the hydatid had taken its origin from. The liver dulness began from the upper border of the fourth rib, and at its lower edge a distinct sulcus could be felt between it and the upper limits of the cyst. As the lower limits of the cyst lay in direct contact with the pouch of Douglas, a counter opening was made into the vagina, and free drainage established. The patient made a good recovery. Three and a half years after the operation, she wrote me to say that her health was very good, and that there was no discharge from the sinus.

E. R., female, aged 13 years. Hydatid of liver.

The cyst was first aspirated in hospital, and three pints of clear fluid removed. The patient had been discharged as "cured." At the end of four weeks she again returned, feeling sick, and looking flushed and ill.

The cyst had refilled, though not quite to its original extent. The tumour was then incised and drained, the contents being bile-stained, about one-third of which was pus, granular *debris*, and parent cyst-wall.

Every effort was made to keep the purulent cavity sweet and well drained, but the patient gradually lost ground and died from exhaustion five weeks after the operation.

R. B., male, aged 10 years. Hydatid of liver.

The hydatid was first treated by aspiration, and one and a half pints of clear fluid removed. The temperature the same evening was 101° F., and it persisted irregularly high for two weeks. The cyst at the end of that time had refilled, and the patient showing signs of septic absorption, the tumour was incised and drained. The contents removed at the operation were bile-stained fluid with pus, and the hydatid cyst-wall. The patient made a good recovery.

E. E., female, aged 20 years. Hydatid of liver.

The hydatid cyst had been aspirated three years previously. There had always been a certain amount of bulging since the operation, but it only increased rapidly during the last month or two. The patient was getting thin and weak. On her admission into hospital the cyst was aspirated again, and three and a

half pints of bile-stained fluid removed containing numerous pus cells. A few hours after the operation of tapping, the patient had a rigor, and the temperature rose to 103° . Ten days afterwards the cyst had refilled. It was opened by Recamier's method. She had a long convalescence, and returned to her home three months afterwards.

I. M'G., female, aged 11 years. Hydatid of liver.

The cyst had been aspirated one month previously, and the patient discharged from hospital as "cured." Two pints of clear hydatid fluid were then removed. On her re-admission, the tumour had attained its original size, and the patient complained of pain over the region of the liver; she was hectic and flushed, with a rapid pulse, and high temperature. The tumour was incised without delay, and the cavity freely irrigated and drained. About two and a half pints of foetid contents were removed. There were no daughter-bladders, and the parent cyst-wall had separated from the ectocyst, and was easily removed. The patient made a good recovery.

W. I., male, aged 49 years. Hydatid of the abdomen.

The tumour presented itself as a large globular swelling in the lower portion of the abdomen. The patient complained chiefly of the discomfort and deformity which the swelling produced. There was no pain or pressure symptoms. Four pints and fifteen ounces of clear hydatid fluid were drawn off by the aspirator. Ten days later the cyst had refilled, and symptoms of septic absorption developing, the tumour was incised, and the contents removed.

Six weeks after the patient died from exhaustion. The *post-mortem* examination showed that the cyst had developed in the great omentum, and that at different parts the walls had become adherent, preventing the cavity from being efficiently drained.

A. C., female, aged 15 years. Hydatid of liver.

The cyst was aspirated three times in four and a half months. After the first two tapplings the temperature varied between 103° and 101° for several days. After the last operation the temperature remained persistently high for twenty days. The patient remained under observation for five weeks, and then was discharged as "cured."

E. E., female, aged 20 years. Hydatid of the liver.

The cyst had been aspirated three years previously. From that time, till three months before admission into hospital, the swelling had only slightly returned. The patient began to suffer from some gastric disturbance, as pain after food, and vomiting. From the onset of these symptoms the cyst began to refill rapidly, and was perfectly tense when she applied for advice.

An opening was made down on the cyst by Recamier's method, and a few days later the hydatid was opened. The contents were purulent fluid, with a number of daughter-cysts. The edges of the wound remained raw and painful for a considerable time. Thirteen weeks afterwards she was able to return to her home, her general condition having much improved.

C. A., male, aged 35. Hydatid of liver.

The hydatid was treated by aspiration on admission,

and three pints of bile-stained fluid removed. Within a week the cyst refilled and was again aspirated.

Refilling again two weeks later, it was incised and drained. The contents were bile-stained fluid with one-half pus and hydatid membrane. The patient gradually sank into a low, weak condition, and died six weeks after the operation.

M. M., female, aged 19 years. Hydatid of lung.

The patient stated that she had suffered from a cough from childhood. She had spat up mouthfulls of blood at intervals during the last two years, and ten weeks before admission into hospital, during a fit of coughing, she had expectorated a large quantity of fluid, mixed with blood and pieces of membrane.

On examining the chest there was evidence of a large vomica in the right lung, coarse crepitations were heard throughout its whole extent. The expectoration contained pus and hydatid *debris*. The patient was in a very exhausted and feeble condition, and died four days after admission.

The *post-mortem* examination showed that a large hydatid cyst had developed in the centre of the right lung. It extended throughout its whole length, being completely encircled with a condensed layer of lung substance. The inner surface of the cavity was in a sloughy condition, and contained about a fourth part of the original hydatid membrane.

A. T., female, aged 25. Hydatid of lung.

The patient had been under treatment for three months previously for pleurisy, but her pain not subsiding, she sought advice in the out-door department

of the hospital. There was some bulging in the axillary line of the right side, extending from the fifth rib to the tenth. The breath sounds over that area were absent, but exaggerated in the upper portion. A fine exploratory needle drew off some clear hydatid fluid, and the aspirator drew off two pints additional. For a week after there was a good deal of pain and fever. Two weeks later, as there appeared to be some re-accumulation of fluid, the aspirator was again inserted, but with no result.

I saw her again four months afterwards at her own home. She was very pale and thin, with a high temperature. There was still dulness in her right lung. I opened the chest and removed a quantity of foetid fluid and the complete cyst-wall. She made a good recovery.


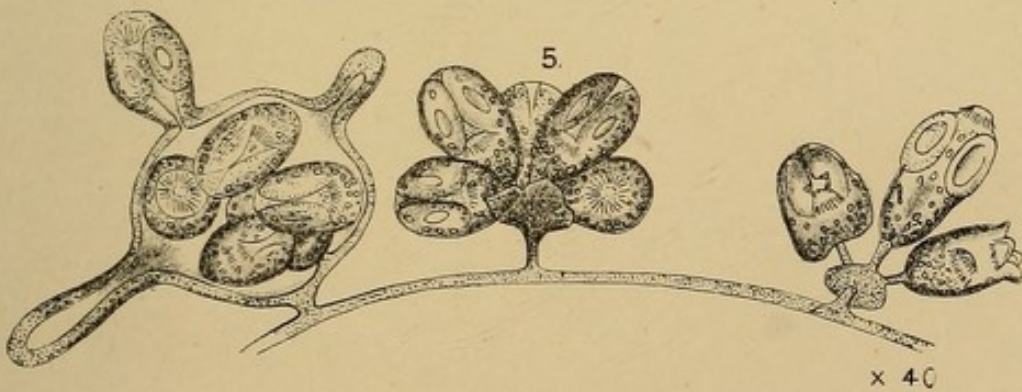
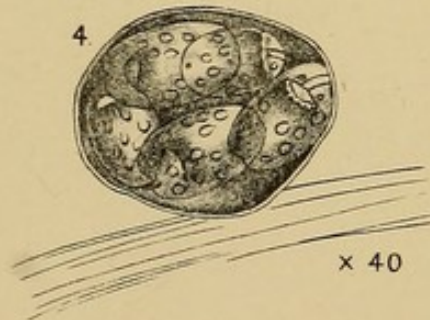
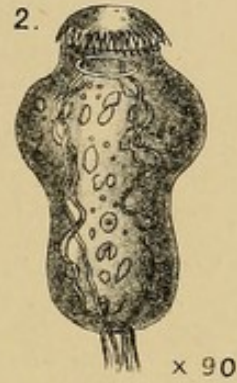
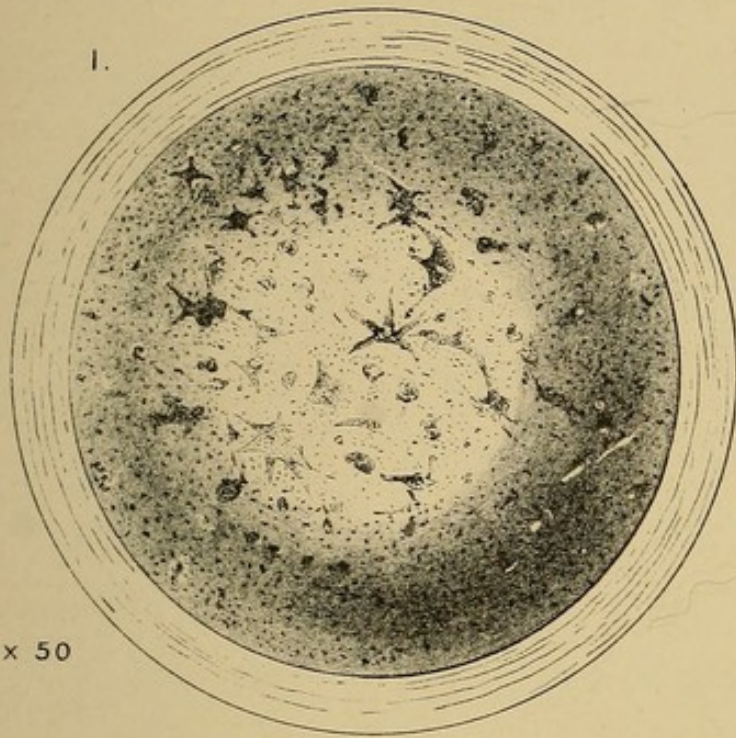


PLATE I.—Hydatid cyst eight weeks old, showing also scolex and brood-capsules. Fig. 1. Echinococcus bladder eight weeks old ($\times 50$). Fig. 2. Scolex of echinococcus ($\times 90$). Fig. 3. Scolex with the anterior part of the head invaginated ($\times 90$). Fig. 4. Brood-capsule with scolices of echinococcus in the interior ($\times 90$). Fig. 5. closed and ruptured brood-capsules showing their connection with the parenchymal layer. *After Leuckart.*

PLATE I



The End



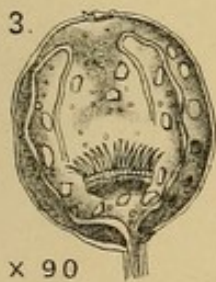
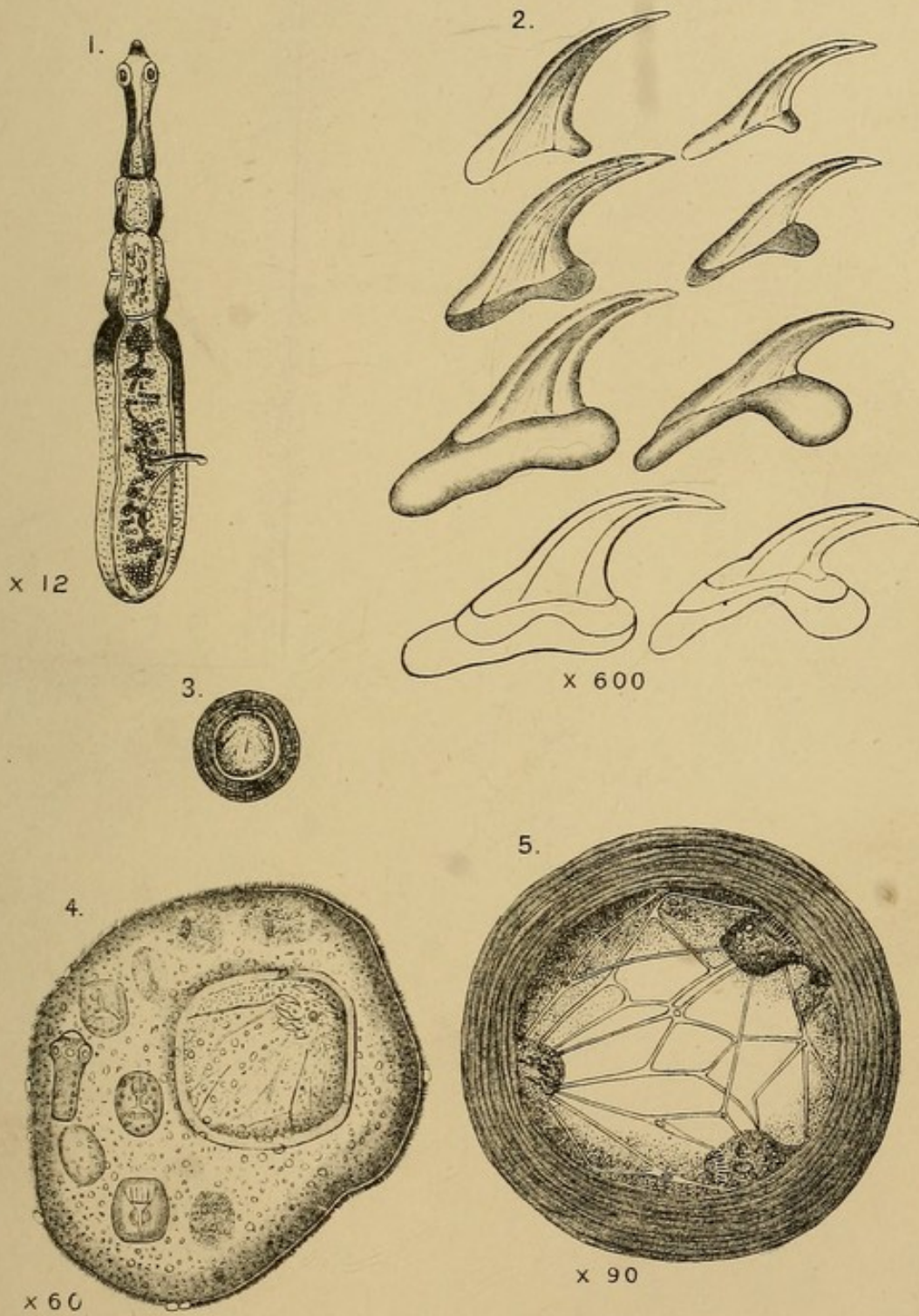


PLATE II.—The *Tænia Echinococcus*, showing also the appearance of hooks and ovum with scolex and brood-capsule becoming transformed into daughter-cysts. Fig. 1. The mature *Tænia Echinococcus*. Fig. 2. Echinococcus hooks ($\times 600$) (*a*) of *E. veterinorum*; (*b*) of *Tænia Echinococcus* in the third week; (*c*) of Adult *Tænia Echinococcus*; (*d*) the three different hook forms drawn one within the other to show their gradual change. Fig. 3. Eggs of the tapeworm with six-hooked embryo. Fig. 4. Metamorphosis of an echinococcus head into a bladder in the interior of the brood-capsule ($\times 60$). Fig. 5. Metamorphosis of the brood-capsules into bladders ($\times 90$). *After Leuckart.*

PLATE II

PLATE II






PLATE III.—Hydatid tumour, with numerous daughter-cysts growing from the gastro-hepatic omentum. The two cysts on the upper surface were growing independently of each other and of the parent hydatid, though they were attached by the same fibrous ectocyst.

PLATE III

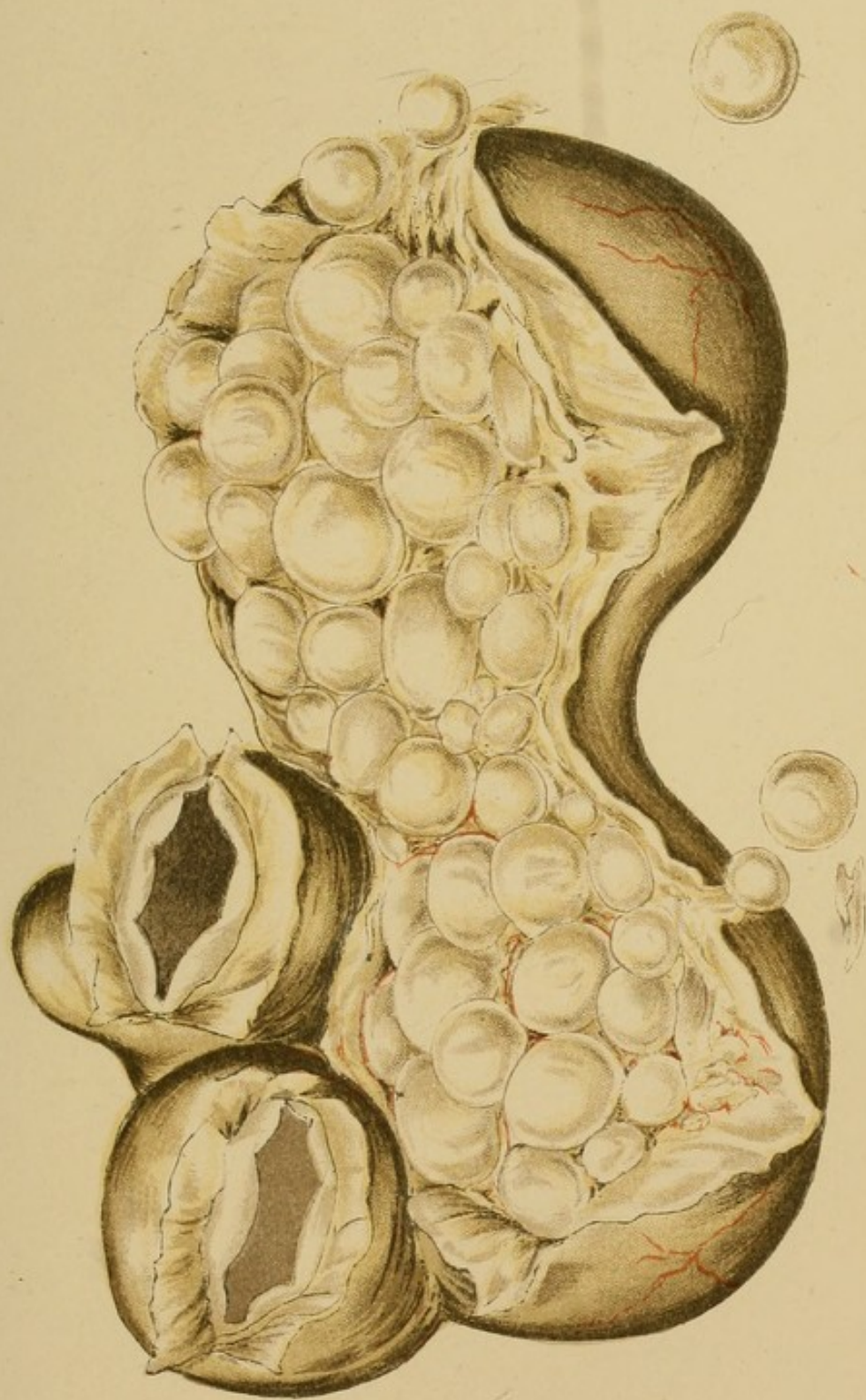


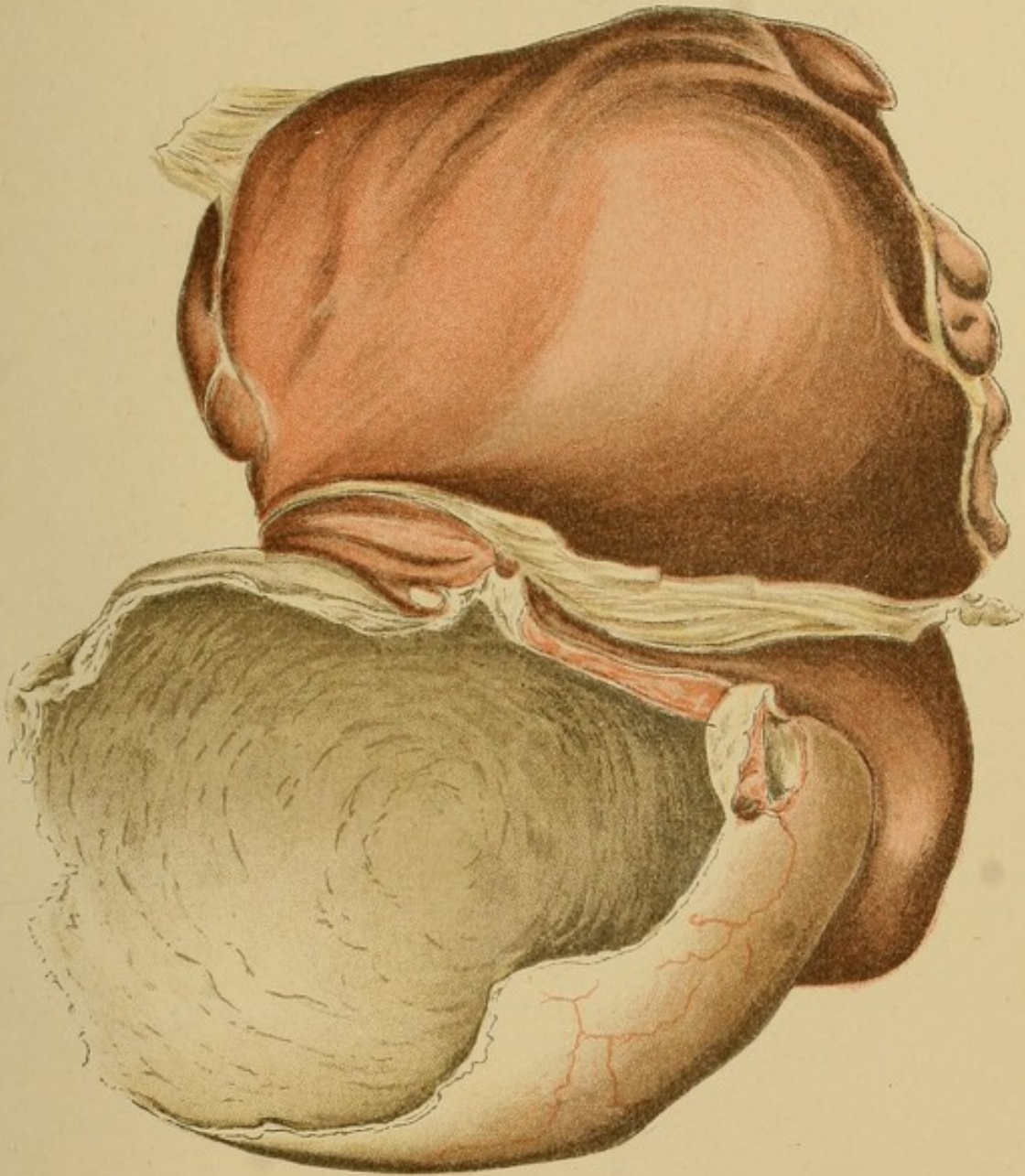


PLATE IV.—Hydatid of the liver destroying almost the whole of the right lobe.
The left lobe has hypertrophied to more than double its normal size.




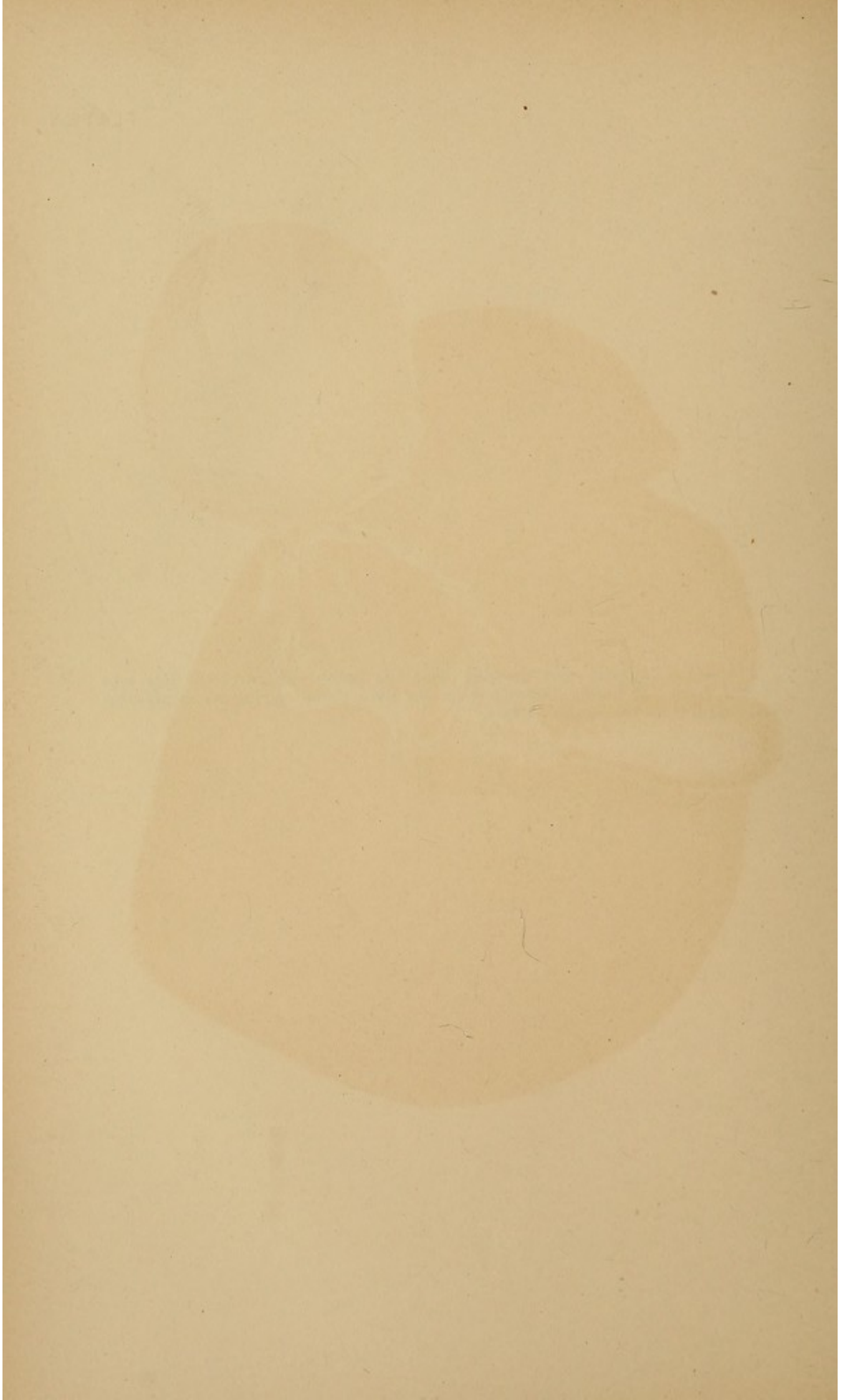
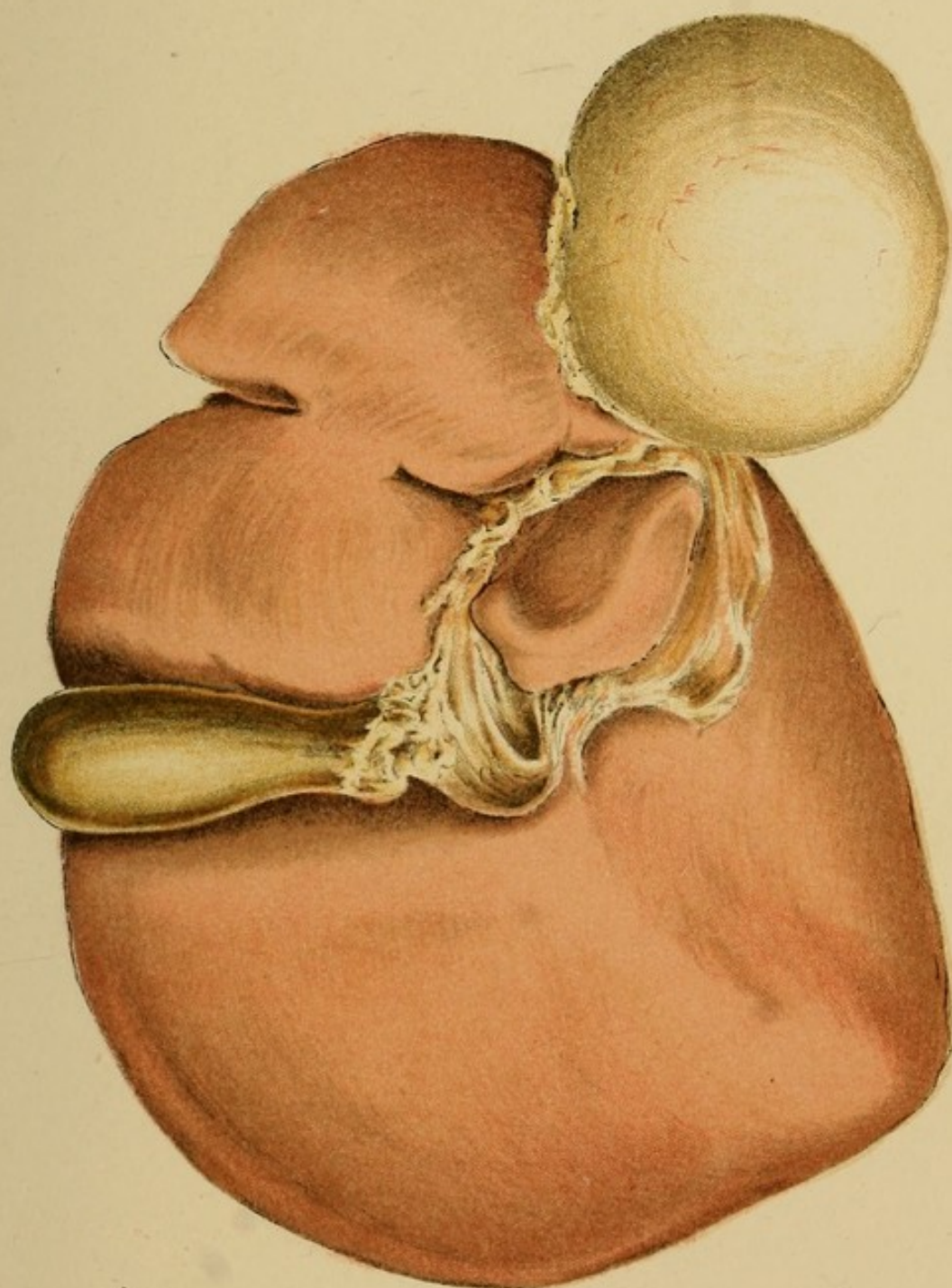


PLATE V.—Hydatid cyst growing from the under surface of the left lobe of the liver. It hardly encroached on the liver tissue, having its attachment and origin from the serous surface.








PLATE VI.—Hydatid tumour growing from the upper surface of the liver, which caused marked bulging of the lower part of the chest-wall on the right side. The interior of the cyst was sloughy and purulent.

STATE M.

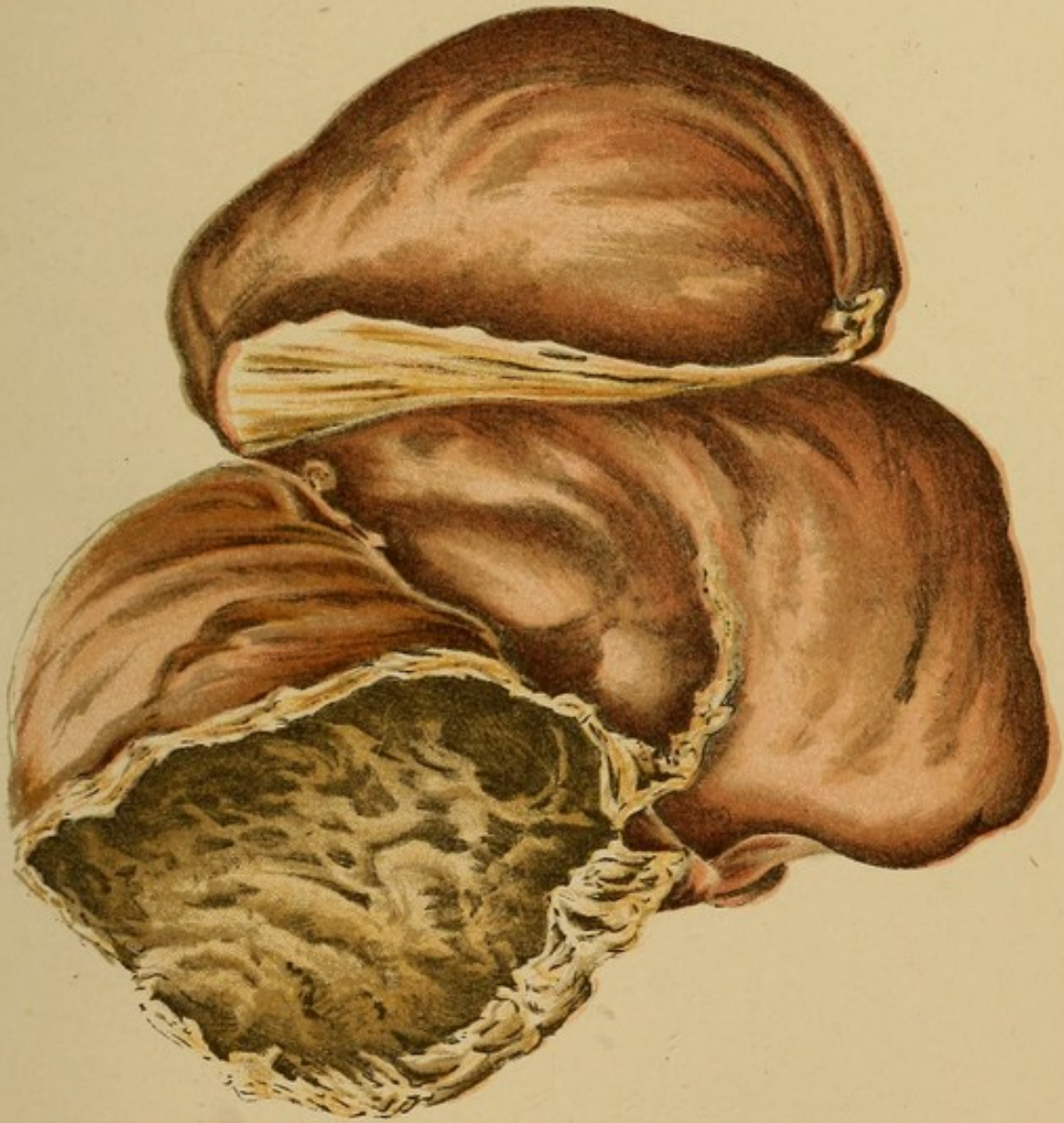





PLATE VII.—Hydatid tumour growing from the upper surface of the right lobe of the liver showing compensating hypertrophy of the right lobe. The cyst burst through the diaphragm into the pleural cavity and set up an attack of fatal pleurisy. The lung is seen *in situ* adherent to the upper surface of the cyst-wall.



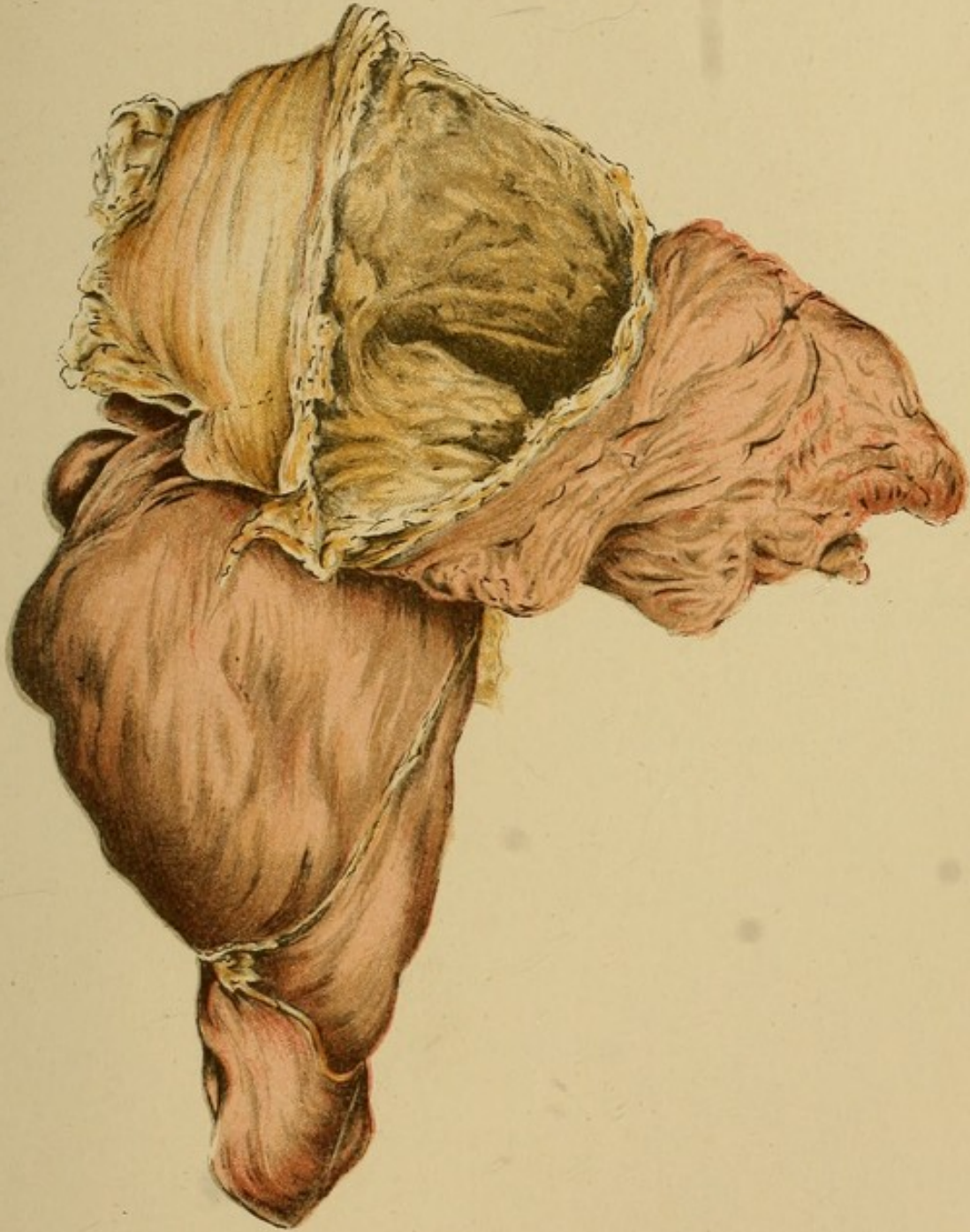


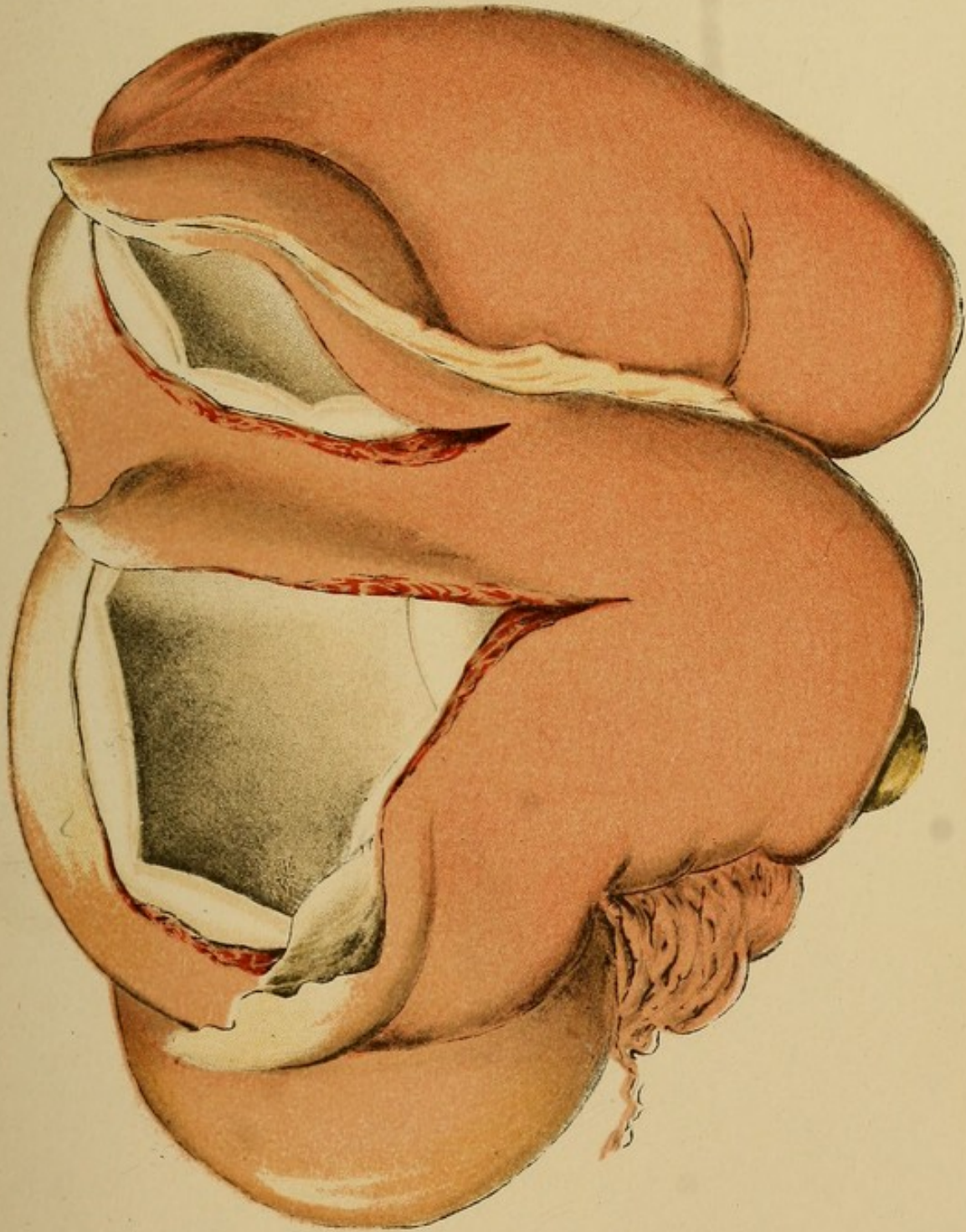


PLATE VIII.—Multiple hydatid cysts of the liver. The liver is uniformly enlarged and the cysts deeply embedded in its substance.

JULY 1911




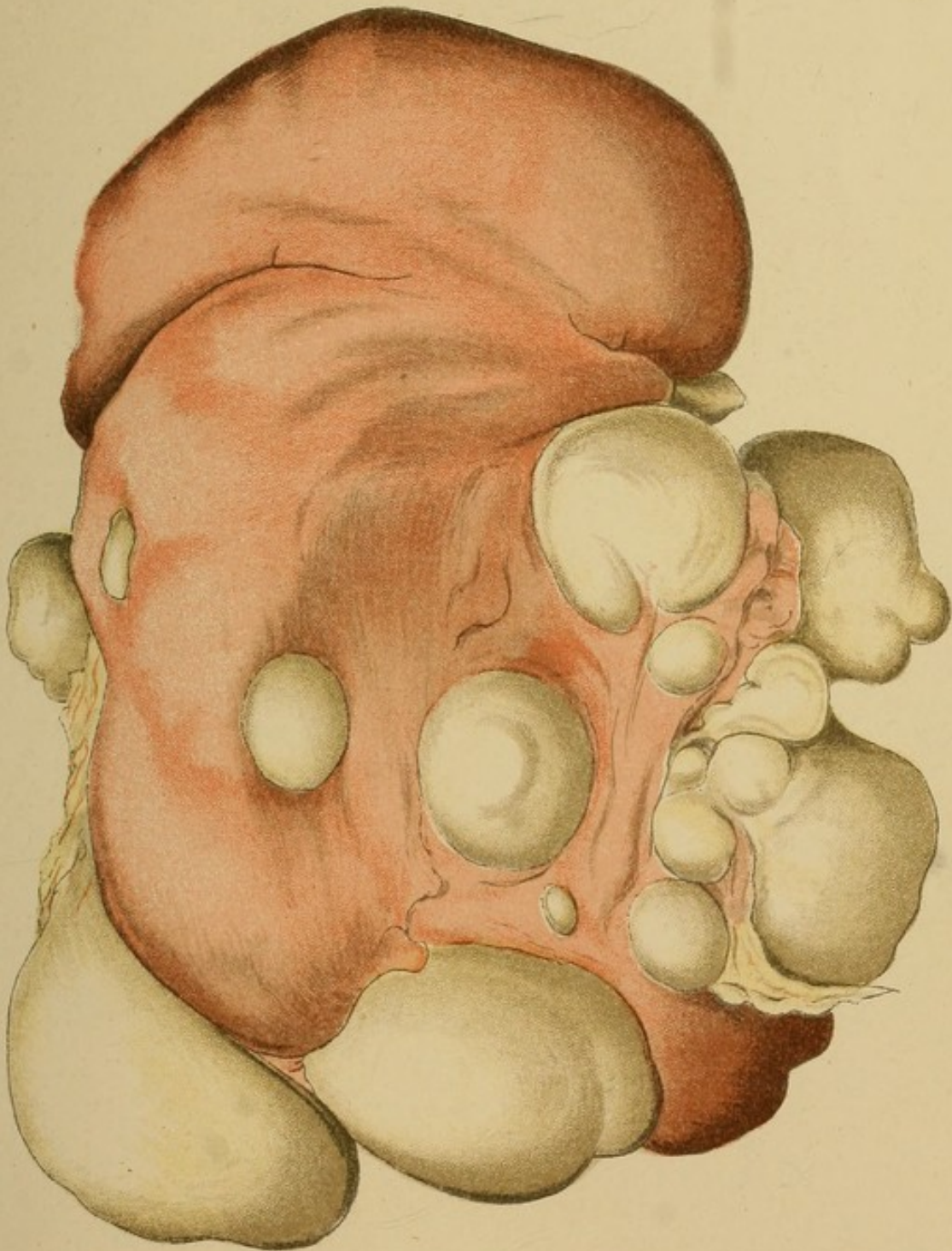


PLATE IX.—Multiple hydatid tumours of the liver (upper surface).




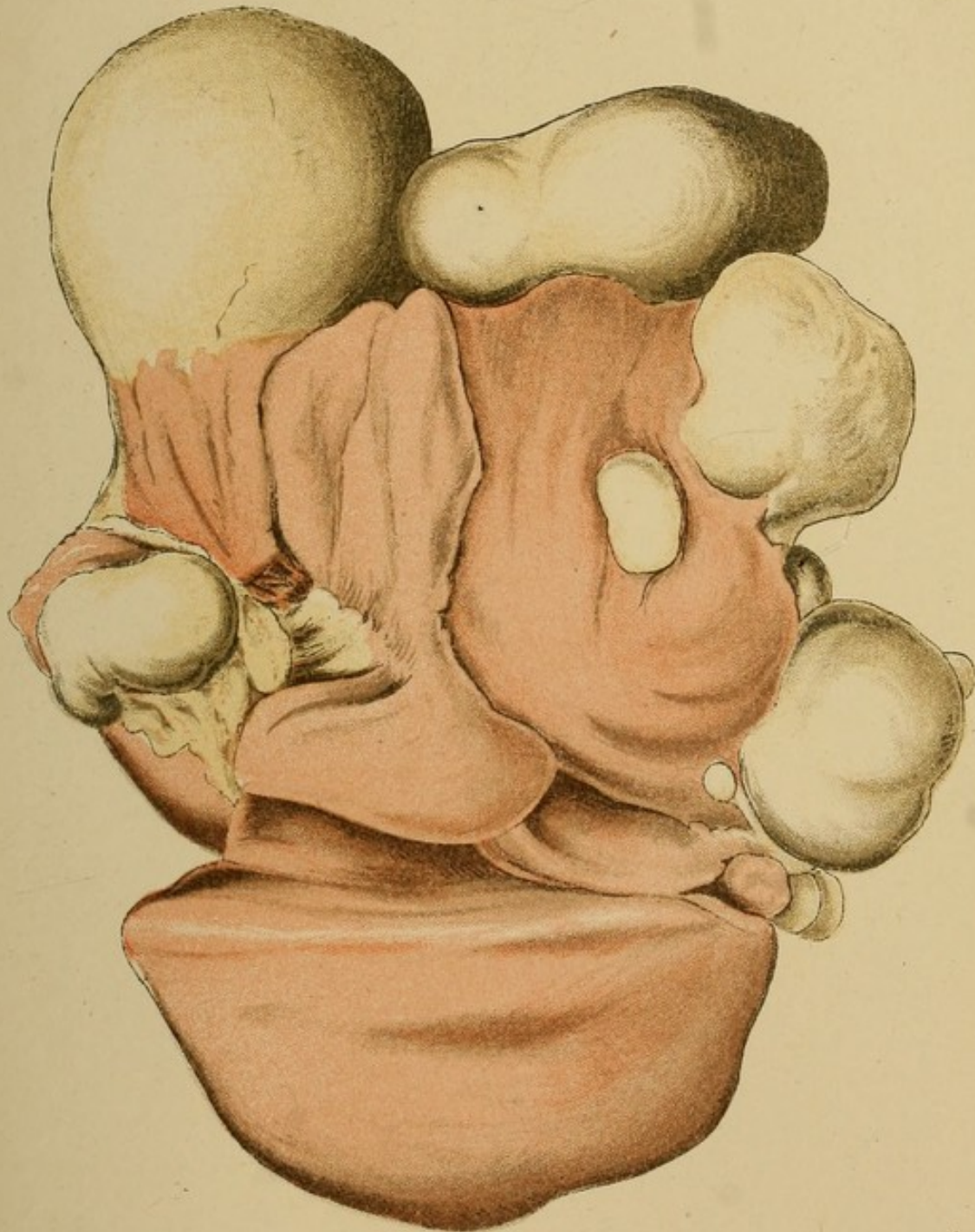


PLATE X.—Multiple hydatid tumours of the liver (lower surface).

PLATE 3




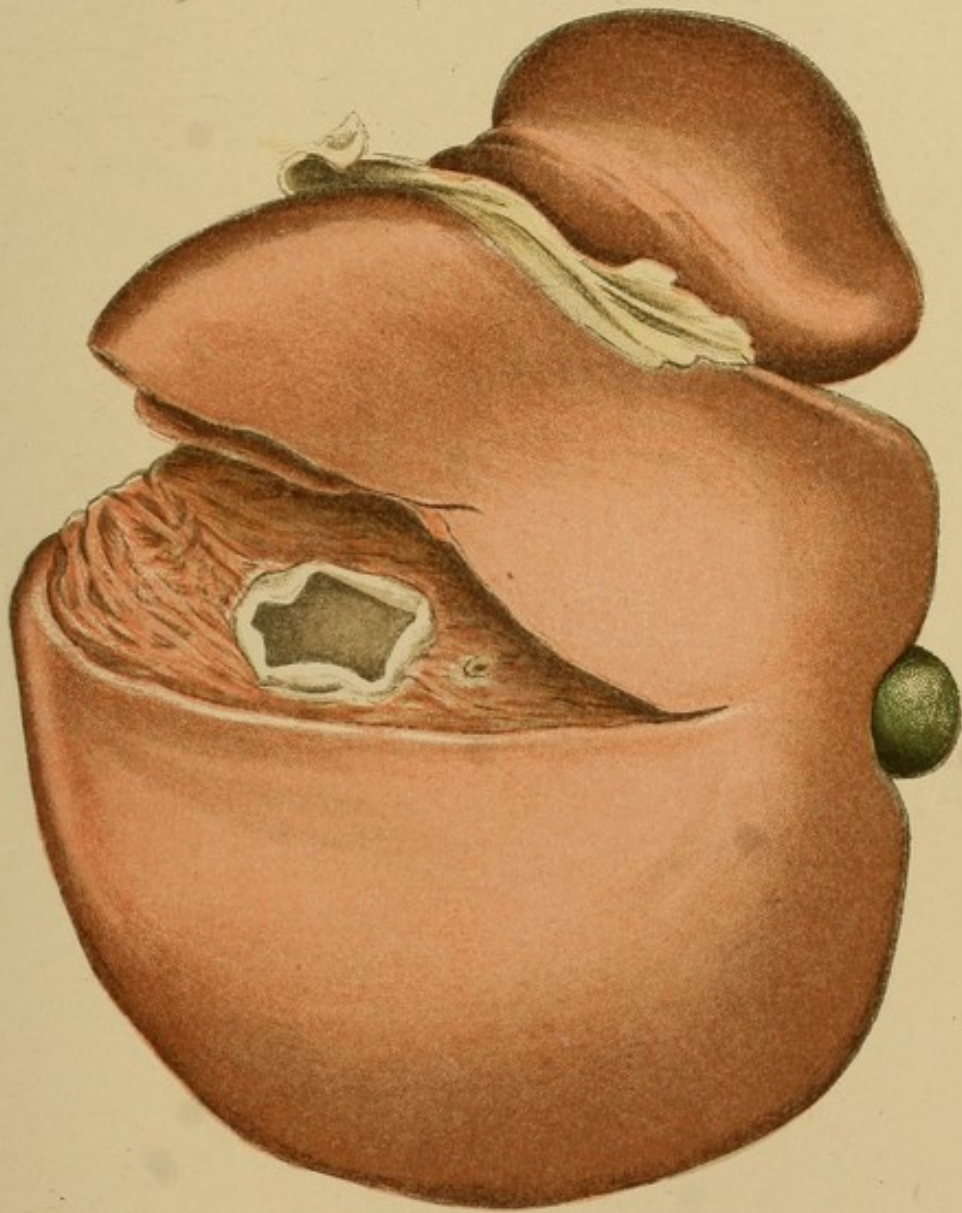


PLATE XI.—Small hydatid cyst embedded in the interior of the right lobe of the liver tissue.

1874






PLATE XII.—Small hydatid cyst in the lower margin of the liver showing the process of natural cure by caseous degeneration.

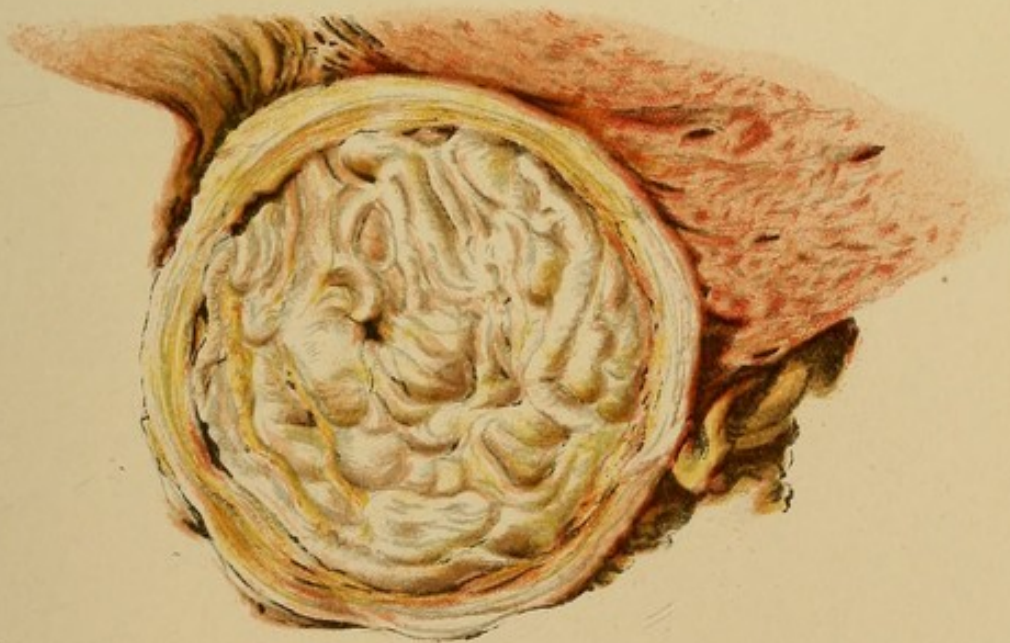
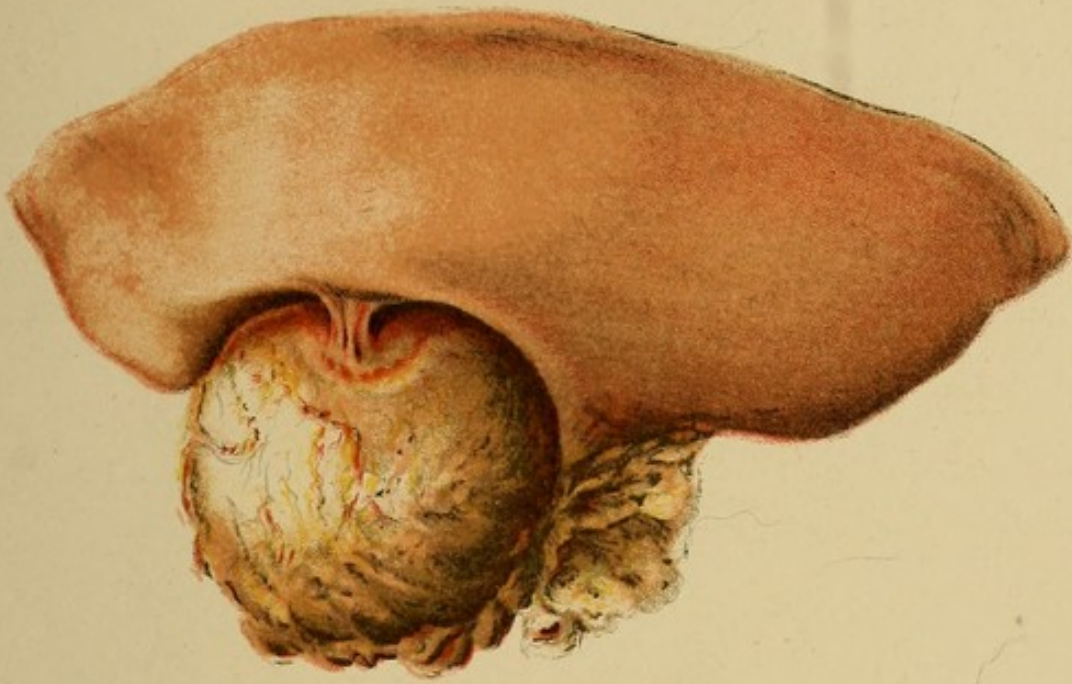



PLATE XIII.—Fig. *A.* shows outline of a hydatid cyst growing from the under surface of the liver.

Fig. *B.* The outline from the side view shows that it has not encroached on the space of the thoracic cavity but has partly invaded the abdomen in its growth.

PLATE XIII

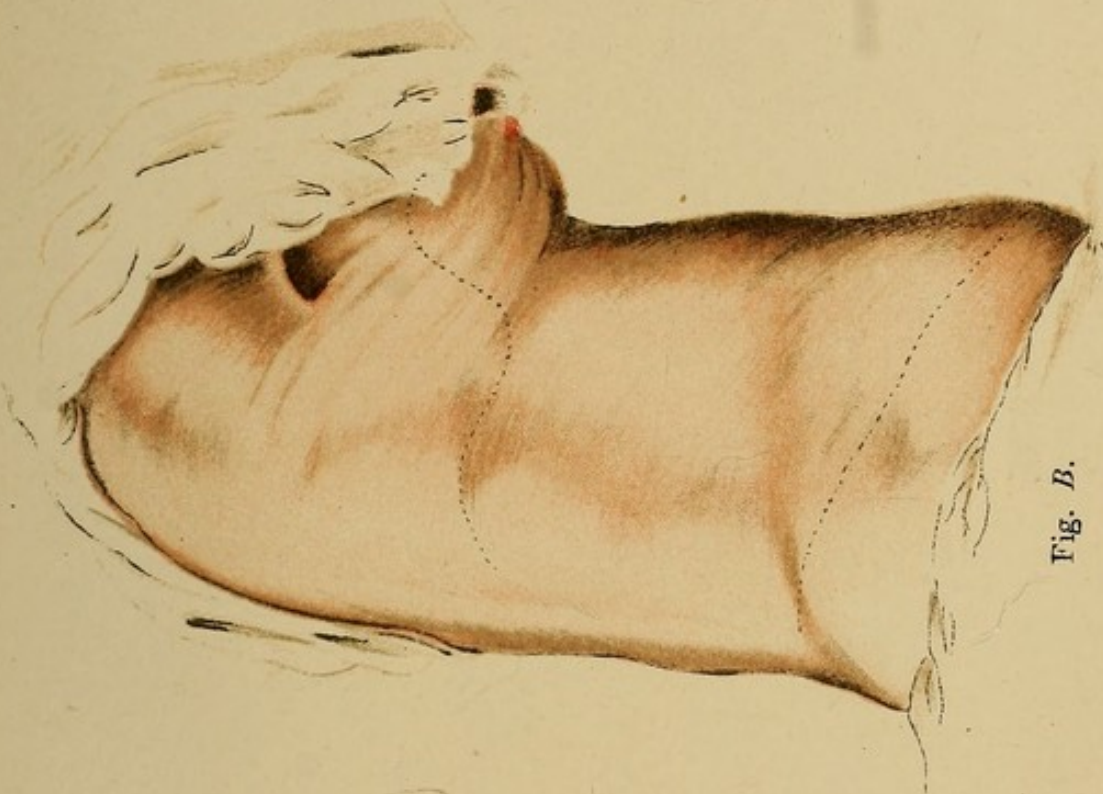


Fig. B.

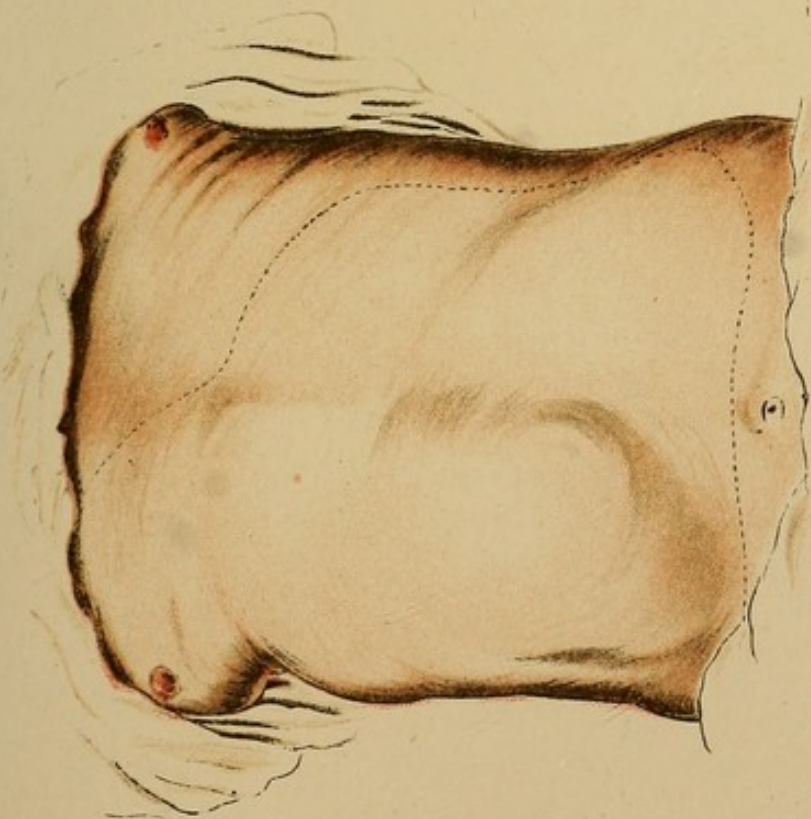


Fig. A.





PLATE XIV.—Large single hydatid cyst of the abdomen. The mottled rash appeared a few hours after an exploratory needle was inserted.



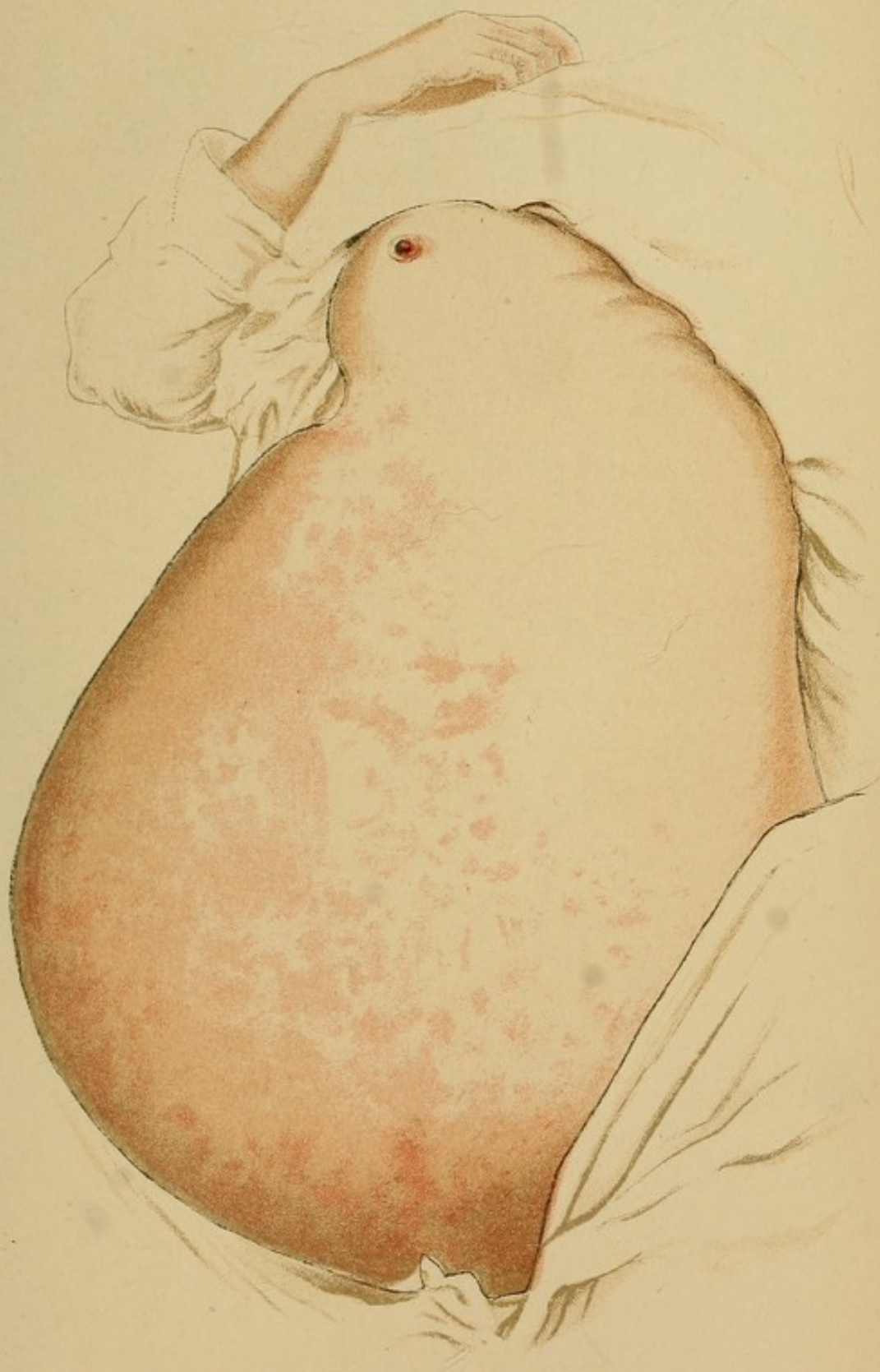




PLATE XV.—Hydatid tumour of the liver, the dotted line showing the area of dulness of the cyst.

The urticaria rash is also represented. It appeared in successive crops for five days, and followed, in the first instance, an exploratory puncture.

PLATE XX

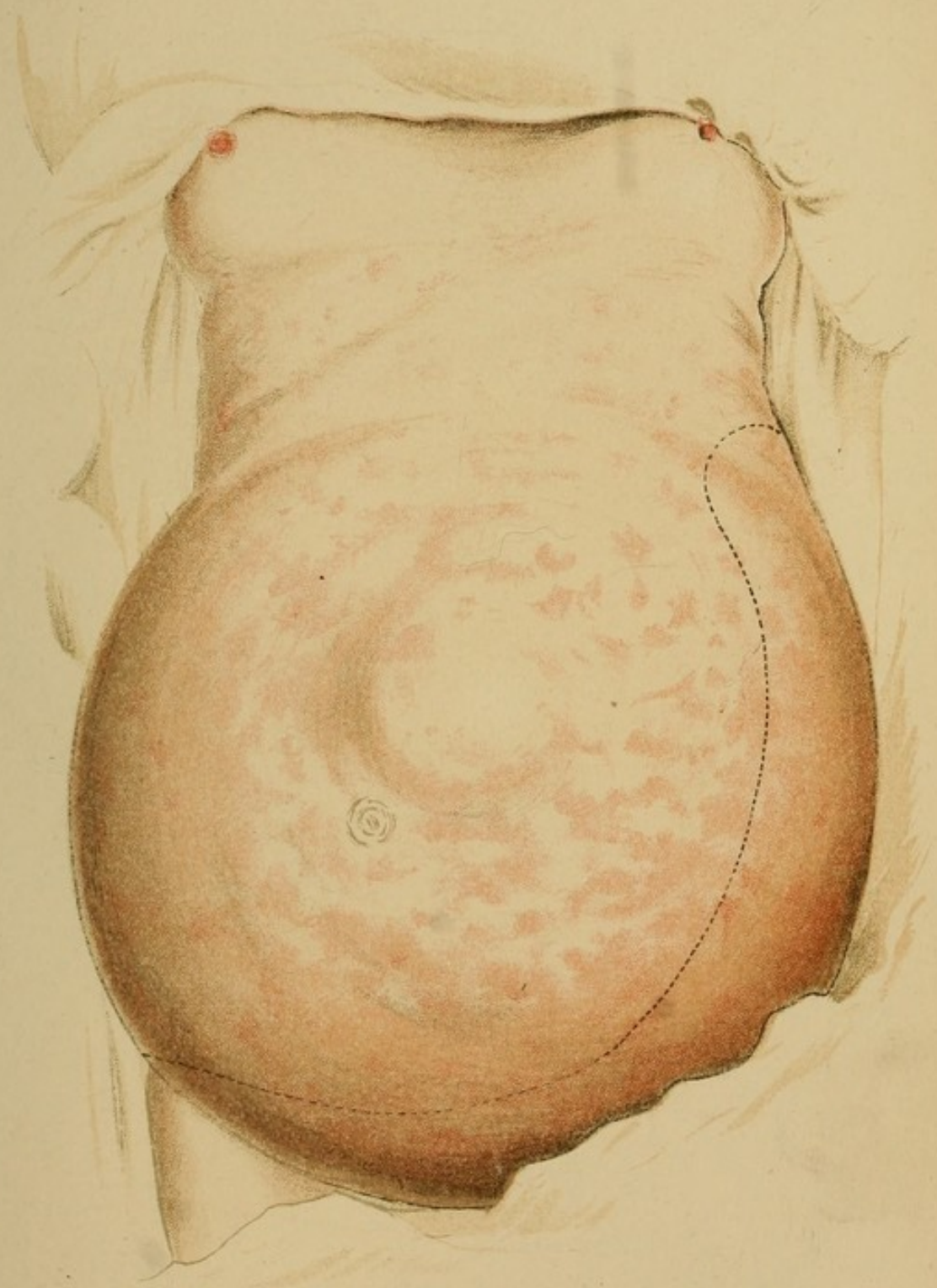


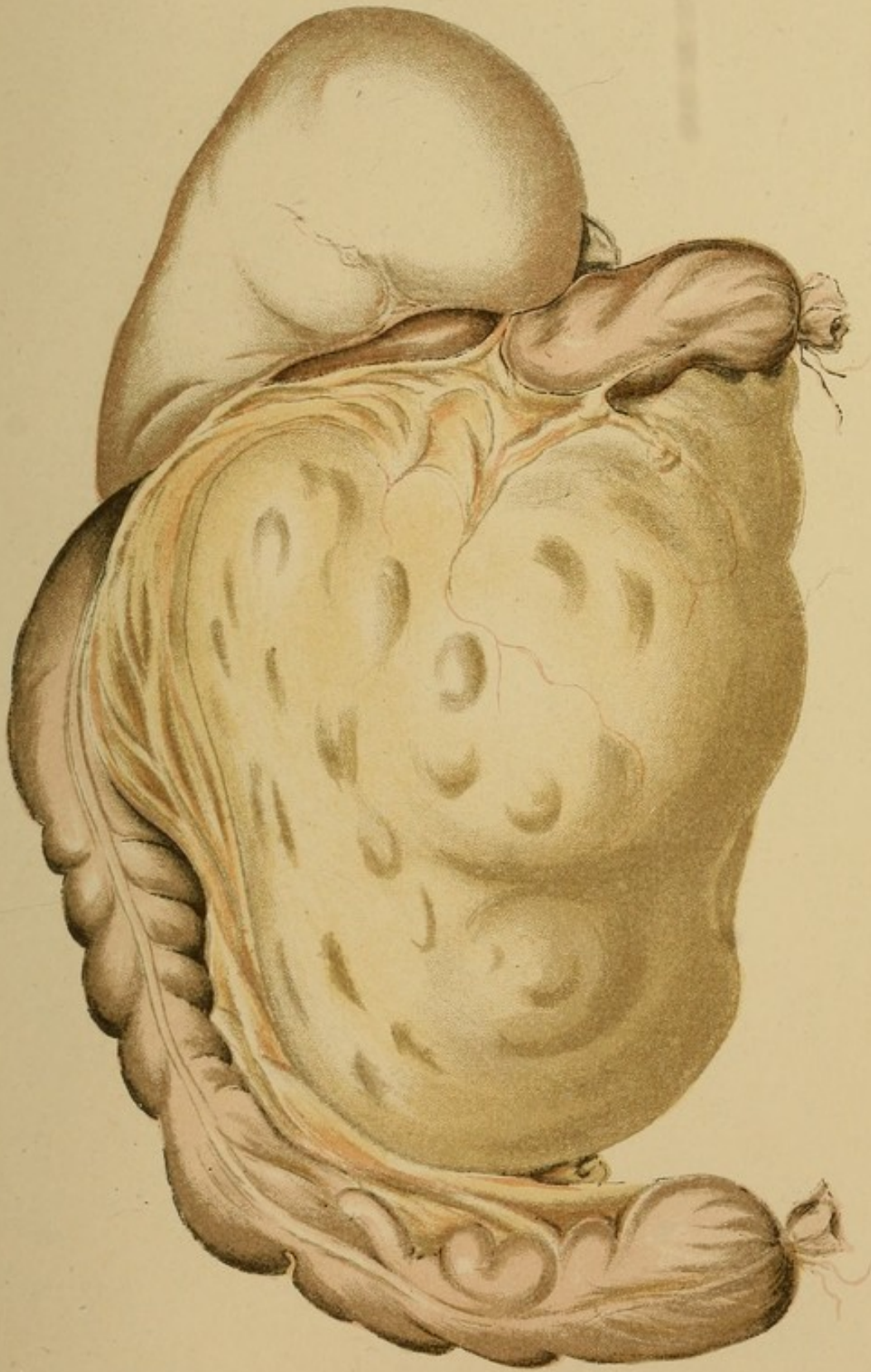


PLATE XVI.—Large hydatid cyst in the great omentum; daughter-cysts showing through the fibrous wall. The stomach was pushed upwards and to the left and greatly compressed.




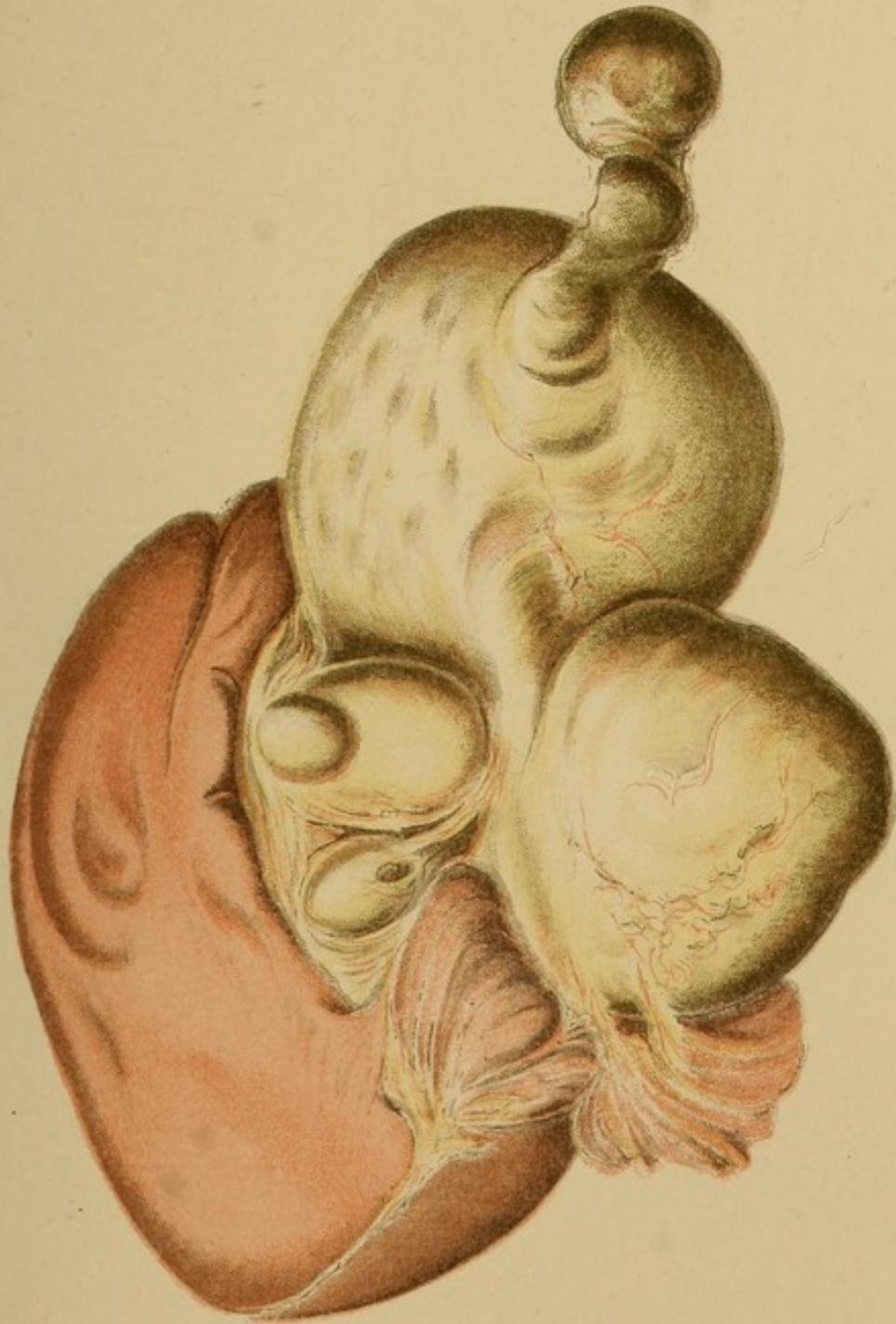


PLATE XVII.—Hydatid tumour growing from the under surface of the liver. At one part it has continued its growth by means of a diverticulum in the direction of least resistance.







PLATE XVIII.—Hydatid tumour in the mesentery causing intestinal obstruction from adhesions and pressure.



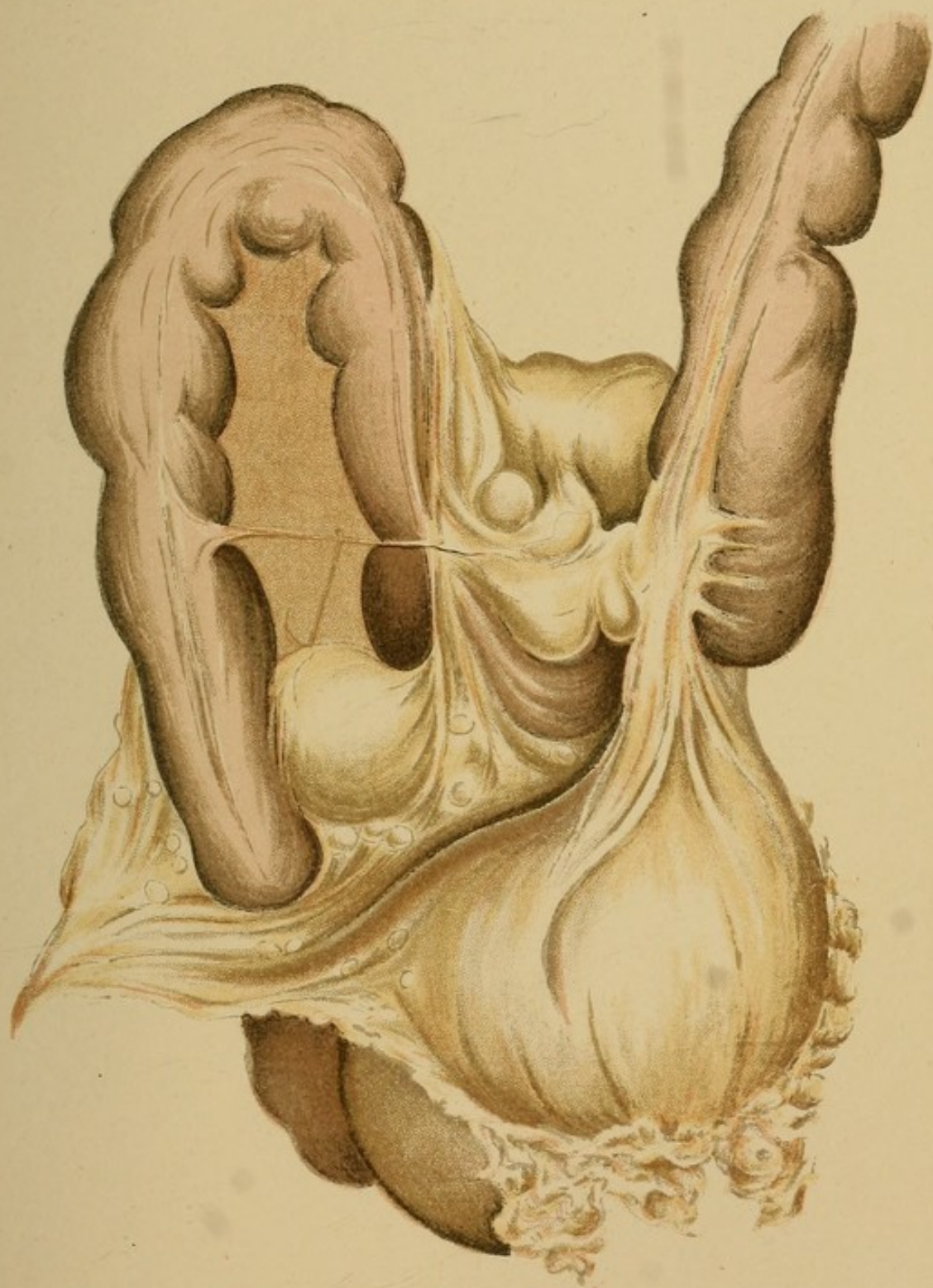


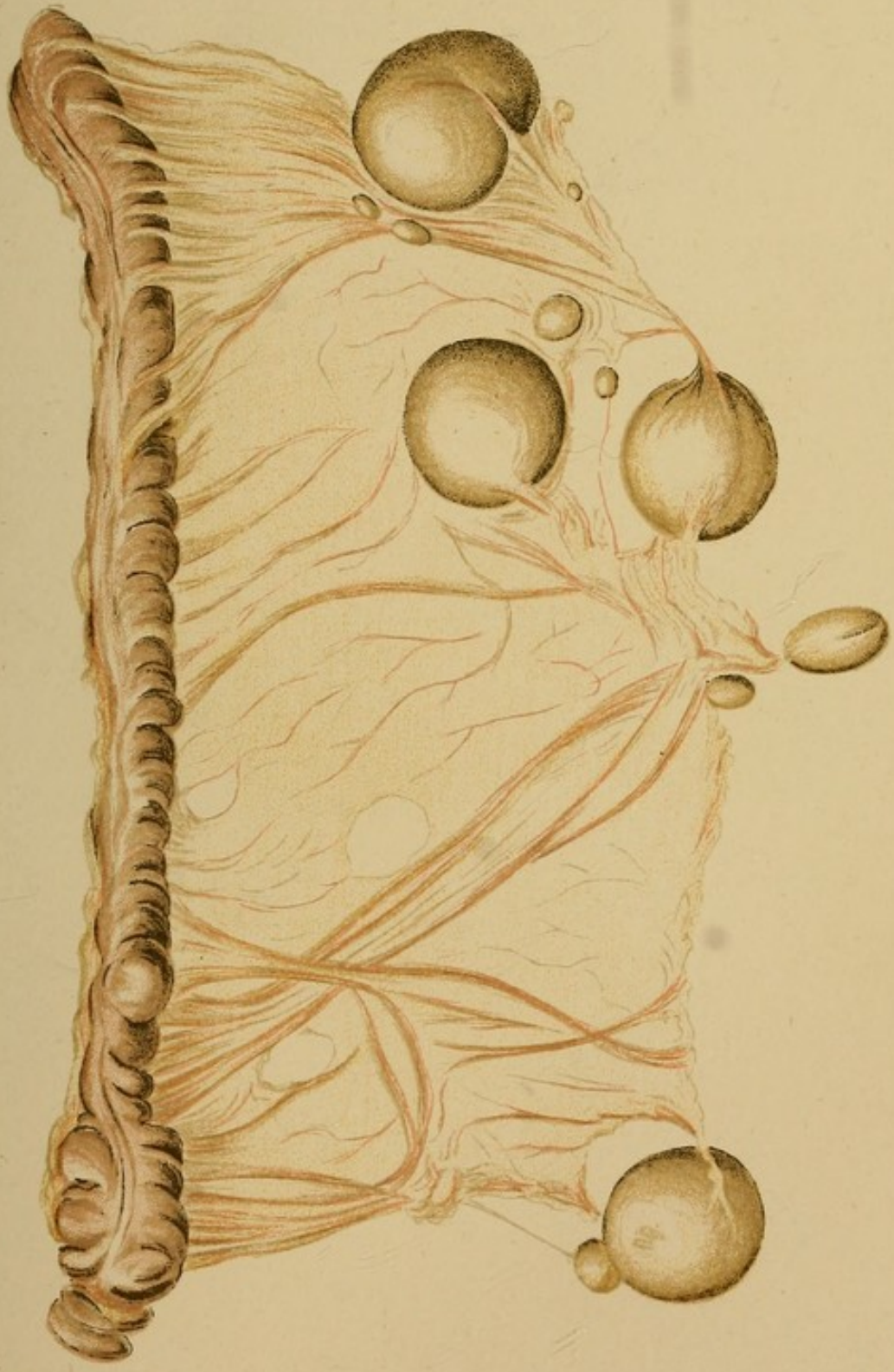


PLATE XIX.—Multiple hydatid cysts of the large omentum.

STATE




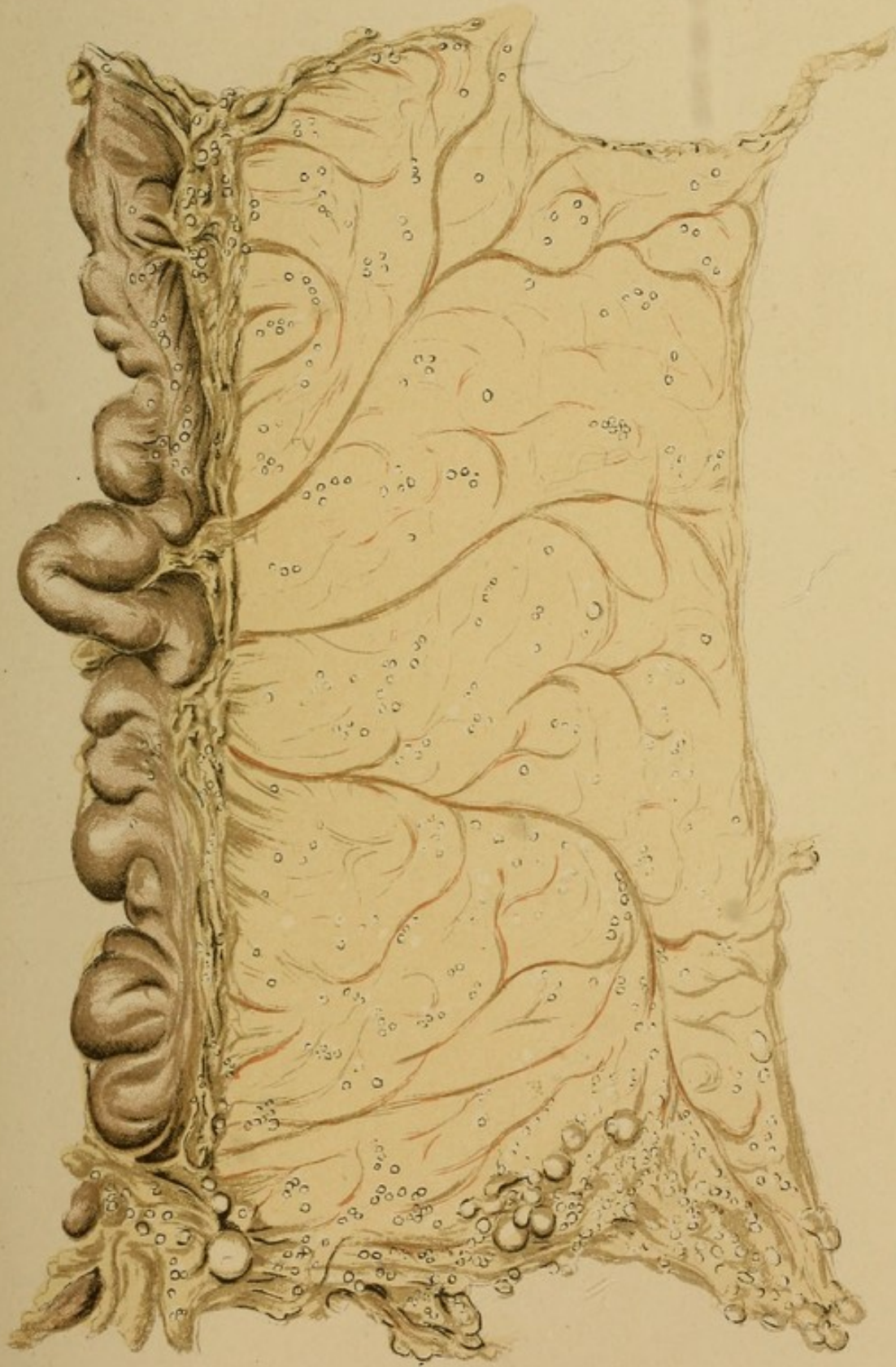


PLATE XX.—Multiple hydatid cysts of a minute size in the great omentum.

PLATE XX




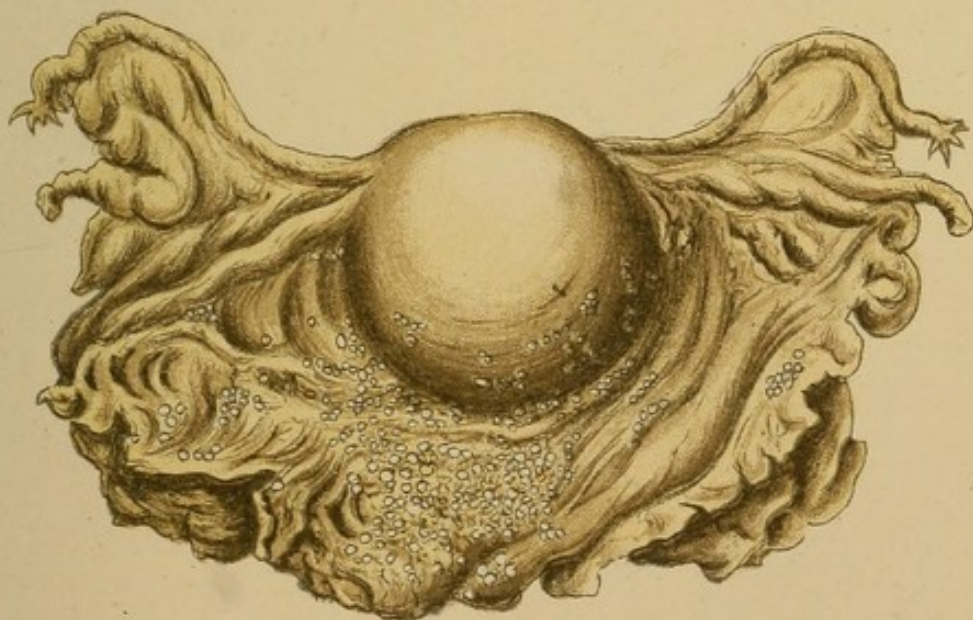
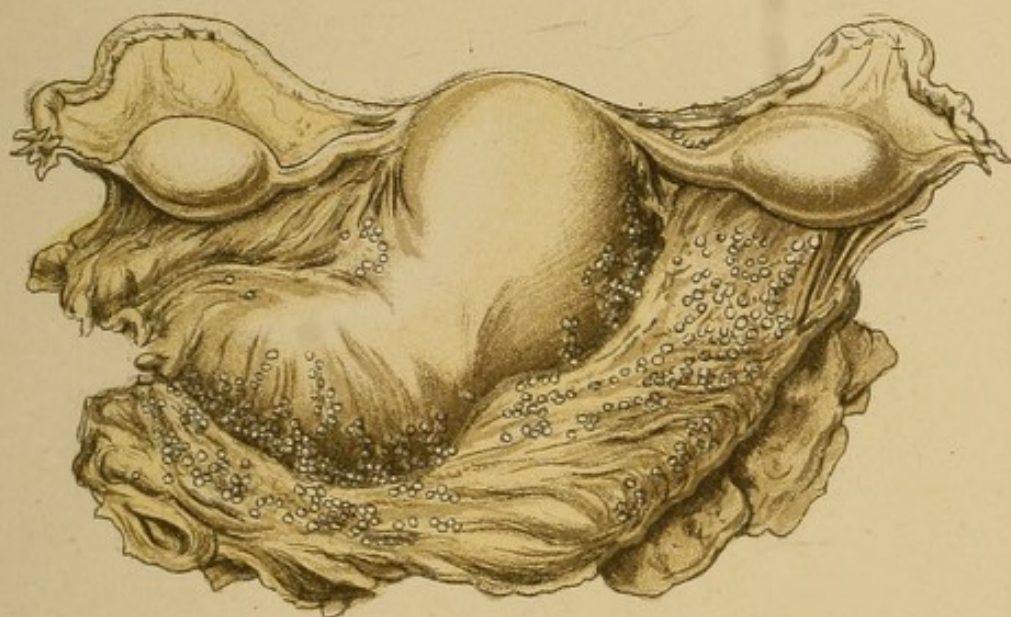


PLATE XXI.—Numerous small hydatid cysts in the serous pouches behind and in front of the uterus.

PLATE NO.





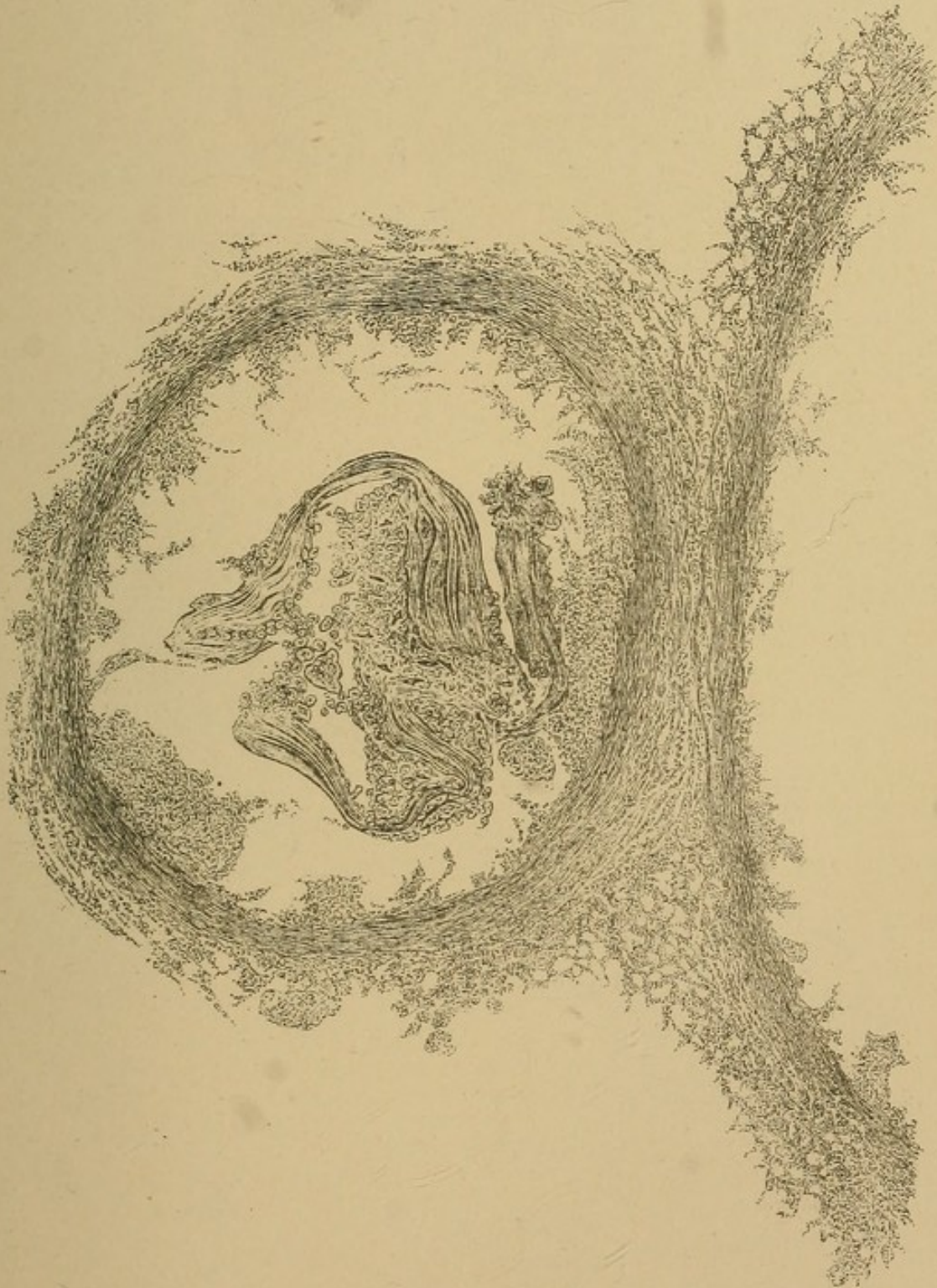


PLATE XXII.—Microscopic appearances of one of the small cysts in plate XXI. showing the actively growing connective tissue of the fibrous capsule. In the centre is seen cyst-wall detached from the ectocyst, with its characteristic laminated appearance, and embedded in its substance numerous scolices.






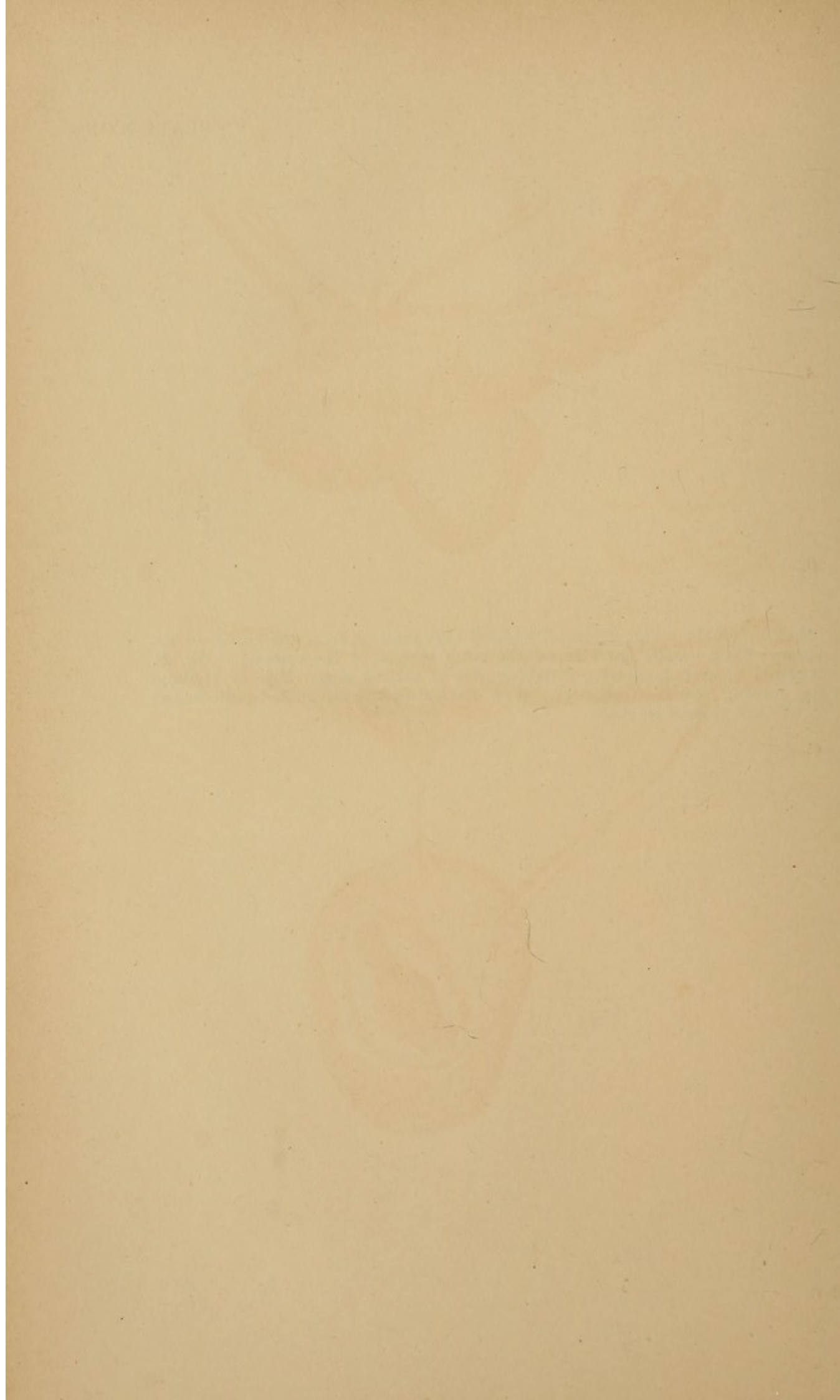
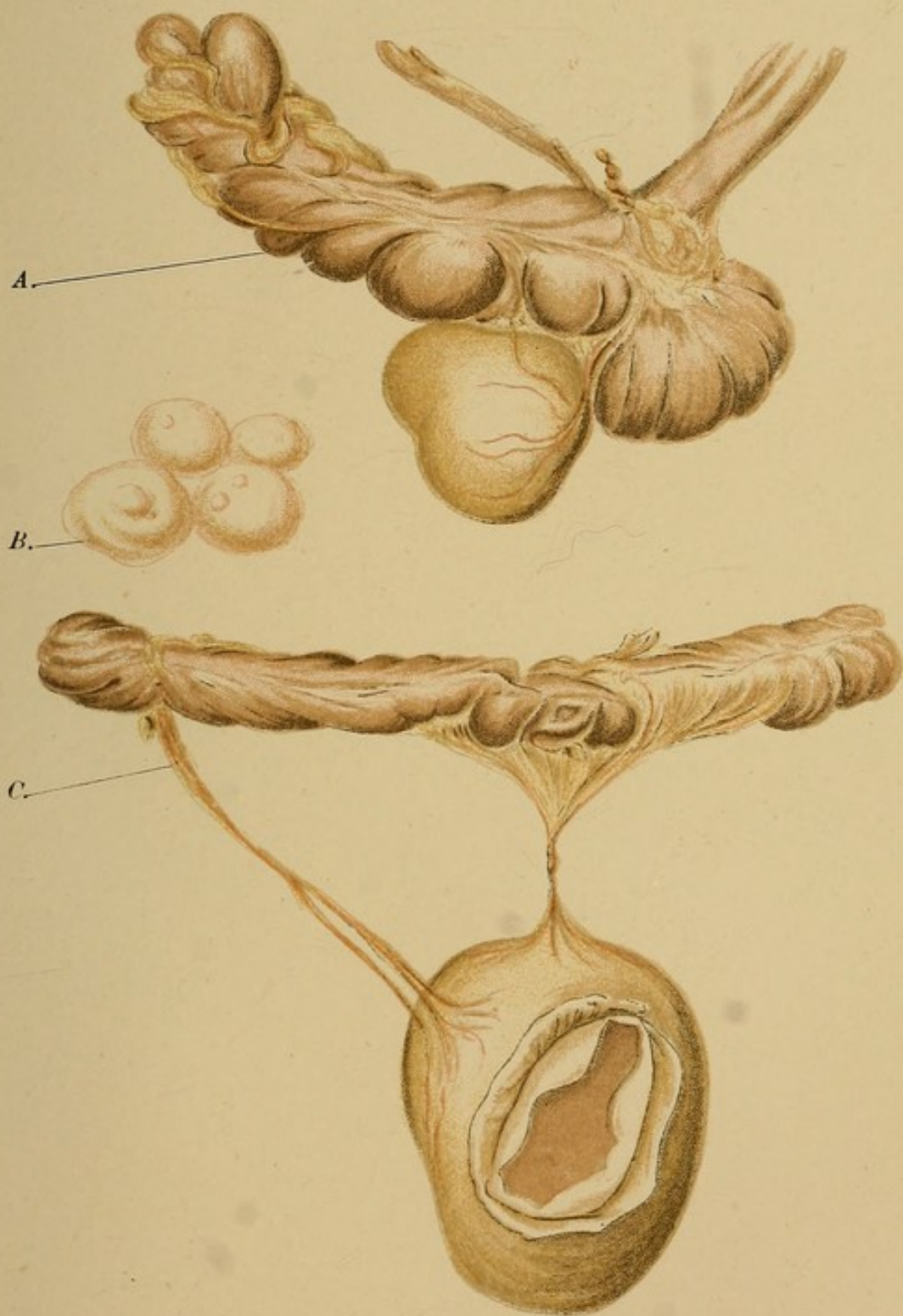


PLATE XXIII.—Fig. *A*, Small hydatid cyst growing from the region of the cœcum; blood vessels are seen on the outer surface of the ectocyst. Fig. *B*. Contents of cyst *A*. showing daughter-cysts of various sizes. Fig. *C*. Hydatid cyst growing from the mesentery. It is attached by two attenuated pedicles, one of which is twisted on itself.





11/11/11

PLATE XXIV.—Fig. *A*. Hydatid tumour growing from the anterior surface of the rectum showing wall of the cyst and its fibrous covering (ectocyst).

Fig. *B*. Small hydatid growing from the peritoneum over the kidney.

Fig. *C*. Hydatid entirely replacing the supra-renal capsule and retaining the shape of the original body.

PLATE XLIX



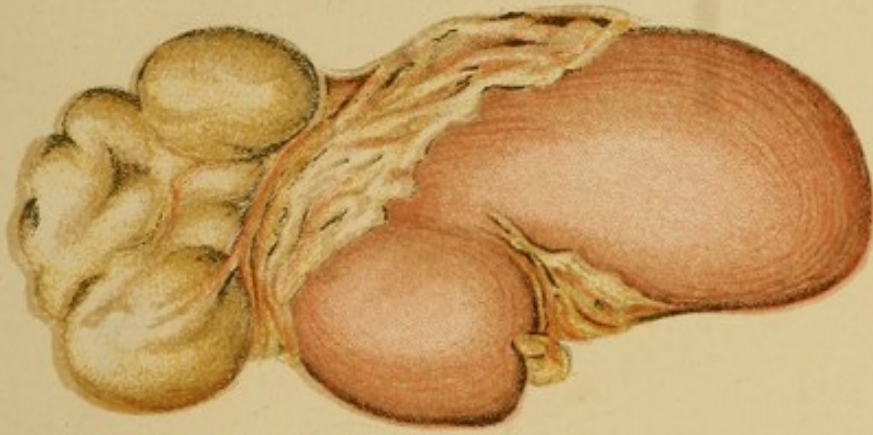


Fig. C.

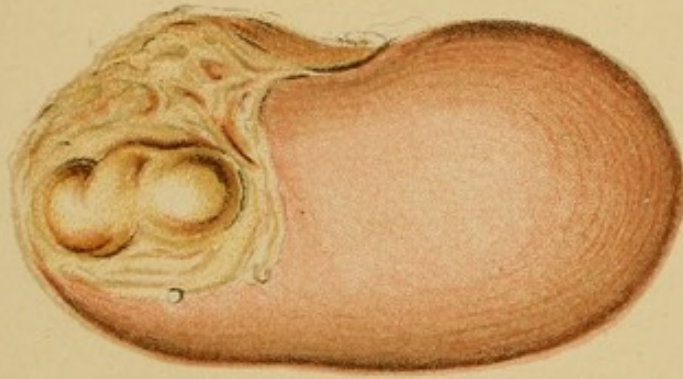


Fig. B.

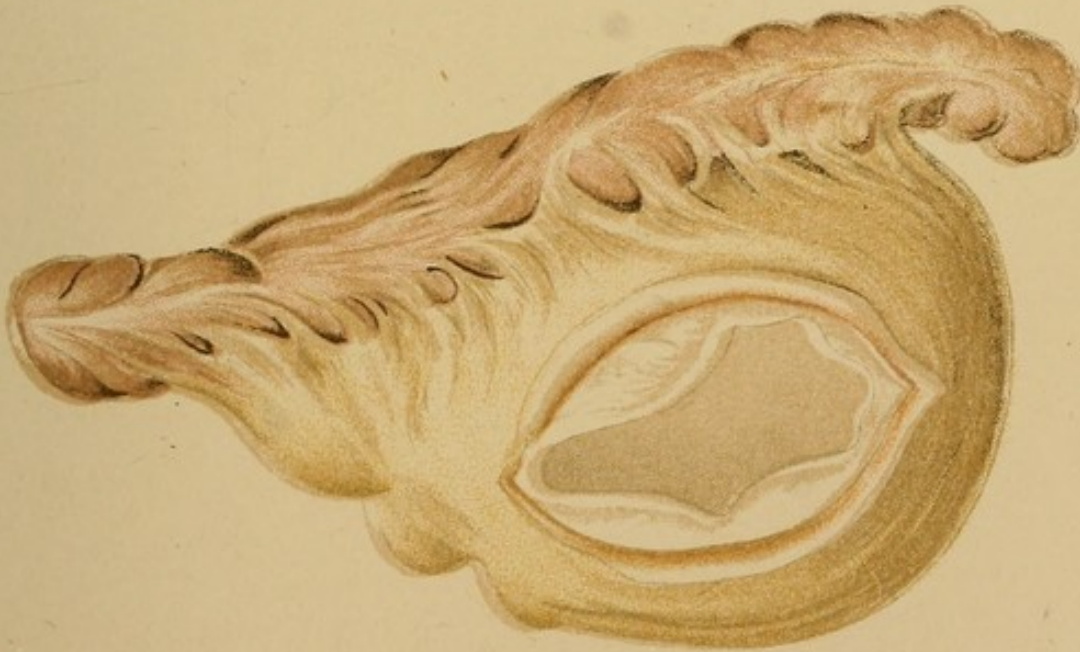

Fig. A.


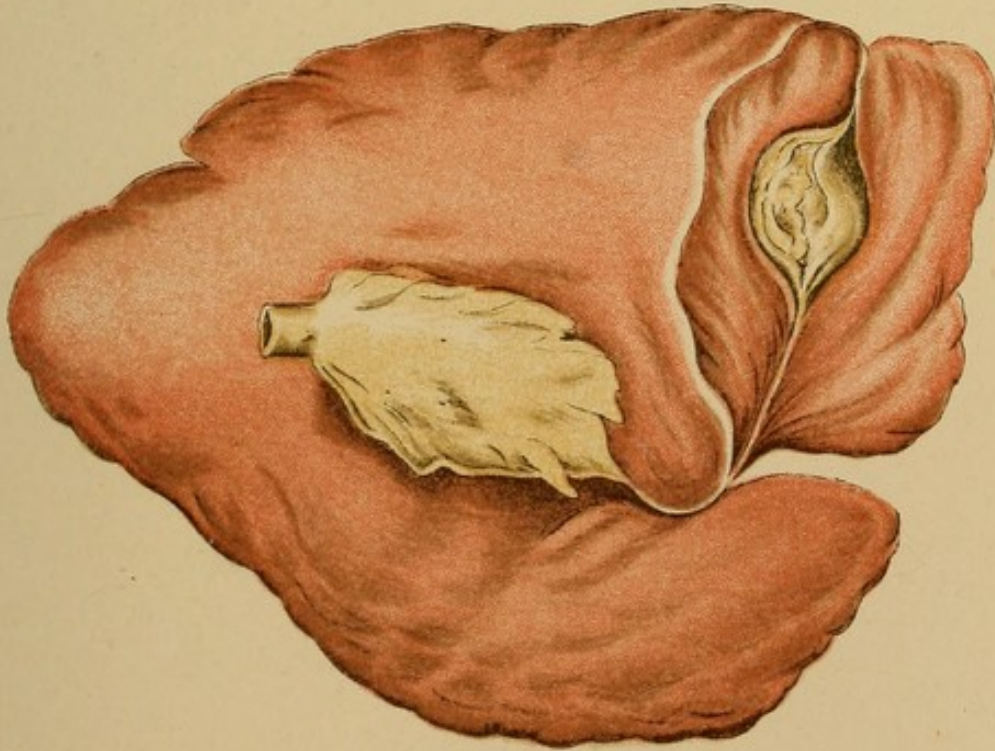


PLATE XXV.—Small hydatid tumours in the lungs. They were filled with daughter-cysts and undergoing calcareous degeneration.

STATE


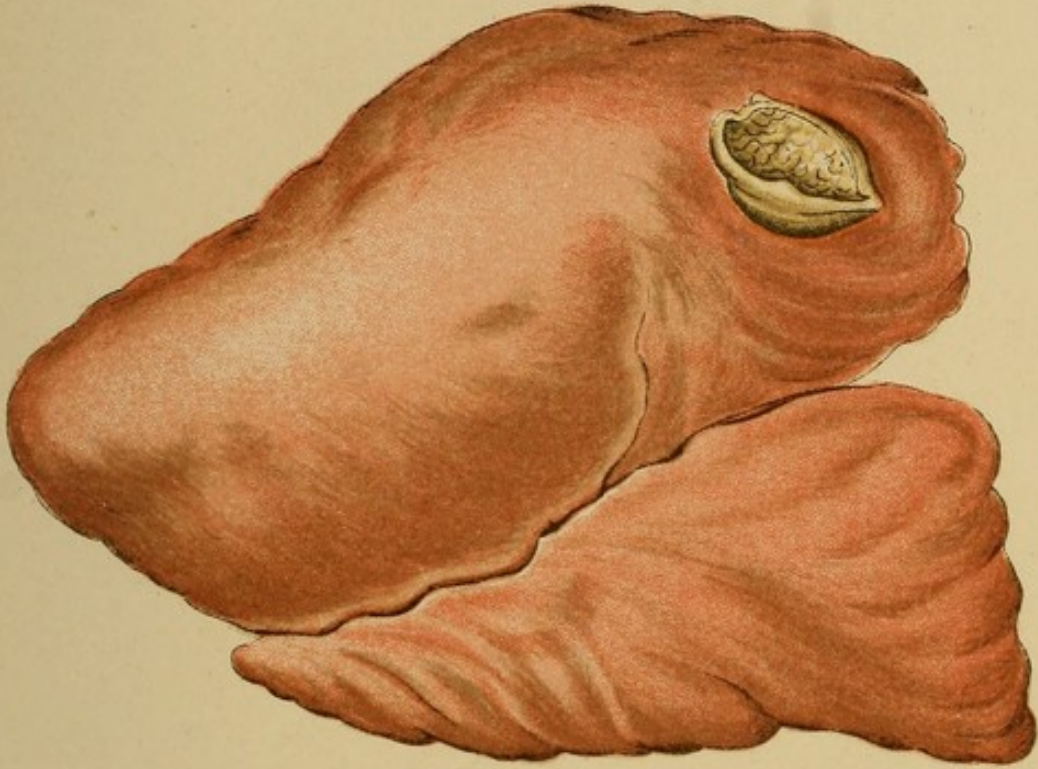



PLATE XXVI.—Fig. A. Hydatid cyst in the lung. The apex and marginal portion were the only parts of the lung tissue remaining.

Fig. B. Hydatid cyst removed by thoracic incision from the lower lobe of the left lung in an aboriginal.

PLATE XXV

Fig. B.

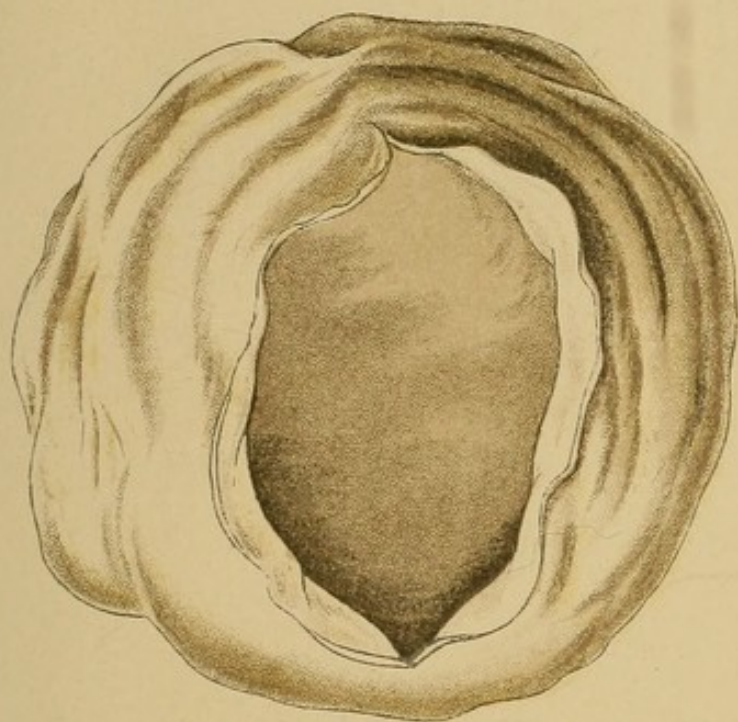
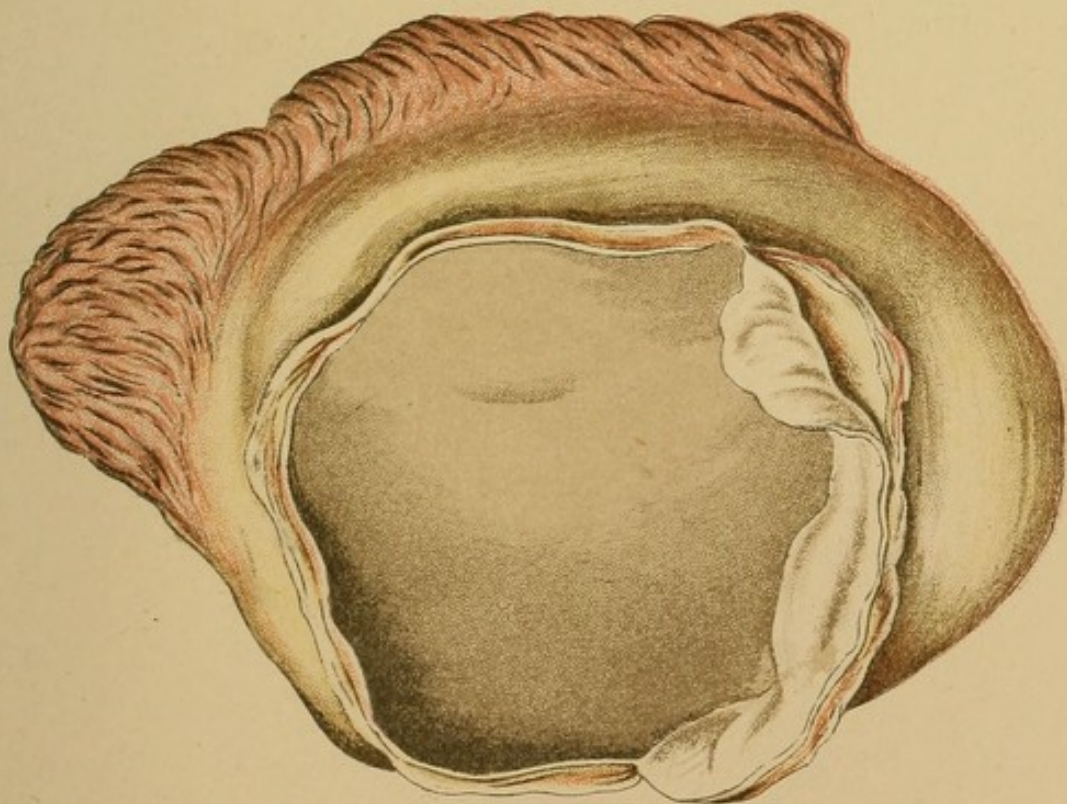


Fig. A.




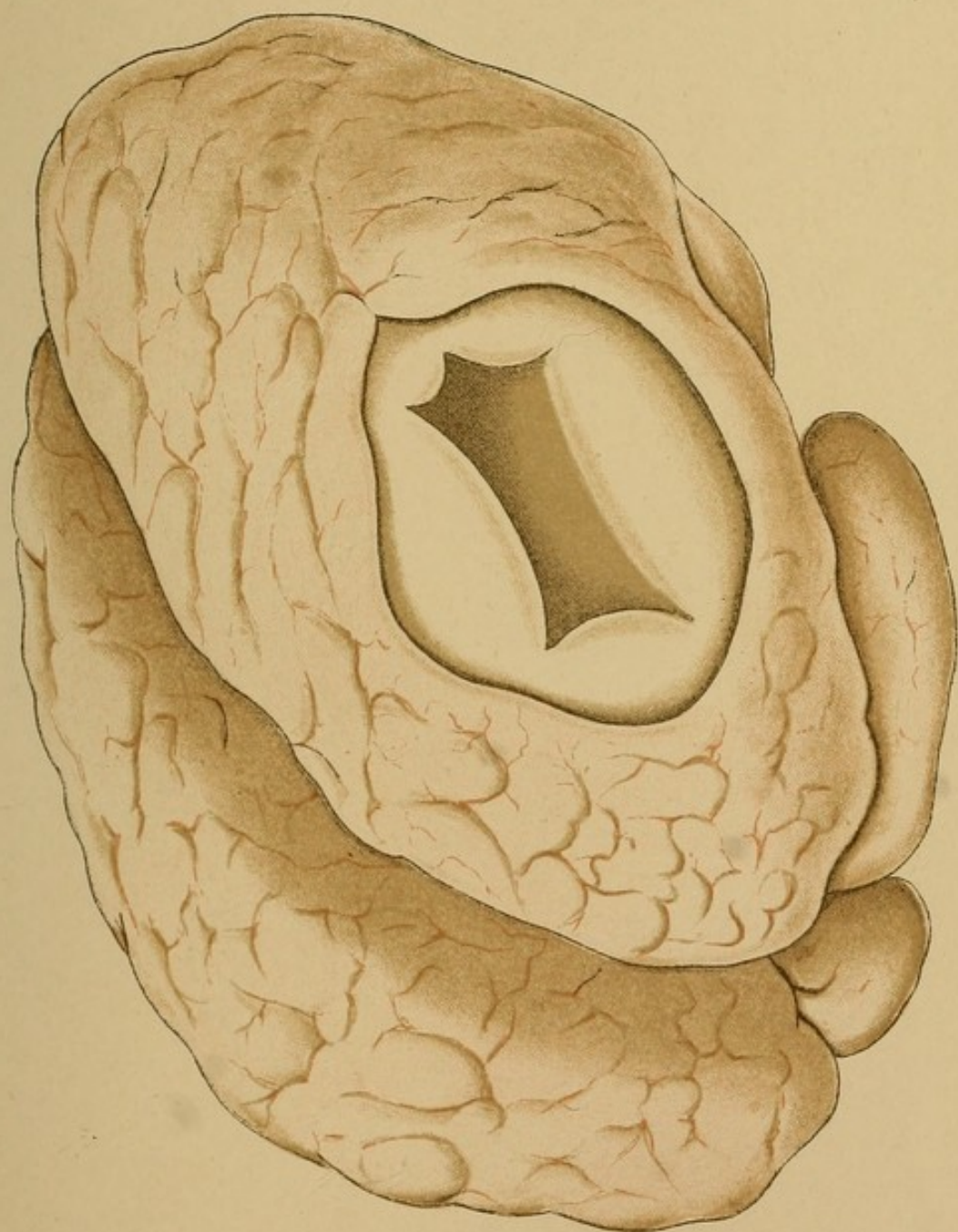


PLATE XXVII.—Hydatid tumour in the right occipital lobe of the cerebrum.

PLATE XXXII




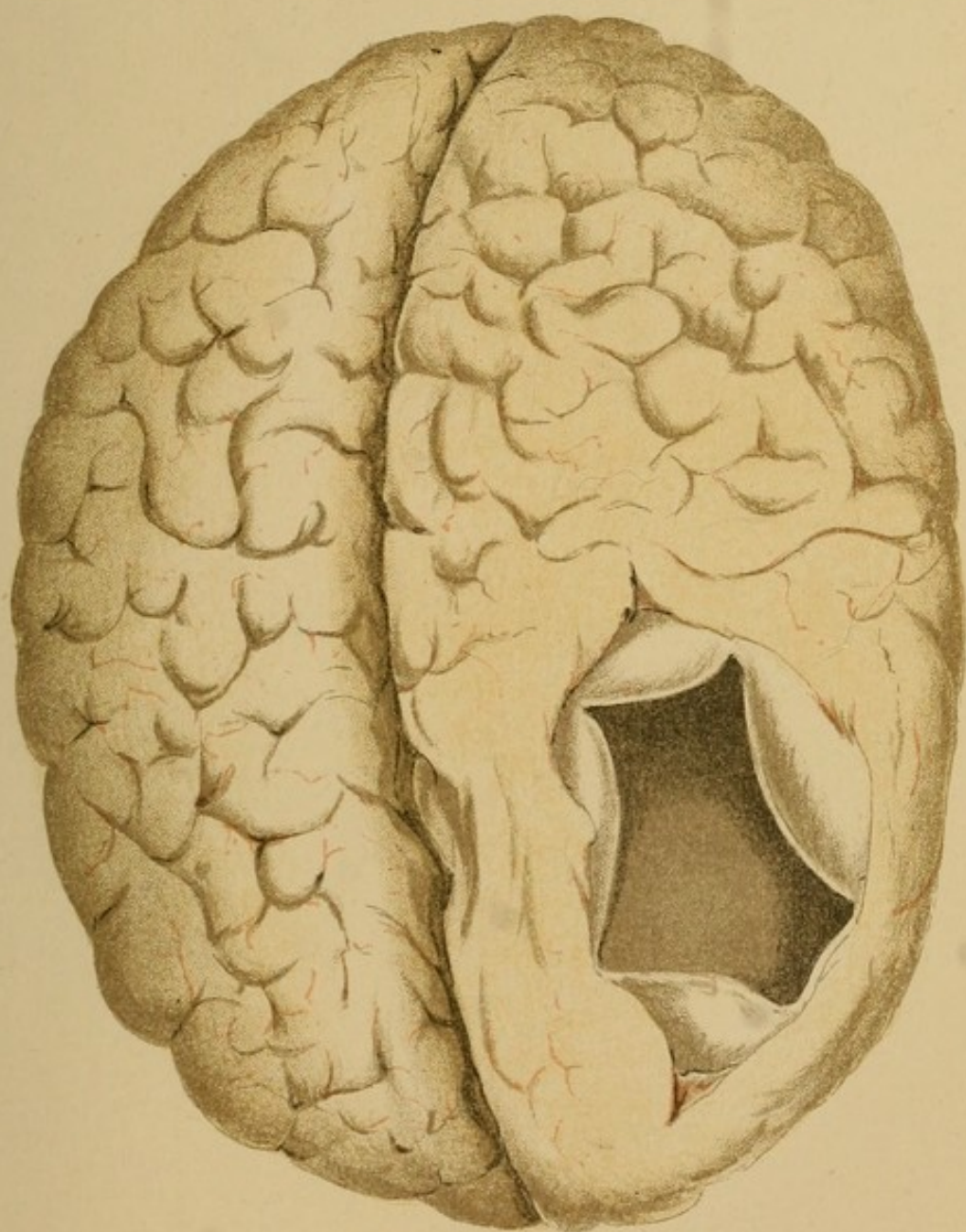


PLATE XXVIII.—Hydatid in the brain, from a girl aged 10 years. The cyst invaded the frontal and parietal lobes of the right hemisphere. For description of case see text, "Hydatid of Brain."

PLATE XXXIII







PLATE XXIX.—Hydatid in the brain : the patient before operation. *From a Photograph.*



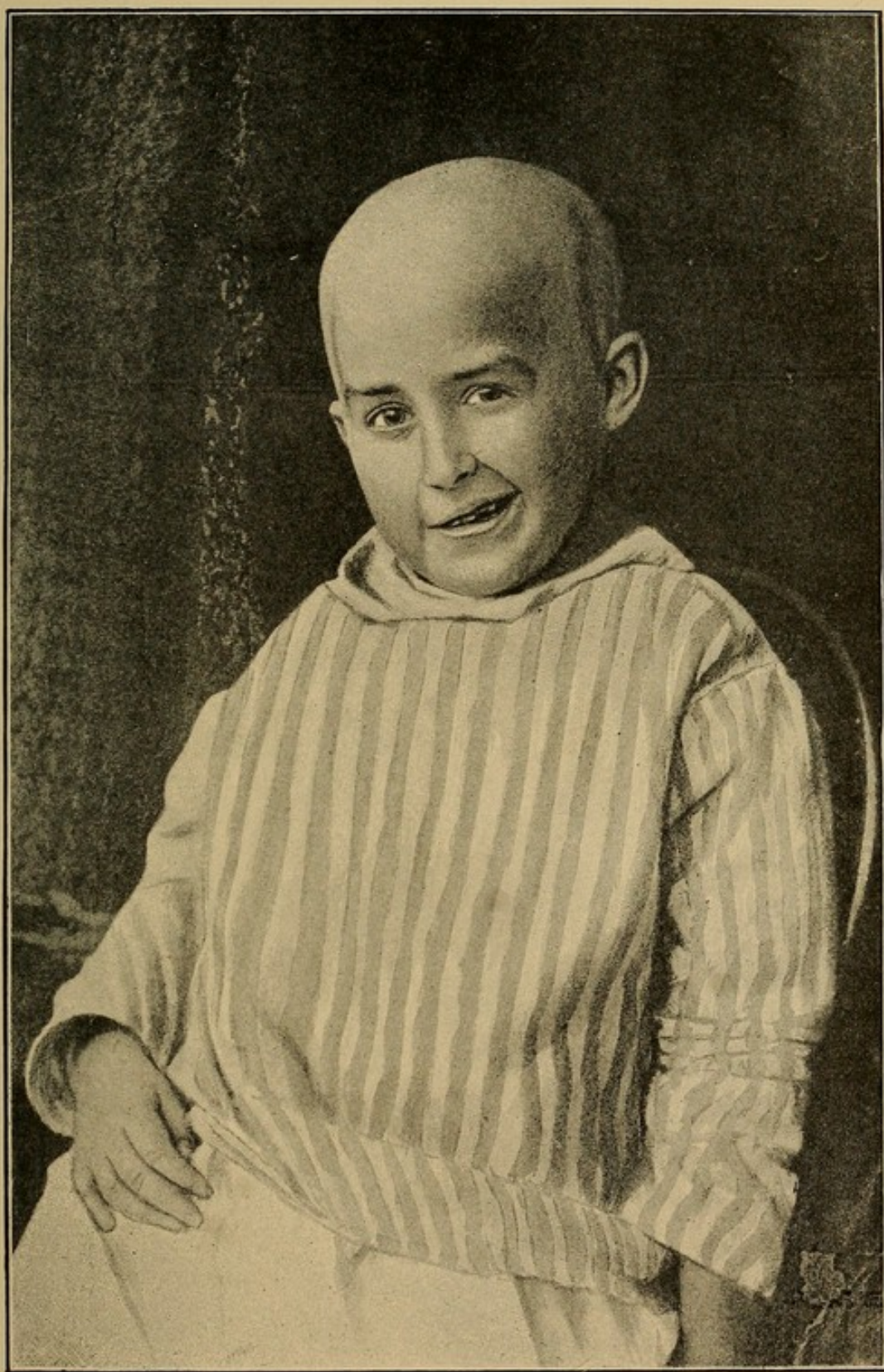


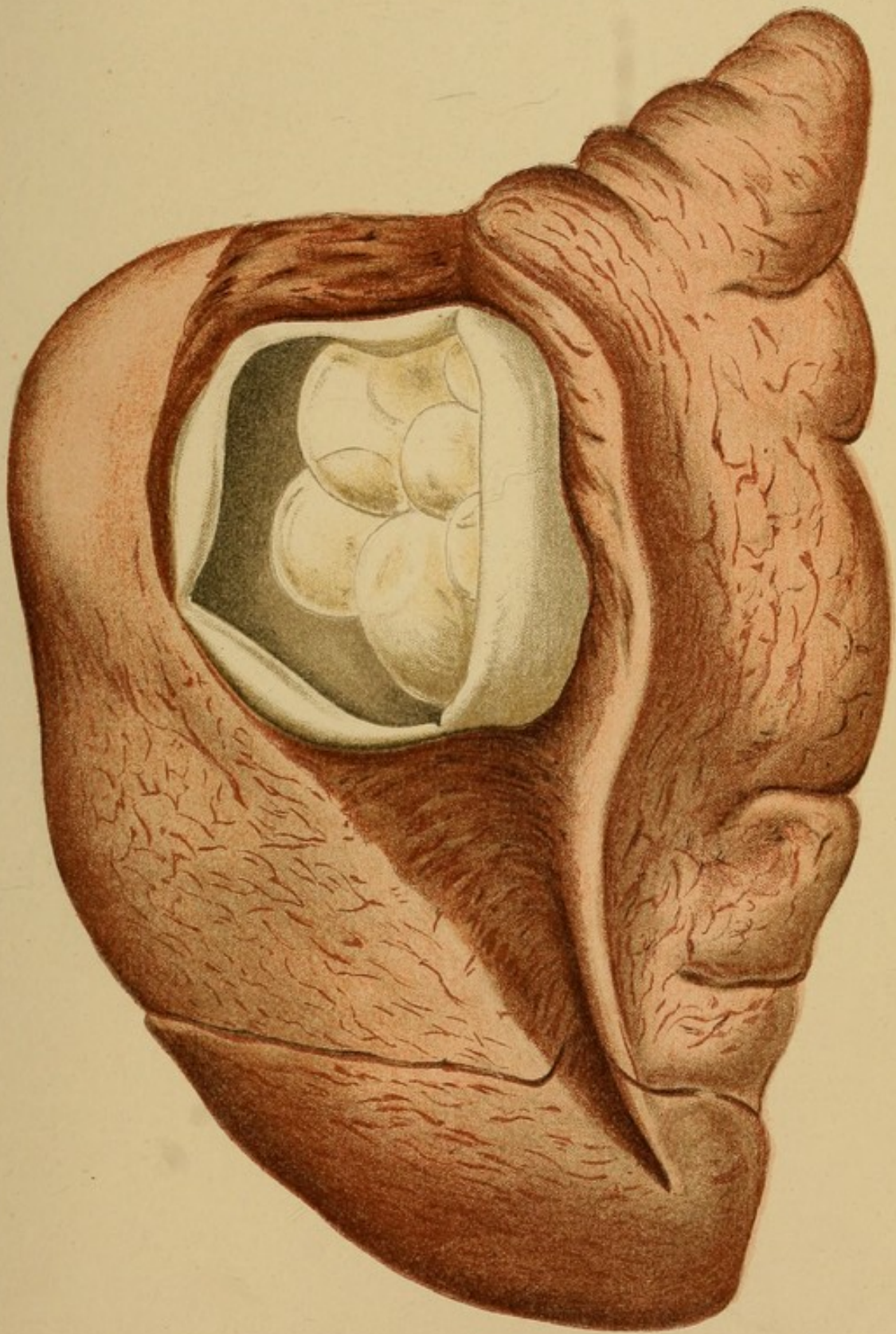


PLATE XXX.—Hydatid of the spleen showing daughter-cysts *in situ*.






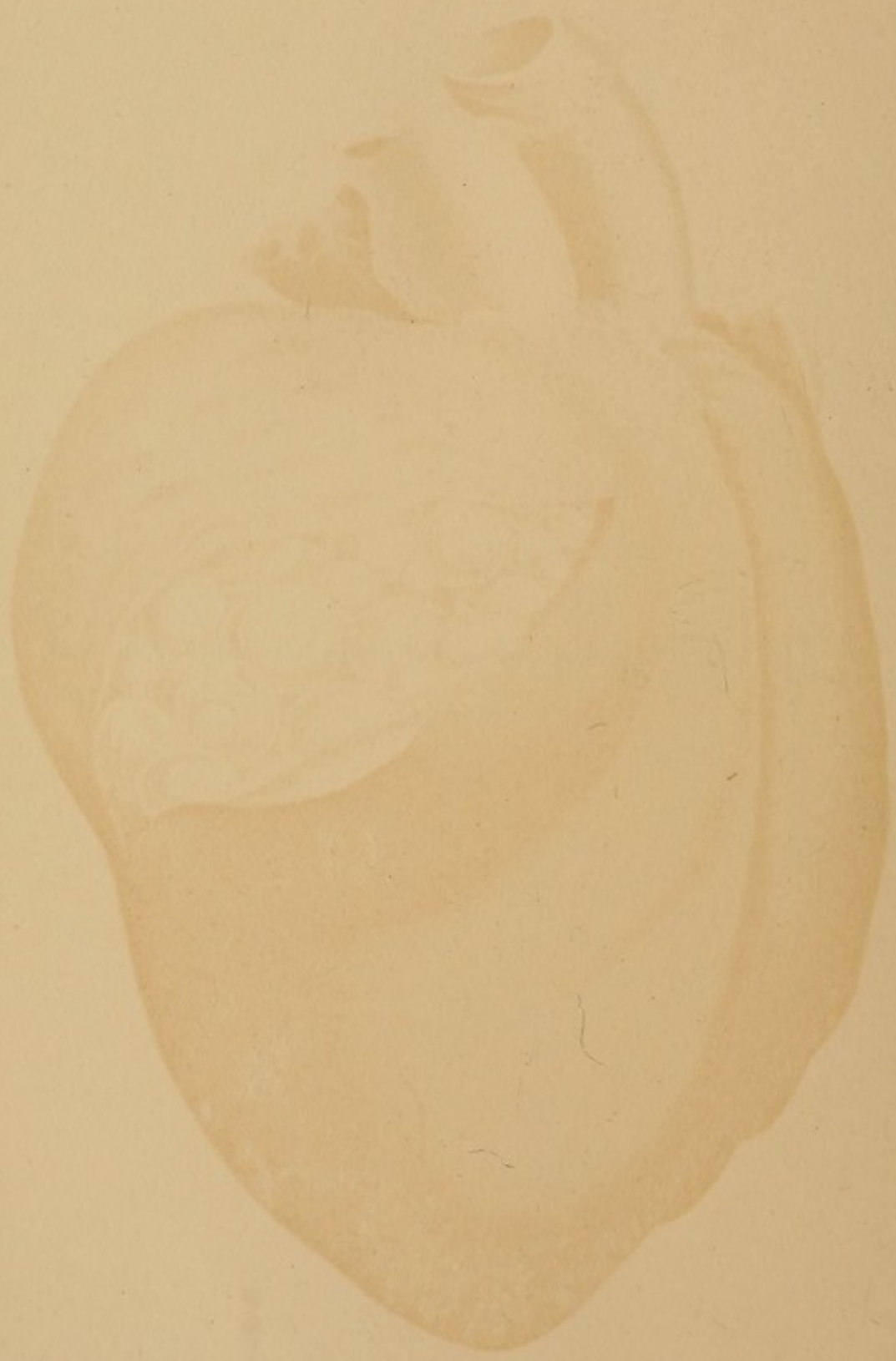


PLATE XXXI.—Hydatid tumour in the wall of the left auricle of the heart showing daughter-cysts *in situ*.

1888 11 11



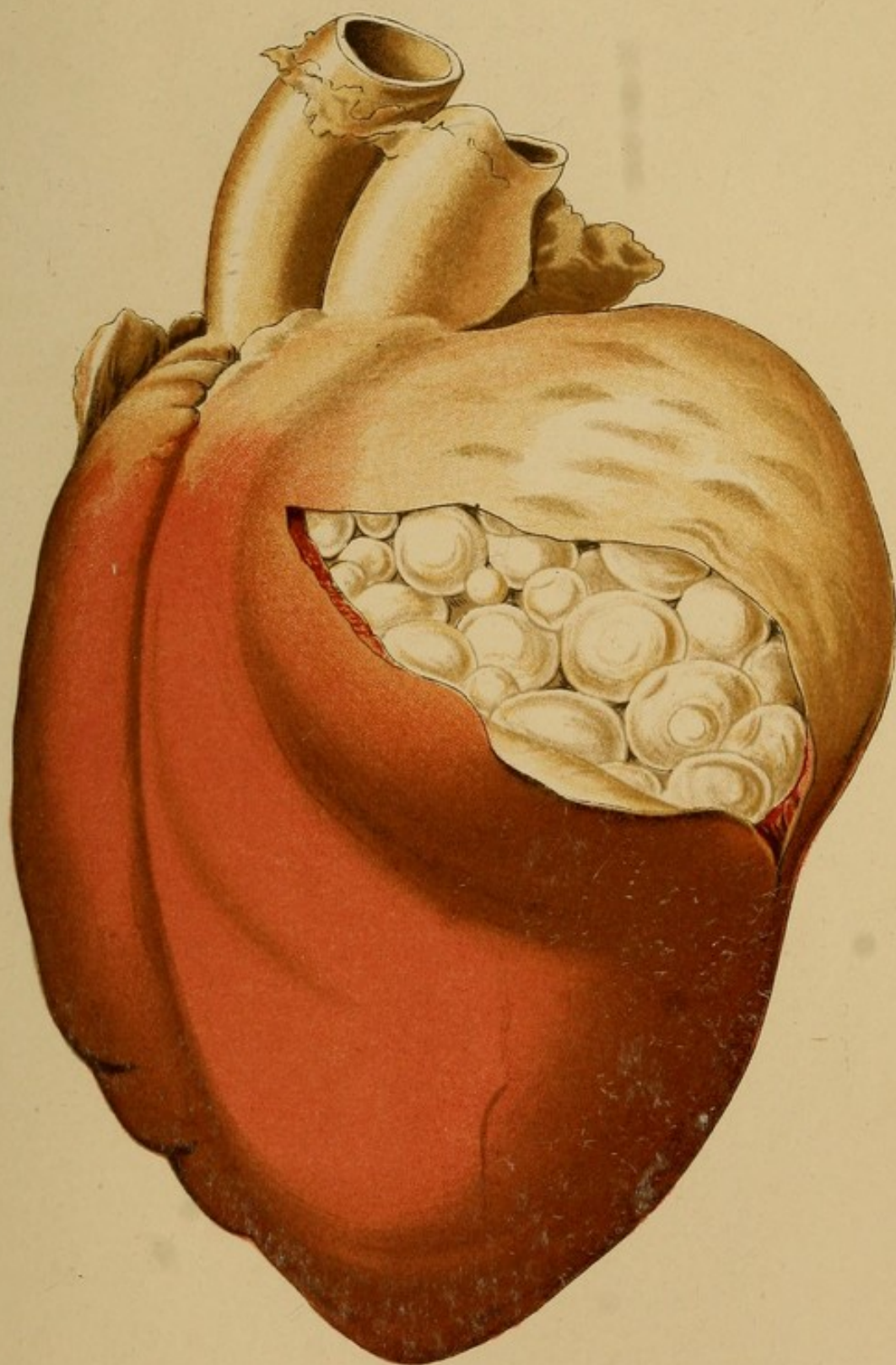

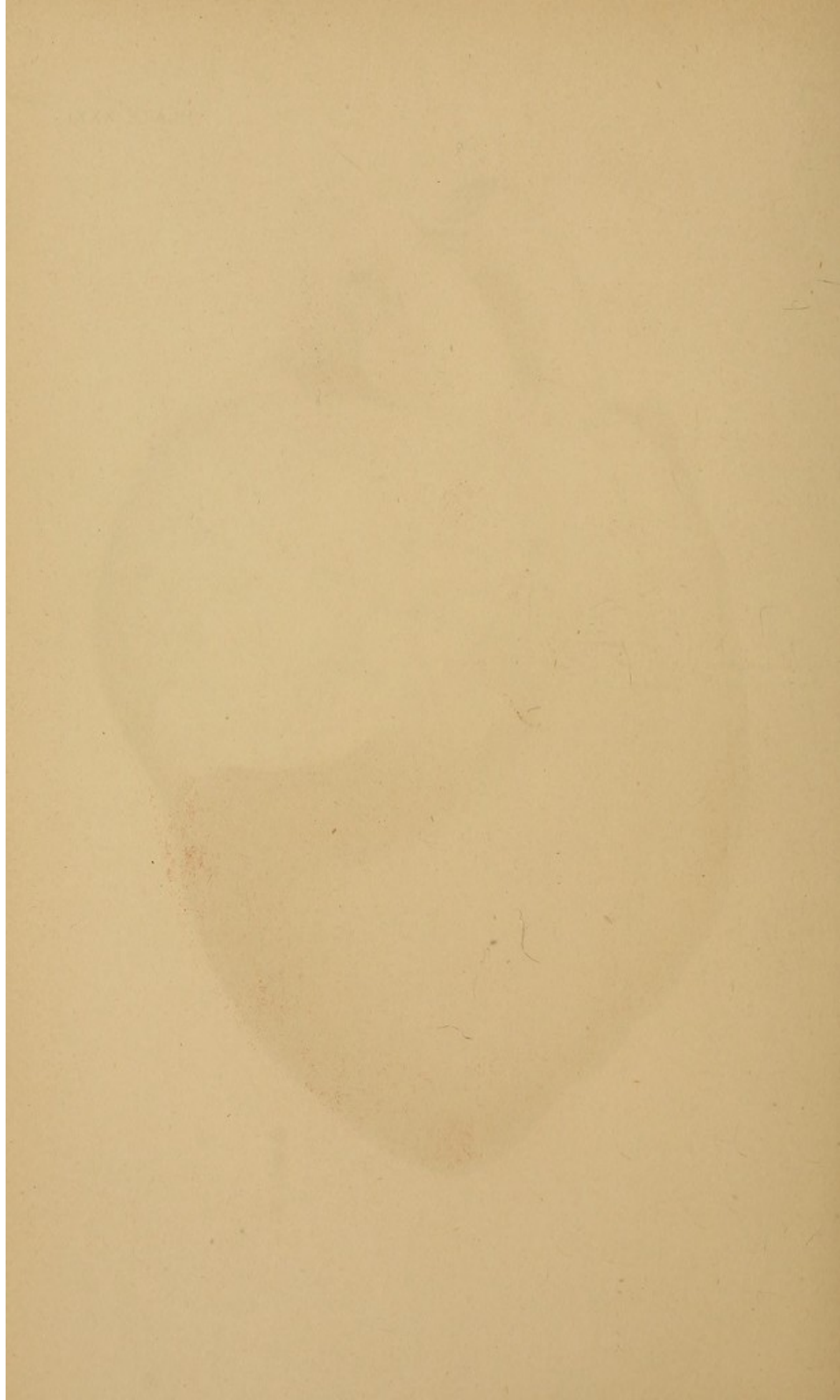


PLATE XXXII.—Hydatid of humerus. The medullary cavity filled with small daughter-cysts; the upper and lower portions of the shaft are distended and the bone partly absorbed.

1877

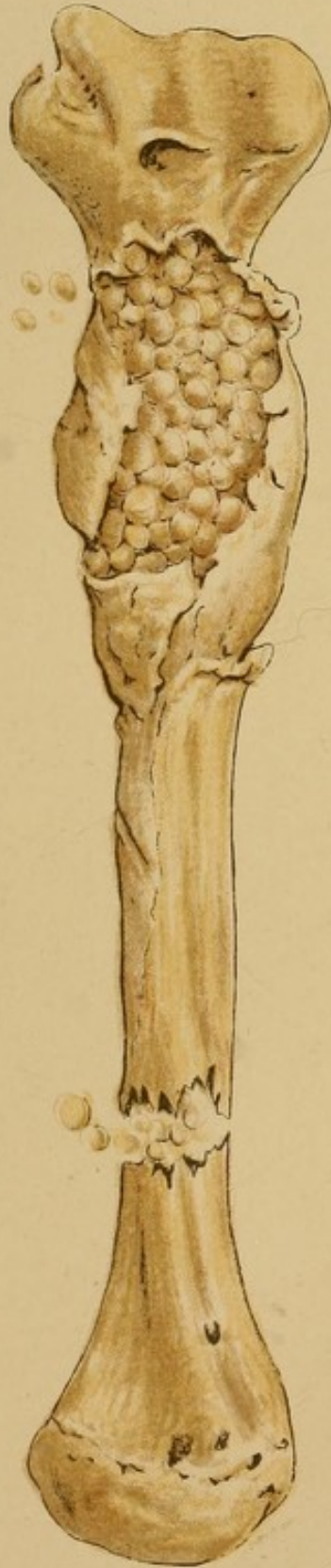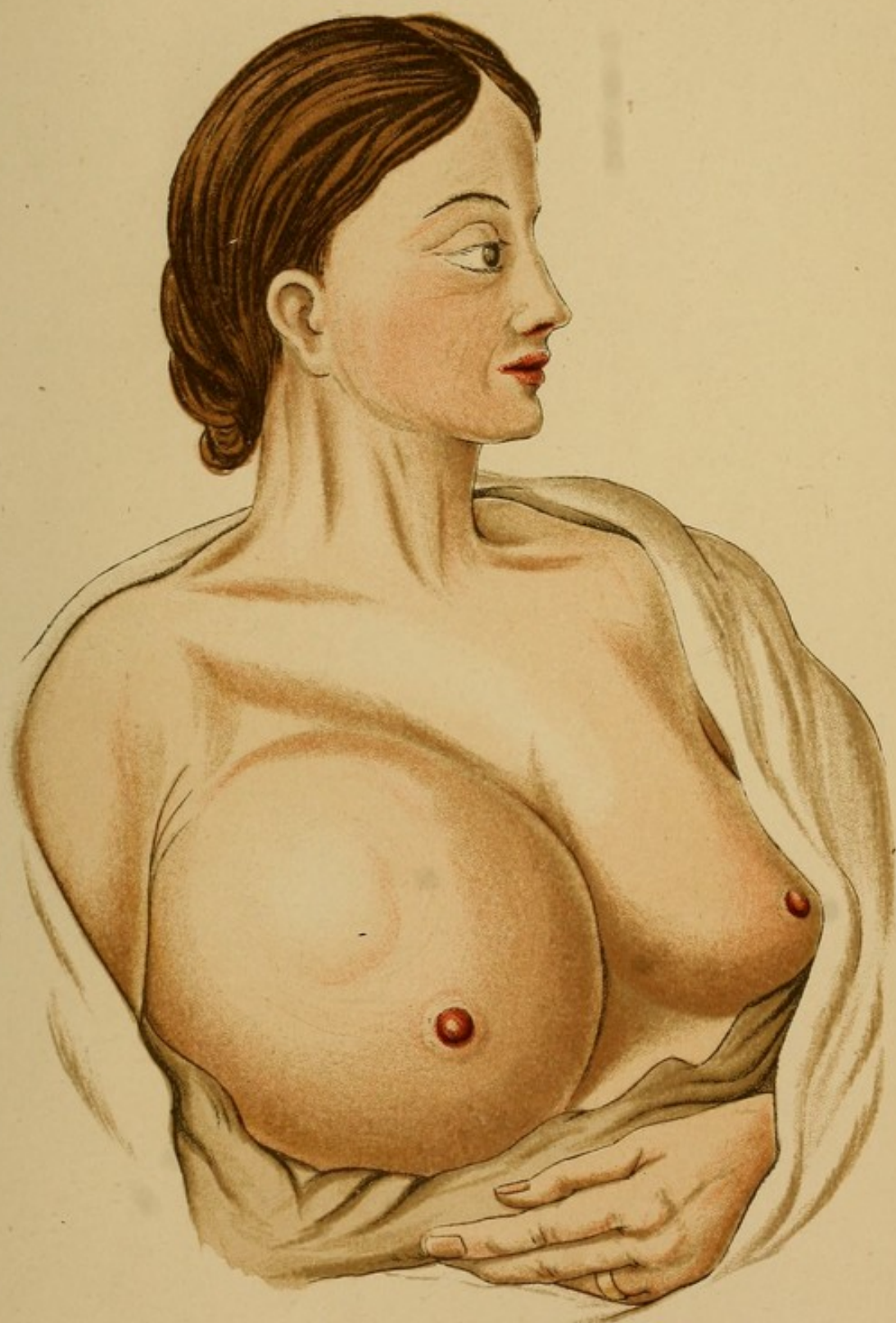


PLATE XXXII

PLATE XXXIII.—Hydatid tumour of the right breast, the cyst bulges at its upper and axillary margin, over which the skin is stretched.

PLATE XXXII






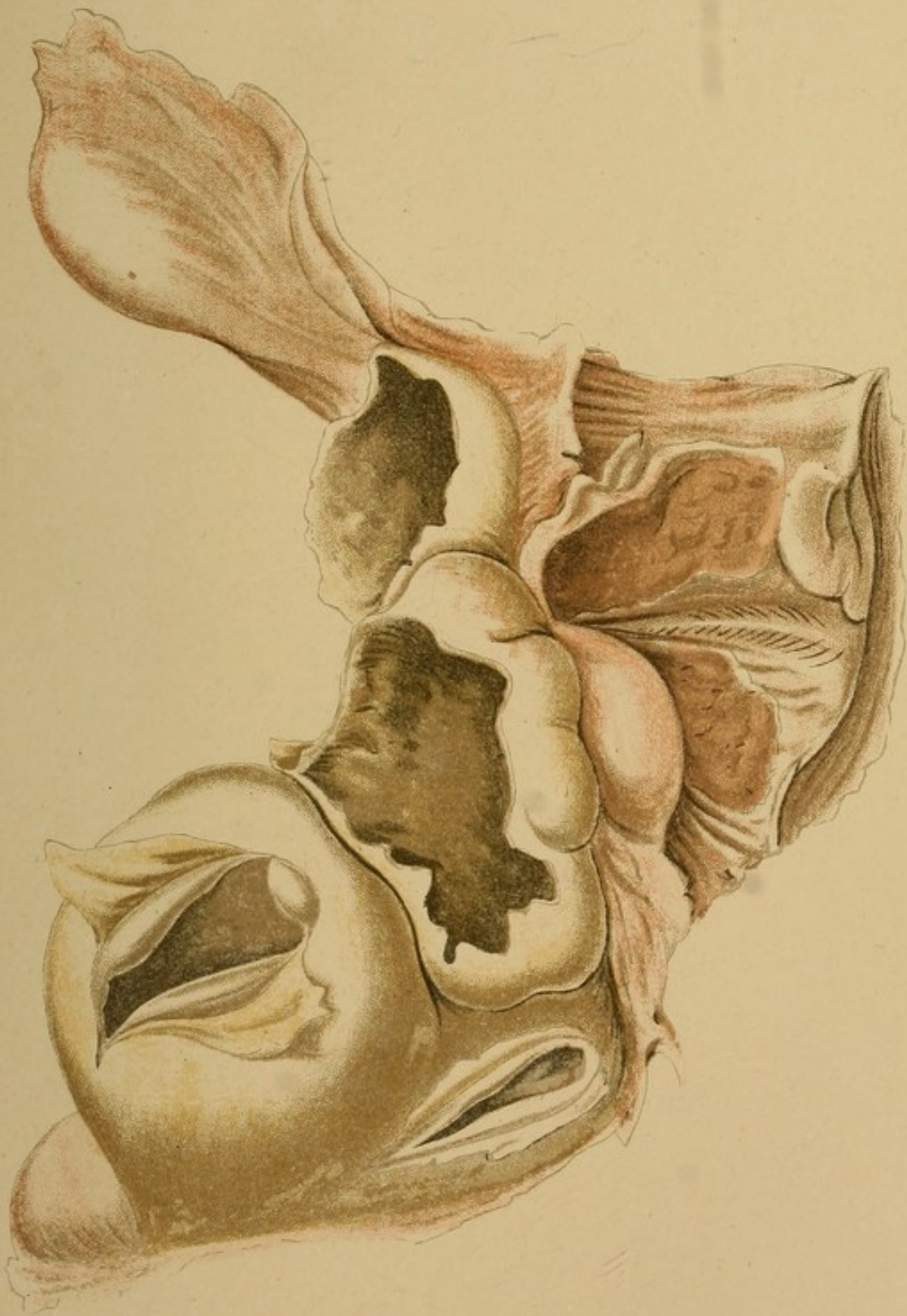



PLATE XXXIV.—Hydatid in the broad ligament. Two others which contained pus are shown lying in the fundus of the uterus.

PLATE 37





GENERAL INDEX.

	PAGE		PAGE
Abdomen, Hydatid disease of,	66, 108, 159	Clinical notes of cases of pulmonary	
Abyssinians, infested by <i>Tænia</i>		hydatids,	101, 106
<i>Saginata</i> ,	21	,, of cases of hydatids	
Acephalocyst,	52	in brain,	113, 121
Acute Cestodic Tuberculosis,	15	,, (various),	173, 195
Alternation of Generations,	7, 8	Clubbing of fingers,	100
<i>Ascaris</i> , infesting West Indian		Cochin China Diarrhoea,	17
negroes,	21	<i>Cœnurus</i> ,	86
,, Ova of,	9	Colours of Hydatid Fluid,	75, 76
,, Tenacity of life of,	9	Convulsions in Hydatid of Brain,	
Ascitic Fluid,	75	112 114, 116, 117	
Aspiration as an aid to diagnosis,	155, 158	Cough accompanying Hydatid of	
,, Cases of, 67, 69, 81, 88,		Lung,	67, 101, 104, 116, 186, 194
103, 106, 128, 150,		Cutis Anserina,	77
151, 155, 175, 178, 195		<i>Cysticercus Tenuicollis</i> ,	17
,, Statistics of,	157	Daughter Cysts, Development of,	57, 58
Aspirator, Objections to use of,	147, 155	,, Function of,	24
Atmosphere as a source of parasitic		,, Passing per anum,	93
infection,	25	,, ,, per urethram,	125
<i>Anguillulidæ</i> ,	6	,, ,, undergoing De-	
Auscultation in diagnosis of		generation,	175
hydatid of lung,	99	Diagnosis of Hydatid Disease,	67, 70, 71, 99
Australia particularly subject to		Diarrhoea, Cochin China,	17
hydatid disease,	26, 30	Diathesis Verminosa,	3
,, Preponderance of males		Differential Diagnosis,	100, 127
subjects of hydatid		<i>Distomidæ</i> ,	7
disease in,	72	<i>Distomum Hæmatobium</i>	14
Bladder Cysts, Development of		,, Hepaticum,	9
<i>Echinococcus</i> ova into,	23	Dog, as a Transmitter of Parasites,	17, 24, 72
,, Worms and tape worms,		<i>Echinococcus</i> ,	
Identity of,	8	,, <i>Altricipariens</i> ,	22, 35
Blindness in hydatid of brain,	111, 115	,, Bladder,	23, 24
<i>Bothriocephalus cordatus</i> , mode of		,, Definition of,	22
introduction into man,	19	,, Description of,	22
,, <i>latus</i> ,	10	,, Development of,	22, 25
,, ,, in regard to health		,, Eggs,	25
of host,	16	,, Endogena,	57, 58
,, ,, transferred to man		,, Etymology of term,	22
by the pike,	19	,, Exogena,	57, 58
,, ,, <i>solidus</i> ,	6	,, Granulosus,	57
Bromide of potash in treatment of		,, <i>Hominis</i> ,	40, 51
hydatid disease,	143, 144		
Burâtis, infested by intestinal worms,	21		

	PAGE		PAGE
Echinococcus, Life History of,	22	Helminthiasis,	31
" Multilocularis,	62, 64, 65	Hemiplegia as a symptom of Hydatid of Brain,	111, 112
" " Degenerative changes,	63	Hydatid,	22
" " Description of,	62	" Cyst,	42
" " Development of,	63	" " Absorbing bones of Cranium,	110
" " in Man,	62	" " behind the Cæcum,	90
" " in the Ox	62	" " causing destruction of Ribs,	131
" " Tendency to ulceration,	63	" " Contents passing by Expectoration, 127, 142, 184, 194	125
" Racemosus,	64	" " " per urethram,	125
" Scolicipariens,	51	" " Degeneration of,	48
" Veterinorum,	40, 51	" " Description of,	42
Ectocyst, Development of,	13	" " Growth of,	47
Endemic occurrence of Parasites,	21	" " in Abdomen, 56, 66, 70, 78, 108, 109, 159, 175, 189, 192	139
Endocyst,	44	" " Axilla,	130
Entozoa,	5, 6, 7	" " Bone,	130
" Animals feeding on Ova of,	10	" " Brain, 68, 111, 113, 115, 117, 119, 144	138
" Development of Eggs of,	9	" " Breast,	131
Environment as a Factor in the Distribution of Parasites,	20, 21	" " Cervical Vertebra,	72, 73
Erythema, following Tapping,	78	" " Children,	132
Esquimaux infested by Intestinal Worms,	21	" " Distal phalanx of index finger,	90
Expectant Treatment,	142	" " Douglas' Pouch,	67, 140, 141
Expectoration, 101, 102, 104, 127, 142, 167, 184, 194	142, 167, 184, 194	" " Eye,	130, 131, 132
Exploratory Puncture,	70	" " Femur,	92
" " Altering charac- ter of Hydatid Fluid,	74, 143	" " Gall bladder,	68, 134, 136
" " as an aid to diag- nosis,	155, 158, 188	" " Heart,	130
" " Diagnosis posi- tively estab- lished by,	70	" " Humerus,	75, 124
" " Fatal Cases of, 82, 84, 95, 148, 149, 159	82, 84, 95, 148, 149, 159	" " Kidney,	125
Female Subjects of Hydatid Disease, Preponderance of,	72	" " Diagnosis of,	125
Filaria Bancrofti,	9	" " Symptoms of,	131, 132
Food as a Medium of Parasitic Infection,	18, 19, 25	" " Knee joint,	70
Frontal Headache in Hydatid of Brain,	111, 113	" " Leg,	46
Gastric Juice, Action on Ova of Parasites,	12, 18, 23, 26, 94	" " Length of life, with,	46
Germany, Females particularly sub- ject to Hydatid Disease in,	72	" " Limits of growth,	48, 67, 68, 75, 78, 82, 90
Glioma in the Cerebellum,	118	" " Liver,	25, 49, 94
Hæmaturia, induced by Distomum Hæmatobium,	14	" " Lung,	100
Hæmoptysis a sign of Hydatid of Lung,	67, 100, 101, 104, 186	" " Differential diagnosis of,	99
Headache as a sign of Hydatid of Brain,	111, 113, 116, 117, 118	" " Physical signs of,	89
		" " Statistics of,	48
		" " Lung of a Dromedary,	107
		" " Mesentery,	92
		" " Mucous Membrane,	86, 88, 90,
		" " Omentum,	107, 108, 109, 193
		" " Orbit,	140
		" " Os ilium,	131
		" " Ovary,	137
		" " Ox,	62
		" " Pancreas,	128
		" " passed per Urethram, 68, 142	128

	PAGE		PAGE
Hydatid Cyst (<i>continued</i>)—		Inspection as a means of Diagnosis of Hydatid of Lung,	99
" " Peritoneum, 85, 88, 107, 108, 126		Iodide of Potash in the Treatment of Hydatid Disease,	143, 144
" " Pigs, 42, 47, 90, 91		Jaundice resulting from Pressure of Tumour on Bile Ducts,	67
" " Pleura, 101		Kamala in the Treatment of Hydatid Disease,	142, 143, 144
" " Pulmonary Artery, 135		Lindemann's Operation described, 161, 165	
" " Racemose form of, 64		Liver Fluke of Sheep, 6, 33	
" " Recto-vesical Pouch, 107		" Hydatid Disease of, 90	
" " Scrotum, 108		" Multiple Cysts in, 155	
" " Spinal Cord, 122, 123		" Plague, 29	
" " Spleen, 78, 82, 90, 127, 128, 157, 159		" Principal Seat of Origin of Hydatids, 89	
" " Spontaneous cure of, 50, 102, 104, 105, 111		Local Occurrence of Parasites, 21	
" " Statistics of, 110		Lung, Hydatids in, 94	
" " Symptoms of, 111, 127		Measly Pork, 17	
" " Thorax, 71		Mensuration as a means of Diagnosis of Hydatid of Lung, 99	
" " Tibia, 132		Mode of Life as a Factor in the Distribution of Parasites, 20	
" " Treatment of, 113		Multiple Cysts, 28, 85, 86, 90, 97, 124, 155	
" " under the Ribs, 67		" " in Brain, 110	
" " Uterus, 108, 136		" " Kidney, 155	
" " Variety in number and size, 24		" " Liver, 155	
" " Vermiform appendix, 92		" " Lung, 97	
" " Voided per anum, 92, 93, 142		" " Mesenteric Coat of small Intestine, 90	
" " Wide distribution in Human Body, 88		" " Peritoneum, 90, 107	
" " Disease, 24, 25, 26, 29, 30, 113		" " Naunyn and Rasmussen's Theory of Origin, 85	
" " Diagnosis of, 67, 70, 75, 93, 119, 125		" " Origin of, 85	
" " Dog as a source of, 24, 25		Myelitis, Case of, 122	
" " Popular ignorance of nature and cause, 28		Nematodes, 9	
" " Statistics of cases of, 30		Oxalic Acid in Hydatids, 75	
" " Symptoms of, 66, 67, 68		Oxyuris, 6, 11	
" " Fluid, altered by Exploratory Puncture, 74, 143, 151		Palpation as a means of Diagnosis of Hydatid of Lung, 99	
" " as a Diagnostic of region of origin of growth, 75		Parasites, Development of Eggs of, 9	
" " as a Poison, 82, 83, 84		" Endemic occurrence of, 21	
" " Composition of, 74		" Environment as a Factor in the Distribution of, 20, 21	
" " Experiments with, 79, 80, 81		" Local occurrence of, 21	
" " Passed per sputum, 101, 102		" Mode of Introduction into Man, 18	
" " Table of Constituents of Normal, 76		" Mode of Life as a Factor in the Distribution of, 20	
" " Various colours of, 75			
" " Rash, 77, 149, 180, 189			
" " Accompanied by Cutis Anserina, 77			
" " Conditions accompanying, 77			
" " Tremor, 71			
Iceland particularly subject to Hydatid Disease, 26, 29, 32, 72			
Incurvature of Nails a Sign of Hydatid of Lung, 100			

	PAGE		PAGE
Parasites, Number of Forms described,	1	Strongylus Causing suppression of urine,	14
„ Origin of,	4	Tænia Cœnurus,	86
„ Predisposition to,	3	„ „ development of,	12
„ Supposed good Effects of,	3	Tænia Echinococcus,	22, 28, 34
„ Theories regarding,	1, 21	„ „ Adaptability to Environment,	11
Parovarian cyst, resemblance of contents to Hydatid Fluid,	75	„ „ Anatomy of,	35
Pentastomum Denticulaturus in the dog,	17	„ „ in the Dog, 17, 22, 34, 38, 39, 41	
Percussion as a means of diagnosis of Hydatid of Lung,	99	„ „ in Man, 28, 34, 35	
Phosphates, Triple, in Hydatid Fluid, as a means of diagnosing seat of growth,	75	„ „ Length of Life,	38
Physical signs of Hydatid of Lung, 99, 100		„ Embryos in Blood,	11
Planarian,	6	„ Marginata, Experiments on Lambs with,	15
Pleurisy with effusion causing difficulty of diagnosis,	100	„ Saginata,	16
Preponderance of female subjects of Hydatid Disease,	72	„ „ infesting Abyssinians,	21
„ of male subjects of Hydatid Disease in Australia,	72	„ Serrata, Experiments on Rabbits with,	18
Prince Alfred Hospital, Sydney,	30	„ Solium,	18, 20
Pulmonary Hydatids,	25, 84, 94, 106	Tapeworm, Common,	17, 18, 20
„ „ Clinical notes on cases of, 101, 106		„ Embryo of,	7
Pyrexia, as a sign of ruptured cyst of Lung,	100	„ Experiments on Rabbits,	16
Recamier's operation,	161, 172, 192, 193	„ Freshwater,	5
„ „ Statistics of mortality from, 172		„ and Bladder Worms, Identity of,	8
Rhabditis Stercoralis,	17	Tapping as a remedy for Hydatid Cysts,	146
Risus Sardonicus, expression of, caused by Hydatid of Brain,	116	Temperature as a means of Diagnosis of Hydatid of Lung	99
Salts of mercury in the treatment of Hydatid Disease,	144	Treatment of Hydatid Disease, Bromide of Potash in, 143, 144	
Savage races specially subject to intestinal worms,	21	„ Carbohc Acid in,	171
Schistocephalus,	6	„ Corrosive Sublimate in,	171
Simon's operation described,	161, 163	„ Direct Incision in,	163
„ „ objectionable features of, 162		„ Electricity in, 146, 169, 170	
„ „ Statistics of mortality from, 163		„ Exploratory Puncture in,	
Statistics of Hydatids treated by carbolic acid, 171		„ Extract of Male Fern and Liquor Potassæ in,	171
„ „ corrosive sublimate, 171		„ Faradism in,	170
„ „ iodine,	171	„ Free Incision in,	70, 96
„ „ injection of bile, 171		„ Galvanism in,	170
Strongylus Gigas,	9	„ Injection of Bile in,	171
		„ Iodide of Potash in, 143, 144	
		„ Iodine in,	171
		„ Kamala in,	142, 143, 144
		„ Lindemann's Operation, 161	
		„ Permanganate of Potash in,	171
		„ Recamier's Operation, 161, 172, 192, 193	
		„ Salts of Mercury in,	144
		„ Simon's Operation in, 161, 163	


	PAGE		PAGE
Treatment of Hydatid Disease (<i>continued</i>)—		Uric acid in Hydatid Fluid as a	
" Tapping in,	78, 82	means of diagnosing seat of	
" Turpentine in,	143, 144	growth,	75
" Volkmann's Operation		Urine, suppression of,	14
in,	165	Urticaria-like Eruption following	
Trephining, cases of,	115, 119	Tapping,	77, 78, 82, 180, 189
Trichina Spiralis,	11, 17, 21		
" Birth of Embryos		Vegetables a source of Parasitic	
of,	18	Infection,	19, 25, 33
" Destruction wrought		Vertigo a symptom of Hydatid of	
by Embryos of,	14	Brain,	111
" Ova of,	8	Victoria Central Board of Health	
Trichinous Flesh not rendered		on the Dog Nuisance,	32
innocuous by boiling,	19	Volkmann's Operation,	165
Triple Phosphates in Hydatid		Vomiting as a symptom of Hydatid	
Fluid as a means of Diagnosing		of Brain	111, 113, 115, 118
seat of growth,	75		
Tuberculosis, Acute Cestodic,	15	West Indian Negroes infested by	
Turpentine in the treatment of		Ascaris,	21
Hydatid Disease,	143, 144		

INDEX OF AUTHORS.

	PAGE		PAGE
Abildgaard,	3	Gosse,	140
Allen,	117, 135	Göze,	3
Anderson, McCall,	81, 82	Hawkins,	117
Andral,	95	Hearn,	100
Annand,	123	Heckford,	143
Barker,	75	Heintz,	74
Barrier,	46	Helm,	59
Bartels,	93	Hicks,	97, 135
Beneden, Van,	39	Hill,	136
Berthold,	48	Hjaltelin,	142
Bird, 25, 94, 97, 98, 99, 100, 134, 143, 147		Hoffmann,	5
Boerhaave,	5	Huber,	62, 125
Bouvier,	98	Hind,	154
Braun,	19	Humphry,	82
Bremser,	3, 58	Hutchinson, J.,	159
Briancor,	71	Huxley,	44, 55
Bright,	108	Jenkins,	118
Brodribb,	134	Jördens,	3
Bryant,	82	Kelly,	50
Budd,	46	Krabbe,	40, 41
Buhl,	62	Kuchenmeister, 8, 18, 34, 39, 40, 51, 85	
Carrière,	62	Kuhn,	57, 64
Chisholm,	119	Laennec,	52
Clubbe,	138	Landau,	131
Cobbold,	28, 34, 92, 117, 123, 131	Leacock,	130
Coppinger,	130	Leisering,	15, 41
Davaine,	35, 92, 144	Leuckart, 9, 14, 15, 16, 18, 19, 21, 31, 34, 36, 39, 40, 42, 54, 55, 59, 60, 64, 65, 72, 85, 91, 130	
Dupuytren,	95, 130	Levison,	40
Eschricht,	7, 16, 60	Limpéropoulo,	95
Fagge, Hilton,	46, 83, 153	Linné,	6
Finsen,	72, 89	Luschka,	63
Fitzgerald,	147, 150	Macgillivray, Dr., 78, 96, 108, 139, 140, 142, 147, 151	
Frerichs,	93	Martin,	137
Gairdner,	101	Martineau,	84
Gardner,	145, 158	Mehlis,	5
Gee,	111	Morrison,	78, 172
Geoffrey,	95		

INDEX OF AUTHORS.

	PAGE		PAGE
Mosler,	15	Siebold, Von,	7, 38, 39, 40, 53, 58
Munro,	115	Steenstrup,	7
Muskett,	108, 139	Sterling,	135
Naunyn, 39, 40, 41, 44, 54, 55, 58,		Swammerdam,	5
	59, 74, 85	Thomas, Davies, 26, 27, 72, 76,	
Neisser,	72, 89	78, 82, 84, 89, 101, 110, 131, 143,	
Nettleship,	39		145, 156, 158
Ogle,	131	Thorstensen,	72
Pagenstecher,	39	Travers,	132
Paget,	127	Velpeau,	46
Pallas,	6, 7	Vercò,	77, 107, 151
Panceri,	34	Vidal,	78
Peacock,	97, 135	Virchow,	62, 63, 65
Pedkoff,	122	Vix,	20
Prougeansky, Marie,	62, 63	Wagener,	58
Quain's <i>Dictionary of Medicine</i> ,	32	Watson, Sir Thomas,	50
Rasmussen,	54, 58, 85	Westphal,	112
Redi,	5	White, Hale,	110
Rendorf,	111	Wilson,	97
Reynal,	46	Wunderlich,	90
Roy,	79, 80	Zeller, Von,	62
Rudolphi,	22, 51	Zenker,	39, 40
		Ziemssen,	91, 92, 93, 125



YOUNG J. PENTLAND'S PUBLICATIONS.

18mo, Cloth limp, pp. xii., 120, Price 3s.

SYNOPSIS OF THERAPEUTICS

ARRANGED FOR THE USE OF PRESCRIBERS:

WITH POSOLOGICAL TABLE AND AN ARRANGEMENT OF THE POISONS.

By R. S. AITCHISON, M.B., EDIN.

(1886.)

8vo, Cloth, pp. x., 220, with 9 illustrations, Price 7s. 6d.

THE TREATMENT OF EPILEPSY,

By WILLIAM ALEXANDER, M.D., F.R.C.S.,

HONORARY SURGEON, ROYAL SOUTHERN HOSPITAL, LIVERPOOL; VISITING SURGEON,
LIVERPOOL WORKHOUSE HOSPITAL; ACTING HONORARY CONSULTING
SURGEON, EPILEPTIC INSTITUTION, MANOR HOUSE, MAGHULL.

(1889.)

For Sale by Subscription only.

*In Three handsome volumes, Royal 8vo, containing about 1000 pages each,
with fully 1700 elaborate Illustrations, Price 30s. per volume nett.*

THE AMERICAN SYSTEM OF DENTISTRY,

IN TREATISES BY VARIOUS AUTHORS.

EDITED BY WILBUR F. LITCH, M.D., D.D.S.,

PROFESSOR OF PROSTHETIC DENTISTRY, THERAPEUTICS, AND MATERIA MEDICA,
IN THE PENNSYLVANIA COLLEGE OF DENTAL SURGERY, PHILADELPHIA.

For Sale by Subscription only. Re-issue in Monthly Volumes

To be re-issued in 8 very handsome volumes, Royal 8vo, Cloth, of about 400 pages each, fully illustrated with Engravings and Coloured Plates, Price 12s. 6d. each, nett.

SYSTEM OF
GYNECOLOGY & OBSTETRICS,
BY AMERICAN AUTHORS.

EDITED BY MATTHEW D. MANN, A.M., M.D.,

PROFESSOR OF OBSTETRICS AND GYNECOLOGY IN THE MEDICAL DEPARTMENT
OF THE UNIVERSITY OF BUFFALO, N.Y.

AND

BARTON COOKE HIRST, M.D.,

ASSOCIATE PROFESSOR OF OBSTETRICS IN THE UNIVERSITY OF PENNSYLVANIA;
OBSTETRICIAN TO THE PHILADELPHIA MATERNITY HOSPITALS;
GYNECOLOGIST TO THE ORTHOPÆDIC HOSPITAL.

Large 8vo, Cloth pp. viii., 325, Price 12s. 6d.

CLINICAL STUDIES ON
DISEASES OF THE EYE,

*Including those of the Conjunctiva, Cornea, Sclerotic, Iris,
and Ciliary Body.*

BY DR. F. RITTER VON ARLT,

PROFESSOR OF OPHTHALMOLOGY IN VIENNA.

TRANSLATED BY DR. LYMAN WARE,

SURGEON TO THE ILLINOIS CHARITABLE EYE AND EAR INFIRMARY; OPHTHALMIC
SURGEON TO THE PRESBYTERIAN HOSPITAL, AND TO THE
PROTESTANT ORPHAN ASYLUM, CHICAGO.

(1885.)

*8vo, Cloth, pp. viii., 374, with 408 Illustrations, finely engraved on Wood,
and 4 analytical tables, new and Cheaper Edition, Price 5s.*

TEXT-BOOK OF
GENERAL BOTANY

BY DR. W. J. BEHRENS.

TRANSLATION FROM THE SECOND GERMAN EDITION.

REVISED BY PATRICK GEDDES, F.R.S.E.

PROFESSOR OF BOTANY IN THE UNIVERSITY OF DUNDEE.

(1891.)

Second Edition, 8vo, Cloth, pp. xvi., 420, Price 14s.

SUGGESTIVE THERAPEUTICS

*A TREATISE ON THE NATURE AND USES
OF HYPNOTISM.*

By H. BERNHEIM, M.D.,

PROFESSOR IN THE FACULTY OF MEDICINE AT NANCY.

TRANSLATED FROM THE SECOND AND REVISED EDITION

By CHRISTIAN A. HERTER, M.D.,

OF NEW YORK.

(1890.)

*8vo, Cloth, gilt top, pp. xx., 678, illustrated with a large series of Coloured
Plates from original drawings, Price 25s.*

DISEASES OF THE EYE.

*A PRACTICAL TREATISE FOR STUDENTS
OF OPHTHALMOLOGY.*

By GEORGE A. BERRY, M.B., F.R.C.S.ED.,

OPHTHALMIC SURGEON, EDINBURGH ROYAL INFIRMARY; SENIOR SURGEON,
EDINBURGH EYE DISPENSARY; LECTURER ON OPHTHALMOLOGY,
ROYAL COLLEGE OF SURGEONS, EDINBURGH.

(Pentland's Medical Series—Volume Second.)

(1889.)

Crown 8vo, Cloth, pp. xii., 83, Price 3s. 6d.

THE ELEMENTS OF OPHTHALMOSCOPIC DIAGNOSIS.

*FOR THE USE OF STUDENTS ATTENDING
OPHTHALMIC PRACTICE.*

By GEORGE A. BERRY, M.B., F.R.C.S.ED.,

OPHTHALMIC SURGEON, EDINBURGH ROYAL INFIRMARY; LECTURER ON
OPHTHALMOLOGY, ROYAL COLLEGE OF SURGEONS, EDINBURGH.

(1891.)

*In two very handsome Imperial 8vo volumes, containing about 1600 pages,
Price 50s. nett.*

THE NATIONAL MEDICAL DICTIONARY

Including English, French, German, Italian, and Latin Technical Terms
used in Medicine and the Collateral Sciences, and a Series of
Tables of useful data.

By JOHN S. BILLINGS, A.M., M.D.,
LL.D., HARV. and EDIN., D.C.L., OXON.,

MEMBER OF THE NATIONAL ACADEMY OF SCIENCES, SURGEON, U.S.A., ETC.

WITH THE COLLABORATION OF

W. O. ATWATER, M.D.	JAMES M. FLINT, M.D.	S. M. BURNETT, M.D.	H. C. YARROW, M.D.
FRANK BAKER, M.D.	R. LORINI, M.D.	J. H. KIDDER, M.D.	WILLIAM LEE, M.D.
C. S. MINOT, M.D.	WASHINGTON MATTHEWS, M.D.	W. E. COUNCILMAN, M.D.	

(1890.)

*Large 8vo, Cloth, pp. xvi., 783, Price 25s. Illustrated with 226 Wood
Engravings, and 68 pages of Lithograph Plates, exhibiting
91 Figures—317 Illustrations in all.*

DISEASES OF THE HEART AND THORACIC AORTA.

By BYROM BRAMWELL, M.D., F.R.C.P.ED.,

LECTURER ON THE PRINCIPLES AND PRACTICE OF MEDICINE, AND ON PRACTICAL MEDICINE
AND MEDICAL DIAGNOSIS, IN THE EXTRA-ACADEMICAL SCHOOL OF MEDICINE,
EDINBURGH; ASSISTANT PHYSICIAN, EDINBURGH ROYAL INFIRMARY.

(1884.)

*Second Edition, Revised and Enlarged, 8vo, Cloth, pp. xvi., 360, illustrated
with Wood Engravings and 53 pages of Lithograph Plates printed
in Colours—183 Illustrations in all, Price 16s.*

DISEASES OF THE SPINAL CORD.

By BYROM BRAMWELL, M.D., F.R.C.P.ED.,

LECTURER ON THE PRINCIPLES AND PRACTICE OF MEDICINE IN THE EXTRA-ACADEMICAL
SCHOOL OF MEDICINE, EDINBURGH; ASSISTANT PHYSICIAN TO THE
EDINBURGH ROYAL INFIRMARY.

(1884.)

8vo, Cloth, pp. xvi., 270, with 116 Illustrations, Price 14s.

INTRACRANIAL TUMOURS.

BY BYROM BRAMWELL, M.D., F.R.C.P.ED.,

LECTURER ON THE PRINCIPLES AND PRACTICE OF MEDICINE IN THE EXTRA-ACADEMICAL
SCHOOL OF MEDICINE, EDINBURGH; ASSISTANT PHYSICIAN TO THE
EDINBURGH ROYAL INFIRMARY.

(1888.)

Large 8vo, Cloth, pp. 150, with 41 Illustrations, Price 4s. 6d.

PRACTICAL MEDICINE AND MEDICAL DIAGNOSIS.

*METHODS OF DIAGNOSIS—CASE-TAKING AND CASE-
RECORDING—MEDICAL THERMOMETRY.*

BY BYROM BRAMWELL, M.D., F.R.C.P.ED.,

LECTURER ON THE PRINCIPLES AND PRACTICE OF MEDICINE, AND ON PRACTICAL MEDICINE
AND MEDICAL DIAGNOSIS, IN THE EXTRA-ACADEMICAL SCHOOL OF MEDICINE,
EDINBURGH; ASSISTANT PHYSICIAN, EDINBURGH ROYAL INFIRMARY.

(1887.)

8vo, Cloth, pp. viii., 72, with 4 Illustrations, Price 3s. 6d.

THE TREATMENT OF PLEURISY AND EMPYEMA.

BY BYROM BRAMWELL, M.D., F.R.C.P.ED., F.R.S.E.,

LECTURER ON THE PRINCIPLES AND PRACTICE OF MEDICINE IN THE EXTRA-ACADEMICAL
SCHOOL OF MEDICINE; ASSISTANT PHYSICIAN TO THE
EDINBURGH ROYAL INFIRMARY.

(1889.)

In Press, to be issued in Fasciculi at intervals of Two Months.

ATLAS OF THE DISEASES OF THE SKIN,

*In a Series of Illustrations from Original Drawings with
Descriptive Letterpress.*

BY H. RADCLIFFE CROCKER, M.D., F.R.C.P.,

PHYSICIAN TO THE DEPARTMENT FOR DISEASES OF THE SKIN, UNIVERSITY COLLEGE HOSPITAL;
PHYSICIAN TO THE EAST LONDON HOSPITAL FOR CHILDREN; EXAMINER
IN MEDICINE AT APOTHECARIES' HALL, LONDON.

* * * Subscribers' Names can now be received.

In one Handsome Volume, Crown 4to, Cloth, bevelled boards, pp. xii., 344, illustrated with numerous Wood Engravings and full-page Lithograph Plates, some Coloured, Price 12s. 6d., nett.

STUDIES IN CLINICAL MEDICINE.

A Record of some of the more Interesting Cases observed, and of some of the Remarks made, at the Author's Out-Patient Clinic in the Edinburgh Royal Infirmary.

BY BYROM BRAMWELL, M.D., F.R.C.P.ED.,

ASSISTANT PHYSICIAN TO THE EDINBURGH ROYAL INFIRMARY; LECTURER ON THE PRINCIPLES AND PRACTICE OF MEDICINE IN THE EXTRA-ACADEMICAL SCHOOL OF MEDICINE, EDINBURGH.

(1890.)

Crown 8vo, Cloth, pp. 154, with 5 Illustrations, Price 4s. 6d.

DISEASES AND INJURIES OF THE EAR: THEIR PREVENTION AND CURE.

BY CHARLES HENRY BURNETT, A.M., M.D.,

AURAL SURGEON TO THE PRESBYTERIAN HOSPITAL; ONE OF THE CONSULTING AURISTS TO THE PENNSYLVANIA INSTITUTION FOR THE DEAF AND DUMB; LECTURER ON OTOTOLOGY, WOMEN'S MEDICAL COLLEGE OF PENNSYLVANIA, IN PHILADELPHIA.

(1889.)

8vo, Cloth, pp. xii., 102, with 4 Illustrations, Price 5s.

SUPPURATION AND SEPTIC DISEASES.

THREE LECTURES DELIVERED AT THE ROYAL COLLEGE OF SURGEONS OF ENGLAND.

BY W. WATSON CHEYNE, M.B., F.R.C.S.,

HUNTERIAN PROFESSOR; SURGEON TO KING'S COLLEGE HOSPITAL; EXAMINER IN SURGERY AT EDINBURGH UNIVERSITY.

(1889.)

THE "COMPEND" SERIES.

A Series of Handbooks to assist Students preparing for Examinations.

- Compend of Human Anatomy**, Including the Anatomy of the Viscera. By SAMUEL O. L. POTTER, M.A., M.D., Cooper Medical College, San Francisco. Fourth Edition, revised and enlarged, Crown 8vo, cloth, pp. 233, with 117 illustrations. Price 4s. 6d.
- Compend of the Practice of Medicine**. By DANIEL E. HUGHES, M.D., late Demonstrator of Clinical Medicine in the Jefferson Medical College of Philadelphia. Fourth Edition, revised and enlarged, Crown 8vo, cloth, pp. 328. Price 7s. 6d.
- Compend of Obstetrics**. By HENRY G. LANDIS, A.M., M.D., late Professor of Obstetrics and Diseases of Women in Starling Medical College. Third Edition, thoroughly revised, enlarged, and improved, Crown 8vo, cloth, pp. 210, with 91 illustrations. Price 4s. 6d.
- Compend of Human Physiology**. By ALBERT P. BRUBAKER, A.M., M.D., Demonstrator of Physiology in Jefferson Medical College. Fourth Edition, thoroughly revised, Crown 8vo, cloth, pp. 174, with 16 illustrations and a Table of Physiological Constants. Price 4s. 6d.
- Compend of Surgery**. By ORVILLE HORWITZ, B.S., M.D., Chief of the Outdoor Surgical Department, Jefferson Medical College Hospital. Fourth Edition, revised, Crown 8vo, cloth, pp. 118, with 17 illustrations. Price 4s. 6d.
- Compend of the Diseases of the Eye**, Including Refraction and Surgical Operations. By L. WEBSTER FOX, M.D., Ophthalmic Surgeon to the Germantown Hospital, and GEORGE M. GOULD, M.D. Second Edition, thoroughly revised, Crown 8vo, cloth, pp. 164, with 71 illustrations. Price 4s. 6d.
- Compend of Gynæcology**. By HENRY MORRIS, M.D., late Demonstrator of Obstetrics and Diseases of Women and Children, Jefferson Medical College, Philadelphia. Crown 8vo, cloth, pp. 178, with 45 illustrations. Price 4s. 6d.
- Compend of Diseases of Children**. By MARCUS P. HATFIELD, A.M., M.D., Professor of Diseases of Children, Chicago Medical College. Crown 8vo, cloth, pp. 186, with coloured plate. Price 4s. 6d.
- Compend of Equine Anatomy and Physiology**. By WILLIAM R. BALLOU, M.D., Professor of Equine Anatomy, New York College of Veterinary Surgeons. Crown 8vo, cloth, pp. 205, with 29 illustrations. Price 4s. 6d.
- Compend of Dental Pathology and Dental Medicine**. By GEO. W. WARREN, D.D.S., Clinical Chief, Pennsylvania College of Dental Surgery. Crown 8vo, cloth, pp. 109, illustrations. Price 4s. 6d.

*In 8 Vols. Royal 8vo, of about 500 pages each, Illustrated with
Wood Engravings in the Text, and numerous full-page Plates.
Price 12s. 6d., per Volume nett, Carriage Free.*

CYCLOPÆDIA
OF THE
DISEASES OF CHILDREN,
MEDICAL AND SURGICAL.

*THE ARTICLES WRITTEN ESPECIALLY FOR THE WORK BY
AMERICAN, BRITISH, AND CANADIAN AUTHORS.*

EDITED BY JOHN M. KEATING, M.D.

*** Detailed Prospectus on application.*

In press, large 8vo, illustrated with Maps and Charts.

GEOGRAPHICAL PATHOLOGY.

An inquiry into the geographical distribution of infective
and climatic diseases.

BY ANDREW DAVIDSON, M.D., F.R.C.P.ED.,

LATE VISITING AND SUPERINTENDING SURGEON, CIVIL HOSPITAL; PROFESSOR
OF CHEMISTRY, ROYAL COLLEGE, MAURITIUS.

*Foolscap 8vo, Cloth, pp. viii., 153, interleaved with plain paper,
Price 4s.*

SYNOPSIS OF CHEMISTRY,
INORGANIC AND ORGANIC,

TO ASSIST STUDENTS PREPARING FOR EXAMINATIONS.

BY THOS. W. DRINKWATER, F.C.S.,

LECTURER ON CHEMISTRY IN THE EDINBURGH SCHOOL OF MEDICINE.

(1882.)

EXAMINATION QUESTIONS

*Set for the Professional Examinations in Edinburgh University
during the past ten years, selected from the Calendars.*

By W. RAMSAY SMITH, B.Sc.,

DEMONSTRATOR OF ANATOMY, EDINBURGH SCHOOL OF MEDICINE, MINTO HOUSE;
LATE SENIOR ASSISTANT TO THE PROFESSOR OF NATURAL HISTORY,
UNIVERSITY OF EDINBURGH.

NATURAL HISTORY, arranged and annotated, price 1s.

BOTANY, arranged and annotated, price 1s. 6d.

CHEMISTRY, answered and annotated, price 2s.

ANATOMY, answered and annotated. *In press.*

* * * OTHER VOLUMES TO FOLLOW.

8vo, Cloth, pp. 54, Illustrated with 16 Coloured Maps, Price 5s.

ON THE
GEOGRAPHICAL DISTRIBUTION OF SOME
TROPICAL DISEASES AND THEIR RELATION
TO PHYSICAL PHENOMENA,

By R. W. FELKIN, M.D., F.R.S.E., F.R.G.S.,

LECTURER ON DISEASES OF THE TROPICS AND CLIMATOLOGY, SCHOOL OF
MEDICINE, EDINBURGH.

(1889.)

8vo, Cloth, pp. 84, Price 3s. 6d.

HYPNOTISM:

OR,

PSYCHO-THERAPEUTICS.

By R. W. FELKIN, M.D., F.R.S.E.,

LECTURER ON DISEASES OF THE TROPICS AND CLIMATOLOGY, SCHOOL
OF MEDICINE, EDINBURGH.

(1890.)

*Crown 8vo, Cloth, xvi., 376, with 101 Illustrations, some coloured,
Price 10s. 6d.*

PHYSICAL DIAGNOSIS,

A Guide to Methods of Clinical Investigation.

By G. A. GIBSON, M.D., D.Sc., F.R.C.P.Ed.,

LECTURER ON THE PRINCIPLES AND PRACTICE OF MEDICINE IN THE EDINBURGH MEDICAL
SCHOOL; EXAMINER ON MEDICINE AND CLINICAL MEDICINE IN THE
UNIVERSITY OF GLASGOW,

AND

WILLIAM RUSSELL, M.D., F.R.C.P.Ed.,

PATHOLOGIST TO THE ROYAL INFIRMARY OF EDINBURGH; LECTURER
ON PATHOLOGY AND MORBID ANATOMY IN THE EDINBURGH
MEDICAL SCHOOL.

(1890.)

(Pentland's Students' Manuals.)

In Press. 8vo, pp. xvi., 220, with 30 full page Coloured Plates.

HYDATID DISEASE

IN ITS CLINICAL ASPECTS,

By JAMES GRAHAM, M.A., M.D.,

LATE DEMONSTRATOR OF ANATOMY, SYDNEY UNIVERSITY; MEDICAL SUPERINTENDENT,
PRINCE ALFRED HOSPITAL, SYDNEY.

(1891.)

Large 8vo, Cloth, pp. 624. Price 16s.

A TEXT-BOOK

OF

PRACTICAL THERAPEUTICS,

WITH ESPECIAL REFERENCE TO THE

APPLICATION OF REMEDIAL MEASURES TO DISEASE AND
THEIR EMPLOYMENT UPON A RATIONAL BASIS.

By HOBART AMORY HARE, M.D. (UNIV. OF PA.), B.Sc.,

CLINICAL PROFESSOR OF THE DISEASES OF CHILDREN AND DEMONSTRATOR OF THERAPEUTICS
IN THE UNIVERSITY OF PENNSYLVANIA; PHYSICIAN TO ST. AGNES'S HOSPITAL AND
TO THE MEDICAL DISPENSARY OF THE CHILDREN'S HOSPITAL.

(1890.)

Crown 8vo, Cloth, pp. xvi., 216, with Coloured Plate and 29 Wood Engravings, Price 5s.

HANDBOOK OF OBSTETRIC NURSING,

By F. W. N. HAULTAIN, M.D., F.R.C.P.ED.,
PHYSICIAN TO THE ROYAL DISPENSARY; LATE CLINICAL ASSISTANT TO PHYSICIAN
FOR DISEASES OF WOMEN, ROYAL INFIRMARY, EDINBURGH,

AND

J. HAIG FERGUSON, M.B., F.R.C.P.ED.,
PHYSICIAN TO THE NEW TOWN DISPENSARY; LATE RESIDENT PHYSICIAN,
ROYAL MATERNITY HOSPITAL, EDINBURGH.

(1889.)

*Second Edition, Revised and Enlarged, oblong Crown 8vo, Cloth, pp. 65,
with 28 Illustrations, Price 4s.*

THE URINE AND THE COMMON POISONS,

Memoranda, Chemical and Microscopical, for Laboratory Use.

By J. W. HOLLAND, M.D.,
PROFESSOR OF MEDICAL CHEMISTRY AND TOXICOLOGY, JEFFERSON MEDICAL COLLEGE,
OF PHILADELPHIA.

(1889.)

*Volume First now ready. In 8vo, pp. 300, illustrated with numerous
full-page plates, Price 12s. 6d. nett.*

INTERNATIONAL CLINICS,

*A QUARTERLY OF CLINICAL LECTURES ON
MEDICINE AND SURGERY.*

EDITED BY

JOHN M. KEATING, M.D.,
J. P. CROZIER GRIFFITH, M.D.,
PHILADELPHIA.

J. MITCHELL BRUCE, M.D.,
DAVID FINLAY, M.D.,
LONDON*

** Volume First contains Articles by Drs. MITCHELL BRUCE (London), JAMES ROSS (Manchester), W. H. PORTER (New York), J. FINLAYSON (Glasgow), Prof. LOOMIS (New York), Prof. GAIRDNER (Glasgow), Prof. M'DONNELL (Montreal), Prof. SHATTUCK (Harvard), Mr. CHRISTOPHER HEATH (London), Prof. KEEN, Philadelphia), Mr. J. W. HULKE (London), Prof. PARKES (Chicago), &c. &c.

8vo, Cloth, pp. xii., 285, Price 9s.

PULMONARY PHTHISIS,

ITS ETIOLOGY, PATHOLOGY, AND TREATMENT.

By ALEX. JAMES, M.D., F.R.C.P.ED.,

LECTURER ON THE PRINCIPLES AND PRACTICE OF MEDICINE IN THE SCHOOL OF MEDICINE,
EDINBURGH; ASSISTANT PHYSICIAN, EDINBURGH ROYAL INFIRMARY.

(1888.)

*Third Edition, Revised and Enlarged, 8vo, Cloth, gilt top, pp. xx., 585, with
Woodcut and 9 double-page Coloured Illustrations, Price 21s.*

DISEASES OF THE SKIN.

A Manual for Students and Practitioners.

By W. ALLAN JAMIESON, M.D., F.R.C.P.ED.,

EXTRA PHYSICIAN FOR DISEASES OF THE SKIN, EDINBURGH ROYAL INFIRMARY; CONSULTING PHYSICIAN
EDINBURGH CITY HOSPITAL; LECTURER ON DISEASES OF THE SKIN,
SCHOOL OF MEDICINE, EDINBURGH.

(Pentland's Medical Series, Volume First.)

(1891)

*Crown 8vo, Cloth, pp. xvi., 260, with 164 Illustrations and a Series of
Floral Diagrams, Price 6s.*

BOTANY,

A Concise Manual for Students of Medicine and Science.

By ALEXANDER JOHNSTONE, F.G.S.,

LECTURER ON BOTANY, SCHOOL OF MEDICINE, EDINBURGH.

(Pentland's Students' Manuals.)

(1891.)

8vo, Cloth, pp. xii., 170, illustrated with 79 Engravings, Price 8s. 6d.

THE

TECHNIC OF LING'S SYSTEM OF MANUAL TREATMENT,

AS APPLICABLE TO SURGERY AND MEDICINE.

By ARVID KELLGREN, M.D. (EDIN.).

(1890.)

12mo, Cloth, pp. 52, Price 2s.

THE ESSENTIALS OF
MEDICAL ANATOMY,

By H. R. KENWOOD, M.B., C.M., L.R.C.P.(Lond.)

(1889.)

*Large 8vo, Cloth, pp. xvi., 600, with 147 Illustrations, some Coloured,
Price 30s.*

THE REFRACTION AND ACCOMMODATION
OF THE EYE,
AND THEIR ANOMALIES.

By E. LANDOLT, M.D.,

PROFESSOR OF OPHTHALMOLOGY, PARIS.

TRANSLATED UNDER THE AUTHOR'S SUPERVISION

By C. M. CULVER, M.A., M.D.,

FORMERLY CLINICAL ASSISTANT TO THE AUTHOR; MEMBER OF THE ALBANY
INSTITUTE, ALBANY, N.Y.

(1886.)

*Large 8vo, Cloth, pp. xxviii., 772, Illustrated with 404 Engravings,
Price 31s. 6d.*

THE PARASITES OF MAN

AND THE DISEASES WHICH PROCEED FROM THEM.

A TEXT-BOOK FOR STUDENTS AND PRACTITIONERS.

By RUDOLF LEUCKART,

PROFESSOR OF ZOOLOGY AND COMPARATIVE ANATOMY IN THE UNIVERSITY OF LEIPSIK

Translated from the German with the Co-operation of the Author

By WILLIAM E. HOYLE, M.A. (Oxon.), M.R.C.S., F.R.S.E.,

CURATOR OF THE MUSEUMS, OWENS COLLEGE, MANCHESTER.

*NATURAL HISTORY OF PARASITES IN GENERAL.
SYSTEMATIC ACCOUNT OF THE PARASITES INFESTING MAN.
PROTOZOA.—CESTODA.*

(1886.)

12mo, Cloth, pp. viii., 136, with 19 Illustrations, Price 3s. 6d.

PRACTICAL SURGERY.

MEMORANDA FOR THE USE OF STUDENTS.

By W. SCOTT LANG, M.D., M.R.C.S., F.R.C.S.E.,

FORMERLY DEMONSTRATOR OF ANATOMY, SCHOOL OF MEDICINE, EDINBURGH.

(1888.)

New Edition, 18mo, Cloth, pp. 303, Price 4s.

STUDENTS' POCKET MEDICAL LEXICON,

Giving the correct Pronunciation and Definition of all Words and Terms in general use in Medicine and the Collateral Sciences.

By ELIAS LONGLEY.

(1891.)

In Press, 8vo, pp. 550, with Coloured Illustrations from Original Drawings.

DISEASES OF THE THROAT, NOSE, & EAR.

By P. M'BRIDE, M.D., F.R.C.P.ED.,

LECTURER ON THE DISEASES OF THE EAR AND THROAT, EDINBURGH SCHOOL OF MEDICINE;
AURAL SURGEON AND LARYNGOLOGIST, ROYAL INFIRMARY, EDINBURGH;
SURGEON, EDINBURGH EAR AND THROAT DISPENSARY.

(Pentland's Medical Series, Volume Third.)

(1891.)

In Press, in 2 handsome volumes, large 4to, illustrated with 100 full-page facsimile Chromo-lithographic Plates, reproduced from Photographs taken by the Author of his own Dissections, expressly designed and prepared for this work, and coloured by him after nature.

REGIONAL ANATOMY

IN ITS RELATION TO MEDICINE AND SURGERY.

By GEORGE M'CLELLAN, M.D.,

LECTURER ON DESCRIPTIVE AND REGIONAL ANATOMY AT THE PENNSYLVANIA SCHOOL OF ANATOMY; PROFESSOR OF ANATOMY AT THE PENNSYLVANIA ACADEMY OF THE FINE ARTS; MEMBER OF THE ACADEMY OF NATURAL SCIENCES, COLLEGE OF PHYSICIANS, ETC., OF PHILADELPHIA.

To be Re-issued in Ten Monthly Parts, Price 6s. each.
Fasciculus I. now ready.

*The Atlas may also be had complete in one handsome Royal 4to Volume,
Extra Cloth, Price 63s. nett.*

ATLAS OF VENEREAL DISEASES.

*A Series of Illustrations from Original Paintings, with
Descriptions of the Varied Lesions, their differential
Diagnosis and Treatment.*

By P. H. M'LAREN, M.D., F.R.C.S.E.,

SURGEON, EDINBURGH ROYAL INFIRMARY; FORMERLY SURGEON IN CHARGE OF THE LOCK
WARDS, EDINBURGH ROYAL INFIRMARY; EXAMINER IN THE ROYAL
COLLEGE OF SURGEONS, EDINBURGH.

Second Edition, Crown 8vo, Cloth, pp. 178, Price 6s.

DOCTOR AND PATIENT.

By S. WEIR MITCHELL, M.D., LL.D.,

PRESIDENT OF THE COLLEGE OF PHYSICIANS, PHILADELPHIA.

(1888.)

Crown 8vo, Cloth, pp. 56, Price 2s. 6d.

THE DISTRIBUTION AND DURATION OF VISCERAL NEW GROWTHS.

Being the Bradshawe Lecture delivered before the Royal College of
Physicians of London, on August 19, 1889.

By NORMAN MOORE, M.D., F.R.C.P.,

ASSISTANT PHYSICIAN AND LECTURER ON PATHOLOGICAL ANATOMY TO ST. BARTHOLOMEW'S HOSPITAL,
AND WARDEN OF ITS COLLEGE; ASSESSOR TO THE REGIUS PROFESSOR OF PHYSIC IN THE
UNIVERSITY OF CAMBRIDGE.

(1889.)

In Press, 18mo.

DOSAGE AND THERAPEUTICS IN THE DISEASES OF INFANTS AND CHILDREN,

By PHILIP E. MUSKETT, L.R.C.P. & S. ED.,

SYDNEY, NEW SOUTH WALES.

(1891.)

In Press, 8vo, with coloured Illustrations.

LEAD POISONING,

ACUTE AND CHRONIC,

Being the Goulstonian Lectures delivered at the Royal
College of Physicians.

By THOMAS OLIVER, M.D., F.R.C.P.,

PHYSICIAN, ROYAL INFIRMARY, NEWCASTLE-ON-TYNE; PROFESSOR OF PHYSIOLOGY, UNIVERSITY
OF DURHAM; HONORARY PHYSICIAN, NEWCASTLE-ON-TYNE
DISPENSARY AND INDUSTRIAL SCHOOLS.

(1891.)

*Second Edition, thoroughly revised, large 8vo, Cloth, pp. 701, with 214
Wood Engravings, and a Coloured Plate, Price 18s.*

THE SCIENCE AND ART OF OBSTETRICS,

By THEOPHILUS PARVIN, M.D., LL.D.,

PROFESSOR OF OBSTETRICS AND DISEASES OF WOMEN AND CHILDREN IN JEFFERSON
MEDICAL COLLEGE, PHILADELPHIA, AND ONE OF THE OBSTETRICIANS
TO THE PHILADELPHIA HOSPITAL.

(1891.)

8vo, Cloth, pp. vi., 55, Price 3s. 6d.

PULMONARY TUBERCULOSIS,

ETIOLOGICAL AND THERAPEUTIC,

BASED ON AN EXPERIMENTAL INVESTIGATION

By R. W. PHILIP, M.A., M.D., F.R.C.P.ED.,

ASSISTANT PHYSICIAN TO THE ROYAL INFIRMARY; PHYSICIAN TO THE VICTORIA DISPENSARY
FOR CONSUMPTION AND DISEASES OF THE CHEST; LECTURER ON THE PRACTICE
OF MEDICINE, SCHOOL OF MEDICINE, EDINBURGH.

(1891.)

8vo, Sewed, pp. 36, Price 1s.

KOCH'S NEW TREATMENT OF TUBERCULOSIS,

By R. W. PHILIP, M.A., M.D., F.R.C.P.ED.,

ASSISTANT PHYSICIAN TO THE ROYAL INFIRMARY, EDINBURGH; PHYSICIAN TO THE VICTORIA
DISPENSARY FOR CONSUMPTION AND DISEASES OF THE CHEST; LECTURER ON THE
PRACTICE OF MEDICINE, EDINBURGH SCHOOL OF MEDICINE.

(1891.)

PRACTICAL LESSONS IN NURSING:
A NEW SERIES OF HANDBOOKS.

Now ready, Crown 8vo, Cloth, each 4s. 6d.

**THE NURSING AND CARE OF THE
NERVOUS AND THE INSANE.**

By CHARLES K. MILLS, M.D.,

PROFESSOR OF DISEASES OF THE MIND AND NERVOUS SYSTEM IN THE PHILADELPHIA
POLYCLINIC AND COLLEGE FOR GRADUATES IN MEDICINE; LECTURER ON
MENTAL DISEASES IN THE UNIVERSITY OF PENNSYLVANIA.

MATERNITY, INFANCY, CHILDHOOD,

**Hygiene of Pregnancy; Nursing and Weaning of Infants;
The Care of Children in Health and Disease.**

*Adapted especially to the use of Mothers or those intrusted with the bringing up
of Infants and Children, and Training Schools for Nurses, as an
aid to the teaching of the Nursing of Women and Children.*

By JOHN M. KEATING, M.D.,

LECTURER ON THE DISEASES OF WOMEN AND CHILDREN, PHILADELPHIA HOSPITAL.

**OUTLINES FOR THE MANAGEMENT
OF DIET:**

**Or, The Regulation of Food to the Requirements of Health and
the Treatment of Disease.**

By E. T. BRUEN, M.D.,

ASSISTANT PROFESSOR OF PHYSICAL DIAGNOSIS, UNIVERSITY OF PENNSYLVANIA;
ONE OF THE PHYSICIANS TO THE PHILADELPHIA AND UNIVERSITY HOSPITALS.

FEVER NURSING.

**Designed for the use of Professional and other Nurses, and especially
as a Text-book for Nurses in Training.**

*Including Fever Nursing in General. Scarlet Fever. Enteric or
Typhoid Fever. Pneumonia and Rheumatism.*

By J. C. WILSON, M.D.,

VISITING PHYSICIAN TO THE PHILADELPHIA HOSPITAL AND TO THE
HOSPITAL OF THE JEFFERSON COLLEGE.

FOR SALE BY SUBSCRIPTION ONLY.

In Eight very handsome Volumes, Imperial 8vo, Cloth, of about 800 pages each, illustrated with Engravings and Coloured Plates. Price per Volume 25s. Carriage free.

A REFERENCE HAND-BOOK
OF THE
MEDICAL SCIENCES,

EMBRACING THE ENTIRE RANGE OF SCIENTIFIC AND PRACTICAL
MEDICINE AND ALLIED SCIENCES BY VARIOUS WRITERS.

EDITED BY

ALBERT H. BUCK, M.D.,

NEW YORK CITY.

(1889-90.)

*8vo, Cloth, pp. xvi., 271, with Coloured Plates and 35 Engravings,
Price 10s. 6d.*

THE CAUSES AND TREATMENT
OF

ABORTION,

By ROBERT R. RENTOUL, M.D., M.R.C.S.,

FELLOW OF THE OBSTETRICAL SOCIETY, LONDON.

WITH AN INTRODUCTION BY

LAWSON TAIT, F.R.C.S.

(1889.)

*Large 8vo, Cloth, pp. 270, illustrated with 13 Plates, mostly Coloured,
Price 9s.*

SURGICAL BACTERIOLOGY.

By NICHOLAS SENN, M.D., PH.D.,

PROFESSOR OF PRINCIPLES OF SURGERY AND SURGICAL PATHOLOGY, RUSH MEDICAL
COLLEGE, CHICAGO.

(1889.)

REPORTS FROM THE LABORATORY
OF THE
ROYAL COLLEGE OF PHYSICIANS, EDINBURGH.

EDITED BY

J. BATTY TUKE, M.D..

G. SIMS WOODHEAD, M.D.,

AND

D. NÖEL PATON, M.D.

VOLUME FIRST, 8vo, Cloth, pp. 212, with 23 full-page Plates, and 19 Engravings. Price 7s. 6d. nett.

VOLUME SECOND, 8vo, Cloth, pp. xiv., 280, with 43 full-page Plates, consisting of Lithographs, Chromo-Lithographs, and Micro-Photographs. Price 10s. 6d. nett.

VOLUME THIRD, 8vo, Cloth, pp. xii., 304, with 11 Plates and Folding Charts. Price 9s. nett.

8vo, Cloth, pp. xii., 302, with 5 Wood Engravings, Price 9s.

DISEASES OF THE MOUTH, THROAT,
AND NOSE,

INCLUDING

RHINOSCOPY AND METHODS OF LOCAL TREATMENT.

By PHILIP SCHECH, M.D.,

LECTURER IN THE UNIVERSITY OF MUNICH.

TRANSLATED BY

R. H. BLAIKIE, M.D., F.R.S.E.,

FORMERLY SURGEON, EDINBURGH EAR AND THROAT DISPENSARY; LATE CLINICAL ASSISTANT,
EAR AND THROAT DEPARTMENT, ROYAL INFIRMARY, EDINBURGH.

(1886.)

8vo, Cloth, pp. xii., 223, with 7 Illustrations, Price 9s.

ELEMENTS OF PHARMACOLOGY.

BY DR. OSWALD SCHMIEDEBERG,

PROFESSOR OF PHARMACOLOGY, AND DIRECTOR OF THE PHARMACOLOGICAL
INSTITUTE, UNIVERSITY OF STRASBURG.

TRANSLATED UNDER THE AUTHOR'S SUPERVISION,

BY THOMAS DIXSON, M.B.,

LECTURER ON MATERIA MEDICA IN THE UNIVERSITY OF SYDNEY, N.S.W.

(1887.)

Crown 8vo, Cloth, pp. xii., 173, with 60 Illustrations, Price 5s.

MANUAL OF CLINICAL DIAGNOSIS.

BY DR. OTTO SEIFERT,

PRIVAT DOCENT IN WURZBURG.

AND

DR. FRIEDRICH MÜLLER,

ASSISTENT DER II. MED. KLINIK IN BERLIN.

THIRD EDITION, REVISED AND CORRECTED. TRANSLATED WITH
THE PERMISSION OF THE AUTHORS,

BY WILLIAM B. CANFIELD, A.M., M.D.,

CHIEF OF CLINIC FOR THROAT AND CHEST, UNIVERSITY OF MARYLAND.

(1887.)

Crown 8vo, Cloth, pp. xii., 67, Price 2s.

ON THE NATURAL AND ARTIFICIAL FEEDING AND CARE OF INFANTS.

BY JOHN SERVICE, L.R.C.S. & P., ED.,

AUTHOR OF THE "LIFE AND RECOLLECTIONS OF DOCTOR DUGUID OF KILWINNING."

(1890.)

Second Edition, Crown 8vo, extra Cloth, pp. xvi., 287, Price 3s. 6d.

THE LIFE AND RECOLLECTIONS OF
DOCTOR DUGUID
OF KILWINNING.

WRITTEN BY HIMSELF, AND NOW FIRST PRINTED FROM THE
RECOVERED MANUSCRIPT.

By JOHN SERVICE, L.R.C.S. & P., ED., Sydney.
(1890.)

Crown 8vo, Cloth, pp. xvi., 222, Price 3s. 6d.

THIR NOTANDUMS,
Being the Literary Recreations of Laird Canticarl
of Mongrynen (of kittle memory),

TO WHICH IS APPENDED A BIOGRAPHICAL SKETCH OF
JAMES DUNLOP, ESQ., F.R.S.S., LOND. & ED.,
*Astronomer-Royal at the Observatory of Paramatta,
New South Wales, 1831-47.*

By JOHN SERVICE, L.R.C.S. & P., ED.
(1890.)

Crown 8vo, Cloth, pp. xvi., 212,

SURGICAL ANATOMY:
A MANUAL FOR STUDENTS.

By A. MARMADUKE SHEILD, M.B. (CANTAB.), F.R.C.S.,
SENIOR ASSISTANT SURGEON, AURAL SURGEON AND TEACHER OF OPERATIVE SURGERY,
CHARING CROSS HOSPITAL.

(Pentland's Students' Manuals.)
(1891.)

*Crown 4to, extra Cloth, gilt top, with 70 Plates exhibiting
over 400 Figures, Price 12s. 6d.*

ILLUSTRATIONS OF ZOOLOGY, INVERTEBRATES AND VERTEBRATES.

BY WILLIAM RAMSAY SMITH, B.Sc.,

DEMONSTRATOR OF ANATOMY, EDINBURGH SCHOOL OF MEDICINE, MINTO HOUSE; LATE SENIOR
ASSISTANT TO THE PROFESSOR OF NATURAL HISTORY, UNIVERSITY OF EDINBURGH.

AND

J. STEWART NORWELL, B.Sc.

(1889.)

*Second Edition, post 8vo, Cloth, pp. 396, with Illustrations,
Price 10s.*

DISEASES OF THE DIGESTIVE ORGANS IN INFANTS AND CHILDREN.

WITH CHAPTERS ON THE INVESTIGATION OF DISEASE AND ON THE
GENERAL MANAGEMENT OF CHILDREN.

BY LOUIS STARR, M.D.,

LATE CLINICAL PROFESSOR OF DISEASES OF CHILDREN IN THE HOSPITAL OF
THE UNIVERSITY OF PENNSYLVANIA; PHYSICIAN TO THE
CHILDREN'S HOSPITAL, PHILADELPHIA.

*In Press, Second Edition, Crown 8vo, pp. vii., 193, with
28 Coloured Illustrations.*

A PRACTICAL GUIDE TO MEAT INSPECTION,

BY THOMAS WALLEY, M.R.C.V.S.,

PRINCIPAL OF THE EDINBURGH ROYAL (DICK'S) VETERINARY COLLEGE;
PROFESSOR OF VETERINARY MEDICINE AND SURGERY.

(1891.)

In Press, Crown 8vo, with 32 pages of Illustrations.

OUTLINES OF ZOOLOGY

By J. ARTHUR THOMSON, M.A.,

LECTURER ON ZOOLOGY, SCHOOL OF MEDICINE, EDINBURGH.

(Pentland's Students' Manuals.

(1891.)

*Second Edition, Revised and Enlarged, Crown 8vo, Cloth, pp. 766, with
150 Illustrations, Price 16s.*

HANDBOOK OF DISEASES OF WOMEN,

INCLUDING

DISEASES OF THE BLADDER AND URETHRA.

By DR. F. WINCKEL,

PROFESSOR OF GYNÆCOLOGY, AND DIRECTOR OF THE ROYAL UNIVERSITY CLINIC FOR
WOMEN IN MUNICH.

AUTHORISED TRANSLATION EDITED BY

THEOPHILUS PARVIN, M.D.,

PROFESSOR OF OBSTETRICS AND DISEASES OF WOMEN AND CHILDREN IN JEFFERSON
MEDICAL COLLEGE, PHILADELPHIA.

(1890.)

*In preparation, Third Edition, Revised and Enlarged, with many
New Illustrations.*

PRACTICAL PATHOLOGY:

A MANUAL FOR STUDENTS AND PRACTITIONERS.

By G. SIMS WOODHEAD, M.D., F.R.C.P.ED.,

DIRECTOR OF THE NEW LABORATORIES OF THE ROYAL COLLEGE OF PHYSICIANS OF
LONDON, AND THE ROYAL COLLEGE OF SURGEONS OF ENGLAND.

*Royal 8vo, Cloth, pp. 927, Illustrated with 190 Engravings,
mostly original, Price 28s.*

TEXT-BOOK OF OBSTETRICS,

INCLUDING THE PATHOLOGY AND THERAPEUTICS OF
THE PUERPERAL STATE.

DESIGNED FOR PRACTITIONERS AND STUDENTS OF MEDICINE.

BY DR. F. WINCKEL,

PROFESSOR OF GYNÆCOLOGY AND DIRECTOR OF THE ROYAL HOSPITAL FOR WOMEN;
MEMBER OF THE SUPREME MEDICAL COUNCIL AND OF THE FACULTY
OF MEDICINE IN THE UNIVERSITY OF MUNICH.

TRANSLATED FROM THE GERMAN UNDER THE SUPERVISION OF

J. CLIFTON EDGAR, A.M., M.D.,

ADJUNCT PROFESSOR OF OBSTETRICS IN THE MEDICAL DEPARTMENT OF THE
UNIVERSITY OF THE CITY OF NEW YORK.

(1890.)

*8vo, Cloth, pp. xii., 174, with 60 Illustrations, mostly Original
(34 in Colours), Price 8s. 6d.*

PATHOLOGICAL MYCOLOGY:

AN ENQUIRY INTO THE ETIOLOGY OF INFECTIVE DISEASES.

BY G. SIMS WOODHEAD, M.D., F.R.C.P.ED.,

DIRECTOR OF THE NEW LABORATORIES OF THE ROYAL COLLEGE OF PHYSICIANS OF
LONDON, AND OF THE ROYAL COLLEGE OF SURGEONS OF ENGLAND.

AND

ARTHUR W. HARE, M.B., C.M.,

PROFESSOR OF SURGERY, OWENS COLLEGE, MANCHESTER.

SECTION I.—METHODS.

(1885.)

~~165/20~~

273/23

