

**Lateral curvature of the spine and round shoulders / by Robert W. Lovett ; with 154 illustrations.**

**Contributors**

Lovett, Robert W. 1859-1924.  
Francis A. Countway Library of Medicine

**Publication/Creation**

Philadelphia : P. Blakiston's son & co., 1907.

**Persistent URL**

<https://wellcomecollection.org/works/vr7xun67>


**License and attribution**

This material has been provided by This material has been provided by the Francis A. Countway Library of Medicine, through the Medical Heritage Library. The original may be consulted at the Francis A. Countway Library of Medicine, Harvard Medical School. where the originals may be consulted. This work has been identified as being free of known restrictions under copyright law, including all related and neighbouring rights and is being made available under the Creative Commons, Public Domain Mark.

You can copy, modify, distribute and perform the work, even for commercial purposes, without asking permission.





Wellcome Collection  
183 Euston Road  
London NW1 2BE UK  
T +44 (0)20 7611 8722  
E [library@wellcomecollection.org](mailto:library@wellcomecollection.org)  
<https://wellcomecollection.org>





BOSTON MEDICAL LIBRARY  
in the Francis A. Countway  
Library of Medicine ~ *Boston*







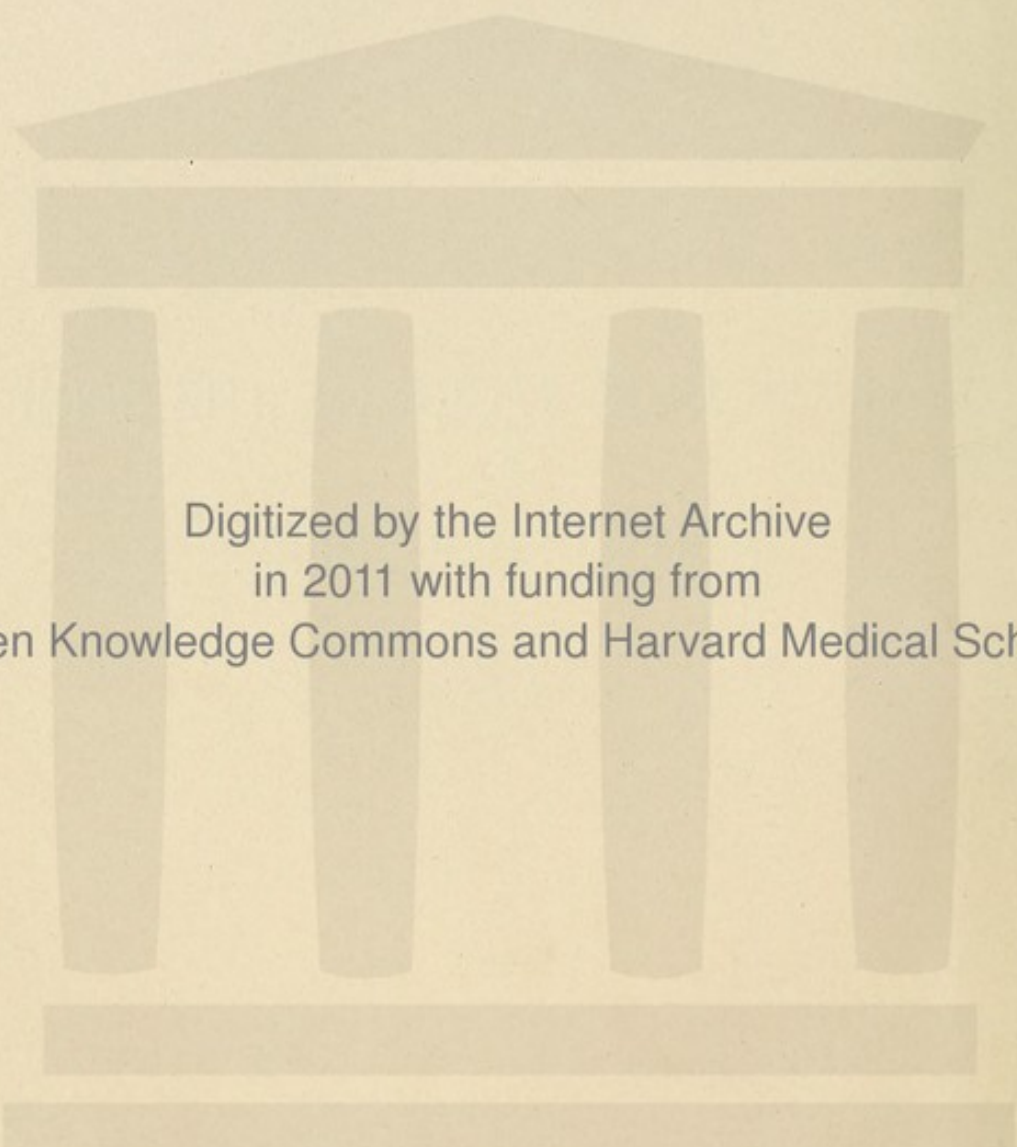




LATERAL CURVATURE OF THE SPINE  
AND  
ROUND SHOULDERS.

---

LOVETT.



Digitized by the Internet Archive  
in 2011 with funding from  
Open Knowledge Commons and Harvard Medical School

# LATERAL CURVATURE OF THE SPINE

AND

## ROUND SHOULDERS

BY

ROBERT W. LOVETT, M.D.

BOSTON

ASSOCIATE SURGEON TO THE CHILDREN'S HOSPITAL, BOSTON; SURGEON TO THE INFANTS'  
HOSPITAL; INSTRUCTOR IN ORTHOPEDIC SURGERY, HARVARD MEDICAL SCHOOL;  
MEMBER OF THE AMERICAN ORTHOPEDIC ASSOCIATION; KORRE-  
SPONDIERENDE MITGLIEDER DER DEUTSCHEN GESELL-  
SCHAFT FÜR ORTHOPÄDISCHE CHIRURGIE

---

With 154 Illustrations

---

PHILADELPHIA  
P. BLAKISTON'S SON & CO.  
1012 WALNUT STREET

1907



9463

---

COPYRIGHT, 1907, BY P. BLAKISTON'S SON & Co.

---

PRESS OF  
WM. F. FELL COMPANY  
1220-24 Sansom Street  
Philadelphia, Pa.

TO  
ALBERT HOFFA  
BERLIN

AS A TOKEN OF FRIENDSHIP AND RESPECT





## PREFACE.

The successful treatment of lateral curvature of the spine cannot in the past be counted as one of the achievements of orthopedic surgery. The affection is not only intrinsically resistant to treatment but the therapeutic measures employed have been on the whole largely empirical and have not been sufficiently correlated to its pathology and to the mechanism by which it is caused. In the last ten years, however, a good deal of progress has been made along new and promising lines, by means of experimental and clinical work, the records of which lie scattered through later medical literature. In the following pages I have attempted to bring together this literature and to add my own personal views and experience, in the hope of presenting the subject in English in a modern light and to call attention to the prospect offered of obtaining better results. That such a book is needed I have been led to infer from many inquiries in connection with this subject by physicians, medical students, and teachers of physical training. If I have devoted too large a part of the book to the question of treatment it is because of the scant attention paid to that part of the subject in most books dealing with deformities.

The anatomical part of the work is from the Anatomical Department of Harvard University, and much of the clinical work is from the Scoliosis Clinic of the Children's Hospital, Boston.


It is impossible to acknowledge my indebtedness individually to those of my colleagues and others who have helped me by contributing material and other assistance. I should, however, express my obligation to Professor Thomas Dwight for his advice given in connection with the anatomical part of my work, for the liberal supply of anatomical material with which he has provided me, and for criticising my chapter on Anatomy. To Miss Amy Morris Homans, Director of the Boston Normal School of Gymnastics, I wish to express my indebtedness for assistance given in many ways; and to my assistants, Fraülein Helene Seltmann and Miss W. G. Wright, for great help in preparing the list of exercises.

I have used freely the chapters on Pathology and Occurrence in the admirable article on Scoliosis by Schulthess of Zürich, recently published in Joachimsthal's "*Handbuch der Orthopädischen Chirurgie.*"

ROBERT W. LOVETT.

BOSTON, 1907.





## TABLE OF CONTENTS.

| CHAPTER  | PAGE |
|--|------|
| I. THE ANATOMY OF THE VERTEBRAL COLUMN AND THE THORAX..... | 1    |
| II. THE MOVEMENTS OF THE SPINE.....                        | 23   |
| III. THE MECHANISM OF SCOLIOSIS.....                       | 38   |
| IV. DESCRIPTION AND SYMPTOMS.....                          | 46   |
| V. EXAMINATION AND RECORD OF SCOLIOSIS.....                | 64   |
| VI. PATHOLOGY.....   | 77   |
| VII. ETIOLOGY—INFLUENCE OF SCHOOL CONDITIONS.....          | 91   |
| VIII. OCCURRENCE.....                                      | 108  |
| IX. DIAGNOSIS.....   | 113  |
| X. PROGNOSIS.....  | 116  |
| XI. TREATMENT.....   | 118  |
| XII. FAULTY ATTITUDE.....                                  | 167  |







# LATERAL CURVATURE OF THE SPINE AND ROUND SHOULDERS.

## CHAPTER I.

### ANATOMY OF THE VERTEBRAL COLUMN AND THE THORAX.

The spine is a flexible weight-bearing column made up of a series of vertebræ separated from each other by twenty-three intervertebral discs and connected with each other by ligaments and muscles. In early life the vertebræ are thirty-three in number. The upper twenty-four, remaining separate throughout life, are distinguished as true, movable, or presacral vertebræ. In the adult the lower nine are fused into two masses to form the sacrum and the coccyx, and are called the false, fixed, or immovable vertebræ. The spine forms the central axis of the skeleton, situated in the median plane of the body and posterior part of the trunk. By the term "the spine" is generally understood the part of the column above the sacrum.

In shape the spinal column is roughly pyramidal, the column of vertebral bodies tapering from below upward, and after early infancy it shows four curves, two anterior and two posterior, in the sagittal or median anteroposterior plane. These are called the physiological curves.

The column is supported in unstable equilibrium on the sacrum. It receives the weight of the arms, the head, and the thorax, and their contents, which it transmits through the sacro-iliac joints to the pelvis and thence through the legs to the ground. The spine encloses and protects the spinal cord, and provides, with the sacrum, thirty-one pairs of intervertebral foramina through which the spinal nerves emerge. It serves by its intervertebral discs to diminish the jar of walking.

The total length of the spine is given as follows by different authors: Cunningham, 70 to 73 cm.; Morris, 70 cm.; and Krause, 72 to 75 cm. (along the curves), which is 45 per cent. of the body-length. The relative length of the separate regions is shown in the following table:

|                      | CUNNINGHAM. <sup>1</sup> | MORRIS. <sup>2</sup> | BEAUNOIS. | DWIGHT. <sup>3</sup> |          |
|----------------------|--------------------------|----------------------|-----------|----------------------|----------|
|                      |                          |                      |           | Males.               | Females. |
| Cervical region..... | 13-14 cm.                | 12.5 cm.             | 10.8 cm.  | 13.3 cm.             | 12.1 cm. |
| Dorsal region .....  | 27-29 cm.                | 27.5 cm.             | 27 cm.    | 28.7 cm.             | 26.5 cm. |
| Lumbar region.....   | 12-15 cm.                | 17.5 cm.             | 16.8 cm.  | 19.9 cm.             | 18.7 cm. |

<sup>1</sup> Cunningham: "Text-book of Anatomy," Macmillan, 1902.

<sup>2</sup> Morris: "Human Anatomy," Blakiston, 1903.

<sup>3</sup> Dwight: "Medical Record," Sept. 8, 1894.



It is frequently stated that the length of the spine in different individuals is pretty constant, but Dwight's figures show rather a wide variation. In fifty-six male spines the longest was 69.8 cm. and the shortest 56.4 cm.

In a straight line, the column measures in men from 66 to 70 cm.,

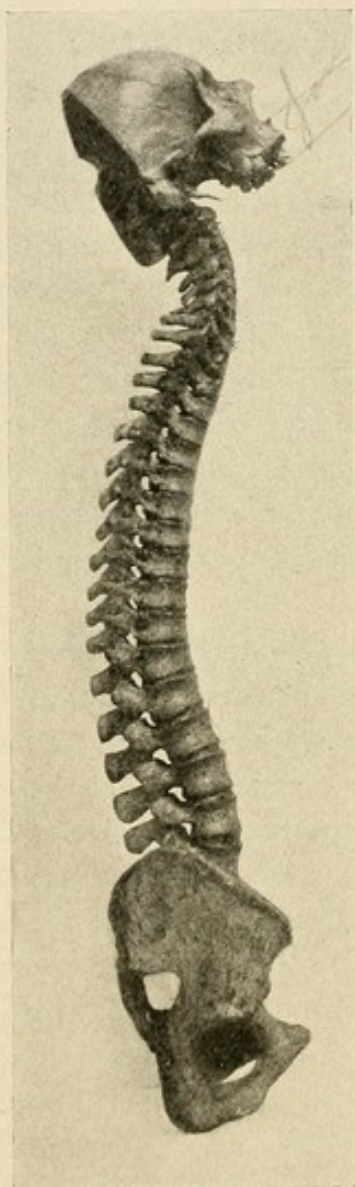

FIG. 1.—THE SPINE SEEN FROM THE SIDE, SHOWING THE PHYSIOLOGICAL CURVES.—(*Warren Museum.*)

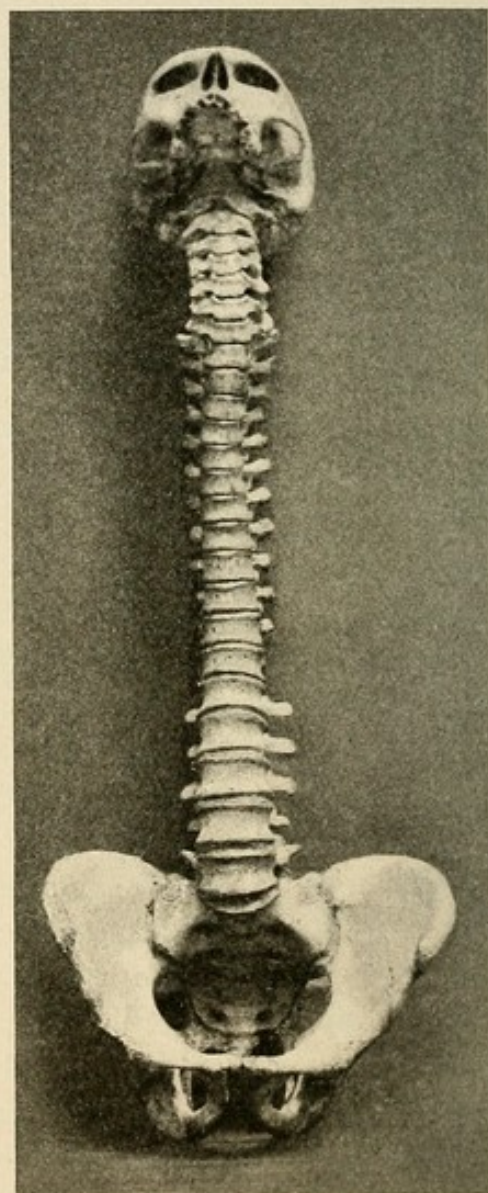


FIG. 2.—THE SPINE SEEN FROM THE FRONT.—(*Warren Museum.*)

and in women from 66 to 69 cm., with an average of 67 cm. (Krause). The height along the chord of this arc is forty per cent. of the total height of the individual. In the fetus and young child the column forms a greater proportion of the body-length. At puberty the more rapid growth of the rest of the body overtakes that of the spine, which



completes its growth between the ages of twenty-three and thirty-one years.

The percentage of total length of the individual occupied by the spine without the sacrum is given for different ages by Moser as follows:

| BODY-LENGTH.   | VERTEBRAL COLUMN LENGTH. | PER CENT. OF VERTEBRAL COLUMN TO BODY-LENGTH. |
|----------------|--------------------------|---|
| 0..... 50      | 19.2                     | 38.4  |
| 3..... 86      | 31.7                     | 36.8  |
| 5..... 112     | 35                       | 30  |
| 11..... 138    | 41                       | 29.7  |
| 14..... 152    | 44                       | 28.9  |
| 15½..... 162   | 45                       | 28.1  |
| Adult..... 167 | 57                       | 34.1  |

The spine is divided into three regions corresponding to the parts of the trunk with which it is connected: (1) The cervical region; (2) the thoracic or dorsal region; (3) the lumbar region.

The cervical region comprises the upper seven vertebræ, including the atlas and axis; the thoracic, twelve vertebræ; and the lumbar, five vertebræ. The lower part of the spine may be spoken of as the posterior end, while the upper part may be called the anterior end of the column. The middle of the spine is placed at the eleventh dorsal vertebra.

The line of gravity in the upright position passes through the bodies of the second and twelfth dorsal vertebræ, and touches the lower anterior border of the last lumbar vertebra.

#### INTERVERTEBRAL DISCS.

The bodies of the vertebræ, from the second cervical to the sacrum, are firmly held together by the intervertebral discs lying between them, twenty-three in number. The discs correspond in size and shape to the horizontal surfaces of the bodies of the vertebræ between which they are found, but they project slightly beyond the edges of the vertebræ. The sum of the heights of all the discs is greatest through the middle portion, next largest through the anterior borders, and least through the posterior borders. Singly the discs vary in height in the different regions of the spine. They are higher anteriorly in the cervical and lumbar regions and posteriorly in the dorsal region. The ratio of the height of the discs to the height of the bodies varies according to different authors. Weber gives the ratio of the average height of all the discs to the average height of all the vertebræ, not including the sacrum, as 1 : 5. According to the same author the ratio of the height of all the discs through the centers to the height of the vertebral column,



represented by a perpendicular from the highest point of the atlas to the sacrum, is as 1 : 4.

The influence of the discs in the formation of the physiological curves of the spine is shown by the two curves in Fig. 5. Curve (*a*) is formed by the bodies and the discs together, and curve (*b*) is the result obtained by placing the bodies one upon the other, forming a long curve with convexity backward, greatest in the lower dorsal region. The convexity of the thoracic spine is flattened in the upper part, and the lumbar

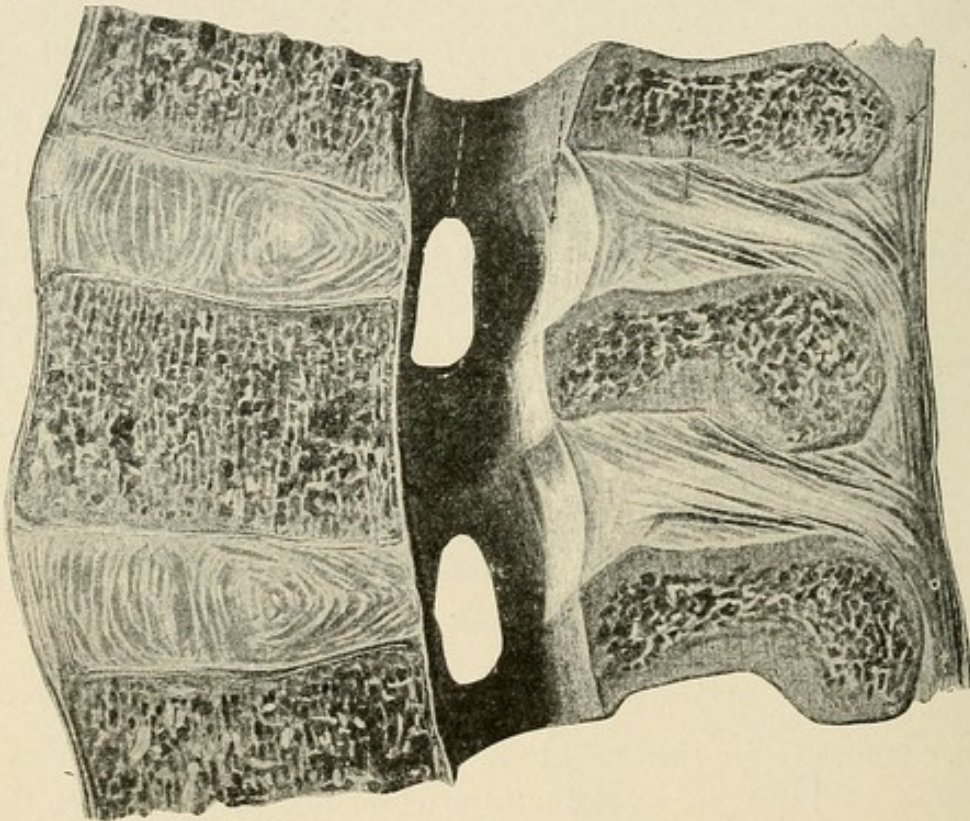


FIG. 3.—MEDIAN SECTION OF A PORTION OF THE ADULT LUMBAR VERTEBRAL COLUMN. THE RIGHT HALF SEEN FROM THE LEFT.—(*Fick.*)

and cervical physiological curves almost completely disappear when the discs are removed.

The discs become smaller and harder with age, shrinking to a greater extent where they are thickest than in the region where they are thin. For this reason the curve of the spine in old age approaches the long convexity backward represented by curve (*b*), and the bowed back of old age is substituted for the upright attitude with a lumbar forward curve which is largely due to the influence of intervertebral discs.

The discs are very firmly attached to the bodies of the vertebræ. On the anterior surface of the column the free edge of the disc shows






FIG. 4.—LINES REPRESENTING THE SUM OF THE THICKNESS OF THE INTERVERTEBRAL DISCS.—(Fick.)

v, At the front border; m, in the middle of the disc; h, at the posterior border.

lamellæ consisting of fibers passing obliquely from one vertebral body to the other. The fibers of successive lamellæ are at right angles to each other, and interlace, suggesting a closed lattice. At the upper and under surfaces the fibers pass into the thin plates of half-calcified hyaline cartilage covering the horizontal surfaces of the bodies. The discs are also attached to the anterior and posterior common ligaments of the spine. The intervertebral discs thus furnish a connecting structure of great strength between each two vertebræ, and

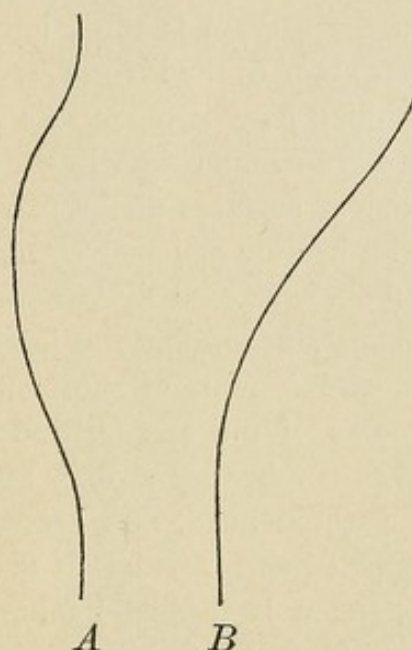


FIG. 5.—CURVES OF THE VERTEBRAL COLUMN.—(Fick.)  
A, With intervertebral discs; B, without intervertebral discs.

at the same time they furnish what amounts to a ball-and-socket joint, on account of the incompressible fluid pulp in the center of each disc, between each two vertebral bodies, except of course the first two cervical.

#### LIGAMENTS OF THE SPINE.

In addition to the connection of the bodies by means of the intervertebral discs the vertebræ are bound together by ligaments which serve to limit movement between them and contribute stability and strength to the column. Ligaments are com-



posed of white fibrous tissue, the strongest tissue in the body, highly elastic, but non-extensible. Two of the spinal ligaments, the ligamentum nuchæ and the subflava, form exceptions to this statement, being made up almost entirely of yellow fibrous tissue.

#### SACRO-ILIAC ARTICULATION.

The strong joint between the sacrum and the ilium through which the whole body-weight is transmitted is a synchondrosis which permits but little motion. What motion occurs between the sacrum and the ilia consists of a forward and backward tilting of the sacrum on the ilia on a transverse axis passing through the second sacral vertebra. If the top of the sacrum is tilted backward because of the obliquity of the articular surfaces the ilia are separated.<sup>1</sup>

The sacro-iliac joint is made safe and strong in part by the wedge shape of the sacrum, but chiefly by the iliosacral ligaments. The corresponding articular surfaces of the two bones are covered more or less completely with hyaline articular cartilage and the very slight joint cavity between them is crossed by fibrous bands. The capsule is formed by the ligaments surrounding the joint. The anterior sacro-iliac ligament is thin, and consists of short strong fibers passing between the adjacent surfaces of the sacrum and the iliac fossæ. The posterior sacro-iliac ligament is very strong, and is responsible for holding the weight of the trunk, head, and arms suspended upon the pelvis and is usually regarded as consisting of two portions. The short posterior sacro-iliac ligament is formed by bundles of fibers passing from the first and second transverse tubercles of the sacrum to the rough posterior part of the inner surface of the ilium, above and behind the auricular surface. The long or oblique sacro-iliac ligament is a superficial part of the short ligament and is a band of fibers extending from the third and fourth transverse tubercles of the sacrum to the posterior superior spine of the ilium.

#### THORAX.

The thorax is a bony cage containing the principal organs of circulation and respiration. It is formed by the thoracic vertebræ, the ribs, the costal cartilages, and the sternum. The ribs, twelve on each side, form a double series of narrow, curved, flattened bones attached posteriorly to the thoracic vertebræ. They extend at first outward,

<sup>1</sup> Goldthwait and Osgood: "Bos. Med. and Sur. Jour.," May 25 and June 1, 1905, with literature.



and then forward, inward, and downward toward the median line anteriorly. The seven upper ribs, called the true, sternal, or vertebro-sternal ribs, are attached directly to the sternum by the costal cartilages anteriorly. The five lower ribs are called false or asternal ribs; the eighth, ninth, and tenth are distinguished as vertebrochondral, as they are anteriorly indirectly united to the sternum by the cartilage of the rib or ribs above; the eleventh and twelfth are called floating ribs, as their anterior extremities are loose in the abdominal wall. The ribs increase in length from the first to the seventh or eighth, decreasing from the eighth to the twelfth. They are approximately parallel with the exception of the eleventh and twelfth, which slant somewhat more downward.

It must be remembered that ribs are lower at their front ends than at their vertebral connection, so that if it is desired to rotate a vertebra by pressure on a rib, the rib horizontally opposite the vertebra is not to be chosen. It has been shown<sup>1</sup> in the cadaver (1) that rotation of vertebræ may be produced, when the extremities of the spine are fixed, by pressure upon any of the intermediate ribs; (2) that the vertebræ attached to the ribs on which pressure is made are the most affected; (3) that the rotation never equals the rib excursion; (4) that the most effective points for pressure or counterpressure are as far as possible from the midline anteriorly and posteriorly except on the lowest four ribs.

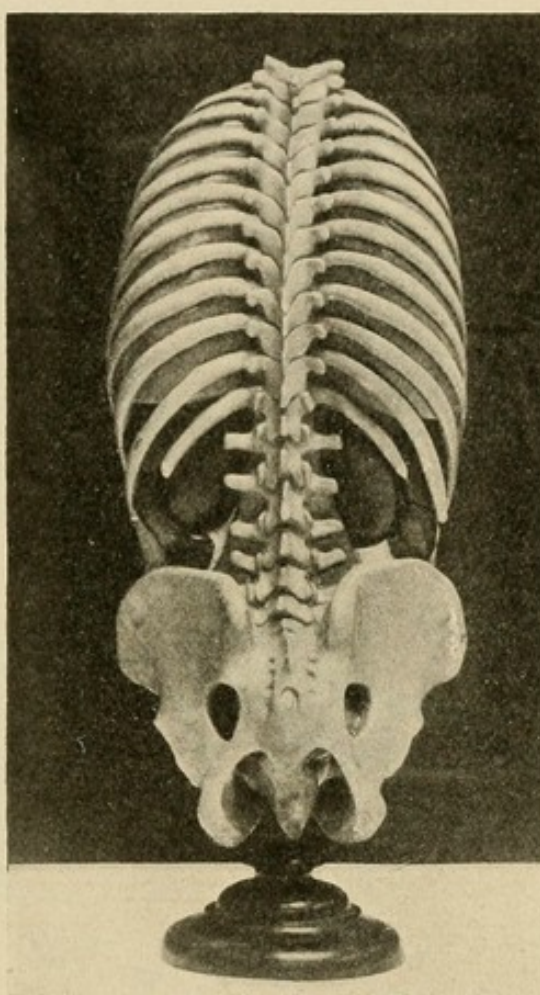


FIG. 6.—MODEL OF THE SPINE SHOWING THE ANATOMICAL RELATIONS, ESPECIALLY THE DISPOSITION OF THE SOFT PARTS IN THE LUMBAR REGION.—(*Warren Museum.*)

<sup>1</sup> Keene: "Amer. Jour. of Orth. Sur.," July, 1906, page 69.



## STERNUM.

The sternum or breast-bone is situated in the median line of the trunk, completing the thoracic cage anteriorly. As a whole, the sternum is a flat bone, and it lies directed obliquely forward and downward. It consists of three parts—the manubrium sterni, the gladiolus, and the ensiform cartilage or xiphoid process.

## SHAPE AND BOUNDARIES OF THE THORAX.

In shape the thorax is somewhat conical, larger behind than in front and compressed anteroposteriorly. The posterior wall is formed

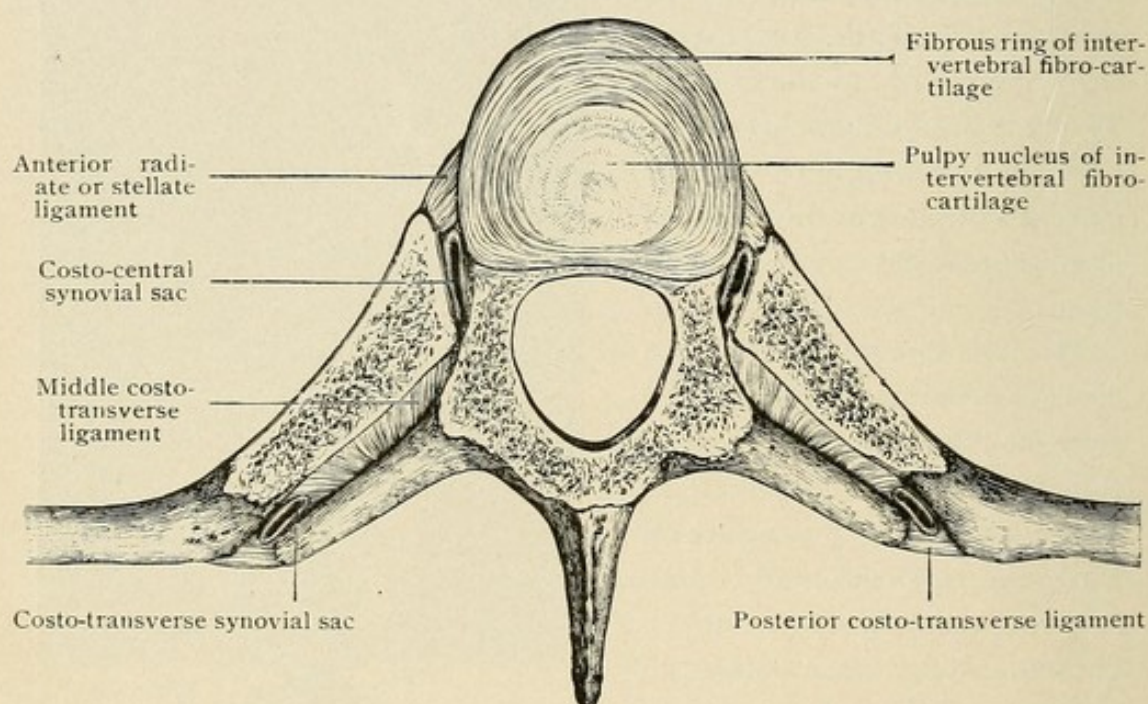


FIG. 7.—HORIZONTAL SECTION THROUGH AN INTERVERTEBRAL FIBRO-CARTILAGE AND THE CORRESPONDING RIBS.—(*Morris's "Anatomy."*)

by the thoracic vertebræ, and by the ribs, from their heads to their angles, and is convex vertically and horizontally. Laterally the cage is formed by the shafts of the ribs; it is somewhat convex vertically, and sharply convex from before backward. The anterior surface, slightly convex and directed forward and downward, is formed by the sternum and the costal cartilages. The plane of the superior opening or inlet of the thorax is inclined forward and downward, showing a greater obliquity in women than in men. The inferior border of the thoracic cage is formed by the twelfth thoracic vertebra, the lower borders of the twelfth rib, and by two curved lines, extending from the anterior extremities of the last rib to the inferior angles of the gladio-



lus, touching the anterior extremities of the eleventh rib and the costal cartilages of the tenth, ninth, and eighth ribs. The angle formed by these lines is known as the subcostal angle. The inferior surface of the thorax is directed forward and downward.

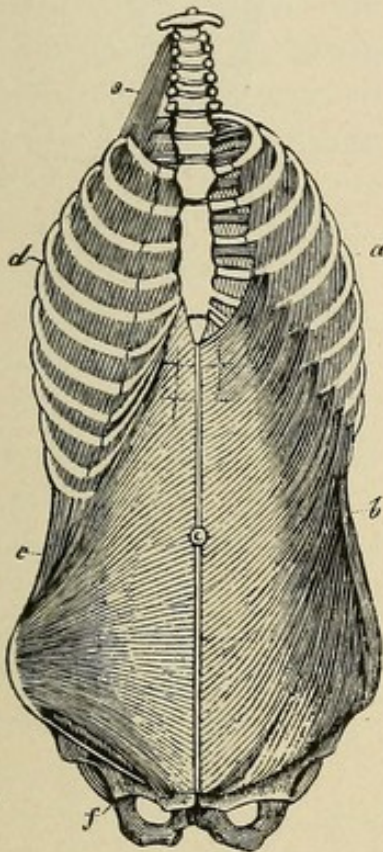


FIG. 8.—G. HERMAN MEYER. THE TWO OBLIQUE MUSCLE PULLS.—(*Feiss.*)

On the left the descending oblique. *a*, External intercostals; *b*, descending oblique or externus abdominis. On the right the ascending oblique muscle pull. *c*, Descending oblique or internus abdominis; *d*, internal intercostals; *e*, scalenus colli; *f*, cremaster.

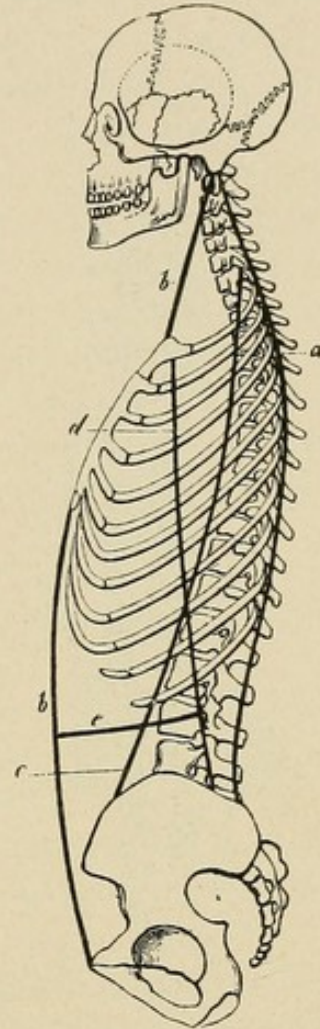


FIG. 9.—G. HERMAN MEYER. THE SCHEME OF THE TORSO MUSCULATURE INDICATING THE DIRECTION OF THE VARIOUS MUSCLE PULLS.—(*Feiss.*)

*a*, Posterior longitudinal muscle pull (sacrospinalis); *b*, anterior longitudinal muscle pull; *c*, oblique descending muscle pull; *d*, oblique ascending muscle pull; *e*, transverse muscle pull.

#### MUSCLES OF THE SPINE AND THORAX.

The general grouping and arrangement of the muscles in their relation to the spine has an important practical bearing on scoliosis. The spine lies at the back of a more or less cylindrical muscular tube of which the abdominal muscles form the front. Of muscles directly



attached to the spine there are two varieties: (1) muscles running from one part of the spine to another part and to the head; (2) muscles running from the spine to the pelvis or shoulder-girdle. The abdominal muscles by their attachment to the thorax, which is comparatively

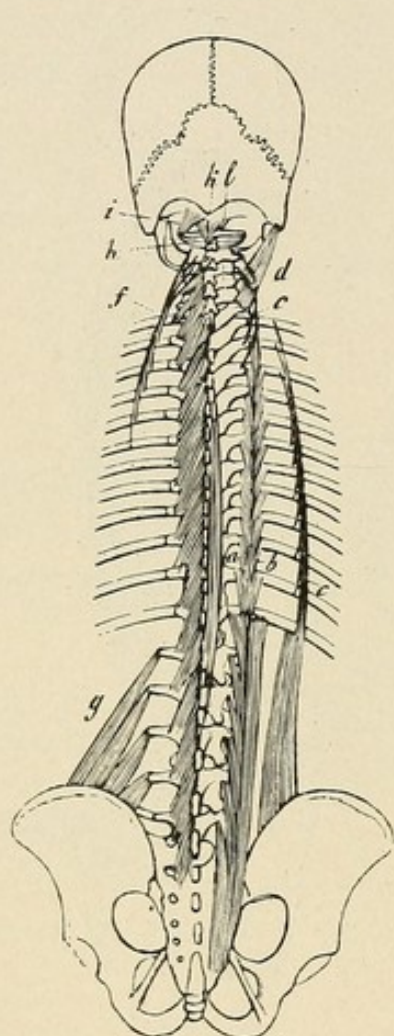


FIG. 10.—G. HERMAN MEYER. THE SYSTEM OF THE SACROSPINALIS.—(Feiss.)

*a*, Spinalis; *b*, longissimus dorsi; *c*, transversalis cervicis; *d*, trachelomastoideus; *e*, ileocostalis; *f*, ascendens cervicis; *g*, ileolumbalis (hinder portion of *m. quadratus lumborum* Auct.); *h*, obliquus capitis inferior; *i*, obliquus capitis superior; *k*, rectus capitis posterior major; *l*, rectus capitis posterior minor.

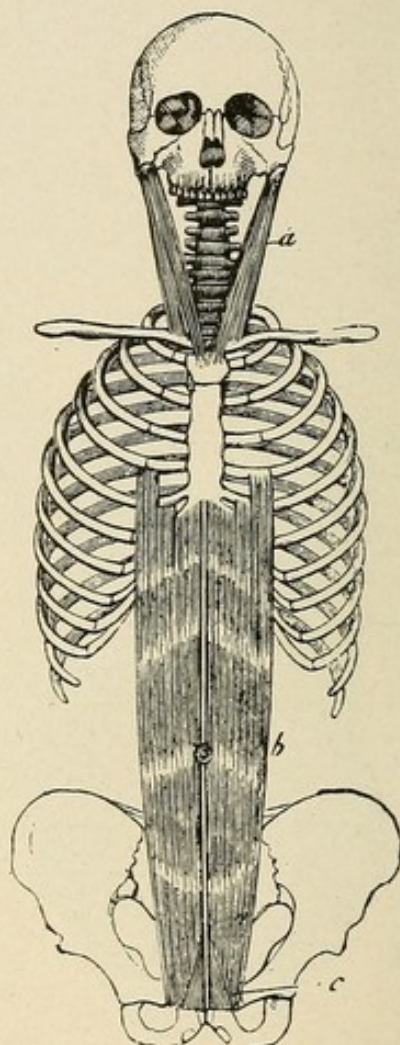


FIG. 11.—G. HERMAN MEYER. ANTERIOR LONGITUDINAL MUSCLES OF THE TRUNK.—(Feiss.)

*a*, Sternocleido-mastoideus; *b*, rectus abdominis; *c*, pyramidalis.

rigid, have an action on the spine. By the combined action of these three the erect position is maintained, or any variation from it is accomplished.

In making a side flexion of the spine from the erect position, for



example, no one muscle or group of muscles is alone active, but it implies a concerted and coördinated action of all the groups mentioned to keep the balance and perform the bending. The maintenance of the spine in the upright position by the muscles has been compared to the way in which a flagstaff is held upright by stays reaching from the top of the staff to the ground. Although there is no one muscle running from the head to the pelvis there is a continuous set of muscles supplementing each other's action. For example, in the anterior line the sternomastoid runs from the skull to the front of the top of the thorax, the sternum connects the upper and lower ribs and forms a rigid piece, and the lower thorax is connected with the pelvis by the rectus abdominis muscle. In the back the continuity of muscular action is shown by the fact that before the top insertion of the longissimus dorsi has been reached the complexus and transversalis cervicis have begun. The whole conception of muscular action in its relation to gymnastics is simplified by remembering the continuity of the muscular tube from the head to the pelvis.

The thorax represents a comparatively fixed cage inserted in a structure quite movable above and below it; muscles attached to the thorax are therefore indirectly attached to the spine. The comparative rigidity of the thoracic part of the spine is due to the fact that the majority of the ribs are attached between two vertebræ, that they pass forward to be also attached to the sternum, and that the whole structure is one well calculated to prevent side bending or extensive forward or backward motion in that region; the cage must therefore largely move as a whole.

It has been pointed out that the dorsolumbar junction is a dividing point for important muscular origins and insertions above and below it, *e. g.*, the psoas muscles originate largely below it and the trapezius above it, and that it forms a weak and movable part of the spine for this reason (Ludloff), but more important than this is the fact that muscles connecting the thorax and pelvis will move the spine where the rigid dorsal region changes to the movable lumbar region and that a large number of muscles will therefore express their contraction by motion at the dorsolumbar junction. A similar weak and movable part of the spine is said to exist at the cervicodorsal junction, where important muscles (splenius and rhomboids) have a dividing point.

#### NERVE-SUPPLY.

The spinal nerves emerge from the spinal canal through the intervertebral foramina and are distributed to the integument and muscles



|  | MOTOR  | SENSORY                              | REFLEX |
|--|--|--------------------------------------|--------|
|  | 1<br>2<br>3<br>4<br>5<br>6<br>7<br>8                         | 1<br>2<br>3<br>4<br>5<br>6<br>7<br>8 |        |
|  | C1<br>2<br>3<br>4<br>5<br>6<br>7                             |                                      |        |
|  | 2<br>3<br>4<br>5<br>6<br>7<br>8                              |                                      |        |
|  | 3<br>4<br>5<br>6<br>7<br>8                                   |                                      |        |
|  | 4<br>5<br>6<br>7<br>8  |                                      |        |
|  | 5<br>6<br>7<br>8   |                                      |        |
|  | 6<br>7<br>8  |                                      |        |
|  | 7<br>8   |                                      |        |
|  | T1<br>2<br>3<br>4<br>5<br>6<br>7<br>8<br>9<br>10<br>11<br>12 |                                      |        |
|  | 2<br>3<br>4<br>5<br>6<br>7<br>8<br>9<br>10<br>11<br>12       |                                      |        |
|  | 3<br>4<br>5<br>6<br>7<br>8<br>9<br>10<br>11<br>12            |                                      |        |
|  | 4<br>5<br>6<br>7<br>8<br>9<br>10<br>11<br>12                 |                                      |        |
|  | 5<br>6<br>7<br>8<br>9<br>10<br>11<br>12                      |                                      |        |
|  | 6<br>7<br>8<br>9<br>10<br>11<br>12                           |                                      |        |
|  | 7<br>8<br>9<br>10<br>11<br>12                                |                                      |        |
|  | 8<br>9<br>10<br>11<br>12                                     |                                      |        |
|  | 9<br>10<br>11<br>12  |                                      |        |
|  | 10<br>11<br>12   |                                      |        |
|  | 11<br>12   |                                      |        |
|  | 12   |                                      |        |
|  | L1<br>2<br>3<br>4<br>5                                       |                                      |        |
|  | 2<br>3<br>4<br>5   |                                      |        |
|  | 3<br>4<br>5  |                                      |        |
|  | 4<br>5   |                                      |        |
|  | 5  |                                      |        |
|  |  |                                      |        |
|  |  |                                      |        |
|  |  |                                      |        |
|  |  |                                      |        |
|  |  |                                      |        |
|  | S<br>2<br>3<br>4<br>5  |                                      |        |
|  | 2<br>3<br>4<br>5   |                                      |        |
|  | 3<br>4<br>5  |                                      |        |
|  | 4<br>5   |                                      |        |
|  | 5  |                                      |        |
|  |  |                                      |        |
|  | Co.<br>Co.   |                                      |        |
|  |  |                                      |        |

FIG. 12.—DIAGRAM AND TABLE SHOWING THE APPROXIMATE RELATION TO THE SPINAL NERVES OF THE VARIOUS MOTOR, SENSORY, AND REFLEX FUNCTIONS OF THE SPINAL CORD. (Arranged by Dr. Gowers from anatomical and pathological data.)—(Morris's "Anatomy.")



all over the body. Eight are cervical nerves (the first passing over the atlas), twelve dorsal, five lumbar, five sacral, and one coccygeal. Each is formed by the union of two nerve roots, which occurs outside the spinal cord and just inside of or at the intervertebral foramen. The anterior, motor, or efferent fibers come from the cells of the anterior horn of the cord; the posterior, sensory, or afferent fibers emerge from the cells of the posterior horn on the same side of the cord. The nerve formed by these two roots on leaving the intervertebral foramen divides into an anterior and posterior branch, each with motor and sensory fibers. The posterior divisions are small and supply the skin and muscles of the back. The anterior divisions are distributed to the neck, the front and sides of the trunk, and to the extremities. Each anterior division is connected with a plexus, ganglion, or nerve of the sympathetic system.

#### EVOLUTION OF THE SPINE.

The history of the spine in its evolution is of interest. In the Cyclostomata the vertebral column consists of a non-segmented, homogeneous, cartilaginous rod. Articular processes first appear in the Rays and Teleostei. The backbone of the lower fishes consists of a series of bony discs bound together by elastic intervertebral discs. It would seem from the history of the spine as if articular processes developed concomitantly with the elaboration of structure, as if they were incidental to its use rather than factors determining of themselves its types of motion.

#### OSSIFICATION.

The ossification of a vertebra occurs from three primary centers, one for the body and one for each lateral mass. These appear in the sixth week, and in the cervical region the lateral centers are the first to appear, while in the dorsal region the one for the body is the first seen. The center for the body is often double in appearance if not in reality. The centers for the lateral masses are found near the bases of the articular processes and from them form the pedicles, laminae, articular processes, and a large part of the transverse and spinous processes, the bodies of the vertebrae forming from the other center. The vertebral epiphyses serve to assist in the formation of joints, to provide for the attachment of ligaments and tendons, and to increase the development in length of the bone of which they form a part. At about puberty appear five other secondary or complementary centers, one at the tip of the spinous process, one at the tip of each transverse process, and one at the upper and one at the lower surface of each body, occur-



ring as a flat meniscus at about the seventeenth year and uniting to the vertebral body a few years later (twenty years). The arrest of the development of one-half of one of these latter may become a serious matter.

#### PLANES OF THE BODY.

The planes of the body will be frequently spoken of and should be defined. The *frontal* plane is a vertical and transverse one. The *sagittal* or anteroposterior plane runs in the anteroposterior axis. The term *horizontal* plane is self-explanatory.

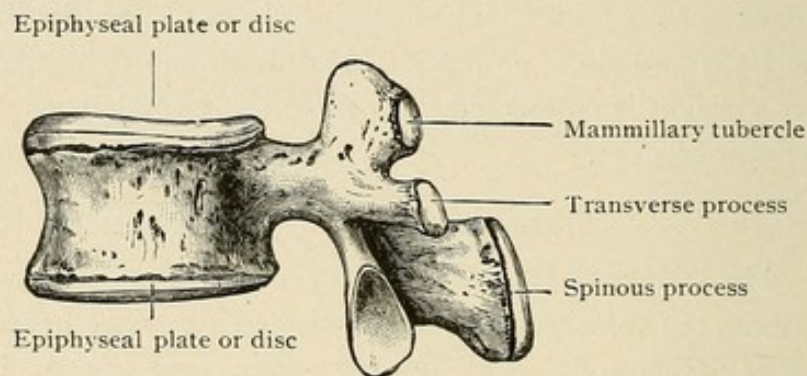


FIG. 13.—LUMBAR VERTEBRA AT THE EIGHTEENTH YEAR WITH SECONDARY CENTERS.—  
(*Morris's "Anatomy."*)

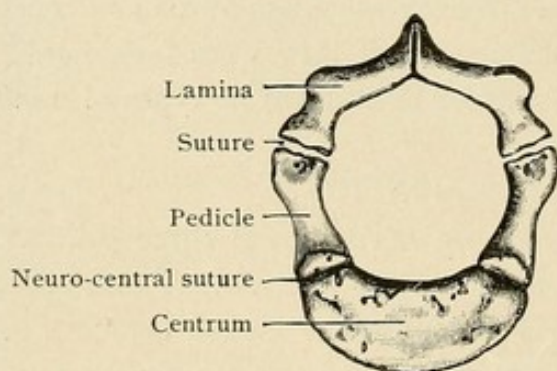


FIG. 14.—OSSIFICATION OF THE FIFTH LUMBAR VERTEBRA.—(*Morris's "Anatomy."*)

#### PHYSIOLOGICAL CURVES.

In examining the literature relating to the physiological curves such contradictory and unsatisfactory information was found that the whole subject was taken up by the writer for investigation, the results of which are presented here.<sup>1</sup>

In this investigation the position of the spine in the human embryo was studied. The spinal curves of the skeletons of mammalia were observed. Measurements were made of the anterior and posterior borders of the bodies of the vertebrae in sagittal section of the spine of new-born children and of a child two years old, and

<sup>1</sup> From a paper presented at the Italian Congress of Orth. Sur., "Arch. di Ortop.," 1906, v and vi, page 372, Milan, Sept. 22, 1906.



lead strip tracings were taken of the back of two hundred normal children between the ages of four days and thirteen years in the positions of slack standing, natural standing, and in prone lying.

Measurements of medial sections of detached spines showed in new-born infants a slight bony curve in the lower dorsal region, convex backward. This curve was visible on the anterior surface of the column and reappeared after corrective manipulation of the spine. The curve of the spine of a child two years old was more developed than in the new-born. Measurement of the anterior and posterior borders of the vertebral bodies showed in the cervical region a difference of 0.5 mm. in favor of the anterior borders, in the dorsal region a difference of 16 mm. in favor of the posterior borders, and in the lumbar spine 9.5 mm. in favor of the anterior borders. In this spine therefore the three physiological curves were present in the bodies of the vertebrae.

Tracings over the spinous processes were taken by means of flexible lead strips and the curves transferred to paper for study. The tracings showed clearly the form and development of the dorsal and lumbar curves in standing and in lying prone. The natural sitting position assumed by all the children was practically the same, a convexity backward of the dorsal and lumbar spines with a maximum at the dorsolumbar junction. In the younger children this curve included the sacrum. Only four of the children between the ages of nine and thirteen showed a lumbar curve in sitting. The character of the curves varied most in the youngest children, and became more constant with age. The variations from the accepted normal type of tracing were most numerous in the youngest children, and decreased in percentage and in variety with age.

In lying the backward dorsal curve was found in 86 per cent. of cases under one year, and in all but two of the 178 children over one year old. The curve was marked at fourteen months, and increased with age. In children under six months the curve included the lumbar and sacral regions; in those over six months it did not. The lumbar curve in lying showed frequently after the age of one year, and in a very large majority of cases after the age of three years. The cervical curve could not be observed to advantage in lying, or in standing, in the youngest children, but over the age of fourteen months a cervical curve with anterior convexity was observed in standing. The dorsal curve appeared in standing in the earliest tracing in this position, that of a child ten months old, and persisted absolutely. The curve was well marked at fourteen months and increased with age, changing in character as it became limited to the dorsal spine, and the maximum receded from the dorsolumbar junction to the middorsal region. The dorsal

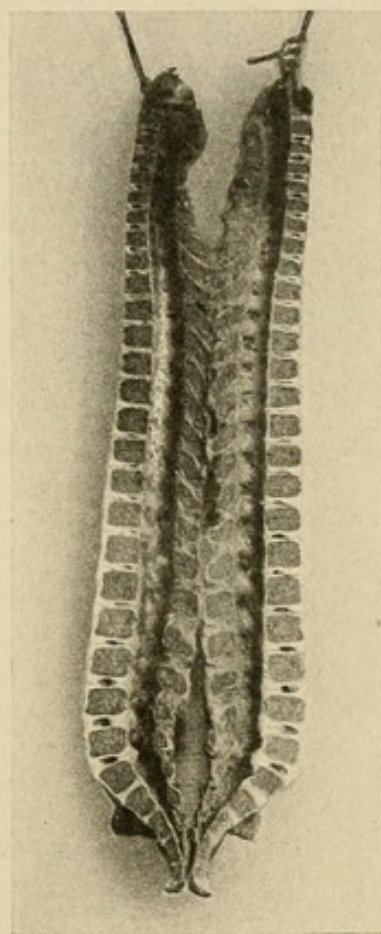


FIG. 15.—SECTION OF THE SPINE OF A NEW-BORN INFANT.



curve was greater in standing than in lying. The lumbar curve in standing appeared first in a child of seventeen months, and from the age of two years persisted in a very large majority of cases, the exceptions being usually children under three years who had not walked. The curve increased at the expense of the dorsal curve, and was usually greater in standing than in lying.

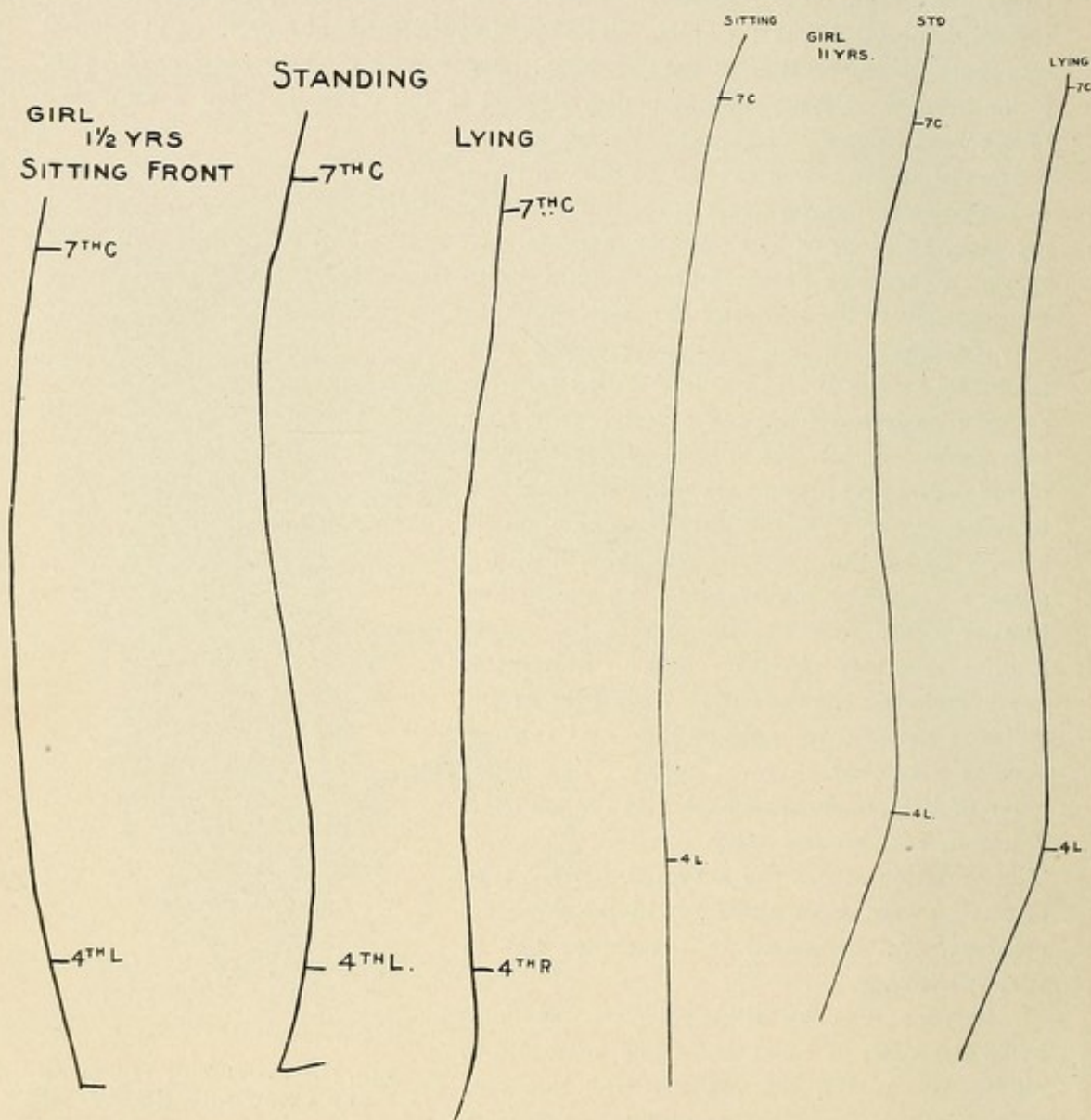


FIG. 16.—TRACINGS OF PHYSIOLOGICAL CURVES OF NORMAL CHILDREN, ON THE LEFT OF A GIRL OF ONE AND A HALF YEARS, ON THE RIGHT OF A GIRL OF ELEVEN.

In the adult, the part played by the bodies of the vertebræ and the discs in producing the physiological curves is shown by the following table:

DIFFERENCE BETWEEN THE SUMS OF THE ANTERIOR AND POSTERIOR BORDERS.

|                      | VERTEBRÆ. | DISCS.   |
|----------------------|-----------|----------|
| Cervical region..... | 1.3 mm.   | 7.8 mm.  |
| Dorsal region.....   | 13.3 mm.  | 9.2 mm.  |
| Lumbar region.....   | 6.7 mm.   | 21.1 mm. |



The cervical curve is formed principally by the intervertebral discs. It is a fairly mobile curve, and may be straightened by suspension. The dorsal curve is formed chiefly by the bodies of the vertebræ; it is a rigid curve and cannot be obliterated. The lumbar physiological curve is produced mainly by the greater anterior height of the intervertebral discs and is therefore mobile.

A slight physiological lateral curve convex to the right has long been recognized in the spine. It has been attributed to the pressure of the aorta on the vertebral bodies, to excessive use of the right side of the body in certain occupations, and to extreme right-handedness. The almost constant occurrence of the curve indicates a common cause, which is most probably aortic pressure. The asymmetry extends from the fifth dorsal to the second or third lumbar vertebra. The body of the fifth dorsal vertebra is flattened on the left side, and the discs above and below are similarly affected. There is a groove from one and a half to two centimeters broad passing downward in a spiral direction, following the course of the aorta, to the anterior surface of the second or third lumbar vertebra. The discs between these vertebræ are usually less projecting than the others, and if the cutting away of the vertebra cannot be seen the flattening of the disc is always apparent.<sup>1</sup>

#### PELVIC INCLINATION.

The position of the pelvis in relation to the horizontal plane is of importance in relation to scoliosis and faulty attitude because it must vary from the normal with every variation from the normal of the body in the upright position. If the front part of the pelvis is lowered and the back part correspondingly tilted up it is spoken of as "increased inclination." If the front part is raised and the back part lowered it is spoken of as "diminished inclination." With the former is associated an increase of the lumbar physiological curve and with the latter a flattening of it.

<sup>1</sup> Pere: "Les courb. lat. norm du Rachis humaine," These de Toulouse, 1900.

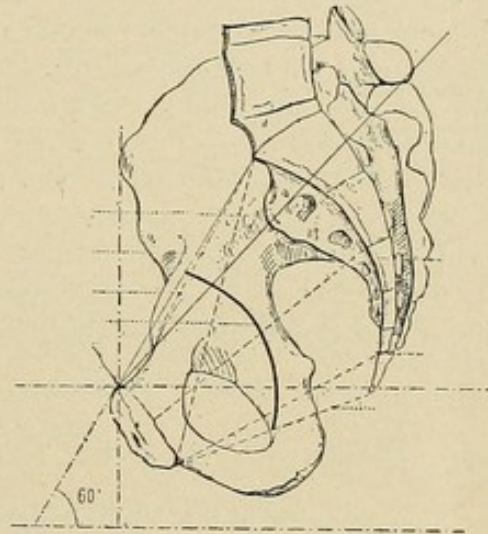


FIG. 17.—FEMALE PELVIS, MEDIAN SECTION.—(*Spalteholz*.)

The solid line running up and back from the symphysis indicates the "external conjugate diameter."



Changes in inclination of the pelvis form an important element in the faulty attitude to be spoken of as round shoulders, but have been to a certain extent overlooked.

The internal or true conjugate diameter (*conjugata vera*) of the pelvis is a line from the sacrolumbar junction to the top of the symphysis pubis and is generally accepted as the line by which pelvic inclination is to be determined. The angle which this line makes with the horizon when the patient stands erect is spoken of as the "angle of pelvic inclination," and the observers do not wholly agree in their results, which are as follows:

|  | AVERAGE IN MEN. | AVERAGE IN WOMEN. |
|--|-----------------|-------------------|
| Year 1745, Müller .....                      | 45 degrees      | ..                |
| Year 1825, Nägele <sup>1</sup> .....         | 60 "            | ..                |
| Year 1836, Weber Brothers <sup>2</sup> ..... |                 | 65 degrees        |
| Year 1841, Krause <sup>3</sup> .....         | 60 "            | 60 "              |
| Year 1873, Meyer <sup>4</sup> .....          | 55 "            | 50 "              |
| Year 1882, Prochovnik <sup>5</sup> .....     | 54.17 "         | 51.72 "           |
| Year 1898, Henggeler <sup>6</sup> .....      | 44 "            | 41.1 "            |

The question has been chiefly studied by gynecologists and obstetricians, and from their point of view most of the work was done over twenty-five years ago. Prochovnik's method of observation commends itself as reliable, and his conclusions are therefore worthy of consideration. He observed living patients, whereas many of the other observations were on cadavers. He measured the patient standing and took in front the height from the ground of the top of the symphysis pubis and the height of the fifth lumbar spinous process behind. The distance between these two was then measured and the inclination thus determined of a line connecting the fifth lumbar spinous process and the top of the os pubis, a line differing but little from the true conjugate. This he called the external conjugate and used as the basis of all his calculations. By adding from 8 to 12 degrees to his measurements the true conjugate is to be found.

Seventy-six males and eighty females, all apparently normal, over the age of fifteen were investigated and tabulated.

|              | LEAST INCLINATION. | GREATEST.  | AVERAGE.      |
|--------------|--------------------|------------|---------------|
| Males.....   | 26 degrees         | 76 degrees | 51.72 degrees |
| Females..... | 40.5 "             | 71 "       | 54.17 "       |

The grouping of the results suggests that a normal pelvis shows an inclination of from 50 to 60 degrees, that there is a subnormal zone from 45 to 50 degrees, a supranormal of 60 to 65 degrees, but that an inclination above 65 degrees or below 45 degrees is to be regarded as pathological. The figures given refer to the external conjugate and are a little higher when the internal conjugate is taken as determining the angle of inclination. The variation in the inclination of the pelvis in individ-

<sup>1</sup> "Das Weibl Becken," etc., Carlsruhe, 1825.

<sup>2</sup> "Mech. d. Mensch. Gehwerkzeuge," Göttingen, 1836.

<sup>3</sup> "Hdbch. d. Mensch. Anat. Hauft.," 1, 1, 324, Hanover, 1841.

<sup>4</sup> "Müller's Archiv," 1873, 9.

<sup>5</sup> "Archiv. f. Gyn.," 1882, xix, 1.

<sup>6</sup> "Zeitsch. f. orth. Chir.," xii, 4, 613.



uals is so wide that the average has but little meaning in any individual case. The angle which the long axis of the leg makes with the horizon as seen from the side in the upright position varies a good deal, being, on the whole, a larger angle for men than for women ( $80\frac{1}{2}$  degrees in men and 77 degrees in women); that is, the leg axis in women is more oblique and less vertical than in men (Prochovnik).

In the normal, upright position the anterior superior spines of the ilium and the tubercle of the os pubis are in the same vertical plane. This was found true by Meyer and Prochovnik and is at least true for Germans. The fact is of importance in determining the normal inclination of the pelvis during life and in measurements of cadavers.

The inclination of the pelvis is influenced by the position of the legs. In the widest possible spread of legs ( $27\frac{1}{2}$  degrees in men and  $22\frac{1}{2}$  degrees in women) the inclination of the pelvis is increased on the average by  $18\frac{1}{2}$  degrees in men and  $16\frac{1}{2}$  degrees in women. The angle between the lumbar spine and external conjugate of the pelvis is not, however, greatly changed by this position, as the lumbar spine changes also. The angle in the normal upright position with the legs together being 148 degrees, with the legs spread it becomes 154 degrees in men and 146 degrees in women, a difference of only a few degrees.

As the method of Prochovnik is slow and tedious, Henggeler attempted to find an available practical measure of the pelvic inclination in the obliquity of a line connecting the anterior and posterior superior iliac spines, and made 661 measurements for this purpose on children for the most part scoliotic or with other abnormality. Knowing the obliquity of this line he attempted to translate it into terms of obliquity of the conjugate diameter by means of anatomical measurements made on the pelves of eight male and fifteen female adult cadavers. He estimated that to obtain the inclination of the conjugate there should be added to the inclination of the line connecting the two superior iliac spines a "constant" which in the measurements varied from 24.5 degrees to 47 degrees, with an average for men of 32 degrees and for women of 35.5 degrees.

Inasmuch as the results of these measurements differ so widely from those of other observers, as the clinical material consisted largely of scoliotic children, and as the "constant" was obtained from the study of adult pelves and applied to the measurements of children's pelves, it is not possible to attach the same importance to these figures as to those of Prochovnik, and this low pelvic inclination cannot be accepted without more extended investigation.

With regard to pelvic inclination in children there are no figures upon which we can rely to determine whether it is greater or less than in adults.

#### NUMERICAL VARIATION IN THE VERTEBRAL COLUMN.

The number of vertebræ in the different regions of the spine may vary, and the subject has a distinct bearing on the etiology of scoliosis.<sup>1</sup> Numerical variation in the human spine is estimated by Bardeen as occurring in 15 or 16 per cent. of people. The following classification of the abnormal spines in the Dwight collection in the Warren Anatomical Museum will show the more usual forms.<sup>2</sup>

1. The number of presacral vertebræ is normal, but there is an irregularity at the junction of the dorsal and lumbar or dorsal and cervical regions.

<sup>1</sup> Fischel: "Untersuchungen über die Wirbelsäule und dem Brustkorb, des Menschen," Wiesbaden, 1906.

<sup>2</sup> Thomas Dwight: "Mem. Bos. Soc. of Nat. Hist.," v, 7, 1901.



2. In some specimens the twenty-sixth presacral vertebra is the one forming the largest part of the auricular surface in contact with the ilium (*vertebra fulcralis*), but in which the twenty-fifth is not quite separated from it.

3. There may be more than twenty-four perfectly free presacral vertebræ, (a) the extra one being thoracic, (b) or lumbar, (c) or both thoracic and lumbar, the latter being sacralized on one side and the twenty-seventh the *vertebra fulcralis*.

4. One or more presacral vertebræ may be imperfectly developed—(a) one or more being fused, (b) the atlas and occiput being fused, (c and d) the twenty-fourth being more or less sacralized.

5. There may be lacking one presacral vertebra—(a) in the lumbar region, (b) in the thoracic region, (c) there being twelve pairs of ribs, the first pair being cervical and perfect on one side. The twenty-fourth is the *vertebra fulcralis* in all groups of this division.

The two sides of the column may vary independently, a point of much importance. Clinically these variations are described as cervical ribs, lumbar ribs, extra lumbar vertebræ, sacralized vertebræ, deficient vertebræ, etc.

When present these variations are usually at the regional boundaries and are found more frequently toward the posterior end of the spine than anteriorly.

The numerical anomalies which occur may be called a variation around a mean. The error in development having once occurred, there is evident an effort on the part of the organism to correct it as much as possible. If there are but eleven thoracic vertebræ the bodies very often are longer than usual. If the last rib be rudimentary the penultimate is unusually long; if there be an irregularity in the lumbar vertebræ an effort is apparent to imitate the usual aspect of the region as nearly as may be in the spread of the transverse processes. In cases where the last rib is like a transverse process and there are only four lumbar vertebræ, the appearance is often very striking.

The thorax may be segmentally reduced or extended at either end, extended at both ends, or extended at one end and reduced at the other; a simultaneous reduction at both ends has not been reported.

According to Bardeen,<sup>1</sup> the original position of the ilium is opposite the anterior part of the lumbar region, and in development it travels downward. When once it has joined a vertebra it never leaves it. The junction of the spine and the ilium occurs about the end of the fifth week. No chondrification has yet occurred, but there is no subsequent change in segmentation. Even at this early period the thoracic vertebræ are differentiated from the others. Consequently an increase or decrease in the number of thoracic vertebræ is not necessarily determined by the point at which the ilium stops in its migration tailward, but presumably depends on an error of segmentation (Dwight, Fischel).

Speaking broadly, these variations may be regarded as being variations (a) in a cranial direction, (b) in a caudal direction; in the former all the regional boundaries are placed higher, there being only six cervical vertebræ; in the latter the regional boundaries are lower than normal. The vertebræ at the regional boundaries are called "transitional vertebræ" and have the features of both regions.

The present condition as to the meaning of these variations is expressed by Dwight as follows: "The cause of the original error is as yet undetermined, but

<sup>1</sup> "Numerical Variation in the Human Adult and Embryo." "Anat. Anz.," Bd. xxv, 1904.



there is no reason to suppose that it is either hereditary or a step toward the future."<sup>1</sup>

### SURFACE ANATOMY OF THE BACK.

The position of the spine in the median line of the body is indicated on the normal back by a longitudinal furrow (median furrow) extending from the occipital bone to the sacrum. The lower end of the furrow corresponds to the interval between the fifth lumbar vertebra and the sacrum. In the cervical region this furrow lies between the trapezii and complexi, and in the dorsal and lumbar regions it lies between the erector spinæ muscles. It is usually most marked in the upper lumbar and lower dorsal regions.

*Identification of Vertebrae.*—In this median furrow the spinous processes of the lower cervical vertebrae can be felt; in a poorly developed individual they can be seen in the erect position, and in one well developed in forward bending. The upper cervical vertebrae lie too deeply to be either seen or felt. The spinous process of the *seventh cervical vertebra* is usually quite prominent, though that of the first thoracic is still more so. In proceeding downward the root of the spine of the scapula should be found opposite the spinous process of the *third dorsal vertebra*, and the inferior angle of the scapula opposite that of the *seventh dorsal vertebra*. The spine of the *fourth lumbar vertebra* is on a level with the highest points of the iliac crests. The spinous process of the fifth lumbar vertebra is very short, and usually forms a slight depression instead of a prominence. The *third sacral vertebra* is on the line drawn between the posterior superior spines of the ilium. The *twelfth dorsal vertebra* is found by counting down from the seventh dorsal and up from the fourth lumbar vertebra, and any vertebra may be found in this way. Of these methods the latter is the more reliable. In the dorsal region the obliquity of the spinous processes causes the tip of each to be opposite the body of the vertebra next below it. So the spine of the second dorsal vertebra corresponds to the head of the third rib, but the eleventh and twelfth dorsal spines are opposite the heads of the eleventh and twelfth ribs. The spinous processes of the lumbar vertebrae are opposite the lower parts of the corresponding bodies and the discs below them.

In the adult the spinal cord ends at the lower border of the first lumbar vertebra; in children the cord terminates at the lower border of the third lumbar vertebra.

*Muscles.*—The outline of the neck posteriorly is formed by the

<sup>1</sup> Rosenberg: "Morph. Jahrb.," xxvii, S. 1-188.



trapezii and underlying muscles. The surface of the shoulder is shaped by the deltoid and the muscles underlying the trapezius. The posterior border of the axilla is formed by the latissimus dorsi, which also takes part in forming the contour of the lower part of the back. In action the anterior edge of the latissimus dorsi may be seen as a fold extending from the crest of the ilium to the axilla. The erector spinæ muscles form a rounded prominence longitudinally on either side of the spine in the lumbar region.

The following table from Gray's "Anatomy" gives the relation of the spines of the vertebræ to important organs:

TABULAR PLAN OF PARTS OPPOSITE THE SPINES OF THE VERTEBRÆ (GRAY).

|              |  |
|--------------|--|
| CERVICAL ... | { 5th. Cricoid cartilage. Esophagus begins.<br>7th. Apex of lung: higher in the female than in the male.   |
| DORSAL ..... | { 3d. Aorta reaches spine. Apex of lower lobe of lung. Angle of bifurcation of trachea.<br>4th. Aortic arch ends. Upper level of heart.<br>8th. Lower level of heart. Central tendon of diaphragm.<br>9th. Esophagus and vena cava through diaphragm. Upper edge of spleen.<br>10th. Lower edge of lung. Liver comes to surface posteriorly. Cardiac orifice of stomach.<br>11th. Lower border of spleen. Renal capsule.<br>12th. Lowest part of pleura. Aorta through diaphragm. Pylorus. |
| LUMBAR.....  | { 1st. Renal arteries. Pelvis of kidney.<br>2d. Termination of spinal cord. Pancreas. Duodenum just below. Receptaculum chyli.<br>3d. Umbilicus. Lower border of kidney.<br>4th. Division of aorta. Highest part of ilium.   |

*Points for Lateral Corrective Pressure.*—The points at which corrective side pressure may be applied to the spine are determined by anatomical conditions. The structures lying on both sides of the spine in the cervical and lumbar regions prevent the use of lateral corrective force in these regions. In the dorsal region side pressure on the ribs is effective on the vertebræ, but it cannot be exerted on the upper vertebræ higher, of course, than the axilla. The anterior border of the axilla is formed by the pectoralis major muscle and is in the line of the fifth rib. This rib articulates with both the fourth and fifth dorsal vertebræ. Although with the arm nearly at the side the third rib may be reached by the exploring hand, side pressure on the thorax cannot be exerted efficiently above the fourth or fifth rib.



## CHAPTER II.

### THE MOVEMENTS OF THE SPINE.<sup>1</sup>

The movements of the spine are generally accepted as being four in number:

(1) Flexion (forward bending); (2) hyperextension (backward bending); (3) lateral bending (side bending); (4) torsion or rotation.

Although this classification is usually found in the books, it has been often recognized that torsion is in some way associated with lateral bending. That lateral flexion probably does not exist as a pure movement has for some time been recognized by some if not all anatomists, and has been taught for some years by Professor Thomas Dwight. As long ago as 1844 Henry J. Bigelow wrote: "The principle of torsion is illustrated by bending a flat blade of grass or a flat, flexible stick in the direction of its width. The center immediately rotates upon its longitudinal axis to bend flatwise in the direction of its thickness. In the same way the spine, laterally flexed, turns upon its vertical axis to yield in its shortest or anteroposterior diameter." Occasional references are found to the association of torsion with lateral flexion, but no general recognition of the relation between the two has existed. The movements of the spine should therefore be considered as three in number: (1) Flexion; (2) extension; (3) side bending, rotation.

The human spine is not an extremely flexible body taken by itself; much of its apparent flexibility is due to accessory movements between the spine and the pelvis and the head. An extreme forward flexion, *e. g.*, in the living model or the intact cadaver, with the flexed head, the drooping shoulders, and the rotated pelvis, implies a greater curve than the spine itself possesses. It is surprising to see in the cadaver how little actual mobility is possessed by the three regions of the spine considered separately, or by the whole spine.

The application of this is obvious without extended comment. If active or passive exercises are given which are intended to take effect upon the spine alone and to be effective there, the pelvis must be fixed. If this is not done, part of the muscular force is used in displacing the pelvis to the opposite side to balance the body, and the movement becomes a general and not a spinal one.

<sup>1</sup> R. W. Lovett: "Bos. Med. and Surg. Jour.," June 4, 1900, Oct. 31, 1901, March 17, 1904, Sept. 28, 1905; "Amer. Jour. of Anat.," ii, 4, 457.



## FLEXION (FORWARD BENDING)

Is a pure anteroposterior movement without perceptible rotation. It is the most evenly distributed of the spinal movements, and in extreme flexion the outline of the tips of the spinous processes forms a curve approaching the arc of a circle. Most of the movement is accomplished in the lumbar region, which in extreme flexion loses most of its forward convexity, but in the observations made was not observed to become convex backward.

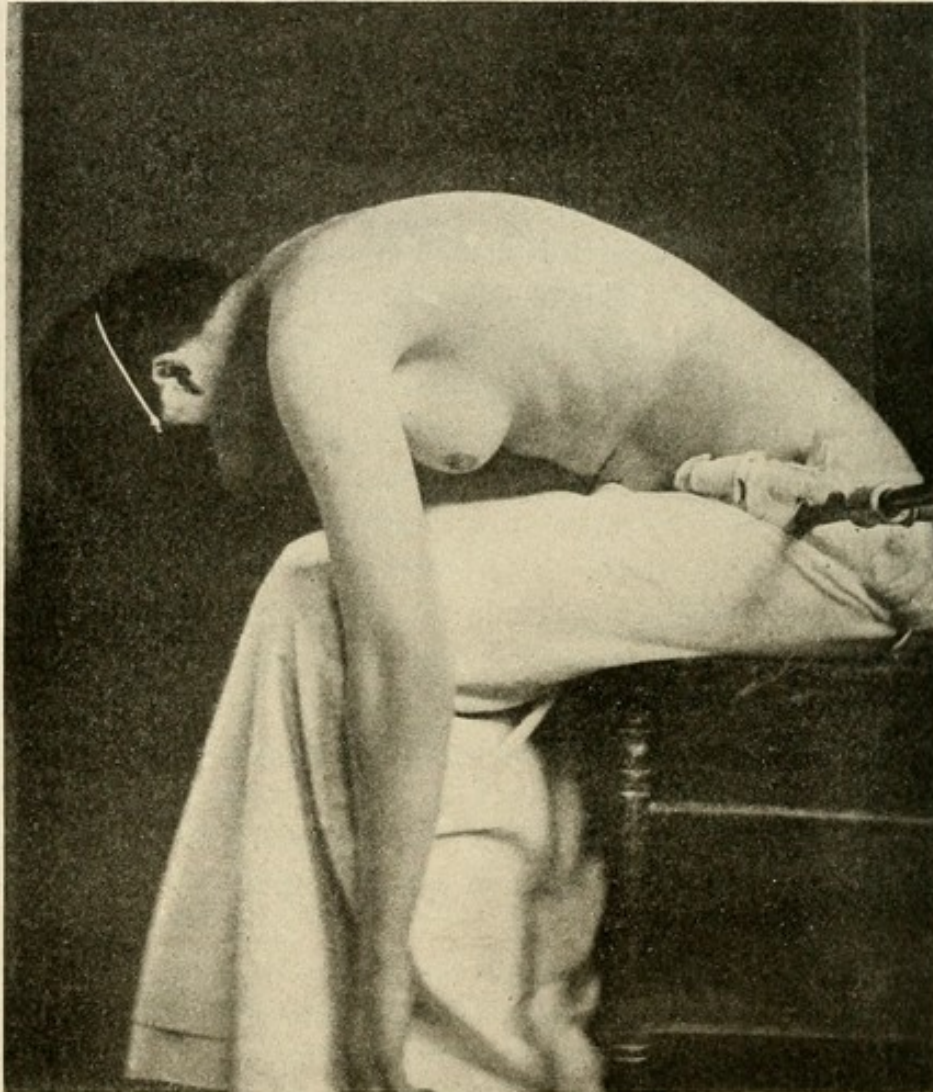


FIG. 18.—FLEXION OF THE SPINE IN THE MODEL.

The dorsal region in extreme flexion becomes decidedly more convex than in the upright position. The twelfth dorsal vertebra takes part in flexion more as a lumbar than as a dorsal vertebra, and free movement occurs below it and fairly free movement between the eleventh and twelfth vertebræ.

The cervical region cannot be accurately observed or measured in the model. In the cadaver it dries so rapidly that no conclusions can be drawn beyond the statement that its forward convexity may be obliterated by forcible flexion with the hands.



The most marked flexion of the spine may be obtained by having the model sit cross-legged and bend forward with the chest between the knees. Extreme passive flexion with the model lying on the side is not so great as that obtained by flexion in the cross-legged position.

In flexion the distance of the seventh cervical vertebra from the sacrum when

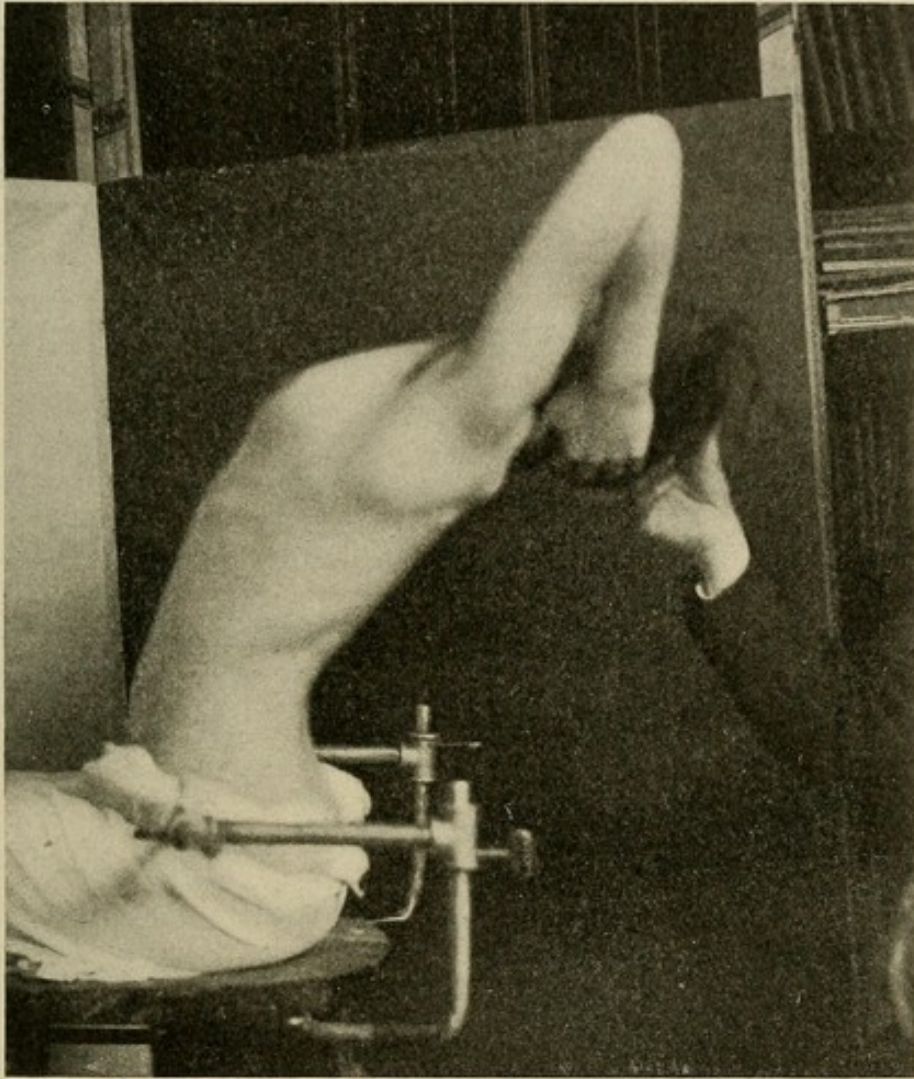


FIG. 19.—HYPEREXTENSION IN THE MODEL.  
The head is supported to secure steadiness.

measured along the spinous processes is increased over the same measurement taken in standing or lying.

There seems to be no constant difference in the amount of flexion obtained in the standing and sitting positions, the resultant curve being practically the same. The chief difference between flexion in the model and cadaver seems to consist in a greater relative participation of the dorsal region in flexion in the model.

Measurements and tracings of the spine in the model and in children show the relaxed sitting position to be one of slight flexion.



## HYPEREXTENSION (BACKWARD BENDING).

Hyperextension is a pure anteroposterior movement of the spine without perceptible rotation. It is not an evenly distributed movement, but occurs almost wholly in the lumbar and lower two dorsal vertebræ. A tracing taken over the spinous processes in extreme hyperextension in outline resembles a hockey stick. The dorsal region is but little affected, being slightly straightened by hyperextension. The bending reaches to about the tenth dorsal, the upper dorsal region showing but little diminution in the physiological curve, the twelfth dorsal vertebra, and, to a certain extent, the eleventh, behaving as do the lumbar vertebræ in hyperextension. The character of the curve obtained in marked hyperextension is practically the same, whether it is obtained by active or passive means, and whether the model




FIG. 20.—HYPEREXTENSION IN THE CADAVER.

lies on the face or on the side, or stands, or sits. The column of bodies alone shows the same character and distribution of the movement as does the intact spine of the cadaver. The illustration in this case shows the characteristic rigidity of the dorsal region to hyperextension.

In hyperextension, the distance from the seventh cervical vertebra to the sacrum, measured over the spinous processes, is decreased from the same measurement taken in the erect position.

## LATERAL FLEXION (SIDE BENDING).

Lateral flexion of the spine apparently does not exist as a pure movement, but is to be considered as one part of a compound movement, of which twisting or rotation forms the other part.

In describing this side bending it must be stated that the character and distribution of the movement vary widely according to the degree of flexion or extension of the spine when the side bending is made. It is also affected if the spine is twisted before it is bent to the side. In other words, there is no one type of spinal side bending as there are types of flexion and extension, but the character and distribution of the movements are wholly dependent upon the anteroposterior position of the spine.

Side bending will first be considered alone without regard to the rotation caused by it, and then the rotation accompanying each kind of side bending will be described.

**Side bending in lying on the face** shows a more evenly distributed lateral curve than does that in the erect position. The character of the curve does not change essentially when the shoulders and pelvis are held and the middle



of the trunk pushed to one side. The curve in this position of the spine is greater in the upper lumbar vertebrae and in the two lower dorsal than in the upper part of the spine.

*Rotation Accompanying Side Bending Lying on the Face.*—With the cadaver lying flat on the face on the table no rotation in side bending was found by v. Meyer and in some experiments by Schulthess; it was, however, found by Benno Schmidt.

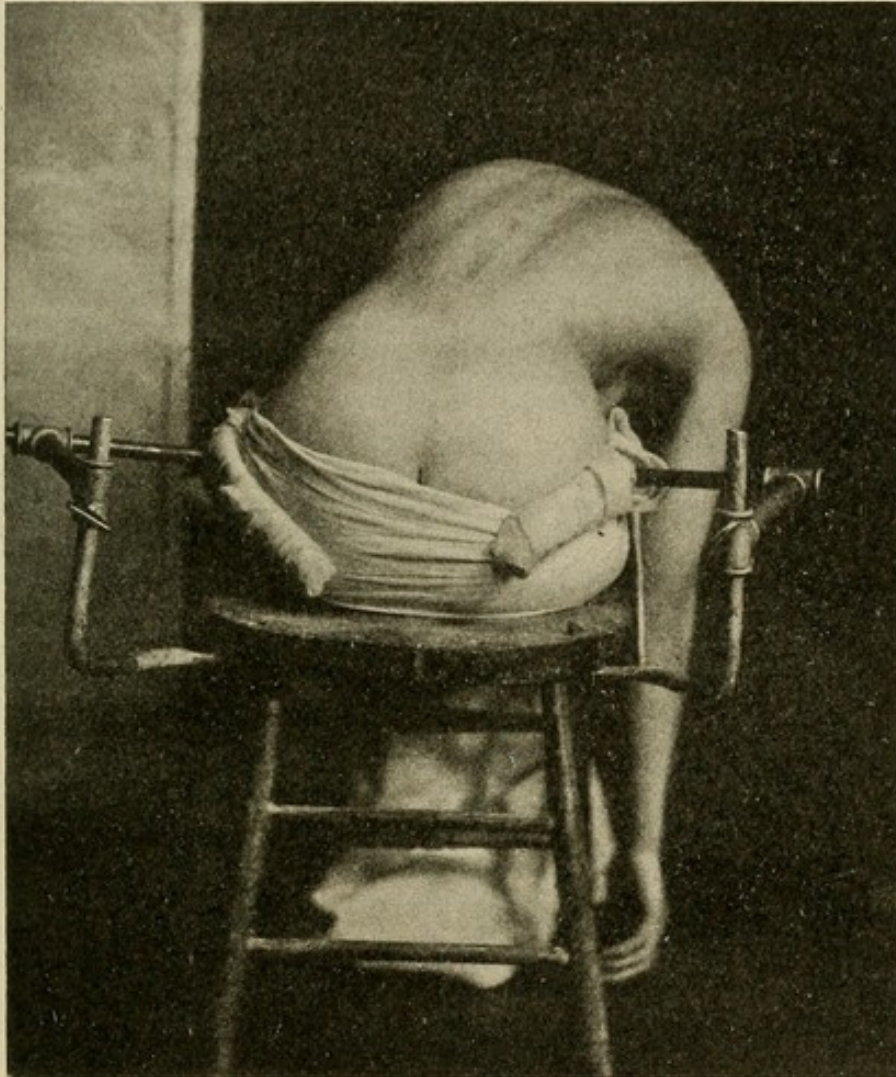


FIG. 21.—SIDE BENDING TO THE RIGHT IN THE FLEXED POSITION OF THE SPINE IN THE MODEL.

A lateral curve convex to the left is formed and the vertebral bodies have turned to the left, as shown by the elevation of the left side of the back.

With the cadaver lying prone on a table the conditions, of course, are against rotation, the thorax and shoulders being to a certain extent held against it by the surface of the table. No perceptible rotation is noted in slight side bending under these conditions, but the vertebral bodies turn to the concave side in marked side bending. In the model lying flat on a table one side of the chest is felt to press on the table harder than the other in moderate side bending. The point is not of great importance, as the practical problem is that of the behavior of the weight-bearing spine.



Side bending in the flexed position of the spine is a more evenly distributed movement in which the dorsal region participates more and the lumbar region less than in the erect position. The greatest deviation from a line connecting the two ends of the spine occurs at about the eighth dorsal vertebra in both cadaver and model. In short, side bending occurs higher in the spine in flexion than in any other position, the lumbar region being comparatively locked against side bending

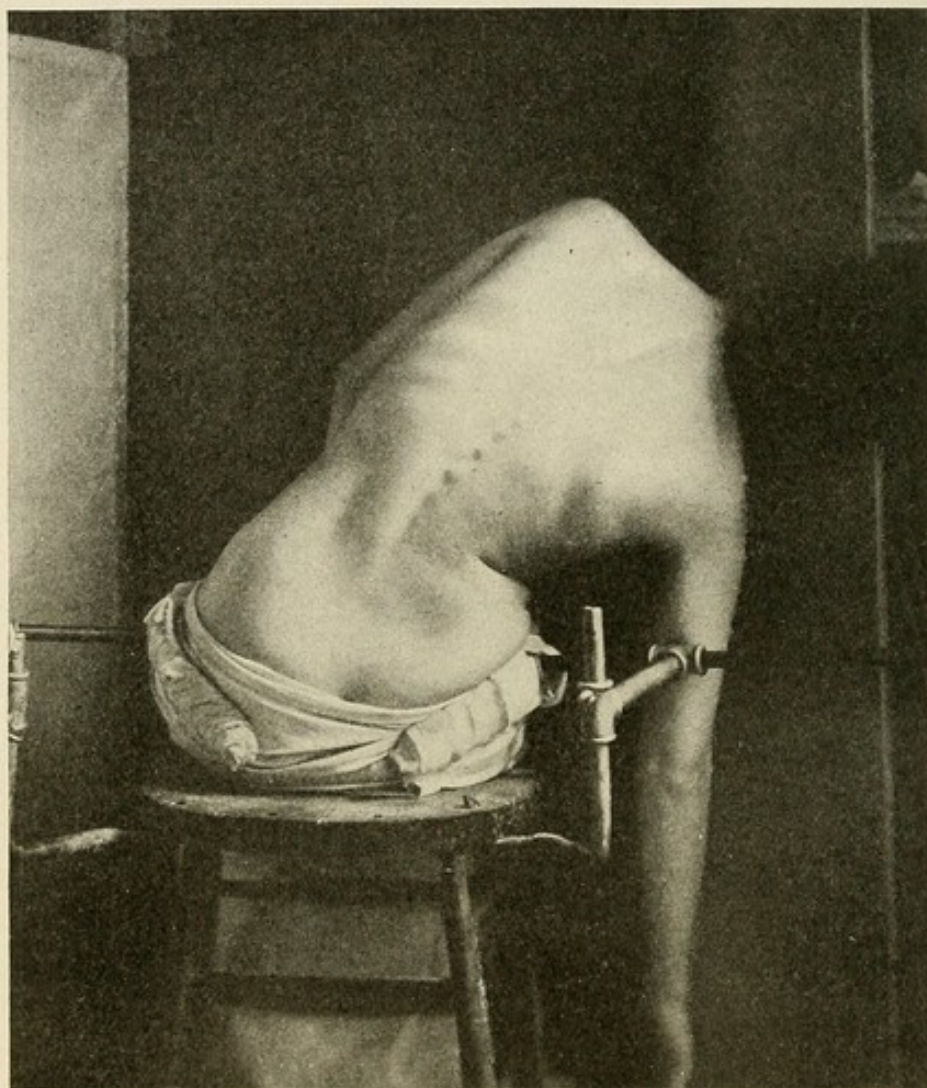


FIG. 22.—SIDE BENDING IN THE UPRIGHT POSITION OF THE MODEL.  
The movement is chiefly located at the dorsolumbar junction.

by the flexed position. The more marked the flexed position, the higher in the spine is the side bending localized.

*Rotation Accompanying Side Bending in Flexion.*—In the flexed position of the spine, side bending is accompanied by rotation of the bodies to the convexity of the lateral curve. This rotation occurs chiefly in the dorsal region. Each vertebra twists upon the one below it in the long axis of the spine, the body turning in one direction and the spinous process in the other.

In side bending of the model in the flexed position the active movement is accompanied by a much greater degree of rotation than is the passive movement,



the addition of muscular force in this movement seeming to accentuate the element of twisting.

**Side Bending in the Erect Position.**—In the cadaver the side bending is most marked below the tenth dorsal vertebra, and the dorsal region shares but slightly. The lumbar region is most affected in its upper part, but shares to some extent throughout. The whole dorsal region takes some part in the movement, but the dorsal region, except its lower part, compared to the lumbar, is resistant to side bending. Side bending in the erect position is, therefore, largely a movement occurring in the neighborhood of and below the lumbar dorsal junction. It shows the same characteristics in the cadaver, the model, and the child, except that in the two last named the dorsal region takes a greater relative part than in the cadaver




FIG. 23.—SIDE BENDING IN THE UPRIGHT POSITION OF THE CADAVER, SHOWING THE SAME CHARACTERISTICS AS IN THE MODEL.

The column of vertebral bodies alone behaves in side bending in all positions in the same way as do the intact cadaver, the model, and the child.

*Rotation Accompanying Side Bending in the Erect Position.*—In this position side bending causes the rotation of the bodies of the vertebræ to the concave side of the lateral curve. It occurs lower down in the spine than in the flexed position. The dorsal region participates less and the lumbar region more in the movement.

**Side Bending in the Hyperextended Position of the Spine.**—With the spine of the cadaver, model, or child hyperextended, the side bending becomes a sharply limited movement, localized low down in the spine and occurring almost wholly below the eleventh dorsal vertebra, becoming, therefore, essentially a lumbar movement. The dorsal region bends as a whole upon the lumbar and rocks over to the side practically unchanged, being locked against side bending by the hyperextended position. Side bending, therefore, is situated highest in the flexed position,



lower down in the erect position, and lowest in hyperextension in the model, cadaver, and child. In side bending in all positions the twelfth dorsal vertebra behaves as a lumbar, not as a dorsal, vertebra.

*Rotation Accompanying Side Bending in the Hyperextended Position.*—This is a sharply limited movement occurring in the lumbar region including the twelfth dorsal as functionally a lumbar vertebra. The thorax rocks over to the side unchanged, and the rotation of the bodies is to the concave side of the lateral curve.

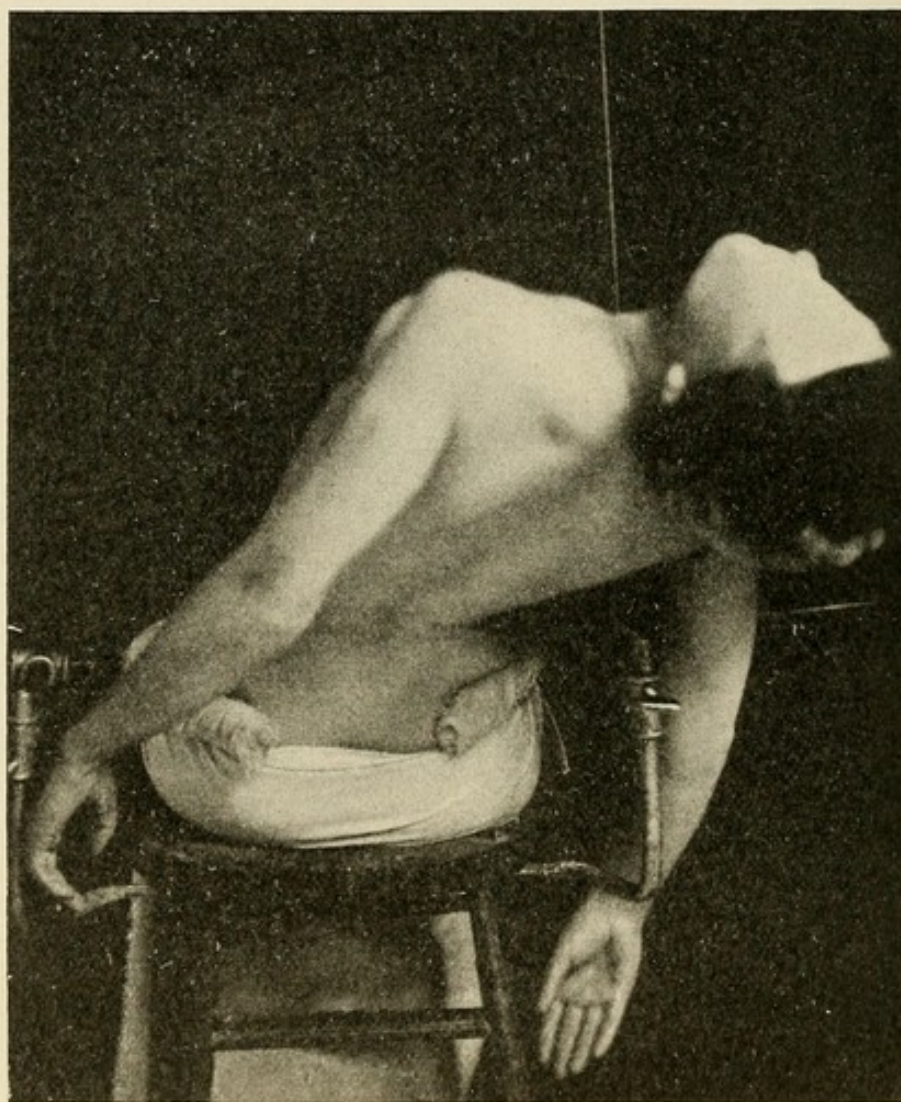


FIG. 24.—SIDE BENDING TO THE RIGHT IN THE HYPEREXTENDED POSITION OF THE SPINE IN THE MODEL.

The head is supported to secure steadiness.

The rotation accompanying this type of side bending is essentially a different kind of motion from that occurring in side bending in flexion, as it is less distributed through the spine and is of a more decided character. The column of bodies alone rotates in essentially the same way as does the intact spine in side bending in the erect and hyperextended position.

Rotation accompanying side bending is, therefore, of a different type in the flexed position of the spine from what it is in the erect or hyperextended position.



In the flexed position the lumbar region is locked against side bending, and the side bend and rotation occur chiefly in the dorsal region and conform to the dorsal type, *i. e.*, the bodies turn to the convexity of the lateral curve. In side bending occurring in the erect or hyperextended position, however, the lumbar region and




FIG. 25.—SIDE BENDING TO THE RIGHT IN HYPEREXTENSION IN THE COLUMN OF VERTEBRAL BODIES.

The same characteristics are shown as in the previous figure.




FIG. 26.—SIDE BENDING TO THE RIGHT IN THE HYPEREXTENDED POSITION OF THE SPINE IN THE CADAVER.

The movement occurs chiefly at and below the dorsolumbar junction, and the bodies of the vertebrae turn to the right, as shown by the pins. The lateral curve is convex to the left.

lower dorsal region is the chief seat of the movement, and as in all side bends in the lumbar region the bodies of the vertebrae turn to the concavity of the lateral curve.

## ROTATION.

Rotation or twisting of the spine is to be considered as part of a compound movement of which side bending forms the other part. For purposes of simplicity the rotation element of the movement will be considered by itself. Under ordinary conditions it is essentially a movement of the dorsal and cervical regions in which the lumbar vertebrae take but little part except in hyperextension and with the use of traction. The lumbar vertebral region possesses some power of rotation, as has been generally observed.

**Rotation in the Erect Position.**—Rotation is freest in the erect position and is situated in the cervical and dorsal regions, reaching its maximum at the top of the cervical column and extending down the spine to the lower dorsal region,



where it disappears. With very forcible rotation applied to the top of the column in the cadaver, the first and even the second lumbar vertebræ may be rotated. The rotation in this position is accompanied by a side bend of the rotated region away from the side to which the bodies of the vertebræ turn. If the rotation is to the right, it is accompanied by a bend convex to the left and vice versâ. In the model an active rotation to the right is accompanied by a displacement of the trunk to the left side and vice versâ. If traction is applied to the head of the erect

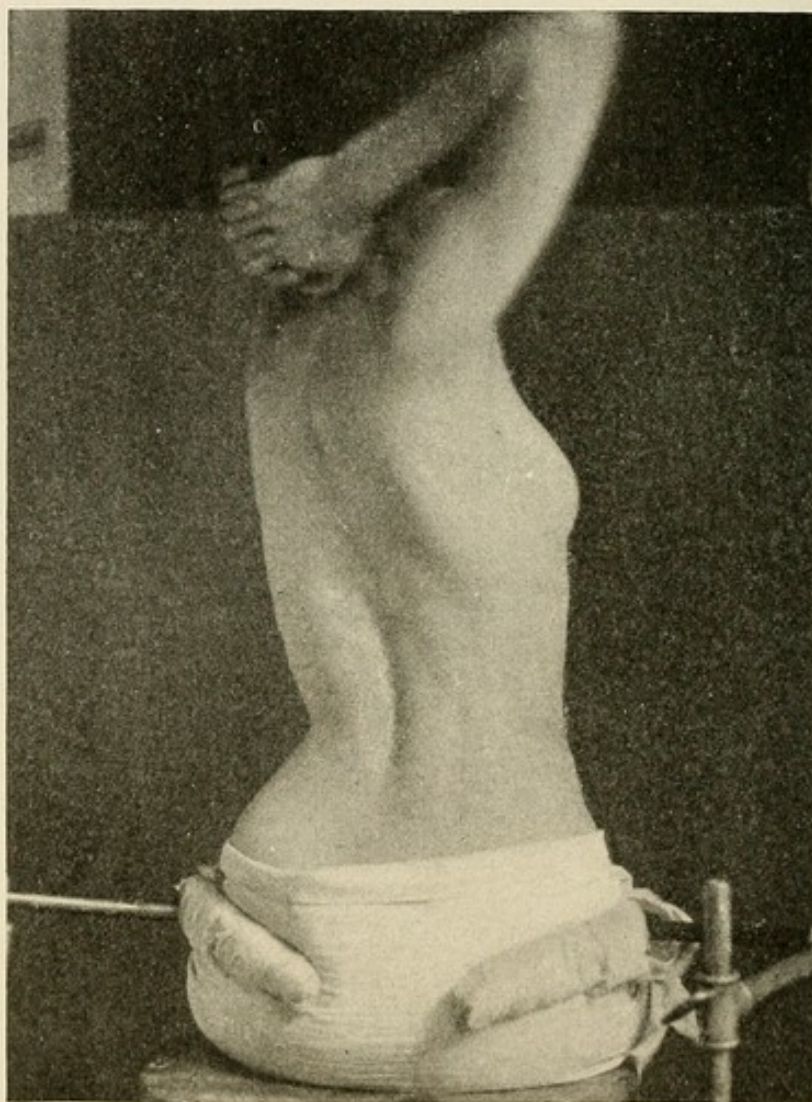


FIG. 27.—ROTATION OF THE MODEL, FACE TO THE RIGHT, CAUSING A DORSAL LATERAL CURVE CONVEX TO THE LEFT AND A DISPLACEMENT OF THE TRUNK TO THE LEFT.

cadaver, forcible twisting of the head results in rotation of the lumbar vertebræ including the fourth.

**Rotation in the Flexed Position.**—Rotation in the flexed position of the spine occurs chiefly in the cervical and upper dorsal spine, the lower dorsal and lumbar region seeming locked against rotating forces by the flexed position. The more extreme the flexion the more markedly in cadaver, model, and child is the rotation restricted to the cervical and upper dorsal spine.



**Rotation in the Hyperextended Position.**—In hyperextended positions rotation with moderate manual force occurs as a twisting of the whole thorax on an axis in the dorsolumbar region, the upper and middorsal regions apparently being locked against rotation by hyperextension. The site of rotating movement in this position is, therefore, in the one or two vertebræ above and the one or two vertebræ below the dorsolumbar junction.

Rotation, therefore, is located high in flexed positions, lower in erect positions, and is situated lowest and is of a different type, being more sharply localized, in hyperextended positions. In the column of bodies alone rotation possesses the same characters as does the intact column.

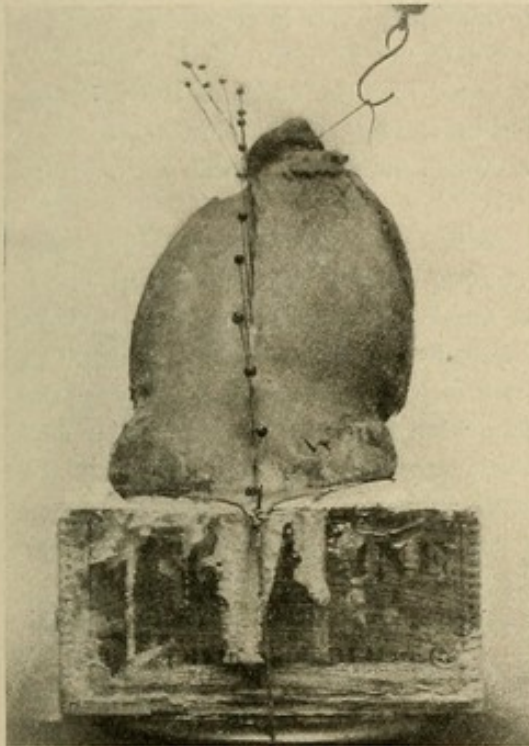


FIG. 28.—ROTATION OF THE SPINE OF THE CADAVER, FACE TO THE RIGHT IN THE FLEXED POSITION OF THE SPINE.

The movement is seen to be located in the upper part of the column by the deviation of the pins.




FIG. 29.—ROTATION OF THE SPINE OF THE CADAVER, FACE TO THE RIGHT, IN THE HYPEREXTENDED POSITION.

The movement is seen to occur in the lower part of the spine by the rotation of the pins.

*Side Bends Accompanying Rotation.*—A lateral deviation of the spine accompanies all rotations. It is situated at the site of the rotation and is convex to the right when the rotation is to the left and vice versa. In the erect position rotation causes a marked side curve in the dorsal region.

**Reasons for Torsion.**—It is obvious from these experiments that there must be some fundamental reason for the constant occurrence of one type of torsion for side bendings in flexion and the occurrence of another type in extension, as well as for the constant association of torsion with side bending. The vertebral column is a flexible rod capable of bearing great weight. It is not equally flexible in all directions, but it is, of course, capable of some movement in all planes, and, as such, should come under the control of the laws governing flexible rods in gen-



eral. The extent of any of the movements of the spine is, of course, greatly influenced by the shape of the vertebral bodies, the curves of the spine, the character of the articular processes, the resistance of the ligaments, and the relative strength of the muscles.

From the mechanical point of view, torsion results from any motion of a straight flexible rod in which all the particles do not move in parallel planes. Consequently, if such a rod is bent in two planes at the same time, torsion must inevitably occur. The vertebral column is not a straight flexible rod, but one bent in the anteroposterior plane by a series of gentle curves; side bending must therefore inevitably lead to torsion, because it means bending in two planes. Nor does the fact that the intervertebral discs permit motion in all directions affect the question, because from a mechanical point of view the vertebral column behaves in general as it would if it were a homogeneous flexible rod, and one does not have to wait for torsion to occur until the intervertebral discs are compressed and the edges of the vertebræ come into contact, for, from a mechanical point of view, the torsion begins with the beginning of the side bending. It therefore seems very unlikely that pure lateral flexion of the spine ever exists.

A strip of sponge rubber, half an inch in diameter and fourteen inches long, rotates in the same way that the vertebral column does in the same position. A lateral curvature, in what corresponds to the flexed position of the spine, may be produced in the rubber strip following the same rule of rotation seen in life; that is, the front of the rod turns toward the convexity of the lateral curve. An artificial lateral curvature in the rubber strip, made in what corresponds to the extended position of the spine, results in a reverse rotation to that from the rotation of the flexed position. A piece of rattan, a piece of rubber tubing, a strip of sponge rubber, round or square, the backbone of a fish, or the backbone of a cat, behave all in the same way, and rotate in the same direction as does the human spine.

**Articular Processes.**—Although it is easy to understand that the column of vertebral bodies by itself might easily behave as a flexible rod, yet the articular processes cannot be left out of account. They must be an important factor in determining torsion, and they must do one of two things. Either they must fall in with the behavior of the flexible column of bodies and serve to carry out the rotation which would occur without them, or they must obstruct or reverse the rotation which would occur in the column of vertebral bodies alone. Experiments seem to show that the articular processes merely serve to accentuate the same rotation that would be present if the column of vertebral bodies were by itself.

Two vertebral columns, which had been previously used and which had conformed to the usual rule, were prepared for experiment by removing the column of bodies by cutting through the pedicles. The columns experimented upon then consisted of laminæ and articular processes with their ligaments. The ribs were not removed from these columns. These could no longer be regarded as flexible rods, and were only anatomical preparations to demonstrate just what part in rotation the articular processes would play if left to themselves.

Each of these spines was then placed in a vise and pulled to the side. When the spine was hyperextended and pulled to the left, rotation occurred of the same type as in the intact column in the similar position, a rotation of the ribs backward on the side of the concavity. That is, the articular processes alone do the same thing in side bending in the extended position that the intact column does.

In side bending from the flexed position, however, the spine without bodies



rotates in just the reverse direction from that of the intact spine in the same position, the rotation of the ribs being backward on the side of the concavity. This, of course, suggests that in side bending in the extended position the articular processes are active, but that in flexed positions they are not.

To see if this state of affairs really existed, a spine which had been used and which had followed the rule was sawed longitudinally in such a way as to divide each articular process in the long axis of the spine. The portion on the outer side of this cleft was removed, giving a view of each articulation. The spine was then flexed, and it was found that as moderate flexion began the articular joint surfaces in the dorsal region, which was the particular field observed, began to separate, and in extreme flexion were separated by an interval of perhaps one thirty-second of an inch. As the spine was extended they seemed to come into close contact at about the point where the flexion rotation changes to the extension rotation. In marked extension they were firmly in contact.

The conclusion from this is that the column of vertebral bodies alone, without articular processes, rotates in just the same way in side bending, in flexion, and extension that the column does with articular processes present; that in flexion they are not sufficiently in contact to determine the rotation, but that in extension they are in contact, and are the active factors in determining the rotation which occurs in extension. That rotation is, however, in the same direction that it would be if the column consisted of vertebral bodies alone. They apparently serve to accentuate and carry out the behavior of a flexible rod in general, although they undoubtedly aid in preventing pure lateral flexion of the spine.

#### THE CERVICAL REGION.

**Flexion.**—It is possible to straighten the anterior physiological curve. Much of the apparent forward flexion in the cervical region in life is evidently due to the motion between the occiput and the atlas.

**Hyperextension.**—The physiological curve can be increased to a certain extent.

**Side Bending.**—Side bending is uniformly distributed throughout the cervical region and is accompanied by rotation of the bodies of the vertebræ to the concavity of the lateral curve, as in the lumbar region. Rotation and side bending seem always associated.

**Rotation.**—Rotation is extremely free between the first and second cervical vertebræ, but for the rest of the region it is limited. Rotation is accompanied by a side bend convex to the side opposite to which the bodies of the vertebræ turn; that is, in a right rotation the curve is convex to the left.

#### DORSAL REGION.

The dorsal region is the least mobile part of the spine as a whole. The twelfth dorsal vertebra from the point of view of function must be regarded as a lumbar vertebra and not as part of the dorsal region.

**Flexion.**—The dorsal spine already convex backward can be made somewhat more convex by forward bending, but the extent of the movement is not great and by no means comparable to the same movement in the lumbar region.

**Hyperextension.**—Hyperextension is a motion of very slight extent in the dorsal region. It consists of a diminution of the backward convexity and is most noticeable in the lower half of the region.



**Side Bending.**—Side bending of the dorsal region is a fairly evenly distributed movement of slight extent, presenting an even curve which is greatest in the mid-dorsal region. It is freest in the erect position or lying on the face. It occurs less markedly in flexed positions and least in hyperextension. Side bending here is always accompanied by rotation of the bodies of the vertebræ to the convex side of the lateral curve. With the upper end of the column free the rotation occurring in flexion is very marked in cadavers from which the sternum has been removed.

**Rotation** is the most marked of dorsal movements. It reaches its greatest extent in the upper dorsal vertebræ and diminishes toward the lower end of the region. In a rotation of moderate force in the upright position it extends to and includes the seventh or eighth dorsal vertebra. Rotation of this region is less in flexion than in the erect position and does not extend so far down. In hyperextension it is much limited and in extreme hyperextension in the cadaver the dorsal rotation movement seems to be obliterated.

Rotation is accompanied always by side bending, the lateral curve being convex to the side away from which the bodies of the vertebræ turn. In a rotation of the top of the column to the left the lateral curve is to the right and vice versa.

The practical points to be borne in mind in the study of the dorsal region are the facts that rotation is freer than side bending, that hyperextension is extremely limited, and that the rotation of the vertebræ in side bending in the dorsal region is always toward the convexity of the lateral curve.

### LUMBAR REGION.

**Flexion** in the lumbar region is a movement of much freedom, but the physiological curve in the adult cadaver has not been obliterated in any case observed by the writer.

**Hyperextension** as a general spinal movement is essentially a lumbar motion and in that region is an evenly distributed bend.

**Side bending** is a free movement in the lumbar region and forms in the erect position a very evenly distributed curve. It varies markedly in the flexed, erect, and hyperextended positions. It is greatest in the erect position and least in extreme flexion.

The rotation accompanying side bending in the lumbar spine is always with the bodies turning to the concavity of the lateral curve; in a bend convex to the left the vertebral bodies turn to the right. This is to be contrasted with the opposite rotation occurring in side bending in the dorsal region.

**Rotation** in the lumbar region is extremely limited. It is diminished by extreme hyperextension and is least or absent in extreme flexion. Under natural conditions the rotation is greatest in the erect position, but by the addition of traction in that position it is decidedly increased.

The lumbar region possesses marked mobility in flexion, hyperextension, and side bending, and but little in rotation. Side bending is more free than rotation in contradistinction to the relation of these two movements in the dorsal region. The rotation which accompanies side bending is also the opposite of that occurring in the dorsal region. In the lumbar region the bodies turn toward the concavity of the lateral curve, *i. e.*, in a bend convex to the left the bodies turn to the right. The lumbar region must be considered in function as including the twelfth dorsal vertebra.



CERTAIN CONCLUSIONS AS TO THE MOVEMENTS OF THE THREE  
REGIONS OF THE SPINE.

1. In the lumbar region flexion diminishes mobility in the direction of side bending and rotation, and extreme flexion seems to lock the lumbar spine against these movements.
2. In the dorsal region hyperextension diminishes mobility in the direction of side bending and rotation. Extreme hyperextension seems to lock the dorsal spine against these movements.
3. In flexion of the whole spine side bending is accompanied by rotation of the vertebral bodies to the convexity of the lateral curve, the characteristic of the dorsal region.
4. In the erect position and in hyperextension of the whole spine side bending is accompanied by rotation of the vertebral bodies to the concavity of the lateral curve, the characteristic of the lumbar region.
5. The dorsal region rotates more easily than it bends to the side, whereas the lumbar region bends to the side more easily than it rotates.
6. Rotation in the dorsal region is accompanied by a lateral curve, the convexity of which is opposite to the side to which the bodies of the vertebræ rotate.
7. The column of vertebral bodies obeys in flexion, hyperextension, side bending, and rotation, and in the combinations of them the same rules which govern the intact spine, a fact of much significance in connection with the rotation theories of v. Meyer and Albert.



## CHAPTER III.

### MECHANISM OF SCOLIOSIS.

**Elasticity of Vertebrae and Intervertebral Discs.**—The spinal column is capable of some movement in all directions. The elasticity of the intervertebral discs is such that the ball-and-socket joint between each two vertebrae allows motion between them in any plane or direction until limited by bony contact and ligamentous or muscular tension. It also allows rotation to occur between two separate vertebrae in an approximately horizontal plane. Bone is slightly compressible, but this is not a factor of importance in contributing to vertebral flexibility.

Lange<sup>1</sup> has experimented with vertebrae at different ages, and has found that their resiliency when released from pressure is greater in adult life than in childhood, but in the former very much less compression is possible. He has further shown that cohesiveness of a vertebra is greatest in children, less in adults, and still less with advancing age. In other words, a child's vertebra may be more easily compressed but less easily torn apart than that of an adult.

Fessler gives the elasticity of intervertebral discs as perfect, inasmuch as they resume their original form after compression and they are exceedingly tough and strong. Fracture of the vertebral column through a disc will occur only under a pull exerted in the long axis of the spine. Under such conditions the separation in the cervical and lumbar regions will occur through the discs, starting at the posterior part and overcoming last the resistance in the anterior common ligament. In the dorsal region, on account of the natural kyphosis of that part of the spine, the anterior ligament will be the first to give way.

In childhood the vertebrae are largely cartilaginous, and the increasing proportion of bone, along with the diminishing proportion of cartilage, causes a decrease of flexibility from youth to adult age, aside from the fact that the flexibility of all joints is greater in youth. With old age the capability of movement of the spine is greatly lessened on account of the atrophy of the intervertebral discs.

**Loss of Height During the Day.**—It has been noticed that measurement of the height of the same individual taken in the morning and in the evening shows a decrease in the total height of the body of from 1 to 2 cm. during the day.

<sup>1</sup> "Zeitsch. f. orth. Chir.," x, 1902, 47.



Story found an average loss in height of 1.452 cm. during the day; 1.342 cm. of this loss occurred in the spine, the rest below the trunk. This point is of practical importance when exact measurement of the height is to be taken, as in individual cases the loss is much more than the average mentioned.<sup>1</sup>

This has been variously attributed to an increase of the normal physiological curves of the spine through fatigue, and to compression of the intervertebral discs due to the continuous weight supported by the spinal column in the upright position, and also to a general settling down of the whole body. Some observations not yet published, made by students of the Boston Normal School of Gymnastics, show no increase of physiological curves.

**Upright Position.**—The spine, it has been seen, is a curved, segmented, weight-bearing rod resting in unstable equilibrium on the sacrum, which forms part of a bony ring balanced on the hip-joints. Its upright position is due to a sense of balance possessed by the living individual, for in the cadaver in the upright position no such erect attitude obtains on account of the absence of muscular action. This sense of balance expresses itself in a muscular contraction by which the living individual keeps his center of gravity over the center of support. It is reflex and instinctive, and the individual has no knowledge of it as such any more than he has of the mechanism of breathing or swallowing.

The living individual, therefore, keeps his spine erect, first, because he has a sense of balance, and, second, because he has a muscular system which responds to his instinctive nervous impulses and carries out of itself the necessary muscular adjustment which is too complicated to describe or formulate. This instinctive sense of balance and equilibrium must be regarded as an attribute of the erect living individual, and must be given a place in the study of scoliosis. It is effective in two directions:

1. The erect person instinctively strives to keep the head approximately over the middle of the pelvis, that is, in the sagittal or antero-posterior median plane of the body.
2. The erect person instinctively strives to keep the eyes straight to the front and the shoulder-girdle approximately in the same plane as the pelvis, *i. e.*, in the frontal or lateral plane of the body.

This adjustment, especially the element which seeks to keep the shoulder-girdle in the same plane as the pelvis while disturbances

<sup>1</sup> T. A. Story: "Amer. Jour. of Orth. Sur.," 1, 2, page 234.



twisting the column below are taking place, is an important factor in explaining the phenomena of scoliosis, as will be seen later.

The body is, however, not a firm mass, but consists of segments joined together, one segment resting upon the other, and firmly connected by a tube made up of muscles, fasciæ, and integument.<sup>1</sup> Since to maintain the erect attitude the line of gravity must pass through the base of support, so in all positions in which balance is maintained there is a constant equilibration by means of shifting segments.

If the pelvis of a cadaver is raised on the right side and the upright



FIG. 30.—THE RIGHT SIDE OF THE PELVIS OF THE CADAVER IS RAISED AND THE UPPER PART OF THE SPINE FALLS TO THE LEFT, MAKING A LATERAL CURVE CONVEX TO THE RIGHT.

spine is left free to move, the top of the column falls to the left and the spine is curved convex to the right. This is the position induced by gravity. If, on the other hand, the right side of the pelvis of a living model is raised and the upright spine is left free to move, the top of the column remains upright and the spine is curved in the opposite direction, convex to the left. This is the position of balance overcoming the position induced by gravity. The sense of equilibrium has worked against the force of gravity and has reversed the position natural to the cadaver. Anything which causes any part of the body to be held in an asymmetrical position will cause a lateral deviation of some part

of the spine, because a straight, erect spine in the sagittal plane is possible only when the person stands on both feet or sits erect with the arms in similar positions and the head pointing straight ahead. Every step, every raising of the arm, every tilting of the head is accompanied by a deviation of the spine from the median plane of the body: in other words, by a temporary lateral curve which disappears as the symmetrical attitude is resumed.

<sup>1</sup> Feiss: "Amer. Jour. of Orth. Sur.," iv, 1, 37.



If there is a visual error that causes the head to be held obliquely; if there is a short leg causing the pelvis to be no longer horizontal but slanted; if the muscles of one side of the back are paralyzed, there must be a constant compensation or curve which will still enable the center of gravity to be held over the center of support. When such a curved position becomes habitual for any of the reasons given or for

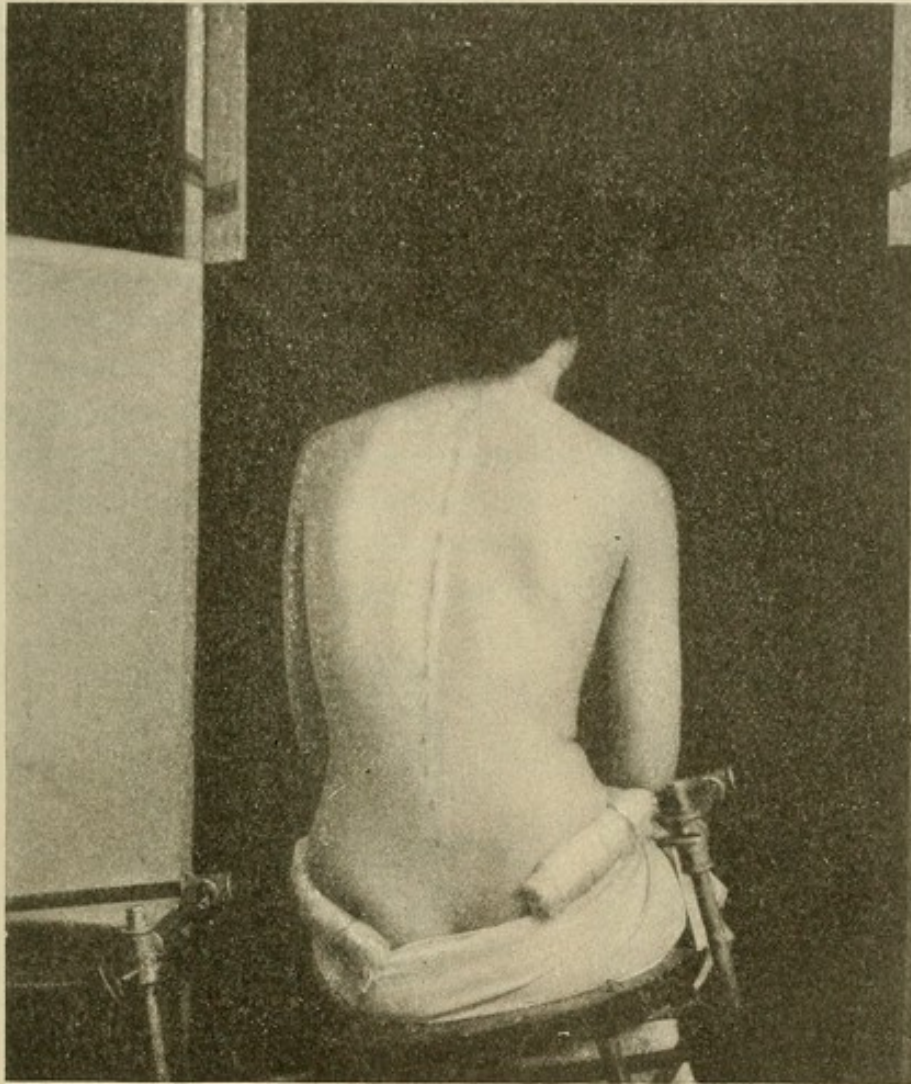


FIG. 31.—THE RIGHT SIDE OF THE PELVIS OF THE MODEL IS RAISED AND THE UPPER PART OF THE SPINE IS CARRIED TO THE RIGHT, MAKING A LATERAL CURVE CONVEX TO THE LEFT. (Cf. Fig. 41.)

other reasons, there exists in the adaptive character of bone a reason why this constantly assumed malposition should make a change in the shape of the bones in a growing child and that these changes should become fixed.

**Plasticity of Bone.**—The adaptability of bone to pressure has been



recognized in general and has been formulated and forms one aspect of what is often spoken of as Wolff's<sup>1</sup> law, which may be expressed briefly as follows: "Every change in the formation and function of the bones, or of their function alone, is followed by certain definite changes in their internal architecture and equally definite secondary alterations of their external conformation in accordance with mathematical laws."

The phenomena of lateral curvature have become somewhat more comprehensible since we have understood that bone is a plastic and adaptable structure adapting itself to the demands on it, following in its growth the lines of least resistance, and in children susceptible to great changes in shape from abnormal conditions. As an instance of this may be mentioned the great distortion of the shape of the bones in the Chinese lady's foot produced by bandaging. It is not necessary to multiply them, for we have direct experimental proof of the case in question in the experiments of Wullstein and Arnd.



FIG. 32.—EXPERIMENTAL SCOLIOSIS IN A RABBIT PRODUCED BY CUTTING THE ERECTOR SPINÆ MUSCLES.—(Arnd.)

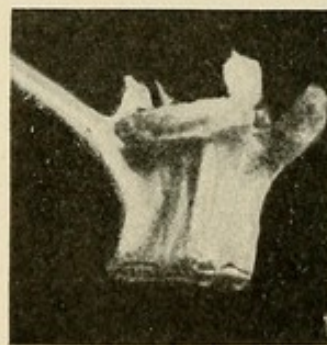


FIG. 33.—FIFTH LUMBAR VERTEBRA FROM EXPERIMENTAL SCOLIOSIS IN RABBIT.—(Arnd.)

Wullstein<sup>2</sup> showed, by bandaging young dogs for months in positions with the spine bent laterally in some and in others bent backward,

<sup>1</sup> Wolff: "Das Gesetz der Transformation der Knochen," Berlin, 1892; Freiberg: "Am. Jour. Med. Sci.," Dec., 1902; "Animal Mechanics," by Sir Charles Bell and J. Wyman, Cambridge, 1902.

<sup>2</sup> "Zeitsch. f. orth. Chir.," x, 2.



that a permanent bony deformity occurred which could not be removed by traction in the length of the spine after death. A section of these columns showed wedge-shaped deformity of the vertebræ with a "lip-ping" of the borders of the vertebræ on the concave side of the curve, the trabeculæ being thickened on the side of the bodies toward the concavity. The changes were more marked at the articular ends of the bones than in the middle of them.

Arndt<sup>1</sup> produced similar permanent curves characterized by bony deformity and marked rotation in rabbits by extirpation of the erector trunci muscles. They showed, as in Wullstein's experiments, that the changes are greatest at the articular ends of the bodies, and the epiphyseal plates in the most deformed vertebræ clearly overlap the sides of the body. There are of course many other causes of lateral curvature which will be mentioned, such as inequalities of structure on the two sides, congenital malformation, and the like.

#### TYPES OF LATERAL CURVATURE.

There are two types of malposition in lateral curvature: in one, the position is that which any normal spine may assume; in the second, the position is one that the normal spine cannot assume, a position which implies a change in the shape of the bones.

The first is due to the adjustment necessary to keep the balance of the spine in the presence of one of the disturbing causes mentioned. If this becomes habitual, it results in a typical attitude to be described as *total* or *postural lateral curvature* in the

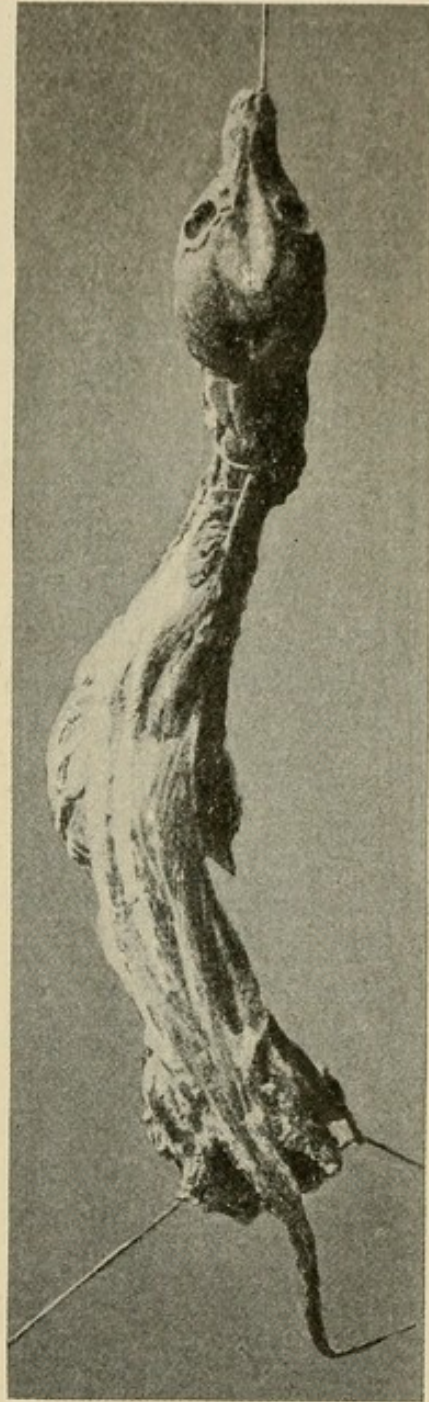


FIG. 34.—EXPERIMENTAL SCOLIOSIS IN A YOUNG DOG PRODUCED BY BANDAGING IN A ONE-SIDED POSITION.—(Wullstein.)

<sup>1</sup> "Archiv f. orth. Chir.," i, 1, 2.



chapter on Description and Symptoms. This attitude may persist as such or change to the second form to be described next.

The second type of lateral curvature implies a change in the shape of the bones. It cannot be reproduced experimentally in the model, cadaver, or child, and is not within the physiological limits of the spine. It must, therefore, be classed as *structural* or *organic lateral curvature*. The characteristic feature is a local backward prominence of the ribs or lumbar transverse processes opposite the lateral curve, and this backward prominence or bony rotation is always backward on the side of the convexity of the lateral curve, *i. e.*, left in left curves.

**Bony Rotation.**—The reason for this seems to be fairly plain. A permanent curve is forming, we will say, convex to the left; the vertebral bodies in their growth will follow the line of least resistance, and if they are plastic, they will expand where the pressure is least and become compressed where it is greatest. They will turn away from the line of weight, which is obviously nearer the concave than the convex border, and their avenue of escape is toward the convex border or away from the middle line of the body. If they were to turn toward the middle line instead of away from it they would encounter the greater resistance and have to raise the whole weight of the parts above them. In so far as they are plastic they will be compressed where the weight is greatest or on the concave side. The deformity of the vertebræ is therefore due to their plasticity yielding to conditions of unequal strain, and turning where they must to escape.

**Double Curves.**—The explanation of a double curve is more difficult. It has been observed that frequently a double organic curve grows out of a single functional one, the reason for which will be explained in the chapter on Description and Symptoms. It cannot be said that every case of organic double curve has first been a single postural one, for congenital, early rachitic, and other cases make that unlikely, but the mechanism is present for forming double curves from single ones under the influence of existing conditions. The occurrence of bony change in some cases and the persistence of functional curves in others can only be explained by assuming a plasticity of the bones in certain individuals which does not exist in the bones of others.

But lateral curvature is not wholly an affair of the upright position—its occurrence in quadrupeds shows that; again it is seen as a congenital condition, and in empyema and paralysis it would probably occur if recumbency were substituted for the upright position. Yet in quadrupeds the phenomena are the same as in cases which are the result of superincumbent weight, the spines of the animals showing a rotation



of vertebral bodies backward on the convex side of the lateral curve, in spite of the fact that superincumbent weight is absent as a deforming factor.

The chain of events in the cases where a single curve changes to a double one is then, first, a disturbance of the symmetry of the body and the appearance of a functional curve; second, the persistence of this curve from the same causes that started it, the phenomena being still within the normal mechanism of the spine; third, the yielding of plastic vertebræ in the line of least resistance and the appearance of rotation on the convex side of the lateral curve; fourth, the formation of double curves from single ones by the normal mechanism of the spine originating in the sense of balance and adjustment. It seems that in many cases, perhaps the majority, these steps cannot be traced, but coincide in time.



## CHAPTER IV.

### DESCRIPTION AND SYMPTOMS.

#### SYNONYMS.

English: Scoliosis, lateral curvature of the spine, rotary lateral curvature of the spine.

German: Skoliose, seitliche Rückgratsverkrümmung, Kypho-skoliose.

French: Scoliose, deviation latérale de la taille.

Italian: Scoliose.

Scoliosis, or lateral curvature of the spine, is the name applied to a condition in which any series of vertebral spinous processes shows a constant deviation from the median line of the body, a deviation always accompanied by an element of twisting. In certain rare cases the twisting may be the predominant appearance. Deviation of a single vertebra from the sagittal plane does not constitute scoliosis.

Although scoliosis is generally studied and classified as a deformity of the spine, the laws of equilibrium of the body are such that any deviation of the vertebral column must disturb the whole balance of the body, and scoliosis is therefore accompanied by compensating displacement of the pelvis and legs. In this wider sense scoliosis is to be regarded as a deformity of the whole body, especially manifest in the spine.

Lateral curvature of the spine has for its chief clinical characteristic a distortion of the symmetry of the body for which the patient or her parents seek advice. It is rarely recognized by the laity as a spinal distortion, but the patient is brought for surgical advice because of "a high shoulder," "a prominent hip," or "a projecting shoulder-blade." Very often the dressmaker is the first to recognize it because she finds that she must make the skirt longer on one side than on the other, or because the distance from the armhole of the waist to the waistband is longer on one side than on the other.

The condition is throughout a distortion, and symptoms other than the deformity are rather unusual in average cases. Occasionally the patient complains of feeling "one-sided," but this is rare. *Pain* is generally not complained of, but in neurasthenic young women, especially



with functional curves, backache may be felt more or less on standing. Pain in the severer cases is caused by the descent of the ribs to the level of the crest of the ilium against which the lower ribs may rub, and severe local pain may be felt. In other severe cases nerve-root pressure may result from the distortion and be referred to the peripheral ends of the spinal nerves.

The shortening of the trunk and the diminished capacity and immobility of the thorax may lead to impairment of the function of thoracic and abdominal organs, and in severe cases this must result to some extent. Shortness of breath is common in such cases on account of diminished respiratory capacity and displacement of the heart. Phthisis frequently occurs in severe cases during adult life. Disturbances of digestion are also frequent from displacement of the stomach and liver. Impairment of vigor is the rule in adults with scoliosis of the severer grades, and impairment of the general health generally results in severe cases in adult life, although children with severe curves as a rule suffer but little deterioration of the general condition.

It is not uncommon for patients to go through life with curves of moderate degree which have given rise to little or no trouble; but after the age of fifty or sixty, when atrophy of the intervertebral discs has become marked, such curves may increase and give rise to a sense of asymmetry or to pain in the back or at nerve terminations. It can generally be predicted that a curve of moderate severity may be more troublesome in later adult life.

#### TERMINOLOGY.

The terms used in describing lateral curvature must be defined. Curves are named right or left according to their convexities, curves convex to the right being called right curves and vice versâ. In addition to the terms right or left the curves are named also according to the anatomical region involved in the curves. If a deviation involves the whole spine, it is called a total curve; all other curves are called cervical, dorsal, or lumbar, according to the region involved, with the qualifying adjective right or left preceding the anatomical name. If a curve involves more than one region, it is classed as cervicodorsal or dorsolumbar. If two curves exist, the upper curve is spoken of first and the lower follows, *e. g.*, right cervicodorsal, left dorsolumbar; or right dorsal, left lumbar.

It is important that the anatomical region affected by the curve be designated accurately and not loosely. For this purpose the seventh cervical and last lumbar vertebral spines are connected by a string repre-



senting the long axis of the spine. Parts of the spine lying to the right of this line are to be classified as right curves, parts to the left as left curves. Such curves must be assumed to begin and end where they pass under this string. For example, if the spine from the seventh cervical to the twelfth dorsal is to the right of the line and below it is to the left, it is a right-dorsal, left-lumbar curve. If the spine from the fourth dorsal to the third lumbar is to the right of the line, it is a right dorsolumbar curve.

This, therefore, provides for a simple rule for the naming of every curve, insisting on the fact that the location of the upper end of the column has nothing to do with the naming of the curve. The upper end of the spine may be in the median plane or at either side of it without affecting in any way the recognition and description of the spinal deviation.

The classification of curves into primary and secondary, or compensatory, is not of great importance. Often it is obvious that one curve is predominant and evidently the one to be attacked in treatment. In other cases this cannot be done, as the curves are of equal degree and importance so far as can be seen. It is, however, of importance to recognize the predominant curve where possible. For example, in a marked and predominant right dorsal curve it matters but little, practically, whether a slight lumbar curve exists or not; for purposes of treatment the case is a dorsal curve. If a marked lumbar curve exists with a dorsal curve, however, the situation is wholly different. In general rational treatment must eliminate unimportant factors and deal with the salient ones.

The former division of lateral curvature into stages has no rational basis. It is a progressive affection passing over only one sharp line, the transition from postural or functional curves to structural or organic ones. This classification of functional and structural will, therefore, be adopted here with slight emphasis on a certain puzzling type of cases evidently in the transitional stage from the functional to the structural type.

#### FUNCTIONAL SCOLIOSIS (TOTAL SCOLIOSIS; POSTURAL SCOLIOSIS).

The term "total scoliosis" is applied to cases where the spine forms one gradual curve to one side without marked rotation or compensatory curves. In 90 per cent. of the cases the curve is to the left. According to the figures of Scholder and at the Children's Hospital clinic,



right total scoliosis is very rarely seen, while the left curve is very common. The greatest point of deviation, *i. e.*, the apex of the curve, is generally found at the ninth or tenth dorsal vertebra, but it may be found in any part of the lower half of the dorsal or upper half of the lumbar region.

In frequency of occurrence total scoliosis stands in the fourth place in the records of the institute of Lünig and Schulthess, where patients

came for treatment, forming but 15.39 per cent. of the entire number of lateral curvatures. As to sex, the percentage shown in these cases is 24 for males and 17 for females. In boys the number of total scolioses increases steadily with age, but in girls a decrease is noted after the twelfth year, coinciding with an increase in the number of left lumbar curves.

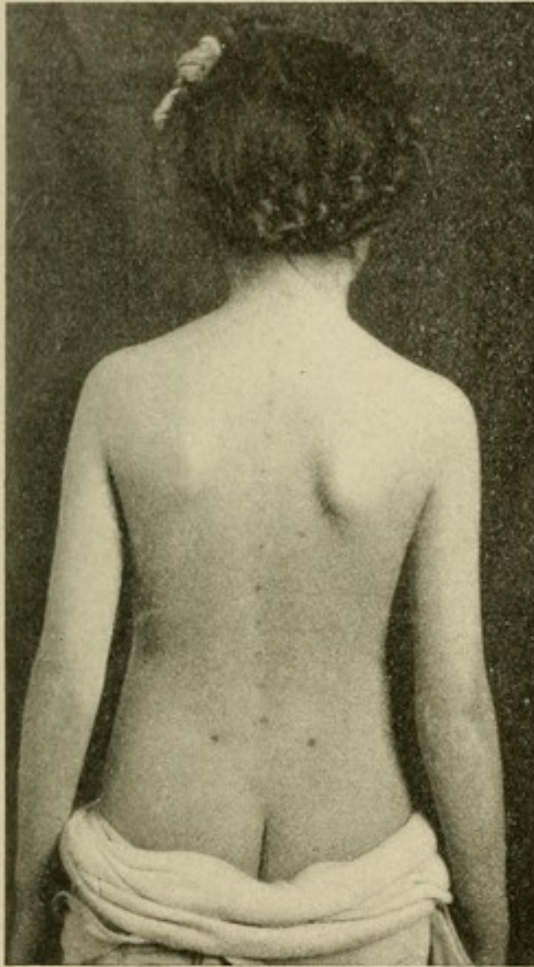


FIG. 35.—LEFT TOTAL CURVE.

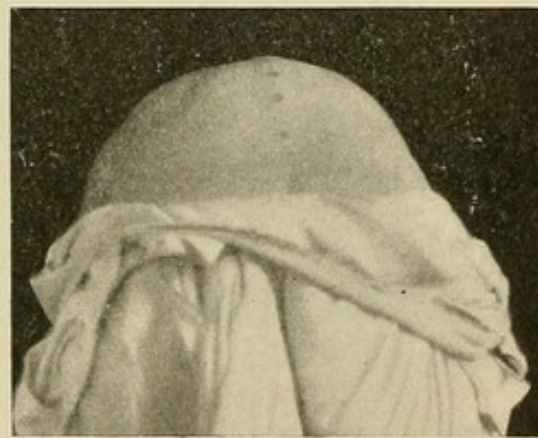


FIG. 36.—LEFT TOTAL CURVE BENT FORWARD, SHOWING PROMINENCE OF BACK ON THE RIGHT (SAME PATIENT AS FIG. 35).

Total scoliosis is found between the ages of five and eighteen years, as a rule.

The deviation at the greatest curve is not often over an inch and a half from the median line of the body. There is no obvious compensatory curve, and the untrained eye is likely to find slight cases normal. There is, however, a perceptible displacement of the trunk to the left, especially as seen from the front, and the plumb-line will detect a decided



deviation of the marked spines from the median plane. The characteristics of the type in a left total scoliosis are as follows: (1) *A general curve convex to the left*; (2) *the left shoulder is elevated*; (3) *the right side of the shoulder-girdle is carried back and the left side forward*; (4) *when the patient bends forward the right side of the back may be*

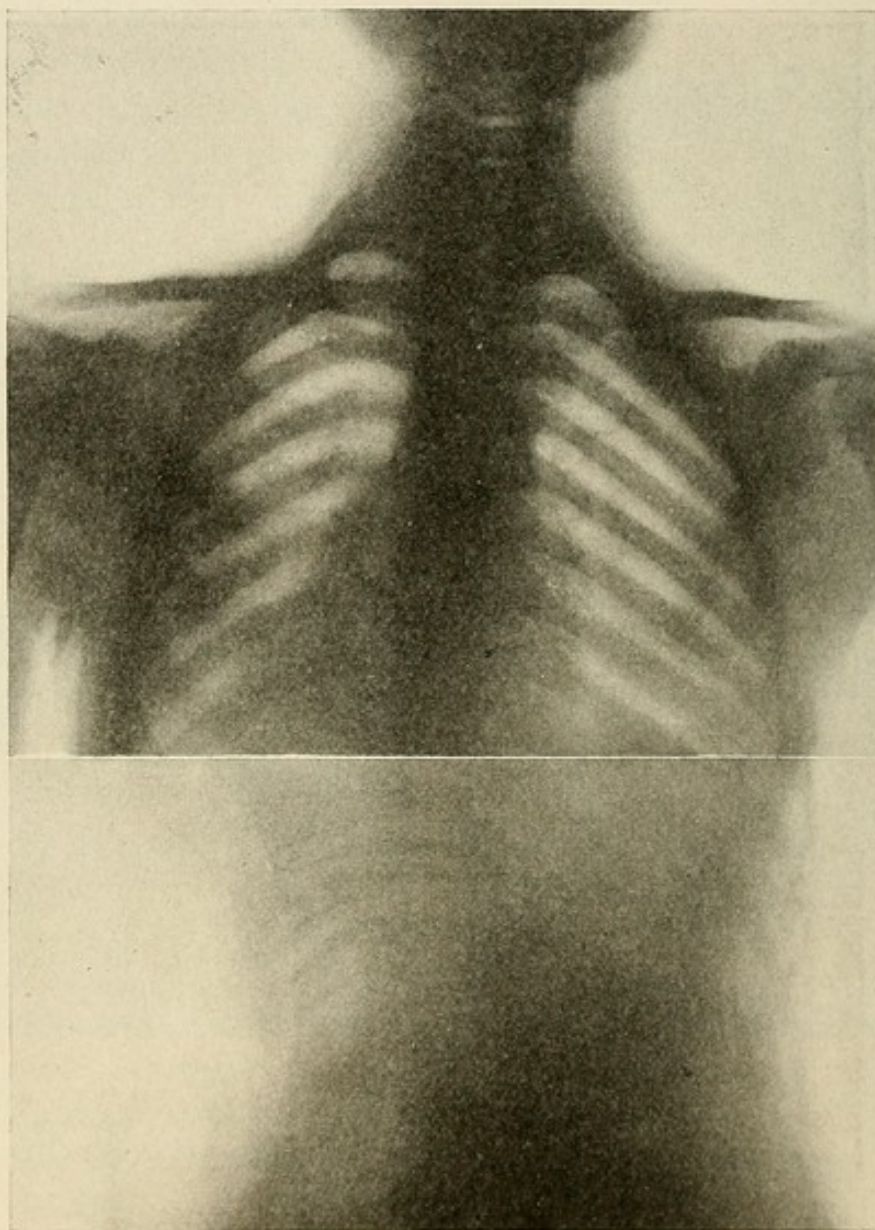
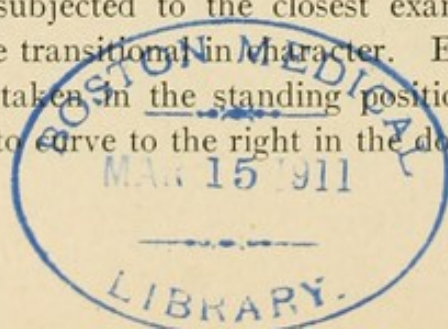


FIG. 37.—RADIOGRAM OF TOTAL CURVE IN PATIENT SHOWN IN FIG. 35.

*slightly higher than the left.* Any case in which these signs are not all present should be subjected to the closest examination and will probably be found to be transitional in character. Even in apparently typical cases an x-ray taken in the standing position will sometimes show a slight tendency to curve to the right in the dorsal region, which





may be due to the physiological curve to the right there or to a beginning structural change. Functional curves disappear on suspension or recumbency, and side flexibility is but little limited, bending to the left being perhaps somewhat restricted. In cases of right curves the description is reversed.

The changed relation of the shoulders to the pelvis is more evident in children with a lumbar curve than in cases with round backs.<sup>1</sup>

The position in a typical functional total curve is merely the physio-

logical one necessitated in every normal spine made convex to the left, and can be produced experimentally by putting a book under the right foot, which raises the right side of the pelvis and necessitates for balance a left convex curve of the spine. A spine making any bend convex to the left in the erect position will turn at its upper end to the right, as explained in the movements of the

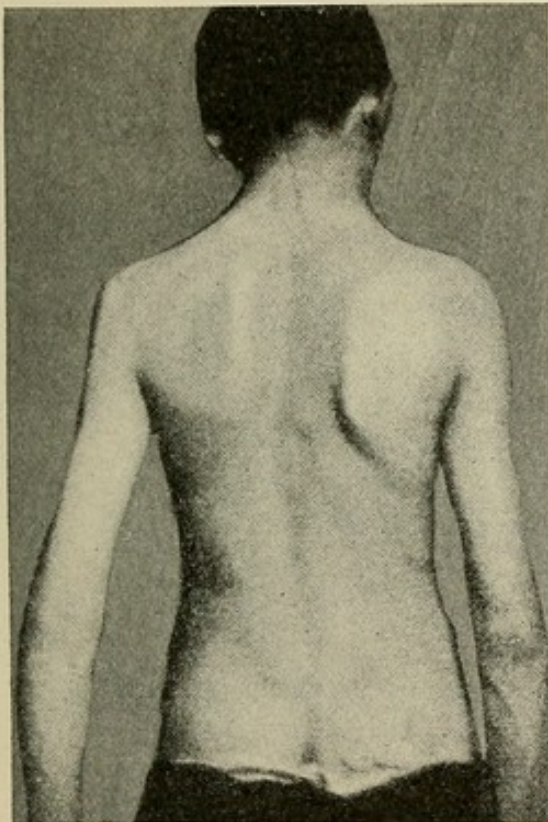


FIG. 38.—CASE OF "PARADOXICAL DORSO-LUMBAR SCOLIOSIS" FIGURED BY WILBOUCHEWITCH. (Compare Figs. 35-37.)

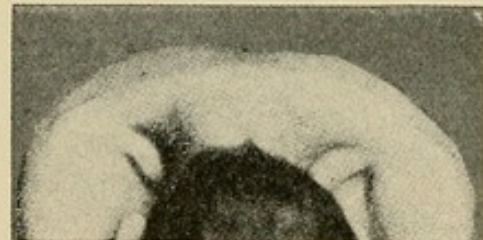


FIG. 39.—SAME CASE AS IN FIG. 38 BENT FORWARD SHOWING PROMINENCE OF RIBS ON RIGHT SIDE WITH LEFT CURVE.—(Wilbouchewitch.)

spine. The thorax and shoulders will be twisted backward on the right, and when the patient bends forward, this twisted position of the shoulders may be carried over into the position of forward bending if the case has been of long standing, and the right side of the back will be higher in this position. This "reverse rotation," "concave torsion," "retrotorsion," as it has been called, has been much discussed<sup>2</sup> and is an accompaniment of total scoli-

<sup>1</sup> Schulthess: "Zeitsch. f. orth. Chir.," vi, 399-566, 1902.

<sup>2</sup> Schulthess: "Zeitsch. f. orth. Chir.," x, page 489.



osis, but it is a physiological matter easily understood by studying the mechanics of the normal spine. It has been claimed that total scoliosis is really a triple-compound curve,<sup>1</sup> and that the torsion to the concave side is really due to a slight right dorsal curve; x-rays of such cases taken in the standing position show, however, in many cases, a gradual curve to the left without compensating curves (Fig. 37); in

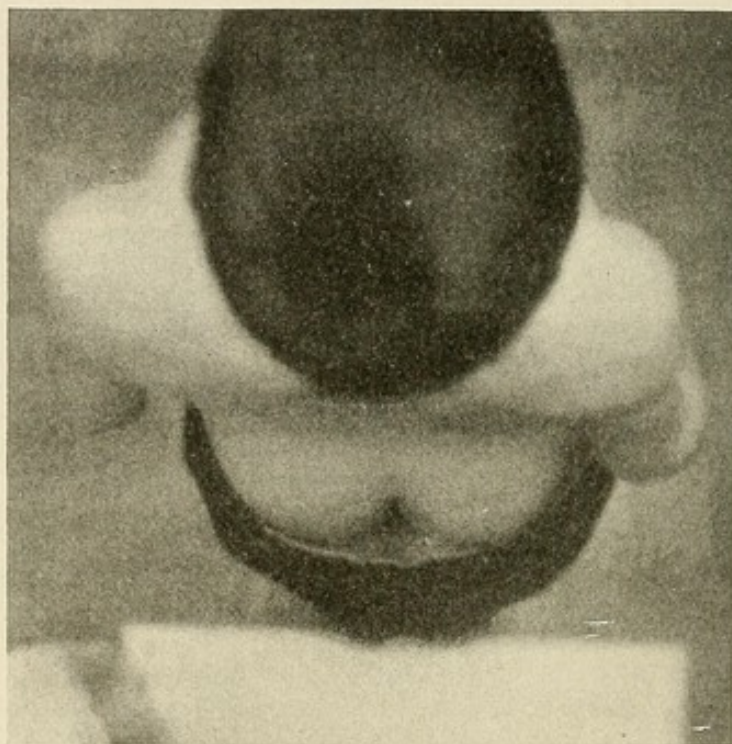


FIG. 40.—BOY WITH LEFT TOTAL SCOLIOSIS PHOTOGRAPHED FROM OVERHEAD, SHOWING THE CARRYING BACK OF THE SHOULDER-GIRDLE ON THE RIGHT.

The front edge of the board on the floor marks the lateral plane of the pelvis.

other cases apparently total curves in x-rays taken in this way seem to be transitional cases.

### TRANSITIONAL CURVES.

In many cases which on first inspection appear to be postural more careful examination will show that the curve is obviously changing from the postural to the structural type, *i. e.*, is beginning to show changes of structure. The mechanism of this is as follows:

If total scoliosis tends to increase, it must do so by an increase of the existing side bend and of the existing twist, since both are correlated, not necessarily of both in exact proportion, but to some extent both factors must share in it. The shoulder-

<sup>1</sup> Reiner and Werndorff: "Verhandl. Deut. Gesel. f. orth. Chir.," 1906, page 232.



girdle will, therefore, be more twisted as the lateral curve increases. One, however, does not see the condition clinically of extreme left total curve and extreme right backward rotation of the shoulder-girdle except, possibly, in cicatricial, hysterical, or paralytic cases. An adjustment apparently takes place when the tendency of the total curve to increase passes beyond a certain point. For the explanation of this one naturally looks to the instinctive tendency to equilibrium and balance spoken of as an intrinsic property of the upright living spine. There must be going on at all times this effort to square the shoulder-girdle with the pelvis and to keep the head and upper spine as nearly as possible in the median line of the body. This ad-

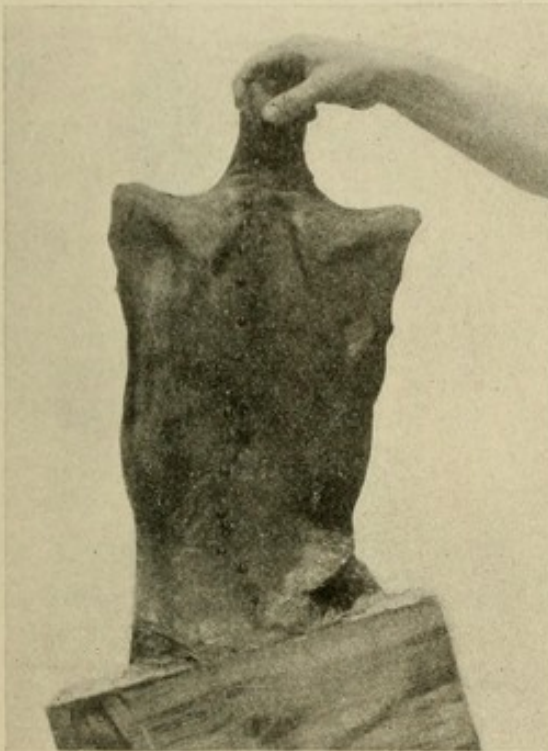

FIG. 41.—THE UPPER END OF THE SPINE OF THE CADAVER IS HELD BY THE HAND OVER THE MIDDLE OF THE PELVIS, WHILE THE RIGHT SIDE OF THE PELVIS IS RAISED, AND A POSITION LIKE THAT OF THE LIVING MODEL IS PRODUCED WITH A LATERAL CURVE CONVEX TO THE LEFT. (Cf. Fig. 31.)



FIG. 42.—EXPERIMENTAL DOUBLE CURVE (RIGHT DORSAL, LEFT LUMBAR) PRODUCED IN THE CADAVER BY ELEVATING THE RIGHT SIDE OF THE PELVIS AND TWISTING THE UPPER END OF THE SPINE, FACE TO THE LEFT.

justment will naturally occur where the spine offers the least resistance to it, and as individual vertebral columns vary, the compensatory adjustment will take various forms.

Assume that a child stands and sits with a left total curve. He will, after a certain point in the deformity is reached, be continually striving to twist the upper part of his spine and his shoulder-girdle forward on the right and to bend the upper part of his spine convex to the right to restore his balance. We have seen that the dorsal spine twists more easily than it bends to the side. He is, therefore, more likely to twist his dorsal spine than to bend it to the side. He will, for this reason,



twist the upper dorsal spine to the left, which twist, as we have seen, necessarily carries with it a dorsal lateral curve convex to the right.

The tendency to correct the twist of the shoulder and upper end of the spine is sufficient to explain the transition of a left total curve to a right dorsal, left lumbar curve. Such a double curve can be reproduced experimentally in the cadaver, the model, and the child by inducing a left total curve and adding a twist, active

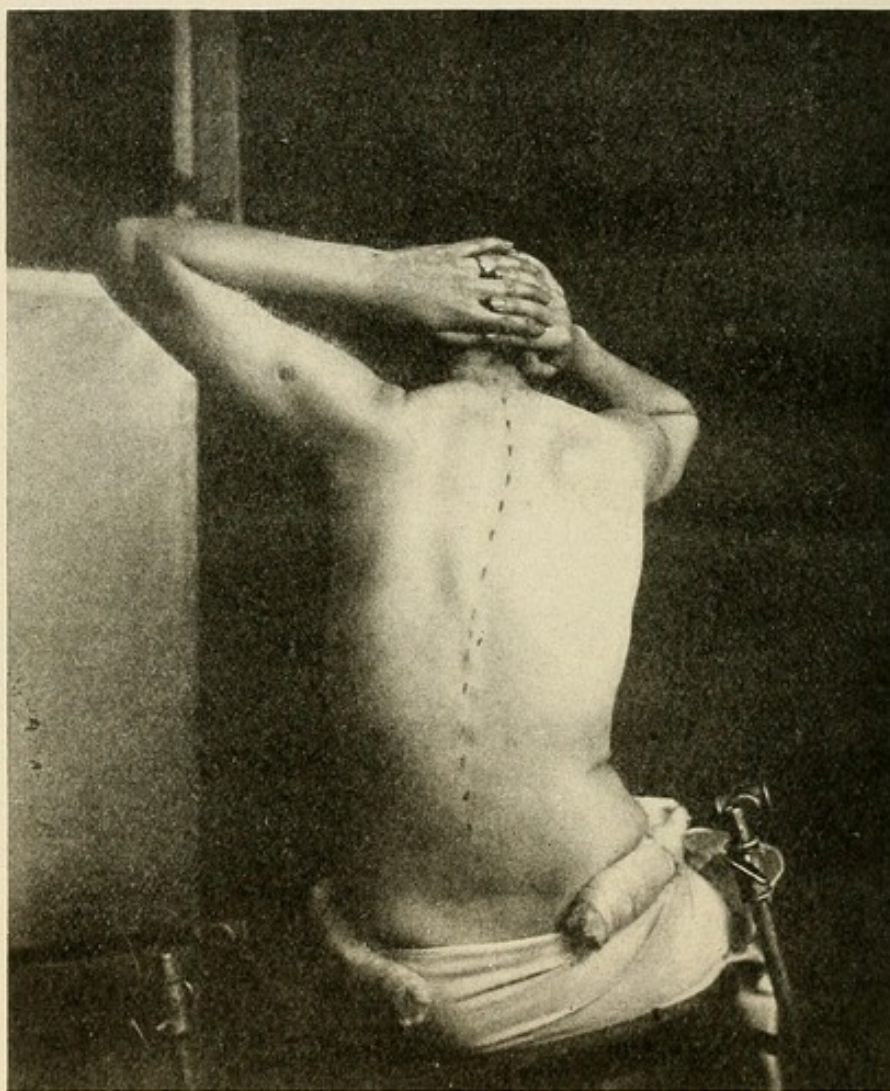


FIG. 43.—EXPERIMENTAL DOUBLE CURVE (RIGHT DORSAL, LEFT LUMBAR) PRODUCED IN THE MODEL BY ELEVATING THE RIGHT SIDE OF THE PELVIS AND HAVING THE MODEL ACTIVELY TWIST THE UPPER SPINE, FACE TO THE LEFT.

or passive, of the shoulder-girdle forward on the right. A right dorsal, left lumbar lateral curve then exists.

Support is given to this idea by the fact that in structural right dorsal, left lumbar curves with bony rotation, one is likely to find in looking down upon the standing patient that the left side of the shoulder-girdle is seen to be carried backward in its relation to the pelvis and the right side forward. This, of course, is the reversed position to that seen in the left total curve. The same relation of the shoulder-



girdle is to be noticed in single curves to the left which are accompanied by bony rotation, the position again being the reverse of that seen in left total scoliosis.

The disappearance of concave-sided torsion which has once existed in any part of the spine may indicate that the compensatory change has already begun and that the so-called total scoliosis has begun on its transition to a compound curve.

We should, therefore, regard with suspicion any case of apparent total scoliosis that shows any departure from the clinical type described (see page 50). Such cases must be regarded as probably having entered on the stage of transition.

That left total curves most frequently change to right dorsal, left lumbar compound curves than to any other form is shown by the figures of Hess and by a statement of Schulthess.<sup>1</sup> But we cannot expect the same final curves always to result from the same initial curve. Various forms of curves may occur from the same simple curve. For example, the dorsal region may not react as described, and the dorsal and lumbar region may yield, as a whole, to the left, later showing bony rotation on the left side. The spine has yielded backward and to the left as a whole, and other types of compound curves may obviously result from the same initial curve.

In such transitional cases the upper part of the spine is less curved than the lower, and one or more of the characteristic signs of postural curves are most often wanting. For example, the right shoulder may be elevated in a left curve, or the left side of the back may be prominent upward in forward bending, or the left shoulder may be carried forward. Such cases must, of course, be recognized as early structural cases, but are so nearly postural that they may be wrongly classed unless identified.

It is not exceptional to notice that in a curve that has been clearly a typical postural one, a few months later the dorsal spine is straightening and even becoming slightly curved to the right, while the twist of the shoulder-girdle has disappeared or become reversed.

In his investigations concerning the persistence of total scoliosis Hess records the observations of 86 cases between the ages of five and twenty-one years during periods varying from two weeks to eight years and a half. Of these 86 cases, 60 persisted as total scolioses, and the remaining 26 underwent various changes, as shown by the list given below.

(a) Left convex total scoliosis in—

- 7 cases changed to right dorsal, left dorsolumbar scoliosis.
- 4 cases changed to left lumbar curves, with two right dorsal.
- 3 cases changed to left dorsal curves.
- 2 cases changed to left dorsal, right dorsolumbar curves.
- 2 cases changed to right dorsal curves.
- 1 case changed to right dorsolumbar, left dorsal.
- 1 case changed to slight left cervicodorsal curve.
- 1 case showed slight compensating curves.

21 cases.

<sup>1</sup> Lüning and Schulthess: "Orth. Chir.," 1901, p. 248.



## (b) Right convex total scoliosis in—

- 1 case became right dorsal, left dorsolumbar.
- 1 case became left dorsal, right dorsolumbar.
- 1 case became left dorsal.
- 1 case became right dorsal.
- 1 case became left dorsal, right lumbar.

---

5 cases.

### STRUCTURAL SCOLIOSIS (ORGANIC OR HABITUAL SCOLIOSIS).

This term is applied to those cases in which there is reason to believe that a structural change has occurred in the vertebræ. What this structural change is, is discussed in the chapter on Pathology, but the phenomena are no longer to be explained in physiological terms, for the spine has assumed a position which implies organic change.

Structural curves are simple or compound—simple when the deviation is accompanied by no compensating curves, *e. g.*, left lumbar scoliosis. The scoliosis is compound when more than one curve is present, *e. g.*, right dorsal, left lumbar scoliosis. The simple curves are sometimes spoken of as C curves and the double as S curves. Triple curves at times exist. When compound curves are present, they alternate to the right and left, two left curves not separated by a right curve never being seen.

No attempt has been made to discriminate between the words "torsion" and "rotation," and they have been used interchangeably in the text. The German writers distinguish between the two terms in a highly technical way, a distinction which it does not seem desirable to transfer to English. By rotation they designate the turning of the vertebral column as a whole at the distorted region; by torsion, the distortion of the individual vertebra.

### LUMBAR SCOLIOSIS.

Lumbar scoliosis exists as a simple curve, but more often is only one component of a compound curve, the dorsal curve being, of course, in the opposite direction. In the Schulthess figures the simple lumbar curve formed 11.7 per cent. of all cases treated, and right and left curves were of practically the same frequency. It occurs later than the total scoliosis, as shown by the ages of the patients observed. It occurs more frequently in females than in males (Scholder: 13.8 per cent. boys, 27.7 per cent. girls. Schulthess: 6.3 per cent. males, 12.7 per cent. females). The greatest deviation from the straight line is most often



found at about the second lumbar vertebra, and as the lumbar region is short, the curve must be in general a sharp one.

The trunk is displaced to the side of the convexity of the curve and the line of the waist flattened on that side, while the waist on the concave side is sunken in, and folds may form in the skin of the flank on the concave side. This is expressed by an apparent prominence and greater size of the hip on the concave side, and it is popularly said that one hip has "grown out" or one hip is "higher" than the other. This inequality of the hips and waist-line is the most striking feature of lumbar curves, and unless corrected forms an unsightly deformity in women with prominent hips and makes it necessary to make the skirt longer on one side than on the other. The height of the shoulders is not noticeably affected by lumbar curves.

As the patient stands, a fullness of the back is noticed in marked cases on the convex side of the curve caused by the rotation of the vertebræ, which carry the heavy transverse processes around and make prominent the overlying structures. In the position of extreme forward bending the side of the back which is on the convexity of the lateral curve is prominent upward, but lumbar rotation is always less prominent than dorsal, and to the untrained eye even in the severer cases seems slight (Fig. 51). In side bending mobility is greater toward the side which makes the curve worse than to the side which improves it (Fig. 55).

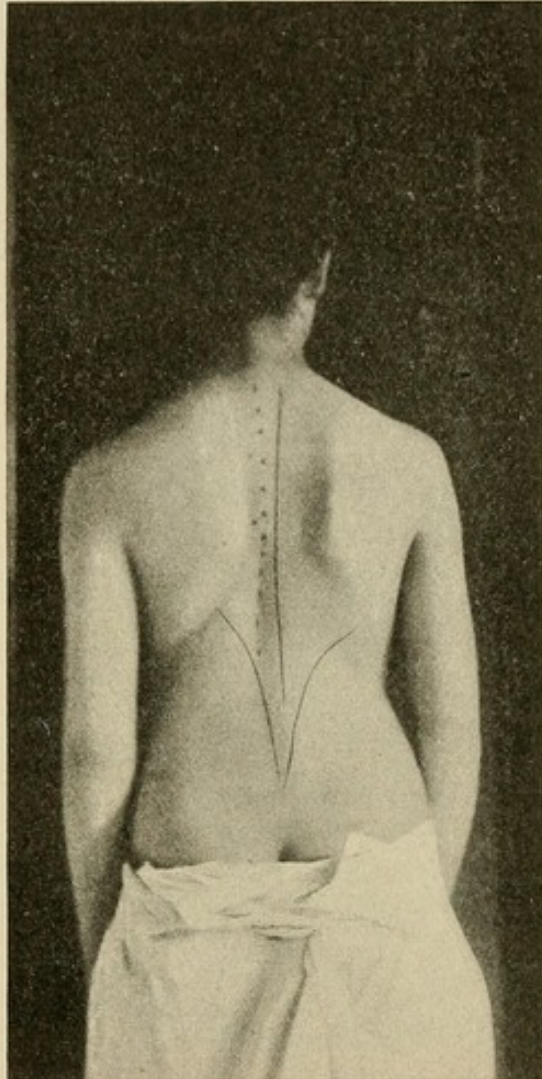


FIG. 44.—LEFT LUMBAR SCOLIOSIS NOT RETURNING TO THE MEDIAN LINE.

The lines indicate the median plane and the flexibility to each side.



## DORSAL SCOLIOSIS.

A single dorsal curve is more frequent than the single lumbar type, but is much less frequent than dorsal curves in combination with other forms; that is to say, dorsal curves are more often than not accompanied by reverse or compensating curves above or below. In the Schulthess figures there were 19 per cent. of single dorsal curves and 30 per cent. where dorsal curves existed with others. The curves

are as frequently to the right as to the left when they exist alone. The point of greatest curve is from the sixth to the eighth dorsal vertebra in the majority of cases.

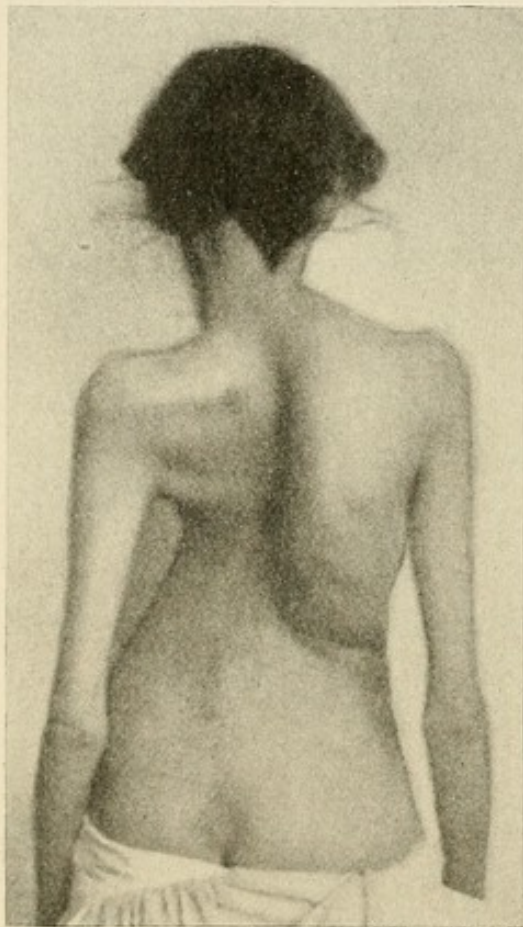


FIG. 45.—ADVANCED RIGHT DORSAL SCLIOSIS IN AN ADULT.

In a marked right dorsal curve, as seen from behind, the thorax is displaced to the right, and the right arm hangs further from the side than the left; the right shoulder is raised and the waist-line on the right is less concave and much flattened in the severer cases, the ribs coming close to the crest of the ilium and obliterating the natural waist indentation. The rotation is made evident by a prominence, in the back, of the right side of the thorax, which may be seen as the patient stands erect (Fig. 49). Unlike the rotation in lumbar cases, the rotation element in dorsal cases

is a very marked feature of the deformity, and a sharp prominence extends down the right side of the thorax, composed of the angles of the ribs, which pushes the scapula backward and to the right. The left side of the thorax as seen from behind is flat or concave, the left scapula sunken and rotated with the glenoid cavity downward and the inferior angle inward. A fold in the skin frequently runs inward and upward from the waist-line. When the patient bends forward until the trunk is horizontal, the rotated ribs are very prominent upward



on the right, and a long arch of rib angles is seen which is much more marked than in the standing position. On the left side the ribs are sunken and fall away, making a flat and even depressed surface to contrast with the striking prominence of the right side.

As seen from the front, the deformity is even more evident, the thorax is displaced to the right, the right shoulder is higher than the left, and the left side of the thorax more prominent in front than the right. In severe cases the lower end of the sternum is generally displaced toward the convexity of the curve—in this case to the right. The contour of the chest is changed, and the longest thoracic diameter is from the point rotated backward on the right to the point rotated forward on the left—in this case from the right scapula to the left nipple. This description is, of course, to be reversed for left dorsal curves.

The dorsal physiological curve is most often increased, making the rounded and distorted back spoken of as *kyphoscoliosis* (Fig. 46). It may, however, be flattened, and even slightly concave forward in the dorsal region. The loss of height and shortening of the trunk are evident in the severer cases. The picture is wholly different from that seen in lumbar cases, where, as has been said, the chief noticeable distortion is in the hips and waist-line; in dorsal cases the distortion is most noticeable in the thorax and shoulders.

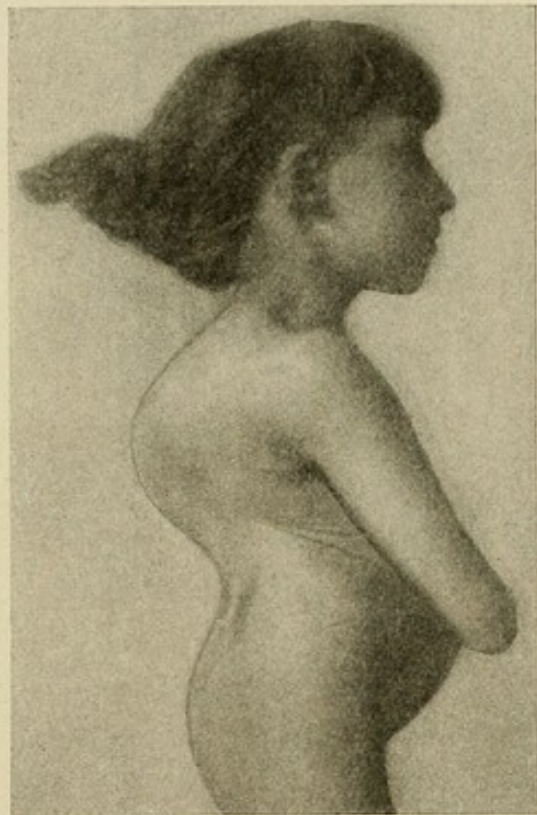


FIG. 46.—KYPHOSCOLIOSIS.

#### DORSOLUMBAR SCOLIOSIS.

Dorsolumbar scoliosis is a form seen as a simple curve with considerable frequency (20 per cent.), being, therefore, much more common than simple lumbar, but about as frequent as simple dorsal scoliosis. It naturally partakes of the character of the two forms just described and affects nine females to one male. The seat of greatest curve is



generally at the dorsolumbar junction. It is four times as frequently convex to the left as to the right. The trunk and lower thorax are displaced toward the side of the convexity of the curve and overhang the pelvis, and the waist-line on that side is flattened or obliterated, while on the concave side the outline cuts in sharply above the pelvis, frequently forming folds in the skin. The attitude is more like that of an exaggerated total scoliosis than like either the dorsal or lumbar form. The severest cases are characterized by a kyphosis of

the spine (kyphoscoliosis). It is not so prone to be associated with compensatory curves as are the other forms.

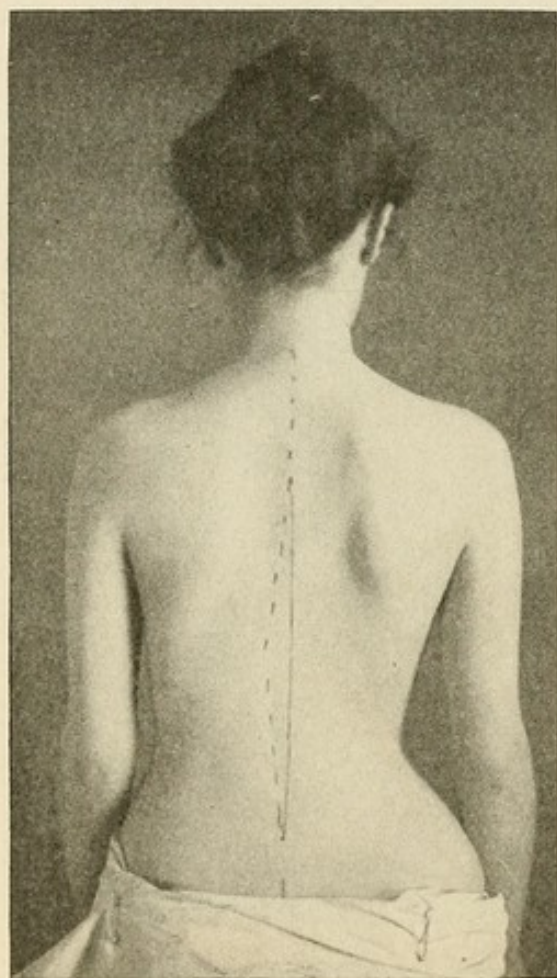


FIG. 47.—LEFT DORSOLUMBAR SCOLIOSIS.

#### CERVICODORSAL SCOLIOSIS.

Cervicodorsal scoliosis is a comparatively rare form of the deformity, occurring in only 3.6 per cent. of all cases. It is convex to the left more often than to the right in the relation of 3 to 2, and the greatest curve is most frequently located at the third or fourth dorsal vertebra. The head is carried forward and tipped to the concave side of the curve. The neck is obviously shortened, and the outline from the base of the skull to the shoulder is fuller and less crescentic in outline on the convex side of the curve than on the other.

The shoulder on the convex side of the curve is raised and the other lowered, and the scapula of the raised side is conspicuously higher. The arm of the convex side hangs further from the side than the other. The rotation appearances are marked, and the sharp angles of the upper ribs are prominent in the lower part of the curve, while above the rotation is less evident because there are only the transverse processes of the cervical vertebræ to make a projection. The trunk is displaced to the side of the convexity of the lateral curve.



## COMPOUND STRUCTURAL CURVES.

The pictures of compound curves cannot, of course, be as simple or uniform as those of the simple types. A right dorsal left lumbar curve, for example, will present a combination of the appearances described in both dorsal and lumbar curves, a right cervicodorsal

left dorsolumbar the sum of the pictures of the two factors. If the dorsal element predominates, the appearances will be more dorsal than lumbar, as is usually the case, and every grade of variation is to

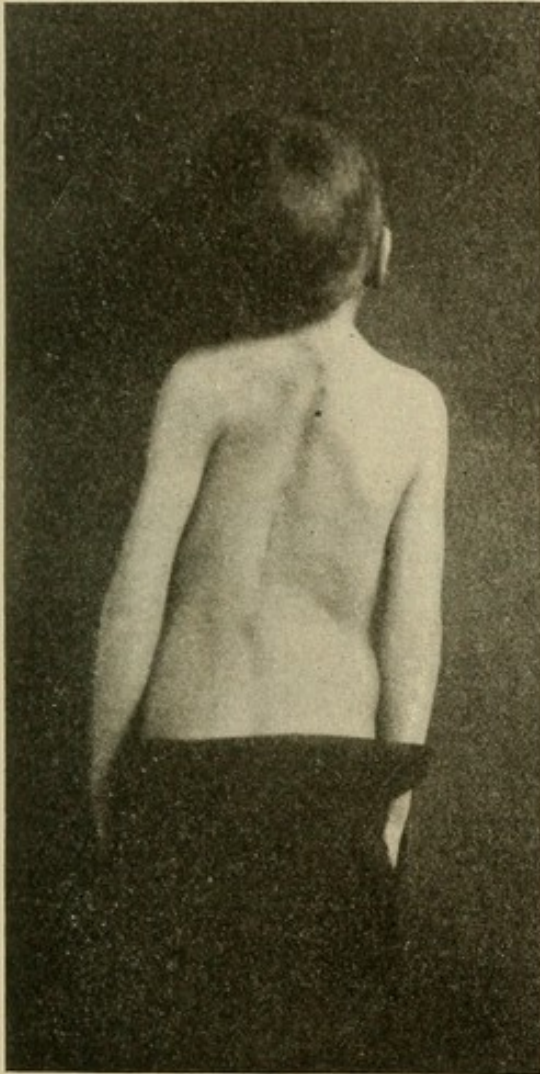


FIG. 48.—CERVICODORSAL CURVE DUE TO DEFECTIVE RIBS AND MALFORMATION OF VERTEBRÆ.

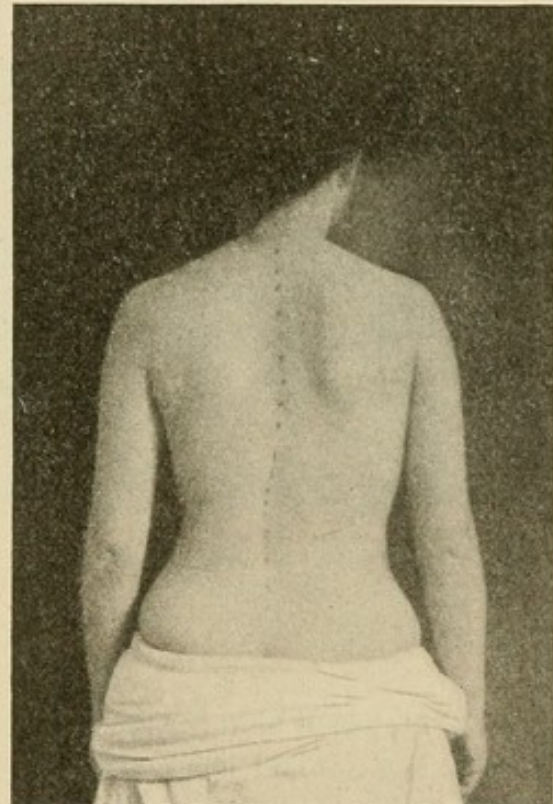


FIG. 49.—RIGHT DORSAL LEFT LUMBAR SCOLIOSIS.

be seen, the predominant curve setting its type on the clinical appearance. The right dorsal left lumbar curve is the one most frequently seen. Dorsal scoliosis with compensating curves formed 30 per cent. of all cases in the Schulthess tables, and of these the dorsal curve was to the right in 80 per cent. of the cases. The greatest point of curve in these was from the sixth to the eighth dorsal vertebra, and



the most frequent reverse curve associated was in the lumbar region. It is a type of curve most frequently seen in older children, the bulk of the cases being from ten to sixteen years old, but it may be seen in very young children. The increased susceptibility to compound curves with increasing years is shown by Scholder's statistics of school children:

|                  |               |
|------------------|---------------|
| 8 years old..... | 0.4 per cent. |
| 9 " " .....      | 1.1 "         |
| 10 " " .....     | 1.2 "         |
| 11 " " .....     | 2.4 "         |
| 12 " " .....     | 2.1 "         |
| 13 " " .....     | 3.3 "         |
| 14 " " .....     | 3.3 "         |

Women are more frequently affected than men, the proportion being 7 to 1.

The appearances shown in the illustration (Fig. 49) will serve to demonstrate how the appearances

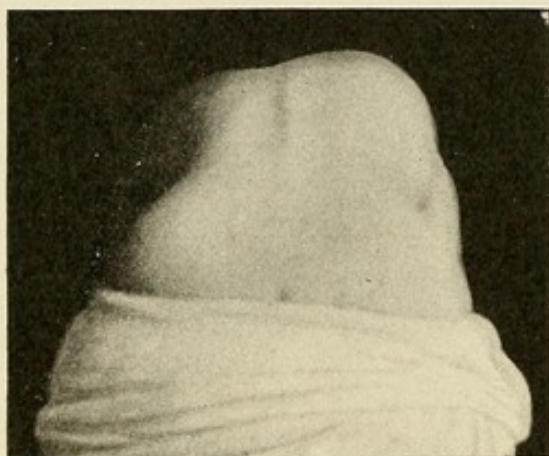


FIG. 50.—DORSAL ROTATION SHOWN BY PROMINENCE OF RIGHT SIDE IN BENDING FORWARD. (SEE FIG. 49.)

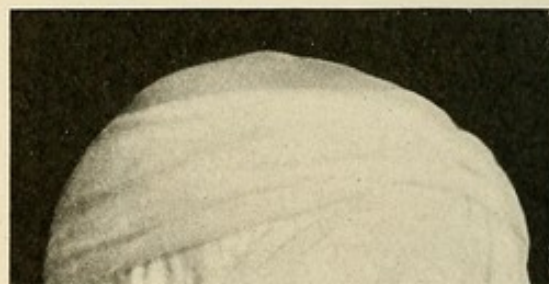


FIG. 51.—LUMBAR ROTATION SHOWN BY PROMINENCE OF LEFT SIDE IN BENDING FORWARD. (SEE FIG. 49.)

of two types of simple scoliosis are brought together in the same patient. In a right dorsal left lumbar curve, the appearances of the thorax are those described for a simple dorsal curve, but the overhang of the thorax is modified by the displacement of the lower trunk in the opposite direction incident to the left lumbar curve. The resultant position may be, as in the simple curves, either accompanied by an increase or diminution of the physiological curves.

That scoliosis may change in type from one clinical picture to another in the same patient in the course of years is well established. Not only does the total curve frequently change to a compound type as mentioned, but the structural curves change most frequently by the



addition of compensatory curves, *e. g.*, the illustration shows the change of a right dorsal to a right dorsal left lumbar curve (Figs. 52 and 53). The frequency of this is not yet known, and can only be determined when a sufficient number of exact records reaching over a series of years has been accumulated.

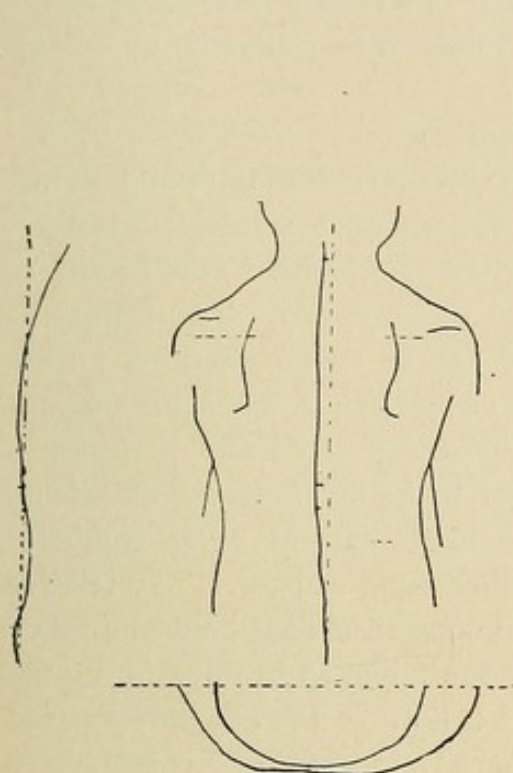


FIG. 52.—SCHULTHESS' TRACING OF A GIRL SIX YEARS OLD.—(*Schulthess.*)

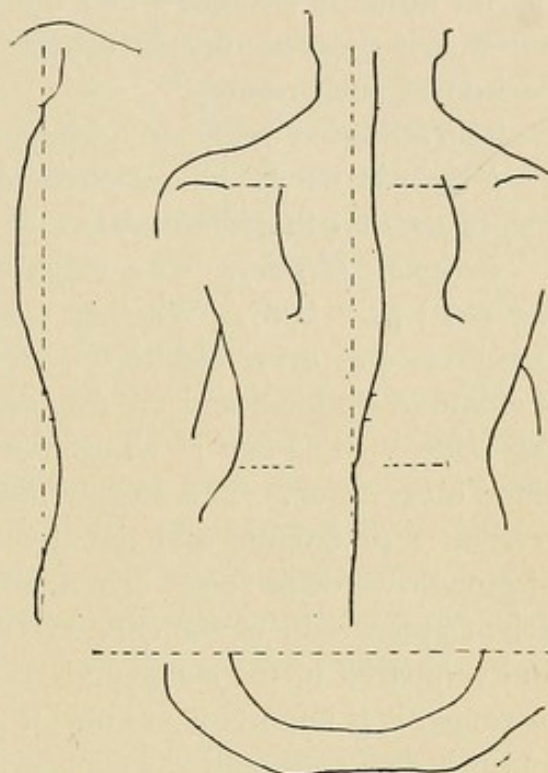


FIG. 53.—TRACING OF THE SAME CASE EIGHT YEARS LATER.—(*Schulthess.*)

The frequency of the common types as tabulated in 1137 cases by Schulthess was as follows:

|                      |       |           |
|----------------------|-------|-----------|
| Total scoliosis..... | 15.39 | per cent. |
| Lumbar.....          | 11.7  | "         |
| Dorsal.....          | 19    | "         |
| Dorsolumbar.....     | 20    | "         |
| Cervicodorsal.....   | 3.6   | "         |
| Compound.....        | 30    | "         |



## CHAPTER V.

### EXAMINATION AND RECORD OF SCOLIOSIS.

It is a matter of practical importance that an accurate examination and reliable record be made of cases of scoliosis, for not only is it essential for accurate treatment that the curves be clearly formulated at the outset, but progress under treatment is only to be estimated by a comparison of such records.

The following points are of importance:

*Family History.*—The occurrence of scoliosis in the family and the history of any hereditary deformity. The existence of a tuberculous history.

*Personal History.*—The character of the labor. The health of the child as a baby. Whether nursed or bottle-fed. The history of infectious and other sicknesses. The age at which dentition began, the date of walking, and the existence of bowlegs or any signs suggesting rickets. The age at which the curve was noted and its progress since observation. The child's mental make-up, progress at school, resistance to fatigue, and liability to slight illnesses. The character of growth, whether recent or not, whether rapid or slow. The relative height and weight of the child are of importance and should be taken and compared to the average given in the table, as in formulating the prognosis it is important to know if the child is of average development and if it may reasonably be expected to have in prospect a considerable period of growth.

AVERAGE HEIGHTS AND WEIGHTS.—(T. M. Rotch.)

| BOYS.              |                    | AGE.     | GIRLS.             |                    |
|--------------------|--------------------|----------|--------------------|--------------------|
| HEIGHT.<br>Inches. | WEIGHT.<br>Pounds. |          | WEIGHT.<br>Pounds. | HEIGHT.<br>Inches. |
| 19.75              | 7.15               | Birth.   | 6.93               | 19.25              |
| 24.75              | 14.30              | 5 mos.   | 13.86              | 23.25              |
| 29.53              | 20.98              | 1 year.  | 19.80              | 29.67              |
| 33.82              | 30.36              | 2 years. | 29.28              | 32.94              |
| 37.06              | 34.98              | 3 "      | 33.15              | 36.31              |
| 39.31              | 37.99              | 4 "      | 36.36              | 38.80              |
| 41.57              | 41.00              | 5 "      | 39.57              | 41.29              |
| 43.75              | 45.07              | 6 "      | 43.18              | 43.35              |
| 45.74              | 48.97              | 7 "      | 47.30              | 45.52              |
| 47.76              | 53.81              | 8 "      | 51.56              | 47.58              |
| 49.69              | 59.00              | 9 "      | 57.00              | 49.37              |
| 51.68              | 65.16              | 10 "     | 62.23              | 51.34              |
| 53.33              | 70.04              | 11 "     | 68.70              | 53.42              |
| 55.11              | 76.75              | 12 "     | 78.16              | 55.88              |
| 57.21              | 84.67              | 13 "     | 88.46              | 58.16              |
| 59.88              | 94.49              | 14 "     | 98.23              | 59.94              |



The weights at birth, and in the first, second, and third years, were without clothing. The ordinary school clothes were worn in the weighing from five to fourteen years.

## EXAMINATION.

### GENERAL CONDITION.

Nutrition and development. Color. Nervous condition. Condition of muscles. Condition of heart and lungs. Chest expansion. Comparative length of legs. Flat-foot. Whether or not spectacles are worn. General attitude and carriage. Manner of wearing clothing, whether objectionable or not.

### EXAMINATION OF SPINE.

A patient with suspected lateral curvature should always be examined with the back wholly bare. The clothes should be firmly pinned or fastened by a strap around the hips at a level low enough to show the top of the cleft between the buttocks and to show the outline of the hips. In children the patients should be stripped to this level; in adolescent and adult young women the chest should be covered by an apron hanging over the front of the thorax, the strings of which are fastened around the neck.

The patient should stand, back to the surgeon, squarely on both feet with the arms hanging at the sides. It is desirable to allow the patient to stand quietly for a minute or two before beginning the examination in order to secure the fatigued or relaxed position which is the characteristic one. The patient should not be handled or touched during inspection, as the contact of the hand frequently stimulates the muscles and negatives for the time being the relaxed position.

**Inspection of the natural standing position** forms the first step in the examination. The surgeon notices first—(1) the body outline, whether symmetrical or not, comparing on both sides the outline from the axilla to the crest of the ilium, whether one is flatter or more curved than the other, whether one arm hangs further from the side than the other. The apparent prominence of one hip is noted. The trained eye estimates this asymmetry as a lateral displacement of the thorax or trunk with regard to the pelvis, and it is the safest guide. The appreciation of symmetry is essential in giving corrective gymnastics, and the most useful method to one trained is to erect an imaginary perpendicular from the cleft between the buttocks (anal fold) and estimate whether it cuts the trunk in the middle or whether more of the trunk



lies to the left or right of it. It is obvious that if any part of the spine is laterally curved, it must carry with it a segment of the body to the right or left. This displacement will be seen by a change of body outline, and a change in body outline on the two sides is presumptive evidence of a lateral curve. The outline of the body and displacement of the trunk to one side may always be seen more plainly from the front than the back, as the outline is sharper. In children this method should follow the one described.

(2) The surgeon next notices the level of the shoulders, whether one is higher than the other, and whether this is a constant position. The elevation of one shoulder is generally a sign of lateral curvature, but may exist rarely with no perceptible curve.

(3) The position of the scapulæ should then be noted and the two sides compared. It is not of primary importance, but it is desirable to note their relative distance from the spine, whether one or both of the scapulæ are displaced forward, and whether any rotation of the bone has taken place.

(4) The habitual position of the head should be noted, whether tipped to one side or held constantly rotated.

(5) The anteroposterior physiological curves should be investigated and any increase or diminution of the dorsal or lumbar curves noted.

**Estimation of the Spinal Curve.**—Over the middle of each spinous process a mark is then made on the skin by a flesh pencil or by ink while the patient still stands as described. The skin must not be drawn to one side or the other in making these marks, or distortion may be caused by the movement of the skin over the bony points. This line of marks is accepted as representing the spinal curve, although it does not accurately represent the position of the bodies of the vertebræ (see Pathology). If a curve is present, the line of marks will be evident as a curved instead of a straight line, for a normal spine shows a line of marks forming a straight line which lies in the median plane of the body.

The median plane of the body is readily determined by holding a plumb-line behind the patient, the lower part of which passes through the cleft between the buttocks. In the normal spine each mark will lie under this plumb-line. The deviation of any number of spinous processes from this line represents a lateral curve which is analyzed as described in Terminology (p. 47).

This method of erecting a perpendicular from below is preferable to the method of dropping a plumb-line from the top of the column (the Beely-Kirckhoff method), which introduces a confusing element



and does away with the consideration of the deviation as a problem of support, making it a problem of the overhang of the top of the column with regard to its base.

Cervical curves must be roughly estimated by the eye, for on account of the inaccessibility of the cervical spinous processes and the instability of the head, they cannot be definitely measured.

The surgeon, having thus recognized and described any bodily asymmetry, and having identified and described the curve, is in a position to investigate the element of rotation or twist which is essential in every case.

**Estimation of Rotation or Twist.**—The surgeon, standing close behind the patient, looks down on her shoulder-girdle from above to estimate whether it is in the same lateral plane as the pelvis or whether twisted forward on one side and back on the other. This is of use chiefly in postural cases, and in structural cases is of less value. By sighting the scapulæ and back of the thorax on the buttocks it is easily seen whether any twist of the thorax has occurred in relation to the pelvis. Evidence of rotation of the ribs or lumbar transverse processes backward on the convex side of the lateral curve, which accompanies structural cases, will in severe cases be evident in the standing position, but it is generally examined for and estimated in a position of forward flexion of the trunk sometimes spoken of as Adams' position. The patient bends forward until the trunk is horizontal with the arms hanging down and the knees not flexed. In this position the patient remains while the surgeon glances along the back from behind or in front, with his head

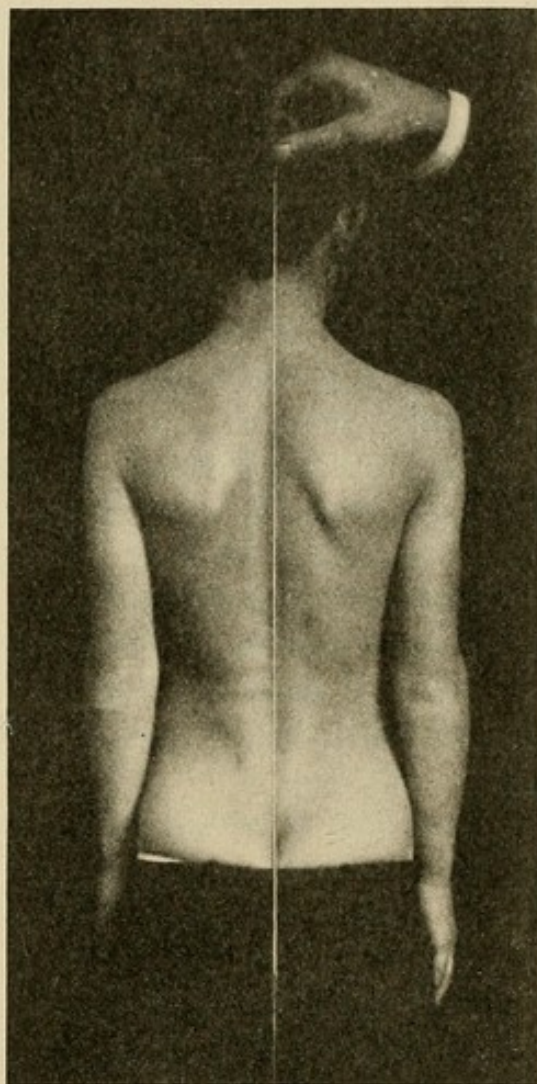


FIG. 54.—THE PLUMB-LINE IN THE CLEFT OF THE BUTTOCKS TO DETERMINE THE MEDIAN PLANE OF THE BODY.



on a level with the spine, and looks to see whether either side of the trunk is more prominent upward in the lumbar, dorsal, or cervical region. Any such upward prominence represents rotation or twist and is a most important matter. If it occurs on the *concave* side of the lateral curve and involves the curved region, it will be slight and evenly distributed through the spine and designates a functional or postural curve. That is, in a left total postural curve the right side of the back will probably be more prominent upward in the forward bent position.

If it occurs as a well-defined local upward prominence occupying the curved region, it designates a structural curve at that location, the curve being *convex* to the side on which the prominence occurs and occupying the same anatomical area. That is, a right dorsolumbar upward prominence designates a right dorsolumbar structural curve. This must be clearly understood, for often a curve which is obscure or confusing in the upright position is cleared up by a recognition of its rotation as seen in the forward bending position. For example, a patient standing erect shows a right dorsal curve, and the inference from the general attitude is that a left lumbar curve probably also exists. It is in any event slight and cannot be clearly defined. If the patient bends forward, lumbar rotation will be present or absent, and on this showing lumbar lateral deviation may be excluded or accepted. A slight difference in the levels of the back at the sides of the lumbar region in the forward bent position is sufficient to establish lumbar rotation.

*Estimation of Spinal Flexibility.*—The patient should now lie on the face and the position of the spinous processes be noted. The marks on the skin will represent the curve of the spine in the erect position, and any straightening of the spine in recumbency will be shown by finding that the spinous processes form a less curved line in recumbency. In postural curves the spine will become straight in recumbency, structural curves will be perceptibly straighter than when the patient is erect. The patient should now be suspended by the arms, or preferably by a Sayre head-sling, enough to take the weight off of the spine, and the straightening of the spine noted. The modification of the asymmetry of the trunk by suspension is most important and should be carefully studied, whether the asymmetry is practically unchanged, whether the overhang of the thorax is corrected, and whether the patient becomes wholly symmetrical. The position of the patient in suspension represents the maximum that may be expected from treatment in that individual case unless further flexibility is restored by treatment directed to that end. The restoration of complete or almost complete symmetry



by suspension points to an early case and one amenable to treatment, for one of the early changes in structural curves is a stiffening of the curved region of the spine which causes the persistence of the curve under suspension. So far as possible it should be noted whether the improvement in symmetry is produced by a straightening of the curve or curves or whether the modification in asymmetry is produced by the other parts of the spine. For example, in a dorsal curve, is the relation of the curved region changed or is the curved part simply pulled away from the pelvis by a stretching out of the lumbar region?

The patient should then bend forward to determine normal flexibility forward. The average child can touch the floor with the fingers while the knees are straight, while in adult life less flexibility obtains.

The flexibility of an individual spine is a matter determined by age, habit, and individual peculiarity. To know in a general way what the normal flexibility at a given age should be is important in children, but in adults it is so much a matter of individual habit that it is of less importance. One man of fifty, for example, who has taken exercise may be able to touch the floor with his hands in forward bending, while another man of the same age of sedentary life cannot get his finger-tips within a foot of the floor in the same position, yet both spines are normal. How rapid the change in flexibility may be owing to habit is shown by the case of a healthy boy of fifteen who could not touch the floor with his finger-tips in forward bending. He injured his knee and was obliged to wear a ham splint. The exertion necessary to dress himself with his leg stiff so increased his forward flexibility that in ten days he could place the palms of his hands on the floor without exertion in forward bending.

The patient then stands with the elbows out and the hands clasped behind the neck, and bends to one side and to the other. The characteristics of side bending have been fully described, and modifications and restrictions of this are to be studied. Patients with curves can, as a rule, bend better to the side that makes the curve worse than to the side that improves it.

*General Condition.*—The examination should conclude with an examination of the chest and heart.

The examination has been dealt with thus at length because rational treatment cannot be undertaken without a clear formulation of the character of the deformity, and experience shows that in the loose use of terms and in slipshod examinations some of the failures to obtain proper results from treatment have their origin.

**X-ray.**—The x-ray is of use in showing the existence of bony defects,



numerical variation, or other anomalies, and the presence of deformity in the bones. It is of great value in showing the character of the curve in doubtful cases, and its results do not always agree with the clinical

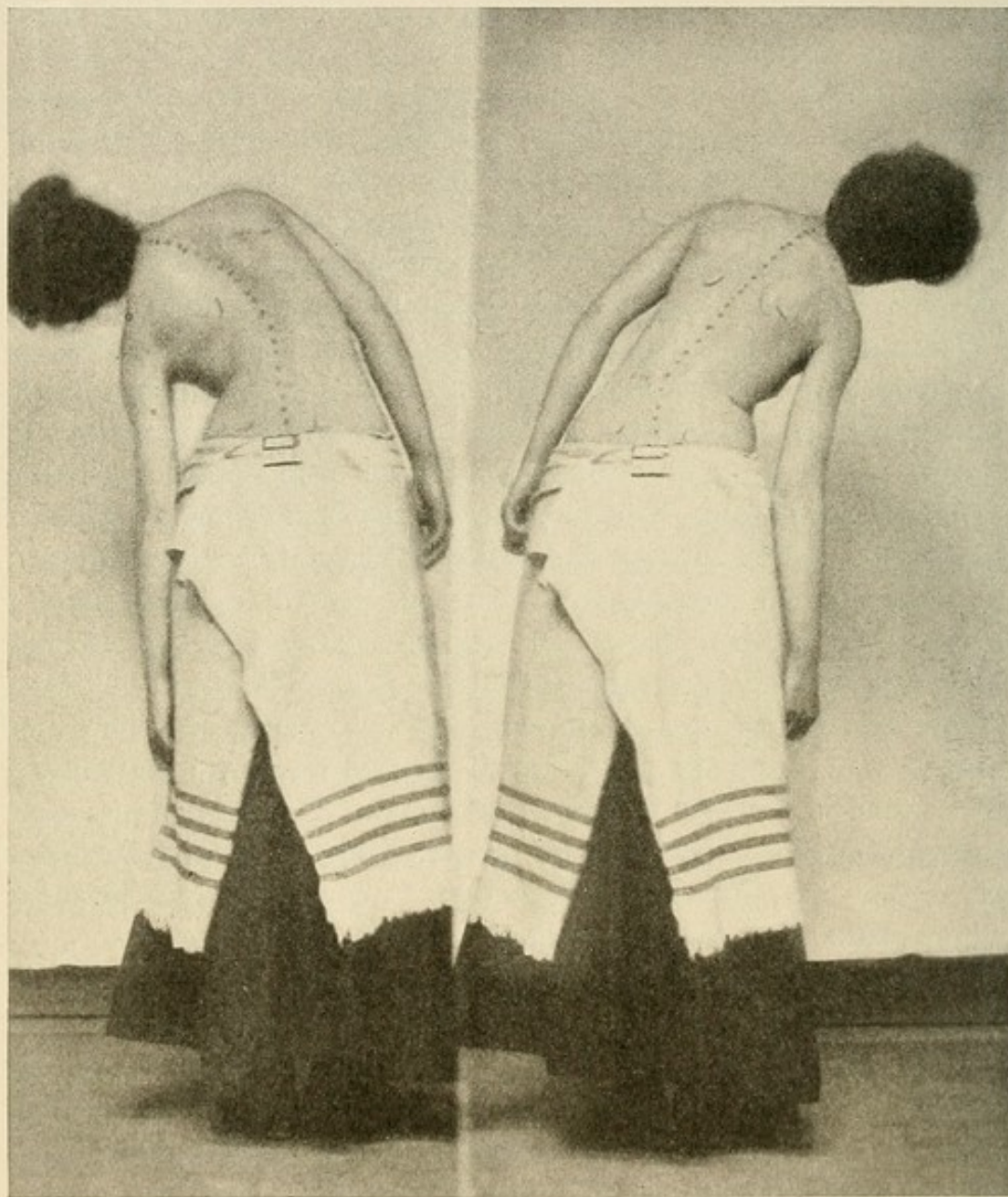


FIG. 55.—PATIENT WITH A RIGHT DORSAL LEFT LUMBAR STRUCTURAL CURVE BENDING TO THE LEFT AND RIGHT, SHOWING THE COMPARATIVE RIGIDITY OF THE LUMBAR REGION TO LEFT BENDING AND OF THE DORSAL REGION TO RIGHT BENDING.

appearances, certain cases judged to be apparently slight by clinical examination showing in the *x*-ray marked bony deformity. The amount of rotation is indicated in the *x*-ray by the position of the shadow of the spinous processes in relation to the shadows of the bodies, normally the



spinous process appearing in the middle of the body. But the element of distortion must be remembered. A patient is likely to be twisted by lying on the back if rotation is present, and any deviation of the tube from the middle line of the body is expressed as distortion of the vertebræ. The *x*-ray does not as yet provide a method of accurate record on account of the ease with which distortion is produced in shadows. *x*-Rays taken in the standing position obviously represent the condition to be treated more correctly than do those taken in recumbency.

### RECORD.

What is required for record is some accurate method within the reach of the average practitioner or specialist on the subject.

#### MEASUREMENTS OF THE LATERAL CURVE.

**Photography**, although open to many objections, is probably the most generally available means of record at our disposal.

The advantages are that no more than average amateur skill in photography is required to get with practice a good picture, that the record can be made in the physician's office, that the results are fairly accurate if taken with great care, and that good photographs may be translated into graphic curves by means of a device to be mentioned.

The objections are that practice is required to obtain proper results, that lights must be studied, that unsteadiness of the patient blurs the picture, that distortion is easily produced by any carelessness, and that the picture at best takes no cognizance of rotation.

The following rules must be observed:

1. The patient must stand at ease with the legs straight and the arms hanging at the sides in the relaxed position, which comes on at the end of about one minute.

2. The heels of the patient must be on a line parallel to the lens, otherwise distortion is inevitable. This relation must be measured and not left to guesswork. The simplest solution is to have a stand for the patient which is provided with two leathers for the heels. This stand is always placed in a definite location, the relation of which to the camera is formulated.

3. The patient must stand at a fixed distance from the camera in all cases if pictures are to be used as accurate records.

4. The light must be oblique from behind, preferably diffused, and not the direct light of the sky if possible, which gives too violent contrasts between light and shadow. A light from overhead throws



the shadow of the shoulders onto the back and obscures the spinal furrow. A light directly from behind gives a flat white picture without contours. A light directly from the side throws the shaded part of the body into such blackness that the body outline of that side is lost. A crossed light obliterates contour and gives a flat and confusing picture.

5. The shadows must be diminished by a white reflector on the side of the patient away from the light. This is easily obtained by the use of a common clothes-horse, one surface of which is covered with sage green, which serves as a background, while the other wing is covered with white to serve as a reflector. The patient faces the green surface while the white surface is placed at the desired angle to throw the light onto the shaded side. By this arrangement contour may be secured in the picture.

6. The unsteadiness and swaying of the patient may be obviated

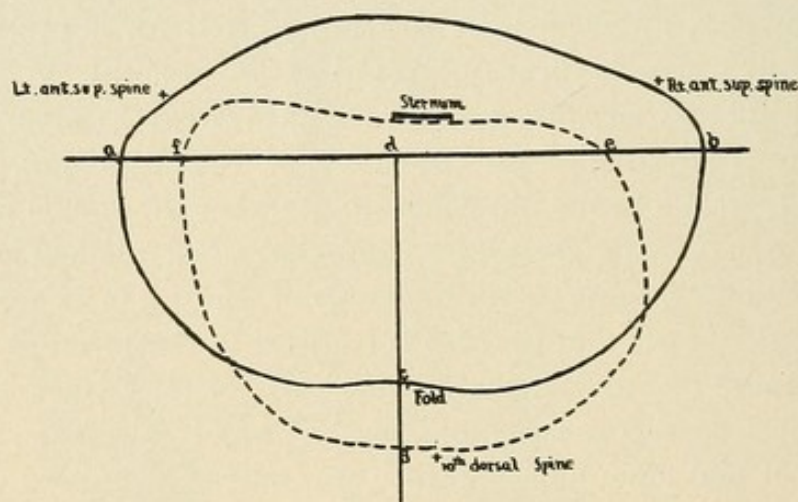


FIG. 56.—TRACING TAKEN BY THE FEISS APPARATUS.—(Feiss.)

in a measure by placing an ordinary photographer's rest against the chest.

*Measurement of Photographs.*—If it is desired to measure and study the curve from the finished photograph, the method devised by Fitz is of value.<sup>1</sup> A fixed distance is decided on at which to take the pictures. A large sheet of paper is then divided into carefully measured squares of any desired size. This sheet of paper is then photographed with the camera at the fixed distance to be adopted. The negative will reproduce the diagram on the paper, each square on the negative representing in measurement the square upon the paper. This diagram on the negative may then be transferred to a thin sheet of clear celluloid

<sup>1</sup> G. W. Fitz: "Bos. Med. and Surg. Jour.," Nov. 16, 1905.



( $\frac{20}{1000}$  of an inch in thickness) by scratching with a needle-point the lines appearing in the negative. By laying this transparent scale upon any print taken at this fixed distance a scale of measurement is provided.

**Tracing.**—A simple and approximately accurate record may be made by marking the spinous processes and laying on the back, while the patient stands erect, a strip of crinoline gauze, through which the spinal marks may be seen. They are thus easily marked on the gauze, which may be kept as a record. The error lies in the possible slipping of the gauze and the necessity of placing the hands on the patient.

Any one interested in the subject may find a number of methods described, together with the literature of the subject, in the reference.<sup>1</sup>

**Record of the Rotation.**—The method of Feiss<sup>2</sup> is fairly accurate and represents the simplest available means of securing a record of rotation in the upright position. The apparatus consists of a square upright on a heavy base; on this upright slides a horizontal arm carrying two arms at right angles with it, all pierced with holes two inches apart, the size of a lead pencil. The patient stands in the apparatus, and by means of a skin pencil pushed through a hole on each side and a hole at the back of the sliding arm three marks are made on the skin in the same horizontal plane. These marks are first made at the level of the anterior superior spines, and then the sliding arm pushed up to the level of the deformity, and through the same holes three similar pencil marks are then made on the skin at that level and at other levels if desired.

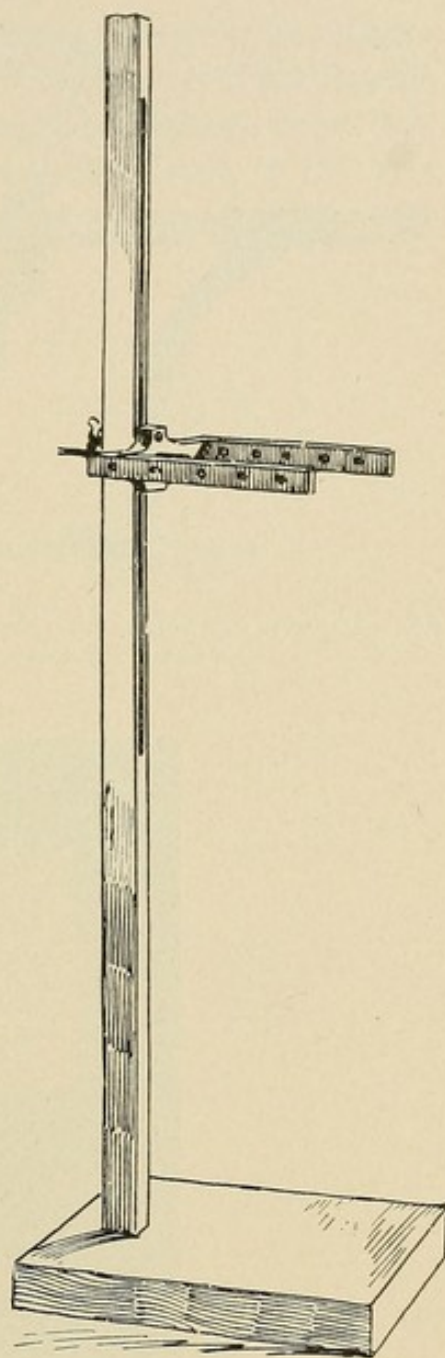


FIG. 57.—APPARATUS FOR RECORDING ROTATION IN SCOLIOSIS.—(Feiss.)

<sup>1</sup> "Ueber die Messmethoden des Rückens," Hovorka, Wien, 1904.

<sup>2</sup> "Bos. Med. and Surg. Jour.," July 13, 1905.



The patient now steps out of the apparatus, and, by means of a rubber flexible rule or a lead strip, front and back tracings are made

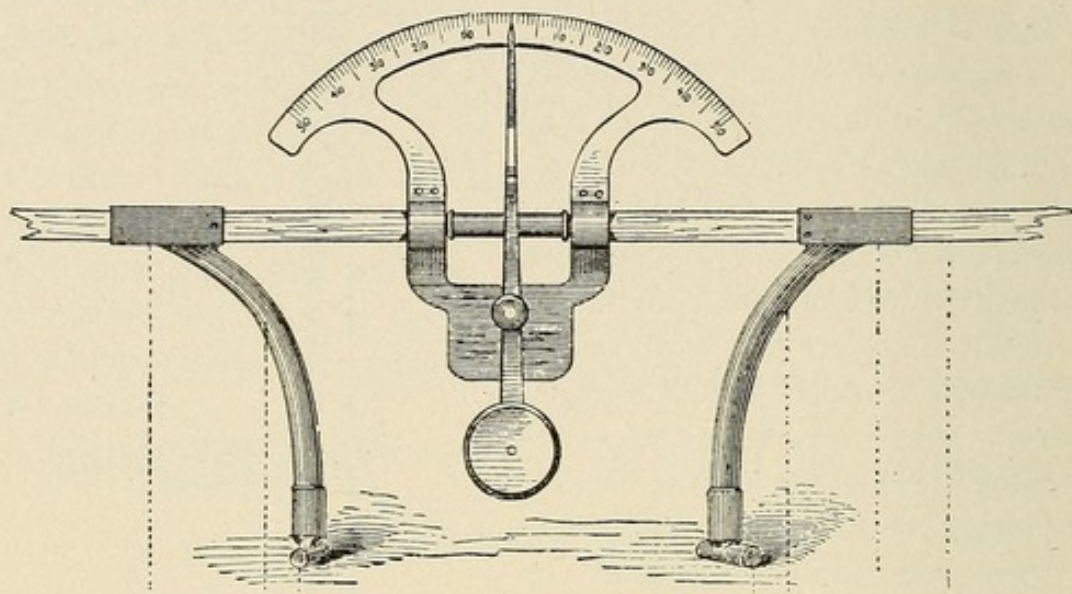


FIG. 58.—LEVELING APPARATUS (NIVELLIER TRAPEZ) FOR THE MEASUREMENT OF ROTATION IN THE FORWARD BENT POSITION.—(*Schulthess.*)




FIG. 59.—SCHULTHESS' MEASURING APPARATUS.

at each level and the three points are marked on the tracings. These tracings are then drawn on a paper, the corresponding marks on each



outline being superimposed, so that as each series of pencil marks is in one vertical plane, the outlines represent a series of superimposed contours in their proper relation to each other.

Rotation may be estimated in degrees with accuracy in the forward bent position by means of the Schulthess level square (Nivellier trapez), which consists of two arms sliding on a rod to which they are at right angles. These arms are placed on corresponding levels of the back

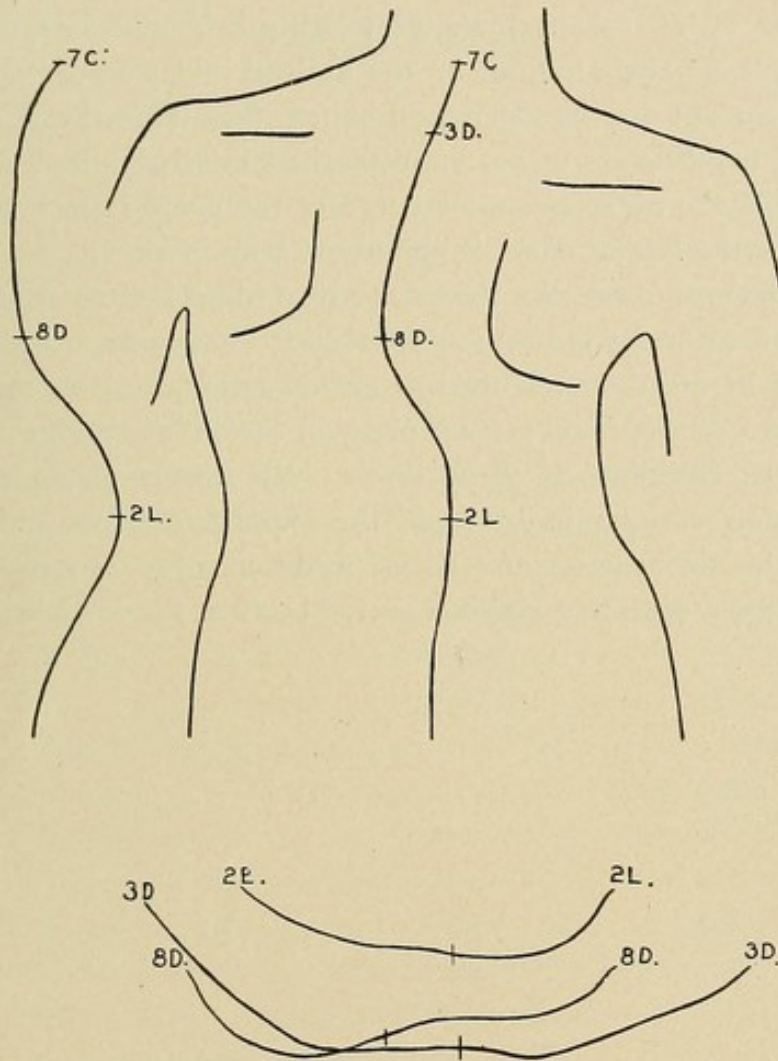


FIG. 60.—TRACING OF A LEFT DORSAL RIGHT LUMBAR CURVE MADE BY THE SCHULTHESS MEASURING APPARATUS.—(*Children's Hospital.*)

at equal distances from the spine, and the rod is provided with a protractor and swinging weight to show the inclination of the rod to the horizontal plane in degrees (Fig. 58).

Methods which would estimate the rotation while the patient lies prone on the face are inaccurate because the pressure of the table on the prominent side of the front of the thorax tends to rotate the chest and cause distortion.



**The Schulthess Apparatus for the Record of Scoliosis.**—The Schulthess apparatus, which is generally accepted as being the most accurate means of record at our disposal, consists of an upright frame in which the patient stands, the pelvis being fixed by clamps and the sternum steadied by an adjustable rod. Behind the patient there is a sliding bridge with counterweights which move up and down on the uprights. Attached to this bridge is a pointer which moves forward and backward and sideways. The movements of this pointer by an arrangement of weights and pulleys are recorded upon two glass panels parallel to the sagittal and frontal plane of the body by means of pencils moving on paper attached to the glass panels. By tracing from below upward the marked lines of spinous processes on one panel the anteroposterior curve of the spine is recorded, while on the other the lateral curve is simultaneously marked.

By a longer pointer the lateral body outline is then traced in the frontal plane after the position of the scapulæ has been recorded. The two pencils in use are then thrown out of action, and by means of a third pencil working upon a glass plate on the sliding bridge horizontal contours are recorded at three levels. By means of an additional sliding bridge working in front of the apparatus a late modification of it provides for anterior as well as posterior contours which may be joined to give a complete contour of the body at different levels (Figs. 59 and 60).



## CHAPTER VI.

### PATHOLOGY.

The pathological changes found in scoliosis are not the result of disease of the bones, but are modifications in shape and structure resulting from abnormal pressure and strain in a growing spinal column.

The pathological changes occurring in scoliosis may vary from moderate asymmetry to extreme distortion. In general the spine is curved to one side in some part of its length, or it is curved in one direction in one part and in the opposite direction above or below or both above and below. This curve is formed by the deviation of the vertebræ from the median sagittal plane of the body and is more marked in the column of bodies than in the column of arches. The lateral curve may be a general sweep to one side, or it may be sharp and in the severer cases angular. In the severer cases it exists not alone in the presacral vertebræ, but may also involve the sacrum and coccyx.

In addition to the lateral deviation, the curved region is rotated or twisted on a vertical axis, the bodies of the vertebræ always turning toward the convex side of the lateral curve. This rotation is the mechanical accompaniment of the lateral curve, and one cannot exist without the other, although in some cases the rotation is out of proportion to the lateral deviation, and in other cases the lateral curve predominates over the rotation. Pure forms of wedge-shaped and lozenge-shaped vertebræ (to be described below) are rare, and both processes are common in the same vertebra.

In connection with the lateral curve, alteration in the normal anteroposterior physiological curves may occur, consisting chiefly of an increased or diminished dorsal convexity. While slightly developed scoliosis leaves the physiological curves almost unchanged, with scoliosis of middle degree there is often found a marked flattening of the dorsal spine, and in severe scoliosis there may be an exaggerated kyphosis in the segment affected by the lateral deviation. In extreme cases there may even be a complete reversal of lumbar and dorsal anteroposterior curves, for, as the lateral deviation is not limited to any one segment,



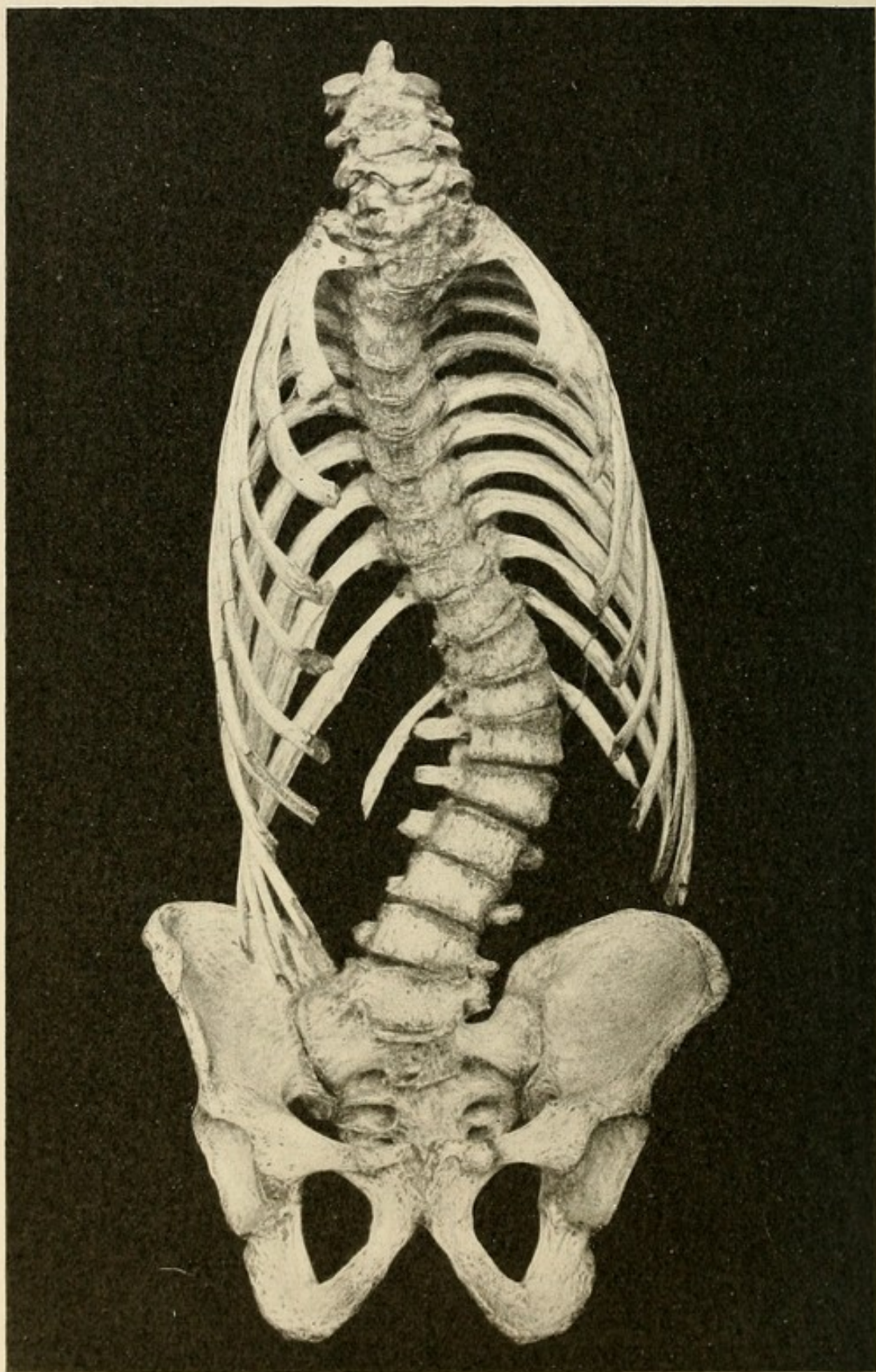


FIG. 61.—SCOLIOTIC SPINE FROM THE DWIGHT COLLECTION OF ABNORMAL SPINES IN THE WARREN MUSEUM.

Sacralization of the twenty-sixth vertebra on the right. Thirteen dorsal and six lumbar vertebrae. Fusion of several vertebrae and of first three ribs on the left. The changes in the vertebral bodies are characteristic of severe scoliosis.



neither is the flattening nor the formation of a backward prominence limited to the points of physiological kyphosis or lordosis. The relation of these changes to the lateral curve is but little understood.

Such being the gross pathological changes occurring in the spine as a whole, it will add to clearness in considering this most complex matter to take up individually the alterations in the separate elements.

#### CHANGES IN THE VERTEBRÆ.

**Vertebral Bodies.**—The scoliotic vertebræ are to be divided into two classes, according to their pathological changes, those in the angle of the curve being called wedge vertebræ, while those between the apices of the curves or between the apices and the normal portion are called lozenge-shaped or oblique vertebræ.

A certain amount of rotation and also a transverse displacement of one vertebra upon another is normally possible up to a certain degree by means of the elasticity

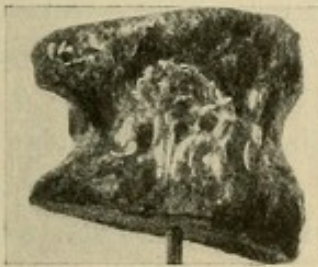


FIG. 62.—A "WEDGE" VERTEBRA.—  
(Schulthess.)

Second lumbar seen from in front; left lumbar curve.

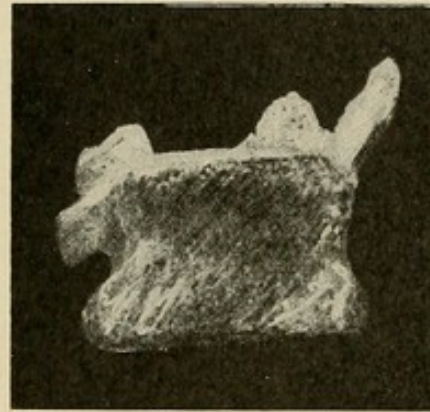


FIG. 63.—AN "OBLIQUE" VERTEBRA.—  
(Schulthess.)

Fourth lumbar seen from the front; from a left lumbar curve.

of the intervertebral discs and the flexibility of the ligaments, but usually the pathological process is not satisfied with the normal excursions, but rotates the vertebra in its structure. This rotation is expressed in the relation of the upper and under surfaces of the vertebral body and in a twist between the body and arch.

**Wedge Vertebrae.**—The vertebræ at the apex of the lateral curve and just above and below it, from one to five in number, are called the wedge or apex vertebræ (Keil- or Scheitelwirbel), and are compressed on one side and consequently wedge-shaped. The obliquity may affect chiefly the upper surface when the vertebræ are below the apex of the curve, and the lower surface chiefly when they are above it, but it may affect both upper and lower surfaces nearly equally, as in



the vertebra at the point of the curve, and some modification of both surfaces is generally to be noted. The thinnest part of a wedge vertebra is found on the side of the concavity of the lateral curve and generally toward the posterior aspect of the body. The side of the body toward the concavity is broadened and lipped in severe cases, and synostosis between two vertebral bodies may occur in this location. As a whole, the apex vertebræ are rotated toward the convexity of the lateral curve.

*Lozenge-shaped Vertebrae* (torsion vertebræ, oblique vertebræ, Interferenz- or Schrägwirbel).—The vertebræ between the apex vertebræ of the two curves or between the apex vertebræ and normal vertebræ are deformed in a somewhat different manner. The upper surface of the vertebra is displaced on the lower in such a way that the outline of the vertebra is lozenge-shaped, the longest diagonal axis being toward the apex of the lateral curve, the top of the vertebra being shoved sideways on the bottom. Such vertebræ may show oblique ridges on the front of the body. The upper part of the body, moreover, twists on the bottom part, below a right dorsal curve, the upper part of the vertebra twisting in the same direction as would the hands of a watch, while above the apex of the curve the twist occurs in the opposite direction. This is called longitudinal torsion.

**The vertebral foramen** in the dorsal region, instead of being round as in the normal, in severe scoliosis becomes pointed at the end toward the concavity. In the lumbar region the normal triangular shape is distorted by being irregularly blunted at the angle on the side of the concavity.

**Arches of the Vertebrae.**—*Pedicles.*—In the wedge vertebra the original elevation of the pedicles may be retained. As a rule, they are lowered on the concave side of the curve and tend to be more oblique on the convex side, but in the vertebra at the point of the curve they may be alike on the two sides. The pedicle on the convex side is directed straight backward and the other backward and outward. In the dorsal vertebræ the pedicle of the concave side may be narrowed, but in the lumbar region it is more generally broadened and the transverse process becomes smaller. In the lozenge vertebræ below the apex the pedicles are likely to be depressed and above it elevated, according to the intensity of the curve. In severe scoliosis the shortening of the trunk is so great that the vertebræ are pressed together, and, as the bodies offer less resistance to compression than the arches, the displacement of the pedicles on the bodies is brought about.

*Articular Processes.*—The articular processes being connected with



the pedicles share in any change that they undergo. Owing to the fact that the joint planes are so different in the dorsal and in the lumbar regions the pathological appearances differ widely in the articular facets of the dorsal and lumbar vertebræ. The crowding together of the articular processes on the concavity of the lateral curve results in an enlargement, deepening, and broadening of the joint surfaces, while on the convex side the facets are smaller and higher. In the lumbar region the superior articular facets on the concave side are hollowed out, while the inferior ones are correspondingly prominent and rounded, and the cartilage is thickened on the concave side. The involvement of these joints is a matter of some practical importance, and the changes suggest an adaptation to greater demands on the joints on the concave side of the column. Synostosis may occur in these joints, and the ligaments may share in the ossification.

*Transverse Processes.*—The transverse processes tend to remain more horizontal than the body of the affected vertebra, and as the vertebra becomes inclined to the horizontal plane by the changes described, the transverse processes strive to remain as nearly horizontal as possible. As a result of this the transverse processes on the convex side above the apex are elevated and below it depressed, on the concave side above the apex they are depressed and below it elevated. In the vertebra at the apex of the curve the level is approximately horizontal. In the lumbar region this change is seen in its most marked form, so that in cases of severe curvature here the transverse processes may point almost straight up and down. Not infrequently the transverse processes are shorter and thicker than normal on the convex side above and below the apex of the curve.

*Spinous Processes.*—The spinous processes are directed toward the convexity of the lateral curve in the dorsal region. This, it seems, may be explained as being the physiological position when the spine is laterally curved and is retained in structural scoliosis under the effect of muscular pull, while the bodies of the vertebræ, being influenced largely by weight bearing, an individual plasticity of bone, and certain unformulated conditions, are forced, as has been said, from the concavity to the convexity of the curve.

In the lumbar region in severe cases the spinous processes are diverted toward the concavity. This deviation, it would seem, is the result of a shoving to the side of the root of the spinous process from extreme rotation, as the tips of the processes show the endeavor to conform to the physiological position by being in some degree approximated to the convexity of the curve. In the dorsal region the spinous



processes are also displaced downward, and the direction of each spinous process is therefore influenced by its contact with the one below it.

The angle between the lower border of the spinous process in this region and the arch becomes on the convex side smaller and on the concave side larger than normal, and the appearance of displacement to the convex side is thus increased. If the arch is displaced horizontally upon the vertebral body, as described above, by the lowering of one pedicle and the elevation of the other the spinous process undergoes

a rotation around its own longitudinal axis. The irregularity of these appearances may be explained by the pull of the muscles, a matter which is at present imperfectly formulated.

**Joints between Vertebrae and Ribs.**—These of course are of two kinds: first, the joints between the heads of the ribs and the sides of the vertebrae; second, the joints between the tubercles of the ribs and the transverse processes. These are both similarly affected in severe scoliosis, being deepened on the side of the convexity and faintly indicated on the side of the concavity, especially above the apex

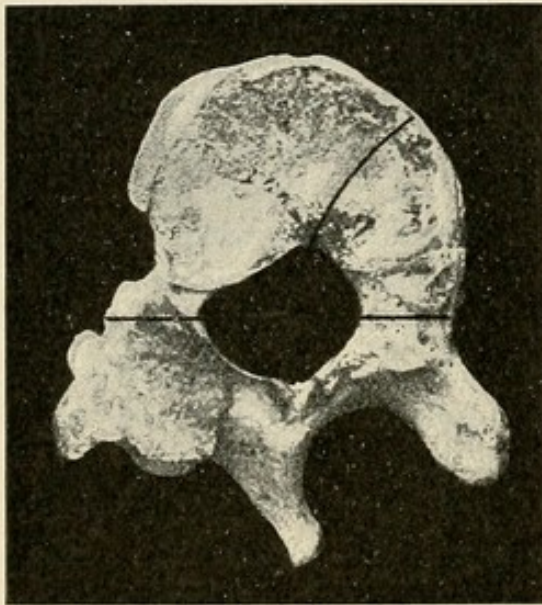


FIG. 64. — DISTORTED ANTEROPOSTERIOR PLANE OF A SCOLIOTIC VERTEBRA.—  
(Riedinger.)

of the curve. The articular facets on the side of the vertebral body are moved forward on the concave side and backward on the convex side.

#### INTERVERTEBRAL DISCS.

These show the earliest changes, and at the points of greatest curve are compressed and project beyond the edges of the vertebral bodies as if the bodies had grown into them. On the convex side they are thicker than on the other.

#### LIGAMENTS.

On the side of the concavity the anterior common ligament is dense and thick, while on the convex side of the curve it is thinned and shows no definite lateral border. In the lozenge-shaped vertebrae the fibers run obliquely in a direction corresponding to the ridges on the anterior



surface of the vertebral bodies. The posterior common ligament near the apex is found more to the convex side than normal because its insertions into the intervertebral discs do not share in the broadening out of the concave side of the vertebral bodies, and the vertebra thus grows to the concave side while the ligament remains more nearly in the middle. The ligaments connecting the heads of the ribs and the spine are long and atrophied on the convex side and short and tense on the concave side.

#### MUSCLES.

Where muscles are thrown out of use they atrophy and may undergo fatty or fibrous degeneration. When increased demands are made upon them they hypertrophy. When under changed conditions they pass over a surface of bone they may become tendinous where the contact occurs. Nutritive or adaptive shortening occurs when the ends of muscles are approximated. All these changes are to be found in cases of severe scoliosis, but the muscular changes in slight scoliosis have not been formulated.<sup>1</sup>

The change which muscles undergo in lateral curvature is first of all a change of direction of pull caused by the displacement of the thorax in relation to the pelvis toward the right or left. For example, if the trunk is displaced toward the left, the muscles taking origin from the crest of the ilium are directed toward the left at their insertion in the spine. Under normal conditions the contractility of the muscles would be sufficient to bring them back to their normal positions, but in a strong lateral inclination of the lumbar segment above the sacrum the psoas muscle, for example, acquires a broad insertion and becomes fan-shaped, thereby assuming a different function. Under normal conditions the insertion of this muscle is more linear and placed at an acute angle to its direction of pull.

Following the loss of function of the muscles on the concave side of the lateral curve in severe cases fatty degeneration is observed. On the convex side the muscles are wasted and thin, and sometimes, in exceptional cases, fatty degeneration is found here also. On the convex side more often a fibrous degeneration is found; that is, atrophy of the muscular tissue and the formation of larger tendons.

The diaphragm assumes an oblique position and is lower on the side of the convexity of the dorsal curve. If the apex of the dorsal curve is situated high up and associated with kyphosis, the top of the diaphragm may be much elevated—even as high as the level of the third rib.

<sup>1</sup> Phelps: "Trans. Amer. Orth. Assn.," vol. xiv.



## THORAX.

In lumbar scoliosis the changes in the thorax are slight, but some rotation of the structure as a whole is noted in relation to the frontal plane of the pelvis.

In dorsal scoliosis the thorax is not only displaced as a whole toward

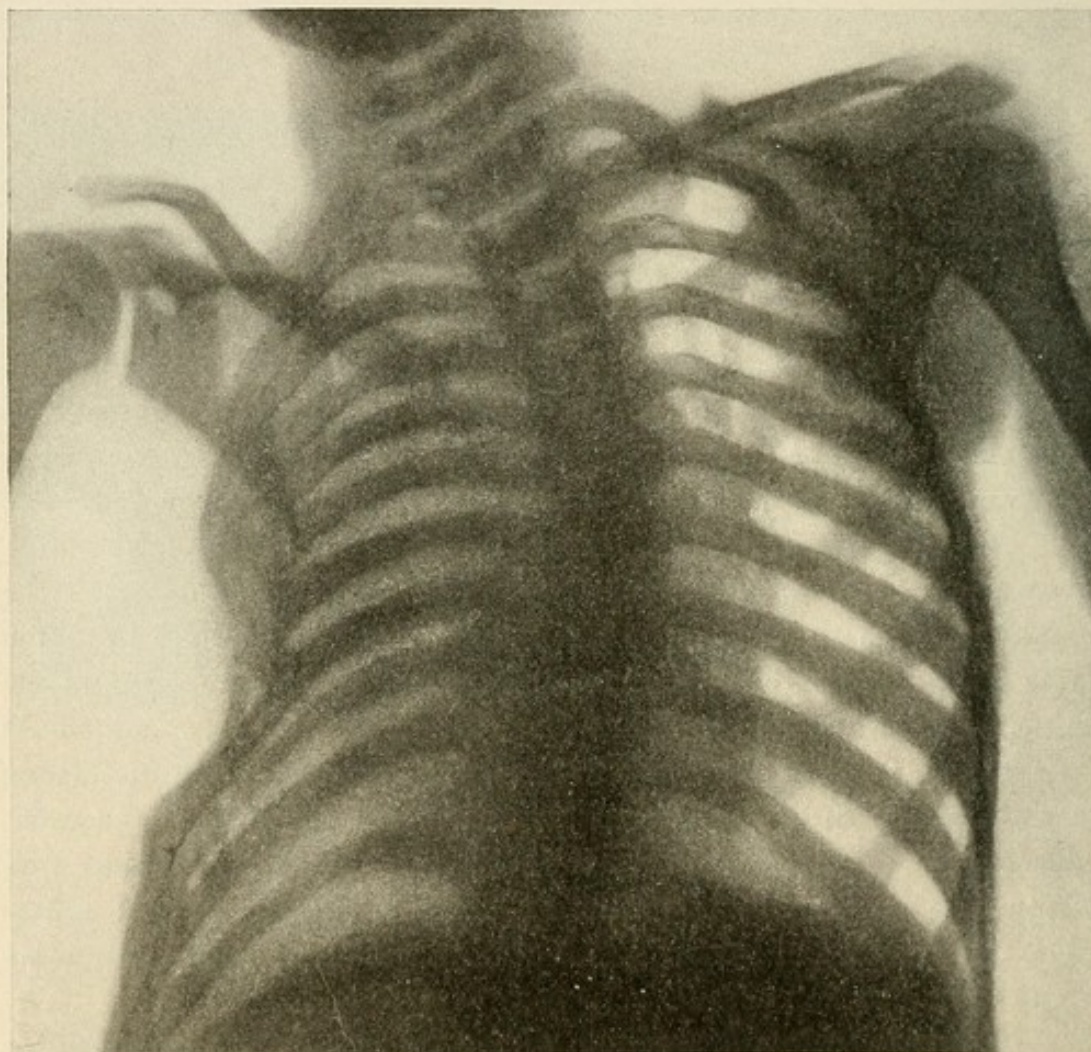


FIG. 65.—RADIOGRAM OF LEFT SCOLIOSIS, RESULTING FROM EMPYEMA OF THE RIGHT SIDE WITH RESECTION OF THE RIBS.

the convexity of the curve, but its structure is distorted. The thorax as a whole tends to retain its normal position with regard to the frontal plane of the body more closely than does the spine, which, as it were, rotates in the thorax. It thus undergoes a twist in the opposite direction from that of the spine. This results in a change in its diagonal diameters, by which the one from the side of the convexity behind to the concavity in front is lengthened, and the corresponding one on the other side is



shortened. For example, in right dorsal scoliosis the thorax is displaced to the right and becomes prominent on the right side behind and the left side in front, and the diagonal diameter from the right side behind to the left side in front is lengthened. As a result of this the internal surfaces of the shafts of the right ribs are brought nearer to the front of the vertebral bodies, and the right side of the thorax is seriously diminished in capacity.

**Ribs.**—The ribs on the convex side of the lateral curve show a backward increase of their angularity, forming on the side of the back of the thorax a more or less sharp and prominent ridge, spoken of technically

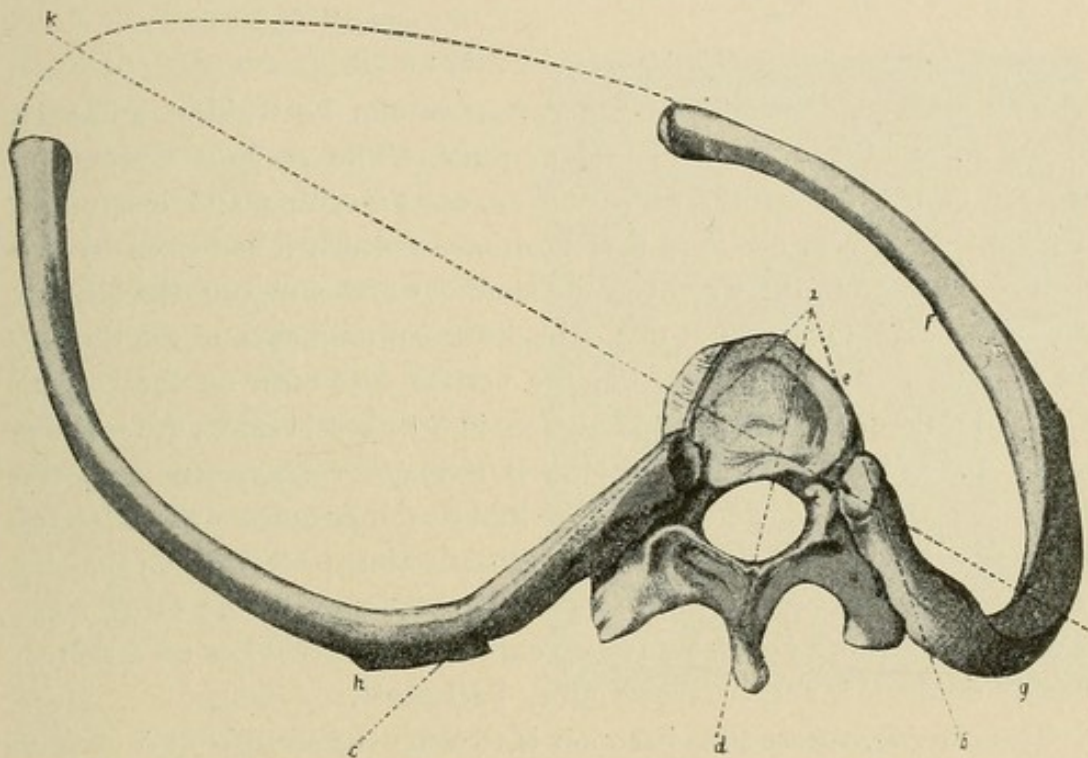


FIG. 66.—THORACIC RING IN A RIGHT DORSAL SCOLIOSIS, SEEN FROM ABOVE.—(Lorenz.)

as "the rotation" (Rippenbuckel). In compound curves of the dorsal region these phenomena accompany each curve.

From the angle forward to the sternum the ribs of the convex side show a loss of their normal curve. The ribs on the side of the concavity of the lateral curve show a straightening of their angles and an increased outward bowing of their shafts. The costal cartilages of the concave side in front show an increased curvature forward and form on the front of the chest a prominence at the side of the sternum (vordere Rippenbuckel).

The ribs of the side of the convexity are spread apart and have a more oblique direction; on the side of the concavity they are closer



together and tend to a more horizontal course. These phenomena are dependent upon the degree of inclination of the part of the spine to which the ribs are attached.

**Sternum.**—The sternum as a rule deviates but little from its normal position and direction except in very severe scoliosis. The variations in position consist—(1) In a lateral displacement; (2) in an obliquity of the lower end, which turns either to the convexity or concavity of the lateral curve; (3) in a rotation around its longitudinal axis, making one lateral border, commonly the one toward the concavity of the lateral curve, more prominent. A detailed study of the variations of the sternum may be found in the reference.<sup>1</sup>

#### SHOULDER-GIRDLE.

The marked deformity of the thorax cannot be without influence on the form of the clavicles and scapulæ. The *scapula* undergoes, because of the deformity, various changes of position and eventually of form. It always acquires that position to which it is forced by the form of the thorax, the weight of the shoulder and arm, and the tension of its muscles. On account of the backward prominence of the thorax, the scapula is moved away from the vertebral column on the convex side, and if the scoliosis is located high up in the dorsal region, the scapula moves upward also. If the thorax is strongly compressed from the side, the scapula may lie sidewise, so that its dorsal surface has a lateral and not a backward direction, or it may swing backward so that its inferior angle crosses the line of spinous processes to the other side. It may furthermore acquire a strong curve on itself if it lies on a thorax sharply deformed, and become convex backward.

The *clavicle*, whose first function is to keep the scapula at a certain distance from the sternum, also changes according to the situation of the spinal curve, and may be found more sharply curved in scoliosis.

#### PELVIS.

**Sacrum.**—In low curves (generally convex to the left in the lumbar region) the sacrolumbar junction becomes practically the apex point, and here one looks for rotation, and pressure changes may continue the curvatures of the presacral vertebræ. The sacrum is affected in such low lateral curves in a way analogous to that of the other vertebræ, but modified in extent by the fixed position of the sacrum. In a right dorsolumbar curve the following changes in the sacrum were found and may be taken as exemplifying them (Schulthess):

<sup>1</sup> Fauconnet: "Zeitsch. f. orth. Chir.," xvii, page 201.



1. A decrease in the height of the first sacral vertebra on the concave side (*cf.* wedge vertebra).
2. A broadening of the base of the sacrum on its concave side (*cf.* broadening of concave side of vertebral body).
3. Forward displacement of the left or concave half with its corresponding ala and backward displacement of the right or convex half (*cf.* rotation of vertebral bodies).
4. Broadening of the part of the sacrum corresponding to the pedicle on the concave side.
5. Lowering of the arch on the concave side.

In addition to this there is to be seen at times a slight indication of a lateral curve of the sacrum, reaching its apex at or below the middle of the bone. In this the coccyx may share, emphasizing the curve, but the sacral curve is most easily seen by sighting along the anterior surface of the sacrum or looking down the vertebral canal. This curve shows slight indications of the same changes noted in the presacral vertebræ.

The pelvis is somewhat changed in diameter and shape in severe low lumbar curves in which the sacrum shows distortion. In a left lumbar curve the diagonal diameter from the left side behind to the right side in front is greater than the opposite diagonal; thus in an individual case of right dorsal left lumbar curve the thorax and pelvis would be twisted in opposite directions.

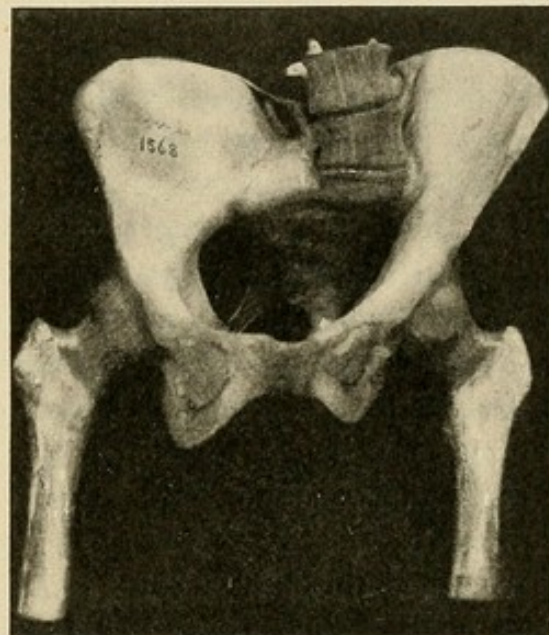


FIG. 67.—OBLIQUE PELVIS ACCOMPANYING SCOLIOSIS.—(Warren Museum, cast from a specimen in Musée Dupuytren, Paris.)

#### SKULL.

In long-continued scoliosis, especially of the upper part of the column, asymmetry of the face and skull has been claimed (Hoffa); on the other hand it has been disputed except in connection with congenital torticollis, asymmetry of congenital origin, and in rickets (Schulthess).



## INTERNAL ORGANS.

In scoliosis, especially in middle and severe forms, a shortening of the trunk is apparent which prevents the normal development and function of the internal organs. By the lateral displacement of the trunk and rotation of the thorax the pleural and abdominal cavities become distorted. The patients become anemic and show a certain disposition to tuberculous pulmonary diseases. Bachmann,<sup>1</sup> in 197 autopsies in scoliotic patients of moderate and severe type, has found in 28.3 per cent. tuberculous disease of the lungs, while in milder degrees of scoliosis there were 66 per cent. so affected.

The secondary changes in the internal organs are essentially dependent upon the narrowing of the containing cavities. In a severe right dorsal curve the right pleural cavity is very much narrowed—so much so that in extreme cases the inner surfaces of the ribs are found lying close to the vertebral column. The narrowing of the pleural cavity on the left, that is, on the concavity, is not so important as that of the right. It follows that the right lung must suffer from the distortion more than the left. Mosse<sup>2</sup> found apex infiltration in 60.2 per cent. of 100 scoliotic children between five and sixteen years old. Kamine v. Zade<sup>3</sup> found apex affections in 73 per cent. of scoliotic women, the lung affection being predominantly of the lung on the convex side of the curve.

Affections of the pleura, adhesive pleuritis, leading to total obliteration of the pleura and atelectasis, are found very frequently. Bachmann gives the following figures: 74.6 per cent. affections of pleura, with 7 per cent. of total obliteration and 31 per cent. atelectasis of lungs. The atelectasis depends either upon the failure of the respiratory muscles to bring about expansion of the lung in certain places, or upon the fact that a real compression between bony walls, or between a bony wall and the diaphragm, has taken place. This compression is more readily possible if certain parts of the lungs are held back by adhesion. Bachmann found such compression in 24.3 per cent. of cases. He furthermore gives the percentage of pneumonia in cases of severe scoliosis as 22.8 per cent.

Undoubtedly the lungs of scoliotic patients, especially in cases of kyphoscoliosis, are predisposed toward a greater number of diseases than the lungs of normal individuals.

<sup>1</sup> Bachmann: "Bib. med.," Abt. 1, Heft 4, 1899.

<sup>2</sup> Mosse: "Zeitsch. f. klin. Med.," xli, pp. 1-4.

<sup>3</sup> Kamine v. Zade: "Deut. Arzte. Zeit.," 1902, xx.



**Heart and Vessels.**—The same narrowing of thoracic space affects the heart. It is frequently found pushed upward and pressed against the anterior chest-wall, and it is at the same time, according to the direction and the extent of the curvature, more or less displaced laterally. In right curves generally the heart is displaced toward the left; but this is not a constant condition. Hypertrophy and dilatation of the cavities of the heart are very frequent, especially of the right heart in severe scoliosis. Bachmann found it in 56.4 per cent. of cases, while the left heart was similarly affected in 17.5 per cent. This phenomenon was found in both right and left sides in 25.9 per cent.

The aorta in general follows the curvature of the spine, particularly in right curves. In a left dorsal curve, however, the aorta does not, as a rule, lie on the convex side of the curve, but runs straight like the chord of an arc, more often in front or even a very little to the right of the spine. The large veins show less typical changes. The vena cava in the region of the liver, where it is relatively fixed, and occasionally at the entrance of the renal veins, may show a change in its course corresponding to the change of position of the organs.

The most reasonable explanation for the hypertrophy of the heart is the insufficient depth of respiration of scoliotic patients. Even in relatively slight distortion of the thorax, respiration is more shallow than the normal, consequently the right side of the heart, in order to push the necessary amount of blood through the lungs, must do an extra amount of work.

If the scoliosis increases, the chest space is restricted still more, and the expansion of the lungs, already damaged by adhesions and thickening, is impeded. The heart is also pressed against the front wall of the chest, and the blood-pressure is changed on account of the bends in the vessels, which conditions add greatly to the work of the heart. The difficulty which the blood finds in passing through the lungs leads to a great degree of venous dilatation if the condition continues long enough. This is especially noticeable in the veins of the head, neck, and arms.

**Esophagus.**—In general the esophagus has a tendency to deviate in the direction of the concavity of the curve, although frequently its form and course are but little changed. The influence upon the course of the esophagus is least when the radius of the curve is a large one and the secondary curve lies below the diaphragm. In every case the esophagus follows a straighter course than the aorta, and it crosses the aorta near the point at which it pierces the diaphragm.<sup>1</sup>

**Intestines.**—The abdominal contents are, in consequence of re-

<sup>1</sup> Hacker: "Wien. med. Woch.," 1887, page 46.



stricted space, pressed downward and forward, and added to this is the influence of the approximation of the chest to the pelvis and the side displacement of the vertebral column. The downward pressure results in crowding the intestines into the true pelvis. The lateral displacement of the thorax affects chiefly the transverse colon, which may become almost vertical.

**Liver.**—In right curves the liver is pushed toward the left, the left half is better developed than the right half, and finally the organ on the right side may be indented by the ribs.

**Kidneys.**—In right dorsal scoliosis the right kidney is often displaced upward along the spine and the left one downward, and while the right kidney suffers as a rule slight changes, the left is more likely to be affected severely from rib pressure. Cystic degeneration and floating kidney are common. Bachmann enumerates, among 180 observations, 14 cystic kidneys, 31 cases of granular atrophy, 18 cases of simple atrophy, and 6 cases of hydronephrosis.

**Spleen.**—The spleen may be higher than normal. Perisplenitis, atrophy, and cyanotic induration have been observed (Bachmann).

**Stomach.**—The position of this is influenced by that of the liver and duodenum. The pylorus is depressed, while the cardiac end generally lies high.



## CHAPTER VII.

### ETIOLOGY—INFLUENCE OF SCHOOL CONDITIONS.

It is difficult to present in a complete yet simple form the manifold causes of scoliosis. The danger of confusion lies in too great subdivision, to which the subject easily lends itself. It is obvious that cases must be of either congenital or acquired origin—further than this the following subdivisions suggest themselves:

- A. Congenital scoliosis.
  - 1. Malformation of the spine.
  - 2. Malformation of the scapula.
  - 3. Malformation of the thorax.
- B. Acquired scoliosis.
  - 1. Anatomical, physiological, or other asymmetries elsewhere than in the spine.
    - a. Torticollis (wry-neck).
    - b. Pelvic asymmetry.
    - c. Pelvic obliquity.
    - d. Unequal vision.
    - e. Unequal hearing.
  - 2. Pathological affections of the vertebræ.
    - a. Rickets.
    - b. Osteomalacia.
    - c. Pott's disease.
    - d. Dislocation.
    - e. Arthritis deformans.
    - f. Tumors, etc.
  - 3. Pathological affections of the bones and joints of the extremities.
    - a. Diseases of bones and joints of the leg.
    - b. Diseases of bones and joints of the arm.
  - 4. Distorting conditions due to disease of the soft parts.
    - a. Infantile paralysis.
    - b. Spastic paralysis.
    - c. Nervous diseases.
    - d. Empyema.
    - e. Organic heart disease.
    - f. Scars.
    - g. Throat and pulmonary disease.
  - 5. Habit or occupation (school scoliosis).



## A. SCOLIOSIS OF CONGENITAL ORIGIN.

Scoliosis due to congenital defects was formerly thought to be a decidedly rare affection. In the last few years it has been recognized that it is much more common than was supposed,<sup>1</sup> and a steadily increasing number of cases are referred to a congenital origin,<sup>2</sup> a change largely due to the use of the x-ray and the more accurate study of the spine thus made possible.

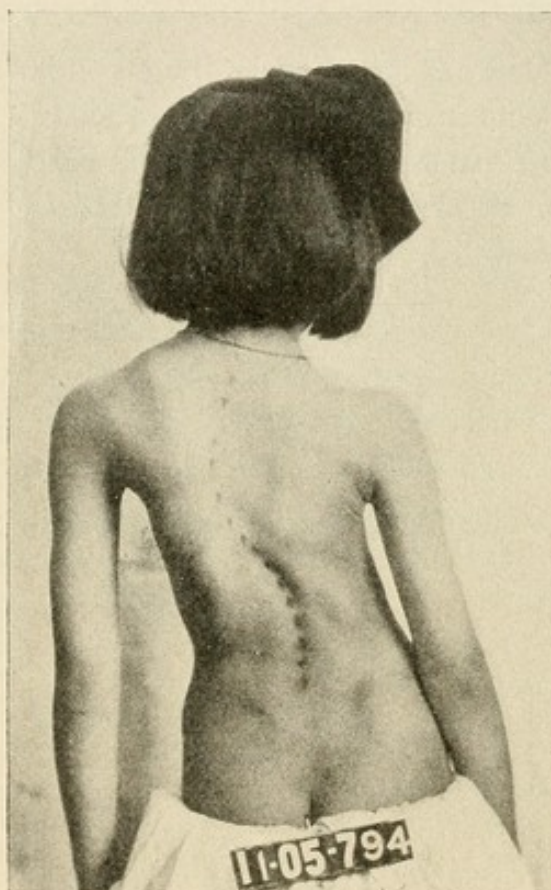


FIG. 68.—SCOLIOSIS DUE TO CONGENITAL DEFECTS IN SPINE AND THORAX, THE RIBS BEING BIFURCATED AND DEFECTIVE.

## 1. DUE TO MALFORMATIONS OF THE VERTEBRAL COLUMN.

Scoliosis may occur as a congenital condition in connection with severe malformations, such as rachischisis and the like,<sup>3</sup> and in connection with "fetal rickets" and paralysis.<sup>4</sup> It occurs also as the result of less severe spinal defects, such as cervical ribs,<sup>5</sup> spina bifida, and abnormal formation of the last lumbar vertebra.

Congenital scoliosis may be evident—(1) immediately after birth, as in the case of the severest malformations (Colville<sup>6</sup> in 1015 cases of new-born children found only one case of scoliosis); or (2) only when the

child begins to walk, in the case of malformations not severe enough to cause a curve in the recumbent position. In these latter cases the curvature appears as the result of the superincumbent weight coming upon the defective spine or as the result of asymmetrical growth due to

<sup>1</sup> Lünig and Schulthess: "Atlas d. orth. Chir.," München, 1901.

<sup>2</sup> Athanassow: "Archiv f. orth. Chir.," 1, 3.

<sup>3</sup> Schmidt: "Allg. Path. und path. Anat. d. Wirbelsäule," Lübersch's "Ergeb. zur allg. Path.," 4. Jahrg., 1897.

<sup>4</sup> Schulthess: "Joachimsthal's Hdbch. d. orth. Chir.," Jena, 1903, iii, 708.

<sup>5</sup> Breuss and Kolisko, quoted by Schulthess.

<sup>6</sup> Colville: "Rev. d. Orth.," 1896, 7.



the malformation. Such cases as these are perhaps not strictly congenital, but might be better spoken of as scoliosis due to a congenital cause.

The two most common locations of congenital defects are in the cervicodorsal and lumbar regions. In the former, cervical ribs are a frequent accompaniment (Halsrippenskoliose). The formation of a cervical rib is often associated with a splitting of the vertebral bodies, as shown by the x-ray, and in some cases the cervical rib is accompanied by a rudimentary extra vertebral body.<sup>1</sup> The shoulder on the side of the cervical rib is elevated, and the curve is a sharp cervico-dorsal one with a compensatory opposite curve below.

In the lumbar region the curve is frequently associated with spina bifida, spina bifida occulta, or sacralization of one side of the last lumbar vertebra.

Böhm<sup>2</sup> has called attention to the fact that numerical variation in the vertebral column apparently plays a part in causing a scoliosis really of congenital origin, but not necessarily appearing at birth. In the Dwight collection of abnormal spines in the Warren Anatomical Museum there are three that show a scoliosis apparently resulting from the numerical variation: (1) a sacrolumbar curve to the left, with caudal variation (see chapter on Anatomy, page 19), and union of the sacrum, one vertebra higher on one side; (2) dorsal scoliosis with cranial variation and cervical ribs of unequal development; (3) dorsolumbar scoliosis with cranial variation and fusion of the last three lumbar and first sacral vertebrae, with asymmetry of the articular processes between the eighteenth and nineteenth vertebrae. All these scolioses are of comparatively slight extent.

Clinically he found from x-ray examination in 16 out of 24 cases of "habitual scoliosis," from which rickets and other acquired causes could be excluded, types of variation at the primary seat of the deformity present. From the fact that numerical variation is not infrequently asymmetrical in the spine the conclusion is presented that such defects may cause scoliosis, which does not appear until the beginning of the second decade on account of the fact that at this time the articular facets undergo a change in character.

Malformation of a part of a vertebra, such as one of the epiphyses, a process, or a part of the arch, will lead to asymmetrical growth, which

<sup>1</sup> Drehmann: "Verhdl. d. Deutsch. Gesell. f. orth. Chir.," 5th Congress, 1906, page 12.

<sup>2</sup> Böhm: "Bos. Med. and Surg. Jour.," Nov. 22, 1906.



may disturb mechanical conditions and lead to scoliosis. Abnormal curves in the anteroposterior plane also occur.

## 2. MALFORMATIONS OF THE SCAPULA.

Congenital elevation of the scapula (Sprengel's deformity) will cause a scoliosis which is usually a high cervicodorsal curve with compensating dorsolumbar curve. One scapula is occasionally absent or malformed (Fig. 69).

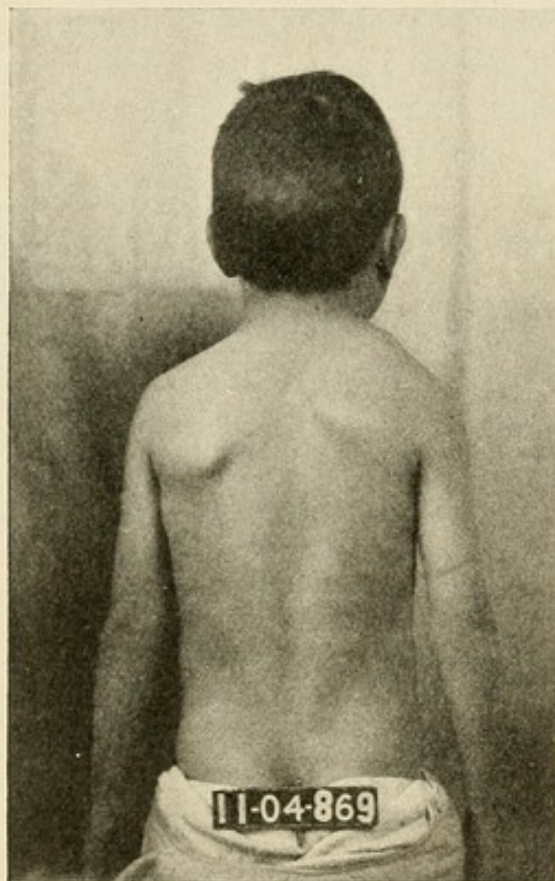


FIG. 69.—CONGENITAL ELEVATION OF THE SCAPULA CAUSING SCOLIOSIS.

## 3. MALFORMATION OF THE THORAX.

Occasionally great irregularity characterizes the ribs of one or both sides. Some may be bifurcated, while others are deficient. Such irregularities are a cause of scoliosis.

Heredity must also be considered, as it is known that scoliosis is apparently inherited in some families, Schulthess estimating that from 10 to 15 per cent. of scolioses are hereditary. Congenital defects of form can be inherited, and would reasonably lead to similar forms of scoliosis, while an inherited weak skeleton or a disposition to rickets would not

necessarily lead to a reproduction of the form of scoliosis. There are cases, however, in which the form also seems to be hereditary.

## B. ACQUIRED SCOLIOSIS.

Scoliosis is to be classed as acquired when the deformity comes on after birth from some cause not apparently congenital, and this includes, so far as we know now, the greater number of cases. It may be said in general that any anatomical or physiological condition which causes the spine to be held habitually curved to one side during the period of growth is a competent cause of scoliosis, and, although certain



individuals under these conditions will escape permanent bony deformity, certain others will acquire a change in the shape of the spinal structure. The experimental production of scoliosis in animals has been demonstrated and is discussed elsewhere (page 42). The acquired varieties of scoliosis may be considered as follows:

# 1. ANATOMICAL OR PHYSIOLOGICAL ASYMMETRIES ELSEWHERE THAN IN THE SPINE.

(a) **Torticollis**, or wry-neck, a condition characterized by the contraction of one sternocleidomastoid muscle, causes a tilted and twisted position of the head and necessitates a compensatory lateral curve of the spine to preserve the balance and enable the head to assume an approximately normal position. Unilateral torticollis, if sufficiently long continued, is always accompanied by scoliosis.

(b) **Asymmetry of the Pelvis**.—The spine is not always located in the middle of the pelvis, but at times is found at one side of the median sagittal plane of the body (amesiality of the pelvis). The pelvis may be in other respects asymmetrical. In these cases a compensating lateral curve is necessary in order to allow the head to be held over the center of the body<sup>1</sup> (Fig. 70).

(c) **Obliquity of the Pelvis**.—Any condition which causes the pelvis to be held higher on one side in the horizontal plane is a competent cause of scoliosis, because such obliquity necessitates a lateral curve of the spine to secure normal balance. A short leg must be counted a frequent cause of scoliosis. But it must be remembered that a difference in the length of the legs is very common in children,<sup>2</sup> and that the frequency of scoliosis is less than the frequency of short legs. The association of short legs and scoliosis has been investigated, with a wide variation in results.

|                    |   |
|--------------------|---|
| Sklifowsowsky..... | 21 cases of scoliosis—17 right leg longer.    |
| Staffel.....       | 230 cases of scoliosis—62 left shorter.       |
| H. L. Taylor.....  | 32 cases of scoliosis—28 shorter on one side. |
| Lorenz.....        | 100 lumbar scolioses—1 case of shortening.    |
| Dolega.....        | 200 scolioses—2 cases of shortening.          |

Schulthess estimates, without analyzing his cases, that from 1 to 5 per cent. show this association. From the figures quoted it may be seen that there is no agreement in the matter, and that it must be determined by the careful examination of large groups of cases. The measurement taken with a tape-measure from the two anterior superior

<sup>1</sup> Barwell: "Edin. Med. Jour.," Feb., 1901; "Brit. Med. Jour.," Feb. 4, 1899.

<sup>2</sup> Bradford and Lovett: "Orth. Surgery," 3d ed., page 476.



spines to the inner malleoli while the patient lies on the back is inexact and of little value as determining the real position of the pelvis in standing, and too much importance must not be attached to it. The most reliable method that we have of determining the horizontal plane of the pelvis and the obliquity which must exist when there is really a

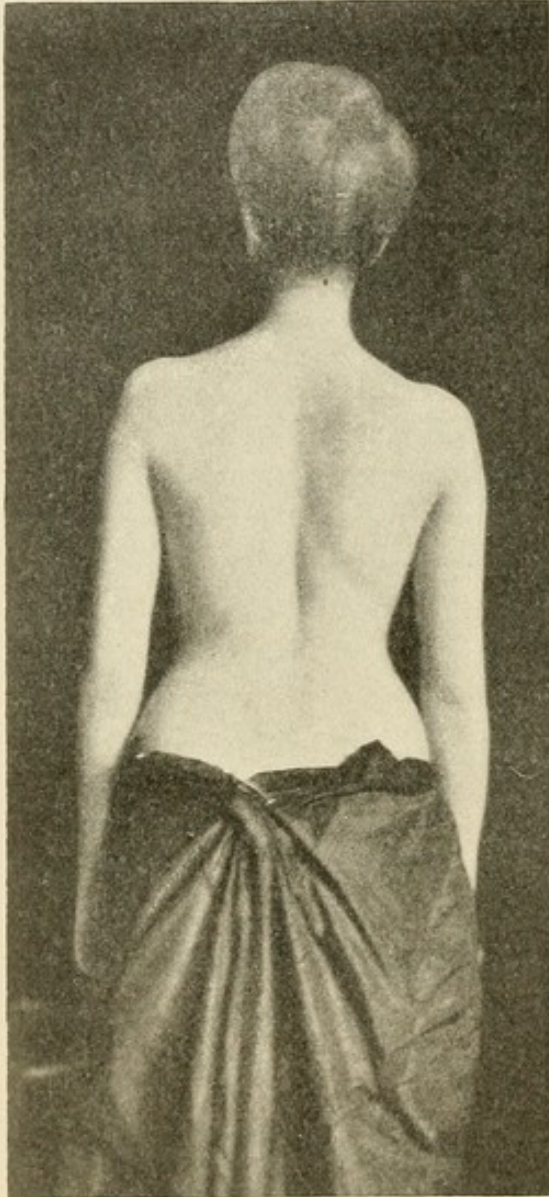


FIG. 70.—SCOLIOSIS DUE TO ASYMMETRY OF THE PELVIS, THE RIGHT SIDE BEING SMALLER.

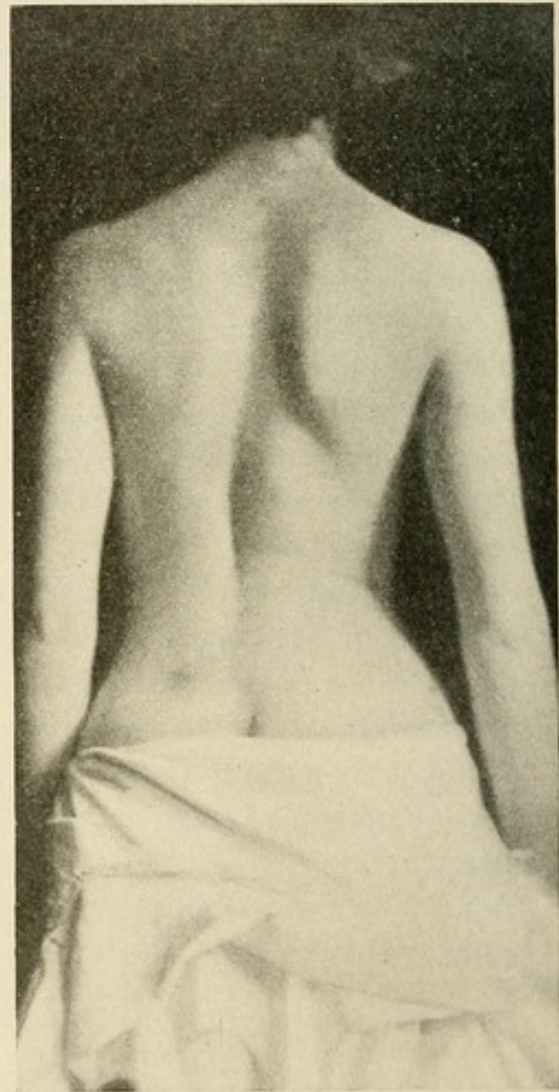


FIG. 71.—LEFT LUMBAR SCOLIOSIS FROM INEQUALITY IN THE LENGTH OF THE LEGS.

short leg is to place a level on the two anterior superior spines when the patient stands erect.

As an example of the little value to be attached to the conventional measurement, the left leg may be one-quarter of an inch shorter by the ordinary measurement taken while lying on the back, yet there may



exist a flat-foot on the right side which does not appear in the measurement and when the patient stands may lower the pelvis a half inch on the right, more than making up for the shortening shown by measurement. It is not an uncommon experience to find that the spinal curve is increased by putting a block under the foot on the side shown to be short by measurement, but that the spinal curve is improved by making the long leg longer by the same method.

To sum up the facts in regard to a short leg and scoliosis: The mechanical aspect would lead us to believe it a likely cause in certain cases. The observers differ widely, and the ordinary method of measurement is inaccurate and often misleading. The determination of the level of corresponding points on the pelvis when the patient stands is the most reliable method of measurement at our command.

(d) **Unequal hearing** causes a tilting or twisting of the head which may produce lateral curvature in the cervical and upper dorsal regions.

(e) **Unequal vision**, necessitating a tilting of the head to bring vertical objects into clearer vision, may cause scoliosis. It has been claimed that the bad postures assumed by children in writing are of ocular origin, and the school observations at Lausanne are of interest here, as a steady increase in the percentage of scoliotic and myopic children was found from the lowest classes upward, as is shown by the table.

| CLASS.    | SCOLIOTIC.    | MYOPIC.       |
|-----------|---------------|---------------|
| I. ....   | 8.7 per cent. | 3.0 per cent. |
| II. ....  | 18.2 "        | 4.5 "         |
| III. .... | 19.8 "        | 5.2 "         |
| IV. ....  | 27.2 "        | 6.0 "         |
| V. ....   | 28.3 "        | 8.5 "         |
| VI. ....  | 32.4 "        | 13.7 "        |
| VII. .... | 31.0 "        | 19.4 "        |

The relation between scoliosis and myopia has not yet been determined.

It is obvious that astigmatism may be a cause of head tilting and consequently will predispose to scoliosis. The subject has been carefully worked out by Gould,<sup>1</sup> whose conclusion is that in asymmetrical astigmatism the axis of the dominant eye determines a tilting of the head to the right or left, but that this does not occur in symmetrical astigmatism.

## 2. PATHOLOGICAL AFFECTIONS OF THE VERTEBRÆ.

(a) **Rickets**, a constitutional disease affecting young children, causes a local or general disturbance in the normal process of ossification

<sup>1</sup> G. M. Gould: "Amer. Medicine," May 21, 1904; Mar. 26, 1904; April 8, 1905; "N. Y. Med. Record," Apr. 22, 1895. H. A. Wilson: "N. Y. Med. Journal," June, 1906.



of the bones, whereby the epiphyses become enlarged and the affected bones soft and plastic. Deformities in the spine occur chiefly in the acute stage of the disease. The softening of the vertebræ causes the column to collapse symmetrically, producing kyphosis, or asymmetrically, producing scoliosis. A large number of scolioses originate directly or indirectly from rickets (Fig. 123).

The severest types of lateral curvature are of rachitic origin. They are distinguished by a shortening of the trunk, so that the ribs may meet the pelvis, and by a marked deformity of the thorax.

(b) **Osteomalacia**, a process like rickets in causing a softening of the bones, but more frequently seen in adolescents and adults, is accompanied occasionally by lateral curvature.

(c) **Tuberculous disease of the spine**, or **Pott's disease**, is a destructive pathological process attacking the bodies of the vertebræ. Lateral deviation of the spine associated with stiffness and very slight rotation often exists in connection with the backward "hump" or kyphosis, which is the characteristic sign of the disease.

(d) Severe injuries of the spine, resulting in chronic sprain of the vertebral column, dislocation of the vertebræ, and injury of the epiphyseal cartilage, may be accompanied by lateral deviation of the spine as a symptom.

(e) **Arthritis deformans** is characterized by a progressive stiffening of the spine due to deposits of newly formed bone on the front and sides of the column, binding the vertebræ together. The intervertebral discs degenerate and the vertebræ become fused; bony deposit occurs in the ligaments, and the articulations of the vertebræ with the ribs may lose some or all motion. Lateral deviation, accompanied by general kyphosis, may result.

Other causes of this class are tumors of the spine and hereditary syphilis. The scolioses of this class are symptomatic of a serious condition, and except for that of rickets are not to be treated like ordinary primary scolioses and would be much injured by such treatment.

### 3. AFFECTIONS OF THE BONES AND JOINTS OF THE EXTREMITIES.

(a) **Diseases of the bones and joints of the lower extremity** play a larger part in the etiology of scoliosis than those of the arm and shoulder. Lateral curvature may be caused by the shortening of one leg, due to derangement of growth; to unilateral diseases of the hip-joint causing shortening, dislocation, contraction, or ankylosis in a position of adduction, abduction, or flexion; to unilateral congenital or paralytic dis-



location of the hip; to coxa vara, coxa valga, and fractures of the lower extremity; to diseases and malformations of the diaphyses of the leg or thigh bones; to diseases of and operations on the knee-joint causing shortening, contraction in the flexed position, or knock-knee on one side; and to diseases and malpositions of the foot, especially flat-foot. Scoliosis due to a shortening of one lower extremity is frequently spoken of as "static scoliosis."

(b) **Diseases of the shoulder-joint**, causing partial or complete ankylosis, may be accompanied by a curve of the spine in the dorsal region.

#### 4. DISTORTING CONDITIONS DUE TO DISEASE OF THE SOFT PARTS.

(a) **Infantile spinal paralysis** or **anterior poliomyelitis** is a fairly common cause of lateral curvature. It occurs during the second dentition in children, although adults show the later changes. The lower extremity is more often affected than the upper. The deformities produced are due to shortening of bone or to muscular paralysis. Scoliosis results in one of three ways:

1. From inequality in the length of the legs, causing a tilting of the pelvis.

2. From unilateral paralysis of the muscles directly controlling the vertebral column, which may cause a deviation of the spine either to that side or to the other side. It does not follow, as shown by Arnd experimentally and as recognized clinically by others, that a paralysis of the muscles of one side of the back is followed by a curve convex toward the paralyzed muscles, as would naturally be expected. The curve is the result of the effort of the patient to adjust his center of

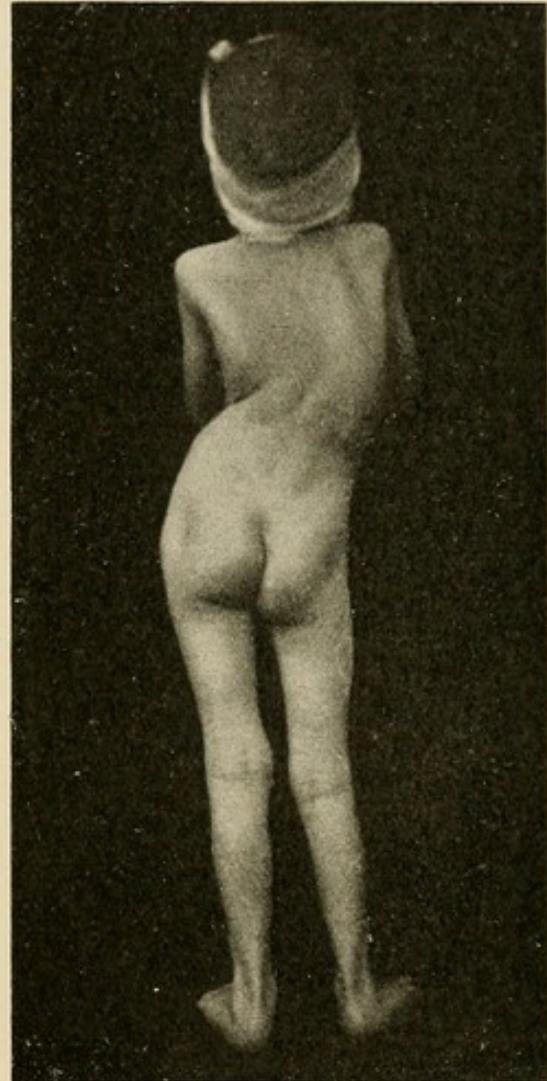


FIG. 72.—RIGHT DORSAL CURVE DUE TO INFANTILE PARALYSIS.



gravity to the new conditions induced by unilateral paralysis. This equilibration may result in a curve convex either to the right or left in a right-sided paralysis.

3. From faulty spinal attitudes assumed in consequence of paralysis elsewhere, as in paralysis of the arm.

(b) **Spastic paralysis** or **Little's disease** in general is the result of a cerebral lesion and a descending degeneration of the lateral columns

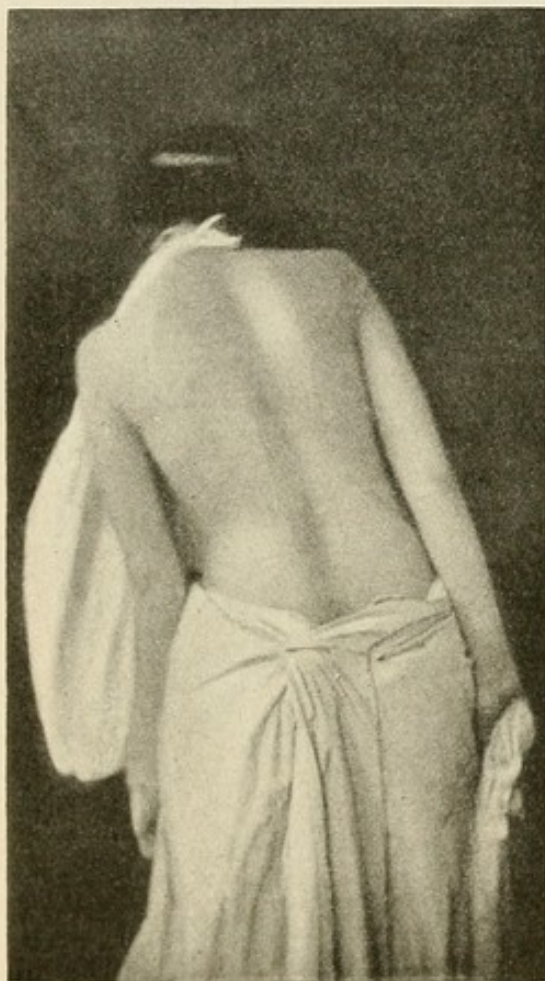


FIG. 73.—HYSTERCAL SCOLIOSIS.

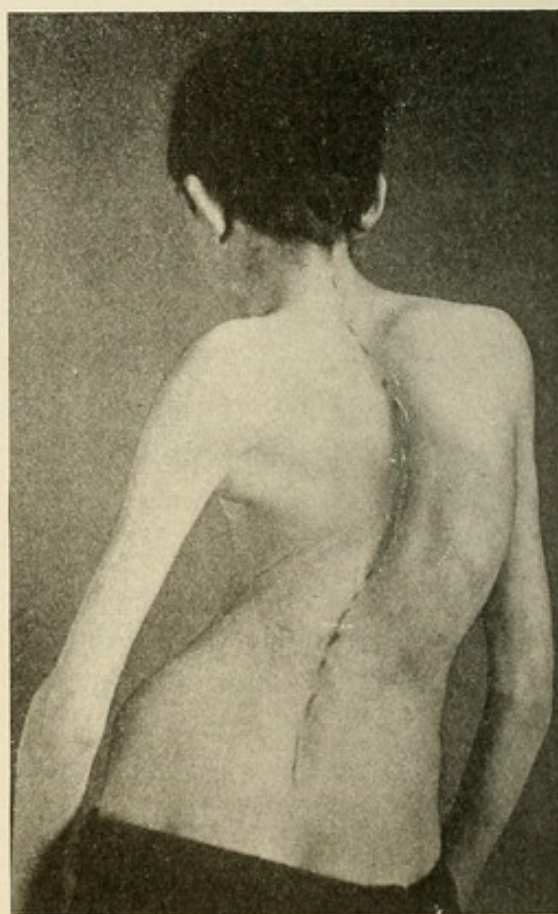


FIG. 74.—RIGHT DORSAL CURVE DUE TO LEFT EMPYEMA.

of the spinal cord. The growth of bones is often retarded, and muscular irritability and stiffness are noted with contractions. Scoliosis is an occasional accompaniment.

(c) **Other nervous diseases**, represented by a much smaller number of cases of lateral curvature, are multiple neuritis, meningitis, cerebrospinal meningitis, syringomyelia, pseudomuscular hypertrophy, locomotor ataxia, Friedreich's ataxia, tumors of the spinal cord, and obstetrical paralysis. Lumbar neuritis gives rise to a lateral curve which is rather



an anomaly of position than a true scoliosis and is called *ischias scoliotica*.<sup>1</sup> A similar malposition is observed in hysteria<sup>2</sup> (Fig. 73). An analogous malposition is found in sacro-iliac disease in which the lateral curve is induced by the instinctive effort to spare the affected joint.

(d) **Empyema** is followed by lateral curvature in certain cases, both without operation and after the operation for removal of a rib. The scar contraction seems to be the cause of the deviation, which is always to the right in left empyema and vice versa.

(e) **Scars** rarely cause scoliosis, although it sometimes is found after extensive burns when the deviation of the spine is brought about by contraction of the scar tissue.

(f) **Phthisis** and diseases of the pleura and obstructions in the nasopharynx are to be mentioned among the diseases of the respiratory organs sometimes followed by scoliosis.

(g) **Organic heart disease**, especially in children, is a competent cause of lateral curvature.

#### 5. HABIT OR OCCUPATION.

A large number of scolioses are observed which cannot be attributed to congenital malformation nor to the direct or indirect results of the pathological process of disease. Some apparently have their cause in an habitual or frequent malposition necessitated by the occupation of the individual, and these are to be classed as habit or occupation scolioses.

In adults, habit or occupation scoliosis is attributed to the habitual and compulsory maintenance of one position for long periods of time, as is required in certain occupations. In these cases the form and extent of the lateral deviation are determined by the form of faulty posture. On account of relative plasticity of bone and periods of rapid growth, accompanied by lax muscular tone, children are especially subject to deformities of attitude and are particularly liable to acquire habit scolioses. Common causes of scoliosis in children are faulty attitudes in sitting and in standing, the former favored by improper school furniture, and the latter by an arrangement of the clothing almost universally bad, which will be discussed elsewhere. Typical instances are found in violin playing, riding horseback on a side saddle, carrying heavy weights asymmetrically, as children on the arm, heavy

<sup>1</sup> Bahr: "Zentralbl. f. Chir.," 1896, 14; Ehret: "Mitt. aus d. Grenzgeb. d. Med. und Chir.," iv, 5.

<sup>2</sup> Binswanger: "Hysterical Scoliosis," "Deutsch. med. Wochens.," Vereinsbeil., 1902, 5.



baskets, and heavy bundles of paper supported by a strap over one shoulder.

It may be considered as possible that the bulk of all scolioses, taking mild and severe cases together, is an "occupation" scoliosis acquired by faulty attitudes at school and elsewhere; but this does not answer the question, because all children are subject to these conditions and only a part develop scoliosis. As a rule, the children affected are of less vigorous build and of slightly poorer physique than those who are not affected. Severe scoliosis accompanied by marked rotation in children is generally due to congenital malformation of the spine, rickets, empyema, or infantile paralysis. Any account of the etiology of scoliosis would be very incomplete which did not make it perfectly clear that in many cases of the deformity the surgeon must be content to leave the cause not satisfactorily accounted for.

**School Fatigue.**<sup>1</sup>—A correct attitude is dependent upon the tone and strength of the muscles by which the upright posture is maintained, so that any cause, such as fatigue, which lowers the muscular tone, has a bearing in this connection.

*Mental Fatigue.*—Muscles become relaxed not alone by physical but by mental exertion and mental fatigue.<sup>2</sup> Mental work is at first stimulating, but if continued for a long time, especially concentrated on one topic, will produce both mental and bodily fatigue.

Continuous mental labor, though of only short duration, will produce a greater degree of fatigue, and that more quickly, than the same amount of work interrupted by brief intervals of rest. A change of work, particularly from a hard to an easy subject, will afford the same relief as a short rest. Severe fatigue comes on with great regularity in periods of the ancient languages and mathematics, while recuperation takes place during history, geography, and nature study. The modern languages occupy a middle place; singing and drawing make rather great demands on those who do well in these branches. After violent or prolonged exercise one is less fit for study, but after moderate exercise intellectual work seems to become easier. The proper relation between physical and intellectual work, in order to obtain the greatest good from each, is a question which should receive the careful consideration of educators.

*Exhaustion in Children.*—One of the first ways in which fatigue shows itself is in the slight amount of force expended in a movement and frequently a lessening in the number of movements. In extreme exhaustion the ordinary movements are not excited by ordinary stimuli, and such as do occur are slow and

<sup>1</sup> Schanz: "Schule und Skoliose," "Zeitsch. f. orth. Chir.," xvii, 170; Krones: "Ueber die Ermüdung und Erholung der gest. Muskeln," Leipzig, 1871; Mosso: "Fatigue," "International Science Series."

<sup>2</sup> Sikorsky: "Sur les effets de la Lassitude provoquée par les travaux intellectuels chez les enfants de l'age scolaire"; Leo Burgerstein: "Die Arbeitskurve einer Schulstunde"; Hugo Laser: "Ueber geistige Ermüdung beim Schulunterrichte."



labored. This may be accompanied by irritability and occasional jerky movements not controlled by circumstances. The eyes may wander and not be distinctly fixed by the sight of the objects around; the face becomes toneless and devoid of expression; there may possibly be a fullness under either eye. Frequently there is manifest an asymmetry of posture and movement. The head is held on one side; the arms when extended are not horizontal—usually the left one is lower; the hand balance is weak; that is, when hands and arms are held straight out in front, the fingers and wrists are not extended, and the thumb is not on the same plane as the fingers; this also is more marked in the left hand. Lack of muscular tone shows itself in a "slumped" position either standing or sitting. The face may be lengthened from relaxation of the muscles and falling of the jaw. Sighing and yawning are common symptoms. Speech is slow, and the tone of the voice altered, and in general there are slowness and inaccuracy of mental response.

**School Furniture.**—It is obviously important to furnish school children with seats and desks which do not favor improper attitudes in sitting and writing. The figures show that scoliosis is a constantly increasing affection during school life, and it is a matter of common information that "school scoliosis" and round shoulders are frequent in school children.<sup>1</sup> In 1842 Barnard, of Hartford, published an article on the subject, followed twenty years later by Fahrner,<sup>2</sup> of Zurich, Meyer,<sup>3</sup> Cohn,<sup>4</sup> Schenk, Lorenz,<sup>5</sup> Schulthess,<sup>6</sup> and Scholder.<sup>7</sup> The most practical study of the matter made in late years was undertaken by the Boston Schoolhouse Commission,<sup>8</sup> and use will be made of their report in this section.

The two things to be prevented in school furniture are—(a) the prolonged stretching of the back muscles by the continued maintenance of flexion of the spine, and (b) the assumption of distorted and twisted attitudes, children with tired muscles tending to rest them by assuming a change of position. Furniture of bad design or improperly fitted tends to favor both of these.<sup>9</sup>

A large number of desks and seats have been devised; it is said that 150 have been proposed, but at least over 30 have been tried. The chair<sup>10</sup> devised for the Boston Schoolhouse Commission in 1903, which

<sup>1</sup> Scudder: "Determination of the Muscular Strength in Growing Girls," "Bos. Med. and Surg. Jour.," Nov. 6, 1890.

<sup>2</sup> "Das Kind u. d. Schultisch," 1865.

<sup>3</sup> "Die Mech. des Sitzens," "Virch. Arch. f. path. Anat.," xxxv, 1867.

<sup>4</sup> "Beitr. zur Losung der Subsellenfrage," Berlin, 1885.

<sup>5</sup> Lorenz: "Ueber die Skol.," Wien.

<sup>6</sup> Schulthess: "Zeitsch. f. orth. Chir.," 1892, i, 1.

<sup>7</sup> "Archiv für Orth.," i, 2.

<sup>8</sup> Boston Schoolhouse Commission Reports for 1901-5.

<sup>9</sup> Feiss: "Cleveland Med. Jour.," Aug., 1905.

<sup>10</sup> Reports of Boston Schoolhouse Commission, 1903, 1904, 1905.



was carefully worked out by Dr. F. J. Cotton in the Scoliosis Clinic of the Children's Hospital, will be here considered as embodying the theoretical requirements and as having worked well on rather a large scale in some years of practical use, there being 22,000 such seats now in use in Boston public schools. The theoretical requirements which are by common consent accepted will be first discussed.

1. The *height* of the seat from the floor should be such that in sitting the feet rest on the floor. Too high a seat produces pressure on the back of the thighs; too low a seat induces flexion of the lumbar spine.

2. The *slope* of the seat should be backward and downward about three-eighths of an inch. The *depth* of the seat should be about two-

thirds the length of the thighs. The *width* of the seat should be that of the buttocks. Some concaving of the seat is comfortable, but not essential.

3. The *back* of the seat should have a slope backward of one in twelve from the vertical line (Saxon regulations). The more modern expression of this is found in two back supports, one low down,  $\frac{1}{2}$  to 1 inch in front of the back edge of the seat, and a second higher up,  $1\frac{1}{2}$  inches behind the back edge of the seat. In the experimental study of school seats alluded to it was found that in



FIG. 75.—BOSTON SCHOOL DESK AND CHAIR.—  
(Boston Schoolhouse Commission.)

a nearly balanced sitting position a relatively low back support was ample and the upper one not required.

4. The *height* of the desk should be such that the back edge allows the forearm to rest on it naturally with the elbow at the side. The height of this edge from the edge of the seat is known technically as the "difference."

5. The *slope* of the desk has been advocated at all angles from 0 to 45 degrees. The theoretically best slope for reading is at least 30 degrees, but this is practically too steep and books slide off, and it is not practicable for writing. From 10 to 15 degrees is the usually accepted inclination. The proper distance of the eyes from the desk is from 12



to 14 inches. The width of the desk is immaterial, 22 to 24 inches being the usual size.

Two separate models for back rests, one for older and one for younger children, were worked out independently by means of modelling wax and wood, and the curves of the two were found to be practically identical. A third model for adolescent girls was later found necessary on account of the larger hips, and was slightly higher, with flattened lower corners. The description of the back rest for the middle group is given here.<sup>1</sup>

"The model finally settled on consists of a curved support of wood, nine and three-quarters inches wide and five inches high, with a concavity of one inch in depth from side to side, with a convexity of one inch in profile, the whole very slightly tilted backward. The maximum convexity lies one-third of the way up, and when properly adjusted comes about opposite, or a little above, the fourth lumbar vertebra. This support is carried on a light casting, running in the groove of a single cast-iron upright attached to the back of the seat. A set-screw fixes the height after adjustment.

"Seats have been manufactured from these models in two sizes, and are used with adjustable desk and seat castings that provide for height and adjustment. As the matter stands, the new furniture provides a seat adjustable for height, with the new back rest also adjustable for height, and a desk likewise provided with a vertical adjustment.

"As to the distance from the seat to the desk, the vertical writing system calls for such a space as shall let the hand come down nearly to the edge of the desk without the elbow striking the back support, namely, a distance from seat-back to desk-edge equal to the length from wrist to elbow. This brings the desk-edge pretty close to the body in comfortable writing position.

"This arrangement makes it possible to write freely and easily with the body pretty evenly balanced, or even leaning backward slightly. With the desk-edge so close the pupil is rather cramped and in poor position for reading. The compromise usually made is to have the desk a few inches further forward; this is well for reading, but for writing this requires a forward sitting position which is undesirable, because—(a) the back loses its support, (b) the supporting of weight on the arm tends to rotated postures of the spine, (c) the posture tends to round shoulders, and (d) the posture tends to bring the eyes too close.

"For these reasons it is desirable to be able to have an adjustment

<sup>1</sup> F. J. Cotton: "American Phys. Education Review," Dec., 1904.



to give a writing and a reading distance to desk from chair to suit the occasion.<sup>1</sup>

"This adjustment should have a range of at least four or five inches. In the avoidance of vicious attitudes this adjustment is of the utmost importance, and a surprising amount has been written in regard to positive, negative, and nil 'distance.'<sup>2</sup> With the 'distance' adjustable we have plenty of room to move about and an easy supported position for reading, and, for writing, a good position with a minimum tendency to lean forward or twist, and with a support to the lower back that works against distortion. With no single position can all these things be attained."<sup>2</sup>

**Writing Position.**—Of late years there has been a tendency to blame the teaching of slanted handwriting for much of the scoliosis, and the teaching of vertical writing was substituted, the patient sitting squarely in front of the desk and writing vertically, with a view of avoiding the distorted position incidental to slanted handwriting. Statistics have been reported in favor of the vertical system. These are:

|                | PERCENTAGE OF SCOLIOTICS. |                      |
|----------------|---------------------------|----------------------|
|                | IN SLANTED WRITING.       | IN VERTICAL WRITING. |
| Nuremburg..... | 24                        | 15                   |
| Zurich.....    | 32                        | 12                   |
| Munich.....    | 24                        | 15                   |
| Fürth.....     | 65                        | 31                   |
| Würzburg.....  | 28                        | 8                    |

To these figures must be attached considerable importance, but the question is by no means settled, Gould, of Philadelphia, having called attention to certain factors previously overlooked.

"With<sup>3</sup> the head and body erect, the paper straight before the median line of the body, and the penholder held as commanded, no person can or will write, for the simple reason that the writing and the writing field about the pen-point are hidden by the writing hand and the penholder. Immediately the pupil skews the paper, tilts the head to the left, and grasps the holder differently—all in order to bring the writing field and letters being made into clear view, and especially of the right or dominant eye.

"The slanted handwriting is due merely to the fact that less torsion

<sup>1</sup> "School Seats," "Bos. Med. and Surg. Jour.," Oct. 5, 1899, page 338.

<sup>2</sup> Distance is the horizontal distance from the desk-edge to the front edge of the chair, positive when the chair is behind the vertical, negative when they overlap, nil (Null-distanz) when the edges are one above the other.

<sup>3</sup> G. M. Gould: "American Medicine," ix, 14, 562, 1905.



or rotation of the head to the right is rendered necessary, and a slight easing is secured by slanting the letters to the right.

"The cure of the false position and of slanted handwriting consists in: (a) Placing the paper vertically, and opposite the right shoulder, and upon a desk leaf pitched at an angle of 30 degrees, and 12 to 14 inches from the eye, the body normally erect and hygienically posed.




FIG. 76.—THE HAND IN THE WRITING POSTURE AS USUALLY ORDERED, BUT NOT PRACTISED, BECAUSE TO THE WRITER THE WRITING FIELD IS HIDDEN BY THE THUMB, FINGER, AND HOLDER.—(*Gould.*)

A view of the hand, as seen by the writer, with the head displaced in photographing.

(b) Or, by the use of angled penholders, leaving the paper straight in front of the body. (c) The grasping the old straight holder between the first and second fingers, or as the Japanese and Chinese do their brushes, from two to three inches from the point, and the upper end held vertically or somewhat slanted to the right. This would require that our common steel pens should be made somewhat differently."



## CHAPTER VIII.

### OCCURRENCE.

Scoliosis is not wholly a disease of the upright position, as it has occasionally been found in mammals, fowls, and fishes. A case occurring in a pig has been carefully studied by Schulthess.<sup>1</sup> A case in a goose has been reported by Schmidt,<sup>2</sup> and it has been observed occurring spontaneously in a goat. In such cases a true rotary lateral curvature has been found with a turning of the vertebral bodies toward the convexity of the lateral curve. Double curves have been observed. Experimentally it has been produced in dogs, rabbits, and goats by Wullstein, Arnd, and Ribbert.

In the human spine scoliosis is usually developed during the years of growth. In its lighter forms it is very frequent. Lateral curvature occurs in all classes of people, though certain forms are more commonly found in certain classes than in others, *e. g.*, in America the rachitic forms more frequently occur in negroes and southern Europeans.

Statistics are lacking as to the percentage of scoliosis in the population as a whole. It is only in hospitals and institutions that such records are made, and these cannot be regarded as indicating the true situation because the clienteles of various hospitals differ so widely. As examples of the numbers furnished by orthopedic institutions may be cited those of Fischer, Behrend, and Schanz. Fischer found 353 scolioses among 3000 patients; Behrend with the same number found 900 scolioses, and Schanz in 1000 patients found 295 cases of scoliosis. The figures of Behrend and Schanz show approximately  $33\frac{1}{3}$  per cent. of scoliosis.

Statistics made from the records of the examination of large numbers of school children are the only means of estimating the percentage of scoliosis rationally, and they are especially valuable as showing the frequency of scoliosis during the school years. The following table shows that scoliosis is found in from 25 to 50 per cent. of the children in city schools. In this, as in all the other tables given, it must be

<sup>1</sup> "Zeitsch. f. orth. Chir.," 1901, ix, 1, page 7.

<sup>2</sup> "Zeitsch. f. orth. Chir.," 1903, xi, 2, page 352, with literature.



remembered that the number of asymmetries recorded depended on the standard of the individual observer, which varies of course with different investigators. A standard which notes the slightest asymmetries of the trunk and the vertebral column will show a much larger percentage of deformities than one which recognizes only the easily identified typical curves. The figures of Scholder may be taken as representative, being recent statistics taken by competent observers.

| INVESTIGATOR.                       | NUMBER<br>EXAMINED. | SCOLIOSES. | PER CENT. |
|-------------------------------------|---------------------|------------|-----------|
| Peter Wissner.....                  | 515                 | 272        | 52.81     |
| Krug.....                           | 1418                | 357        | 25.17     |
| Scholder.....                       | 2314                | 571        | 24.7      |
| Brunner, Klaussner, and Seydel .... | 4169                | ..         | 46.4      |
| Meyer.....                          | 336                 | 189        | 37        |
| Guillaume .....                     | 731                 | 218        | 30        |

## SEX.

In adults it is generally the opinion that women show a greater number of scolioses than men, although published statistics confirming this fact do not exist. Records of the relative frequency of scoliosis in boys and in girls made in orthopedic institutions where patients apply for treatment show a very much larger percentage of scolioses among girls than in boys. That this is not the case in all classes of the community was proved recently by the examination of the school children, which shows that young boys and girls are almost equally affected with scoliosis and that in some instances the percentage of boys is even greater than that of girls. To explain this difference we must either assume that boys outgrow scoliosis, or that they do not come to the institutions for treatment until the curves become severe or until complications arise, while in girls the effects of scoliosis upon the figure are perceptible much earlier, and treatment is sought to remedy curves which in boys would pass unnoticed by the parents. According to different authors, severe forms of scoliosis, usually rachitic, occur quite as frequently among boys as in girls.

The two tables which follow are excellent examples of the difference existing between the records of orthopedic institutions and the figures resulting from the examination of school children. The first table, from the records of institutions where patients apply for treatment, shows 75 to 93 per cent. of scoliosis in girls, and 7 to 20 per cent. in boys. The second table, from the examination of school children, shows the approximately equal occurrence of scoliosis in both sexes.



## FIGURES FROM INSTITUTIONS WHERE PATIENTS ARE TREATED.

|                | BOYS.     | GIRLS.    |                 | BOYS.     | GIRLS.    |
|----------------|-----------|-----------|-----------------|-----------|-----------|
|                | Per Cent. | Per Cent. |                 | Per Cent. | Per Cent. |
| Eulenburg..... | 13        | 87        | Adams.....      | 12.8      | 87        |
| Ever.....      | 7         | 93        | Scholder.....   | 14.8      | 85        |
| Ketch.....     | 17        | 83        | Schanz.....     | 25        | 74.8      |
| Kölliker.....  | 20        | 80        | Rosenthal.....  | 22        | 78        |
| Roth.....      | 8.5       | 91        | Schulthess..... | 14.2      | 85.5      |
| Wedberger..... | 15.9      | 84        | Redard.....     | 15.6      | 83.3      |
| Behrend.....   | 13.4      | 86        |                 |           |           |

## FIGURES FROM SCHOOL CHILDREN.

|                     | BOYS.     |                |           | GIRLS.    |                |           |
|---------------------|-----------|----------------|-----------|-----------|----------------|-----------|
|                     | Total No. | No. Scoliotic. | Per Cent. | Total No. | No. Scoliotic. | Per Cent. |
| Drachmann.....      | 16,789    | 141            | 0.8       | 11,386    | 227            | 2         |
| Scholder and Combe. | 1,290     | 297            | 23        | 1,024     | 274            | 26.7      |
| Krug.....           | 695       | 181            | 26        | 723       | 163            | 22.5      |
| Wisser.....         | 292       | 167            | 57.23     | 223       | 105            | 47.08     |

## AGE.

Scoliosis is an affection of the years of growth in a large majority of cases, but it is often extremely difficult to form an accurate idea of the age at which the deformity begins in individual cases. Scoliosis in very young children may occur from the first up to the fifth year, due to rickets and congenital causes. In general, however, the inaccurate observations of parents furnish no foundation upon which to base theories or statistics concerning the time of the beginning of the scolioses observed in older children.

For the school age, the investigations of Scholder at Lausanne show a steady increase in the percentage of scoliosis, in both girls and boys, from the eighth to the thirteenth year. This increase is especially noticeable from the eighth to the eleventh year, and is probably connected with the rapid growth of children during this period.

| AGE.         | BOYS.         | GIRLS.        |
|--------------|---------------|---------------|
| 8 years..... | 7.8 per cent. | 9.7 per cent. |
| 9 ".....     | 16.7 "        | 20.1 "        |
| 10 ".....    | 18.3 "        | 21.8 "        |
| 11 ".....    | 24.2 "        | 30.8 "        |
| 12 ".....    | 27.1 "        | 30.2 "        |
| 13 ".....    | 26.3 "        | 37.7 "        |

In regard to the age at which scoliotic children are brought for treatment, Eulenburg found over 50 per cent. of all cases between seven and ten years old, and but 10 per cent. between the ages of ten and fourteen years.

The clinical material collected by the Institute of Lünig and Schulthess at Zurich has been used by Sutter and Müller in preparing curves of the frequency of scoliosis at different ages. Müller finds the



greater number of cases in the fourteenth year. The number increases gradually from the eighth to the fourteenth year, and decreases rapidly from the fourteenth to the seventeenth year. Sutter found that the number of boys brought for treatment reached the maximum in the ninth, thirteenth, and fourteenth years. The number of cases under treatment at fourteen years of age is double that for nine years, and shows not only an increase in frequency of scoliosis, but an increase of deformity in curves already existing.

Reviewing the occurrence and frequency of scoliosis the following statements can be made: (1) Scoliosis occurs in all classes of people. (2) There are no statistics concerning the proportion of scoliosis among adults. (3) Children of both sexes show from 25 to 50 per cent. of scoliosis during the school years, with the best authenticated average at about 26 per cent. (4) With regard to sex—(a) in adults women are generally supposed to be affected with scoliosis more often than men; (b) of children at school, boys and girls are about equally affected; (c) of children coming for treatment, the girls very largely outnumber the boys. (5) Scoliosis has been observed in children from the first year. The age at which the greater number of cases are recorded for treatment is given by Eulenburg as from seven to ten, and by Schulthess as fourteen years.

#### RELATIVE FREQUENCY OF THE DIFFERENT FORMS OF SCOLIOSIS.

Statements concerning the frequency of the simple forms of scoliosis are of very recent origin. All statistics agree, however, in showing that for all forms there are more scolioses convex to the left than to the right. There is less unanimity as to which of the single forms is the most frequent. Lorenz states that left lumbar scoliosis is the most numerous. Kölliker, from the examination of 721 cases, finds the simple dorsal scoliosis the most frequent. By considering the tables of other investigators Schulthess found the compound right dorsal scoliosis the most frequent form, followed in order by the simple dorso-lumbar curves, total scoliosis, and lumbar scoliosis. The cervicodorsal form was the least frequent.

Among the 571 school children with lateral curvature out of 2134 children examined by Scholder at Lausanne, 401, or 60.3 per cent., showed curves convex to the left, 121, or 21.1 per cent., curves convex to the right, and 49, or 8.6 per cent., compound curves. The table compiled by Scholder shows the percentage of curves as to their form and convexity. The total curve is the most frequent form in school children,



and is followed by the left and right lumbar curves and by left dorsal scoliosis.

|                          | LEFT CONVEX.   | RIGHT CONVEX. | TOTAL.       |
|--------------------------|----------------|---------------|--------------|
| Total scoliosis .....    | 48.1 per cent. | 7.8 per cent. | 56 per cent. |
| Dorsal scoliosis.....    | 8.4     "      | 4.3     "     | 12.7     "   |
| Lumbar scoliosis.....    | 11.8     "     | 8.5     "     | 20.3     "   |
| Combined scoliosis ..... | 8.5 per cent.  |               | 8.5     "    |

Almost the only records that have been studied and tabulated for definite study are those of the Institute of Lünig and Schulthess, and it is from these investigations that much of the following material is drawn.

**Age.**—At eight years the left scolioses form 64 per cent. and the right scolioses 33 per cent. of the total number of curves. In the fourteenth year the number of curves convex to the left and right is about equal. The number of compensating curves increases from 27 per cent. in the eighth year to 45 per cent. in the seventeenth year.

**Position of Apex of Deviation.**—To ascertain the location of the point of deviation Durrer has constructed a set of curves which show that for the left convex scolioses the maximum deviation is at the dorsolumbar junction, and for the right convex curves the apices are found in the region of the seventh dorsal vertebra, which showed a much greater deviation than the adjacent vertebræ, while in the left convex curves the deviation is more evenly distributed over the length of the spine.

Schulthess finds four principal apices of deviation for single and compound forms of scoliosis: (1) The upper dorsal region to the right; (2) the dorsolumbar junction to the left; (3) the upper dorsal and lower cervical regions to the left; (4) the lower lumbar region to the right.

In the eighth year the maximum deviation of the right dorsal curves is in the region of the sixth to the eighth dorsal vertebræ, and is still found there in the seventeenth year. The apex of the left convex curves in the eighth, ninth, and tenth years is at the ninth or tenth dorsal vertebra; between the ages of eleven and thirteen it is found at the twelfth dorsal vertebra, and descends to the first or second lumbar vertebra between the ages of fifteen and eighteen years.



## CHAPTER IX.

### DIAGNOSIS.

Scoliosis is an affection in most cases appearing before the tenth year; it is not a disease of the spine but the result of mechanical forces acting upon a spine which for some reason is abnormally formed or possesses less than normal resistance. It is not accompanied by any degree of pain and none in its earlier stages. Stiffness, if it is present, is an accompaniment of late cases and the result of long-continued structural changes. The curvature of the spine is self-evident if one hangs a plumb-line in the middle of the back, and scoliosis can be said either to be present or absent in any given case. Of course, absolute symmetry does not exist, but a perceptible variation of the line of spinous processes from a straight line situated in the median anteroposterior (sagittal) plane of the body constitutes scoliosis.

It is important, first, to recognize lateral curvature when it exists; second, it is desirable to identify the cause of the affection if possible; and, third, it is essential to discriminate from scoliosis other affections resembling it, of which it is only a symptom.

*First*, the recognition of scoliosis has been sufficiently discussed in speaking of the method of examination (see chapter on Examination and Record).

*Second*, the differentiation of the varieties of scoliosis is to be made by the recognition of special characteristics in each case (see chapter on Description and Symptoms).

**Scoliosis of Congenital Origin.**—The *x*-ray is of importance in making plain the character of the bony deformity. In the class of cases where a comparatively slight congenital anomaly is present the use of the *x*-ray is essential to establish the congenital origin of the case. Where due to defects in the thorax or scapula, the scoliosis is located in the upper part of the column, is severe and exists in early life. The defects in the chest or thorax are usually self-evident.

**Acquired Scoliosis.**—In acquired scoliosis the existence of torticollis, pelvic asymmetry, and impaired vision or hearing are competent causes of the deformity and should have been identified in the examination. The existence of any one makes it likely that the scoliosis is due



to that as a cause. The discovery that one leg is shorter than the other does not establish that as the necessary cause of the scoliosis for the reasons mentioned, although it is a competent cause.

Rickets is one of the most frequent causes of severe scoliosis. It occurs early and, as a rule, this is a severe and intractable form. Most often the curve is lumbar or dorsolumbar, a compound curve with marked deformity of the thorax, or cervicodorsal. Asymmetry of the head is said by Schulthess to be a frequent accompaniment. The curves are generally rather sharp, thoracic deformity is frequent, and rotation appearances conspicuous. The existence of signs of former rickets is presumptive evidence of this form of deformity; these are enlarged epiphyses, a rosary or beading of the anterior ends of the ribs, a square prow-shaped forehead, and the curvature of the long bones.

*Osteomalacia* as a cause of scoliosis is made evident by the existence of the disease elsewhere.

*Diseases of the joints, of the arms, or legs* is easily distinguished and mention need only be made that this is a competent cause of scoliosis.

*Infantile paralysis* is a motor paralysis of certain groups of muscles or of a whole limb. It is manifested by loss of power in the affected muscles, by loss or diminution of reflexes, by coldness and muscular atrophy, and the reaction of degeneration in the muscles to electricity. The resulting curves are most often low in the spine, are characterized by great deformity and shortening of the trunk, and are not easily mistaken for other forms of scoliosis. The frequent association of scoliosis with infantile paralysis of one or both legs from some slight involvement of the back muscles makes it imperative to examine the back in every case of infantile paralysis.

*Nervous disease* of other forms may be accompanied by scoliosis, but in these it is generally of secondary importance and only of slight or moderate degree as a rule.

*Empyema* and *pleurisy* are recognized as the causes of a severe form of scoliosis, especially when a resection of the rib has been performed in empyema. The curve is always convex toward the unaffected side of the chest and is dorsal or dorsolumbar. It is identified by the scar on the chest or the auscultation signs in the thorax and the history of the case. Any other scar of sufficient size is competent to produce the same result.

*Organic heart disease* is in some cases accompanied by and is presumably the cause of a scoliosis. As the examination of the heart should form a routine part of all examinations for scoliosis, this should be easily detected.



Cases of scoliosis which do not fall into one of the above divisions may be classed as *habit* or *school scolioses*, which is an admission that we are ignorant of the real cause in the individual case.

**Pathological Conditions Accompanied by Lateral Curvature as a Symptom.**—Cases of lateral curvature accompanied by pain, especially if this is exaggerated by motion, should not be given exercises, but kept under careful observation until a perfectly definite diagnosis has been made. The same applies to slight curves accompanied by stiffness of the spine. Doubtful cases may be cleared up by the use of the x-ray.

These must be carefully separated from true scoliosis. The chief one of these is *Pott's disease*, or tuberculosis of the spine. The symptoms of this affection are stiffness of gait and loss of mobility in the spine, pain on motion or jar and spontaneous pain in the chest and abdomen, elevation of temperature, and impairment of the general condition. As the disease progresses a sharp prominence backward of the spinous processes occurs at some part of the spine. Abscesses in the neck, the loin, and the iliac region occur in severe cases. Lateral deviation of the spine occurs in the acute stage of practically all cases, but it is a leaning of the body to one side rather than a true gradual curve; there is no rotation of note, and the lateral deviation is an index of the severity of the disease disappearing after a period of recumbency in bed and being controlled by efficient treatment. The danger of mistaking Pott's disease for scoliosis lies in the early cases before the knuckle, or backward deformity, has occurred.

A form of lateral deviation of the spine accompanies *arthritis deformans*, which is also known under the names of osteoarthritis of the spine, spondylitis deformans, ankylosis of the spine, spondylose rhizomélisque, Bechterew's disease, Steifigkeit der Wirbelsäule, etc. This is essentially an affection of adult life, but not unknown in children. The spine is stiff and painful, the lumbar convexity is diminished or lost, and the curve a gradual one with slight or no rotation. The lateral curve accompanying tumors of the spine, dislocation of the vertebræ, etc., would hardly be mistaken for real scoliosis, the usual signs of those affections being present.



## CHAPTER X.

### PROGNOSIS.

#### WITHOUT TREATMENT.

*Total curves* may remain as such through life, probably increasing somewhat; they may change to structural curves, or they may be cured by proper treatment, but they are not likely to disappear spontaneously. So long as they remain purely functional curves, as defined above, they will probably not influence the general health unfavorably or produce any unpleasant result further than slight asymmetry. In neurasthenic women they are frequently accompanied by backache.

*Structural curves*, whether simple or compound, in young children should be regarded as serious, as almost sure to increase, and perhaps to increase rapidly. They will surely lead to some deformity, and perhaps to grave deformity. They are likely to affect the general health and to shorten life by inducing phthisis and ill health. Adults with severe scoliosis are, as a rule, less vigorous than normal.

Structural curves in older children and adolescents which have not progressed rapidly through childhood are after puberty likely to increase but slowly until late middle life, when the atrophy of the intervertebral discs is likely to make them more evident and troublesome. Severe structural scoliosis at any period of life is to be regarded as likely to shorten the patient's life and to induce ill health. The rapid increase of a postural or structural curve is a threatening symptom demanding attention.

#### WITH TREATMENT.

*Total scoliosis* should be entirely and permanently cured by adequate treatment.

*Structural scoliosis* in young children when of moderate degree should be practically cured by *adequate* and *long-continued* treatment, but only by that. If severe, it should be much improved by the same means, the prognosis in both classes being better in children with a long period of growth ahead than in adolescents.

Structural curves in older children and adolescents when of moderate degree should be greatly improved by *adequate* and *long-continued*



treatment, but cannot be wholly cured. Severe structural scoliosis under these conditions can be markedly improved.

When growth has been reached, only improvement and not complete cure is to be hoped for from treatment in scoliosis of any form. In adults with severe scoliosis the general condition of the patient may be greatly improved by an improved position of the spine. In late adult life support of the spine in the best obtainable position is the only outlook from treatment, again often attended by improvement of the general health.

Scoliosis due to severe congenital defects of the vertebræ, scapulæ, or thorax, to infantile paralysis, or to empyema cannot be cured, but can be improved. Rickets contributes a class of cases on the whole resistant to treatment, and in severer cases, even in young children, a complete cure is not obtainable. The existence of organic heart disease or phthisis makes the prospect of obtaining much improvement from treatment unfavorable.



## CHAPTER XI.

### TREATMENT.

The treatment of scoliosis can be most clearly considered if one separates for purposes of discussion the two types of cases already described (page 49)—(1) the postural or functional, and (2) the organic or structural. That such a distinction is not always sharply to be made, that transition cases are to be seen, and that many therapeutic measures are common to both classes of cases, applies here as in most other departments of medicine and surgery where functional and organic conditions are separated.

#### THE TREATMENT OF POSTURAL SCOLIOSIS (FUNCTIONAL SCOLIOSIS).

Regarding the condition as an habitual inability to stand correctly, as a postural malposition without marked structural change, it is evident that the treatment should consist in the substitution of a correct attitude for the faulty one. This is obviously to be preceded by eliminating conditions unfavorable to the maintenance of a correct upright position and by tonicity. The conditions requiring investigation and possible correction are—(1) seats and desks at school; (2) the manner of clothing the child; (3) the condition of the eyes and ears; (4) the existence of a short leg; (5) overwork or too long hours, leading to persistent fatigue. These matters are also of importance in structural lateral curvature. Having placed the patient under the most favorable conditions obtainable and having corrected the defects above mentioned, the patient should work on the exercises to be described for from half an hour to two hours a day for a period of some weeks. The exercises should not be pushed beyond the limit of fatigue, and after the active period has ceased the child should do home gymnastics and be kept under supervision for at least a year. The length of treatment, the period of the exercises, and the extent to which they can be pushed will depend on the vigor of the child, as half-way measures are not likely to be successful and exercises done at home under the supervision of careless parents are less efficient than those given by



persons trained in the art of gymnastics. The treatment lies within the range of any good teacher of gymnastics who will carry out the instructions of the surgeon. The causes of failure are to be found in the fact that such children are generally in poor muscular condition and are often overworked at school or under unfavorable conditions at home, or that the exercises are given too seldom and are not sufficiently vigorous.

If flexibility to one side is limited, *i. e.*, if the child can bend further to the right than to the left in a left total curve, the flexibility of the spine must be made equal, preferably by means of passive lateral stretching in the apparatus, described on page 146, or by means of gymnastic exercises. Having restored the flexibility of the spine by this means or if flexibility to the two sides is alike, a treatment differing but little from the "setting-up drill" of the army recruit is to be instituted. Exercises suitable for the treatment of postural cases will be described in connection with the gymnastic treatment of structural scoliosis (page 127).

#### TREATMENT OF STRUCTURAL SCOLIOSIS (ORGANIC SCOLIOSIS, HABITUAL SCOLIOSIS, FIXED SCOLIOSIS).

The problem to be met in the treatment of lateral curvature with fixed bony changes is a perfectly definite one. A clear understanding of the obstacles to be met and of the means at our disposal for meeting them is essential to successful treatment.

The spinal column having curved to one side has in the course of years become fixed in the deformed position. In addition to the side curve, a rotation or twist in the length of the column has occurred at the seat of the main and compensatory lateral curves, particularly evident in the thorax. As the result of the maintenance of the vicious position over a long time, covering part of the period of growth, changes in bones, muscles, ligaments, and intervertebral discs have occurred. The individual vertebræ have become compressed on one side or twisted by the rotation. The ligaments and muscles have become adaptively shortened on one side and stretched on the other, and the intervertebral discs to a greater or less extent have become compressed on one side. The region of the vertebral column involved by the curve has lost its normal mobility and is partly or wholly stiff. There are secondary changes in the thorax and abdomen and in the contained organs.

It is obvious that in the upright position gravity works to increase



the deformity by exerting pressure upon the concavity of the curves already atrophied by an abnormal weight bearing. Of the twenty-four hours in each day only some eight or ten at most are spent in recumbency. During the remaining fourteen or sixteen hours the vertical position is assumed and gravity is at work.

The treatment of structural lateral curvature presents, therefore, a much more serious and much less encouraging problem than the treatment of postural cases, and measures must be vigorous, adequate, and *surgically* sound to produce a permanently satisfactory result.

The causes of failure lie in the unwillingness of the parents or the patient to submit to sufficiently long-continued and effective treatment to remedy a condition which, on the slightest consideration, can be seen to be one which is necessarily difficult and resistant.

The surgical treatment of structural lateral curvature must obviously consist of two divisions: First, to loosen up the stiffened parts of the spine to make an improved position possible, and, second, to hold the improved position when it has been rendered possible. These two elements are not sufficiently separated as a rule in treatment; they frequently go hand in hand and treatment must often be simultaneous for both, but it adds very much in a clear formulation of treatment to keep the two things perfectly separate.

The treatment of structural lateral curvature will be described under the following headings: Gymnastics with Apparatus; Gymnastics without Apparatus; Passive Stretching; Forcible Correction; Braces and Corsets; Operative Treatment.

#### GYMNASTICS.

Gymnastics have a two-fold object—first, to loosen up the curved portion of the spine to make an improved position possible, and, second, to aid in retaining the improved position by strengthening certain groups of muscles. Most exercises tend in a measure to accomplish both of these, so that a division into mobilizing and retentive exercises is not possible, and one can only point out that a certain exercise is especially valuable for one or the other purpose.

It is essential to define and limit what place gymnastics should occupy in the treatment of structural scoliosis. It is obviously unreasonable to expect free standing gymnastic exercises to straighten marked or severe curves or to change the shape of distorted bones. But after the greatest possible improvement has been secured in such curves by more efficient measures (passive stretching and forcible correction) one must look to gymnastics to develop the muscles which will hold



the improved position and make the gain permanent after the corrective jacket has been gradually discontinued. In marked and severe structural scoliosis, therefore, gymnastic treatment finds its best use as supplementary to forcible correction.

The *purely* gymnastic treatment of severe structural scoliosis is to-day being largely pursued by two classes of persons. First, by irresponsible masseurs and medical gymnasts who hold as a tradition that gymnastic exercises are curative or at least helpful in scoliosis, and, second,

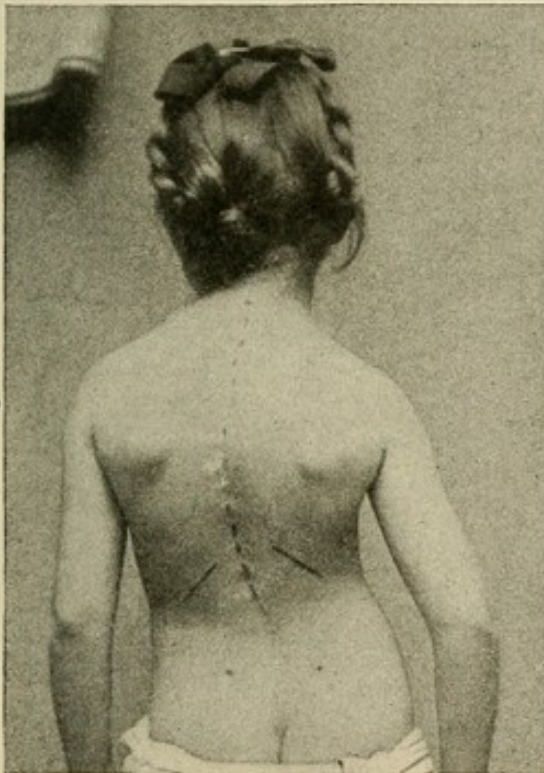


FIG. 77.—PATIENT WITH LEFT DORSAL CURVE IN 1900.

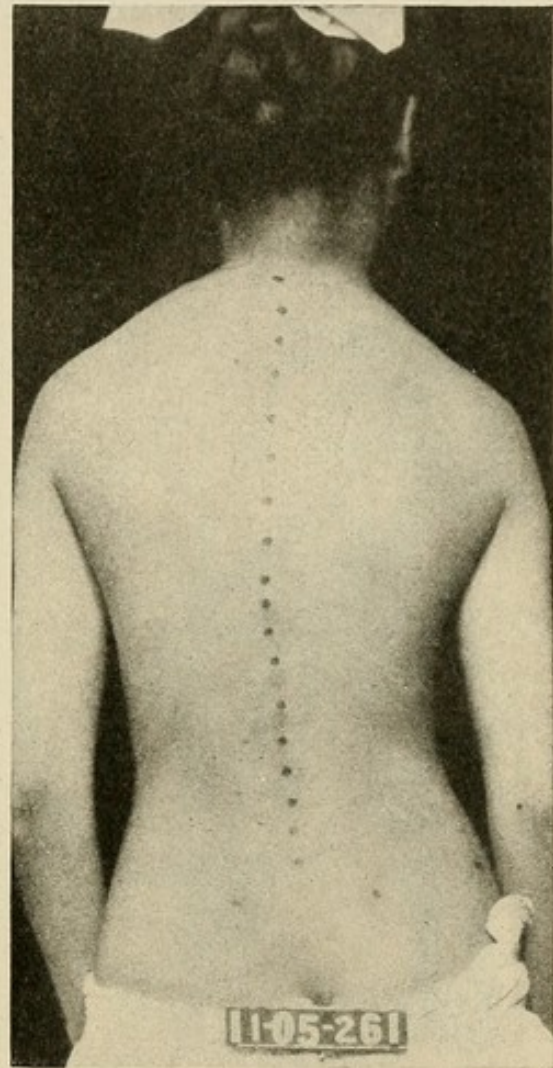


FIG. 78.—SAME PATIENT IN 1905 AFTER FIVE YEARS OF GYMNASTIC TREATMENT.

by competent surgeons who do not believe in corsets or supports.<sup>1</sup> The former class serves only to bring the legitimate use of gymnastics for scoliosis into disrepute; the latter class use the gymnastics understandingly, and, on the whole, take a pessimistic view of the results to be obtained in severe scoliosis. Moreover, it is a mistake

<sup>1</sup> Teschner: "N. Y. Med. Rec.," Dec. 6, 1903; Erich: "N. Y. Med. Jour.," Oct. 7, 1899.



to make a spine more flexible unless one is prepared to hold the spine in the improved position by a corset or brace or by muscular development, because if flexibility is increased, the spine will sink further into the bad position by virtue of its increased mobility unless some means is provided to prevent this. In mild structural scoliosis efficient gymnastics may constitute the sole treatment, and may be continued as the sole treatment so long as the improvement from one

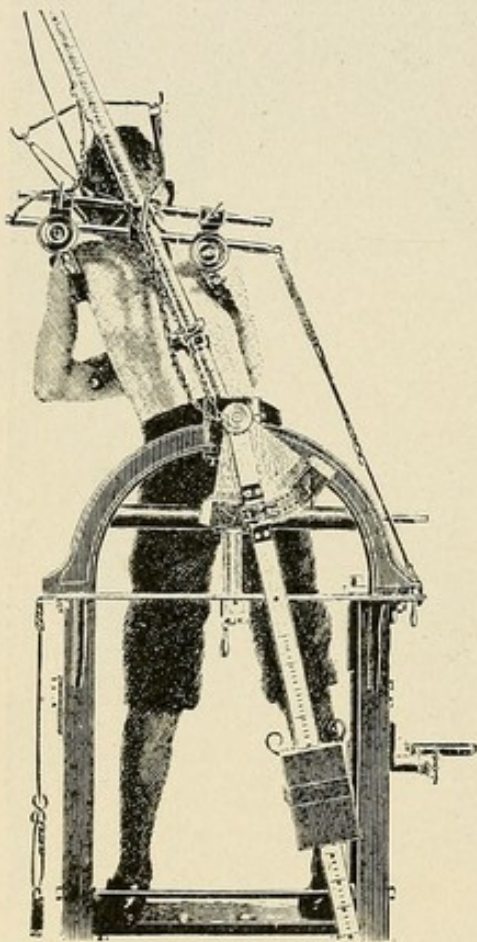


FIG. 79.—TRUNK BENDING APPARATUS.—(*Schulthess.*)

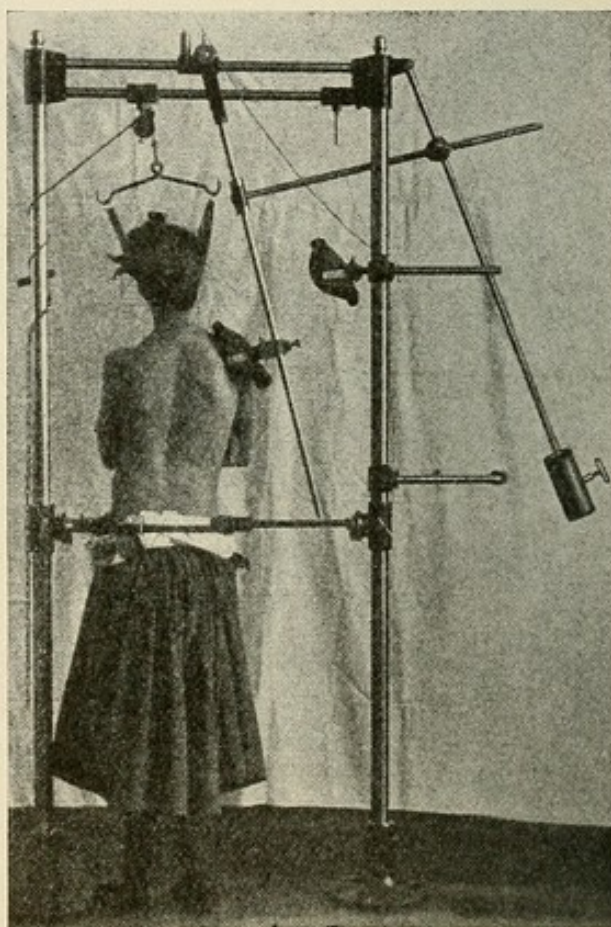


FIG. 80.—SHOULDER PUSHING APPARATUS.—(*Schulthess.*)

exercise period persists until the next one. If such improvement is not held between exercises it must be assumed—(1) that the exercises are not good ones; (2) that they are not properly carried out; (3) that the amount of treatment is insufficient, or (4) that the case is too severe for purely gymnastic treatment. Progressive improvement must be assumed as the criterion of efficient gymnastic treatment, and it must be recognized that, on the whole, gymnastic treatment by itself is



*not* satisfactory in scoliosis characterized by any marked degree of bony deformity.

The treatment by gymnastics alone may be supplemented (*a*) by the use of jackets, braces, or corsets, or (*b*) by the use of intermittent passive stretching, or (*c*) by both. If the case is too severe for gymnastics, (*d*) forcible correction followed by gymnastics and corsets is the proper treatment. The use (*e*) of braces and corsets alone is not

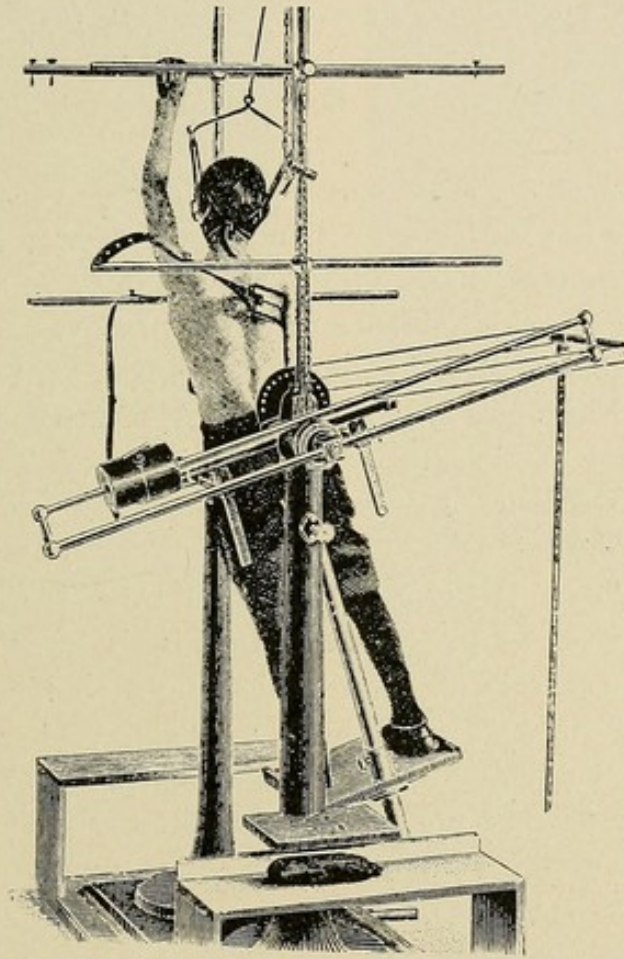


FIG. 81.—HIP-PENDULUM AND SHOULDER-RAISING APPARATUS.—(Schulthess.)

to be considered a treatment for lateral curvature. Gymnastic treatment may be given with or without apparatus.

**Gymnastics Given in Apparatus.**—By means of apparatus gymnastic exercises can be very much more correctly localized, and the work of loosening the spine and of strengthening the desired muscles can go hand in hand. This method, which is in general use in Europe, has never found a foothold in this country on account of the complicated and expensive apparatus.

The system of apparatus devised by Schulthess and its modifica-



tions and the apparatus of Zander are the best examples of the kind. The aim of this method of treatment, as stated by Schulthess, is "to correct, and in the corrected position to allow exercises to be done, or through the movements carried out in the apparatus to shape over the body from the pathological to the corrected form." The various forms of apparatus are as follows: (1) For side bending with the pelvis fixed; (2) for side bending with the shoulders and pelvis fixed; (3) for forward and backward bending; (4) for trunk rotation; (5) for active transverse pushing of the shoulder-girdle; (6) for active raising of the shoulder; (7) for active movement of the thorax with shoulders and pelvis fixed. In some of these the pendulum principle is used.

The precision of the apparatus, its adaptation to anatomical needs, and the principle of securing correction and the development of desired muscles at the same time make the system sound and efficient. It is described in detail in the reference,<sup>1</sup> and is not dwelt on here as it is a treatment not often available in America (Figs. 79, 80, 81).

**Gymnastic Exercises Given without Apparatus.**—This method of treatment is the one in most general use in America. It is open to the objection that the force exerted is not sufficiently localized, but is distributed over the spine.

*Fixation of Pelvis.*—It is essential that the pelvis should be fixed during such exercises, as otherwise the pelvis is displaced and the movement becomes a general and not a local one. A simple wooden apparatus may be constructed which holds the pelvis and does away with the necessity of holding the hips of the patient between the knees, which must otherwise be done. This saves labor on the part of the person giving the exercises, and permits a closer supervision of the back than is possible when part of the attention must be fixed on holding the patient firmly.

The apparatus, which was suggested by that of Bade,<sup>2</sup> consists of a wooden clamp made by two flat boards set at right angles to a horizontal board on which they slide to hold the sides of a pelvis of any width. The whole apparatus moves up and down on an upright fastened to a large round floor platform and may be inclined at any angle to the horizontal plane. The patient is secured in place by sliding in and fastening the lateral clamps at the sides of the pelvis, and by securing the front of the pelvis by a broad leather strap passing from one arm

<sup>1</sup> Schulthess: Joachimsthal's "Hdbch. der orth. Chir.," Lief v, page 1104.

<sup>2</sup> "Zeitsch. f. orth. Chir.," xii, 4, 799.



to the other. The floor platform is so large that the apparatus cannot upset (Fig. 84).

*General Routine and Precautions.*—It is desirable that the back should be exposed during the exercises in order to note the effect of each one. For this purpose the patient should wear during exercises a loose cotton

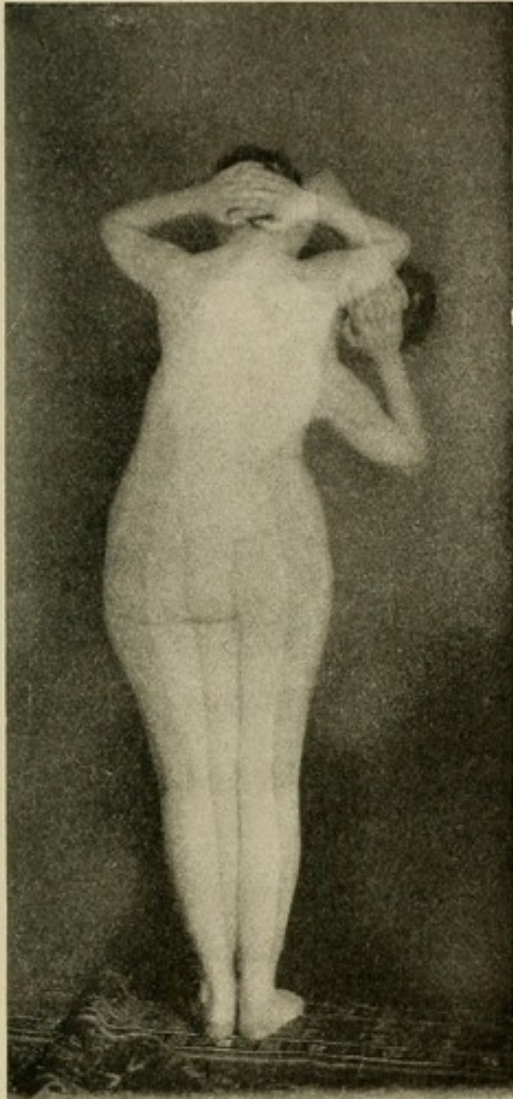


FIG. 82.—COMPOSITE PHOTOGRAPH (TWO EXPOSURES ON THE SAME PLATE) SHOWING THE MODEL STANDING ERECT AND BENDING TO THE RIGHT WITHOUT FIXATION OF THE PELVIS. THE MOVEMENT IS A GENERAL ONE.

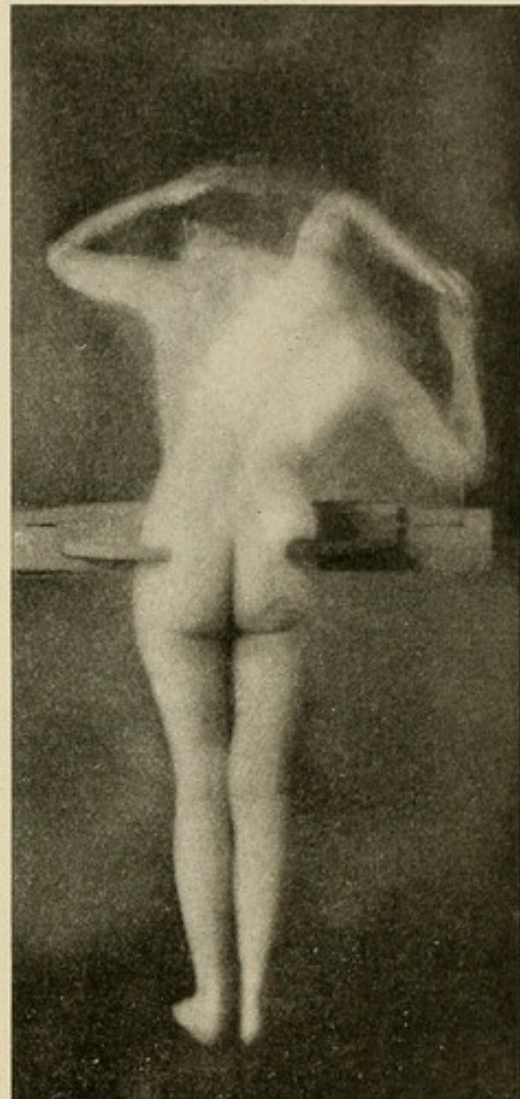


FIG. 83.—COMPOSITE PHOTOGRAPH OF THE MODEL STANDING ERECT AND BENDING TO THE RIGHT WITH THE PELVIS FIXED. THE MOVEMENT IS LIMITED TO THE SPINE.

dressings jacket, fastened around the neck and opening in the back. This protects the front of the body but permits inspection of the spine.

Such exercises should be simple and corrective in the strict sense; that is to say, an exercise which is of use should be seen to straighten the spine visibly. Complicated exercises are dangerous and unsur-



gical. Work to obtain results must be given by a competent gymnast for a period of from one to three hours a day, according to the vigor of the patient, and must be continued under personal supervision for a period of some weeks or months to obtain satisfactory results. After this exercises at home can be substituted for part of the personal work.

As a preliminary of gymnastic work the heart of the patient should have been, of course, examined, and the weight should be taken each week. Persistent loss of weight is an indication for moderating or




FIG. 84.—APPARATUS FOR FIXING THE PELVIS DURING GYMNASTIC EXERCISES.

discontinuing temporarily the exercises, providing that the patient is not being overworked at school, in which case the school conditions should first be remedied. During menstruation gymnastic exercises should be suspended. Persistent fatigue, anemia, loss of appetite, nervousness, and frequent or profuse menstruation should cause a careful investigation of the patient's environment, as they may arise from excess of gymnastic work.

The following list of gymnastic exercises, selected from a large number, may be regarded as representative of the kind of gymnastics likely to be of use *within the limits mentioned above*. They will first



be described individually and then analyzed, and their application to different conditions will be indicated.

The selection of exercises must depend on the requirements of each case, and so far as possible the especial value of each exercise has been indicated. Simple developmental exercises have not been included here, as a description of them can be found in books on gymnastics.

In the explanations to be given in connection with each exercise the general mechanical features will be discussed, but it must be remembered that conditions observed in the normal do not necessarily hold true in the deformed spine of scoliosis, although they form the best basis for analysis. The more nearly a spine approaches the normal, the more likely is such analysis to be correct.

## SYMMETRICAL EXERCISES.

### EXERCISES IN THE STANDING POSITION.

In all exercises given in this position *the pelvis should be fixed* unless otherwise stated. It must be remembered that exercises in this position call into play in varying relations all muscles concerned in maintaining the upright position, and therefore cannot be as highly specialized as can exercises given in the lying position. It must also be remembered that the superincumbent weight rests on the laterally curved spine, and that the curves are therefore not in as favorable a condition in such exercises as in the lying position. On the other hand, they are useful because any improvement of scoliosis must be interpreted as meaning improvement in the upright position, and all muscles concerned in that are therefore of importance.

**Fundamental Standing Position.**—The patient stands with the knees extended, the hands on the hips, the back straight, the head erect, and the scapulæ brought close to each other. The patient should not exaggerate the lumbar curve, and should press down with both hands on the hips.

**I. Shoulder Raising and Sinking.**—(1) From the fundamental standing position the patient stretches the whole spine upward. The surgeon holds his hand slightly above the patient's head and urges her to stretch until she can touch his hand with her head, keeping both heels on the ground. The position of the hand is made higher as necessary. (2) From the upward stretched position the patient relaxes to the fundamental standing position. In count (1) the patient breathes in and in count (2) breathes out (Fig. 85).

This is a general exercise calling upon the muscles which maintain the proper erect position, notably the spinal extensors. The elevation of the shoulders elevates and fixes the shoulder-girdle, giving a fixed point for the pull of the inspiratory muscles, thus tending to increase chest capacity, and a general stretching of the spine is also made easier by the fixed shoulder-girdle. The exercise is applicable to any case of scoliosis, especially to postural curves, as a general mobilizing and corrective one.

**II. Trunk Bending Forward with Shoulders Raised.**—(1) The shoulders are raised as in Exercise I (1). (2) The patient bends her trunk forward to the hor-



horizontal position, the spine being held straight and the shoulders raised, movement occurring only in the hip-joints. (3) The patient raises the trunk to the upright position with the shoulders still raised and the spine straight. (4) The patient relaxes to the fundamental standing position (Fig. 86).

This combines the essentials of Exercise I with the weight of the trunk thrown on the extensor muscles of the back and on the glutei, which must be held con-

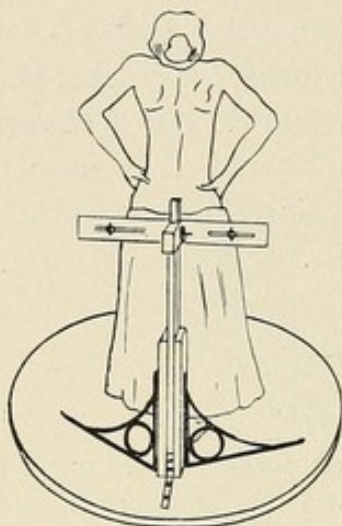


FIG. 85.

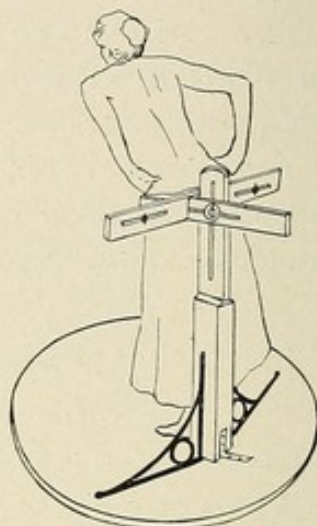


FIG. 86.

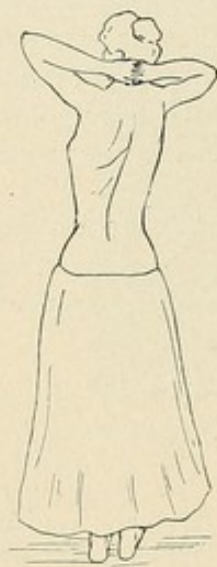

FIG. 87.

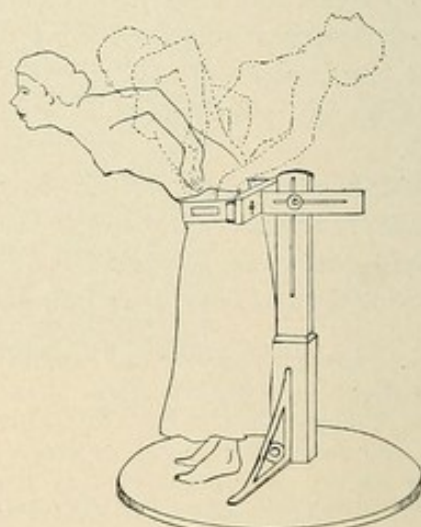


FIG. 88.

tracted to maintain the forward bent position and which must contract to bring the trunk again into the upright position. It has the corrective effect of Exercise I, in addition to which it is a fairly strong extensor spinal exercise with the lumbar curve flattened. It is a general mobilizing and corrective exercise which may be safely used in cases with a tendency to exaggeration of the lumbar curve. The patient inspires in (1), holds the breath during (2) and (3), and breathes out in count (4).

The above exercises may be modified and made slightly harder by having



the patient place both hands behind the neck with the elbows square back as far as possible. This raises the center of gravity of the trunk and therefore increases the leverage against the muscles.

III. *Trunk Twisting*.—Position: Without pelvic fixation, the feet parallel and touching, the hands on the hips, the head and spine erect. (1) From this position the patient twists her whole body as far as possible to the right or left, the head being turned as far as possible in the same direction. (2) The original standing position is resumed (Fig. 87).

Trunk rotation to the right causes a left dorsal curve and vice versa; in addition to this the exercise is intended to be mobilizing to the whole body, especially the hip-joints, and greater trunk excursion is possible with the feet parallel than with the legs rotated outward. The exercise is suitable for general spinal mobilization, and when given only to one side is a mild corrective exercise for lateral deviation; in the latter case the pelvis should be fixed to localize the movement in the spine.

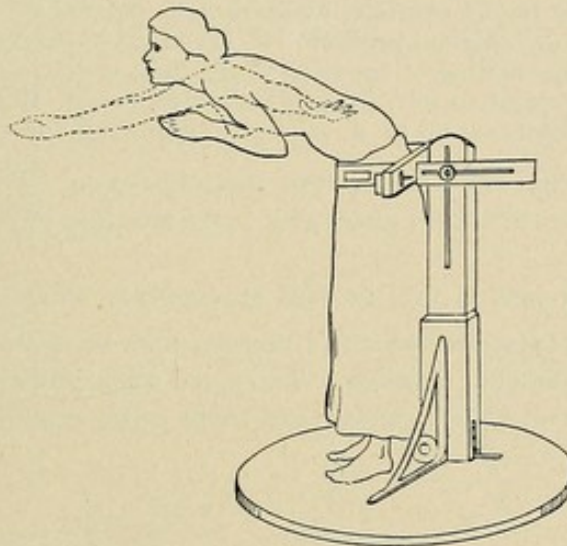


FIG. 89.

The effect of rotation upon the spine, especially in causing a lateral curve, may be located higher in the spine by giving the rotation in the forward bent position, and located lower by giving it in the hyperextended position. These two variations should be done with the pelvis fixed.

IV. *Trunk Circling*.—Position: Hands on the hips, the trunk flexed to the horizontal, the spine straight. From this position the patient describes a circle with the trunk about a vertical axis passing between the feet. The horizontal plane of the circle described is quite irregular, and the movement is divided into four counts: (1) From the position of forward bending the trunk passes to the right or left through side bending with flexion and rotation to extreme side bending. (2) From extreme side bending the circle is continued backward through side bending with its accompanying rotation to extreme hyperextension of the median plane. (3) The reverse of count (2). (4) The forward bent position is assumed. The face is directed forward during the entire exercise (Fig. 88).

This is a general mobilizing and strengthening exercise. When a marked lumbar curve is present, the exercise is preferably made unilateral to the side that improves rather than increases the lumbar curve, *e. g.*, in a left lumbar curve



half circling to the left is preferable to the complete circle so far as any corrective aspect is concerned.

*V. Swimming.*—Position: The patient bends forward until the trunk is horizontal, the arms are held at the sides, the elbows flexed, and the hands together against the chest. (1) The arms are extended upward beside the head. (2) The arms describe a half circle outward and are brought to the sides of the body. (3) The arms return to position (Fig. 89).

In this exercise the pelvis is flexed on the hip-joints and the weight of the trunk is thrown forward. The extensor muscles of the spine and the glutei are called upon to maintain the position during the movements of the arms. All the muscles of the shoulder-girdle, especially those concerned in drawing the scapulæ together, take part in the movement. This is a general strengthening exercise, especially addressed to spinal extensors, and is also valuable in cases of flexible round shoulders.

*VI. Head Movements from the Fundamental Standing Position.*—The head and cervical spine, as far as possible, alone should participate in these exercises. *A.* (1) Head flexion, (2) original position. *B.* (1) Head hyperextension, (2) original position. *C.* (1) Side bending of the head to the right or left, (2) original position. *D.* (1) Head twisting, right or left, (2) original position. *E.* Head circling with the face to the front, a combination of *A*, *B*, and *C* following one another.

General mobilizing exercises for the cervical region. For corrective effect in a cervical curve they should be given only to the side that improves the curve.

#### EXERCISES GIVEN IN THE HORIZONTAL POSITION.

In this group of exercises one set of muscles may be more readily picked out for exercise than in the erect position. The spine when prone is less curved than in the upright position, and is slacker and more easily capable of side displace-

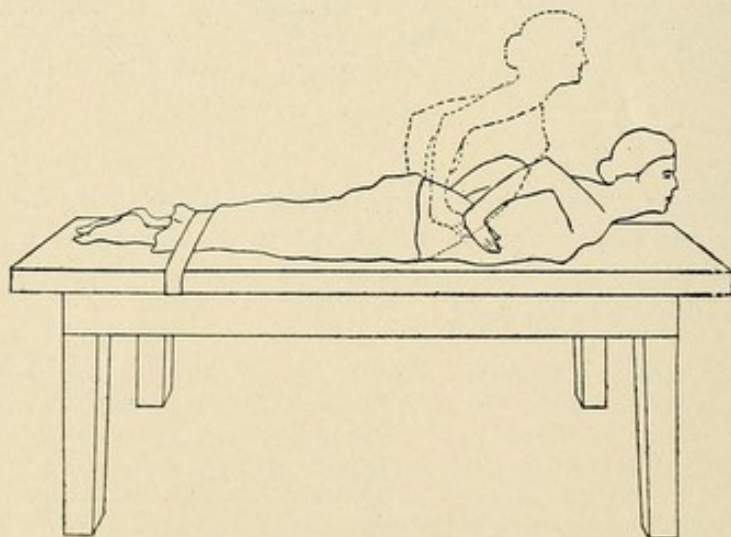


FIG. 90.

ment. The fact that symmetrical hyperextensions are so much used for their corrective effect is explained by their empirical value and by anatomical reasons (page 35).

*Lying on the Face.*—*VII. Trunk Raising.*—Position: The patient lies face downward on a table with the spine straight, the hands on the hips, the scap-



ulæ approximated to each other, the toes brought over the end of the table, and the legs secured to the table by a strap passing around the table and legs just above the ankles, or the legs may be held by the hands of an assistant. (1) The patient inspires and raises the trunk from the table, hyperextending the spine as far as possible, keeping the head back and the face up, with the elbows still held well back. (2) The patient breathes out and sinks to the original position (Fig. 90).

This is an extension of the spine from its normal position to extreme hyperextension in which the spinal motion occurs largely below the tenth dorsal

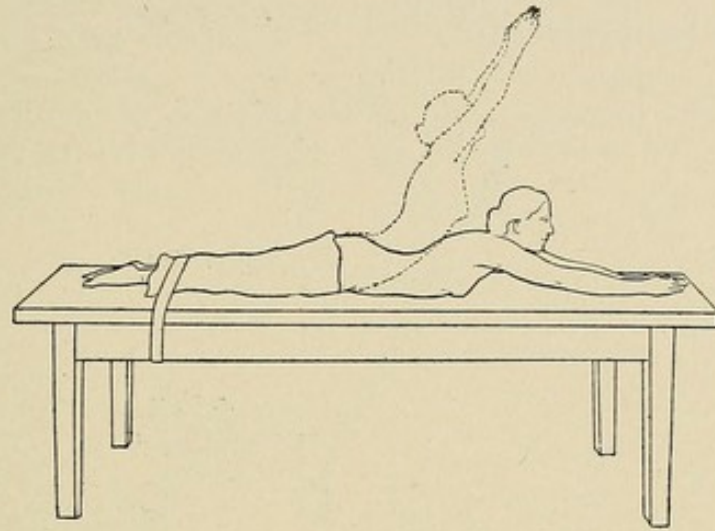


FIG. 91.

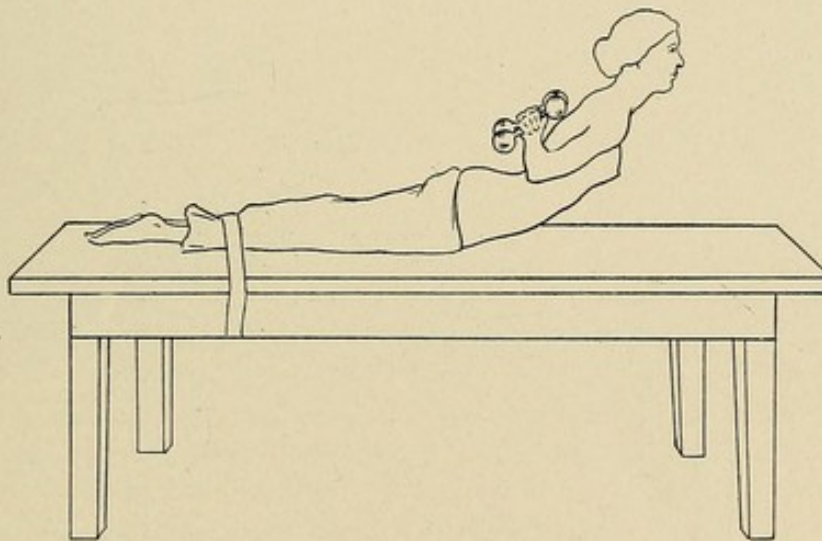


FIG. 92.

vertebra, where hyperextension anatomically takes place. The weight of the trunk is raised by action of the back extensor muscles, which are very generally called into play. It is a general strengthening exercise for these muscles, but in cases with marked increase of the lumbar curve it must not be used to increase this, in such cases Exercise II being available. The latter is probably a weaker exercise, because in it the extensor muscles do not contract to their fullest extent. The exercise may be made harder by placing the hands behind the neck and squaring the elbows back or by extending the arms beside the head, which raises the center of gravity (Fig. 91).



The above may be modified in the following manner: The patient clasps his hands behind his back above the level of the waist-line, with elbows flexed and hand closed against the back, and, as he hyperextends his trunk, stretches his arms backward forcibly, extending the elbows, and keeping the hands clasped. By this modification the scapulæ and shoulder-joints are carried back and the hyperextension done with an improved position of the shoulders. This is particularly suited to round shoulders.

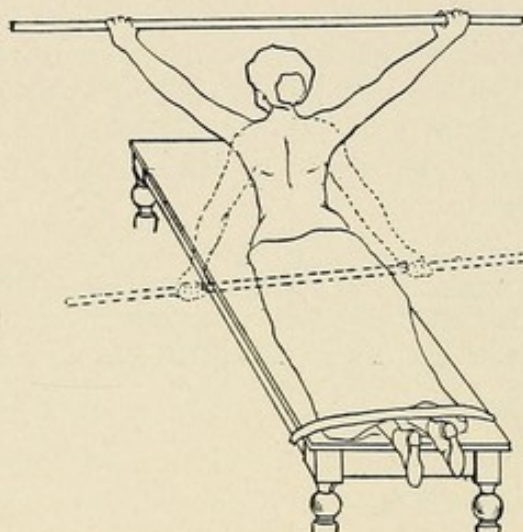


FIG. 93.

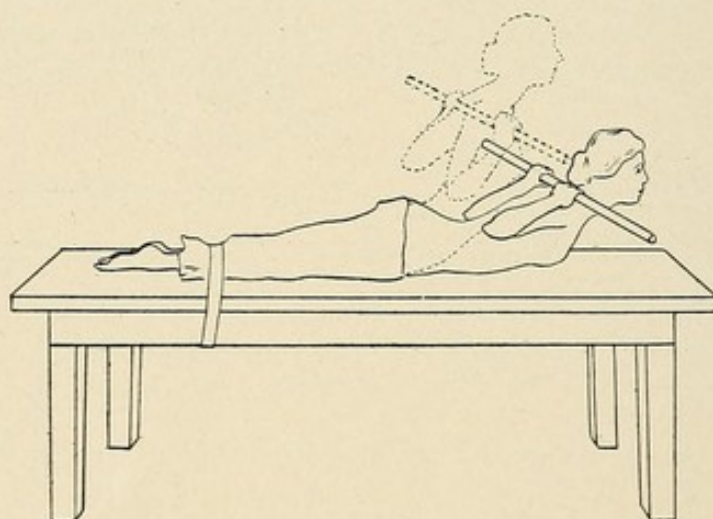


FIG. 94.

VIII. *Trunk Raising with Dumb-bells and Staff.*—These are merely varieties of Exercise VII, in which the position of the shoulders is modified by means of dumb-bells or wands held in the hands, or in which the center of gravity is changed by the dumb-bells, making the exercise harder. (a) The patient grasping dumb-bells, places them together against the back and as high up as possible. (b) The patient grasping the dumb-bells with the arms extended above the head, circumducts the arms during the two counts of the exercise. (c) A staff is grasped in both hands by the patient, who lies with arms extended above the head, hands palms down and rather widely separated. This position of the arms is maintained during the exercise. (d) This exercise differs from the last (c) in that the



staff is brought over the head and down behind the scapulæ during "raising," and the original position resumed during "sinking" (Figs. 92-94).

These exercises increase the muscular effort elicited by Exercise VII by changing the center of gravity; most of them call into action the muscles which approximate the scapulæ and tend to stretch contractions holding them in a forward position. Probably in some an element of forced hyperextension of the dorsal spine is present. They find their use, consequently, in addition to scoliosis, in cases of both flexible and resistant round shoulders. The individual application must be decided by the special characteristics of the case.

**Exercises Lying on the Face, the Trunk Projecting over the End of the Table.**—The legs rest on the table, the surgeon making the ankles secure by means of a strap or by holding them. The body above the hip-joints hangs over the table end, head downward. The hands are placed behind the neck with the elbows squared back.

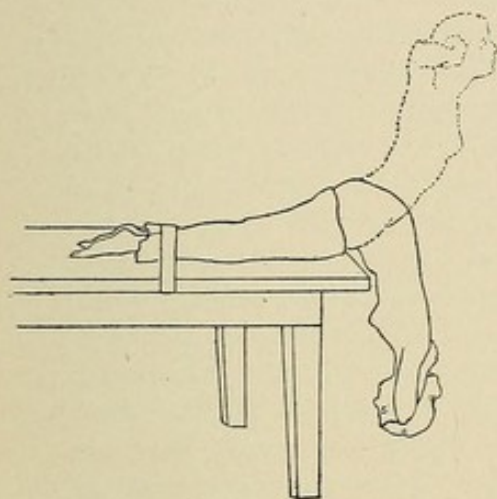


FIG. 95.

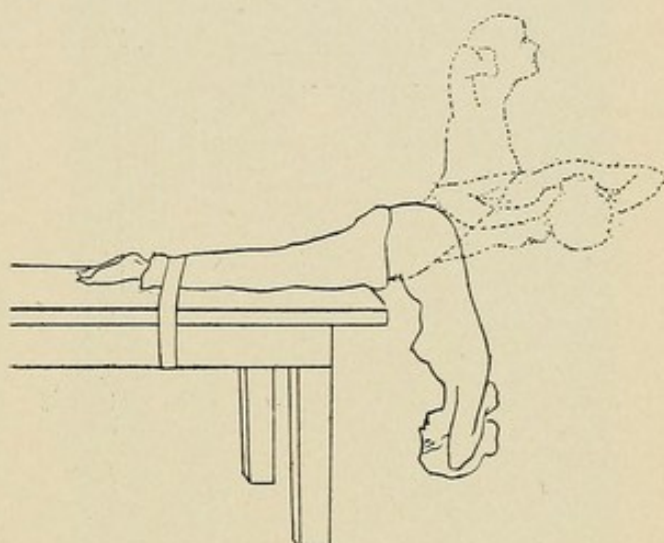


FIG. 96.

**IX. Trunk Raising from Head Downward Position.**—(1) The patient inspires, and raises the trunk as far as possible by hyperextending the hip-joints and the spine. (2) During expiration she sinks to the primary position. The spine should be kept in the mid-plane and the head not allowed to flex (Fig. 95).

This is a spinal extension movement mostly without superincumbent weight, beginning at forward flexion and ending in marked hyperextension, calling the extensor muscles into activity from a stretched to a completely contracted condition. It thus combines the range of motion in Exercise II with that of Exercise VII. It is a heavier exercise than either. From the start of the exercise till the horizontal position is reached the spinal extensors and glutei are the muscles chiefly active, as the maintenance of balance does not require the contraction of other trunk muscles. The exercise may be made easier by placing the hands on the hips. It is of use as a general strengthening exercise for the back muscles in any case where the patient is strong enough to take it.

**X. Trunk Circling.**—The position is the same as in Exercise IX. The exercise is done in four counts, as described under Exercise IV (Fig. 96).

This is a heavier exercise than IV because the weight of the trunk is a factor



entering into each component of the movement. For corrective effect it should be given only to the side that improves the lateral curve.

XI. *Swimming*.—This exercise is done in the same way as Exercise V, except that the patient first raises his trunk as high as possible, and holds the position while he goes through the movements of swimming (Fig. 97).

It differs from Exercise V because the spine is held in a position of hyperextension, and is not flexed on the pelvis. It thus exercises chiefly the spinal extensors

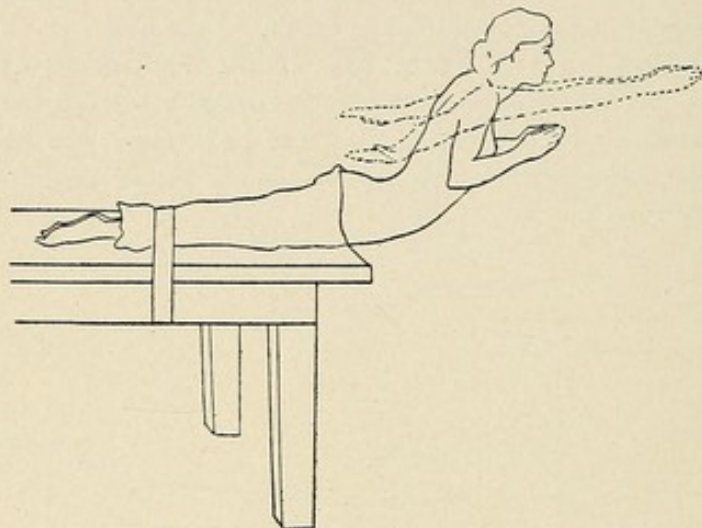


FIG. 97.

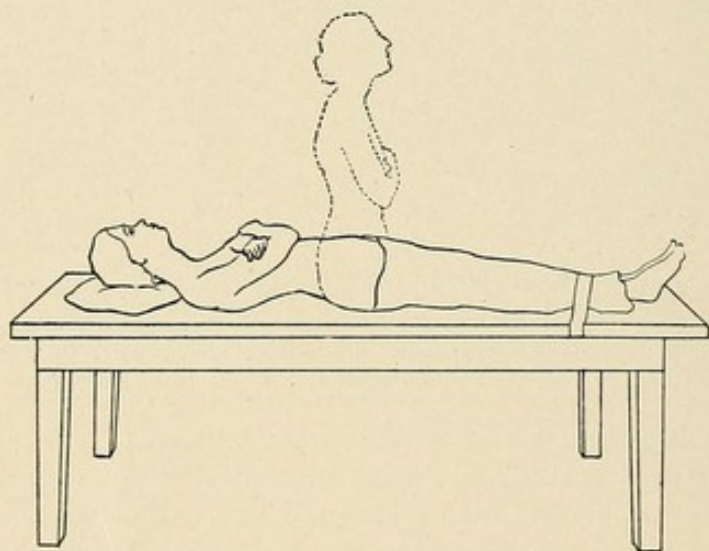


FIG. 98.

in a position necessitating their maximum contraction. It is not suitable to cases with increased lumbar curve.

**Exercises Lying on the Back.**—The patient lies on a table or on the floor with the head, trunk, and legs straight, and the feet secured either by a strap or by being held. The arms are folded on the chest.

XII. *Trunk Raising to Sitting Position*.—(1) The patient rises slowly to the sitting position with the spine stiff and not allowed to flex. (2) The patient sinks to the primary position with the spine still stiff, the head touching the table before the back (Fig. 98).



The exercise is made easier by placing the hands on the hips, and harder by placing the hands behind the neck with the elbows squared back. The upright position is brought about by the contraction of the abdominal muscles, which aid in maintaining the upright position, and require exercise in cases of prominent abdomen and of increase of the lumbar physiological curve accompanying scoliosis and round shoulders.

#### EXERCISES IN THE SUSPENDED POSITION.

The patient stands erect, and the head is pulled vertically upward by means of a Sayre head-sling, which embraces the chin and occiput. Traction should be made by a compound pulley, and the patient or the surgeon may hold the rope. Suspension is mildest—(1) when the feet are not made to leave the floor; next in grade comes (2) the position of tiptoe induced by the traction, and (3) a greater pull is secured by lifting the whole body until the feet swing free. In this case the traction force equals the body-weight. The maximum traction can be secured (4) by strapping the thighs down to a seat on which the patient sits. An upward pull greater than the body-weight can now be exerted on the head (Fig. 99).

Head suspension is a passive stretching of the spine, corrective through its entire length, tending to improve both rotation and side deviation at the curves, but exercising still more force upon the more nearly normal parts of the spine because the latter are more movable. Suspension by the arms is less efficient, and does not affect the cervical vertebrae as does head suspension. Hanging is a generally useful and purely mobilizing procedure suitable to any case, slight or severe.

If it is desired to make hanging exercises more locally corrective in the dorsal region, the patient should hang by the hands from a bar, the hand on the convex side of the lateral curve grasping a loop on the bar which is at least two inches below it. By this means the concave side will be subjected to a greater stretching.

XIII. *Hanging—Body Circling.*—In the original position the patient is not suspended by the head-sling, but the sling is lax and the feet touch the floor. The patient then swings forward until restrained by the suspension apparatus, and

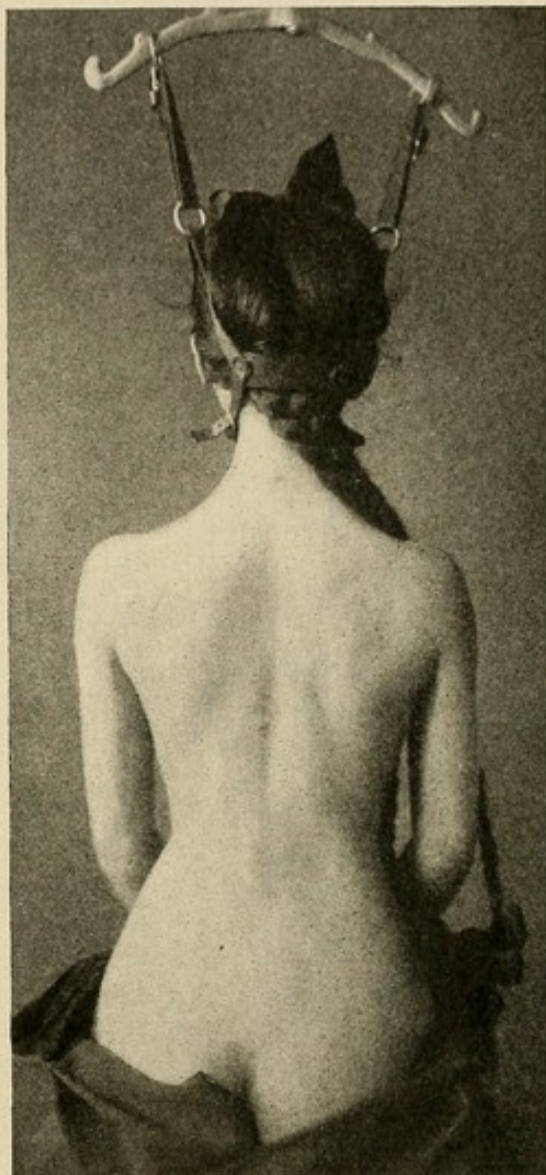


FIG. 99.—HEAD TRACTION.



then circles to the right, backward and forward, and to the left, gaining a momentum with which to continue the circling. After the patient has circled to the right the desired number of times she reverses the direction and circles a desired number of times to the left. In this exercise the body is swung about the feet as a pivot. The feet are kept in one place on the floor, the trunk describing a circle which involves the entire range of side bending and forward and backward motion.

This is a general mobilizing exercise for the entire spine, and may be modified by being given only to the side that improves the lateral curve to increase its corrective effect.

XIV. *Hanging—Pelvic Rotation.*—The patient hangs by both hands from a bar and rotates the pelvis and legs rapidly and forcibly first to the right and then to the left, alternating the two rotations in succession.

The exercise is intended to mobilize the lower dorsal and upper lumbar region.

#### MISCELLANEOUS SYMMETRICAL EXERCISES.

XV. *Heavy Weight Raising*<sup>1</sup> (Teschner).—The patient stands facing a table, which touches the front of the thighs or pelvis, against which she rests. She then raises slowly a heavy bar, weighing from 10 to 30 or more pounds, over the head as high as the arms will reach, keeping the eyes fixed on the middle of the bar and keeping the bar horizontal. It is then lowered slowly, but should be held or rested at the level of the shoulders and not allowed to drag on the arms. The exercise is repeated as often as may be. The patient should use as heavy a bar as can be put up steadily and which produces a corrective effect on the curve when the point of upward stretch is reached. The weight should be steadily increased as the muscular capacity of the patient increases (Fig. 100).

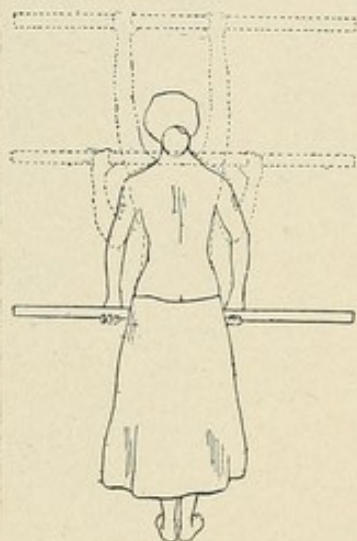


FIG. 100.

The exercise tends to develop all the muscles of the trunk, as its correct performance necessitates a contraction of the muscles maintaining the erect position. It is not particularly corrective to the curve, but fills out the flanks, improves the body-outline, and tends to strengthen the muscles maintaining a correct upright attitude, in this way tend-

ing to fix the improved position. It is a developmental exercise suited to any curve, of retentive rather than corrective value, and therefore best used as supplementary to other and more corrective work.

XVI. *Weight Carrying on the Head.*—A bag filled loosely with sand, weighing from 3 to 15 pounds, is placed on the top of the patient's head, and she walks slowly to and fro with the arms preferably clasped behind the neck and the elbows squared back. The exercise may be made more difficult by having the patient walk on tiptoe. The attitude assumed should be as erect as possible and the weight as heavy as can be carried steadily.

It is a matter of common information that the habitual carrying of baskets and loads upon the head induces an erect carriage and a straight spine. The presence of weight upon the head necessitates getting the spine as straight as

<sup>1</sup>Teschner: "Ann. of Surgery," Aug., 1895: "Orth. Trans.," vol. ix.



possible under the weight, as it is thus most economically carried, and this instinctive adjustment to superincumbent weight is depended on for its corrective effect. To carry a weight on the head with the spine not held in its best position by muscular effort would be undesirable. The exercise is suited to mild cases with noticeable bad carriage and poor balance.

**XVII. Mirror Self-corrective Exercise.**—The patient, bared to the hips, faces a mirror in front of which hangs a plumb-line. The patient then stands in such a position that the plumb-line cuts the middle of the pelvis, and by a muscular effort brings the middle of the thorax and the vertical line of the face as nearly as possible under the plumb-line, bringing thus three important landmarks into the median line of the body, thus securing an improved position. This is held for a few seconds and then the relaxed position resumed. The exercise is repeated several times, the improved position being held longer each time.

The exercise is a muscle training and is not in any way a mobilizing exercise, but enables the patient to associate a certain position with a certain muscular effort, and is of great value in enabling patients to identify by muscular sense the corrected position. The exercise requires but little effort and may be done at home without assistance. It may be modified in various ways by adding free-arm, staff, or dumb-bell exercises, which change the center of gravity, strengthen muscles approximating the scapulæ, and prolong the corrected attitude.

#### ASYMMETRICAL EXERCISES.

**XVIII. Hip Sinking (Hoffa).**—Position: From the fundamental standing position the patient advances the foot, on the side opposite to the convexity of the lateral curve, forward and outward about two foot-lengths. (1) The patient bends the forward knee, sinking the hip on that side. (2) The patient resumes the primary position (Fig. 101).

A passive side correction of the lumbar curve, due to a lowering of the pelvis on the side of the advanced leg when the knee is bent. Suitable for lumbar curves.

**XIX. Self-correction (Lorenz).**—The patient assumes the fundamental standing position and places the hand of the side to which the dorsal spine is convex upon the side of the thorax opposite to the greatest dorsal curve; the other hand is then placed on the ilium. (1) By a side thrust of the hand on the thorax the patient corrects or overcorrects the dorsal curve, maintaining the correction for a few seconds. (2) The patient relaxes to the primary position. The exercise may be modified by placing the hand on the side to which the dorsal spine is concave on the top of the head, as it thus tends to raise a low shoulder. The rest of the exercise is performed as described (Fig. 102).

A side thrust of the dorsal spine with pressure applied to the convexity of the dorsal curve against resistance furnished by the other hand on the ilium or the head. Suitable for dorsal scoliosis, but not powerful, and useful as a means of stretching; chiefly good because it can be done by the patient unaided at frequent intervals. Exercises XVIII and XIX may be combined for a double curve with one element dorsal and the other lumbar.

**XX. Hip Sinking from Stool.**—Position: The patient stands erect on a stool on one foot (the foot on the side of the convexity of the curve). (1) The patient lets the free leg sink as much as possible, thus lowering the pelvis and hip on that side. The knee of the supporting leg must be kept straight. (2) The patient resumes the original position (Fig. 103).



A passive side stretching of the lumbar curve suitable for lumbar scoliosis. The leg and pelvis drag down on the side of the concavity of the lateral curve, tending to stretch contracted structures and straighten the curve.

XXI. *Trunk Hyperextension with Side Bending—Lying on the Face.*—The patient lies face downward on a table or on the floor as described in Exercise VII. (1) The trunk is raised from the table as far as possible by hyperextending the spine. (2) From this position the trunk is bent to the side toward which the lumbar curve is convex. (3) Position 1 is resumed. (4) The prone lying position is resumed (Fig. 104).

This exercise is an active lateral flexion of the spine in the position of hyperextension. As hyperextension locks the dorsal region against side flexion, the movement is almost wholly confined to the lumbar region. If there is a right dorsal curve in connection with a left lumbar curve, bending to the left, while it corrects the lumbar curve, does not at the same time greatly increase the dorsal curve,

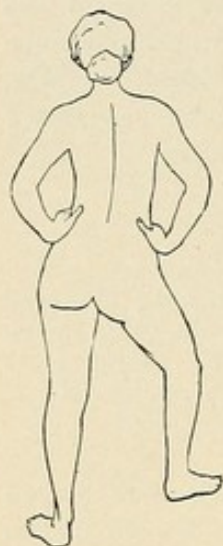

FIG. 101.

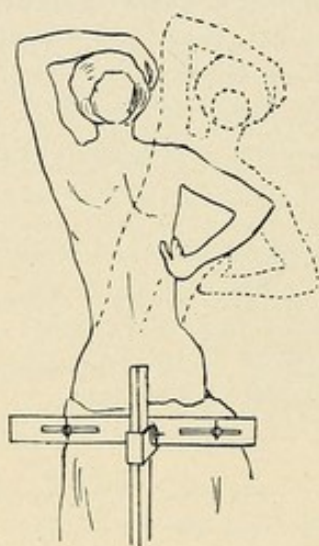


FIG. 102.

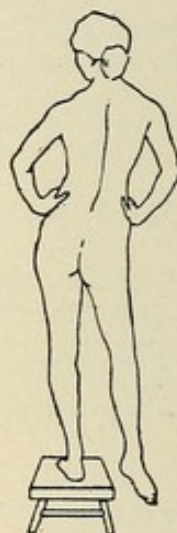

FIG. 103.

as that part of the spine is locked against side bending. The exercise is, therefore, suited not only to lumbar curves, but especially to compound curves in both dorsal and lumbar regions.

XXII. *Drawing up the Hip—Lying on the Face.*—Position: The patient lies prone on a table, holding the end with both hands, the arms extended and the spine and legs in a straight line. (1) The surgeon grasps the ankle on the side of the lumbar convexity and resists while the patient draws the hip up as far as she is able, the knee being kept straight. (2) Position 1 is resumed (Fig. 105).

The approximation of the side of the pelvis and the thorax on the side to which the lumbar curve is convex is brought about by an active contraction of the muscles on the convex side of the lumbar curve which it is desirable to develop. The amount of work thrown on these is determined by the amount of traction made on the ankle. The exercise is suited to cases of lumbar curves or to the lumbar element of compound dorsal and lumbar curves.

XXIII. *Side Flexion of the Trunk from the Side-lying Position.*—Position: The patient lies on a table with the concavity of the lateral curve downward and the trunk projecting over the edge of the table above the pelvis, the patient being



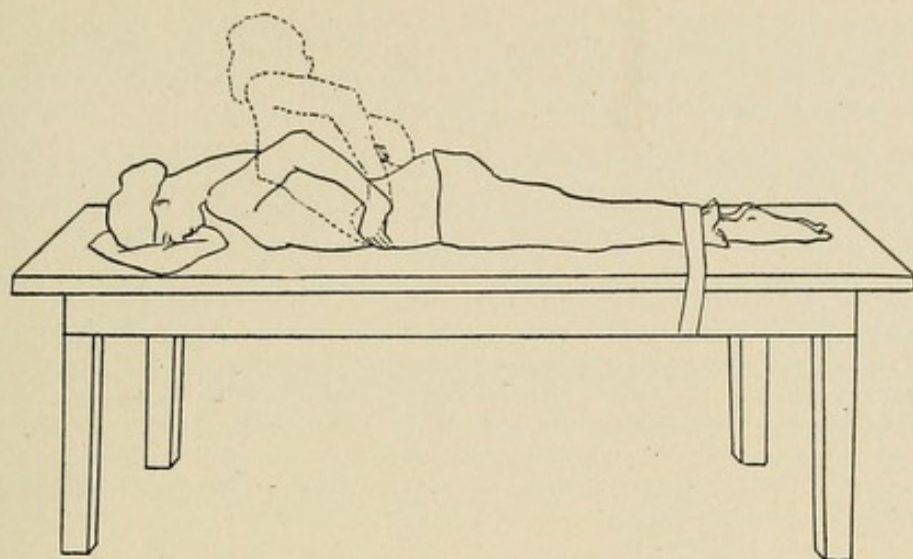


FIG. 104.

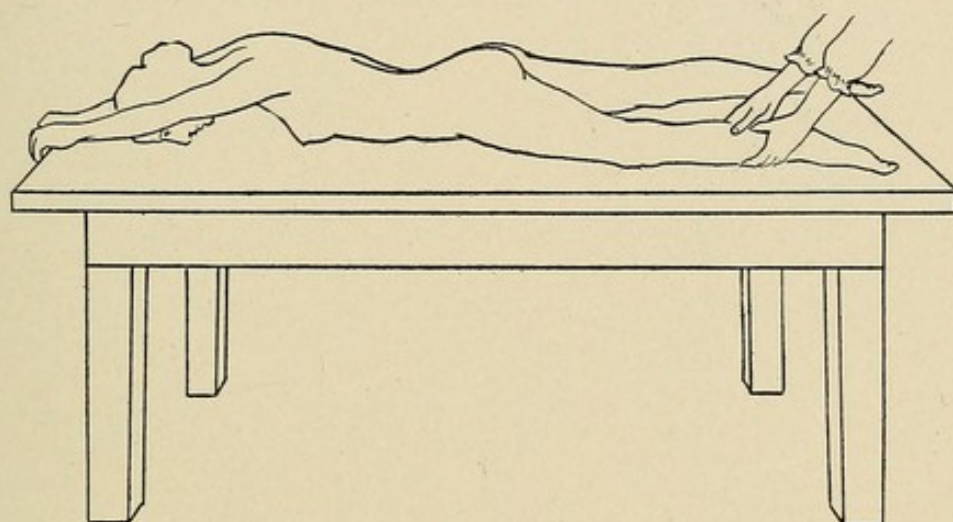


FIG. 105.

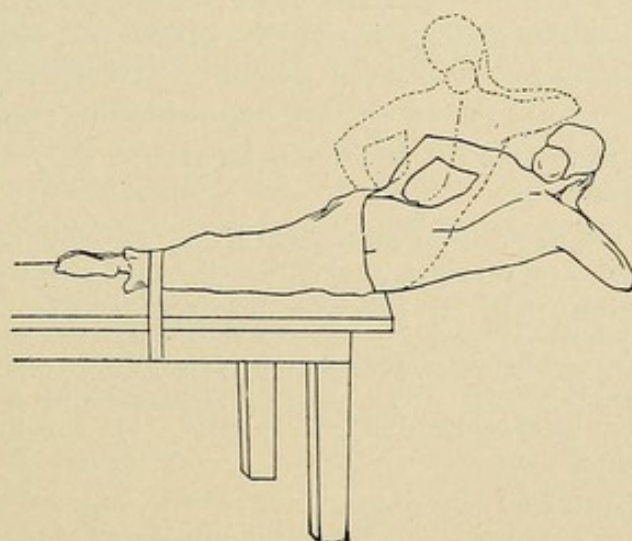


FIG. 106.



supported in this position, and the ankles secured by means of a strap. The spine is held in medium extension, the upper hand on the hip and the lower hand on the back of the neck. (1) The trunk is bent laterally and upward as far as possible. (2) The original supported position is resumed (Fig. 106).

In this exercise the weight of the trunk is thrown on the muscles of the convex side of the lateral curve. The raising of the trunk tends both to diminish a curve existing near the dorsolumbar junction and to exercise strongly the muscles which aid in its correction. It is suited to total, lower dorsal and dorsolumbar curves.

XXIV. *Self-correction with Arms Extended Behind Back (Mikulicz).*—The patient stands without pelvic fixation with the arms hanging behind the back, with extended elbows, and the hands clasped loosely with the palms together. (1) The patient bends forward, flexing the spine. (2) The patient then straightens the

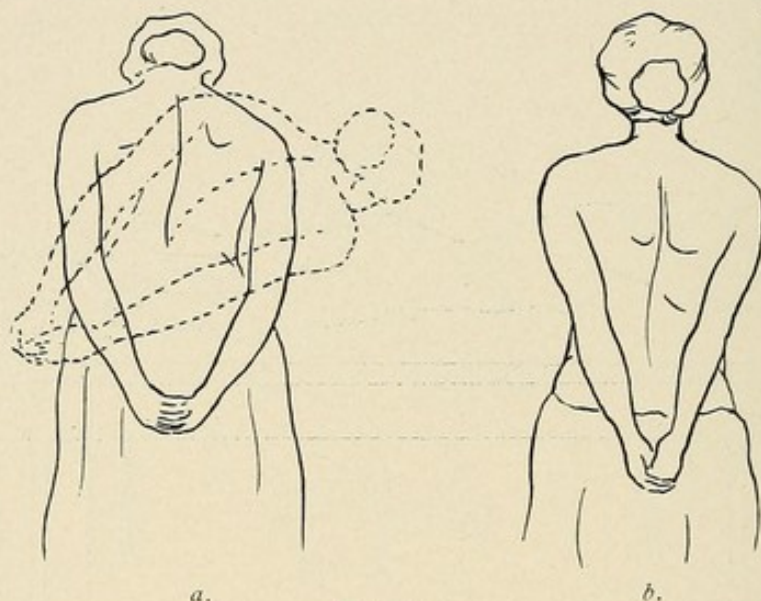


FIG. 107.

arms with force, getting the shoulders as far back as possible and stretching the hands down, and then describes a half circle to the right or left to the hyperextended median position. The bend is to the right in right curves and vice versa (Fig. 107).

The exercise is a side flexion made in the direction that improves the lateral curve, with the shoulders in a corrected position. The arm on the convex side presses against the rotated thorax and has some corrective effect. The exercise is particularly useful in dorsal scoliosis with increase of the dorsal physiological curve (kyphoscoliosis).

XXV. *Trunk Bending to Both Sides with Hand Pressure (Mikulicz).*—Position: In the case of a right dorsal left lumbar curve the patient places the right hand on the prominence of the ribs just under the shoulder-blade, and the left above the ilium on the lumbar curvature. (1) She then bends the body slowly to the right side, while the right hand and thumb press against the dorsal prominence. (2) The upright position is resumed. (3) The patient bends to the left and backward, pressing with the left hand against the lumbar curve. (4) The upright position is resumed (Fig. 108).

This is a combined mild active and passive correction for a double curve. Opposing forces are applied to the convexities of the curves, thus tending to straighten



the spine, which is at the same time bent by means of muscular action, first to the side of the convexity of the dorsal curve and then to the side of the convexity of the lumbar curve.

XXVI. *Passive Head Side Bending*.—Position: The patient stands with the hand on the side of the concavity of the lateral curve against the side of the head above the ear. (1) The head is pushed as far as possible to the side that corrects the curve. (2) The original position is resumed (Fig. 109).

A passive correction of the cervical lateral curve by a side bend of the upper part of the cervical region which tends to diminish the curve. Of use in cervical and cervicodorsal curves, either alone or existing in combination with others.

XXVII. *Trunk Raising with Asymmetrical Position of Staff*—from *Prone Lying Position*.—Position: The one described for exercises with the patient lying on the face (Exercise VIII) with a staff grasped in both hands, the arms being extended beside the head. (1) The trunk is raised from the table and the staff brought over

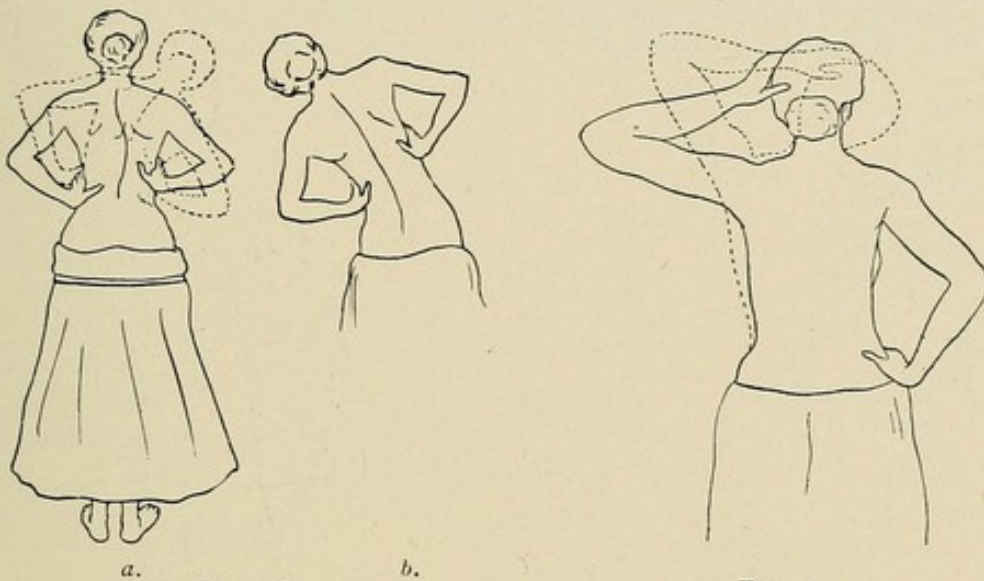


FIG. 108.

FIG. 109.

behind the head obliquely, the hand on the side of the convexity of the curve being carried down toward the feet and the other carried up over the head until the staff is brought as nearly as possible into the long axis of the body and pressed against the back. (2) By a reversal of the movement the original position is resumed (Fig. 110).

The scapula on one side is raised, and the position of the staff tends to correct an existing curve in the dorsal region. The exercise amounts to a spinal hyperextension in a corrected position of the dorsal spine. The exercise is suited to total curves, to simple dorsal curves, and to compound dorsal and lumbar curves.

XXVIII. *Partial Suspension by One Arm with Other Arm and Leg Locked*.—Position: The patient standing by a ladder or under a bar that can be reached without rising on the toes, grasps one rung of the ladder or the bar with the hand of the side to which the spine is concave. On the opposite side, the convex, the arm passes under the knee, the thigh being flexed at the hip, and the shoulder and pelvis are thus approximated. (1) The patient thus standing on one leg flexes that knee and allows the body-weight to come upon the arm. (2) The original position is resumed (Fig. 111).

When the arm is placed under the knee the pelvis and shoulder are approximated on that side and the spine made convex to the other side as far as it will go.



The structures on the concave side are thus put on the stretch and, by allowing the body-weight to come on the arm holding to the ladder, a further stretching force is exerted on the structures on the concave side. The exercise is suited to total and dorsal curves.

**Creeping Exercises (Klapp).**—In these exercises the patient supports the trunk in a horizontal position with the hands and knees or feet on the floor. The hands, knees, and toes should be protected by leather pads which are strapped on.

**XXIX. Symmetrical Creeping.**—The hand and knee of the right side are placed close together with the hand to the outer side of the knee, the head is twisted with the face to the right, and the trunk is rotated with the left shoulder upward. The left arm is extended beyond the head and the hand placed on the floor, palm down and fingers forward, as far forward as possible and directly in front of the right knee. The left knee is placed as far back and as near the median line as possible; the spine is strongly bent to the right. The creeping consists of forward locomotion by a series of reversals and regainings of the position described. The mechanism of the first reversal is as follows: the left knee is drawn forward to the inner side of the left hand in its original place and position, the right arm is extended above the head, and the hand placed as far in front of the left knee as possible with the palm down and

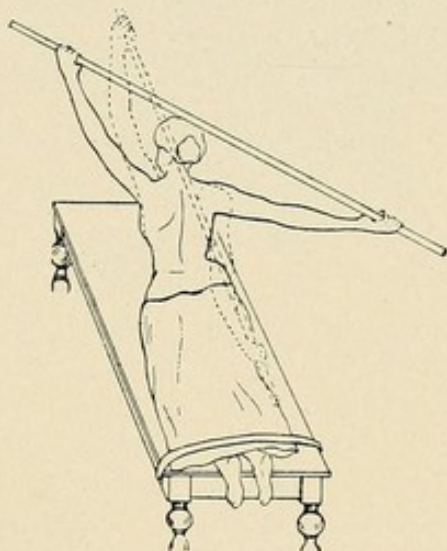


FIG. 110.

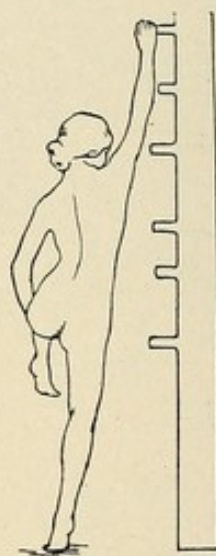


FIG. 111.

fingers front. At the same time the spine is rotated to bring the right shoulder high, the face is twisted to the left, and the spine flexed to the left. The restoration to the first position is secured by again moving the back knee (right) and the back hand (left) (Fig. 112).

This is a general muscle-strengthening and spine-mobilizing exercise. It is comparatively mild and may be continued for long periods of from twenty to forty minutes. It is said to be of value to lengthen shortened muscles and ligaments on the concave side. Symmetrical creeping is properly that which is done rapidly, and is of most value in restoration of flexibility.

A modification is made by creeping slowly, holding each position and putting force into the stretching, usually holding the position longest which stretches the concavity of the most marked curve (Fig. 113). Another modification is creeping in place, which differs from the above in that the patient does not attempt locomotion. The position is somewhat as above except that the fingers of both hands are placed on the floor, pointing opposite to the side to which the face looks. The trunk is rotated



till the side with the forward arm is uppermost, and the arm is carried directly over the head while the under arm is flexed at the elbow which points to the side toward which the face is turned; the posterior knee is straightened, and the foot only of that limb touches the floor. The patient then endeavors to look upward beneath

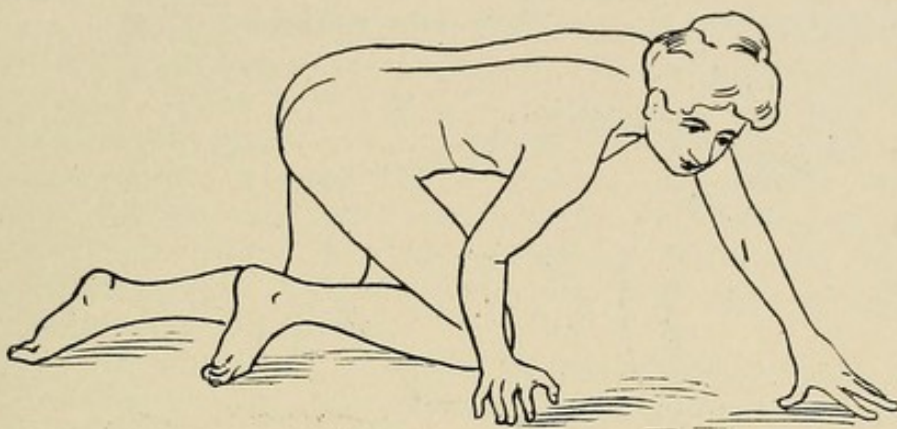


FIG. 112.

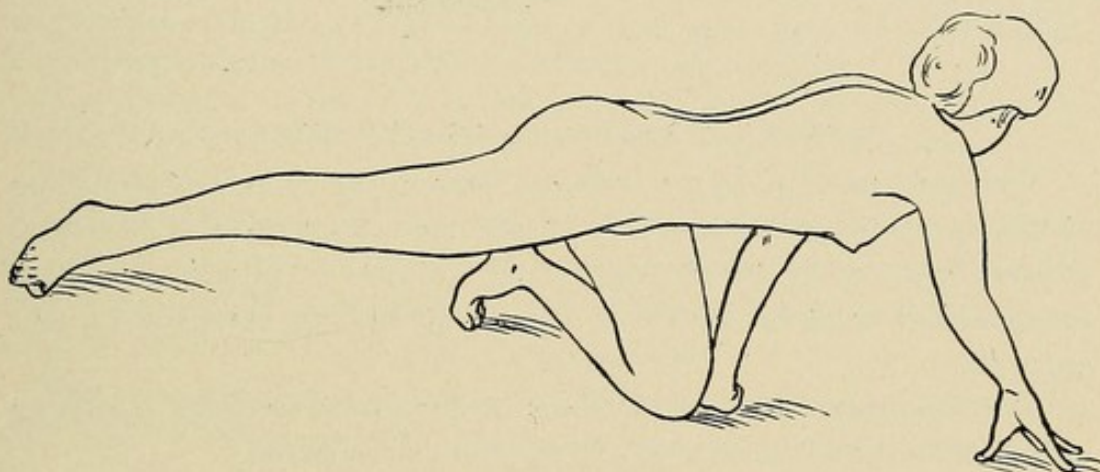


FIG. 113.

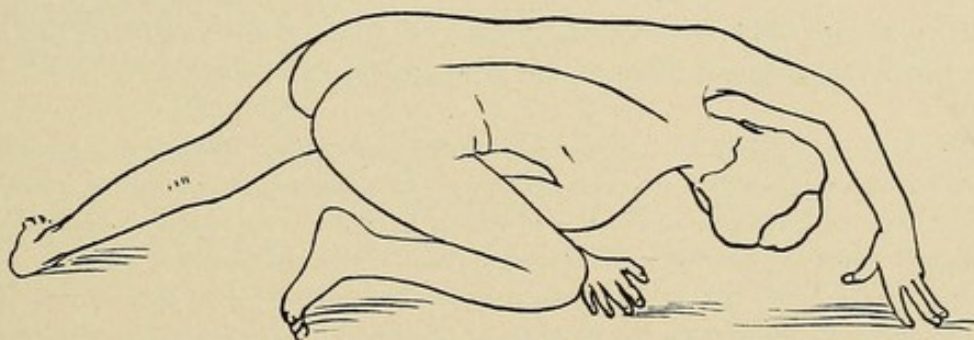

FIG. 114.

the forward reaching arm (Fig. 114). This is best employed as an asymmetrical exercise to correct the dorsal convexity and stretch the side of the concavity.

XXX. *Creeping Sidewise*.—There is a third asymmetrical variation in “creeping sidewise” toward the side showing the concavity of the curve to be corrected, for



example, in a left total curve. The patient creeps sidewise to the right. The left hand and knee are placed under the trunk, and as far as possible to the right of the right hand and knee. The right hand and knee are then advanced to the right and the above is repeated. The face should look to the left (Fig. 115).

This is a corrective exercise similar to other forms of creeping, and may also be used for dorsal curves as well as for those of the total type.

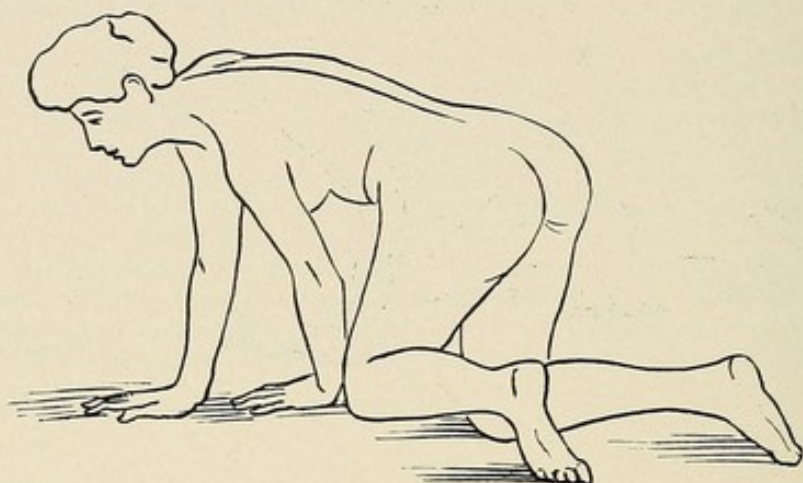


FIG. 115.

#### PASSIVE STRETCHING OF THE SPINE.

Increased mobility of the stiffened parts of the spine and stretching of the contracted structures is in all but the milder cases of structural scoliosis more easily to be obtained by intermittent passive stretching in apparatus than by active or passive gymnastic exercises without apparatus.

The following considerations bear on the use of force for stretching in both intermittent stretching and in forcible correction.

Such passive stretching of the spine is commonly secured by hanging by the arms from a bar, but preferably by upward traction on the head by means of a Sayre head-sling. A pull in the length of the vertebral column is not, however, an economical use of force.

The least economical use of force in straightening, for example, a bent stick is to pull the two ends away from each other, *i. e.*, to straighten it by a pull in its length. The most economical use of force is to take it by the two ends and press the point of greatest convexity against some resisting point which shall push it straight. The relative force exerted will be recognized if one is reminded how easy it is to break a bent stick by striking it on the knee while one hand holds each end and how very difficult it would be to break the same stick by a pull in its length.

Again, if one wishes to secure the greatest side displacement in a flexible rod, such displacement is more easily secured when the rod is not stretched in its length. If a rubber tube, for example, is fastened to a table by two pins, one at each end and is not put on the stretch, the middle of it can easily be pulled an inch to one side by the forefinger. If, however, it is pinned to the table by two pins separated,



enough to hold it on the stretch, it will require much more force to displace it one inch to the side. The same is true of a strip of sponge rubber or a piece of rattan.

To be sure that this theoretical consideration applied to the human spine the following experiment was made at the Harvard Medical School by the courtesy of Prof. Thomas Dwight.

A young male cadaver was laid on the face, and straps passed around the body at the level of the right shoulder and the right hip. These straps were then fastened to the left side of the table, holding the shoulder and hip against pressure from the left. A strap was then passed around the left side of the thorax and by means of a spring balance pulled to the right. The side deviation of the spine was then measured at four levels, the measurements being taken from a base-line connecting the cervical spine and the sacrum. The measurements were all made from pins driven into the spinous processes. Three experiments were made with a side pull of 25 pounds and the results were recorded.

A Sayre head-sling was then put around the head of the cadaver still lying on the face, and a traction force of 75 pounds was made in the length of the spine, the feet of the cadaver being fastened to the table. While the traction on the head was thus in force the same side pull of 25 pounds was made as before and the results noted. Two experiments of this sort were made. It was found that the spine without traction was displaced to the side nearly twice as far by a definite side pull as by the same amount of side pull when traction was being made.

A confirmatory experiment was made on a healthy boy of fifteen, using 75 pounds of head traction and 15 pounds of side pull. The result was the same.

The conclusion is that extension of the spine by an upward pull on the head is a corrective force in the normal spine, but that much more force is required to accomplish a certain amount of side correction than is the case if the force is applied from the side.

The other conclusion is that to secure the maximum of side displacement from a given amount of side pressure the spine must be slack and not stretched in its length.

Apparatus for the purpose has been devised, and is known as the Weigel-Hoffa frame, in which the patient is suspended by the head, while pads are run in from the sides of the frame, making lateral pressure in various directions.

Correction of the lateral curve of the spine is, however, to be obtained most economically by pressure on the slack spine, which is most easily secured by having the patient lie prone, and the corrective force should be divided into two elements, the force to correct the rotation and the force to correct the side deviation. A simple apparatus for this is as follows (Fig. 116):

The patient lies face downward, with the knees flexed, on a board three feet wide by four feet long. Assuming the case to be of a right dorsal curve, a broad canvas strap is passed around the left upper thorax, over and under the patient, and fastened to a cleat on the right side of the board. This furnishes a point of pressure



to the left against the upper thorax at the level of the axilla. A broad canvas strap is then passed around the pelvis of the patient above and below, and is fastened to a cleat at the right side of the board. This furnishes a point of pressure to the left at the level of the pelvis. A broad canvas strap is then passed around the thorax at the level of the greatest point of curve; it passes above and below the thorax and its

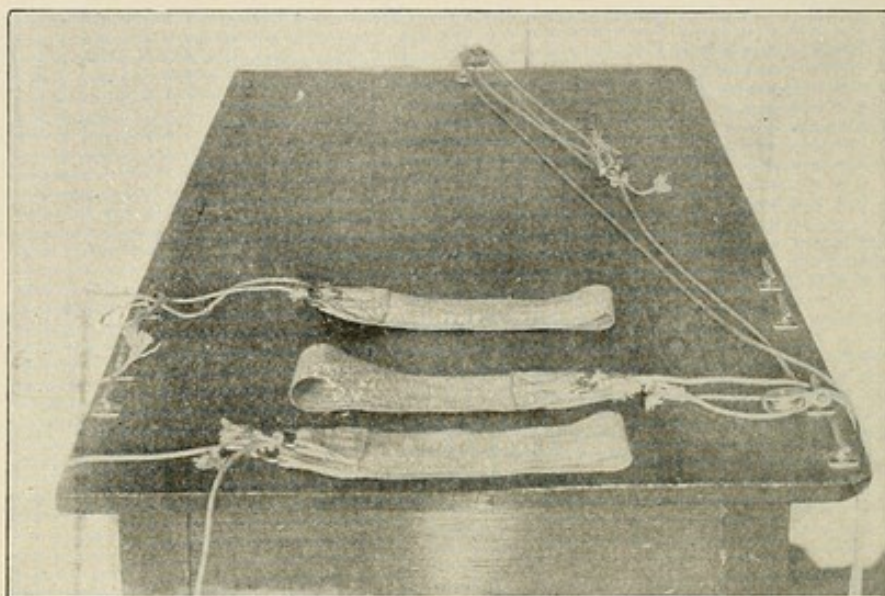


FIG. 116.—STRETCHING BOARD WITH LOOPS, READY FOR APPLICATION.—(*Jour. Am. Med. Assn.*)




FIG. 117.—STRETCHING BOARD WITH LOOPS APPLIED TO A PATIENT.—(*Jour. Am. Med. Assn.*)

upper end is fastened to a cleat at the left side of the board (Fig. 117). Its lower end is fastened by means of a string into a compound pulley attached to a cleat at the left side of the board. By means of this pulley any reasonable degree of force may be exerted against the right side of the thorax, pulling it to the left, and at the same time that it pulls, it tends to reduce the rotation from the fact that its upper end is fastened and its lower end moving toward the pulley.



A better and much more efficient appliance has been made by Dr. Z. B. Adams, of Boston.

In this a patient lies prone, with the knees flexed, on a table which is split transversely into five parts. The lower one, on which the pelvis rests, is furnished with two sliding wooden horns, which hold the pelvis firm. The next three pieces are provided with a pad sliding in from the side and a pad coming down from the top. These three movable pieces slide from side to side, and also rotate on a gas-pipe running the length of the table longitudinally. The patient is placed in the

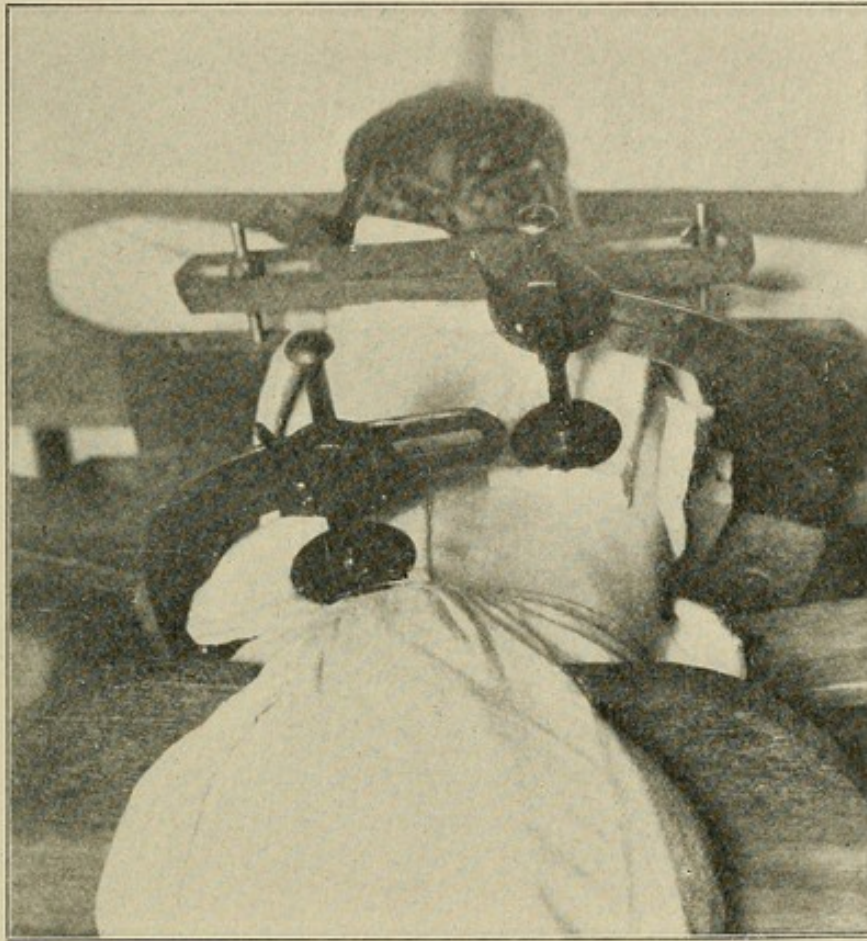


FIG. 118.—MACHINE FOR INTERMITTENT CORRECTION APPLIED TO A PATIENT.—(*"Jour. Am. Med. Assn."*)

apparatus, the pads are adjusted to the side and back of the loin or thorax, or both, and, by side pressure and a twisting of each arm, both rotation and lateral deviation are corrected separately at each level. In this way it is possible to correct both lateral deviation and rotation at one, two, or three levels for the purposes of stretching the spine by directly applied pressure. The top part of the table farthest away from the pelvis of the patient is fixed and on it rest the arms and head.

The patients are stretched daily in this apparatus and left in the corrected position for as long a time as can be borne comfortably—generally from fifteen minutes to half an hour.



# CONTINUOUS STRETCHING BY MEANS OF PLASTER-OF-PARIS JACKETS (FORCIBLE CORRECTION).

In severe cases of structural lateral curvature no means of treatment is so efficient as continuous stretching by means of plaster jackets applied under force. This method is spoken of as "forcible correction." Such jackets are applied in the hope of stretching the contracted structures and of inducing an improvement in the curve. By virtue of their being at work day and night they accomplish much better results than are to be obtained in any other way.

The treatment of severe scoliosis by plaster jackets applied in a corrected position is not new. But the force has generally been applied to the spine during suspension. Bradford and Brackett<sup>1</sup> described a frame in which the jacket was applied as the patient lay prone, but even here head traction was used. Nebel,<sup>2</sup> Calot,<sup>3</sup> Redard,<sup>4</sup> and others have used the horizontal position.

The whole question was given a new impetus by Calot's work on the forcible correction of the deformity in Pott's disease published in 1896.<sup>5</sup> The later tendency has been toward the use of much greater force than was previously employed.

The most noteworthy advance in the forcible corrective treatment of scoliosis was made by Wullstein, who has applied the above-mentioned principles with force and precision and who published photographs showing marked improvement in patients (Fig. 119). His method is to forcibly extend the head while the patient's pelvis is strapped to a seat which can be tilted to make the pelvis oblique and which also can be rotated to change the relation of the pelvis to the spine. Lateral pressure is made by pads running in horizontally from the sides of the apparatus. By a combined motion of the seat and adjustable pads any degree of twist of the spine upon the pelvis may be produced. Wullstein uses a large amount of force in his traction, applying up to 250 pounds of pull, and he applies a plaster jacket while the patient is thus stretched and pushed into a corrected position. This jacket embraces, as must all such jackets to be wholly efficient, the chest, shoulders, and head. The amount of force required, however, is excessive, as must be the case where force is not economically applied. He is attempt-

<sup>1</sup> "Bos. Med. and Surg. Jour.," May 11, 1893; Oct. 10, 1903.

<sup>2</sup> "Nebel: "Zeitsch. f. orth. Chir.," iv.

<sup>3</sup> Calot: XII Internat. med. Kongress zu Moskau, 1897.

<sup>4</sup> Redard: "Trans. Amer. Orth. Assn.," xi, 447.

<sup>5</sup> Calot: "France Méd.," 1896, 52; Schanz: "Berl. klin. Wochens.," 1902, 48



ing to straighten the bent stick by pulling the two ends apart, and when a great amount of force has thus been expended in stretching the spine, lateral pressure is applied, when it also must be pushed to an extreme on account of the stretching of the spine in its length.

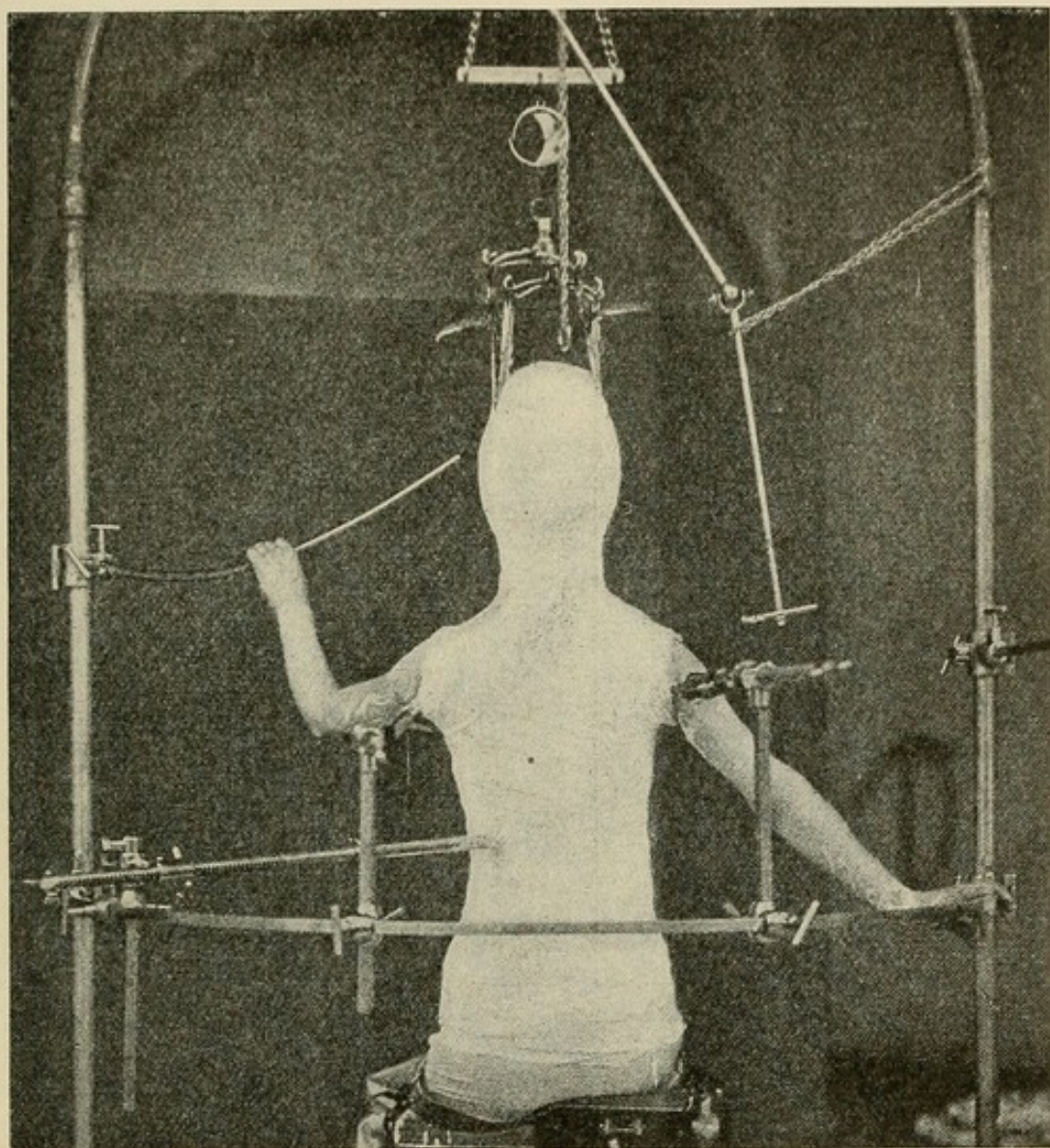


FIG. 119.—PATIENT WITH PLASTER JACKET APPLIED IN WULLSTEIN'S APPARATUS.—  
(*Wullstein.*)

In some experiments<sup>1</sup> on the scoliotic spine of a cadaver the following points were evident:

There was in the spine a fixed region, bounded above and below by the most movable parts of the spine—the lower cervical and the lower dorsal region. Manipulations to correct either the rotation or the lateral curve were, therefore, more likely to take effect above and below the curve than in the curve itself. Side pres-

<sup>1</sup> R. W. Lovett: "Bost. Med. and Surg. Jour.," Oct. 31, 1901.



sure pushed the whole dorsal region to the left, but made little impression on the curve itself.

This contrast between the fixed and movable portions was notably to be seen in attempts to correct the rotation. If oblique forward pressure were made upon the angles of the ribs, as prominent on the right side of the back, the cage of the thorax revolved horizontally, in one piece, upon the two movable parts above and below it, and the lateral curve, as seen from the back, was increased. This was

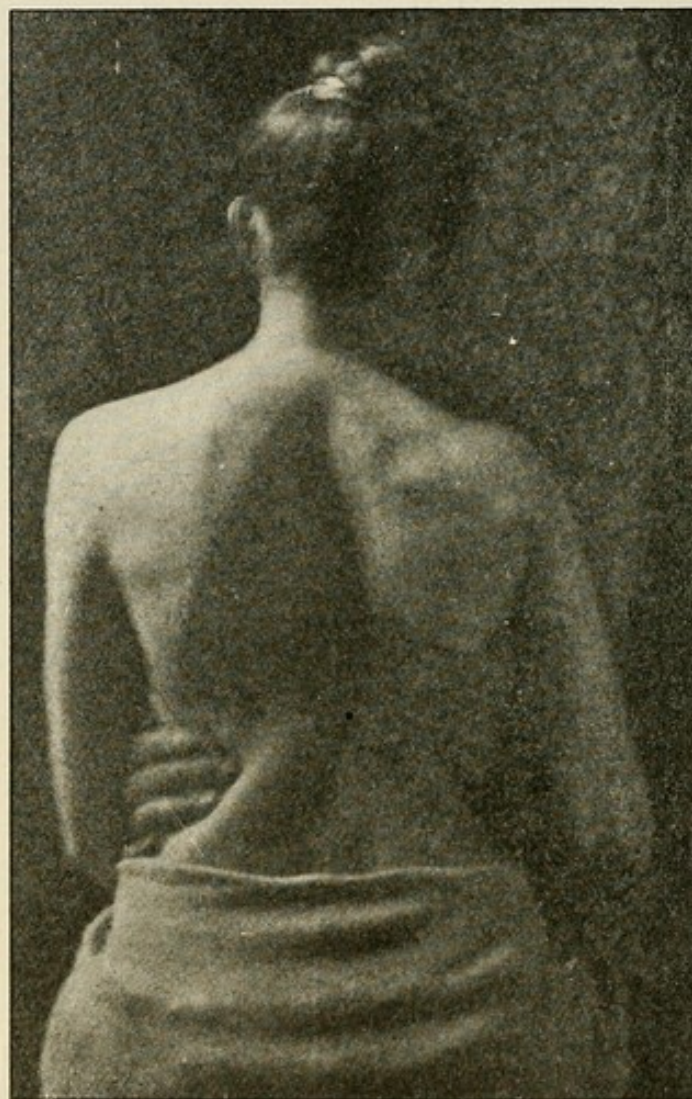


FIG. 120.—PATIENT WITH RIGHT DORSAL CURVE WITH RIGHT SIDE OF THORAX CARRIED FORWARD AND THE ROTATION IMPROVED WHILE THE LATERAL CURVE IS MADE MORE EVIDENT.

because the curved part of the spine, convex to the right, was twisted and carried further to the right, and the convexity of the lateral curve was apparently increased by being carried into another plane, thus making the whole lateral curve appear more marked, as seen from the back.

The reverse of this manipulation (that is, backward side pressure upon the right side of the chest) increased the rotation, but diminished the lateral deviation of the spinous processes and made the spine straighter when viewed from the back.



A similar experiment was made upon an adult woman patient, with a severe fixed curve similar to that of the cadaver. It will be seen that, when the bony rotation was diminished by forward pressure on the angles of the ribs on the right side, the lateral deviation was increased, no side pressure being made. When the rotation was increased by backward twisting of the right side, on the other hand, the lateral deviation was diminished (Figs. 120 and 121).

This criticism applies not only to the use of much corrective apparatus, but

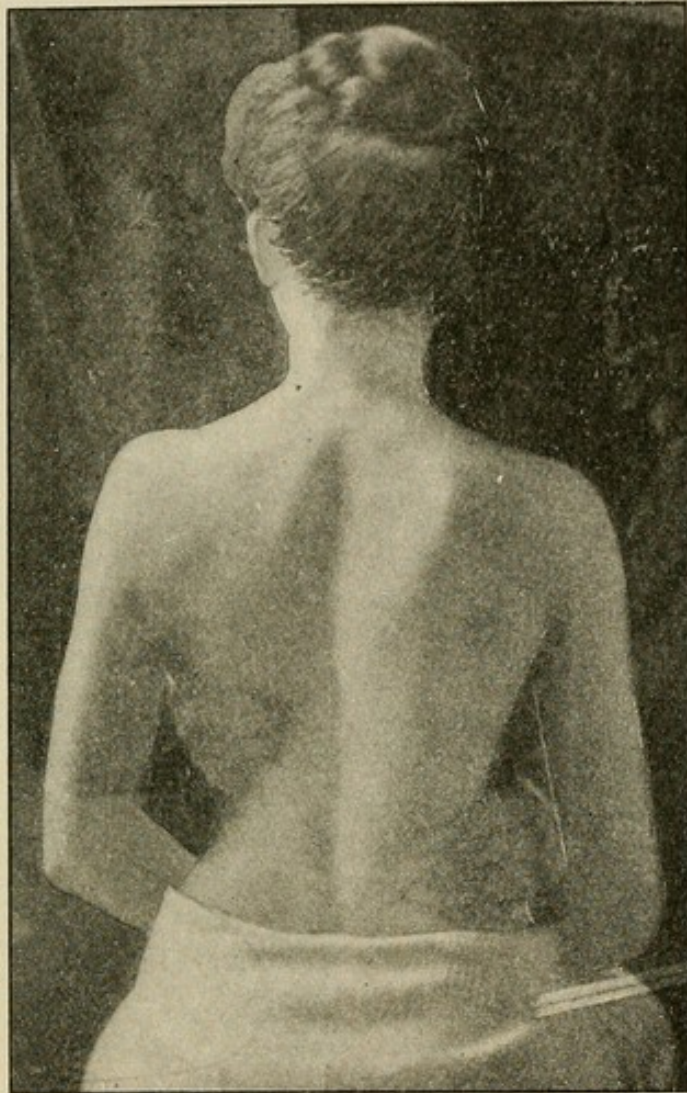


FIG. 121.—SAME PATIENT WITH THE RIGHT SIDE OF THE THORAX CARRIED BACKWARD AND THE ROTATION INCREASED BUT THE LATERAL CURVE MADE LESS EVIDENT.

also to gymnastic work where attempts to correct the rotation in fixed curves is made by manual pressure upon the prominent ribs.

Forcible correction by pure side pressure may increase the rotation, but, so far as it is effective, will diminish the lateral deviation. That this is not new may be appreciated by a quotation from Schreger<sup>1</sup> in 1810: "*Der seitliche Druck auf die Rippen biege diese an den ohnehin schon mehr spitzen Winkeln noch mehr*

<sup>1</sup> Fischer, quoted by Hüssey.



*Spitzig zu.*" That plaster jackets may cause increase of the rib angles is demonstrated by Hüssey.<sup>1</sup> The same point, that plaster jackets may increase the bony rotation apparent in the back, has been alluded to by Schulthess and Vulpius.<sup>2</sup>

It may, therefore, be stated that attempts, in fixed curves, to diminish the rotation by force in any degree directed forward, not carefully antagonized, will lead to an increase of the lateral curve. Conversely, attempts to diminish the lateral curve, by pure lateral pressure, not carefully antagonized, will result, in fixed curves, in an increase of the rotation.

The solution lies in dealing

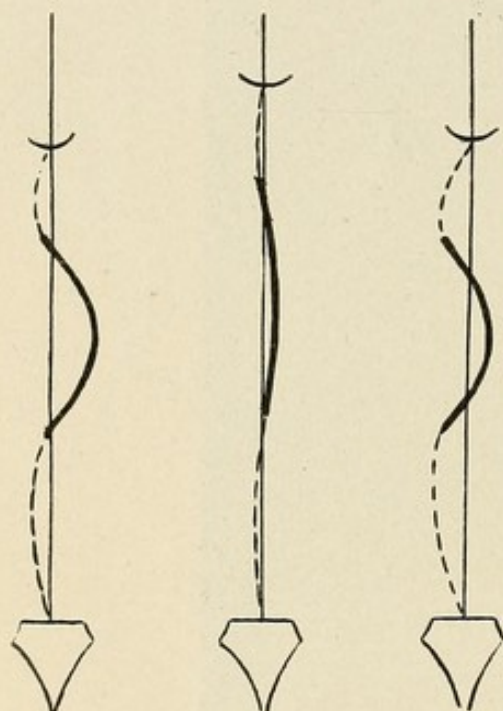


FIG. 122.—ON THE LEFT IS A DIAGRAM SHOWING A RIGHT DORSAL LEFT LUMBAR CURVE.

In the middle diagram the curve is shown straightened; on the right the curve has been pushed over to the left unchanged.

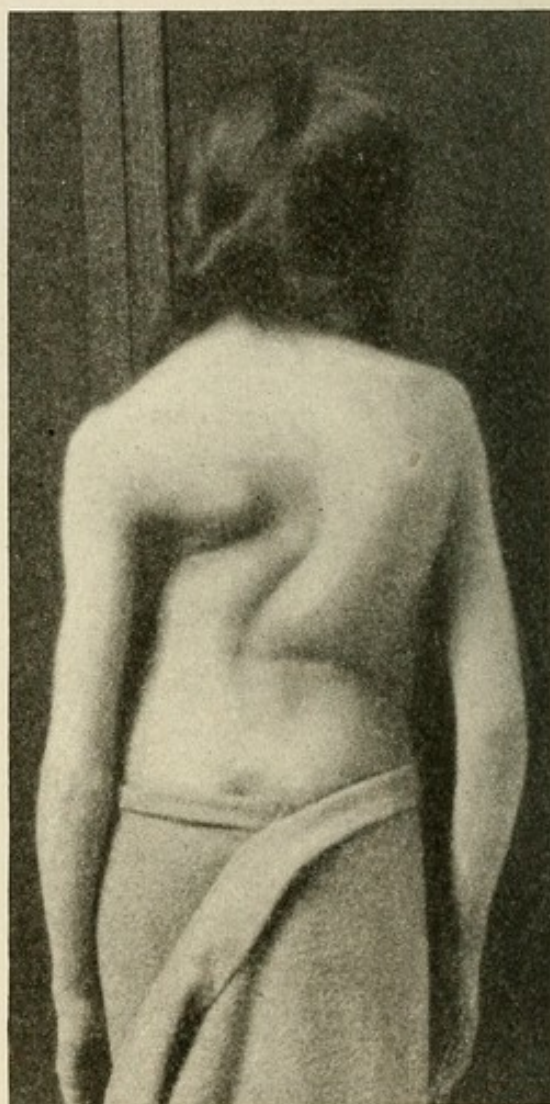


FIG. 123.—PATIENT THIRTEEN YEARS OLD. CURVATURE DUE TO RICKETS; NEVER TREATED.

separately with the rotation and with the lateral deviation. Having corrected the lateral deviation first, this correction is held, as will be

<sup>1</sup> Hüssey: "Zeitsch. f. orth. Chir.," viii, 2, 235.

<sup>2</sup> Vulpius: "Volkman's Samml. klin. Vort.," 276.



described, while the rotation is corrected or vice versa. In this way one element is not improved at the expense of the other.

Corrective jackets should be applied to the patients prone, and preferably with the legs flexed, as this diminishes the physiological curves of the spine and further simplifies the problem. With a patient thus lying prone, the spine is in the most favorable condition for side correction, both as regards side deviation and rotation, and by an intelli-

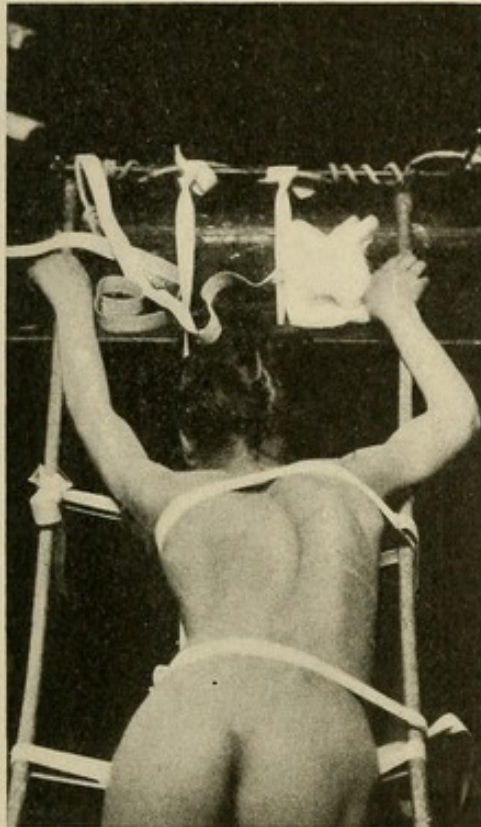


FIG. 124.—PATIENT LYING IN CORRECTIVE FRAME, SHOWING THE IMPROVEMENT GAINED BY THE HORIZONTAL POSITION.

Photographed from above. Patient same as in Fig. 123.




FIG. 125.—PATIENT IN CORRECTIVE FRAME WITH SIDE PRESSURE APPLIED BY STRAP.

Showing additional correction to that in Fig. 124.

gent application of force to correct each of these elements separately and independently. In this improved position the jacket is applied.

A simple application of this method is to be found by having the patient lie prone in a rectangular gas-pipe frame on two straps of webbing running from end to end, cross straps supporting the pelvis and shoulders. By means of webbing straps attached to the side of the frame, in a right dorsal curve, one going around the left side of the pelvis and another around the left upper thorax, while a third pulls on the right side of the thorax against these as points of resistance, great



improvement in the position may be obtained, which is secured by the application of a plaster jacket, but the apparatus is deficient because it corrects chiefly the side deviation and makes but little provision for the correction of rotation, which must be largely done by the hands.

The problem of the application of plaster jackets on this plan having thus presented itself was worked out mechanically by Dr. Z. B. Adams, of Boston.

The apparatus consists of a heavy gas-pipe frame, three by four feet. The patient lies face downward on two webbing strips running from end to end of the

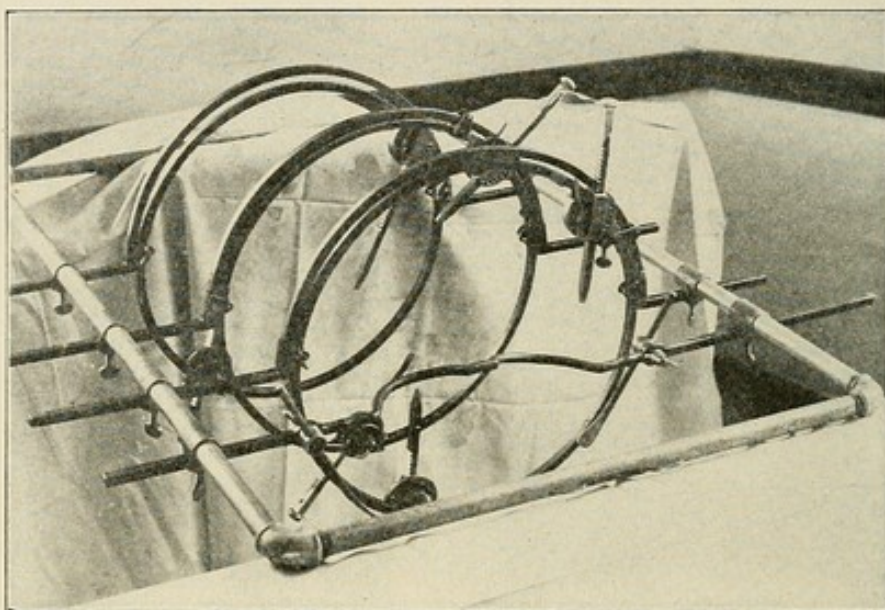


FIG. 126.—APPARATUS FOR FORCIBLE CORRECTION BY PLASTER JACKETS.—(*Jour. Am. Med. Assn.*)

frame with the legs flexed. Near the bottom of the frame is an adjustable cross-bar bent to fit into the flexure between the thigh and the pelvis on which the patient rests the lower part of the body. Sliding on this bar are two arms, which slide in and clamp down on the buttocks, holding the pelvis steady on the cross-bar. This bar is movable from side to side in order to induce or correct curvature in the lumbar region when necessary. There are three vertical transverse rings, two feet in diameter, fastened to pieces on the sides of the frame so that they can be moved to any desired point along the frame. These rings are also movable from side to side, and by an independent movement they can also be rotated through a half circle. Any one of these movements can be checked at any point by turning a screw. The shoulders are held by a pair of axillary straps fastened together by a strap across the chest in front. These straps are suspended from the ring nearest to the top of the frame, and can be made to hold the shoulders in any desired degree of twist by a rotation of the ring.

Each ring is provided with two long rods at the two poles of the ring. These rods are adjustable on the ring, and can be set at any desired angle to it. They can be pushed up or down and are controlled by a ratchet. By rotating the ring



and adjusting the angle of the rods they can be made to press down or up on any part of the back or chest.

For the application of the jacket the patient lies on the face on the two webbing strips, the lower part of the trunk resting on the cross-rod and the bars clamping

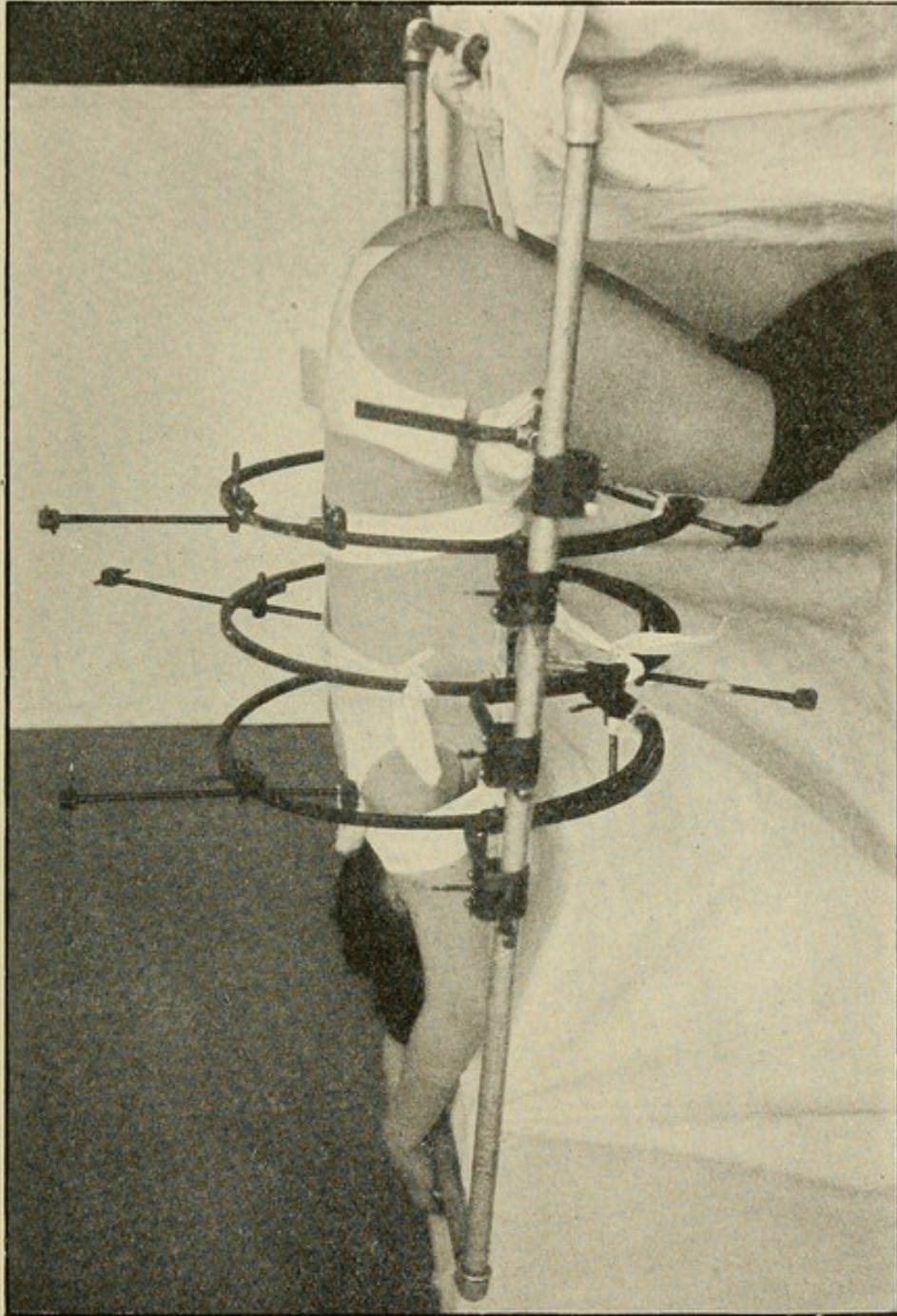


FIG. 127.—APPARATUS FOR FORCIBLE CORRECTION BY PLASTER JACKETS, APPLIED.—(*"Jour. Am. Med. Assn."*)

the buttocks; the feet rest on the floor, and the arms are extended above the head. The rings are then adjusted at the two levels where it is desired to make correction. For side correction a bandage is fastened to one side of the ring, carried around the patient's side over a heavy pad of felt, and back to the ring. The same is done to the other ring at the other level where side correction is desired, while the



top ring controls the shoulders by means of the pads and two loops of bandages passing through each axilla and fastened to the top of the ring. The rings are then pulled to one side, the bandages around the patient tighten, and any endurable degree of side correction is thus obtained.

When the side correction is made, the ring is rotated till the rods are opposite the points where it is desired to correct rotation. They are then pushed down on to the patient, their points being protected by sheet-iron pads, two by three inches, which are covered with heavy felt. These pads are incorporated in the jacket.

A plaster jacket is applied to the patient held in this way. It is easy to see

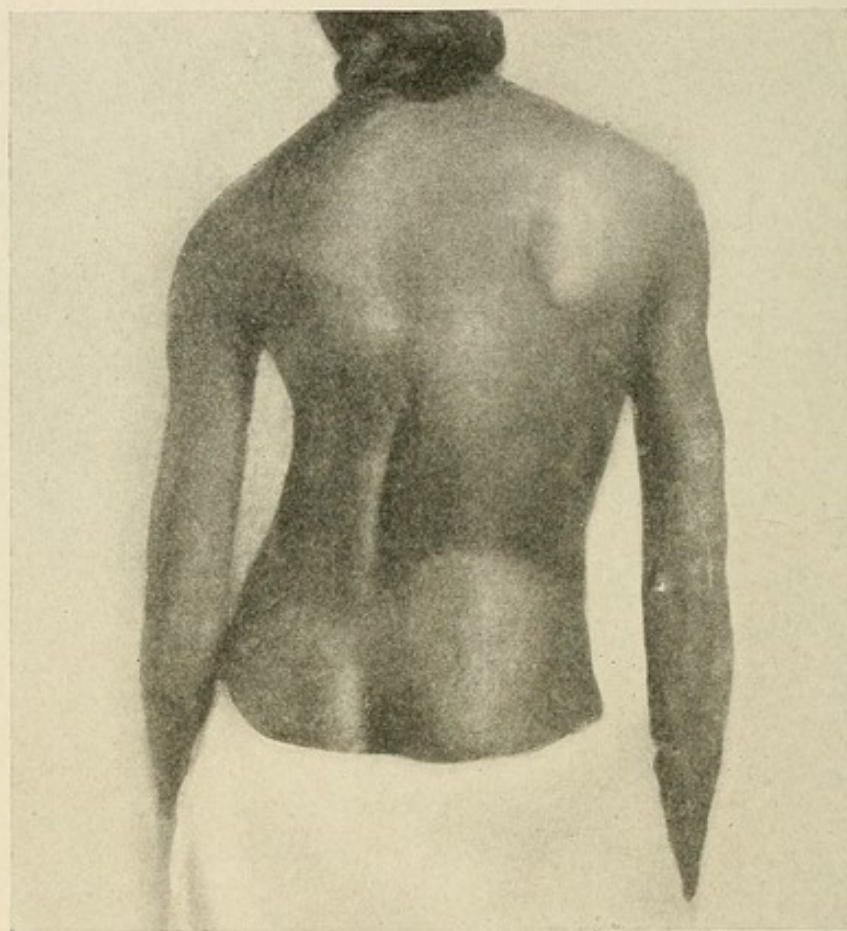


FIG. 128.—PATIENT OF WHOM RADIOGRAMS WERE TAKEN, BEFORE TREATMENT. (JANUARY, 1906.)—(*"Jour. Am. Med. Assn."*)

that the method is perfectly definite and that the amount of force at the operator's disposal is very great.

*Technic of Application.*—The patient should preferably be stretched once or twice daily for two or three days preliminary to the correction in the machine in which the jacket is to be applied, but this is not essential. Anesthesia is never necessary, as all endurable correction may be obtained without much pain. A seamless undervest is put on and the iliac crests padded with heavy felt; a pad should also be placed over the sacrum. Under the side straps heavy felt pads are required.

The correction is pushed to the point of causing mild discomfort, and difficulty



in breathing is a sign of too much correction. The amount to be obtained in any case is better decided by the patient's sensations than by any theoretical standard. The danger lies on the side of obtaining too much rather than too little correction, for the jacket will be much more uncomfortable when the erect position is assumed. After the patient has been removed from the apparatus the shoulders are incorporated in the jacket.

After correction the patient should remain in a hospital or under close observation for at least twenty-four hours. Some shock is not infrequently experienced

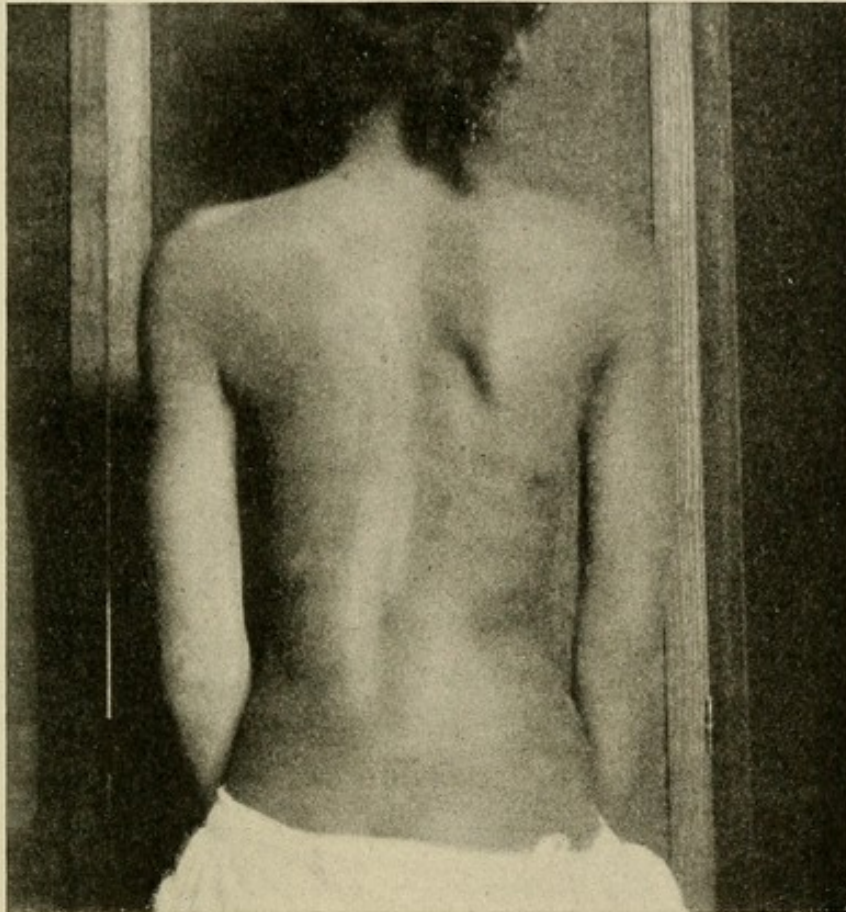


FIG. 129.—PATIENT SHOWN IN FIG. 128 AFTER WEARING CORRECTIVE JACKET FOR OVER A YEAR. (MARCH, 1907.)

and in a case of the writer's very serious collapse and cyanosis followed the correction of a severe curve due to infantile paralysis in a child of six. Wullstein has recorded the occurrence of somewhat serious symptoms following correction.

Successful permanent results can be obtained in hospital practice in only selected cases, the average patient being unable to appreciate the importance of following out the after-treatment. The most favorable cases for forcible correction are curves affecting the lower dorsal and dorsolumbar regions. Lumbar curves are not accessible to side pressure, and high dorsal curves are resistant because one cannot obtain a counterpoint higher than the axilla, which is not far above the



center of the curve. Such cases are to be corrected, if at all, by jackets applied in suspension by the head by a Sayre sling. Curves due to infantile paralysis, rickets, and empyema are available for forcible correction.

*Permanence of Results.*—The criticism that such correction is not

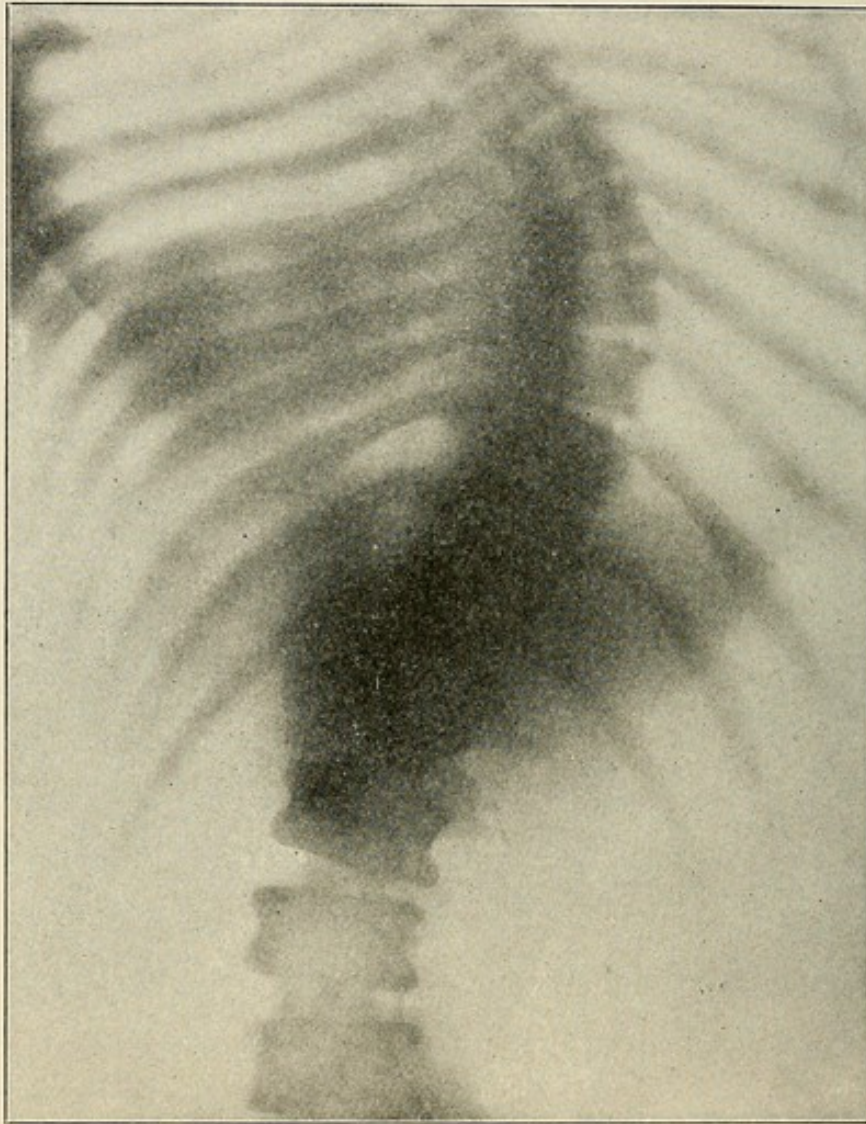


FIG. 130.—RADIOGRAM OF A PATIENT SEVENTEEN YEARS OLD (FIG. 128) LYING ON THE BACK, BEFORE THE APPLICATION OF JACKET. (JANUARY, 1906.)—(*Jour. Am. Med. Assn.*)

likely to be permanent at once presents itself. The grounds that lead one to suppose that retention of the growing spine in a corrected position over a sufficient period will lead to a change in the shape of the bones of the vertebral column and to a permanently improved position are as follows:

- (1) Club-foot may be cured by a similar proceeding.



(2) The bones of the feet of Chinese women of rank are seriously misshapen by retention in an unnatural position.<sup>1</sup>

(3) Wullstein produced bony changes in dogs by a few months of abnormal position.

(4) W. Arbuthnot Lane<sup>2</sup> has demonstrated that the carrying of

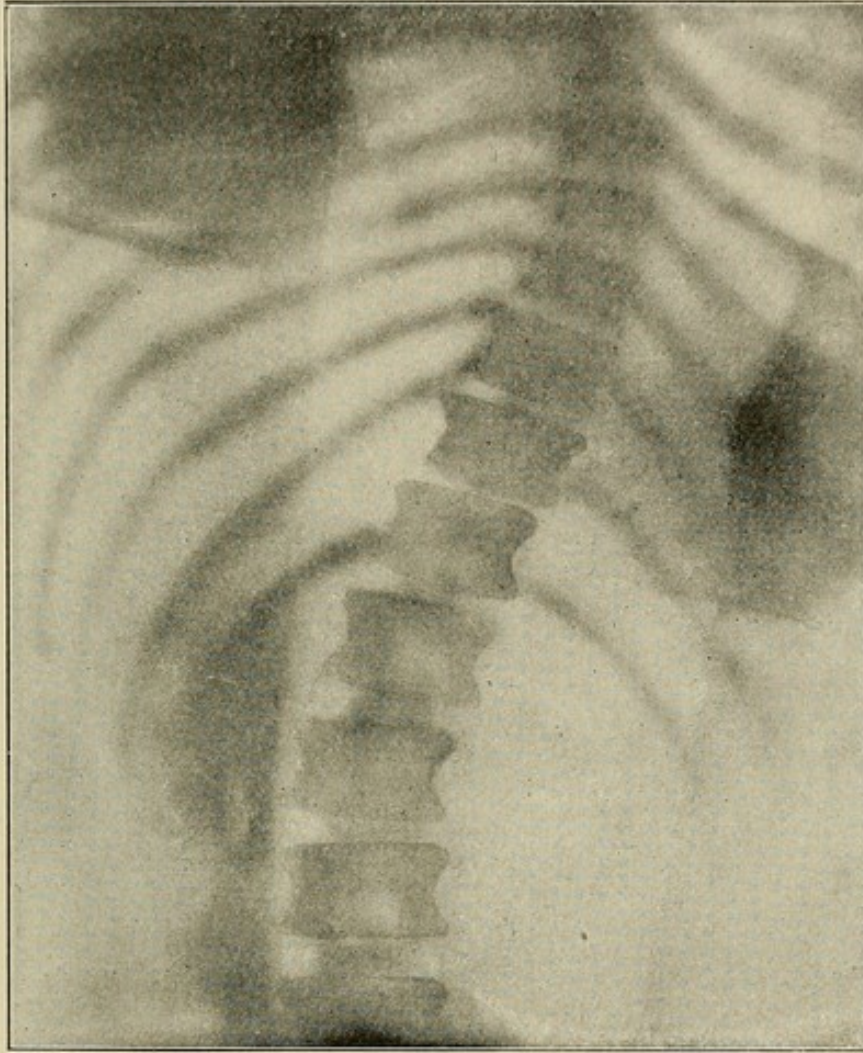


FIG. 131.—RADIOGRAM OF SAME PATIENT AS SHOWN IN FIG. 128, TAKEN AFTER THE APPLICATION OF A PLASTER JACKET THROUGH WINDOWS CUT IN FRONT AND BACK OF JACKET. (JANUARY, 1906.)—(*Jour. Am. Med. Assn.*)

heavy loads by laborers will produce changes in the bony skeleton and that the changes vary according to the habitual position of the load, the bones subject to the greatest pressure undergoing changes in shape.

(5) The fact that bone under pressure changes shape after growth

<sup>1</sup> P. Brown: "Jour. Med. Research," Dec., 1903.

<sup>2</sup> Guy's Hosp. Rep., xxviii.



has been reached is shown in the fact that scar tissue pressing on bone will cause a change in shape,<sup>1</sup> *e. g.*, on the chin.

(6) Pressure of tumors or aneurysm will cause absorption of bone.

These facts all point to the conclusion that bone alters its shape under changed conditions of pressure, and that although this would

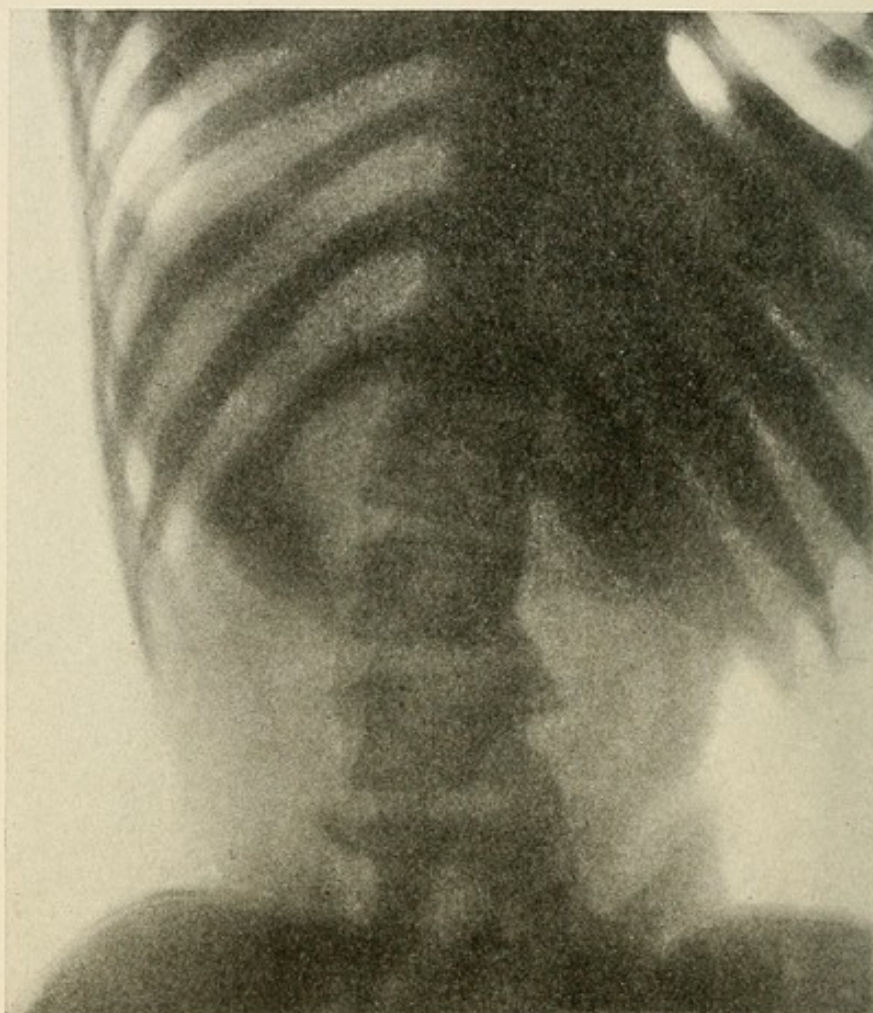


FIG. 132.—RADIOGRAM OF PATIENT SHOWN IN FIG. 128 AFTER WEARING CORRECTIVE JACKET FOR OVER ONE YEAR. (MARCH, 1907.)

be more marked during growth, the phenomenon is not unknown in adult life.

That a practical gain in the curved part of the spine may be secured by this method is demonstrated by the *x*-rays shown in the illustrations. The patient was a girl of seventeen, with a severe right dorsal curve, which was extremely rigid and had never been treated. The first *x*-ray was taken with the patient lying on the back. A corrective jacket was applied in the Adams apparatus, the front and back of

<sup>1</sup> Ziegler: Pathology, English ed., 1896, ii, 146.



the jacket were cut away to permit another x-ray, and the improvement in position is evident. It seems reasonable to hope that the maintenance of such an improved position may be expected in time to produce a change in the shape of the vertebræ. It is obvious that such a corrected position must be maintained over a period of many months to secure permanent results. As a rule, the first corrective jacket does not secure the maximum correction, and a second or even third corrective jacket should be applied if there is reason to suppose that there is

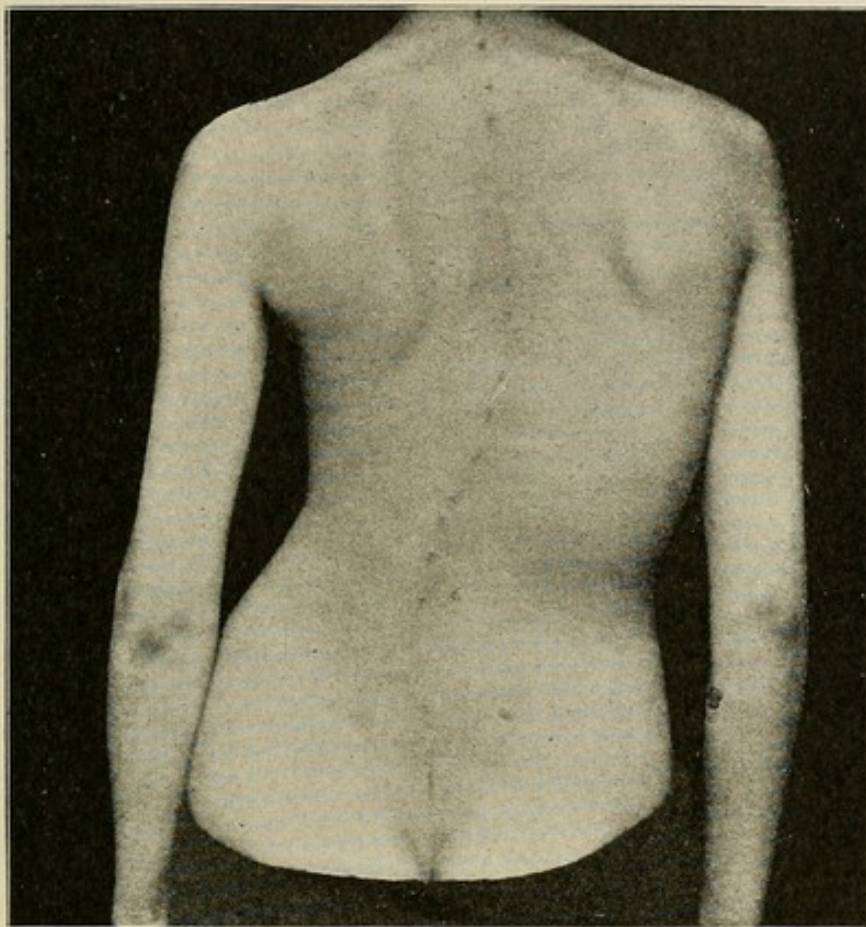


FIG. 133.—PATIENT SEVENTEEN YEARS OLD, NEVER PREVIOUSLY TREATED, BEFORE TREATMENT.—(*"Jour. Am. Med. Assn."*)

further gain to be obtained. An interval of one or two weeks between the jackets is sufficient (Figs. 130-132).

When this final jacket has been applied, there are two methods of procedure. (1) The final jacket may be removed, and one holding an equally good position may be applied after a month or more from the forcible correction (see Braces and Corsets). This jacket is worn night and day, and is to be removed only during the exercise periods, gymnastic treatment having been commenced when the final jacket is re-



moved. (2) In the second method of procedure the final corrective jacket is worn for a year or more without being split, with a view to conforming the child's figure to the shape of the jacket, just as a club-foot is made to grow straight in a corrective plaster splint and as the Chinese girl's foot is shaped by continuous bandaging (Figs. 128 and 129).

The choice between these methods must be determined by the circumstances of the patient, the temperament of the child, and similar considerations. Careless hospital patients will do better in a fixed

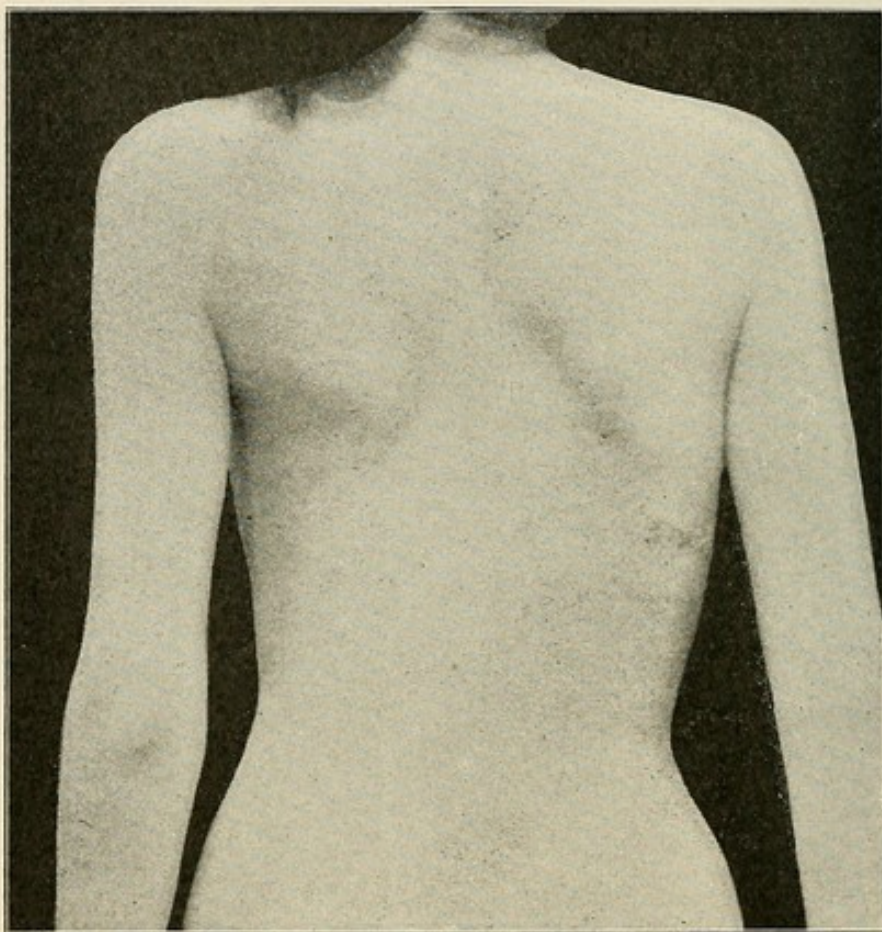


FIG. 134.—SAME PATIENT AS IN FIG. 133, AFTER TWO JACKETS. WHOLE INTERVAL, THREE WEEKS.—(*Jour. Am. Med. Assn.*)

jacket for a year or two, while nervous girls in private practice will do better in split jackets.

Schanz has provided clinical evidence of the permanence of results in a series of cases reported by photograph,<sup>1</sup> and presents his conclusion, which expresses thoroughly the views of the writer, as follows:

"That one by a careful selection of cases and correct carrying through of the necessary measures can retain the results of forcible

<sup>1</sup> "Verhandl. d. Deutsch. Ges. f. orth. Chir.," 4. Congress, page 61.



correction of scoliosis and permanently avoid the danger of relapse, my experience of over eight years with the method has proved beyond doubt."

It is undesirable to undertake forcible correction unless the patient can be under control for a period of two years at least.

**Gymnastics Following Forcible Correction.**—So soon as the final corrective jacket has been removed and replaced by a removable one, gymnastic treatment should be begun. The exercises to be used have been described in the section on Gymnastics. Such treatment to accomplish results must be given from one to four hours a day for a period of at least six months from the removal of the final corrective jacket, after which less frequent and vigorous exercises may be sufficient. Exercises must be continued until the corrected position is maintained without apparatus from month to month, and the supporting apparatus discontinued at first for short periods, gradually increasing in length. The length of time that active treatment must be continued will depend on the age of the child, the severity of the case, the efficiency of the treatment, and similar factors, but any case of scoliosis severe enough to require forcible correction will not, as a rule, occupy less than two years, and often a longer period.

The present discredit of gymnastic retentive treatment is due to its use in too small dosage and to a failure to appreciate that a problem so grave as the permanent maintenance of the corrected position in a spine, which has suffered some degree of bony distortion, is only to be obtained by a long continuance of accurate and mechanically sound treatment.

#### BRACES AND CORSETS.

Braces and corsets of themselves have no place in the corrective treatment of lateral curvature, and are only to be regarded as a means of retaining the gain secured by other methods. They must be regarded as having in themselves no *corrective* value, for such apparatus applied to a spine not previously loosened up by treatment is not able to secure any considerable correction by pressure on the spine because the base for the leverage to be obtained from the pelvis must consist in a pressure obtained from the space between the crest of the ilium and the top of the trochanter. Direct pressure on the crest of the ilium is not tolerated, and pressure on the trochanter interferes with walking and sitting. It is manifestly impracticable from this small space to obtain a hold which will exercise a sufficient side thrust on the thorax to be corrective. The current practice of the instrument-makers of fitting



corsets and braces to such patients and allowing the parents to hope for any considerable benefit is therefore to be condemned.

The most easily made and available corset is to be manufactured by removing from the patient the last corrective jacket, filling it with plaster-of-Paris and water, thus securing a torso of the patient. This torso is then further corrected by cutting away the plaster on the convex side and by building up on the concave side so as to secure a symmetrical or overcorrected model on which a jacket may be applied, or the patient may be suspended by a Sayre sling and a jacket applied and cut off to serve as a model for a torso. The torso is then shellacked and covered with a layer of stockinet or an undershirt, and a plaster jacket, having been applied on the torso, is cut off, furnished with lacings,

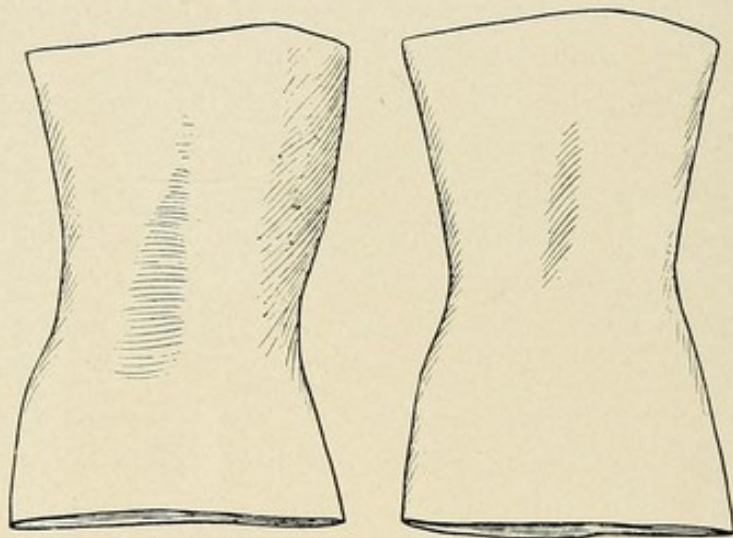


FIG. 135.—ON THE LEFT IS A PLASTER TORSO MADE FROM A CORRECTIVE JACKET. ON THE RIGHT IS THE SAME TORSO MADE MORE SYMMETRICAL FOR THE APPLICATION OF A REMOVABLE JACKET.

and supplied to the patient. All plaster jackets applied for forcible correction and retention must embrace the shoulders, and even the head should be included, but the disfigurement is so great that most patients are unwilling to submit to it in America. On the torso obtained as described may be constructed jackets of celluloid, leather, or other material, or corsets made of cloth and reinforced by steel.

The writer has found a segmented jacket of more general use than the ordinary one. A jacket is applied on a plaster torso in the usual way, and then the upper section, corresponding to the thorax, is separated from the rest of the jacket by a transverse cut. The lower section, corresponding to the pelvis, is separated in a similar way, and the two sections are then set in any desired relation to each other by means



of three steel strips, running vertically at the back and sides of the jacket, connecting the two sections. The thorax may thus be lifted in relation to the pelvis, displaced to either side, or rotated in relation to the pelvis, or any combination of these may be brought about. As treatment progresses the gain may be secured by changed relations of thoracic and pelvic sections (Fig. 136). The shoulders are controlled by pads pressing on the anterior aspect of the shoulder-joints.

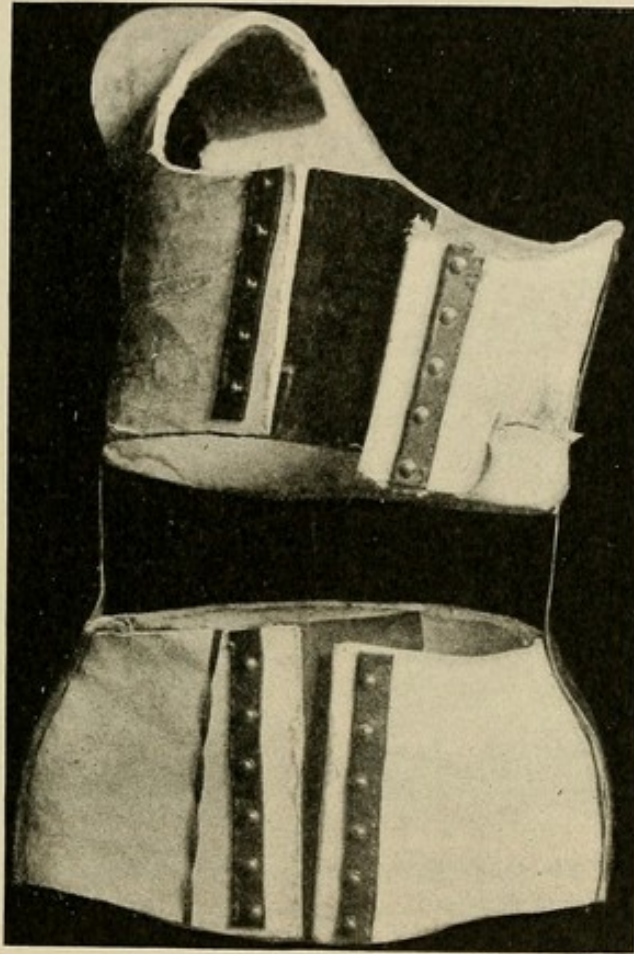


FIG. 136.—SEGMENTED CORRECTIVE PLASTER JACKET.

The complicated braces in former use have been largely displaced by the jacket or corset. They may be found described in the references.<sup>1</sup> The corset used in Germany is shown in the illustration (Fig. 137). The brace devised by C. W. Keene, of Boston, is efficient and may be taken as an example of the type of modern brace (Fig. 138).

*Operation.*—The question of the operative relief of scoliosis is still *sub judice*. An operation was proposed by Volkmann<sup>2</sup> in 1889, consist-

<sup>1</sup> Hoffa: "Lehrb. d. orth. Chir.," fourth ed., 1905, page 429; Redard: "Chirurgie Orthopedique," Paris, 1892, page 382; Bradford and Lovett: "Orth. Surg.," first ed., 1890, page 168.

<sup>2</sup> Volkmann: "Berl. klin. Wochens.," 1889, 50.



ing of resection of the ribs on the convex side of the curve, and this operation was also performed by Casse<sup>1</sup> and Hoffa<sup>2</sup> with fair results. A similar operation was thought out by N. M. Shaffer, of New York, about fifteen years ago, and spoken of to the writer at that time but never put on record, as the general surgeons to whom it was referred refused to sanction it.<sup>3</sup>

A good operative correction has been obtained by Hoke,<sup>4</sup> of Atlanta, Ga., who resected the ribs on the convex side of a girl of nineteen and

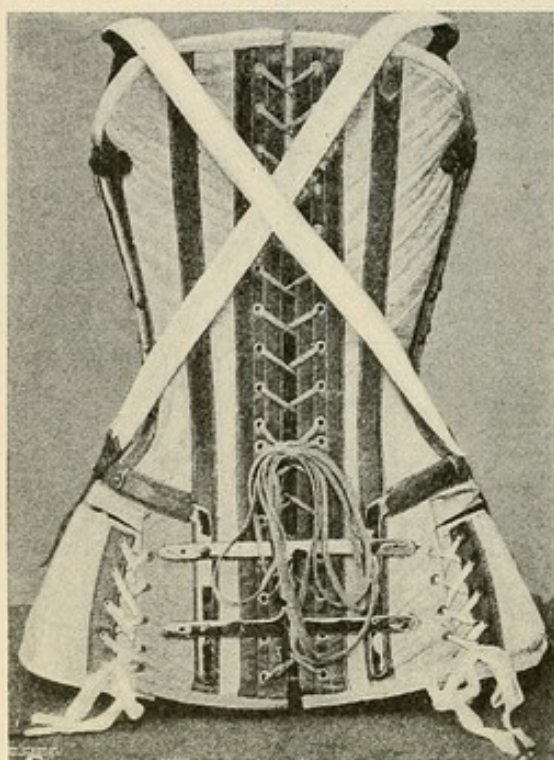


FIG. 137. — CORSET FOR SCOLIOSIS STRENGTHENED BY STEEL.—(*Dolega.*)

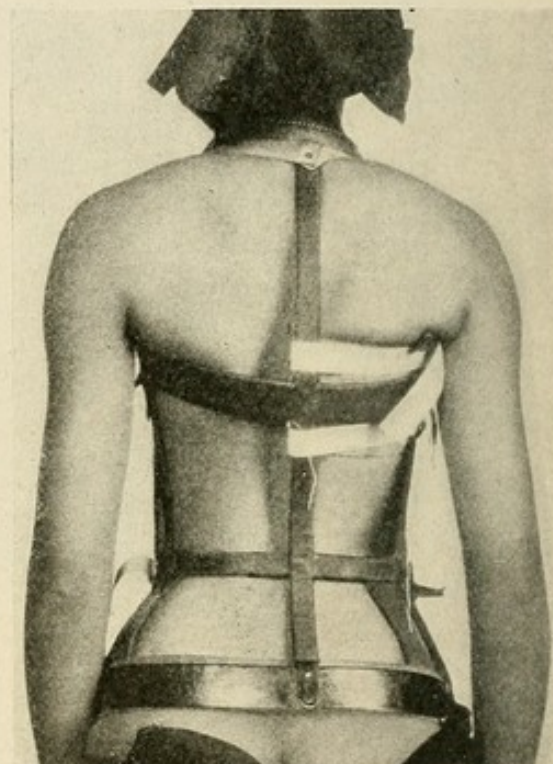


FIG. 138. — BRACE FOR A CASE OF RIGHT DORSAL SCOLIOSIS, APPLIED.—(*C. W. Keene.*)

lengthened those of the concave side in a severe dorsal curve. By the application of a corrective jacket great improvement was obtained.

Jaboulay<sup>5</sup> divided the cartilage of a single rib with a view of improving the shape of the thorax. Bade<sup>6</sup> has reported a case where he resected the ribs, but cautions against the use of narcosis in severe scoliosis.

<sup>1</sup> Casse: "Bull. de l'Acad. Royal de Med. de Belgique," Dec. 30, 1893; Jan. 27, 1894.

<sup>2</sup> Hoffa: "Zeitsch. f. orth. Chir.," 1896, 401.

<sup>3</sup> Shaffer: "Amer. Surg. Bulletin," Jan. 1, 1894.

<sup>4</sup> Hoke: "Amer. Jour. of Orth. Surg.," i, 2.

<sup>5</sup> Jaboulay: "Prog. Med.," Nov., 1893.

<sup>6</sup> Bade: "Klin. Mittheil. in Centralbl. f. Chir.," 1903, 38, 1045.



## CHAPTER XII.

### FAULTY ATTITUDE.

The investigation of the types of faulty attitude must be preceded by a consideration of the normal attitude in the anteroposterior plane.

### NORMAL ATTITUDE.

Normals have been described by Weber,<sup>1</sup> Meyer,<sup>2</sup> Langer,<sup>3</sup> Parou,<sup>4</sup> Henke,<sup>5</sup> Staffel,<sup>6</sup> and others,<sup>7</sup> which differ much among themselves, as would have been expected from the lack of a uniform system of measurement and because the normal type of standing is affected by age, sex, race, fashion, and occupation. A military cadet would not be expected to present the same normal as a woman of the same age who had worn tight clothes, heavy skirts, and pointed boots for some years.

One simple relation seems fairly constant above ten or twelve. A plumb-line held against the back of the sacrum touches or comes near the convexity of the dorsal spine. In young children it cuts this convexity. Slack standing makes the dorsal spine more prominent backward, and the dorsal curve lies in part back of this line under these conditions.

In order to approach the subject of normal attitude and the variations from it with some hope of solution a method of analysis and measurement was devised which has proved satisfactory.

Former observations have been concerned mostly with the spinal curve alone, but to appreciate the affection properly the base of support must also be considered. This method of record throws a certain practical light upon the question of treatment.

The apparatus by which the measurements are taken consists of the ordinary wooden upright with a sliding arm used for measuring the height.

<sup>1</sup> "Mechanik der mensch. Gehwerkzeuge."

<sup>2</sup> "Ueber den Mech. des mensch. Ganges," 1885.

<sup>3</sup> Langer and H. Meyer: "Anat. der äusseren Formen d. mensch. Körpers."

<sup>4</sup> Parou: "Virchow's Arch.," 1864, xxxi, 1-2.

<sup>5</sup> Henke: "Anat. u. Mech. der Gelenke," p. 213.

<sup>6</sup> Franz Staffel: "Die menschl. Haltungstypen," etc., Wiesbaden, 1889.

<sup>7</sup> Frorie: "Anat. f. Künstler," Leipzig, 1880, p. 40.



On this sliding arm and at right angles to it is a horizontal arm eighteen inches long, which is placed six inches from the back surface of the upright rod. This back surface of the upright rod is taken as the perpen-

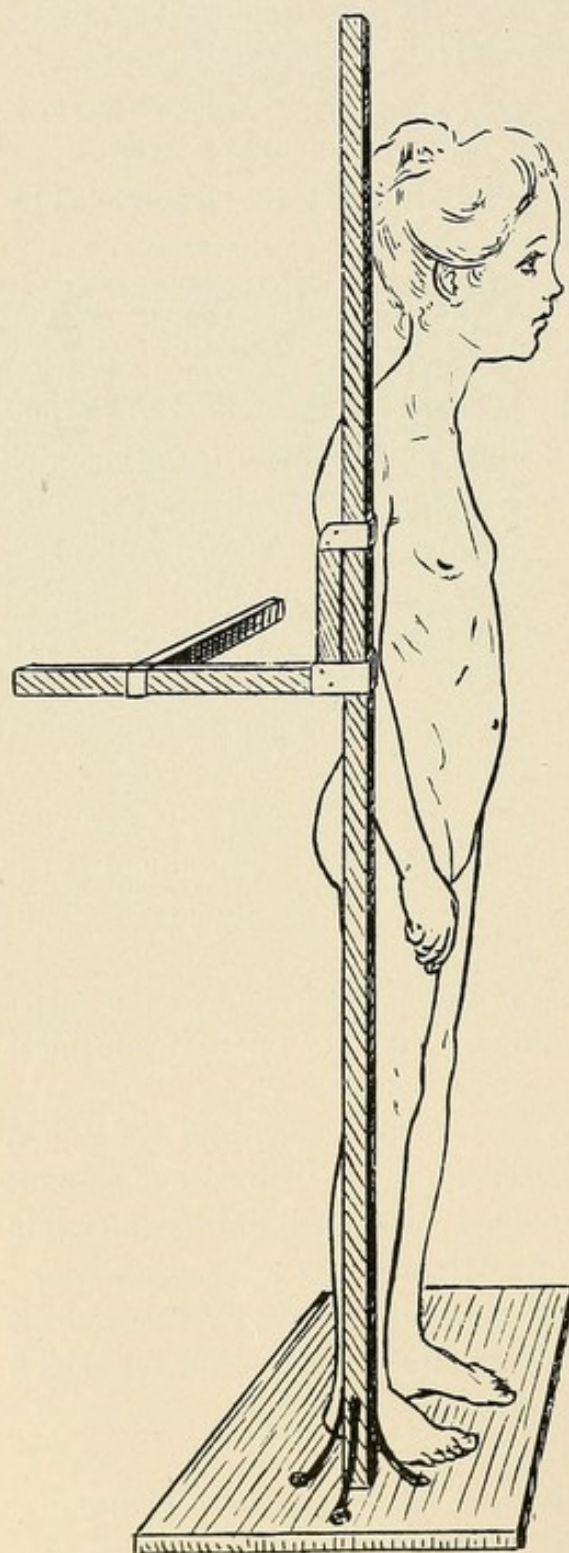


FIG. 139.—APPARATUS FOR MEASURING VARIATIONS FROM NORMAL ATTITUDE IN THE ANTEROPOSTERIOR PLANE.

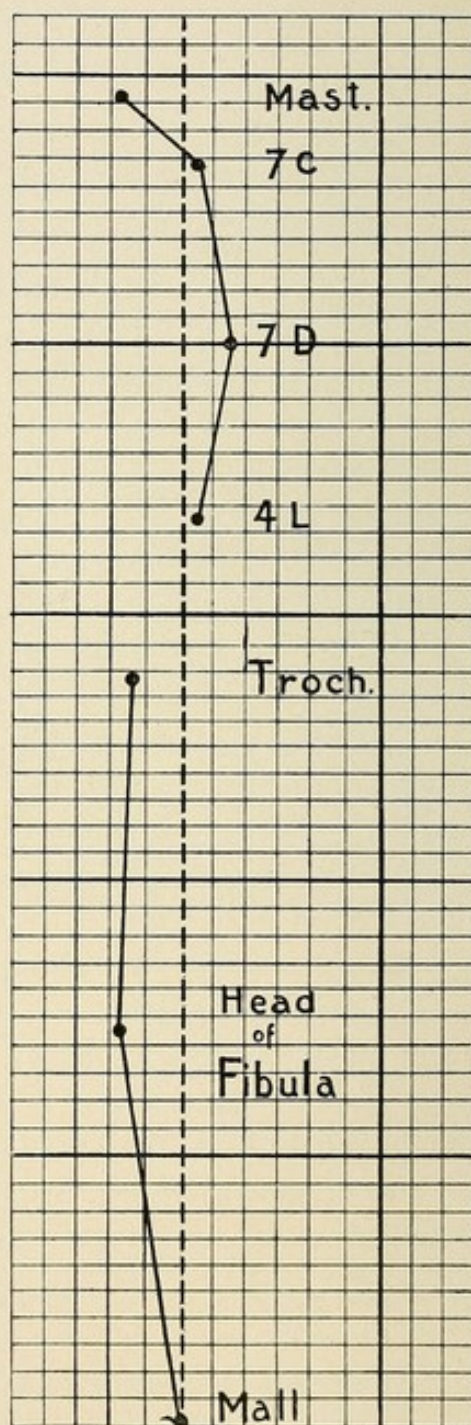


FIG. 140.—GRAPHIC REPRESENTATION OF STANDING POSITION, WITH THE PATIENT FACED TO THE LEFT.



dicular plane from which distances are to be noted, and the measurements are made from the sliding horizontal arm, which is always six inches distant from the back surface of the upright. Any point, therefore, more than six inches from the sliding horizontal arm is in front of the perpendicular plane agreed on, and any point less than six inches is behind it (Fig. 139).

The middle of the external malleolus was taken as the lower end of the perpendicular plane from which measurements were to be made. The patient stands without boots, in a natural position, with the feet forming an angle of 45 degrees, and with the middle of one malleolus opposite the back surface of the upright, the back of the patient being toward the sliding horizontal arm.

The measurements of the bony landmarks to be mentioned are then taken from the sliding horizontal arm, and the height at which each measurement is taken is recorded. This may be done, of course, either in inches or centimeters. Having then the height of each point desired as well as its distance from the ground, it is a simple matter to produce graphically the relation of these points by using ordinary coördinate paper and allowing one inch or one centimeter to each space on the paper. To secure uniformity of results, it may be assumed that the patient is seen facing the left.

The landmarks taken for measurement were those which could be easily identified by touch. They are as follows from above downward: (1) The middle of the mastoid process; (2) the spine of the vertebra prominens; (3) the spine of the seventh dorsal vertebra (on a level with the inferior angle of the scapula); (4) the spine of the fourth lumbar vertebra (on a level with the top of the iliac crest); (5) the middle of the great trochanter; (6) the middle of the head of the fibula; (7) the middle of the external malleolus.

The measurement is taken by marking with a skin pencil the points to be measured. The patient is then placed with the back to the sliding arm and the outer malleoli opposite the back edge of the upright. In order to get the measurements before the patient becomes fatigued and sways, it is necessary to work quickly. The mastoid measure is taken, and then the arm pushed rapidly down while the distances of the points from it are measured with a rule at each level. Having taken these down, it is necessary, if the curve is to be reproduced graphically, to record the height from the ground of each bony landmark, and the sliding arm is again pushed up and the level of each marked bony landmark recorded. By this division of the two measures



the first and important one should be finished before the patient becomes unsteady, and in the second set swaying is of no account.

A typical measurement would be as follows:

| CASE M. L. TYPE <i>a</i> . |                         |                    |
|----------------------------|-------------------------|--------------------|
|                            | DISTANCE FROM UPRIGHT.  | HEIGHT.            |
| Mastoid.....               | 7 $\frac{3}{4}$ inches. | 49 inches.         |
| Seventh cervical.....      | 5 $\frac{1}{2}$ "       | 46 $\frac{1}{2}$ " |
| Seventh dorsal.....        | 4 $\frac{1}{2}$ "       | 40 "               |
| Fourth lumbar.....         | 5 $\frac{1}{4}$ "       | 33 $\frac{1}{2}$ " |
| Trochanter.....            | 7 $\frac{1}{4}$ "       | 27 $\frac{3}{4}$ " |
| Head of fibula.....        | 7 $\frac{3}{4}$ "       | 14 $\frac{1}{2}$ " |
| Malleolus.....             | 6 "                     | 2 $\frac{1}{4}$ "  |

The curve is plotted by marking the points on coördinate paper and drawing lines between them. As below the level of the fourth lumbar vertebra the line no longer follows the back outline of the body, but changes to the axis of the leg; the fourth lumbar and trochanter marks are not connected by a line.

The method has been repeatedly tested by taking two successive independent measurements of the same patient and comparing them, and by taking measurements on succeeding days and comparing them, with the result of finding that the two conformed on the whole, the type persisting and the chief difference being in slight swaying forward or back which was at times evident.

The method is not intended to be mathematically accurate, but to give a fairly accurate graphic representation of the patient's method of standing. It has the advantage of being applicable in adults, where record by full-length photographs is not available, and the measurements can obviously be taken without objectionable exposure in the case of women.

The measurements of seventy-two normal boys between the ages of fifteen and nineteen, taken by Dr. Greenwood, seem the material most available to compare with the normals described. They were all healthy, well-developed boys, averaging eighteen years of age, and the individual tracings differed but little from each other. An average curve of the tracings is, therefore, representative of the standing position of these young men (Fig. 141).

Tracings of the curves of the normal attitudes as represented by v. Meyer, Langer, and Staffel were then taken by marking on their figures the places of the bony landmarks adopted, connecting them with lines and considering them in their relation to a perpendicular erected through the external malleolus in each case. The normal of v. Meyer reproduced in that way was unlike any curve found in normal persons, while that of Langer is also unusual. The normal curve constructed from



Staffel's figure is, however, practically identical with that of the seventy-two boys.

With regard to the curves of six hundred college girls, taken by the

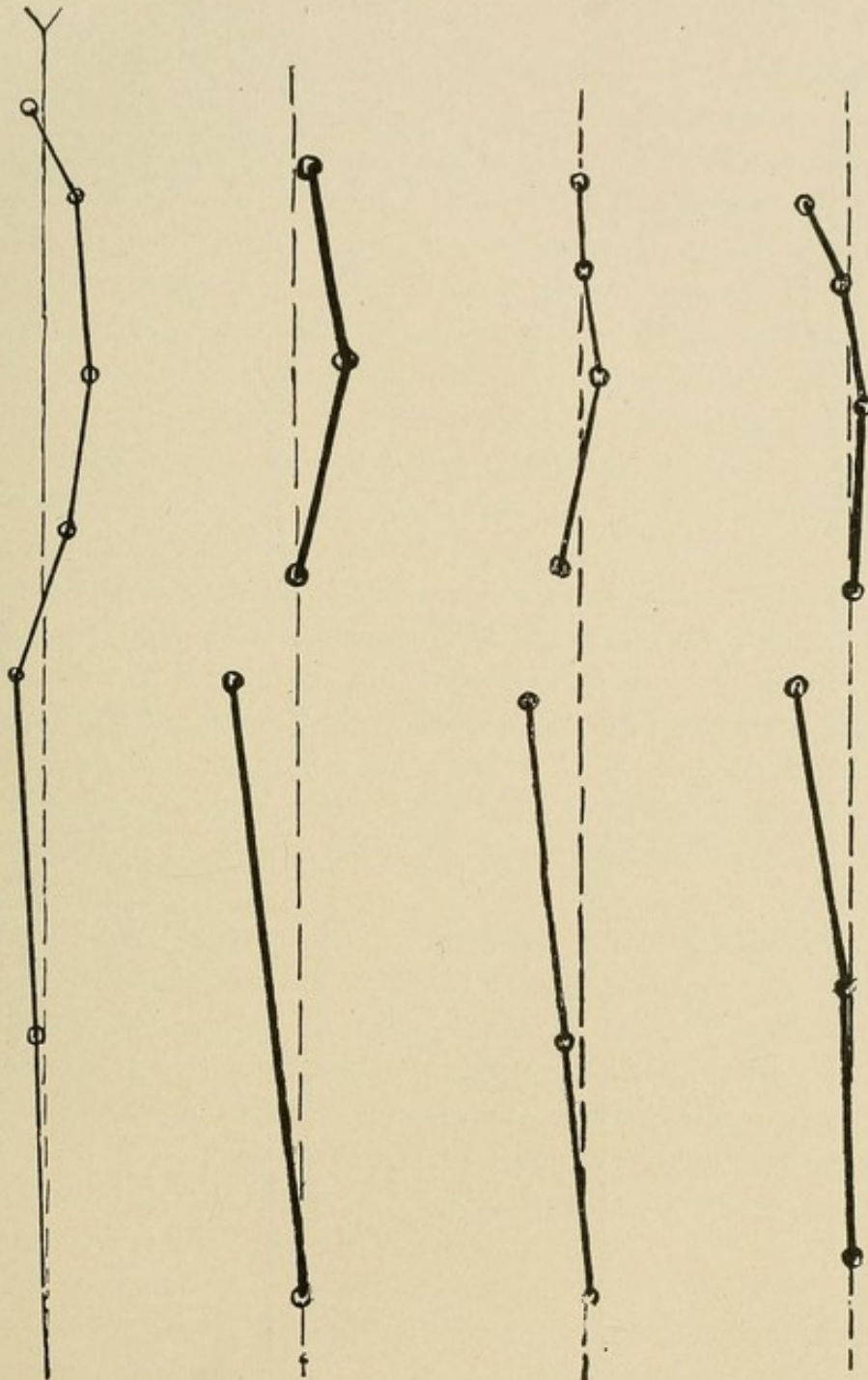


FIG. 141.—COMPOSITE CURVE OF SEVENTY-TWO NORMAL BOYS. —(*Greenwood.*)

FIG. 142.—STAFFEL'S NORMAL.

FIG. 143.—LANGER'S NORMAL.

FIG. 144.—V. MEYER'S NORMAL.

physical examiner of the college, the individual variations are much greater than in the males, and there is a general tendency to carry the



body further forward and to hyperextend the knees, the lumbar curve, also, as one would expect, being greater than in the males (Fig. 148).

*Types of Variation in Faulty Attitude.*—As no one classification of these types has been universally adopted, and as the classifications differ among themselves, it seemed best to start afresh

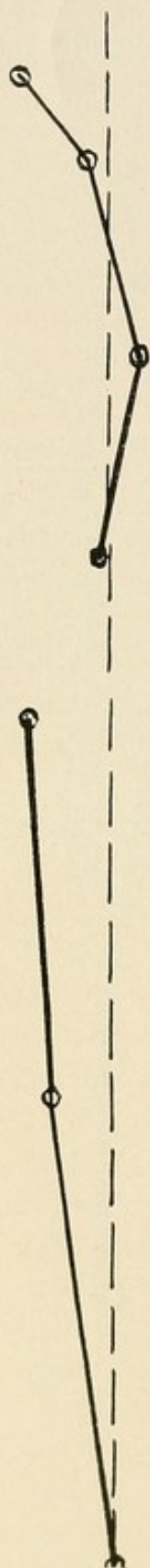


FIG. 145.—TYPE A OF ROUND SHOULDERS.

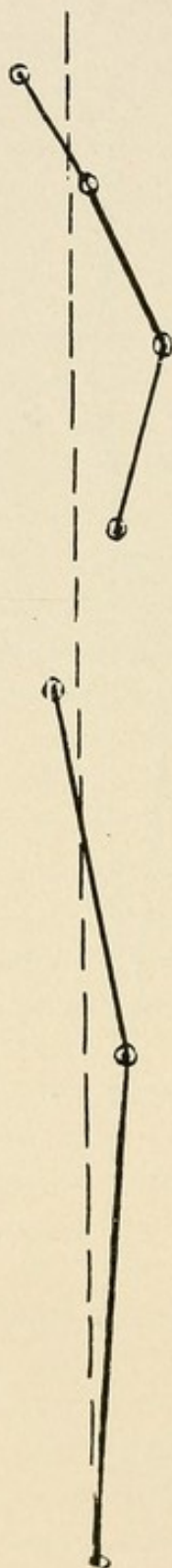

FIG. 146.—TYPE B OF ROUND SHOULDERS.



FIG. 147.—TYPE C OF ROUND SHOULDERS.



FIG. 148.—CURVE OF YOUNG ADULT FEMALE OF GOOD CARRIAGE.



and see if these measurements of patients (mostly children) offered any basis of reasonable classification by which they might be divided into groups for study, to see what constant types of variation the curves showed, and to find out by photographs to what clinical types of faulty attitude these variations corresponded.

It was difficult to decide what factor in the attitude should be the basis for classification; whether it should be the relation of the trunk to the legs, of the pelvis to the perpendicular, of the whole swing of the body backward or forward, or of the relation of the points in the spine itself. On examining the graphic representations of the tracings of faulty attitude in this connection the most constant grouping seemed to be by the spinal curve. That is, the cases showed four types of spinal curves, and, arranged according to these types, the other characteristics of the curves seemed to be fairly constant in each group.

The four types of spinal curve were as follows:

*Type A.*—A general curve (an exaggeration of the normal lines), where the spine from the mastoid to the fourth lumbar forms one general curve backward. As a rule, there is little lordosis in these cases (as shown by the relation of the fourth lumbar to the trochanter). The pelvis is, as a rule, well in front of the perpendicular, and the body axis lies generally in the perpendicular, but may be wholly in front of it, and in one case only lay behind it. The legs, as a rule, incline forward, and are rarely hyperextended at the knee. This is the most frequent type, and consists, in a word, of rounded back with little forward lumbar curve (Fig. 145).

*Type B.*—Backward projection greatest in the mid-dorsal region, the seventh cervical and mastoid points forming a straight line above it. There is generally lordosis, the pelvis is near the perpendicular, and the body axis lies, as a rule, behind the perpendicular. The legs are rather vertical, and if there is not marked lordosis, the knees are apt to be hyperextended. This type is second in frequency, and represents the seventh dorsal point as the most prominent point backward, with some lordosis in the lumbar region (Fig. 146).

*Type C.*—The lower part of the back is straight, and the head runs forward from the seventh cervical. There is generally not much lordosis, the pelvis is not pushed forward, but is near the perpendicular, and the body axis lies back, as a rule. The knees may or may not be hyperextended. In this case the head is thrust forward from the upper part of the spine, and the body weight is thrown back (Fig. 147).

*Type D.*—The spinal points form a line nearly or quite straight.



The back is nearly flat, lordosis is marked, the pelvis is generally back, but it may be forward, and the knees generally somewhat flexed.

It is of interest to inquire what relation these types bear to the types formulated by Staffel. Points were marked on his figures corresponding to the bony landmarks selected, lines drawn, and a perpendicular erected through the external malleolus. Group A in this classification corresponds to his "round back"; Group B is his "round hollow back"; Group C is his "hollow back"; and Group D is his "flat back." The difference between Groups C and D in his classification is not so distinct as in these cases.

The *flat back* is to be considered rather a peculiarity of conformation than a deformity requiring attention. It is significant largely from the fact that such children are particularly likely to develop scoliosis.

The *hollow back* within moderate limits is in the same way to be regarded as a peculiarity of conformation. The hollow back or lordosis, however, may reach a high degree in certain pathological conditions. The least abnormal pathological deviation in lordosis is found in the marked hollow back of backward contortionists. Lordosis occurs pathologically in connection with pregnancy, in paralysis of abdominal or back muscles, in tuberculous disease of the lumbar spine, in severe rickets, in double congenital dislocation of the hip, in double coxa vara, in ankylosis of the hip in a flexed position from tuberculous disease or other cause, and in spondylolisthesis.

### ROUND SHOULDERS.

Stoop or slant shoulders, round back, round hollow back, stooping, faulty attitude, kyphosis, bowed back.

German—Schlechte Haltung, runde Rücken, Kyphose, hohlrunde Rücken, Kypholordose, habituelle Kyphose.

French—Dos Vouté, Cyphose.

Italian—Schiene rotonde.

Grouped under this name are various types of faulty attitude. Variations from the normal attitude in the lateral plane of the body have been discussed under scoliosis. Variations in the anteroposterior plane will now be taken up. When the two variations coëxist, as frequently happens, the lateral variation is in general considered the important one, and the case is classed as scoliosis. Variations from the normal anteroposterior attitude are in general grouped under the name of round shoulders, shading into each other and characterized by a disposition to economize muscular force in maintaining the erect position.



These deviations have been but imperfectly studied or formulated, and have in general been grouped as round shoulders because an increased convexity of the dorsal spine is the most common characteristic.

In general the attitude is familiar, the head is carried forward and is somewhat flexed, the physiological curve in the dorsal region is increased and the dorsal region unduly prominent behind, in which backward curve the lumbar region may share, or there may be also an increased lumbar curve forward. The shoulders are drooping and the chest narrow and flat, while the scapulæ behind are prominent on their posterior borders and the inferior angles may stick out markedly (*scapulæ alatae*). The abdomen is prominent and the pelvic inclination varies. Flat-foot or pronated foot frequently coexists.

Children with round shoulders are, as a rule, below the average in muscular development and lack vigor; they are clumsy in their movements and walk heavily. In some cases the deformity can be removed by a muscular effort on the part of the patient or by gentle pressure with the hands, but in most cases of even average severity the deformity cannot be wholly corrected by gentle passive force, as the maintenance of the malposition has led to adaptive shortening of the soft parts concerned. The cases may therefore be considered as flexible or resistant, an important distinction in treatment. Great injustice is done to children with resistant round shoulders by the continual commands to "sit straight," a position which it is impossible for them to assume.

If such a child is laid face downward on a table with the arms at right angles to the body the arms may by passive force be carried back of the middle line of the body. If in this position the arms are carried up beside the head and then lifted back they cannot as a rule be carried so far as the median plane of the body. If such a child is told to put the arms up in the air in the standing position it is done by making the back hollow in the lower part and protruding the abdomen, because the soft parts between the chest and arms do not permit a free movement.<sup>1</sup> Lateral curvature of the spine coexists in the majority of cases of this sort.

The affection is not wholly one of the spine, but implies a disturbance of relations from the feet upward because an increase in the backward curve of the spine implies a forward curve or forward displacement somewhere else to balance it. The dorsal spine in other words cannot become more convex without a compensating lumbar curve forward, or a forward displacement of the pelvis and legs if the lumbar spine is involved in the backward dorsal curve.

<sup>1</sup> E. H. Bradford: "Round Shoulders," "Orth. Trans.," vol. x, page 162.



Round shoulders, therefore, is not to be considered or treated as an affair wholly concerning the dorsal spine and shoulders. On closer analysis these cases will be found to fall into three not very well-defined groups. Transition cases of all grades are seen, and the division is mentioned simply to aid in the study of the cases and their treatment. The groups are as follows:

#### 1. ROUND BACK.

The dorsal and lumbar spine form one convexity backward, which is physiologically a persistence of the infantile position. A lordosis is apparently often present, but on identifying the landmarks this will be found to be merely the upward and forward slope of the sacrum

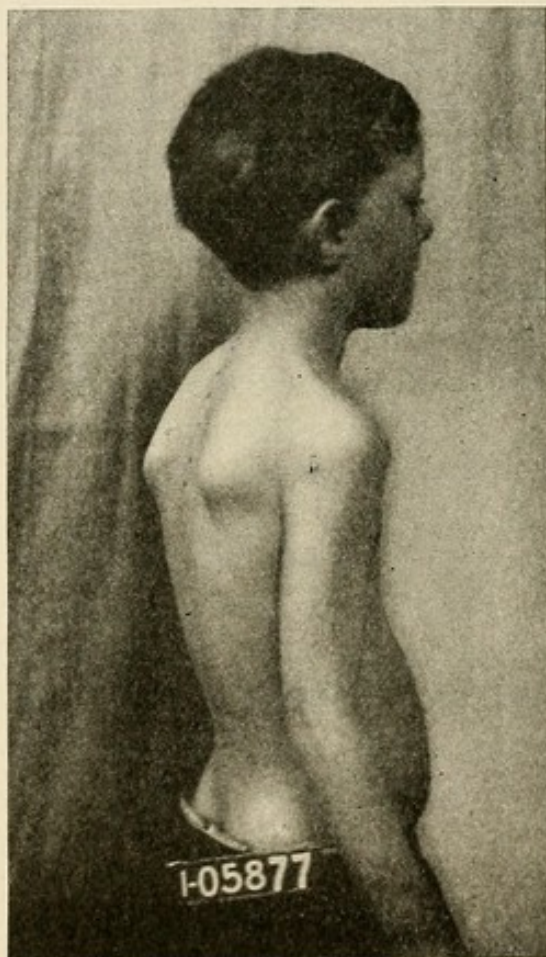


FIG. 149.—ROUND BACK.

and that the lumbar spine does not share in it. A plumb-line dropped through the mediotarsal joint passes behind the ear and the hip-joint, but most of the dorsal curve is behind it. The pelvic inclination is diminished. This corresponds to Type A of the classification given above and to the round back of Staffel and Combe.



## 2. ROUND HOLLOW BACK.

The dorsal spine is bowed backward, but the lumbar spine is bowed forward. The appearance of round shoulders is present, but the general attitude is modified because the pelvis has a greater inclination than in round back and is not so far forward, the abdomen is prominent, and the gross appearance is the same as in round back—the essential modification being produced by the greater pelvic inclination. This corresponds to Type B of the classification given above, to the round hollow back of Staffel, and the kypholordosis of Combe.

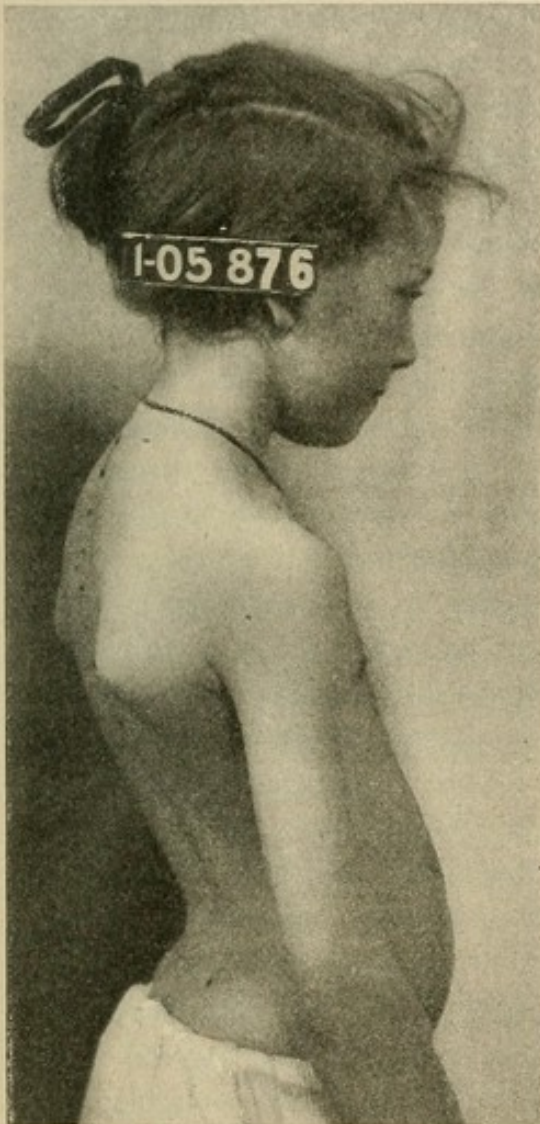


FIG. 150.—ROUND HOLLOW BACK.

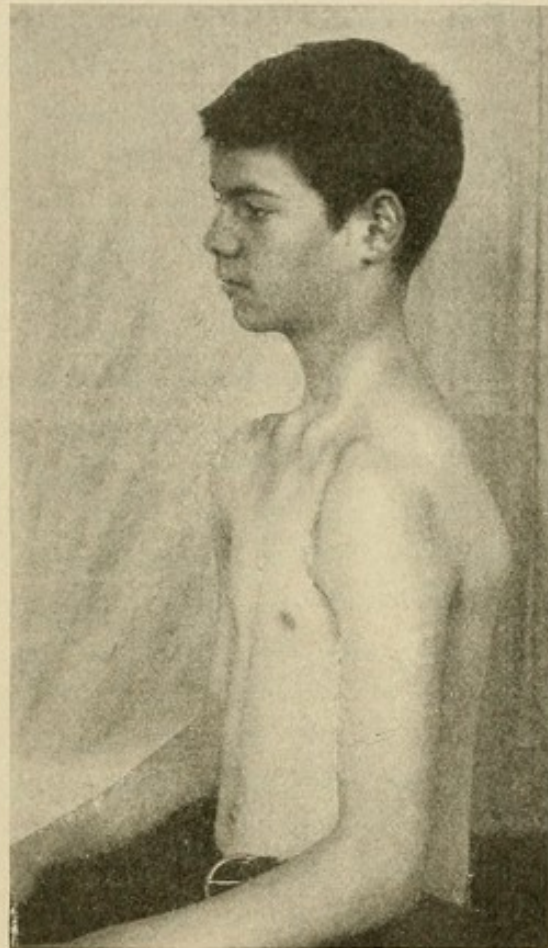


FIG. 151.—FORWARD POSITION OF THE SHOULDER-GIRDLE.

## 3. FORWARD DISPLACEMENT OF THE SHOULDERS.

A condition has been described by Hasebrook<sup>1</sup> in which a forward displacement of scapulæ and shoulders is the chief characteristic.

<sup>1</sup> "Zeitsch. f. orth. Chir.," xii, 4, 613.



This displacement may exist with a flat back, in which case it is quite unlike ordinary round shoulders, or it may exist in connection with a rounded back, in which case it is not conspicuously different from the types described. The displacement may be flexible or resistant to correction by passive force. For purposes of clearness the name round shoulders will be used to designate the three groups.

#### ETIOLOGY.

In general the causes of round shoulders are to be sought in—(a) conditions causing muscular weakness; (b) conditions causing a flexed position of the lumbar spine for long periods, and in (c) overweighting of the shoulders by improperly arranged clothing. Hoffa inclines toward the view that a weakness of the will is a more important cause than weakness of the muscles.

a. Conditions causing muscular weakness are found in rapid growth, overwork and bad air at school, improper school furniture, acute illness, bad hygiene at home, and similar conditions.

b. Prolonged flexion of the spine is induced by school furniture which fails to support the back, by errors in vision which necessitate stooping over the books in reading, and in careless attitudes of reading and sitting permitted at home. The child with normal eyes should not have to hold the book nearer than twelve to fourteen inches.

c. The customary method of supporting a child's clothes in this community consists in the use of a waist, loose around the abdomen, to which drawers and skirts or trousers are buttoned.<sup>1</sup> To this waist are also attached side elastic stocking supporters which are kept tight to prevent the stockings from wrinkling. This waist is supported above by two shoulder-straps passing over the shoulders near their tips. The whole weight of the clothes and the added pull of stout elastics is thus transferred to the child's movable shoulders, of all parts of the body the least suited to hold against a steady downward pull. This pull is transferred in a measure to the spine by the muscles, clavicles, and thorax, and tends to produce flexion.

The remedy of this condition consists in supporting as much as possible the clothing from a belt, in using round garters, and in having a waist made in which the pull comes at the root of the neck instead of at the tips of the shoulders.

<sup>1</sup> Bradford: "Orth. Trans.," vol. x, 162; Goldthwait: "Amer. Jour. of Orth. Surg.," vol. i, 64.



## OCCURRENCE.

Scholder found 5.8 per cent. of round backs in the school children of Lausanne, about equally divided between boys and girls, the percentage of scoliosis in these children being above 25. The age of occurrence of round shoulders covers the period of childhood from shortly after the time that walking begins to adolescence; most cases are seen by the surgeon in middle childhood and about puberty, when in girls especial attention is paid to the figure and carriage.

## PATHOLOGY AND MECHANISM.

The pathological changes in round shoulders must be determined rather by inference and interpretation of clinical symptoms than by postmortem examination.

Permanent kyphosis in a healthy growing dog was produced experimentally by Wullstein, who approximated the pelvis and shoulders by straps, causing a flexed position of the spine. In children who continue to grow with the spine in flexion analogous adaptive changes must occur in the spine and its surrounding structures to those found in scoliosis. Fitz, in a series of dissections on about one hundred normal cadavers, supplemented by clinical observation on fifty-six children with round shoulders, concluded that in resistant round shoulders the obstacle to reposition was not to be found in the pectoral muscles, but that the most common factor was tightness of the serratus muscle. Occasionally associated with this was to be found shortness of the coracoclavicular and acromioclavicular ligaments.<sup>1</sup>

Hasebrook<sup>2</sup> considered the cause of resistant forward displacement of the shoulders to lie partly in the costoclavicular and coracoclavicular ligaments and partly in the pectoralis and serratus muscles. He divided the cases into two groups—first, those due to contraction of the muscles holding the shoulders forward, and, second, to weakness of the muscles holding them back.

## PROGNOSIS.

The attitude of round shoulders is not to be regarded as one which will be spontaneously outgrown. On the other hand, it requires treatment, and with adequate treatment and proper hygiene the prognosis for recovery is good in young children. In older children and adolescents improvement and perhaps cure are to be obtained. Even

<sup>1</sup> G. W. Fitz: "Bos. Med. and Surg. Jour.," Apr. 19, 1906.

<sup>2</sup> "Zeitsch. f. orth. Chir.," xii, 4, 613.



in young adults an improved position of the shoulders and a better expansion of the chest are to be secured by adequate treatment.

#### DIAGNOSIS.

The diagnosis of round shoulders, as a rule, presents no difficulty, but at times it is not easily distinguished from more serious affections, causing a backward bowing of the spine. The means of distinguishing between the different varieties of round shoulders have been sufficiently indicated in the description of them. The most important point is to distinguish a static bowing of the spine from one caused by disease. In the former there is no marked stiffness of the spine, pain is absent, the bowing is gradual, and *x-ray* appearances are normal.

**Differential Diagnosis.**—*Pott's disease* (tuberculosis of the spine, angular curvature of the spine) is discussed in speaking of the diagnosis of scoliosis. At certain stages of dorsal *Pott's disease* the attitude may resemble round shoulders.

*Arthritis deformans of the spine* is discussed under the diagnosis of scoliosis.

*The neurasthenic spine* (hysterical spine, irritable spine) exists both by itself and as a complication of round shoulders in persons of a nervous temperament. It affects generally female adults, but may occasionally be seen in children, generally in girls approaching puberty. The back is painful and perhaps somewhat stiff on motion, the skin is sensitive, and symptoms of irritability are acute. The *x-ray* appearances are normal. Such irritable spines may follow accidents, strains, and overuse.

No gymnastic treatment for a case of round shoulders should be undertaken in a patient where pain or stiffness of the back is present without a very careful preliminary period of observation and a careful elimination of the first two conditions mentioned above.

#### TREATMENT.

The treatment of round shoulders is different in flexible or non-resistant cases and in resistant cases.

**Non-resistant Round Shoulders (Flexible Round Shoulders).**—The treatment does not differ radically from that of postural scoliosis in that both are of the type of the "setting-up drill" of the army recruit. In both one tries to substitute a correct attitude for the incorrect or faulty one. What has been said with regard to the treatment of postural or functional scoliosis applies equally to the treatment of flexible round shoulders, the routine and exercises being described in that place (page



124) for both conditions, and certain exercises being designated as especially adapted to round shoulders.

**Resistant Round Shoulders.**—The treatment of these cases is similar in plan to that of structural scoliosis where first mobilizing and then retentive measures must be separately recognized, even if both are carried out simultaneously.

*Mobilization.*—When the shoulders are held forward by contraction of the soft parts and cannot easily be replaced in the normal position, simple gymnastics are likely to prove unsatisfactory and some stretching of the contracted parts is necessary in order to save time and make gymnastics more effective. To stretch these soft parts by gymnastic exercises is slow and often unsatisfactory, and when it is done must be accomplished by passive stretching induced by pulling back the shoulders either with the arms at the sides or on a level with the shoulders, whichever position offers the greatest resistance.

Passive stretching, however, by means of an apparatus is more efficient and quicker. The means to be described offers a simple method.

The apparatus consists of an oblong gas-pipe frame of the ordinary pattern. Fastened to this near the middle, and hinged so as to be raised to any degree, is another section of gas-pipe lying on the frame proper and of the same shape and size as the upper half of the frame. To this movable section is fastened, at right angles to it and movable on it, a gas-pipe bridge rising about eighteen inches from the movable section (Fig. 152).

When prepared for use two strips of webbing, lying one over the other, run from each of the buckles at the bottom of the frame. The lower two strips are tightly drawn, and run to the buckles at the end of the movable section. The upper two are loosely fastened to the bridge over the movable section. The cross-pieces are tightened and the patient laid face downward on the webbing strips, which may, if desired, have laid over them a folded piece of sheet wadding. The strips, however, even in adults, are not uncomfortable. The thighs are flexed and the feet rest on the floor, so that the lumbar spine is flattened. Two pieces of webbing are passed over the middorsal region from side to side, tied to the lower non-movable frame on each side. These furnish the resistance for the straightening of the spine when the upper end of the frame is lifted, carrying with it the head and upper chest. The upper part of the frame is lifted after the patient is in place and as much force as seems advisable is exerted. This should never be pushed beyond the point of mild discomfort. Several stretchings are first made of a few seconds each, and the movable part of the frame again let down to rest the patient.

*Forcible Correction.*—In average cases intermittent stretching is sufficient to loosen up the contraction and to make an improved position possible. In the severer cases, however, a plaster jacket should be applied in the improved position.



The patient's spine is hyperextended as described, by raising the movable part of the frame, which is then fastened in this position and a plaster-of-Paris jacket applied, including the shoulders, which must be well padded by felt on their anterior surface. This jacket holds the dorsal spine somewhat extended,<sup>1</sup> and the shoulders back by firm pressure, and the pressure can be increased from day to day by inserting more felt between the jacket and the shoulders.




FIG. 152.—APPARATUS FOR STRETCHING ROUND SHOULDERS AND FOR THE APPLICATION OF FORCIBLE JACKETS.

Such jackets should be worn from two to four weeks, and on their removal efficient gymnastic work begun, supplemented by braces, if necessary, to hold the improved position between treatments.

*Braces.*—The use of supports to maintain the spine in a correct position is indicated—(1) in the case of children with lax muscles who are unable to hold an erect position between gymnastic treatments; (2) after forcible correction to retain what has been gained, and (3) in resistant cases which are being stretched but which cannot maintain

<sup>1</sup> R. W. Lovett: "Amer. Jour. of Orth. Sur.," ii, 2, 200.



between stretchings the improvement secured by each one. In all of these the brace is to be regarded as a temporary measure supplementary to the other treatment, whether gymnastic or mobilizing, and to be given up as soon as it can be dispensed with. As the sole treatment of resistant round shoulders the use of a brace, which by its correc-

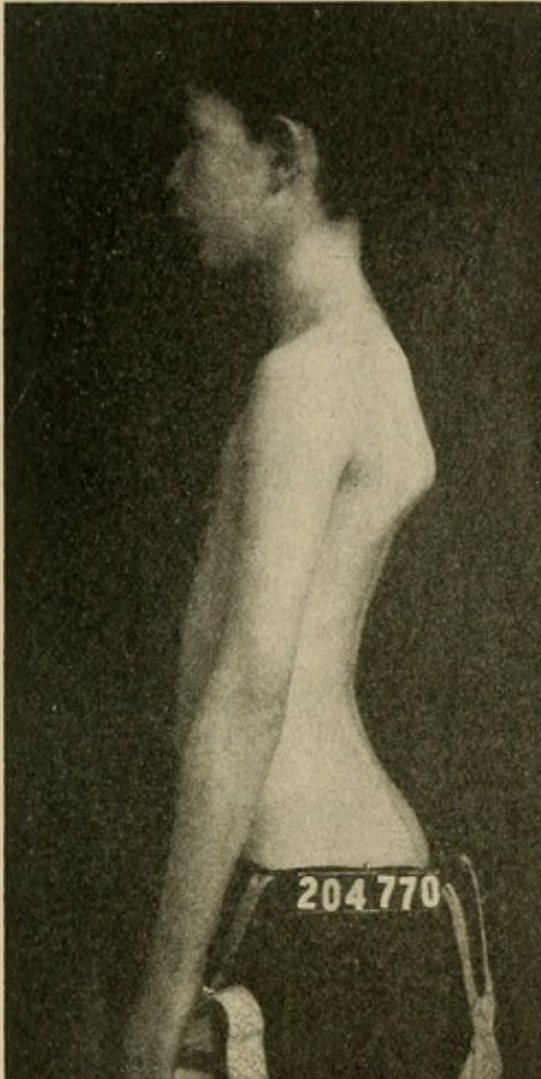


FIG. 153.—ROUND SHOULDERS BEFORE FORCIBLE CORRECTION.

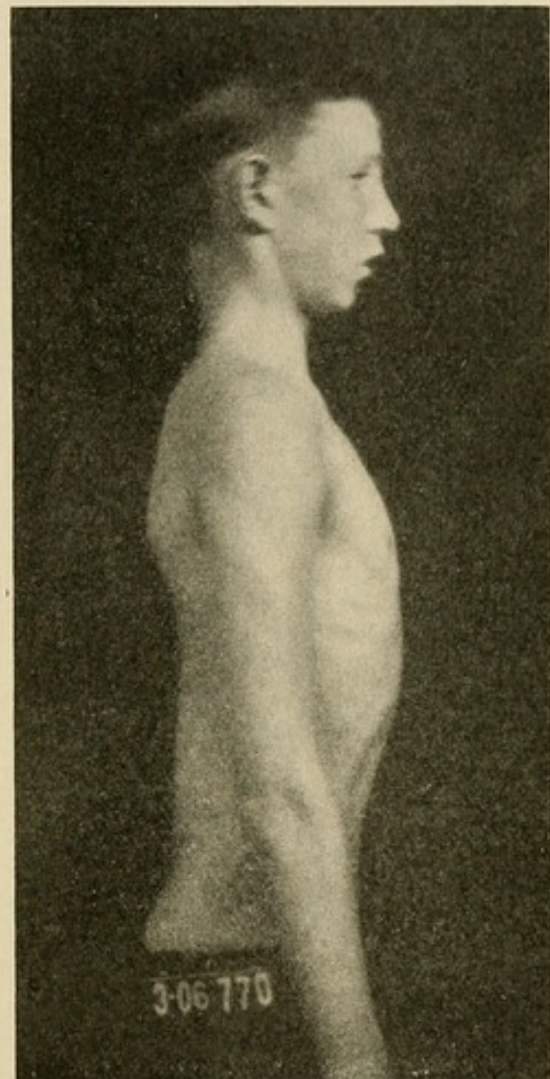


FIG. 154.—ROUND SHOULDERS AFTER TREATMENT FOLLOWING FORCIBLE CORRECTION.

tive effect is to cure the malposition, is not to be advised. The use of modified suspenders, known as "shoulder braces," as sold in the instrument shops, is not satisfactory. The brace which, on the whole, is the most generally effective is the tempered steel upright support. It is made as follows:

This form of apparatus consists of (a) a horizontal pelvic band, (b) two up-rights, and (c) a cross-bar.



*a.* The horizontal pelvic band encircles the posterior part of the pelvis from a point one inch posterior to the anterior superior spine on one side to a similar point on the other side. It is curved to fit the contour of the pelvis and should lie close against it. It is made of No. 15 gauge sheet steel, one and one-eighth inches wide. The uprights run from the posterior pelvic band along the sides of the spine to a point about on a level with the acromion process. At this point they are curved outward on the flat on an angular turn at an angle of forty-five degrees or more, and run upward and outward to a point just behind the anterior border of the trapezius. In their upper part they are curved to fit the contour of the shoulders and should lie flat against the skin when the axillary straps are tightened.

*b.* The uprights at their lower part are farther from each other than they are at the top. At the bottom their outer edges should be separated by a distance somewhat less than the distance between the two posterior superior spines. At the top they should lie over the transverse processes. They are made of No. 16 gage sheet steel, five-eighths of an inch wide, and should follow the outline of the back in general, but whatever correction is desired in the standing position is to be made by bending the uprights to fit the curve of the back in a corrected position rather than in the faulty position.

*c.* The cross-bar consists of a piece of steel, which in length should be one inch less on each side than the breadth of the body at the level where it is placed. It is riveted transversely to the uprights at a point just below the posterior fold of the axilla. The projecting ends beyond the bars should not rest on the scapulæ, but, if necessary, should be set backward by an angular curve to clear the scapulæ. These are made of the same material as the uprights.

Holes are drilled for buckles at each anterior end of the pelvic band, at the top of the uprights, and at the ends of the cross-bar. Buckles are placed on the ends of the pelvic band, and the cross-bar and axillary straps are riveted to the upper ends of the uprights, one on each side. The brace is finished by being covered with leather sewed down the back throughout, or by being nickel-plated and having its anterior surface only covered with padded leather strips slightly wider than the metal parts of the brace. These are attached to the brace by loops running around the uprights, pelvic band, and the cross-bar. The brace is attached to the body at the top by means of axillary straps and below by means of a broad belt of sheep-skin or surcingle cloth, which connects the anterior ends of the pelvic band by passing over the lower part of the abdomen. In cases in which there is much prominence of the abdomen, it is desirable to add an abdominal band, from four to six inches wide, running from one upright around the abdomen to the other upright.

Such a brace is worn continuously between exercise periods but not during the night.

A brace used by the writer in cases where forward displacement of the shoulders is a factor consists of two parts—(*a*) an anterior chest piece; (*b*) two triangular steel plates to be used posteriorly, one on each side. (*a*) The chest piece consists of two slightly oval pads of sheet steel about the size of a silver dollar, which fit over the anterior surfaces



of the shoulder-joints and are connected by a flat iron strip of the proper length, curved so as not to touch the chest. Each pad is provided with a vertical piece of steel about three inches long, on the top and bottom of which is a buckle. (b) Two triangular flat steel plates, about half the size of the scapula of the child, are made of sheet steel and provided each with three buckles. One of these lies over each scapula. The front piece holds the shoulders back, and each end is secured to the triangular plate on that side behind by one strap passing over the shoulder and one through the axilla. The front piece being fastened to each of the triangular plates, the latter are brought together by a webbing strap connecting them until an efficient pull is secured. A webbing support which is of use in the slighter cases has been described by Goldthwait.<sup>1</sup>

"Occasionally, when the stoop shoulder is marked, some additional support may be necessary, and with many of the cases it has been possible to accomplish the result by using a brace made of firm webbing one inch wide, carried as a loop around each shoulder, the ends crossing in the back, and being attached to the belt of an ordinary stocking supporter. The attachment of the shoulder strap to the belt should be at the side, directly over the stocking straps, and the belt should be worn about the hips, and not about the waist, as they are ordinarily used. The straps should be sewed where they cross at the back, over the angles of the scapulæ, but should not be sewed where they cross in the midline. This allows all the body movements, both side and forward bendings, without straining upon the straps or changing the position of the belt, the level of the belt not being changed in the movement.


"It is at once apparent that with such a brace the pull occasioned by the stocking supporters, which is a very appreciable force, tends constantly to draw the shoulders backward; and, while so simple a brace cannot be expected to take the place of the many forms of apparatus which are used to correct round shoulders, it has, nevertheless, been of real value in many cases."

*Summary of the Treatment of Round Shoulders.*—Flexible cases are treated by gymnastics like postural scoliosis; a brace may be necessary to maintain a correct position between treatments.

Resistant cases must first be made flexible—(a) by gymnastics; (b) by manual stretching; (c) by stretching in apparatus; (d) by forcible correction, after which the problem is to maintain the improved position, just as in cases originally flexible.

<sup>1</sup> "Am. Jour. Orth. Surg.," i, 64.







# INDEX.

- |  |   |
|--|---|
| <p style="text-align: center;">A.</p> <p>Acquired scoliosis, 94<br/>         Age in scoliosis, 110<br/>         Asymmetrical exercises, 137<br/>         Asymmetry of the pelvis, 95<br/>         Attitude, 167<br/>             faulty, 167<br/>             normal, 167</p> <p style="text-align: center;">B.</p> <p>Balance of spine, 39<br/>         Braces and corsets, 163</p> <p style="text-align: center;">C.</p> <p>Cervico-dorsal scoliosis, 60<br/>         Compound curves, 61<br/>         Congenital scoliosis, 92<br/>         Creeping exercises, 142</p> <p style="text-align: center;">D.</p> <p>Diagnosis of scoliosis, 113<br/>         Dorsal scoliosis, 58<br/>         Dorso-lumbar scoliosis, 59</p> <p style="text-align: center;">E.</p> <p>Elasticity of spine, 38<br/>         Errors in vision, 97<br/>         Etiology, 91<br/>         Examination for scoliosis, 64<br/>         Exercises, asymmetrical, 137<br/>             creeping, 142<br/>             symmetrical, 127</p> <p style="text-align: center;">F.</p> <p>Faulty attitude, 167<br/>         Forcible correction, 148<br/>         Forward displacement of the shoulders, 177<br/>         Frequency of different forms, 111<br/>         Functional scoliosis, 48</p> <p style="text-align: center;">G.</p> <p>Gymnastics, 120</p> | <p style="text-align: center;">H.</p> <p>Habit scoliosis, 101</p> <p style="text-align: center;">I.</p> <p>Intervertebral discs, 3</p> <p style="text-align: center;">J.</p> <p>Joint disease as a cause of scoliosis, 98</p> <p style="text-align: center;">L.</p> <p>Ligaments of the spine, 5<br/>         Lumbar scoliosis, 56</p> <p style="text-align: center;">M.</p> <p>Mechanism of scoliosis, 38<br/>         Movements of the spine, 23<br/>         Muscles of the spine, 9</p> <p style="text-align: center;">N.</p> <p>Normal attitude, 167<br/>         Numerical variation, 19</p> <p style="text-align: center;">O.</p> <p>Occupation scoliosis, 101<br/>         Occurrence of scoliosis, 108<br/>         Operative treatment, 165</p> <p style="text-align: center;">P.</p> <p>Paralytic scoliosis, 99<br/>         Passive stretching of the spine, 144<br/>         Pathology of scoliosis, 77<br/>         Pelvic inclination, 17<br/>         Physiological curves, 14<br/>         Plaster-of-Paris jackets, 148<br/>         Plasticity of bone, 41<br/>         Postural scoliosis, 48<br/>         Prognosis of scoliosis, 116</p> <p style="text-align: center;">R.</p> <p>Rachitic scoliosis, 97<br/>         Rate of normal growth, 64</p> |
|--|---|



Record of scoliosis, 71  
 Round back, 176  
   hollow back, 177  
   shoulders, 174  
   treatment of, 180

## S.

Sacro-iliac articulation, 6  
 School conditions, influence of, 91  
   fatigue, 102  
   furniture, 103  
 Scoliosis, acquired, 94  
   age in, 110  
   cervico-dorsal, 60  
   congenital, 92  
   diagnosis of, 113  
   dorsal, 58  
   dorso-lumbar, 59  
   examination for, 64  
   functional, 48  
   habit, 101  
   joint disease as a cause of, 98  
   lumbar, 56  
   mechanism of, 38  
   occupation, 101  
   occurrence of, 108  
   paralytic, 99  
   pathology of, 77  
   postural, 48  
   prognosis of, 116  
   rachitic, 97  
   record of, 71  
   sex in, 109  
   structural, 56

Scoliosis, symptomatic, 115  
   terminology of, 47  
   transitional, 52  
   treatment of postural, 118  
     of structural, 119

Sex in scoliosis, 109

Short leg, 95

Spinal nerves, 11

Spine, balance of, 39  
   elasticity of, 38  
   ligaments of the, 5  
   movements of the, 23  
   muscles of the, 9  
   passive stretching of the, 144

Structural scoliosis, 56

Symmetrical exercises, 127

Symptomatic scoliosis, 115

Surface anatomy, 21

## T.

Terminology of scoliosis, 47

Thorax, 6

Torticollis, 95

Transitional scoliosis, 52

Treatment of postural scoliosis, 118  
   of structural scoliosis, 119

## V.

Variations in height, 38

## W.

Writing position, 106







AUG 8 1911



COUNTWAY LIBRARY OF MEDICINE

RD  
771  
S3 L94

RARE BOOKS DEPARTMENT



