

The surgical treatment of disfigurements and deformities of the face / by John B. Roberts.

Contributors

Roberts, John B. 1852-1924.
Francis A. Countway Library of Medicine

Publication/Creation

Philadelphia : Philadelphia Medical Pub. Co., 1901.

Persistent URL

<https://wellcomecollection.org/works/g92yutck>

License and attribution

This material has been provided by This material has been provided by the Francis A. Countway Library of Medicine, through the Medical Heritage Library. The original may be consulted at the Francis A. Countway Library of Medicine, Harvard Medical School. where the originals may be consulted. This work has been identified as being free of known restrictions under copyright law, including all related and neighbouring rights and is being made available under the Creative Commons, Public Domain Mark.

You can copy, modify, distribute and perform the work, even for commercial purposes, without asking permission.


**wellcome
collection**


Wellcome Collection
183 Euston Road
London NW1 2BE UK
T +44 (0)20 7611 8722
E library@wellcomecollection.org
<https://wellcomecollection.org>

DEFORMITIES OF THE FACE.

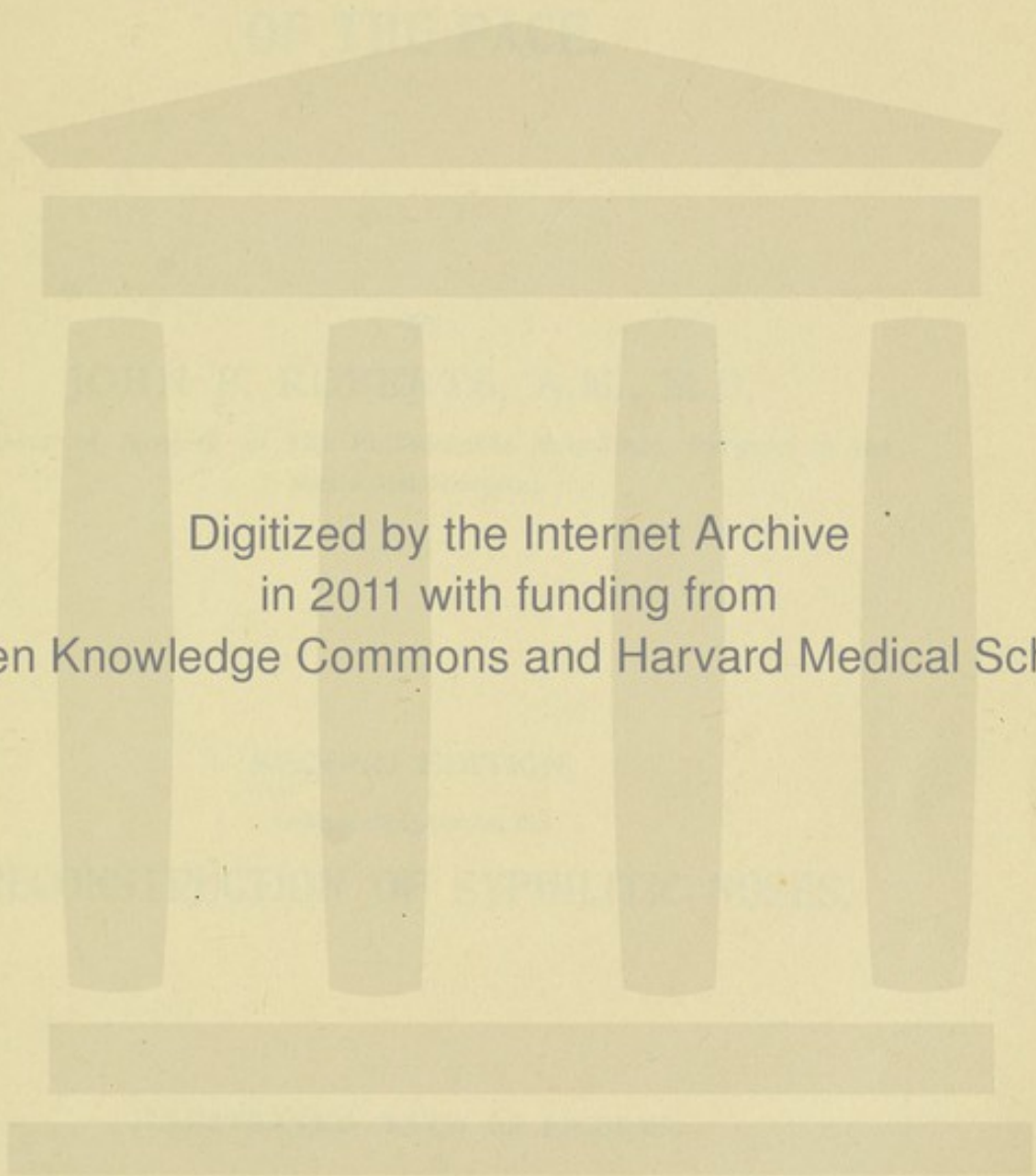
JOHN B. ROBERTS, M. D.

23. 6. 27






THE SURGICAL TREATMENT OF THE
FRODOMENTS AND DEFORMITIES
OF THE



Digitized by the Internet Archive
in 2011 with funding from
Open Knowledge Commons and Harvard Medical School



**THE SURGICAL TREATMENT OF DIS-
FIGUREMENTS AND DEFORMITIES
OF THE FACE.**

BY

JOHN B. ROBERTS, A.M., M.D,

Professor of Surgery in the Philadelphia Polyclinic, Surgeon to the
Methodist Hospital.

SECOND EDITION,

with a chapter on the

RECONSTRUCTION OF SYPHILITIC NOSES.


ILLUSTRATED WITH 62 FIGURES.

PHILADELPHIA :
THE PHILADELPHIA MEDICAL PUBLISHING CO.

1901.

THE SURGICAL TREATMENT OF DIS-
FIGUREMENTS AND DEFORMITIES
OF THE FACE

2451



Contents.

MÜTTER LECTURES.

LECTURE I.

	PAGE
A Brief Review of the Development of Reparative or Plastic Surgery . . .	1

LECTURE II.

A Rapid Survey of the Anatomy of the Human Face	5
---	---

LECTURE III.

Characteristics of Surgery in the Face.—The Principles of Plastic Surgery of the Face	12
---	----

LECTURE IV.

The Removal of Disfigurements Due to Pigments, Cicatricial Distortions, Errors of Development, Tumors and Skin Diseases	15
---	----

LECTURE V.

Deformities of the Lips and Mouth	22
---	----

LECTURE VI.

The Reconstruction of the Lips and Cheeks	27
---	----

LECTURE VII.

The Correction of Deformed Noses	35
--	----

LECTURE VIII.

The Construction of New Noses	45
---	----

LECTURE IX.

The Operative Treatment of Deformed or Deficient Ears	54
---	----

LECTURE X.

The Cosmetic Surgery of the Eyes	60
--	----

:o:

SUGGESTIONS FOR THE RECONSTRUCTION OF SYPHILITIC NOSES	66
--	----

Contents

WRITTEN LECTURES

LECTURE I

The importance of the study of the history of the English language 1

LECTURE II

A brief survey of the development of the English language 2

LECTURE III

The influence of Latin on the English language 3

LECTURE IV

The influence of French on the English language 4

LECTURE V

The influence of German on the English language 5

LECTURE VI

The influence of Italian on the English language 6

LECTURE VII

The influence of Spanish on the English language 7

LECTURE VIII

The influence of Dutch on the English language 8

LECTURE IX

The influence of Latin on the English language 9

LECTURE X

The influence of French on the English language 10

SUGGESTIONS FOR THE RECONSTRUCTION OF SYLLABIC WORKS

PREFACE TO THE SECOND EDITION.

Under the title "The Surgical Treatment of Congenital and Pathological Disfigurements of the Face," I had the honor of delivering the Mütter Lectures of the College of Physicians of Philadelphia for 1900. Abstracts of the lectures were subsequently published in a small volume; the entire edition of which has now been exhausted. The little book seemed to be of interest to professional readers, and I have accordingly had published a second edition. In this case I have changed the title somewhat; and have added, as a supplementary chapter, an article on the "Reconstruction of Syphilitic Noses," which was originally prepared for the American Medical Association. Continued study of the plastic or reconstructive surgery of the face has greatly widened for me its interest and its operative field. Other surgeons will doubtless find, as I have found, that cases, which they at first considered hopeless, are with increasing experience approached with a confident feeling of ultimate success.

J. B. R.


1627 Walnut St., Philadelphia.

November 1st, 1901.

PREFACE TO THE SECOND EDITION.

I under the title "The Surgical Treatment of Con-
genital and Pathological Displacements of the
Larynx," I had the honor of delivering the Miller Lec-
ture at the College of Physicians of Philadelphia
for 1890. Abstracts of the lectures were subse-
quently published in a small volume; the entire edi-
tion of which has now been exhausted. The book
proved to be of interest to professional read-
ers, and I have accordingly had published a second
edition. In this case I have changed the title some-
what, and have added, as a supplementary chapter,
an article on the "Resection of the Larynx."
American Medical Association. Continued study
of the habits of reconstructive surgery of the larynx
has greatly widened for me its interest and its op-
erative field. Other surgeons will doubtless find as
I have found, that cases which they at first con-
sider hopeless are with increasing experience ap-
proached with a confident feeling of ultimate suc-
cess.

J. H. K.
107 Walnut St. Philadelphia.
December 1st, 1901.



MÜTTER LECTURES.

LECTURE I.

A Brief Review of the Development of Reparative or Plastic Surgery.

It is often forgotten that, until the revival of plastic operations upon the face about the year 1800, reconstructions of lost areas of tissue and readjustments of textural relations by operation had been practically unknown to the scientific world for a couple of centuries. The operative methods of Tagliacozzi at Bologna, detailed in his book, published in 1597, and the methods employed for many centuries in India for restoring mutilations of the nose had been forgotten or disbelieved. Carpue in England and Graefe in Germany aroused surgical attention to plastic surgery in the second decade of the nineteenth century. It was rhinoplastic operations that were particularly advocated by these surgeons and their colleagues, and which gave birth to a knowledge of the physiological possibilities of reparative surgery.

About this time public attention was called to rhinoplastic operations by a number of writers on non-medical subjects. Dr. Ferriar, in his "Illustrations of Sterne with other Essays and Verses," published in 1798, said truly that Sterne, in his novel "Tristram Shandy," should have included among his allusions to the nose, taken from literature, the operations of Tagliacozzi. Ferriar says that the Italian surgeon was the more entitled to notice be-

cause his fame had been unjustly and unaccountably eclipsed. Ferriar, in his enthusiasm, describes in detail the operation of rhinoplasty and compares the physiological deductions of the Italian surgeon with those of John Hunter. Hunter had died only five years before the publication of the "Illustrations of Sterne," and his experiments on grafting tissues were evidently known to Ferriar. The latter lays much stress upon the fact that in Tagliacozzi's time the arteries were supposed to be full of air, and that the circulation of the blood was unknown to him; and that the Italian investigator's views on the method of union of living parts are exceedingly interesting and remarkably accurate. The *Gentlemen's Magazine* of 1794 and *Pennant's Views of Hindoostan*, published about the same time, give accounts of the reconstruction of noses from the forehead, performed in India to relieve the horrid facial disfigurements so common in that country. Amputation of the nose was there frequently performed as a punishment to prisoners and as retribution for supposed marital unfaithfulness.

It is curious to read at the present time the doubt felt by Hiester, Coote, and other surgical writers of more or less recent date, as to the possibility of rhinoplastic operations. This doubt of the professional mind is a little difficult to understand, when it is recollected that there was even then a considerable amount of literature showing the possibility of the adhesion of parts, entirely separated from the body, if they were reapplied and sutured within a reasonable time.

In 1823 Büniger, of Marburg, made a new nose for a woman from the tissue of her thigh. In Europe, Dieffenbach, Graefe, Blandin, Serre, Jobert and Zeis were earnest advocates of reparative surgery. In America, Warren, Mütter and Pancoast were the early advocates of plastic operations. Thomas D. Mütter, the founder of the Mütter Lectureship,

published articles on plastic surgery a very few years after his graduation in 1831. They were followed by other American surgeons, among whom may be mentioned as conspicuous operators Post, Buck, Andrews and Prince.

Szymanowski, of Russia, published in 1867 an elaborate attempt to systematize the various operative procedures for the relief of deformities requiring plastic surgery. He devoted many pages of his operative surgery to illustrations showing the principles upon which the integuments can be satisfactorily displaced. His experiments on the cadaver aided him very much in the preparation of this part of his book, which has become a classic. A decided advance was made in 1871 by Reverdin, who proposed epidermic grafting, often called skin-grafting, for covering ulcers and granulating wounds. Other steps in the progress of reparative surgery were the announcement by Thiersch, in 1886, of his method of transplanting large shavings of the upper layers of the skin. Previous to this time, however, Wolfe, of Glasgow, had shown that moderate size pieces of skin could be transplanted without a pedicle with comparative certainty of union. Krause has greatly improved the method of transplanting skin without pedicles.

Other steps in reparative surgery are the substitution of adjacent muscles for those torn away by accident or paralyzed, the transference of nerve-trunks, and similar procedures. Among the most interesting are the substitution by Czerny of a fatty tumor from the thigh for a portion of the mammary gland which had been excised for malignant tumor. Gluck has experimentally succeeded in repairing a defect of the carotid artery by patching that vessel with a piece of jugular vein. Van Lair has suggested the possibility of taking portions of organs, or possibly whole organs, at the moment of death and using them for the restoration of internal parts. The thyroid gland of the sheep has been implanted in the abdomen of man to act as a substitute for his

diseased or extirpated thyroid gland. The ovary has been transplanted successfully, from one animal to another and from one region to another of the same animal. It is said that such ovaries have carried on their function and even made pregnancy possible.

Nicoladoni has recommended, for the loss of the thumb, the grafting of a toe upon the hand. Glass balls have been introduced into the eye to represent the vitreous humor and maintain the globular shape of the organ. Celluloid and metal supports are worn within the tissues of the nose to give them a proper shape. The mental distress of despondent men has been relieved by the substitution of similar materials for extirpated testicles. This "implantation-therapy" is susceptible of far greater use than is yet realized.

LECTURE II.

A Rapid Survey of the Anatomy of the Human Face.

The frontal and temporal regions of the cranium must be included in the present study; because the disfigurements to be considered concern the ears and forehead, as well as that portion of the head usually called the face in anatomical treatises.

Good surgery of any region is impossible without a knowledge of the bony landmarks and the mutual relations of the soft parts. It is therefore necessary to spend a little time at least in describing the bones, muscles, arteries and nerves of the region, the surgery of which is to be discussed. The carotid, temporal and facial arteries must be remembered, because of the hemorrhage, which occurs from them during operations, and because the bloodsupply of flaps made in plastic operations is a matter of supreme importance. The situation of the branches of the facial nerve and the position of the duct of the parotid gland must be always in the mind of the operator, lest wounds of these important structures occur.

The upper jaw is of major importance in the construction of the face, forming, as it does, portions of the walls of the orbit, nose and mouth. Its alveolar arch must correspond with the same portion of the lower jaw, in such a way that the upper teeth may lie in front of the lower jaw when the mouth is closed. The incisive portions of the two upper jaw bones are developed by special centers of ossification. They therefore have much to do with the shape of the lower portion of the face and mouth. Harelip and cleft palate are the most conspicuous and most common congenital deformities due to improper development of this portion of the facial skeleton. Another disfigurement is that in which

the lower jaw with its teeth project in front of the upper jaw. This deformity is said to be due at times to precocious ossification of the sutures between the body of the upper jaw and its intermaxillary or incisive portion. As a result, the upper jaw and teeth do not develop in a forward direction as much as they should and the lower jaw gains an undue relative prominence. The lower segment of the face is therefore altered in an unseemly manner. Mechanical appliances to prevent this ugly alteration in the relation of the two jaws may be successfully employed in young children.

The lower jaw varies greatly in shape in different individuals and at different periods of life. The angle between ramus and body in the adult male is about 122° . It is very obtuse in infants, and more obtuse in women than in men. Changes in the angle of the mandible and in the prominence of the chin, produced by the loss of teeth and the absorption of the alveolus in old age, give the characteristic appearance of the senile face. Ankylosis of the temporo-maxillary joints preventing movement of the lower jaw will, if occurring in childhood, lead to atrophy or want of proper development. An immature chin thus results, causing conspicuous disfigurement of the individual. Burns of the lower part of the face and neck in early life often prevent proper mobility of the lower jaw and lead to a lengthening and bending downward of the bone. Persistent thumbsucking in young children after the second dentition causes deviation of the teeth and an abnormal relation of the jaw-bones.

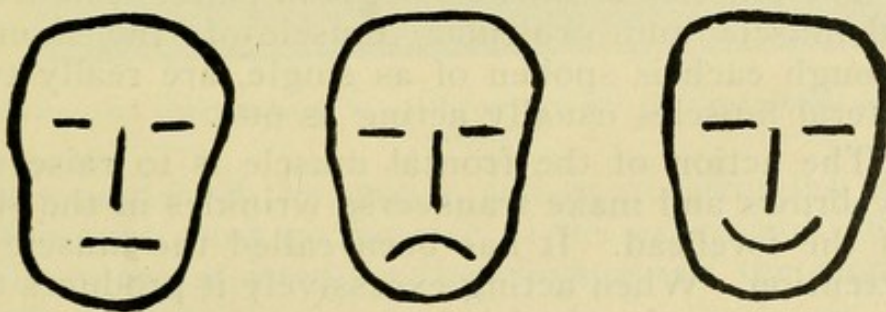
The frontal eminences are better marked in young persons and women than in adult males, because in the latter the greater development of the frontal sinuses brings the lower portion of the frontal bone forward in the neighborhood of the superciliary ridges. The frontal sinus begins to develop at about seven years of age.

A study of the facial angle and its measurement

by the goniometer of Camper are interesting to anatomists and surgeons as well as to artists.

The face of the infant is small in comparison with the rest of the head. The cranium of the baby is five or six times as large as the face. The development, as the infant grows, of the superciliary arches and frontal sinuses makes the frontal eminences less conspicuous, and the forehead therefore assumes a more receding character. The face at first is short in comparison with its breadth and lacks the prominence of the adult face. This is largely due to the absence of teeth. The growth of the jaws, which occurs when the teeth have erupted, changes the lower portion of the face into that of the adult.

The appearance of the human face has varying characteristics in different races of men and in different individuals of the same race. A protruding face is called prognathous; the nonprotruding face, orthognathous; and a broad face eurygnathous. The Caucasian face is orthognathous and often prominent mesially and centrally, while the African and Mongolian races have prognathous faces. The Mongolians have faces which are broad and centrally depressed as well as prognathous.



Crude diagram showing difference in expression caused by change in shape of mouth.

The muscular structures of the face differ from the muscles of the extremities in that one end of many of the muscles is inserted into the skin, which is movable and drawn into folds and wrinkles at right angles to the direction of the muscular pull.

In subjects whose skin is thin and flexible muscular contraction causes many and delicate wrinkles. When the skin is thick and stiff by nature or as the result of disease, a slight action of the muscles of expression will produce no visible wrinkling. More active contraction will cause few and thick wrinkles. Under the latter circumstances delicate shades, and variety and beauty, of facial expression are absent.

There are two main muscular landmarks on the front of the face. One about the two eyes and one around the mouth. They are in a certain sense sphincter muscles, closing the eyelids and the opening of the mouth. The orbicular muscle of the mouth has its fixed attachments in the middle line above and below, but the orbicular muscles of the eyelids have their fixed points at the outer and inner ends. Many of the muscles of expression are inserted into or blend with the fibers of the orbicular muscle of the mouth, and by acting upon it make great changes in the expression of the face.

The mobility of the lips, the bulk of which is chiefly the orbicular muscle, gives expression to the face to a much greater extent than any muscular movement about the eyelids and forehead.

The muscles of the face occur in pairs. The frontal muscle and orbicular muscle of the mouth, though each is spoken of as single, are really two lateral muscles usually acting as one.

The action of the frontal muscle is to raise the eyebrows and make transverse wrinkles in the skin of the forehead. It has been called the muscle of attention. When acting excessively it produces the appearance of astonishment.

The corrugator muscles of the eyebrows pull the eyebrows inward and downward near their nasal ends, making vertical wrinkles between the eyebrows above the root of the nose. This expresses frowning, as shown in mental and physical suffering. The greater zygomatic muscles draw upward




Action of corrugators of eyebrow shown in expression of suffering.

the angles of the mouth and cause wrinkles under the eyes, thus giving rise to the expression of joy. They are assisted by the elevators of the angle of the mouth.

A well-marked furrow in the face is the nasolabial line extending downward and outward from the wing of the nose to a point external to the angle of the mouth. It is seen in all faces, especially in the aged. The nasolabial line changes its shape with the action of various muscles of emotion. It is important to the surgeon, because incisions made

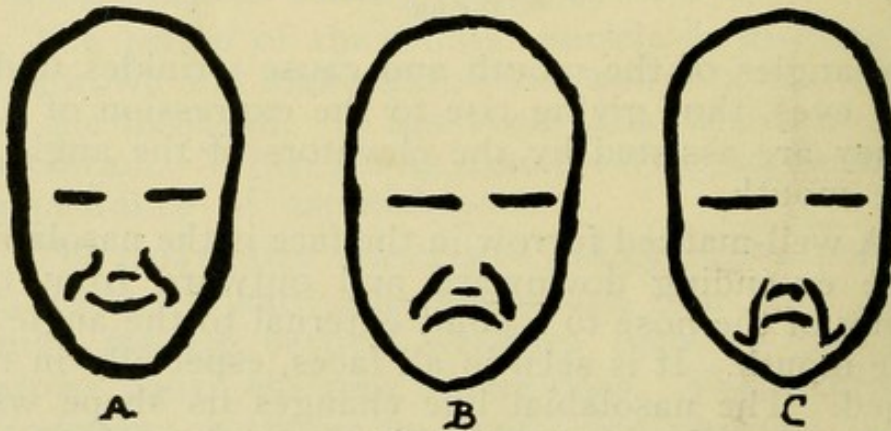
along its groove show little scar. In laughter the nasolabial line assumes a double curve like the old italic S. In pain it is straight; in grief, convex out-



The nasolabial line and the transverse furrows of the forehead are well shown in this photograph.

ward. In contempt it is drawn in at the lower end and extended around the angle of the mouth.

Other emotions are shown by similar actions and combinations of action of the small muscles of the face, which are inserted into the skin or into the muscular mass of the lips.



Crude diagrams showing change of expression caused by alterations in the nasolabial lines.

In true emotions the muscles of the various portions of the face act in consonance involuntarily and produce expressions which seem to us natural. We can, however, by distinct voluntary effort bring dissociated muscles into action, and thereby produce a grimace. It is interesting to observe how the anatomic situation and nervous supply of muscles indicate what emotions can occur together. This anatomic basis of expression corresponds exactly with the psychic relations of the phenomena. It is impossible, for example, to give attention to external objects and to be at the same time in a state of meditation. The impossibility of such a mental contradiction is anatomically shown in the fact that the frontal muscle cannot carry the eyebrow upward to indicate attention while the orbicular muscle of the eyelids is pulling it down to indicate meditation.

LECTURE III.

Characteristics of Surgery in the Face.—The Principles of Plastic Surgery of the Face.

The skin of the face is thin, elastic, and very vascular. Its vascularity and elasticity render it suitable for plastic procedures. Incision should be made in positions where there is usually a shadow, as under the eyebrow or beneath the lower jaw, or in the bottom of the furrows produced by the habitual expressions of the patient. When these positions cannot be chosen the surgeon's cut should be made parallel to the facial lines rather than across them. A slightly curved line makes a less conspicuous scar than a straight or abruptly curved one. Accurate apposition should be made by means of sutures. Oblique incisions through the skin permit more accurate apposition than those dividing the skin in a plane at right angles to the surface. The intracutaneous suture is sometimes valuable; but is not necessary, if fine silk is employed and the wound kept aseptic. Formaldehyd catgut may be used instead of silk, because it may be thin without being absorbable as soon as the ordinary catgut suture. The infrequency of valves in the veins of the face is said to be the cause of the rapid spread of septic inflammations in this region. Wounds should therefore be kept free from contamination. The bones of the face have a good blood-supply, and many of them are comparatively soft. They may be utilized for plastic operations without much danger of necrosis.

Portions of the nose, ear or lip, which have been cut off, should be readjusted and sutured in position, for there is a fair prospect of immediate union of such parts accidentally separated from the face.

It is better as a rule to keep the wounds dry. They may be covered with a small piece of aseptic gauze, or an aseptic scab may be formed by dusting a little boric acid powder over the wounds and allowing it to form a crust with the serum.

Incisions in the cheek should, when possible, avoid perforating the mucous membrane. This prevents infection from the bacteria within the mouth. Drainage, when necessary, should be into the mouth and not upon the surface of the face. The duct of the parotid gland must be avoided. If it is cut, the proximal end should be carried into the mouth through a properly placed incision. This avoids the occurrence of external fistula.

Plastic surgery is called into requisition to correct congenital malformations, and to relieve deformities, the result of injury or disease. Plastic surgery may also have for its object the curtailing of abnormally large organs, such as noses, ears and lips.

Displacement of skin by stretching or sliding, transferring a flap with a pedicle, and transplanting portions of tissue from the face or other regions, without pedicles, are the chief methods employed. Occasionally the flap to be used for repairing a gap is not put into position until inflammatory changes have increased its vascularity and thickness.

Plastic surgery should not be done upon a patient in poor health nor when septic contamination is particularly likely to occur. Syphilitic processes should be stopped by treatment before the deformities caused by them are corrected by operation.

A series of operations may be necessary to obtain the best cosmetic result. A bulky resemblance to the organ to be constructed is made first. Subsequent improvement is then obtained by minor operations, with sufficient intervals between them to permit the absorption of inflammatory exudate and subsequent cicatricial shrinking.

Flaps may be jumped across a bridge of skin, or turned upside down and then skin-grafted upon the raw surface, or one flap may be put upon the top of another to raise depressed portions of the face. Flaps containing periosteum and bone are sometimes used. Skin flaps should contain a good deal of subcutaneous tissue, and should have a wide pedicle when possible. The flaps should be about one-third larger than the space to be covered.

In transplanting portions of skin without pedicles the best results are usually obtained by removing the subcutaneous fatty tissue, and keeping the wound absolutely dry and free from antiseptic solutions. Asepsis, not antisepsis, is an essential here.

If gangrene occurs it is wise not to remove hastily the tissue which seems to have lost its vitality. Very often only the surface or the edges will actually die, and a much better result will be obtained than the surgeon expected when he saw the tissue beginning to slough.

LECTURE IV.

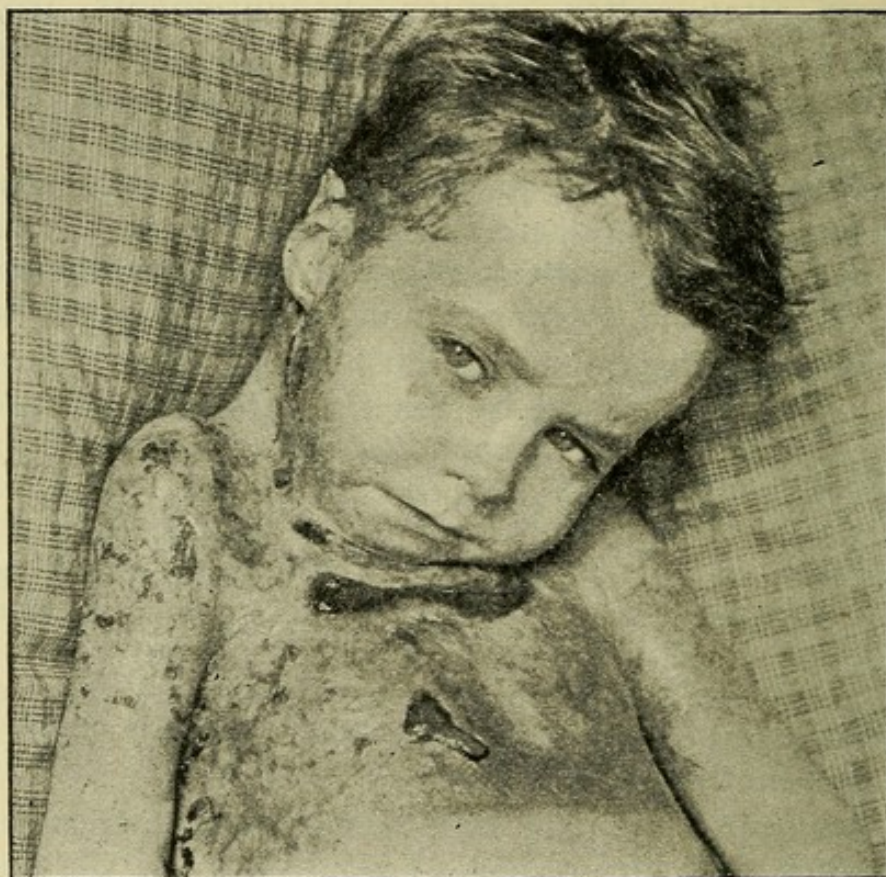The Removal of Disfigurements Due to Pigments, Cicatricial Distortions, Errors of Development, Tumors and Skin Diseases.

Unburnt powder imbedded in the skin and subcutaneous tissue and intentional tattooing with black pigments cause blue stains in the skin. Coal miners often suffer similar disfigurements from wounds being soiled with coal dust. Wounds soiled with gunpowder or coal dust must be at once thoroughly scrubbed with soap and hot water and a brush, to remove the particles of carbon. Anesthesia, local or general, may be needed for such treatment. Washing with solution of hydrogen dioxide may remove the powder grains. When the skin has healed over the imbedded carbon, the discoloration can only be removed by excising the stained area or tediously removing each particle. Croton oil has been picked into the skin to cause suppuration and extrusion of the black particles. Combustive destruction of the carbon by introducing a red hot galvanocaustic needle has been proposed. Dermatologists employ chemical means to remove intentional tattooing. The discolorations due to accidental wounds are probably too deep for success by this method.

Glycerole of papain has been picked deeply into the skin with the object of removing the pigment after tattooing. Another method sometimes employed is to pick into the skin a solution of tannic acid. A stick of silver nitrate is then firmly rubbed over the punctured area. Silver tannate is formed where the tannin has been picked into the skin. Scabs form and, on removing the scabs in about two weeks, the operator finds that the pigmentary stain is gone.

Cicatricial distortions, unimportant in other regions, are unsightly upon the face. Operations producing distorted scars should be avoided, if possible. Syphilitic ulcers should be treated early and vigorously. Abscesses may be opened on the mucous surface of the cheek. Tuberculous glands may be removed or drained before they, by spontaneous opening, cause ugly scars.

Tumors should be excised by incisions so placed as to prevent cicatricial distortion of the eyelids,



Case of disfigurement from burns. Improved by incising scar-tissue under chin and taking two long flaps from back, which were brought around the front of the neck like a cravat.

mouth or nose. Plastic operations to fill the gap left by removal of the tumor will often be necessary.

Burns make extensive and horrid deformities of the face. Keloid degeneration of scars is a cause


of disfigurement in many scars otherwise unimportant. The disease occurs more frequently in the black race than in the white. It may attack leech bites, acne pustules, smallpox scars and even fly blisters, as well as ordinary wounds. The keloid growth may return after excision. It is a disease of youth and adolescence, and usually disappears spontaneously before middle life. Extract of thyroid gland internally and local applications of colloidion have been used by White in hypertrophy of scar tissue resembling keloid disease. Excision, if employed, should be made at a considerable distance from the boundaries of the keloid mass.

The unsightliness of depressed or irregular scars may be lessened by excision and by transference or transplantation of skin. Moderately depressed scars may be treated by rubbing the skin with finely powdered calcium carbonate. This attrition removes or prevents the epithelial accumulation along the edges, which makes the depression more conspicuous. The pits of smallpox may be thus treated with some success. Elevated scars may sometimes be made less prominent by massage combined with inunctions of *adeps lanæ*. The white spots of vitiligo may be made less conspicuous by removing the excess of pigment which usually appears at the margin of the white spots. This is to be done by applications similar to those used in the removal of freckles. Corrosive sublimate, three or five grains to the ounce, is a good application.

Congenital fistules and fissures occur from imperfect closure of the branchial clefts. They are usually best treated by excision. Fistules due to suppurative disease of the accessory sinuses of the nose are difficult to close because of the difficulty of thoroughly sterilizing the mucous-lined cavities from which they arise. Drainage and disinfection are important parts of the treatment.

Meningocele and encephalocele cause tumors upon the face which should be treated by aseptic

excision. Deficiency and atrophy of the bones of the face are curious conditions due to irregularities

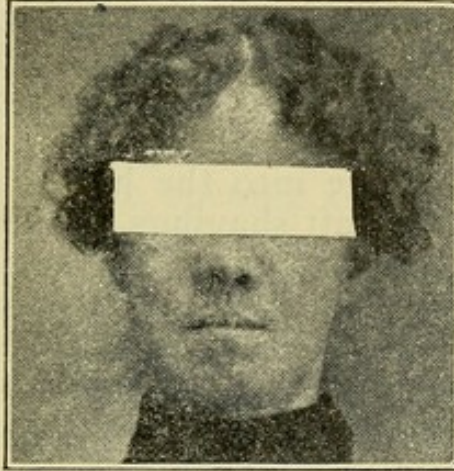

Case of hemiatrophy of the face, with small abscess communicating with one of the accessory sinuses of the nose on the same side as the atrophy.

in development and nutrition. Osteoplastic operations may under some circumstances be valuable. Prosthetic appliances of wax, papier maché or celluloid are occasionally of service in concealing excessive deformity due to these causes.

Facial hemiatrophy is another disfiguring condition due to a trophoneurosis occurring not only in children, but also in adults. Hypertrophy of the bones of the face occurs, giving a leonine appearance to the patient. The bulky bone may be reduced by chiseling operations.

Many skin diseases are very disfiguring when occurring upon the face. A large number of them are

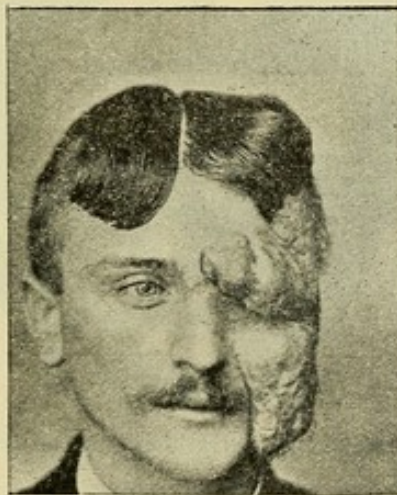


Hypertrophy or Leontiasis of the Jaws.

readily removed by judicious treatment directed to the general health of the patient and accompanied by proper local remedies to alter the nutrition of the skin.

Comedo, sebaceous cyst, and various forms of acne are characteristic dermal affections, which need a combination of general and local treatment. Surgical management is sometimes required.

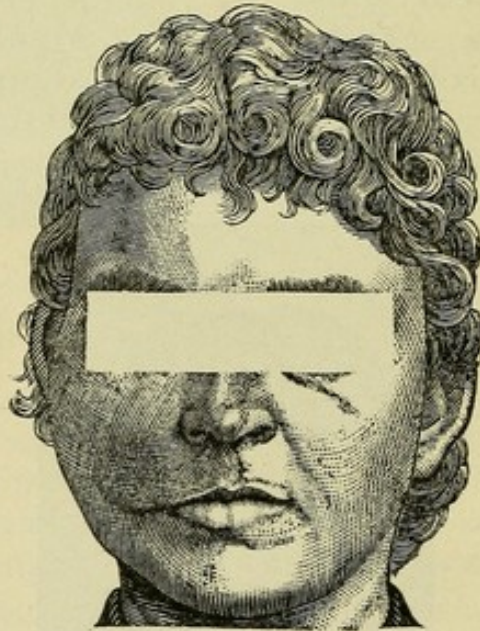Warts, horns and moles are occasionally allowed



Case of dermatolysis treated successfully by excision followed by application of flaps from the arm, neck and forehead and by skin-grafting.

to become a source of great perturbation to the patient's mind, and need mechanical treatment. Congenital moles are often large, pigmented and hairy. Such growths require extensive surgical operations for their removal. Hairy growths are best removed by electrolysis. The method is a slow one; but is effectual, if the electrolytic needle at the negative pole is inserted with care into the hair-follicles. It has been proposed to graft shavings of skin, taken after the method of Thiersch, upon the surface left after shaving off the pigmented tissue which forms the bulk of the mole. It is said that grafts of skin containing hair may be transplanted, when a portion of the face normally covered with hair is to be repaired.

Vascular tumors and discolorations may be treated by extirpation with a knife and in some cases by electrolysis. When possible, excision is most expeditious and radical. If well done, it leaves little scar to cause disfigurement.



Subcutaneous angioma of right cheek treated by excision.

A circumscribed hypertrophy of the skin, called dermatolysis, in which soft masses of thickened integument hang in loose folds over the face, is of oc-

casional occurrence in the face. It is to be treated by excision, skin-grafting and the transference of cutaneous flaps.

Lupus, which is a cutaneous tuberculosis, causes great ravages to the skin. It produces ectropion of the eyelids and lips, a shrunken, beak-like nose or even complete destruction of the external nose, contraction of the opening of the mouth, and distortion of the lips and ears. The disease should be removed by dissection and covering the space with skin-shavings, by scraping the diseased structures away with the curet, or by using strong caustics. The use of tuberculin was supposed to be beneficial. A more prolonged experience with the remedy has, however, not proved its claims to be wholly substantiated.

LECTURE V.

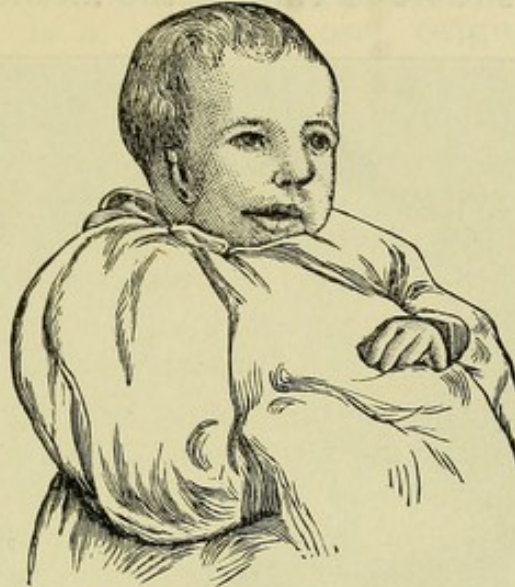Deformities of the Lips and Mouth.

The chief congenital deformity of the mouth is harelip, which with its complications gives ample opportunity for the exercise of constructive skill. Other congenital defects are atresia oris, macrostoma, microstoma, cleft of the lower lip, hypertrophy of the lips, and excessive eversion of the lower lip. Distortion of the mouth and lips and deficiencies of the lips and cheeks occur as the result of sloughing and injuries.

The treatment of congenital occlusion of the mouth and of cicatricial contraction consists, in the former case, in dividing the occluding membrane and preventing readhesion of the lips, and, in the latter case, in making horizontal incisions outward from the orifice representing the mouth. The mucous membrane must be sutured into the end of the incision to prevent reunion of the edges of the wound. Occasionally a V-shaped piece of cheek must be removed with the point of the V extending outwards.

Imperfect closure of the branchial clefts may cause a congenital horizontal fissure at one or both sides of the mouth, extending outward into the cheek and causing the condition termed macrostoma. This deformity is treated by freshening the edges and applying sutures. Similar deficiencies in closure of fetal structures cause fissures in the upper lip, termed harelip, and occasionally in the lower lip. In rare instances these fissures may extend up as far as the orbit or down to the sternum. Sometimes a mere cicatricial line is seen in the child's lip, as though an intrauterine cure of such a fissure had taken place. The treatment of all these

fissures is based on the same general operative procedure as that just described for macrostoma.

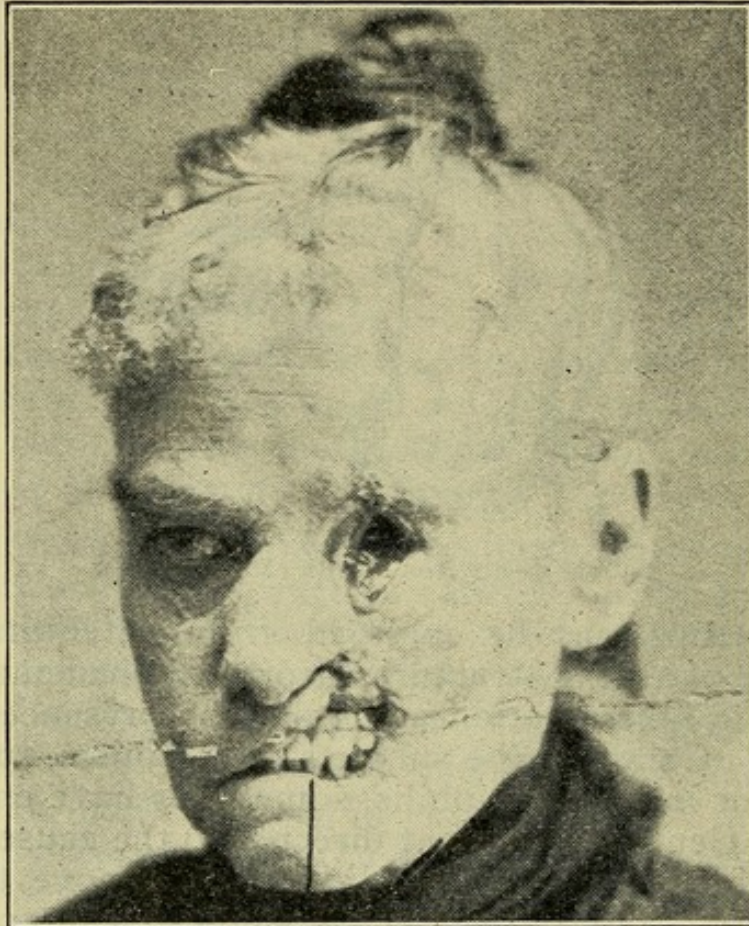


Lateral fissure from mouth (Macrostoma).

The lips may be enlarged from interstitial increase of all the structures, from lymphedema, from chronic inflammation and from the presence of tumors. Children, the subjects of cretinism, tuberculosis or inherited syphilis, sometimes have enlarged lips. General treatment directed to the cause of the trouble will usually ameliorate or remove the deformity. Thyroid extract is suggested in cretinoid cases. A hypertrophied lower lip may be altered by excision of a V-shaped piece in the middle line with the apex of the V near the chin. This lessens the width of the lip. Its thickness may require a second operation to remove a wedge of tissue by incisions running across the free border of the lip. Eversion of the lips, giving rise to what is sometimes called double lip, is to be treated by excision of a section of the lip by means of transverse incisions along the mucous surface.

Eversion of the lip, due to burns of the chin and neck, must be corrected by sliding upward a V-shaped flap from the throat or chest, transferring a flap with a pedicle from the side of the neck, or

transplanting a piece of skin without a pedicle from some other part of the body. Occasionally it will be found desirable to employ the method of Taglia-



Scarring the result of burns. Incisions to reconstruct lower lip marked with ink. Great improvement made in face by a series of operations.

cozzi and use the arm for supplying the flap. I have recently, in a case of everted lip from burn, in which there was also a cicatricial deformity of the hand, used the hand for carrying a portion of the abdominal skin to the chin. This was done by first suturing a flap of skin from the abdomen to the back of the hand where the cicatrix had been freed by incisions. After adhesion had taken place, the flap was cut loose from the belly and the hand applied to the face, so that a portion of the abdominal skin could be sutured to the raw surface made upon the chin, by dissecting loose the scar-tissue in the lower lip.

Gypsum bandages held the arm in position until the graft had become attached, when the hand was cut loose. This method of using the hand for transferring tissue is a valuable one, originally suggested, I believe, by Shrady.

When the cheek is distorted by operation or by injury, a U-shaped flap may be turned up from the neck and thrust through a buttonhole incision made along the lower margin of the jaw, so that the skin-surface is turned toward the teeth. This operation is only satisfactory when there is not much beard upon the skin turned inward.

Deformities of the lower part of the face arise after excision of the mandible for necrosis or tumor, because the muscles displace the portion of the lower jaw which is retained. This displacement may be largely prevented; by having a dentist cap the teeth and anchor the fragment of the lower jaw to the teeth of the upper jaw; or in some similar manner arrange a spring within the month, to hold the normal portion of the jaw in proper position. An artificial appliance may subsequently be made to represent the removed bone, and a vulcanite cheek-plumper may be adapted to fill out the collapsed cheek.

The obliquity of the mouth due to facial paralysis may be improved by excising an elliptical portion of tissue from the cheek. Dental irregularities and malformations and discolored teeth require the skilful work of a trained dentist. This branch of surgery has been greatly developed in recent years. Contracted jaws, irregular eruption of teeth, and abnormal relation in the projection of the upper and lower jaws may be corrected, if proper appliances are adopted.

Much harm is done by the erroneous extraction of teeth, in the endeavor to make room for the eruption of other teeth. The canines should seldom if ever be extracted for this purpose, because they have much to do with the shape of the face. Care-

ful study of the physiology of dentition is required before deciding which is the proper tooth to extract. Prominence of the lower jaw, causing prognathism, may be greatly improved by a net cap worn at night with proper rubber bands attached to a pad pressing against the jaw. A change in the bite, or articulation of the teeth, may often be made; and by this means the improper relation between the upper and lower jaw may be gradually corrected. The success of such corrective measures is greater and more promptly obtained in adolescents than in adults. It is probable that between the ages of 12 and 20 is the best period; but even up to 30 years of age much can be done by patient, judicious mechanical treatment.

Where the lower jaw is greatly deformed by dragging down of the lower lip from cicatricial contraction, a section removed from both sides of the jaw may enable the surgeon to bring the chin and the lower teeth into proper relation to the rest of the face. These cases require careful study and aseptic operative treatment.

I have at the present time under consideration a case of relatively retracted chin; on which it is possible I may operate to bring forward the chin, by detachment and displacement of the mental tubercle and the grafting of bone taken from the tibia.

LECTURE VI.

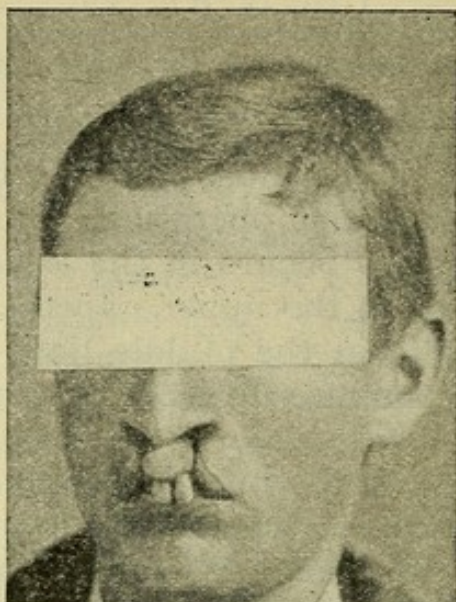
The Reconstruction of the Lips and Cheeks.

Congenital fissure of the upper lip, usually called harelip, is one of the most common deformities requiring reconstructive operations about the mouth. Labial fissure also occurs in the lower lip, but not as commonly as in the upper. In the lower lip, the fissure is usually in the middle line. In the upper lip, it is more common to have it at one side of the middle line. These deformities are due to imperfect coalescence of the branchial arches during fetal life. Reconstructive operations are also required after removal of malignant tumors of the lips and cheeks, and to overcome deformities the result of cicatricial contraction, particularly from burns of the face.

Harelip may be unilateral or bilateral. It may be complicated with cleft of the alveolar process of the jaw, cleft of the entire palate, or with the protrusion of the entire intermaxillary bone. The intermaxillary bone is sometimes displaced and attached, as it were, to the point of the nose, giving the child a snout-like deformity of the upper lip and nose.

The various forms of labial fissure are treated by freshening the edges of the cleft, replacing protruding portions of the intermaxillary bone, and suturing the soft parts alone, or the soft parts and the replaced bony tissues. The operation should, as a rule, be done before the third month of the child's life, unless the child is sickly or the operation is going to be a bloody one because of the complicated nature of the case. An early closure of the lip seems to aid in causing a tendency for an accompanying

palatal fissure to become less, as the child grows up. Anesthesia should always be employed. To operate without anesthesia is a cruel practice.



Double harelip, with protrusion of intermaxillary bone, which was greatly improved by operation.

Complicated harelips may be left until about the second year, if the child's health is bad or the danger of hemorrhage producing ill effects great. The methods of bringing the parts into apposition vary greatly with different operators, but the principles are simple enough. The edge of the cleft should be pared in such a way as to give a broad surface of contact, and to make that side of the lip, which is the shorter, long enough to make the lip have the proper shape. To prevent the formation of a notch at the vermilion border, the incisions should be so placed as to give plenty of tissue at the free margin of the lip. Suturing should be done so carefully that the mucous membrane does not show upon one side at a higher point than the other.

The length of the lip from the nose to the orifice of the mouth should be made sufficiently great. Surgeons often neglect this important point. The flattened nostril should be altered by changing the position of the wing of the nose. This can often be

done by an incision outside of the wing of the nose in the curve between it and the cheek. It may be necessary to saw the alveolar process and bring a portion of that bony structure toward the middle line, in order to make a floor for the wing of the nose to rest upon. This is easily done before closure of the lip.

Trusses to press the cheek inward toward the middle line, metal supports to the lip, harelip pins and similar devices are to be discarded. Properly placed incisions with sutures of silk, silkwormgut or formaldehyde catgut are all that is necessary.

The intermaxillary bone, if thrust forward, should be bent backward, after fracturing the cartilage and bone, or excised. It is sometimes necessary to cut out a V-shaped portion of the septum of the nose before pushing backward the projecting intermaxillary bone. The soft tissues over the intermaxillary bone may be used to construct the columella of the nose or to aid in making the central portion of the lip. Care should be taken to make the columella come a little lower down than the alae.

Very little dressing is required after the operation. Gauze and collodion, dry gauze, or a little boric acid powder may be used. Adhesive strips are a disadvantage because they are liable to lead to septic contamination.

It is occasionally necessary to make long incisions outwards into the cheeks to get sufficient tissue to displace towards the middle line. In cases in which there has been very little tissue to repair a double harelip, the patient has, even after a well-performed operation, a very taut and drawn upper lip, which contrasts badly with the full and prominent lower lip. A V-shaped portion of the lower lip should then be removed, in order to make the balance between the two lips more nearly like that in a normal patient.

It is sometimes necessary in harelip cases to in-

prove the appearance of the lip by minor operations after the child grows up to adolescent life.

Reconstructions of the lower lip are necessary at times, even if it is impossible to restore the expression and beauty of the mouth in anything like a perfect manner. The operation is desirable because it will prevent the escape of saliva and mucus, improve speech, enable the patient to keep the tongue within the mouth, permit drinking and taking of food, and lessen the interference with digestion which is apt to result from imperfect mastication and insalivation. Even if the expression of the face, after the lips and cheeks have been restored, is imperfect; and even if the newly constructed part is absolutely immobile, the operation makes the patient less ugly and makes him more willing to mix in the society of his fellows.

It is difficult to give definite directions for cheiloplastic procedures, because the surgeon must be governed by the peculiarities of the case under observation. Almost every time one operates the method must be varied to meet the requirements. Often, indeed, the necessities of the case determine the lines of incision only after the operation has been commenced.

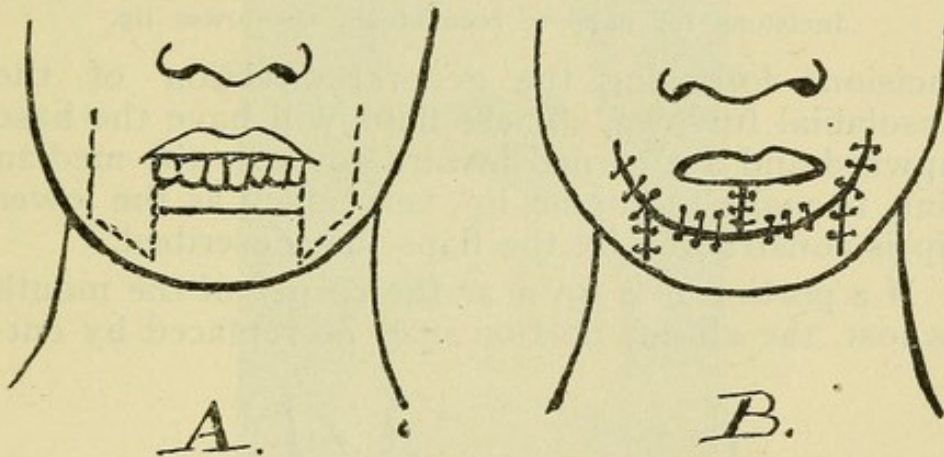
Pancoast said in 1843 that there is scarcely any loss of substance, however hideous, of the mouth and lips, which cannot be remedied by the skill and ingenuity of modern surgeons. This statement is even more true to-day than it was fifty years ago.

The tissues of the cheeks are usually so mobile that unless the cicatricial deformity about the lips involves them, they can be displaced by proper incisions so as to construct an upper or lower lip. The structures beneath the chin and of the neck are also used for making lower lips.

A large flap from the chin with the pedicle towards the angle of the jaw may be turned upwards to make a lower lip. If necessary, a portion of the lower jaw forming the chin may be cut away

to lessen the tension on a flap. A bridged-shaped flap dissected from the region below the chin may be lifted up over the chin and put in the place of the removed lower lip. It has been suggested to take a strip of the periosteum from the jaw in such a flap, in order to give it a little more rigidity. This rigidity is to take the place of muscular tissue in the flap.

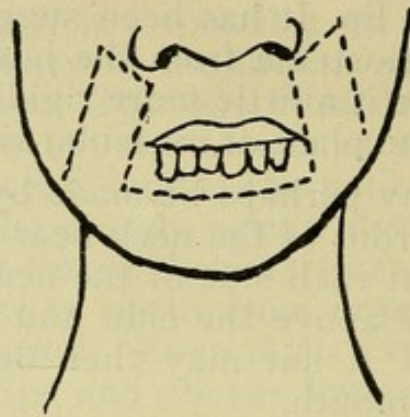
Both lips may perhaps be made by taking a large flap from the front of the neck near the hyoid bone, with pedicles at each side of the neck, and carrying it like a bridge above the chin and fastening it below the nose. A slit may then be made in it to represent the mouth.



A. Shows lines of incisions for one method of cheiloplasty. B. Shows flaps sutured in position.

A lower lip may be made, after excision of the whole lip for malignant disease, by two flaps; each made by parallel vertical incisions, one running downward from the corner of the mouth; the other starting in the cheek from a point a little outside of and below the wing of the nose. These incisions are connected below by an incision parallel to the margin of the jaw. The two flaps are united in the middle line in such a way as to construct a lower lip. This displacement modifies a little the corners of the mouth, but this is unimportant. Another method is to cut flaps in the region of the nasolabial grooves, as is shown in the illustration.

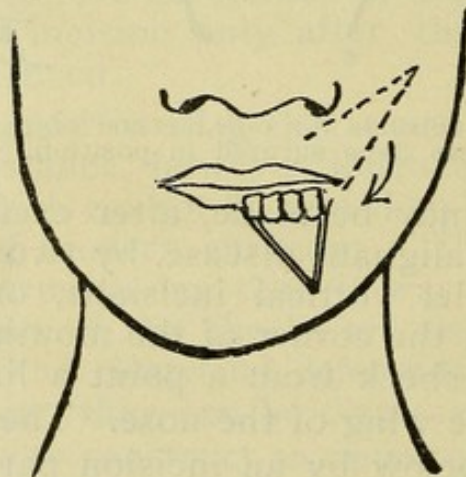
The upper lip may be constructed in a somewhat similar way by two lateral flaps made by parallel



Incisions for flaps to reconstruct the lower lip.

incisions following the general direction of the nasolabial furrows. These flaps will have the base upward and are turned inward towards the median line, to make the upper lip, very much as the lower lip is constructed by the flaps just described.

If a portion of a lip near the corner of the mouth is lost, the absent portion may be replaced by cut-

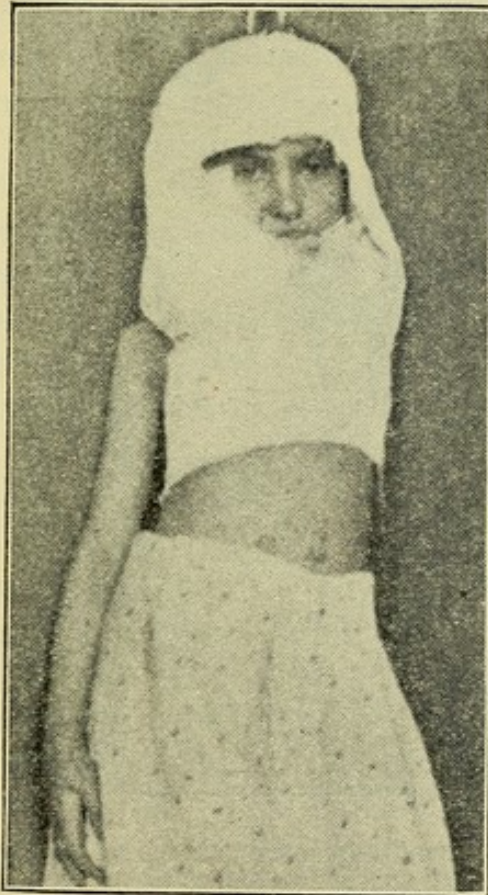


Incisions to make flap to reconstruct a portion of a lip.

ting a triangular flap from the other lip, swinging it downward or upward around the corner of the mouth to bring it into position. It is also possible to make a lower lip by cutting a flap from the neck with its base upwards and making a buttonhole in-

cision through the skin near the chin. Through this incision the turnedup flap may be thrust. By twisting the flap the skin-surface may be directed outwards. A similar operation may be done without making a buttonhole incision in the skin near the chin. Then the flap is simply jumped across the normal skin on the chin; or it is laid in a groove, made by a vertical incision in the tissues covering the chin.

After making new lips in any of these ways the edge may be lined with mucous membrane by taking flaps of mucous membrane from the inside of



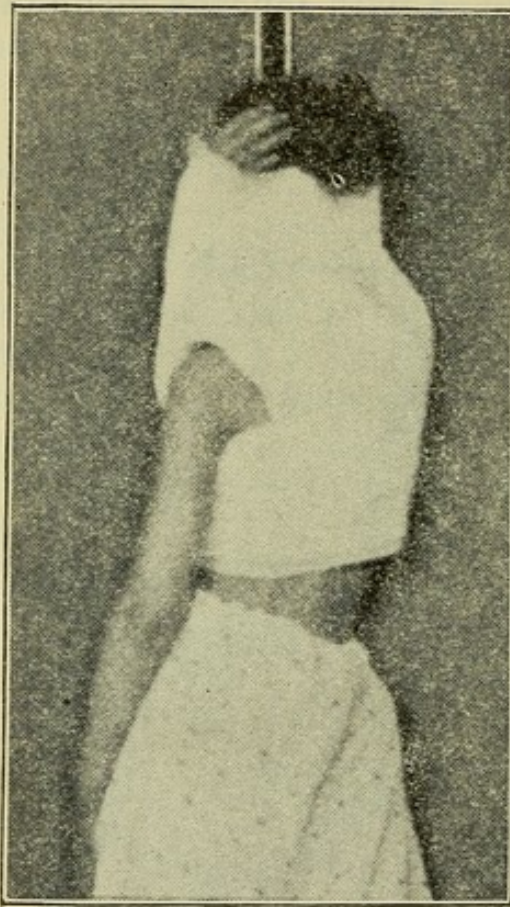
Gypsum bandage applied to keep arm to face in making lower lip from tissues of arm. Front view.

the cheeks near the normal lip and twisting these flaps into proper position. They are then sutured to the newly made organ.

It is also possible to get tissue for a lip from the

arm by binding the hand to the head, by the method of Tagliacozzi. I have recently had such a case under treatment which has resulted very satisfactory. A method which I have used is to transfer the skin of the abdomen to the hand and then transfer from the hand to the lip, after the abdominal flap has become united to the hand.

Portions of the cheek may be made by flaps from other regions of the face or from the neck. A con-



Gypsum bandage applied to keep arm to face in making lower lip from tissues of arm. Posterior view.

venient way sometimes is to turn up a flap from the neck and thrust it through a buttonhole incision along the edge of the lower jaw. The skin surface may thus be turned inward and the outer surface skin-grafted. This operation is not satisfactory if the skin of the neck is covered with a heavy beard, because the hair grows into the mouth.

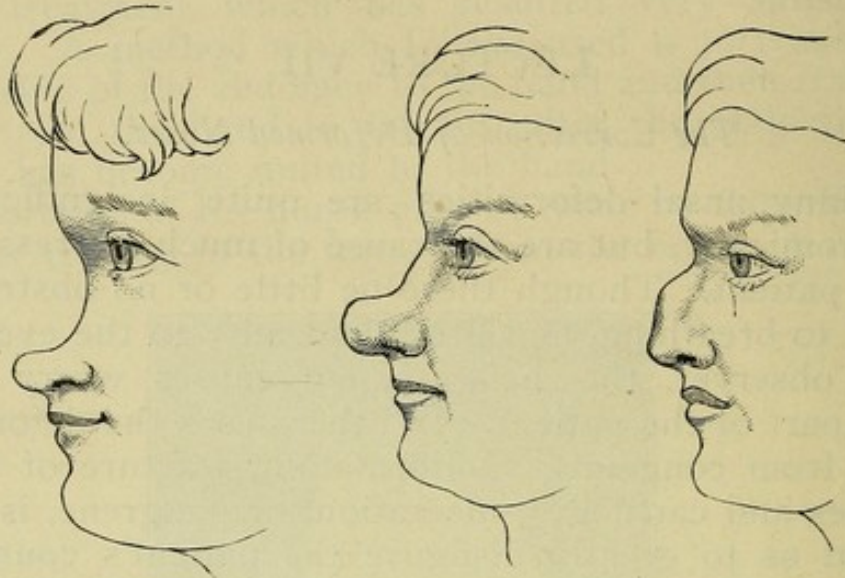
LECTURE VII

The Correction of Deformed Noses.

Many nasal deformities are quite insignificant anatomically, but are the cause of much distress to the patient. Though there be little or no obstruction to breathing, and little deformity to the eye of the observer, the disfigurement causes worry on the part of the patient. In other cases the deformity, from congenital malformation, fracture of the bones and cartilages, ulceration, or gangrene, is so great as to greatly disfigure the patient's countenance. Syphilis, giving rise to necrosis of the bones and cartilages which form the support of the nose, is a potent cause of nasal deformity. Epitheliomatous ulcers occurring upon the nose may render such cutting operations necessary as will leave deficiencies, which must be filled by operative treatment.

Destruction of tissue, from the application of caustics, to relieve real or supposed malignant growths, is not infrequently the cause of disfigurement. Some of the distortions of the nose are due to deviations of the cartilaginous septum. Many of these deviations are the result of fracture following comparatively insignificant, and perhaps forgotten, blows upon the nose. The saddleback nose arises from a want of proper development of the bones and cartilages forming the septum. A somewhat similar sunken-in nose is found in inherited syphilis. These are much less conspicuous disfigurements than the dreadful deformity of this organ, which arises from syphilitic necrosis of the internal structures of the nose, which give shape to its external contour. In these cases the middle of the organ

sinks inward because of lack of support. The tip of the nose, therefore, rises and the nostrils instead



Saddleback Nose.

Tuberos Nose.

Angular Nose

of opening downward look directly forward.. The saddleback nose, the angular nose due to undue prominence of the lower end of the nasal bones, and the nose with a tuberos lobule are all amenable to operative treatment.

In the saddleback nose a piece of metal or celluloid may be sterilized and slipped underneath the skin in such a way as to fill up the hollow on the dorsum of the nose, and give the organ a straight, or nearly straight, surface from the forehead to the tip.

The sunken or saddleback nose of inherited or acquired syphilis requires much more active surgical intervention; at least in the majority of cases. Here it is necessary to elevate the parts; and then support them. Chiselling portions of bone from the nasal processes of the maxillary bones, or from the nasal bones themselves, if they have not been destroyed, has been adopted. These detached fragments are displaced in such a manner as to give

support to the nasal tissues which have previously



Twisted Nose.



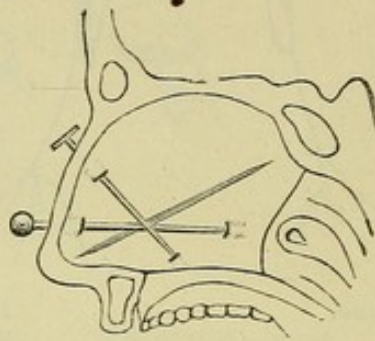Bent Nose.

been elevated by subcutaneous incisions. The introduction of intranasal supports of metal, to hold up the external nose, has been adopted. In syphilitic cases foreign materials used for this purpose are more apt to set up irritation than in non-syphilitic cases. It is probably better to build up the dorsum by flaps taken from the cheeks or forehead, than by using internal supports made of metal.

The angular nose is usually remedied by the very simple operation of making an incision, and chiseling away the redundant cartilage and bone. It is usually better to make the cut along the edge of the nose, than directly in the middle line. The elasticity of the skin then permits the surgeon to displace the flap laterally, and get access to the prominence to be removed. The scar, being a little to one side of the anterior surface of the bridge of the nose, is less conspicuous than if in the middle.

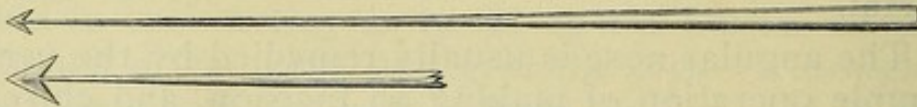
Bent and twisted noses are remedied by incising the septum, removing redundant portions of the septal cartilage and bones, separating the soft tis-

sues of the nose from the bony supports beneath by the free use of a tenotome, and forcing the distorted organ into proper position. It is held here by means of pins introduced through the nostril and from the external portion of the nose. The use of pins is often more satisfactory than intranasal splints or tubes, because the nostrils are kept free from obstructing foreign bodies, and can be easily irrigated or sprayed with antiseptic solutions. In



Use of pins to hold incised septum in corrected position.

correcting bent or twisted noses, the surgeon should usually overcorrect the deformity, because there is a tendency for the nose to return to its abnormal position. Chisels, saws, and the surgical engine are instruments very useful in correcting the septal deformity which is often associated with these exter-

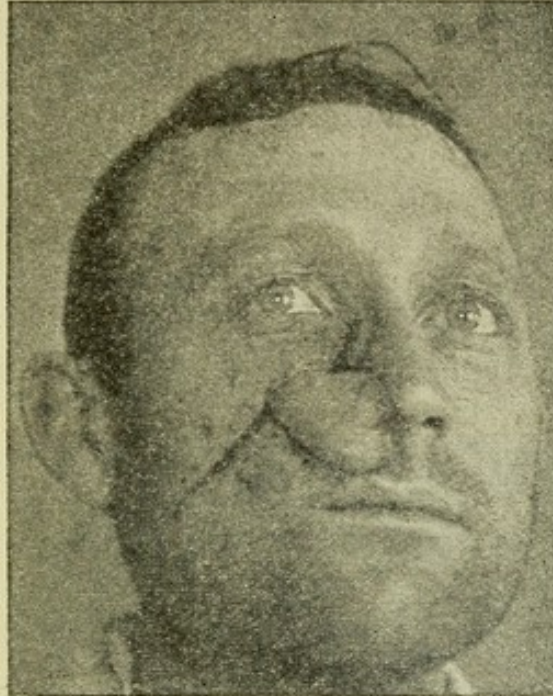

Barbed Needle.

nal disfigurements. Surgeons should not forget the importance of examining all recent fractures of the nasal bones and cartilages with great care. Imperfect examination and consequent inefficient treatment are the causes of many deformed noses.

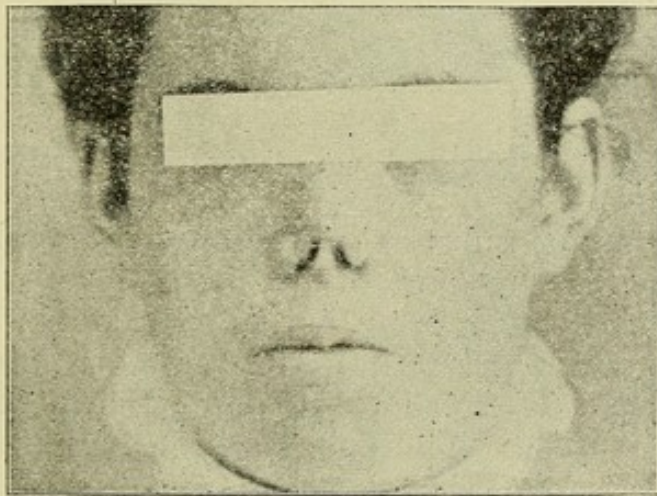
In removing cartilaginous excrescences upon the septum, a long barbed needle is often valuable. It is thrust into the mass, which is thus steadied, until it is excised with knife or saw. The long needle

gives the surgeon control of the little tumor, and permits the removal to be quickly done.



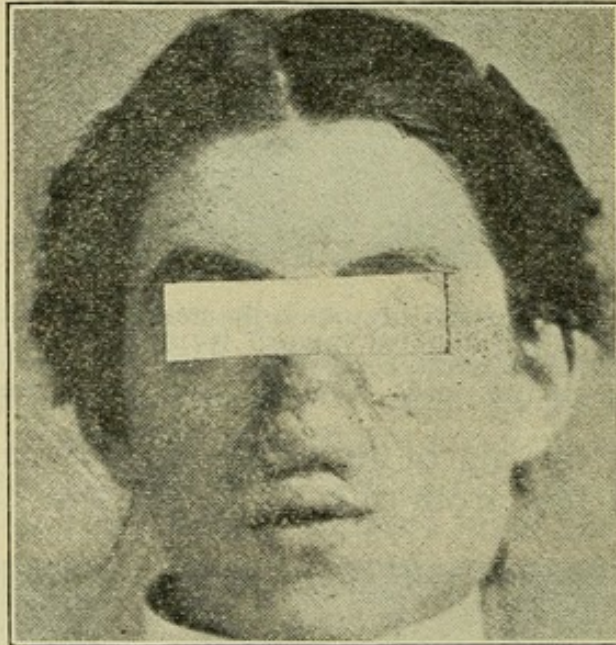
Ala of nose and portion of upper lip made from flap cut from the cheek. Flap doubled inward to make naris by a double stitch tied over a piece of rubber tube placed alongside of the bridge of the nose. (Taken a few days after operation.)

Loss of the ala of the nose may be repaired by making a flap from the upper lip and cheek, and



Loss of end of nose from caustic applied by quack doctor.

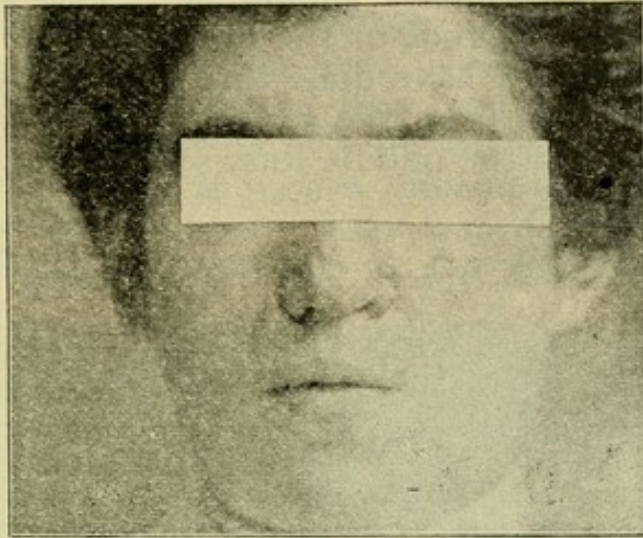turning it into the gap. Sometimes it is better to take the new tissue from the cheek alone, making the incisions in the nasolabial furrow. Portions of the nose have been constructed from the tissues of one of the fingers. This may be done by splitting a finger of the left hand on its palmar surface, removing the phalanx, and stitching the laid-open soft tissues to the stump of the nose. The nail is removed either before or after the plastic operation, which attaches the digit to the nose. After the lapse of about two weeks the finger is amputated from the hand. Nearly a complete nose has been



Showing flaps taken from cheek to make end of nose. First operation on case shown in previous figure.


made by using a finger in a somewhat similar way. The color of the skin of the hand is apt to differ from that of the face. Flaps may be taken from the forehead, with or without periosteum, and turned or twisted downward to close a gap on the top or side of the nose. The color is then more natural.

The contour of a syphilitic nose may be improved by a transverse incision across the depressed nose at the deepest part of the furrow above the lobule



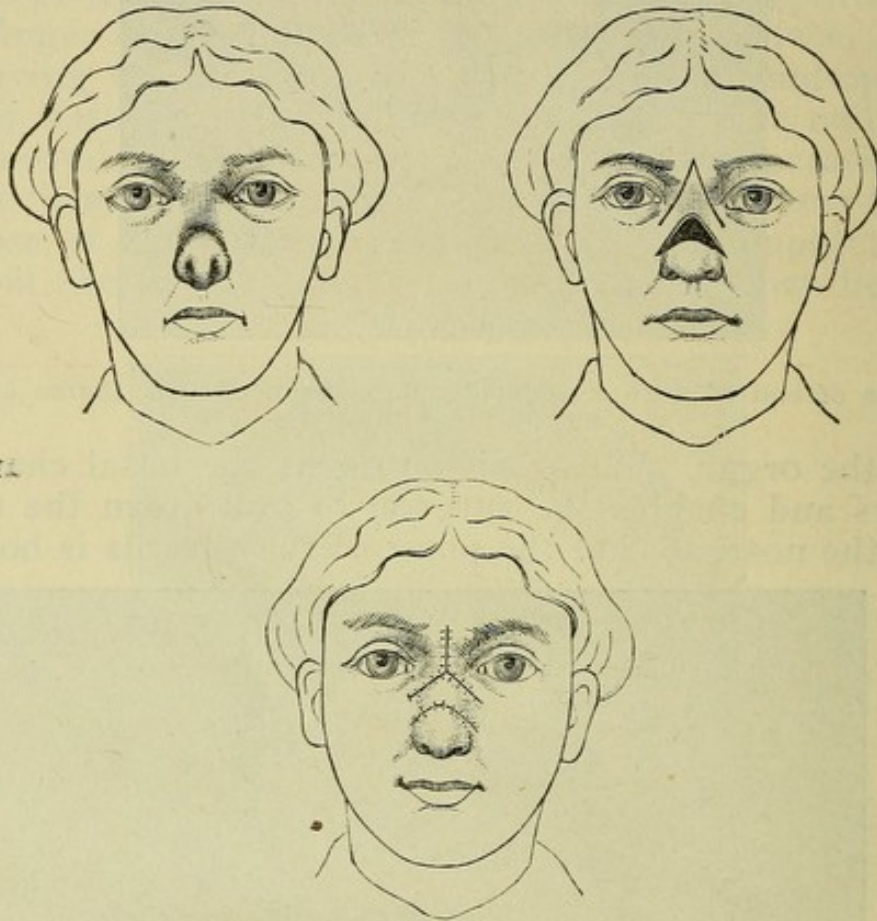
Loss of end of nose repaired by flaps from cheeks. [Same case as previous figure.]

of the organ. This incision opens the nasal chambers and enables the surgeon to pull down the tip of the nose, so that the plane of the nostrils is hori-



Portion of ala of nose made from tip of finger. (Dr. J. P. Tunis' case.) The notch in the new ala was subsequently repaired by the author with a flap taken from the cheek.

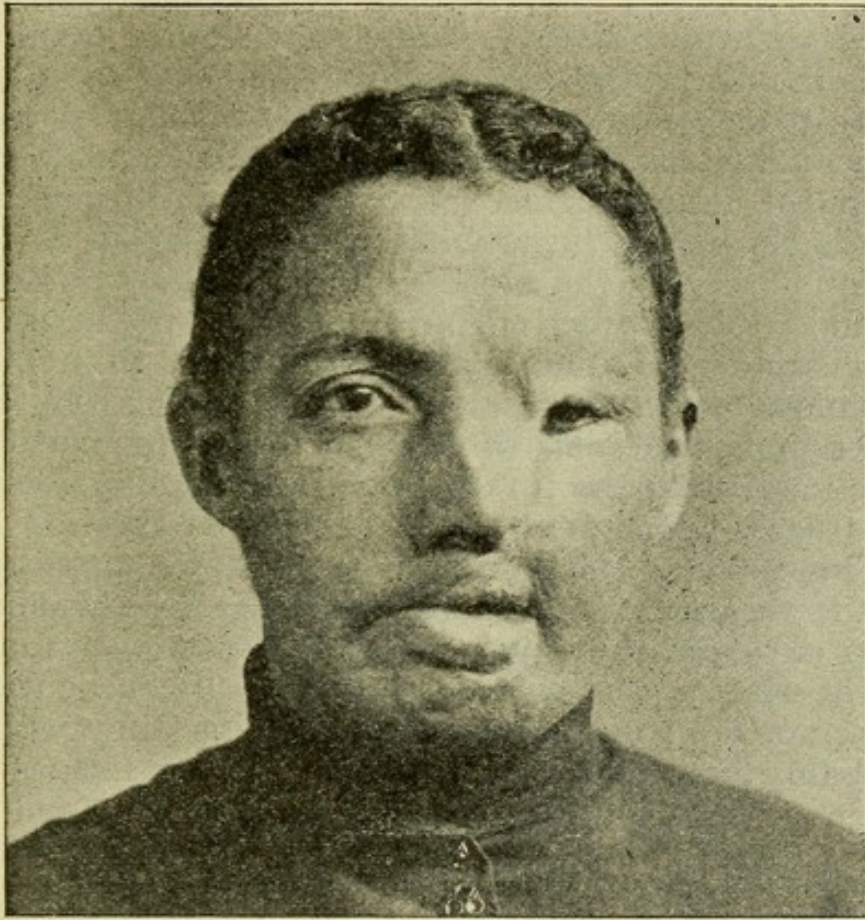
zontal, as it normally should be. The great gap left between the root of the nose and the tip must then be filled. I have done this quite satisfactorily by taking flaps from the cheeks and turning them inward toward the middle line, so that the skin-sur-



Three diagrams showing a sunken syphilitic nose and one method of repairing it.

face presented toward the nasal cavity. The tissue of the forehead was then brought downward to cover these flaps, and make the mass of tissue thick, so as to give rigidity to the newly formed portion of the nose. Another method is to make a V-shaped incision between the eyes with the point of the V upward, and displace this flap downward to fill the gap left by the original transverse incision, which was made to bring down the point of the nose. This flap is scarcely rigid enough, but may be held in position by spectacles supplied with a

spring, like eyeglasses. Many modifications of these plans will suggest themselves to operators. I have made a forehead flap, containing periosteum and a thin shaving of bone, turned that downward and thrust it through a transverse buttonhole at the base of the nose. This was done with the hope of giving more solidity to the new dorsum.



Patient deformed by burns so that the nose was twisted to the left, the naris closed, the lips everted and the eyelids distorted. Much improvement was obtained by a series of operations.

The columella of the nose may be made by two vertical incisions extending downward through the upper lip. The central portion of the lip is then turned upward and stitched to the tip of the nose in such a way as to make a partition between the two nostrils. The gap in the lip is then closed by stitches as in hare-lip. The mucous membrane

which then covers the external surface of the new columella may be subsequently excised so as to get rid of its red color. I have on the cadaver constructed a satisfactory columella by cutting a vertical piece from the inner surface of the lip and turning it upwards through a transverse buttonhole made at the junction of the nose and lip.

It is probable that the ala of the nose may be lined with mucous membrane in a similar manner. This may be necessary when occlusion of the naris takes place after reconstruction of an ala. A portion of mucous membrane and muscle may be cut from the inner surface of the lip and turned upwards through a buttonhole made in the lip at the lower border of the nostril. It is perhaps possible to make the columella from the dorsum of the nose, by cutting a flap containing periosteum from over the nasal bones themselves, and thrusting this cutaneo-periosteal flap through a transverse buttonhole made near the tip of the nose. The flap should then be stitched to the upper portion of the lip.

This same method might perhaps be employed in the treatment of saddleback noses by thrusting flaps cut from the cheek through buttonholes made in the skin at the side of the nose. If the cuticle is removed from these cheek flaps, they would probably become adherent to the deeper tissues of the nose, and build up a mass of connective and fibrous tissue underneath the skin at the front of the nose. A hollow creating the saddleback condition could probably be thus obliterated. These operations I have only tried upon the cadaver, but they seem to promise success.

LECTURE VIII.

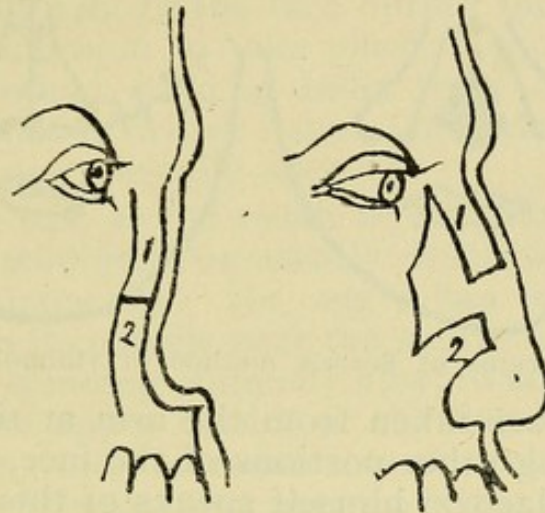
The Constructton of New Noses.

Rhinoplastic operations, for the construction of an entire nose or a portion of that organ, are required to repair the damages of syphilis and lupus and of intentional and accidental mutilations. American and Continental surgeons have very little experience with these operations, except in cases due to syphilis and lupus. English surgeons in India have very many patients with the cartilaginous portion of the nose cut off by sharp instruments. This mutilation is frequently adopted in India as a means of revenge. Keegan states that the number of such mutilations effected in a single year in India is unknown. That it must be large is evident from his statement that in the year 1897 there were 152 rhinoplastic operations known to have been performed in that country. In a single evening he saw, while riding through one of the native cities, as many as three or four women with mutilated noses, sitting near their huts. As a consequence of this distribution of rhinoplastic work, American and European surgeons have had much less experience than Indian surgeons. The cases seen outside of India are usually much more difficult to bring to a satisfactory conclusion by operation, because the tissues which remain have been distorted and altered by the syphilitic or tubercular ulceration which has destroyed the nose. In many of these nasal deficiencies, due to disease, the internal bony and cartilaginous structures have been entirely destroyed. In some instances even the nasal bones which support the nose at its bridge are also absent, as the result of syphilitic necrosis.

Until recent years the technic of total rhinoplasty was somewhat imperfect; and, as a consequence, surgeons undertook the construction of a nose with considerable hesitation. More recent studies and the advantages of aseptic surgery have improved conditions to such an extent that these operations are now undertaken with much more certainty of obtaining an improvement in the patient's appearance. A very great deal can be done when only the soft parts of the external nose have been cut off. Quite a satisfactory gain is possible, even in cases greatly deformed by cicatricial contraction, subsequent to syphilitic ulceration of the hard and soft parts. In the latter cases the main difficulty is to get support to the flaps of skin, which are used to make the new nose. Metallic supports and bridges of various sorts have been employed to hold up and give the requisite projection forwards of the flaps of skin which represent the new nose. In some cases these have been worn for a number of years and apparently with satisfaction. In others they have set up irritation, which has finally led to their removal. It is probable that it is better, as a rule, to build up the nose by using superimposed flaps of skin and connective tissue. Such flaps may be piled one upon the other by successive operations and a fair semblance of a rigid nose be thus made.

Portions of bone have been chiseled, from the nasal bones and from the superior maxillary bones, and displaced in such a way as to hold the integument forward. These osteoplastic operations have been to a certain extent satisfactory. Ollier, Koenig and Israel have made interesting suggestions in this connection. Sabine, of New York, constructed a new nose from a finger, which he attached to the sides of the chasm left by the loss of the nose. The finger-nail was removed and the palmar surface of the finger split so as to form lateral flaps. The hand

was then applied to the face and the finger stitched to the edges of the nasal cavity. After circulatory



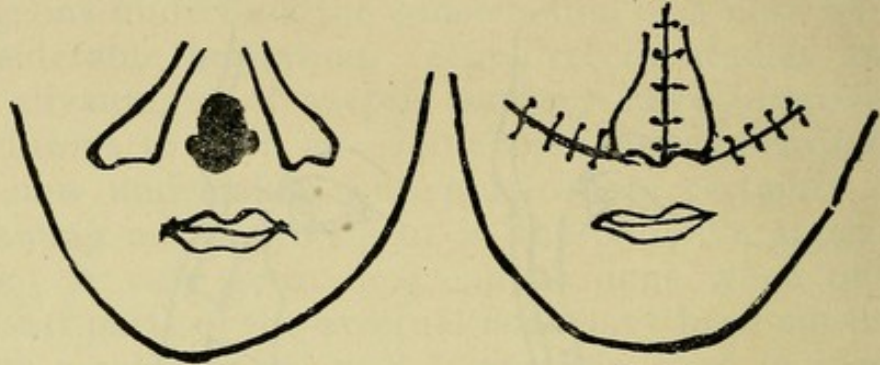
Langenbeck and Ollier split the nose vertically, laid the soft parts to each side, and then sawed bony flaps from the edges of the nasal aperture above and below on each side. They then bent these bony flaps forward to give support to the frontal flap or the replaced soft structures.

connection was established, the finger was amputated from the hand through the first phalanx; and the end of the portion of finger, left attached to the face, was bent at the joint between the first and second phalanx, so as to make the end of the nose and its columella. A number of minor operations were subsequently done to improve the shape of the new nose.

The usual methods of rhinoplasty are the Italian, in which the tissues of the arm are attached to the stump of the nose; the French—sometimes called the German—method, in which the new organ is constructed from flaps taken from the cheeks; and the Indian method, in which the skin of the forehead is utilized in the nasal reconstruction.

The Italian method was brought to the notice of surgeons in 1597 by the Latin treatise of Tagliacozzi. Before that time, however, rhinoplastic operations were performed by Sicilian operators. A brief reference is found, it is said, in a publication of Benedictus, dated 1497. Tagliacozzi's method was

subsequently modified in various minor particulars, and is sometimes used at the present day. In



Diagrams of Serre's method of rhinoplasty.

fact, flaps are taken from the arm at times for reconstructing other portions of the face, such as the lips. Tagilacozzi himself speaks of this application of his method, and gives illustrations of it.

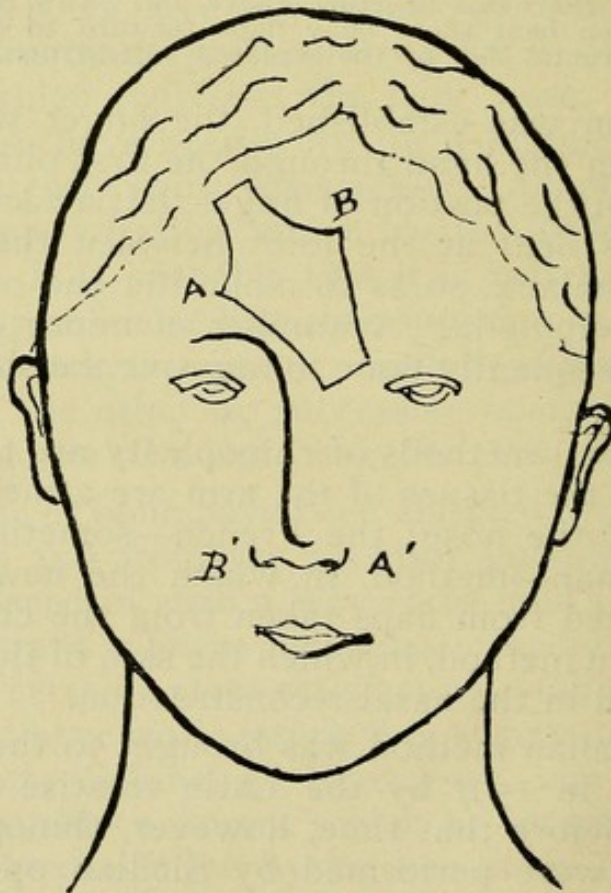


Diagram showing Keegan's outline for the frontal flap in rhinoplasty. When the flap is rotated downward the point A is stitched at A' and B at B'.

The brachial method, as it may be called, of Tagliacozzi, is tedious to the patient and requires more or less complicated bandaging or apparatus for holding the arm to the face during the time necessary for adhesion to take place. Hence, either the frontal method, used in India from a very early time, or that in which flaps are taken from the cheeks is more usually adopted.

Keegan has, as the result of his great experience in India, modified the usually described method of frontal rhinoplasty. He cuts a flap from the forehead, with its pedicle near the supraorbital notch of one eye, extending obliquely upward across the forehead. The upper border of the flap has a projection, from which he constructs the columella of the nose. He first makes a pattern of the flap by using a piece of banana leaf, which is flexible and supple. Having made this pattern, he cuts from stout brown

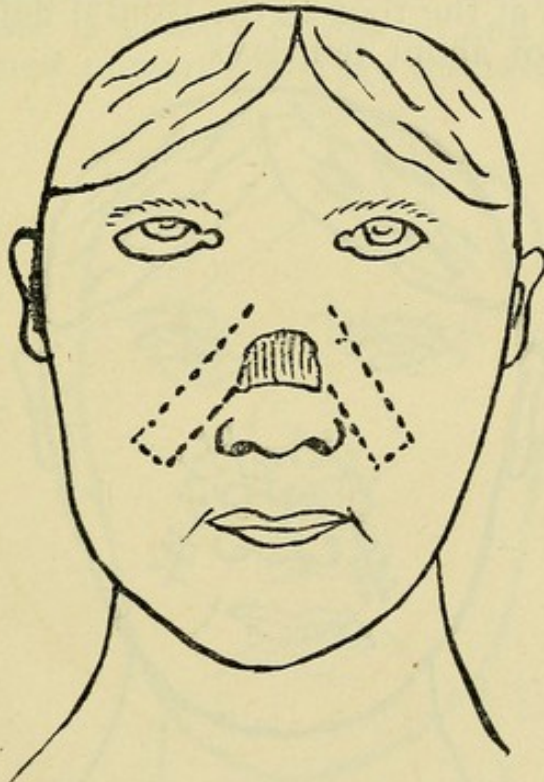


Diagram of Roberts's method of reconstructing a sunken nose. The dotted lines indicate the flaps taken from the cheeks to cover the opening into the nasal chambers left by the detachment and drawing downward of the cartilaginous nose.

paper an exact duplicate in shape. This is fixed to the forehead by an adhesive material, so as to render it easy to make a flap, exactly satisfactory both as to size and shape. The soft tissues over the nasal bones are then converted into two flaps, which are turned downward upon a hinge, as it were, near the inferior border of the nasal bones. This maneuver puts the skin-surface of these flaps inwards towards the nasal cavity. The frontal flap is then cut and, by twisting its pedicle, it is carried downward so as to cover the denuded nasal bones and the raw surface of the turned-down tissues, which previously covered those bones. The columnar portion of the frontal flap is then properly sutured into a groove or bed in the upper part of the superior lip. Sutures are applied to close the frontal wound and fix the edges of the flaps in proper relation. Drainage tubes are inserted in the newly formed nostrils. The pedicle at the root of the frontal flap is divided at the end of about ten days.

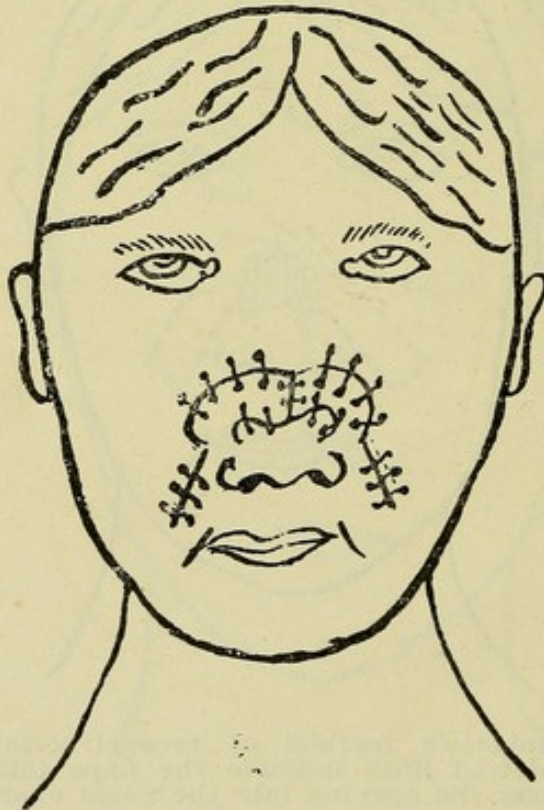


Diagram of second step in Roberts's method. The cheek flaps sutured to close the opening.

The object in using the tissue covering the nasal bones to form the internal surface of the nostrils is to prevent contraction of the nostrils. These underlying flaps also give support and strength to the new nose, so that it is less likely to become flattened.

Portions of noses may be constructed by various rhinoplastic procedures, but they need not be further discussed here. Some of them have been already mentioned in the previous lecture. The tissues of the lips and cheeks may be utilized for the formation of the necessary flaps, which are then displaced, so as to fill the gaps which are the cause of the nasal deformity.

The construction of a portion of the nose in cases of sinking-in, due to syphilitic destruction of the internal cartilaginous and bony supports, is often a difficult problem. In these cases the middle portion of the nose is greatly depressed and the tip of the nose turned upwards so that the nostrils look for-

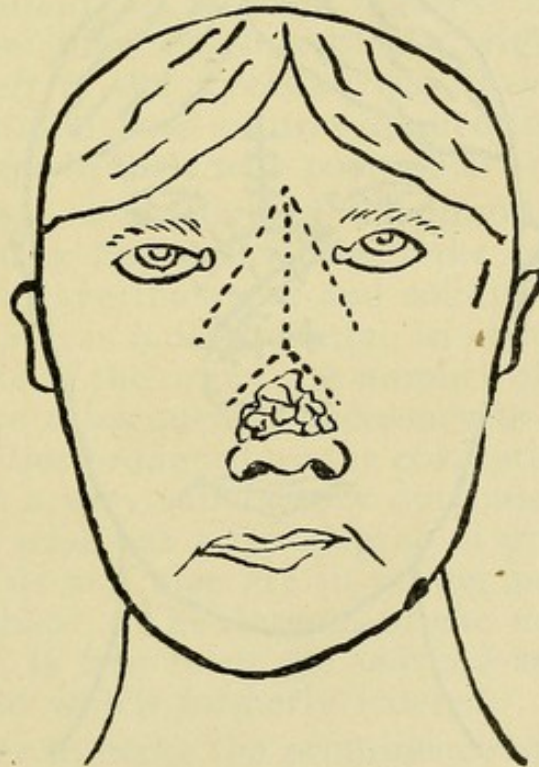


Diagram of third step in Roberts's method. The dotted lines show the outlines of the two frontonasal flaps.

ward instead of downward. In some cases the nasal bones are destroyed but they often remain uninvolved by the syphilitic necrosis. I have recently reconstructed such a nose in a very satisfactory manner by a combination of plastic procedures which is, so far as I know, new. The first step was to make a transverse incision in the hollow above the tip and alae of the nose, where the depression due to cicatricial contraction and want of support was the greatest. This enabled me to pull down the lower end of the nose and bring it forward so that the nostrils looked downward and the tip of the nose had its normal projection forwards. This left a large opening between the cartilaginous nose and the lower end of the nasal bones. This space was covered by lateral flaps cut from the cheeks and turned inward towards the middle line with the skin surfaces towards the nasal chambers. These flaps should be cut in the line of the nasolabial fur-

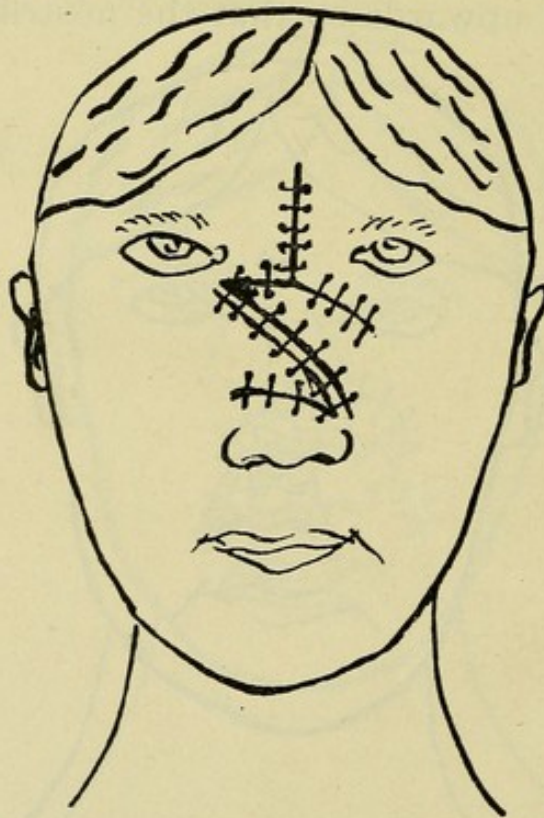


Diagram of fourth step in Roberts's method. The frontonasal flaps sutured on top of the cheek flaps.

row in order that the linear scar may correspond with this line more or less accurately and therefore be comparatively inconspicuous.

After these flaps had become united in this position, the irregularity due to the twisting of their pedicles was removed by a small plastic operation on each side. The next major step was to make two diverging incisions from the middle of the forehead, downwards and outwards, in the manner shown in the diagram. Two other incisions were made just above the granulating surface, situated at the point where the cheek-flaps had been united in the middle line. A median vertical incision was made to connect the apices of the inverted V's made by these four incisions. The two flaps thus made over the nasal and frontal bones were then dissected from the underlying tissues and turned downward so that the upper point of the right flap could be attached to the base of the left ala, and the uppermost point of the left flap turned over to the right side of the patient, so as to fit, against the other flap, below the inner canthus of the right eye. The wound left in the forehead was then closed vertically and numerous sutures applied to hold the displaced flaps in their new positions.

This maneuver covered the granulating surface of the cheek flaps that closed the opening in the nose; and gave thickness and solidity in the region where firmness is so essential, in order to maintain the outline of the organ. A number of minor operations were subsequently necessary to get rid of the irregularities produced by the coaptation of so many flaps, but a very satisfactory outcome has resulted. The new nose has a fair degree of prominence and the nostrils and alae are in proper position and of normal shape. The dorsum of the nose, while not beautiful, is free from the marked and disfiguring depression which formerly existed.

In order to make the prominence of the nose and upper lip relatively greater, a portion of the lower lip was removed by a V-shaped incision.

LECTURE IX.

The Operative Treatment of Deformed or Deficient Ears.

Operations for the relief of aural disfigurement have received very little attention until within the last six or eight years. This is rather remarkable because the deformities are quite conspicuous and the operations for their relief free from serious risk. It is the more strange because Italians of the time of Tagliacozzi and earlier did plastic operations upon the ear, and because, according to Szymanowski, such operations are mentioned in Sanscrit writings.

The ears of prize-fighters often receive injuries which result in permanent cicatricial deformity. Sexton called attention some years ago to the fact that the ancient Greeks must have been familiar with deformed ears in boxers, because the characteristic disfigurement is, according to him, shown in statues representing ancient Greek pugilists.

The external ear is quite often the seat of incised and lacerated wounds which require accurate suturing to reproduce the normal outline. The auricle may be torn almost completely from the skull and yet be easily restored to its position by a few sutures. Completely detached portions should be cleansed and sutured in position, even if some time has elapsed since the accident. Union may sometimes be obtained even in these unfavorable cases.

Sloughing after frost-bite is a not unusual cause of aural disfigurement. Plastic operations may improve the appearance of the organ. A common injury is laceration of the lobule from earrings having been torn out of the ear by children, grasping at the trinket, while being carried in the arms. The fissure

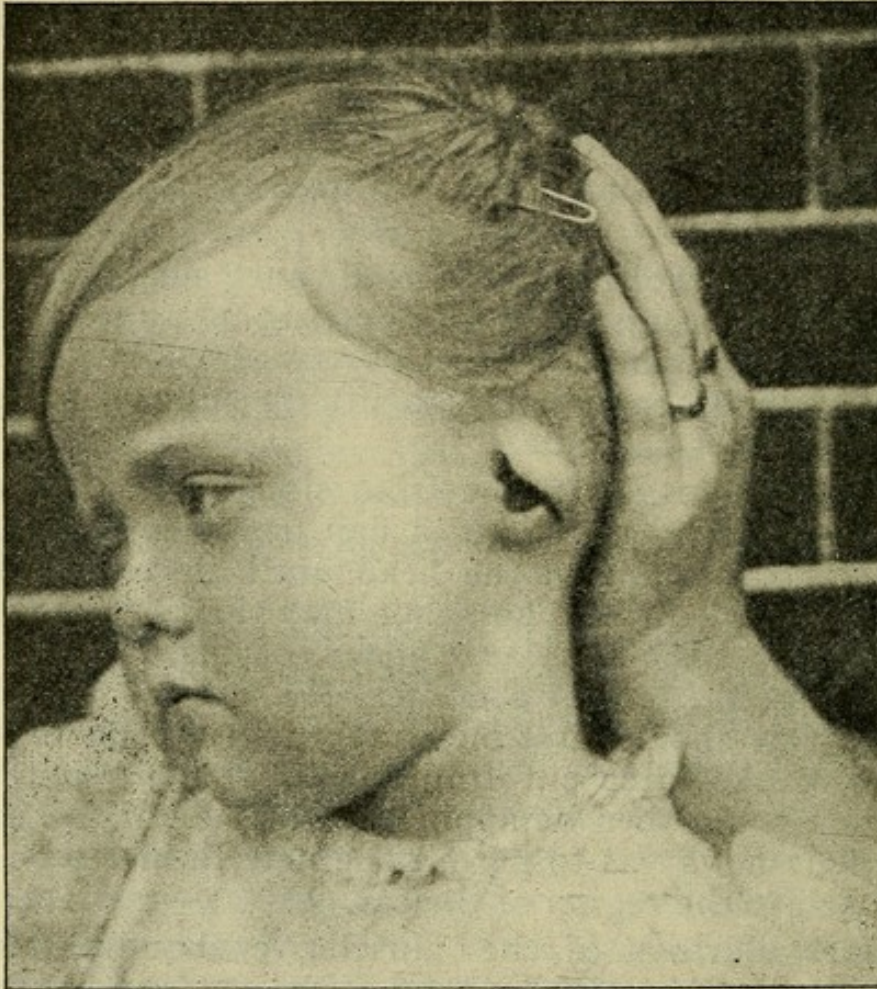so made may be easily closed, even if cicatrization has previously occurred, by freshening the edges of the cleft and applying sutures. I have operated when the ear has had several such cicatrized tears in its lobule. A similar plastic operation is necessary after the removal of the keloid growths that occasionally result after piercing the ears for earrings. A little ingenuity will greatly improve such cases.

Burns of the side of the head cause sloughing and cicatricial disfigurement. Poncoast many years ago made a new lobule to an ear by two crescentic incisions which enabled him to lift up sufficient tissue to construct a lobule.

A great loss of tissue from sloughing may need to be replaced by taking a flap from the hand, applied to the side of the head until circulation has been established. The tissue may then be detached from the hand. A large piece of tissue may be transferred from the abdomen. In such an operation the graft should first be attached to the hand, and two weeks later cut from the abdomen; and the hand should then be applied to the side of the head in such a way as to permit the new tissue to be attached to the region of the ear.

Irregularities of the auricle, enchondromatous nodules in the neighborhood of the ear, and fistulous openings occur as congenital defects. They are due to irregular coalescence of the branchial arches and imperfect closure of the branchial clefts. Sometimes there is a deficiency of cartilage in the pinna which allows the external ear to assume abnormal positions on account of its flaccid character. I recently operated upon the case of this sort which is shown in the figure. At other times the cartilage in the pinna may become buckled or bent during birth or soon afterwards, and asymmetrical ears result from want of correction of this abnormality. The lack of cartilaginous material may perhaps be compensated for by excising a portion of the skin back of the ear and stitching it to the side of the

head. It has been suggested that a thin sheet of platinum or other material be inserted beneath the



Congenital deformity of ear, treated by elliptical incision and bending of the cartilage.

skin, to give rigidity and a proper contour to the external ear. This could perhaps be bent in shape, even after the tissues had healed over it. The deformity due to bending or buckling of the cartilage may be remedied, if the child is treated when young, by bending the organ in the opposite direction and holding it there by means of adhesive strips, or some form of spring going across the top of the head and having a pad to press upon the ear. If the deformity is slight, the contracting influence of collodion may be utilized.

Exceedingly large ears, due to a sort of hypertro-

phy of all the tissues, occasionally require curtailment. This may be done satisfactorily by excising a V-shaped portion of the auricle with the base of the V towards the outer margin of the organ. Careful suturing will restore the general outline and maintain the regularity of the natural elevations and depressions. The excision of a crescentic piece from the central part of the pinna, with a tongue-shaped process extending from the convex border of the crescent to the border of the pinna, makes a rather neater operation and restores more accurately the normal contour. This method was, I believe, first suggested by Dr. Parkhill. These elephantine ears are greatly improved by such operations. Flaring or outstanding ears are very ugly, especially when the flaring condition is associated with great size. Such ears may be brought closer to the head by the excision of an elliptical piece of tissue behind the auricle, and the insertion of stitches so as to draw the cartilage nearer to the surface of the cranium. The elliptical portion removed should have its long diameter in the vertical direction and should be wide at the point where it is desired to draw the cartilage inward to the greatest extent. The portion removed should be quite large and its outer edge on the posterior surface of the pinna should extend further outwards as the amount of retraction desired is greater.

The border of the ellipse on the surface of the skull should be comparatively close to the bottom of the furrow between the ear and the head. By the insertion of stitches in an oblique direction the axis of the ear can be somewhat changed.

Some operators have removed only the skin and subcutaneous tissue; others have taken out the entire thickness of the pinna, including the cartilage, and the skin on both the back and front. It is probably best to remove a large portion of skin and subcutaneous tissue on the posterior surface of the ear and the skull, and to excise a wedgeshaped portion

of the cartilaginous structures ; but the cartilaginous piece which is removed should be much narrower

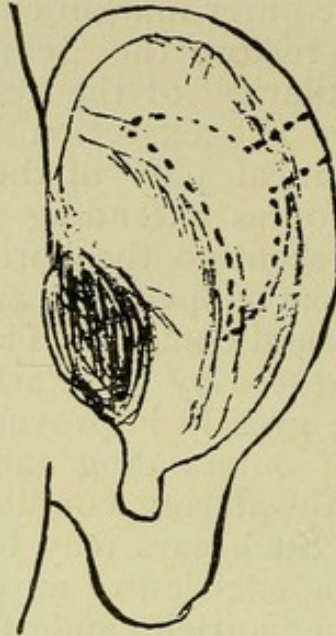
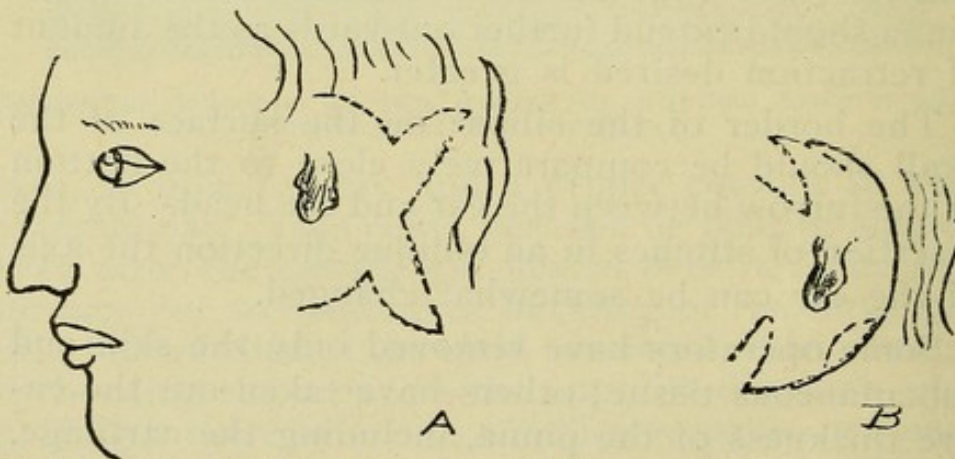


Diagram of method of Parkhill for reducing size of ear. Dotted lines show piece to be excised.

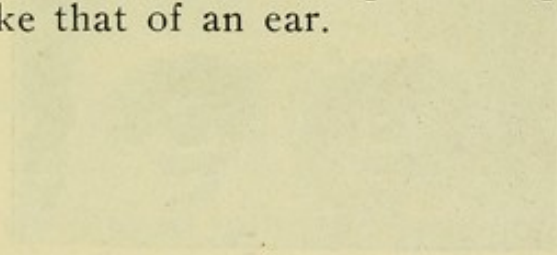
than that cut out of the skin. This method I have used satisfactorily. It is usually not necessary to carry the incision through the skin on the front of the ear.



Method suggested by Szymanowski for constructing an auricle in congenital absence of the external ear. A. Dotted lines show incisions by which the skin is raised and doubled so as to make a crude auricle. The posterior flap is thrust under the anterior one and sutured by through-and-through sutures. B. Shows incisions made at a subsequent operation to model the crude auricle into more perfect shape.

Congenital absence of the ears may be treated by the adoption of an aluminum ear properly tinted and held in place by a spring inserted in a slit in the soft tissues. Westlake adapted such a contrivance to a man's head, and the patient was unable to unlock the artificial organ and remove it. This was done by means of a spring situated behind the artificial ear.

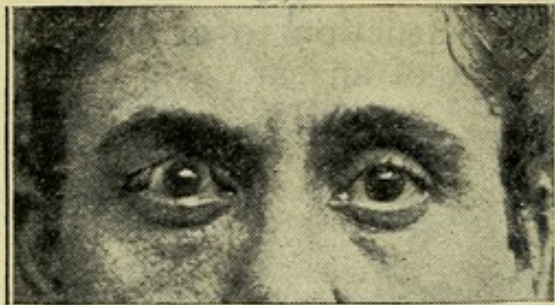Szymanowski has suggested the making of a cutaneous ear in these cases of congenital absence of the organ. The diagram shows the incisions for the reconstruction of a rudely shaped ear which is afterwards to be modelled by smaller incisions and proper suturing. It seems as if it might be possible to insert an aseptic piece of metal into such a cutaneous reconstruction to give it rigidity and a contour like that of an ear.



LECTURE X.

The Cosmetic Surgery of the Eyes.

Much can be done for improving disfiguring conditions of the eyeball and eyelids. One of the most common of the ocular conditions causing an unseemly expression of the countenance is strabismus. The internal form is usually associated with hyperopia and requires proper correction of the re-

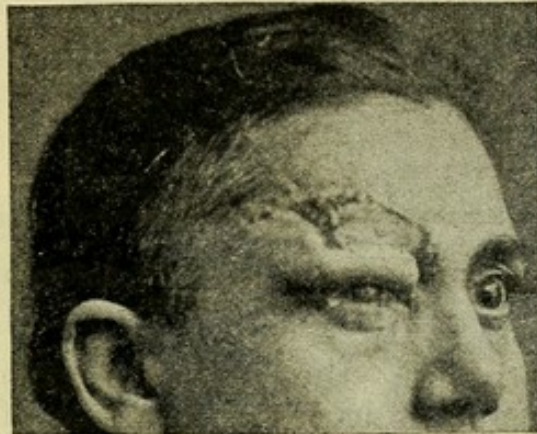

Loss of right upper eyelid after injudicious excision of small tumor.

fractive condition, in addition to section of the internal rectus muscle. Failure to wear lenses to correct the refractive defect causes not infrequently a return of the cross-eye condition. I have now under my care a patient in which the strabismus returned, apparently from neglect of this precaution on the part of the former operator. The various operations for correcting internal and external squint, or strabismus, by cutting the muscles, advancing the tendons, or by a combination of both operations, need not be discussed in detail; they are familiar to all ophthalmic surgeons.

Disfiguring white spots upon the cornea may be tinted with India ink. This little operation must be frequently repeated in order to get the tint of the

scar-tissue sufficiently dark. Such eyes are defective in vision and the tattooing is simply to make the conspicuous white spot of such a color that it will not attract attention.

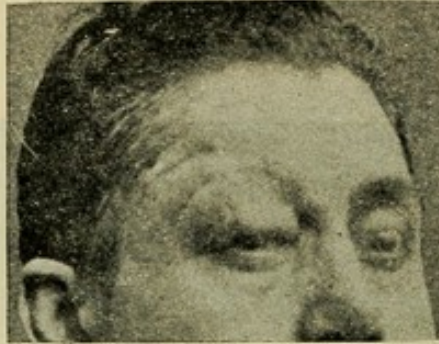

New eyelid made with flap from forehead. Photograph taken three weeks after operation.

Blind eyes, due to injury or any other lesions which destroy the appearance and shape of the globe, may be covered with artificial eyes of glass, so colored as to correspond with the normal eye on the other side. Anterior section may be required, if there is a prominence of the diseased eyeball due to anterior staphyloma. Mules's operation, in which a glass ball is inserted into the eviscerated sclera to give sufficient prominence to the globe, is a very satisfactory method of maintaining the prominence and the motions of the eyeball. The glass shell or eye placed in front of this has a much more normal appearance than when it is used after the globe of the eye has been entirely removed. A small eye due to atrophy may, if it is blind, be made to appear larger by wearing a strong convex lens in front of it. In front of the opposite eye a piece of plain glass may be inserted in the spectacle frame.

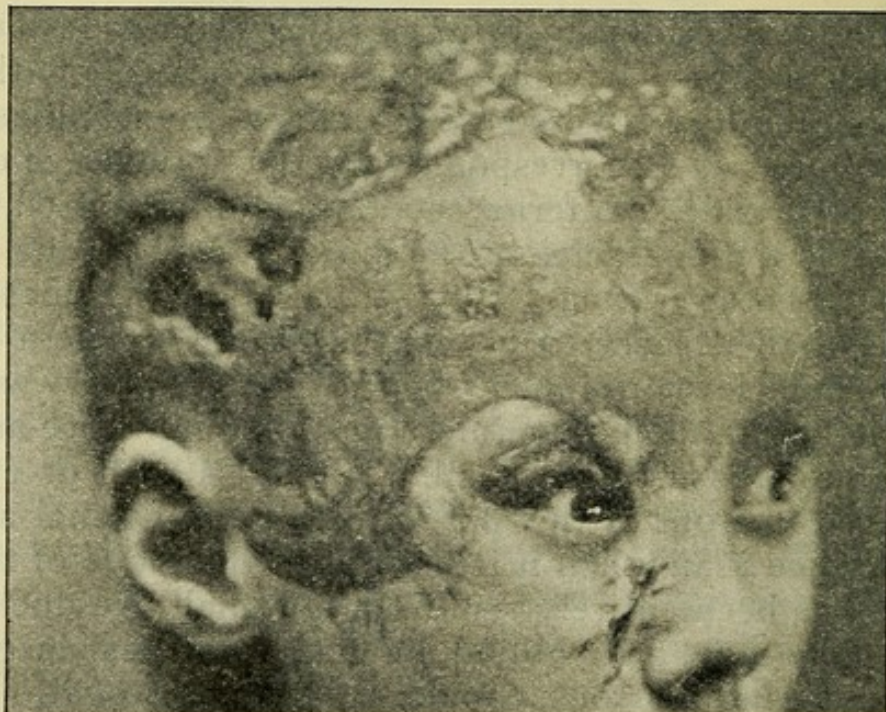In conditions of exophthalmos, and especially in

that form due to the disease called exophthalmic goitre, the disfiguring bulging of the eyes may be



New eyelid made with flap from forehead, taken at a later date than other figure.

relieved by stitching the eyelids together at the outer canthus so as to lessen the size of the palpebral fissure. This operation should not be done until the active symptoms of the disease have subsided. At that time, if the bulging of the eye per-



Ectropion of upper eyelid, due to cicatrization after avulsion of entire scalp. Operation consisted in using flaps from temporal region and side of nose. Incisions marked with ink. Head shows result of skin-grafting on ulcerated surface.

sists, the removal of a little of the mucous membrane at the outer angle of the eyelids and the insertion of a couple of stitches will so cover the eyeball as to make the bulging disappear.

There are many operations possible upon the eyelids which improve the appearance of the upper part of the face. The congenital condition called epicanthus, in which folds of skin extend over the inner angles of the eyelids, is improved by the re-

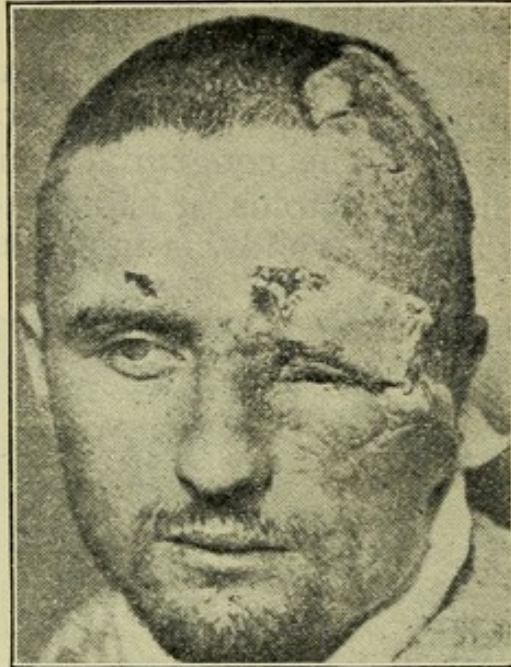


Excision of epithelioma below the eye. Flap from temple used to prevent ectropion. Outline of flap marked with ink.

moval of a vertical ellipse of skin at the root of the nose. Drooping of the eyelids, technically called ptosis, is remediable by removing a section of the skin of the upper lid or giving a new attachment to the elevator muscle. Warts and other tarsal tumors are very disfiguring, but most of them are easily removed by simple operations.

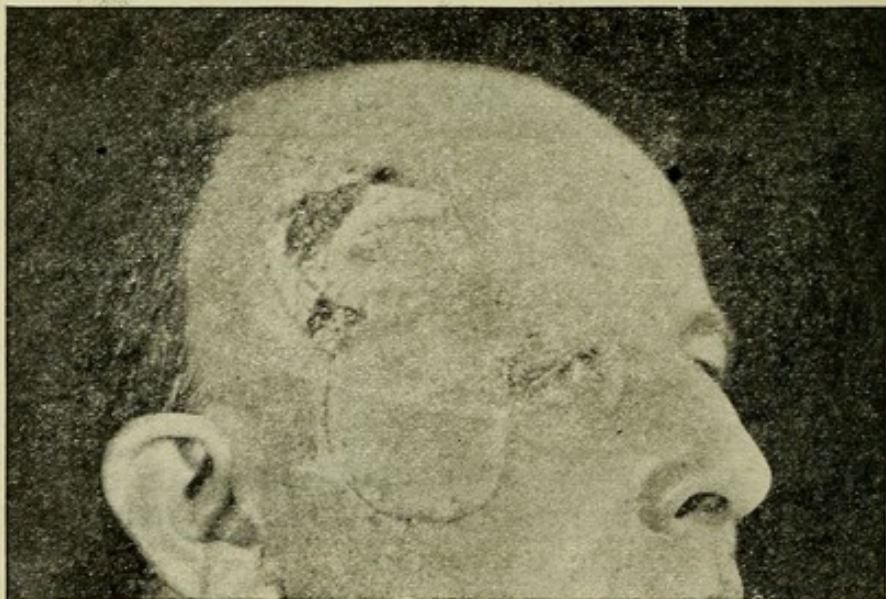Wounds of the eyelids should be made aseptic and sutured with care to prevent cicatricial distortion.

One of the ugliest of the deformities of the eyelids is eversion of the lid caused by cicatricial contrac-



Showing flap taken from arm, by Italian method, to cover raw area, in supra-orbital region left after excision of hypertrophied skin.

tion following burns, lupus, or ulceration. Thoughtless surgeons sometimes cause this deformity by re-



Epithelioma near outer canthus removed, the space filled in with flap from temple, shavings of skin applied to surface left by transfer of the flap.

moving tumors of the face and placing their incisions so that cicatricial contraction drags the lower lid downwards or the upper lid upwards. This contingency should always be recollected in operations in the neighborhood of the eyelids. If the incisions cannot be placed in such a way as to make the drag of the cicatrix operate so as not to disturb the position of the eyelids, a plastic procedure to transfer the tension to another position should be adopted after the excision of the growth. Adhesion of the eyelids to the eyeball after burns of the conjunctiva are very difficult to repair with satisfaction. Many of them, however, may be relieved by plastic operations upon the conjunctiva or the transplantation of skin or mucous membrane. These conditions of symblepharon tax the ingenuity of the surgeon. Ankyloblepharon is another deformity difficult to deal with surgically. In it the two eyelids are united by cicatricial adhesion. Various operations have been devised and are more or less successful.

The plastic procedures required to make new eyelids, after their removal by sloughing or accident, or to fill in a space left by the replacement of an eyelid which has been dragged outwards so as to cause ectropion, must be performed in accordance with the principles of plastic surgery already laid down. The various forms of skin-grafting will be of some value, but as a rule it is necessary to turn a flap of skin and subcutaneous tissue into the gap left by the incisions made for restoring the eyelid. The space left by the removal of this flap may then with advantage be covered with skin-grafts. It is usually better to thus utilize the skin-grafting process for covering the wound left by the transference of the flap than to depend on it for lessening the tendency to cicatricial contraction at the point of operation.

SUGGESTIONS FOR THE RECON- STRUCTION OF SYPHILITIC NOSES.

Nasal deformity from syphilitic destruction of bone and cartilage is a very frequent result of the tertiary stage of the disease. This disfigurement varies in extent and character, but is always very noticeable because of the importance of the nose in facial contour. The mental distress of the patient is usually acute, because the disfigurement is associated in the public mind with a loathesome and disgraceful disease. The fact that syphilis may be inherited or be acquired in an innocent manner avails little in the public's estimate of a person carrying ever upon his countenance the well-known mark of sexual impurity. Nearly every other lesion of syphilis may be concealed from public observation, or may at least be attributable to diseases of a less dishonorable nature. The patient with the sunken or distorted nose of syphilis has, however, scarcely any shield to protect him from impertinent scrutiny and the innuendo that his tissues are contaminated with the scourge usually due to to unchastity.

These circumstances make the condition one to appeal to the sympathy of the surgeon, whose every effort should be given to the consideration of adequate operative relief.

My attention has been forcibly directed to this surgical problem, because I have recently seen more than one patient who had in vain applied for relief to the general surgeon and nasal specialist. For years past the correction of deformities of the face has been of increasing interest to me; and I have been more and more gratified at the results

obtainable by intelligent operative measures. The literature of this surgical field has become quite voluminous, but it will be found to repay those who take time to study it.

Syphilitic deformities of the nose may be roughly divided, for the present purpose, into: 1, those in which one or both alae, the lobule, the columella, or other parts of the external nose have ulcerated away; 2, those in which the internal supports of the cartilaginous nose have been destroyed and the middle of the organ has fallen inward, causing a transverse depression below the nasal bones; and 3, those

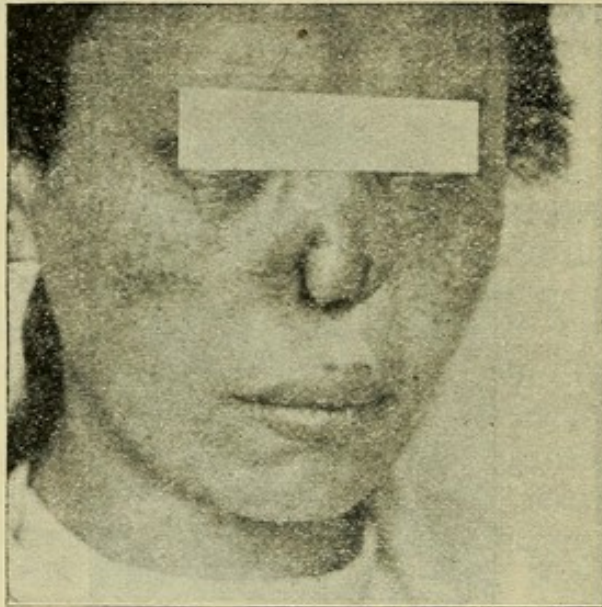


Destruction of alae and lobe of nose, due to syphilis.

in which a similar internal destruction has been followed not only by the transverse depression, but a cicatricial invagination of an ala, both alae, or the end of the nose. The more serious cases may be complicated with necrotic perforation of the hard palate, loss of portions of the alveolar process of the upper jaw, cicatricial changes from ulcerative destruction of the soft palate, and even actual loss of portions of the sunken or retracted external nose. The first group contains the cases which are improved by the comparatively simple plastic procedures; and hence they are not often refused treatment. It is not difficult to make a new ala out of

the tissues of the cheek by cutting a flap with its pedicle at the side of the nose, and swinging it around into the gap in the outer wall of the naris. A columella may be constructed with sufficient ease by cutting a column of skin and muscle from the middle of the upper lip and turning it upward. One operation, supplemented by a little trimming or modelling of the parts at a later date, is usually sufficient to ensure a fair reconstructive result.

The patients, who belong to the second and third groups, are those who meet with discouragement

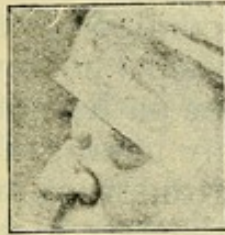

Destruction of alae, columella and portion of hard palate, due to syphilis.

when they apply for surgical relief; and yet much, very much, may be done to lessen the horrid deformity of countenance and to alleviate the despondency due to the consciousness of facial ugliness. I have seen evidence that some members of the medical profession believe that these syphilitic noses should go untouched, because the constitutional taint may militate against healing after operation wounds. This opinion is fallacious. It would not be proper to operate on a nose the seat of active syphilitic inflammation; but, after the active process has ceased, incisions heal as promptly in syphilitics as in

healthy persons. I have never seen any more reason to hesitate to cut bone, cartilage and skin in the former than in the latter class of patients.

The simplest form of sunken nose is that in which the organ has caved in, as it were, at the middle of the dorsum. Thus the lobule is thrown upward, the plane of the openings of the nostrils is more or less vertical instead of horizontal, and projection of the cartilaginous nose is greatly reduced. To remedy the deformity, the tip of the nose must be brought downward and forward. This is usually to be done by a free transverse cut across the nose at the point of greatest depression. This incision permits the operator to pull the lobule and alae downward, until the tip of the nose stands out prominently from the plane of the face, and the nostrils with the inter-



Reconstructed nose after syphilitic deformity. This nose was much sunken before operation.

vening columella lie in a horizontal plane. The detachment of the lower part of the organ from the nasal bones above and its reposition leave an opening into the nasal chambers extending across the middle of the face. This space must be filled with flaps of tissue, sufficiently large not to draw the lower part of the nose upward when healing takes place, and sufficiently rigid to maintain a straight or a nearly straight line along the dorsum or bridge of the nose.

Various methods of operating have been devised. Some surgeons have inserted metallic supports, with legs resting on the nasal bones or the frontal bone above and on the superior maxillary bones below. These foreign bodies are not very desirable

occupants of reconstructed syphilitic noses. I prefer to build, of superimposed flaps, a thick fibrous wall which will maintain its shape; or else to hold such a reconstructed wall in proper shape by some form of inconspicuous spring attached to a spectacle frame.

Recently I operated on such a case with gratifying results, by turning into the gap two pairs of cheek flaps and bringing down two flaps from the forehead. The first cheek flaps were turned into the gap with the skin surface toward the nasal cavity. Subsequently two flaps were made from the frontal tissue between the eyebrows and rotated downward on top of the cheek flaps. At a still later period two more cheek flaps were cut and rotated on the top of the new portion of nose. Minor operations were needed to properly adjust these various masses of borrowed skin and connective tissue and others will be required. The result, however, justifies the time and annoyance to the patient of so many operations. She is now one of my most grateful patients.

In all such nasal reconstructions, the patient should know at the start that six months or a year is not too long a time to devote to the operative relief. Each step must be followed by a period of inactivity to allow cicatricial influences to show their effects. The surgeon must be guided by the experience obtained in each patient, and can not promise exactly when he will operate again or what he will do as the next step.

Some years ago I satisfactorily slipped a triangular flap down from the forehead, and pinched it up into a fair-looking dorsum with an eyeglass spring attached to a pair of spectacles supported by the ears.

Another method which might be employed is that used by Keegan in rhinoplasty for amputated nose. He dissects the tissue from over the nasal bones and turns it downward into two flaps, which then lie with their raw surfaces upward. Over these might

be placed two flaps made from the cheeks or a frontal flap similar to, but smaller than, that used in making an entire cartilaginous nose. Other suggestions are to bring down a frontal flap after making a groove down the middle of the upper part of the nasal bridge, by splitting the soft tissues in the middle line and drawing them aside; to make a small frontal or frontonasal flap, perhaps containing periosteum or a thin layer of bone, and thrusting it downward through a transverse button-hole or tunnel made in the tissues covering the lower end of the nasal bones; to detach one of the nasal bones and displace it downward; to chisel loose the nasal bones and pry them forward; to cut the edge of the superior maxillary bone with a chisel and bend it forward.

If there is an opening in the hard palate, an obturator must be made close to it. In this event it might be possible to attach a long lever to the nasal surface of the artificial palate and let it hold up the flaccid new part of the nose. The end of this lever might be provided with a narrow pad to act as a sort of ridge pole to the nasal roof; and the lever might be provided with a spring joint like that controlling the blade of a pocket knife. The patient could then adjust the obturator in the mouth and push the lever and its pad into position by a probe or hook introduced through the nostril.

Sunken noses not requiring such extensive operative treatment might perhaps be improved by two cheek flaps turned up and thrust through subcutaneous tunnels extending from the sides of the nose to the middle line. This maneuver would fill up a slight hollow on the dorsum of the nose. It might be utilized also in congenital saddle-back nose, which has a hollow in the dorsum of the organ.


Syphilitic noses in which much tissue has been lost must be treated by rhinoplastic operations, which will bring a sufficient bulk of tissue to give opportunity for modelling. The new tissue may be

taken from the forehead, the cheeks, the arm, or the palm of the hand. A large flap from the abdomen or thigh may be attached to a raw surface made on the hand; and afterward be transferred to the face.


After a crude resemblance of the nose has been thus made, minor operations will shape it so as to improve the outline and provide alae and columella. The ala may be lined to prevent cicatricial occlusion, by a strip of mucous membrane cut from the inside of the upper lip, and thrust through a button-hole made in the upper part of the lip.


The incisions made in the plastic restorations of syphilitic noses may be free, and usually must be so; but the scars become in time scarcely perceptible. Even if they are evident to close observers, they are much less disfiguring than the lesion, for relief of which they were demanded.


Many persons, both in and out of medical circles, believe that syphilitic nasal deformity is incurable. This is an error and should be combatted by practitioners everywhere. Aseptic methods, carefully planned and well executed operations, and judicious after-treatment hold out the same hope of benefit as in other departments of surgery. The degree of benefit varies only with the complicated character of the problem. Many patients may be very satisfactorily relieved of the greater part of the unsightly deformity; and there are very few who can not have their condition considerably ameliorated. It is sad to meet in one's daily walks so many deformed noses that could readily be improved.



Faint, illegible text, likely bleed-through from the reverse side of the page. The text is arranged in several paragraphs, but the characters are too light and blurry to be transcribed accurately.







Y 12 1906

