

Atlas and epitome of operative gynecology / by Oskar Schaeffer.

Contributors

Schaeffer, Oskar, 1863-
Francis A. Countway Library of Medicine

Publication/Creation

Philadelphia : W.B. Saunders, 1904.

Persistent URL

<https://wellcomecollection.org/works/zwn6enj6>

License and attribution

This material has been provided by This material has been provided by the Francis A. Countway Library of Medicine, through the Medical Heritage Library. The original may be consulted at the Francis A. Countway Library of Medicine, Harvard Medical School. where the originals may be consulted. This work has been identified as being free of known restrictions under copyright law, including all related and neighbouring rights and is being made available under the Creative Commons, Public Domain Mark.

You can copy, modify, distribute and perform the work, even for commercial purposes, without asking permission.




Wellcome Collection
183 Euston Road
London NW1 2BE UK
T +44 (0)20 7611 8722
E library@wellcomecollection.org
<https://wellcomecollection.org>



SAUNDERS'

MEDICAL HAND-ATLASES.



THE series of books included under this title are authorized translations into English of the world-famous

Lehmann Medicinische Handatlanten,

which for **scientific accuracy, pictorial beauty, compactness, and cheapness** surpass any similar volumes ever published.

Each volume contains from **50 to 100 colored plates**, besides numerous illustrations in the text. The colored plates have been executed by the most skilful German lithographers, in some cases more than twenty impressions being required to obtain the desired result. Each plate is accompanied by a full and appropriate **description**, and each book contains a condensed but adequate **outline of the subject** to which it is devoted.


One of the most valuable features of these atlases is that they offer a **ready and satisfactory substitute for clinical observation**. Such observation, of course, is available only to the residents in large medical centers; and even then the requisite variety is seen only after long years of routine hospital work. To those unable to attend important clinics these books will be absolutely indispensable, as presenting in a complete and convenient form the most accurate reproductions of clinical work, interpreted by the most competent of clinical teachers.


While appreciating the value of such colored plates, the profession has heretofore been practically debarred from purchasing similar works because of their extremely high price, made necessary by a limited sale and an enormous expense of production. Now, however, by reason of their projected **universal translation** and reproduction, affording international distribution, the publishers have been enabled to secure for these atlases the **best artistic and professional talent**, to produce them in the **most elegant style**, and yet to offer them at a **price heretofore unapproached in cheapness**. The great success of the undertaking is demonstrated by the fact that the volumes have already appeared in **thirteen different languages**—German, English, French, Italian, Russian, Spanish, Dutch, Japanese, Danish, Swedish, Roumanian, Bohemian, and Hungarian.


The same careful and competent **editorial supervision** has been secured in the English edition as in the originals. The translations have been edited by the **leading American specialists** in the different subjects. The volumes are of a uniform and convenient size ($5 \times 7\frac{1}{2}$ inches), and are substantially bound in cloth.

(For List of Books, Prices, etc., see back cover and fly-leaf)

Pamphlet containing specimens of the Colored Plates sent free
on application







ATLAS AND EPITOME
of
OPERATIVE GYNECOLOGY

BY
DR. OSKAR SCHAEFFER

Privatdocent of Obstetrics and Gynecology in the University of Heidelberg

AUTHORIZED TRANSLATION FROM THE GERMAN
WITH EDITORIAL NOTES AND ADDITIONS


EDITED BY
J. CLARENCE WEBSTER, M.D. (Edin.), F.R.C.P.E., F.R.S.E.

Professor of Obstetrics and Gynecology in Rush Medical College, in Affiliation
with the University of Chicago; Obstetrician and Gynecol-
ogist to the Presbyterian Hospital.

*With 42 Colored Lithographic Plates and
Many Text-illustrations, Some in Colors*

PHILADELPHIA, NEW YORK, LONDON
W. B. SAUNDERS & COMPANY

1904



4205

Copyright, 1904, by W. B. Saunders & Company.

Registered at Stationers' Hall, London, England.

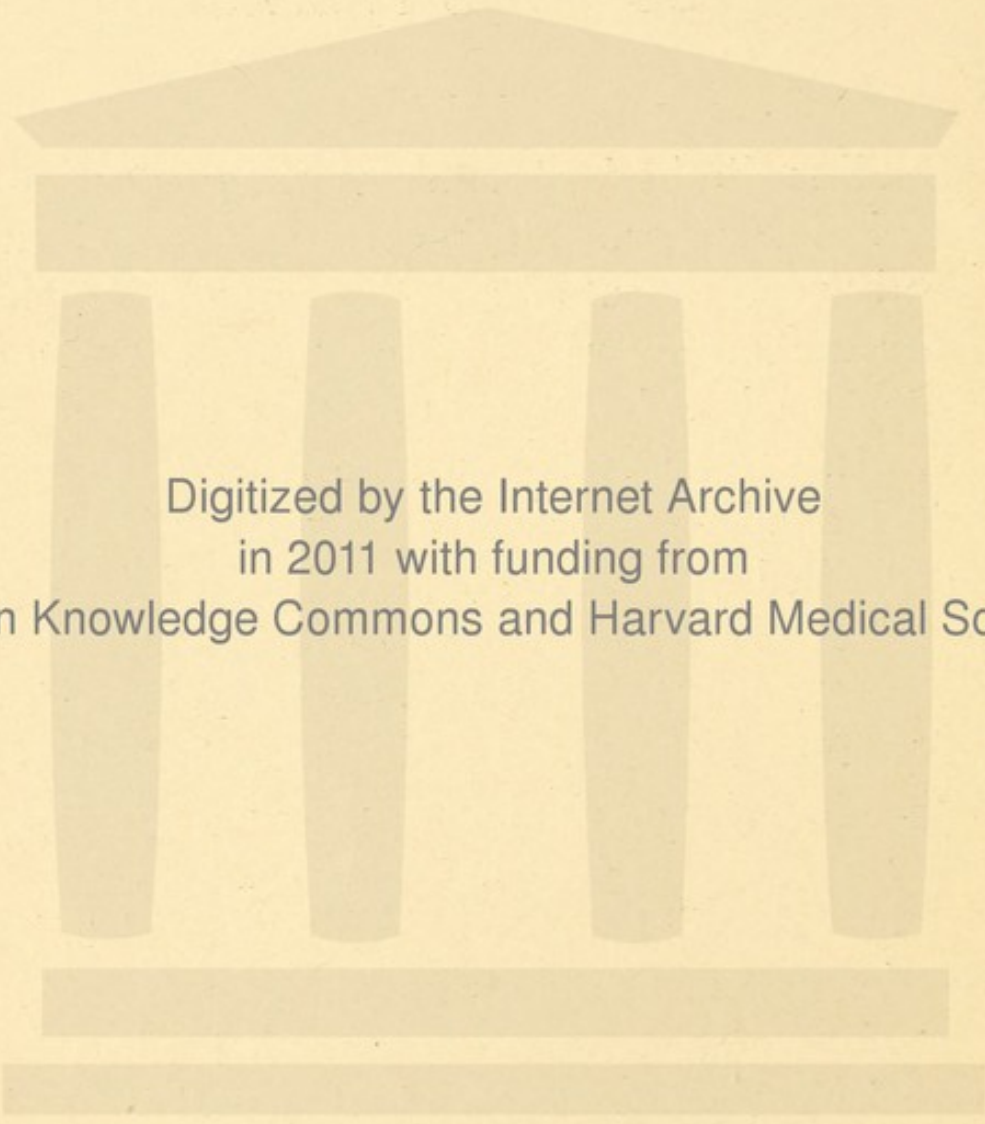
ELECTROTYPED BY
WESTCOTT & THOMSON, PHILADA.

PRESS OF
W. B. SAUNDERS & COMPANY.

EDITOR'S PREFACE.

IN all medical schools students who graduate each year know less about gynecologic operations than about almost any other department of operative surgery. Amphitheater demonstrations are valuable only to the few who are fortunate enough to be placed very near the field of operation. In several European schools courses are given to limited numbers in which certain operative procedures are practised on genitalia removed from bodies and fastened into manikins. The value of the method is very restricted, even for the few students who have the opportunity of employing it. In a large medical school, owing to the difficulty of obtaining material, it cannot benefit the great body of students. For many years teachers have been forced to depend largely upon pictorial representation in demonstrating gynecologic operations.

The author, a well-known German teacher, has made a specialty of demonstrating by illustrations, and issues this volume as an aid to those who wish to study the surgical part of gynecology. The work represents mainly the experience and practice of Dr. Schäffer, and is not to be regarded as a comprehensive text-book. The editor holds himself in no way responsible for the general plan or for the details.



Digitized by the Internet Archive
in 2011 with funding from
Open Knowledge Commons and Harvard Medical School

PREFACE.

EIGHT years have now elapsed since the appearance of the first of these atlases, the plans for which were somewhat tentatively sketched by the publisher and the author, because the technic had to contend with a number of difficulties; but even at that time the *Atlas of Gynecologic Technic* which is now presented to the reading public was included in the general plan of the undertaking. Much patient endeavor has been expended by the author, the artist, and the lithographer in the preparation of this series of water-colors and pen-and-ink drawings. They are based on hundreds of photographs taken from nature, and, it is hoped, reproduce as faithfully and in as instructive a manner as possible the various surgical situations which they are intended to illustrate. As we gained in experience and became accustomed to working together and to the peculiarities of the subject, the sketches improved in quality and gained in accuracy; and we, therefore, crave indulgence for the crudities and irregularities which, we are well aware, characterize some of the earlier pictures. A mass of original material had to be collected, for which I was thrown entirely on my own resources. My thanks are due to Mr. A. Schmitson, the artist, whose devotion to the work and ability, not only in handling the pencil and the camera, but also in entering into the

technical details of the various operative procedures and in reproducing the colors of the tissues, it gives me the greatest pleasure to acknowledge. The many technical difficulties attending the reproduction of the pictures have been successfully overcome, thanks to the well-known energy and unwearying devotion of the publisher, Mr. J. F. Lehmann.

It is the hope of the author that this atlas, as well as the earlier ones, will prove a useful aid in the study of operative gynecology by means of the object-lessons it contains, particularly as it is impossible to demonstrate the individual steps of an operation clinically to the majority of the students on the benches. The plan invented by von Winckel, of using an "operative phantom," marks a distinct improvement in didactic methods, but the desiccated condition of the anatomic specimens and the loss of the natural color greatly detract from the value of the method. Pictures and "phantom" are mutually complementary.

The text closely follows the illustrations. No attempt whatever has been made to give an exhaustive exposition of the subject or to include all possible complications.

DR. O. SCHAEFFER.

CONTENTS.

	PAGE
INTRODUCTION	17

I. Operations that are Performed without the Speculum.

TOPOGRAPHIC AND SURGICAL ANATOMY OF THE PELVIC FLOOR	17
OPERATIONS ON THE VULVA	24
1. Complete Plastic Operation on the Perineum—Repair of a Complete Perineal Laceration	26
2. Repair of Incomplete Perineal Lacerations	33
3. Episiotomy	43
4. Extirpation of Portions of the Vulva or of the Hymen .	43
5. Operations to Correct Incontinence of Urine	44
6. Resection of the Urethra	45

II. Operations Requiring for their Performance Exposure of the Vagina.

TOPOGRAPHIC AND SURGICAL ANATOMY OF THE VAGINA AND OF PORTIO VAGINALIS	46
1. Posterior Kolporrhaphy or Kolpoperineorrhaphy . . .	49
2. Posterior Kolporrhaphy	52
3. Anterior Kolporrhaphy	56
4. Operation for the Narrowing of the Lumen of the Vagina	57
5. Kolpocystotomy for the Removal of Foreign Bodies from the Bladder, and Operation to Unite Traumatic Vesi- covaginal Fistulæ	59
5 a. Dilatation of the Urethra	59
5 b. Kolpocystotomy	61
5 c. Method of Closing a Vesicovaginal Fistula	62
6. Operation for the Cure of Rectovaginal Fistula	65

	PAGE
7. Dissection of the External Os	67
8. Emmet's Operation for the Repair of Commissural Lacerations	68
WEDGE-SHAPED EXCISIONS FROM THE CERVIX	69
9. Wedge-shaped Excision from the Wall of the Portio Vaginalis	69
10. Schröder's Wedge-shaped Incision	70
11, 12. Hysteroceleisis and Kolpocleisis	71
 III. Operations Performed after Artificial Dilatation of the Cervical Canal of the Uterus.	
TOPOGRAPHIC AND SURGICAL ANATOMY OF THE CERVIX AND VAULTS OF THE VAGINA	72
1. Sounding the Uterus—Bloodless Dilatation of the Cervix	78
2. Curetment (Abrasio Mucosæ; Curettage; Raclage)	81
3. Removal of Polyps	83
4. Vaporization of the Uterine Cavity (Atmokausis)	83
 IV. Operations Performed after Dissecting away the Vault of the Vagina and Enlarging the Cervix by Operative Means.	
1. Division of the Anterior Wall of the Cervix	85
2. Ligation of the Uterine Artery	89
3. Supravaginal Amputation of the Cervix	92
4. Operation for the Closure of Cervicovesical and Cervico-ureteral Fistulæ	94
5. Method of Opening Abscesses in the Parametria (Pelvic Abscess)	96
 V. Operations that Require Opening of the Vesico-uterine Fossa.	
1. Anterior Kolpoceliotomy	97
2. Vaginifixation (Vaginifixura Vesicofixatio Uteri)	98
3. Operations that can be Performed on the Uterus with the Aid of Anterior Kolpoceliotomy	101
4. Operations on the Adnexa	102

VI. Operations that are Performed through the Posterior Pouch of Douglas.

	PAGE
1. Posterior Kolpoceliotomy and Retrofixation of the Cervix	105
2. Operative Treatment of Ectopic Gestation and its Consequences	106
3. Operative Treatment of Abscesses in the Pouch of Douglas	107

VII. Operations Performed after Opening One or Both Peritoneal Pouches and an Entire Wall of the Uterus

109

VIII. Total Extirpation of the Uterus through the Vagina by Opening the Anterior and Posterior Peritoneal Pouches

111

IX. Operations on the Genital Organs that Require a Celiotomy.

TOPOGRAPHY AND ANATOMY OF THAT PORTION OF THE GENITAL ORGANS EXTENDING INTO THE PERITONEAL CAVITY.	114
1. The Oblique Incision in the Hypogastric-inguinal Region	121
2. The Transverse Incision in the Suprapubic Region . . .	121
3. Celiotomy with an Ordinary Median Incision through the Abdominal Wall	122
4. Abdominal Hysterectomy	125
5. Supravaginal Abdominal Hysterectomy for Myoma . . .	127
6. Ventrofixation of the Uterus	128


X. Alexander-Adams Operation, Performed after Exposure of the Inguinal Canal.

TOPOGRAPHIC AND SURGICAL ANATOMY OF THE INGUINAL REGION.	129
ALEXANDER-ADAMS OPERATION FOR SHORTENING THE ROUND LIGAMENT	130

INDEX	133
-----------------	-----

LIST OF PLATES.

	PAGE
Plate 1.—Repair of a Complete Perineal Laceration	26
Plate 2.—Repair of a Complete Perineal Laceration	28
Plate 3.—Kolpoperineorrhaphy with Retrofixation of the Neck	48
Plates 4-8.—Kolpoperineorrhaphy with Retrofixation of the Cervix	50
Plate 9.—Anterior Kolporrhaphy (Denudation after Hegar) . .	58
Plate 10.—High Vaginorrhaphy	58
Plate 11.—Removal of Foreign Body from the Bladder through the Dilated Urethra	60
Plate 12.—Method of Closing a Vesicovaginal Fistula	62
Plates 13, 14.—Method of Closing a High Rectovaginal Fistula .	64
Plate 15.—Double Wedge-shaped Excision of the Cervix in Chronic Metritis	68
Plate 16.—Wedge-shaped Excision in Eversion and Cervicitis .	70
Plates 17-19.—Supravaginal Amputation of the Cervix	86
Plates 20-23.—Enucleation of a Polypous Fibromyoma after Division of the Anterior Wall of the Cervix .	86, 88
Plate 24.—Anterior Kolpoceliotomy	96
Plate 25, Fig. 1.—Anterior Kolpoceliotomy	98
Fig. 2.—Vaginifixation of the Uterus after Kolpoceli- otomy	98
Plates 26-28.—Ovariectomy after Anterior Kolpoceliotomy .	98, 102
Plates 29-33.—Total Extirpation of the Uterus through the Vagina	110, 112
Plates 34-37.—Abdominal Hysterectomy	124
Plates 38-41.—Abdominal Hysterectomy in a Case of Myoma of the Uterus	126
Plate 42.—Abdominal Hysteropexy or Ventrofixation of the Uterus	126



OPERATIVE GYNECOLOGY.

INTRODUCTION.

THE technic of the individual gynecologic operations depends very much on the methods adopted to bring the diseased portions into view and to prepare them for operative intervention. It is a noteworthy fact that modern gynecology and its operative technic were made possible only by the invention of bivalve and spatular specula, double tenacula, and shepherd's crook hooks, with the aid of which the internal portions of the genitalia are brought into view. These inventions we owe to Simon and Marion Sims.

It therefore appears to me appropriate in an atlas designed to represent the technic as it appears to the eye, to classify the operations not according to the parts of the organs on which they are performed, but according to the methods of gaining access to them for the purpose of operation.

I. OPERATIONS THAT ARE PERFORMED WITHOUT THE SPECULUM.

Topographic and Surgical Anatomy of the Pelvic Floor.

THE anatomic region here concerned includes, of course, the external genitalia in the ordinary restricted

sense of the term, the vulva, and, in addition, in a broader sense, the anal, symphyseal, and inguinal regions of both sides. The latter are included for pathologic as well as for anatomic reasons, for they not only contain the insertions of the round ligaments which must be found in the operation of shortening the round ligament for the purpose of correcting the retroflexion of a mobile uterus, but also the inguinal glands which receive infective organisms from the vulva, as well as metastatic cells from malignant tumors of the vulva. A portion of the vagina can be seen without a speculum, especially if the hymen has been destroyed, by simply separating the labia with the fingers. The internal boundary of the visible portion corresponds to the two folds on the walls of the vagina formed by the levator ani (*levatores ani et trigoni urethrogenitalis*—Waldeyer) muscles and by the approximation of the two *columnæ rugarum vaginae*. The line thus formed approximately maintains the same relation with the skeleton when the soft parts are relaxed or prolapsed, but not with the soft parts themselves. The walls of the vagina follow any downward pouchings of the bladder or rectum, and, in conditions of relaxation, it is the latter that form the internal boundary of the visible field.

Assuming that the topography of the external parts is sufficiently well known, we shall call attention to a few points in connection with the surgical topography of the inner urethral and perineal region.

The perineum is the most important structure that engages our attention, both on account of its size and of its important position at the outlet of the pelvis, of whose floor it forms part. It represents the continuation of the

rectovaginal septum that has increased in size and become reinforced by strands of strong connective and muscular tissue, and acts as a support for the pelvic viscera, directly for the ampulla of the rectum, and indirectly for the upper portion of the rectum, the ligaments of the uterus, the vault of the vagina, and the bladder, although these organs find their direct support in the more or less movable tissues of the pelvic connective tissue. (See *Atlas of Obstetrical Diagnosis and Treatment*, Plate 8, Fig. 18.)

[It cannot be too strongly emphasized that the perineum has no distinct anatomic entity, but is the anterior portion of the sacral segment of the pelvic floor. It is really the central area of strength in the floor, being the meeting-place of important divisions of the pelvic fascia and of various muscles.—ED.]

The pelvic floor derives its chief strength and elasticity from the fasciæ and from the fibers of the levator muscles, which separate the upper, movable portions of the viscera from the lower or fixed tissues. These structures are included in the term "supradiaphragmatic," first employed by Waldeyer; while the "infradiaphragmatic" structures are either closely adherent to the bone, like the internal obturator muscles and the crura of the clitoris, or firmly embedded in muscular and fatty tissue, like the *pars trigonalis* of the urethra, the *pars perinealis* of the rectum immediately below the ampulla. A certain portion of the internal boundary-line of the vagina above referred to may also be included. The openings of the three hollow viscera are situated in the subcutaneous tissue and quite movable. (See *Atlas of Obstetrical Diagnosis and Treatment*, Plate 31, Figs. 68, 69.)

This "diaphragm," which closes the lower outlet of the pelvis and supports the pelvic structures, is convex on its lower surface. Above, it is in immediate relation with the intestines and is formed by the union of the visceral pelvic fascia and its reflection into the parietal pelvic fascia, which is designated the superior diaphragmatic fascia of the pelvis; lower down the levator ani muscle and the inferior diaphragmatic fascia of the pelvis, which invests that muscle on its outer aspect and whose reflection joins the fascia of the obturator internus, enter into the formation of the "diaphragm."

Between these fasciæ are the *levator ani muscles*, and more posteriorly, completing the diaphragm, the coccygeal and pyriform muscles. The levator muscle takes its origin in a curved line extending from the lower third of the symphysis across the obturator foramen as far back as the spine of the ischium. It divides into two portions, and, after passing to the lower third of the vagina and below the ampulla of the rectum, which it embraces in part with a loop of fibers, is inserted into the anterior surface of the coccyx by means of the sacrococcygeal and anococcygeal ligaments and directly into the lateral border of the bone.

The *coccygeal muscles* follow the course of the sacrospinal ligaments from the spine of the ischium to the lateral border of the sacrum and coccyx, where they are joined above by the pyriform muscles which have their origin at this point; the latter pass out of the pelvis by the great sacrosciatic foramina and are inserted into the great trochanters.

The levator ani muscles derive material support, both

laterally and from below, from the obturator fasciæ and their muscles, which closely invest the lateral wall of the pelvis. In front the obturator fasciæ merge into the fasciæ of the *musculus trigoni urogenitalis* of Waldeyer. The fasciæ of the bulbocavernosus, transversus perinæi, and other muscles of that group are much less important; they are imperfectly developed, and inserted chiefly in loose connective tissue; nevertheless they are intimately connected with the above-described fascial apparatus. The anococcygeal ligament is analogous to the aponeurotic *trigonum urogenitale* and closes the pelvic cavity posteriorly. (See *Atlas of Obstetrical Diagnosis and Treatment*, Plates 17 and 31, Figs. 30 and 68.)

The hollow organs that pass through the outlet of the pelvis do not perforate the fasciæ; the latter, on the contrary, become reflected at these points, and at the same time frequently give off an investment for another muscle. These points, therefore, represent *loci minoris resistentiæ*; but the abdominal and pelvic viscera cannot descend at these points unless there takes place a simultaneous prolapse of the hollow organs referred to.

Other points of diminished resistance are found in the intervals between the individual muscles and portions of muscles that make up the above-described "diaphragm," chiefly on the side in the lateral portions of the pelvis and toward the coccyx, in the sciatic foramina. These intermuscular clefts are covered only by loose, fatty connective tissue and the pelvic fascia, or by pelvic fascia and peritoneum. Intramuscular gaps may also result from injuries.

Other natural openings are found at the points where

the obturator vessels and nerves, the vessels of the clitoris,—*i. e.*, the pudendal plexus between the clitoris and the symphysis,—emerge from the pelvis. The inferior gluteal vessels and nerves, the pudendal vessels, and the great sciatic nerve escape through the infrapyriform foramen,—that is, the cleft between the pyriform and coccygeal muscles,—while the suprapyriform foramen gives passage only to the superior gluteal artery.

These passages must be explored in cases of lateral or perineal hernias, thrombosis, abscess, metastatic tumors, when these processes have extended from the external genitalia inward and upward or from within outward.

The larger trunks, both venous and arterial, that convey the blood into and away from the pelvis are, therefore, to be sought in the localities just described; the smaller branches, on the other hand, ramify chiefly on the lateral walls of the hollow organs. The clitoris and the bulbi vestibuli especially enjoy an abundant blood-supply. The larger branches of the internal pudendal arteries, accompanied by the corresponding branches of the perineal nerves (*nervi labii posterioris*) and the dorsal nerves of the clitoris, pass along the internal obturator muscle and the *trigonum urigenitale*,—in other words, in a sagittal direction,—and disappear on the dorsal surface to the inner side of the gluteus maximus and through the infrapyriform foramen.

Hence an incision beginning in the vagina and running between the anus and the tuberosity of the ischium, or the inner border of the internal oblique, even if deep enough to divide the levator ani muscle, cannot injure any large arterial or nervous trunks; such an incision

would divide only branches of hemorrhoidal arteries, veins, and nerves, practically all of which radiate around the anus.

The very numerous lymphatics of the vulva empty into the superficial inguinal glands.

The group of movable *infradiaphragmatic* hollow organs at the pelvic outlet accordingly includes that portion of the urethra which is below the *trigonum urogenitale*; that portion of the vagina which comes into view when the labia are separated and which is situated below the trigonum and the levator ani muscles and the rectum below these muscles and the ampulla.

Since the lower surface of the "diaphragm of the pelvis" is convex, there is between it and the pelvic wall an empty, compressible space which is filled with connective and fatty tissue and is known as the *ischio-rectal fossa*. An outrunner from this fossa, the pubic recess, becomes gradually narrower as it approaches the anterior wall of the pelvis and ends in a sharp point at the symphysis; toward the skin it is, however, covered by the *trigonum urogenitale*. As this fossa, which is filled with connective tissue, communicates with the openings in the diaphragm that have been described, pathologic processes originating within the latter spread by direct extension to the ischio-rectal fossa. (See *Atlas of Obstetrical Diagnosis and Treatment*, Plate 17, Fig. 30.)

The *rectum* in this region is covered by a layer of smooth muscle-fibers, and, in addition, is encircled by the *external sphincter ani*, a voluntary muscle, the fibers of which are inserted in the anococcygeal ligament and in the center of the perineum, and mingle with fibers of the

levator ani and bulbocavernosus muscles. In a similar manner the vagina and the urethra are surrounded by muscular fibers that are more or less capable of acting independently and run in a sagittal direction; they are the transversus perinæi, bulbocavernosus, and ischio-cavernosus muscles. These muscles are capable of constricting the vagina, hence the name, "constrictor cunni," which is also applied to them. (See *Atlas of Obstetrical Diagnosis and Treatment*, Plate 31, Fig. 69.)

[There is a difference of opinion among authors as to the relative importance of the fascial and muscular structures of the pelvic floor as regards the element of strength. It is generally held that the latter are most important, though it is highly probable that this view is incorrect.—ED.]

OPERATIONS ON THE VULVA.

Most operations on the perineum are performed for the purpose of repairing solutions of continuity in the tissues resulting from lacerations during labor. They are performed immediately after the injury to secure primary repair; or, more rarely, after the wound has begun to granulate, when healing by second intention is expected; or a plastic operation is performed, with or without excision of the cicatricial tissue, and with or without a flap. The best plan, whether for the purpose of obtaining the best possible healing or to make the course of the puerperium as easy as possible, or to insure the proper involution of the pelvic organs *in situ*, is to repair a recent perineal laceration without delay. Owing to the situation of the wound, infection is very apt to take place, while the

active absorption of the tissues during the puerperium readily brings about ascending lymphatic or phlebotrombotic inflammations of the pelvic structures. The gaping of the vulva that later takes place not only predisposes to vaginitis, but also favors prolapse of the walls of the vagina; and, if the ligamentary apparatus is not particularly strong, this may be followed by various forms of prolapsus—*e. g.*, of vagina, rectum, bladder, uterus, etc.

Three grades of perineal laceration are distinguished, according to the depth: (1) **Lacerations extending as far as the thick mass of the perineum.** As a subdivision of this variety I should like to mention a class of cases that are frequently overlooked, though pathologically of much importance—*viz.*, those in which the integument remains intact, but the tissues give way underneath. (2) **Lacerations extending as far as the external sphincter ani.** (3) **Complete perineal lacerations,** extending into the rectum. A special variety is represented by the rare accident known as a central laceration—*i. e.*, a laceration of the second degree in which the anterior portion of the perineum is preserved.

As the technic of the repair of a perineal laceration of the second degree is the same as that employed in placing the final sutures for the repair of lacerations of the third degree, the method of primary repair of a recent tear of that kind will first be given.

Plate 1.

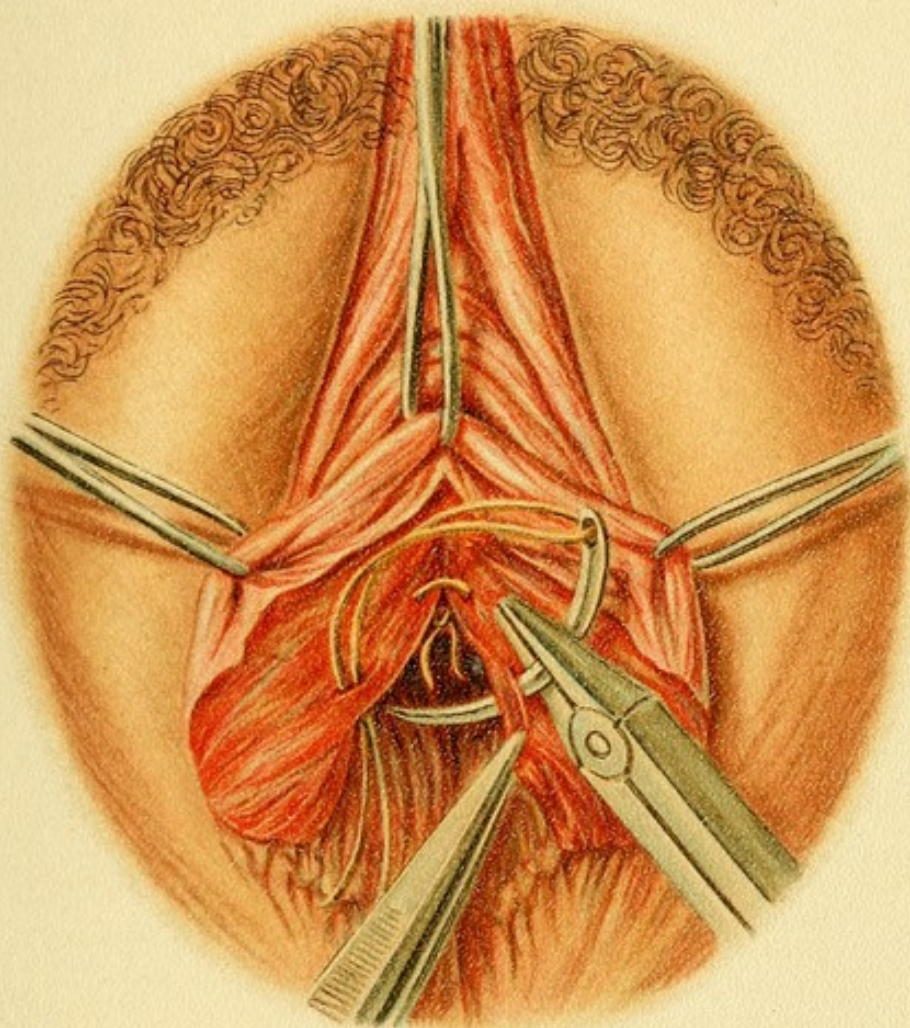
Repair of a Complete Perineal Laceration.—*Placing the Rectal Sutures.*—The wound has the shape of a butterfly. It is held open by means of three double tenacula, applied at the inner angle of the vaginal tear and at the edge of the vestibule. The sutures, which are of catgut, are introduced in such a way as to be tied in the rectum.

1. Complete Plastic Operation on the Perineum—Repair of a Complete Perineal Laceration.—(See Plates 1 and 2; and Fig. 1.)

The wound, which is held apart with hooks or double tenacula, has the shape of a butterfly (Plate 1), because the true rectovaginal septum, which is situated higher up, is narrower than the lower portions of the perineum, which rapidly broadens out below. The latter also heals rapidly, while the narrow part often becomes the seat of small abscesses or fissures during the process of repair. It follows from what has been said in regard to the anatomy that the chief object in the operation must be to bring the torn ends of the muscles, especially the levator ani and sphincter muscles and the median aponeurotic connections between the muscles, into perfect apposition with one another, and not to leave broad masses of connective tissue between them to stretch later on.

In placing and tying the sutures two peculiarities of the wound must be borne in mind: it has three openings through the integument, each of which must be closed with a row of sutures, and two of the latter meet at the above-mentioned narrow portion of the septum.

The rectal sutures are first introduced after the upper angle of the wound in the vagina and the outer tags of the frænulum perinæi have been seized with three double



tenacula, as shown in Plate 1. As these sutures are inaccessible after the entire wound is closed, they are to be tied at once in the lumen of the rectum; for the same reason an absorbable material, such as catgut, is chosen, or at least not a draining material like ordinary twisted silk. The needle must not be introduced too near the edge of the wound, to prevent the sutures from tearing through and producing stitch abscesses, thus imperiling the success of the operation. After the rectum has been thoroughly cleansed, the needle is introduced into the rectal mucous membrane, and, after taking in a goodly portion of the lateral tissues, is made to emerge in the wound; it is then reintroduced in the opposite wall of the wound surface and brought out again in the rectum. By pulling on the ends of the sutures the edges of the wound are brought into exact apposition, and the sutures are then tied with a double knot, care being exercised that the rectal mucous membrane is not turned into the wound. The first suture is placed at the highest point in the wound—that is, at the narrowest portion of the recto-vaginal septum; it is important that the suture should not lie too close to the vaginal mucous membrane, and that it be not drawn too tight, because necrosis at this point is followed by escape of the feces.

Single “interrupted sutures” like those described are surer than a continuous suture, but they must be at least $\frac{1}{2}$ cm. apart. The last suture in this row unites the ends of the external sphincter ani.

The second row of sutures closes the vaginal wound; the needle is again introduced from within outward as far as the frænulum perinæi; the sutures should not be tied

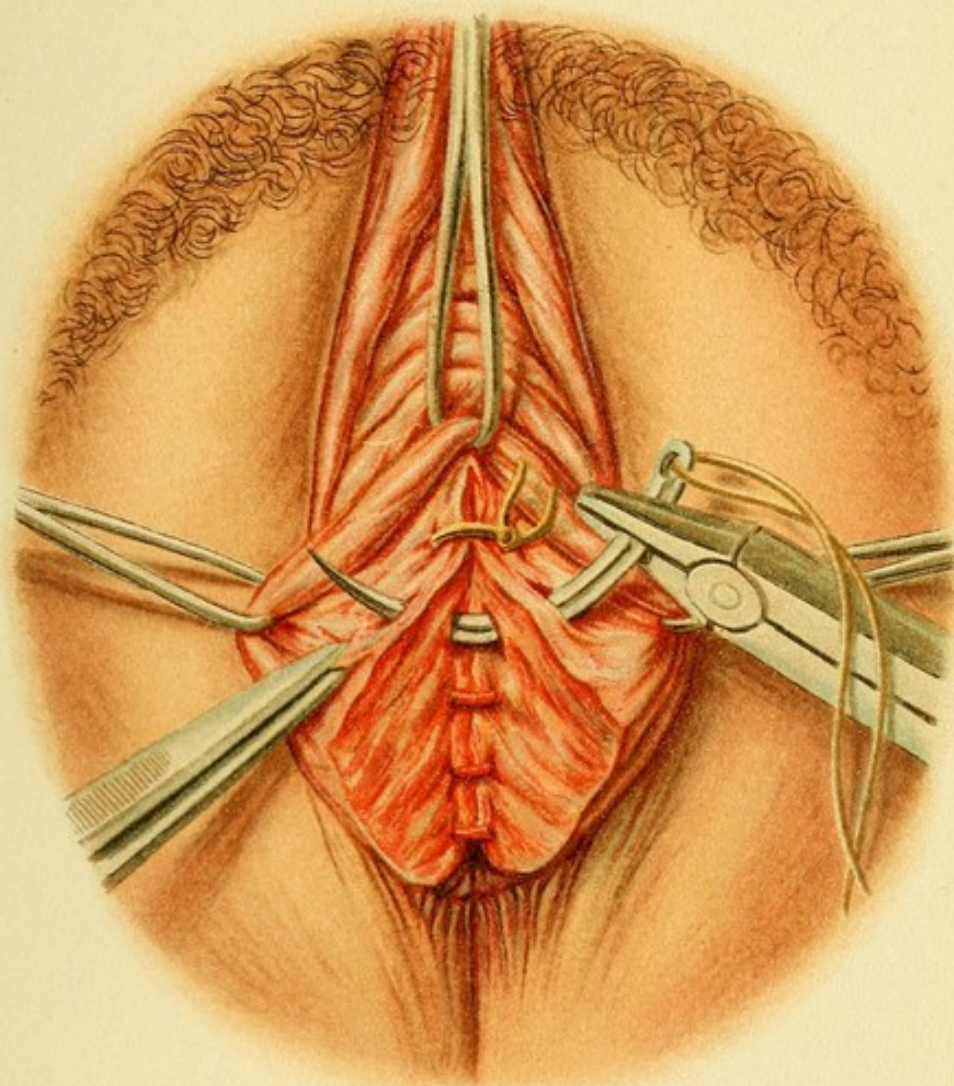
Plate 2.

Repair of a Complete Perineal Laceration.—*Placing the Vaginal Sutures.*—The rectal wound is closed. The vaginal sutures are introduced in a horizontal row as far as the frænulum perinæi, and should be of catgut. Buried catgut sutures are introduced at the broadest portion of the defect.

until they have all been placed (Plate 2). It is important that none of these sutures, especially at the narrowest point of the rectovaginal septum, should come in contact with the rectal sutures. Catgut should be used, and the sutures should be of the interrupted kind.

While these two rows of sutures are laid horizontally in the long axis of the organs, the third row must be placed vertically—that is, in the direction of the perineum (Fig. 1). It is for this reason that the vaginal sutures must not extend beyond the frænulum perinæi; if they were to be accidentally carried beyond that point, the operation might result in a low perineum and a widely gaping vagina projecting outward.

As the tissues in the broadest portion of the wound are often too massive for a single suture, it is advisable to introduce a few buried catgut sutures at this point (Werth)—in other words, to close the wound in several layers (“stages”). The true perineal sutures should include plenty of tissue at the sides, so as to bring the deeper portions of the perineal wound into apposition with one another, without subjecting them to the danger of necrosis. No pockets should ever be left in the tissues, as retention of the secretions is very apt to result in abscesses. Such recesses are readily recognized, before the sutures are introduced, wherever the torn or divided



ends of muscles retract the tissues ; and these ends must be brought together to insure a perfect restoration of the perineum to its original strength. The **needle**, to be introduced in the manner prescribed, must be curved, of good size, and made of good steel ; it is first held at right angles to the surface at the edge of the wound and then introduced with a broad lateral sweep (Fritsch). If the mass of tissue is more than the needle can hold, the latter is brought out in the bottom of the wound and reintroduced *as nearly as possible at the same point* ; this has the additional advantage that when the suture is drawn tight, the floor of the wound is pushed back.

The **material for suture** in this operation should be one that can be allowed to remain in place for some time, and one that does not drain, such as silver wire, aluminium-bronze (this is apt to tear through), or impregnated, non-draining thread, such as silk impregnated with a 10 per cent. solution of gutta-percha, as first suggested by the author ; celluloid twine (Braun, Pagenstecher) ; fil de Florence (silkworm-gut) ; reindeer-tendon ; kangaroo-tendon, and the like. For buried sutures catgut, or at most very thin linen or silk thread, should be used ; the former is absorbed, the latter frays out. [There can be little doubt that the buried sutures should always be easily absorbable catgut.—ED.]

The success of the operation depends quite as much on the preparatory and after-treatment as on exactness in technic.

The **preliminary treatment** consists in thorough evacuation of the bowel, which must be begun, in the case of plastic operations for the repair of old perineal

lacerations, several days beforehand and encouraged by keeping the patient on an exclusively liquid diet. The

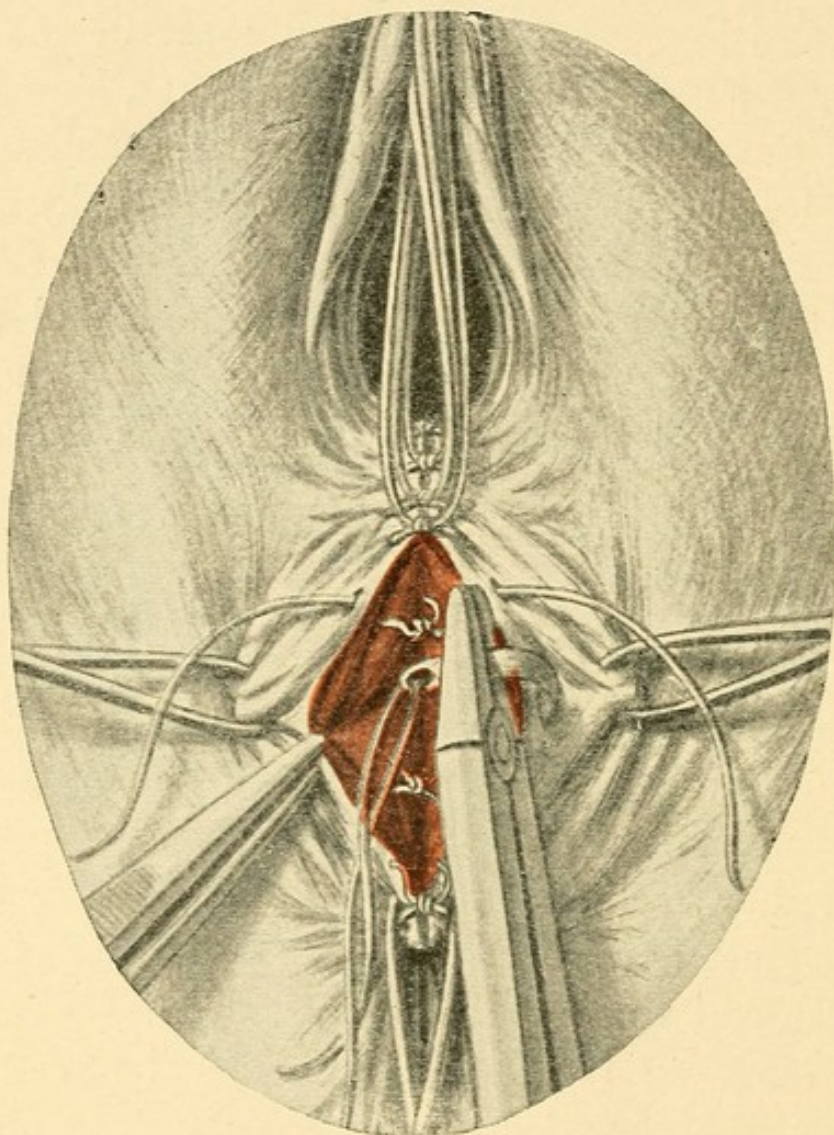


FIG. 1.—Repair of a complete perineal laceration (placing the perineal sutures). The vaginal sutures are held up out of the way. Observe the method of introducing the needle; it is applied perpendicularly to the surface near the edge of the perineal wound; it is then introduced with a broad lateral sweep, and carried down below the floor of the wound. In the depths of the wound the knots of the buried catgut sutures are seen.

parts around the operative wound, including the rectum, are thoroughly cleansed and disinfected, the vulvar hair being shaved for this purpose. The rectum often does

not well endure the application of corrosive sublimate ; if a preparation of mercury is insisted upon, the oxycyanid should be selected, otherwise cresol soap ("Seifenkresol") may be used.

The **after-treatment** consists, above all, in absolute rest in the dorsal position ; the woman's thighs should be bound, but not too tightly, so as to avoid the accumulation of secretions in the pudendal region. During the first few days it is well to catheterize, with the usual precautions. [Many operators allow the patient to pass urine, if she can, spontaneously, the vulva and perineum being thereafter irrigated with an antiseptic solution or covered with a moist antiseptic dressing.—ED.] If the patient has been properly prepared, it is usually unnecessary to give opium to prevent a bowel movement for five days ; in some cases a few drops of tincture of opium may have to be given after a few days. If during this period the diet has been principally liquid, a semisolid stool usually takes place at this time, either spontaneously or after the administration of a mild laxative. [Many prefer to introduce carefully into the anus before the first movement a small quantity of olive oil and glycerin.—ED.]

The wound is not to be touched, nor is the vagina to be irrigated ; it must, however, be thoroughly washed and carefully wiped clean after every pollution, and at least three times a day ; the entrance to the vagina and the perineal region are then covered with an antiseptic drying powder, such as airol, europhen, itrol, iodoform, iodoformogen, nosophen, vioform, or possibly dermatol. If the patient complains of burning or if the edges of the wound become swollen, lead-water or aluminium acetate

may be applied, or one or two sutures may even be removed. The final removal of the perineal sutures usually takes place between the fifth and the eighth days, but may be later. Abscesses and fistulæ are to be treated according to general surgical principles. It is to be observed in this connection that a recent rectovaginal fistula responds readily to measures that stimulate granulation, and give a fairly good prognosis. If the woman continues to have fever for several days, especially if she is a puerpera, great caution must be exercised in allowing her to get up, on account of the danger of infective phlebothromboses in the pelvis.

Plastic operations for the repair of old **cicatrized complete perineal lacerations**—in contradistinction to primary *perineorrhaphy* in recent perineal lacerations—are performed in the same way, except that more time may be expended on the preparatory treatment. *Denudation* of the torn area is necessary, the cut surface having the butterfly shape shown on Plate 1, special care being devoted to dissecting out the ends of the muscles. [Kelly's procedure of stitching together the ends of the sphincter muscles with catgut is always advisable.—ED.] The method of *introducing the sutures* and the after-treatment are the same as that above described. The woman stays in bed two or three weeks.

The earliest appropriate date for the performance of a secondary operation is six weeks after delivery, or, in the case of women who do not nurse their infants, after the first menstruation, which usually occurs at this time.

The operation of uniting already **granulating** perineal tears *per secundam* is more often successful than might be

supposed. Alarming febrile manifestations may, however, occur as the result either of the absorption of scrapings and trimmings from the wound, or the formation of small abscesses which, in the author's experience, have always ruptured externally by a fistulous tract and ended in good recovery.

The final result is necessarily the formation of a high, and also somewhat thickened, perineum (Fig. 1). [In America operators are, as a rule, averse to operating when the wound is granulating.—ED.]

2. Repair of Incomplete Perineal Lacerations.

In the operation for the repair of perineal lacerations of the first and second degrees the vaginal and perineal sutures are placed in the same way as in the case of complete perineal lacerations already described. If the gap is wide, buried sutures are also used; these must not be too numerous, because the wound-surfaces have enough to do to effect good union, without their absorptive powers being unduly taxed. The repair of an **injury of the fossa navicularis** under the intact integument of the perineum demands special care.

The *after-treatment* is the same as that just described.

Much is, however, to be said about the denudation of the field of operation in old **cicatrized incomplete perineal lacerations**, or, in other words, in regard to the *perineo-plastic technic* in the repair of such lacerations. (See Figs. 2-12.)

Lacerations of this character are rarely in the median line; as a rule, they are found by the side of the posterior column of the vagina. Accordingly, Küstner advised

lateral denudation of the wound along the course of the scar, although originally it had always been taught that the denudation should be along the median line or have a symmetric shape; and even now this method is the one chiefly used and yields uniformly excellent results. The principles governing the operation depend somewhat on the nature of the denudation, and are as follows:

(a) Symmetric denudations in the median line, disregarding the *columna rugarum*—methods of Fritsch, Hegar, and Simon.

(b) The same, taking the *columna rugarum* into consideration—methods of Bischoff, Freund, A. Martin, and von Winckel. [Emmet's work in this connection deserves special mention.—ED.]

Both forms (a) and (b) may, if the denudation is continued high enough, contribute to the contraction of the vagina—**kolpoperineorrhaphy** or **kolpoperineoplastic operation**.

(c) Denudations performed in such a way as to preserve the partly loosened flaps (flap-plastic operation after Lawson Tait, Säger, Simpson). This variety includes simple division (splitting) (Fritsch and Küstner).

According to the method employed and the extent of the denudation downward into the vagina, or upward and to the sides as far as the *labia minora*, the resulting perineum will be broad or narrow, very high, or only moderately high. Thus a narrow high perineum, for example, may suffice in cases in which the walls of the vagina are tense and the internal genitalia retain their normal position, but in which the vestibular portions are separated and thus afford an opportunity for the production of

catarrhal irritations—that is, for the entrance of germs from the air. The method is adapted especially for young women who presumably will have to bear children repeatedly (von Winckel's method).

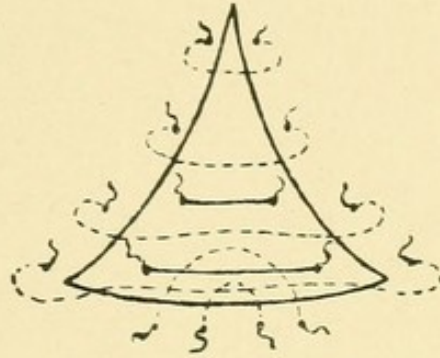


FIG. 2.—Hegar's kolpoperineorrhaphy with two buried sutures.

Hegar's kolpoperineorrhaphy, which belongs to this group, requires the use of instruments to expose the parts, as it is performed high up in the vagina, and will be discussed later (Fig. 2).

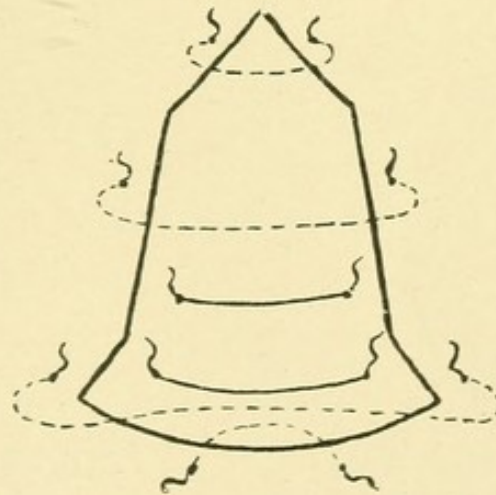


FIG. 3.—Fritsch's kolpoperineorrhaphy.

The **kolpoperineoplastic operation** of Bischoff, to which that of Freund is similar, belongs to group (b), and is illustrated in Fig. 4. It consists in the dissection of a

flap by means of the following incisions : the first incision results in the formation of a circumscribed tongue-shaped flap in the vagina, which is allowed to remain ; a second curved incision, almost parallel to the first, follows the line of the original frænum perinæi ; on the sides this incision is made to diverge as it is carried higher up, almost or quite as far as the labia minora ; at this point it is connected, by means of straight incisions, with the inner extremities of the vaginal incision. After the flap outlined by these incisions has been dissected away, the figure shown in Fig. 5 is produced. Each of the two

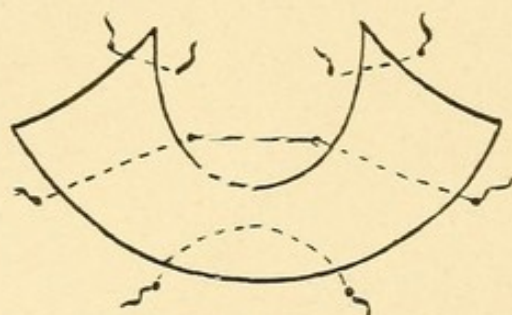


FIG. 4.—Bischhoff's perineoplasty.

lateral triangles is closed separately, so that the vagina is narrowed on each side. The outer convexity of the perineum is united with the tongue-shaped flap in the vagina, and the distal edges of the wound on either side are laid one on the other and secured with sutures (Fig. 5).

If it is desired to economize tissue, the edges of the wound, both in the perineum and in the tongue-shaped vaginal flap, which contains the columna posterior, are undermined.

Freund's denudation (Fig. 6) is similar, but the lateral triangles are carried further into the vagina and upward along the columna.

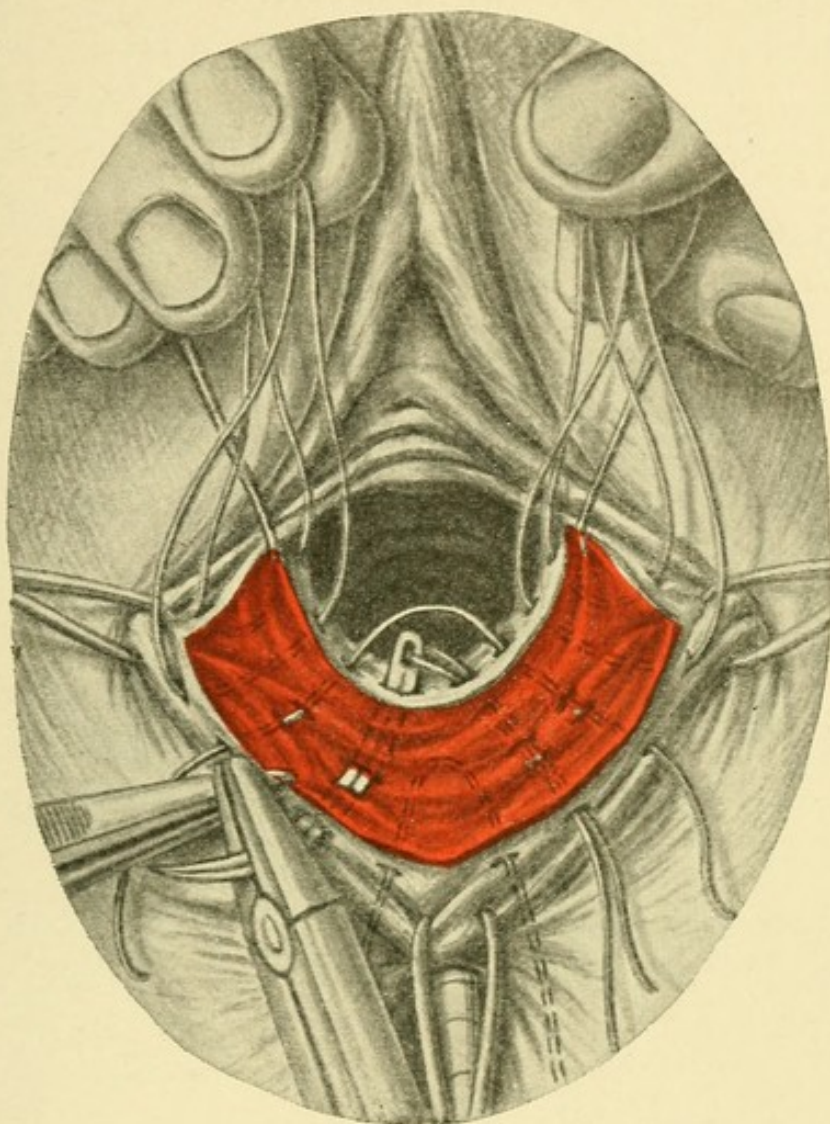


FIG. 5.—Perineoplastic operation after Bischoff (see Fig. 4). Method of placing the sutures. The upper tags of the wound are brought out of the vagina with hooks. These tags are united separately, while the remaining sutures that have been introduced through the perineum are carried to the median vaginal flap and then beyond the latter to the other side. In this way the opposite surfaces of the wound are superimposed one upon the other when the sutures are tied. The lateral margins of the wound should be undermined. The tying of the sutures should not be begun until they are all in place, so as to have the opportunity of correcting any asymmetry that may have formed.

If we imagine Bischoff's denudation narrower and stretched out sideways without lateral triangles (Fig. 7), we shall have a slightly curved oblong area corresponding to the posterior commissure of the vestibule, one side of which is applied to the other and united to it with sutures. All the sutures are introduced on the convexity of the

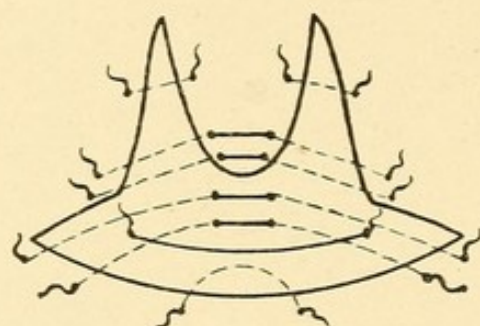


FIG. 6.—Freund's kolpoperineorrhaphy.

perineum and brought out in the vagina ; here they are reinserted on the other side and finally brought out on the corresponding side of the perineal convexity. The line of union that results has a \perp -shape, above which the flaps are united after they have been reduced to half their

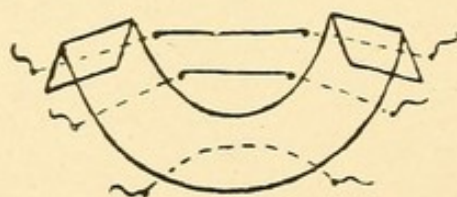


FIG. 7.—Von Winckel's perineorrhaphy.

original length. The operation, devised by von Winckel, is exclusively perineoplastic, and is employed in the conditions detailed above.

A. Martin adds to the curved incision of the commissure two superior incisions parallel to the *columna posterior*, extending up into the vagina to any height de-

sired, and two lateral incisions. When denudation is completed, the raw area resembles four outstretched fingers; he then closes the vaginal surfaces separately, and then the lateral portions of the denuded surface in

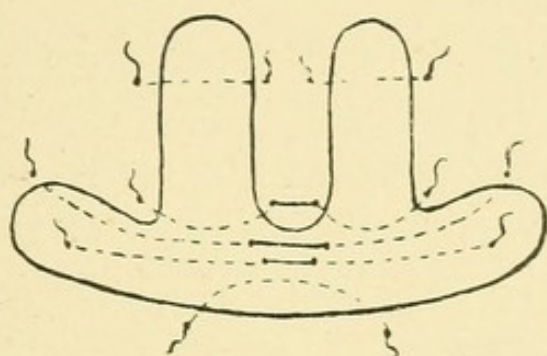


FIG. 8.—A. Martin's posterior kolporrhaphy and perineorrhaphy with a buried suture.

the region of the commissure of the vestibule, as in the other methods, by superposition. (See Fig. 8.)

The underlying principles in the plastic operations with **flaps** and **division of the tissues** (group *c*) are the preservation of the tissues remaining, which are usually shortened, and the division of parts that have

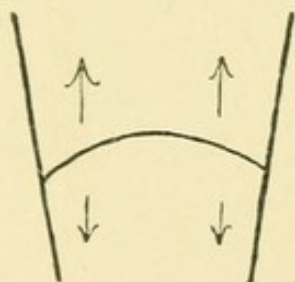


FIG. 9.—Incision to form the perineal flaps (after Lawson Tait-Sänger).

united in a faulty manner. Lawson Tait and Säger [and A. R. Simpson.—ED.] effected this by separating the vagina from the rectum by means of a transverse incision in the region of the perineal scar, and keep-

ing these two passages apart by means of flaps. To form the latter, lateral incisions are made beginning at the extremities of the transverse incision, and running both toward the labia and toward the anus—in other words, four lateral incisions running practically perpendicular to the transverse incision, and forming two tongue-shaped flaps (Fig. 9). The walls, which are practically quadrangular, are united by a superficial and a deep row of transverse sutures (Fig. 10). The distal edges of the flaps then form a truncated cone.

Fritsch makes a similar transverse division (Fig. 11),

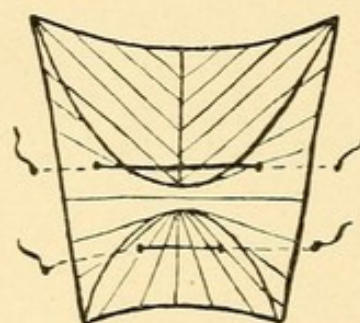


FIG. 10.—Introduction of the sutures after the flaps have been unfolded.

but instead of making vertical lateral incisions to form flaps, he enlarges the transverse wound in the vertical direction with the aid of two hooks inserted one at the center of the vaginal, and the other at the center of the anal, border of the wound; the latter is then closed by means of deep and superficial transverse sutures, and a high perineum is obtained, without any sacrifice of tissue (Fig. 12).

All these operations are performed with the woman in the lithotomy position. After the denudation has been outlined with the scalpel [many operators prefer to make the incision with scissors.—ED.], the flaps are dissected

off with the scissors, cutting from below upward, because the hemorrhage is then less profuse and does not obscure the operative field. When flaps are removed, they should be intact, so as not to leave any islands of squamous epi-

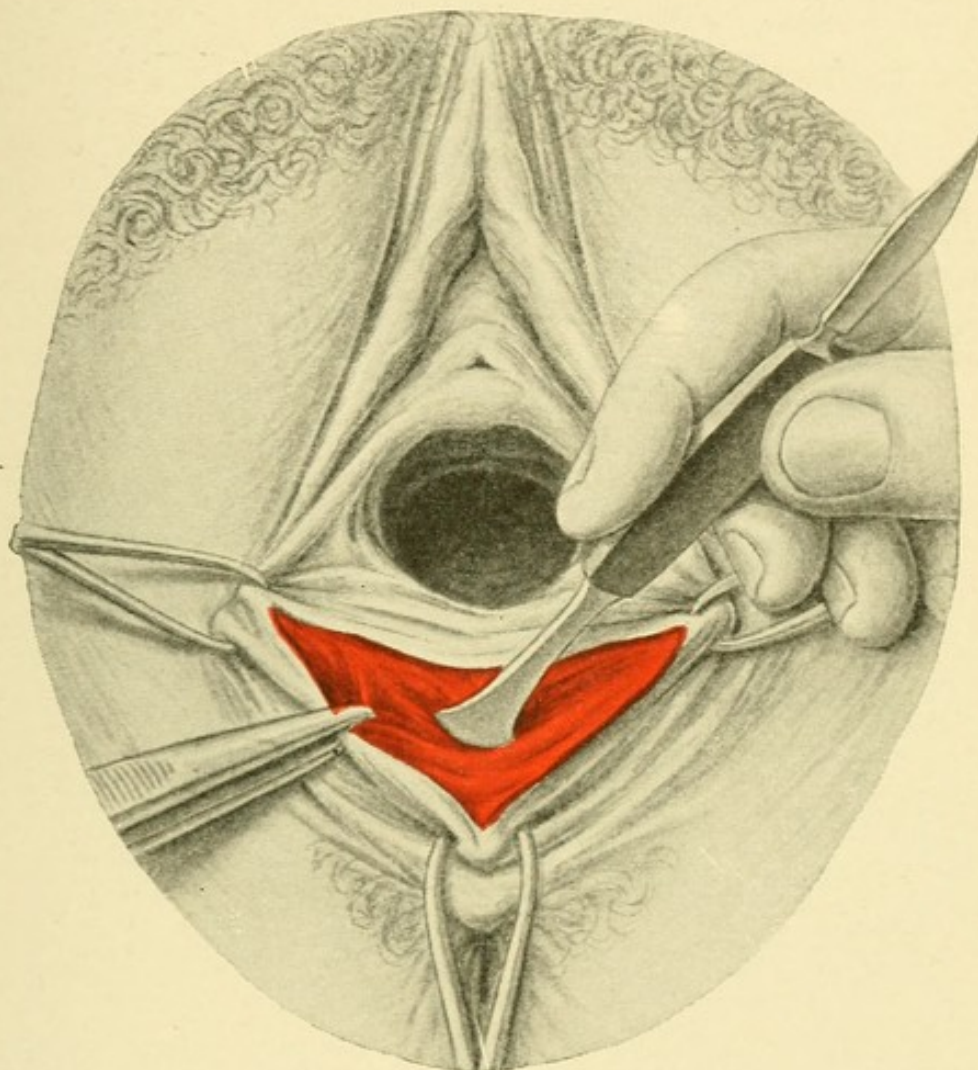


FIG. 11.—Perineoplastic operation by means of flaps and division (after Fritsch). The vagina is separated from the rectum with a blunt dissector after the transverse incision has been made.

thelium behind. The sutures run crosswise ; the needle is inserted and brought out again close to the edge of the wound, but must be carried with a wide sweep into the lateral tissues and below the floor of the wound. The

necessity of avoiding the formation of "dead" spaces has already been mentioned. The individual sutures must be at least $\frac{1}{2}$ cm. apart. Full anesthesia is de-

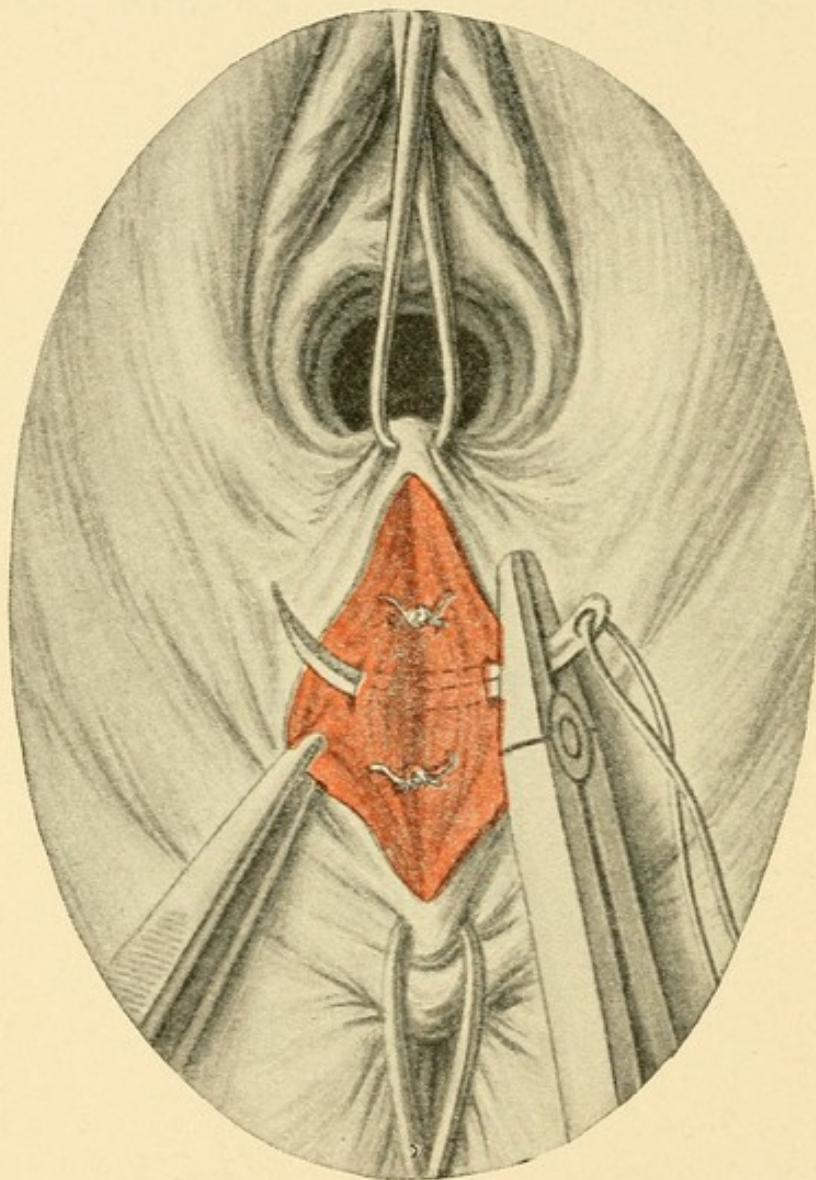


FIG. 12.—Perineoplastic operation by means of flaps and division (after Fritsch). Placing the transverse sutures that close the wound, after the transverse incision has been enlarged vertically with double tenacula. The knots of the buried sutures are visible.

sirable. Schleich's infiltration method can be used, but the resulting edema has an unfavorable influence on the subsequent healing of the wound.

3. Episiotomy.

For the purpose of avoiding the accident of a deep perineal tear, or of assisting the escape of the head if the infant's life appears to be in danger, an oblique incision of varying depth is made from the vestibule of the vagina toward a point midway between the tuberosity of the ischium and the anus. The incision may be made deep enough to divide the levator ani muscle. In closing the wound the ends of that muscle, as well as the ends of the bulbocavernosus, must be brought into apposition—if necessary, by means of a buried catgut suture. The retraction of these muscles draws the floor of the wound downward; the wound assumes the shape of a rhomboid.

[Episiotomy is much oftener practised in Germany than it is in America or in Great Britain. Except in the cases of extreme rigidity of the external genitals or marked narrowness, the operation is rarely necessary if the obstetrician employs proper manipulations during the passage of the fetal head. Of great importance is the position of the woman. The greatest relaxation of the perineum is obtained when the limbs are placed in the Walcher posture or merely extended. In the lithotomy posture it is most tense and most liable to rupture. The author's incision is only one of several which are employed.—ED.]

4. Extirpation of Portions of the Vulva or of the Hymen.

This procedure may be necessary in cases of malignant neoplasms, kraurosis, obstinate pruritus with or without chronic hypertrophic folliculitis of the nymphæ, and

vaginismus. In the first-named condition the incision must be carried at least one and one-half centimeters beyond the recognizable limit of the diseased tissue. The line of incision depends on the course of the neoplasm,—including diffuse, multiple, benign papillomata,—and in other diseases according to the extent of the tissues involved. In removing a hyperesthetic hymen the operator must be careful to remove at the same time the part that surrounds the urethral orifice and the knob-like invagination of the hymen into that canal. For all the sutures silkworm-gut and very fine needles must be used; the latter precaution is especially important in the region of the clitoris and the urethra, in order to avoid hemorrhage. The wound is to be dusted with an antiseptic drying powder. These operations require full anesthesia.

Of the operations performed on the urethra, “dilatation” will be described in connection with the removal of foreign bodies by means of kolpocystotomy.

5. Operations to Correct Incontinence of Urine.

Gersuny's operation consists in dissecting out the urethra and twisting it 180° to 350° ; the canal, which has been somewhat roughly freed from the adherent connective tissue, is then fixed in this position with sutures.

In two cases the author obtained good results with Ziegenspeck's operation for narrowing the internal sphincter of the urethra, in one case combined, however, with anterior kolporrhaphy. After exposing the posterior portion of the urethra and carefully dissecting out the muscular fibers, a fold is made in the latter in the sagit-

tal direction and secured with a few fine sutures. It is important to secure the formation of a fibrous ridge in the shape of a firm scar which contracts the vaginal mucosa in the neighborhood of this area. A fine silk-worm-gut suture, which serves to unite the superficial layers of the mucous membrane, is at the same time drawn through the artificial sphincter ridge. During the operation the degree of narrowing is controlled by means of a small catheter or a uterine sound.

6. Resection of the Urethra.

This operation is indicated in prolapse of the urethral mucous membrane and in the presence of urethral polypi or ulcers. The operation consists, in the main, of an incision around the posterior boundary of the urethral mucous membrane, the formation of flaps on each side, and stretching of the wound in the direction of the *carina urethralis*, so that it has a triangular shape. The posterior portion of the urethral mucous membrane, therefore, remains as a tongue-shaped flap, very much as in Bischoff's denudation of the perineum, and the lateral edges of the wound are united in part with this flap and in part with one another by means of fine silkworm-gut sutures. During the operation a hook is applied on each side of the meatus.

II. OPERATIONS REQUIRING FOR THEIR PERFORMANCE EXPOSURE OF THE VAGINA.

The entire extent of the vagina is brought into view by merely inserting a tubular glass or metal speculum, or an adjustable bivalve speculum provided with screws to regulate the width of the two parts, like the model originally devised by Cusco; or by means of a grooved or flat speculum which depresses the posterior wall, such as Simon's, Marion Sims', or A. Martin's. The last are also known as "vagina-holders," and their efficiency may be increased by adding "lateral retractors." The latter are used in operations; the anterior and lateral walls of the vagina are held aside by means of hooks or double tenacula, with which the upper portions of one of the four walls of the vagina or one of the lips of the external os is seized and drawn upward. For the os, a double-jawed Muzeux forceps is the most appropriate instrument.

The field of operation must be fully exposed, so that it will not be obscured by folds and pockets or present an asymmetric appearance.

Topographic and Surgical Anatomy of the Vagina and of the Portio Vaginalis.

On first introduction of the speculum the pelvic diaphragm described previously is spread out and pushed back; a little higher up the ampulla of the rectum is then depressed. The anterior wall of the vagina, presenting the prominence of the urinary bladder, accordingly descends. The rectovaginal septum separates the two muscular layers of the rectum and of the vagina,

and consists of loose connective tissue. Opposite the ampulla of the rectum the septum is extremely thin, the distance between the lumen of the gut and that of the vagina being scarcely more than 1 cm. [often less.—ED.]. A band of connective tissue, the rectovaginal fascia, is attached to the floor of the recto-uterine and rectovaginal fossa, or, in other words, to the peritoneal fold, and, passing between the loose connective tissue and the outer longitudinal muscular layer of the rectum, descends to the diaphragm; the inner muscular layer of the rectum is circular. Two layers of smooth muscle are found in the vaginal wall. (See *Atlas of Obstetric Diagnosis and Treatment*, Plate 8, Fig. 18.)

Higher up the interval between the rectum and the vagina is occupied by the peritoneal pouch of Douglas (recto-uterine and rectovaginal fossa); this represents a pocket of the peritoneum and occasionally contains ovary, oviducts, or loops of intestine. It varies in size in different cases, and invests the posterior vault of the vagina and the lower third of the pelvic portion of the rectum as far down as the first transverse fold of the vagina, known as Kohlrausch's fold, at the level of the posterior vault of the vagina.

Between the muscular wall of the bladder and the anterior wall of the vagina the vesicovaginal fascia passes in a similar way between the anterior peritoneal pouch and the "diaphragm." The structure of this connective tissue septum becomes looser and looser as the neck of the uterus is approached; hence the fundus of the bladder can be dissected away from the vagina at and above this point, which corresponds with the anterior

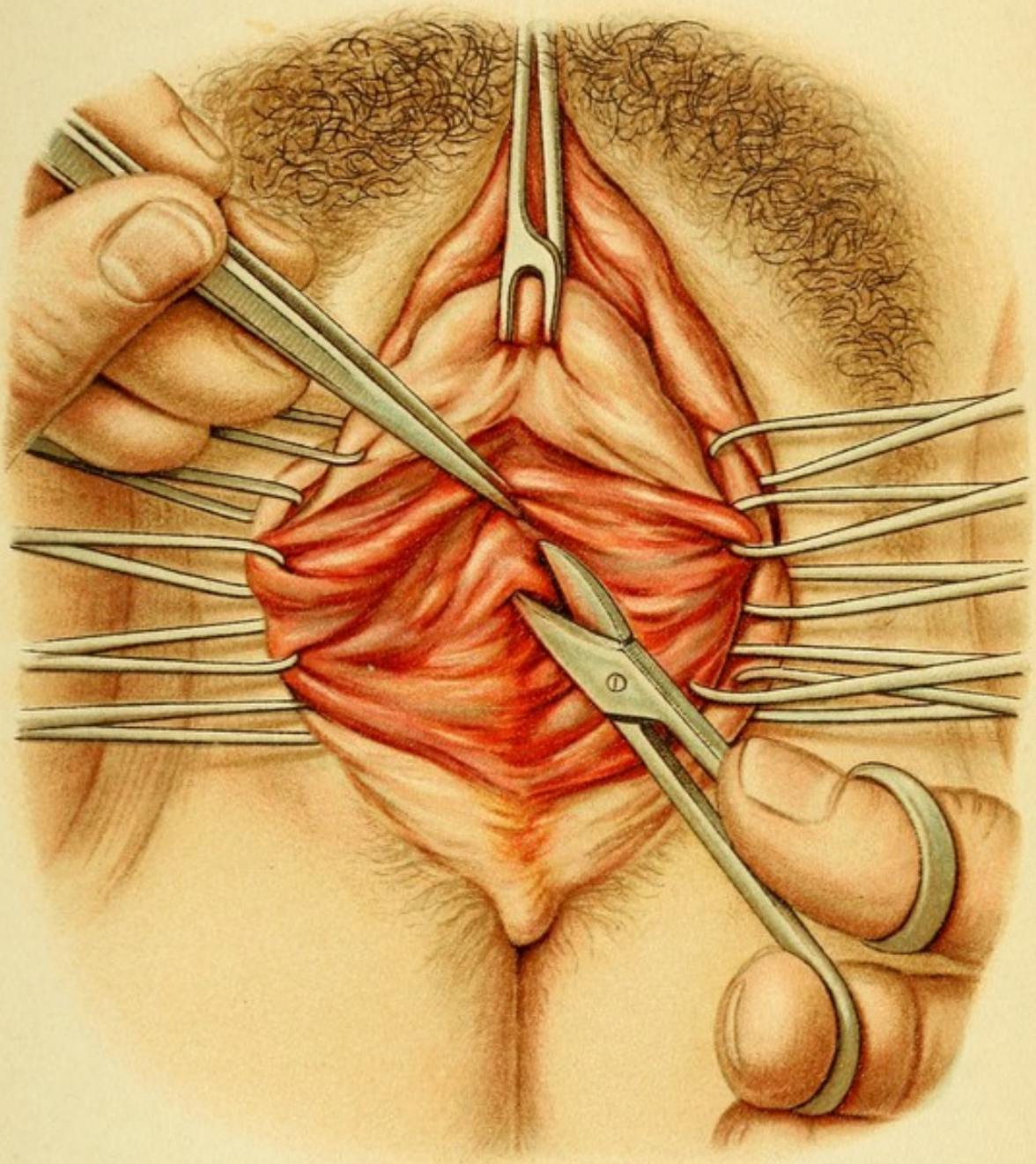
Plate 3.


Kolpoperineorrhaphy with Retrofixation of the Neck (after Hegar and Sanger) (see Figs. 2, 3).—*Opening of Douglas' Pouch After Freshening up a Triangular Area on the Posterior Wall of the Vagina.*—This is accomplished by drawing upward the vaginal portion with a Muzeux forceps inserted in the posterior lip of the os; the lateral edges of the wound are held aside with the aid of a series of double tenacula, which are applied as far up as the posterior vault of the vagina.

vault of the vagina better than anywhere else. The space below this point is occupied by a denser connective tissue forming the *trigonum Lieutaudii*. The openings of the ureters in the bladder are situated at a point somewhat below the external os, having passed down between the bladder and the vagina at the level of the vault and converged forward. The ureters possess a special sheath and lie loosely embedded in the cervicovesical connective tissue, so that they are quite movable; at the level of the anterior lip of the os they come in immediate relation with the wall of the vagina, which is very thin at this point.

On each side of the vagina are found rich venous plexuses.

The lumen of the vagina, which in its intermediate portion shows the familiar H-form, assumes the shape of a balloon in the portio vaginalis, on account of the conic continuation of the cervix, which projects into the vault of the vagina at this point. The anterior wall of the vagina is extremely thin, while the posterior wall is considerably thicker, and gives support to the *portio vaginalis*. The latter consists in the main of connective tissue, containing a few relatively sparse muscular fibers and numerous elastic fibers, which are united to form a





kind of sphincter about the external os. Its outer investment of squamous epithelium greatly resembles that covering the vaginal walls.

1. Posterior Kolporrhaphy or Kolpoperineorrhaphy.

This is the commonest operation performed in the vagina. The method in most general use is that of Hegar. It consists in freshening up a triangular portion of the perineal scar and of the vagina, the base of the triangle corresponding in direction with the posterior commissure of the vestibule and the two sides running up into the vagina so that the apex reaches the upper third of that structure. Sanger combined this method with Frommel's plan of fixing the cervix of the descended uterus behind and above, and obliterating the posterior cleft of Douglas; hence the apex of his triangle is practically in the pouch of Douglas, which was opened by a posterior kolpotomy incision. This combination of perineal plastic operation with narrowing of the vagina and seroso-serous retrofixation of the cervix is represented on Plates 3 to 8, etc. I shall content myself here with describing only Hegar's kolpoperineorrhaphy, which is properly considered in this connection. (See Plate 8 and Fig. 13; Plate 2 and Fig. 1.)

After the field of operation has been freely exposed, the two sides of the triangle are marked out with the knife, from the apex to about the edge of the labia minora, the two lateral incisions being then united with the familiar convex line corresponding to the commissure of the vestibule. The flap of mucous membrane is dissected away, partly with scissors and partly by tearing from

Plate 4.

Kolpoperineorrhaphy with Retrofixation of the Cervix (after Hegar and Sängcr).—The posterior pouch of Douglas has been opened, and the entire operative wound in the posterior wall of the vagina is seen.

Plate 5.

Kolpoperineorrhaphy with Retrofixation of the Cervix (after Hegar and Sängcr).—*Introduction of the Fixation Sutures.*—The catgut sutures, after passing through the perimetrium or anterior wall of the pouch of Douglas, are introduced into the serous membrane of the posterior wall of Douglas' pouch, which overlies the sacrum and the rectum for the purpose of obliterating the recto-uterine fossa.

Plate 6.

Kolpoperineorrhaphy with Retrofixation of the Cervix (after Hegar and Sängcr).—*Introduction of the Tobacco-Pouch Suture in the Peritoneum of Douglas' Pouch.*—The last fixation suture is seen in the depths of the wound. The obliterating suture for the peritoneal fold of Douglas may be introduced after the manner of a tobacco-pouch suture.

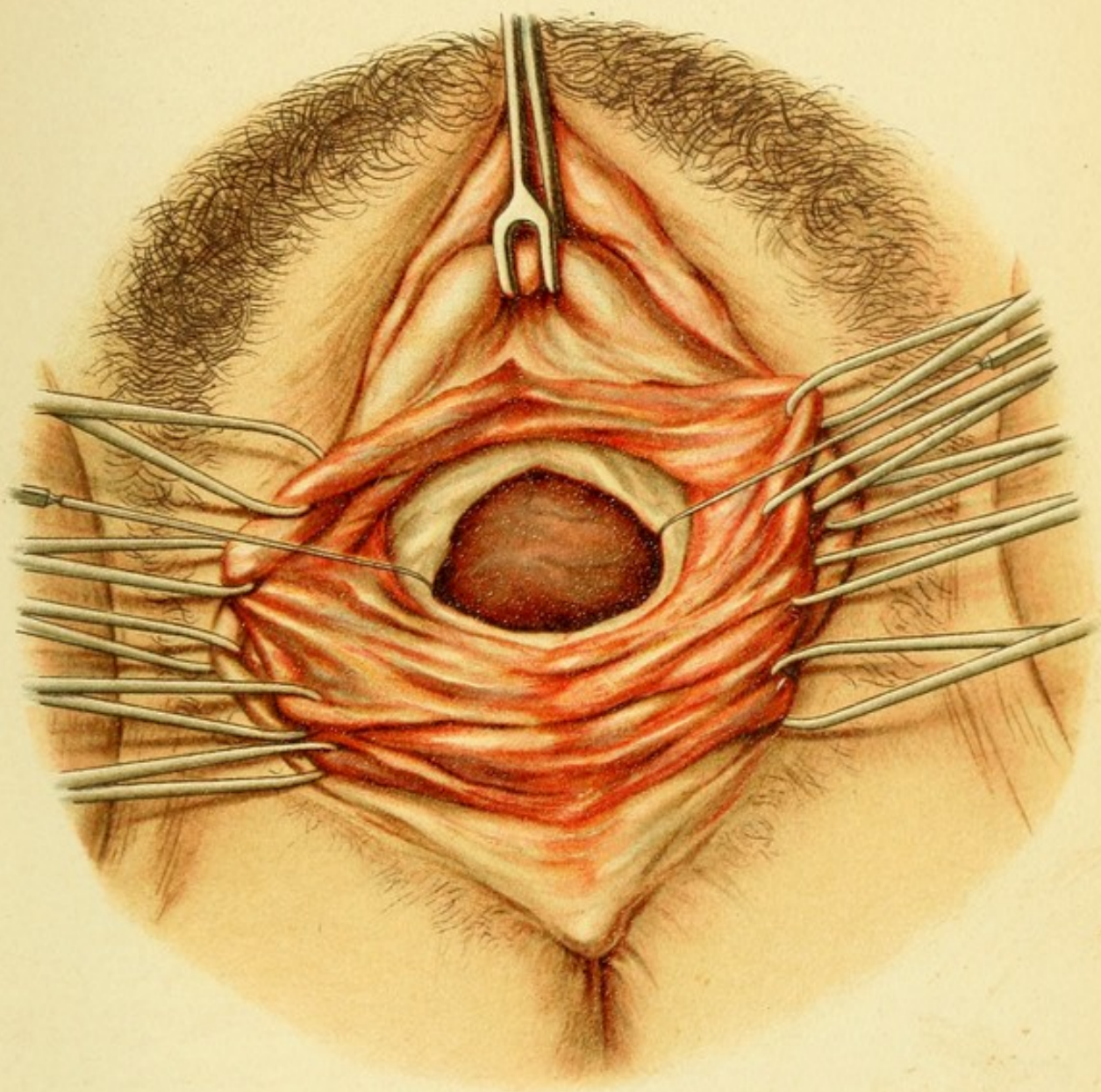
Plate 7.

Kolpoperineorrhaphy with Retrofixation of the Cervix (after Hegar and Sängcr).—*Introduction of Buried Sutures in the Posterior Vault.*—These sutures close the transverse incision and may at the same time be used to bring the serous membrane together.

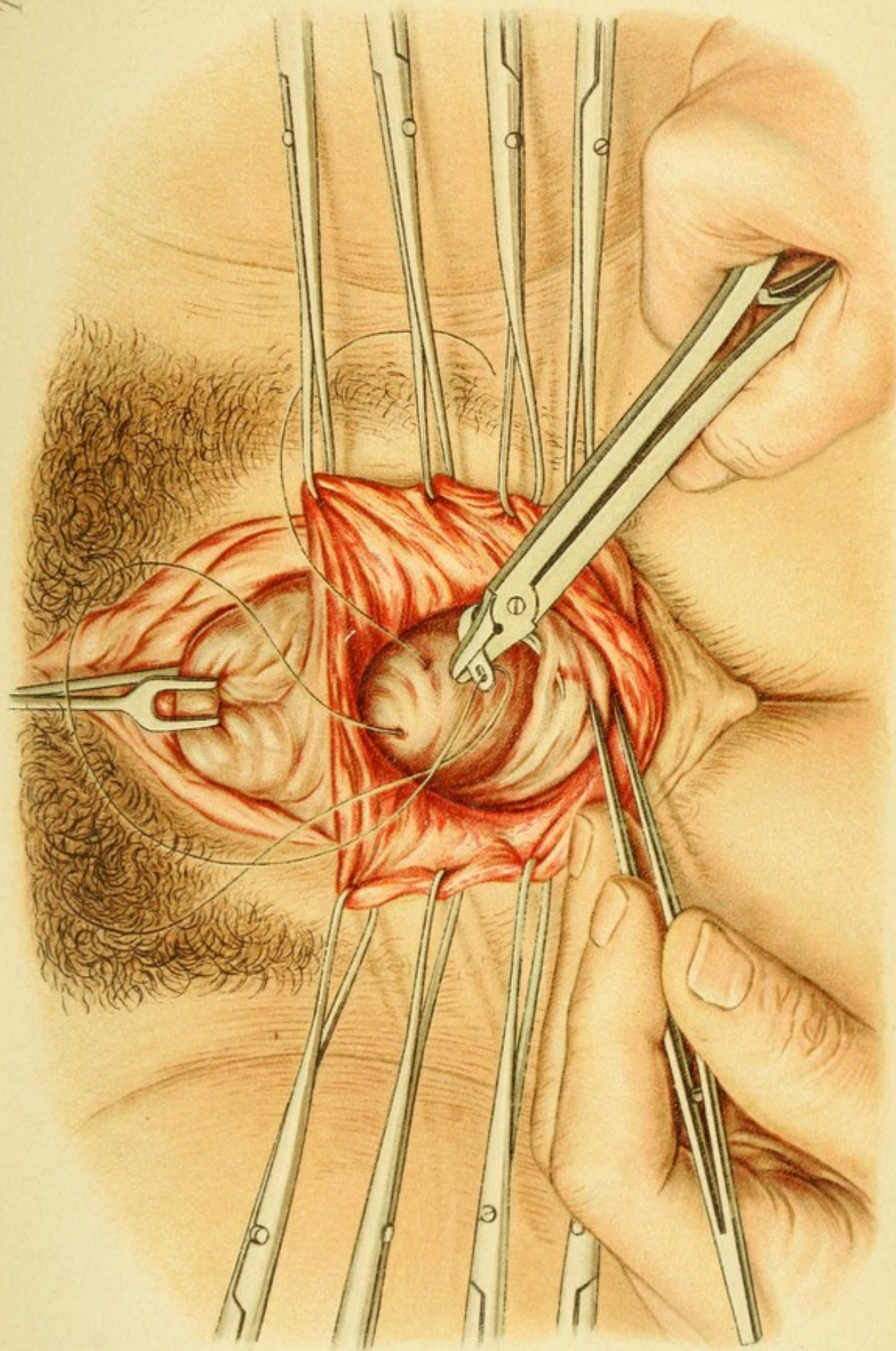
Plate 8.

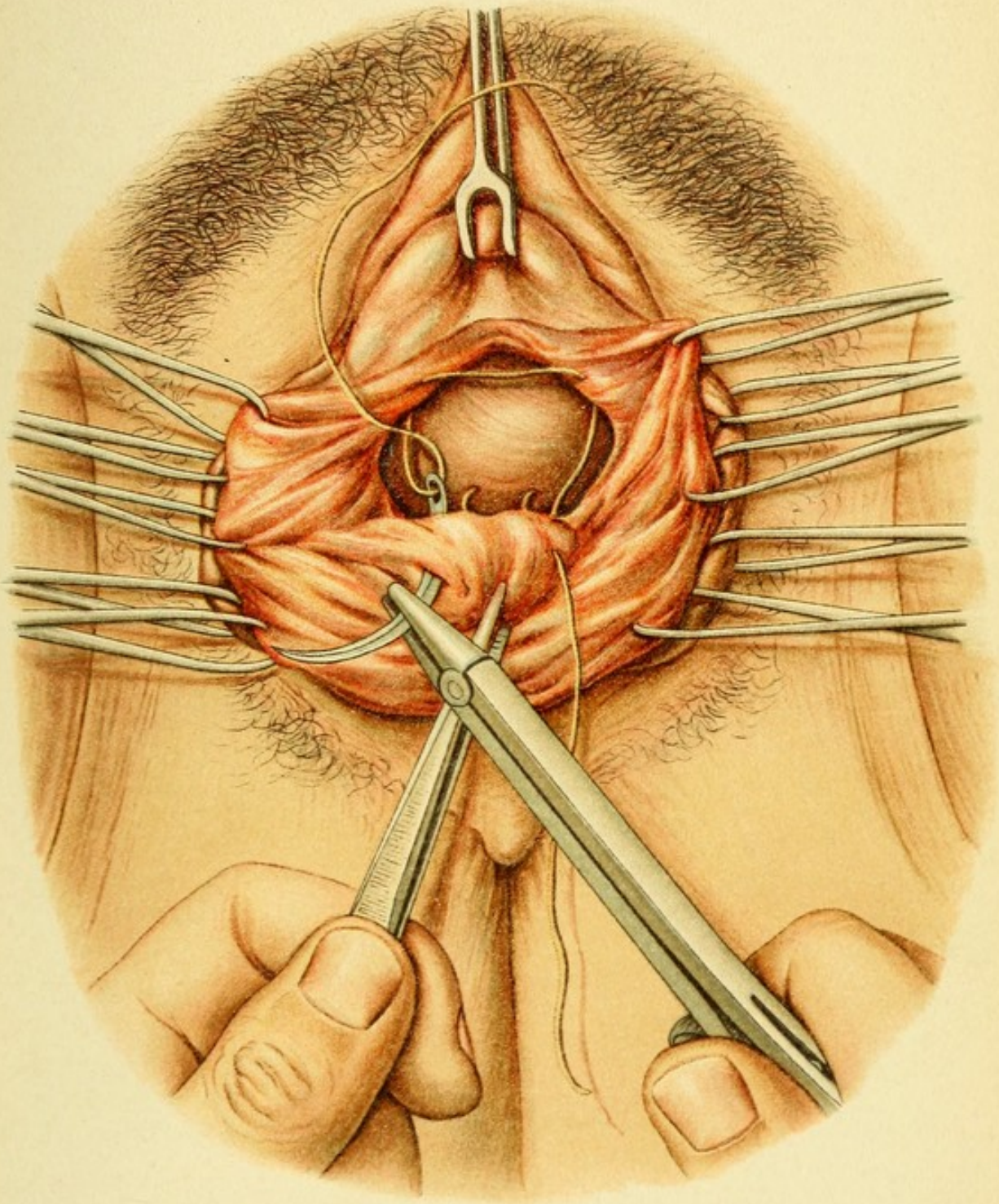
Kolpoperineorrhaphy with Retrofixation of the Cervix (after Hegar and Sängcr).—*Introduction of Buried Sutures along the Middle of the Vagina for the Purpose of Reefing the Rectocele.*—The two flaps of mucous membrane on each side which result from the former steps of the operation have not yet been cut away. A heavy sound has been introduced into the rectum to guard against the lumen being included in the suture.


without inward. Over the rectocele the septum is extremely thin, and great care is, therefore, required in this region. The edges of the raw surface are then approxi-

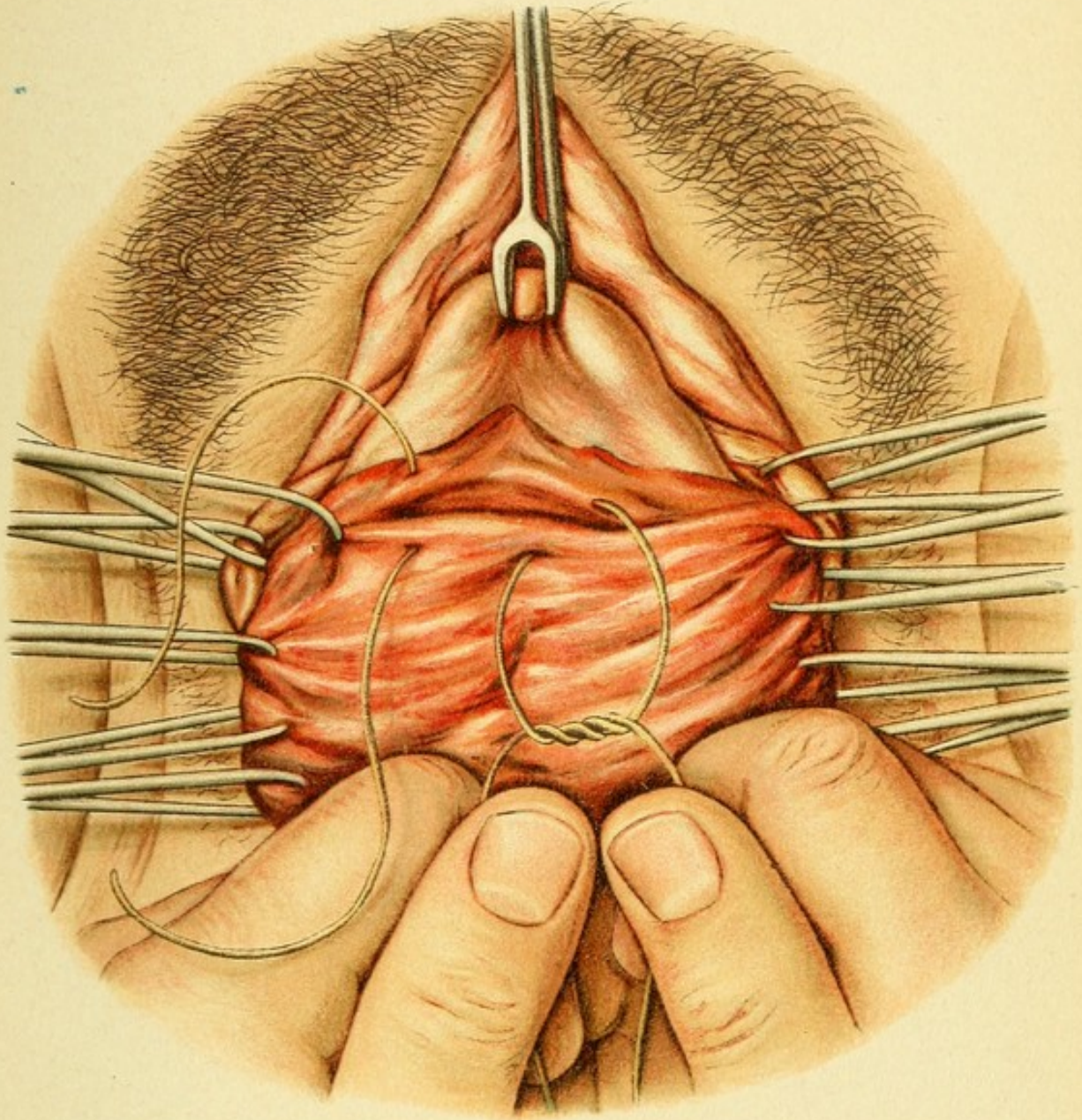





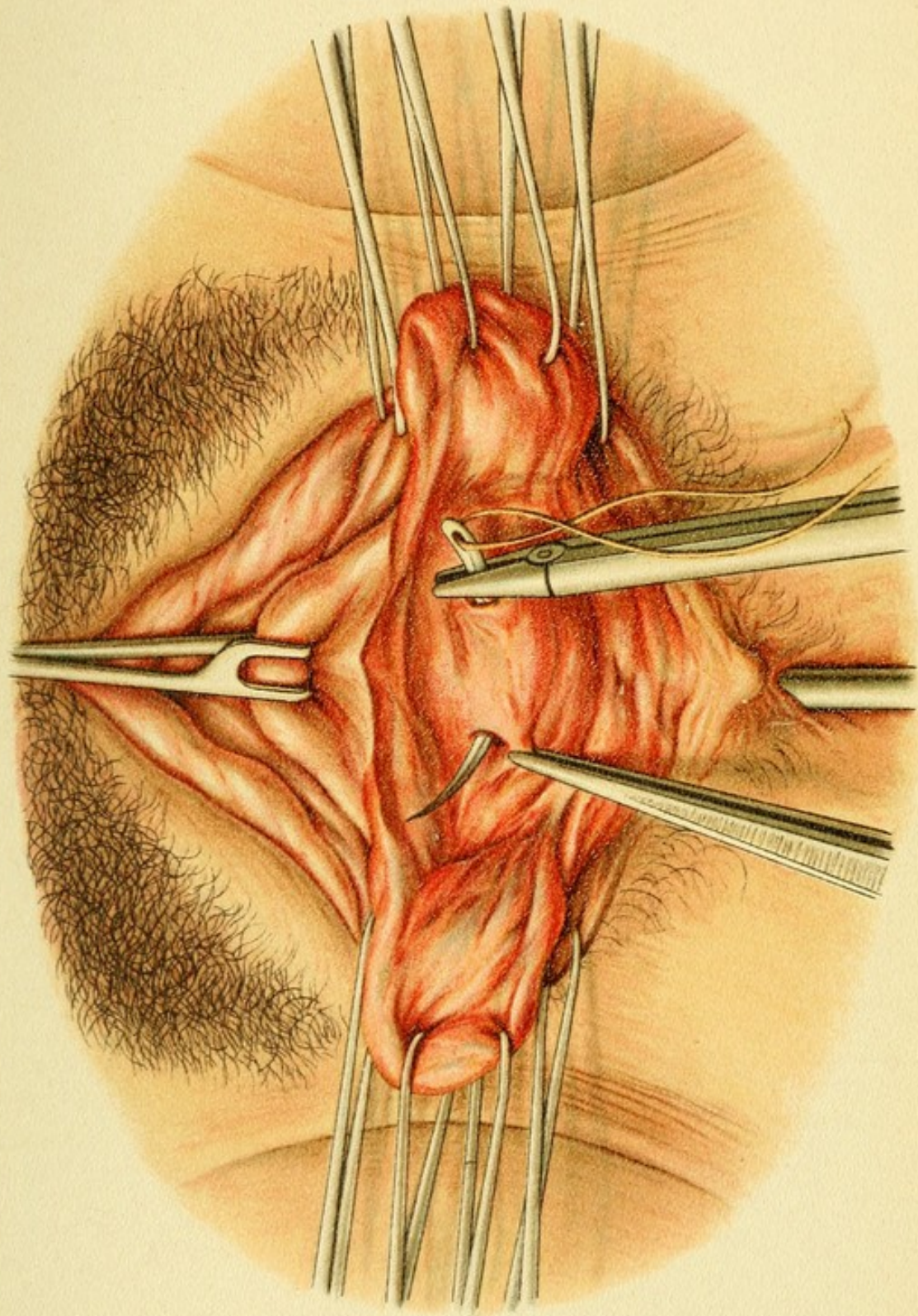















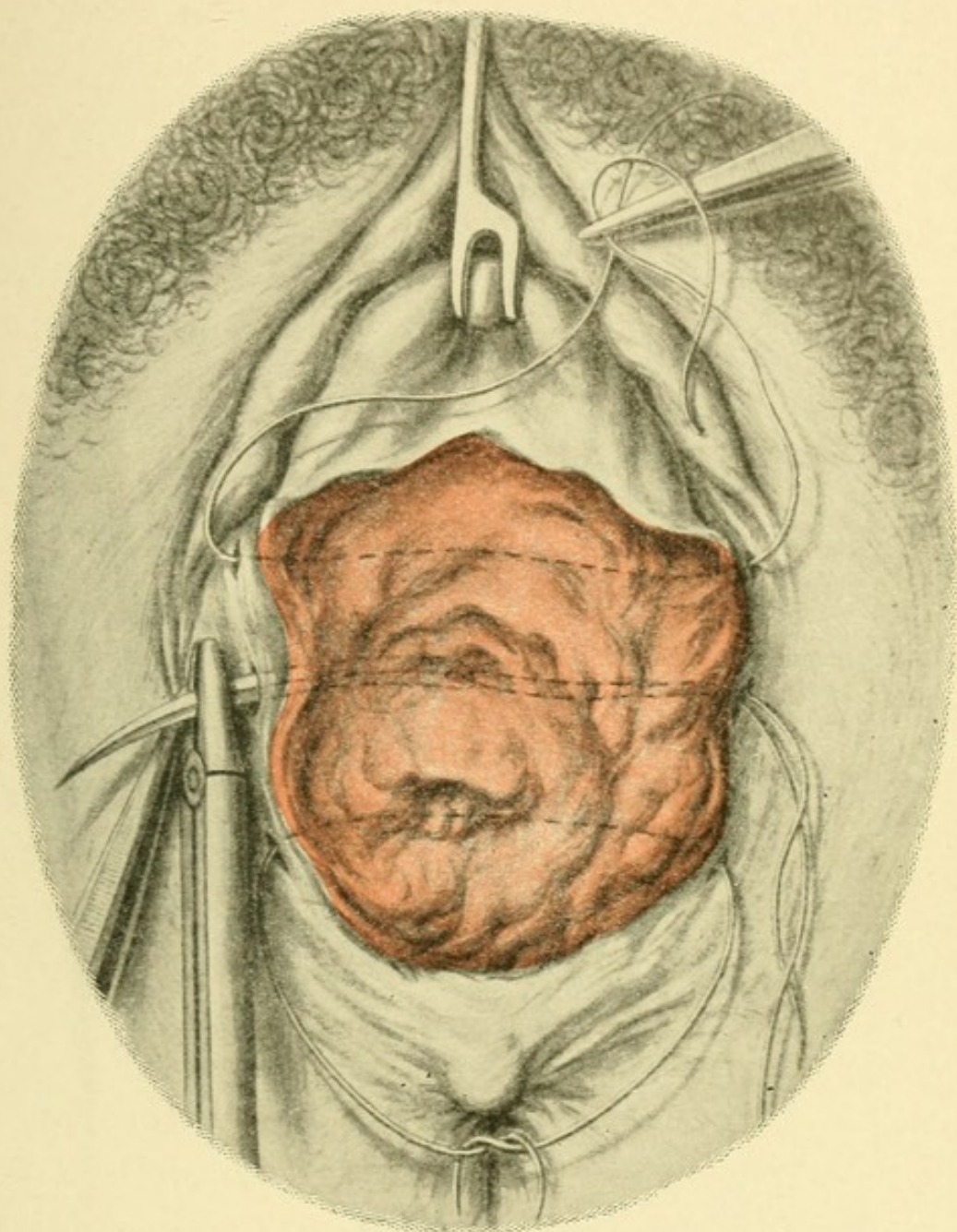


FIG. 13.—Kolpoperineorrhaphy with retrofixation of the cervix (after Hegar and Säger). Introduction of the transverse suture after the mucous membrane has been removed from the vagina and perineum. The edges of the wound have been undermined and the sutures have been introduced more laterally underneath the first sutures. The subsequent steps of the operation are shown on Plates 2 and 2a.

mated by means of transverse sutures, catgut being used within the vagina and some non-absorbable and non-draining material, such as gutta-percha silk, in the perineum. Over the rectocele and at the point of greatest transverse tension buried catgut sutures must be introduced. The same precautions are to be observed as in any plastic operation on the perineum. The edges of the wound may be advantageously undermined in order to get easy approximation.

It is a mistake to bring about narrowing of the posterior vault of the vagina, which ought to afford a kind of recess for the portio vaginalis; but immediately below that point the tissues may, under certain circumstances, require to be contracted. In the author's opinion it is, however, much more important to effect a lateral narrowing of the vault of the vagina and to fix the cervix high up and on one side (lateral hanging of the cervix) in cases of prolapse of the uterus, when vesicofixation and simple kolpoperineorrhaphy have failed to improve the anatomic conditions.

A much rarer procedure is simple narrowing of the posterior wall of the vagina without a perineal plastic operation, in cases of relaxation after enterocele or rectocele. This will be discussed in the next section (posterior kolporrhaphy).

2. Posterior Kolporrhaphy.

The denudation has a λ shape, and this outline is preserved in bringing together the edges of the wound (Fig. 14).

When the same condition is present in the anterior

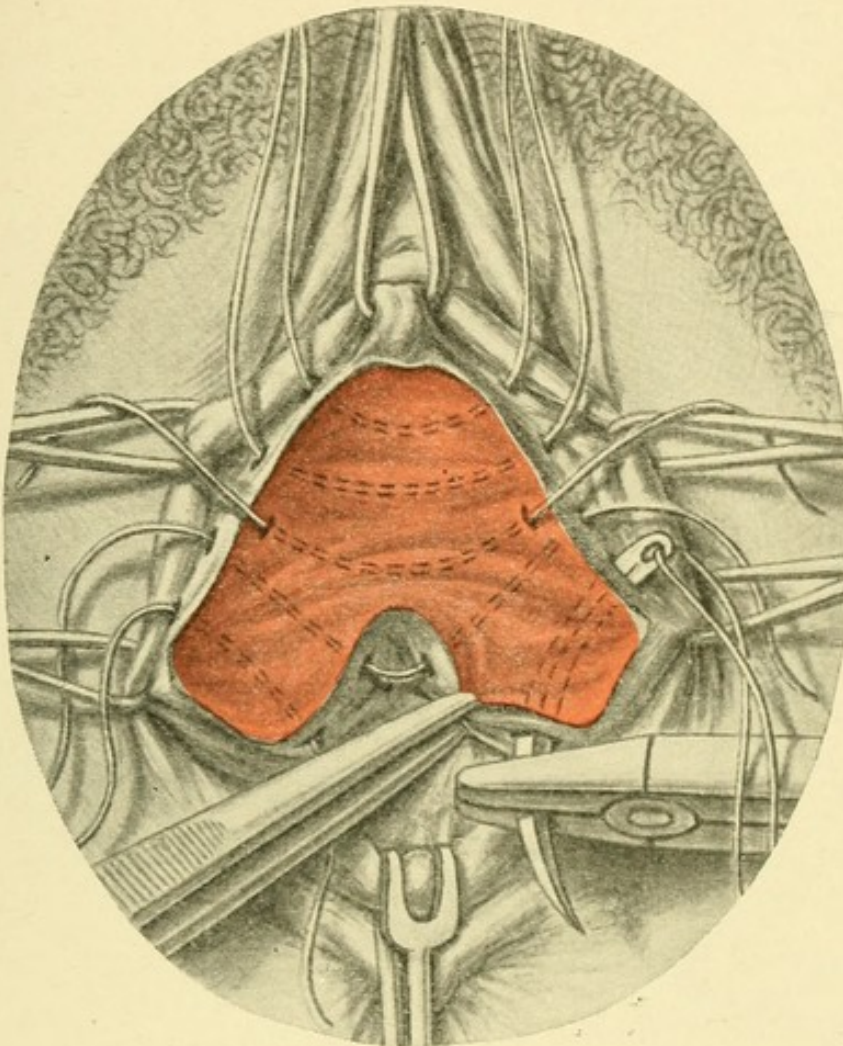


FIG. 14.—Posterior kolporrhaphy (λ shaped). Introduction of the sutures. The two legs of the inverted λ are united separately. One of the sutures used to bring together the two halves of the upper portion of the denuded surface is made to include the flap of mucous membrane, which projects into it, by introducing the suture in such a way that it passes over the flap of vagina and emerges on the other side of the denuded surface. The edge of the wound must be undermined, and the denudation must not extend into the vault of the vagina.

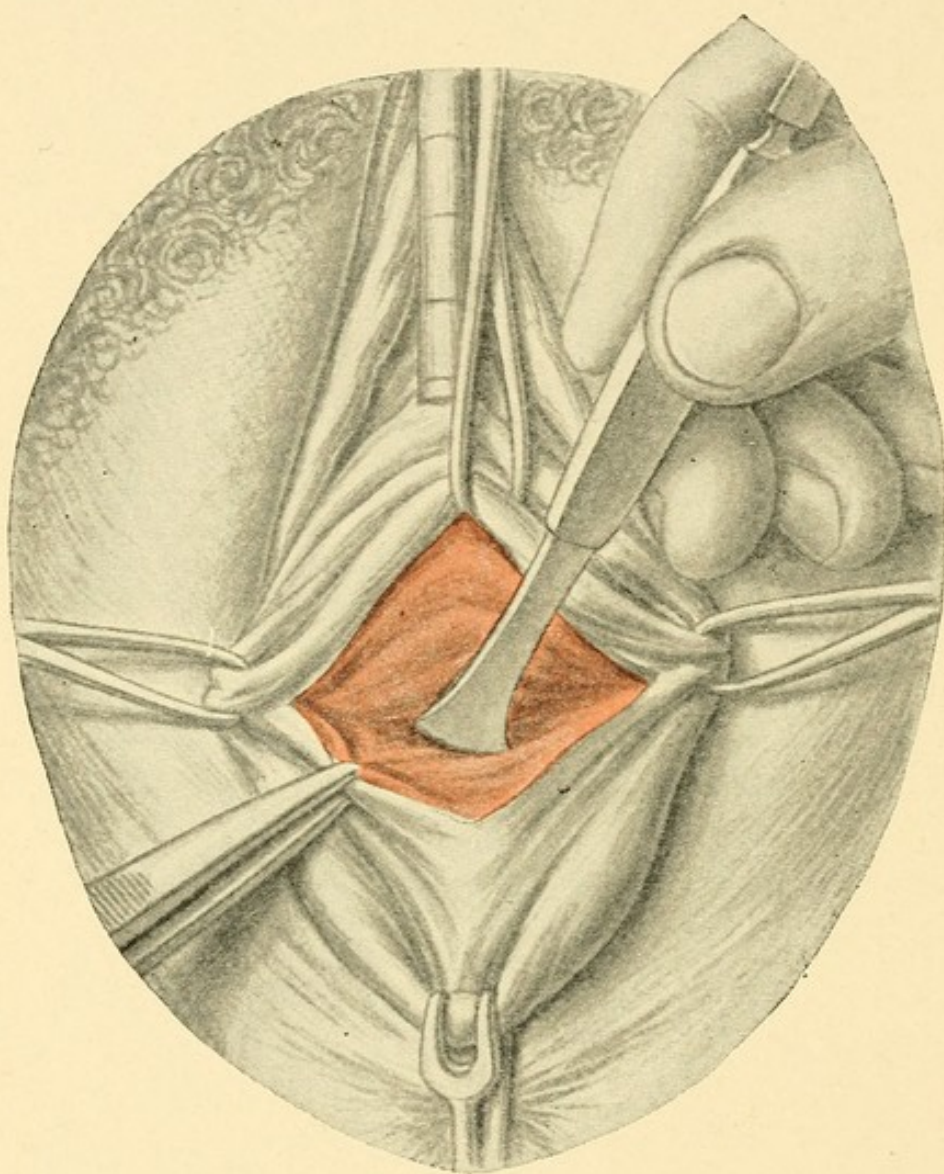


FIG. 15.—Anterior kolporrhaphy and obliteration of the cystocele (denudation after Hegar). The bladder is separated from the cervix with the handle of the scalpel. This consists in the removal of a rhomboid flap of mucous membrane from the anterior wall of the vagina, a catheter being introduced into the bladder to protect its wall from injury.

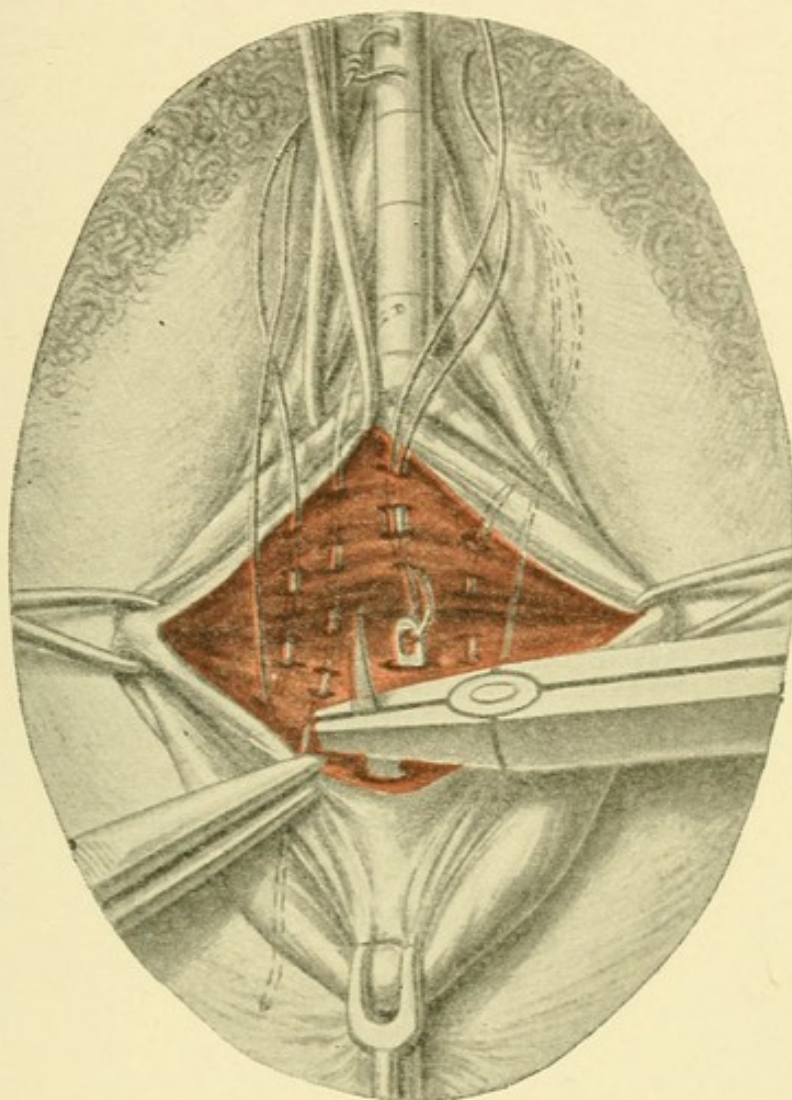


FIG. 16.—Anterior kolporrhaphy and obliteration of the cystocele (denudation after Hegar). Introduction of buried catgut sutures in the long axis of the vagina through the wall of the bladder and through the cervix. The sutures are passed in and out of the mucous membrane several times.

wall—*i. e.*, when there is a cystocele—anterior kolporrhaphy is performed.

3. Anterior Kolporrhaphy.

Plastic operation on the anterior wall of the vagina for the purposes of bringing about narrowing is much more rare than in the case of the posterior wall, because relaxation of the anterior wall occurs passively only as a result of relaxation of the perineum. The author has, therefore, practically given up simple anterior kolporrhaphy and performs the operation only in the following combination.

A rhomboid area is denuded, as in the original Hegar method (Fig. 15); the outlines of the area to be denuded are indicated by means of four double tenacula or hooks; the obtuse angle is directed toward the *portio vaginalis*; the acute angle, with the longer sides, is directed toward the urinary meatus. The tenacula are applied at the anterior lip of the cervix, at the prominence of the meatus, and in the two lateral sulci, which are drawn forward. The bladder is then separated from the cervix with the finger, the scissors, or the handle of the knife (Fig. 15).

The relaxation of the cystocele is first corrected by means of longitudinal sutures. The author has found by experience that the introduction of transverse sutures in the walls of the vagina after the usual fashion does not offer sufficient permanent resistance to the pressure of the bladder, hence the needle is inserted several times in the median line of the wall of the bladder at its most prominent point (Plate 9). The tissues are puckered in

several places superficially, and the needle is carried to the depths of the wound, after which it is passed through the wall of the cervix and emerges near the edge of the wound. Two or three sutures are introduced in this way at short intervals one from the other, to avoid the terminal portions of the ureters being included in them. The sutures, which should be of catgut, are at once tied, so that the bulging of the cystocele is completely removed.

The edges should be undermined and then brought together with transverse sutures (Plate 9). A strip of iodoform gauze is introduced into the vagina and left in position for a week to act as a support for the anterior wall of the vagina. The woman usually urinates spontaneously, but if not, she must be carefully catheterized. A slight admixture of blood or turbidity of the urine during the first few days is of no great significance. It is due to some catarrhal irritation which is readily corrected by means of urotropin. If incontinence had been present before, especially in old women, it usually disappears promptly. The plastic operation for the correction of incontinence, which has been described elsewhere, can readily be combined with this operation. In that case the apex of the rhomboid representing the denudation is carried up as far as the meatus. The patient should stay in bed two weeks.


4. Operation for the Narrowing of the Lumen of the Vagina (after v. Winckel) (Plate 10, Fig. 17).

This operation is performed when the ordinary kolpoperineorrhaphy has failed to bring about permanent correction of the prolapsed uterus, especially in women who

Plate 9.

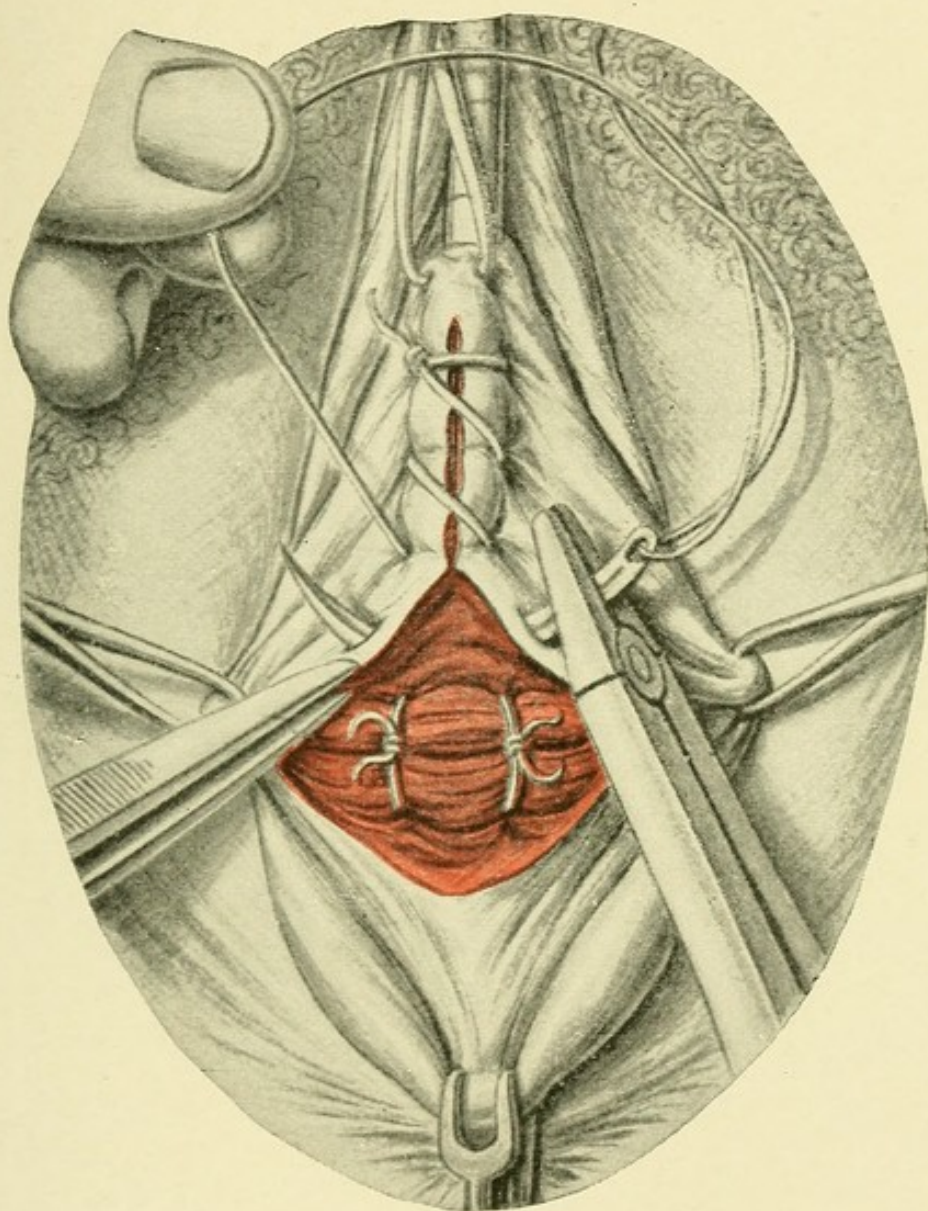
Anterior Kolporrhaphy (Denudation after Hegar).—*Introduction of the Transverse Vaginal Suture to Close the Wound and Narrow the Vagina (Continuous Suture).*—The longitudinal sutures first introduced have been tied so that the cystocele is pushed up and fixed to the cervix. The suture must be drawn through each time, and tension must be made by an assistant while the operator reintroduces the needle. At the other extremity of the wound a simple interrupted suture is introduced and tied. The free end of the continuous suture is then tied to one of the ends of the interrupted suture. (See Plate 28.)

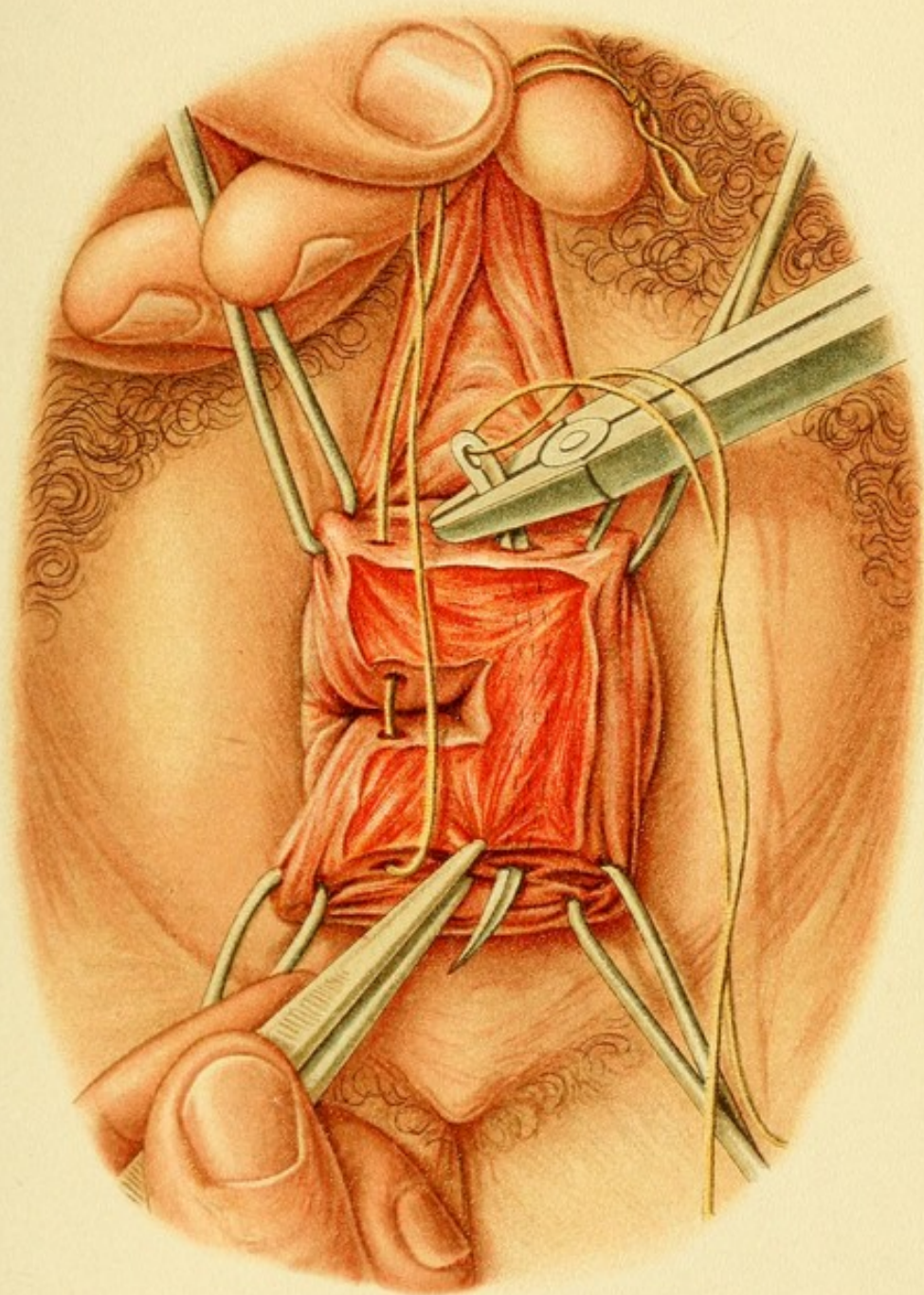
Plate 10.

High Vaginorrhaphy (after v. Winckel) (Fig. 17).—*Introduction of the Narrowing Sutures.*—The operative wound has the shape of three sides of a square, ; two sides are on the anterior or posterior wall of the vagina, and the third side on the left lateral wall. These lines are indicated by means of four double tenacula, introduced two in the anterior and two in the posterior wall of the vagina. Between the two arms of the raw area is seen the left half of the lumen of the vagina; this is closed by means of an interrupted catgut suture, which is introduced in the arm on the anterior wall of the vagina, passes over the lumen, and is reinserted on the corresponding arm on the posterior wall of the vagina. When the knot is tied, the two arms of the figure are brought together and the two walls of the vagina become adherent laterally. The third arm of the figure is drawn together by means of interrupted sutures.

are approaching the menopause. If the width of the upper third of the vagina for a certain distance is diminished by performing both anterior and posterior kolporrhaphy at the same time, a circular narrowing of the vagina is produced which prevents not only the descent of the uterus, but also the inversion of the vaginal walls. Von Winckel obtained a similar result by denuding an area on both lateral walls of the vagina in the form of a square with one side lacking, the two free arms of the figure occupying the anterior and posterior walls, while

Tab. 9.





the connecting link occupied the lateral wall. The free sides were then sutured together (see Plate 10), and the lumen of the vagina on that side was thus closed to a distance equal to the length of the free arms of the figure.

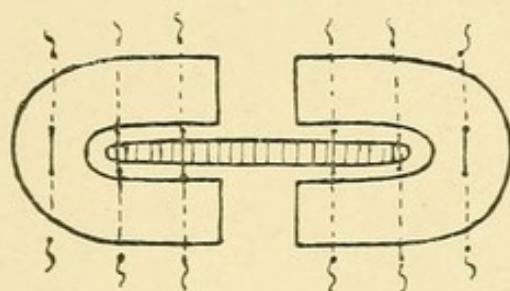


FIG. 17.—Von Winckel's high kolporrhaphy

The same thing was then done on the other side, so that an opening was left in the middle.

5. Kolpocystotomy for the Removal of Foreign Bodies from the Bladder, and Operation to Unite Traumatic Vesicovaginal Fistulæ.

The most obvious and the usual path for the removal of foreign bodies from the bladder is through the **urethra**, which usually in such cases must be *dilated*.

5a. Dilatation of the Urethra.

The tissues about the urethra are seized with two hooks, one above and one below, or with four hooks placed symmetrically at a distance of 1 cm. from the urinary meatus, and successive numbers of Simon's dilating urethral specula are then introduced until one the size of the little finger has been passed. It is not advisable to carry the dilatation further than this size, because it is apt to be followed by incontinence. The

Plate II.

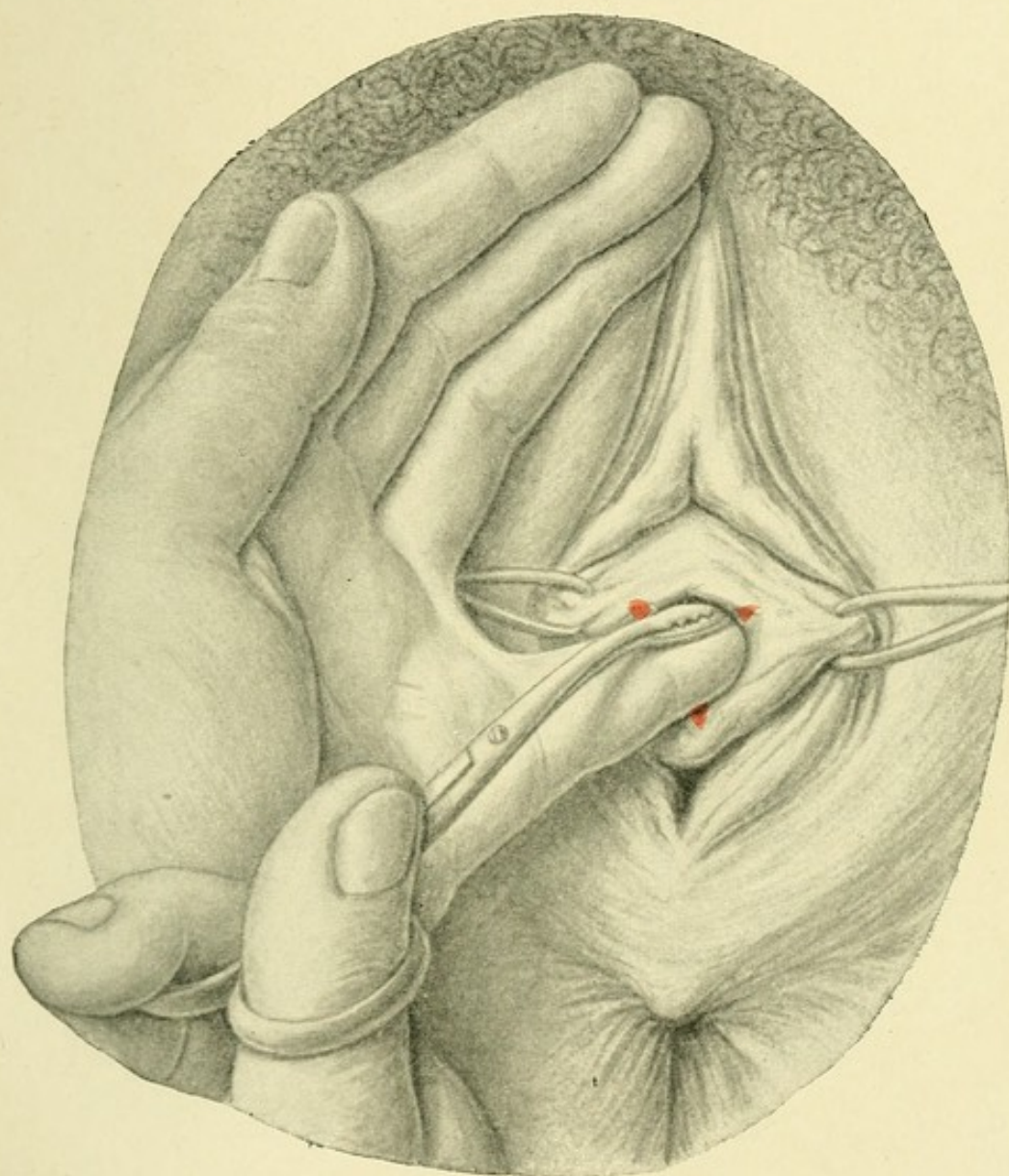
Removal of a Foreign Body from the Bladder through the Dilated Urethra.—The foreign body is located with the little finger introduced into the meatus, and a dressing forceps is passed in along the finger until it seizes the foreign body. If the latter has an oblong shape, it is seized by one extremity. The urethra is fixed by means of double tenacula inserted on each side. The figure shows three small incisions that are usually necessary.

dilatation must be carried out gradually, especially with the smaller instruments, to avoid making false passages. To prevent the latter accident, the course of the urethra should first be determined by means of a catheter. The dilators are to be well oiled and introduced with a to-and-fro rotary movement.

Dilatation may itself be a therapeutic measure—as, for instance, in the case of fissures at the inner orifice of the urethra, which are thus stimulated and heal up by granulation if the action of the sphincter is temporarily abolished. As a rule, however, dilatation is performed for the purpose of making intravesical operations, such as the removal of small tumors or foreign bodies; or, for the purpose of diagnosis, either to enable the operator to make a bimanual examination or to introduce a small Simon's speculum and admit air into the bladder. Dilatation for the purposes of diagnosis was performed more commonly in the past than it is at the present time, as cystoscopy without dilatation of the urethra by means of Casper's or Nitze's instruments, in which the source of light is directly introduced into the bladder with a catheter, has largely taken its place.

The fissures produced by dilatation must be carefully

Tab. 11.



closed by means of fine sutures. To anticipate a tearing of the tissues in an undesirable direction, as toward the vascular region of the clitoris, small incisions are made above, to either side of the median line, and below in the median line. These also must be immediately closed after the operation.

The **removal** of a foreign body, such as a calculus or a hair-pin, from the urethra, is effected, under the guidance of the little finger, with a bent dressing forceps, as indicated on Plate 11. [In general it is far more satisfactory to dilate the bladder with air in the extreme elevated lithotomy posture and to remove the small body through a short speculum.—ED.]

5b. Kolpocystotomy (Plate 11).

In the event of failure by the foregoing operation, the bladder is opened through the vagina by means of a longitudinal incision, a catheter being introduced as a guide to the knife. Care must be exercised to avoid opening the urethra at its inner orifice. Before the bulging portion of the urethra is incised, the tissues should be secured with four tenacula inserted above, below, and on either side, as in anterior kolporrhaphy. After the septum has been divided, the vesical mucous membrane, which has been made to protrude with the catheter, is held to one side by means of lateral sutures. The palpating finger can then be introduced alone or along with the dressing-forceps directly into the opening in the bladder, or the finger alone may be introduced into the dilated urethra. By means of this operation the removal of a

Plate 12.

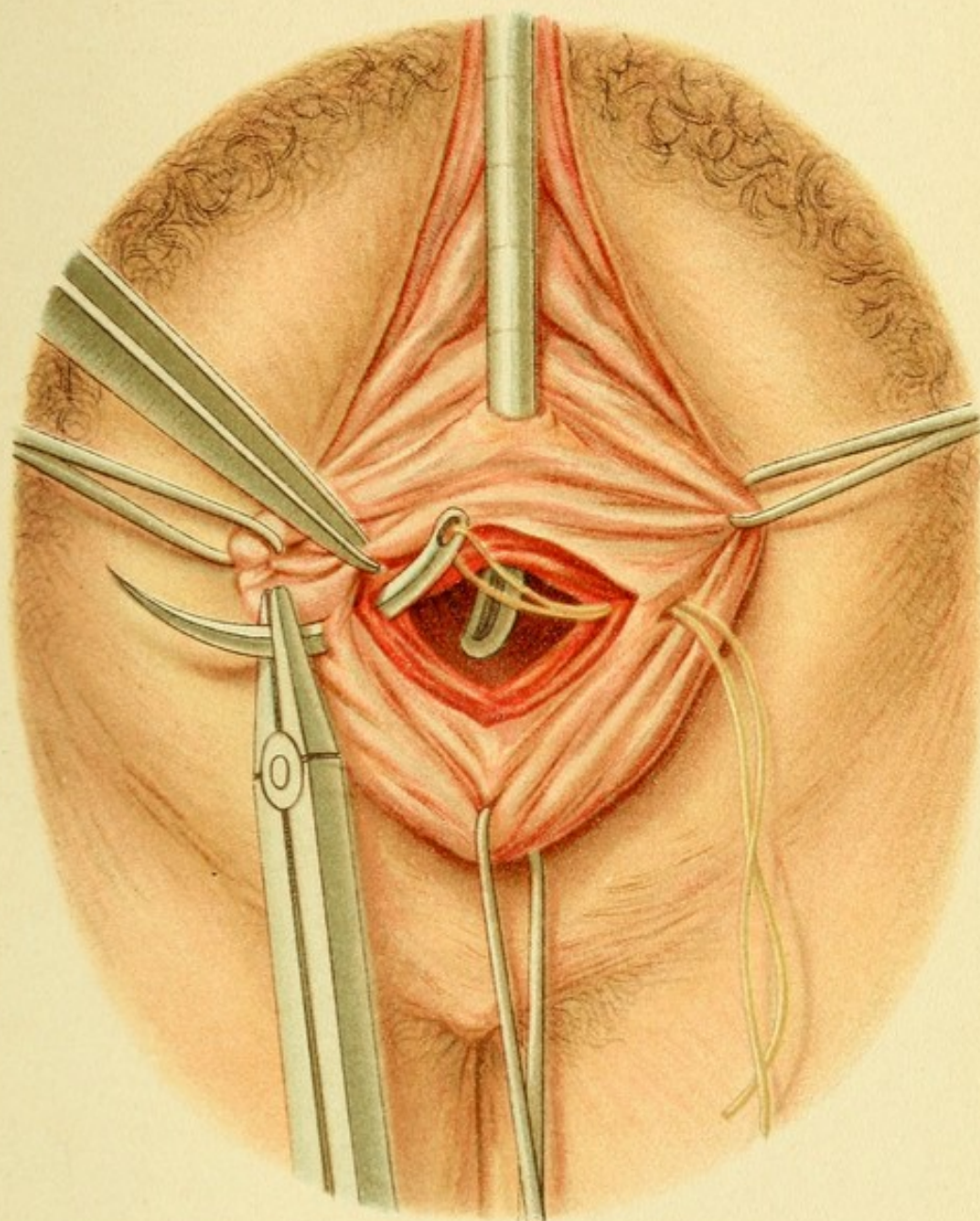
Method of Closing a Vesicovaginal Fistula (after Simon).—The edges of the fistula are denuded in the form of a funnel. The needle is introduced from the vaginal side; it is carried deep into the tissues, so as not to include the mucous membrane of the bladder, except, possibly, at the edge of the wound. The needle is then passed through the opposite side in the same way. Interrupted sutures are used and tied in the vagina. The operative field is exposed in the same manner as in anterior kolporrhaphy.

foreign body is facilitated because the opening is larger, because the resistance of a spontaneously contracting sphincter is obviated (as by the urethral route), and because the body can be reached by a shorter path. If the artificial fistula is to remain open for some time, as, for example, in the case of obstinate vesical catarrh, the edges of the wound must be closed provisionally—that is to say, the vesical mucous membrane must be united with the vagina around the opening.

The artificial fistula is *closed* by means of the operation described in the next paragraph.

5c. Method of Closing a Vesicovaginal Fistula (after Simon (Plate 12) and Fritsch).

The cicatricial edges of the original wound are first denuded so as to form an oval or funnel-shaped opening. Transverse and interrupted sutures of any material, providing it does not drain and is not absorbable, are employed and introduced as shown in Plate 12. The needle is introduced near the edge of the wound; it is then carried at some depth through the lateral submucous tissue and back in a short curve to the edge of the wound in the bladder, which, owing to the funnel-



shaped character of the denudation, is narrower than the vaginal wound. The needle should pass through the muscular layer of the vagina, and, on emerging, should avoid the vesical mucous membrane. In this way, while the edges of the vesical mucous membrane are brought into close contact when the suture is drawn together, the deposition of urinary salts on the suture which might form the nucleus for foreign bodies is avoided. The sutures must not be drawn too tight, especially if the material employed is not elastic (silk), to avoid necrosis of the tissue; nor should the sutures be too close together—they must be at least $\frac{1}{2}$ cm. apart. The tying of the sutures should not be begun until they have all been introduced, so as to avoid producing asymmetry. The sutures in the angle of the wound do not include the vesical mucous membrane; at the point of greatest tension—that is, about the middle of the wound—the sutures should be introduced with great thoroughness. After the completion of the operation the bladder should be filled with one-third of a liter of potassium permanganate solution to determine whether the sutures are water-tight.

It is well to leave a rubber *catheter* in the bladder for several days. It may be secured with straps of adhesive plaster in the region of the loins, or by means of a suture passed through one of the labia minora. The catheter should be from 18 to 25 cm. long and about as thick as an ordinary female catheter. The end that is introduced into the bladder must be carefully rounded off. It should not project more than a very short distance beyond the inner opening of the urethra, to avoid ulceration of the bladder-wall from pressure, and secondary

Plate 13.

Method of Closing a High Rectovaginal Fistula.—After the field of operation has been exposed and the edges of the wound have been freshened up, the rectal opening is closed with catgut. The needle is introduced through the rectum, passed through the rectovaginal septum, and made to emerge again in the rectum.

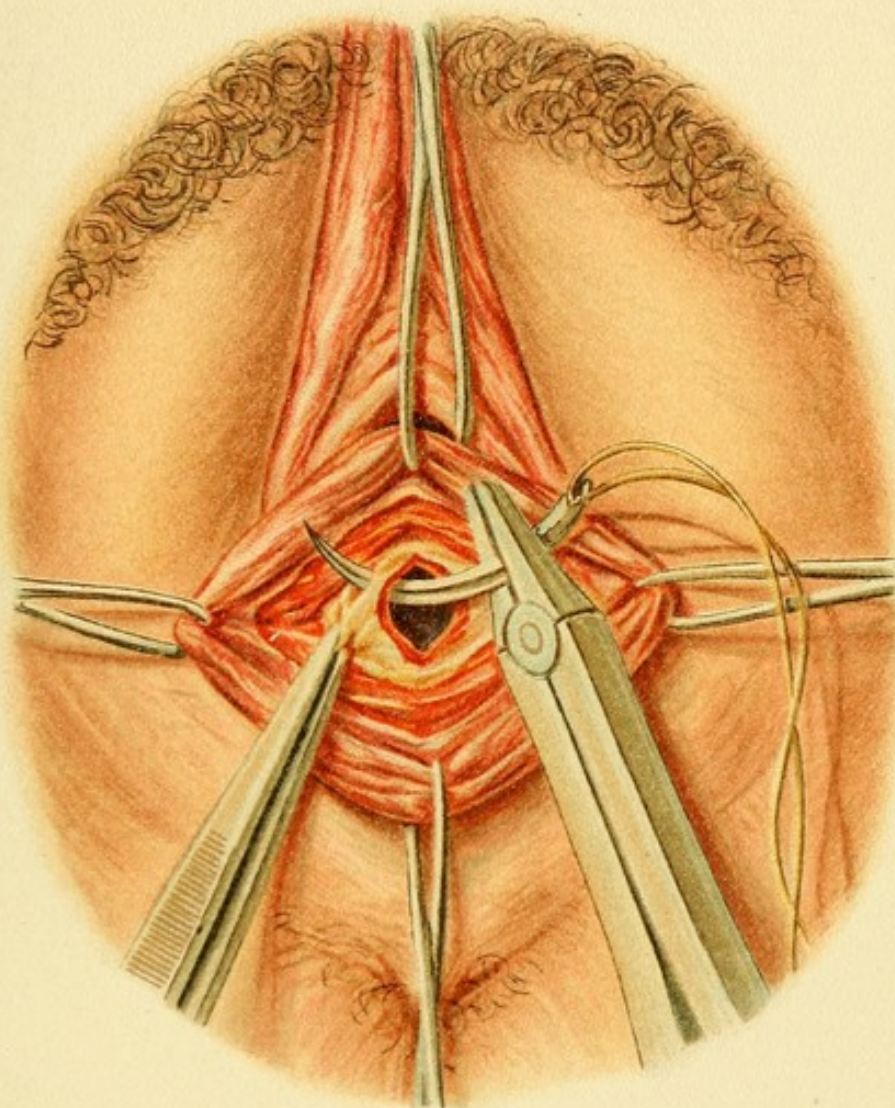
Plate 14.

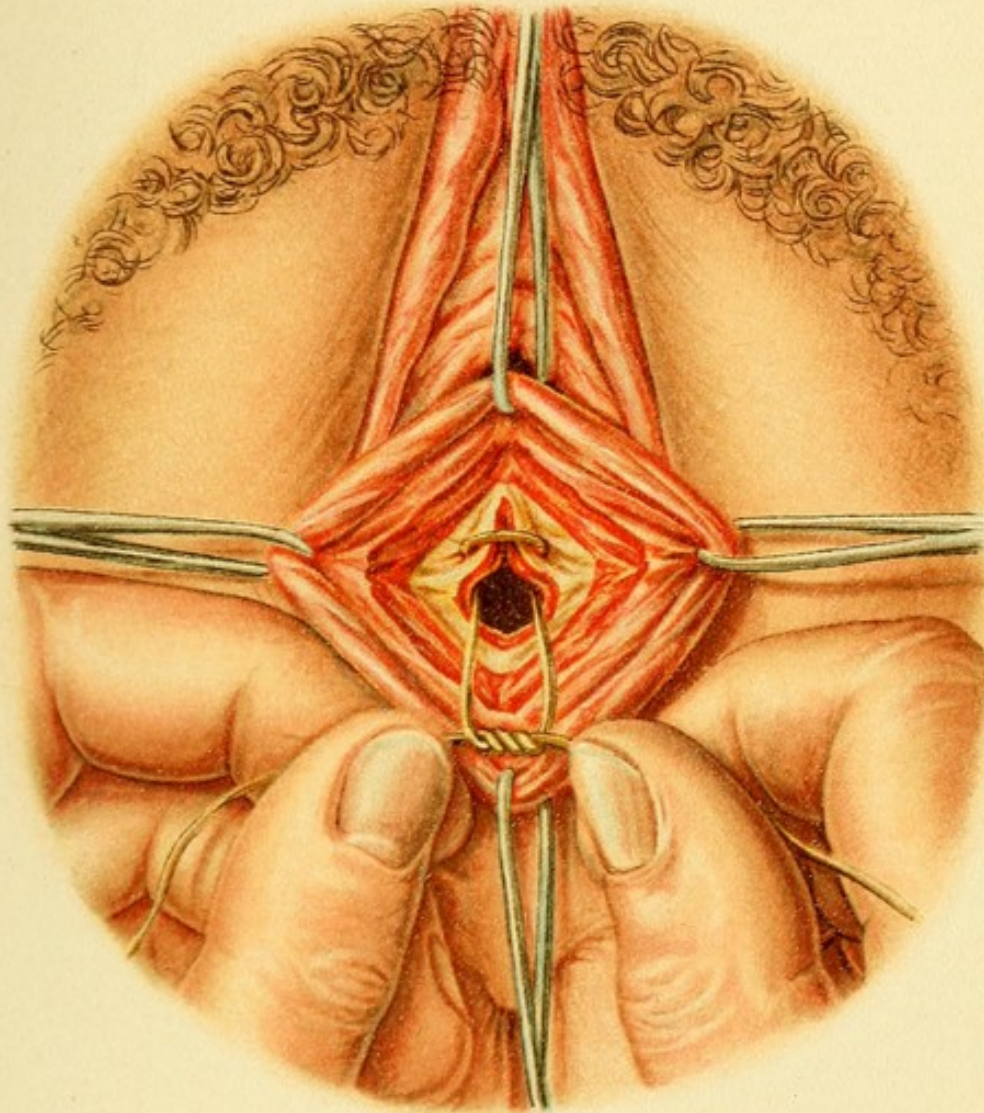
Method of Closing a High Rectovaginal Fistula.—*Tying of the Rectal Sutures.*—The sutures are all introduced before tying is begun, and the knots are laid in the lumen of the rectum. Afterward the edges of the vaginal wound are brought together over the rectal sutures.

vesical catarrh and disturbance of the reparative processes at the site of the scar. To effect this, the catheter is slowly introduced with a rotary movement, and the first appearance of urine should be the signal to stop its progress. [The most satisfactory drainage catheter is one with an expanded inner end.—ED.]

No irrigation of bladder or vagina is necessary. After the operation the vagina should be dusted with a disinfecting powder, or a strip of iodoform may be lightly introduced and left in place for a few days. The woman remains in bed for from ten to fourteen days, when the wound will have healed. If ordinary silk sutures have been used, they must be removed at the end of a week. [The credit for having made known this method of treating vesicovaginal fistula rightly belongs to Marion Sims. At the present day; however, it has been widely displaced by the flap-splitting method.—ED.]

The method of closing a vesicovaginal fistula by **splitting the flaps** was first employed by Fritsch. It is analogous to the plastic operation on the perineum by the same





author that has been described elsewhere. Fritsch employed it in cases in which, owing to extensive tissue destruction or scar-formation, it was impossible to obtain enough material for a plastic operation. A hook is inserted 2 cm. above, and another 2 cm. below, the fistula. Between these points a longitudinal incision is made over the opening, and another incision laterally around the edges of the fistula. The edges are undermined and held out of the way with double tenacula, so that, as the undermining is continued, a muscular flap is produced on each side. The fistulous tract is then freshened up as far as the vesical mucous membrane and the two edges brought together by a horizontal row of sutures running from right to left—that is to say, each individual interrupted suture is placed by introducing the needle in a vertical direction. Finally, the flaps are united by means of transverse sutures—that is, by an ordinary vertical row of sutures; in this way the sutures which unite the deeper tissues of the septum, say from the middle as far as the vesical mucous membrane, are buried, and these sutures should, therefore, be of catgut. If the vesicovaginal fistula is higher up, and the anterior lip of the os has suffered a median laceration, or if the fistula is situated altogether above the os, it is termed a vesico-cervical fistula. The operation for the closure of such a fistula requires artificial exposure of the cervical canal, as will be described in a subsequent paragraph.

6. Operation for the Cure of Rectovaginal Fistula.

The physiologic and anatomic conditions necessary for the cure of rectovaginal fistulæ are quite different from

those that obtain in the case of a vesicovaginal fistula, and the treatment is accordingly different (Plates 13, 14).

When the fistula is situated near the perineum, in the narrowest portion of the entire rectovaginal septum, it is found by experience that the only hope of success consists in splitting the entire perineal septum, or, in other words, in producing a complete perineal laceration. The injury is then repaired after the same methods as have already been described in that connection. As regards the fistula itself, the edges must be thoroughly denuded and undermined laterally, and thick flaps must be dissected away so as to provide as much elastic tissue as possible for the future septum instead of the old cicatricial tissue, and to relieve the strain on the sutures.

If the fistula is situated high up near the vault of the vagina, the edges are freshened up and undermined—that is to say, the vagina and the rectum are separated one from the other, forming an oval wound so as to enable the operator to introduce one row of sutures in the rectal wall and a separate row of sutures in the **vagina**, with the greatest possible degree of accuracy. In this way a broad septum will be obtained. The rectal row of sutures, which should consist of catgut, are tied on the inner surface of the rectum. The needle is, therefore, introduced into the rectal mucous membrane, near the edge of the wound, passed laterally through the septum wound, and made to emerge within the latter (Plate 13). After all the sutures have been introduced, they are tied one after the other, beginning in the upper edge of the wound, and the knots are pushed into the lumen of the rectum (Plate 14). A second row of interrupted sutures is then intro-

duced from the vagina and tied on the vaginal surface. The after-treatment is the same as that prescribed for complete plastic operations on the perineum.

All the operations on the *portio vaginalis* of the uterus can be performed after introducing a spatular speculum and securing one lip of the cervix, usually the anterior, or the two commissures of the os, by means of tenacula.

7. Discission of the External Os.

This procedure is indicated in stenosis of the os, a condition that is not infrequently present when the entire organ is undeveloped, and is usually combined with catarrhal cervicitis or sterility. The cervical canal is usually dilated. After introducing a posterior spatular speculum, the anterior lip of the os is drawn forward by means of a tenaculum. The two lateral commissures are then incised to the depth of a finger's breadth; two approximately triangular wound-surfaces are thus produced on each side, and these are united separately with a transverse suture so as to avoid adhesion of the wound-surfaces. Instead of introducing sutures, an iodoform strip may be packed between the raw surfaces and left in position for a week. The patient should remain in bed for a week.

During labor the dilatation-period may be abridged by means of incisions when the edge of the os is rigid. The incisions are made with a long curved Siebold's scissors under the guidance of two fingers, either in the lateral commissures, although this is less advisable on account of the danger of hemorrhage if the incision should tear, or, what is better, in the anterior and posterior lips of the os.

Plate 15.

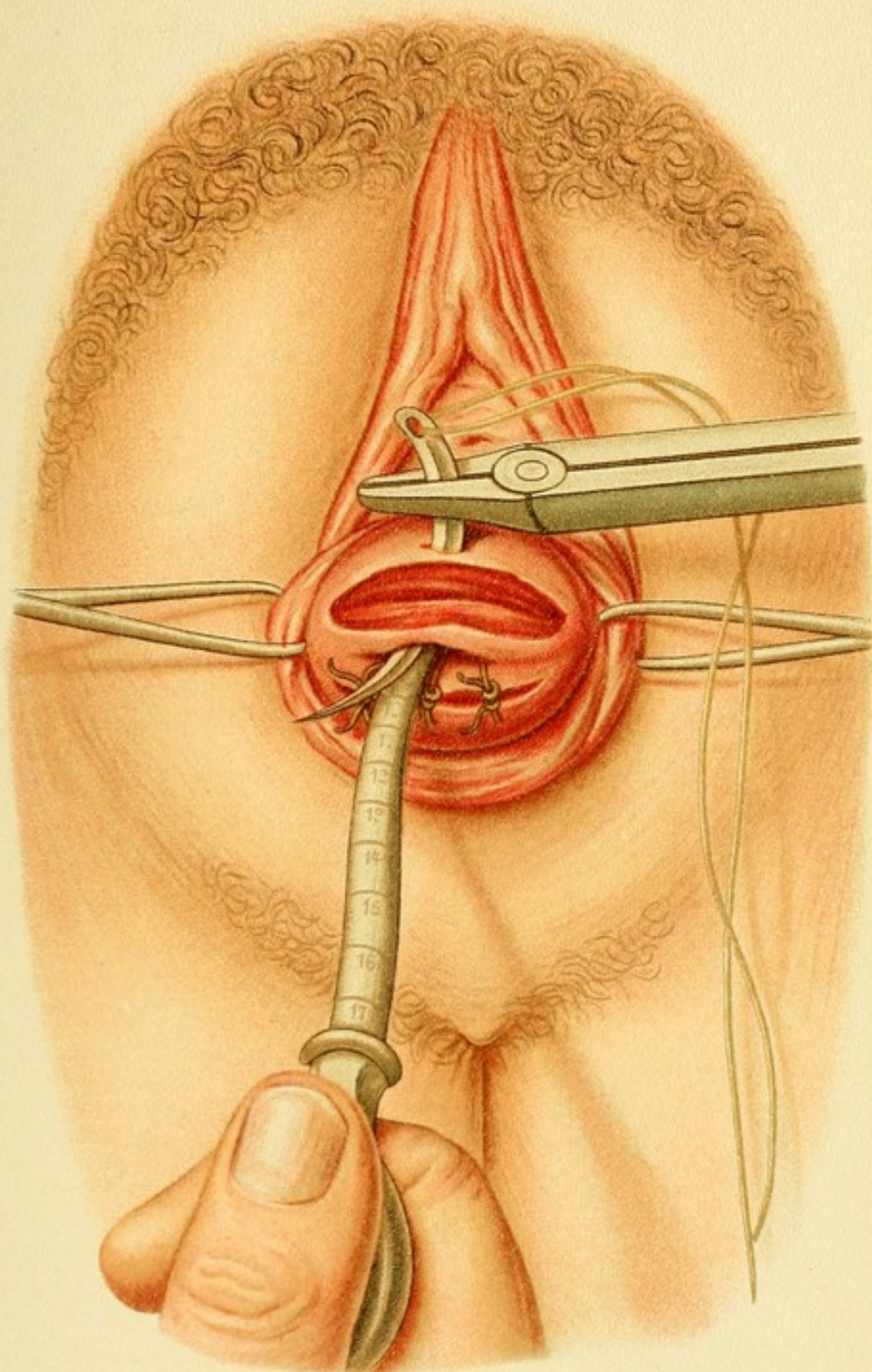
Double Wedge-shaped Excision of the Cervix in Chronic Metritis.—Showing the excisions and the method of closing the gaps by means of interrupted catgut sutures, the needle being introduced down to the floor of the wound.

As there is usually little hemorrhage, there is no need to close the incisions with sutures. This is not true, however, in the case of deep incisions of the cervix as employed by Dührssen, which must be sutured.

8. Emmet's Operation for the Repair of Commissural Lacerations.

When lacerations of the commissures of the os are produced in labor, whether on account of the rigidity of the external os, the use of forceps, or as the result of a lateral incision, the lacerations, unless they are at once united by sutures, heal by second intention and form scars that extend to the lateral vault of the vagina, and may be quite painful, or the scars may produce an insufficiency of the external os, leading eventually to the well-known condition of **eversion** of the cervical mucosa, cervicitis, and inflammatory hypertrophy of the mucous membrane.

The treatment of the laceration consists in freshening up both the anterior and the posterior lips of the os near the commissures in the form of two oblong areas which merge into each other, the two lips being held apart with tenacula. The denudation is carried laterally as far as the scar extends on the lateral wall of the vagina. The two oblong wounds are then brought into apposition and united with interrupted catgut sutures, the needle being inserted from within outward as far as the external os,



and the sutures tied on the vaginal surface ; the needle is, therefore, introduced on the outer side. The denudation in the lateral portion of the vagina is united separately. [Care must be taken not to injure the ureters.—ED.] A sound is then introduced into the cervical canal. An additional suture is passed through the edge of the commissure that has been restored. The vagina is packed with iodoform gauze. The patient must stay in bed twelve days.

WEDGE-SHAPED EXCISIONS FROM THE CERVIX.

This method is employed in chronic metritis and to check inflammatory hyperplasia of the vaginal portion of the cervix. The excision may be made either in the wall of the vaginal portion only or may include the cervical mucosa, according to the indications.

9. Wedge-shaped Excision from the Wall of the Portio Vaginalis (Plate 15).

This may be done with or without discissions, and is usually performed both on the anterior and posterior lips, which are alternately seized on their outer side with a tenaculum, the posterior wall of the vagina being depressed with a spatular speculum. Two transverse incisions are made with a knife in the anterior lip of the cervix, converging so that a wedge-shaped portion of tissue is removed. The posterior lip is similarly dealt with (Plate 15). Each wound is then closed by means of a continuous suture or several interrupted sutures of catgut which must be passed through the deep portion of the wound.

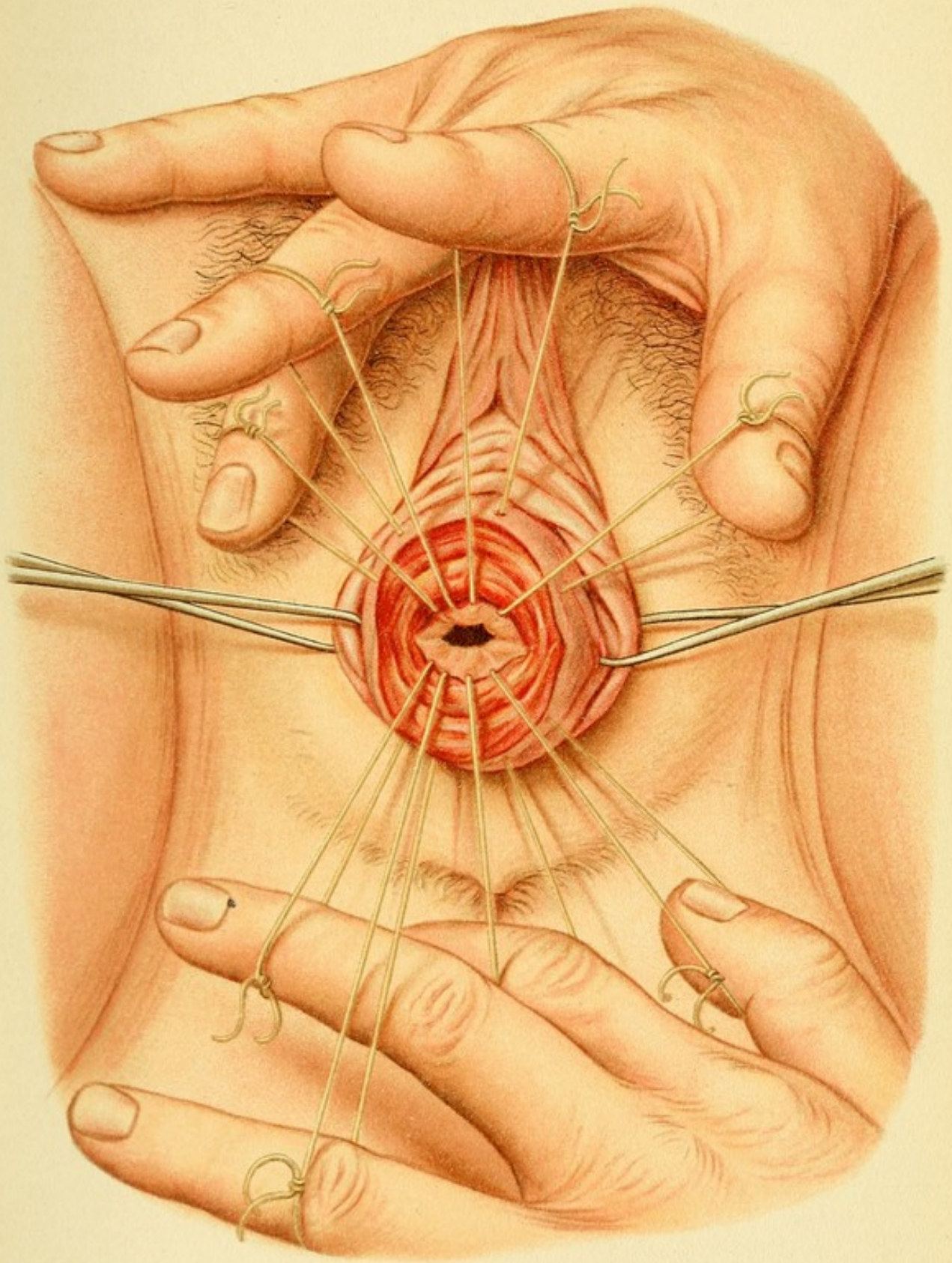
Plate 16.**Wedge-shaped Excision in Eversion and Cervicitis (after Schröder).**

—Excision of the inner half of each lip of the os, including the diseased cervical mucosa as far down as the internal os; showing the manner of introducing the sutures from the internal os toward the outer edge of the wound, beneath the entire depth of the wound. The illustration shows all the interrupted catgut sutures in position.

10. Schröder's Wedge-shaped Incision (Plate 16).

This is used in metritic thickening of the wall of the vaginal portion when the diseased and everted cervical mucous membrane is also to be removed. The scalpel is thrust deep into the middle of the vaginal portion in its longitudinal direction, so as to divide the cervix into two portions. The inner portion with the mucous membrane is removed by means of a second incision in the depths of the cervical canal, forming a right or oblique angle with the first incision. Thus there remains only one-half the thickness of the wall of the vaginal portion as far down almost as the internal os, the inner half of the mucous membrane having been removed. As most cases of eversion are due to laceration of the commissure, Schröder's wedge-shaped incision is often combined with Emmet's operation, which has just been described.

The wedge-shaped wound is covered by turning the flaps from the wall of the vaginal portion inward and uniting their outer edges to the inner edge of the mucous membrane by sutures. The needle is inserted on the inner surface of the cervical canal near the internal os, the introduction of the needle being rendered easier by the splitting of the commissures. [The operation is much easier if it be preceded by the division of each



commissure, the posterior and anterior portions of the vaginal portion being respectively dealt with.—ED.] The needle must include the entire depth of the wound and is brought out near its outer edge. Thus there results a circle of radiating interrupted sutures as shown in Plate 16, the points where the needles are introduced on the cervical canal being closer together than the points where the needles emerge on the surface of the cervix. After all the sutures have been placed, the tying is begun, the flap from the vaginal portion being at the same time turned inward with forceps. The lateral commissural incisions or Emmet's denudations are to be closed in the manner already described. The patient remains in bed for from ten to twelve days.

11 and 12. Hysteroceleisis and Kolpocleisis.

These operations are employed as a last resort in uro-cervical and ureterovaginal fistulæ when for any reason the plastic operation described in this or in the following groups is inapplicable or has proved unsuccessful. To avoid extirpation of the kidney, according to the position of the fistula, either the external os is denuded and the two lips sewed together so that they grow fast, or the vaginal portion is obliterated in the same way. In the latter case an artificial vesicovaginal fistula is first made by means of a kolpocystotomy, followed by suturing together the edges of the wound. Immediately beneath this opening a broad strip of the vagina is then denuded, and the two surfaces sewed together. Until firm union has taken place the bladder is drained with a permanent catheter.

72 OPERATIONS AFTER CERVICAL DILATATION.

FIG. 18.—Distribution of the arteries of the internal genitalia and the ureters. The internal spermatic artery supplies the ovaries and tubes; the branches of the spermatic artery anastomose with the uterine artery on both sides at the lateral margin of the uterus. The uterine artery, a branch of the hypogastric, crosses the ureter at the level of the supravaginal portion of the cervix, and from this point the cervicovaginal artery is given off. The main trunk passes along the lateral border of the uterus and to the fundus and in its course gives off numerous branches. *T*, tube; *Ov.*, ovary; *Lg. r.*, round ligament; *Ur.*, ureter; *R.*, kidney; *Ut.*, uterus.

These artificial atresiae are usually followed by serious consequences; the menstrual flow is forced to take the way of the bladder and urethra, and the urine is apt to deposit incrustations on the walls of the vagina, with the result that decomposition of the urine and cystitis usually develop.

III. OPERATIONS PERFORMED AFTER ARTIFICIAL DILATATION OF THE CERVICAL CANAL OF THE UTERUS.

Topographic and Surgical Anatomy of the Cervix and Vaults of the Vagina.

The anterior and posterior vaults of the vagina present certain differences in their development, in their anatomy and histology, in their topographic anatomy, and in their pathology. The anterior vault is flat, the posterior is a true pouch, a kind of receptacle for the vaginal portion of the cervix, for the sexual act, for the evacuated menstrual fluid, and for the descending head in labor. (See *Atlas of Obstetrical Diagnosis and Treatment*, Fig. 32, Plate 19.)

The *anterior vault* in the non-gravid condition is not in relation with the anterior peritoneal pouch; the wall of the posterior vault, on the other hand, is covered by the

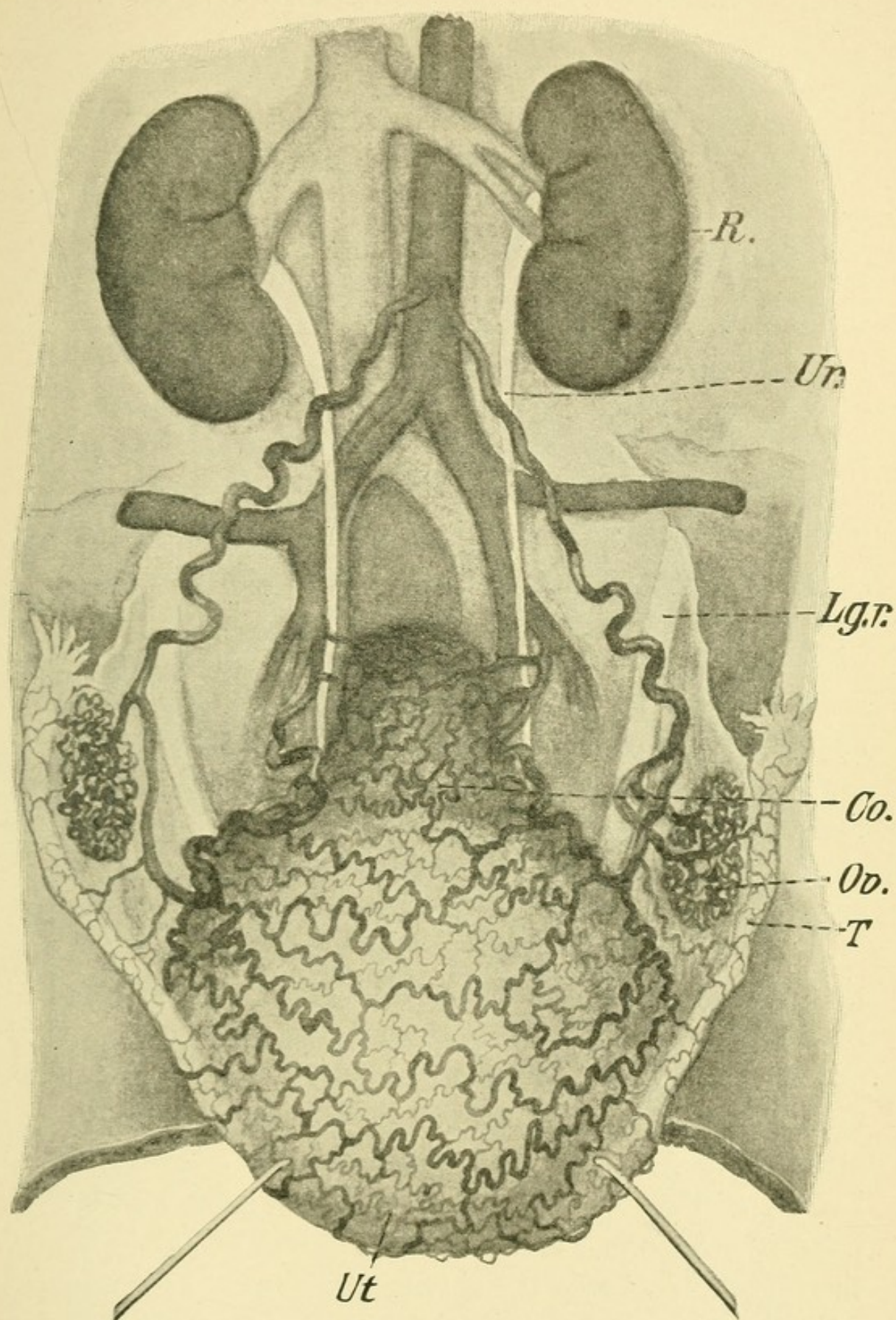


FIG. 18.

serous membrane of the posterior pouch of Douglas. The latter usually extends more deeply than the vaginal vault, and in infantile genitalia it extends further down the posterior vaginal wall than in the adult. We have, therefore, at the posterior vault an extremely thin mucous, muscular, and connective-tissue septum which divides the vagina from the peritoneal cavity. The connective tissue which forms a subserous layer in the posterior wall of the cervix is loose for some distance (Fig. 18, p. 73). At the level of the internal os, however, the serous membrane is found to be densely adherent to the outer muscular layer of the uterus.

In front, on the other hand, the loose connective-tissue septum projects above the internal os, that is, about four or five centimeters above the vaginal portion of the cervix. In this region the *bladder* is adherent to the anterior vault of the vagina and to the cervical wall as far up as a point a little higher than the internal orifice; the connective tissue is loosest in women who have borne children, and most firm in women who have in the past suffered from inflammation of the septum or parametrocystitis. [Inflammatory deposits are rarely found between the cervix and bladder.—ED.] This portion of the bladder forms a diverticulum contiguous above with the *trigonum Lieutaudii*—that is to say, the region where the ureters and the urethra have their orifices. The loose attachment of the *plica peritonei* to the uterus, at the bottom of the vesico-uterine fossa, is on a level with the point of attachment of the bladder and only a little lower than the solid fibrous tissue uniting the serous membrane with the wall of the uterus; here also the conditions in

the main are different from those that obtain in the recto-uterine (or rectovaginal) peritoneal fossa.

On each side the cervix is closely surrounded by connective tissue which contains elastic fibers, muscle-fibers, and dense bands of fibrous tissue traversed by blood-vessels, forming the true parametria. This tissue forms the base of each peritoneal fold known as the broad ligaments. (Compare *Atlas of Obstetrical Diagnosis and Treatment*, Plate 17.)

This connective tissue, therefore, shares with the vaginal connective tissue in its blood supply, which is most important in this region as the *chief arteries* of the inner genitalia, which also in large part supply the vagina, and enter the tissue of the uterus at this point (Fig. 18). The *main trunk* of the uterine artery passes horizontally toward the supravaginal portion of the cervix, after crossing the ureter, which has a forward direction, at a point about 2 cm. distant from the wall of the cervix. If the lateral vaginal vault is opened in order to reach this point of intersection, the cervicovaginal artery, which is given off at a sharp angle, is first encountered, while the main vessel makes a right angle and passes toward the fundus. In its upward course to the fundus it makes numerous bends and is surrounded by a rich network of veins and gives off numerous branches to the uterine wall; finally the artery takes a recurrent course along the tube and anastomoses with the ovarian artery. The bifurcation of the two diverging branches of the artery is near the intersection of the uterine artery with the ureter. The ureter at this point is found 2 cm. from the wall of the cervix; from this point it passes forward

along the intermediate portion of the cervix and is then only 1 cm. from the lateral wall; after that it enters the loose cervicovesical connective tissue. Along the cervix the ureter is placed between the venous plexuses of the uterus and those of the bladder and vagina.

Most of the veins and lymph-vessels are found in the subserous layer at the posterior aspect of the uterus, corresponding to the origin of the adnexa. From these points the veins accompany the arteries in their lateral course and form the uterovaginal plexuses; at the level of the external os they unite to form the uterine veins and communicate with the vesicovaginal plexuses. The lymphatic vessels, on the other hand, pass both from the cervix and from the vagina to the hypogastric lymph-glands (**lymphoglandulæ hypogastricæ**), which are situated in the angles between the external iliac and hypogastric arteries. (See *Atlas of Obstetrical Diagnosis and Treatment*, Plate 35, Figs. 77, 78.)

The cervix extends from the internal os, a narrow canal about 1 cm. in length, to the external os, being traversed by the spindle-shaped and gradually enlarging cervical canal. We distinguish the "*supravaginal*" portion and true vaginal portion, or "*portio vaginalis*."

The entire wall of the cervix consists in the main of various kinds of connective-tissue fibers containing comparatively few muscular fibers; these pass directly from both the anterior and the posterior vault of the vagina and in part return from the os to the muscular layer in the vagina. Others pass over into the broad and uterosacral ligaments, reinforced by fascia-like strands of connective tissue that run along the vessels through the

broad ligaments and contribute not a little to the elastic fixation of the uterus (Fig. 19).

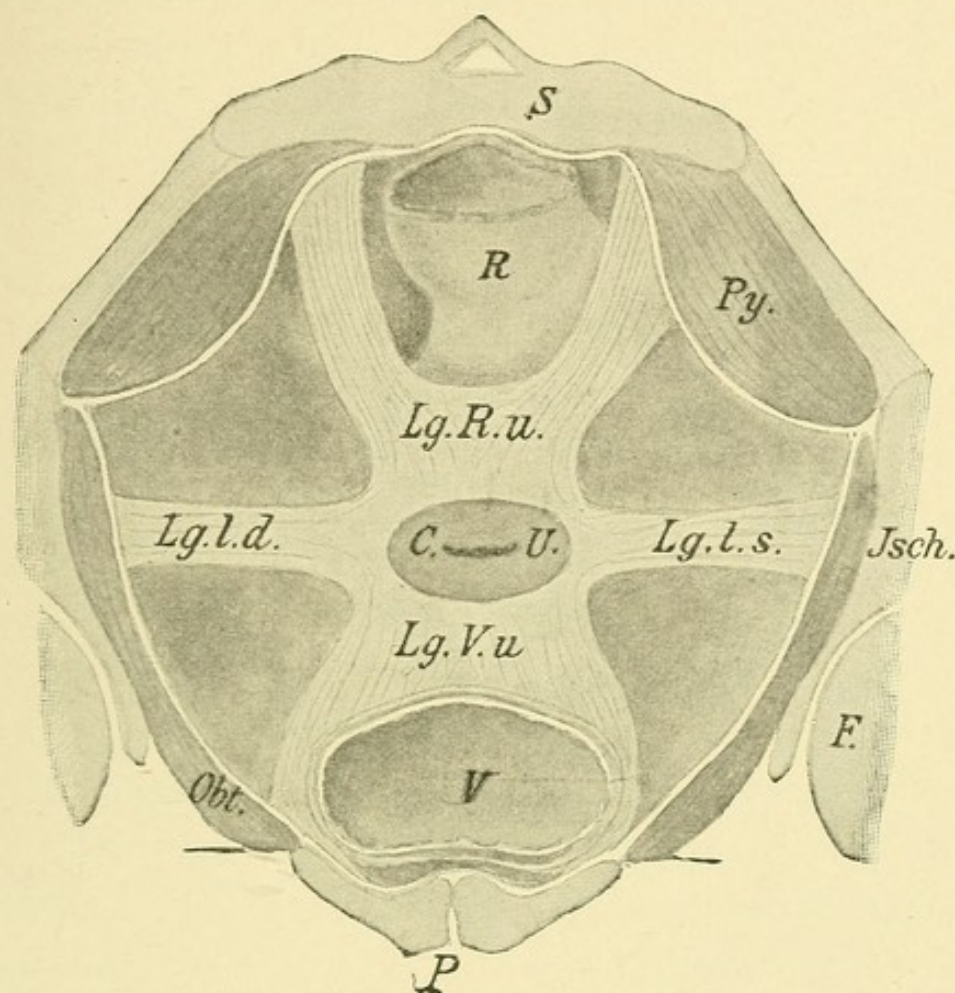


FIG. 19.—Schematic representation of a cross-section of the pelvis at the level of the internal os, for the purpose of showing the fibrous ligamentary apparatus. The cervix (*C. U.*) is supported by six fibrous ligamentary bands which connect the structure with other organs as follows: Two pass forward (*Lg. V. u.*) to the bladder (*V*) and to the os pubis (*P*); two pass laterally to the walls of the pelvis (*Jsch.*) in the base of the broad ligaments (*Lg. l. d.*, *Lg. l. s.*); while two others pass backward (*Lg. R. u.*) to the rectum (*R*) and sacrum (*S*). These ligamentous bands are accompanied by smooth muscle-fibers; the intervals between them are filled in part by loose connective tissue and in part by peritoneal tissue. These spaces are bounded externally by the pyriform (*Py.*) and internal obturator (*Obt.*) muscles.

Operations that are performed after bloodless dilatation of the cervical canal include accurate probing and digital

examination of the uterus, curettage (*abrasio mucosæ* and *raclage*), the removal of remains of the ovum, of mucous polyps, fibrous polyps, foreign bodies, and, finally, the employment of *atmokausis* (local steam bath).

1. Sounding the Uterus. Bloodless Dilatation of the Cervix.

Dilatation may be performed rapidly or gradually, both on the gravid and on the non-gravid organ. In the latter case the quick operation is performed by the introduction successively of graduated hard-rubber (Hegar) or metal (Fritsch) sounds or by introducing dilating instruments constructed on the principle of a glove-stretcher. The operation must be performed with due care. The vault of the vagina having first been disinfected, the smallest sound is introduced with slow rotary movements (Plate 21). To guard against injuring the mucous membrane with the dilating sounds (especially those that are pointed) and against the production of a false passage or even dangerous perforation, the direction of the uterine canal must first be accurately determined with the aid of a probe. Especially must it be determined whether the internal os is surrounded by concave valves with the concavity pointing toward the vagina, as the dilating sounds are particularly apt to catch in structures of this kind. The probe, after having been thoroughly disinfected, is carefully introduced after the insertion of a vaginal speculum, the position of the uterus having first been determined by bimanual examination. Special care is necessary in carrying the sound to the fundus to detect a perforation of the uterine wall. In women who have

borne children the distance between the internal and external os is, on the average, from 2.5 to 3 cm.; the distance from the internal os to the fundus is 4 to 4.5 cm., so that the whole length of the organ is, on the average, $6\frac{1}{2}$ to $7\frac{1}{2}$ cm.; in virgins the same measurements are $2.5 + 3 = 5.5$ cm.

Gradual dilatation may be effected by introducing iodoform gauze, laminaria, or other tents. A speculum is introduced into the vagina, the anterior lip of the os is seized, and the smallest tent is introduced into the internal os, or, if that is impossible, as far as the internal os; it is then packed tight with gauze and allowed to remain in place from six to twelve or twenty-four hours, according to the body-temperature. To prevent infection, the tents must be kept for weeks beforehand in a mixture of iodoform, ether, and alcohol; or they must be boiled for a few minutes in a 5 per cent. solution of carbolic acid. After the first tent has been in place for a number of hours, the internal os begins to yield and a thicker tent and finally several thicker tents may be introduced, until the cervical canal admits a finger. The removal of greatly swollen tents is often very difficult; if the internal os has been spasmodically contracted and the tent has been reduced to a pulpy mass so that it cannot be seized with instruments, its removal may then require several deep incisions. [Dilatation with tents has been widely abandoned in recent times.—ED.]

The cervical canal may be rapidly dilated during labor by inserting first one and then two and finally the remaining fingers into the cervical canal (**accouchement force**), until the presenting part can be brought down or

a leg can be seized. Dilatation may also be effected by hard-rubber dilators. Other methods, however, such as tamponade with glycerin-iodoform gauze or the introduction of dilatable rubber bags (metreurynter) of gradually increasing sizes into the cervical canal or above the internal os are to be preferred in the case of gravid or parturient women (Barnes, Fehling, and Champétier de Ribes).

The Barnes bags, in either small or medium sizes, are violin-shaped and provided with a rubber tube through which the bag may be distended with an antiseptic or aseptic (non-poisonous) fluid. By means of this tube, which may be hung over the foot of the bed and weighted with one or two pounds, a degree of traction can be exerted which, together with the distending pressure, suffices to complete the dilatation of the os within a short time—say half an hour (Mäurer, Dührssen).

The method of introducing the metreurynter is as follows: After bringing down and fixing the vaginal portion of the cervix and disinfecting the cervical canal, the latter is dilated with the small- and medium-sized metal dilators, and the rubber bulb, which has been previously sterilized by boiling, is held in a large dressing forceps with smooth jaws and introduced as far as the internal os. The metreurynter is then distended with a sterile or feebly antiseptic fluid by means of the tube attached to it. Lysol should not be used, as it macerates the rubber. The vault of the vagina is packed with sterile cotton, both to expedite the dilatation and relaxation of the cervix and to prevent the escape of the rubber bulb. After a few hours a larger bulb is introduced, and

this is repeated at intervals until the desired degree of dilatation has been secured. In some women the procedure has the disadvantage that while the os is dilated the fundus of the uterus is not stimulated to contract; instead, a spasmodic stricture may be produced at the internal os, causing a rapid contraction of the latter as soon as the rubber dilator is removed.

After the internal os has been sufficiently dilated, the cavity of the uterus can be examined by palpation, remains of membranes can be removed with the finger, a procedure that, under certain circumstances, is to be preferred to curetment for diagnostic purposes. But even direct palpation does not always secure against error, as is shown by Werth's case, in which a malignant growth of the chorion was separate from the decidua, which was found to be entirely benign on histologic examination, so that curetment or palpation of the uterus might have failed to reveal the necessity for a radical operation. A total extirpation of the uterus was nevertheless performed on account of the history and of the subsequent course of the disease, which was marked by atypical hemorrhages. According to A. Martin, direct palpation does not even enable one to determine whether small multiple myomata have been properly enucleated.

2. Curetment (Abrasio Mucosæ; Curettage; Raclage).

This operation is performed for the purpose of obtaining specimens of the mucous membrane from the cavity of the uterus for examination and for the purpose of removing diseased endometrium or retained secundines.

As the uterine wall in subinvolution of the organ may be abnormally soft, curetment must be performed with the following definite precautions: The length of the uterine cavity must first be determined with a probe, or, since preliminary dilatation is usually necessary, with a dilator; the curet should be blunt at the end, and its cutting-edge should not be too keen. The instrument is introduced very cautiously as far as the fundus, and drawn down with a steady, even movement to the internal os. Successive strips of the mucous membrane are thus removed at each stroke of the curet. First the anterior, then the posterior, wall, then the two narrow sides, and finally the fundus, are to be curetted. Before terminating the operation the uterine cavity is wiped out but not irrigated, unless the operator is certain that no perforation has been made. The Fritsch-Bozemann double catheter is the best instrument for irrigation. To make sure that there is no perforation, the uterus can be examined with the hand applied to the outside of the abdomen. [This is not at all a reliable procedure.—ED.]

The operation is terminated by packing the uterine cavity with sterile iodoform gauze, which remains in place twenty-four hours. The woman must stay in bed a week. If the uterine muscle is flaccid and hemorrhage continues to recur, a styptic should be applied to the cavity immediately after curetment, and, if necessary, at some future time. To remove secundines that cannot be taken out with the finger, an abortion forceps or broad dressing forceps is necessary.

3. Removal of Polyps.

Mucous polyps growing from the mucous membrane may be twisted off with a polyp forceps or ligated at the base and then removed. It is well to follow the operation with curetment and the application of styptics to the cavity.

Fibrous polyps are not infrequently regularly "delivered" after spontaneous dilatation of the cervix. In other cases the cervix is dilated artificially and the tumor enucleated with the finger, the base being packed with sterilized ferripyrin or chlorid of iron gauze. If additional prominent tumors are felt by the palpating finger, they must be seized with an instrument and loosened with the finger. Large polyps are to be removed in sections. The instrumental procedures should be carried out under the guidance of the palpating finger.

4. Vaporization of the Uterine Cavity (*Atmokaussis*).

This is a method recently introduced by Sneguirew and developed by Dührssen and Pincus; the latter has devised a number of improved instruments. It is used to arrest metrorrhagia and menorrhagia, when the condition has resisted all other methods of treatment, when curetment and cauterization are impossible, and a radical operation is not necessary. The treatment of obstinate relaxation of the uterus and of chronic metritis without disease of the adnexa in multiparæ has been successfully carried out with the aid of atmokaussis. The method has also been used in a series of cases by the author himself, but there is as yet no unanimity of opinion as to its value. That vaporization is a sovereign remedy against uncontrollable

hemorrhage at the climacteric cannot be doubted, dissenting opinions to the contrary notwithstanding, as the efficiency of the treatment is vouched for by authorities like Fritsch and von Winckel.

The author has used vaporization for three years in about 150 cases; his method, based on that experience, is as follows: Twenty-four hours before vaporization a moderately large laminaria tent is introduced. Before the application of the steam the vagina and the uterine cavity are carefully cleansed both mechanically and with antiseptic solutions; the anterior and posterior walls of the vagina are covered with thin moist pads of cotton, and the grooved speculum, which is introduced, is similarly padded. The pad covering the anterior wall of the vagina and urinary meatus is held in place by the Muzeux forceps, which fixes the anterior lip of the os. The catheter, which is provided with a cervix protector consisting of "celluvert," is then introduced, the stop-cock which admits the steam being closed. The latter may have a temperature ranging between 102° and 120° C. (215° and 248° F.), according to the object of the procedure. The double catheter, which has been previously sterilized, must be kept in a cool aseptic solution to prevent its producing too great a heating effect by contact.

The stop-cock is now opened, and the steam, which rapidly condenses, rushes into the uterine cavity. The uterus contracts in a short time, and this contraction, as the author and his assistants have determined, is followed at first by retardation of the pulse, then by its entire cessation, and after that by increased frequency and

reduction in volume ; at the same time a distinct fall in the blood-pressure at the radial artery may be recorded by Gärtner's tonometer.

As the uterus contracts the condensed steam is expelled through the outflow tube mixed with blood and mucus. The application generally lasts from ten to fifteen seconds ; in other cases, if atresia is not to be feared or even perhaps desirable, it may last as long as two minutes.

The author always performs a preliminary exploratory curetment. Carcinoma of the body of the uterus is always a contraindication. The operation is also contraindicated in young individuals, in the presence of inflammation of the adnexa and of appendicitis with tumor formations.

The woman must stay in bed ten days after the operation. During this time the genitalia are washed with disinfecting solutions ; the cavity of the uterus is not disturbed. After two or three weeks, or sometimes earlier, the sound is introduced to break up any adhesions that may have formed.

IV. OPERATIONS PERFORMED AFTER DISSECTING AWAY THE VAULT OF THE VAGINA AND ENLARGING THE CERVIX BY OPERATIVE MEANS.

The topographic and surgical anatomy of this operation is the same as that just described for the last two groups.

1. Division of the Anterior Wall of the Cervix.

Bloodless dilatation of the cervical canal offers obstacles to any subsequent operative procedures in the uterine

Plate 17.

Supravaginal Amputation of the Cervix (after Kaltenbach).—Circular incision of the vaginal portion beginning in the anterior vault of the vagina. The operating field is exposed as for an anterior kolporrhaphy, the two lips of the os being held with double tenacula.

Plate 18.

Supravaginal Amputation of the Cervix (after Kaltenbach).—Ligation of the uterine artery. The artery is, of course, ligated before the neck is excised, not, as shown in the picture for the sake of clearness, after excision of the cervix. The ligation is performed opposite the supravaginal portion of the cervix, the point being readily recognized by the pulsation.

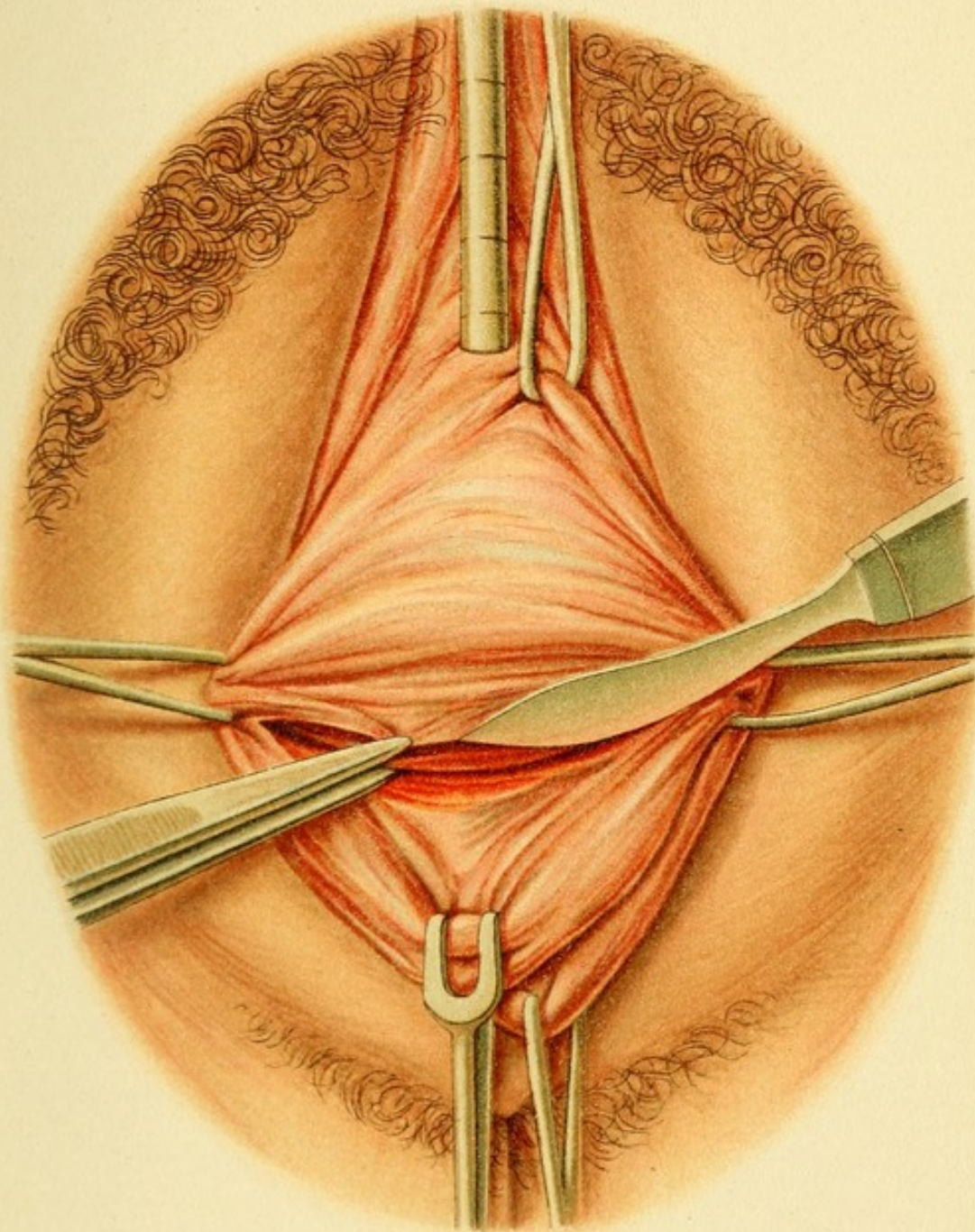
Plate 19.

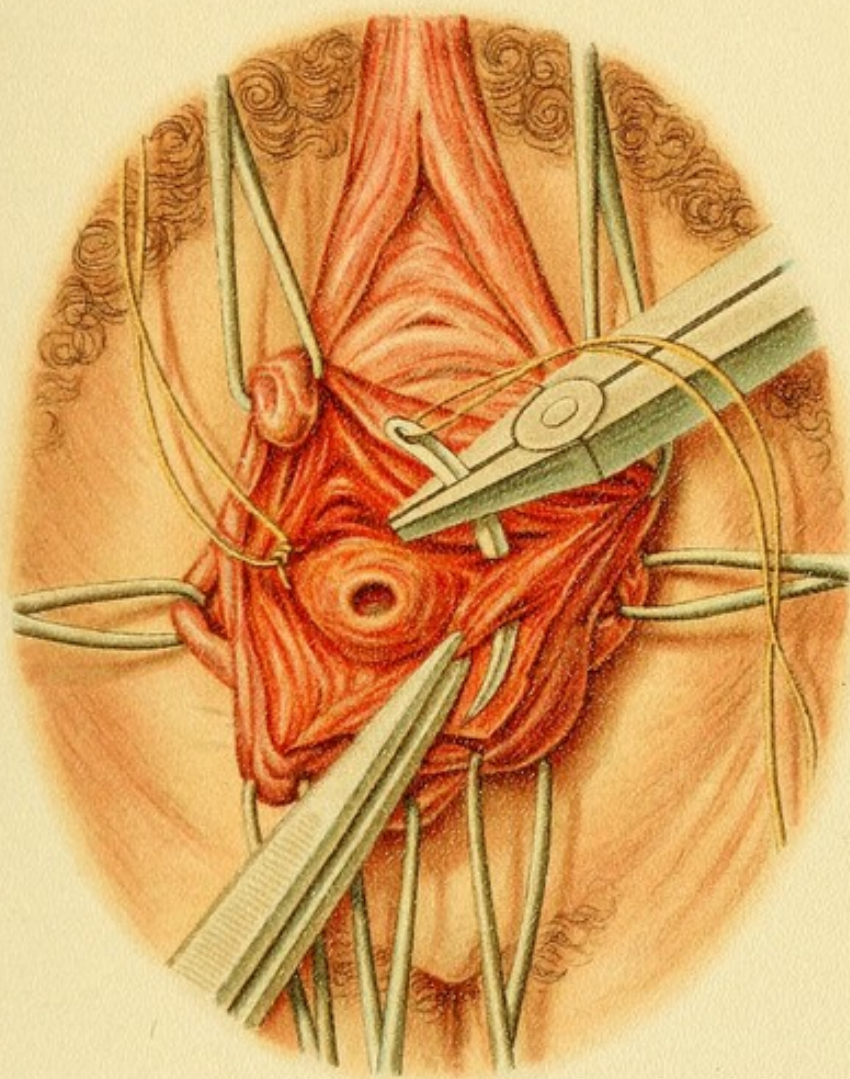
Supravaginal Amputation of the Cervix (after Kaltenbach).—Division of the cervix, which has been dissected out; the anterior half of the wall is divided first. On either side the ligatures of the uterine artery are seen. Sutures are then introduced, uniting the border of the wound in the cervical mucous membrane with the vaginal wound. [The figure represents this as having been carried out anteriorly.—ED.]

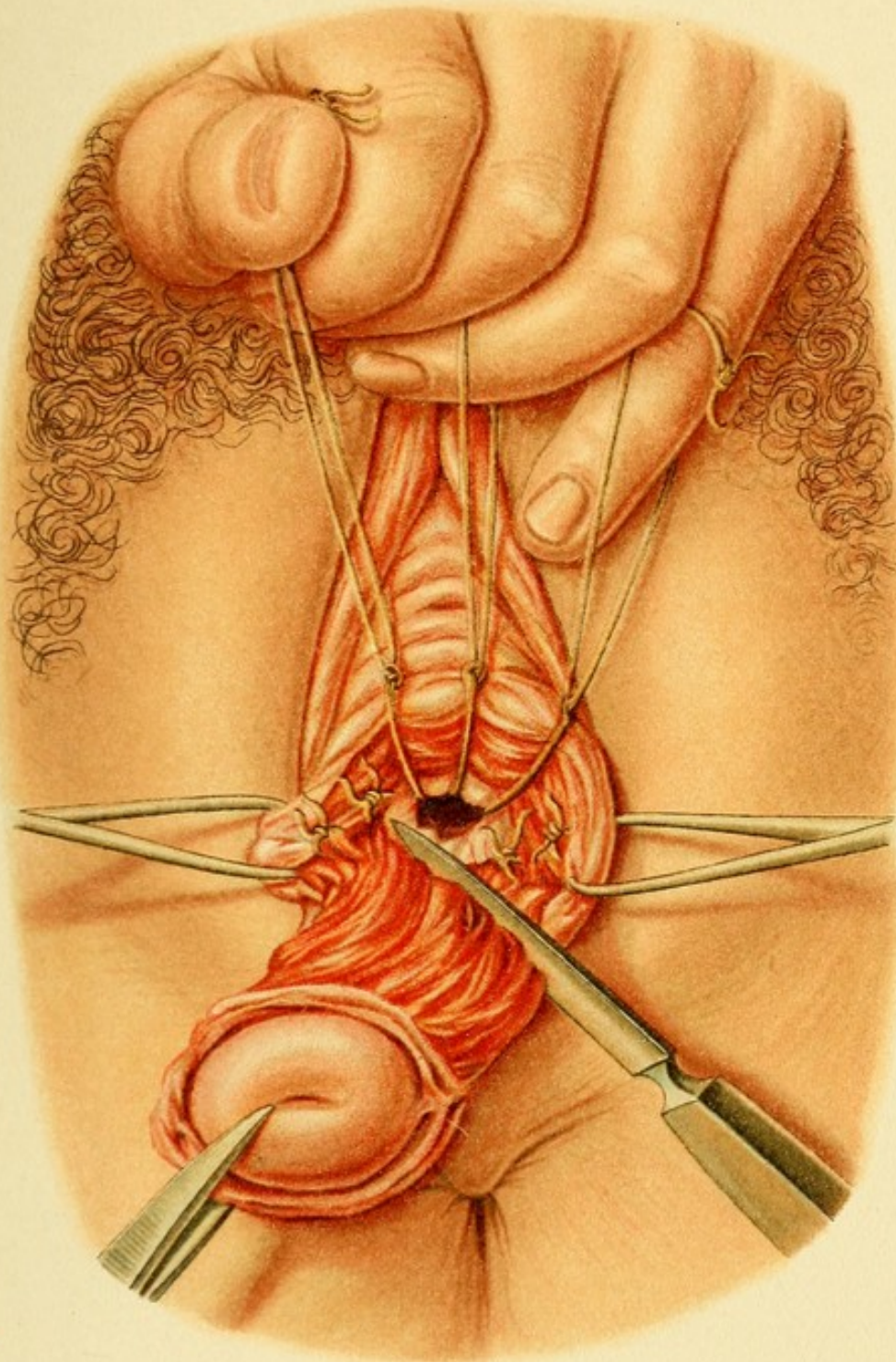
Plate 20.

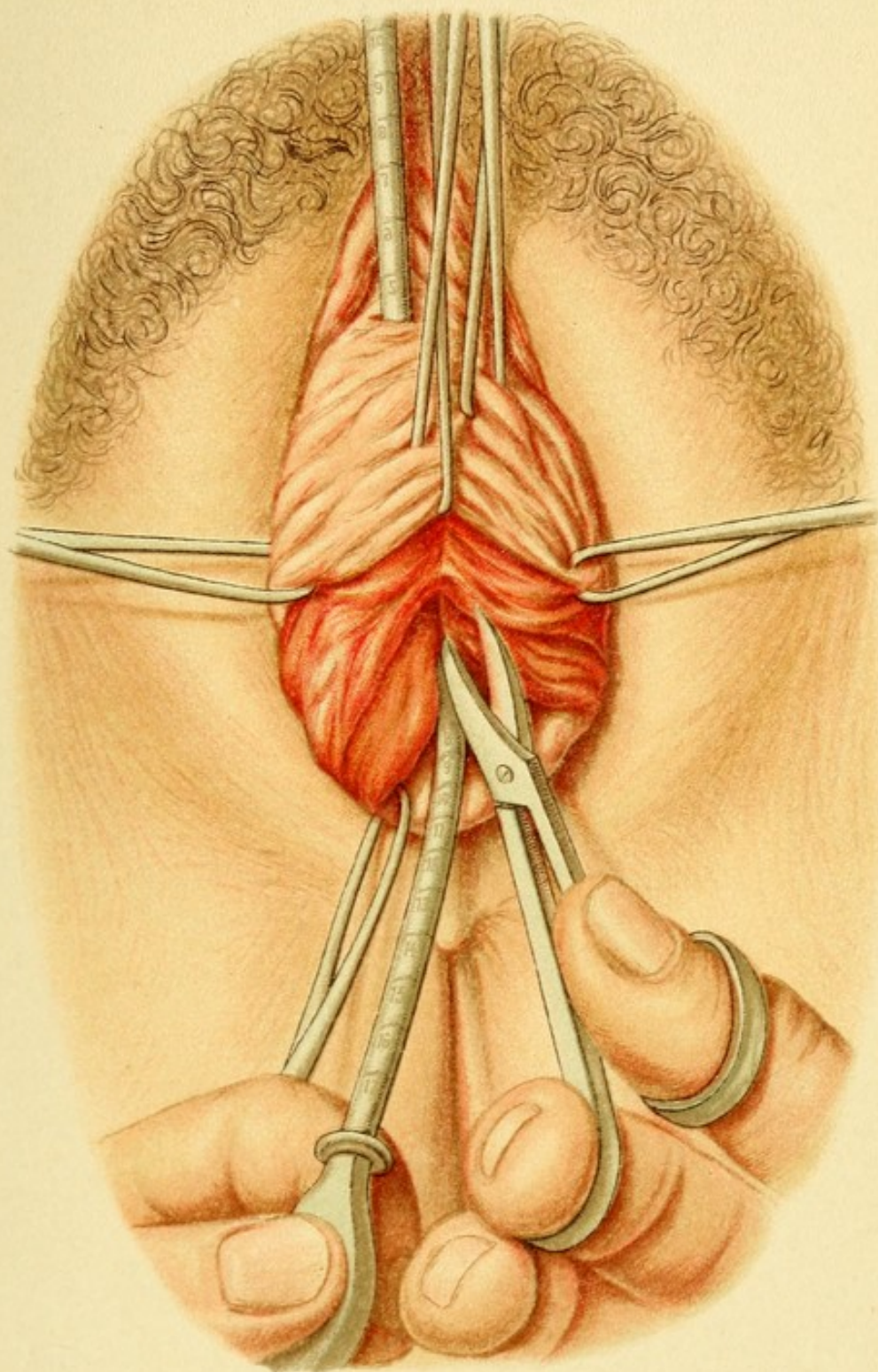
Enucleation of a Polypous Fibromyoma after Division of the Anterior Wall of the Cervix.—Separation of the anterior wall of the cervix; a catheter or probe is introduced into the urethra so as to avoid any injury to the wall of the bladder. A second probe serves as guide for the scissors in dividing the inner os.

cavity similar to those found in operating in the bladder after dilatation of the urethra—namely, increased difficulty of manipulation from the fact that the object to be removed has to be carried through the entire length of the cervix. Moreover, the internal os varies greatly as regards its dilatability, is often enlarged with difficulty, and rarely admits a finger. A. Martin first conceived the idea of dividing the entire anterior wall of the cervix up









to and including the internal os. To do this the bladder must be dissected away from the cervix after the anterior vault of the vagina has been opened by a transverse or T-shaped incision.

The vaginal portion is drawn down into the speculum, the anterior lip of the cervix seized with a double tenaculum and drawn down until the entire anterior vault of the vagina comes into view. By means of two hooks or double tenacula the folds may be drawn out, and, with the aid of a third tenaculum, drawing the *columna rugarum* toward the urethra, the anterior wall of the vagina may be stretched out perfectly smooth. This surface is crossed by a transverse fold (Fig. 21) corresponding to the line of attachment of the urinary bladder, which consists of firmer tissue than that of the fossa, which contains the loose cervicovesical connective tissue. In dissecting the bladder away this fold must be avoided. The dissection is carried through the looser tissue to the level of the internal os extraperitoneally. The serous membrane may be detached if necessary. The dissection is accomplished by means of a transverse incision between the anterior lip of the os and the transverse fold above referred to (Plate 17), the loose connective tissue being pushed aside with a blunt instrument, as shown in Fig. 15.

To enlarge the wound, and at the same time to remove the bladder beyond the reach of cutting instruments, the upper tenaculum is inserted into the upper surface of the wound and drawn upward; or a narrow retractor may be used instead of a tenaculum. The wound is then enlarged in both directions with a blunt instrument. The dissecting scissors should always be held close to the dense tissue

Plate 21.

Enucleation of a Polypous Fibromyoma after Division of the Anterior Wall of the Cervix.—Dilatation of the internal os with Fritsch metal dilators.

Plate 22.

Enucleation of a Polypous Fibromyoma after Division of the Anterior Wall of the Cervix.—Morcellement of larger polyps and removal of small polyps near their base after the latter has been ligated.

Plate 23.

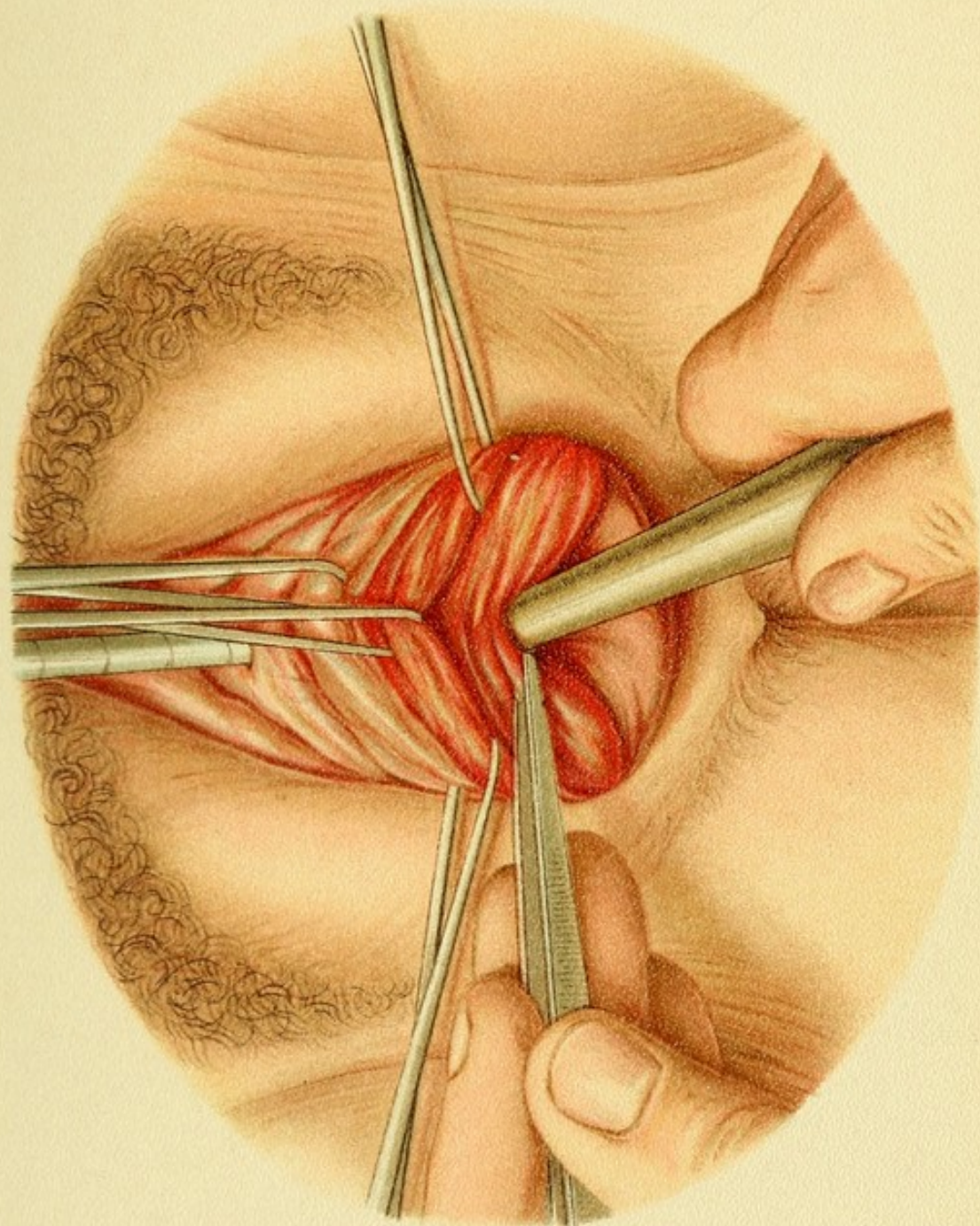
Enucleation of a Polypous Fibromyoma after Division of the Anterior Wall of the Cervix.—Method of closing the cervical wound with interrupted catgut sutures tied in the lumen of the cervix (illustration of the surgical double knot).

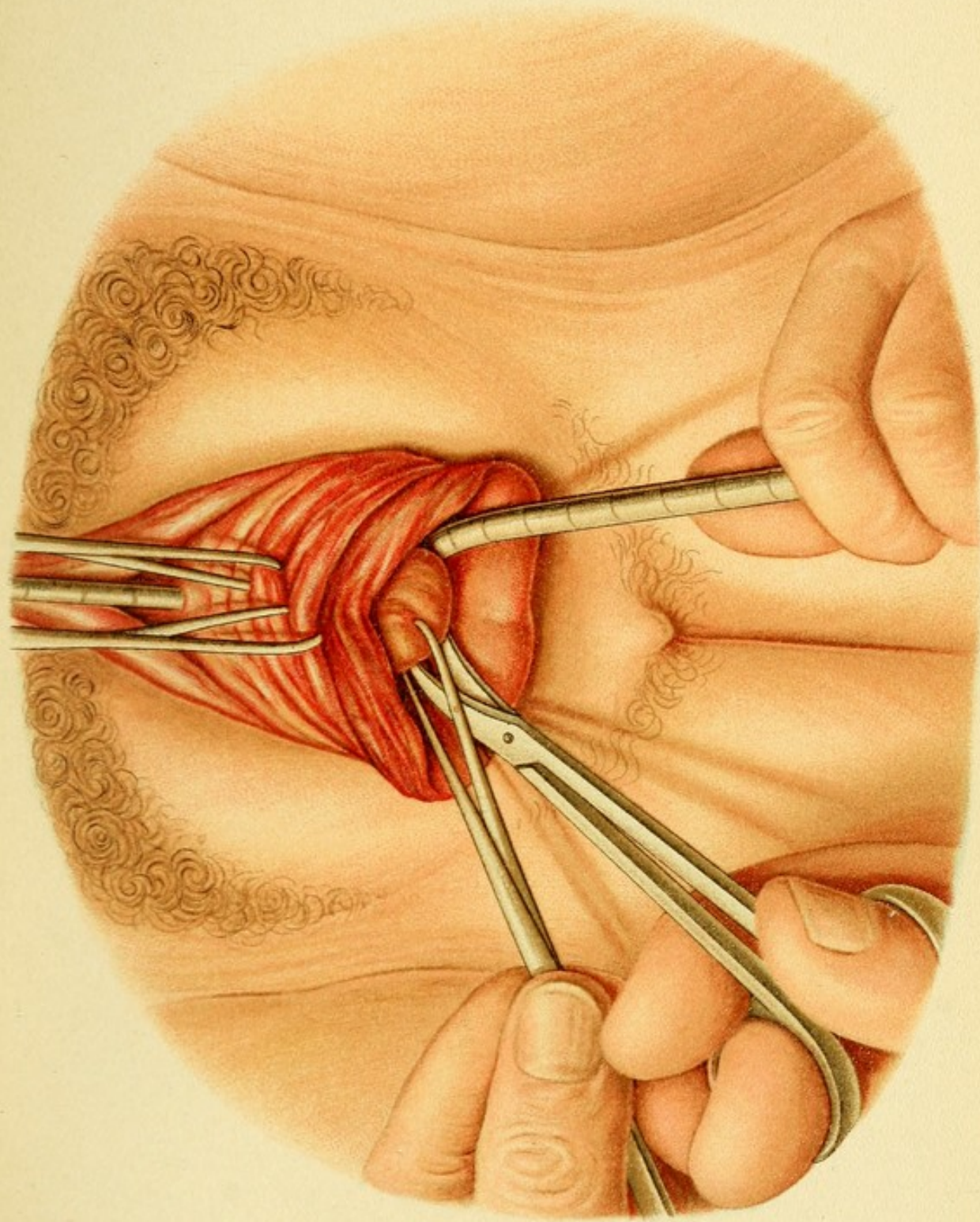
of the wall of the cervix. As soon as the latter has been completely exposed, it is divided along the median line as far as and including the internal os (Plate 20).


If a preliminary simple dilatation of the cervical canal has been performed (Plate 21), this operation enables us to palpate the uterine cavity, or proceed to certain other operations, such as the removal of foreign bodies (a broken uterine catheter or a tent that has accidentally entered the uterine cavity); the removal of polyps and prominent submucous fibromyomata with or without preliminary morcellement (Plate 22). The method of performing the latter operations is the same as that already described.

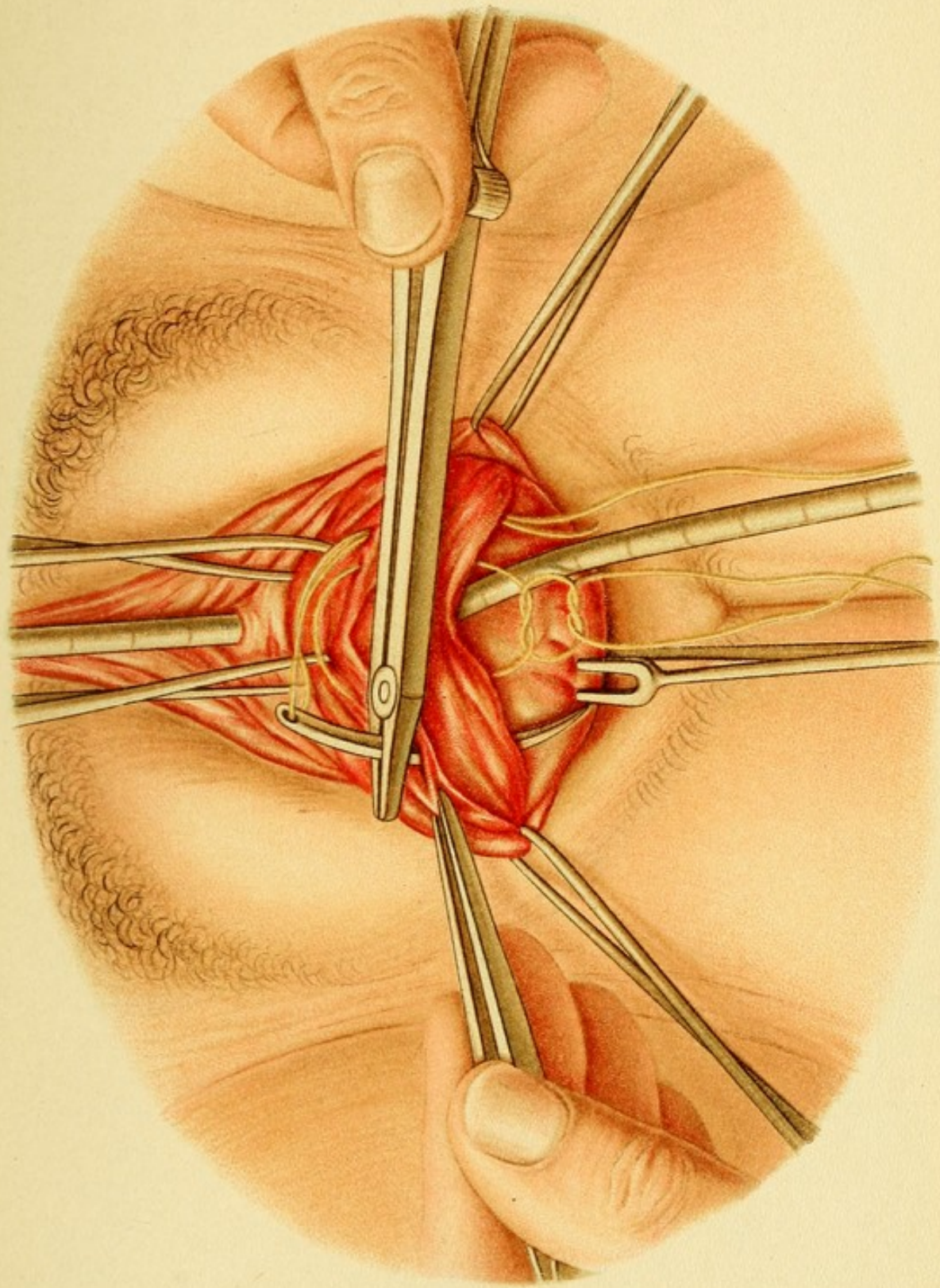
The divided wall of the cervix is afterward closed by means of transverse catgut sutures passing through the entire wall of the viscus from without inward, and tied in the cervical canal (Plate 23). The bladder, which has been separated from the cervix, is reattached by means of a transverse row of sutures, so that no "dead spaces" are

Tab. 21.









left in the depths of the wound. One or two very deep or buried sutures, as shown on Plate 20, are usually required. The edges of the incision in the mucous membrane must be brought into accurate apposition and included in the last-mentioned sutures (Plate 28).

Simple division of the vesicocervical septum and of the parametrium is performed as a preliminary measure to the following operations: Ligation of the uterine artery, supravaginal amputation of the neck of the uterus, operations for the cure of vesicocervical and vesico-ureterocervical fistulæ, and the evacuation of abscesses in the parametria.

2. Ligation of the Uterine Artery.

This is performed as a preliminary step in total or partial extirpation of the uterus; as an independent measure in the presence of profuse bleeding myomata in patients who, as the result of menorrhagia lasting for years, have become so reduced in their general condition and whose hearts are so weak that they cannot be subjected to the risk of a radical operation or even to anesthesia—in other words, as a palliative operation.

It has been shown in the consideration of the anatomy that the uterine artery approaches the uterus from above and from the side, and at the level of the supravaginal portion of the cervix, 2 cm. from the wall, divides into its branches; this point is, therefore, about 3 cm. above the external os. The artery at this point intersects the ureter so that the latter, which up to that point was median and posterior to the artery, now lies behind the horizontal portion of the artery and passes forward in

front of the branch known as the cervicovaginal artery. At the same time it approaches to within 1 cm. of the wall of the cervix, then converges toward the ureter of the opposite side, and enters the posterior wall of the bladder after passing through the loose connective tissue of the cervicovesical septum.

It follows from the foregoing description that the uterine artery is most accessible when the posterior wall of the bladder and the ureters have been detached from the cervix as far as possible in a lateral direction—that is to say, when the parametria have been actually divided into two portions, the anterior of which includes the bladder and ureters, while the posterior portion contains the neck of the uterus and the uterine vessels.

Hence there are two methods of effecting the ligation: Either the lateral walls of the vaginal vault may be opened separately and each ureter pushed away from the uterus with the finger, after which three or four ligatures are placed about the cervicovaginal artery, about the horizontal portion, and finally about the main trunk of the uterine artery itself; or access may be obtained by a transverse incision in the anterior vault of the vagina, which is enlarged as much as possible in a lateral direction; the bladder and both ureters are then pushed back as a whole, thus avoiding the dangers of injuring them, of passing a ligature about them, or of producing a kink in one of them. The steps in the operation are, therefore, the same as in that previously described (see p. 87), except for the division of the cervix. Instead of the latter procedure the pulsating vessels are sought for with the palpating finger; the cervicovaginal branch in the

vault of the vagina is usually found and ligated first. Then the main trunk or the horizontal portion running to the cervix is ligated. Two ligatures should be applied

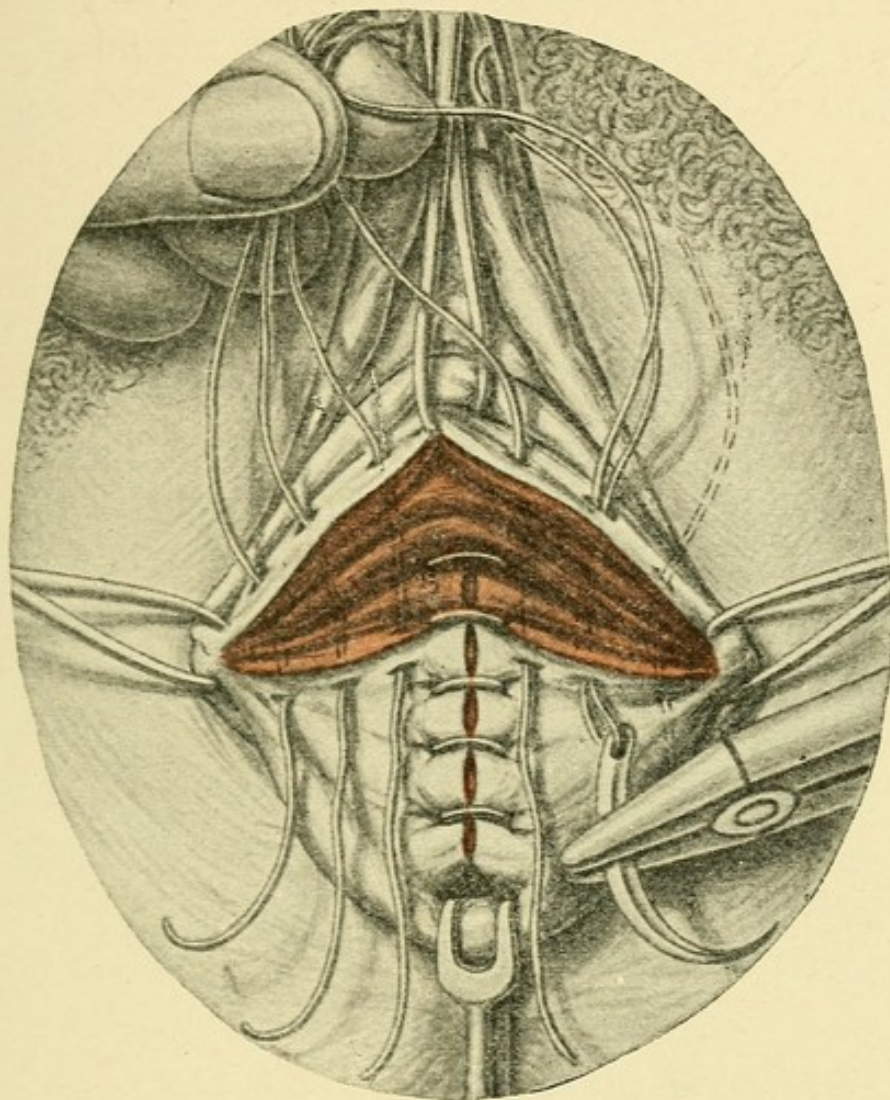


FIG. 20.—Enucleation of a polypoid fibromyoma after division of the anterior wall of the cervix. Closure of the wound in the anterior vault of the vagina by button sutures. These are placed from right to left, whereas the tied sutures of the vaginal wall run from above below—both in the direction of the incisions. While the sutures in the vaginal portion are visible, buried sutures are placed in the pars supravaginalis.

and the vessel divided between them. If the uterus is drawn too far downward, or the specula are too tightly packed in the vagina, the pulsation ceases to be felt;

hence it is important to remember to loosen these instruments from time to time (compare Plate 18).

The wound in the vault of the vagina (Plates 20, 28) is closed in the same way as already described (see Fig. 20), the lateral portions of the wound especially being held together with deep buried sutures.

The reports in regard to the *result of this palliative operation* in the presence of bleeding myomata and in greatly debilitated patients are extremely variable, and the operation is, therefore, rarely performed. In one remarkable case in which the bleeding had lasted ten years and the patient had become extremely anemic and the heart was very weak, I obtained a brilliant result. The operation when performed without anesthesia is, of course, extremely painful, owing to the proximity of so many ganglia, especially the large cervical ganglion. To secure the necessary time to put a patient in good condition for a radical operation, the procedure is distinctly to be recommended. There is little danger of gangrene, owing to the anastomoses of the uterine artery with the ovarian artery.

3. Supravaginal Amputation of the Cervix (Schröder, Kaltenbach).

This operation consists in supravaginal and extraperitoneal amputation of the neck of the uterus below the internal os, and is usually performed in strictly circumscribed cancer of the vaginal portion. It is to be emphasized, however, that even in the early stages of a tumor, malignant tissue has been found in the body of the uterus. If, therefore, the latter is thickened; if there is a

history of atypical bleeding, or the tumor in the vaginal portion partakes of the nature of an adenocarcinoma, the latter operation is to be preferred in every case. The concensus of opinion inclines to total extirpation. [Most emphatically.—ED.] Nevertheless it is not to be denied that excellent permanent results have been obtained by high amputation of the cervix.

The first step in the operation consists in division of the cervicovesical septum (Plate 17). The incision is enlarged in a lateral direction, since the cervix lies in the distribution of the main branches of the uterine artery, which accordingly must be ligated after the method just described, before amputation of the cervix is begun.

The anterior vault of the vagina is drawn out with two double tenacula, as shown on Plate 17, and the vaginal portion is drawn upward. The two lateral extremities of the incision are then united by a curved incision around the vaginal portion. The branches of the uterine artery are then ligated (Plates 18, 19). The vaginal mucous membrane is pushed back, and the cervix is completely pulled down so that the edges of the vaginal mucous membrane that surrounds the os like a collar give the organ the appearance of a mushroom.

The vaginal portion is drawn downward and the anterior wall is divided with the knife near the internal os, so that the cervical canal is completely laid open and its mucous membrane can be secured with catgut sutures, which are carried through the outer edges of the wound in the vagina (Plate 19). This is then followed by a complete amputation of the cervix. The closure of the wound is then completed in the manner just described, so

that eventually the cervical and vaginal mucous membranes are united by a wreath of sutures similar to those shown in Plate 16. The ligatures around the uterine artery are buried (Plate 19).

4. Operation for the Closure of Cervicovesical and Cervico-ureteral Fistulæ.

This operation can be performed only when the genital opening of the fistula has been made readily accessible by simple dilatation of the cervical canal (rarely), or, what is usually necessary, by completely laying bare the wall of the cervix after dissecting away the bladder, or, as has been done in a few cases, after simple division of the cervix.

The second method is the surest, because the fistulous canal is divided into two different parts, a vesical and a cervical portion, so that each segment can be independently cureted and obliterated by bringing surfaces of fresh tissue together. When the bladder is dissected away, as much loose tissue as possible must be left attached to it, so as to give the viscus as much mobility as possible. Whether the vesicouterine excavation will require to be opened and the anterior uterine wall utilized in the plastic operation will depend, in an individual case, on the extent of the defect.

The sutures are introduced in essentially the same way as in the case of a vesicovaginal fistula and in closure of the wound after division of the vesicocervical septum (Plate 12 and Fig. 20).

The patient must not be allowed to leave her bed for two weeks. The after-treatment is the same as that in

all operations on the vaginal vault. [The bladder should be drained several days with a catheter.—ED.]

The surest method of closing a **ureterovaginal fistula** is that of Mackenrodt—through the vagina. An artificial

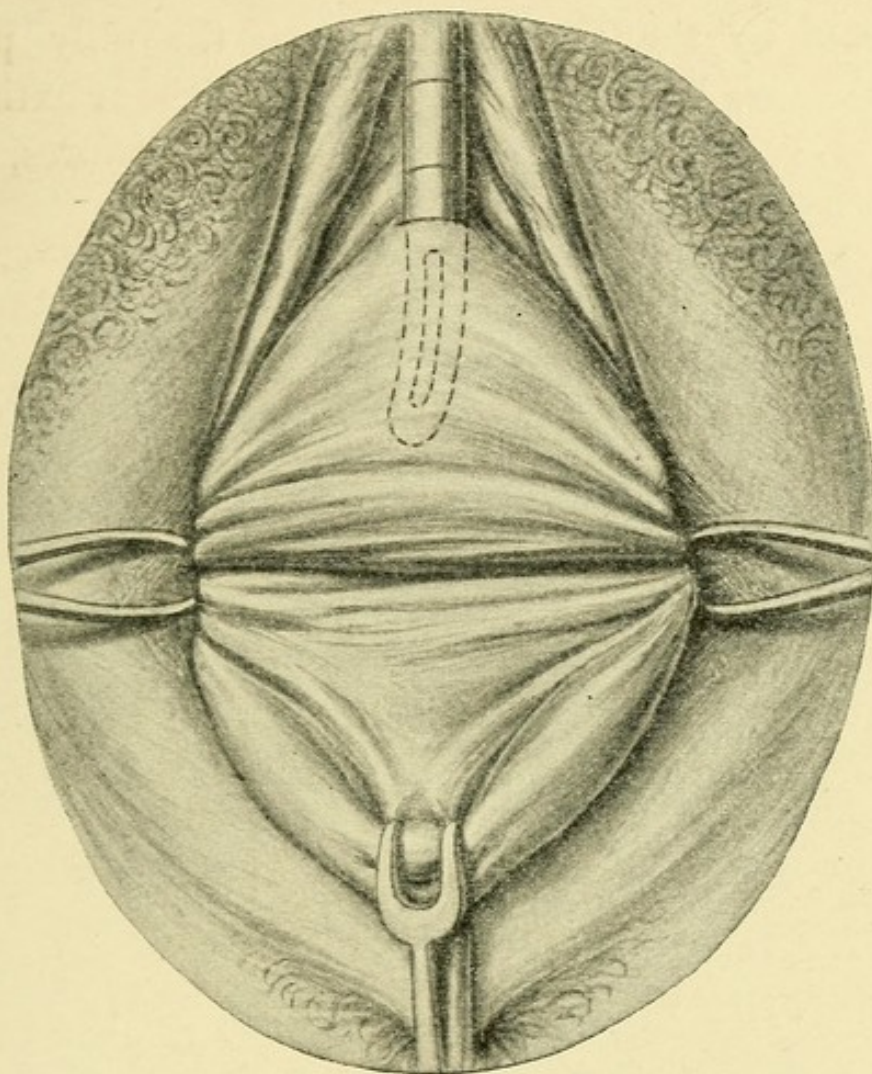


FIG. 21.—Anterior kolpoceliotomy. Showing the fold which is made permanent when the vaginal portion is drawn forward, and which indicates the line of insertion of the bladder.

vesicovaginal fistula is made, and a vaginal flap, somewhat larger than the artificial opening, is dissected from around the opening of the ureteral fistula; this flap and the opening of the ureter are then utilized to cover in the artificial vesicovaginal fistula.

Plate 24.

Anterior Kolpoceliotomy.—Dissecting the bladder away from the cervix (anterior kolpotomy).

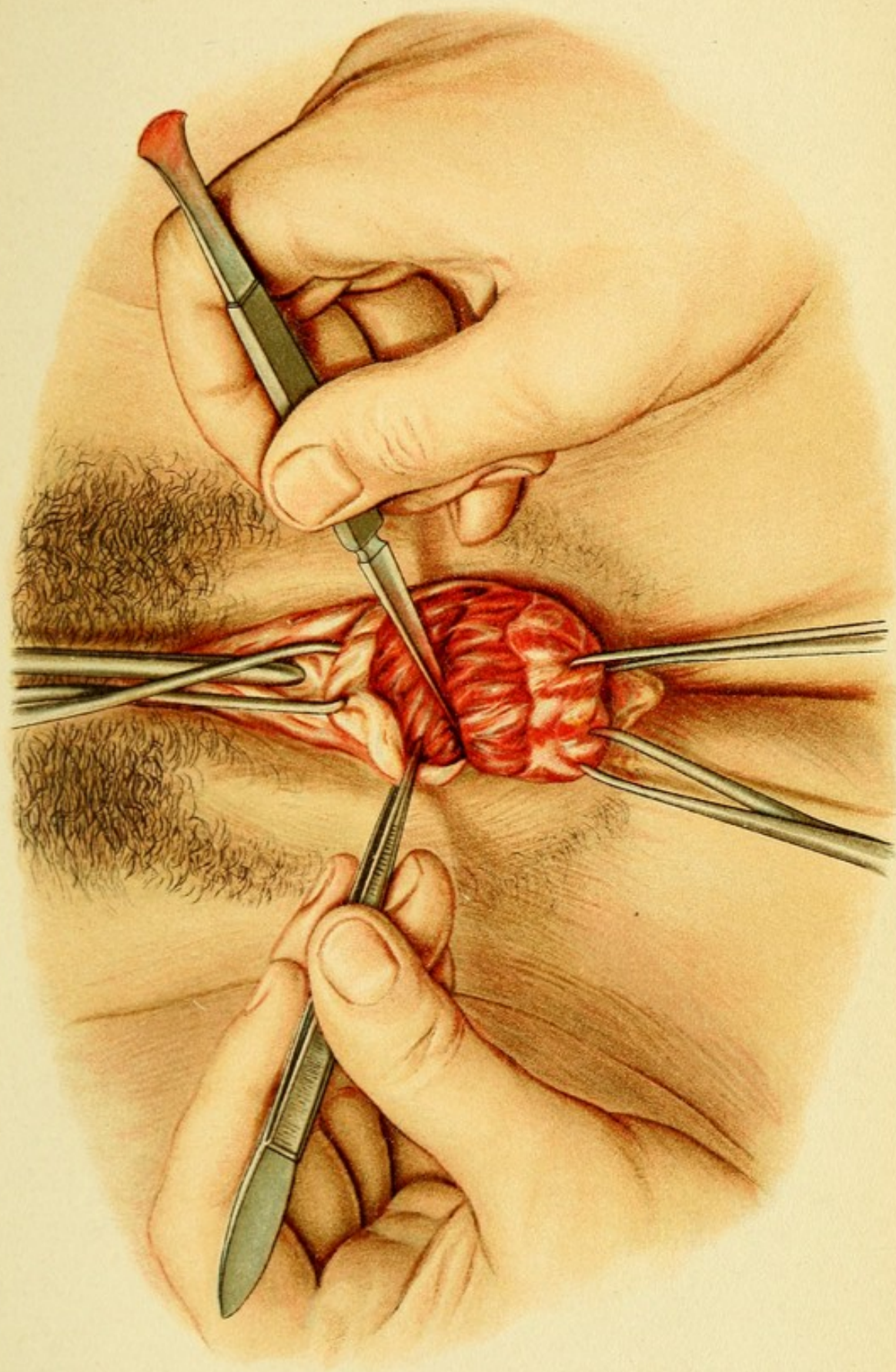
If these operations fail and the surgeon does not desire to operate by the abdominal route, the only possible expedients are hysterocleisis or kolpocleisis, or extirpation of the corresponding kidney. These procedures, as has already been said, are very unsatisfactory.

5. Method of Opening Abscesses in the Parametria (Pelvic Abscess).

If pus has been obtained by exploratory puncture or the temperature-chart indicates a hectic condition and appears to indicate absorption of pus, the abscess should be incised at the point where fluctuation is made out or where the tissues appear most prominent. After the abscess cavity has been opened, free drainage is maintained by means of a drainage-tube or a loose packing of iodoform gauze.

V. OPERATIONS THAT REQUIRE OPENING OF THE VESICO-UTERINE FOSSA.

The vesico-uterine peritoneal pouch is opened, partly to fix the uterus anteriorly and partly as a preparatory measure, in operations on the exterior or interior of the uterus after it has been delivered through the kolpotomy opening, and in operations on the adnexa when the latter are not situated too high, at the pelvic inlet or in the posterior pouch of Douglas, and are not fixed by peritoneal adhesions that cannot be directly seen.



(For the topographic and surgical anatomy see Groups II., III., and IX.)

1. Anterior Kolpoceliotomy.

The beginning of the operation is the same as the opening of the anterior fornix described in the foregoing section. Instead of a transverse incision, a longitudinal incision may be made, reaching as far up as the **portio vaginalis**. After the vaginal flaps have been undermined and dissected away, the wound is stretched to form a rhomboid. Two incisions may also be united in the form of a T. The bladder is now pushed back above the internal os, which is about three centimeters higher than the external os (Fig. 15, Plate 25), the cervico-vesical connective tissue being divided with a blunt instrument. The incision must be lengthened laterally—and this may be accomplished by lateral stretching with the fingers. The bladder, after being exposed, is raised along with the ureters by means of a retractor. The **boundary of the bladder** is usually marked by a fold (Fig. 21); if not, it can be determined by means of the catheter. The peritoneal fold of the anterior peritoneal pouch must then be reached underneath the bladder. It may frequently be recognized by the eye as a bright transverse line. The peritoneum should not be separated above the internal os. The dissection is carried on in the main with a blunt instrument, assisted with a few clips of the scissors to divide the firmer fibers, especially in the median line. The bladder is the only structure that is apt to be injured, and this accident may be avoided

Plate 25.

Fig. 1.—Anterior Kolpoceliotomy.—Exposing the vault of the vagina by means of two double tenacula inserted in the vaginal wall. The retroflexion of the uterus has been corrected. The point where the anterior pouch of Douglas is opened is indicated in the cervicovesical septum.

Fig. 2.—Vaginifixation of the Uterus after Kolpoceliotomy (Dührsen).—Introduction of the suture underneath the fundus of the uterus in the fold of the anterior pouch of Douglas.

Plate 26.

Ovariectomy Following Anterior Kolpoceliotomy.—The uterus and ovary are drawn forward in front of the vulva through the anterior kolpotomy wound, after opening of the anterior peritoneal pouch, the peritoneal fold of which surrounds the organs in the picture. The subserous vessels in the fundus of the uterus appear engorged on account of the strangulation.

by keeping close to the wall of the cervix, which is readily recognized by its greater hardness.

After a small incision has been made in the peritoneal cavity with the scissors, it is to be enlarged with the fingers or dressing forceps. The edges of the peritoneal wound are temporarily secured with catgut sutures, and the lateral retractor, which had been used to raise the bladder, is introduced into the opened vesico-uterine fossa.

2. Vaginifixation (Vaginifixura Vesicofixatio Uteri) (Dührsen and Mackenrodt).

These operations may be performed immediately after anterior kolpoceliotomy.

If the uterus is movable and retroflexed and reposition and retention have not been effected by means of a pessary, the organ may be secured by some anterior operation, such as fixation of the anterior uterine wall to

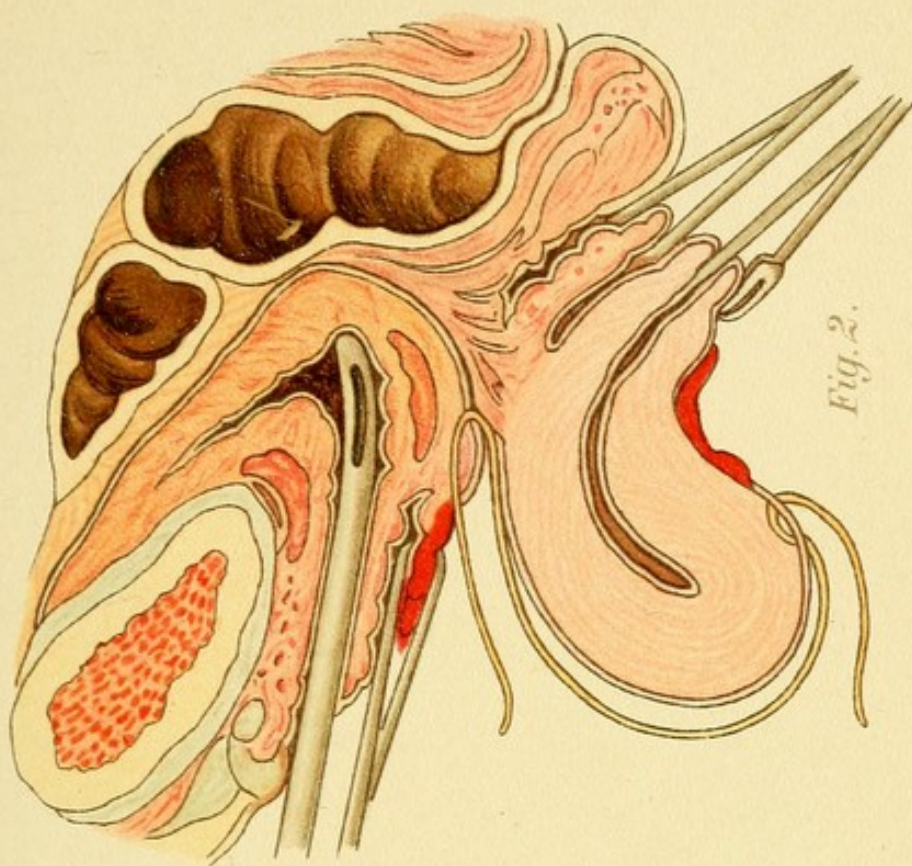


Fig. 2.

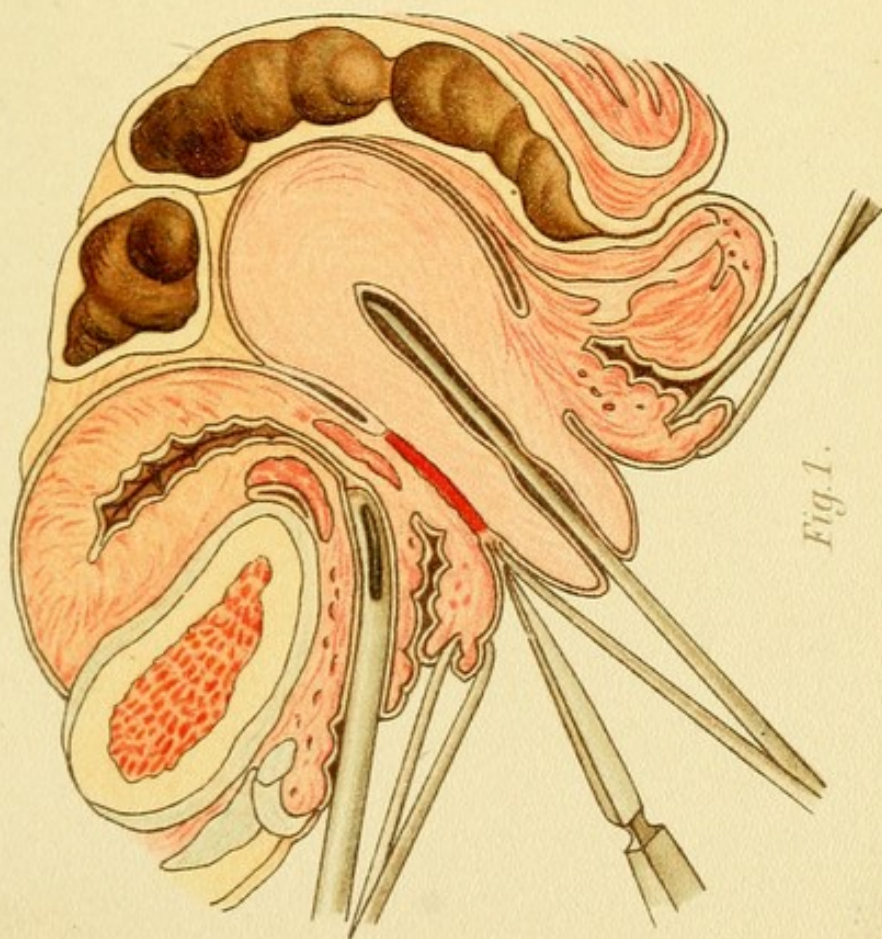
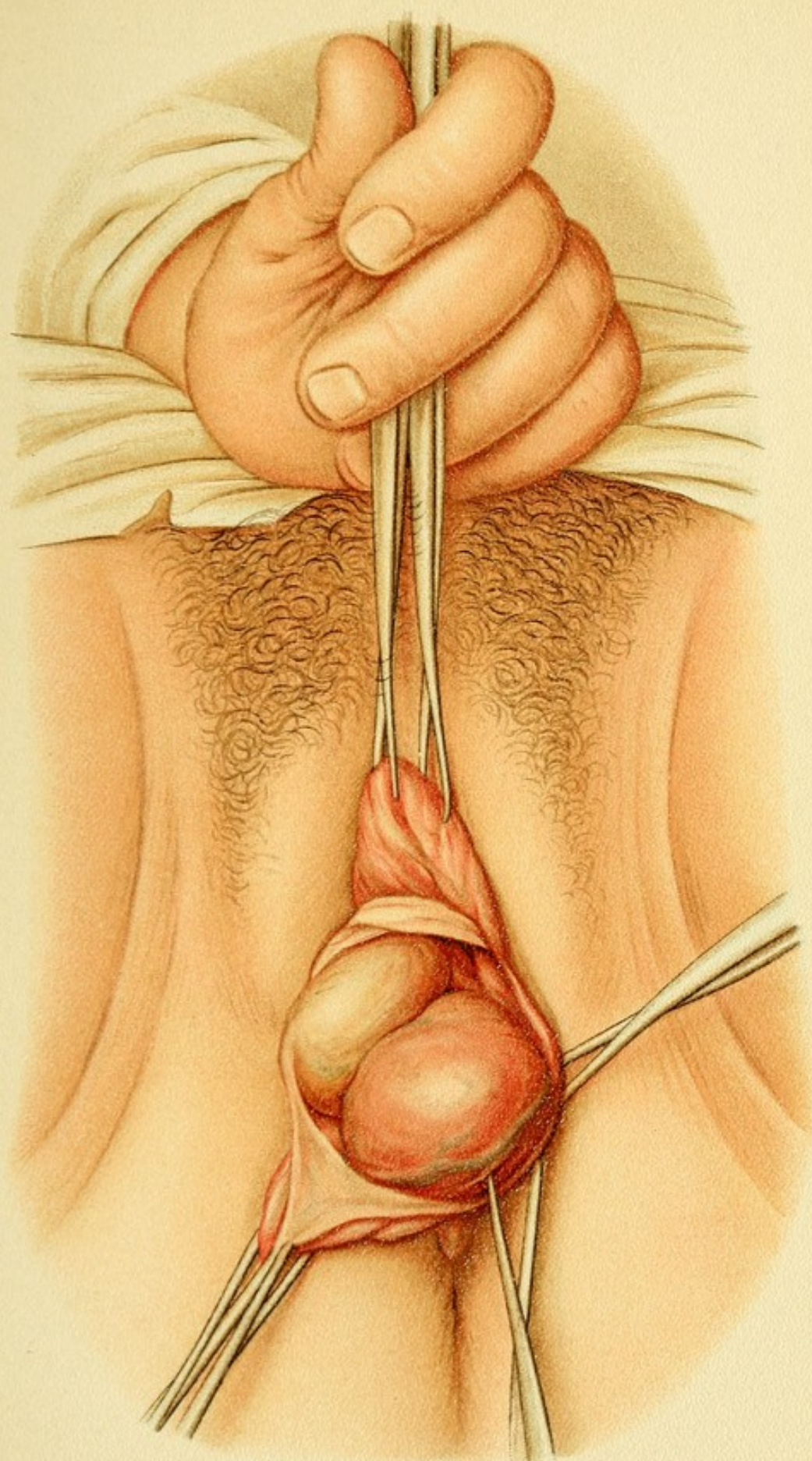


Fig. 1.



a vaginal incision by means of sutures. To obtain the greatest amount of fixation the perimetrium should be denuded and made to adhere to the true cervicovesical septum, because in this way a fibrous union would be secured; but as this operation is apt to interfere with labor, it is to be performed only when the woman is approaching the climacterium. Another important point is to close the peritoneal pouch before the fixation sutures are tied, for it has been found by experience that sutures introduced through the fundus of the uterus are apt to interfere with the development of the anterior wall of the organ at the next succeeding pregnancy, resulting either in abortion or in mere distention of the posterior wall. It also interferes with dilatation of the os, so that the anterior wall of the cervix may have to be laid open or a Cesarean section performed.

In performing the operation of **fixation** in women capable of bearing children the following precautions must be observed, it being remembered that the fundus of the uterus may become firmly fixed below. As a rule, therefore, one should advise against the operation in women of this class. The Alexander-Adams method of shortening the round ligaments or ventrosuspension of the uterus is much to be preferred.

After the vesico-uterine fossa has been opened (Plates 17, 24, Fig. 21) and the edges of the peritoneal incision have been secured with sutures, the uterus is to be drawn over forward out of its position of retroversion or retroflexion. This is accomplished by seizing the os with a tenaculum and pushing the latter backward—that is, toward the curve of the sacrum (Plate 25, Figs. 2,

26). The uterus is thus brought into a vertical position, making it possible to seize the anterior wall with a double tenaculum. A second tenaculum is then applied higher up, near the fundus, and a third above that, and so on, each successive tenaculum seizing a higher point of the organ until the part to be fixed has been brought into view or the body of the uterus can be brought through the peritoneal incision into the vagina or in front of the vulva (Plates 25, 26).

The *fixation sutures* are now introduced either near the point of attachment of the round ligaments, which may be included, or directly in the wall of the uterus—not at the fundus, however, but two or three centimeters above the internal os; the sutures are carried through the peritoneum near the incision, and emerge on the vesical surface (Plate 25, Fig. 2). Before these sutures are drawn tight, all the sutures passing from serous membrane to serous membrane required to close the wound in the peritoneal fold must be put in place, or the wound in the peritoneal fold may be closed first, after two silkworm-gut sutures have been introduced in the wall of the uterus and their free ends brought out through the vagina. If the latter are tied after the vaginal wound has been closed in the manner already described, the fundus of the uterus will be brought in close contact with the floor of the vesico-uterine fossa; and adhesions will form at this point with the anterior wall of the uterus. The silkworm-gut sutures are removed later. Convalescence requires two weeks.

[It cannot be too strongly urged that uterine fixation

should never be performed in women who are likely to become pregnant.—ED.]

3. Operations that can be Performed on the Uterus with the Aid of Anterior Kolpoceliotomy.

These operations include removal of subserous fibromyomata or of early interstitial or cornual pregnancies.

Subserous fibromyomata are either pedunculated, like polyps, or they represent prominent tumors with a broad base which is embedded in the wall of the uterus. In the former case the pedicle is ligated and a suture introduced under its base for the purpose of drawing the tumor or the neck of the uterus down into the vagina. In the other case the tumor must be enucleated from its foundation, a procedure which can be performed without much trouble. The exception is formed by adenomyomata situated near the tubes, which, in accordance with their mode of origin, are closely adherent to the surrounding tissues. In the latter case the tumor is ligated in sections unless the uterus is to be completely extirpated. In both cases the entire bed of the tumor, including the deeper layers, must be closed and accurately covered with peritoneum. If the base of the tumor extends as far as the endometrium, or if the uterine cavity is opened during its removal, the mucous membrane and contiguous muscular layers must be united separately and the sutures tied in the uterine cavity. If it is desired to avoid having the sutures project into the cavity,—although with a healthy mucous membrane the procedure is perfectly safe,—buried sutures are introduced so that they just catch the edge of the endometrium, very

Plate 27.

Ovariectomy after Anterior Kolpoceliectomy.—Application of the ligatures to tie off the ovaries and tubes. One of the ligatures includes the utero-ovarian ligament and the uterine insertion of the tube; the other is passed over the latter and the suspensory ligament of the ovary, or infundibulopelvic ligament.

Plate 28.

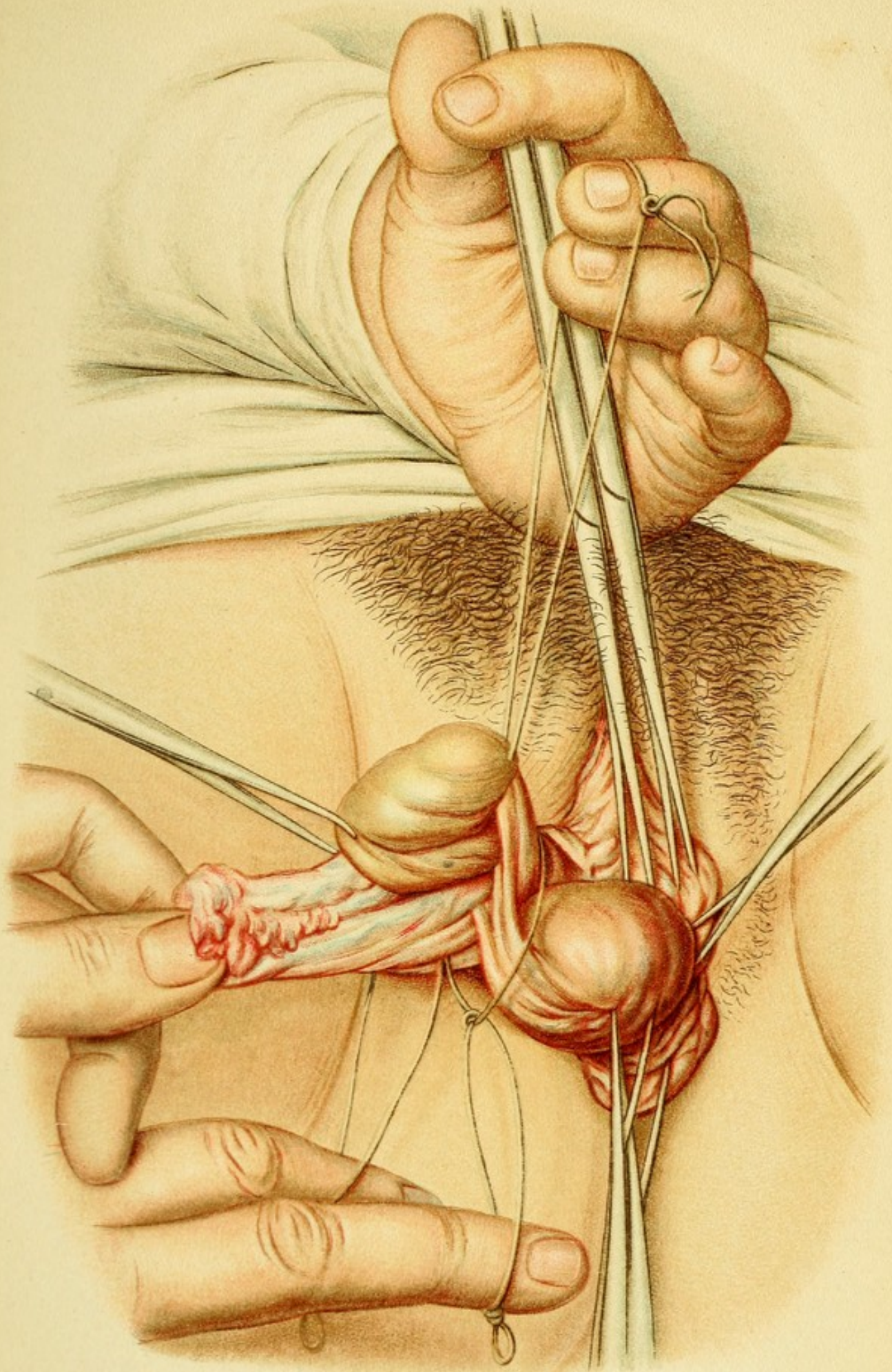
Ovariectomy after Anterior Kolpoceliectomy.—Continuous suture to close the peritoneal and vaginal wounds (compare Plate 9).

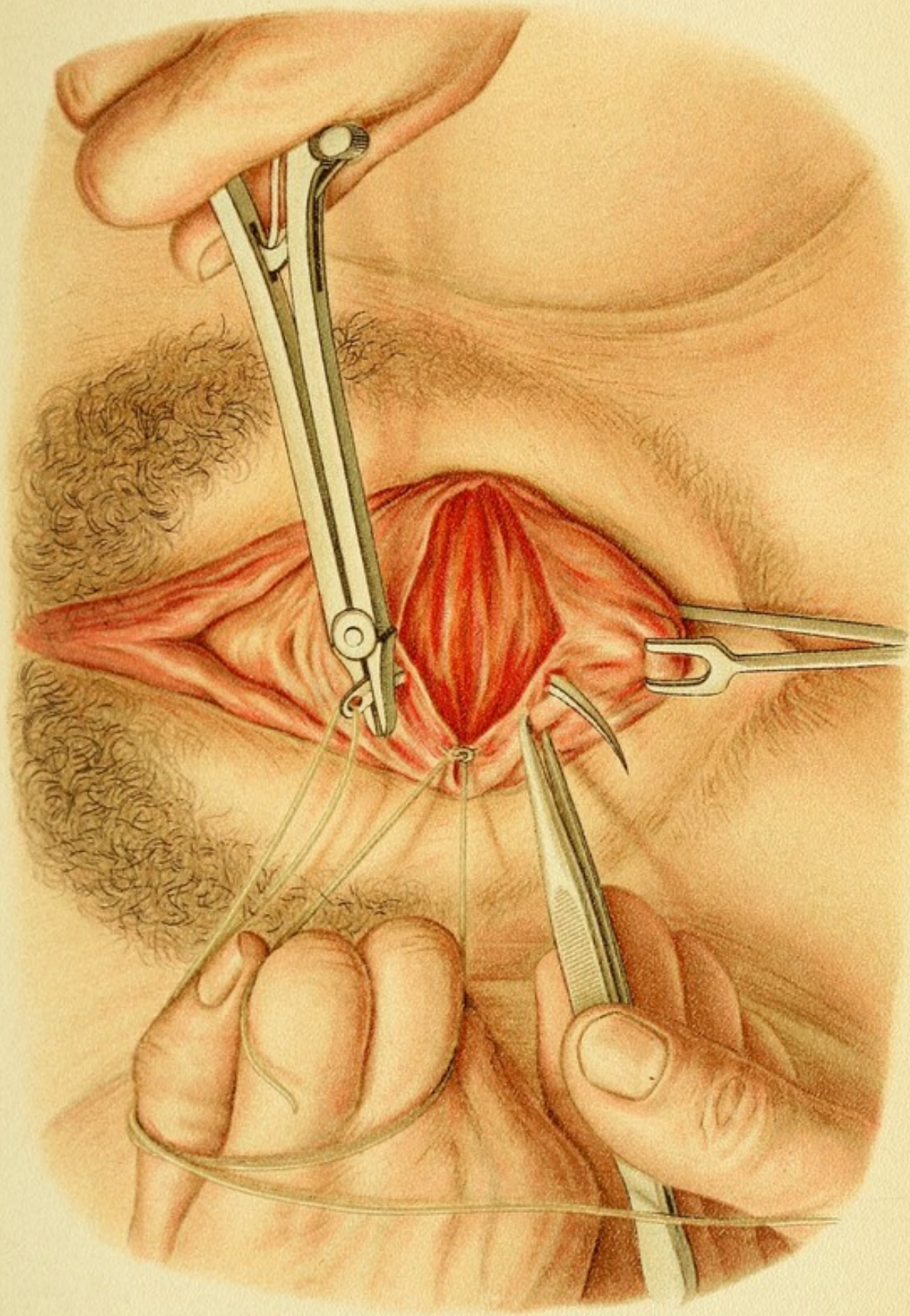
much as in the case of a vesicovaginal fistula (Plate 12). It goes without saying that only small fibromyomata, smaller than an apple in size, should be removed by this method.

The removal of a **gravid accessory cornu** in the case of a bicornute uterus, or of an interstitial pregnancy, conditions in which rupture is apt to take place into the peritoneal cavity, cannot be described as typical procedures. The former resembles in its technic the operations on the adnexa, especially the removal of a tubal sac; the latter belongs rather to enucleation of myomata. Such pathologic structures usually require a celiotomy for their removal.

4. Operations on the Adnexa.

The question whether an operation on the adnexa can be performed by anterior kolpoceliectomy depends not so much on the size of the tumor, since the contents are usually fluid and can be removed by a previous incision, as on its seat—viz., whether it is fixed at the pelvic inlet or in the posterior pouch of Douglas; whether there are numerous vascular adhesions with knuckles of intestine





or with the omentum, which are difficult to reach; or whether there are other extensive adhesions with the peritoneum. The field of usefulness of anterior kolpoceliotomy, therefore, includes large tumors that are readily evacuated, or smaller, hard growths, freely movable and situated below the pelvic inlet in the anterior pouch of Douglas or on the posterior surface of the uterus if the latter is normally placed. It does not include tumors adherent in the posterior pouch of Douglas. The list of pathologic conditions embraces ovaries (castration), parovarian and ovarian cysts, cystoma, dermoid cysts, small ovarian fibromata, and the like; tubal gestation in the first months; hydrosalpinx and pyosalpinx, when not situated too high and not bound down by too many adhesions; and, possibly, tumors of the appendix.

The removal of ovarian tumors and the like is regarded as a typical operation consisting chiefly in ligation of structures more or less distinctly pedunculated. Another typical operation is "sterilization" (castration) by excision of the tubes from the horns of the uterus, followed by double ligation of the former.

After the tumor, the ovary, or the uterus and its oviducts have been exposed as in the method described in connection with vaginal fixation (Plate 26), the arteries are ligated and the entire base of the part to be removed is tied off. The most important vessels are the ovarian, which reach the adnexa by way of the suspensory ligament of the ovary (infundibulopelvic ligament), and the tubal and ovarian branches, which pass upward from the uterine artery. Ligation of the sharp-edged suspensory ligament, of the insertion of the tube in the uterus, and

of the utero-ovarian ligament (Plate 27), suffices to cut the adnexa completely off from the portion of the circulation by which they are supplied. Partly to guard against possible secondary hemorrhage, or to control it more readily if the accident occurs, and partly to fix the uterus anteriorly, it is well to attach the stump in the corresponding side of the vaginal wound by means of sutures, as shown in a semidiagrammatic way on Plate 33. The kolpotomy wound is closed by means of interrupted or continuous catgut sutures (Plate 28); in infectious cases, however, the wound must be drained.

Intraligamentary subserous cysts and those situated in the posterior wall of the pouch of Douglas require a special technic for their enucleation. They cannot be removed by means of kolpoceliotomy unless they are quite small. **Pelvic abscesses**, owing to the great tendency of **pus-tubes** to become adherent in the posterior pouch of Douglas, are usually attacked through the **posterior** wall of the vagina.

The possibility of error in the diagnosis is always to be kept in mind, and preparations should be made for a possible celiotomy or total extirpation.

In cystadenomata, even when they are benign, the danger of metastasis is greater with kolpoceliotomy than with celiotomy.

VI. OPERATIONS THAT ARE PERFORMED THROUGH THE POSTERIOR POUCH OF DOUGLAS.

It follows from the topographic description under Groups II., III., and IV., that the distance to the recto-uterovaginal fossa is much shorter posteriorly than ante-

riorly. The actual distance, however, to the normally situated ovary is greater by the posterior route than by the anterior; hence the peritoneal cavity should be entered posteriorly only for operations on masses situated in the posterior peritoneal pouch itself, or associated with a retroflexed uterus. The conditions that may be attacked in this way are, therefore, ovarian and parovarian tumors, intraligamentary or retroperitoneal tumors, tubal pregnancies, pus-tubes, pelvoperitoneal incapsulated abscesses, retro-uterine hematocele, tumors of the uterus, and adhesions in the posterior pouch of Douglas; also, in cases of infantile scanty development with a tendency to enterocele in which the pouch of Douglas is to be obliterated, with or without retrofixation of the cervix.

If a tumor in the pouch of Douglas is closely related to the rectum and the entire mass has prolapsed into the lumen of the vagina, removal is often effected most easily through a **rectal incision** in the rectocele thus produced. [Such a procedure as this would not be considered as justifiable by most authorities, unless removal were found to be impossible by the vaginal or abdominal routes.—ED.]

1. Posterior Kolpoceliotomy and Retrofixation of the Cervix.

The posterior vault of the vagina is brought into view by drawing the posterior lip of the os upward and inserting two hooks in the lateral folds of the posterior vault of the vagina, the perineum and posterior vaginal wall being at the same time depressed with a spatular speculum. After the posterior vaginal fornix has been incised (Plate 3), the

rectum, along with the entire peritoneal pouch, is separated for a short distance from the cervix with a blunt instrument. The pouch is readily recognized with the finger by the gliding of one smooth surface over another. The vaginal surface is picked up with forceps and snipped with the scissors. The incision is then enlarged by dilatation (Plate 4). The edge of the peritoneum is fixed with sutures. If the hemorrhage is profuse, several fixation sutures are introduced, as above, in the vaginal mucous membrane. According to Löhlein, the mere act of opening the retro-uterine fossa has a curative effect in pelvoperitoneal tuberculosis.

Retrofixation of the cervix and **obliteration of the peritoneal pouch** are effected by means of several intraperitoneal catgut sutures introduced between the posterior wall of the cervix and the parietal investment of the sacrum and rectum (Plate 5). The edge of the peritoneal wound is closed with catgut, an interrupted, a continuous, or even a tobacco-pouch suture being used (Plate 6). The vaginal vault is closed by means of deep buried sutures (Plate 7). This operation may be immediately followed by a posterior kolporrhaphy, described elsewhere (Plate 8, Fig. 13), it being remembered that the vaginal vault itself is not to be narrowed. Convalescence lasts two weeks.

2. Operative Treatment of Ectopic Gestation and its Consequences.

The tubal sac containing the young ovum is readily ligated and removed, especially when it is fixed only by soft adhesions. If the sac is ruptured or a tubal abortion

has taken place, the pelvic cavity will be filled with fresh or freshly clotted blood; in some cases the tube itself is found to be bleeding. If the hemorrhage has taken place some time before, the retro-uterine fossa is found filled with a mass of thickly clotted blood and blood intermingled with layers of fibrin. This retro-uterine hematocele offers no protection against secondary hemorrhage, as the cells of the chorion which remain are capable of eating through the wall of the tube. It is, therefore, quite justifiable to turn out the clot and ligate the tube. The ligation, however, is not necessary if the tube is free and uninjured and no enlargements are felt anywhere. [This section must be regarded as a very scanty and inexact account of the operative treatment of ectopic gestation.—ED.]

3. The Operative Treatment of Abscesses in the Pouch of Douglas.

Simple **inflammatory adhesions** between the uterus and its adnexa may be divided with a blunt instrument [or finger.—ED.]. If the adhesions are vascular, they should be tied with two ligatures and the intervening tissues divided. **Pus-tubes** that are not adherent or only slightly adherent should be excised from the corresponding horn of the uterus; but the prospect of a permanent cure is doubtful. Sometimes an **inflamed appendix** occupies the pouch of Douglas and may be removed directly from that situation. [Not a satisfactory procedure.—ED.] In some cases the entire peritoneal space corresponding to the pouch of Douglas and the pelvis is filled with adhesions and intervening **multiple abscesses**, the original

tissue having been entirely destroyed. In such a case it is, of course, quite out of the question to open the posterior peritoneal pouch, nor should the scissors or knife be used, on account of the danger of injuring loops of intestine which may have become caught in the adhesions. The collections of pus must be evacuated one after another, the tissues being dissected away with a blunt instrument. Complete extirpation of the uterus and adnexa is the best treatment for such a condition.

Sometimes abscesses of this kind have already evacuated their contents into the rectum; but partly because the evacuation has been incomplete, and partly because of the reinfection that usually takes place on account of the rigidity of the pus-cavity which enables it to aspirate material from the rectum, the suppuration continues. Free drainage must then be provided by laying the abscess wide open from the vagina. If the abscess is situated higher up, it must be secured to the wall of the vagina by means of sutures. Under these circumstances there is also the danger of the passage of feces into the vagina—that is, of the formation of a high rectovaginal or ileojejunovaginal fistula. The author has, however, seen several of these fistulæ cured by the introduction of strips of gauze saturated in oil of turpentine as soon as suppuration had ceased. In other favorable cases a minute fistula remains and gives rise to no symptoms. In all cases of this kind the pouch of Douglas should be packed with iodoform gauze.

VII. OPERATIONS PERFORMED AFTER OPENING ONE OR BOTH PERITONEAL POUCHES AND AN ENTIRE WALL OF THE UTERUS.

This combination of procedures, which has as its object the preservation of an organ so as to be capable of parturition, may be indicated for the simultaneous enucleation of multiple subserous, intramural, or submucous fibromyomata, and for the purpose of bringing about a reinversion of an inverted uterus.

In the case of tumors, a longitudinal incision through the wall of the body or of the entire uterus enables the operator not only to remove single deeply situated tumors, but also to determine the presence of smaller tumors by direct palpation and inspection, and this, according to A. Martin, is of the greatest importance to guard against the occurrence of the so-called relapses.

In regard to **reinversion**, it may be performed, according to Küstner, through the posterior wall of the vagina. The vault and the posterior wall of the body of the uterus alone are incised. The divided wall is invaginated toward the perimetrium, which forms a pocket, and at the same time the latter is drawn out by means of a curved dressing forceps from the posterior pouch of Douglas.

Failure to effect reinversion in this way is due to insufficient length of the incision. In such a case it is better to divide the entire wall, including the neck and vaginal portion (Westermarck-Borelius), and not to invaginate the uterus toward the perimetrium, but, on the contrary, to widen the incision so that the fundus may be pushed into the pouch of Douglas. The posterior wall of

Plate 29.

Total Extirpation of the Uterus through the Vagina (Czerny).—A ligature is tied around the suspensory ligament of the ovary (the infundibulopelvic ligament), and a second ligature applied around the broad ligament, which should reach as far as the round ligament. The uterus has been turned through the anterior kolpotomy wound, bringing the portion separated from the bladder into view.

Plate 30.

Total Extirpation of the Uterus through the Vagina.—Ligation of tissues down to the vaginal vault. This ligature is in immediate contact with the last-mentioned ligature, and ties off the uterine artery.

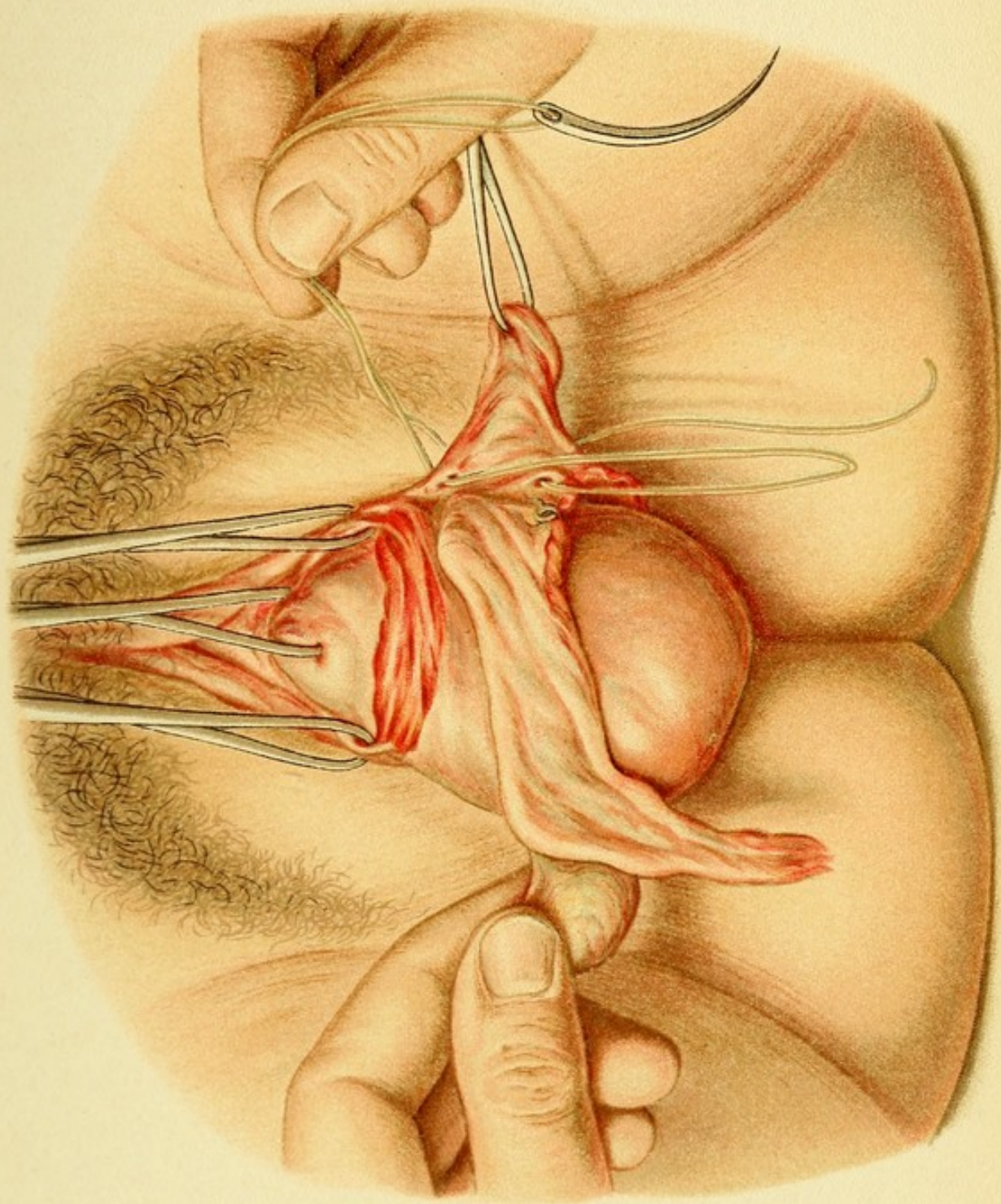
Plate 31.

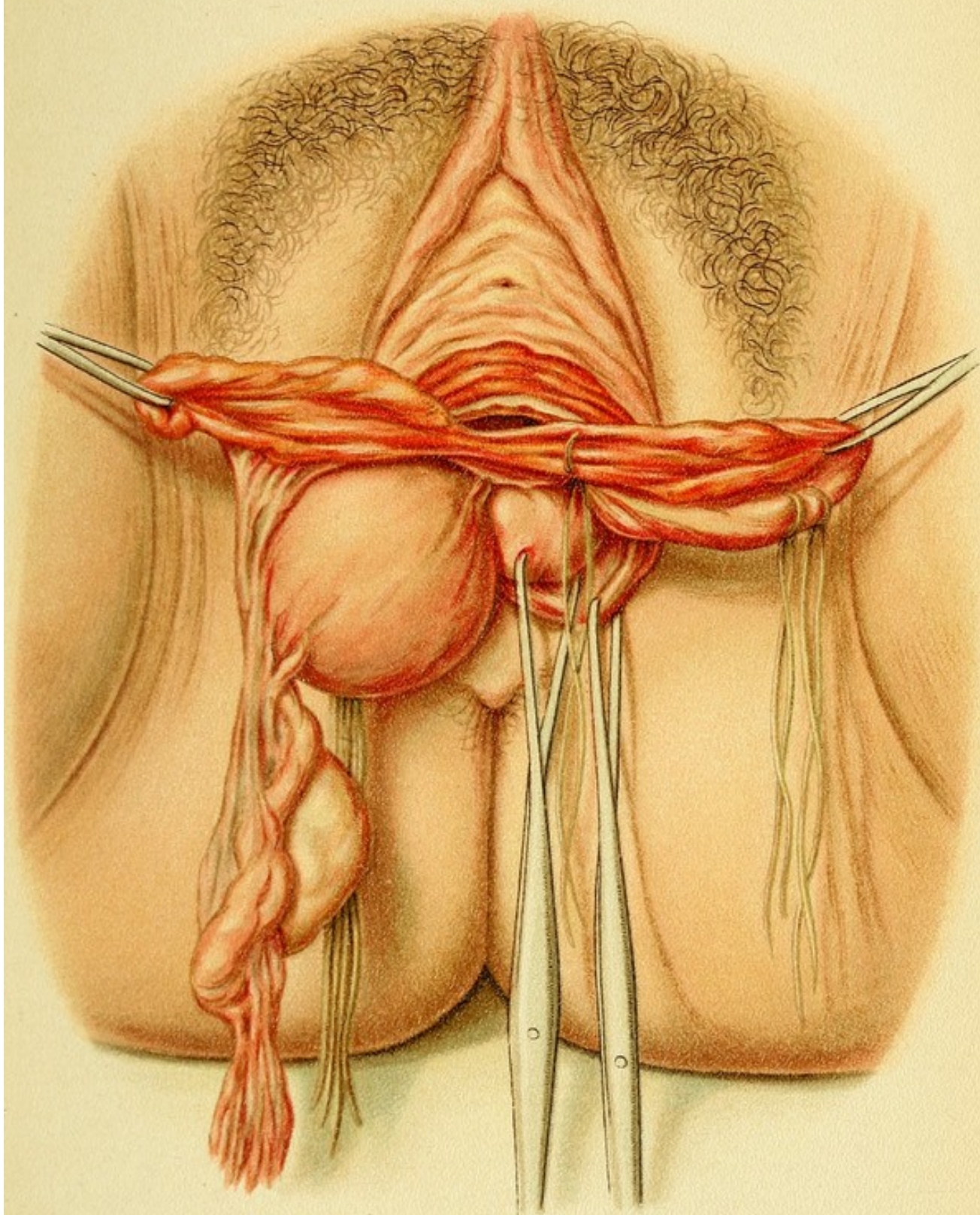
Total Extirpation of the Uterus through the Vagina.—Method of separating the uterus, also the left broad ligament, after all the ligatures in that ligament have been tied. The organ is in extreme ante flexion.

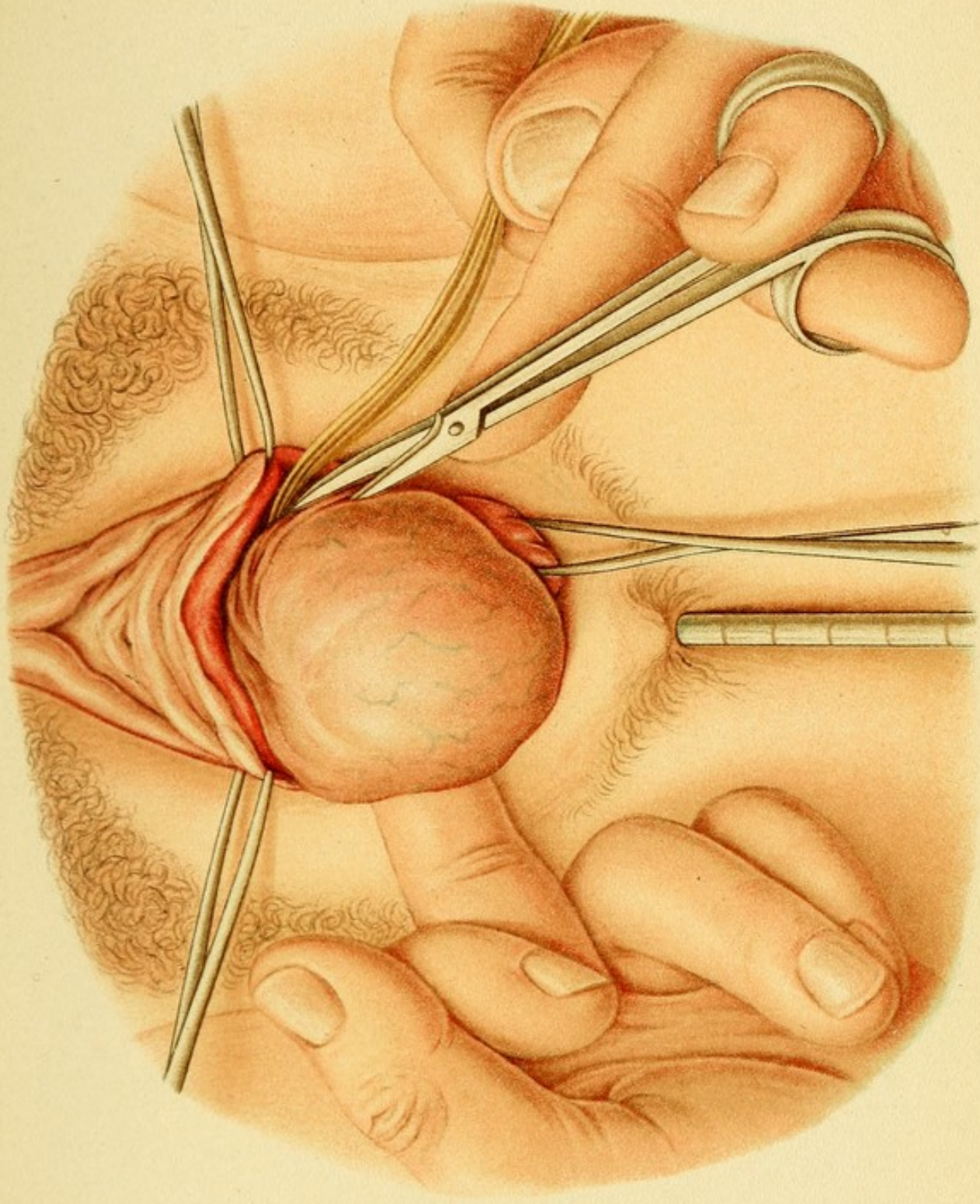
Plate 32.

Total Extirpation of the Uterus through the Vagina (Czerny).—Opening of the posterior pouch of Douglas. This is followed by opening of the anterior pouch, after which the bladder and both ureters are dissected out. The vaginal portion is drawn forward and upward. The cervix is separated from the posterior pouch of Douglas and from the rectum by a transverse incision, and, if necessary, by an additional median longitudinal incision. The peritoneal cavity is then opened. The field of operation is exposed by means of four double tenacula, the lowest of which may be replaced by a grooved speculum.

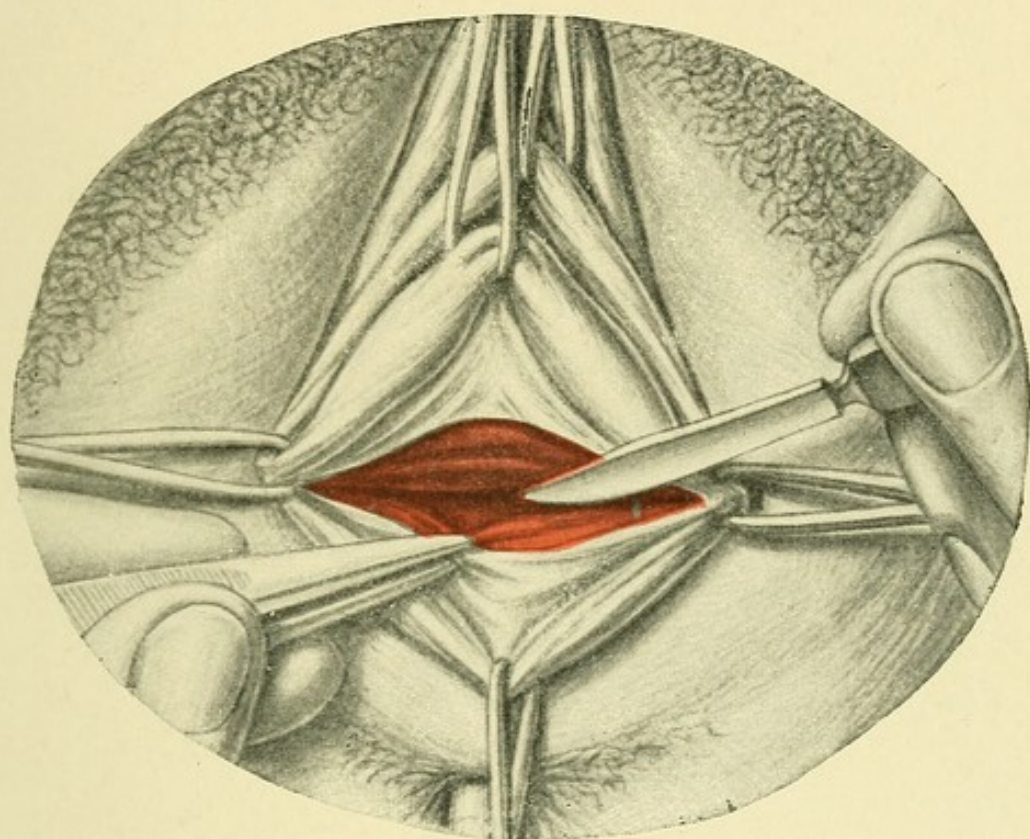
the uterus is now closed by means of transverse interrupted sutures of catgut, and the posterior wall of the vagina is finally closed *secundum artem*. Sometimes the same operation is more readily performed through the anterior vault (Kehrer), but Küstner's method is adopted probably because in these cases retroflexion is more common than antero flexion.







Tab. 32.



VIII. TOTAL EXTIRPATION OF THE UTERUS THROUGH THE VAGINA BY OPENING THE ANTERIOR AND POSTERIOR PERITONEAL POUCHES.

(For the topographic and surgical anatomy see Groups II., III., and IX.)

After the recto-uterine fossa has been opened after the manner described in Group VII., Plates 3, 4, 32, and the raw surfaces, which in carcinoma usually bleed freely, have been temporarily closed with serosomucous sutures, the vaginal portion is drawn down (Plate 25). In carcinoma the os should be closed with two or three strong silk sutures which also serve as retractors, after all the external tumor tissue has been removed with the Paquelin cautery. The anterior peritoneal pouch is then opened (Fig. 15, Plates 17, 24), and the edges of the wound closed with sutures. The anterior and the posterior incisions should meet at an acute angle as far out as possible, so as to enable the operator to push away the bladder and ureters and to clear away as much as possible of the tissue surrounding the uterus.

If the vagina is narrow and the uterus large, or if there is much tissue to be removed from the sides of the organ, access is obtained to the vault of the vagina by separating the posterior wall of the vagina with the rectum from the vault and from the labia. The hidden field of operation can then be brought into view and made accessible to the hand by means of two deep Dührssen's incisions extending to the posterior vault of the vagina on both sides. Schuchardt first employed

Plate 33.

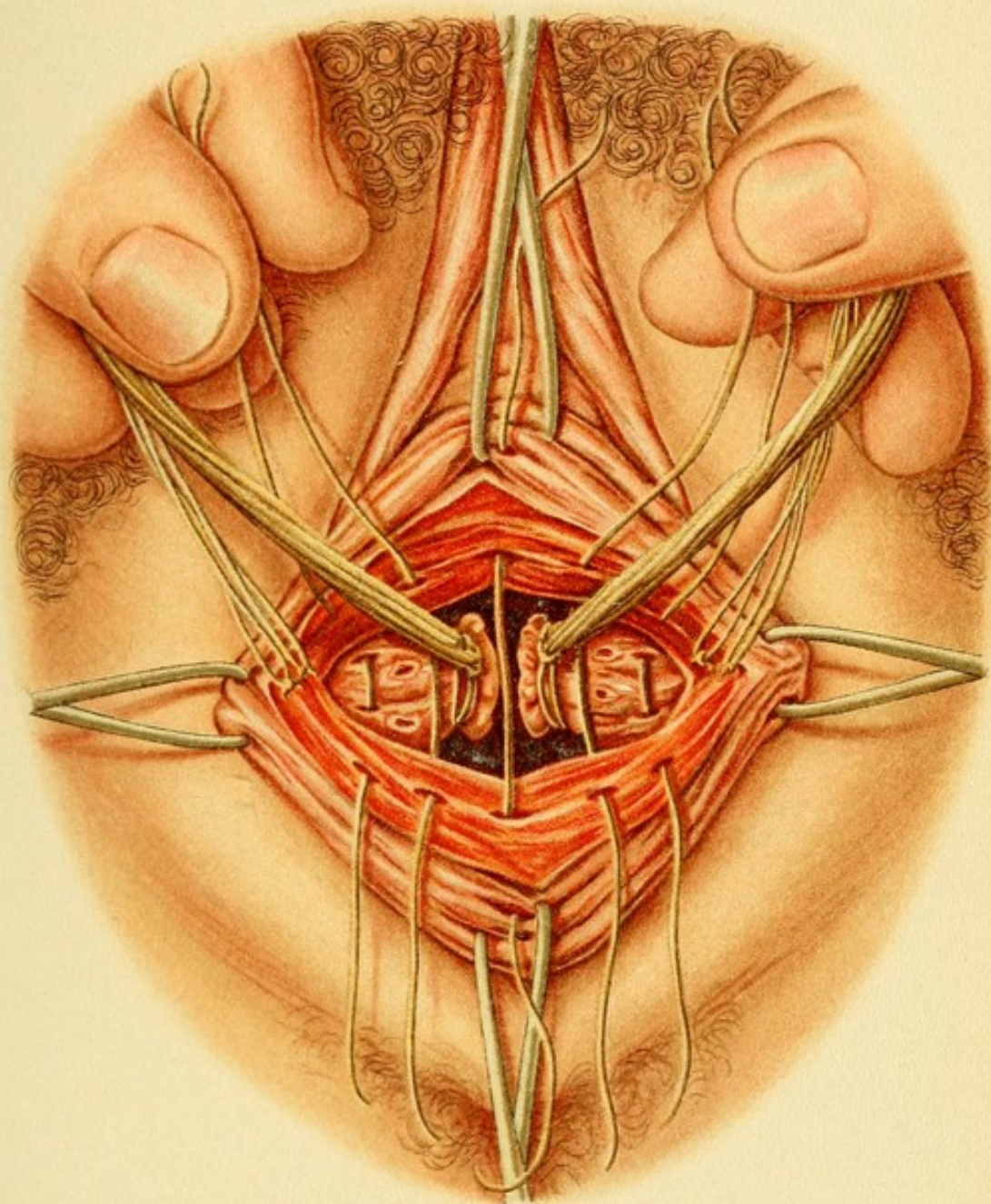
Total Extirpation of the Uterus through the Vagina.—Method of closing the vaginal vault. The two stumps are sewed fast in the angles of the vaginal wound, where the ligatures about the uterine artery may be seen.

these incisions for this purpose, and united them in the posterior vault by a transverse incision.

The uterus is now seen hanging *in situ*, held along its entire length by the two broad ligaments. To make it still more movable, the base of the broad ligament must be divided on each side. But this tissue contains the principal branches of the uterine artery; the latter must, therefore, be ligated, the finger being introduced into the posterior pouch of Douglas for the purpose of palpating the connective tissue and guiding the needle, which is inserted at the anterior peritoneal pouch and passed around and through the entire base of each broad ligament (see Plate 18).

The uterus is now tipped over; that is to say, the vaginal portion is forced back into the hollow of the sacrum and the body is drawn down into the opening in the vault of the vagina with the aid of a double tenaculum (Plates 25, 26, 29). The fundus is drawn through the opening by the method described under vaginofixation; if this, however, is found impossible on account of the swelling of the organ, the uterus must be divided lengthwise in the median line (P. Müller). [Division of a carcinomatous uterus is a very unwise procedure, owing to the risk of transplanting cancer cells.—Ed.]

The next step is ligation of the broad ligaments, which are tied off in several sections. According to Werth's



recent suggestion, the ovaries should be left behind in all cases in which disease of these organs can be excluded. If the ovaries are to be removed, the *first ligature* should include the ovarian vessels running in the infundibulopelvic ligament; the *second ligature* is applied to the round ligament immediately afterward (Plate 29); the *third* includes the remainder of the broad ligament, containing the main branches of the uterine artery, and takes in all the tissues as far down as the vagina (Plate 30).

After the vessels of one side have been taken care of in this way, the uterus may be carefully separated from the broad ligament on one side by cutting between the ligatures and the wall of the uterus with the scissors in a line extending from the suspensory ligament of the ovary to the vault of the vagina (Plate 31). The same is then done on the other side. In dividing the last strands of tissue in the lateral portions of the vagina great care is necessary because the uterine artery at this point is apt to slip from the ligature, or the cervicovaginal branch may not have been included in the ligature, so that a severe hemorrhage suddenly occurs. If a ligature is then hurriedly introduced, or the artery is seized with the forceps along with the surrounding tissue, constrictions or other injuries of the ureters may easily be produced.

The **sutures** and **ligatures** that have been introduced into the **adnexa** are to be secured in the two lateral angles of the wound, as described elsewhere in connection with anterior kolpoceliotomy. The wound may be entirely closed (Plate 28), or, as in putrefying carcinoma, may be drained with iodoform gauze and allowed to

granulate. It strengthens the newly formed floor of the pelvis to suture the stumps of the broad ligaments to it.

IX. OPERATIONS ON THE GENITAL ORGANS THAT REQUIRE A CELIOTOMY.

Topography and Surgical Anatomy of that Portion of the Genital Organs Extending into the Peritoneal Cavity.

If an incision is made in the median line, between the umbilicus and the symphysis, it will pass through the panniculus adiposus and the loose-meshed tissue of the superficial abdominal fascia, which, in the lower abdominal region, is made up of several layers and gradually fades away into the fatty tissue. Beneath this the strong aponeurosis of the external oblique comes into view, blending with the aponeurosis of the other side in the linea alba. This aponeurosis invests the recti muscles and the subjacent aponeurosis of the internal oblique, while the latter is connected with the aponeurosis of the transversalis, which occupies a still deeper level. These fasciæ all unite in the median line and form the linea alba. Immediately below the navel and a little higher up the recti muscles are covered only by the aponeurosis of the external oblique and an outer layer of the aponeurosis of the internal oblique, which undergoes division at this point; a posterior layer assists the aponeurosis of the transversalis muscle to cover the inner surface of the rectus.

Underneath these fasciæ, or underneath the linea alba and united to that structure, is the transversalis fascia, which is covered with serous membrane on the side pre-

senting toward the peritoneal cavity. In the lower abdominal region this serous membrane forms the sole covering of the recti muscles on their posterior surface. The bladder may come into immediate contact with the abdominal walls if it is greatly overfilled. The empty bladder lies behind the symphysis, and only the middle umbilical ligament comes in contact with the linea alba in the median line. The *cavum prævesicale superius*, filled with fatty tissue (see *Atlas of Obstetrical Diagnosis and Treatment*, Plate 58, Fig. 18), extends as far as the upper border of the symphysis.

The linea alba and the suprainposed fatty tissue are poorly supplied with blood-vessels. On the deep surface of the recti muscles, between them and the transversalis fascia, the epigastric vessels come up from below behind the inguinal canal and form a fold,—the *plica epigastrica*,—passing in toward the recti muscles and finally upward. In the Trendelenburg position the intestines gravitate toward the diaphragm, and a view of the pelvic organs from above is afforded. The bladder, if empty, comes into view; it is supported by the three umbilical ligaments and the peritoneal *plicæ vesicales transversæ*, which, for a certain distance, run parallel to the round ligaments. Its anterior surface shows a deep cup-shaped depression, due to the pressure of the normally anteflexed uterus (*impresio uterina*).

The *prevesical space* merges on the side into the *perivesical* and *peri-uterine* spaces. The vesical fascia runs in one direction from the upper border of the symphysis upward and in the other backward toward the inner orifice of the urethra. It separates the prevesical space

from the subperitoneal fatty tissue which surrounds the bladder-wall. The subperitoneal fatty tissue again merges with that of the broad ligaments, from which it is separated only by the visceral fascia of the pelvis. (See *Atlas of Obstetrical Diagnosis and Treatment*, Plate 17, Fig. 29.)

A knowledge of the relations of these various spaces is important not only for the technic, but also to enable one to understand the course of an inflammatory process in the connective tissue, as, for instance, the extension of parametritis.

Between the posterior surface of the bladder and the anterior surface of the uterus is the *vesico-uterine* (*peritoneal*) *fossa*. This is bounded on the side by the broad ligaments with the uterine insertions of the tubes. Below this peritoneal fold (*plica peritonealis*), which is found at the level of the internal os, the posterior wall of the bladder (*fundus vesicæ*) and the cervix are united with connective tissue, which, as the vagina is approached, becomes looser in texture and adherent at the orifice of the ureters, as has already been described. At this point the inferior vesical arteries and branches of the cervicovaginal arteries enter the wall of the bladder, while the veins pass to the posterior and lateral uterovaginal and vesicovaginal plexuses, as described elsewhere.

The broad ligaments now leave the bladder and pass backward. The position of the uterine body approaches the horizontal or the vertical, according to the amount of urine in the bladder. The lateral and posterior portions of the broad ligaments, with the ovaries attached to their posterior surfaces, have, under ordinary circum-

stances, a more or less definite relation to the bony pelvis. The **position of the tube**, especially of the freely movable **fimbriated extremity**, depends on the position of the **ovary**, which is embedded in the ovarian fossa; that is to say, it lies in the posterior portion of the obturator fossa, which is bounded above and in front by the iliac vessels or the umbilical artery; behind, by the ureter; and below and in front, by the round ligament of the uterus. The **position of the ovary** is such that it comes into relation behind with the ureter and the uterine artery and the obturator internus muscle; above and in front with the umbilical artery; it is roofed over both by the pelvic inlet and by the tube, so that it cannot be seen at once when the abdomen is opened.

If a sagittal plane is drawn through the pelvis from a point midway between the superior spine of the ilium and the symphysis, and this is intersected by a frontal plane passing through the middle of the crest of the ilium or through the promontory, the point of intersection will give the position of the ovary as projected on the abdominal wall.

After repeated pregnancies or conditions attended with swelling the ovary is apt to prolapse from the ovarian fossa into the hypogastric fossa or into the posterior pouch of Douglas.

The ovary is attached along its **lateral** surfaces by means of the "mesovarium" and the posterior surface of the broad ligament. It is **roofed over** by the ampullary portion of the tube, the distal portion of which, known as the "descending limb," together with the fimbriæ of the infundibulum of the tube, hangs free by

the "mesosalpinx" and projects over the inner and posterior surfaces of the ovary. The mesosalpinx contains numerous venous plexuses, as well as the rudimentary structures known as the epoöphoron and paroöphoron, which possess a great tendency to undergo cystic degeneration. The ovaries are not visible at once when the abdomen is opened. The middle portion of the tubes, along with the ovary, is attached to the lateral wall of the pelvis by means of the infundibulopelvic or suspensory ligament of the ovary; this structure conveys the internal spermatic vessels to the tube and to the ovary. The ovary and the fimbriated extremity of the tube are in the immediate neighborhood of the ureter, a relation that must be kept in mind both during operations and in judging of the extension of a perioöphorosalpingitis.

The tubes and ovaries also come in contact with the intestines. The loops of the small intestine which hang from the root of the mesentery dip down and may completely cover them. On the right side complications occur on account of the immediate vicinity of the cecum and vermiform appendix to the adnexa. The appendix may descend as far as the recto-uterine (peritoneal) fossa.

While the **uterus** is supported along its lateral margins by the broad ligaments as by a pair of wings, the anterior and posterior surfaces, as well as the fundus, are completely free. Like the broad ligament, these parts are covered on the side toward the peritoneal cavity by serous membrane,—the *perimetrium*,—which is closely united to the muscular wall of the uterus by a thin layer of subserous tissue. Between this area of firm union

and the cervix, where the connection is much looser, there is a transitional zone covered by thin but loose-meshed, subserous tissue which can readily be dissected away. The boundary of the firm union is formed by a crescentic line, with the concavity presenting downward, and terminating with its two points, behind, in the utero-ovarian ligament, and in front, in the round ligament. The perimetrium merges in front with the peritoneal investment of the bladder; behind, with that of the rectum and parietal peritoneum of the sacrum. The edges of the uterus, which are embedded in the broad ligaments, are connected with the wall of the sacrum by the two *recto-uterine folds*, which arch backward around the *recto-uterine fossa* and the rectum. They divide the posterior pouch of Douglas into an upper, wide portion, the "atrium," and a deeper narrow portion, the "fundus." The two folds convey the *sacrorecto-uterine ligaments*, which contain smooth muscle-fibers (Luschka's muscle) and merge one into the other on the posterior wall of the cervix, forming a transverse fold, the "torus uterinus." (See *Atlas of Obstetrical Diagnosis and Treatment*, Plate 17, Fig. 29.) The fundus of Douglas's pouch corresponds to Kohlrausch's transverse fold of the rectal mucosa, on the one hand, and to the posterior vault of the vagina, on the other; it lies 5 or 6 cm. above the anus, and measures from 3 to 5 cm. in depth. Normally, intestines are found only in the atrium; if the "fundus" descends, or if its depth is greater and it contains loops of intestine, there exists an infantile arrest of development which may result in the formation of an enterocele or a perineal hernia, or, by constriction, lead to the formation of cysts.

Cysts of this kind originate in "peritoneal diverticula." On both sides of the rectum two peritoneal pouches extend backward, known as the *recessus* or *sacci pararectales*; they lodge the ovaries and tubes.

The *abdominal cavity must be opened to permit the following operations*: extirpation of fibromata, fibromyomata, sarcomata, carcinomata, and other solid tumors or tumors filled with a viscous fluid, whether of the uterus or of the ovaries, if they are larger than the fist; the extirpation of smaller tumors fixed within or above the pelvic inlet, especially tumors of an inflammatory nature, such as pyosalpinx, ovarian abscesses, adhesions with an inflamed appendix, the masses caused by extra-uterine pregnancy; ventrofixation of an adherent retroflexed uterus after the adhesions have been removed; the removal of fully matured or almost fully matured macerated fetuses in retention of the ovum, when the uterus is high up and it is impossible to dilate the cervical canal, especially if there is fever; the removal of fetuses that have escaped into the peritoneal cavity through a complete rupture of the uterus; the Porro operation for a condition of this kind; and, finally, the purely obstetric delivery of the child through a Cesarean section on account of absolute or relative impossibility to extract it *per vias naturales*. The incision is usually made in the median line, along the *linea alba*; in rare cases the transverse incision in the suprapubic region, advised by Küstner and Pfannenstiel, or in certain cases an oblique incision in the hypogastric-inguinal region, is employed.

1. The Oblique Incision in the Hypogastric-inguinal Region.

This is used mostly in *perityphlitis*, for the evacuation of *parametritic abscesses*, and in a prolonged form in *injuries of the ureter* that cannot be reached through the vagina. The abdomen is opened, the posterior parietal layer of the peritoneum is incised, and the ureter with its sheath dissected out from between the layers of the peritoneum along the ileum as far as the bladder, where implantation is performed. The first peritoneal incision is closed, and a gauze drain passed down to the site of implantation.

2. The Transverse Incision in the Suprapubic Region.

The incision is extraperitoneal. It is used for the following operations on the bladder: *fixation of the bladder* above, in high degrees of cystocele which cannot be permanently fixed through the vagina, according to the method described in Group II.; the removal of large *vesical calculi* which cannot be removed either through the dilated urethra or with the aid of kolpocystotomy; the extirpation of large *tumors of the bladder* that cannot be subjected to cystoscopic treatment, and the treatment of *tuberculosis of the bladder* by packing the organ with iodoform gauze from above. 35 31

The transverse incision in the suprapubic region may be extended into the peritoneum after the insertions of the recti muscles have been severed and the bladder protected. The original **transverse incision** in such a case must be enlarged **lengthwise**; by this means a number of operations otherwise requiring an incision in the median line of the abdomen can be performed without danger of

the formation of hernia, which does not occur after a transverse incision. In closing the incision the tissues are united in separate layers with catgut; the ends of the muscles may, in addition, be advantageously secured with deep silver wires or silkworm-gut sutures passing through the skin.

3. Celiotomy with an Ordinary Median Incision through the Abdominal Wall.

An incision in the skin is carried first as far down as the fascia; nothing is gained by making the incision through one of the recti muscles either to hasten the healing of the wound or to avoid the subsequent production of a hernia. [This is not my practice. I open the sheath of each rectus so that the muscles may be closely approximated in closing the abdomen. I believe this method gives the best result.—ED.] The abdomen should be disinfected the day before and covered with a wet bichlorid dressing. Immediately before the operation the surface of the abdomen is again cleansed with warm soap and water, then with tincture of soap, and finally with a solution of bichlorid. The skin must be well scrubbed with a brush.

The peritoneum, as it bulges through the wound, is seized with forceps and opened with the aid of a grooved director or a finger inserted to protect the intestines, which are not infrequently found in immediate contact with the peritoneum. If adhesions are found between the peritoneum and a tumor, they must be broken up with a blunt instrument. If the adhesions are extensive and the tissues are firmly united, the question of removing the

entire serous surface may have to be considered. The defect thus produced must later be repaired by means of a plastic operation.

If the intestines escape from the cavity during the operation, they must be carefully protected against pressure and sudden cooling; they are, therefore, covered with sterilized cloths or pieces of gauze [soaked in hot normal saline solution.—ED.]. Certain other precautions are necessary: fluids contained in a tumor or pus from an abscess must be caught in a basin or wiped up [care being taken that the general peritoneal cavity is walled off by gauze pads.—ED.]; all bleeding vessels must be ligated, as blood in the peritoneal cavity forms the best medium for the development of bacteria which may have effected an entrance during the operation.

To afford a good view of the pelvis, the woman is placed in the Trendelenburg position, which causes the intestines to gravitate toward the diaphragm. Incidentally it enables the patient to take the anesthetic more satisfactorily. While the abdominal wound is being closed, however, the patient must be placed in the horizontal position, because adhesions and ileus are less apt to form in this position (Schauta). The field of operation may be made more accessible to the operator by tightly packing the vagina with iodoform gauze or introducing a kolpeurynter. (The vagina, as well as the abdominal walls, should be carefully disinfected immediately before the operation.)

Before the abdominal wound is closed, a final inspection should be made to determine whether anything, such as sponges or pads, has been left behind; the nurse is

Plate 34.

Abdominal Hysterectomy (Freund).—Ligating the adnexa. The abdominal walls are held apart with Fritsch's retractors, being covered over with sterile cloths. The internal genitalia are in plain view. The left suspensory ligament of the ovary and the left round ligament have already been ligated. The uterine extremity of the tube is being tied.

Plate 35.

Abdominal Hysterectomy.—Division of the left broad ligament between the ligatures, placed as shown on Plate 34.

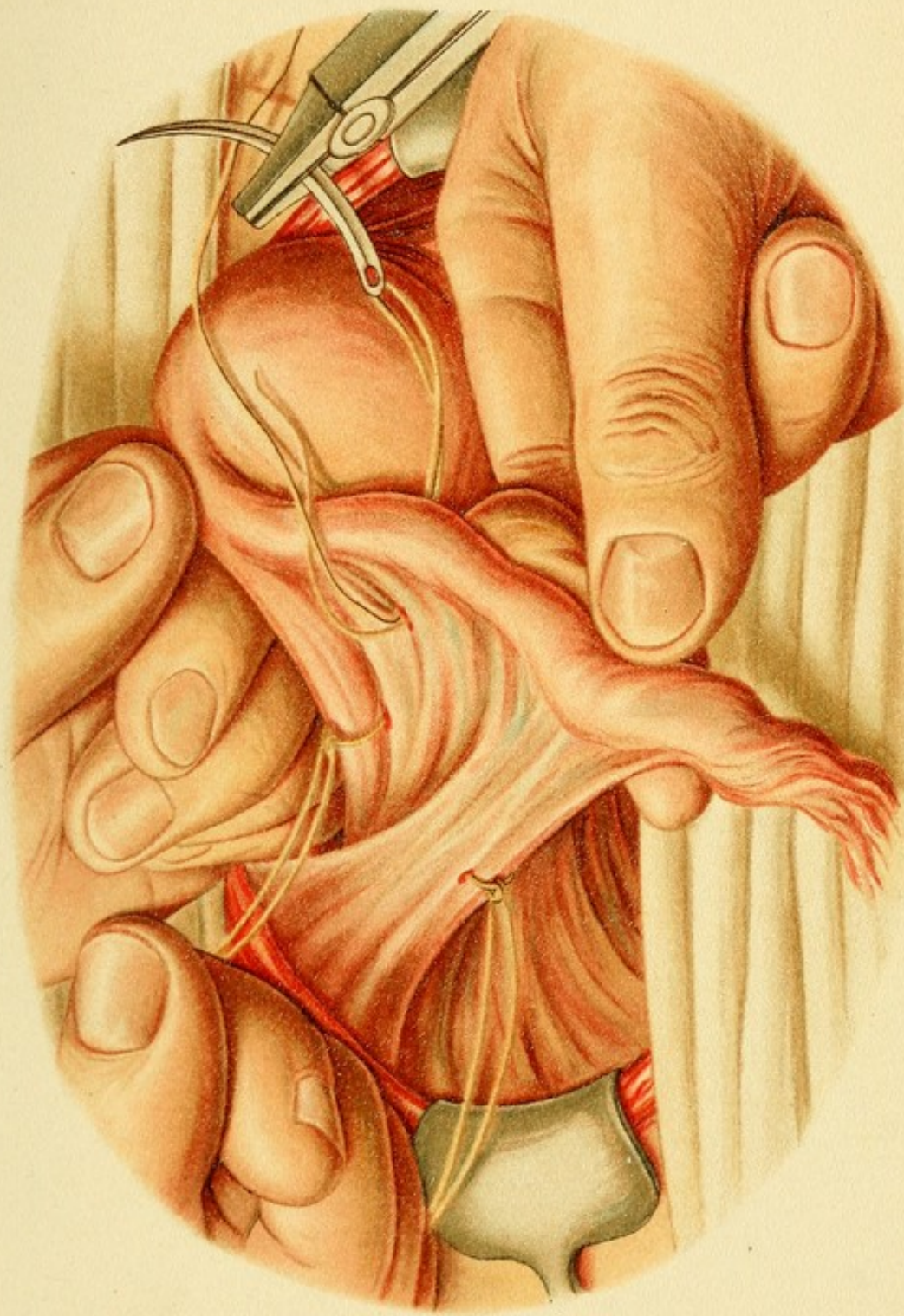Plate 36.

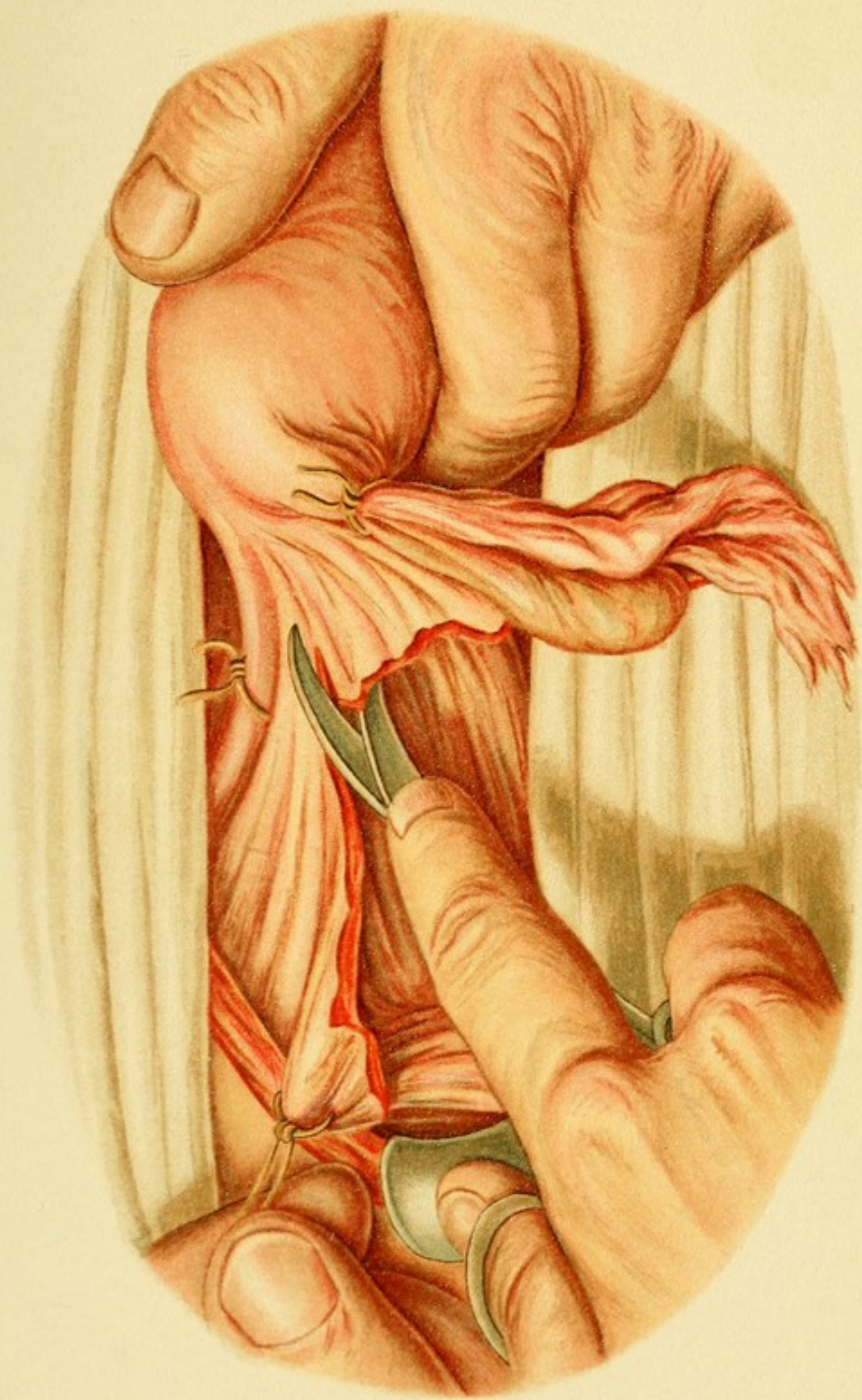
Abdominal Hysterectomy.—Ligation of the left uterine artery. The entire perimetrium of the left side has been exposed, partly by cutting and partly by blunt dissection of the two layers of the broad ligament, so that the uterine artery can be seen and felt to pulsate alongside of the ureter in the depths of the wound. The plate shows the method of passing a needle around the vessel.

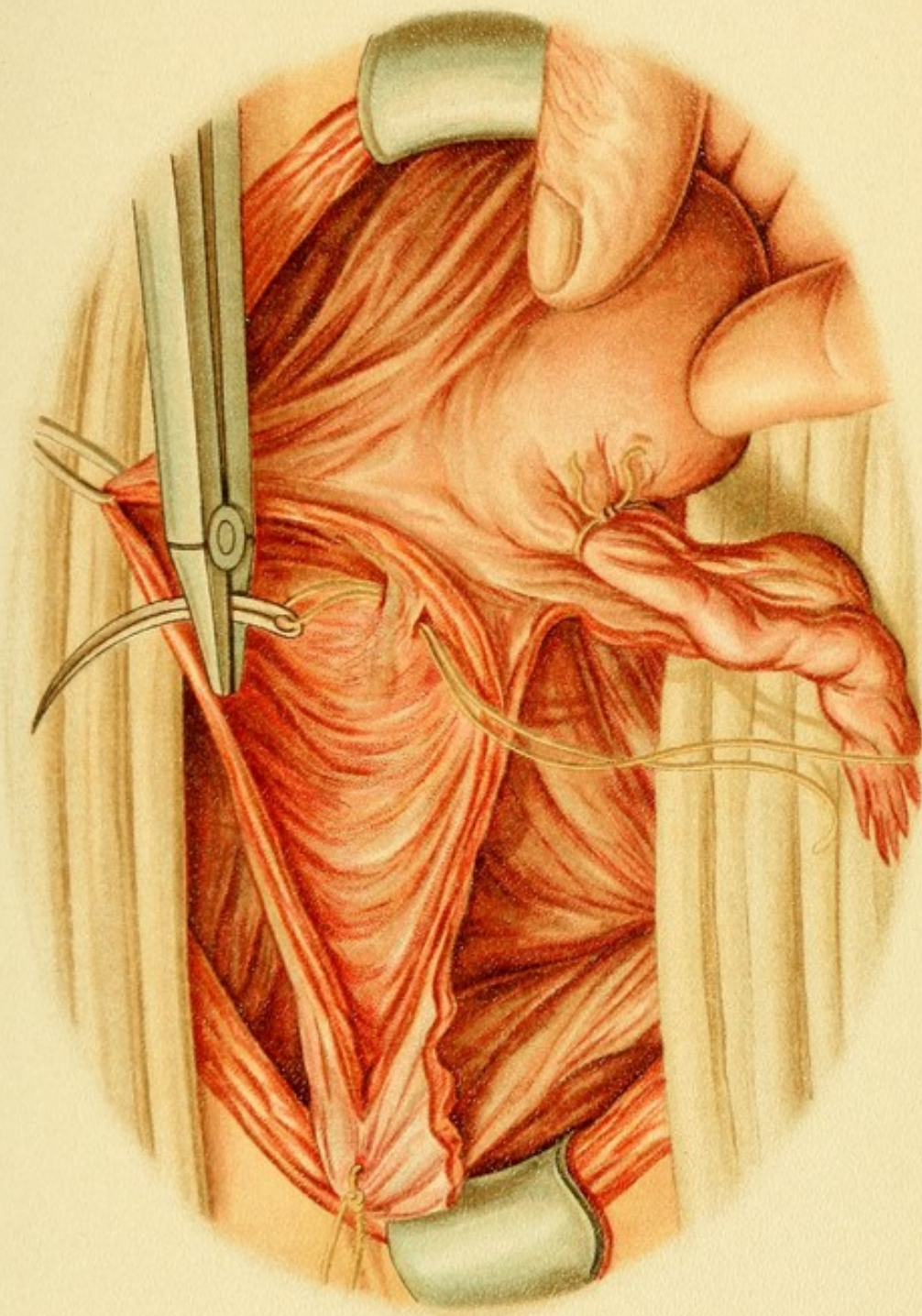
Plate 37.


Abdominal Hysterectomy.—Amputation of the uterus and its removal from the vault of the vagina. The three principal ligatures that remain are visible. Similar ligatures have been placed on the right side, so that the amputation of the uterus is practically unattended by hemorrhage.

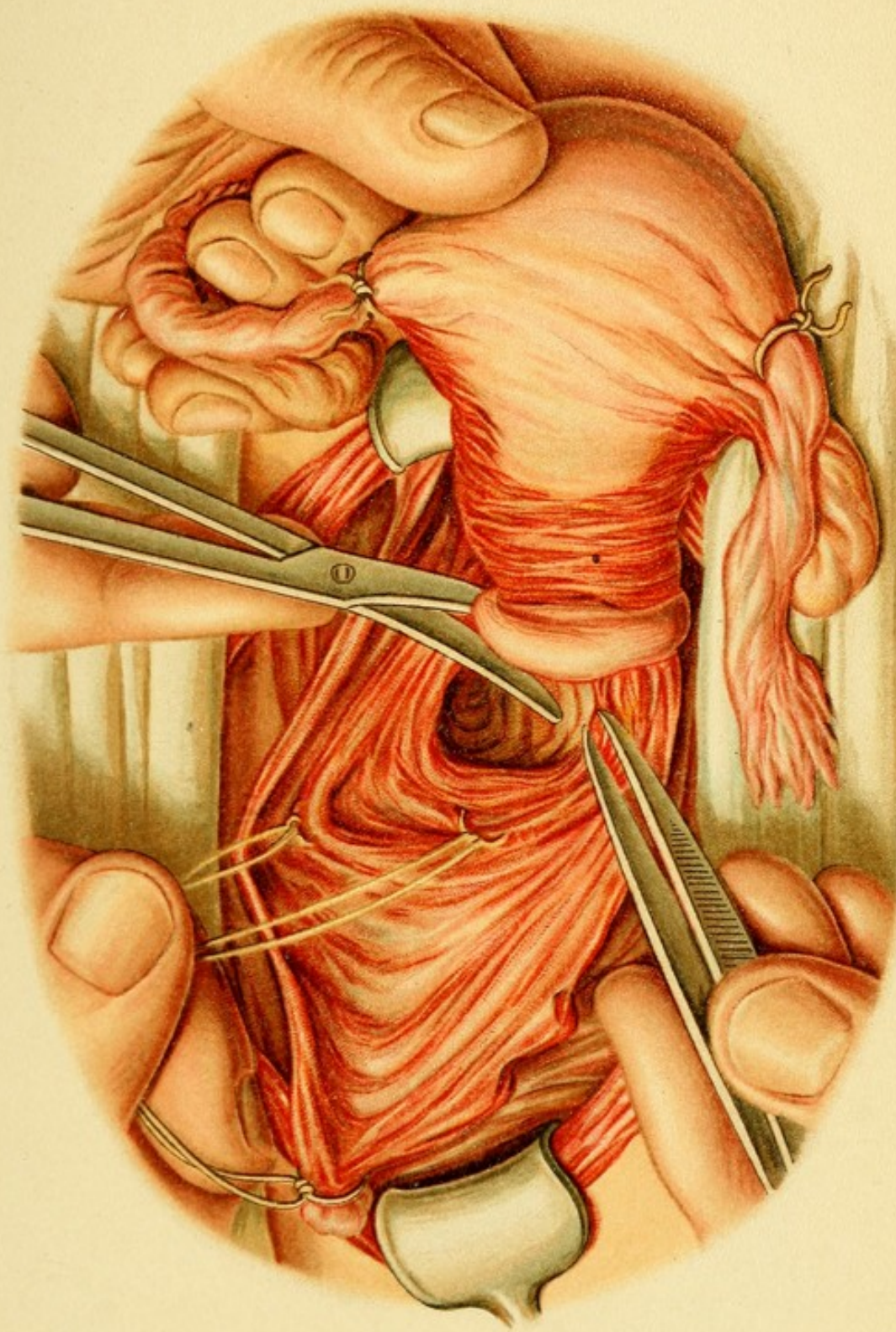
always instructed to count sponges and pads both before and after the operation. [It is well that the chief assistant should do this also.—ED.] The best way to close the abdominal wound is by several rows of sutures—at least two: (1) A suture uniting the peritoneum and the fascia; (2) a suture uniting the muscle and skin. For the first, catgut is used; and for the last, celluloid twine or gutta-percha silk, as these are not capillary, or aluminium bronze, or silver wire. The wound is then covered with an air-tight bandage, consisting, say, of iodoform collo-











dion or Bruns' airol paste and gauze. A circular bandage around the body, well padded with cotton, completes the dressing. In a normal case the woman stays in bed for two weeks and is discharged at the end of the third week.

4. Abdominal Hysterectomy.

This operation, according to Freund, is to be performed both in myomatosis and in carcinomatosis of the organ if the uterus, either on account of the tumors or on account of a complicating pregnancy, is too large, or if it is bound down by numerous large adhesions and cannot be removed through the vagina. The operation consists in removing the uterus, oviducts, and ovaries from the broad ligaments and from the vault of the vagina through the peritoneal cavity in such a way as to avoid hemorrhage and injury of neighboring organs, such as the bladder, the ureter, and the rectum. The ligation of the vessels compared to the same procedure in the vaginal operation is extremely simple, except the ligation of the uterine artery, as in the latter procedure there is greater danger of injuring or including the ureter because the bladder and ureters cannot be so thoroughly dissected away from the uterine arteries.

The ligatures are placed on each side as follows: (1) One around the suspensory (infundibulopelvic) ligament of the ovary, laterally from the pavilion of the tube; this includes the internal spermatic or ovarian arteries. (2) One including the utero-ovarian ligament and the uterine insertion of the tube with the arterial branches of the tubes and ovaries. (3) One ligature around the

Plate 38.

Abdominal Hysterectomy in a Case of Myoma of the Uterus.—Retro-peritoneal treatment of the stump after Chrobak. Ligature of the uterine artery after the vessels and all ligaments have been tied, as in the last-described operation. In ligating the uterine artery the needle is at the same time passed through the walls of the cervix.

Plate 39.

Abdominal Hysterectomy in a Case of Myoma of the Uterus.—Securing a flap from the posterior wall of the uterus for the purpose of covering the stump of the cervix (Chrobak). The ligatures described in the last operation have all been tied.

Plate 40.

Abdominal Hysterectomy in a Case of Myoma of the Uterus.—Wedge-shaped excision of the stump of the cervix. The ligatures about the uterine arteries are seen on both sides of the stump. The lumen of the cervix is vigorously disinfected and covered with the two thick flaps, which have been made less rigid by excising portions of tissue and by dissection.

Plate 41.

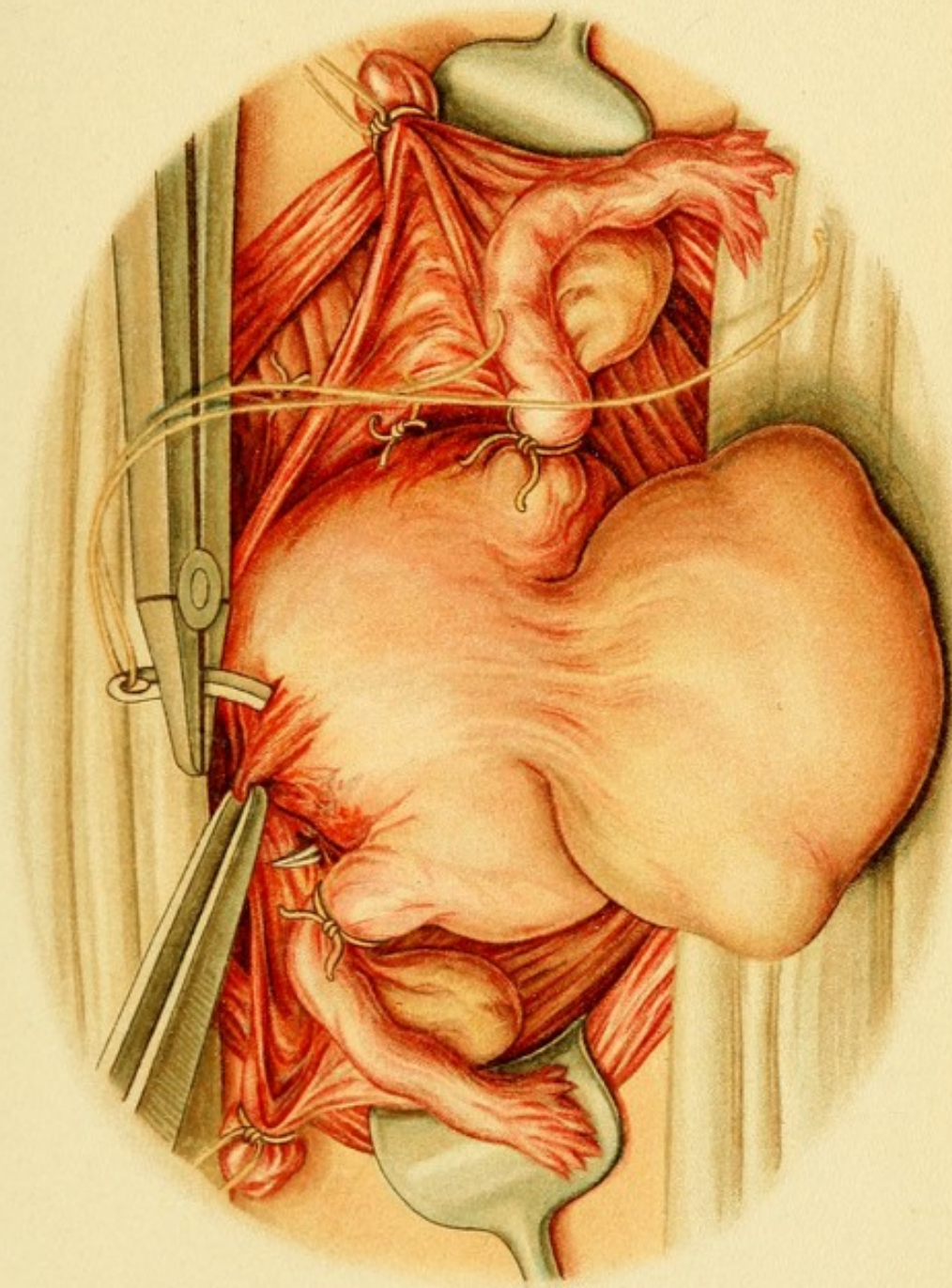
Abdominal Hysterectomy in a Case of Myoma of the Uterus.—Closing the peritoneal wound. The wound in the broad ligaments is closed from one suspensory ligament of the ovary to the other with a continuous buried catgut suture. This includes subserous disposal of the stump of the cervix, which has already been sewed together and the sutures tied in the lumen of the cervix.

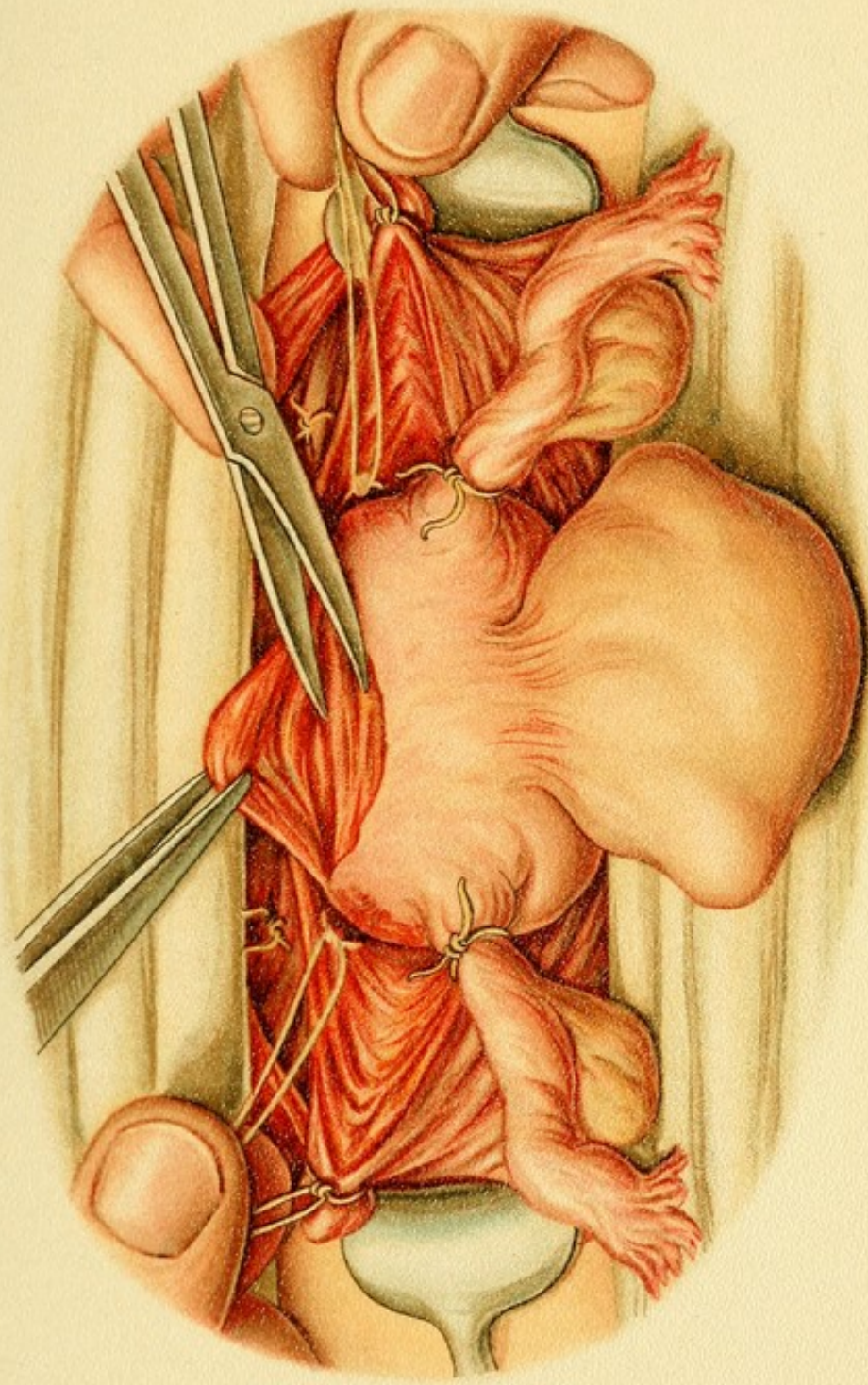
Plate 42.

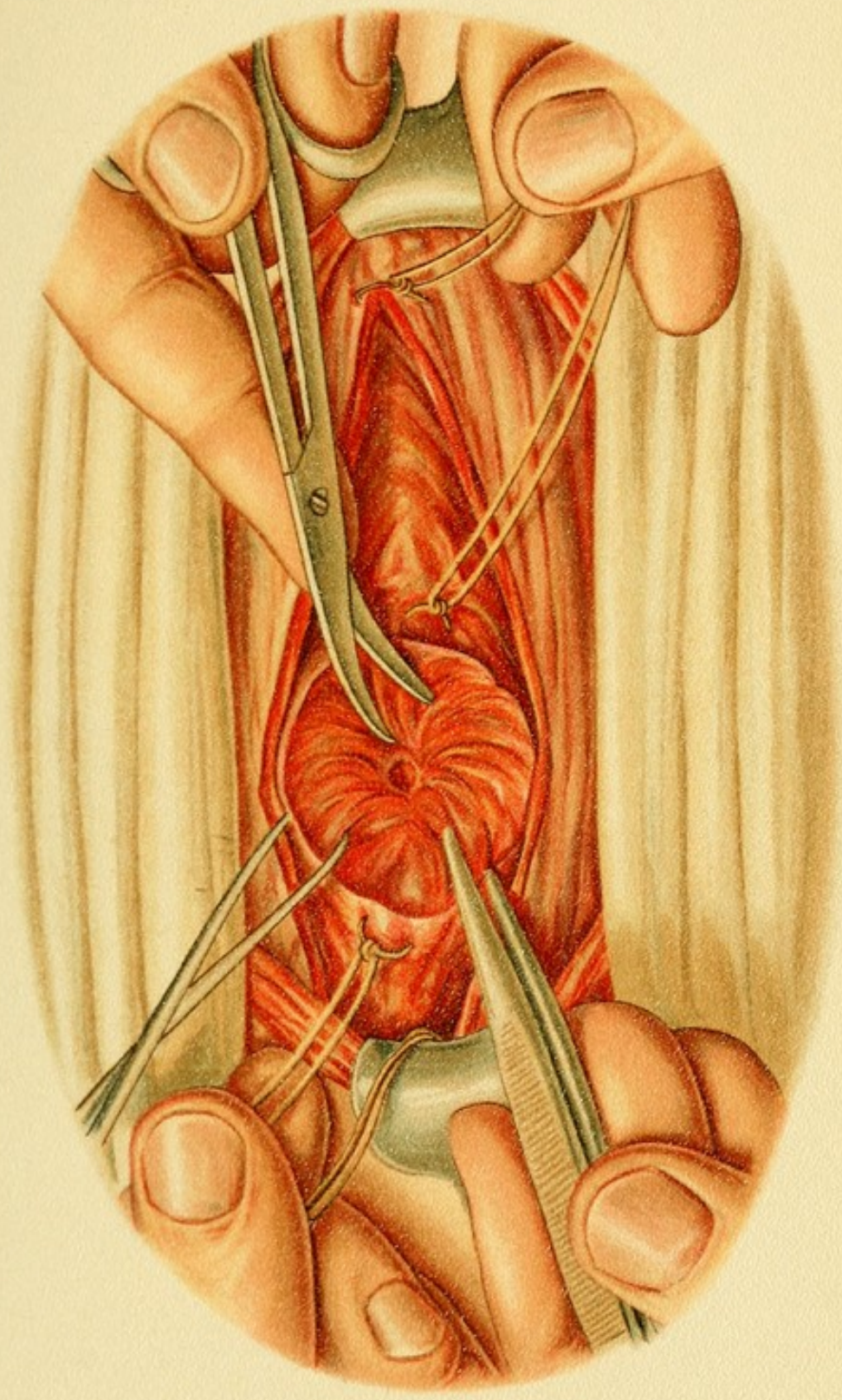
Abdominal Hysteropexy or Ventrofixation of the Uterus (after Olshausen).—The round ligaments are secured by sutures to the peritoneal wound. Czerny and Leopold pass the sutures through the fundus of the uterus.

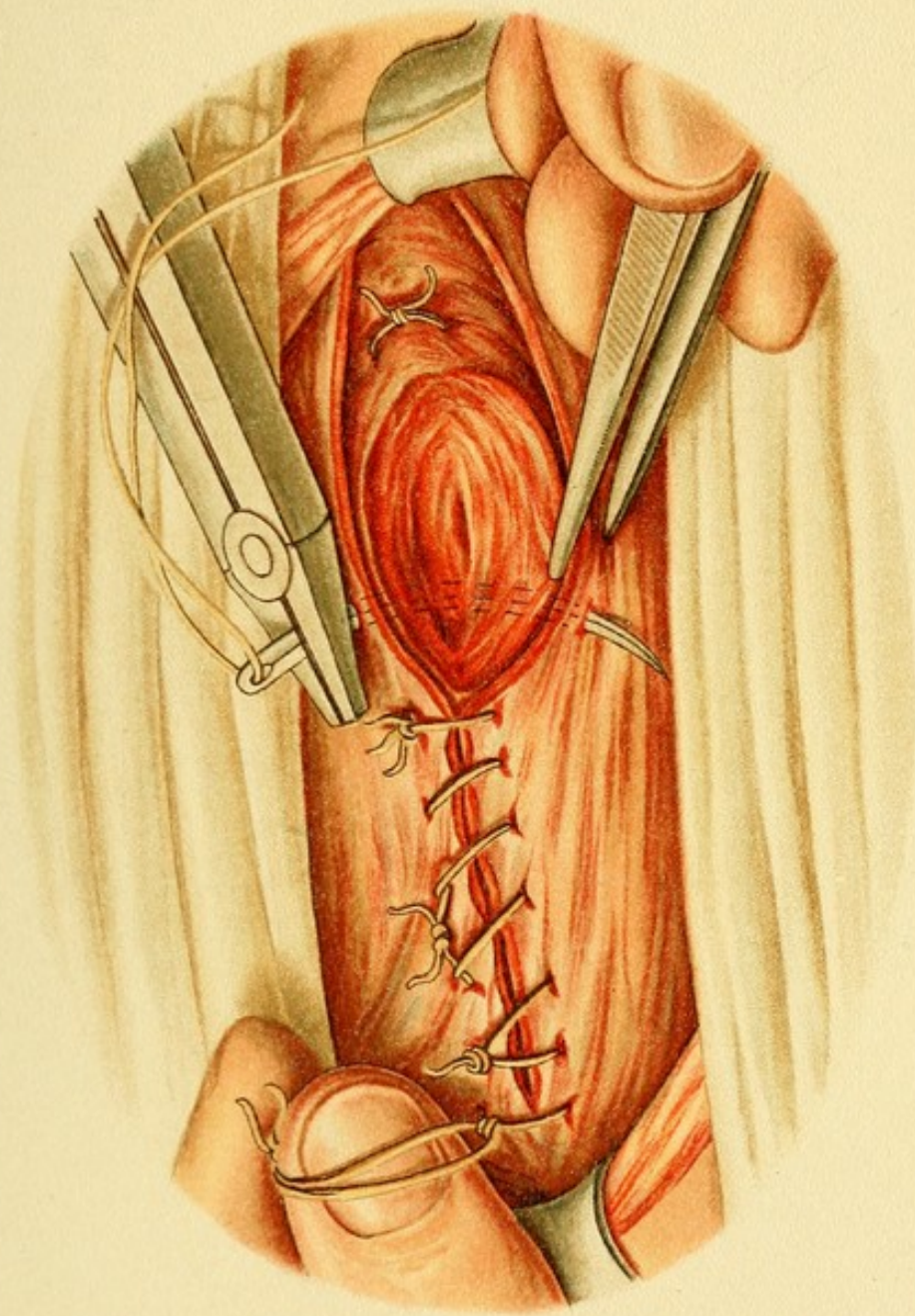
round ligament at about its center, which includes the arteries of the round ligament (see Plate 34).

The broad ligament is now divided on the median side of the ligatures, the incision beginning at the insertion

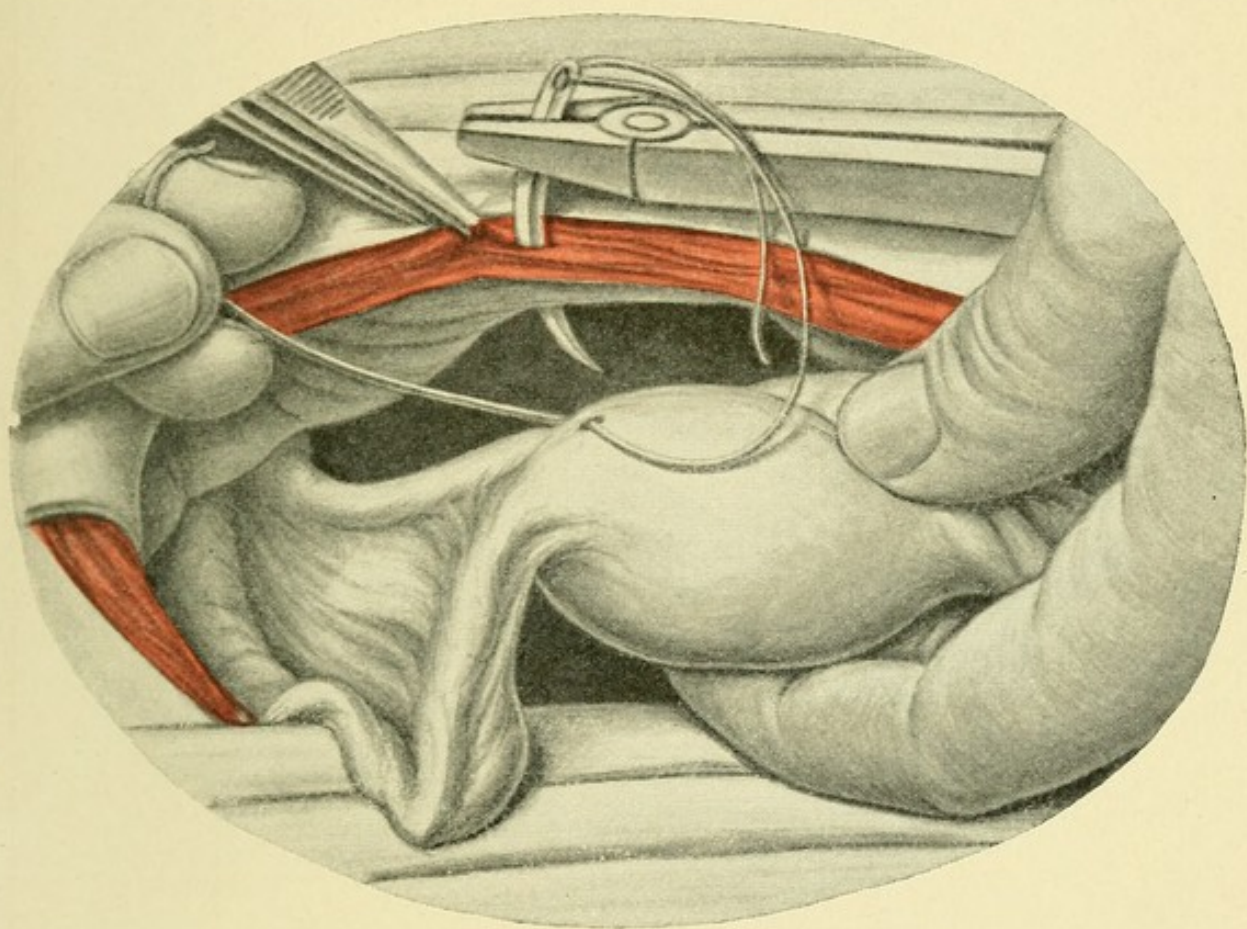









Tab. 42.





of the tube into the suspensory ligament of the ovary and ending a little above the internal os, leaving the ligature of the round ligament a little to one side (Plate 35).

At this point the pulsation of the uterine artery can be felt. The vessel is dissected out from the surrounding connective tissue, isolated from the ureter, and then ligated (Plate 36). After the cervicovaginal artery has also been secured, the uterus is separated from the bladder with a blunt instrument and one of the two vaults of the vagina is opened. Finding of the various structures will be greatly facilitated if the vagina has first been packed with gauze. After these preliminary steps the complete separation of the uterus from the vagina presents no difficulty (Plate 37).

The vault of the vagina is closed separately, and after that the entire transverse wound in the parametrium, from one suspensory ligament of the ovary to the other, is closed with a continuous catgut suture which should also include once more the edges of the vaginal wound (Plate 41). If interrupted sutures are used, they must be so placed that the knots and ends of the sutures will be in the vagina.

5. Supravaginal Abdominal Hysterectomy for Myoma.

This operation is used in the case of tumors larger than a child's head ; in obstetric operations, to take the place of the conservative Cesarean section when the uterus is lacerated or has ruptured [If an infected uterus must be removed, *total extirpation* should be performed.—ED.] or become infected and the ovum has escaped into

the peritoneal cavity ; or prophylactically in the case of multiparæ whose children are always still-born *per vias naturales* or cannot be delivered at all in any other way.

The following description of a typical hysterectomy for uterine **myoma** is based in the main on Chrobak's method of securing the stump of the cervix retroperitoneally.

The operation is begun like the one just described, and no difference is made until the ligation of the uterine artery. In ligating this vessel the ligature is made to include the edge of the muscular wall of the uterus (Plate 38). Before the uterus is emptied, a muscular flap covered with serous membrane is excised from its posterior wall, large enough to cover the stump of the cervix and thick enough so that its vascular supply suffices to guard against necrosis (Plate 39). The stump of the cervix is cut out in wedge or funnel shape (Plate 40), so that the walls of the cervix can be sewed together as a protection against the passage upward of micro-organisms from the vagina and cervical canal. The sutures uniting the muscular tissue are buried by covering the entire stump with the serous flap. The sutures which close the serous flap form part of the line of sutures used to close the wound in the broad ligaments (Plate 41) described in the last operation.

6. Ventrofixation of the Uterus.

This operation, according to Olshausen, Czerny, and Leopold, is to be preferred to vaginofixation or the Alexander-Adams operation in younger women, because it does not interfere with labor. [The author evidently

means ventrosuspension.—ED.] It is especially appropriate in retroflexion with fixation of the uterus when the adhesions have been broken up.

Olshausen secures the insertions of the round ligaments to the angles of the peritoneal wound and to the sheaths of the recti (Plate 42), while Czerny and Leopold pass the sutures through the fundus itself. The same sutures that are used to close the abdominal wall are passed through the fundus. Catgut may also be used.

X. ALEXANDER-ADAMS OPERATION, PERFORMED AFTER EXPOSURE OF THE INGUINAL CANAL.

Topographic and Surgical Anatomy of the Inguinal Region.

The skin is divided immediately above Poupart's ligament and in a direction parallel with it, then the panniculus adiposus, and, underneath that, the superficial abdominal fascia, in which, midway between the symphysis and the anterior superior spine of the ilium, the epigastric vessels will be found. The superficial fascia is divided only by a thin layer of fat from the much thicker aponeurosis of the external oblique. The latter covers and forms the inguinal canal, the internal opening of which is situated at a point somewhat lateral to the epigastric vessels. The external inguinal ring is situated a short distance to the outer side of the pubic tubercle, which can be readily palpated. It is formed by the aponeurosis of the external oblique (intercrural fibers), which here undergo division and form the radiating *crura ligamenti inguinalis superius et inferius*. The opening is covered by the thin cremasteric fascia. Between the limbs of the inguinal ring the

round ligament emerges with the ilio-inguinal nerve. The latter courses downward and crosses the external pudendal vein on the ligament. Behind these structures the external spermatic nerve runs down and sends one branch behind the ligament and upward from this point.

The round ligament can, therefore, be followed along with the ilio-inguinal nerve laterally into the inguinal canal. To expose the round ligament and the nerve, the aponeurosis must be divided in a line parallel with Poupart's ligament, from the pubic tubercle or external inguinal ring to the anterior superior spine of the ilium, a distance of 7 or 8 centimeters from the symphysis. The posterior wall of the canal, formed by the transversalis fascia and the reflected inguinal ligament, is then exposed. Near the internal inguinal ring there is a sac-like protuberance on the outer side of the round ligament. This is the *peritoneal diverticulum of Nuck*, the vaginal process of the peritoneum which is loosely united to the round ligament. The internal, like the external, inguinal ring is bounded by aponeurosis, the boundary of the internal ring being a portion of the transversalis fascia—namely, the semilunar fold. Behind or underneath the inguinal canal we come upon the deep epigastric vessels.

Alexander-Adams Operation of Shortening the Round Ligament.

The topography having thus been described, the steps of the operation are as follows: A curved incision is carried from the pubic tubercle to the anterior superior spine of the ilium, a little above and parallel with Poupart's ligament. The epigastric vessels must be avoided.

About the middle of the incision the aponeurosis of the external oblique is dissected out, and the external inguinal ring is then found. This structure is recognized by the intercrural fibers and the inguinal crura. This procedure is attended with the division of the branches of the above-described blood-vessels, and the resulting hemorrhage obscures the view. Werth avoids this by directly dividing the aponeurosis and laying open the inguinal canal.

The round ligament is then carefully drawn out of the canal for a distance of about 10 cm. If more than this is drawn out, the uterus tips over backward, because peritoneal fibers in the broad ligament are put on the stretch and thus bring about a retroversion of the organ (Zweifel). The diverticulum of Nuck (Nuck's canal) is drawn out at the same time with the round ligament and may be opened when the ligament is shortened.

The fixation sutures should close both the peritoneal sac and the inguinal canal. They are accordingly carried from the external oblique through the round ligament and through the two serous edges to Poupart's ligament. Interrupted catgut sutures are used; the wound is finally closed by means of deep through-and-through sutures.

INDEX.

- ABDOMINAL** cavity, operations
 requiring opening of, 120
 hysterectomy, 125, Pls. 34-37
 in myoma of uterus, 127, Pls.
 38-41
 hysteropexy, 128, Pl. 42
 wall, celiotomy with ordinary
 median incision through,
 122
 Abrasio mucosæ, 81
 Abscess, pelvic, opening of, 96
 Accouchement force, 79
 Adnexa, operations on, 102
 Alexander-Adams operation after
 exposure of inguinal canal,
 129
 for shortening round liga-
 ment, 130
 Amputation of cervix uteri, su-
 pravaginal, 92
 Anococcygeal ligament, 21
 Atmokaussis, 83

BARNES' bags, 80
 Bischoff's kolpoperineorrhaphy,
 35
 Bladder, relations of vagina to, 74
 boundary of, 97
 foreign bodies in, kolpocystot-
 omy for, 59, 61, Pl. 11
 Bladder, foreign bodies in, removal
 of, through urethra, 59,
 61, Pl. 11
 Broad ligament, 75
 Bulbocavernosus muscle, 24

CASTRATION, 103, Pls. 26, 27, 28
 Cavum prævesicale superius, 115
 Celiotomy, operations on genitals
 requiring, 114
 with ordinary median incision
 through abdominal wall,
 122
 Cervical canal, dilatation of, 79
 of uterus, artificial dilatation
 of, operations after, 72
 Cervicitis, 68, Pl. 16
 Schröder's wedge-shaped inci-
 sion for, 70
 Cervico-ureteral fistula, operation
 for closure of, 94
 Cervicovesical fistula, operation
 for closure of, 94
 Cervix, excision of, double-
 wedged, 69, Pl. 15
 uteri, amputation of, suprava-
 ginal, 92
 bloodless dilatation of, 78
 retrofixation of, 106
 Coccygeal muscles, 20

- Columnæ rugarum vaginae, 18
 Constrictor cunni, 24
 Crura ligamenti inguinalis superioris et inferioris, 129
 Curetment, 81
 Curettage, 81
- DESCENDING limb of tube, 117
 Diaphragm of pelvis, 20
 Diverticulum of Nuck, peritoneal, 130
 Douglas' pouch, 47
 abscess in, operative treatment, 107
 atrium of, 119
 fundus of, 119
 opening of, Pl. 3
 posterior, operations performed through, 104
- ECTOPIC gestation, operative treatment, 106
 Emmet's operation for commissural lacerations, 68
 Episiotomy, 43
 Epoöphoron, 118
 Eversion of cervical mucosa, 68, Pl. 16
 Schröder's incisions for, 70
 External inguinal ring, 129
 oblique, 114
 os, dissection of, 67
 sphincter ani, 23
 Extirpation, total, of uterus through vagina, Pls. 29, 30, 31, 32, 33
- FIBROMYOMA, polypous, enucleation of, 88, Pls. 20-23
 Fibromyoma, subserous, of uterus, removal, 101
 Fistula, cervico-ureteral, operation for closure of, 94
 cervicovesical, operation for closure of, 94
 ureterovaginal, Mackenrodt's method of closing, 95
 vesicovaginal, traumatic, operations for, 59
 Fossa navicularis, repair of injury to, 33
 Freund's kolpoperineorrhaphy, 36, 38
 Fritsch's kolpoperineorrhaphy, 34, 35
 Fundus vesicæ, 116
- GENITALS, anatomy, 114
 operations on, requiring celiotomy, 114
 surgical anatomy, 114
 topographic anatomy, 114
 Gersuny's operation for incontinence of urine, 44
 Gestation, ectopic, operative treatment, 106
 Gravid accessory cornu, removal, 102
- HEGAR'S kolpoperineorrhaphy, 35, 49, Pls. 4-8.
 Hymen, extirpation of portions of, 43
 Hypogastric-inguinal region, oblique incision in, 121
 Hysterectomy, abdominal, 125, Pls. 34-37

- Hysterectomy for myoma of uterus, 127, Pls. 38-41
- Hysteroceleisis, 71
- Hysteropexy abdominal, 128, Pl. 42
- IMPRESIO uterina, 115
- Incision, median, through abdominal wall, celiotomy with, 122
- oblique, in hypogastric-inguinal region, 121
- transverse, in suprapubic region, 121
- Incontinence of urine, operation for, 44
- Infradiaphragmatic hollow organs, 23
- Inguinal canal, anatomy, 129
- exposure of, Alexander-Adams operation after, 129
- surgical anatomy, 129
- topographic anatomy, 129
- ring, external, 129
- internal, 130
- Internal inguinal ring, 130
- oblique, 114
- Intestine, ovary and, 118
- Ischiocavernosus muscle, 24
- Ischiorectal fossa, 23
- KOHLRAUSCH's fold, 47
- Kolpoceliotomy, anterior, 97, Pls. 24, 25-Fig. 1
- operations on uterus with aid of, 101
- ovariotomy after, 103, Pls. 26-28
- Kolpoceliotomy, anterior, vaginifixation of uterus after, 98, Pl. 25-Fig. 2
- in pelvic abscess, 104
- posterior, 105
- Kolpocleisis, 71
- Kolpocystotomy, 61, Pl. 11
- for foreign bodies in bladder, 59, 61, Pl. 11
- Kolpoperineorrhaphy, 34, 49, Pls. 4-8
- Bischoff's, 35
- Freund's, 36, 38
- Fritsch's, 34, 35
- Hegar's, 35, 49, Pls. 4-8
- with retrofixation of cervix, 49, Pls. 4-8
- of neck, Pl. 3
- Kolporrhaphy, anterior, 56, Pl. 9
- posterior, 49, 52
- Kolporrhaphy - perineorrhaphy, Martin's, 38
- Kolpotomy, anterior, 97, Pls. 24, 25-Fig. 1
- LEVATOR ani muscle, 20
- Levatores ani et trigoni urethrogenitalis, 18
- Linea alba, 114
- Luschka's muscle, 119
- Lymphoglandulæ hypogastricæ, 76
- MACKENRODT's method of closing ureterovaginal fistula, 95
- Martin's kolporrhaphy-perineorrhaphy, 38
- Menorrhagia, atmokausis for, 83
- Mesosalpinx, 118

- Mesovarium, 117
 Metreurynter, method of using, 80
 Metrorrhagia, atmokausis for, 83
 Musculus trigoni urogenitalis, 21


 NUCK's canal, 130

 OBLIQUE incision in hypogastric-
 inguinal region, 121
 Operations on genitals requiring
 celiotomy, 114
 performed after opening one or
 both peritoneal pouches and
 wall of uterus, 109
 through posterior pouch of
 Douglas, 104
 without speculum, 17
 requiring exposure of vagina, 46
 requiring opening of abdominal
 cavity, 120
 requiring opening of vesico-uter-
 ine fossa, 96
 Os, commissures of, lacerations of,
 68
 Emmet's operation, 68
 Ovarian tube, descending limb of,
 117
 intestines and, 118
 position of, 117
 tumors, removal of, 103, Pls. 26,
 27, 28
 Ovariectomy after anterior kolpo-
 celiotomy, 103, Pls. 26, 27,
 28
 Ovary, intestines and, 118
 position of, 117

 PARAMETRIA, opening abscess in,
 96
 Parametria, true, 75
 Paroöphoron, 118
 Pelvic abscess, kolpoceliotomy in,
 104
 opening of, 96
 floor, anatomy of, 17, 19
 openings, 21
 Pelvis, blood supply, 22
 diaphragm of, 20
 Perimetrium, 118
 Perineal region, inner, surgical
 topography, 18
 Perineoplastic operations in the
 flaps, 39
 Perineoplasty, Bischoff, 35, 36
 Perineorrhaphy, 25
 for complete lacerations, 26, Pls.
 1, 2
 after-treatment, 31
 cicatrized, 32
 granulating, 32
 needle, 29
 preliminary treatment, 29
 secondary operation, 32
 suture material, 29
 for incomplete lacerations, 33
 cicatrized, 33
 von Winckel's, 38
 Perineorrhaphy - kolporrhaphy,
 Martin's, 38
 Perineum, anatomy, 18
 lacerations of, 25
 repair of, 25. See also *Perin-*
 orrhaphy.
 operations on, 24
 complete plastic, 26, Pls.
 1, 2
 rectovaginal fistula near, closing
 of, 66

- Peritoneal diverticulum of Nuck,
 120
 fossa, 116
 pouch and wall of uterus, oper-
 ations performed after open-
 ing, 109
 obliteration of, 106
 total extirpation of uterus
 through vaginal opening
 in, 111
 Peri-uterine space, 115
 Perivesical space, 115
 Plica epigastrica, 115
 peritonealis, 116
 Plicæ vesicales transversæ, 115
 Polypoid fibromyoma, enucleation
 of, 88, Pls. 20-23
 Polyps, removal, 83
 Portio vaginalis, 48
 anatomy, 46
 operations on, 67
 wall of, wedge-shaped exci-
 sion from, 69, Pl. 15
 Pouch of Douglas, abscess in,
 operative treatment 107
 atrium of, 119
 fundus of, 119
 posterior, operations per-
 formed through, 104
 peritoneal, and wall of uterus,
 operations performed after
 opening of, 109
 obliteration of, 106
 total extirpation of uterus
 through vagina by opening
 of, 111
 Pregnancy, vaginifixation and, 99
 Prevesical space, 115
 Pyriform muscles, 20
- RACLAGE, 81
 Recessus pararectales, 120
 Recto-uterine folds, 119
 fossa, 119
 Rectovaginal fistula, high method
 of closing, 66, Pls. 13, 14
 near perineum, closing of, 66
 Rectum, 23
 Reinversion, 109
 Retrofixation of cervix uteri, 106
 Round ligament, Alexander-
 Adams operation for short-
 ening, 130
- SACCI pararectales, 120
 Sacrorecto-uterine ligaments, 119
 Schröder's wedge-shaped incision,
 70, Pl. 16
 Speculum, operations performed
 without, 17
 Sterilization, 103, Pls. 26-28
 Suprapubic region, transverse in-
 cision in, 121
- TORUS uterinus, 119
 Transversalis fascia, 114
 Transverse incision in suprapubic
 region, 121
 Transversus perinæi muscle, 24
 Trigonum Lieutaudii, 48
 urogenitale, 21
 True parametria, 75
- URETEROVAGINAL fistula, Mac-
 kenrodt's method of closing,
 95
 Urethra, dilatation of, 59
 removal of foreign bodies in
 bladder through, 59, Pl. 11

- Urethra, resection of, 45
- Urethral region, inner, surgical topography, 18
- Urine, incontinence of, operation for, 44
- Uterine artery, ligation of, 89
cavity, vaporization of, 83
- Uterus, attachments of, 118
cervical canal of, artificial dilatation of, operations after, 72
cervix of. See *Cervix uteri*.
extirpation of, ligation of uterine artery, 89
myoma of, abdominal hysterectomy in, 127, Pls. 38-41
operations on, with aid of anterior kolpoceliotomy, 101
performed after opening wall of, and one or both peritoneal pouches, 109
position, 118
sounding of, 78
subserous fibromyoma of, removal, 101
total extirpation of, through vagina, Pls. 29-33
by opening peritoneal pouches, 111
vaginifixation of, after kolpoceliotomy, 98, Pl. 25-Fig. 2
ventrofixation of, 128, Pl. 42
- VAGINA, anatomy, 46
anterior vault, 72
bladder and, relations of, 74
cervix of, anatomy, 72
blood supply, 75
- Vagina, cervix of, division of anterior wall of, 85, Pls. 17-19
supravaginal amputation, 85, Pls. 17-19
wall of, 76
lumen of, 48
narrowing of, 57, Pl. 10
surgical anatomy, 46
topographic anatomy, 46
total extirpation of uterus through, Pls. 29-33
by opening peritoneal pouches, 111
vaults of, anatomy, 72
blood supply, 75
operations after dissecting away of, 85
- Vaginifixation, 98, Pl. 25-Fig. 2
precautions, 99
pregnancy and, 99
sutures, 100
- Vaginifixura vesicofixatio uteri, 98, Pl. 25-Fig. 2
precautions, 99
pregnancy and, 99
sutures, 100
- Vaginorrhaphy, high, 57, Pl. 10
- Vaporization of uterine cavity, 83
- Ventrofixation, 128, Pl. 42
- Vesico-uterine fossa, 116
operations requiring opening of, 96
- Vesicovaginal fistula, flap-splitting method, 64
method of closing, 62, Pl. 12
traumatic, operation for, 59
- von Winckel's perineorrhaphy, 38
- Vulva, extirpation of parts of, 43
operations on, 24



SAUNDERS' MEDICAL HAND-ATLASES

A SERIES OF BOOKS OFFERING
A SATISFACTORY SUBSTITUTE FOR ACTUAL CLINICAL WORK

SPECIAL OFFER

AS it is impossible to realize the beauty and cheapness of these atlases without an opportunity to examine them, we make the following offer: Any one of these books will be sent to physicians, carriage prepaid, upon request. If you want the book, you have merely to remit the price; if not, return the book by mail.

A Descriptive Catalogue of all our Publications Sent on Request

W. B. SAUNDERS & COMPANY

925 Walnut Street

Philadelphia

NEW YORK

LONDON

Fuller Building, 5th Ave. and 23d St. 9, Henrietta St., Covent Garden

SAUNDERS' MEDICAL HAND-ATLASES

IN planning this series of books arrangements were made with representative publishers in the chief medical centers of the world for the publication of translations of the atlases in thirteen different languages, the lithographic plates for all being made in Germany, where work of this kind has been brought to

Moderate Price

the greatest perfection. The enormous expense of making the plates being shared by the various publishers, the cost to each one was reduced approximately to one-tenth.

Thus, by reason of their **universal translation** and reproduction, affording international distribution, the publishers have been enabled to secure for these atlases the **best artistic and professional talent**, to produce them in the **most elegant style**, and yet to offer them at a **price heretofore unapproached in cheapness**.

Substitute for Clinical Observation

One of the most valuable features of these atlases is that they offer a **ready and satisfactory substitute for clinical observation**.

Such observation, of course, is available only to the residents in large medical centers; and even then the requisite variety is seen only after long years of routine hospital work. To those unable to attend important clinics these books will be absolutely indispensable, as presenting in a complete and convenient form the most accurate reproductions of clinical work, interpreted by the most competent of clinical teachers.

Adopted by U. S. Army

As an indication of the great practical value of the atlases and of the immense favor with which they have been received, it should be

noted that the **Medical Department of the U. S. Army** has adopted the "Atlas of Operative Surgery" as its standard, and has ordered the book in large quantities for distribution to the various regiments and army posts.

Sobotta and Huber's Human Histology

Atlas and Epitome of Human Histology. By PRIVAT-DOCENT DR. J. SOBOTTA, of Würzburg. Edited, with additions, by G. CARL HUBER, M. D., Professor of Histology and Embryology, and Director of the Histological Laboratory, University of Michigan, Ann Arbor. With 214 colored figures on 80 plates, 68 text-cuts, and 248 pages of text. Cloth, \$4.50 net.

INCLUDING MICROSCOPIC ANATOMY

This work combines an abundance of well-chosen and most accurate illustrations with a concise text, and in such a manner as to make it both atlas and text-book. The great majority of the illustrations were made from sections prepared from human tissues, and always from fresh and in every respect normal specimens. The colored lithographic plates have been produced with the aid of over thirty colors, and particular care was taken to avoid distortion and assure exactness of magnification. The text is as brief as possible; clearness, however, not being sacrificed to brevity. The editor of the English translation has annotated and altered very freely certain portions of the sections on the adenoid tissues, blood and the blood-forming organs, muscular tissues, special sense organs, and peripheral nerve distributions, in order to make these parts of the work conform to the latest advances in the study of these tissues.

OPINIONS OF THE MEDICAL PRESS

Boston Medical and Surgical Journal

"In color and proportion they are characterized by gratifying accuracy and lithographic beauty. . . . May be highly recommended to those who are without access to histological collections."

Bulletin Johns Hopkins Hospital

"A ready means of getting a good idea of the appearance of normal human tissues, hardened, sectioned, and stained. . . . The additions which the editor of the translation has made are of such value that one wishes he had used his hand more freely."

Unsurpassed for accuracy, pictorial beauty, completeness, cheapness

Grünwald and Newcomb's Mouth, Pharynx, Nose

Atlas and Epitome of Diseases of the Mouth, Pharynx, and Nose. By DR. L. GRÜNWARD, of Munich. *From the Second Revised and Enlarged German Edition.* Edited, with additions, by JAMES E. NEWCOMB, M. D., Instructor in Laryngology, Cornell University Medical School; Attending Laryngologist to the Roosevelt Hospital, Out-Patient Department. With 102 illustrations on 42 colored lithographic plates, 41 text-cuts, and 219 pages of text. Cloth, \$3.00 net.

INCLUDING ANATOMY AND PHYSIOLOGY

In designing this atlas the needs of both student and practitioner were kept constantly in mind, and as far as possible typical cases of the various diseases were selected. The illustrations are described in the text in exactly the same way as a practised examiner would demonstrate the objective findings to his class, the book thus serving as a substitute for actual clinical work. The illustrations themselves are numerous and exceedingly well executed, portraying the conditions so strikingly that their study is almost equal to examination of the actual specimens. The editor has incorporated his own valuable experience, including notes on the use of the active principle of the suprarenal bodies.

OPINIONS OF THE MEDICAL PRESS

American Medicine

"Its conciseness without sacrifice of clearness and thoroughness, as well as the excellence of text and illustration are commendable."

Journal of Ophthalmology, Otology, and Laryngology

"A collection of the most naturally colored lithographic plates that has been published in any book in the English language. . . . Very valuable alike to the student, the practitioner, and the specialist."

Each volume contains from 50 to 100 colored plates

Helferich and Bloodgood's Fractures and Dislocations

Atlas and Epitome of Traumatic Fractures and Dislocations. By PROFESSOR DR. H. HELFERICH, Professor of Surgery at the Royal University, Greifswald, Prussia. Edited, with additions, by JOSEPH C. BLOODGOOD, M. D., Associate in Surgery, Johns Hopkins University, Baltimore. *From the Fifth Revised and Enlarged German Edition.* With 216 colored illustrations on 64 lithographic plates, 190 text-cuts, and 353 pages of text. Cloth, \$3.00 net.

SHOWING DEFORMITY, X-RAY SHADOW, AND TREATMENT

This department of medicine being one in which, from lack of practical knowledge, much harm can be done, and in which in recent years great importance has obtained, a book, accurately portraying the anatomic relations of the fractured parts, together with the diagnosis and treatment of the condition, becomes an absolute necessity. This present work fully meets all requirements. As complete a view as possible of each case has been presented, thus equipping the physician for the manifold appearances that he will meet with in practice. The illustrations show the visible external deformity, the X-ray shadow, the anatomic preparation, and the method of treatment.

OPINIONS OF THE MEDICAL PRESS

Medical News, New York

"This compact and exceedingly attractive little volume will be most welcome to all who are interested in the practical application of anatomy. The author and editor have made a most successful effort to arrange the illustrations that the interpretation of what they are intended to present is exceedingly easy."

Brooklyn Medical Journal

"There are few books published that better answer the requirements for illustration than this work of Professor Helferich. . . . Such a collection of illustrations must be the result of much labor and thought."

They are Satisfactory Substitutes for Clinical Observation

Sultan and Coley's Abdominal Hernias

Atlas and Epitome of Abdominal Hernias. By PRIVAT-DOCENT DR. GEORG SULTAN, of Göttingen. Edited, with additions, by WILLIAM B. COLEY, M. D., Clinical Lecturer on Surgery, Columbia University (College of Physicians and Surgeons), New York. With 119 illustrations, 36 of them in colors, and 277 pages of text. Cloth, \$3.00 net.

DEALING WITH THE SURGICAL ASPECT

This new atlas covers one of the most important subjects in the entire domain of medical teaching, since these hernias are not only exceedingly common, but the frequent occurrence of strangulation demands extraordinarily quick and energetic surgical intervention. During the last decade the operative side of this subject has been steadily growing in importance, until now it is absolutely essential to have a book treating of its surgical aspect. This present atlas does this to an admirable degree. The illustrations are not only very numerous, but they excel, in the accuracy of the portrayal of the conditions represented, those of any other work upon abdominal hernias with which we are familiar. The work will be found a worthy exponent of our present knowledge of the subject of which it treats.

PERSONAL AND PRESS OPINIONS

Robert H. M. Dawbarn, M. D.,

Professor of Surgery and Surgical Anatomy, New York Polyclinic.

"I have spent several interested hours over it to-day, and shall willingly recommend it to my classes at the Polyclinic College and elsewhere."

Boston Medical and Surgical Journal

"For the general practitioner and the surgeon it will be a very useful book for reference. The book's value is increased by the editorial notes of Dr. Coley."

They have already appeared in thirteen different languages

Brühl, Politzer, and MacCuen Smith's Otology

Atlas and Epitome of Otology. By GUSTAV BRÜHL, M. D., of Berlin, with the collaboration of Professor DR. A. POLITZER, of Vienna. Edited, with additions, by S. MACCUEN SMITH, M. D., Clinical Professor of Otology, Jefferson Medical College, Philadelphia. With 244 colored figures on 39 lithographic plates, 99 text-illustrations, and 292 pages of text. Cloth, \$3.00 net.

INCLUDING ANATOMY AND PHYSIOLOGY

This excellent volume is the first attempt to supply in English an illustrated clinical handbook to act as a worthy substitute for personal instruction in a specialized clinic. This work is both didactic and clinical in its teaching, the latter aspect being especially adapted to the student's wants. A special feature is the very complete exposition of the minute anatomy of the ear, a working knowledge of which is so essential to an intelligent conception of the science of otology. The illustrations are beautifully executed in colors, and illuminate the text in a singularly lucid manner, portraying pathologic changes with such striking exactness that the student should receive a deeper and more lasting impression than the most elaborate description could produce. Further, the association of Professor Politzer in the preparation of the work, and the use of so many valuable specimens from his notably rich collection especially enhance the value of the work. The text contains everything of importance in the elementary study of otology.

PERSONAL AND PRESS OPINIONS

Clarence J. Blake, M. D.,

Professor of Otology, Harvard University Medical School, Boston.

"The most complete work of its kind as yet published, and one commending itself to both the student and teacher in the character and scope of its illustrations."

Boston Medical and Surgical Journal

"Contains what is probably the best collection of colored plates of the ear, both of normal and pathological conditions, of any hand-book published in the English language. In addition to this the text is presented in an unusually clear and direct manner."

They are offered at a price heretofore unapproached in cheapness

Lehmann, Neumann, and Weaver's Bacteriology

Atlas and Epitome of Bacteriology: INCLUDING A TEXT-BOOK OF SPECIAL BACTERIOLOGIC DIAGNOSIS. By PROF. DR. K. B. LEHMANN and DR. R. O. NEUMANN, of Würzburg. *From the Second Revised and Enlarged German Edition.* Edited, with additions, by G. H. WEAVER, M. D., Assistant Professor of Pathology and Bacteriology, Rush Medical College, Chicago. In two parts. Part I.—632 colored figures on 69 lithographic plates. Part II.—511 pages of text, illustrated. Per part: Cloth, \$2.50 net.

INCLUDING SPECIAL BACTERIOLOGIC DIAGNOSIS

This work furnishes a survey of the properties of bacteria, together with the causes of disease, disposition, and immunity, reference being constantly made to an appendix of bacteriologic technic. The special part gives a complete description of the important varieties, the less important ones being mentioned when worthy of notice. The lithographic plates, as in all this series, are accurate representations of the conditions as actually seen, and this collection, if anything, is more handsome than any of its predecessors. As an aid in original investigation the work is invaluable.

OPINIONS OF THE MEDICAL PRESS

American Journal of the Medical Sciences

"Practically all the important organisms are represented, and in such a variety of forms and cultures that any other atlas would rarely be needed in the ordinary hospital laboratory."

The Lancet, London

"We have found the work a more trustworthy guide for the recognition of unfamiliar species than any with which we are acquainted."

There have been 82,000 copies imported since publication

Zuckerkandl and DaCosta's Operative Surgery

Second Edition, Revised and Greatly Enlarged

Atlas and Epitome of Operative Surgery. By DR. O. ZUCKERKANDL, of Vienna. Edited, with additions, by J. CHALMERS DACOSTA, M. D., Professor of the Principles of Surgery and Clinical Surgery, Jefferson Medical College, Philadelphia. With 40 colored plates, 278 text-cuts, and 410 pages of text. Cloth, \$3.50 net.

ADOPTED BY THE U. S. ARMY

In this new edition the work has been brought precisely down to date. The revision has not been casual, but thorough and exhaustive, the entire text having been subjected to a careful scrutiny, and many improvements and additions made. A number of chapters have been practically rewritten, and of the newer operations, all those of special value have been described. The number of illustrations has also been materially increased. Sixteen valuable lithographic plates in colors and sixty-one text-figures have been added, thus greatly enhancing the value of the work. There is no doubt that the volume in its new edition will still maintain its leading position as a substitute for clinical instruction.

OPINIONS OF THE MEDICAL PRESS

Philadelphia Medical Journal

"The names of Zuckerkandl and DaCosta, the fact that the book has been translated into 13 different languages, together with the knowledge that it is used in the United States Army and Navy, would be sufficient recommendation for most of us."

Munchener Medicinische Wochenschrift

"We know of no other work that combines such a wealth of beautiful illustrations with clearness and conciseness of language, that is so entirely abreast of the latest achievements, and so useful both for the beginner and for one who wishes to increase his knowledge of operative surgery."

Each volume is edited, with additions, by a leading specialist

Dürck and Hektoen's Special Pathologic Histology

Atlas and Epitome of Special Pathologic Histology.

By DR. H. DÜRCK, of Munich. Edited, with additions, by LUDVIG HEKTOEN, M. D., Professor of Pathology, Rush Medical College, Chicago. In Two Parts. Part I.—Circulatory, Respiratory, and Gastro-intestinal Tracts. 120 colored figures on 62 plates, and 158 pages of text. Part II.—Liver, Urinary and Sexual Organs, Nervous System, Skin, Muscles, and Bones. 123 colored figures on 60 plates, and 192 pages of text. Per part: Cloth, \$3.00 net.

A RARE COLLECTION OF BEAUTIFUL PLATES

The colored lithographs of this volume are beautifully reproduced, and are extremely accurate representations of the microscopic changes produced by disease. The great value of these plates is that they represent in the exact colors the effect of the stains, which is of such great importance for the differentiation of tissue. The text portion of the book is admirable, and, while brief, it is entirely satisfactory in that the leading facts are stated, and so stated that the reader feels he has grasped the subject extensively. The work is modern and scientific, and altogether forms a concise and systematic view of pathologic knowledge.

PERSONAL OPINIONS

William H. Welch, M. D.,

Professor of Pathology, Johns Hopkins University, Baltimore.

"I consider Dürck's 'Atlas of Special Pathologic Histology,' edited by Hektoen, a very useful book for students and others. The plates are admirable."

Frank B. Mallory, M. D.,

Assistant Professor of Pathology, Harvard University Medical School, Boston.

"The information is presented in a very compact form; it is carefully arranged, briefly and clearly stated, and almost always represents our latest knowledge of the subject."

They represent the best artistic and professional talent

Haab and deSchweinitz's Ophthalmoscopy

Atlas and Epitome of Ophthalmoscopy and Ophthalmoscopic Diagnosis. By DR. O. HAAB, of Zürich. *From the Third Revised and Enlarged German Edition.* Edited, with additions, by G. E. DESCHWEINITZ, M. D., Professor of Ophthalmology, University of Pennsylvania. With 152 colored lithographic illustrations; 85 pages of text. Cloth, \$3.00 net.

Not only is the student made acquainted with carefully prepared ophthalmoscopic drawings done into well-executed lithographs of the most important fundus changes, but, in many instances, plates of the microscopic lesions are added. It furnishes a manual of the greatest possible service.

The Lancet, London

"We recommend it as a work that should be in the ophthalmic wards or in the library of every hospital into which ophthalmic cases are received."

Haab and deSchweinitz's External Diseases of Eye

Atlas and Epitome of External Diseases of the Eye. By DR. O. HAAB, of Zürich. Edited, with additions, by G. E. DESCHWEINITZ, M. D., Professor of Ophthalmology, University of Pennsylvania. 88 colored illustrations on 48 lithographic plates and 232 pages of text. Cloth, \$3.00 net.

SECOND REVISED EDITION—JUST ISSUED.

In this thorough revision the text has been brought up to date by the addition of new matter, including references to some of the modern therapeutic agents. There have also been added eight chromolithographic plates.

The Medical Record, New York

"The work is excellently suited to the student of ophthalmology and to the practising physician. It cannot fail to attain a well-deserved popularity." (Review of previous ed.)

They are convenient in size and uniformly bound

Schäffer and Edgar's Labor and Operative Obstetrics

Atlas and Epitome of Labor and Operative Obstetrics.
By DR. O. SCHÄFFER, of Heidelberg. *From the Fifth Revised and Enlarged German Edition.* Edited, with additions, by J. CLIFTON EDGAR, M. D., Professor of Obstetrics and Clinical Midwifery, Cornell University Medical School. 14 lithographic plates in colors; 139 other cuts; 111 pages of text. \$2.00 net.

The book presents the act of parturition and the various obstetric operations in a series of easily understood illustrations. These are accompanied by a text that treats the subject from a practical standpoint.

Dublin Journal of Medical Science, Dublin

"One fault Professor Schäffer's Atlases possess. Their name, and the extent and number of the illustrations, are apt to lead one to suppose that they are merely 'atlases,' whereas the truth really is they are also concise and modern epitomes of obstetrics."

Schäffer & Edgar's Obstetric Diagnosis and Treatment

Atlas and Epitome of Obstetric Diagnosis and Treatment. By DR. O. SCHÄFFER, of Heidelberg. *From the Second Revised German Edition.* Edited, with additions, by J. CLIFTON EDGAR, M. D., Professor of Obstetrics and Clinical Midwifery, Cornell University Medical School. 122 colored figures on 56 plates; 38 other cuts; 315 pages of text. \$3.00 net.

This book treats particularly of obstetric operations, and, besides the wealth of beautiful lithographic illustrations, contains an extensive text of great value. This text deals with the practical, clinical side of the subject.

New York Medical Journal

"The illustrations are admirably executed, as they are in all of these atlases, and the text can safely be commended, not only as elucidatory of the plates, but as expounding the scientific midwifery of to-day."

These are the famous "Lehmann medicinische Handatlanten"

Mracek and Stelwagon's Skin

Atlas and Epitome of Diseases of the Skin. By PROF. DR. FRANZ MRACEK, of Vienna. Edited, with additions, by HENRY W. STELWAGON, M. D., Clinical Professor of Dermatology, Jefferson Medical College, Philadelphia. With 63 colored plates, 39 half-tone illustrations, and 200 pages of text. Cloth, \$3.50 net.

This volume, the outcome of years of scientific and artistic work, contains, together with colored plates of unusual beauty, numerous illustrations in black, and a text comprehending the entire field of dermatology. The illustrations are all original and prepared from actual cases in Mracek's clinic.

American Journal of the Medical Sciences

"The advantages which we see in this book and which recommend it to our minds are: First, its handiness; secondly, the plates, which are excellent as regards drawing, color, and the diagnostic points which they bring out. We most heartily recommend it."

Mracek and Bang's Syphilis and Venereal Diseases

Atlas and Epitome of Syphilis and the Venereal Diseases. By PROF. DR. FRANZ MRACEK, of Vienna. Edited, with additions, by L. BOLTON BANGS, M. D., late Prof. of Genito-Urinary Surgery, University and Bellevue Hospital Medical College, New York. With 71 colored plates and 122 pages of text. Cloth, \$3.50 net.

According to the unanimous opinion of numerous authorities, to whom the original illustrations of this book were presented, they surpass in beauty anything of the kind that has been produced in this field, not only in Germany, but throughout the literature of the world.

Robert L. Dickinson, M. D.,

Art Editor of "The American Text-Book of Obstetrics."

"The book that appeals instantly to me for the strikingly successful, valuable, and graphic character of its illustrations is the 'Atlas of Syphilis and the Venereal Diseases.' I know of nothing in this country that can compare with it."

The lithographs, all made in Germany, are unrivalled

Schäffer and Webster's Operative Gynecology

Atlas and Epitome of Operative Gynecology. By DR. O. SCHÄFFER, of Heidelberg. Edited, with additions, by J. CLARENCE WEBSTER, M. D. (EDIN.), F. R. C. P. E., Professor of Obstetrics and Gynecology in the Rush Medical College, in affiliation with the University of Chicago. With 42 lithographic plates in colors, many text-cuts, a number in colors, and 138 pages of text. Cloth, \$3.00 net.

JUST ISSUED

The excellence of the lithographic plates and the many other illustrations in this atlas render it of the greatest value in obtaining a sound and practical knowledge of operative gynecology. Indeed, the artist, the author, and the lithographer have expended much patient endeavor in the preparation of the water-colors and drawings. They are based on hundreds of photographs taken from nature, and they reproduce faithfully and instructively the various situations. The text closely follows the illustrations, and is fully as accurate.

Shäffer and Norris' Gynecology

Atlas and Epitome of Gynecology. By DR. O. SHAFFER, of Heidelberg. *From the Second Revised and Enlarged German Edition.* Edited, with additions, by RICHARD C. NORRIS, A. M., M. D., Gynecologist to Methodist-Episcopal and Philadelphia Hospitals. With 207 colored figures on 90 plates, 65 text-cuts, and 308 pages of text. Cloth, \$3.50 net.

The value of this atlas will be found not only in the concise explanatory text, but especially in the illustrations. The large number of colored plates, reproducing the appearance of fresh specimens, will give the student a knowledge of the changes induced by disease that cannot be obtained from mere description.

Bulletin of Johns Hopkins Hospital, Baltimore

"The book contains much valuable material. Rarely have we seen such a valuable collection of gynecological plates."

These books are next best to actual clinical work

Jakob and Eshner's Internal Medicine & Diagnosis

Atlas and Epitome of Internal Medicine and Clinical Diagnosis. By DR. CHR. JAKOB, of Erlangen. Edited, with additions, by AUGUSTUS A. ESHNER, M. D., Professor of Clinical Medicine in the Philadelphia Polyclinic. With 182 colored figures on 68 plates, 64 illustrations in black and white, and 259 pages of text. Cloth, \$3.00 net.

In addition to an admirable atlas of clinical microscopy, this volume describes the physical signs of all internal diseases in an instructive manner by means of fifty colored schematic diagrams. As a means of instruction its value is very great; as a reference handbook it is admirable.

British Medical Journal

"Dr. Jakob's work deserves nothing but praise. The information is accurate and up to present-day requirements."

Grünwald and Grayson's Diseases of the Larynx

Atlas and Epitome of Diseases of the Larynx. By DR. L. GRÜNWARD, of Munich. Edited, with additions, by CHARLES P. GRAYSON, M. D., Physician-in-Charge, Throat and Nose Department, Hospital of the University of Pennsylvania. With 107 colored figures on 44 plates, 25 text-illustrations, and 103 pages of text. Cloth, \$2.50 net.

This atlas exemplifies a happy blending of the didactic and clinical, such as is not to be found in any other volume upon this subject. The author has given special attention to the clinical portion of the work, the sections on diagnosis and treatment being particularly full.

The Medical Record, New York

"This is a good work of reference, being both practical and concise. . . . It is a valuable addition to existing laryngeal text-books."

For "Special Offer" regarding these atlases see page I

Hofmann and Peterson's Legal Medicine

Atlas of Legal Medicine. By DR. E. VON HOFMANN, of Vienna. Edited by FREDERICK PETERSON, M. D., Professor of Psychiatry, College of Physicians and Surgeons, N. Y. 120 colored figures on 56 plates, 193 half-tone illustrations. Cloth, \$3.50 net.

The Practitioner, London

"The illustrations appear to be the best that have ever been published in connection with this department of medicine, and they cannot fail to be useful alike to the medical jurist and to the student of forensic medicine."

Jakob and Fisher's Nervous System and its Diseases

Atlas and Epitome of the Nervous System and its Diseases. By PROF. DR. CHR. JAKOB, of Erlangen. *From the Second Revised German Edition.* Edited, with additions, by EDWARD D. FISHER, M. D., Professor of Diseases of the Nervous System, University and Bellevue Hospital Medical College, N. Y. 83 plates and copious text. Cloth, \$3.50 net.

Philadelphia Medical Journal

"We know of no one work of anything like equal size which covers this important and complicated field with the clearness and scientific fidelity of this hand-atlas."


Golebiewski and Bailey's Accident Diseases

Atlas and Epitome of Diseases Caused by Accidents. By DR. ED. GOLEBIEWSKI, of Berlin. Edited, with additions, by PEARCE BAILEY, M. D., Consulting Neurologist to St. Luke's Hospital and Orthopedic Hospital, N. Y. 71 colored illustrations on 40 plates, 143 text-cuts, 549 pages of text. Cloth, \$4.00 net.

Medical Examiner and Practitioner

"It is a useful addition to life-insurance libraries, for lawyers, physicians, and for every one who is brought in contact with the treatment or consideration of accidents or diseases growing out of them, or legal complications flowing from them."

The "Atlas of Operative Surgery" has been adopted by U. S. Army



SAUNDERS' MEDICAL HAND-ATLASES

Atlas and Epitome of External Diseases of the Eye. By DR. O. HAAB, of Zurich. Edited, with additions, by G. E. DE SCHWEINITZ, M.D., Professor of Ophthalmology in the University of Pennsylvania. *Second Revised Edition.* With 98 colored illustrations on 48 plates and 232 pages of text. Cloth, \$3.00 net.

"The work is well done, and is valuable to physicians in general, as well as to ophthalmologists. I shall take pleasure in recommending it."—JOHN E. WEEKS, M.D., *Clinical Professor of Ophthalmology, University of Bellevue Hospital Medical School, N. Y.*

Atlas and Epitome of Internal Medicine and Clinical Diagnosis. By DR. CHR. JAKOB, of Erlangen. Edited, with additions, by AUGUSTUS A. ESHNER, M.D., Professor of Clinical Medicine in the Philadelphia Polyclinic. With 179 colored figures on 68 plates and 259 pages of text. Cloth, \$3.00 net.

"Dr. Jakob's work deserves nothing but praise. The information is accurate and up to present-day requirements."—*British Medical Journal.*

Atlas of Legal Medicine. By DR. E. VON HOFMANN, of Vienna. Edited, with additions, by FREDERICK PETERSON, M.D., Professor of Psychiatry, College of Physicians and Surgeons, New York. With 120 colored figures on 56 plates and 193 half-tone illustrations. Cloth, \$3.50 net.

"It is rare indeed that so large a series of illustrations are found which demonstrate so well and so accurately the conditions which they are supposed to represent."—*Boston Medical and Surgical Journal*

Atlas and Epitome of Diseases of the Larynx. By DR. L. GRUNWALD, of Munich. Edited, with additions, by CHARLES P. GRAYSON, M.D., Physician-in-Charge, Throat and Nose Department, Hospital of the University of Pennsylvania. With 107 colored figures on 44 plates, 25 text-illustrations, and 103 pages of text. Cloth, \$2.50 net.

"Excels everything we have hitherto seen in the way of colored illustrations of diseases of the larynx."—*British Medical Journal.*

Atlas and Epitome of Operative Surgery. By DR. O. ZUCKERKANDL, of Vienna. *From the Second Revised and Enlarged German Edition.* Edited, with additions, by J. CHALMERS DACOSTA, M.D., Professor of the Principles of Surgery and of Clinical Surgery, Jefferson Medical College, Philadelphia. *Second Edition, Revised and Greatly Enlarged.* With 40 colored plates, 278 text-cuts, and 410 pages of text. Cloth, \$3.50 net.

"It may be said that few, if any, books of this description are so comprehensive in their scope."—*Philadelphia Medical Journal.*

Atlas and Epitome of Syphilis and the Venereal Diseases. By PROF. DR. FRANZ MRACEK, of Vienna. Edited, with additions, by L. BOLTON BANGS, M.D., late Professor of Genito-Urinary Surgery, University and Bellevue Hospital Medical College, New York. With 71 colored plates and 122 pages of text. Cloth, \$3.50 net.

"A glance through the book is almost like actual attendance upon a famous clinic."—*Journal of the American Medical Association.*

Atlas and Epitome of Skin Diseases. By PROF. DR. FRANZ MRACEK, of Vienna. Edited, with additions, by HENRY W. STELWAGON, M.D., Clinical Professor of Dermatology, Jefferson Medical College, Philadelphia. With 63 colored plates, 39 half-tone illustrations, and 200 pages of text. Cloth, \$3.50 net.

"The illustrations are very well executed, and the coloring remarkably accurate; they will serve as substitutes for clinical observation."—*Medical Record, New York.*

Atlas of Bacteriology and Text-Book of Special Bacteriologic Diagnosis. By PROF. DR. K. B. LEHMANN and DR. R. O. NEUMANN, of Würzburg. *From the Second Revised and Enlarged German Edition.* Edited, with additions, by G. H. WEAVER, M.D., Assistant Professor of Pathology and Bacteriology, Rush Medical College, Chicago. Two volumes. Part I.—632 colored figures on 69 plates. Part II.—511 pages of text, illustrated. Per volume: Cloth, \$2.50 net.

"The illustrations . . . are works of art; they are true in color and relationship and are much superior to the usual photographic reproductions."—*Buffalo Medical Journal.*

Atlas and Epitome of Special Pathologic Histology.—

By DR. H. DURCK, of Munich. Edited, with additions, by LUDVIG HEKTOEN, M.D., Professor of Pathology, Rush Medical College, Chicago. In Two Parts. Part I.—Circulatory, Respiratory, and Gastro-intestinal Tracts. Part II.—Liver, Urinary and Sexual Organs, Nervous System, Skin, Muscles, and Bones. With 243 colored figures on 122 Plates, and 350 pages of text. Per part: \$3.50 net.

"The work maintains the high standard of its predecessors. The plates are most beautifully reproduced and are accurate representations of the microscopic structure of the various organs concerned and the changes produced by disease."—*The Lancet*, London.

Atlas and Epitome of Diseases Caused by Accidents.

By DR. ED. GOLEBIEWSKI, of Berlin. Translated and edited, with additions, by PEARCE BAILEY, M.D., Consulting Neurologist to St. Luke's Hospital, New York. With 71 colored figures on 40 plates; 143 text-illustrations; 549 pages of text. Cloth, \$4.00 net.

"This volume appeals not only to the medical student and the practitioner, but to the medico-legal specialist and accident insurance companies also."—*New York Medical Journal*.

Atlas and Epitome of Gynecology.

By DR. O. SCHAFFER, of Heidelberg. *From the Second Revised and Enlarged German Edition.* Edited, with additions, by RICHARD C. NORRIS, A.M., M.D., Lecturer on Clinical and Operative Obstetrics, University of Pennsylvania. With 207 colored illustrations on 90 plates, 65 text-illustrations, and 308 pages of text. \$3.50 net.

"The book contains much valuable material. . . . Rarely have we seen such a valuable collection of gynecological plates."—*Bulletin of Johns Hopkins Hospital*.

Atlas and Epitome of Labor and Operative Obstetrics.

By DR. O. SCHAFFER, of Heidelberg. *From the Fifth Revised and Enlarged German Edition.* Edited by J. C. EDGAR, M.D., Professor of Obstetrics and Clinical Midwifery, Cornell University Medical School. With 14 lithographic plates in colors, 139 other illustrations. \$2.00 net.

"A careful study of the plates and drawings is the next best thing to actual clinical experience."—*Buffalo Medical Journal*.

Atlas and Epitome of Obstetrical Diagnosis and Treatment.

By DR. O. SCHAFFER, of Heidelberg. *From the Second Revised and Enlarged German Edition.* Edited, with additions, by J. C. EDGAR, M.D., Professor of Obstetrics and Clinical Midwifery, Cornell University Medical School. With 122 colored figures on 56 plates, 38 other illustrations, and 315 pages of text. Cloth, \$3.00 net.

"The illustrations are admirably executed . . . and the text expounds the scientific midwifery of to-day."—*New York Medical Journal*.

Atlas and Epitome of the Nervous System and its Diseases.

By PROF. DR. CHR. JAKOB, of Erlangen. *From the Second Revised and Enlarged German Edition.* Edited, with additions, by E. D. FISHER, M.D., Professor of Diseases of the Nervous System, University and Bellevue Hospital Medical College, New York. 83 plates; 215 pages of text. \$3.50 net.

"Represents with wonderful accuracy the macroscopic and microscopic anatomy of the nervous tissues as found in normal and pathologic conditions."—*American Medicine*.

Atlas and Epitome of Ophthalmoscopy and Ophthalmoscopic Diagnosis.

By DR. O. HAAB, of Zurich. *From the Third Revised and Enlarged German Edition.* Edited, with additions, by G. E. DE SCHWEINITZ, M.D., Professor of Ophthalmology in the University of Pennsylvania. With 152 colored figures; 82 pages of text. Cloth, \$3.00 net.

"Nowhere else can be found such a fine pictorial collection of changes and lesions of the eye-fundus as this volume contains."—*Journal of the American Medical Association*.

SAUNDERS' MEDICAL HAND-ATLASES

Atlas and Epitome of Otology. By G. BRUHL, M.D., of Berlin, with the collaboration of PROF. DR. A. POLITZER, of Vienna. Edited, with additions, by S. MACCUEEN SMITH, M.D., Clinical Professor of Otology, Jefferson Medical College, Philadelphia. 244 colored figures on 39 lithographic plates, 99 text-cuts, and 292 pages of text. Cloth, \$3.00 net.

"The most complete of its kind as yet published."—CLARENCE J. BLAKE, M.D., *Professor of Otology, Harvard Medical School, Boston.*

Atlas and Epitome of Abdominal Hernias. By PRIVATDOCENT DR. GEORG SULTAN, of Göttingen. Edited, with additions, by WILLIAM B. COLEY, M.D., Clinical Lecturer on Surgery, Columbia University, N. Y. 119 illustrations, 36 in colors; 277 pages of text.

Cloth, \$3.00 net.

"For the general practitioner and the surgeon it will be a very useful book for reference. The book's value is increased by the editorial notes of Dr. Coley."—*Boston Medical and Surgical Journal.*

Atlas and Epitome of Traumatic Fractures and Dislocations. By PROF. DR. H. HELFERICH, of Greifswald. Edited, with additions, by JOSEPH C. BLOODGOOD, M.D., Associate in Surgery, Johns Hopkins University, Baltimore. With 216 colored figures on 64 lithographic plates, 190 text-cuts, and 353 pages of text. Cloth, \$3.00 net.

"The author has given the anatomy of fractures his special attention. . . . It is this feature of the work which gives it special value."—*University of Pennsylvania Medical Bulletin.*

Atlas and Epitome of Diseases of the Mouth, Pharynx, and Nose. By DR. L. GRÜNWALD, of Munich. *From the Second Revised and Enlarged German Edition.* Edited, with additions, by JAMES E. NEWCOMB, M.D., Clinical Instructor in Laryngology, Cornell University Medical School. With 102 colored figures on 42 lithographic plates, 41 text-cuts, and 219 pages of text. Cloth, \$3.00 net.

"A distinct and valuable addition to the armamentarium of the worker in rhinologic fields."—*American Medicine.*

Atlas and Epitome of Human Histology and Microscopic Anatomy. By PR. DR. J. SOBOTTA, of Würzburg. Edited, with additions, by G. CARL HUBER, M.D., Professor of Histology and Embryology, University of Michigan, Ann Arbor. With 214 colored figures on 80 plates, 68 text-cuts, and 248 pages of text. Cloth, \$4.50 net.

"The 200 or more colored plates are, above all things, natural, and just as one would see them under the microscope."—*Indian Lancet, India.*

Atlas and Epitome of Operative Gynecology. By DR. O. SCHAFER, of Heidelberg. Edited, with additions, by J. CLARENCE WEBSTER, M.D. (EDIN.), F.R.C.P.E., Professor of Obstetrics and Gynecology, Rush Medical College, in affiliation with the University of Chicago. With 43 colored figures on 42 lithographic plates, 21 text figures, many in colors, and 138 pages of text. \$3.00 net. *Just issued.*

Atlas and Epitome of General Pathologic Histology. By PR. DR. HERMANN DURCK, of Munich. Edited, with additions, by LUDVIG HEKTOEN, M.D., Professor of Pathology, Rush Medical College, in affiliation with the University of Chicago. With 172 colored figures on 77 lithographic plates, 36 text-figures, many in colors, and about 450 pages of text. *Ready Shortly.*

W. B. SAUNDERS AND COMPANY

Philadelphia

New York

London

